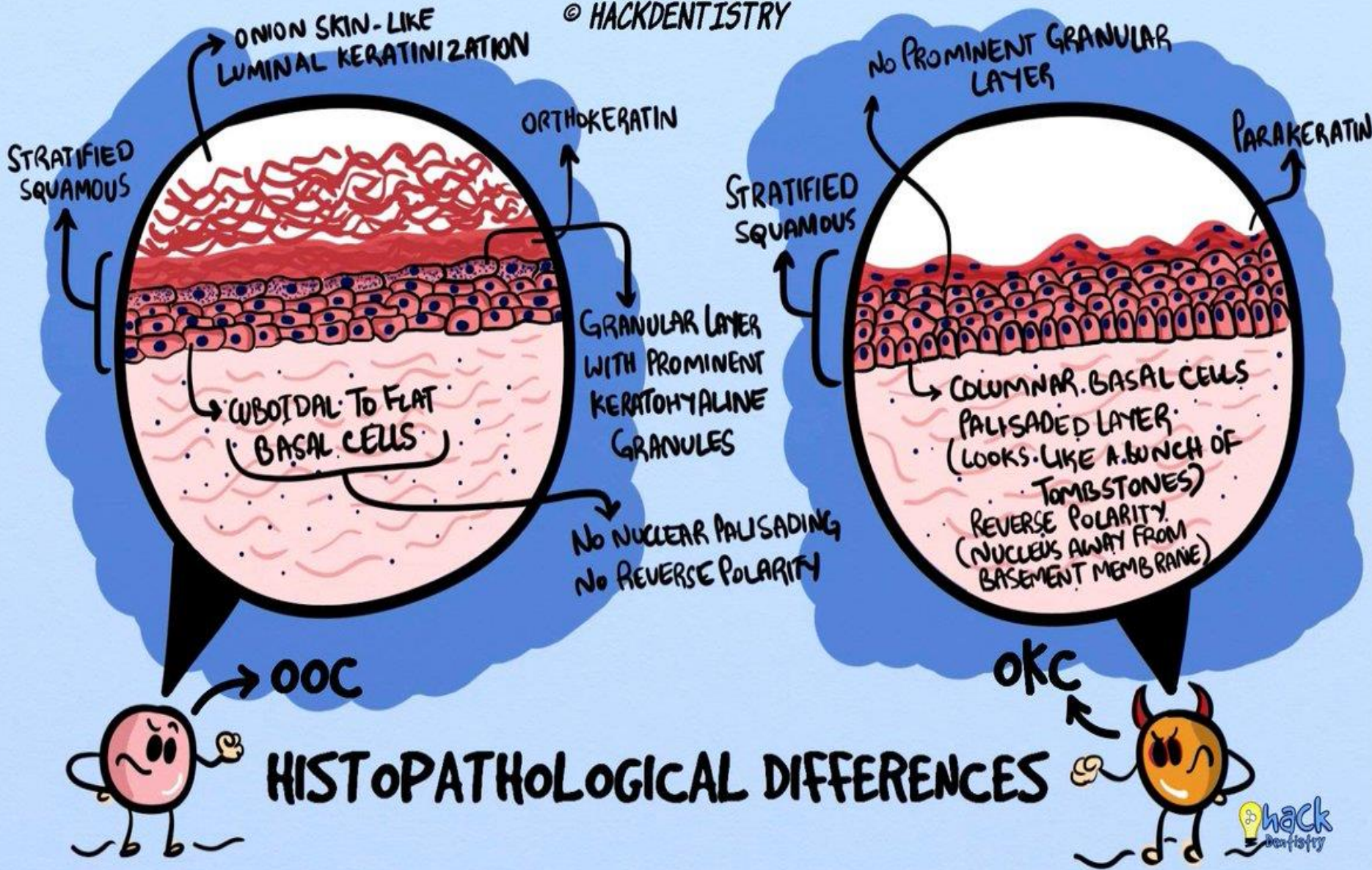


© HACKDENTISTRY



Odontogenic cysts of inflammatory origin. Odontogenic and non-odontogenic developmental cysts. Pathology of the temporo-mandibular joint.

Odontogenic cysts of inflammatory origin. Odontogenic and non-odontogenic developmental cysts. Pathology of the temporo-mandibular joint.

Microprepareate:

№ OP2. Radicular cyst (periapical). (*H-E stain.*)

Indications:

1. Luminal surface of the cyst lined by stratified squamous epithelium.
2. Cyst wall with chronic inflammatory infiltration.
3. Cholesterol crystals in the cyst wall.

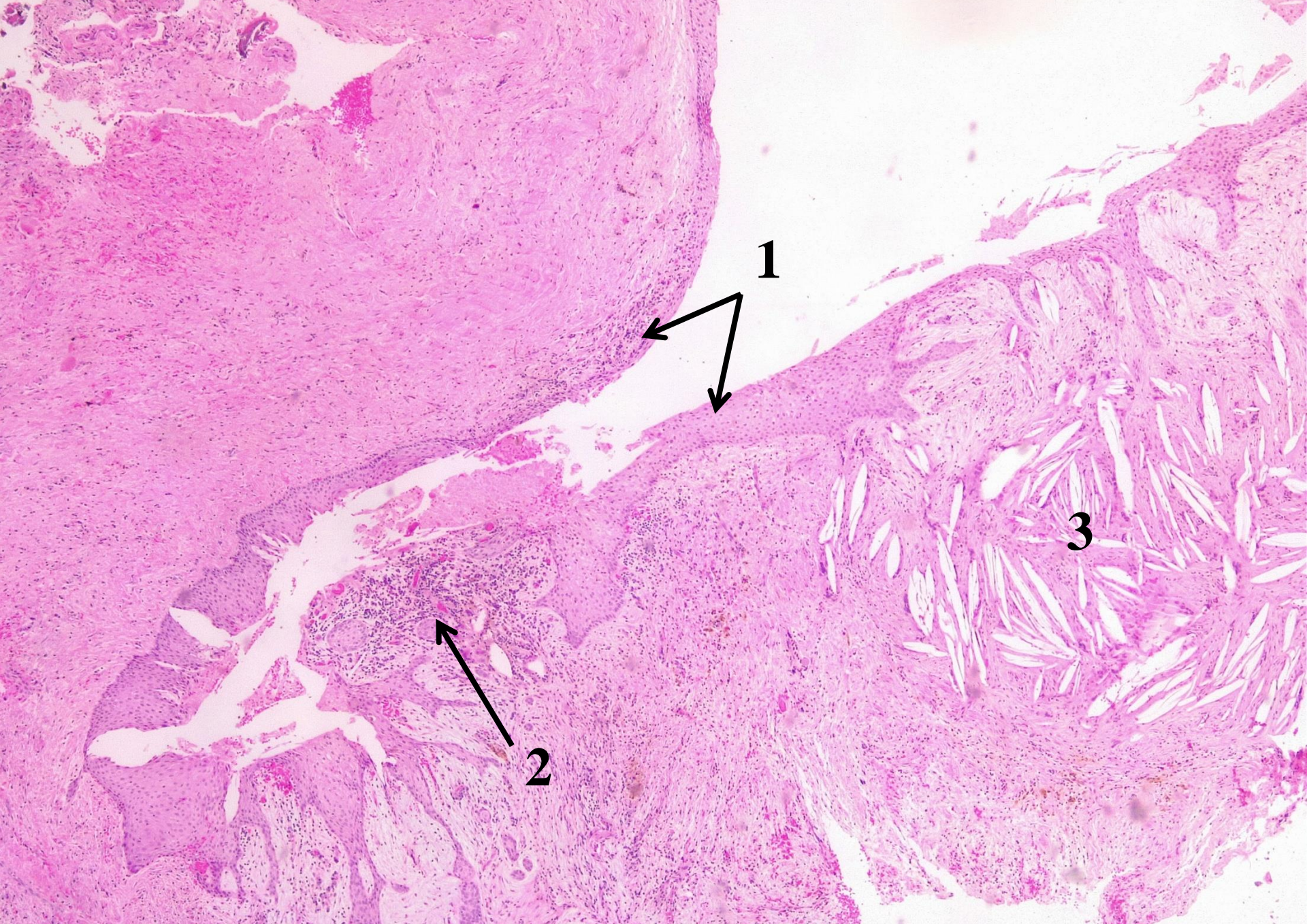
Microscopically, the cavity of radicular cyst is delimited by a stratified squamous non-keratinized epithelium, containing an eosinophilic material, with desquamated epithelial cells, and chronic inflammatory infiltrate, associated with erythrocytes, foamy macrophages, and deposits of cholesterol crystals.

Macroscopically, is composed of a fibrous wall, of variable thickness, inside containing necrotic material, with deposits of lipids or cholesterol..

It is the most common form of odontogenic cyst, is interest any gangrenous tooth and can appear at any age. The cyst is formed as a result of pulpitis or periapical infectious process, which includes epithelial remnants at this level. As a result of the inflammatory process, the epithelial rests of Malassez included in the granuloma transform cystically, appearing as a cavity that inserts around the root ends of the respective tooth.. Radiologically, there is a radiotransparent area, unilocular, usually larger than 5mm. in diameter, which is at the apex of the tooth, in continuation of the periodontal space.

Odontogenic cysts represent cystic formations, in which the formation mechanism involves the dental lamina, the enamel organ and epithelial rests of Malassez. Activation and proliferation of epithelial cells is initiated under the influence of insufficiently known stimuli, but there is also a predisposition of the patient. The mechanism of growth of the cyst is explained by the fact that the colloid-osmotic pressure inside the cyst is higher, which causes the accumulation of fluid and impairs the hydrostatic expansion. Slow and progressive, the resorption of the surrounding bone occurs. Clinically, these cysts have a latency period (they are asymptomatic) and are accidentally discovered on the dental x-ray. If, after dental extractions or endodontic treatments through the alveolus and the root canal, a sero-citrine fluid is drained, the presence of the cyst may be intuited. During the period of externalization, there is a deformation in the direction in which the cyst meets the lowest resistance, the most common vestibular or palatine.

In the case of the maxilla, it can evaluate to the sinus by partially or completely occupying the sinus. As the exteriorizing of compact layer of the bone becomes more and more bulging, it becomes thinner, giving the sensation of a "broken eggshell" and after the complete resorption of the bone fluctuation is perceived.



№ OP2. Radicular cyst (periapical). (H-E stain.)

No OP 42. Dentigerous cyst (follicular). (H-E stain.)

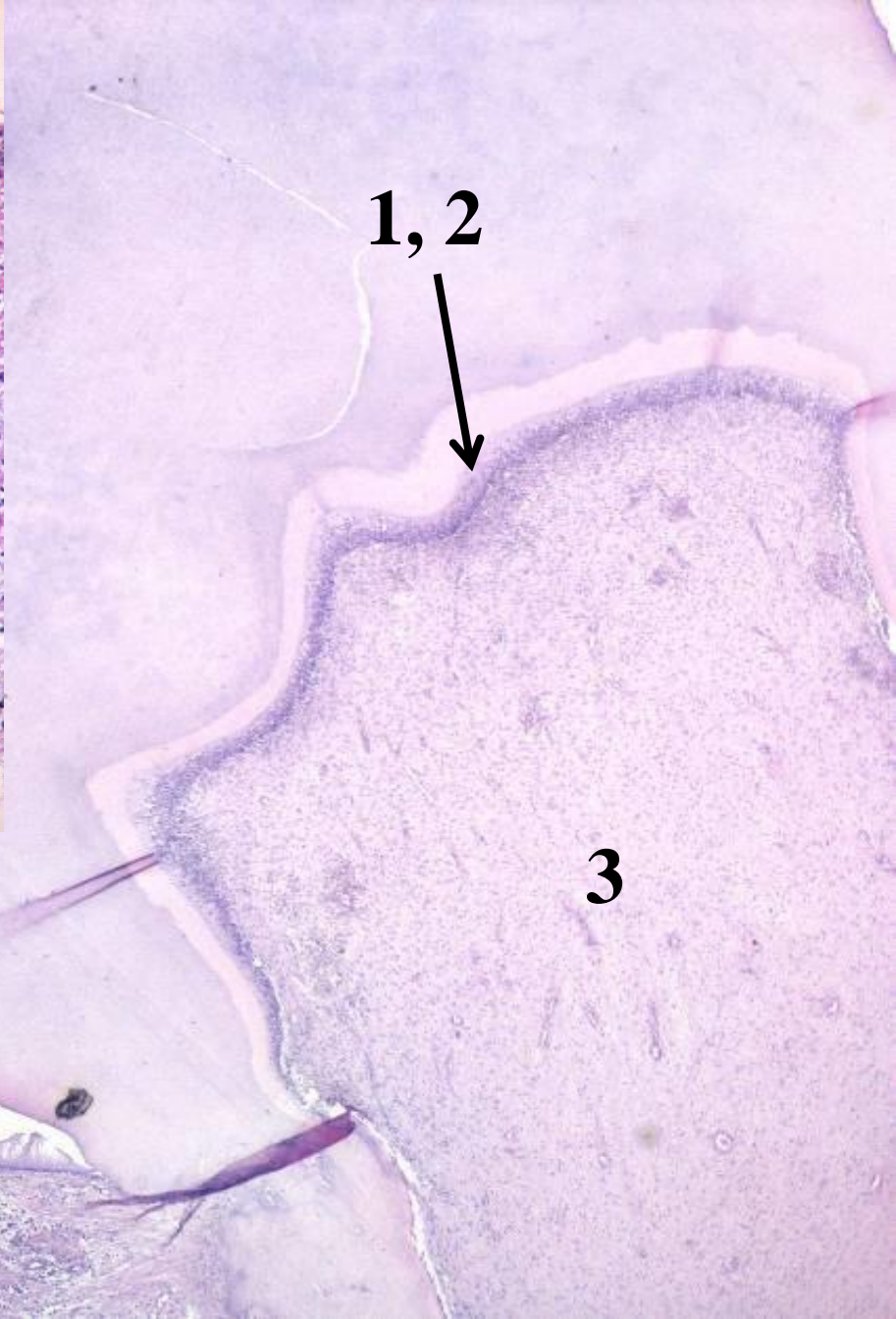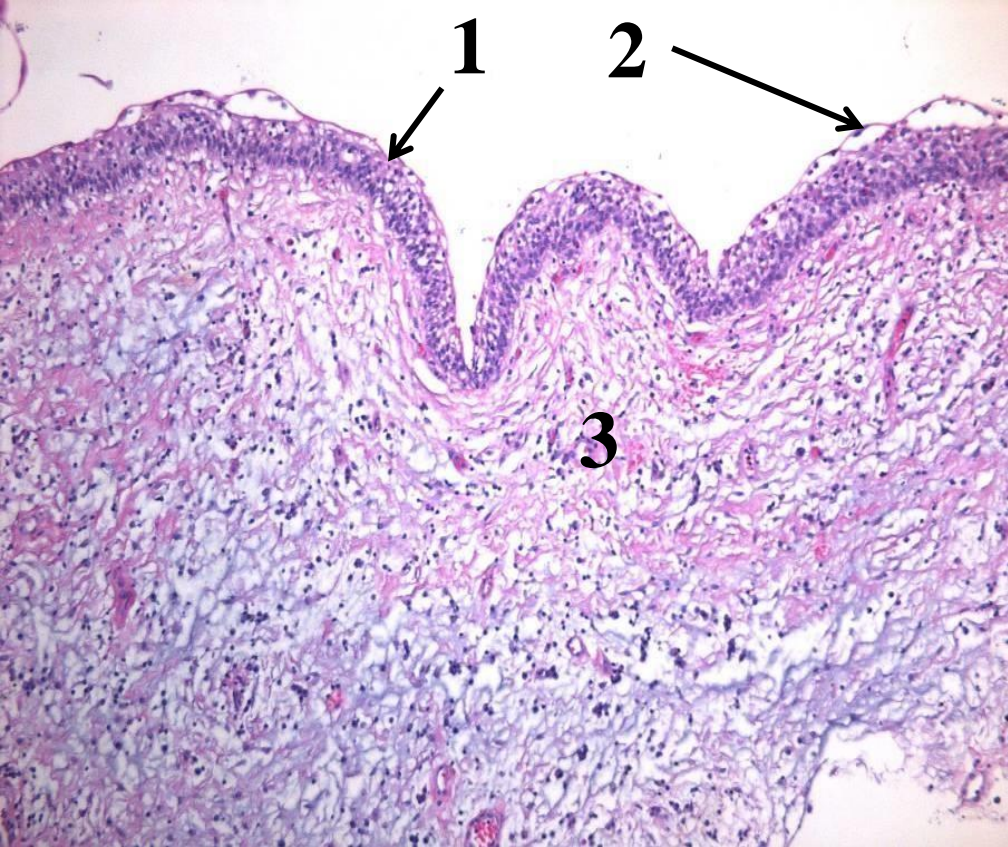
Indications:

1. Luminal surface of the cyst lined by stratified squamous epithelium.
2. Mucinous metaplasia of the epithelium.
3. Wall of the cyst represented by connective tissue with myxomatosis.

Microscopically, the cavity contains a eosinophilic material, with desquamated epithelial cells, delimited by squamous non-keratinized epithelium, flat or stratified, and surrounded by a connective tissue capsule. Inflammatory reaction is usually absent.

Macroscopically, the cystic cavity is round, contains liquid inside, has a smooth wall and is inserted on the tooth's neck, the crown protrudes into the cyst cavity. It has much larger dimensions than the radicular one.

Follicular cyst represents a cystic cavity that develops from the reduced enamel epithelium, which persists on the surface of the crown being in connection with an included tooth. In relation to the teeth, the dentigerous cyst of the lower lower wisdom molar is the most frequent, evolving in the angle of the mandible and ascending branch. Next in frequency is the lower canine dentigerous cyst, which is smaller in size. The cystic formation surrounds the crown of a temporary or permanent unerupted tooth.



№ OP 42. Dentigerous cyst (follicular). (H-E stain.)

No OP 3. Lateral periodontal cyst. (H-E stain.)

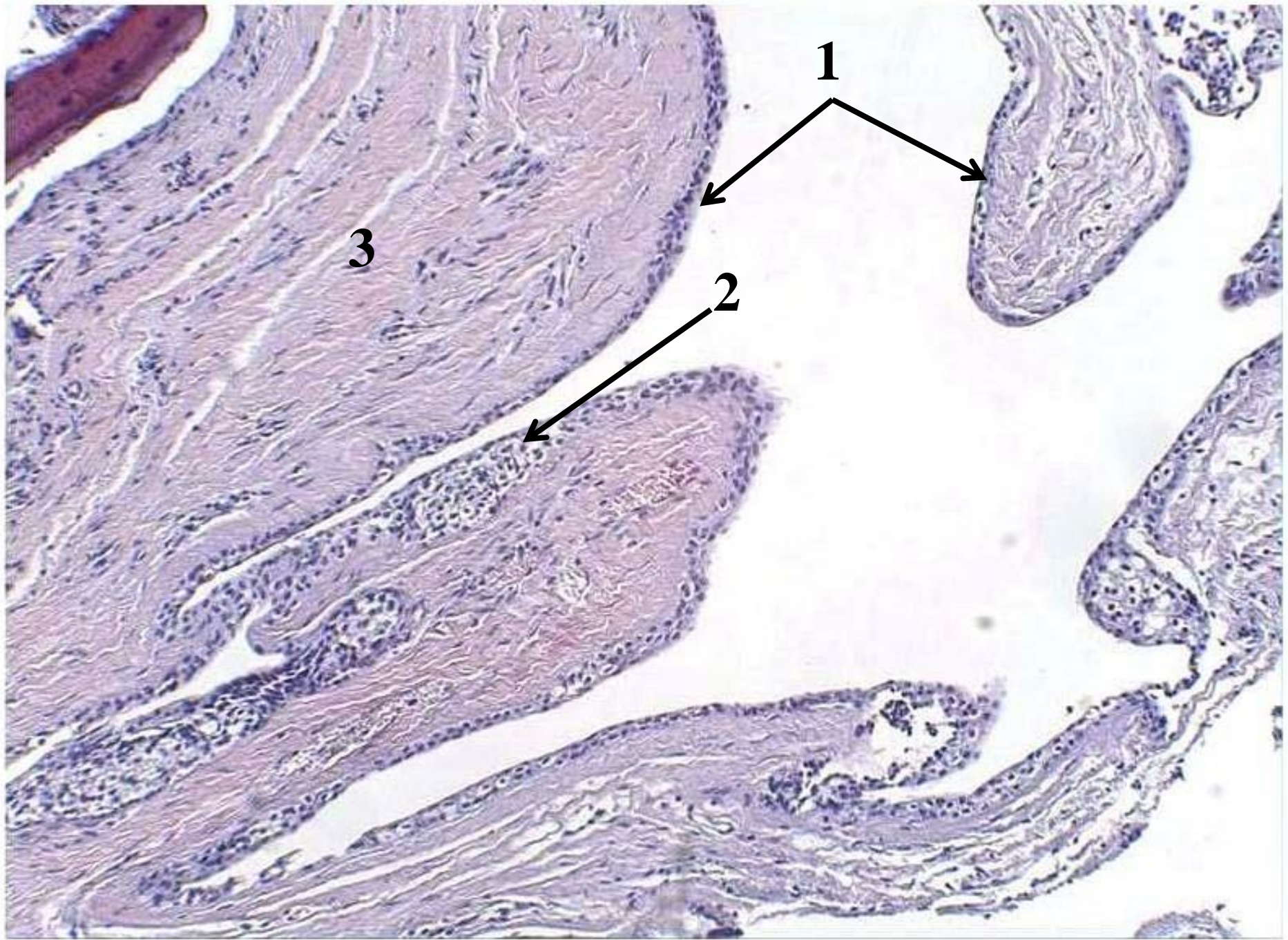
Indications:

1. Luminal surface of the cyst lined by stratified squamous epithelium.
2. Focal nodular thickening of the epithelium.
3. Wall of the cyst represented by connective tissue.

Microscopically, the cavity of the lateral periodontal cyst is delimited by a stratified squamous non-keratinized epithelium and is not associated with an inflammatory process.

Macroscopically, it is small, well defined and is teardrop-shaped.

It represents a cyst located laterally from the root of the vital teeth, which is formed by the cystic degeneration of the epithelial rests of the periodontium. Most often it forms on the distal face of the lower third molar.



№ OP 3. Lateral periodontal cyst. (H-E stain.)

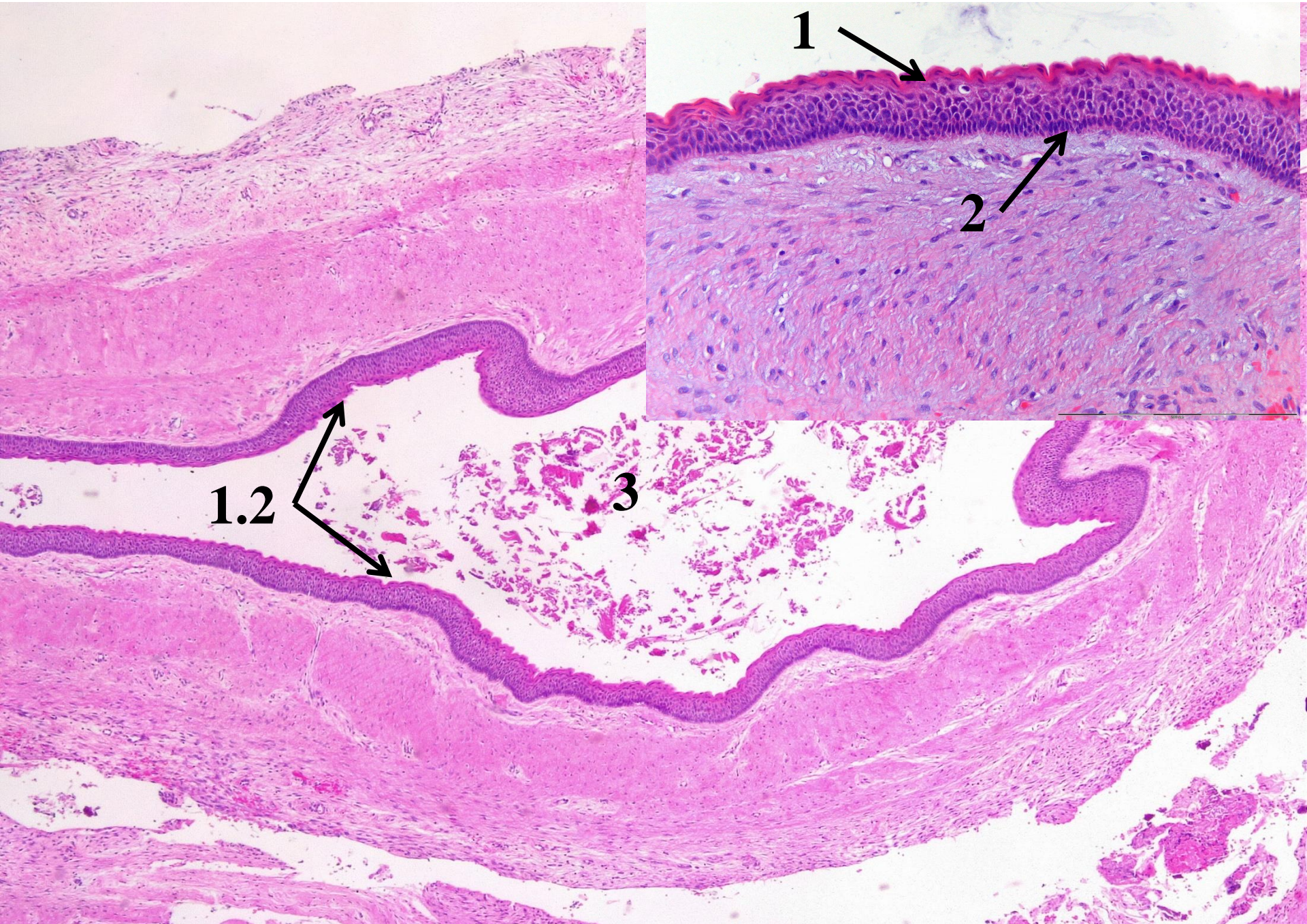
No OP4. Odontogenic keratocyst. (H-E stain.)

Indications:

1. Luminal surface of the cyst lined by parakeratinized stratified squamous epithelium.
2. Palisaded basal layer consisting of columnar or cuboidal cells.
3. Keratin debris in the cyst lumen.

Microscopically, the cyst cavity is lined by a parakeratinized stratified squamous epithelium, the basal layer of the epithelium is palisaded with columnar or cuboid cells and delimited by a capsule whose thickness may be epithelial rests.

Macroscopically, the lesion may be uni- or multilocular. It develops from epithelium of the enamel organ or epithelial rests of Malassez, is more frequently located in the angle and on the ascending branch of the mandible.



№ OP4. Odontogenic keratocyst. (H-E stain.)

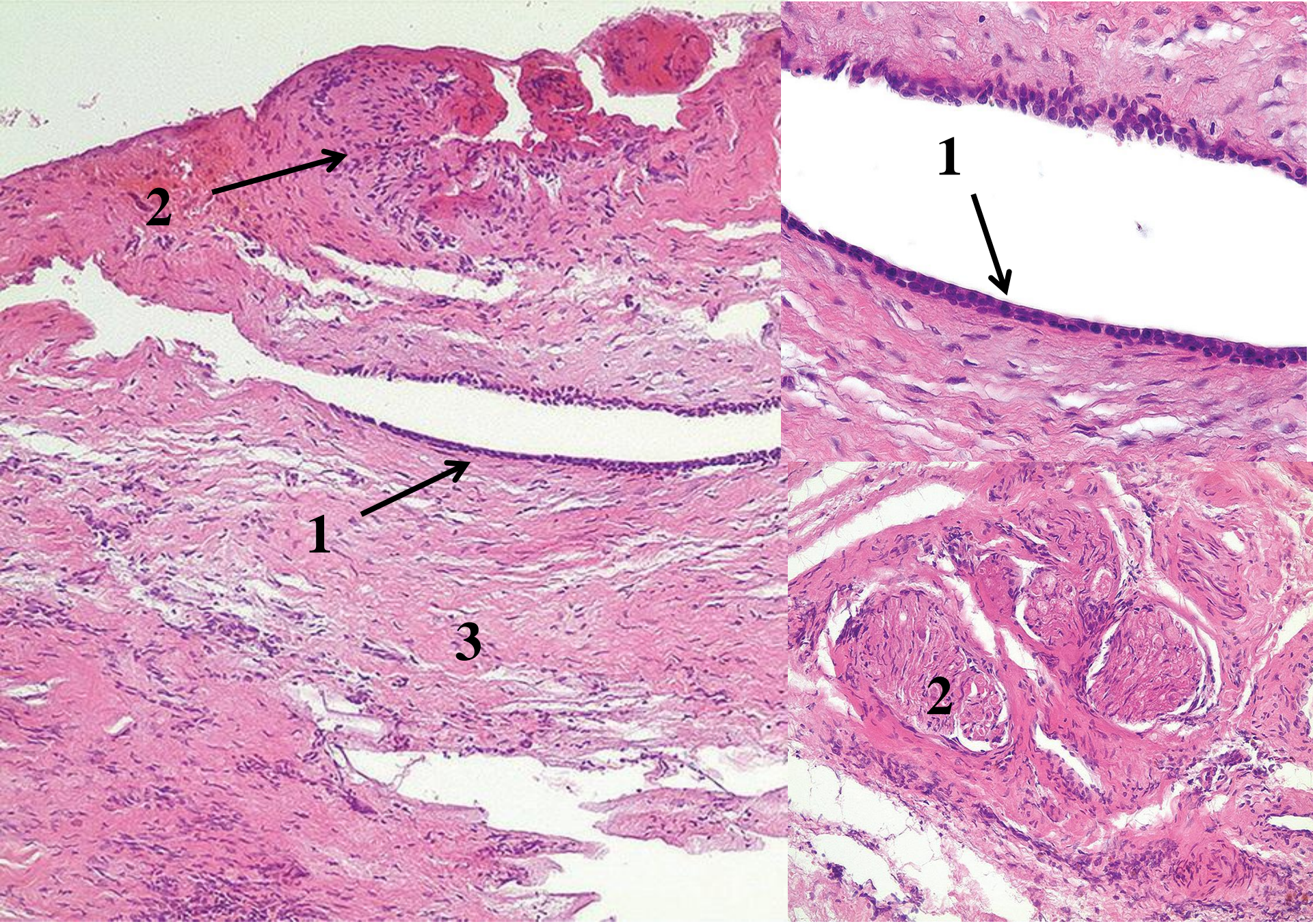
№ OP 41. Nasopalatine cyst. (H-E stain.)

Indications:

1. Luminal surface of the cyst lined by cuboidal epithelium of respiratory type.
2. Wall of the cyst represented by connective tissue.
3. Nerve bundles in the cyst wall.

Microscopically, the nasopalatine cyst is delimited by a stratified squamous epithelium (when it develops towards the oral end of the duct) or pseudostratified, ciliate of respiratory type (when it develops towards the nasal end of the duct). Under epithelium is a connective tissue with vessels, nerves, minor salivary glands, small islands of hyaline cartilage and a moderate inflammatory infiltrate.

Macroscopically, it has a round shape, with a diameter of 1.5 cm. It is formed from the cells of the epithelium of the nasopalatine duct, which in the embryo makes the connection between nostrils and oral cavity. It is the most common neodontogenic cyst and is located on the midline of the maxilla between the upper incisors, causing the divergence of the roots, the crowns thus converging. Teeth are vital.



No OP 41. Nasopalatine cyst. (*H-E stain.*)

Necrotic pulp

Chemical mediators

Periapical abscess
Acute inflammation

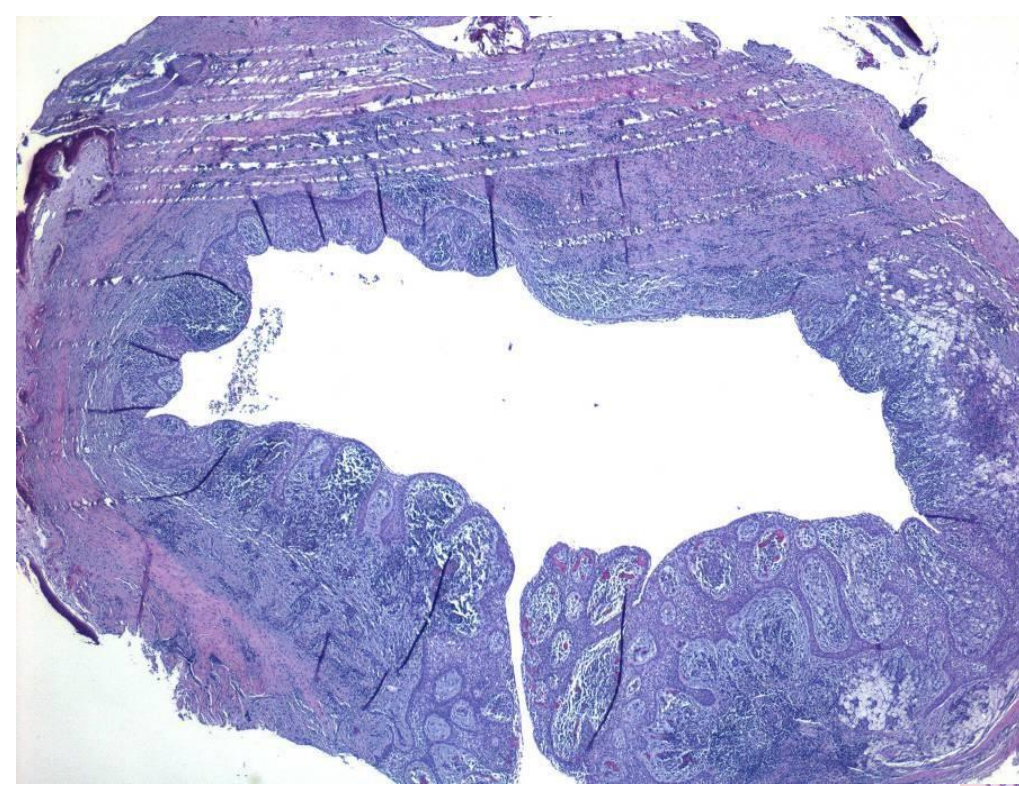
Periapical granuloma
Chronic inflammation

Drenaj

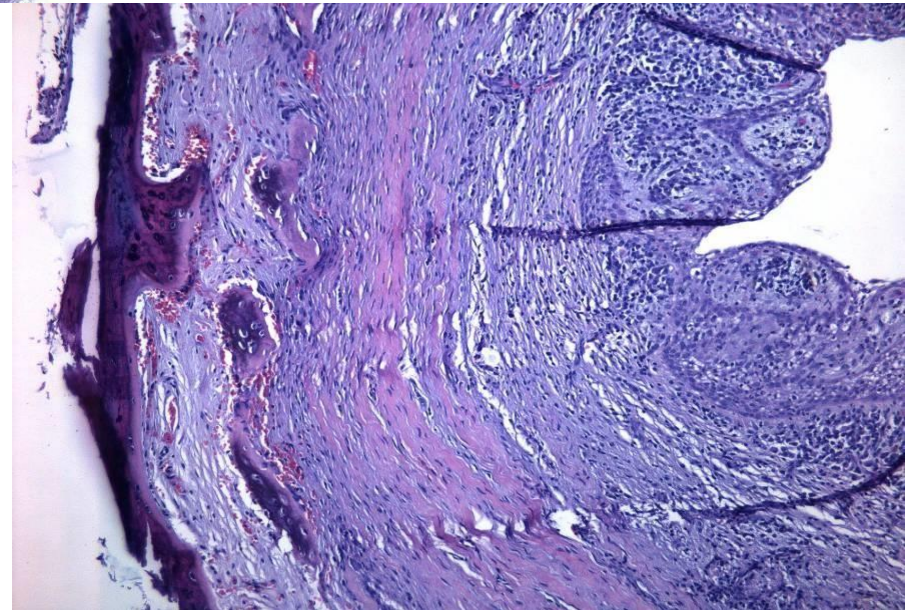
stimuli
continue

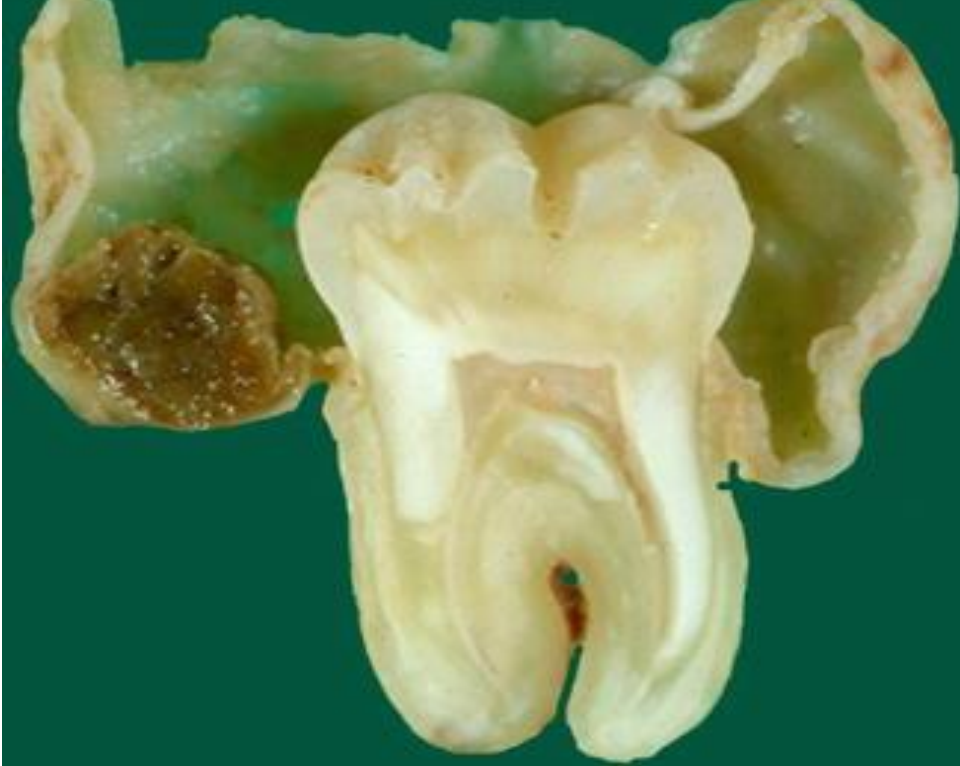Fistula

Periapical cyst

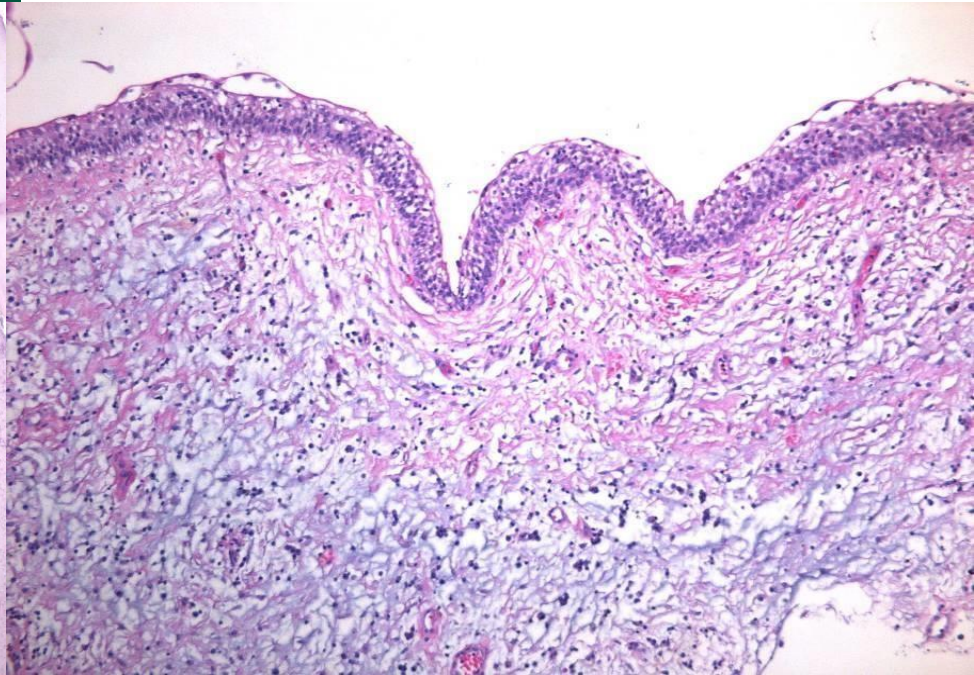
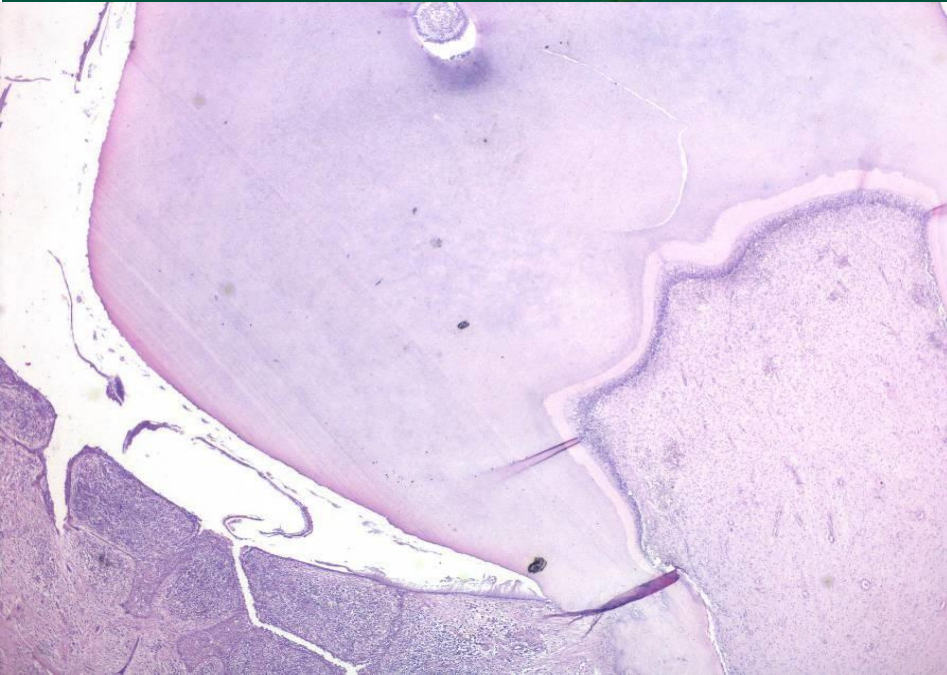


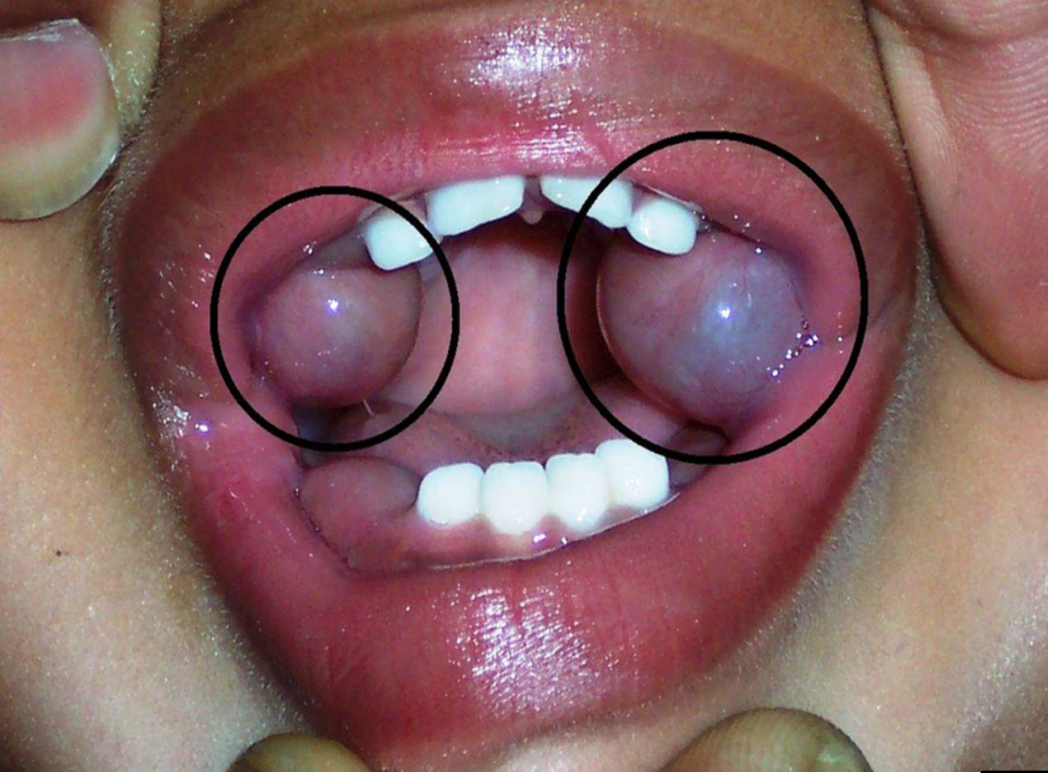
Radicular cyst.



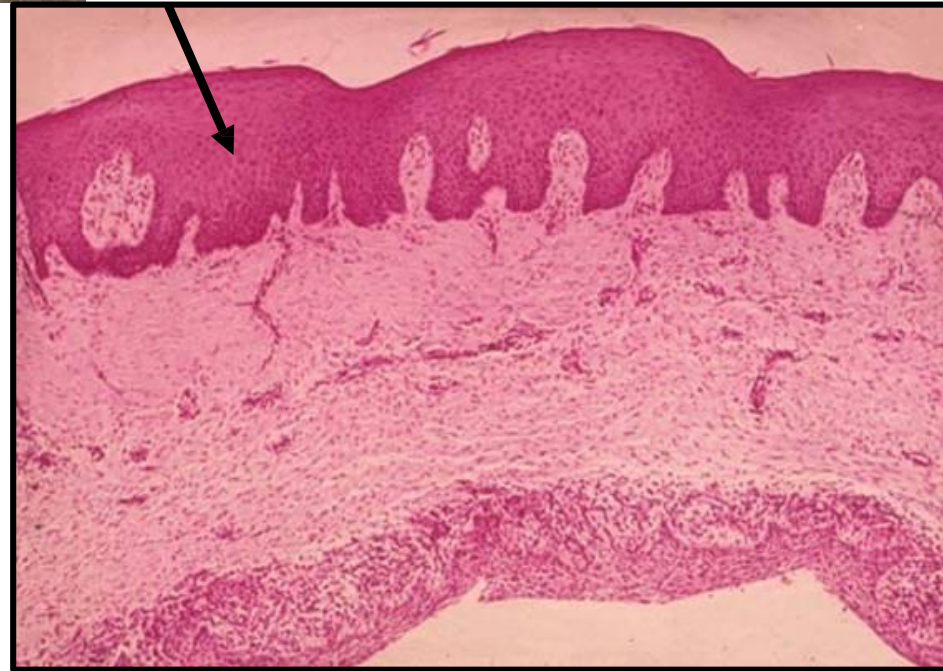


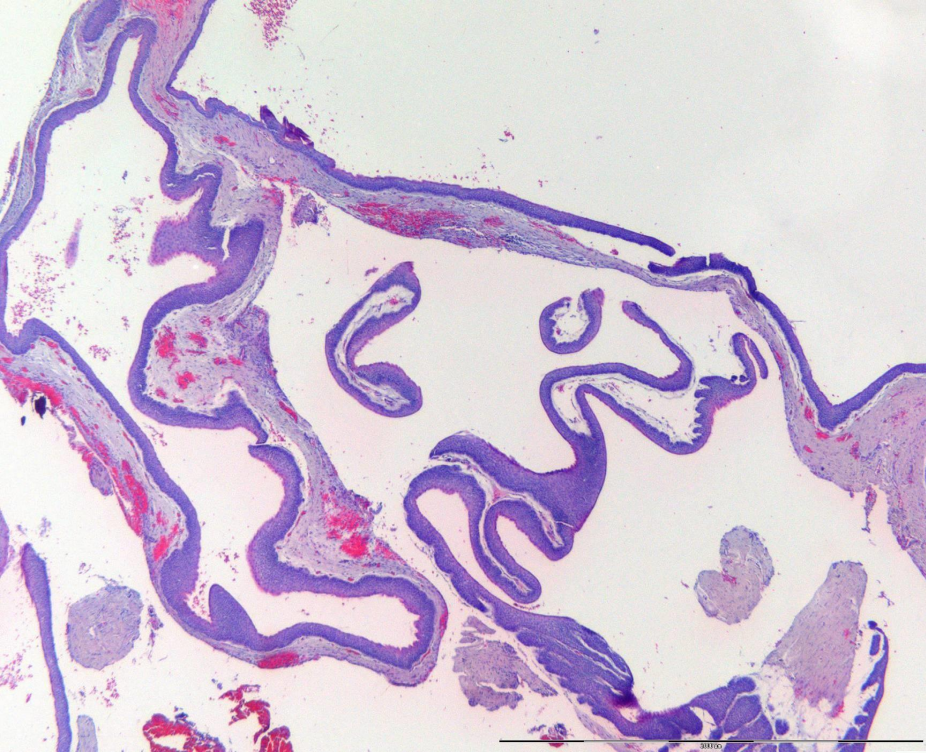
Dentigerous cyst
(follicular).



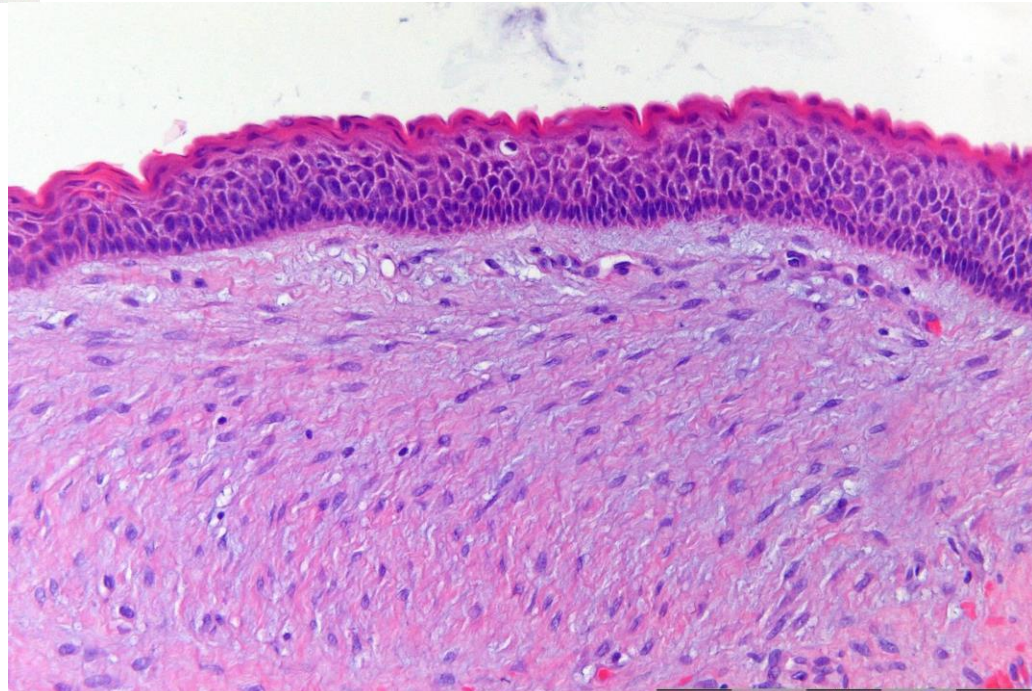


Cyst of eruption.

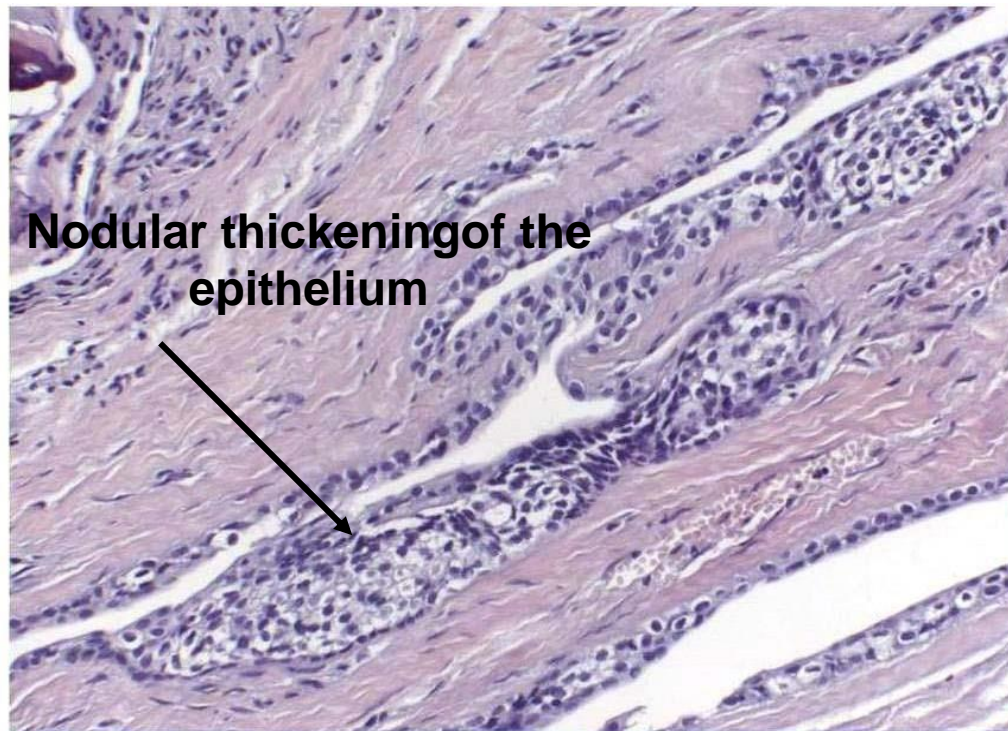
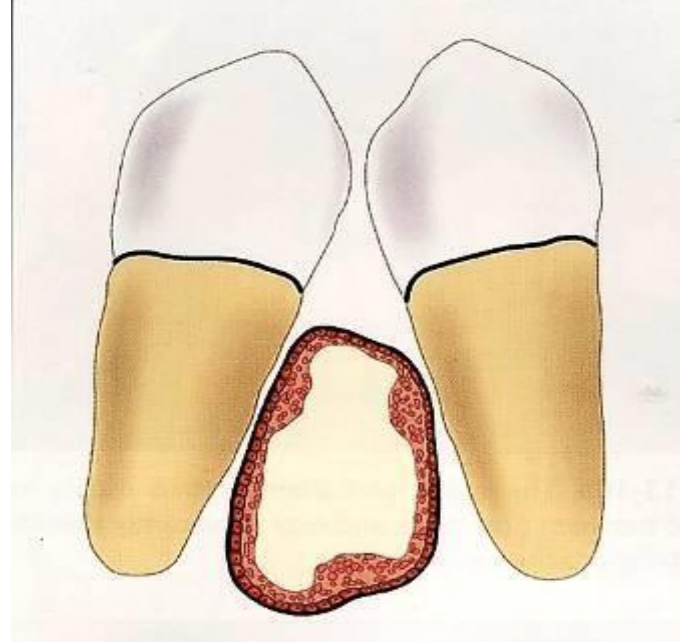




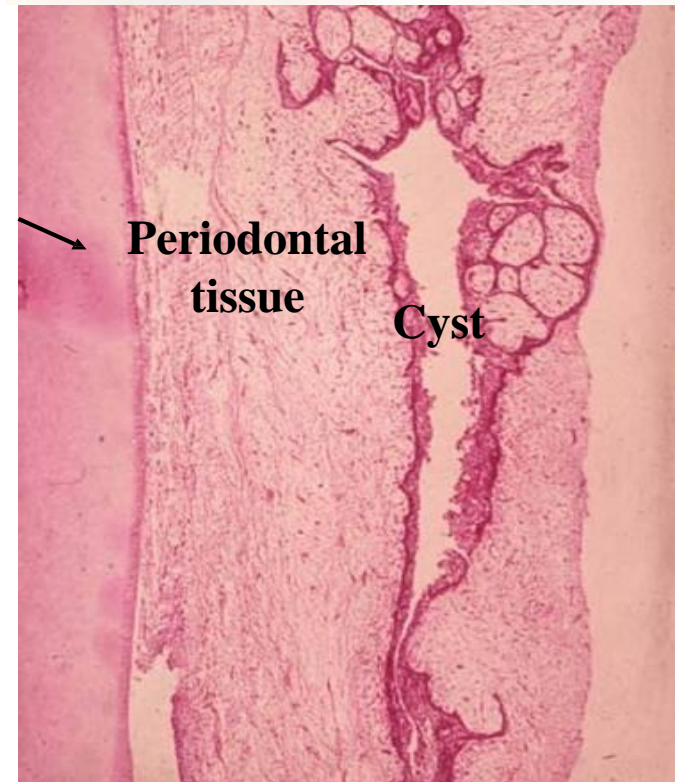
Odontogenic keratocyst.



Lateral periodontal cyst.

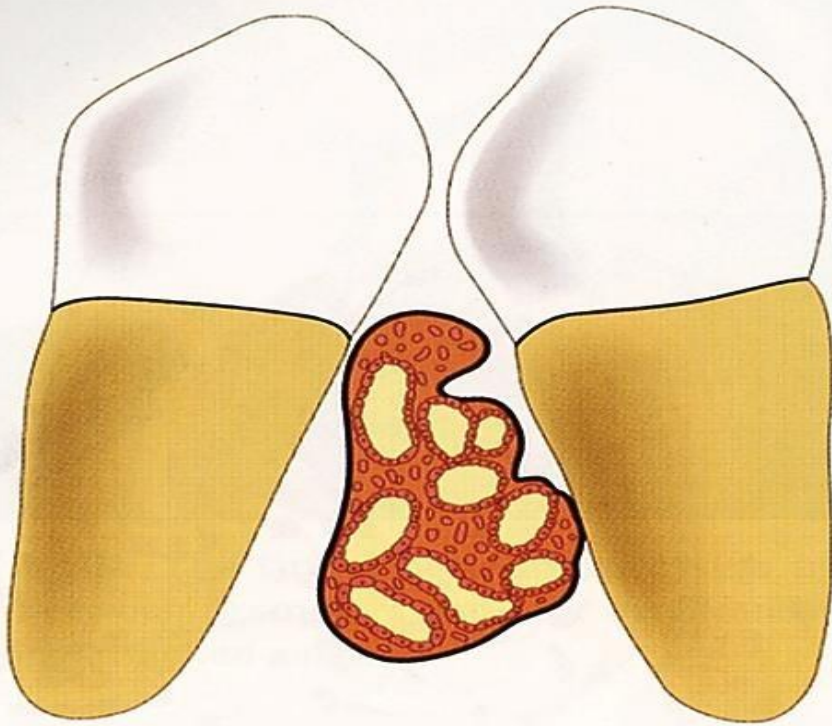


Tooth

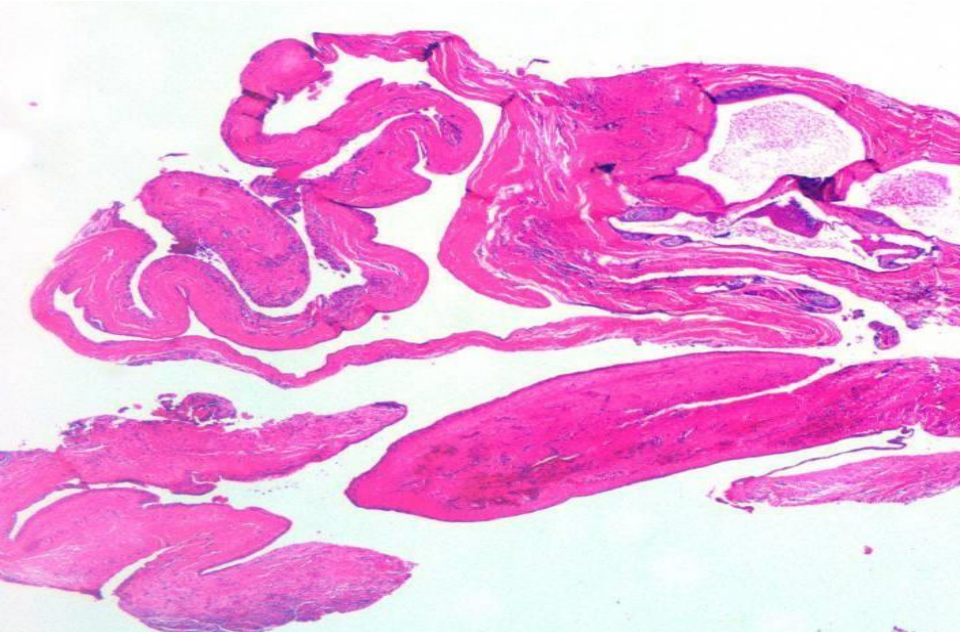
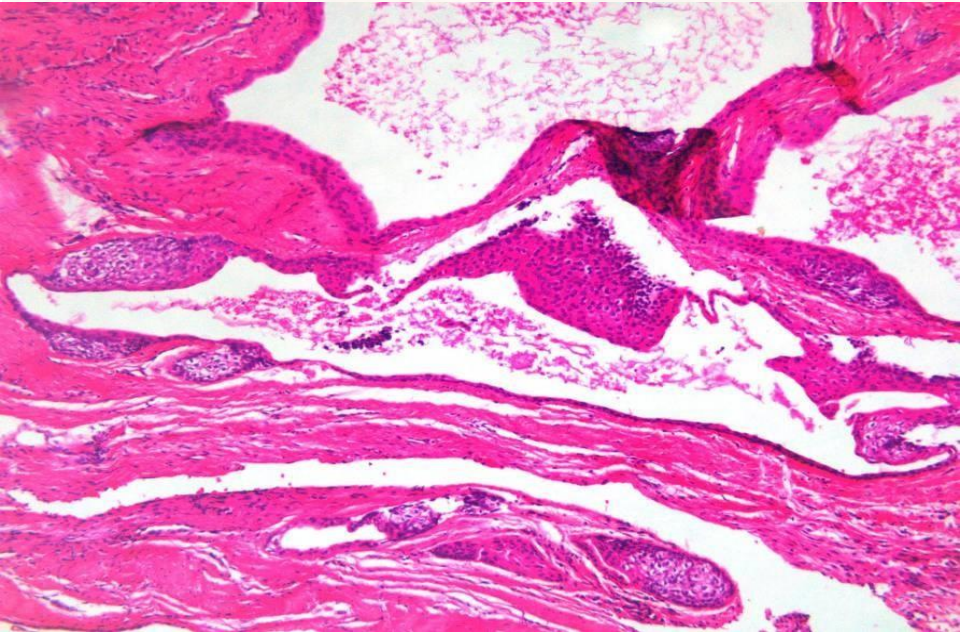


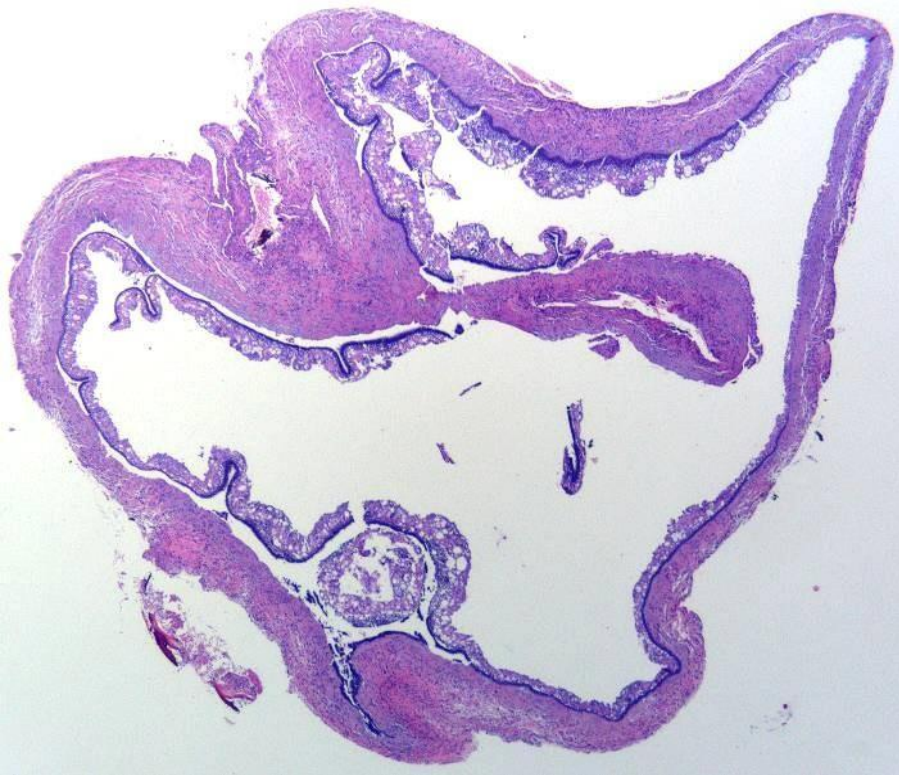
Periodontal tissue

Cyst

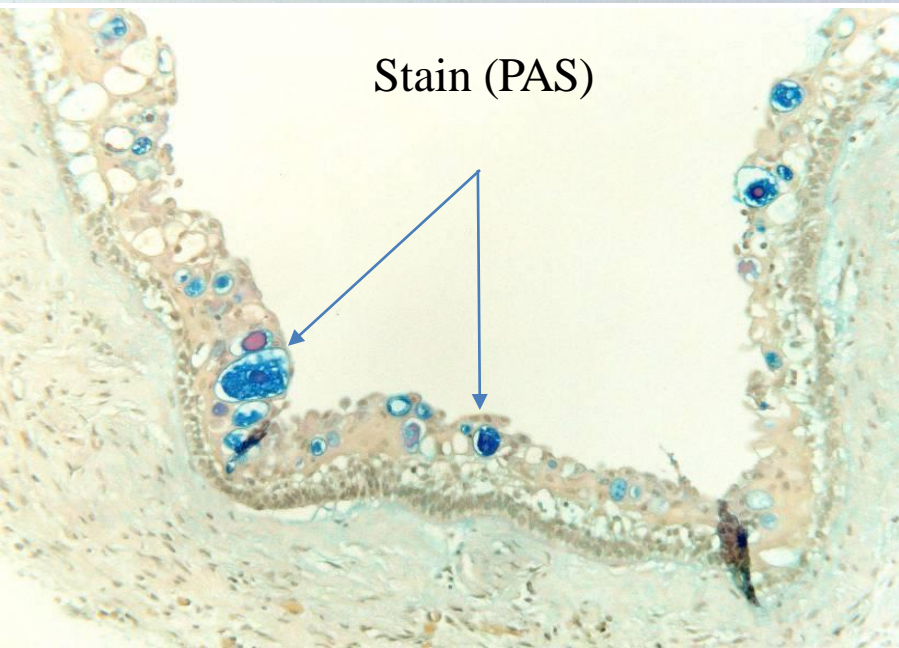


Botryoid cyst.

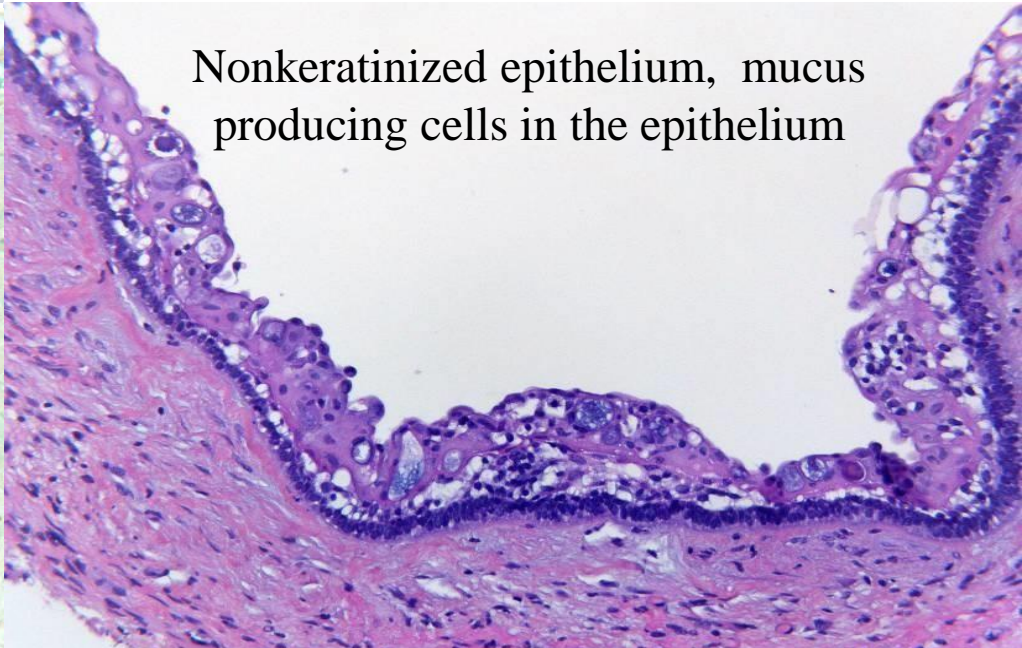




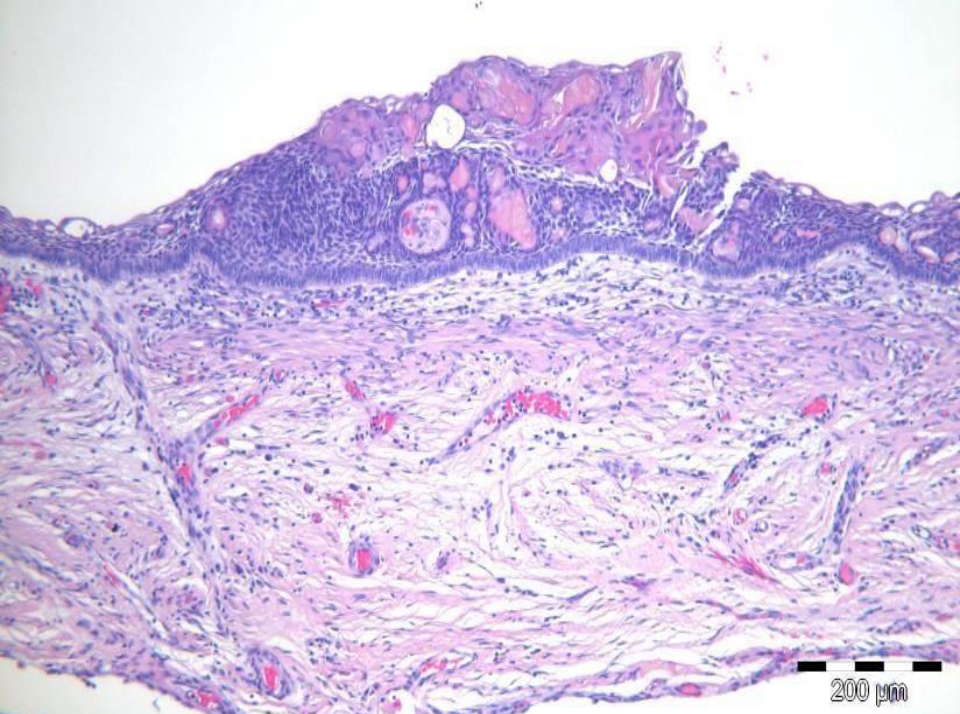
Glandular odontogenic cyst.



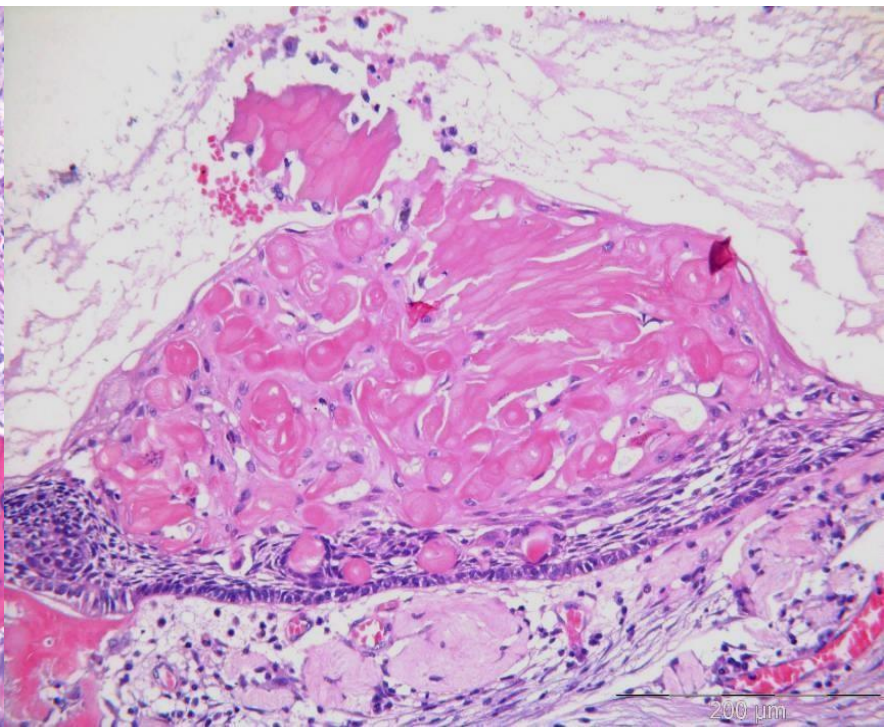
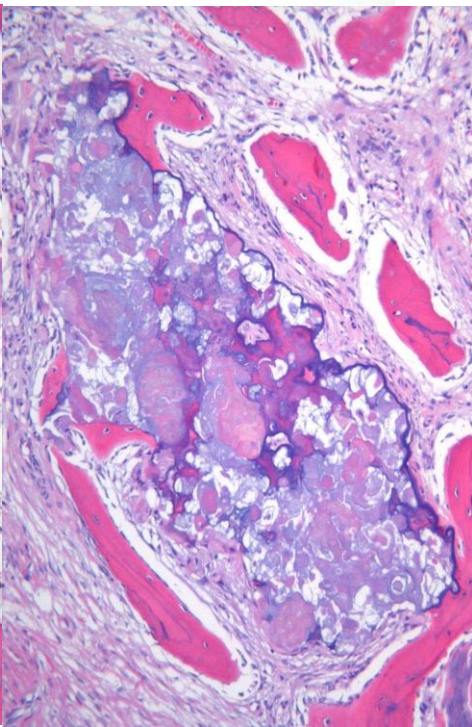
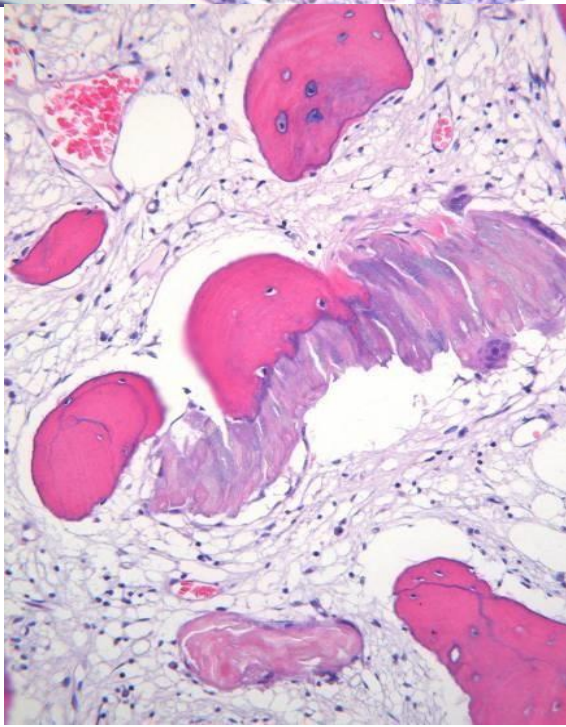
Stain (PAS)

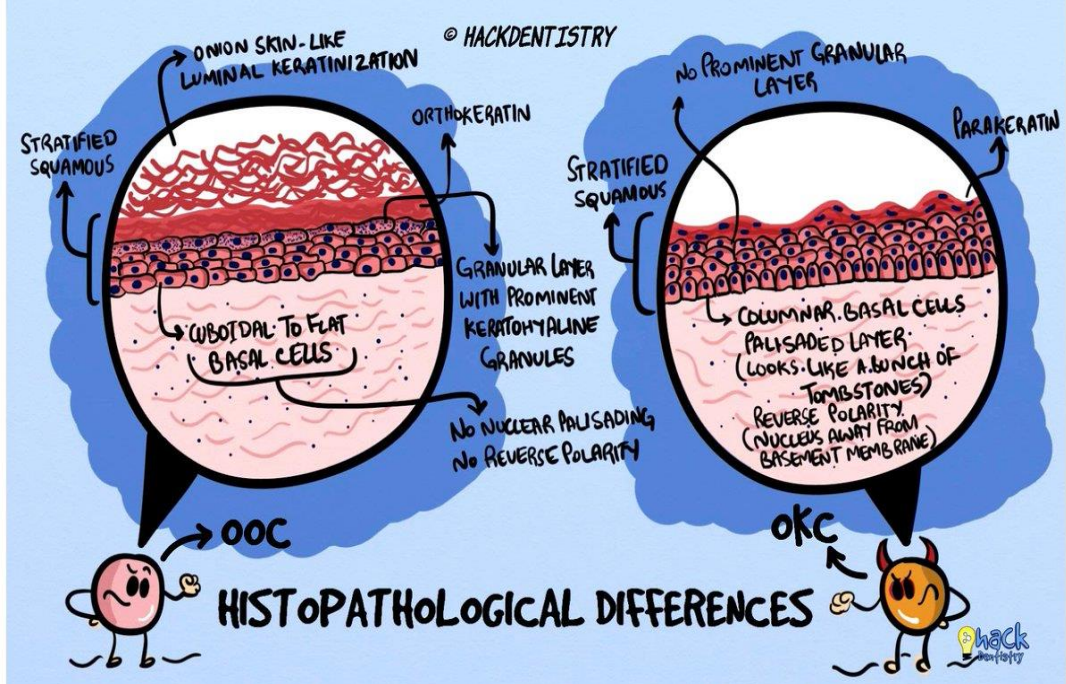


Nonkeratinized epithelium, mucus producing cells in the epithelium

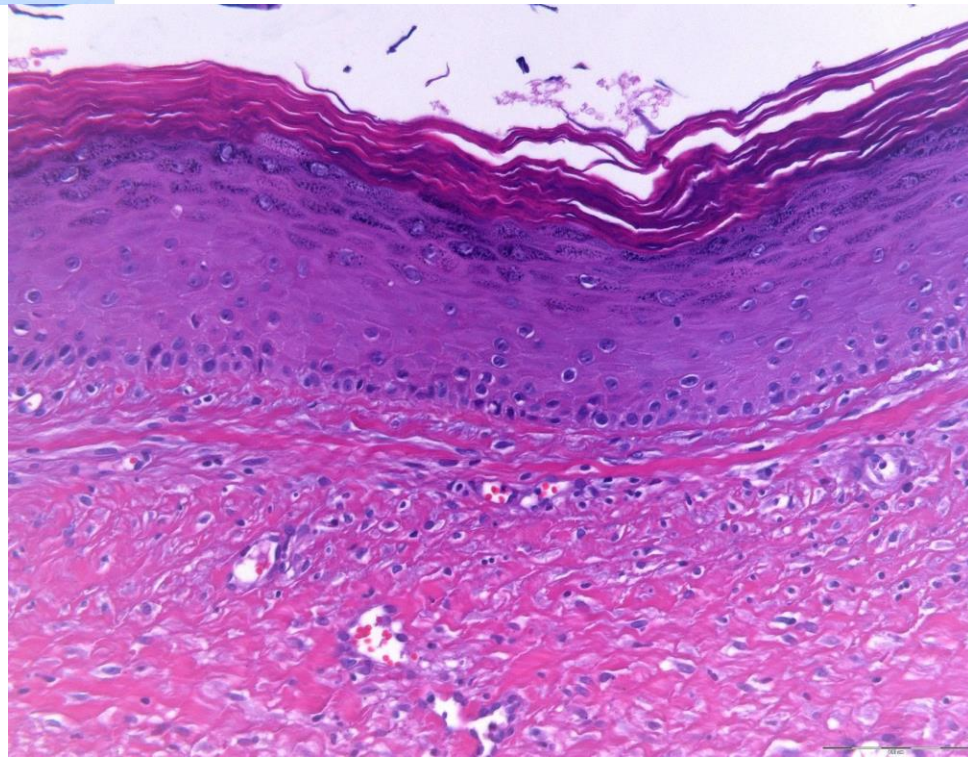


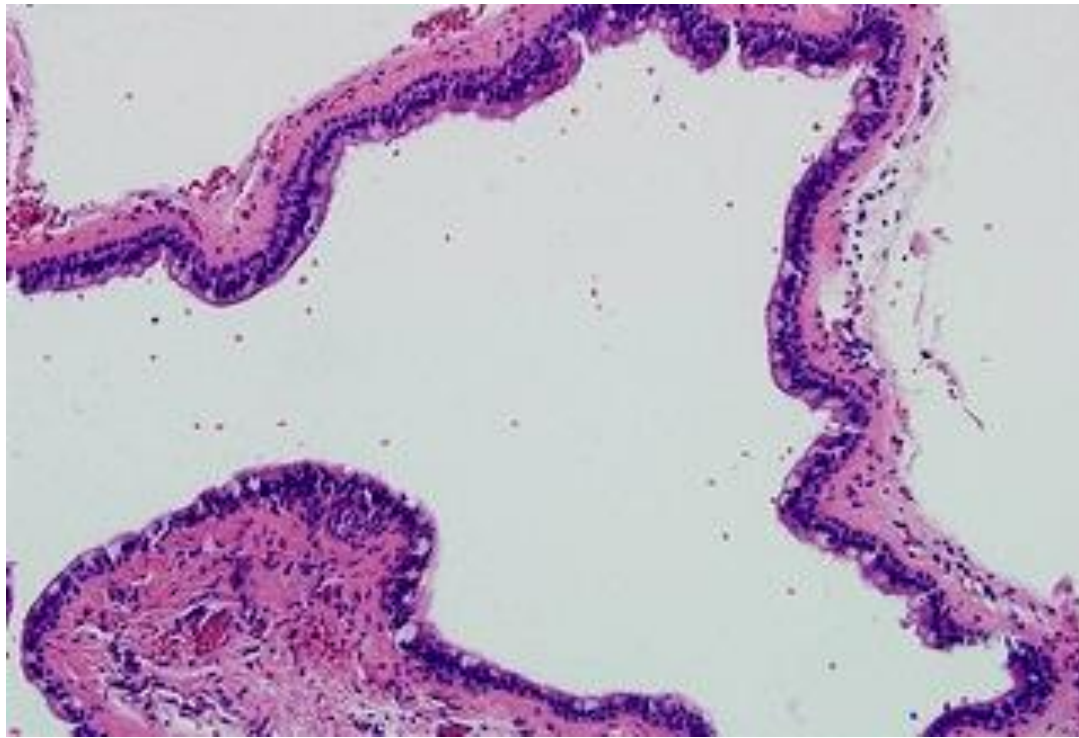
Calcified odontogenic cyst.





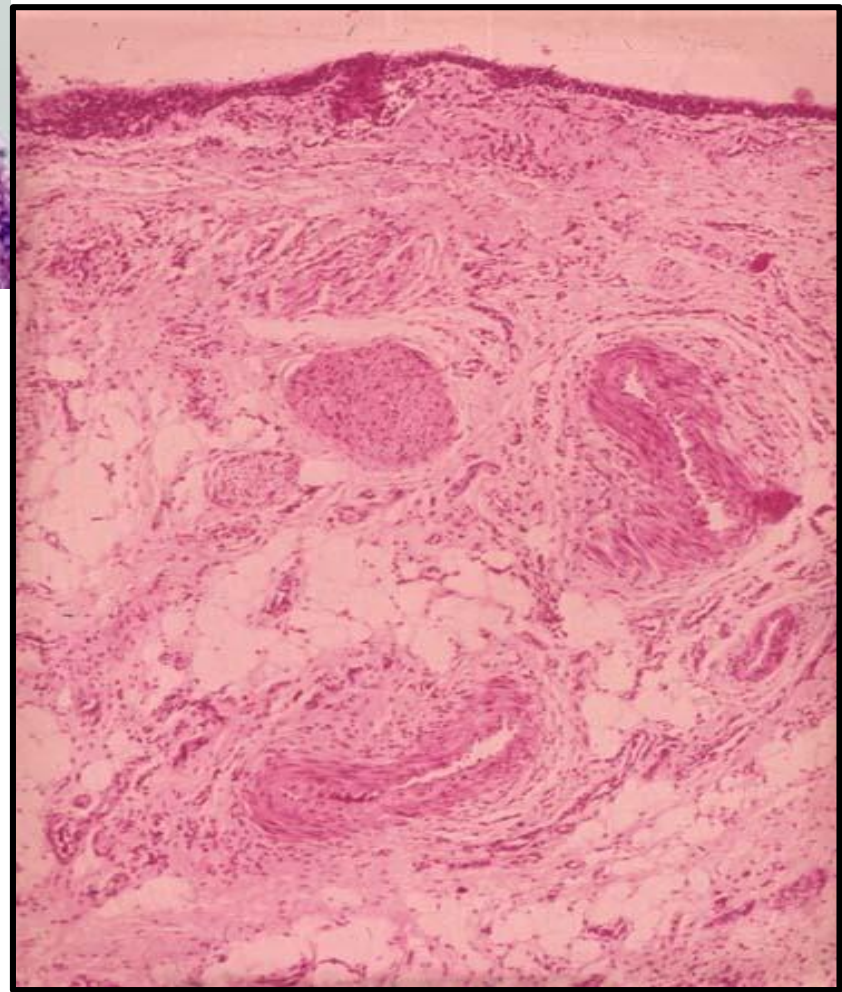
Orthokeratinized
keratocyst.





Nasopalatine duct cyst.

Nasolabial cyst
(nasoalveolar).

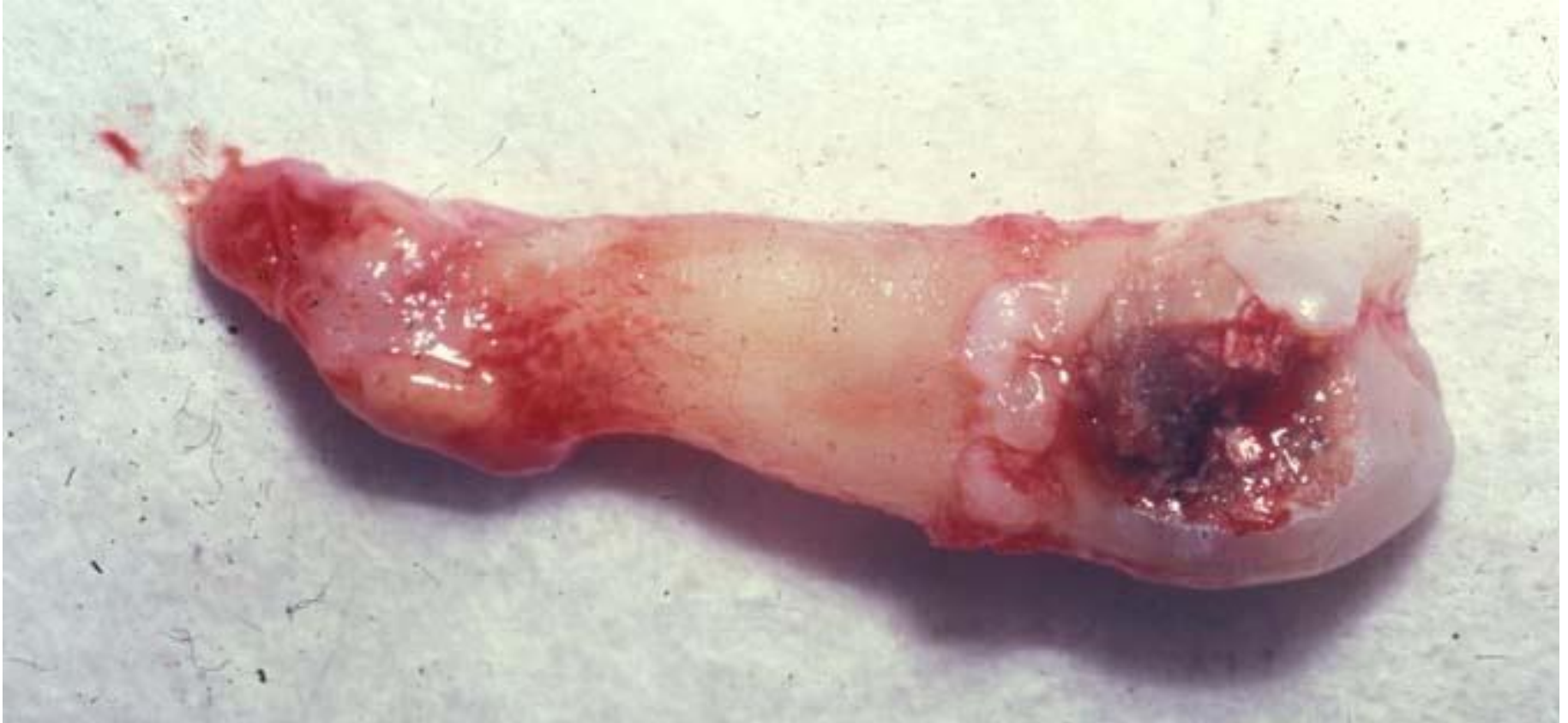

- Odontogenic cysts of inflammatory origin
 - Radicular cyst
 - Inflammatory collateral cysts
- Odontogenic and non-odontogenic developmental cyst
 - Dentigerous cyst (follicular cyst)
 - The odontogenic keratocyst
 - Lateral periodontal cyst
 - Botrioid odontogenic cyst
 - Gingival cyst
 - Glandular odontogenic cyst
 - Calcified odontogenic cyst
 - Orthokeratinized odontogenic cyst
 - Nasopalatine canal cyst

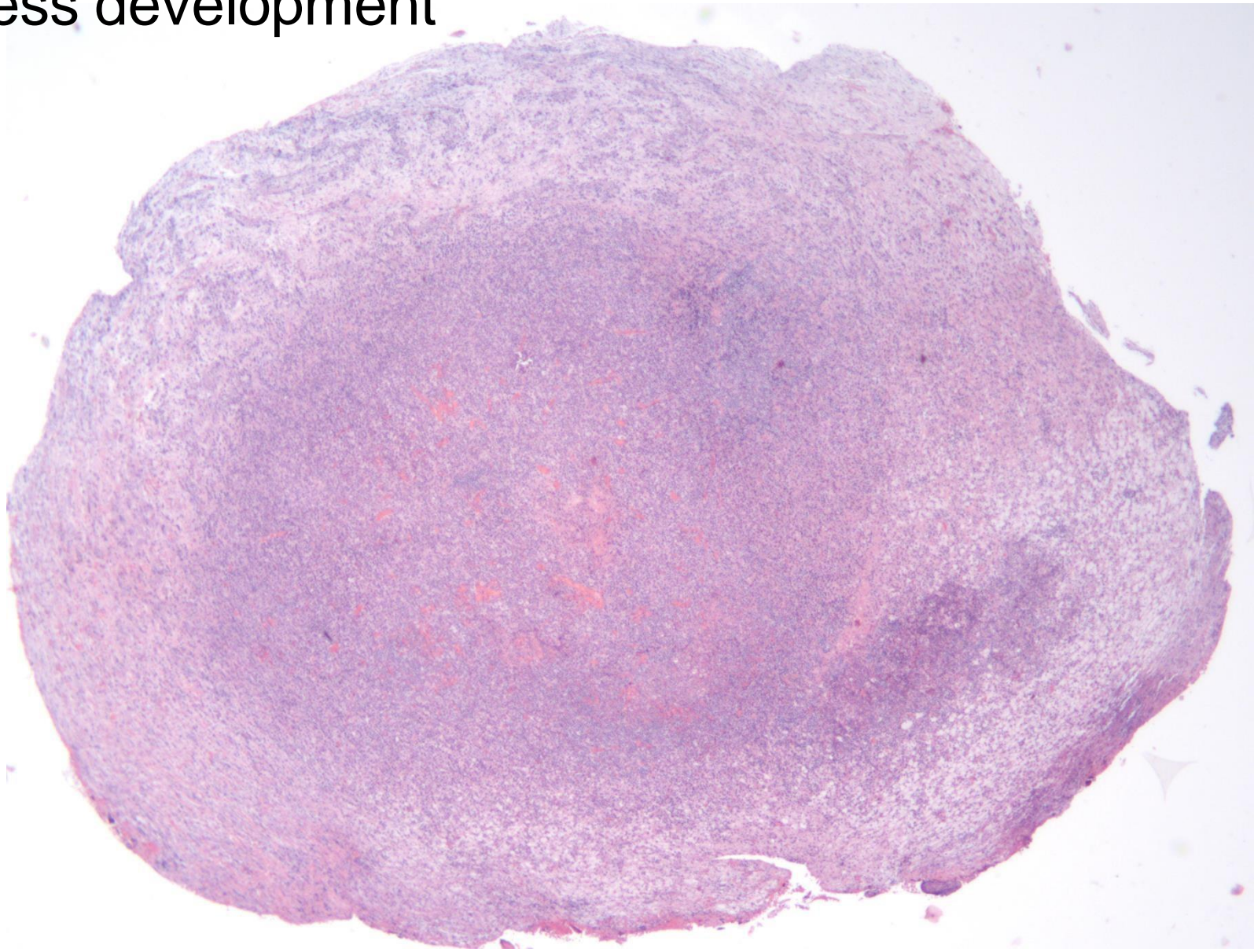
*Cyst: the preformed cavity
with liquid content, lined by
epithelium*

- Most cysts are intraosseous
- Only the root cyst can be linked to the infection
- It can be accidentally discovered on the X-ray
- May have clinical symptoms
- Vital teeth (except root cyst)
- Some have a high recurrence rate and can be aggressive

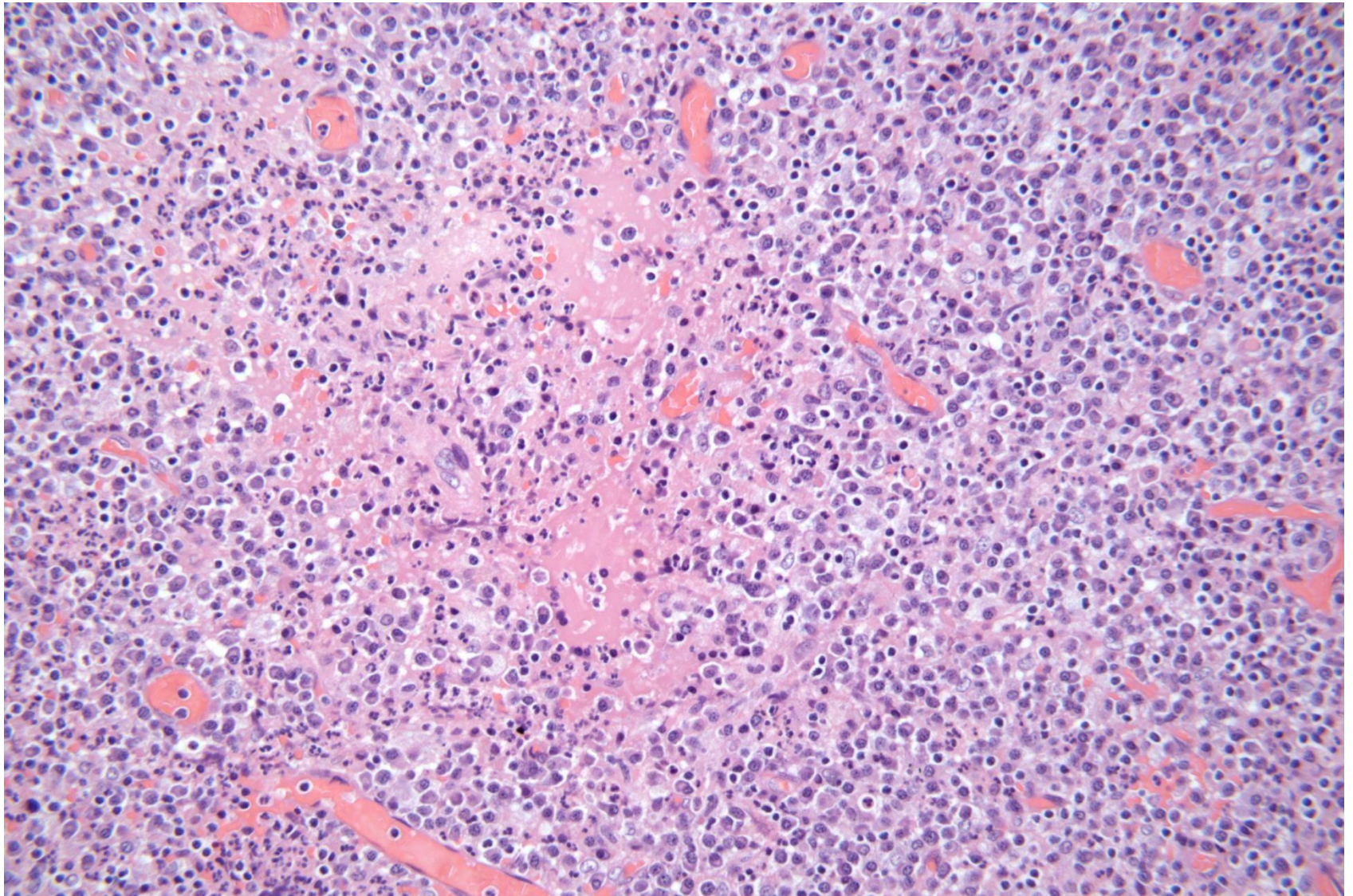
- Odontogenic cysts of inflammatory origin
- Radicular cyst
- Inflammatory collateral cysts



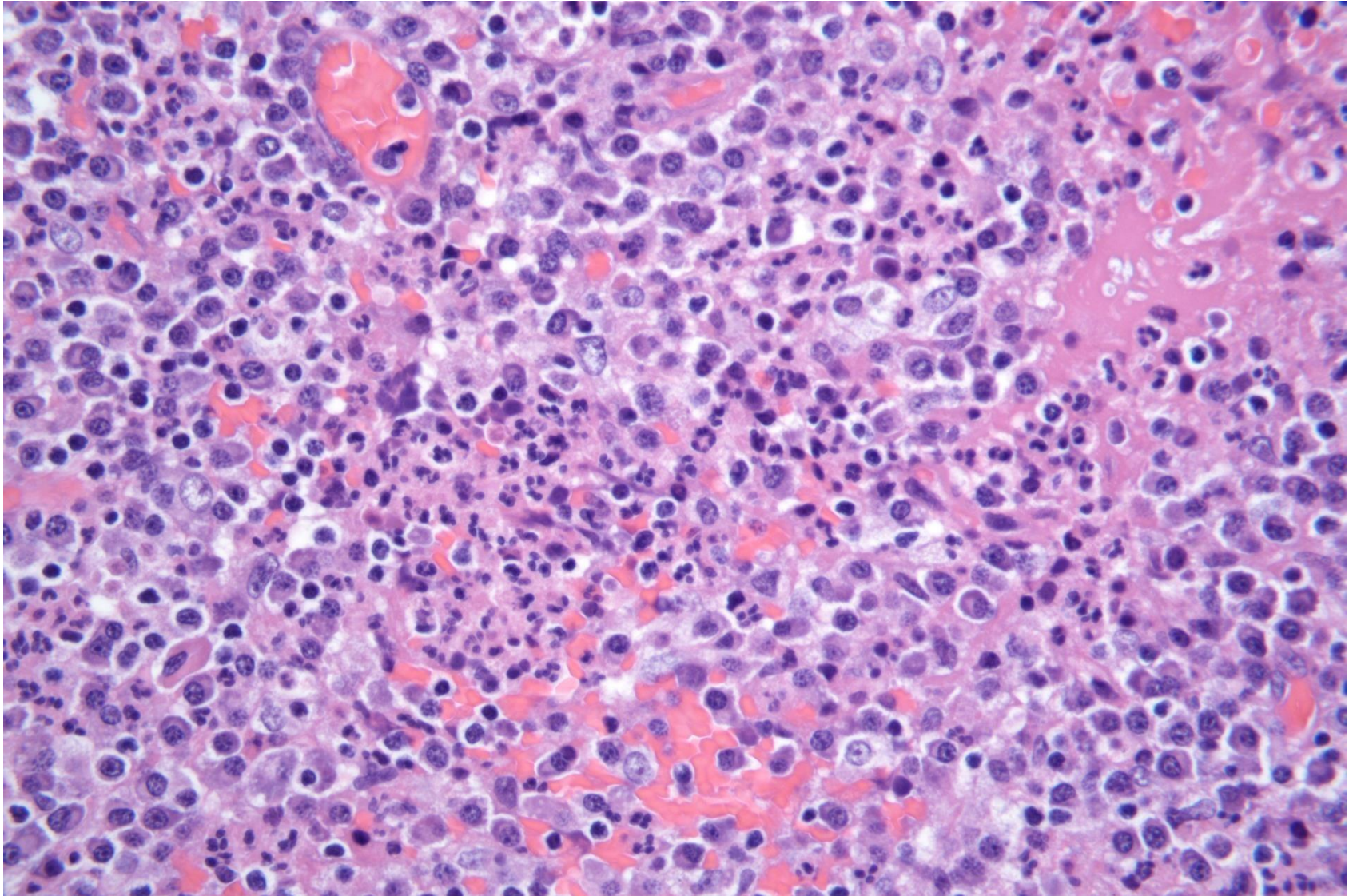
Abscess development



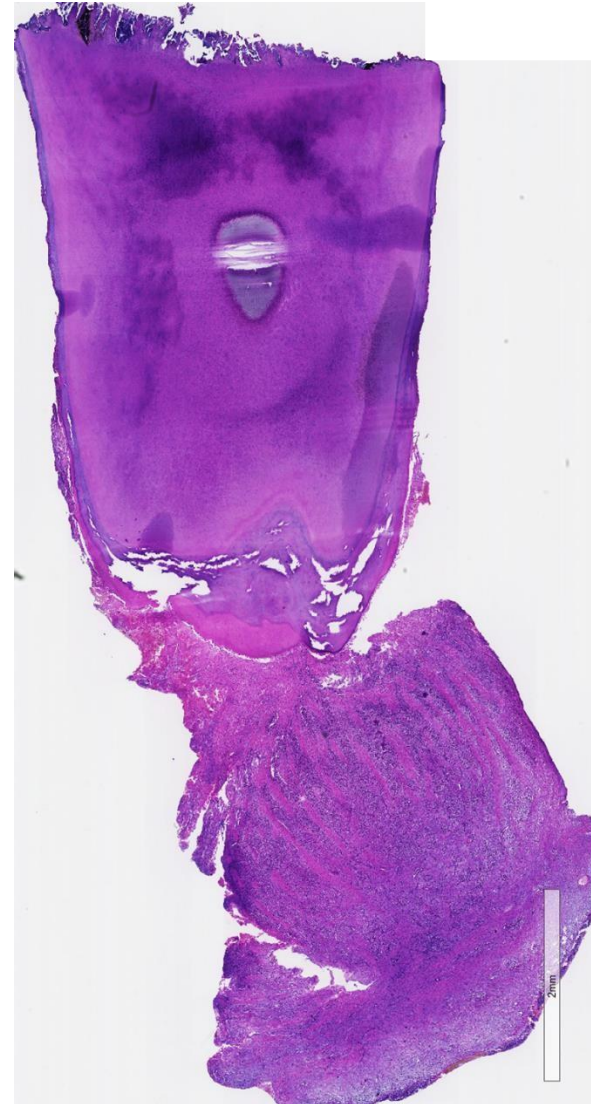
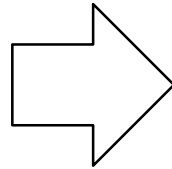
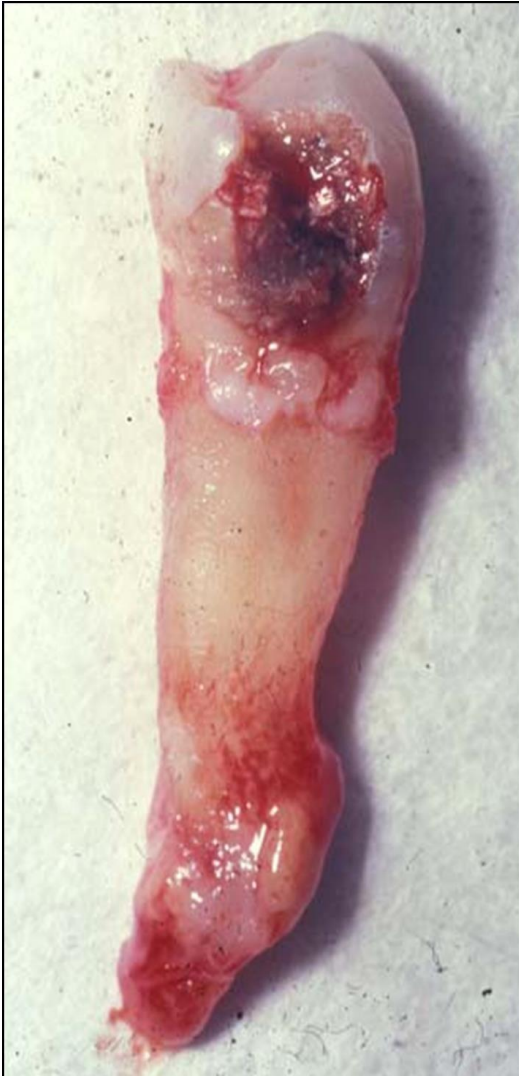Formation of fluid in the center

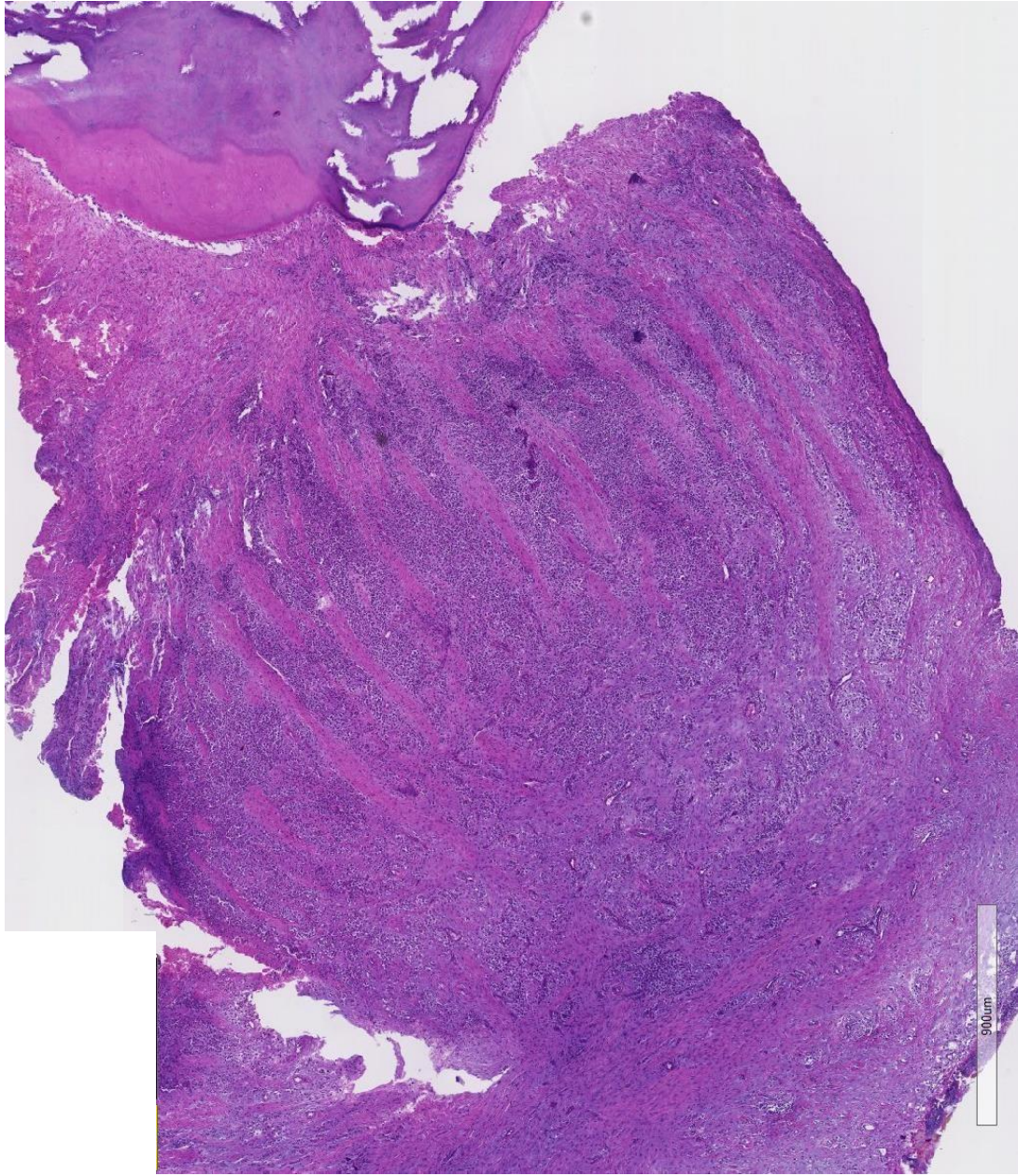


Neutrophilic granulocytes

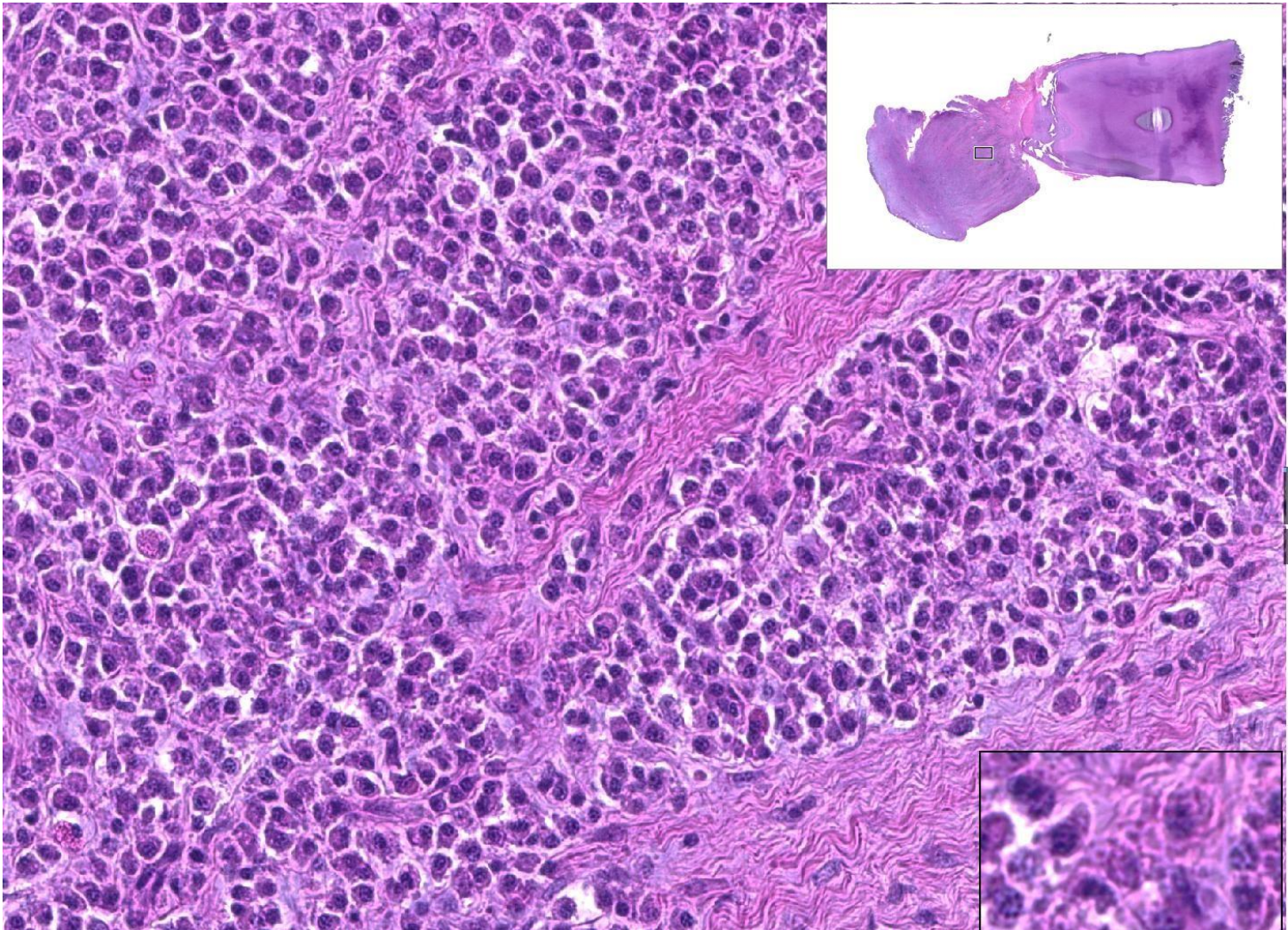


Periapical granuloma

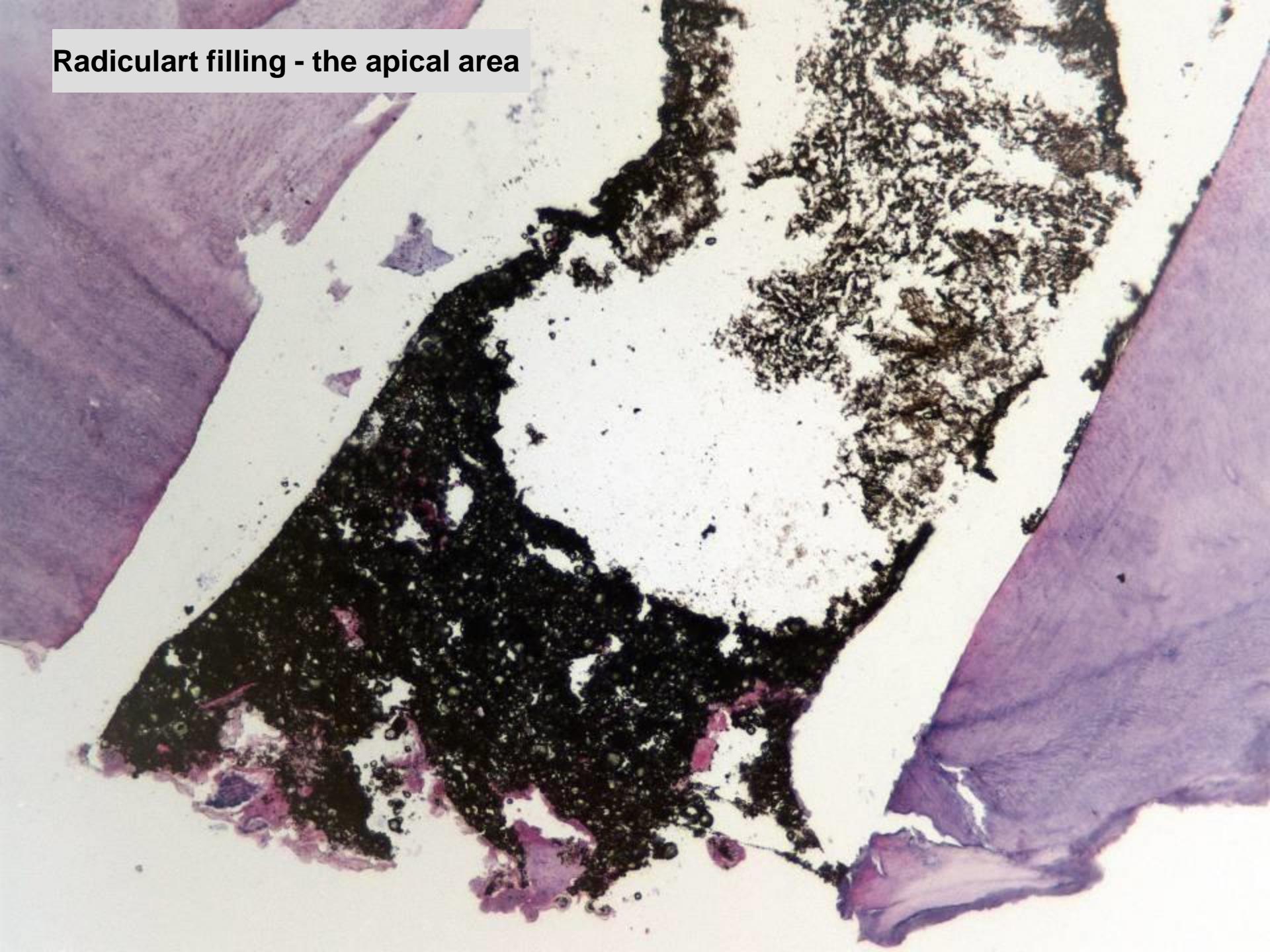




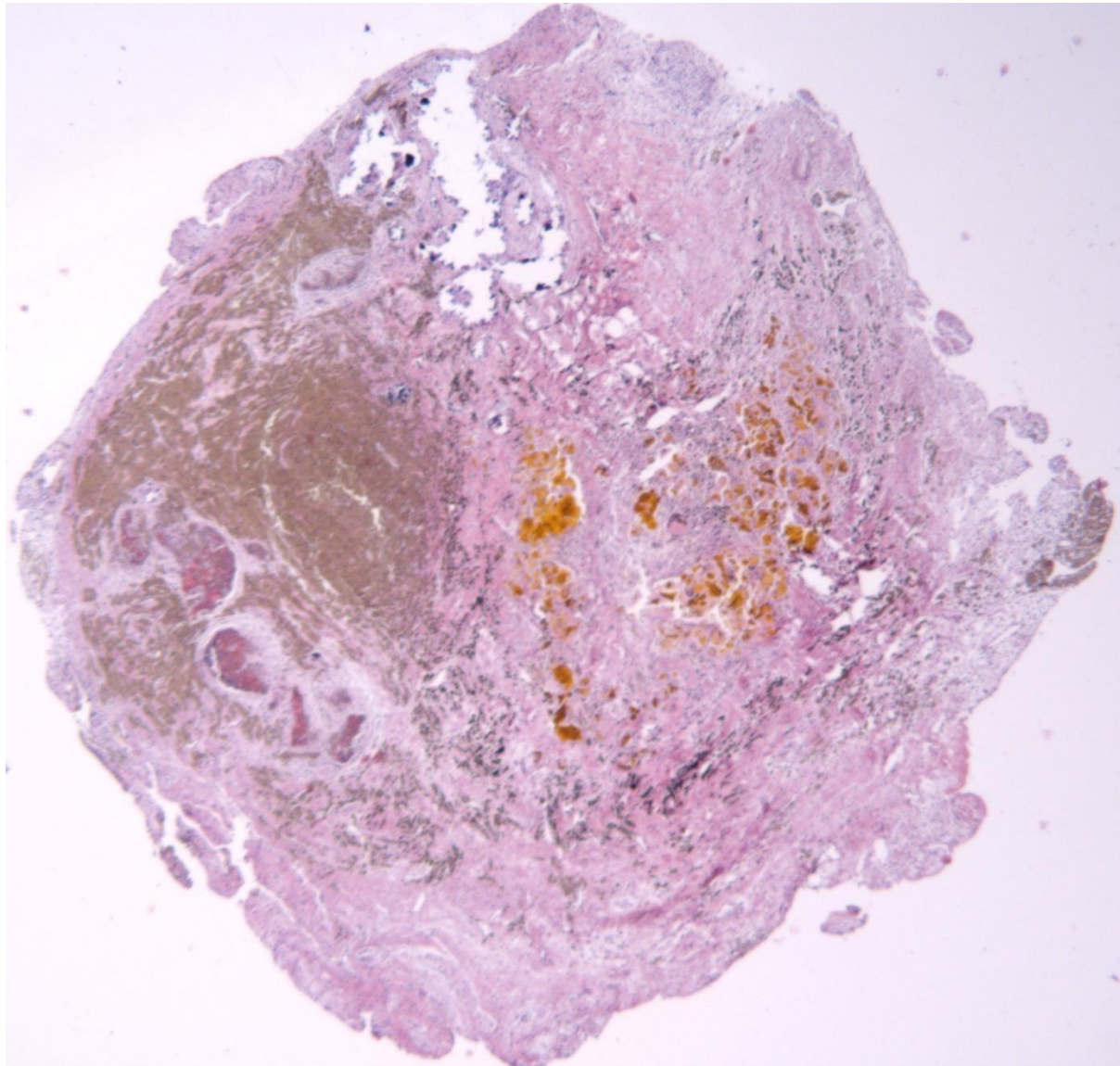
Chronic inflammation - plasma cells predominate



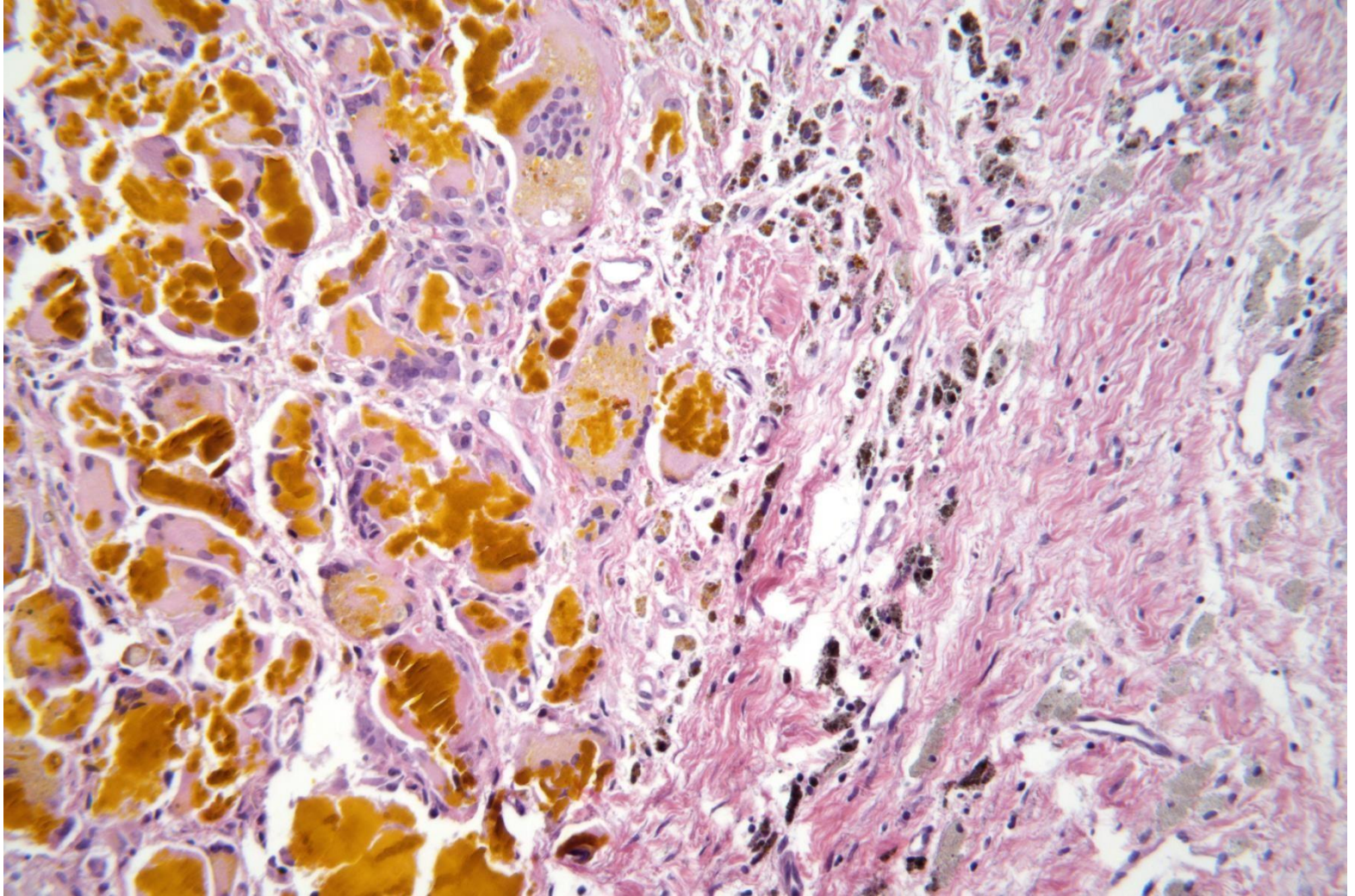
Radiculart filling - the apical area



Exogenous foreign bodies in the periapical region

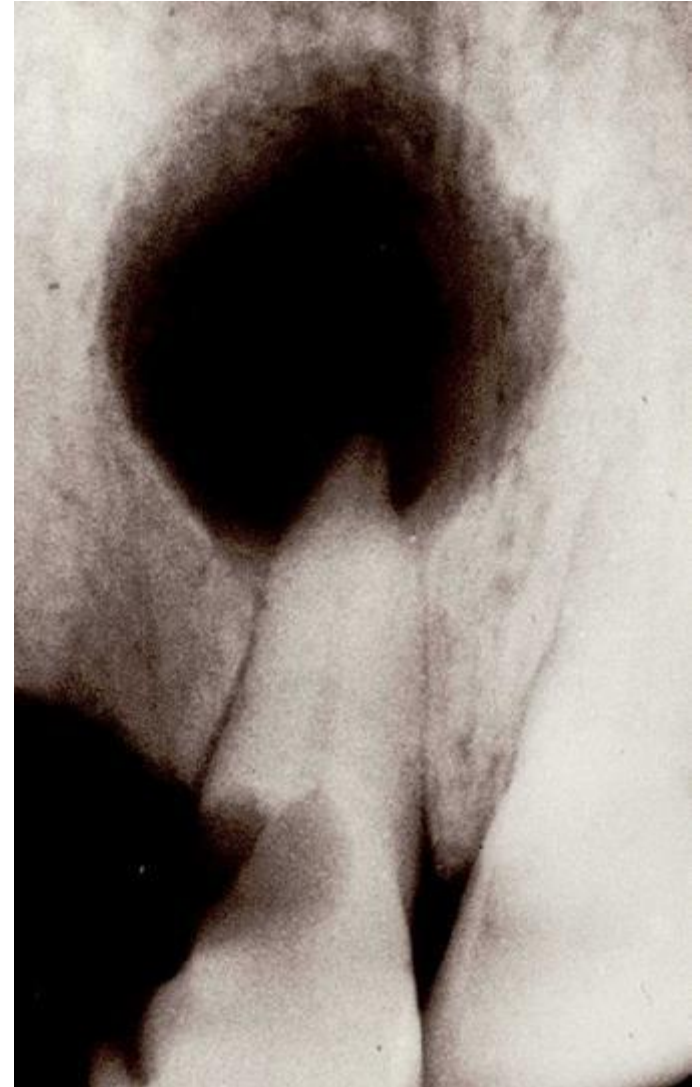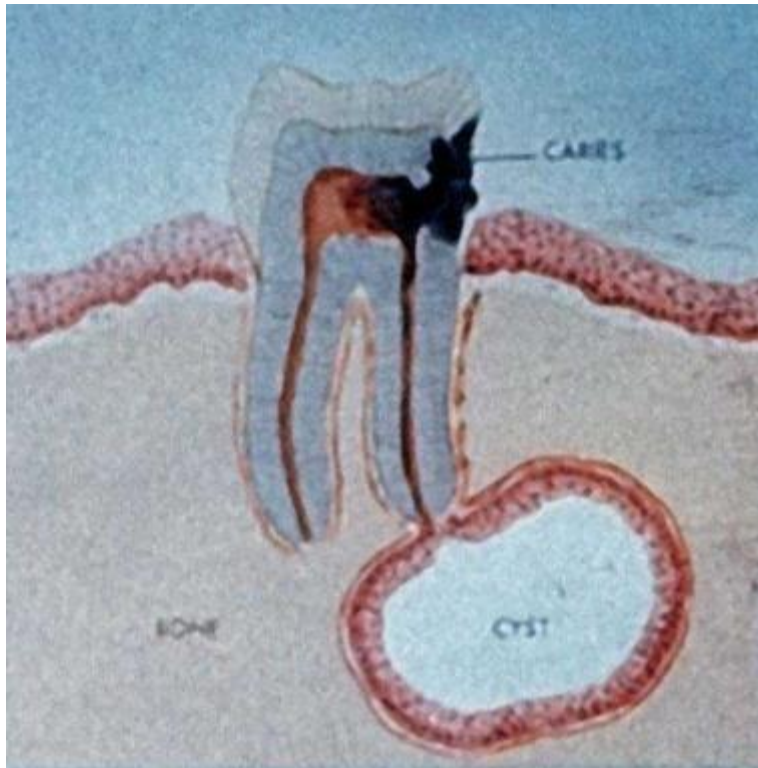


Reaction of foreign bodies with multinucleated cells



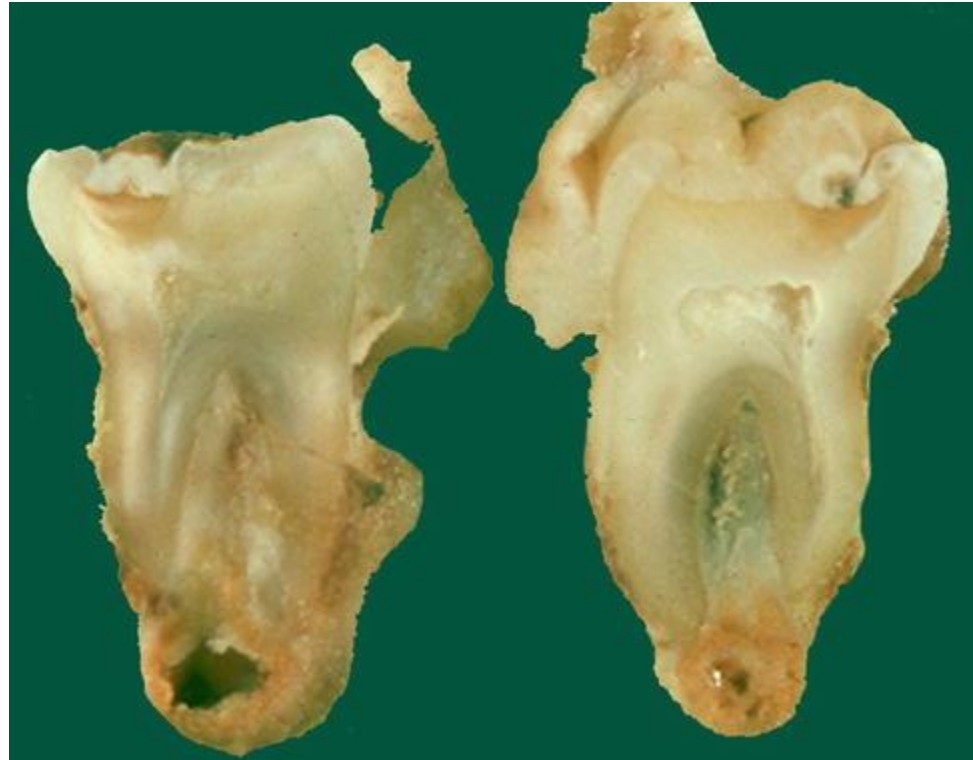
Radicular cyst

- Inflammatory
- Associated with pulp pathology

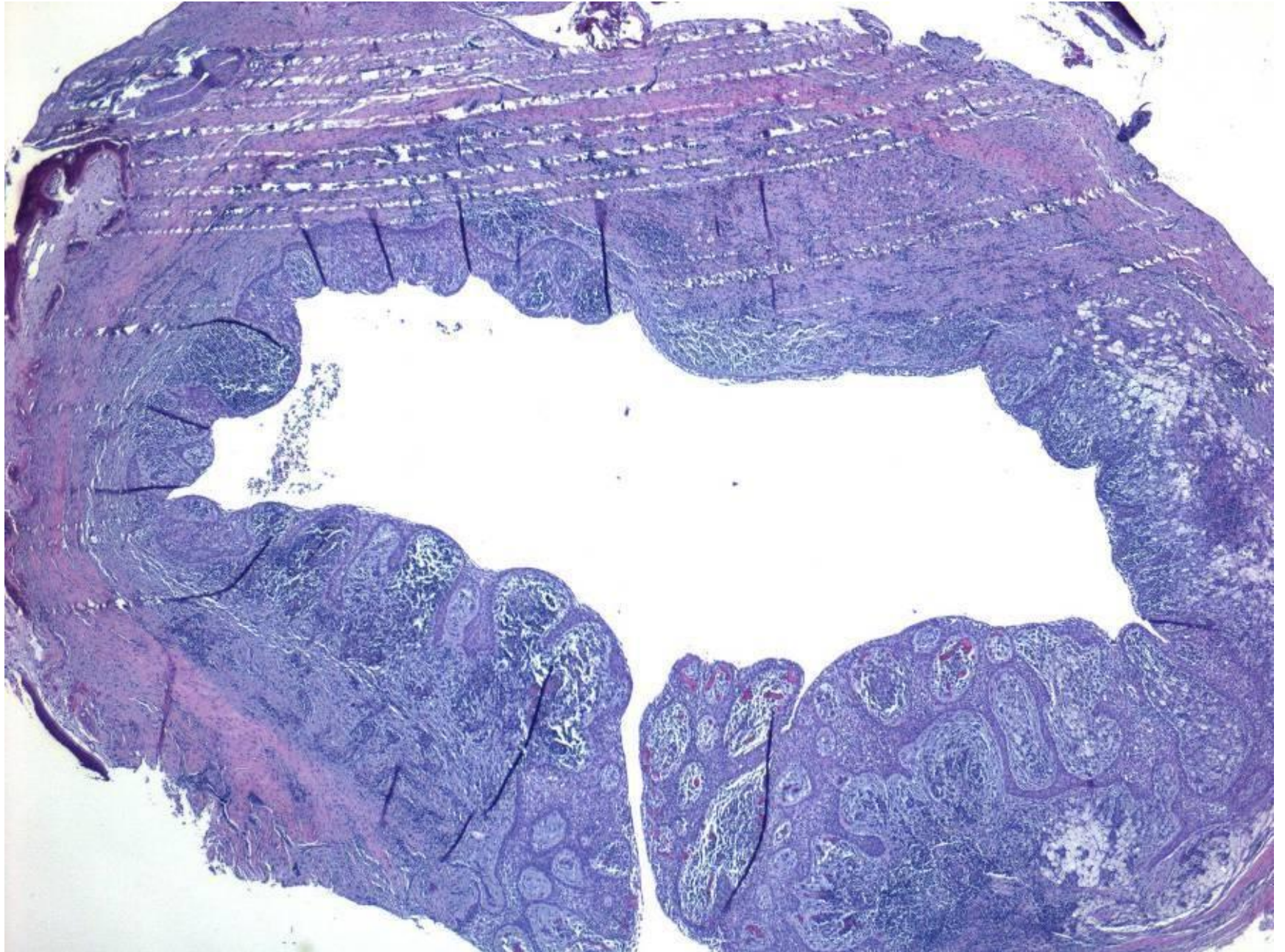


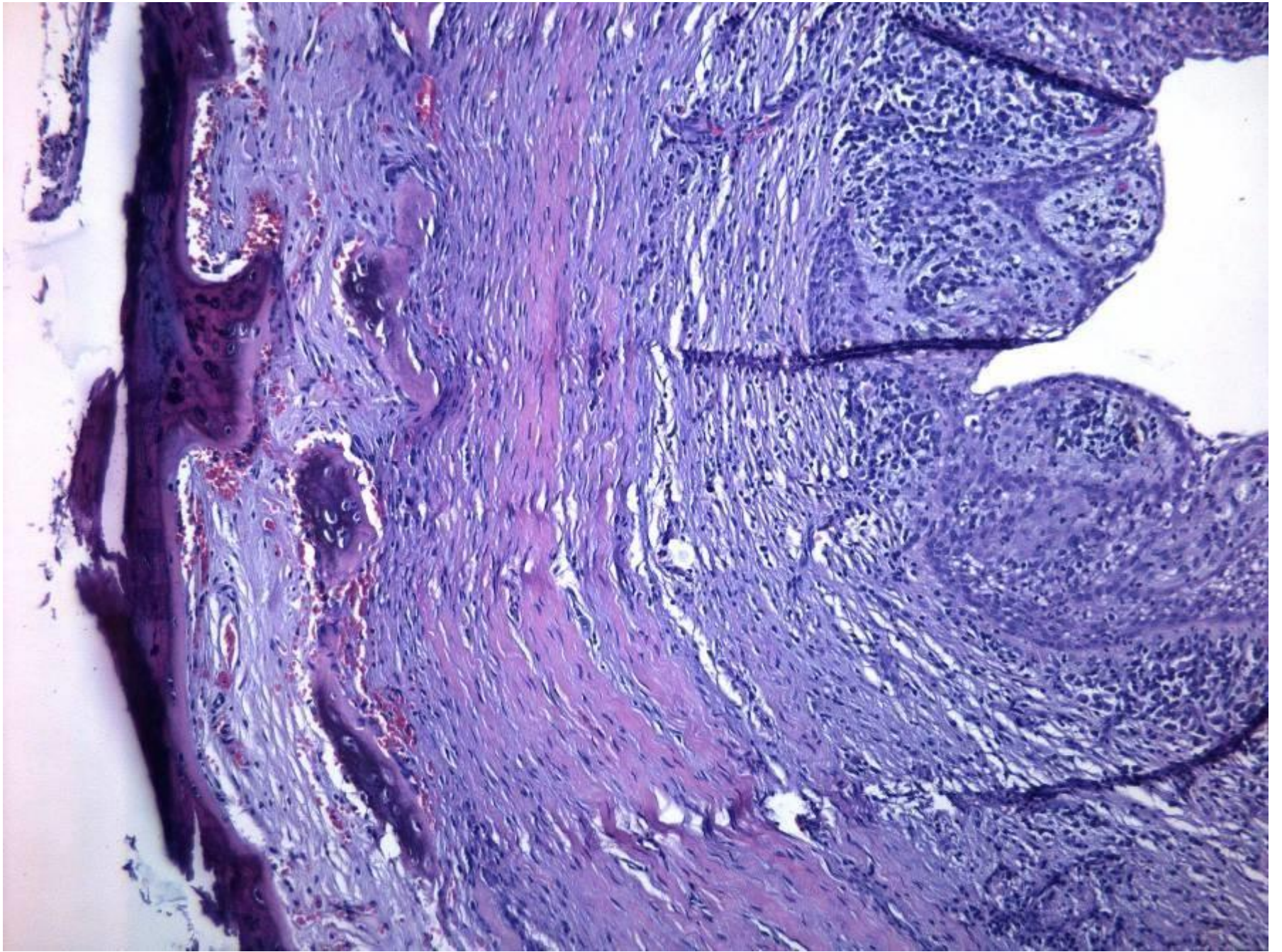
Radicular cyst

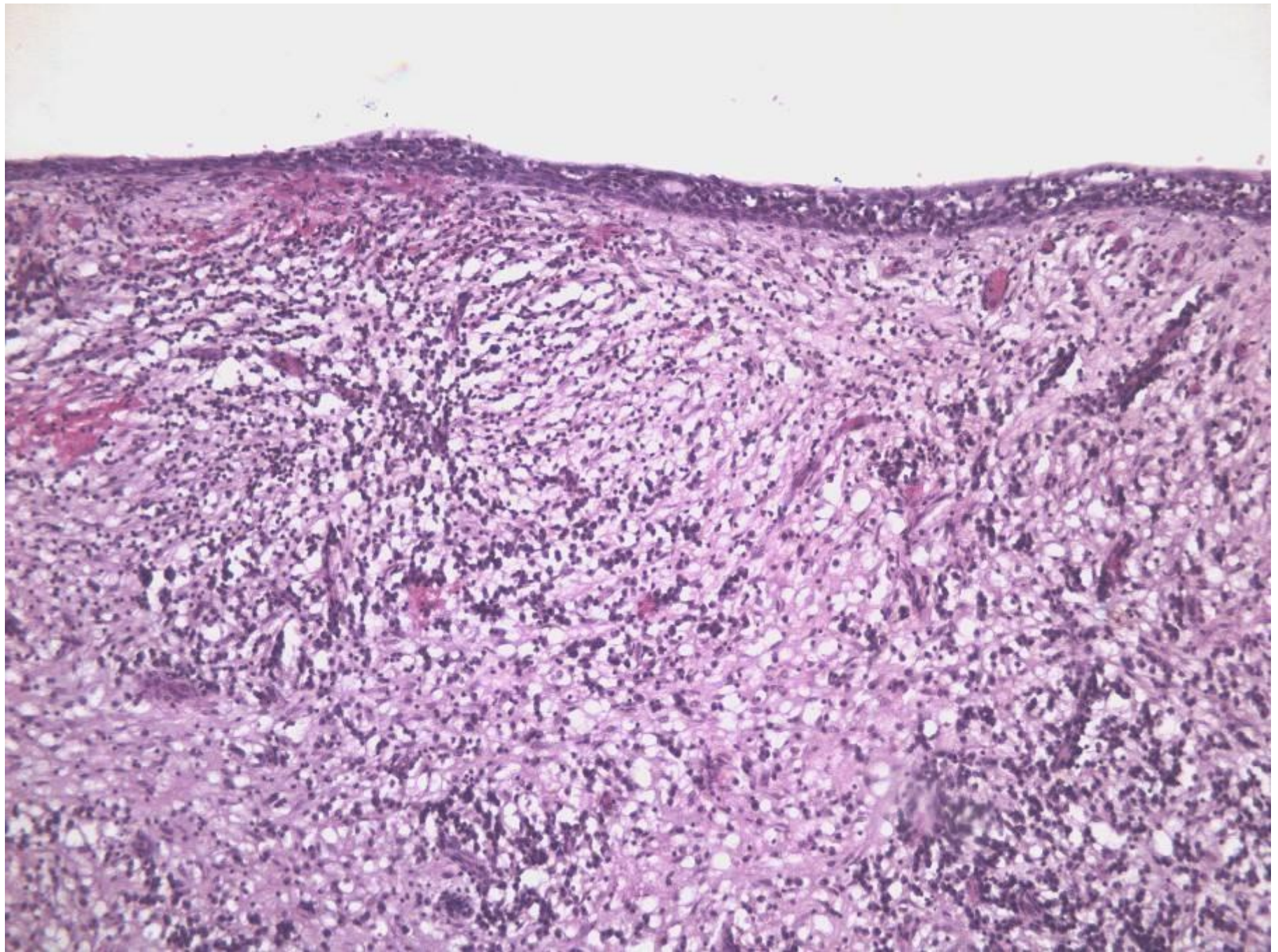
- It develops following the proliferation of Malassez epithelial remnants into a chronic periapical granuloma
- Upholstered with squamous stratified epithelium
- The wall is represented by connective tissue with inflammatory infiltration
- Presence of cholesterol crystals
- Around the capsule there is osteoclastic activity and resorption of the lavelolar bone



Radicular cyst

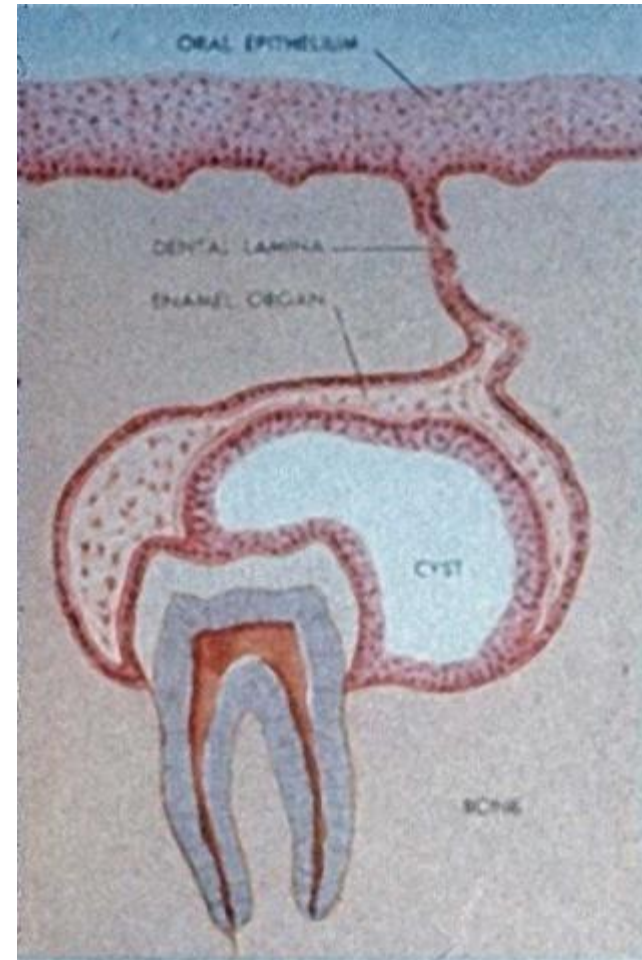
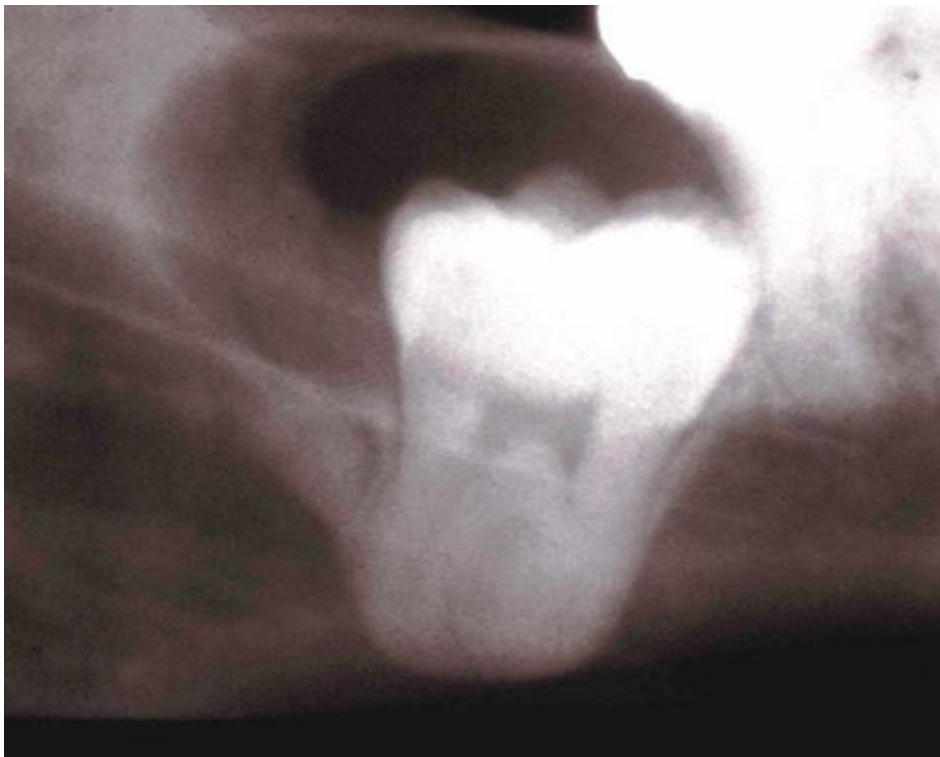






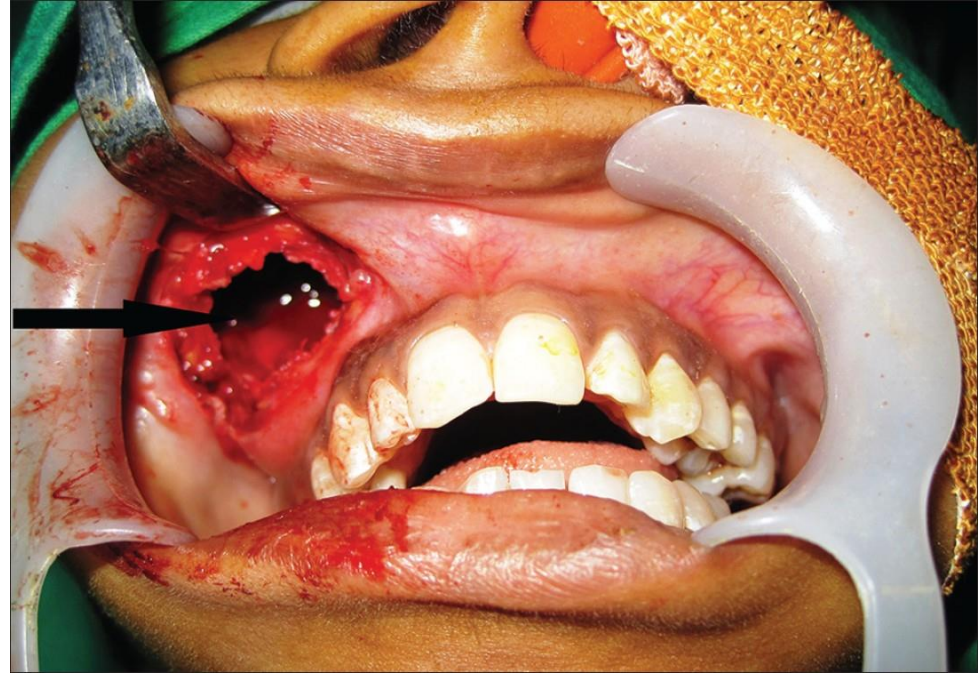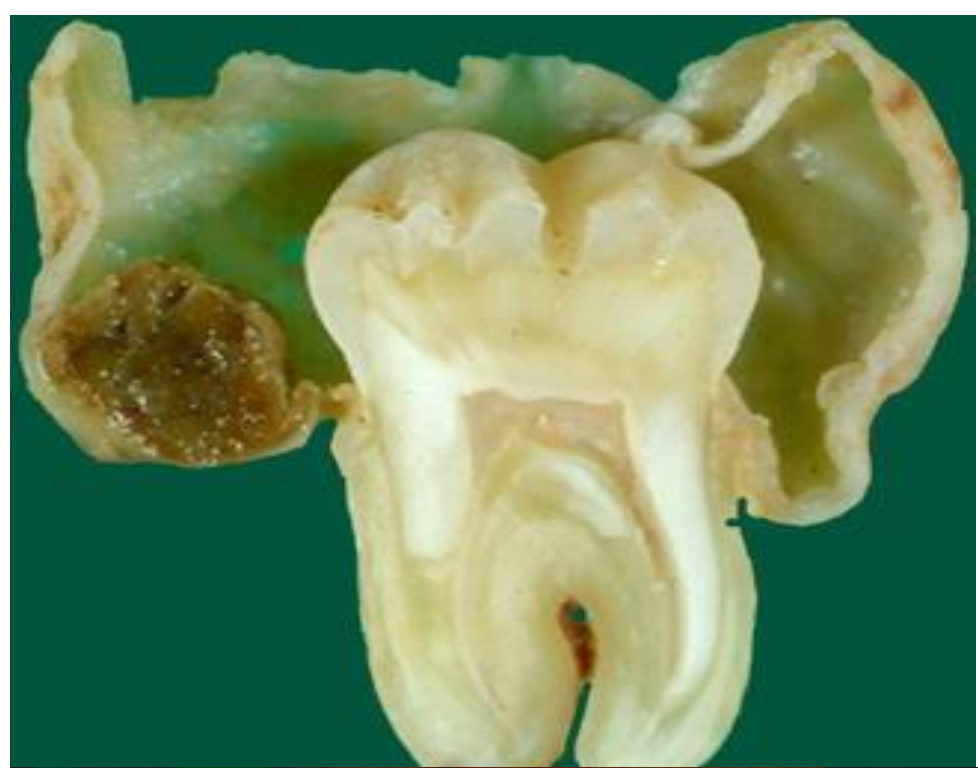Follicular cyst (dentiger)

- It surrounds the crown of an involved tooth
- Origin: reduced enamel epithelium



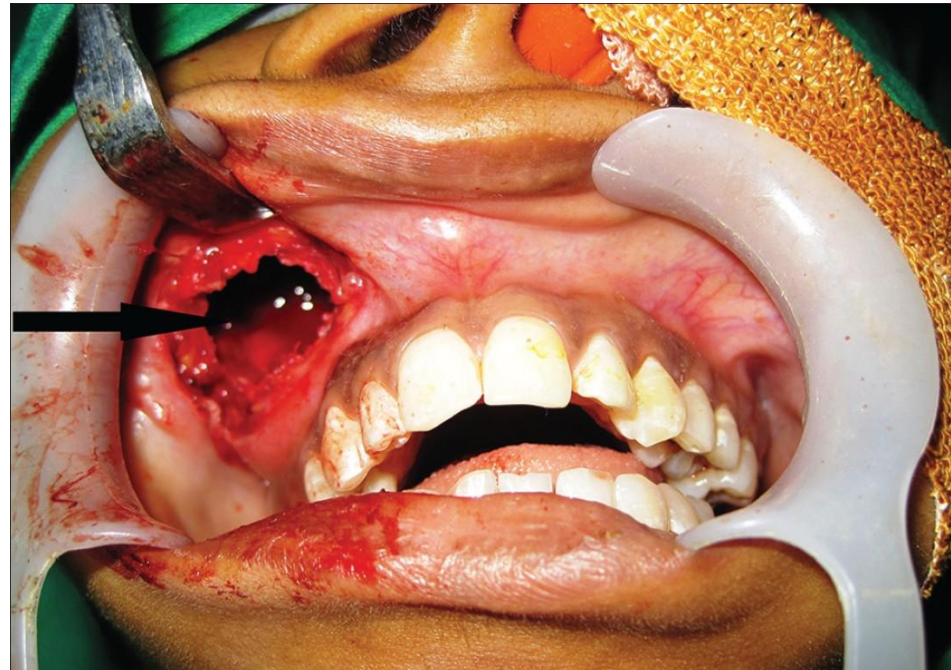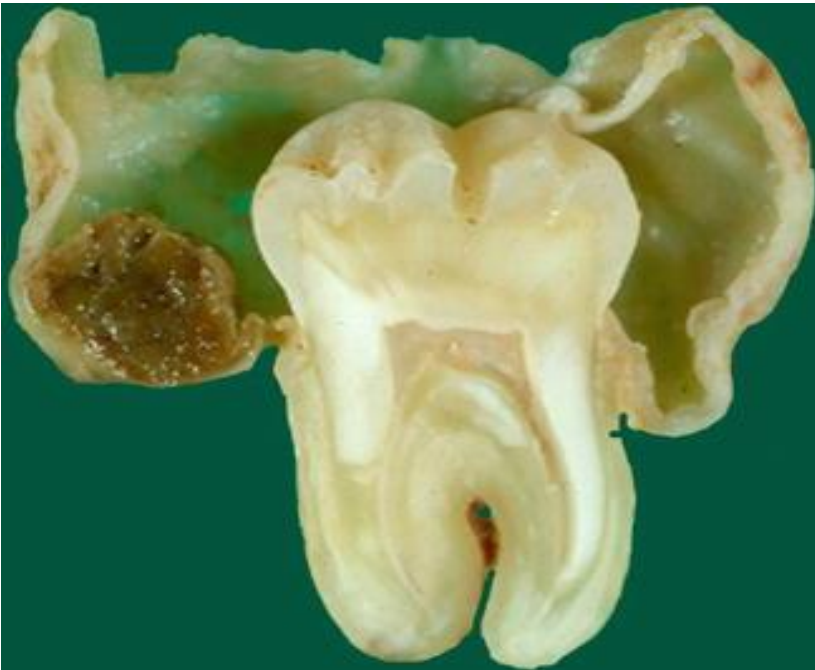Follicular cyst (dentiger)

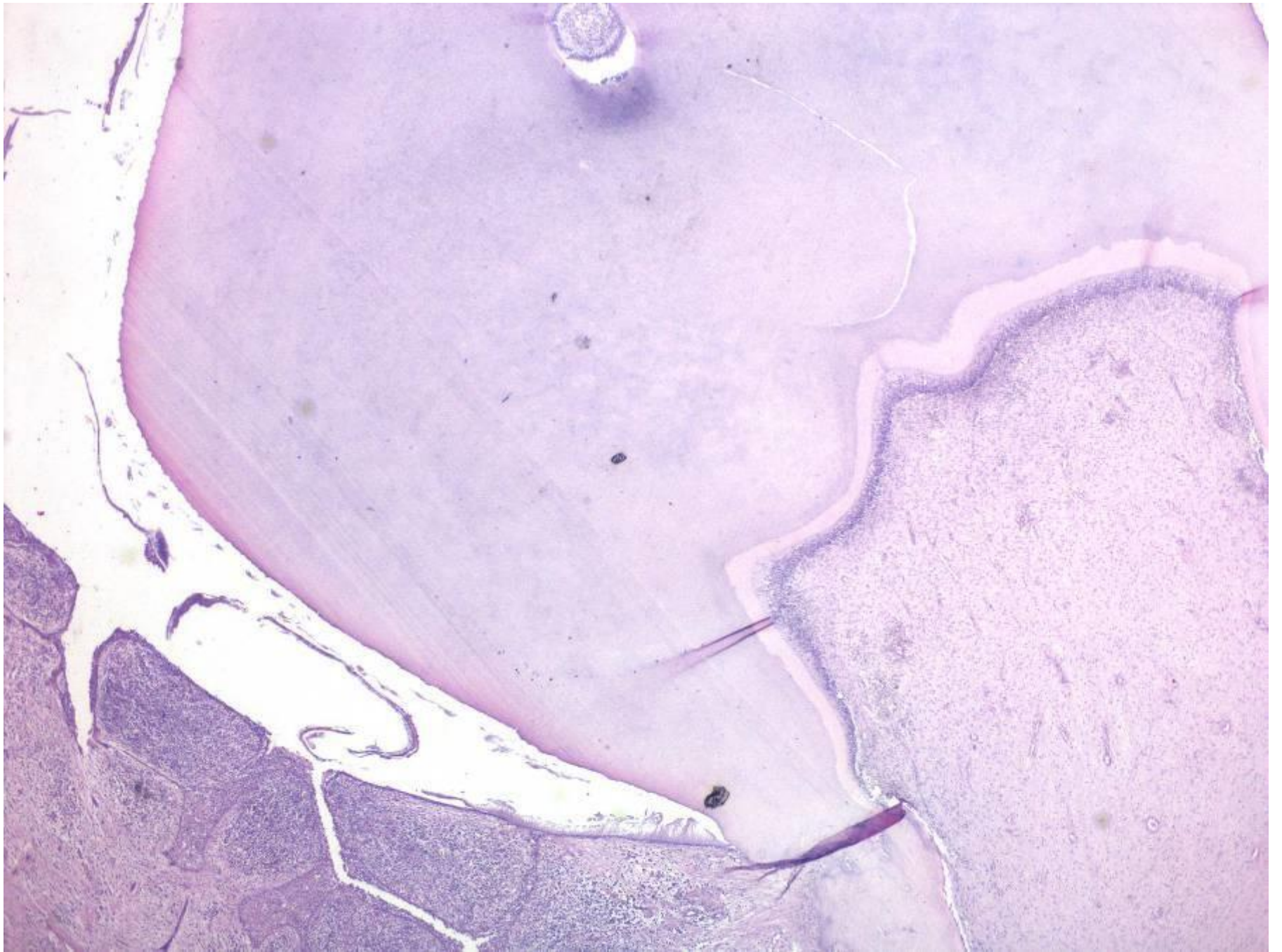
- Relatively common
- It can be large before diagnosis
- Frequency
 - The molars of mind
 - Canines
 - Premolars
 - Meziodens

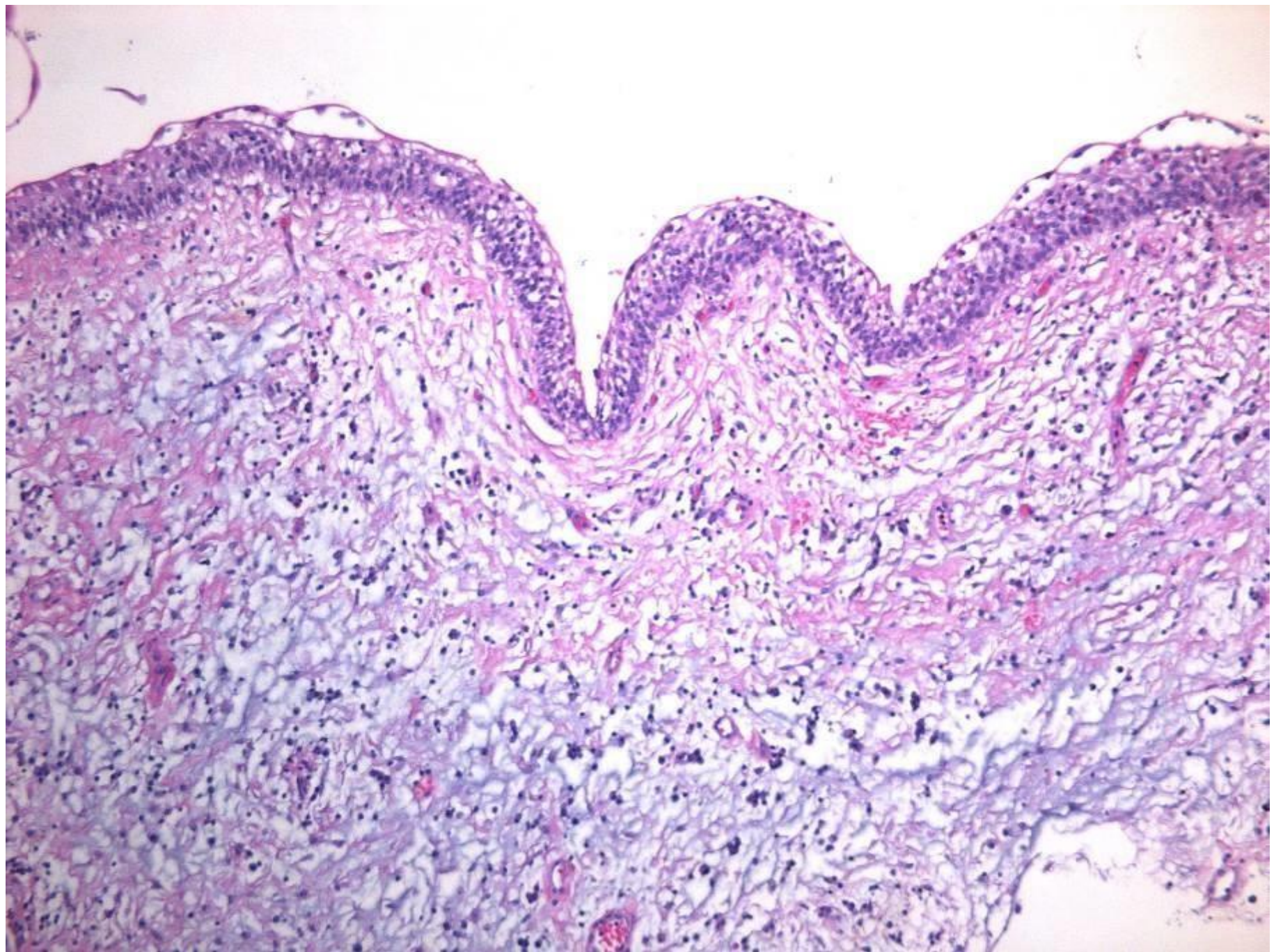


Follicular cyst (dentiger)

- Upholstered with squamous stratified epithelium
- It may represent mucosal metaplasia of the epithelium
- The wall is represented by connective tissue with several inflammatory cells and myxomatosis
- Unique cases of malignant transformation (ameloblastoma)

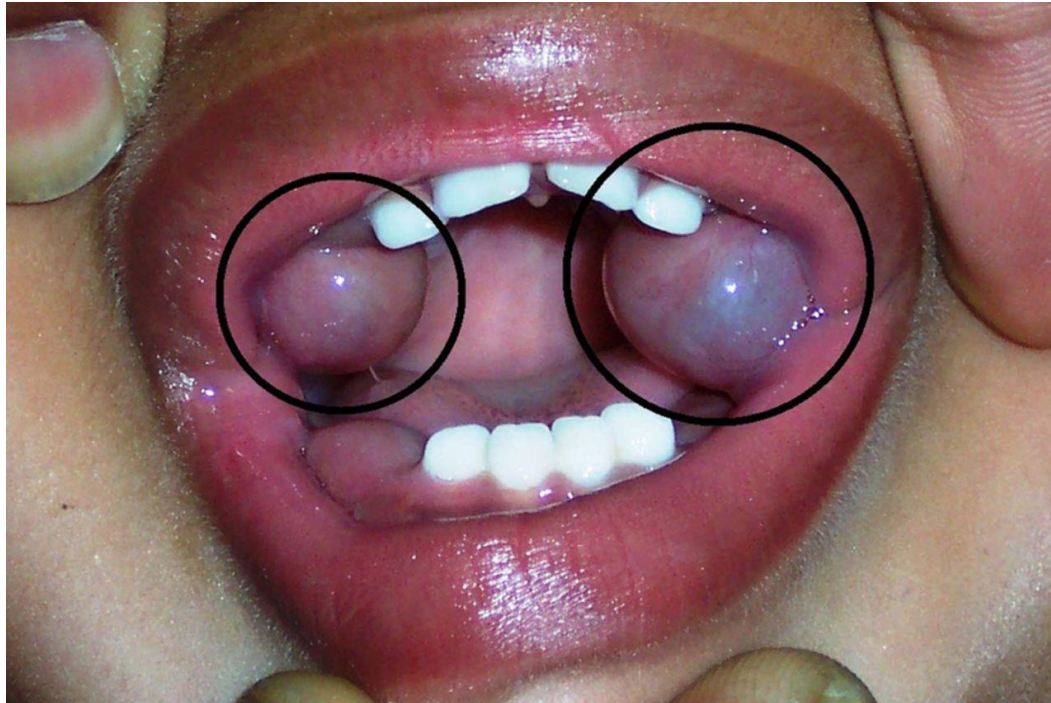






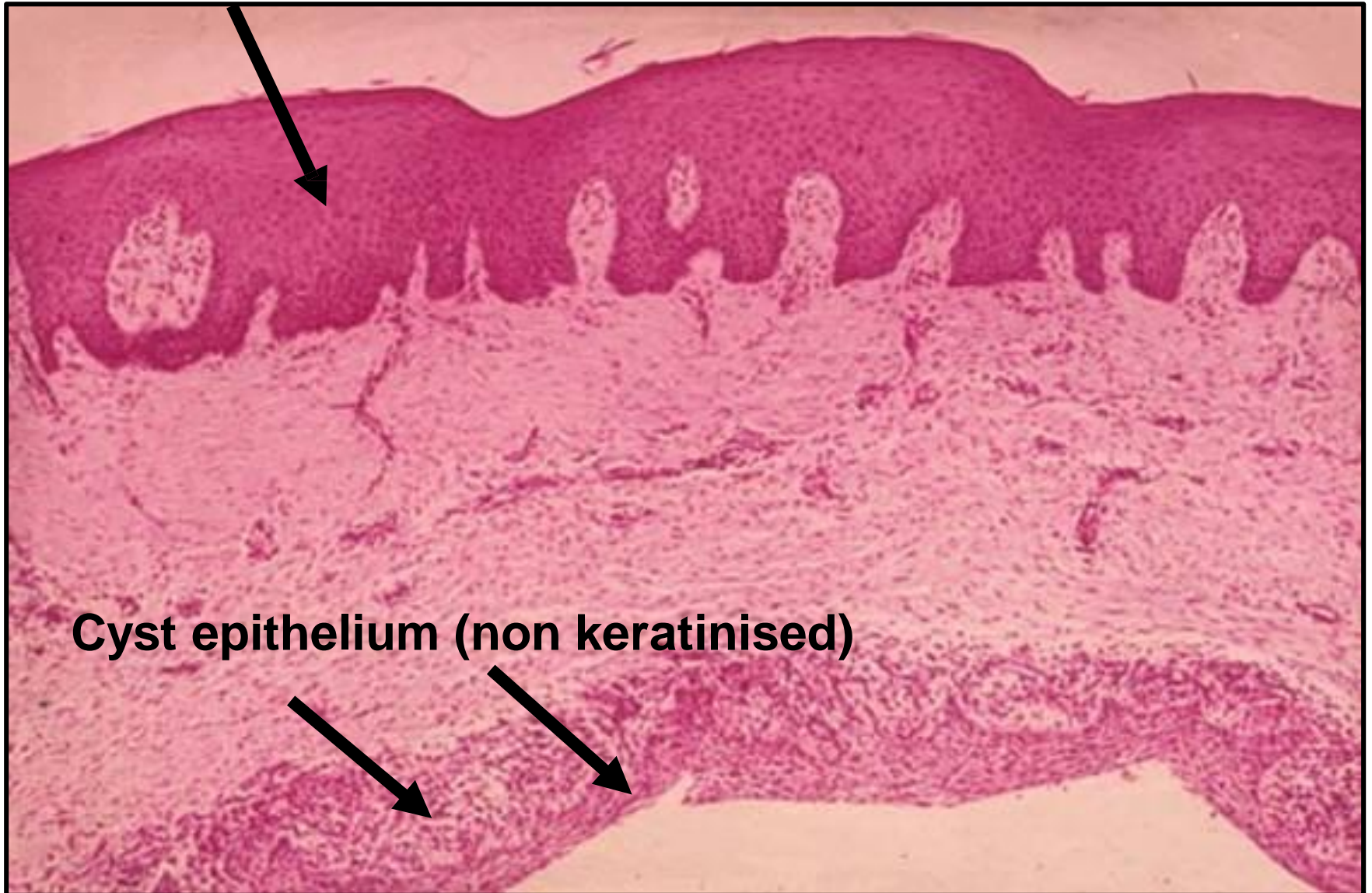
Cyst of eruption

- It has the histological aspect of a follicular cyst that surrounds the crown of a tooth that erupted through but not in the overlying tissues
- It is lined with squamous epithelium, separated from the oral mucosal epithelium by connective tissue
- Since teeth erupt through cysts, they do not require treatment. If spontaneous rupture or infection does not occur, surgical incision is recommended.



Cyst of eruption

Surface epithelium (parakeratinised)

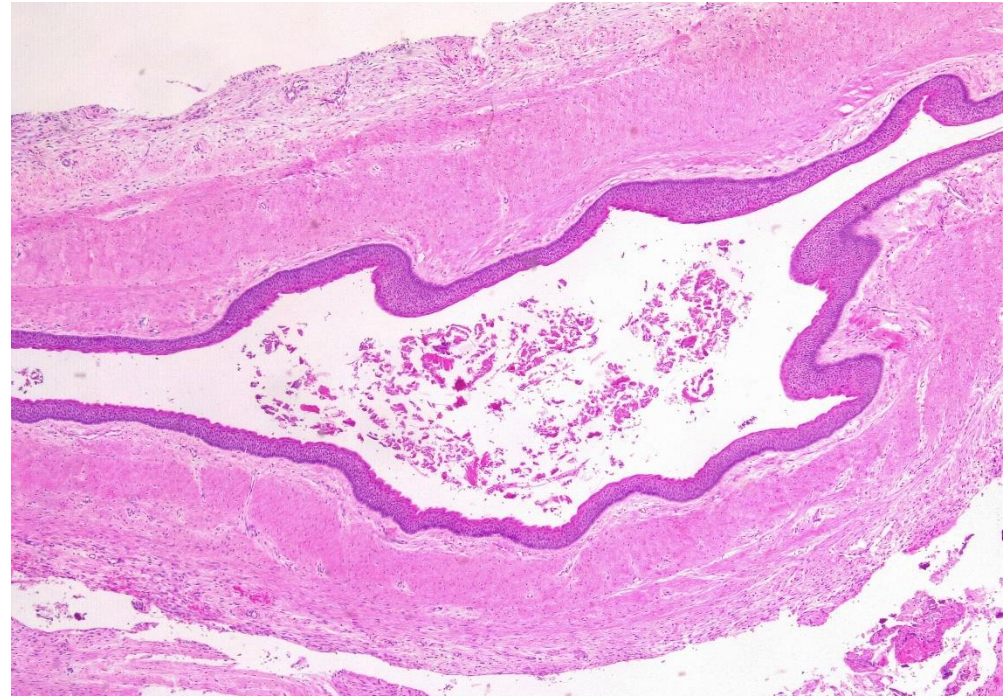


Odontogenic keratocyst (parakeratinised) (keratocystic odontogenic tumor)

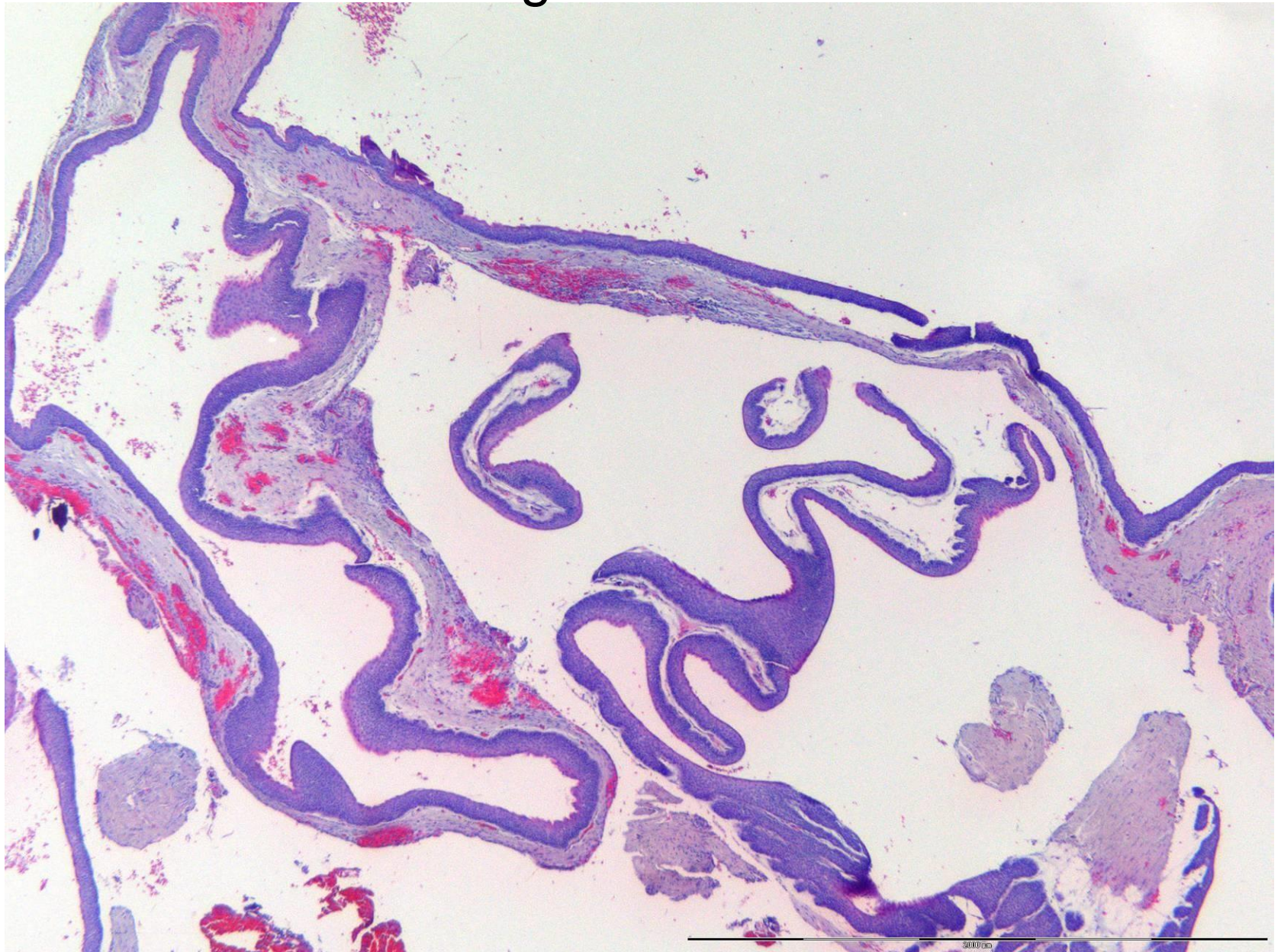
- WHO 2005: odontogenic tumor
- WHO 2017: odontogenic cysts
- It most often occurs in the mandibular angular region
- multilocular
- High recurrence rate
- It can be large
- Differential diagnosis (x-ray): ameloblastoma

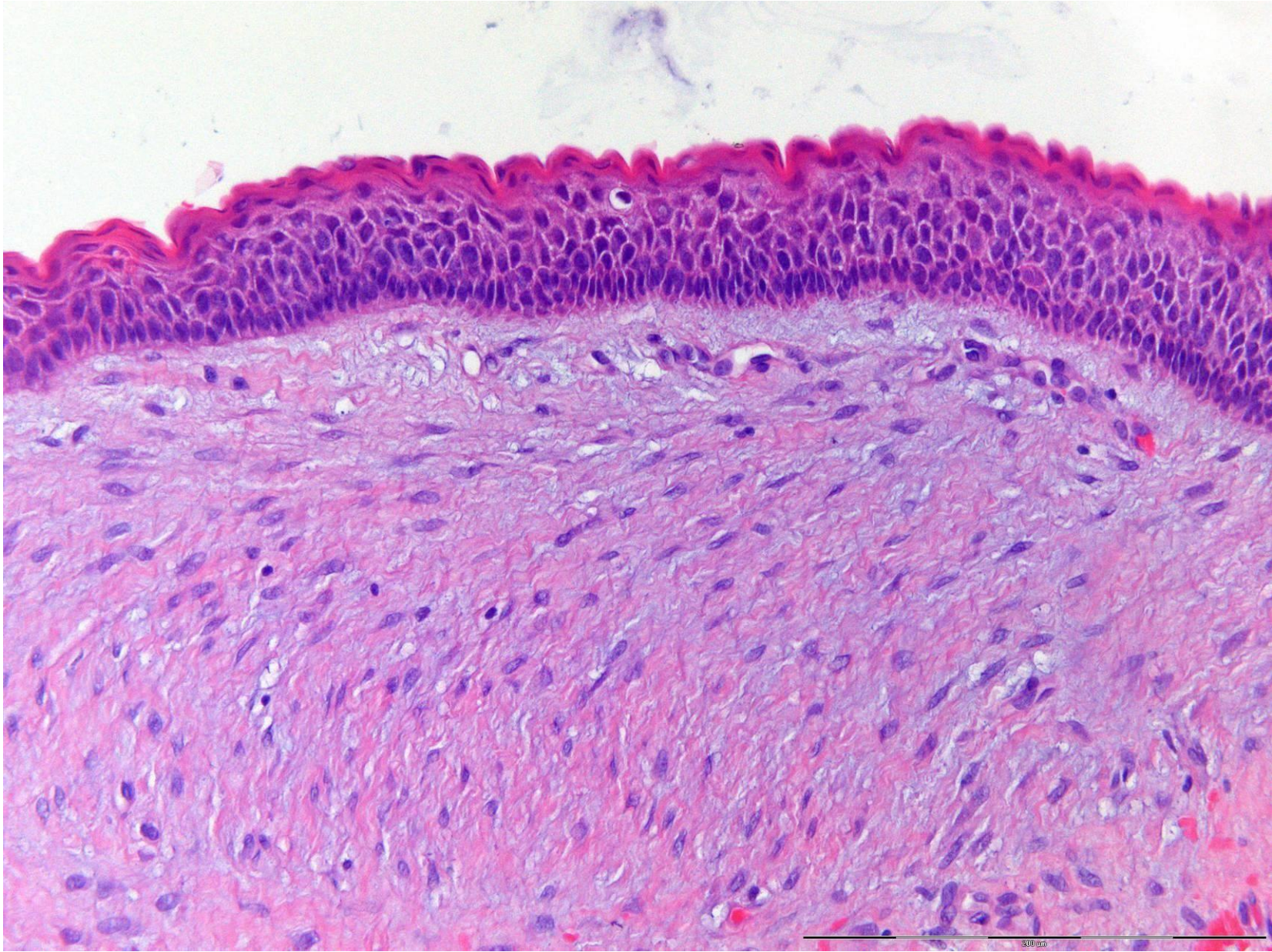
Odontogenic keratocyst

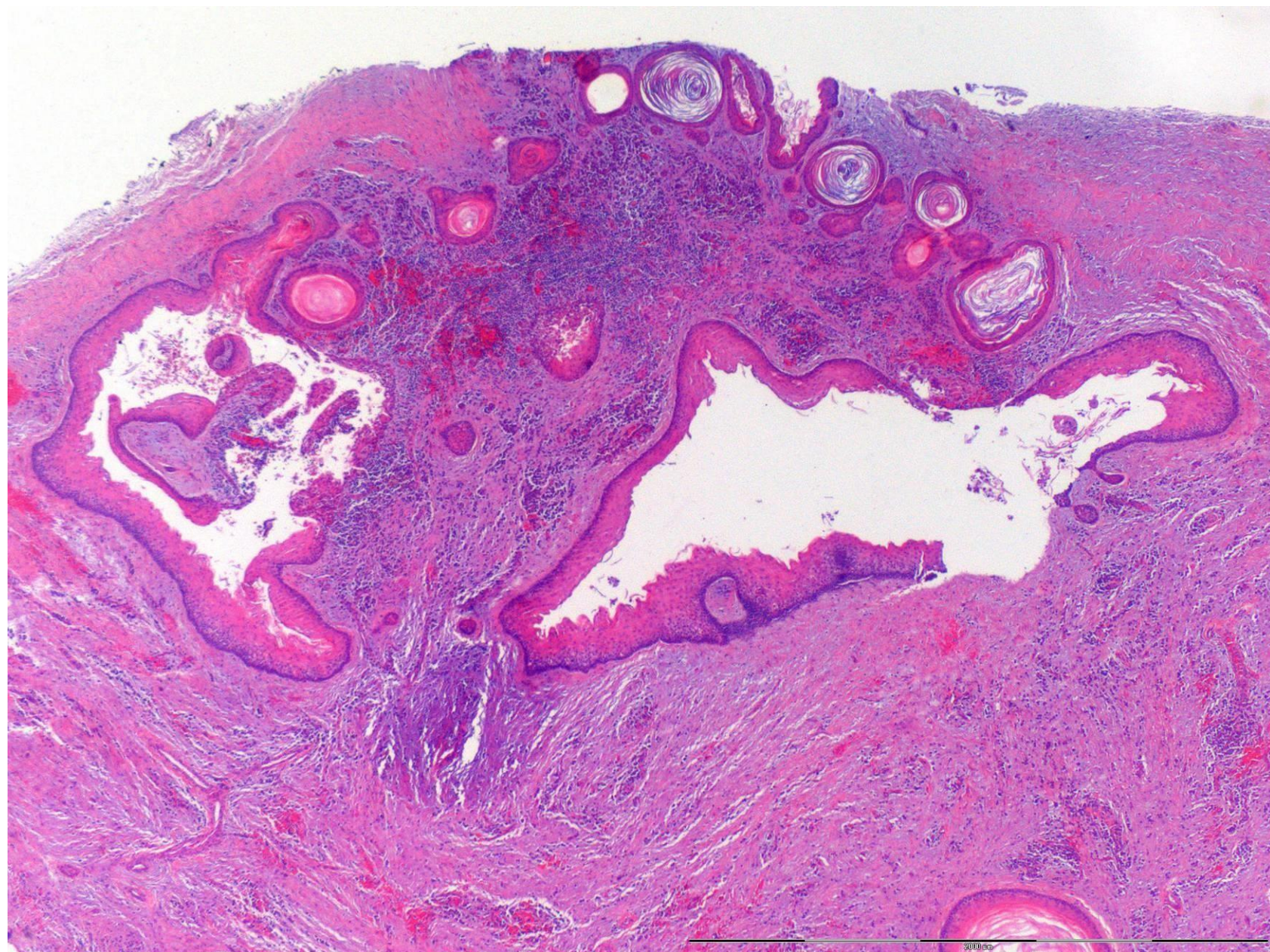
- It develops from the odontogenic epithelium (the dental lamina and its remnants, and from the extensions of the basal layer of the covering epithelium)
- It is lined with parakeratinized squamous epithelium
- There is a basal layer with palisade consisting of columnar or cuboid cells
- A variable amount of keratin is present in the lumen
- It has the potential for malignancy

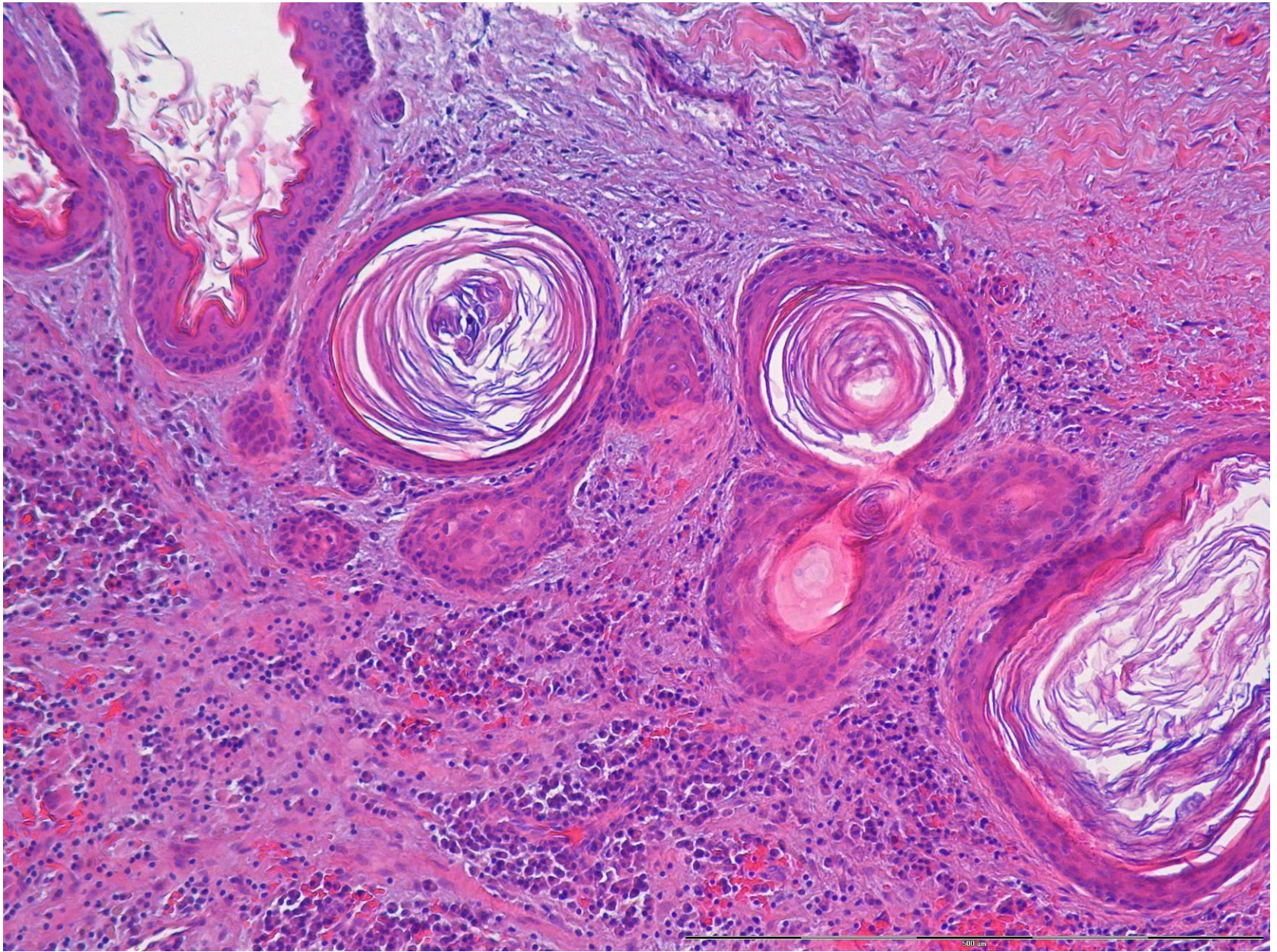


Odontogenic keratocyst

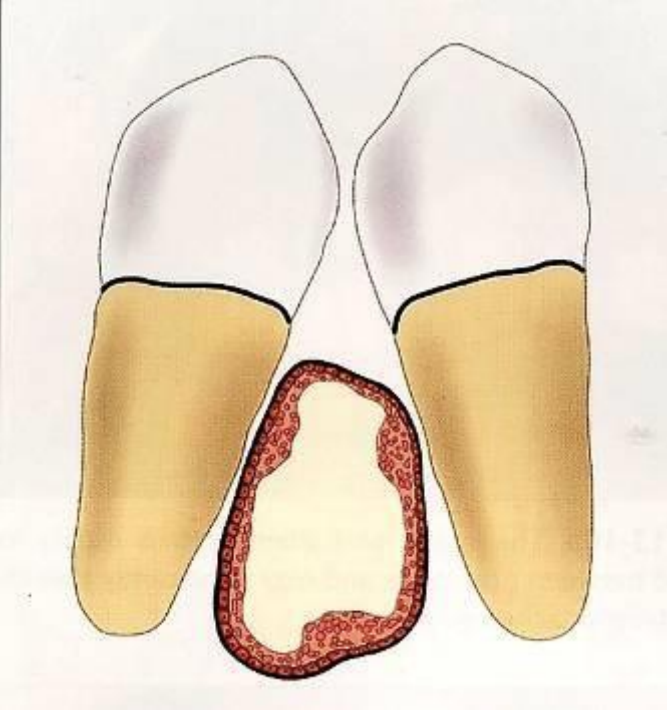




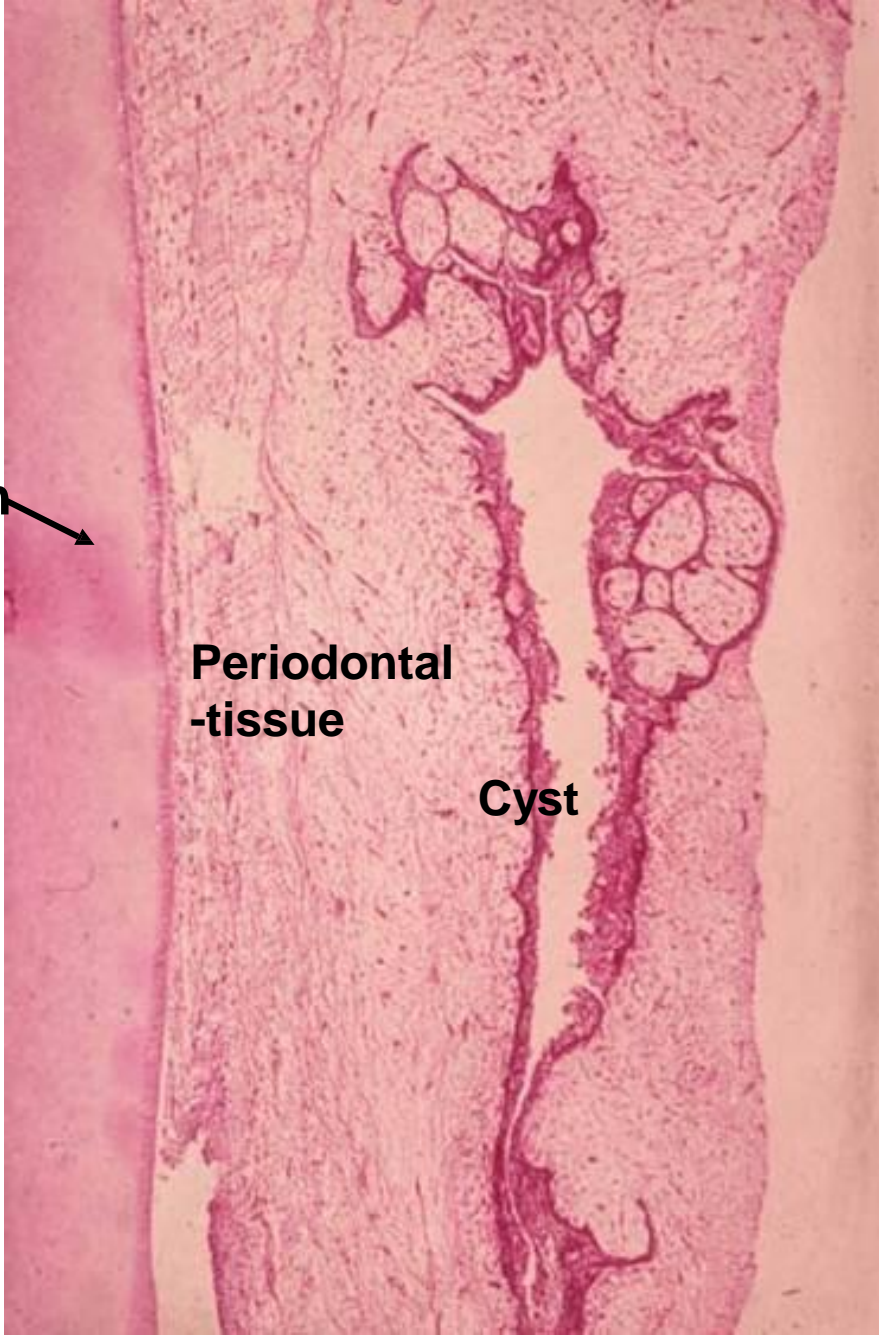




Lateral periodontal cyst



Tooth



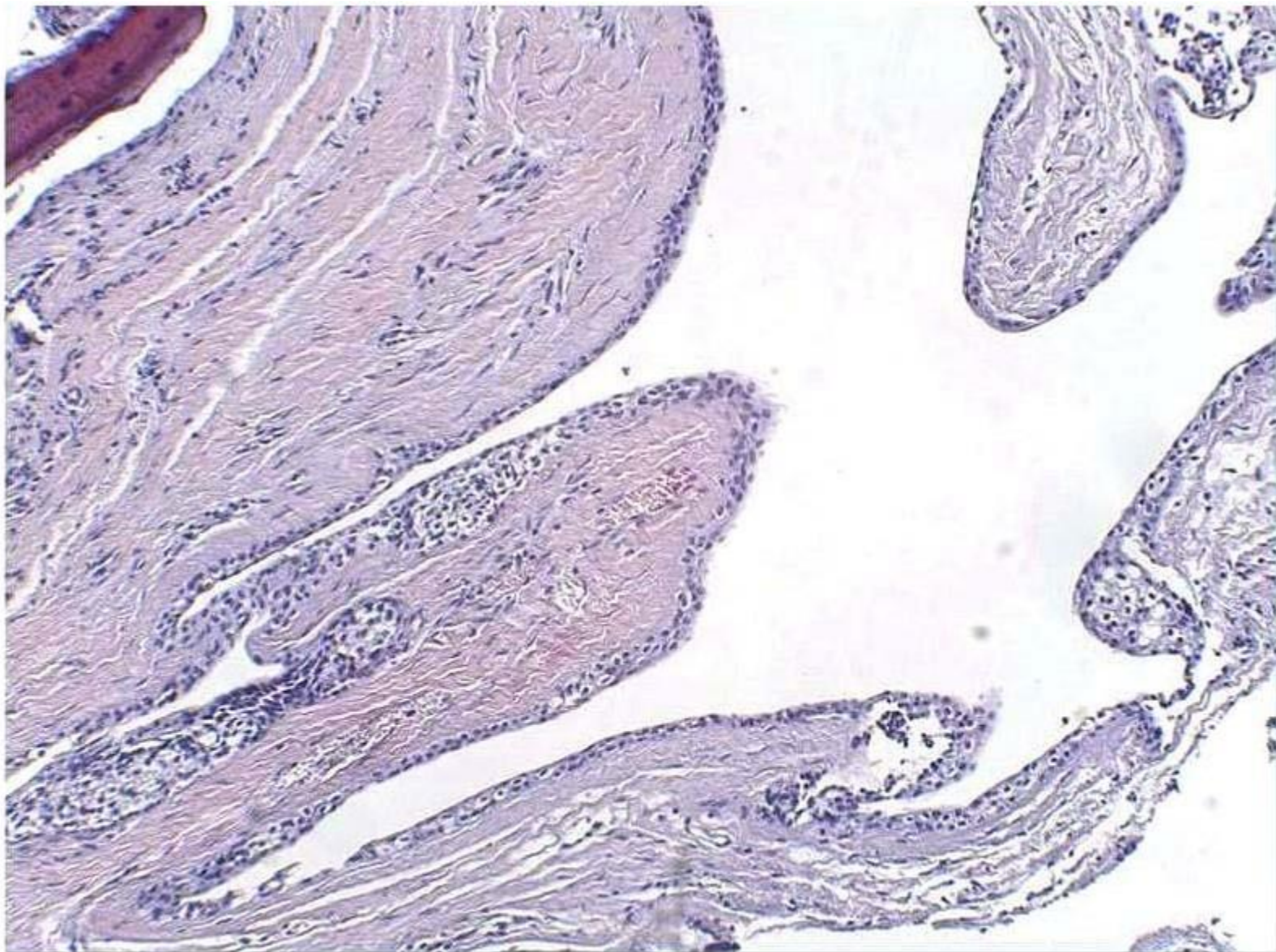
Periodontal-tissue

Cyst

Lateral periodontal cyst

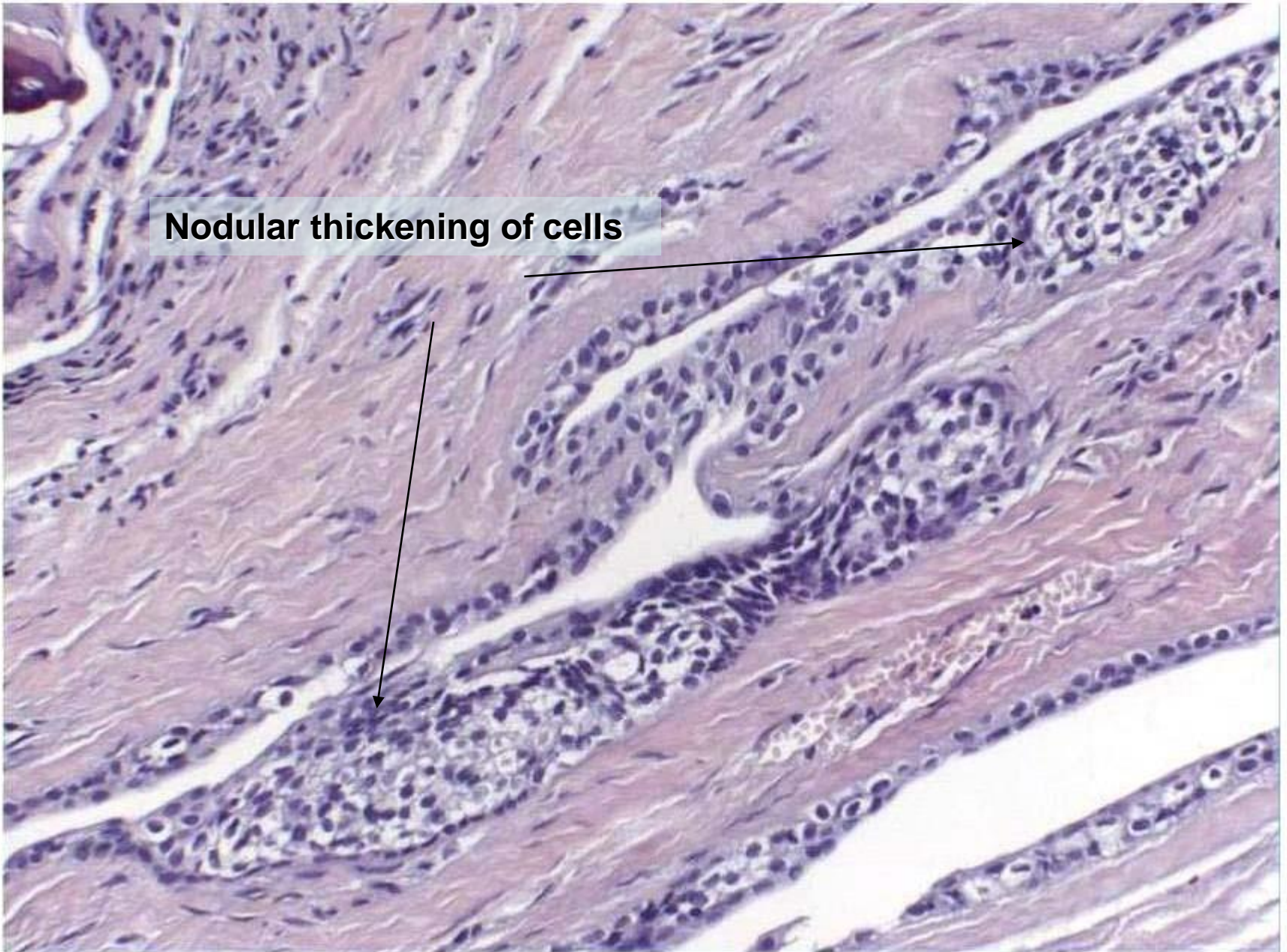
- Cyst of development arises from epithelial debris that persists after the degradation of the dental lamina
- Slow growth does not recur
- The bulky ones induce bone defects of the jaws involved
- Elution treatment of its enucleation without the extraction of the adjacent tooth

Lateral periodontal cyst



Thin epithelium, non-keratinized
focal nodular thickening

Lateral periodontal cyst

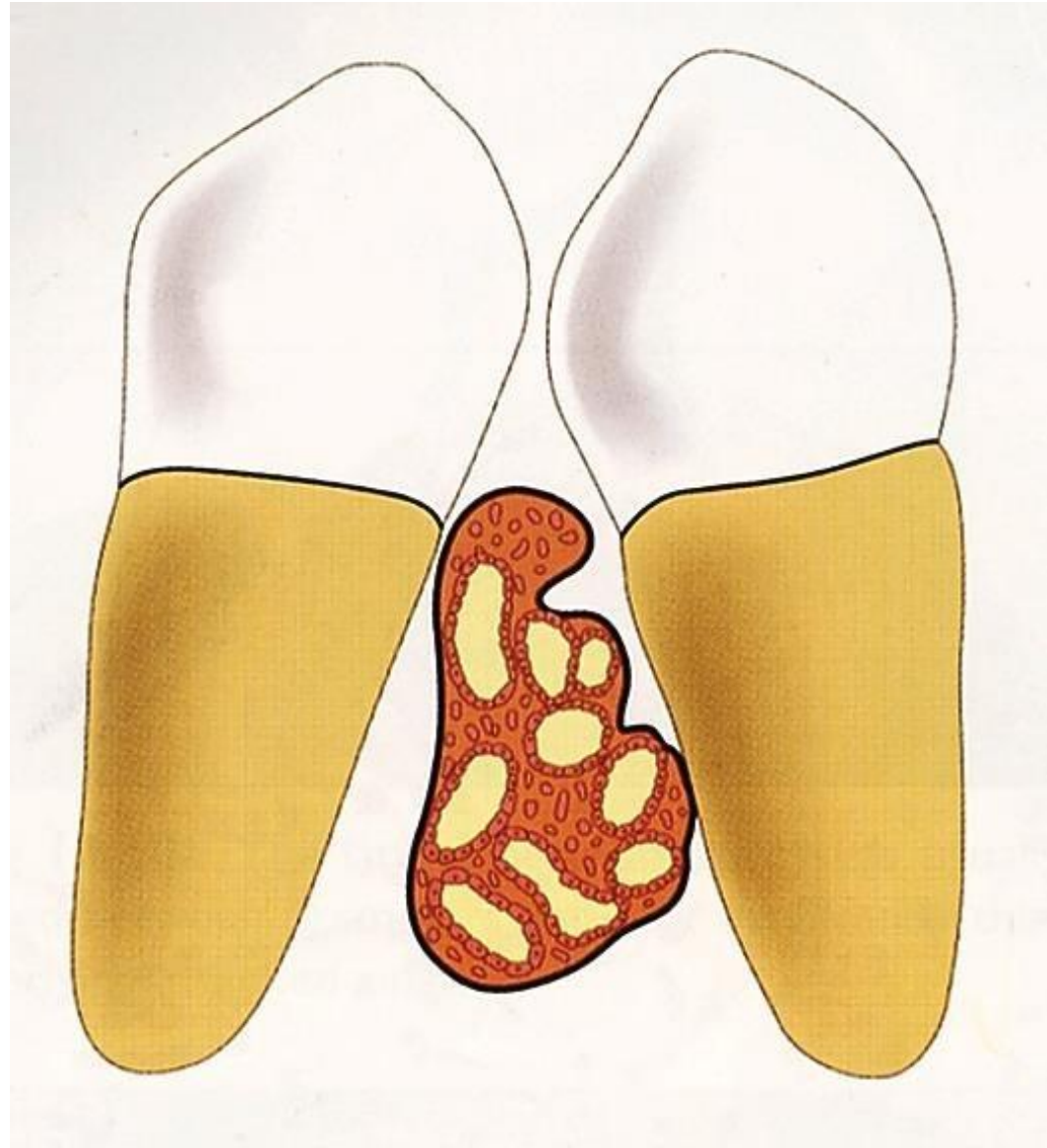


Botryoid cyst

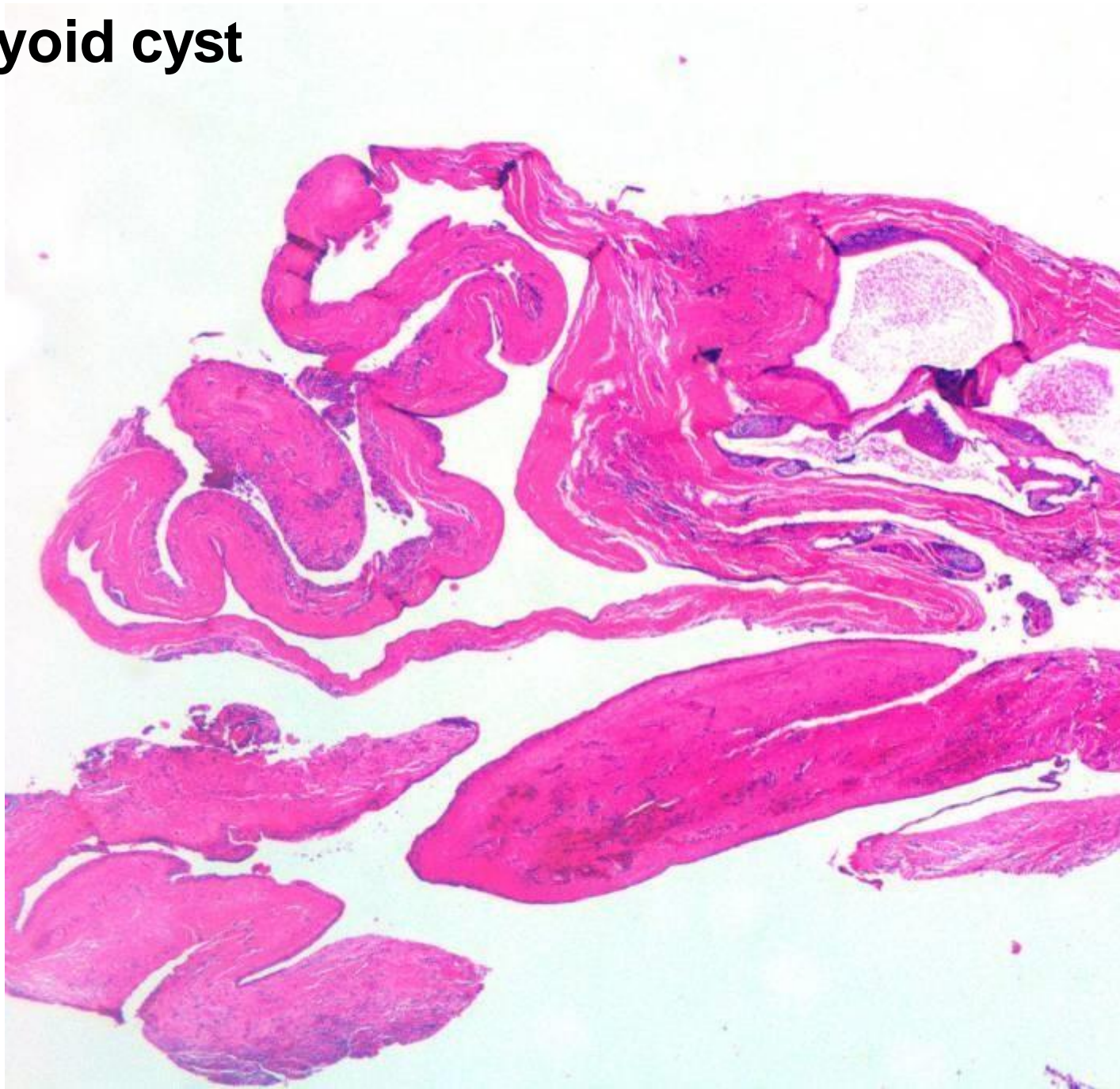
**Multilocular variant
of the lateral
periodontal cyst**

**Radiological has a
multichistic aspect**

**Locally aggressive and
relapsing**



Botryoid cyst

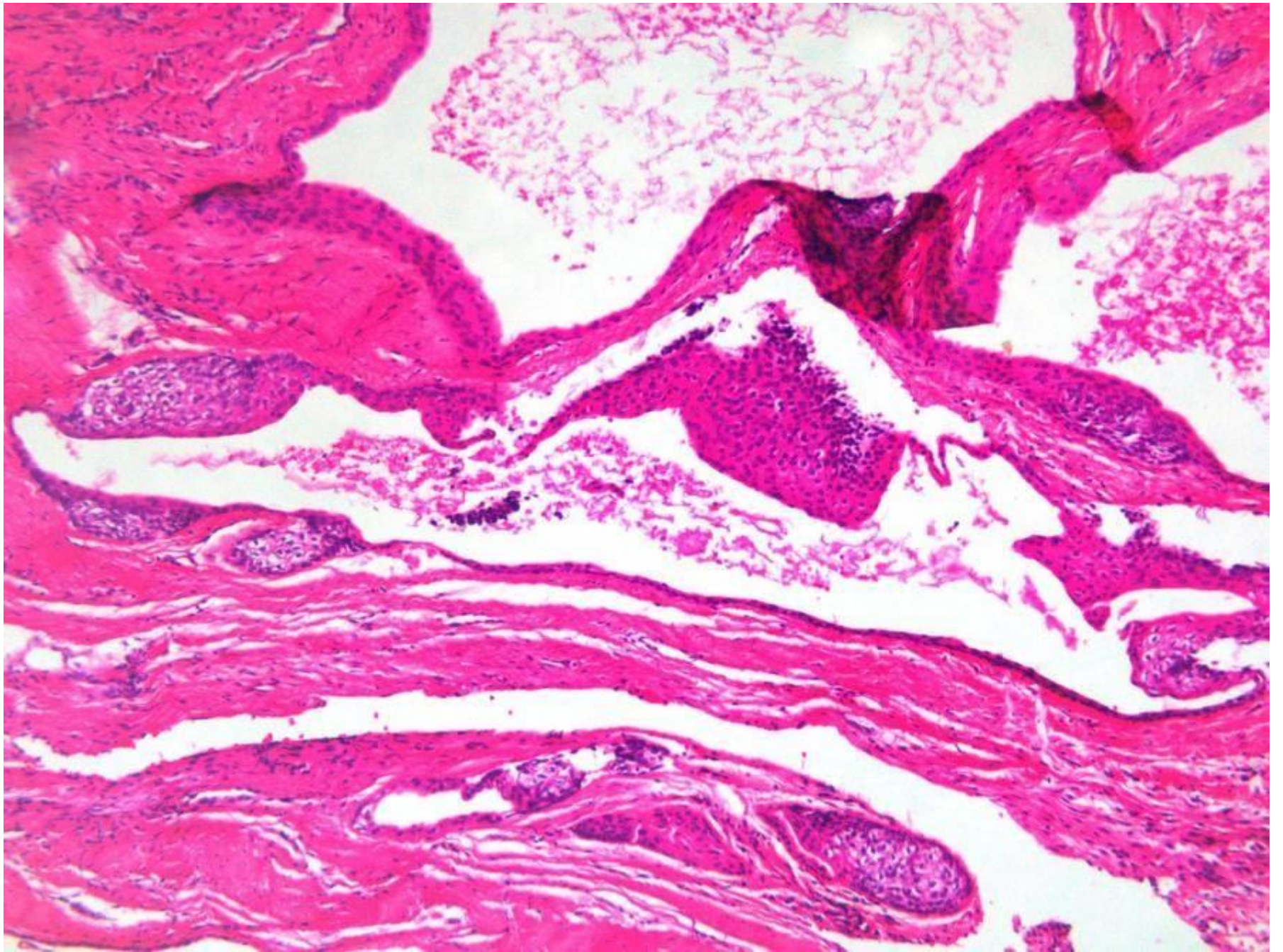


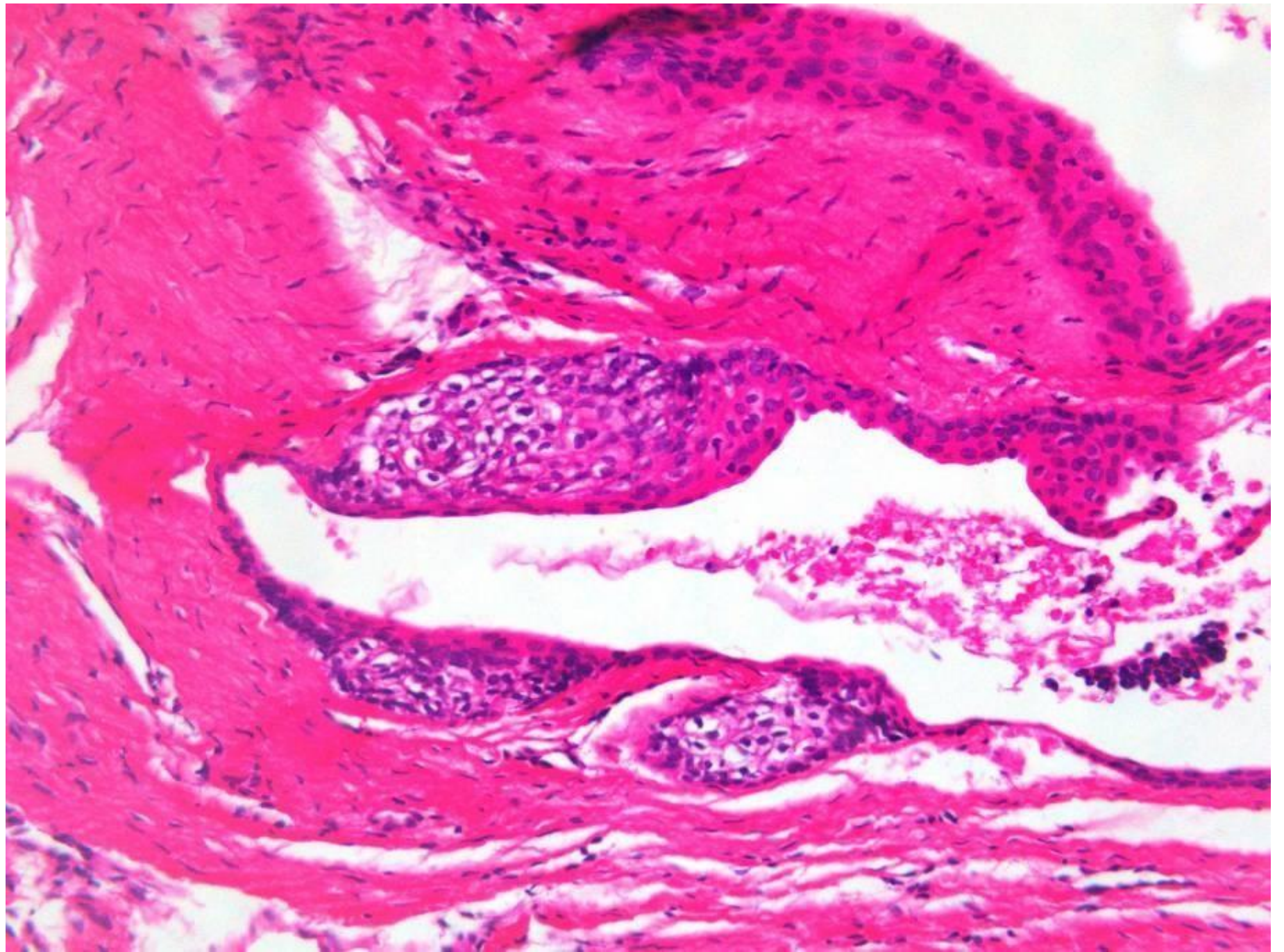
Botryoid cyst

- The polycystic aspect is due to the proliferation and cystic changes that have occurred in several epithelial remains.
- Identical to the lateral periodontal cyst, the only difference being the multicystic character
- Due to the recurrent character, interventions such as excision and not enucleation are recommended.
- Radiological surveillance is required for a minimum of 10 years

Botryoid cyst

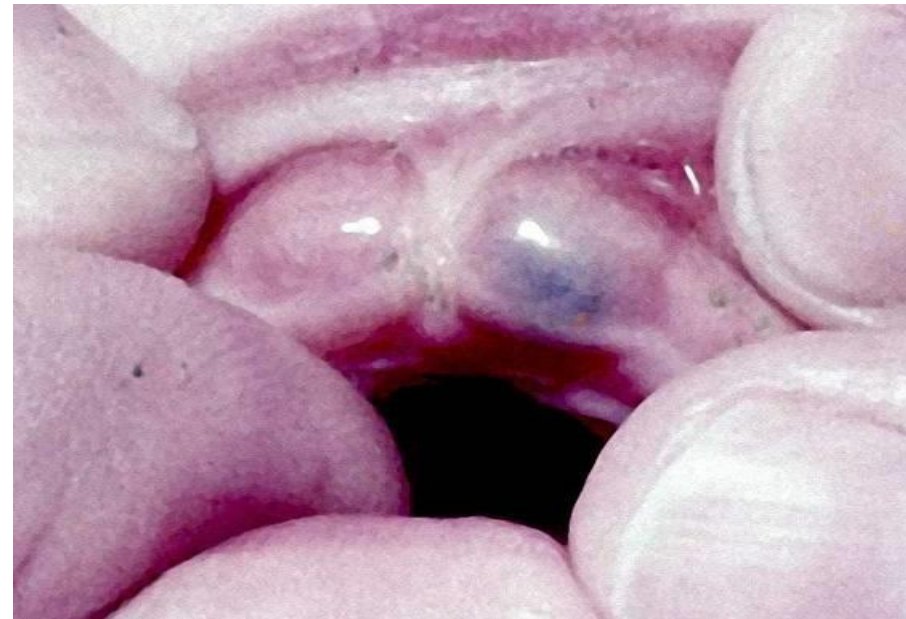- The recurring character can be explained by:
 - incomplete removal of the lesion with many compartments
 - persistence of odontogenic epithelial remains in the connective tissue adjacent to the distant cyst.



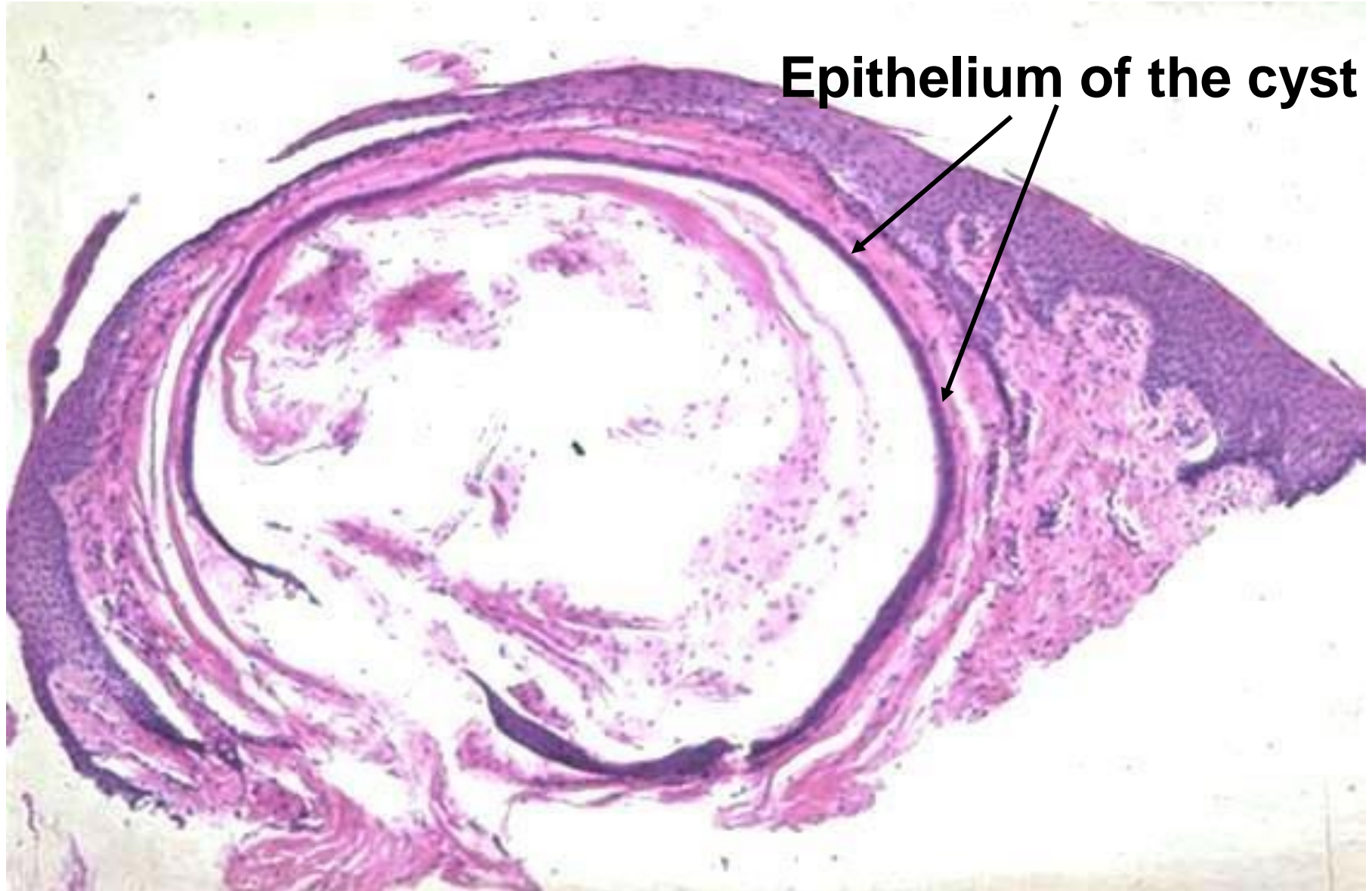


Gingival cyst of the newborn

- Microcyst developed superficially, subepithelially on the alveolar ridge from the remnants of the dental lamina
- Treatment is not recommended as the lesion involuntarily or breaks spontaneously in the oral cavity

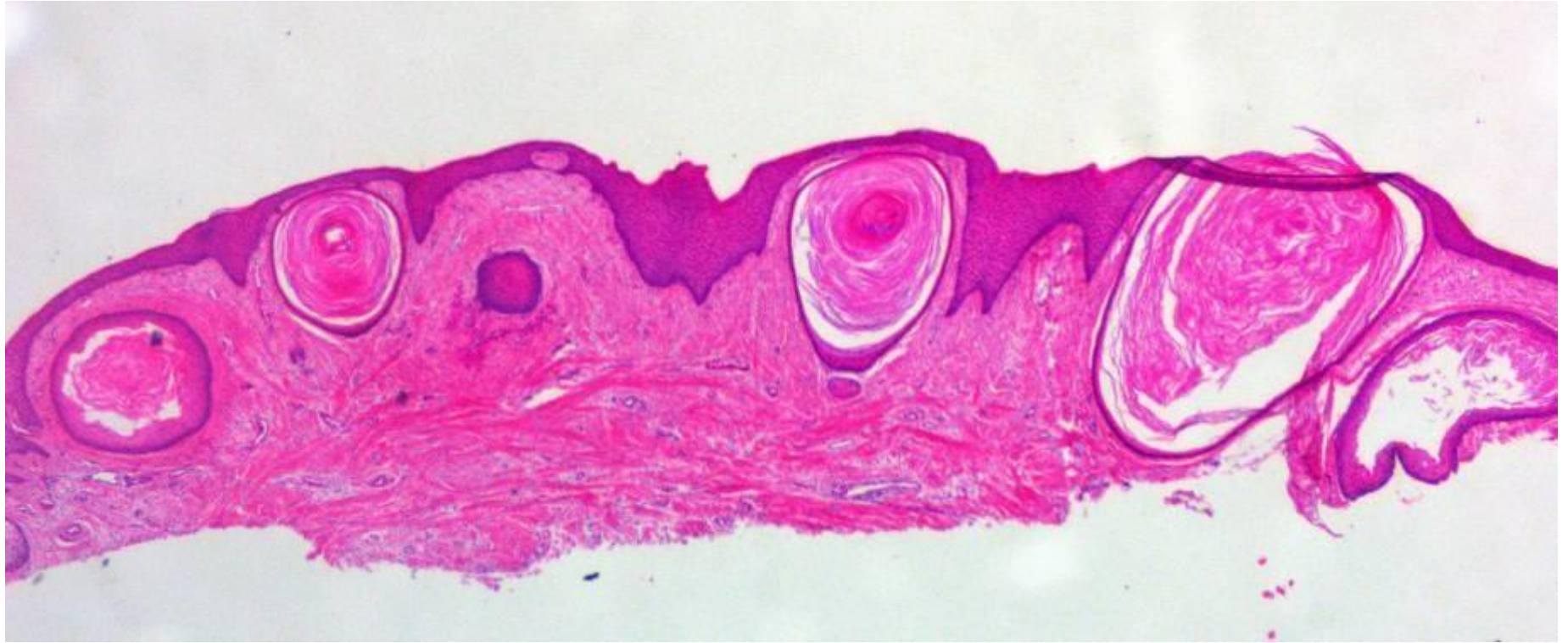

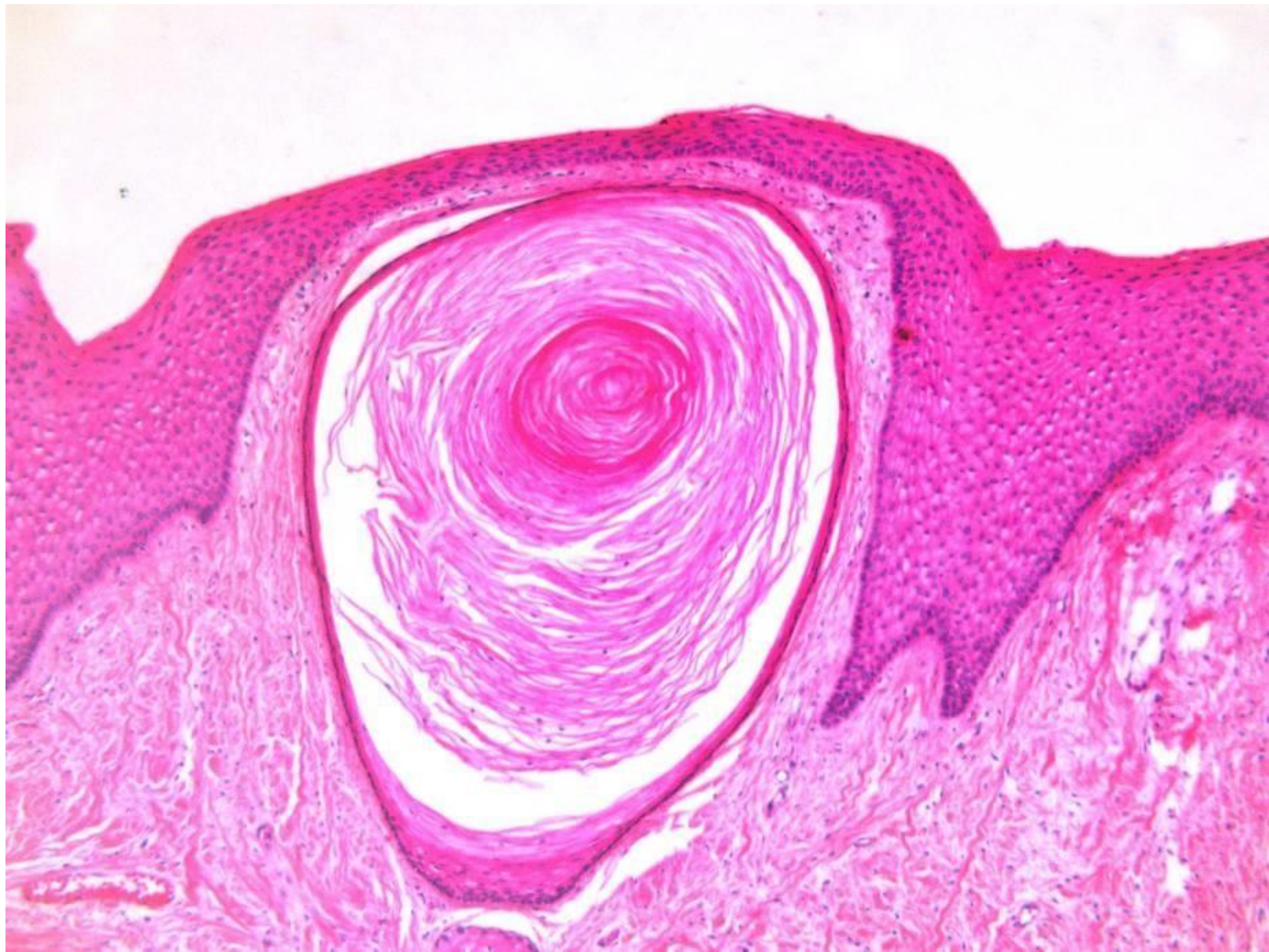
It is lined by a squamous epithelium presenting a flattened basal layer and parakeratinized surface. The lumen contains keratin.

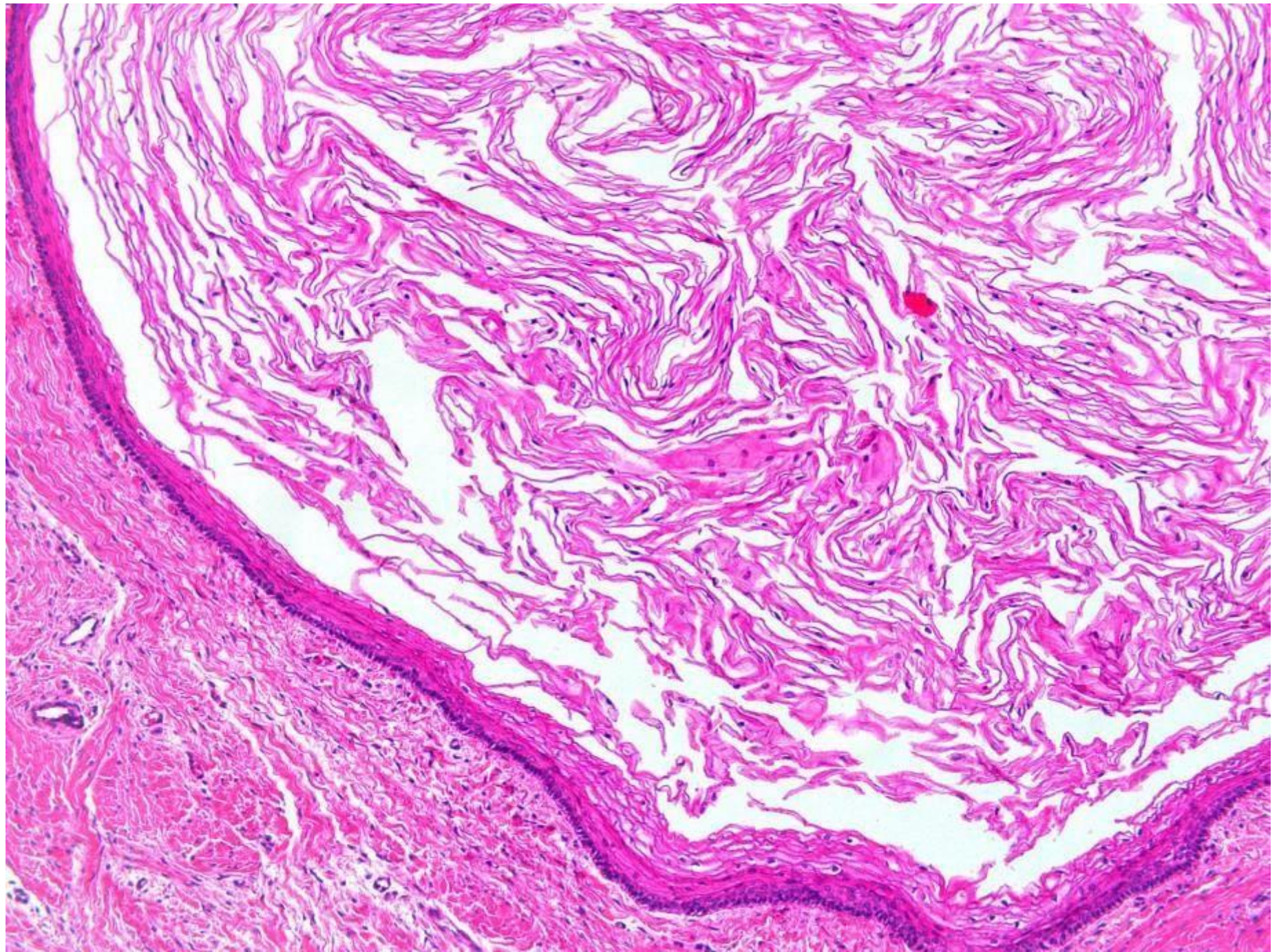


Adult gingival cyst

- Rare
- In soft tissues (gum)
- Little, no symptoms
- In the jaw, canines - premolars
- 50 - 70 years
- Surgical excision
- Don't relapse



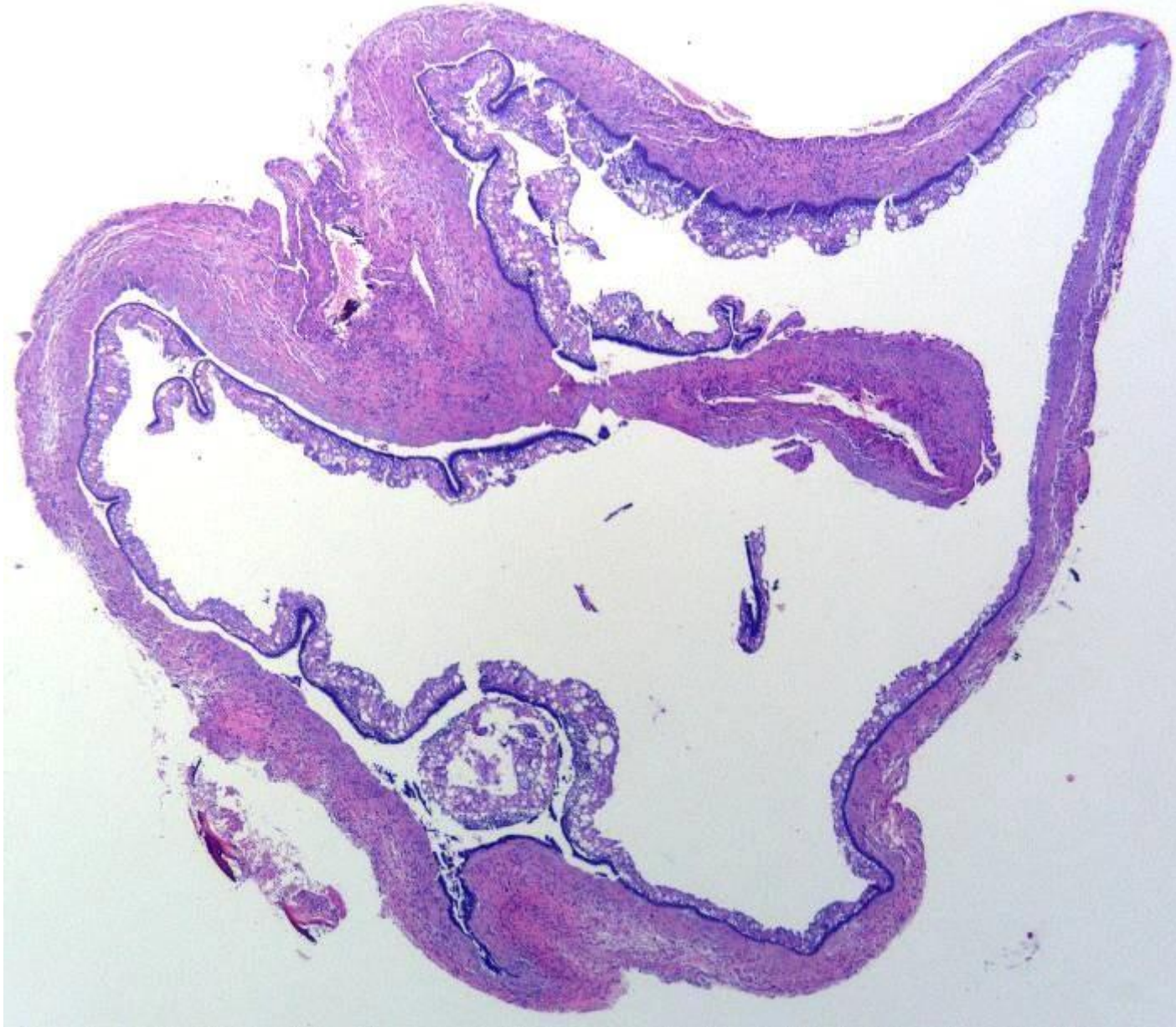




Chist odontogen glandular

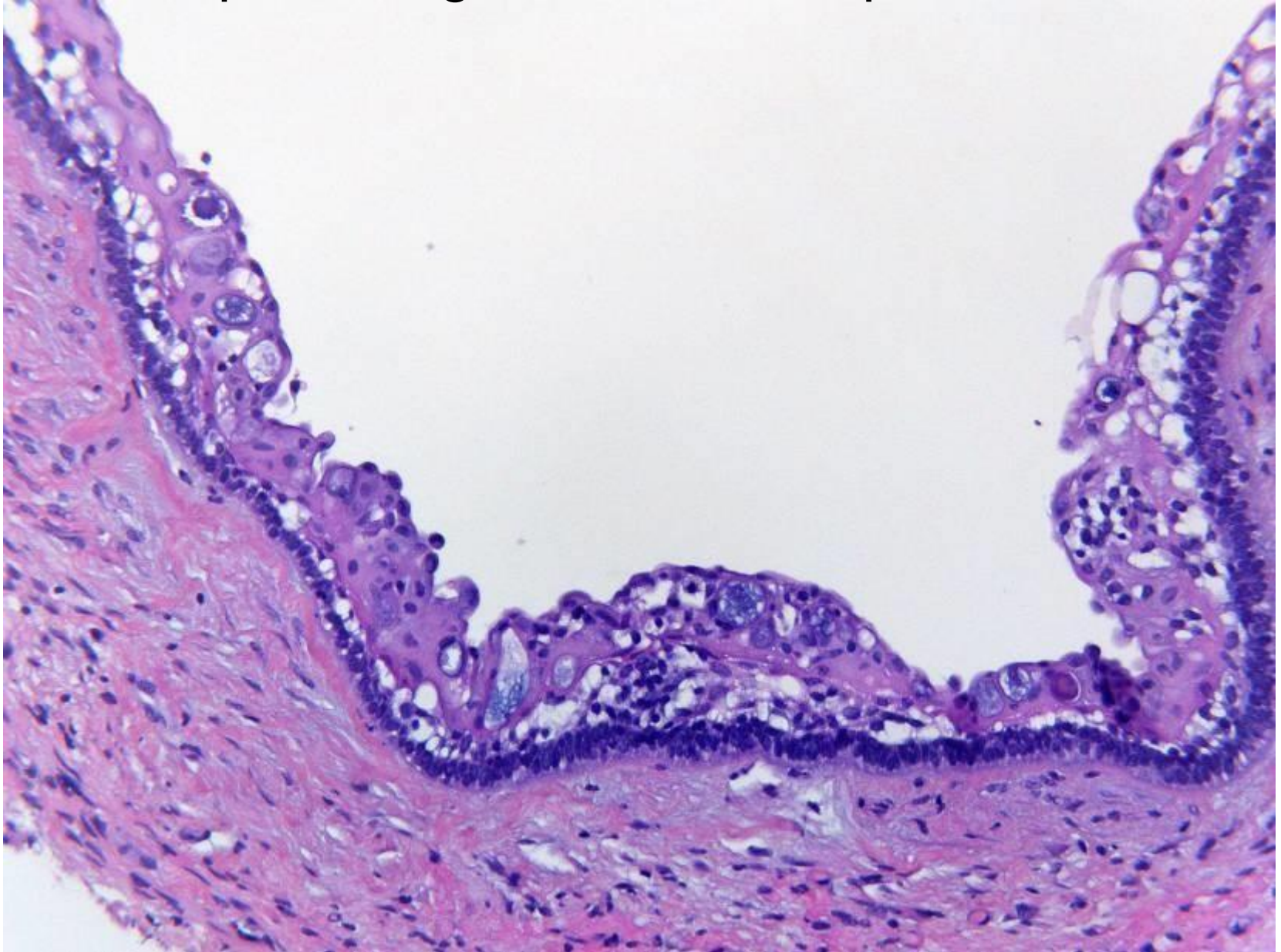
- Enitiate din 1987
- Rar
 - Intraosos la nivelul mandibulei, mai ales în partea sa anterioară
- X-ray: multilocular
- Probabil din lamina dentară
- 25 % rata recurenței → perioadă lungă de supraveghere

Glandular odontogenic cyst

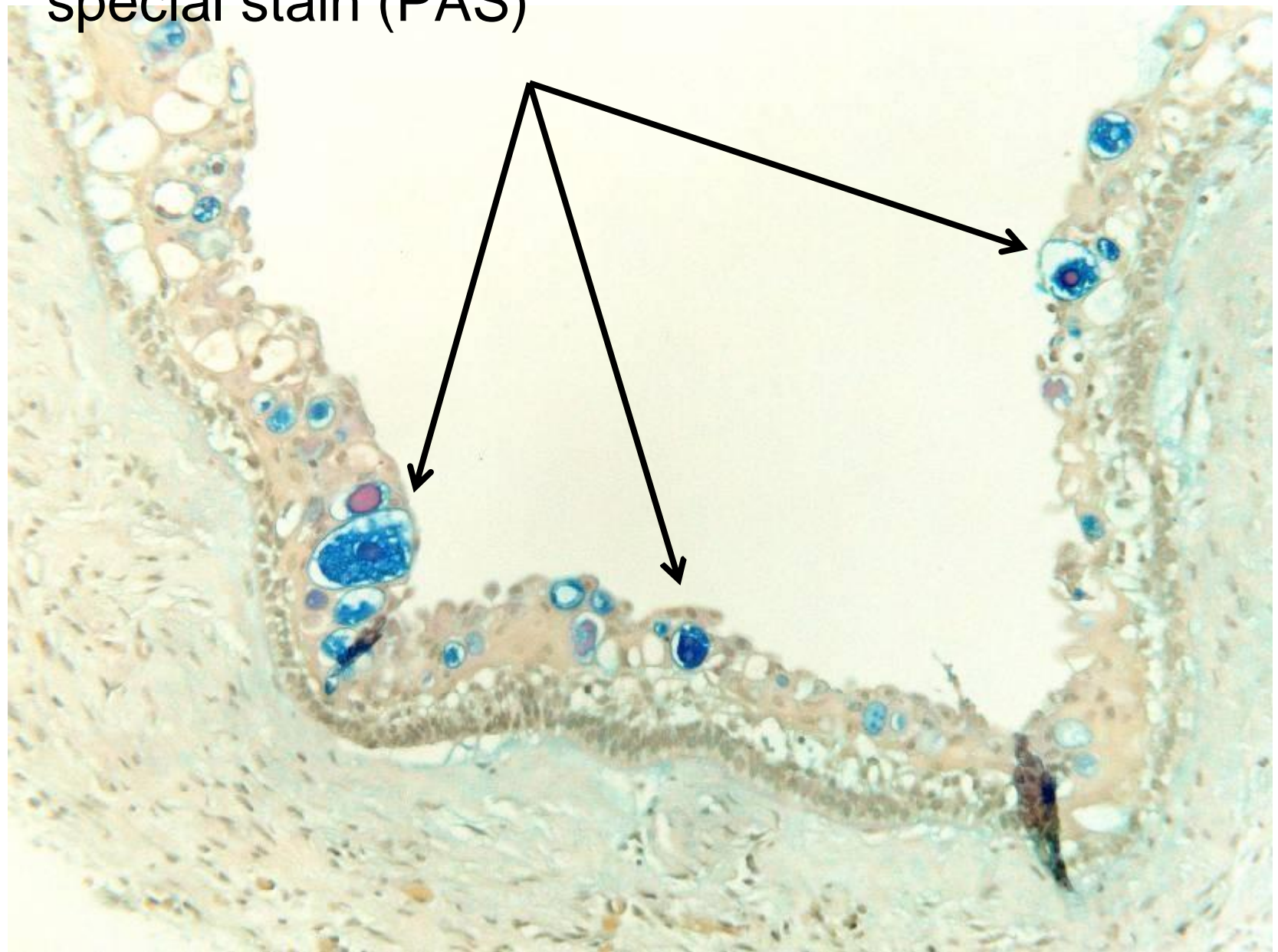


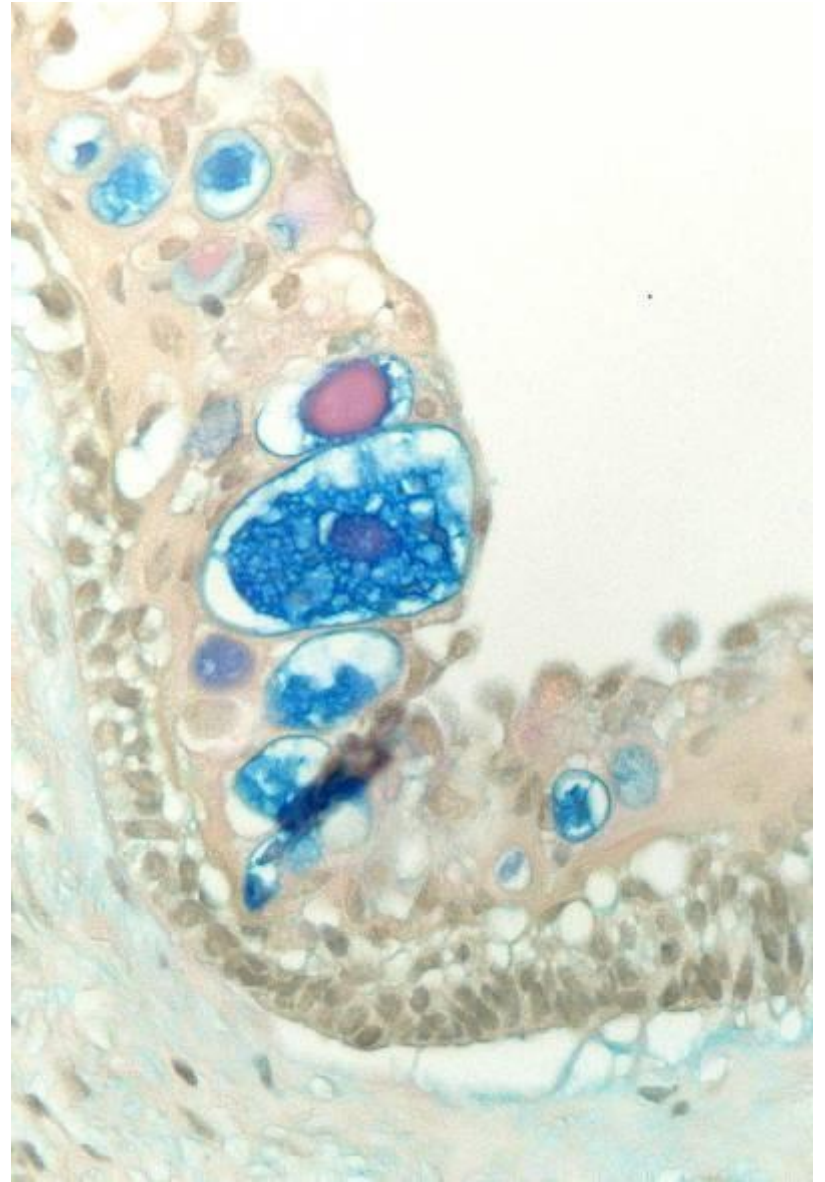
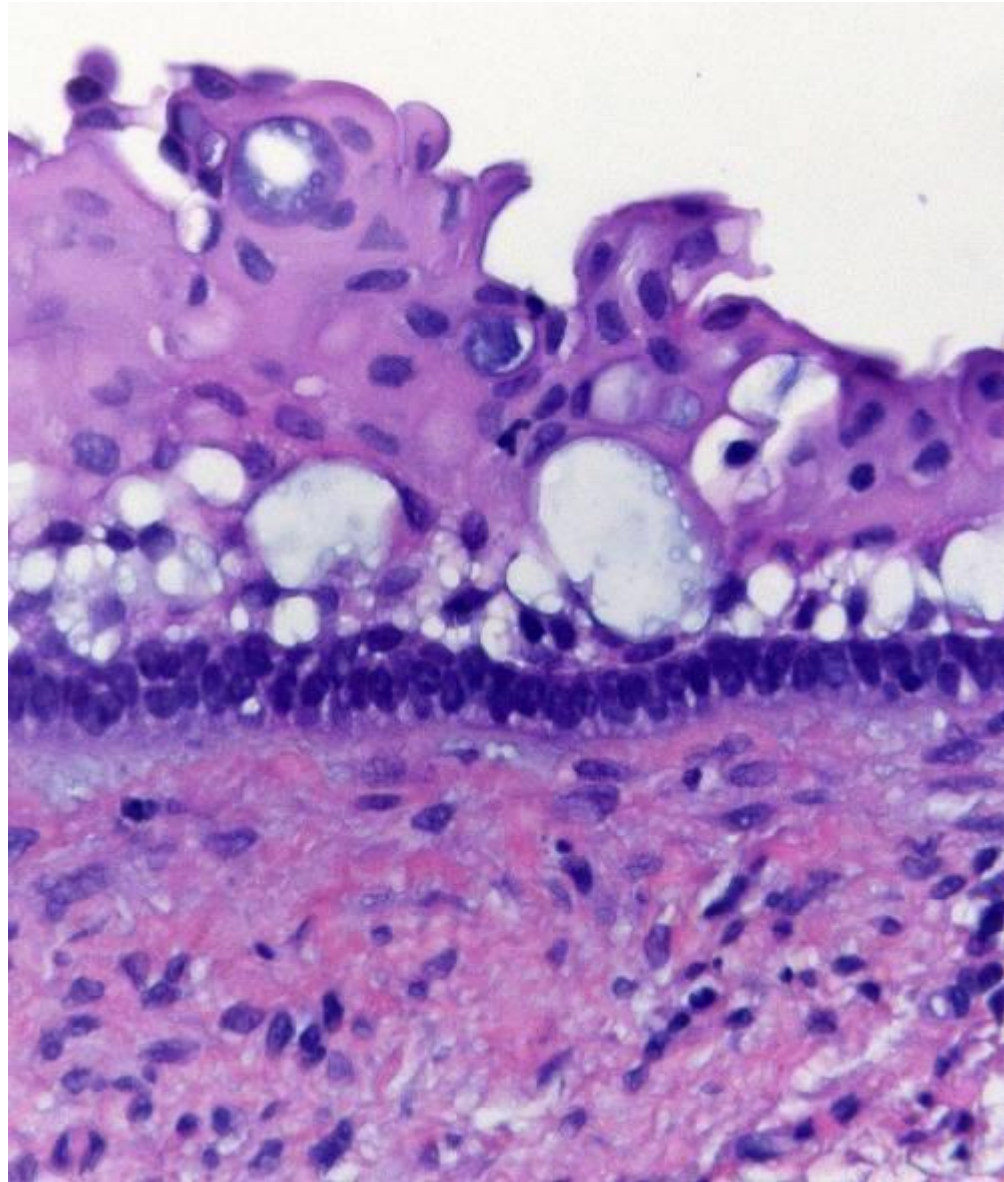
Non keratinized epithelium

The cells producing mucus in the epithelium



Mucus producing cells, visualized with a special stain (PAS)



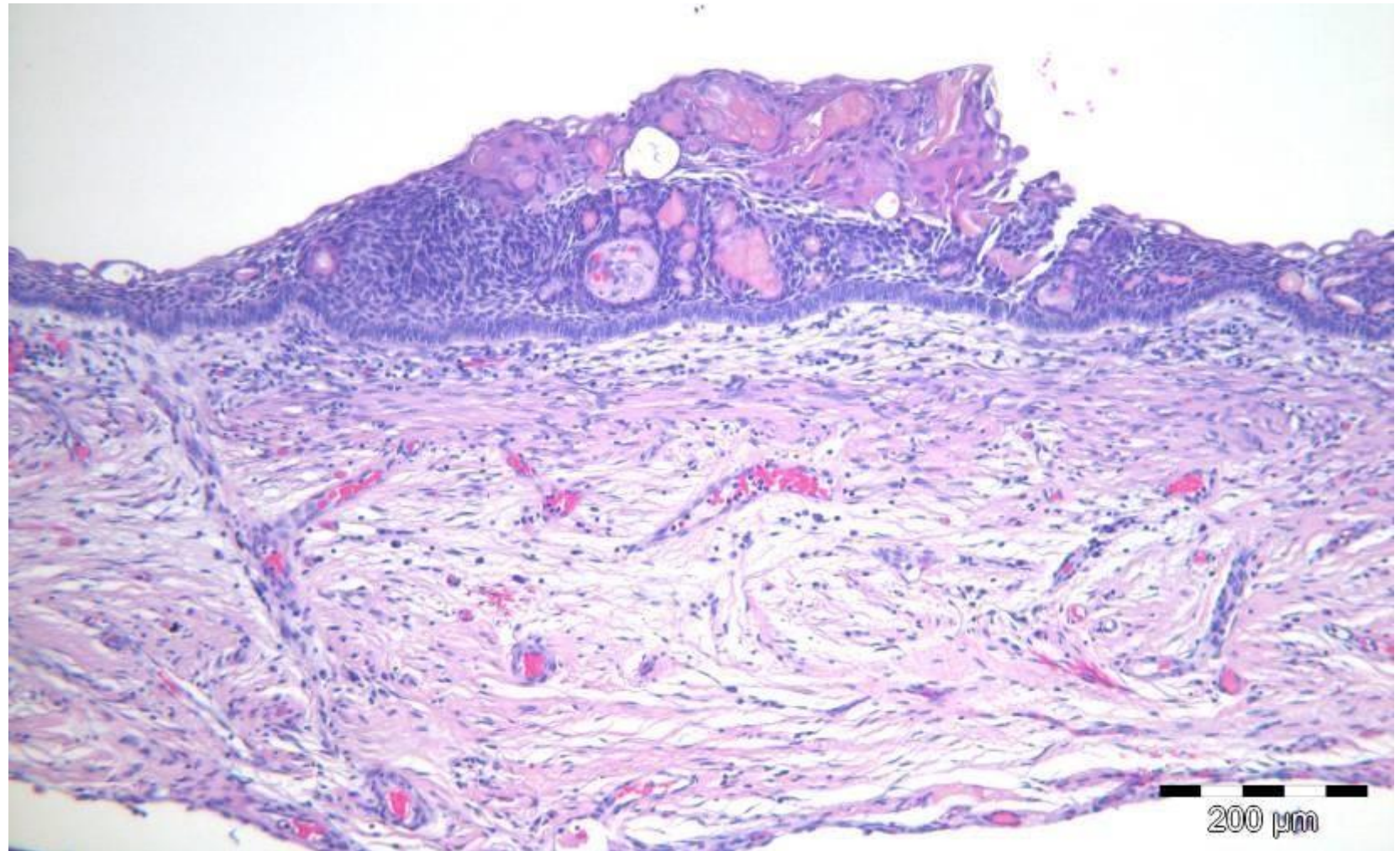


Calcified odontogenic cyst

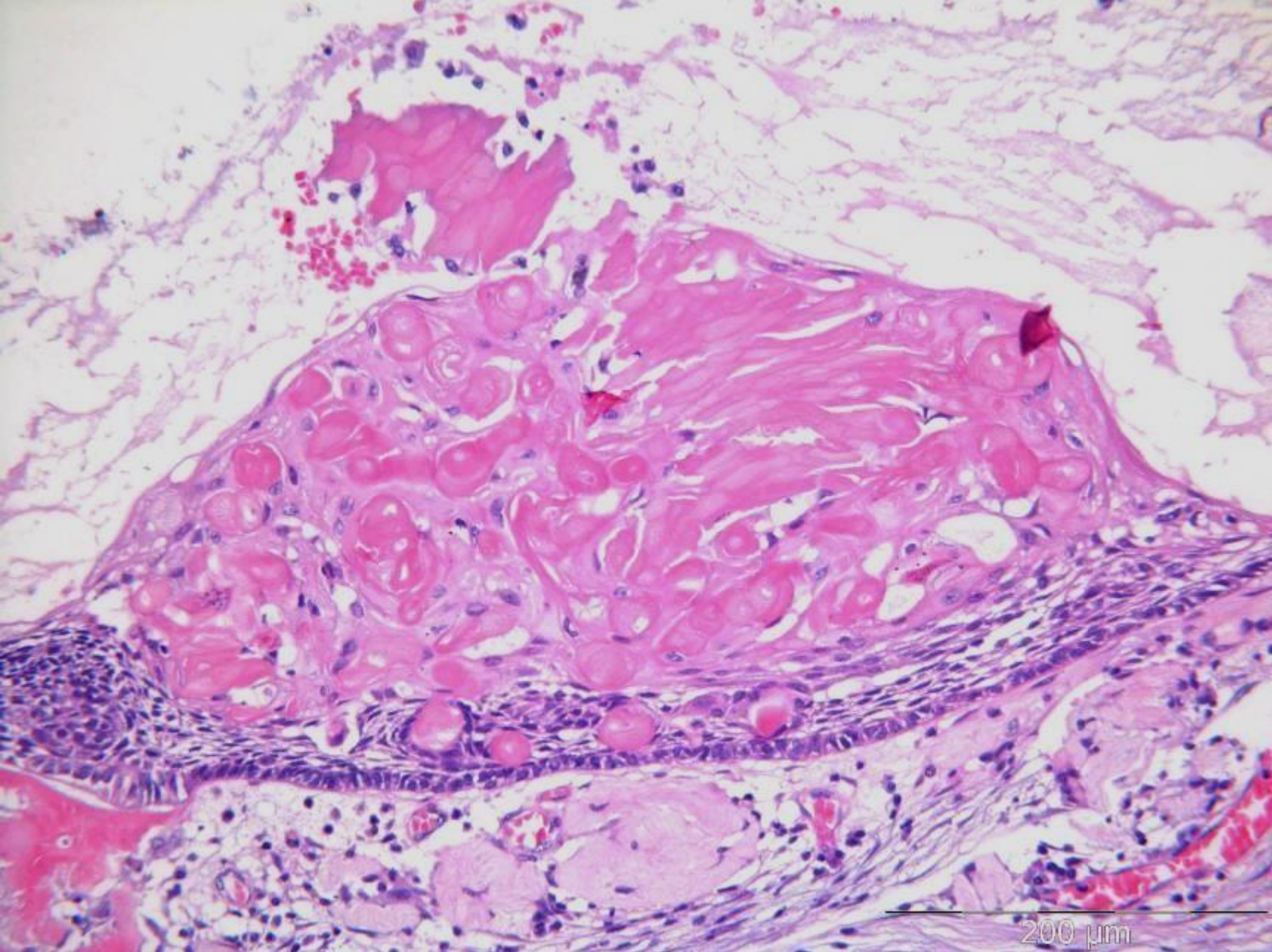
(WHO 2005: calcified cystic odontogenic tumor)

- Ameloblastoma-like epithelium with "ghost cells", which can calcify
- → X-ray radiopacities
- It can be intra- or extras
- All ages, both jaws
- Most commonly unilocular
- Frequently (1/3) associated with an uninterrupted tooth

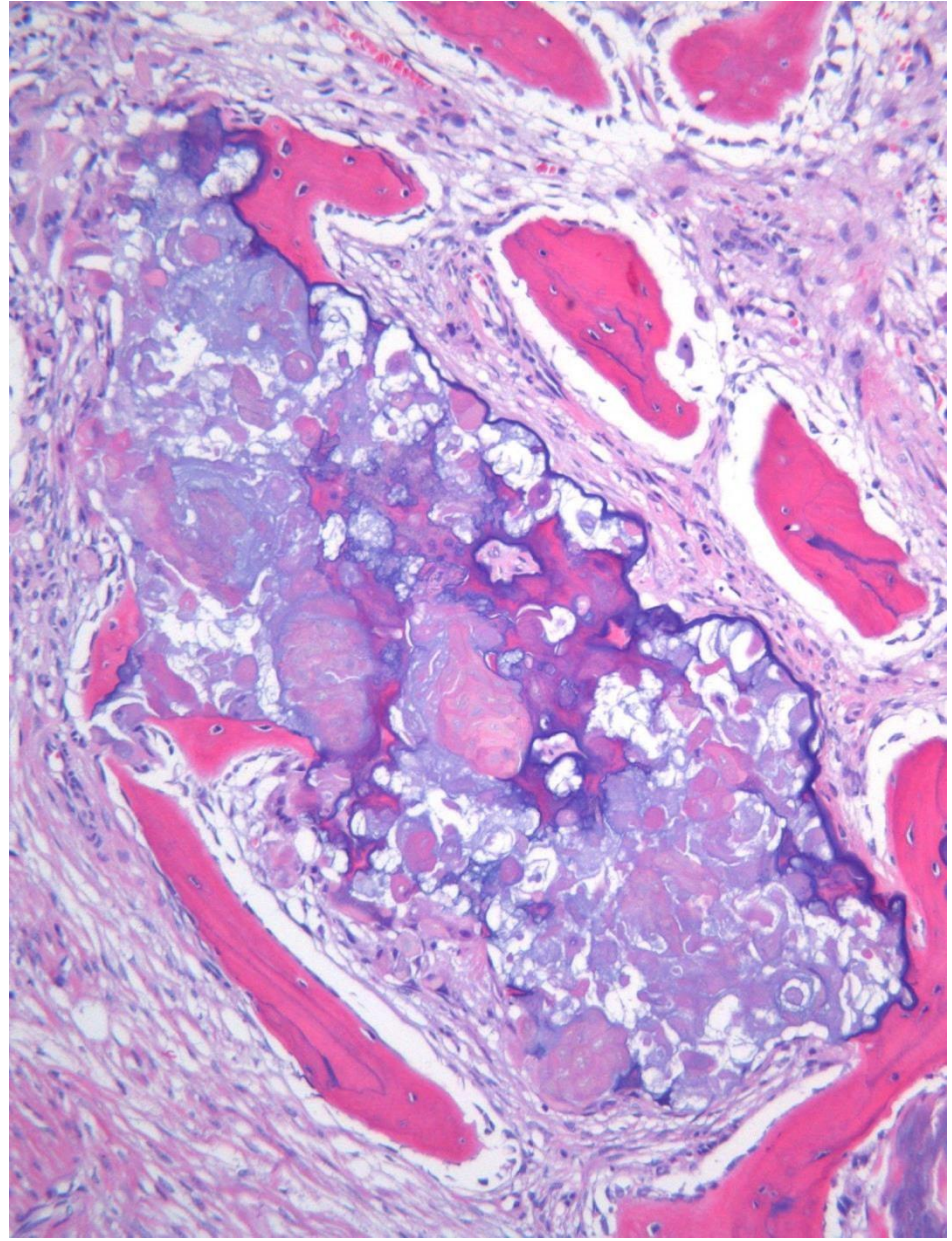
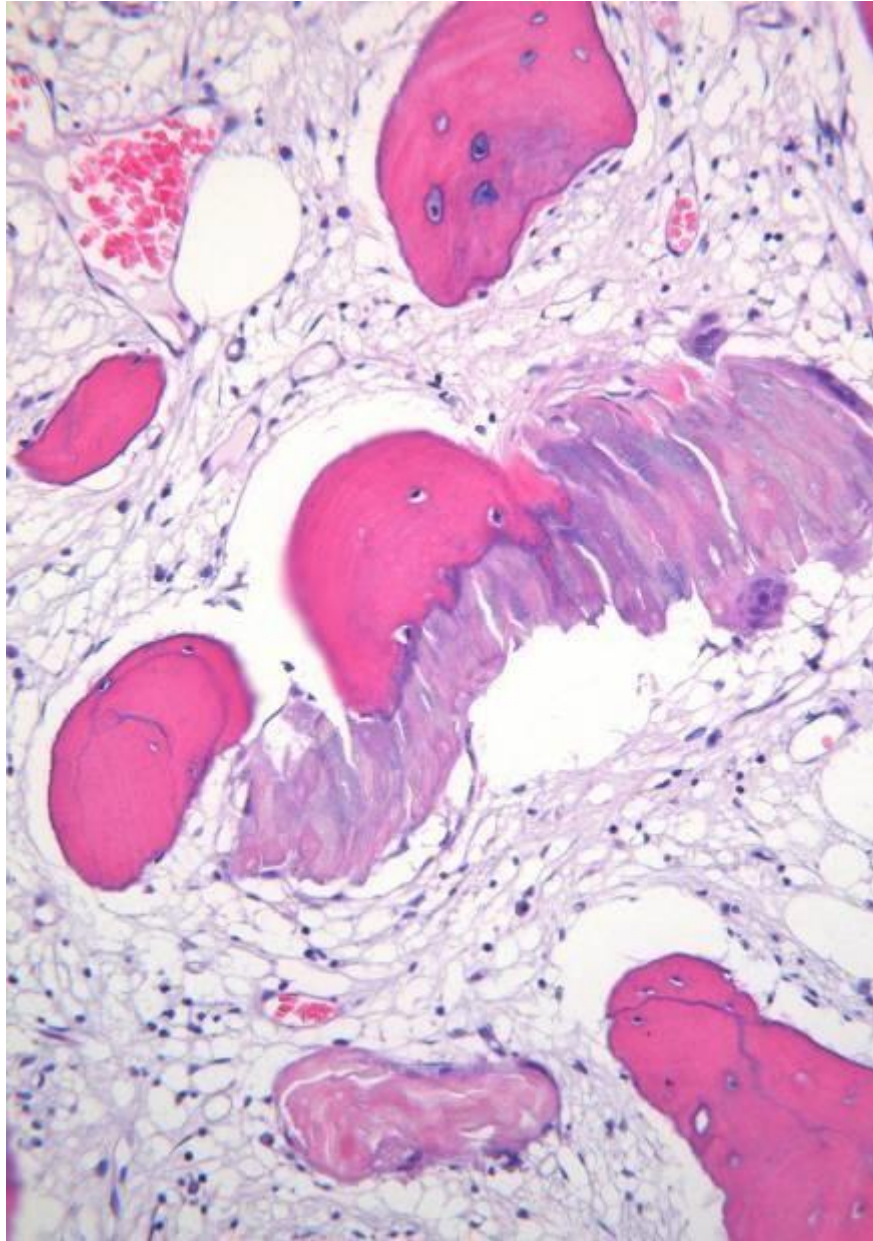
Calcified odontogenic cyst



Calcified odontogenic cyst

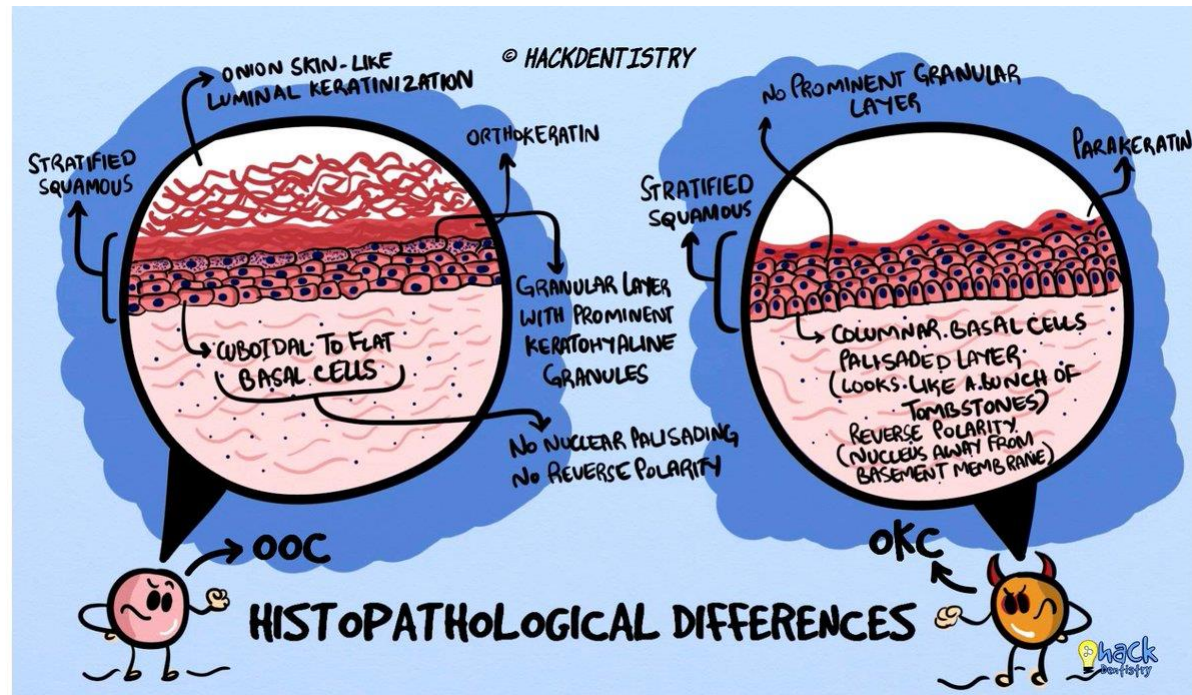


Calcified odontogenic cyst

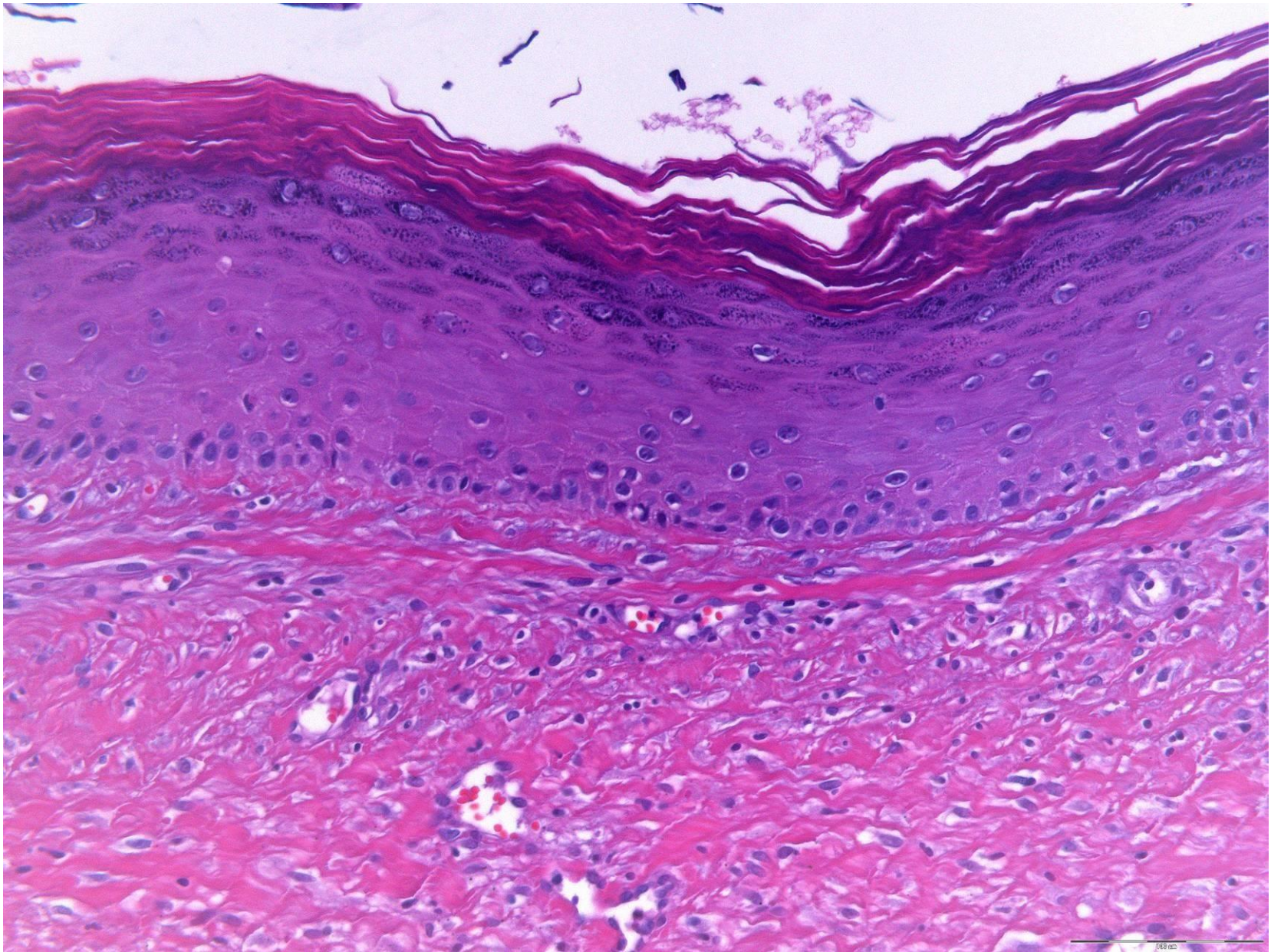


Orthokeratinized keratochist

- Rarely, compared to parakeratinized
- It is not considered a tumor
- Don't relapse

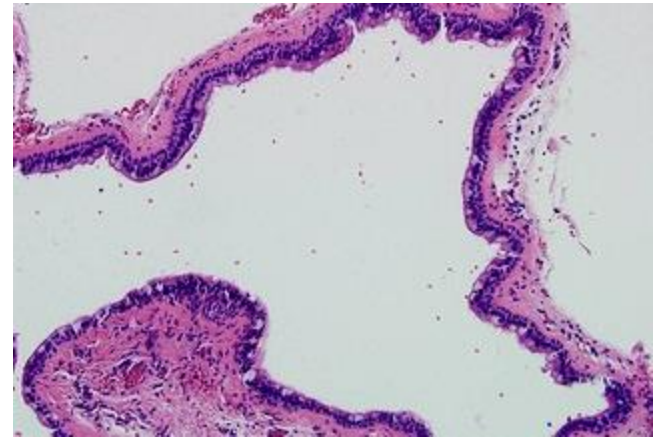


Orthokeratinized keratochist



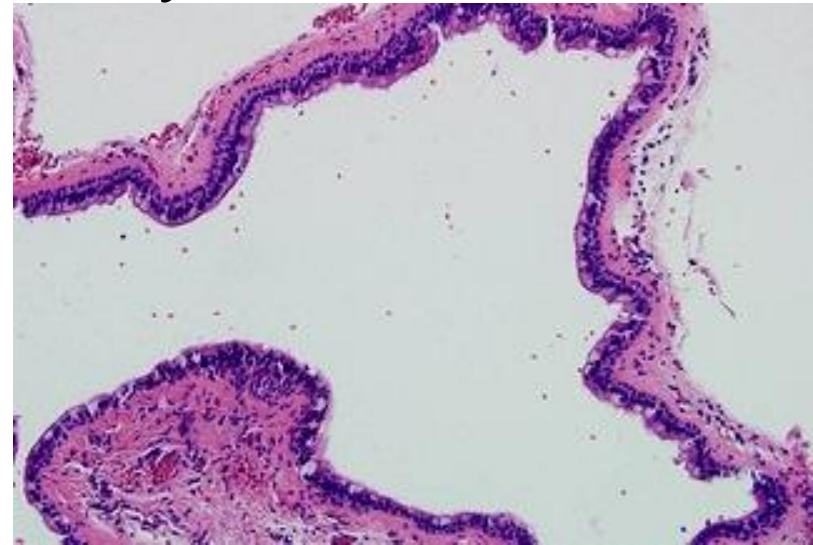
(Nasolabial cyst, nasoalveolar cyst)

- Soft tissue cyst
- It develops slightly outside the midline, between the nasal wing and the alveolar process.
- The epithelium is histologically identical to that of the nasal-tear duct
- Epithelial remnants of the lacrimal canal
- Middle-aged women



(Nasolabial cyst, nasoalveolar cyst)

- The epithelium is cylindrical, ciliate with mucosal cells
- The fibrous wall contains muscle fibers and is highly vascularized
- DD with glandular odontogenic cyst



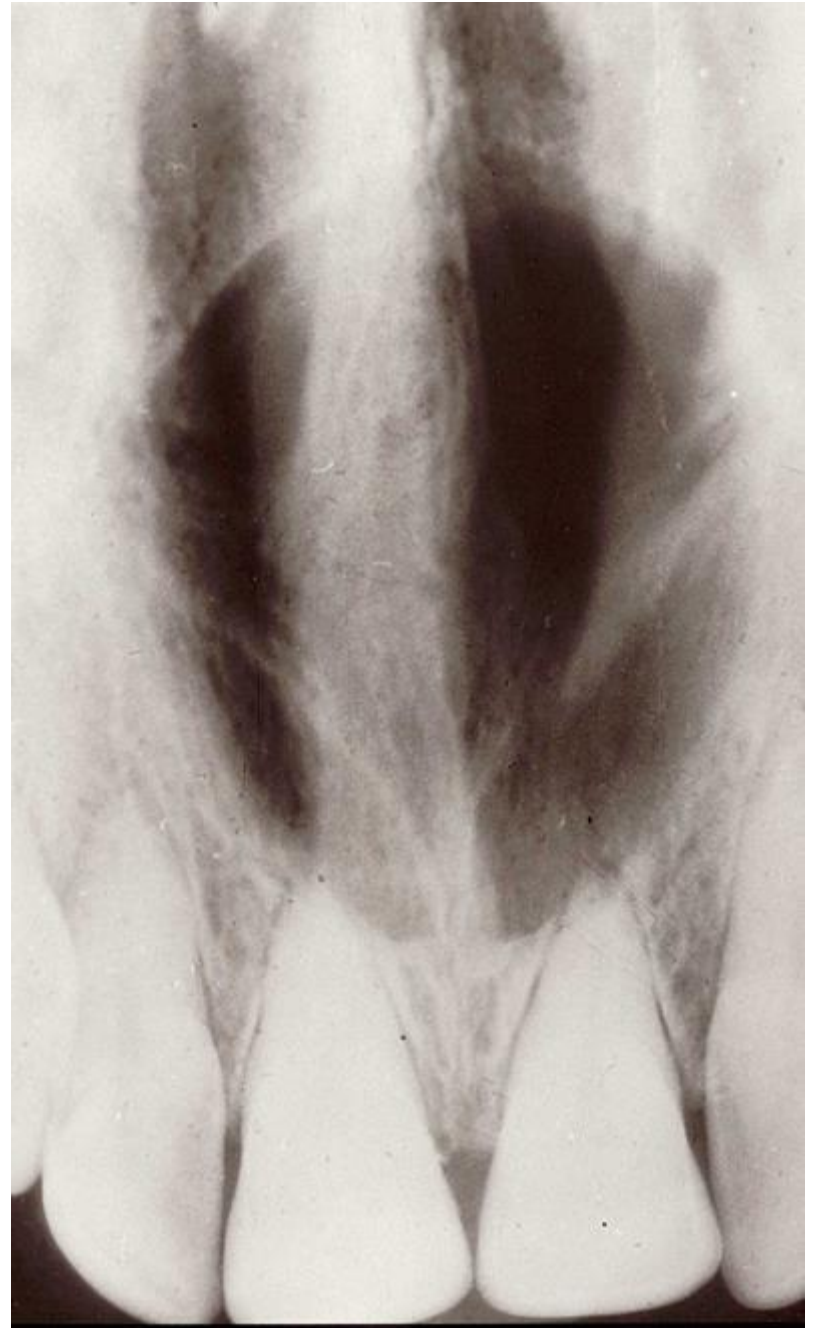
Nazopalatine canal cyst

Vital teeth

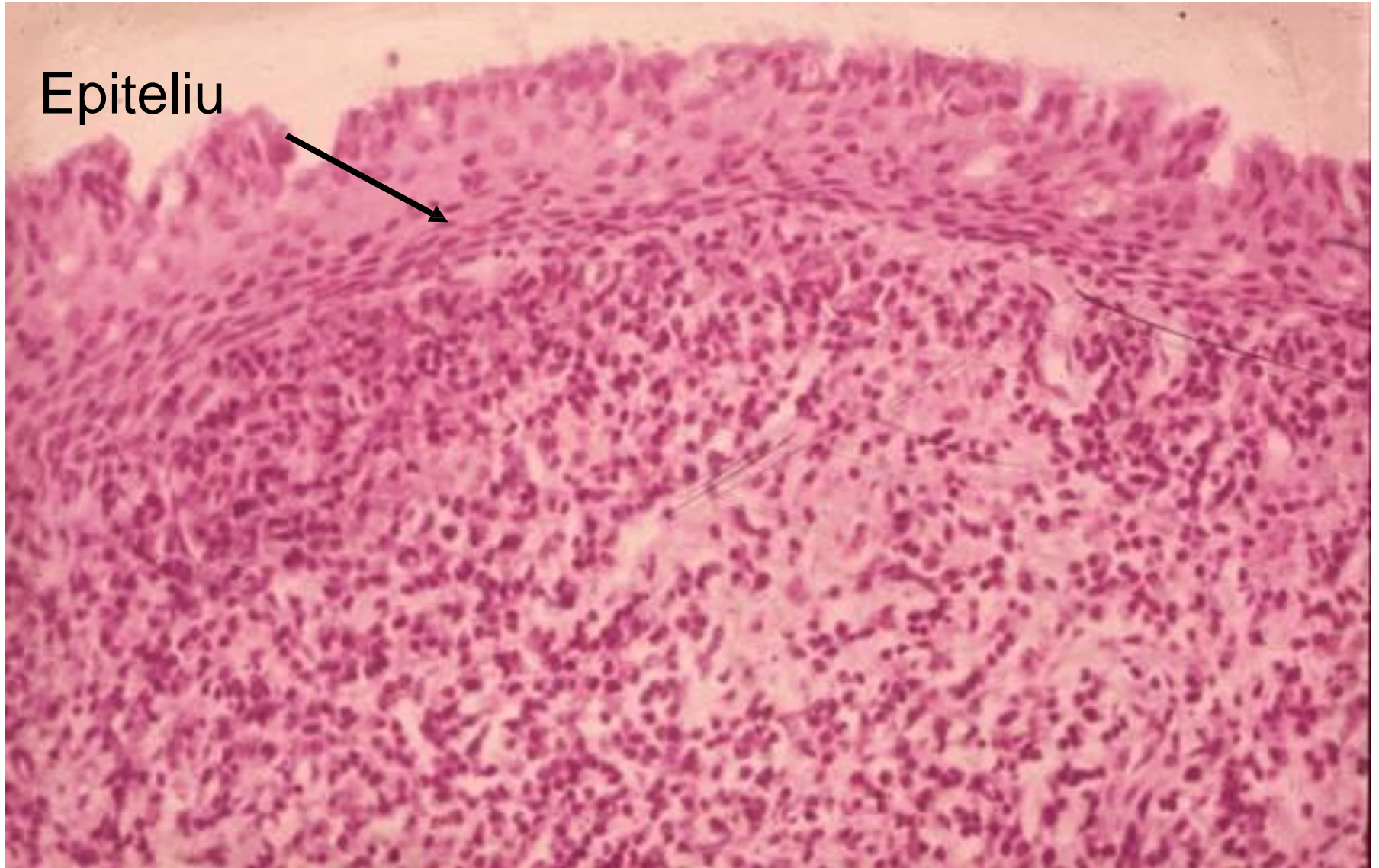
Well demarcated,

Radiolucency circular, > 5mm

It can be heart shaped



Nasopalatine canal cyst (incisal canal cyst)

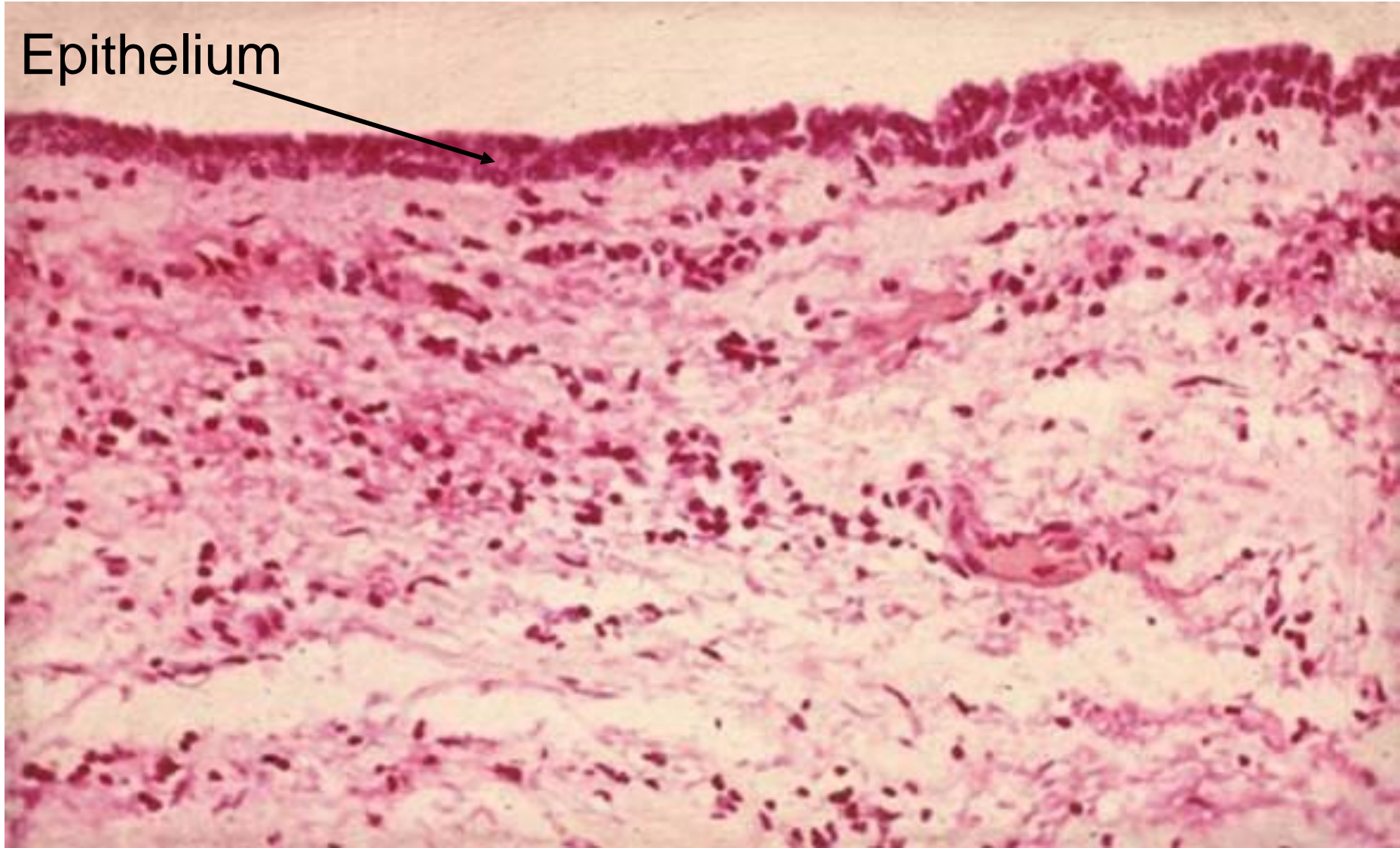


Epitelium

The lower part of the incisive canal

Nasopalatine canal cyst

Epithelium



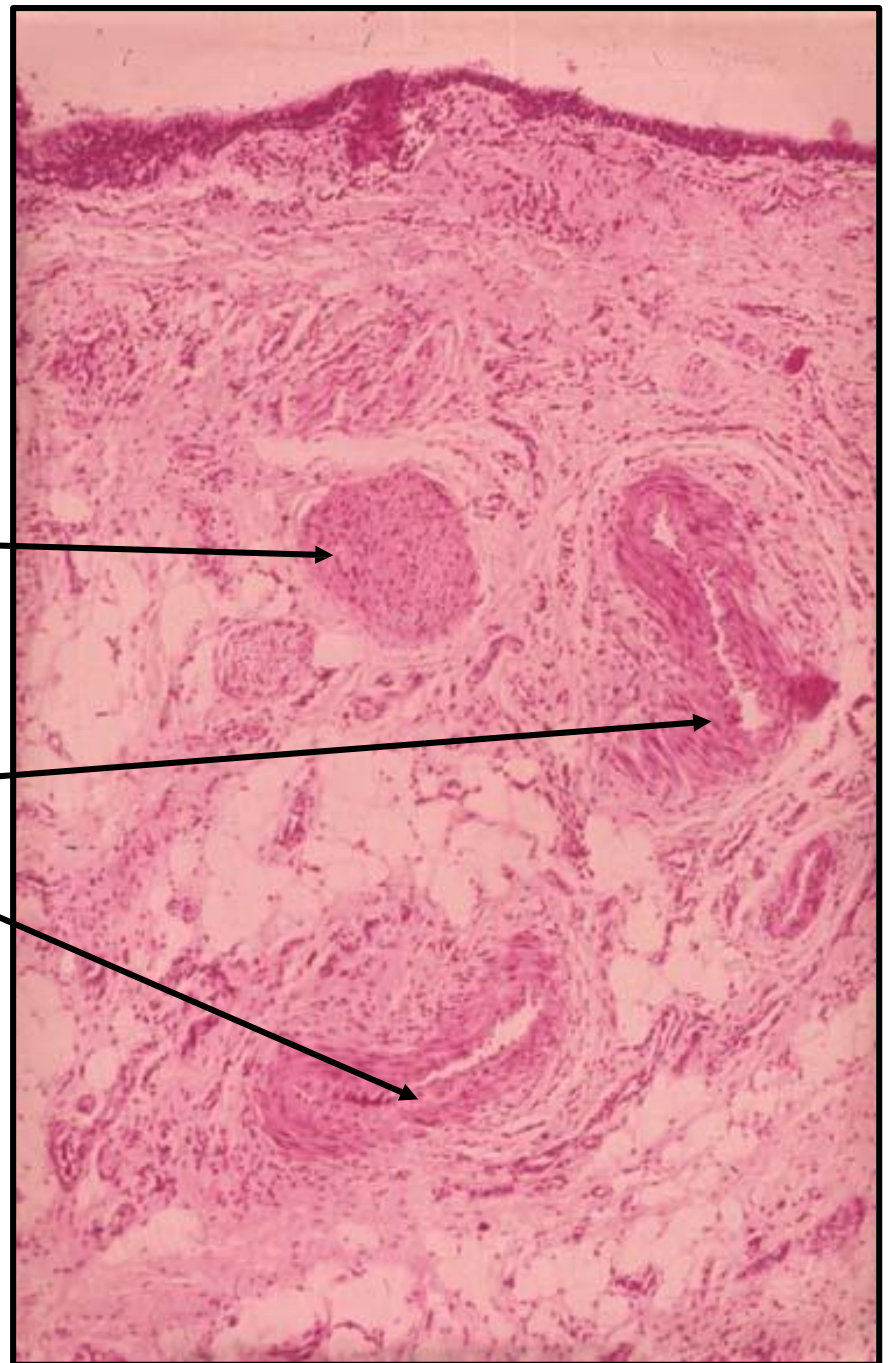
Upper part of the incisive canal

Nasopalatine canal cyst

Typical:

large nerve bundles

Vascular spaces of
the incisor canal

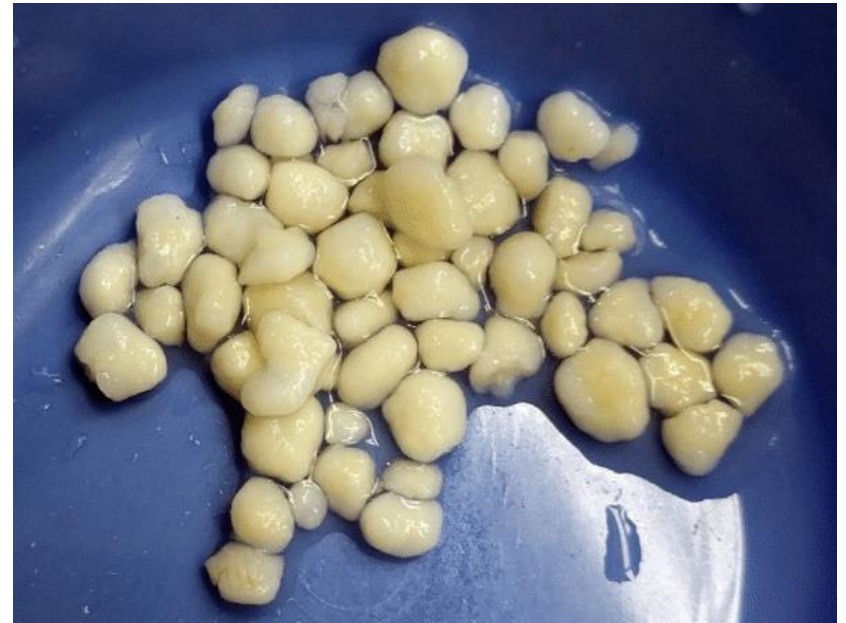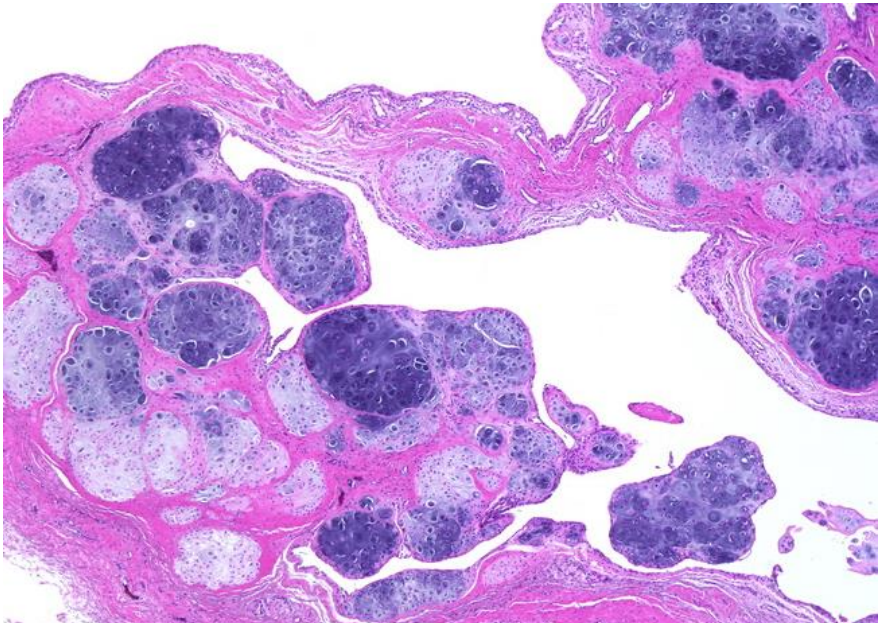


Summarizing

- Most cysts are intraosseous
- Only the root cyst can be linked to the infection
- They can be discovered accidentally on the x-ray
- They may have clinical symptoms
- Vital teeth (except root cyst)
- Some have a high recurrence rate and can be aggressive

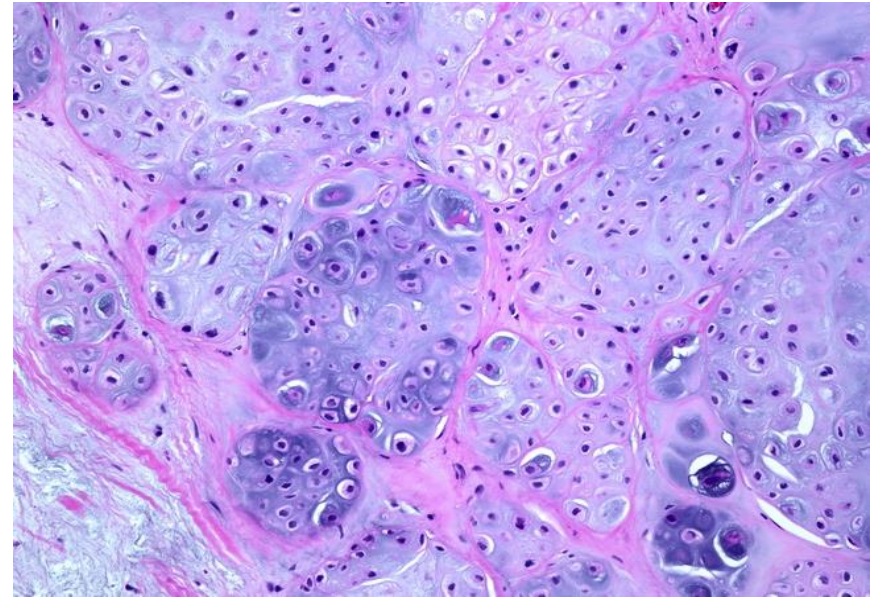
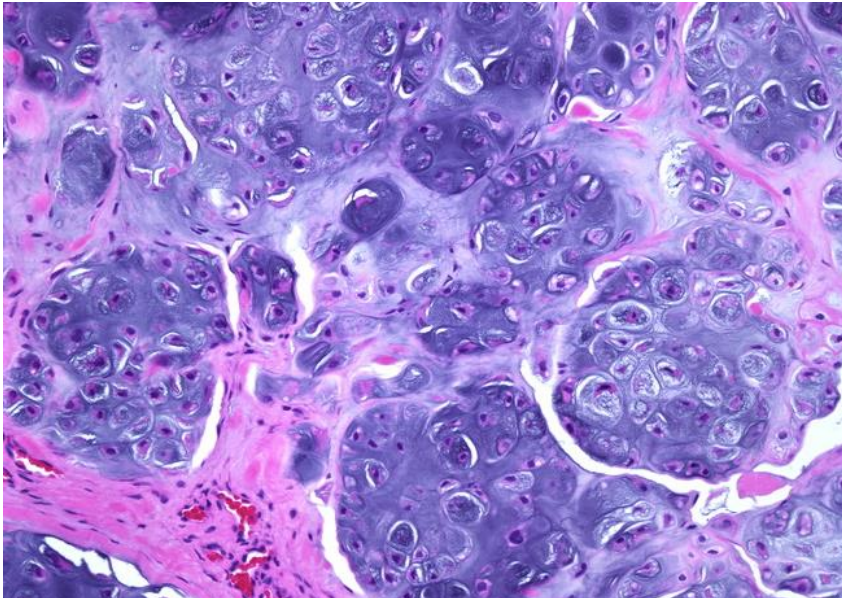
Synovial chondromatosis (SC) of the temporo-mandibular joint

- SC is a rare monoarticular benign arthropathy characterized by the formation of cartilaginous and / or osteocartilaginous metaplastic nodules in the synovial connective tissue and in the articular space (loose bodies).
- It is due to the metaplastic action initiated in the synovium in case of trauma and arthritis.
- Macroscopically, it shows multiple fragments of variable size (1-10 mm.), of dense consistency, whitish-yellowish color, ovular shape and with smooth surface (loose bodies)



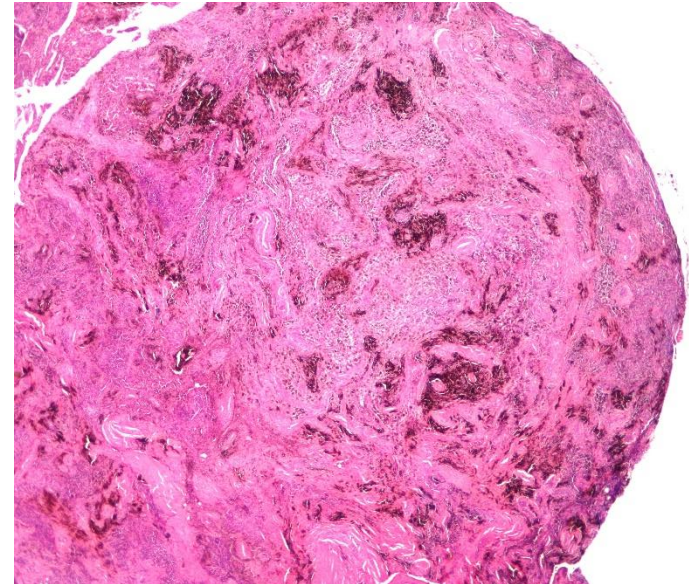
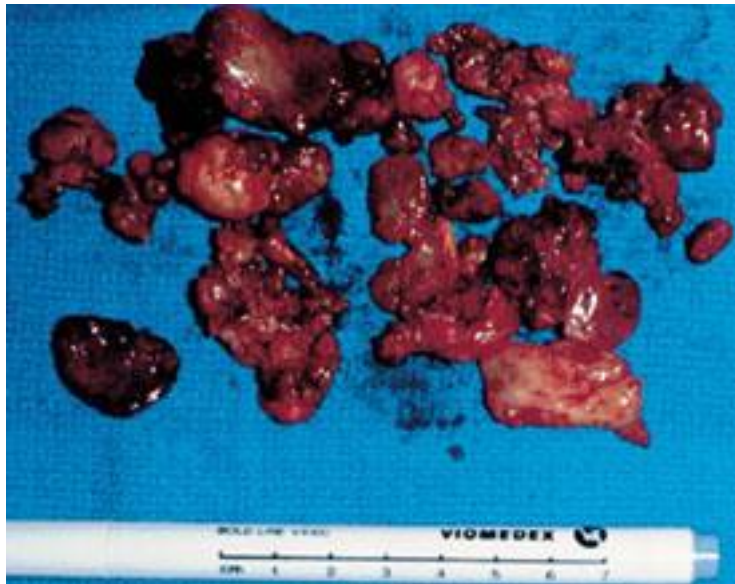Synovial chondromatosis (SC) of the temporo-mandibular joint

- Microscopically, there is cartilaginous metaplasia of the mesenchymal cells, immediately below the superficial synovial layer, islands or round cartilaginous nodules surrounded by sub-synovial connective tissue.
- As these nodules grow, they invaginate into the intra-articular space, some detach becoming (loose bodies).
- Chondrocytes can be binucleate and agglomerated by producing hypercellular clusters with minimal mitotic activity.



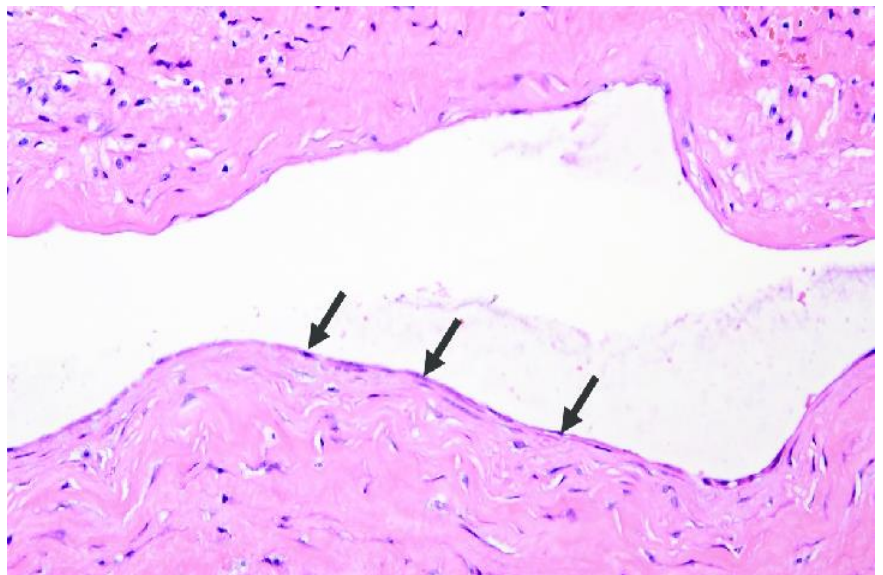
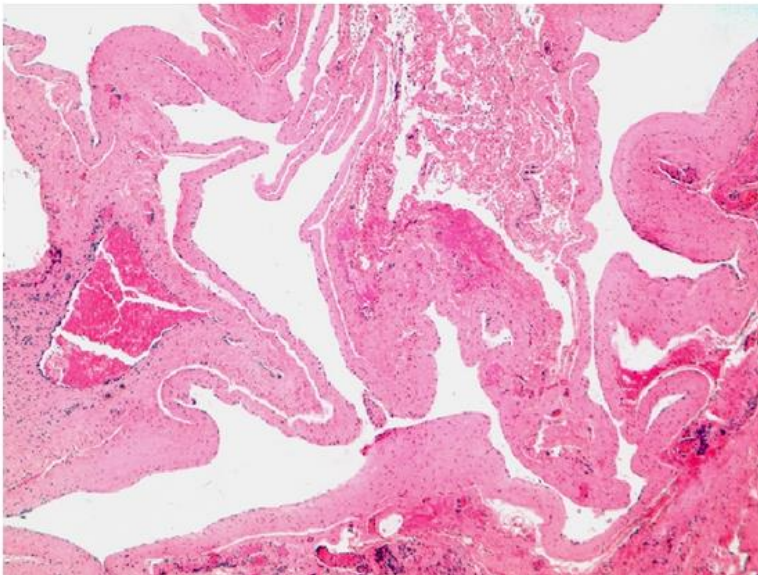
Pigmented villonodular synovitis (PVS) of the temporo-mandibular joint

- PVS, Monoarticular proliferative lesion of unknown etiology develops from the synovial membranes of the joints, bursae and tendon sheaths
- Macroscopically, synovial thickening is observed in the form of villi, their appearance is brown as a result of hemosiderin deposits.
- Microscopically, papillary proliferation is represented by fibrous stroma covered by a layer of oval hyperplastic epithelioid cells of the histiocyte type.



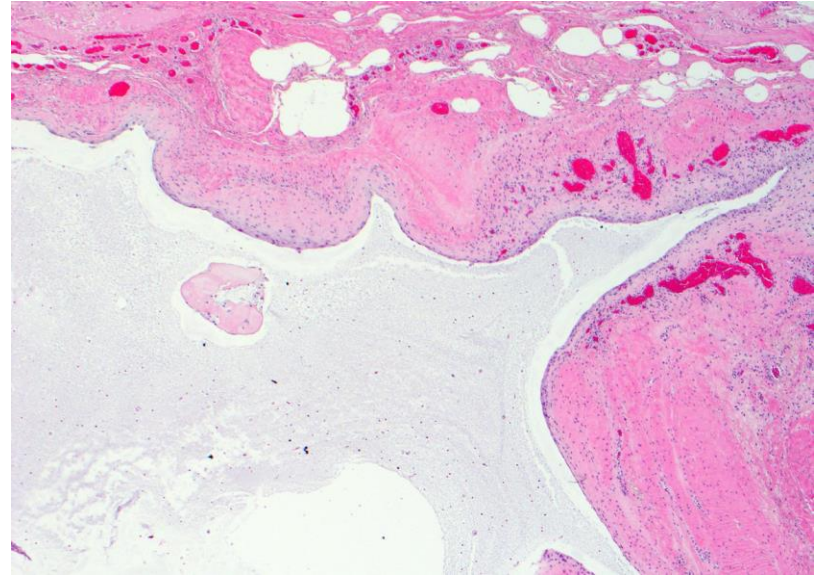
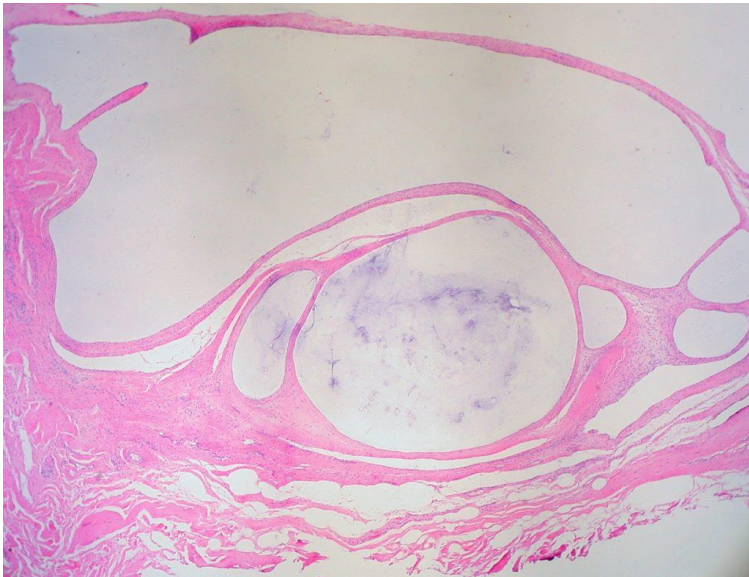
Synovial cyst of the temporo-mandibular joint

- It represents a true cystic structure, covered by a unistratified epithelium of synovial origin that may or may not communicate with the articular cavity
- It contains fluid similar to the joint synovial fluid
- It is the consequence of myxoid degeneration of the connective tissue of the joint capsule
- Don't relapse



The ganglion cyst of the temporo-mandibular joint

- It is a pseudo cyst delimited by fibrous tissue without being lined with synovial cells and unrelated to the joint cavity.
- Contains gelatinous viscous liquid
- It develops as a result of synovial herniation in surrounding tissues or by migration of synovial tissue during embryogenesis
- Don't relapse

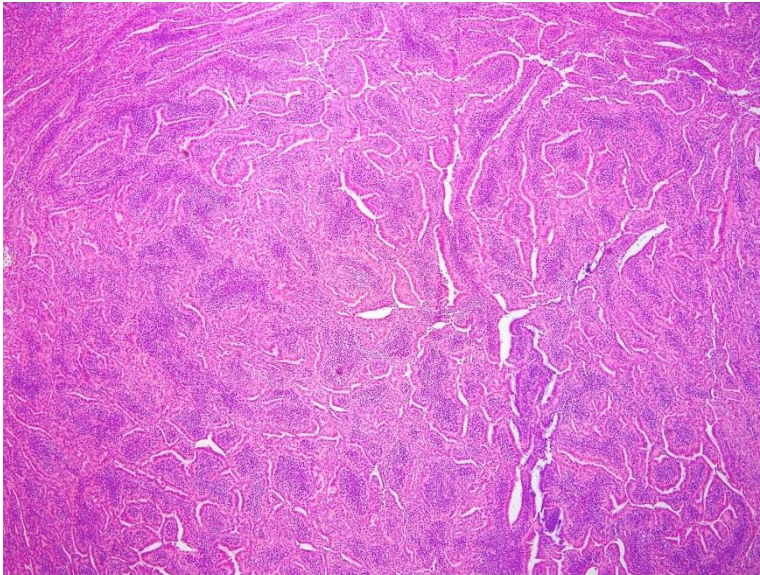


Benign tumors of the temporo-mandibular joint

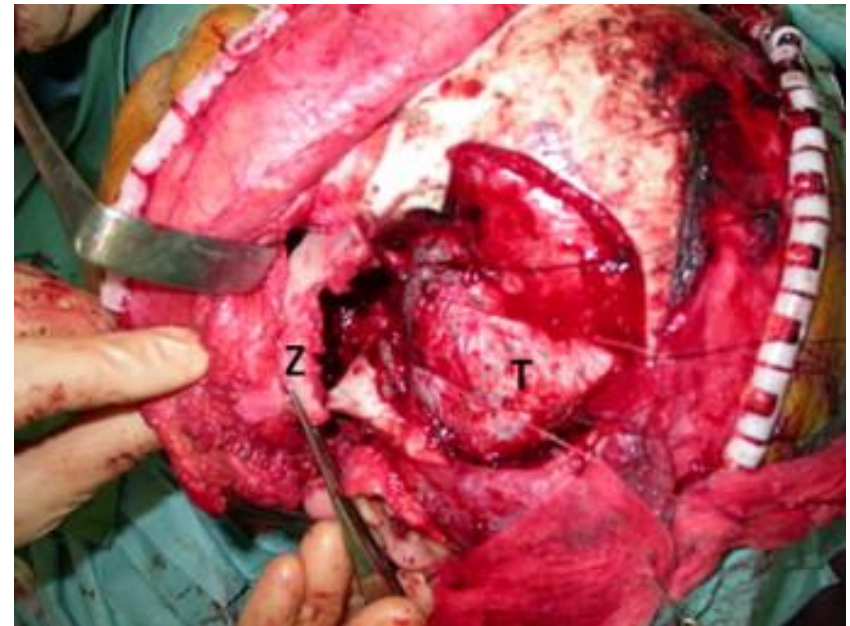- **Nonossifying fibroma** – it represents solitary fibrous proliferation, well delimited, developed at the level of the mandibular condyle.
- **Osteochondroma** - it is an exophytic osteochondromatoid projection on the surface of the bone, having a continuous medullary cavity with that of the underlying bone.
- **Osteoma** – osteogenic benign neoplasia composed of well differentiated mature bone tissue, developed at the level of the mandibular condyle.
- **Osteoblastoma** – rare intracondylar osteoforming benign tumor, characterized by proliferation of osteoblasts that will form bone trabeculae in a well-vascularized fibrous connective tissue stroma.

Malignant tumors of the temporo-mandibular joint

- **Synovial sarcoma** – aggressive malignant neoplasm of soft tissue developed from multipotent mesenchymal cells in the vicinity or outside of the articular surfaces
- Macroscopically, multinodular and / or multicystic masses, well defined, attached to the articular capsule or periosteum of the mandibular condyle and has yellowish color.
- Microscopic, două tipuri de celule neoplazice (tip bifazic): Microscopically, two types of neoplastic cells (biphasic type): 1. epithelial resemble with those of carcinomas. 2. spindle shaped, fibrosarcomatous.



Biphasic synovial sarcoma, 4x: spindle cell background with prominent glandular formation



Malignant tumors of the temporo-mandibular joint

- Chondrosarcoma
- Osteosarcoma
- Ewing's sarcoma
- Epithelioid sarcoma
- Fibrosarcoma
- Malignant fibrous histiocytoma
- Malignant peripheral nerve sheath tumors

They have characteristics similar to other locations