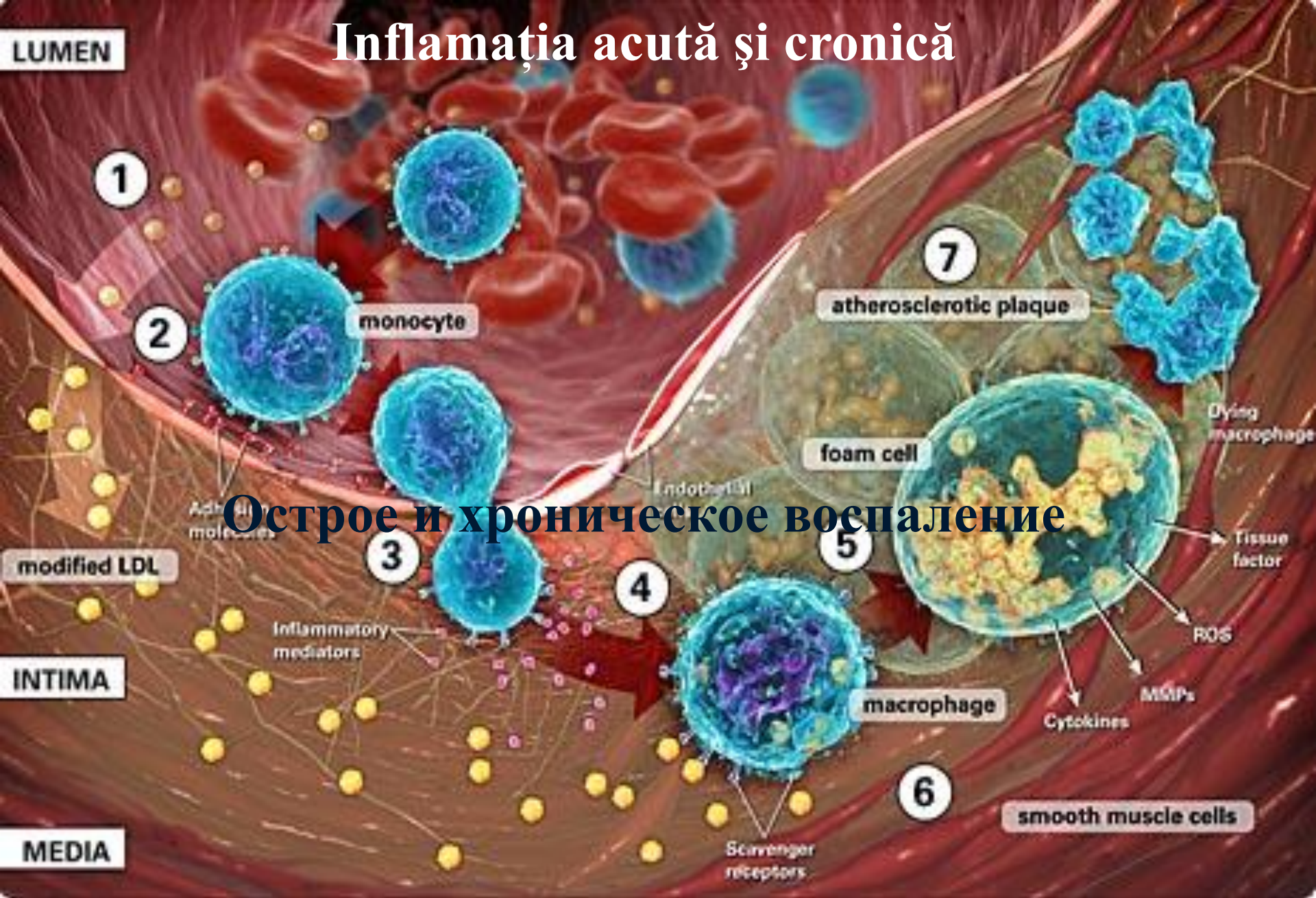


Inflamația acută și cronică



Острое и хроническое воспаление

Acute and chronic inflammation.

Tema: Inflamația acută și cronică.

I. Micropreparate:

№ 62. Pericardită fibrinoasă. (*Colorație H-E.*). Indicații:

1. Depozite de fibrină pe suprafața epicardului.
2. Infiltrația epicardului cu leucocite.
3. Miocardul.

№ 28. Leptomeningită purulentă. (*Colorație H-E.*). Indicații:

1. Infiltrație cu neutrofile a leptomeningelui.
2. Puroi (neutrofile) în spațiul subarahnoidan.
3. Țesutul cerebral edemațiat.

№ 12. Miocardită interstițială. (*Colorație H-E.*). Indicații:

1. Infiltrat celular inflamator în stroma miocardului.
2. Fibre musculare.

№ 82. Tuberculoza miliară renală. (*Colorație H-E.*). Indicații:

1. Granulom tuberculos:
 - a. focarul de necroză cazeoasă în centrul granulomului;
 - b. stratul de celule epitelioid;
 - c. celule gigante polinucleate Langhans;
 - d. stratul de celule limfoide.
2. Țesutul renal adiacent.

II. Macropreparate:

№ 11. Pericardită fibrinoasă (cord vilos).

№ 32. Bronhopneumonie abcedantă.

№ 33. Pneumonie francă lobară (stadiul de hepatizație cenușie).

№ 34. Pleurită fibrinoasă.

№ 152. Peritonită fibrinoasă.

№ 12. Cardioscleroză difuză.

№ 21. Echinococoza inimii.

Тема: Острое и хроническое воспаление.

I. Микропрепараты:

№ 62. Фибринозный перикардит. (окраска Г-Э.). Обозначения:

1. Наложения фибрина на поверхности эпикарда.
2. Инфильтрация эпикарда лейкоцитами.
3. Миокард.

№ 28. Гнойный лептоменингит. (окраска Г-Э.). Обозначения:

1. Инфильтрация нейтрофилами мягкой мозговой оболочки.
2. Гной (нейтрофилы) в субарахноидальном пространстве.
3. Отёчная мозговая ткань.

№ 12. Межуточный миокардит. (окраска Г-Э.). Обозначения:

1. Воспалительный клеточный инфильтрат в строме миокарда.
2. Мышечные волокна.

№ 82. Милиарный туберкулез почек. (окраска Г-Э.). Обозначения:

1. Туберкулезная гранулема:
 - а. казеозный некроз в центре гранулемы;
 - б. слой эпителиоидных клеток;
 - в. гигантские многоядерные клетки Ланганса;
 - г. слой лимфоидных клеток.
2. Прилежащая паренхима почки.

II. Макропрепараты:

№ 11. Фибринозный перикардит.

№ 32. Абсцедирующая бронхопневмония.

№ 33. Крупозная пневмония (стадия серого опеченения).

№ 34. Фибринозный плеврит.

№ 152. Фибринозный перитонит.

№ 12. Диффузный кардиосклероз.

№ 21. Эхинококкоз сердца.

Acute and chronic inflammation.

I. Microspecimens:

№ 62. Fibrinous pericarditis. (*H-E. stain*). Indications:

1. Fibrin deposits on the surface of the epicardium.
2. Leukocytic infiltration of epicardium.
3. Myocardium.

№ 28. Pyogenic leptomeningitis. (*H-E. stain*). Indications:

1. Neutrophilic infiltration of leptomeninges.
2. Pus (neutrophils) in the subarachnoid space.
3. Edematous brain tissue.

№ 12. Interstitial myocarditis. (*H-E. stain*). Indications:

1. Infiltration with inflammatory cell of the myocardial stroma.
2. Muscle fibers.

№ 82. Renal milliary tuberculosis. (*H-E. stain*). Indications:

1. Tuberculous granuloma:
 - a. focus of caseous necrosis in the center of granuloma;
 - b. layer of epithelioid cells;
 - c. giant cells Langhans;
 - d. layer of lymphoid cells .
2. Adjacent renal tissue.

II. Macrospecimens:

№ 11. Fibrinous pericarditis.

№ 32. Focal pneumonia with abscess formation.

№ 33. Lobar pneumonia (grey hepatisation).

№ 34. Fibrinous pleuritis.

№ 152. Fibrinous peritonitis.

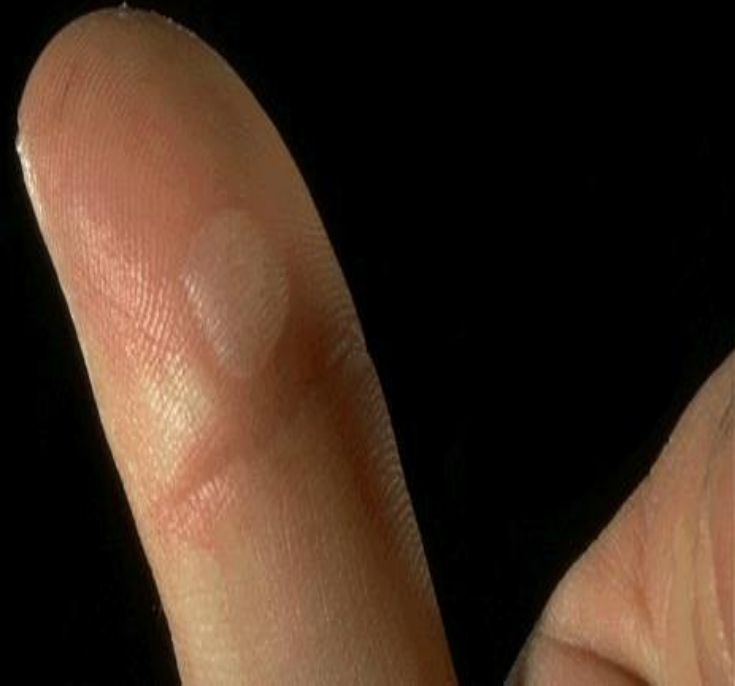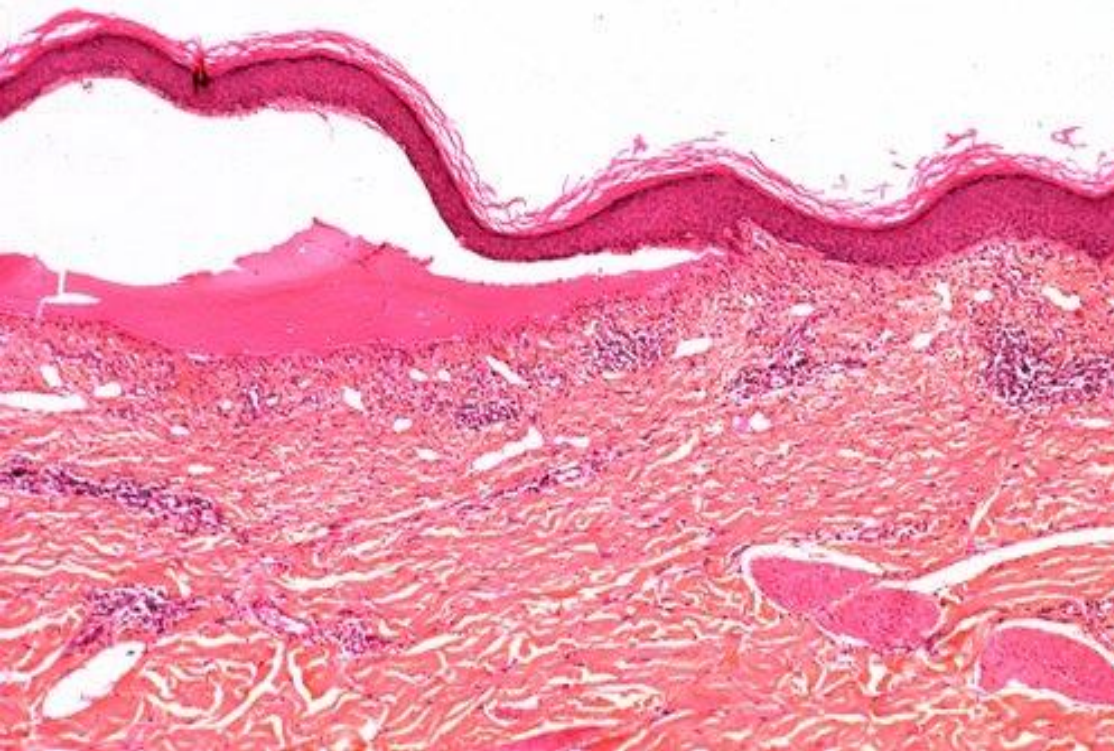
№ 12. Difuse cardiosclerosis.

№ 21. Echinococcus into heart.

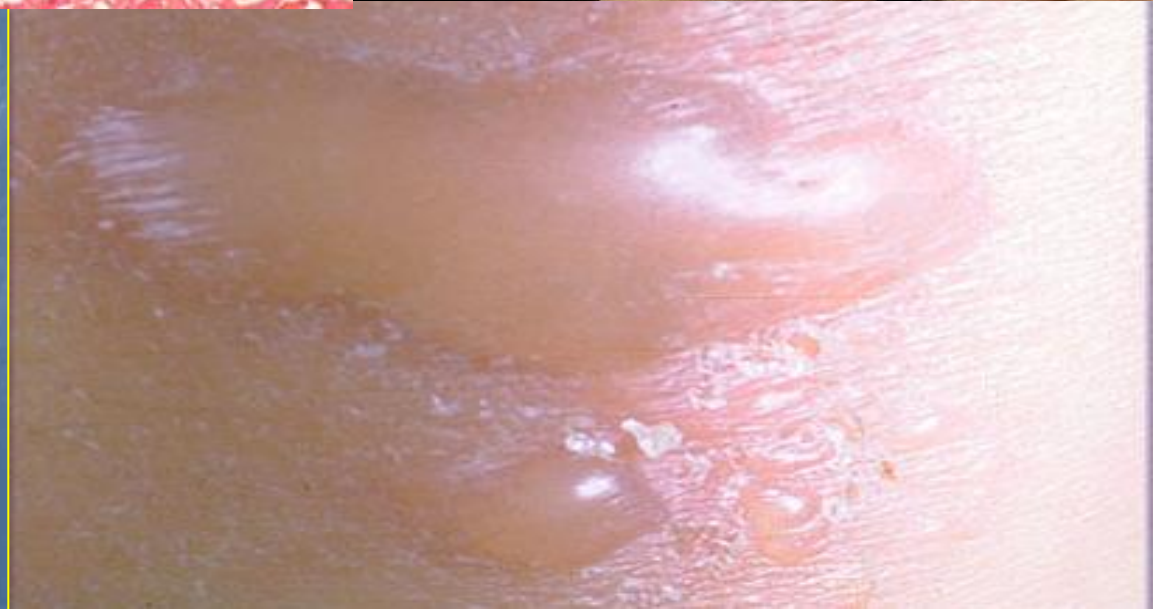


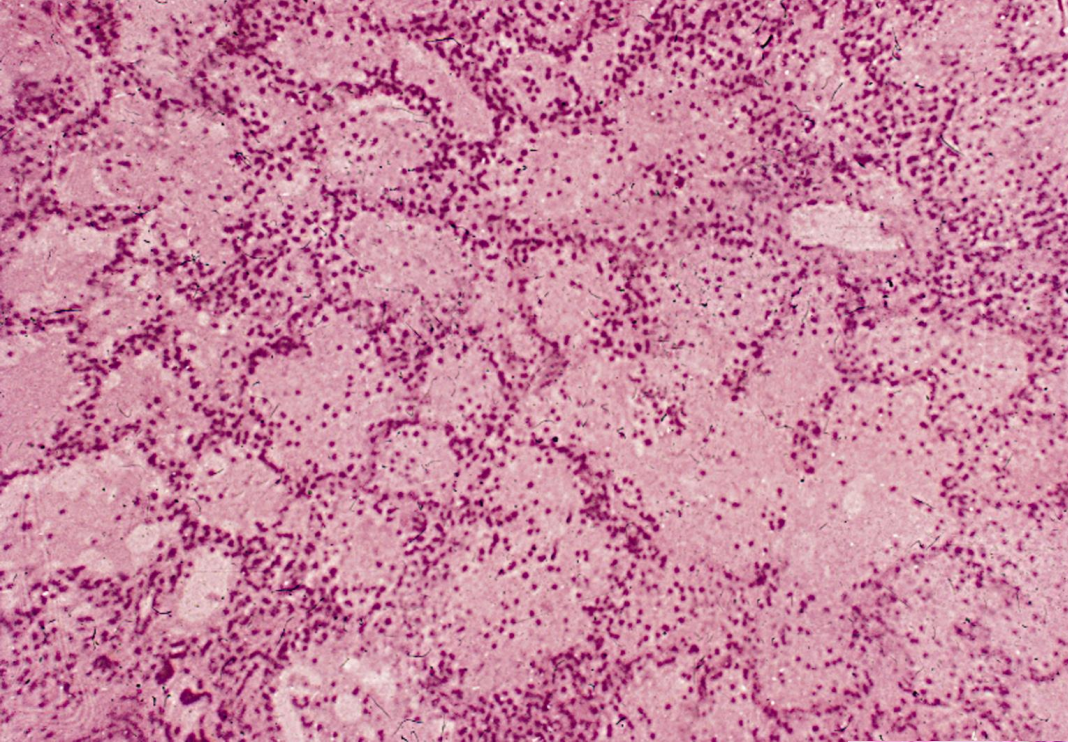
Semnele clinice ale inflamației

(căldură, roșeață, tumefacție, durere, alterarea funcției).

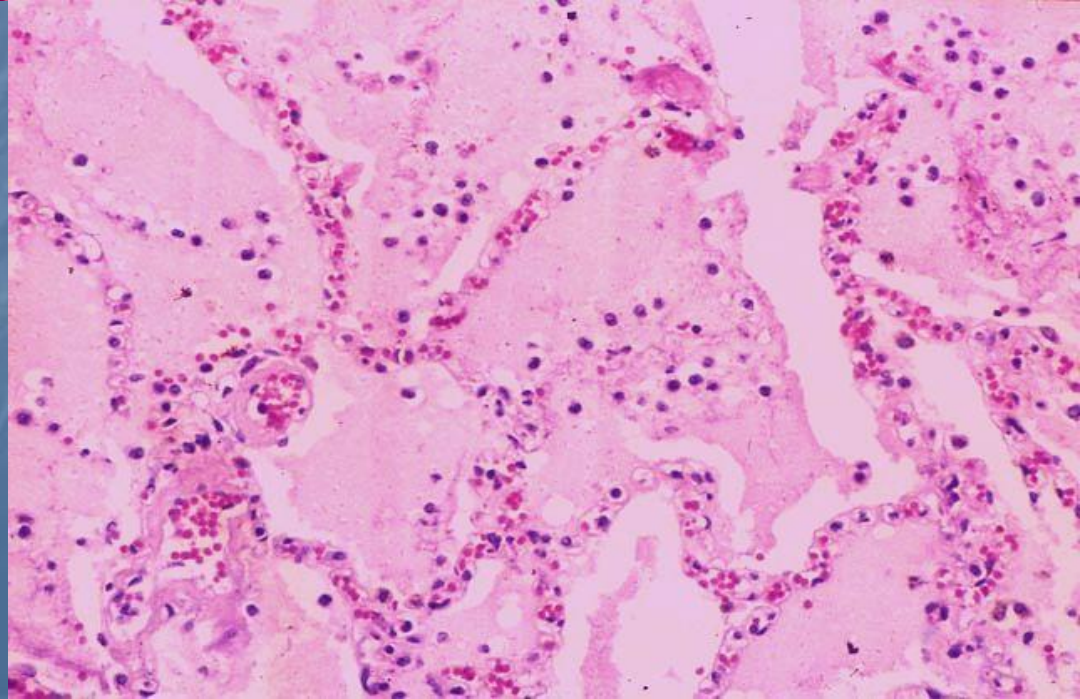


**Veziculă epidermică
cu exsudat seros.**

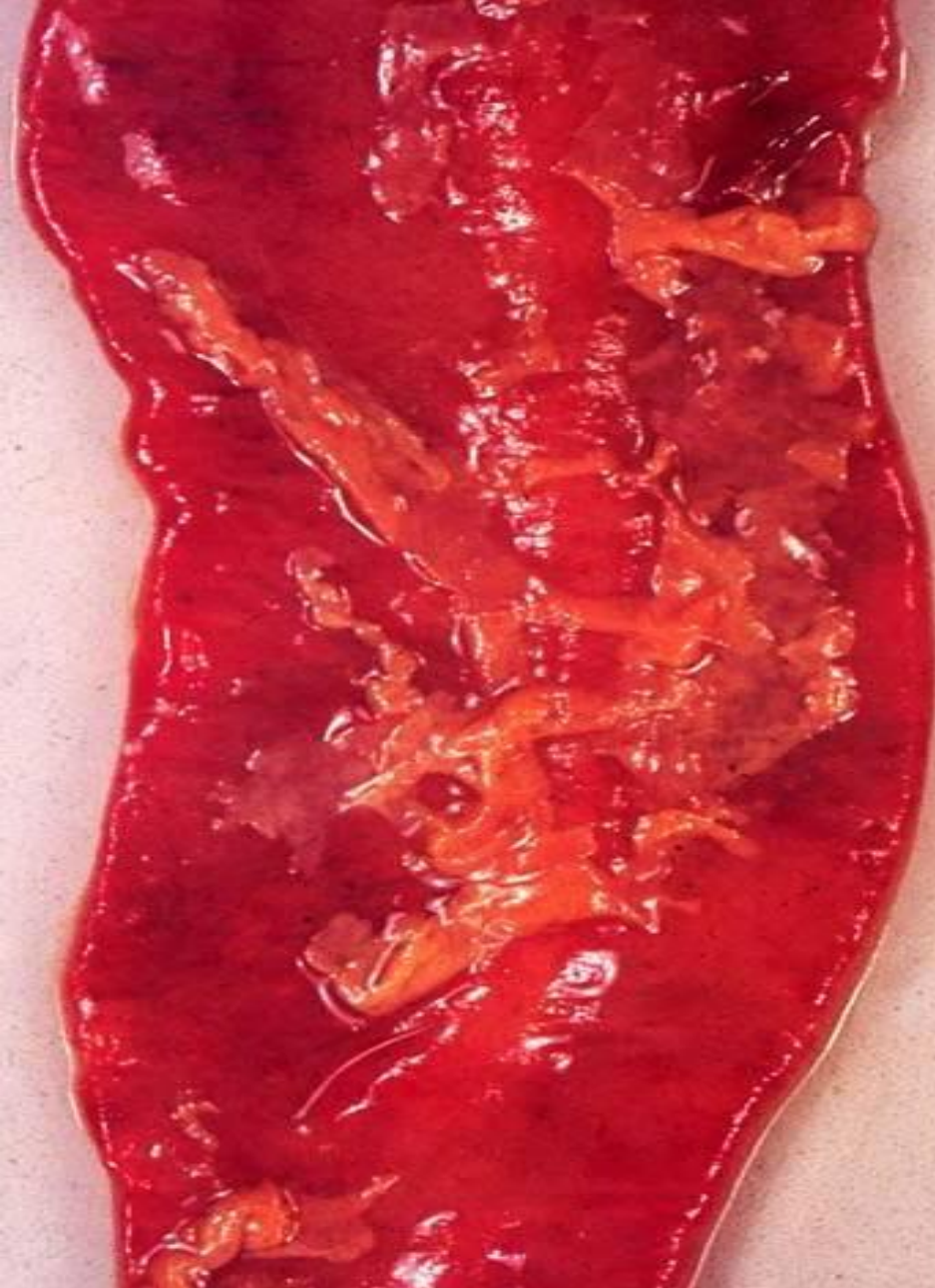
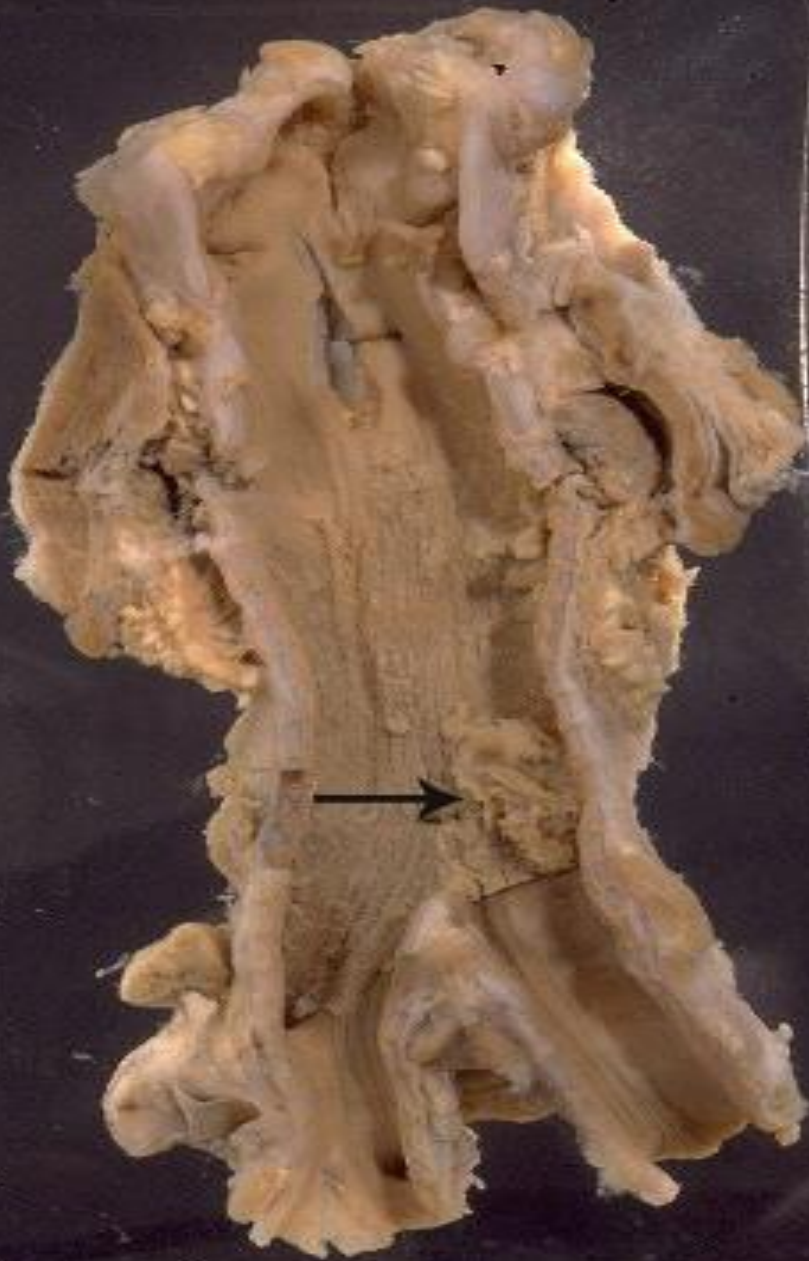


**Pneumonie focală
seroasă.**

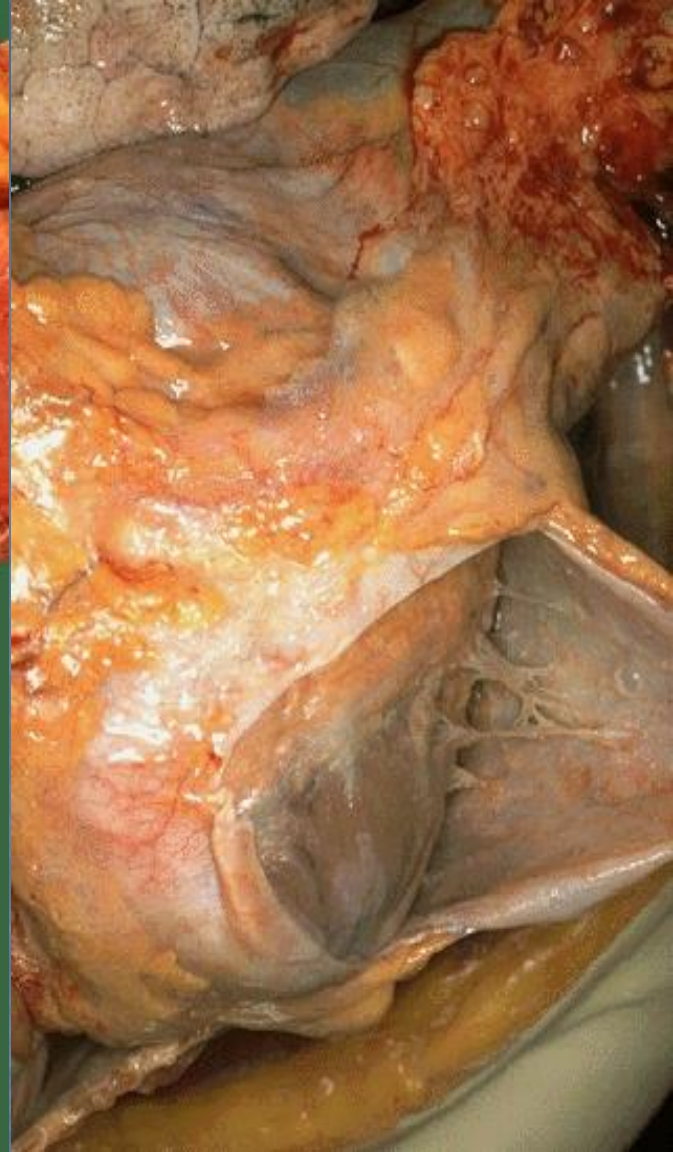
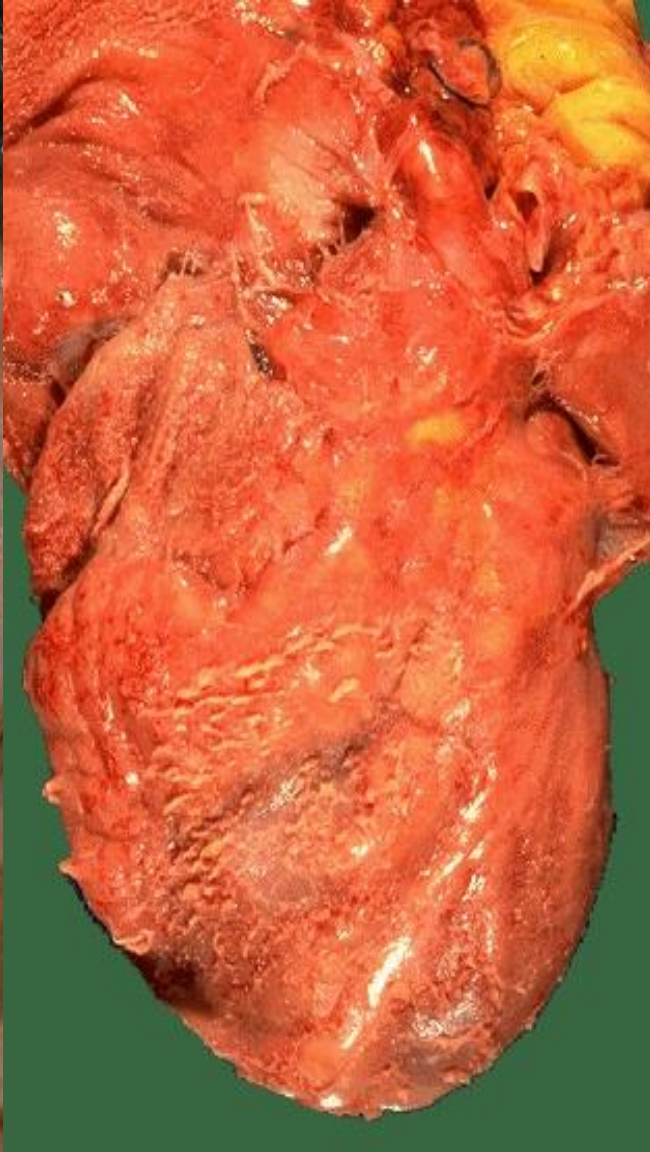
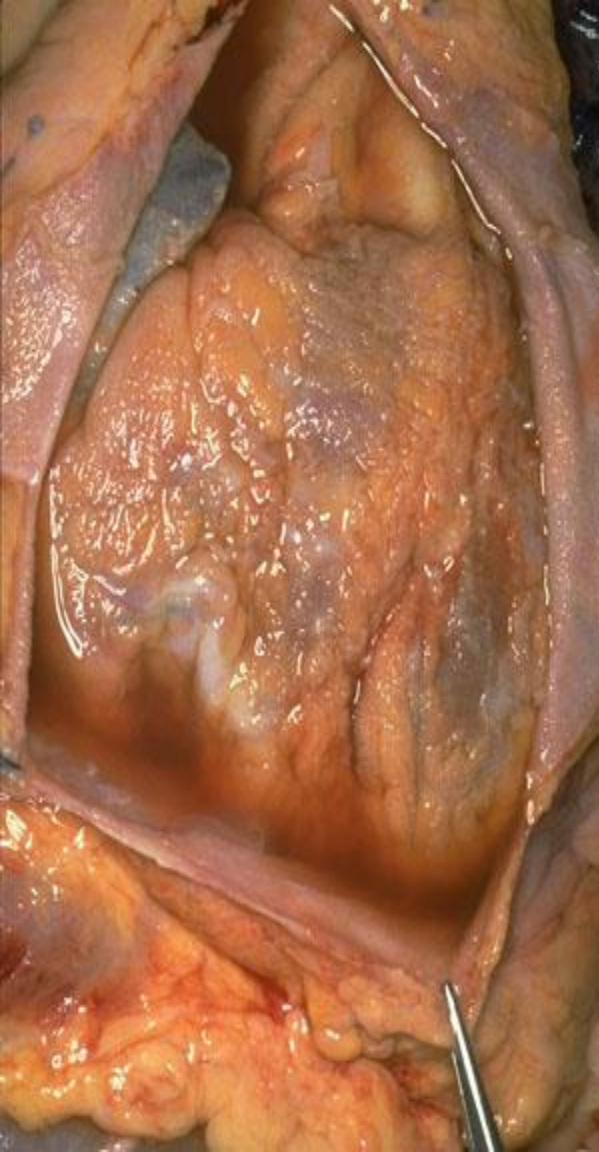
Inflamație fibrinoasă.

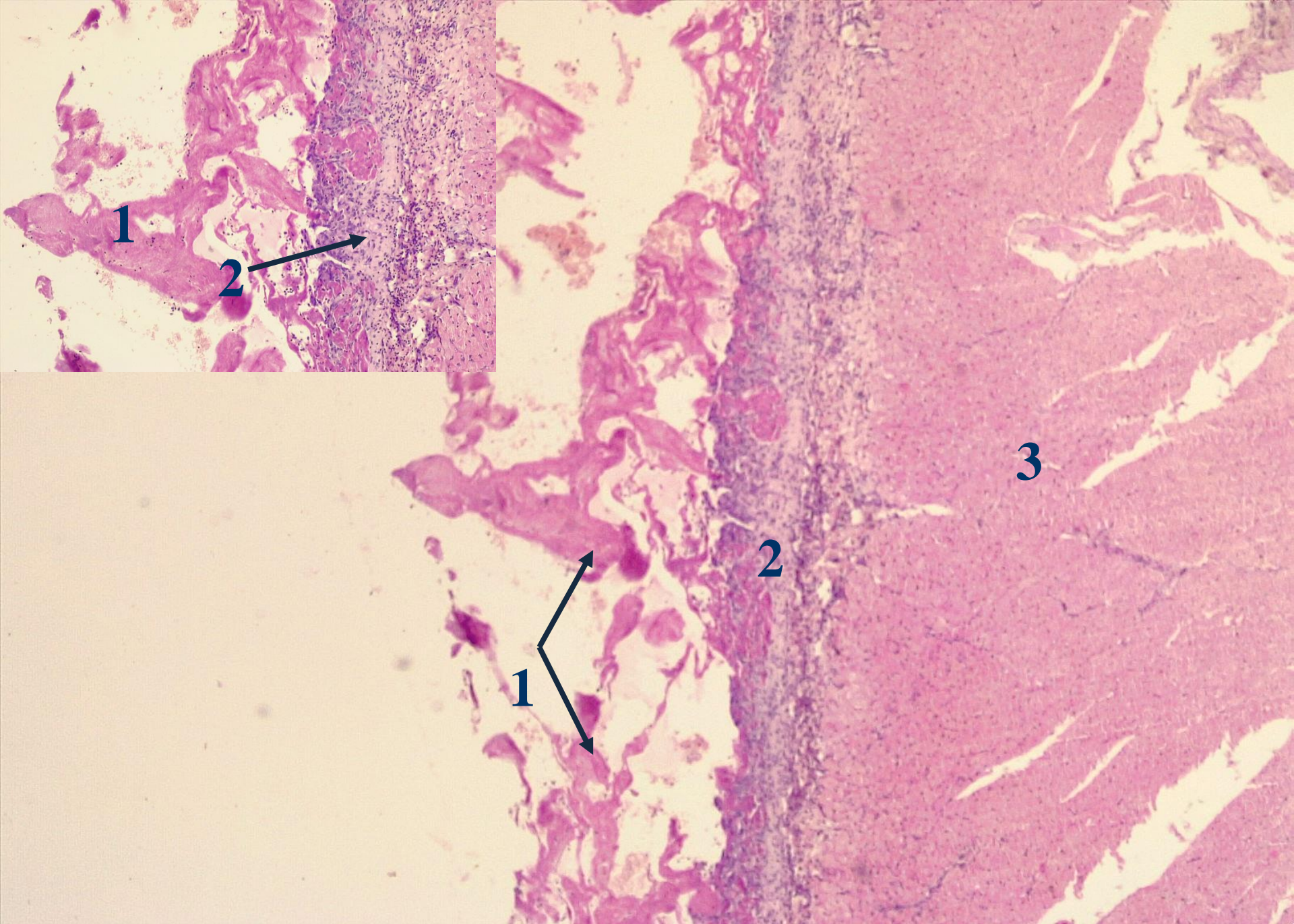




**Pneumonie francă
lobară**
*(stadiul de hepatizație
cenușie).*

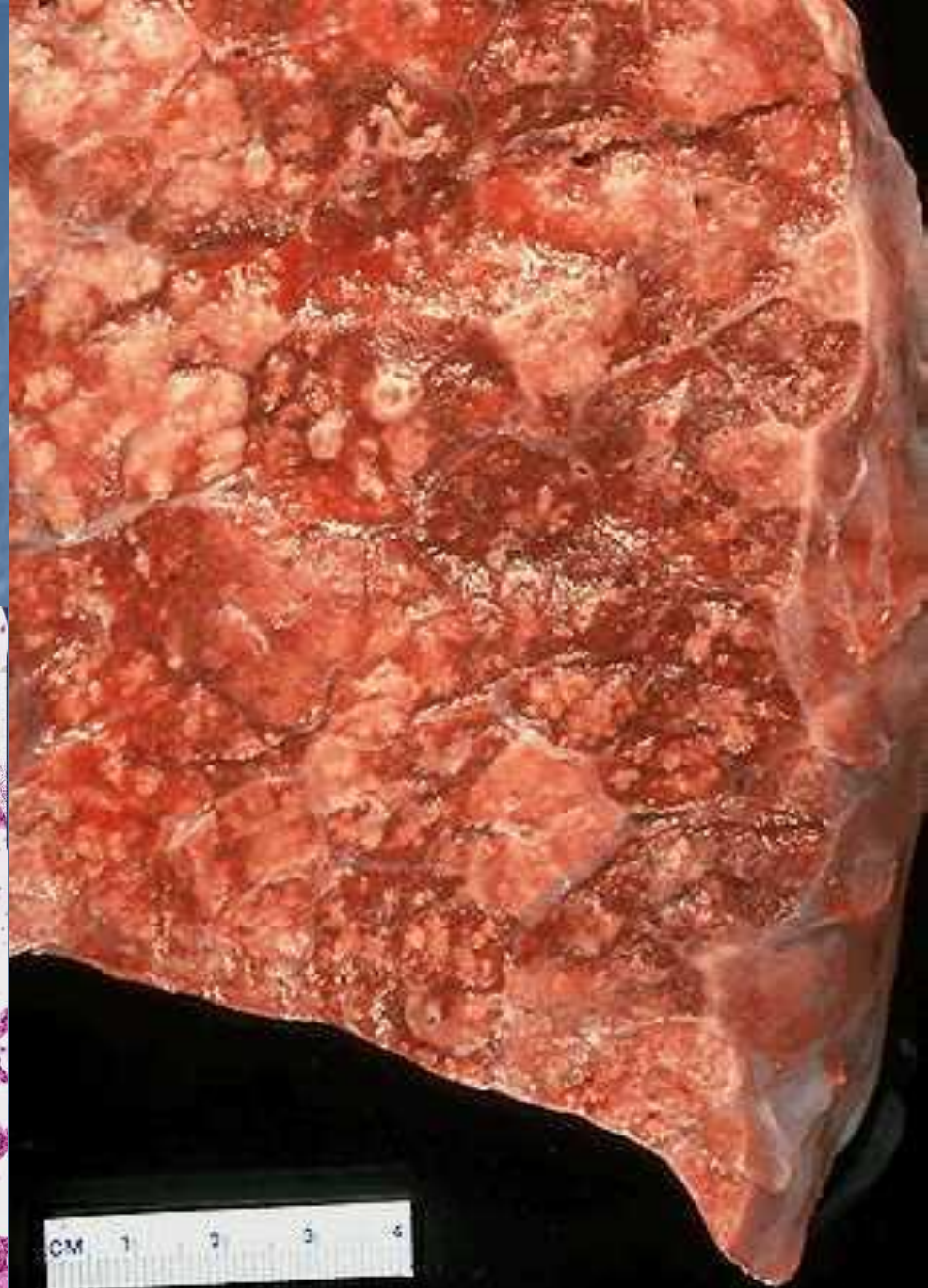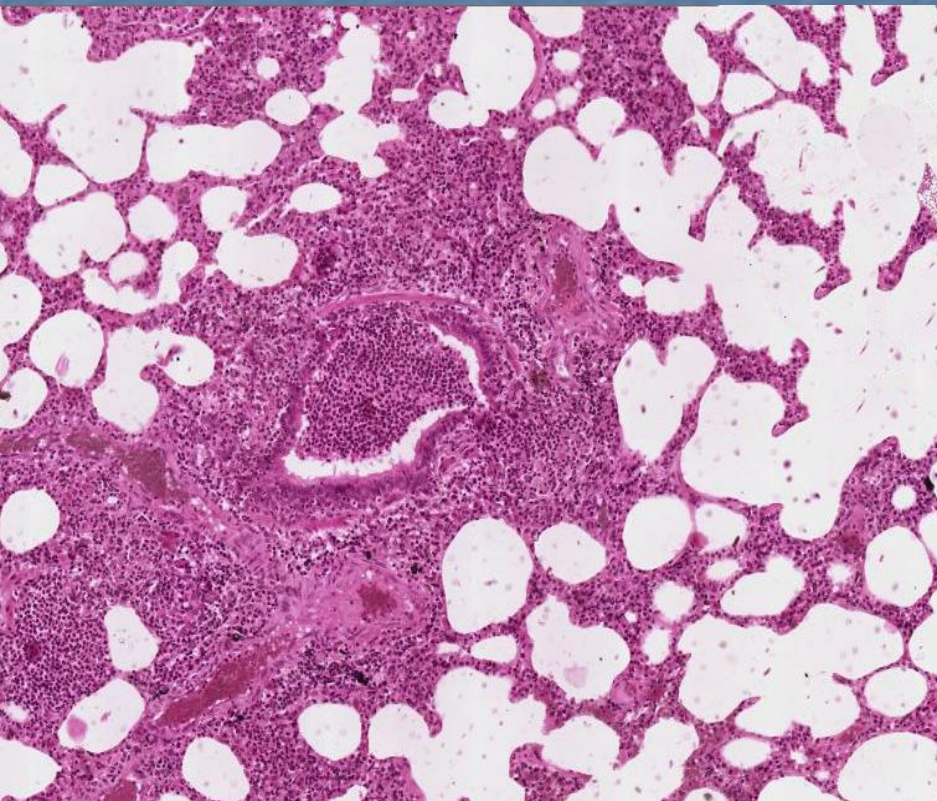


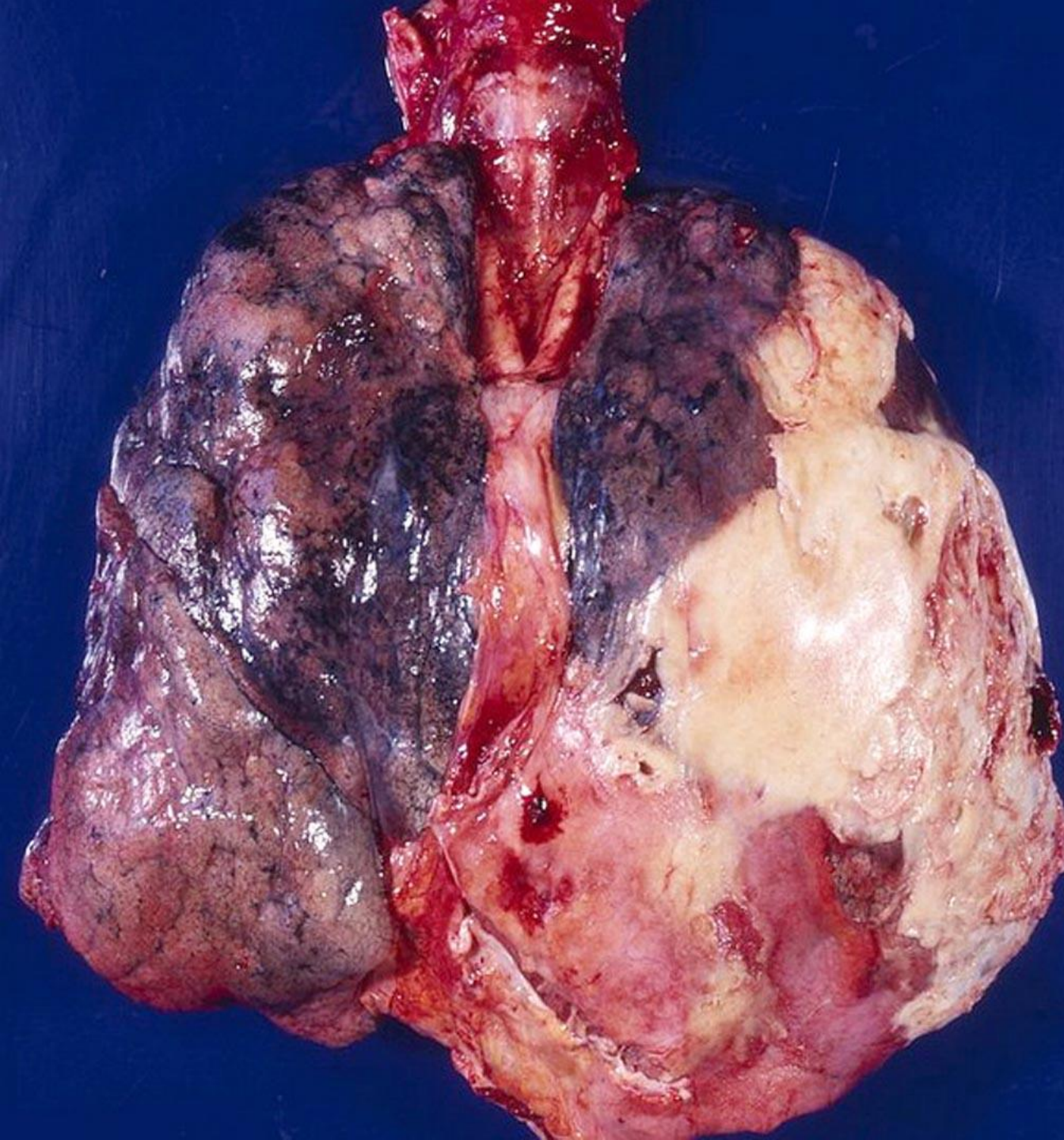
Pericardită fibrinoasă.



№ 62. Pericardită fibrinoasă. (Colorație H-E.).

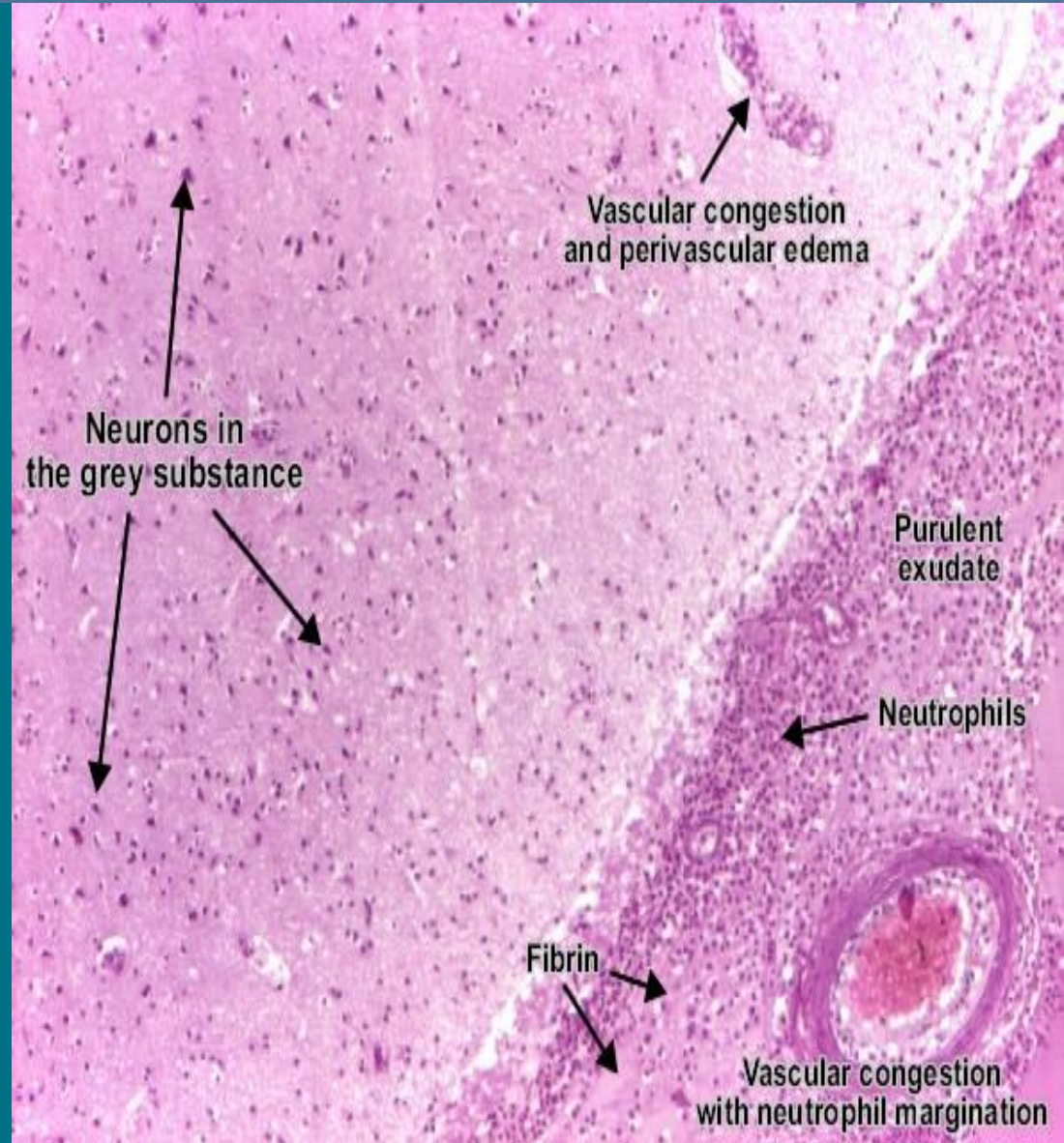
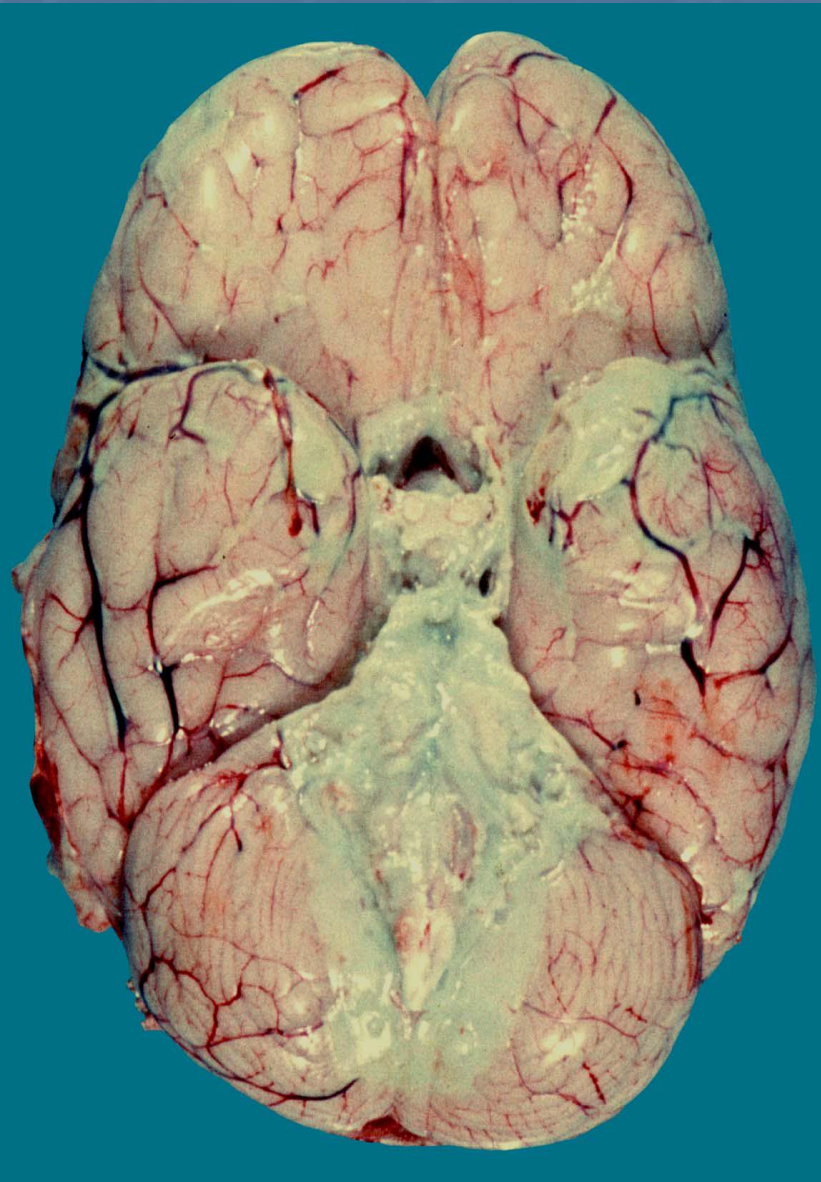Pneumonie focală.

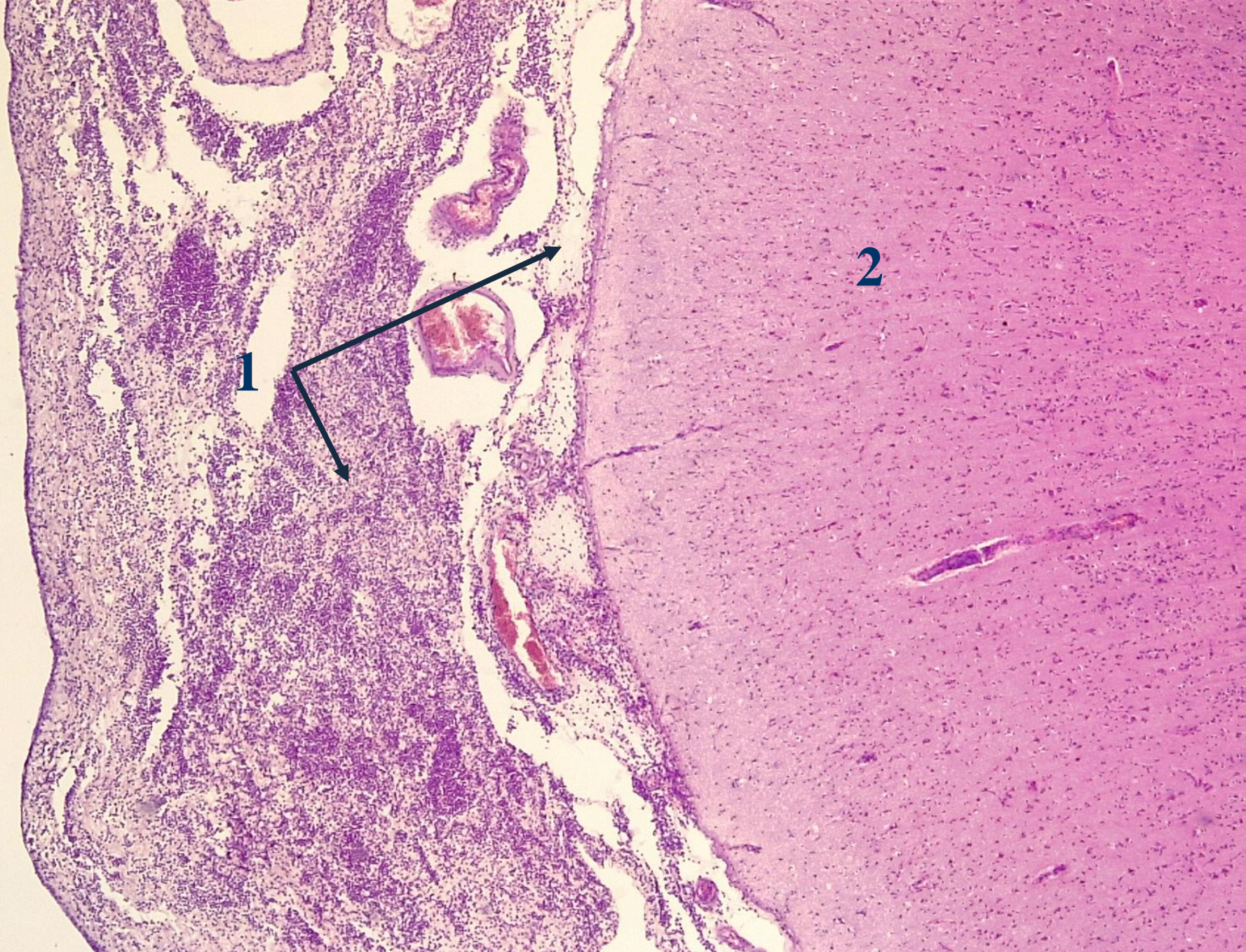




**Pleurită purulentă
(empiem pleural).**

Leptomeningită purulentă.

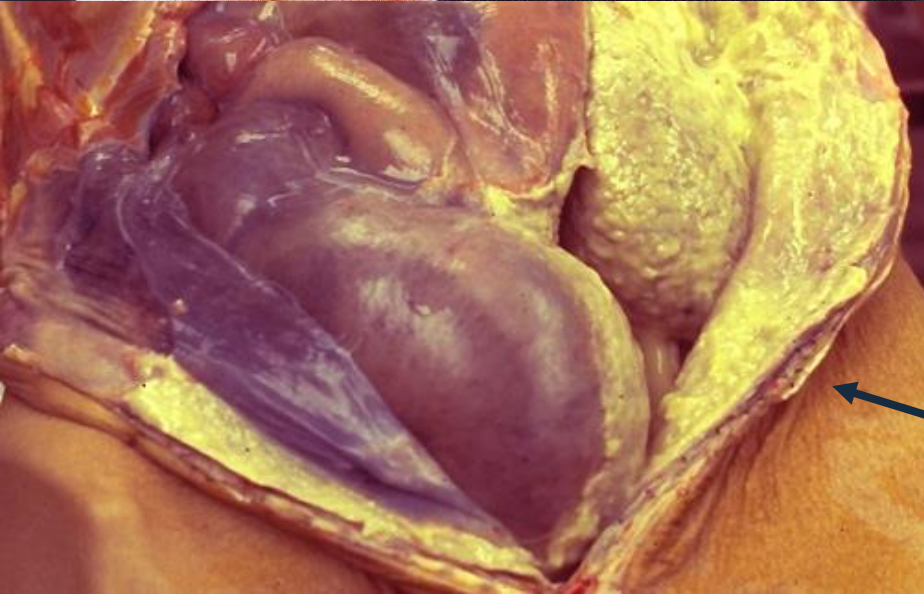
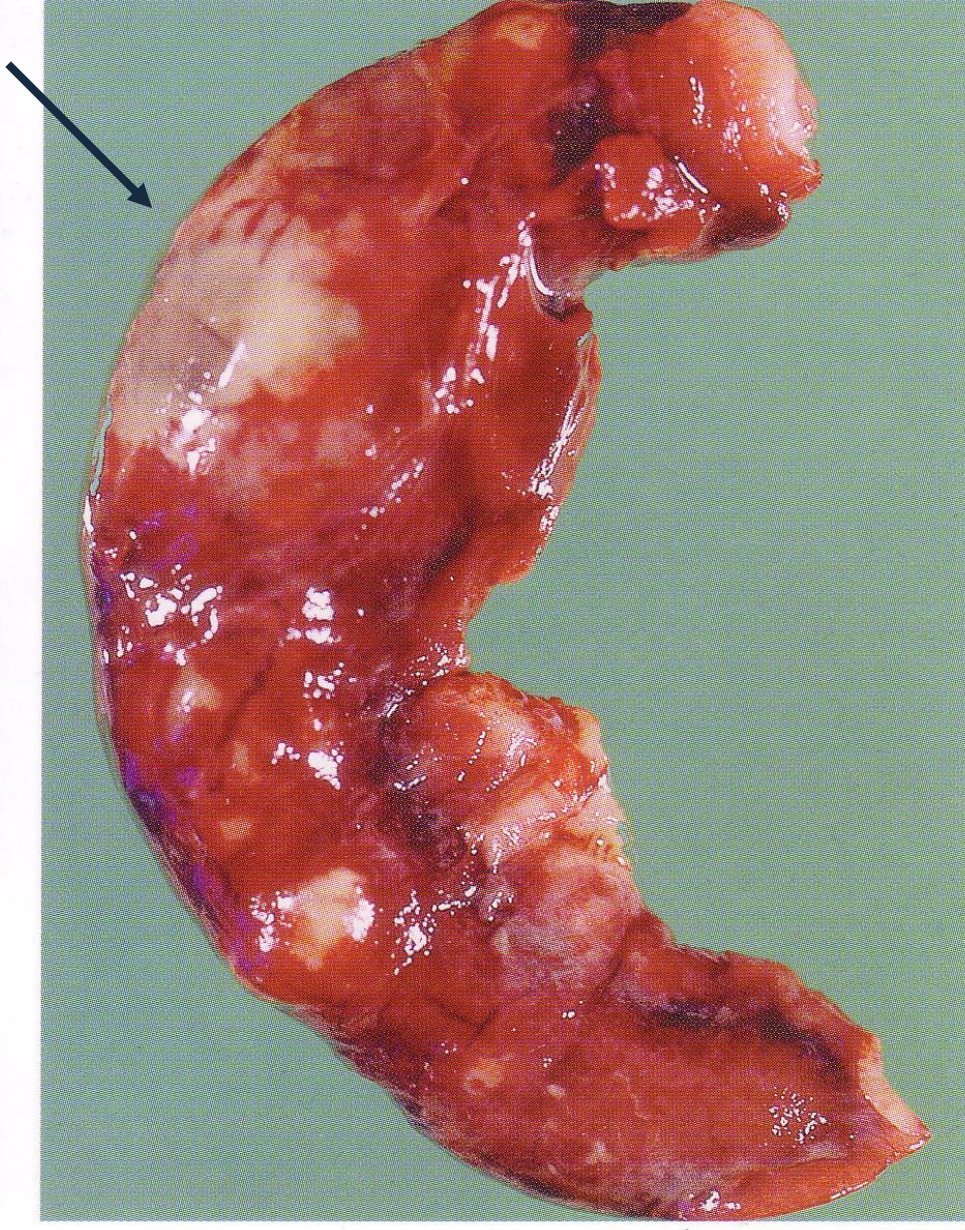
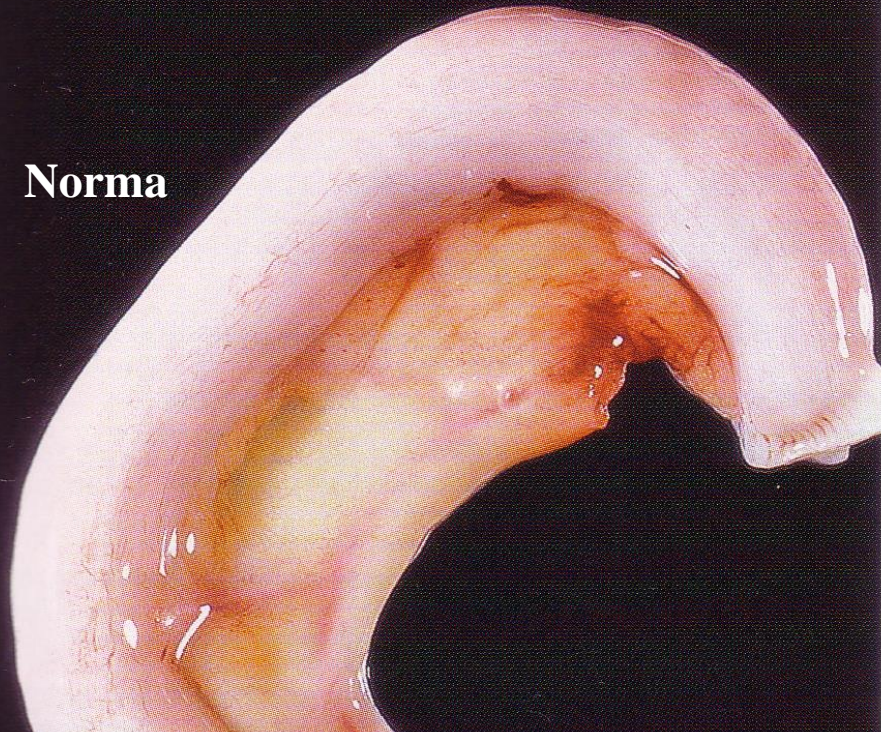




№ 28. Leptomeningită purulentă. (Colorație H-E.).

Apendicită acută flegmonoasă.

Norma



**Peritonită purulentă
(complicație).**

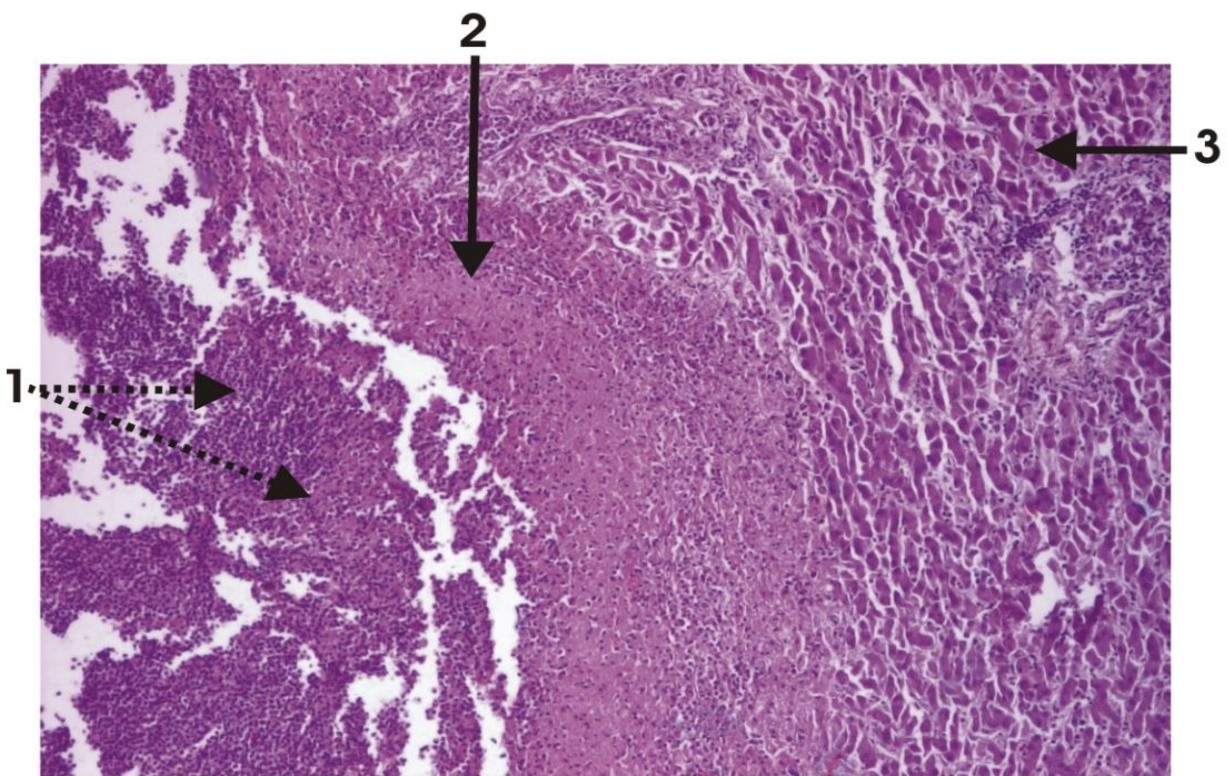
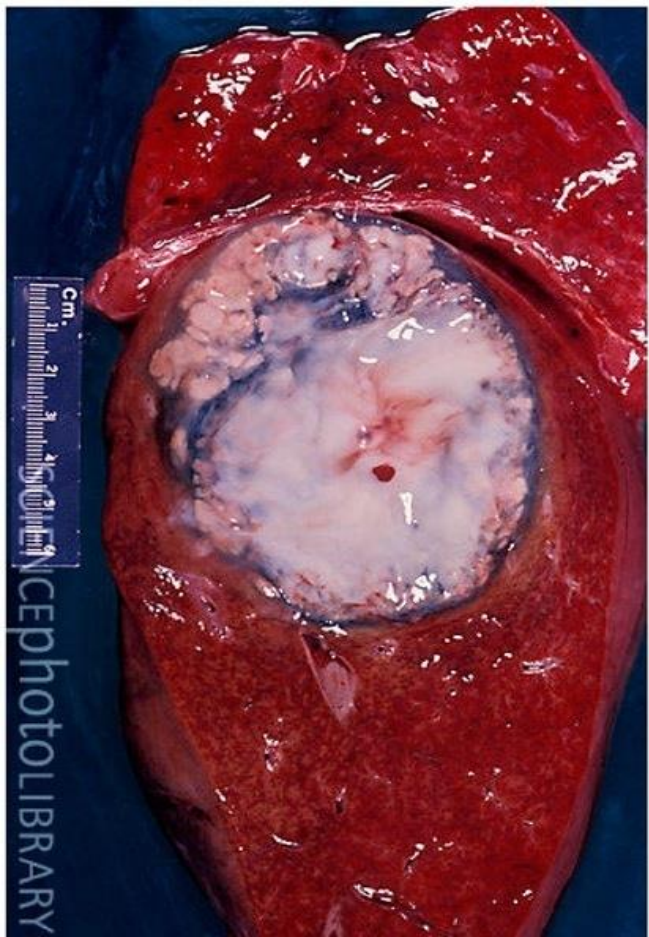
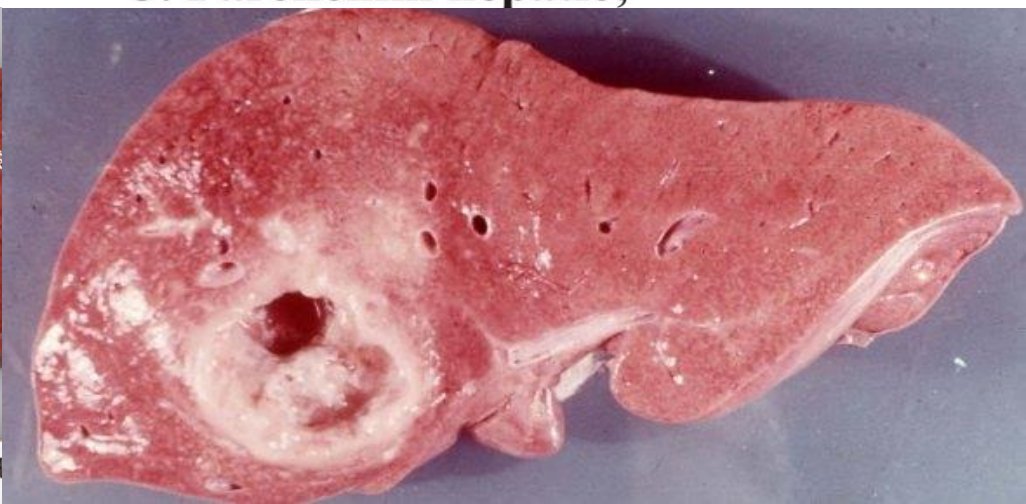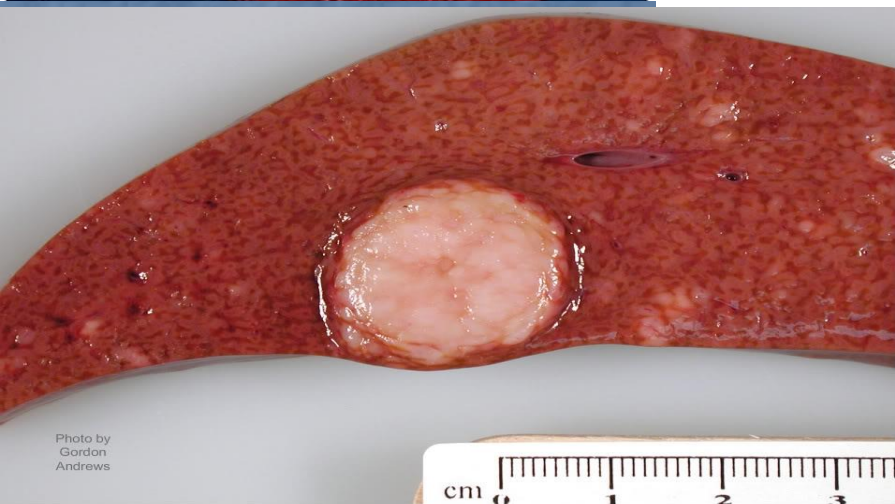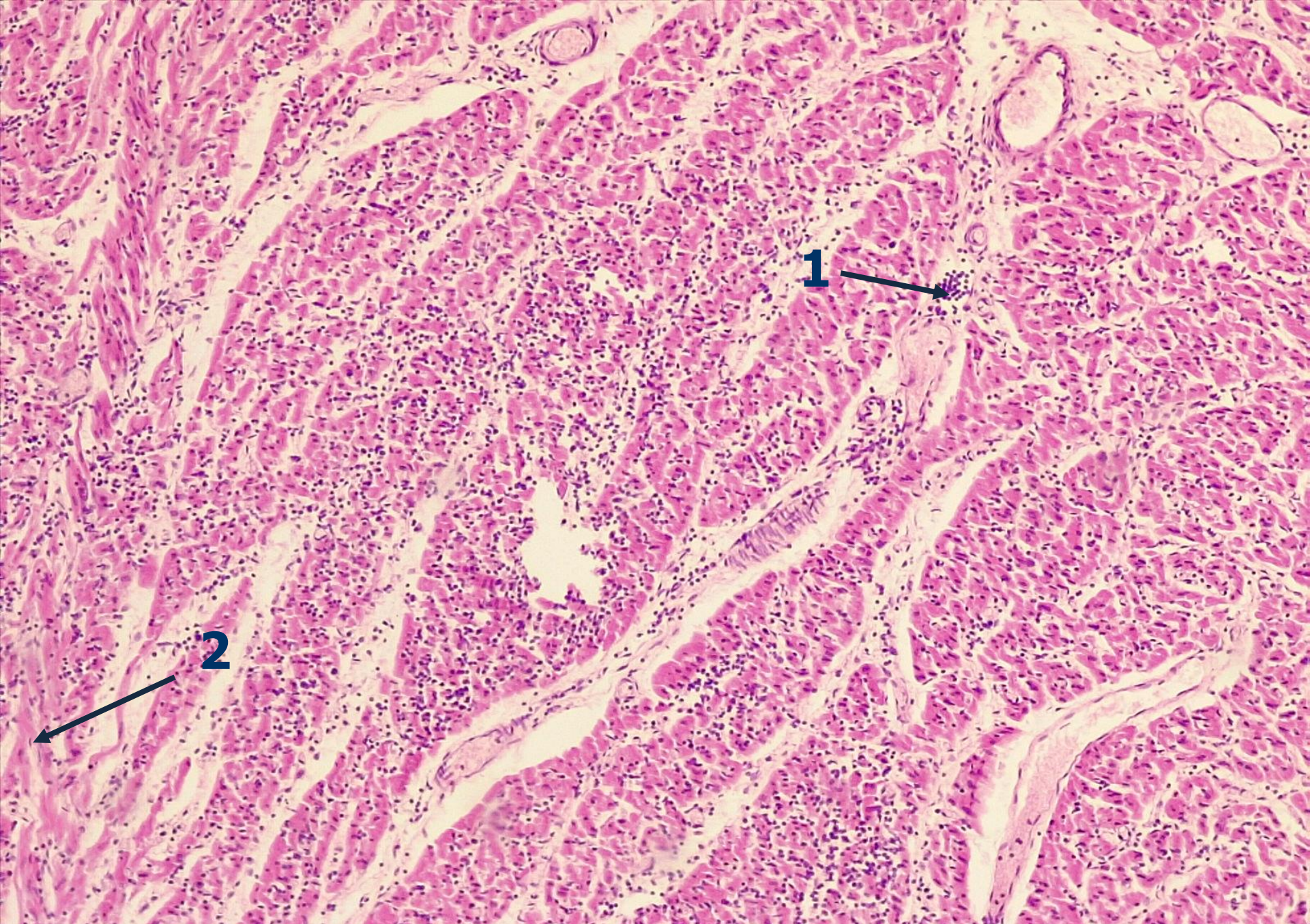
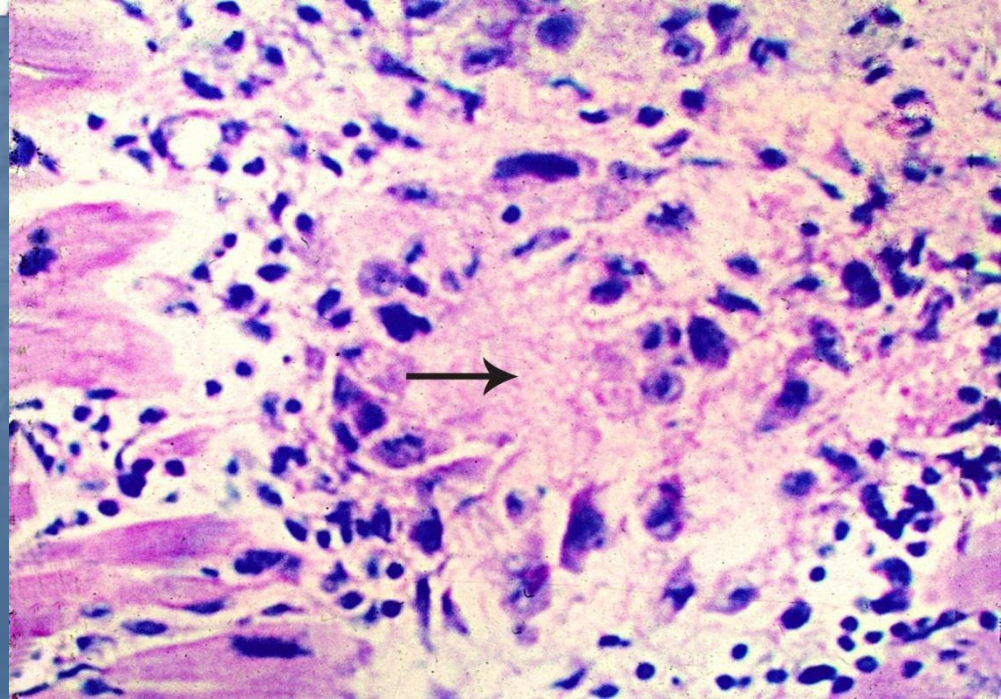
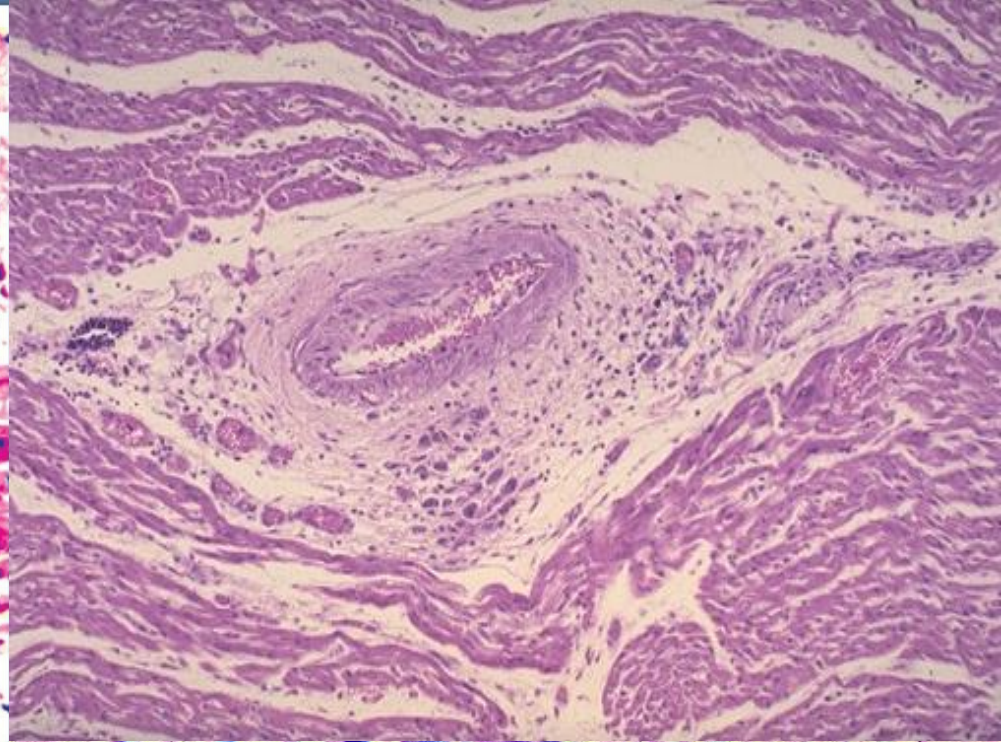
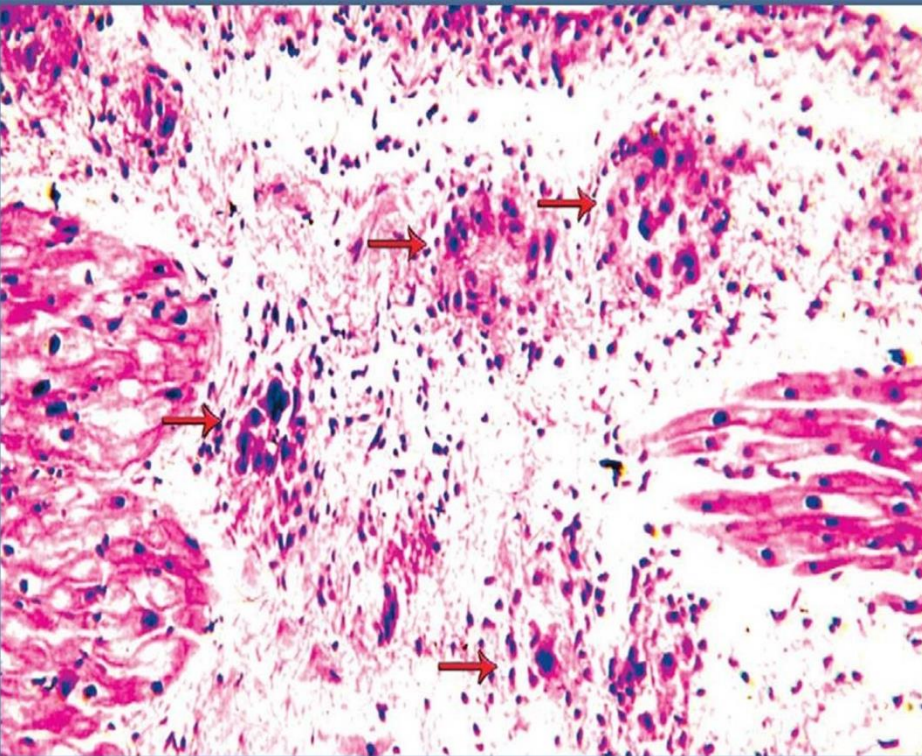


Fig.IV.A.5 Abces hepatic, col. H.E., Ob. 4
1. Detritus necrotic si PMN-uri; 2. Capsula piogena;
3. Parenchim hepatic;

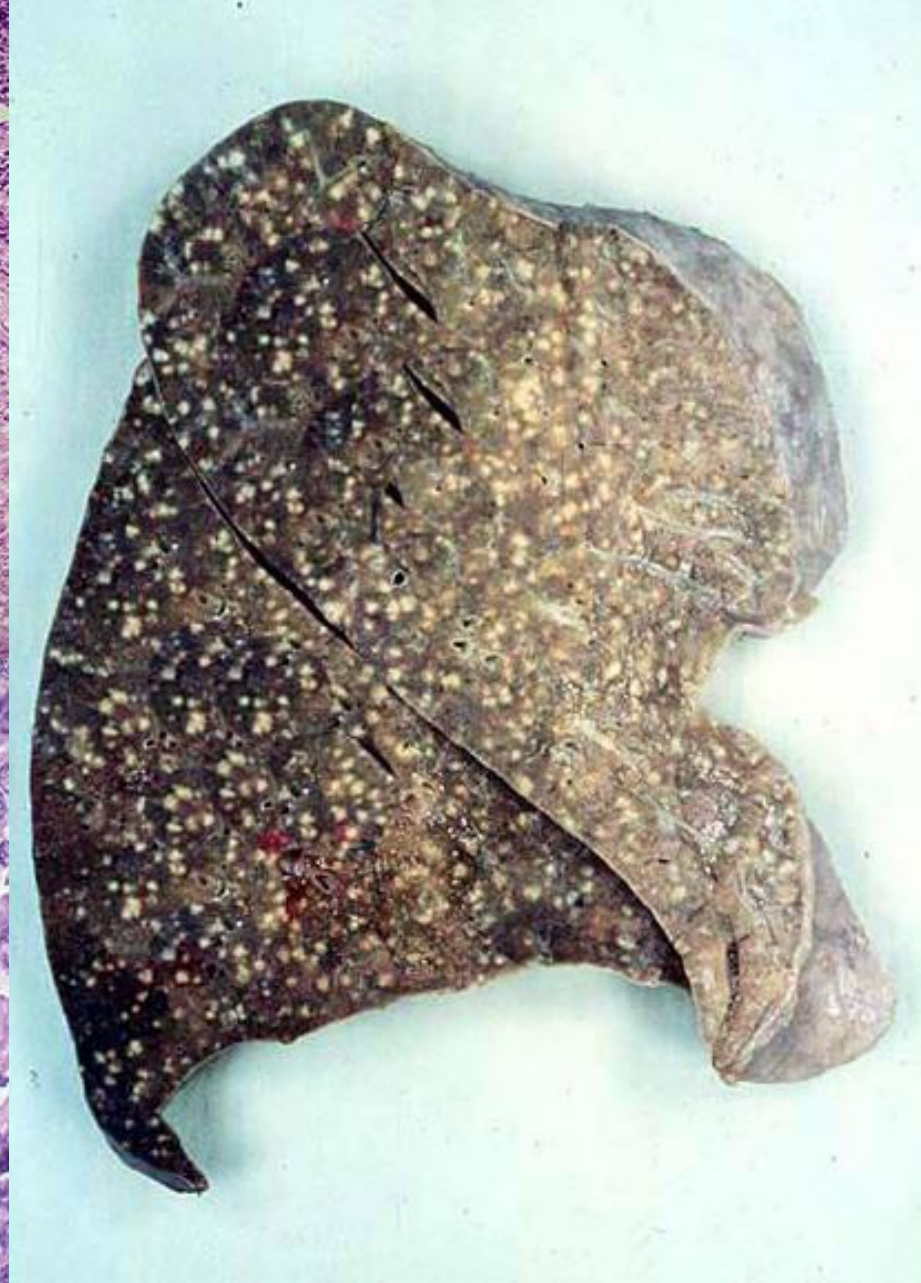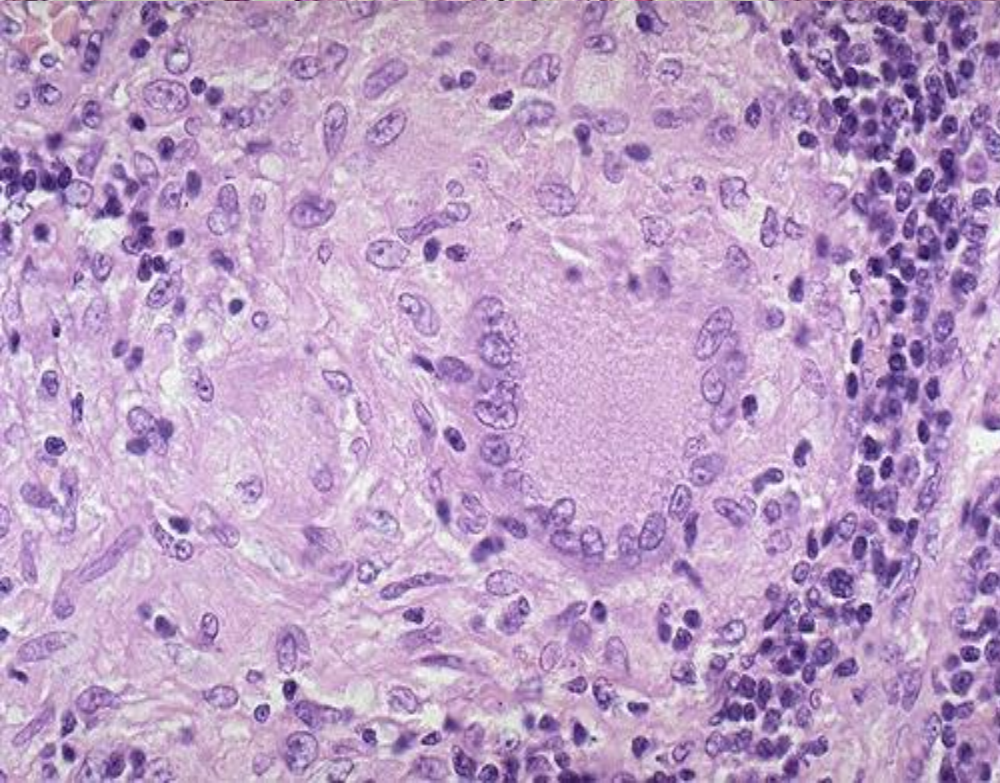
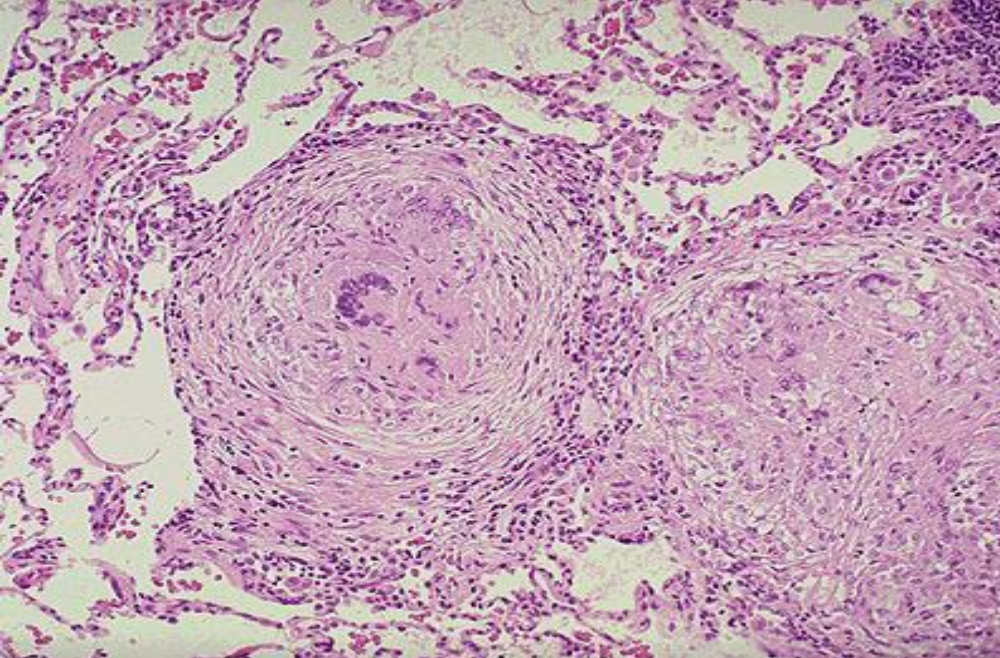




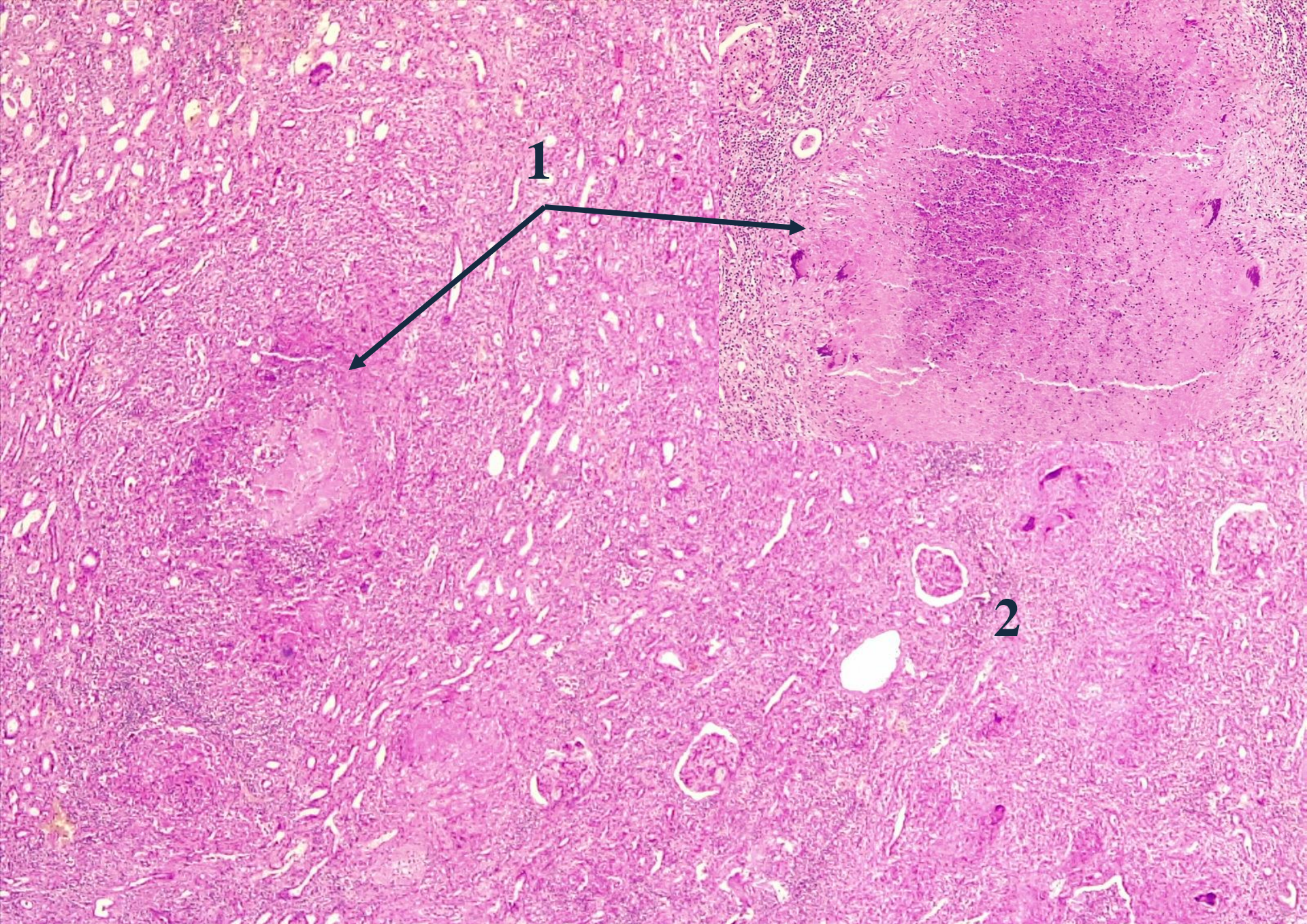
№ 12. Miocardită interstițială. (*Colorație H-E.*)



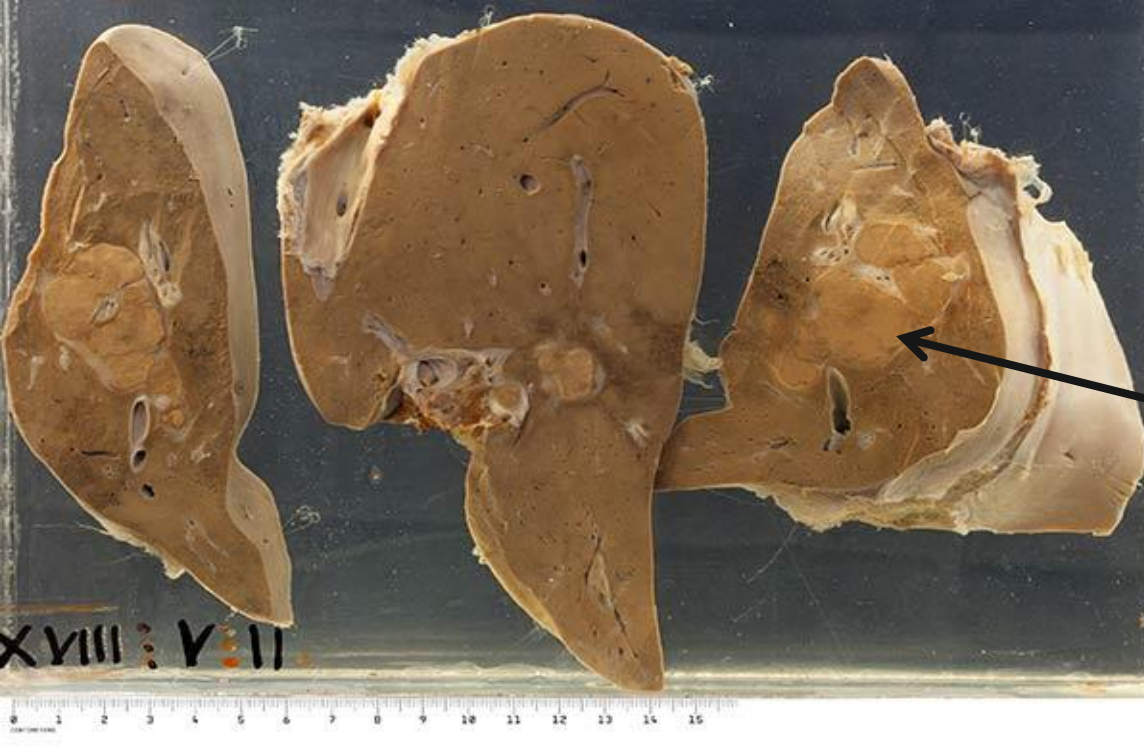Inflamația granulomatoasă a
endocardului și a miocardului
în reumatism. (H-E).



**Granuloame tuberculoase
cu celule gigante de tip Langhans.**

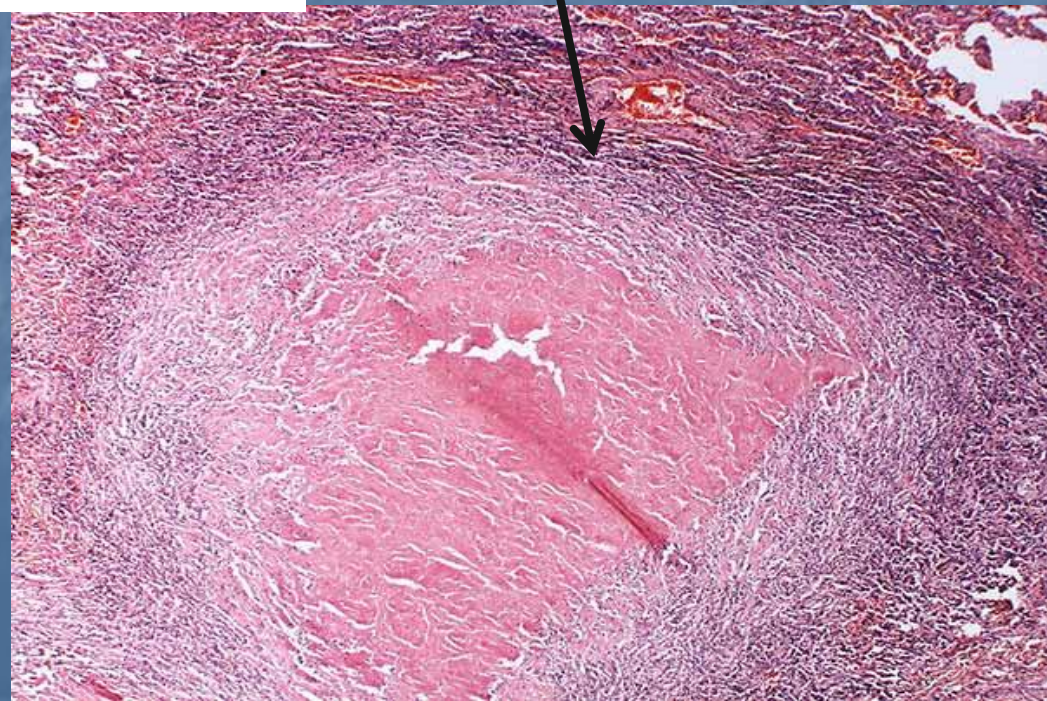

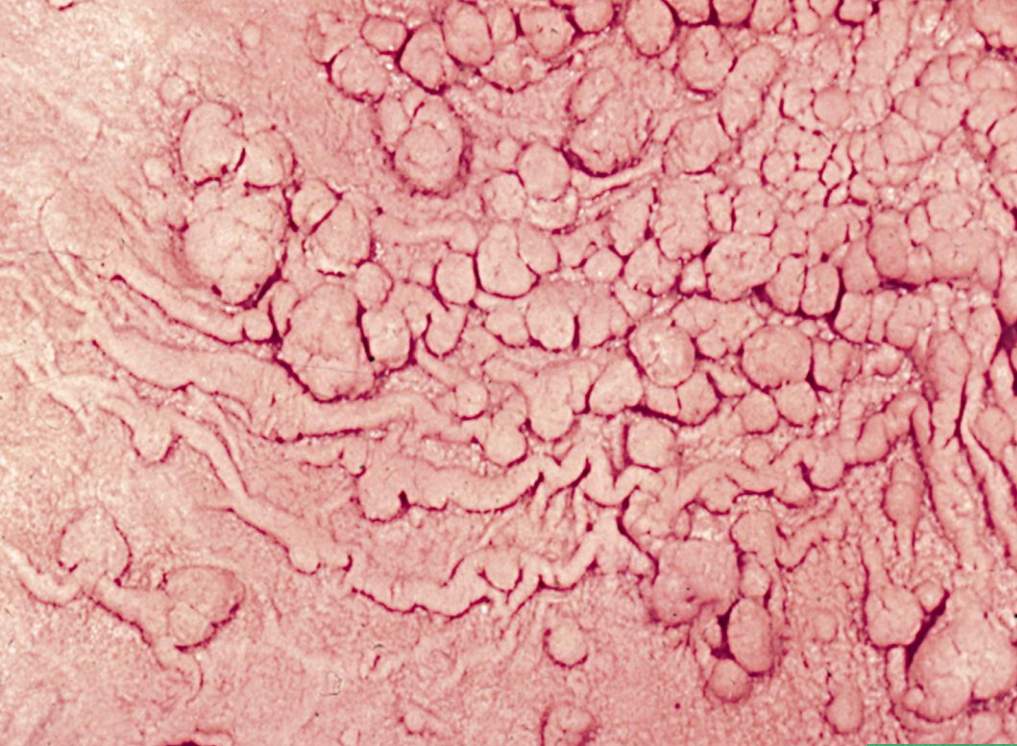
№ 82. Tuberculoza miliară renală. (Colorație H-E.).



Goma sifilitică.

Ficat.





Polipoză gastrică.

Polip endometrial.

