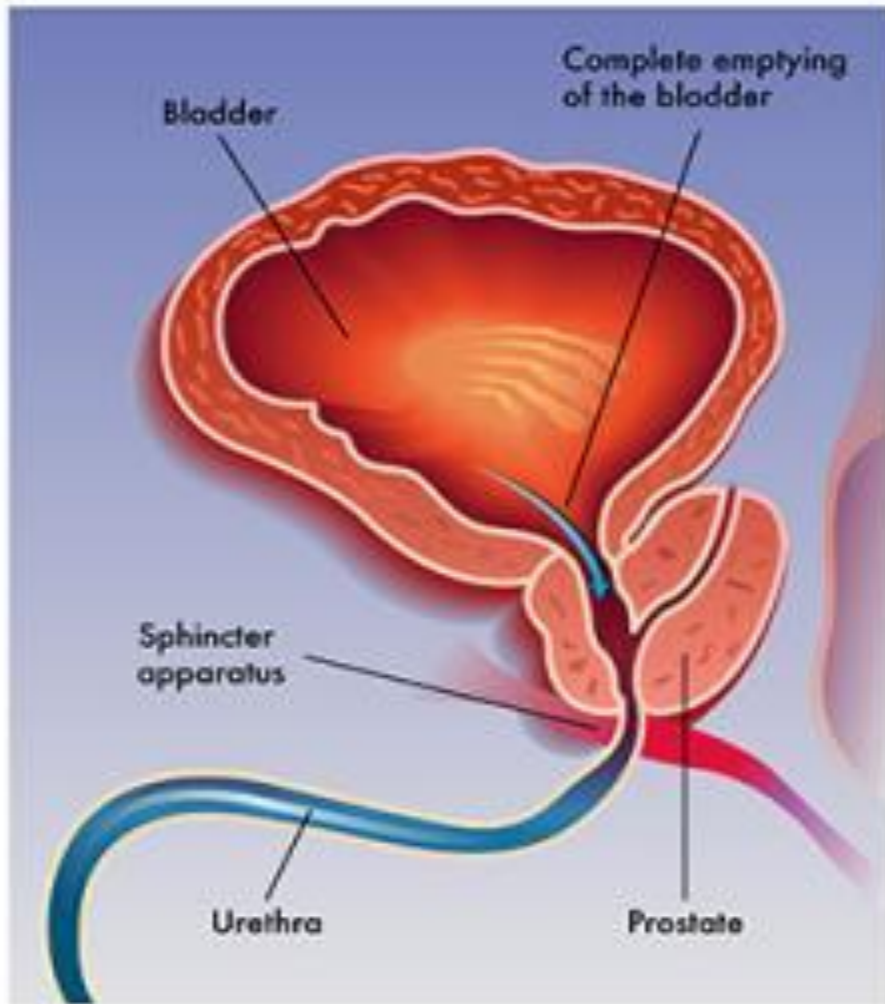
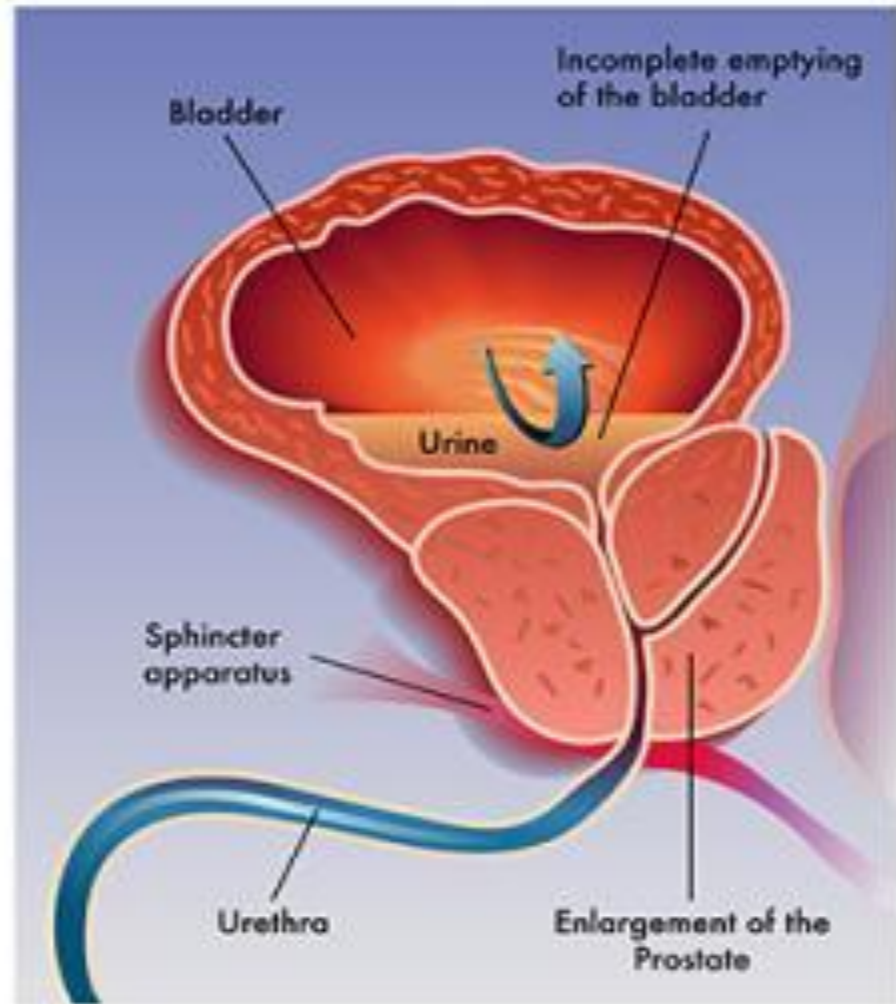


Normal Prostate



Prostatic Hypertrophy



**Male genital tract diseases. Urinary bladder pathology.
Sexual transmitted infections.**

Male genital tract diseases. Urinary bladder pathology. Sexual transmitted infections.

№ 227. Acinar adenocarcinoma of the prostate. (H.E. stain).

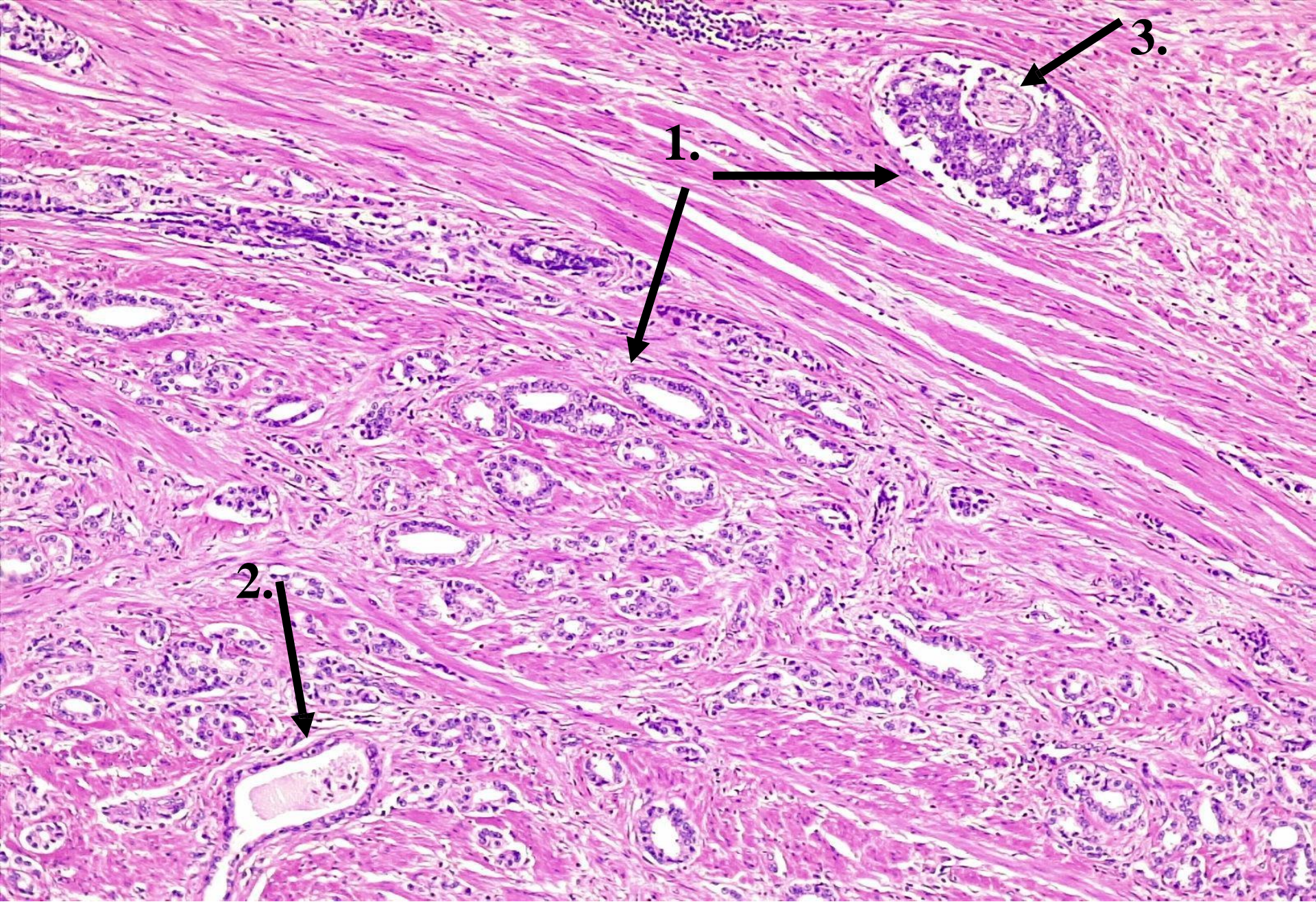
Indications:

- 1.Focus of atypical glandular structures;
- 2.Cystically dilated glands of irregular shape;
- 3.Neoplastic glands with perineural invasion.

In microspecimen there are agglomerations of small, deformed, compact, "back to back" cancer glands, papillary invaginations and poor interglandular stroma. The glands are composed of a single layer of cubic or cylindrical epithelial cells, of intensely basophilic color, nuclei are enlarged with conspicuous nucleoli. The basal cell layer present in the benign glands is absent. Invasive growth in adjacent tissue is observed. Around the cancerous foci are benign, dilated glands, varied in shape and size, in most of them there are papillary proliferations of the epithelium, which protrude into the lumen. The epithelium is bistratified, the inner layer is composed of cylindrical cells and the outer layer of flattened basal cells, nuclei are monomorphic located at the basal pole of cells, nucleoli are not highlights, in the stroma there is chronic inflammatory infiltration, predominantly lymphoid.

Prostate carcinoma is the second most common form of carcinoma in men after lung carcinoma, especially in older age groups. Usually, it develops in men over 50 years. Macroscopically the prostate can be enlarged in size or normal, sometimes even smaller than in the norm of dense consistency. In 95% of cases is located in the peripheral areas of the prostate, predominantly in the posterior lobe, as opposed to benign hyperplasia (BPH) which occurs in the inner periurethral region. In 15-20% of cases, nodular hyperplasia of the prostate is associated with carcinoma. It is considered that in 50% of men over 80 years old is asymptomatic (latent) prostate carcinoma. The most common histological variant (96%) is adenocarcinoma. An important role in the diagnosis of prostate carcinoma is puncture-biopsy.

Complications: invading seminal vesicles, bladder wall, rectum and adjacent soft tissues. Lymphogenous metastasis occurs in the pelvic, iliac, paraaortal lymph nodes and hematogenous in bones (pelvis, vertebral column), lungs, kidneys, brain.



№ 227. Acinar adenocarcinoma of the prostate. (H.E. stain).

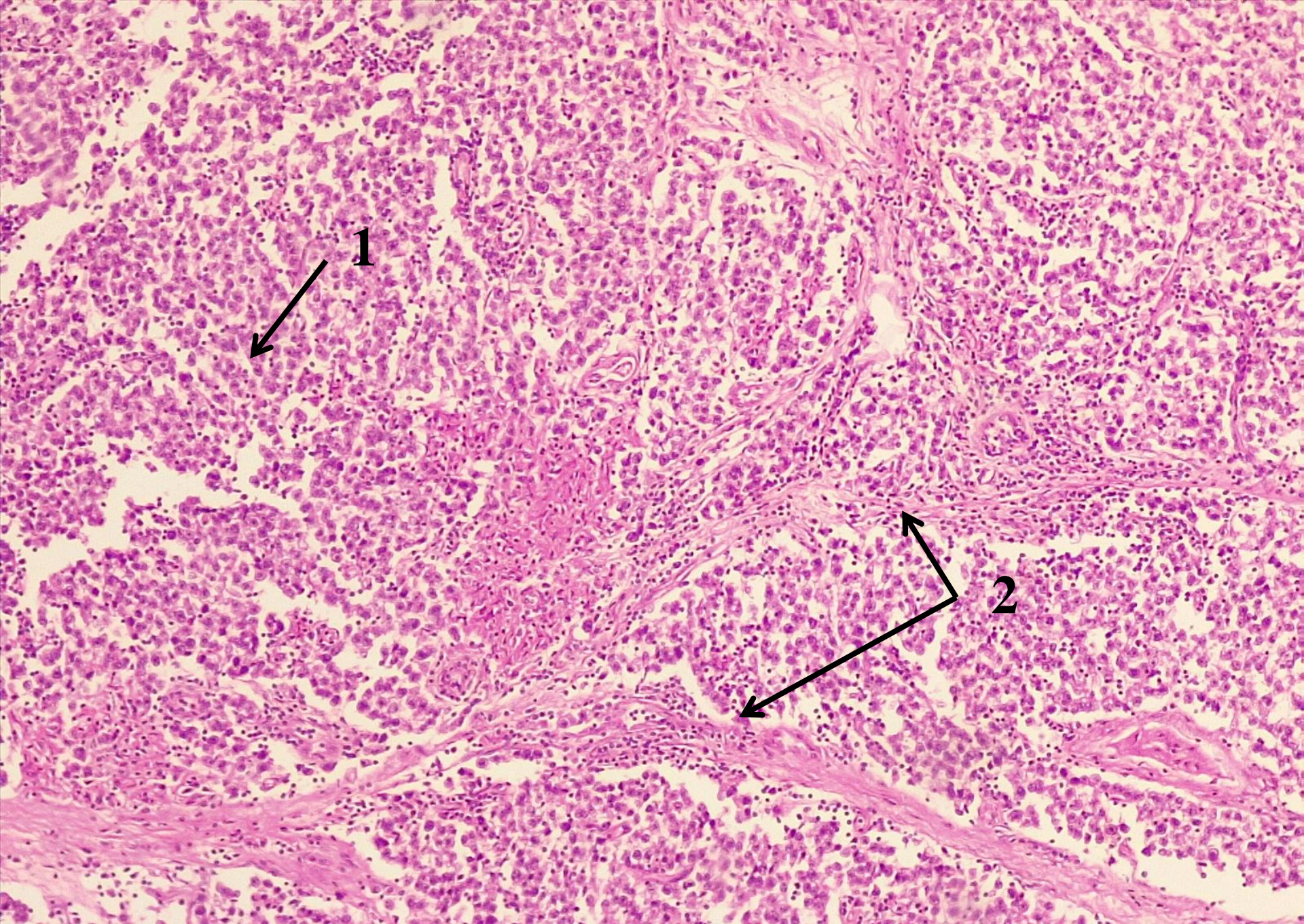
№ 214. Testicular seminoma. (*H.E. stain*).

Indications:

1. Tumoral cells with clear cytoplasm and polygonal shape.
2. Lymphoid infiltrates into connective tissue bundles.

The tumor node has a lobular structure, consists of large round or polygonal well contoured cells with clear cytoplasm due to its high glycogen content, the nuclei are with unevenly distributed chromatin with granular appearance, 1-2 prominent nucleoli, pathological mitoses are observed. Cellular agglomerations are separated by thin connective tissue septa with lymphocytic (T lymphocytes) and plasmacytic infiltrates, may be germinal centers; small foci of necrosis are observed.

Seminoma is the most common malignant tumor from germ cells (~ 50% of the total number of germ cells tumors) and the most common testicular tumor. Histologically it is identical with ovarian dysgerminoma. It is found in young men from 30 to 49, it is rare until puberty and after 70 years. It is a unilateral tumor, macroscopically can be one or more tumor nodules of soft, elastic consistency, on section of light gray color, small foci of necrosis and hemorrhages may occur. The first metastases appear in the retroperitoneal lymph nodes, later in the mediastinal and cervical ones, visceral metastases develop late, more frequently in the lungs. Main risk factors: family predisposition, cryptorchidism, gonadal dysgenesis.



№ 214. Testicular seminoma. (H.E. stain).

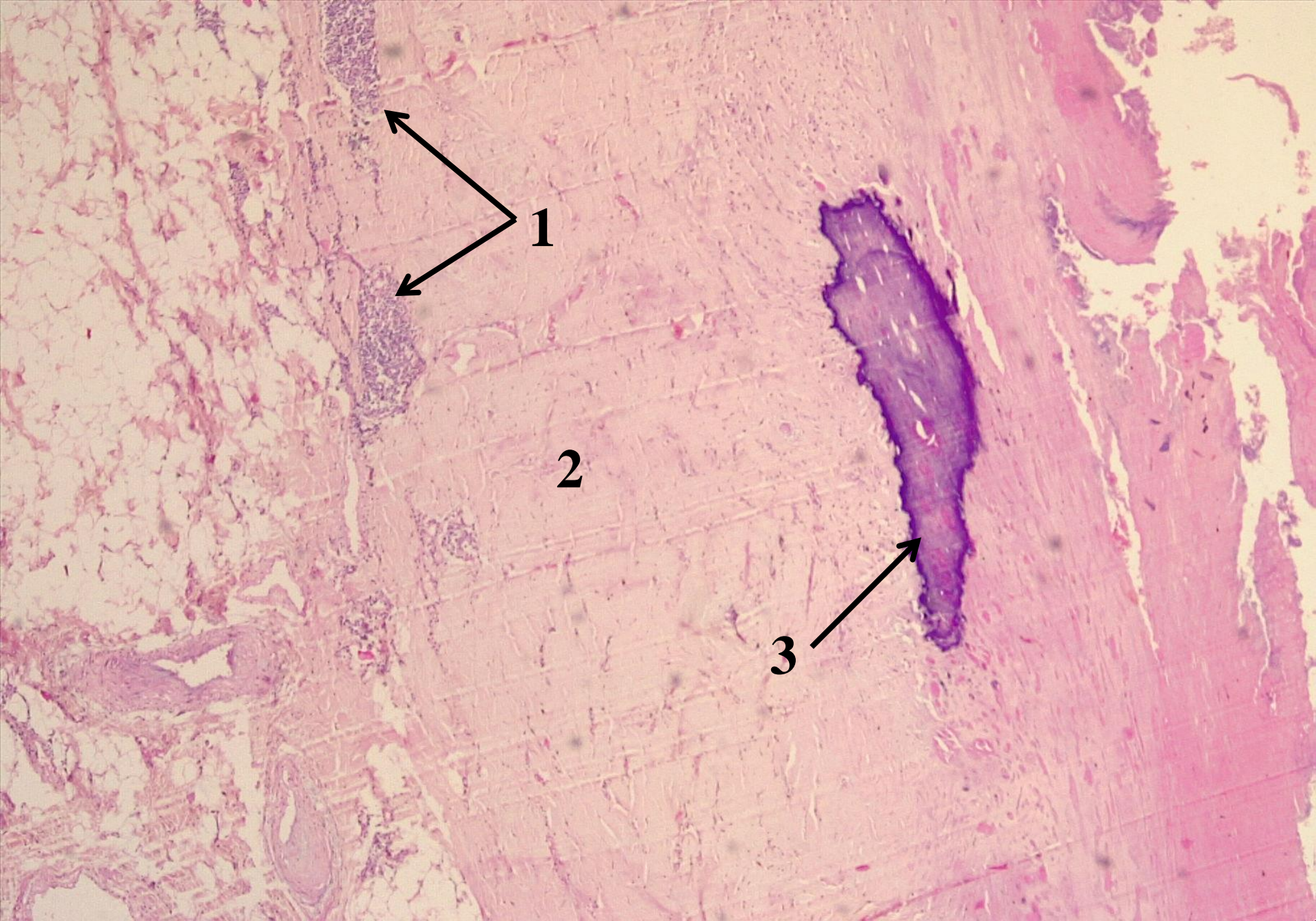
№ 33. Syphilitic mesaortitis. (*H.E. stain*).

Indications:

1. Lymphoplasmacytic infiltration around vasa vasorum, in adventitia and in media of aortic wall ;
2. Foci of destruction of elastic fibers;
3. Foci of calcinosis.

In the wall of the aorta, media and adventitia, infiltrates with lymphocytes, plasmocytes and macrophages are observed , can be Langhans giant cells located in the walls and around the vasa vasorum (endarteritis and periarteritis of vasa vasorum), there are foci of elastic membranes destruction with hyalinosis and calcinosis, the intima is thickened and hyalinized.

Syphilitic aortitis (mesaortitis) is encountered in the tertiary period of the disease, which develops over many years after infection in approximately 30% of the untreated patients. In ~ 80% of all patients with tertiary syphilis, aortitis is observed, affecting the ascending portion and the arch of aorta. It is considered that this preferential localization of the aortitis is due to the involvement of the mediastinal lymph nodes in the secondary syphilis and the spread of the treponema in the lymphatics around the arch of the aorta. The lesions decrease in intensity and disappear completely below the level of the diaphragm.



№ 33. Syphilitic mesaortitis. (*H.E. stain*).

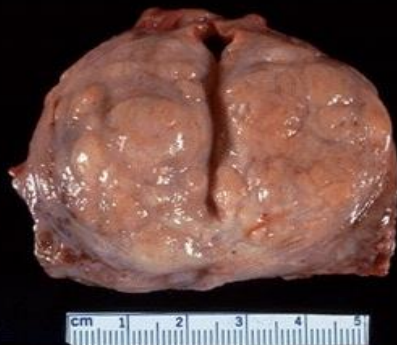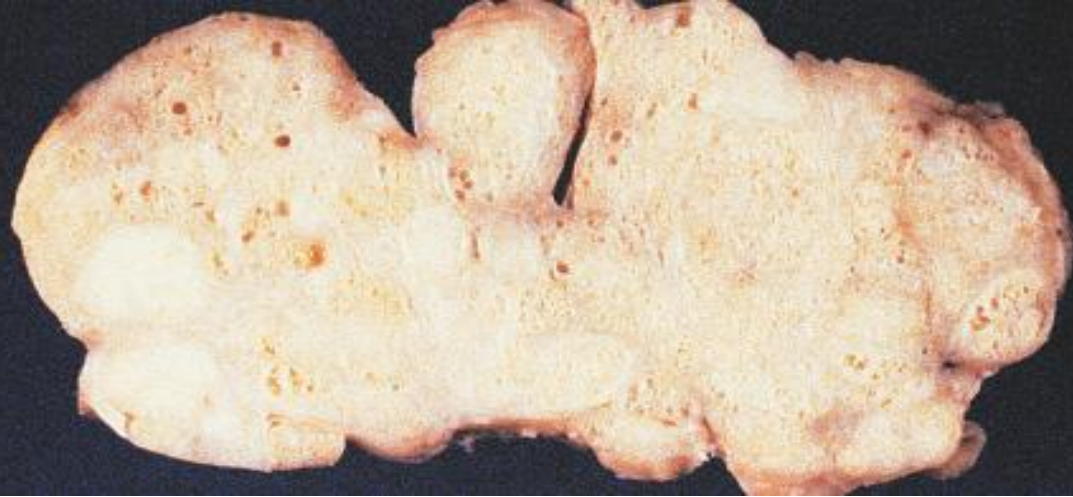
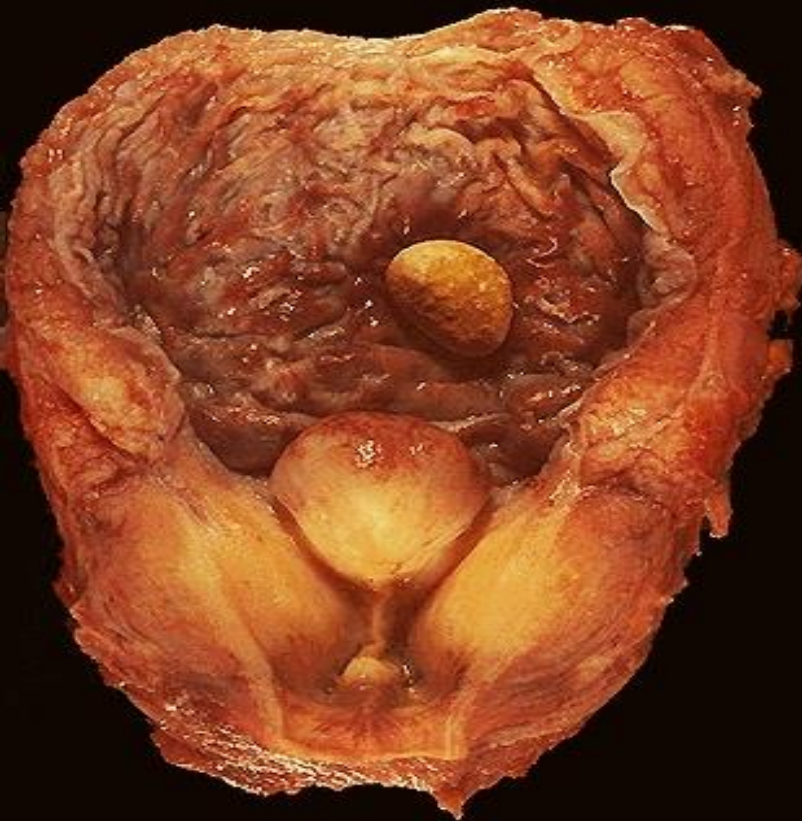II. Macrospecimens:

№ 90. Glandular prostatic hyperplasia with urinary bladder wall hypertrophy.

The prostate is enlarged in size, has a nodular appearance, dense consistency and protrudes into the cavity of the urinary bladder. The wall of the bladder is thickened, hypertrophied, the mucosa has a trabecular appearance. The hypertrophy of the urinary bladder wall is compensatory due to the compression of the prostatic portion of the urethra and retention of urine.

Prostatic nodular hyperplasia is a dyshormonal process, which occurs morphologically by proliferating of 3 types of tissues: glandular, connective tissue and smooth muscle in varying proportions. The prostate is enlarged in size, mass up to 100 g and above (norm 20-25 g), with nodular structure, on section nodules have solid consistency or may contain cystic cavities (dilated glands).

Urinary tract infections may be associated with the development of cystitis, ureteritis, ascending pyelonephritis, prostatitis, orhoepididimitis, hydroureter and hydronephrosis. In cases of prolonged urinary stasis, calculi may appear in the urinary bladder.

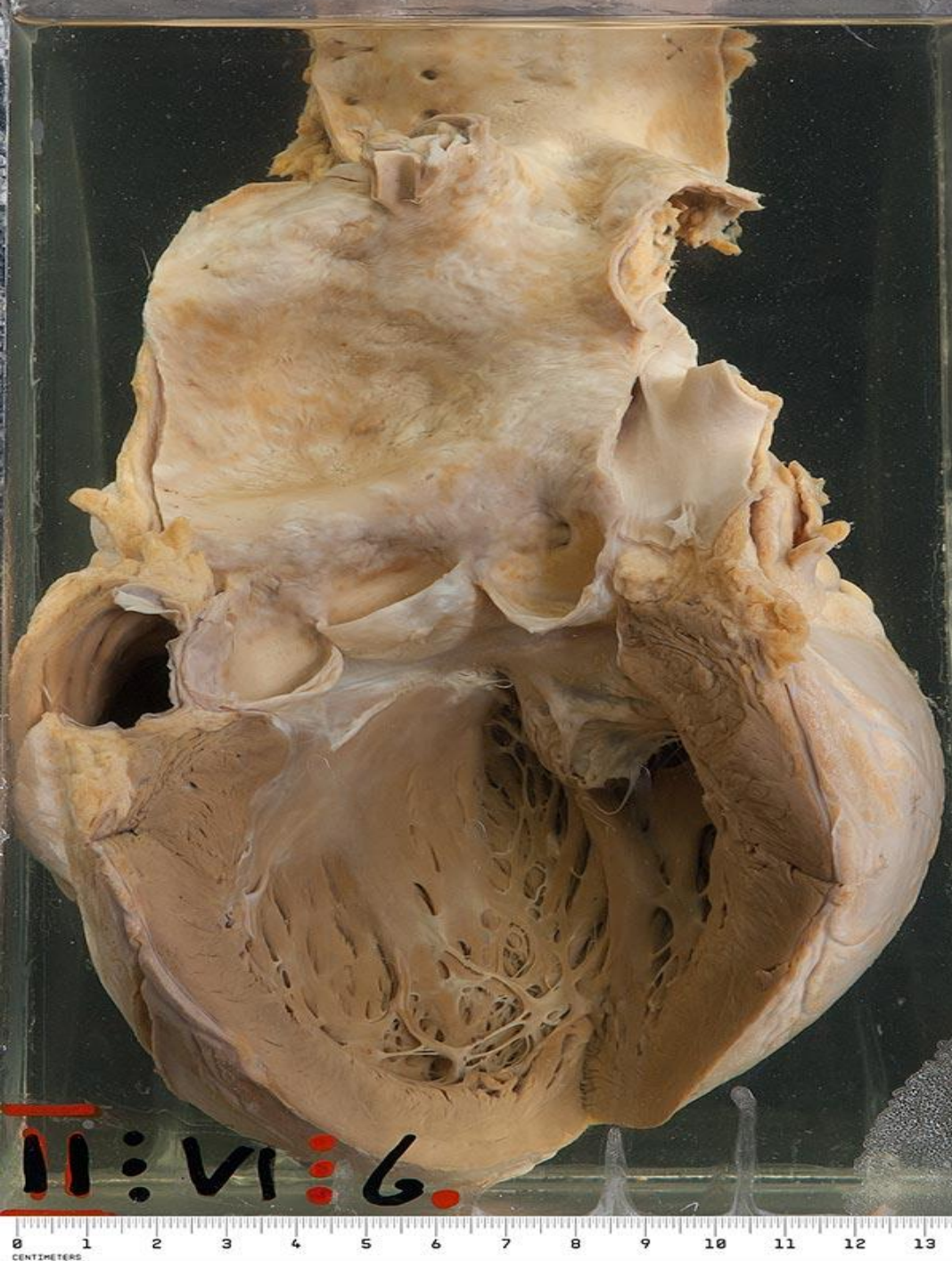


№ 90. Glandular prostatic hyperplasia with urinary bladder wall hypertrophy.

№ 15. Aortic aneurysm in syphilis.

The ascending portion of the aorta, above the level of the orifice, is dilated, the wall is thickened, the intima is irregular, rough, it has a tree-bark appearance. The semilunar valves are thickened, sclerosed, deformed, the orifice is dilated.

These lesions of the aorta are caused by syphilitic aortitis (mezaortitis), which leads to the destruction of the elastic membranes, the reduction of the elasticity of the aortic wall and the appearance of the aneurysm. At the same time, the inflammatory process extends to the valve and the fibrous ring of the aorta. Sclerosis and valve deformity with dilation of the aortic orifice lead to the installation of severe aortic valve insufficiency and massive hypertrophy of the left ventricle. Coronary arteries ostial stenosis occur. All of these changes as a whole result in severe, progressive cardiovascular failure. Aortic aneurysm can cause compression and wear of adjacent tissues / organs and rupture with lethal bleeding.



№ 15. Aortic aneurysm in syphilis.

№ 91. Urinary bladder carcinoma.

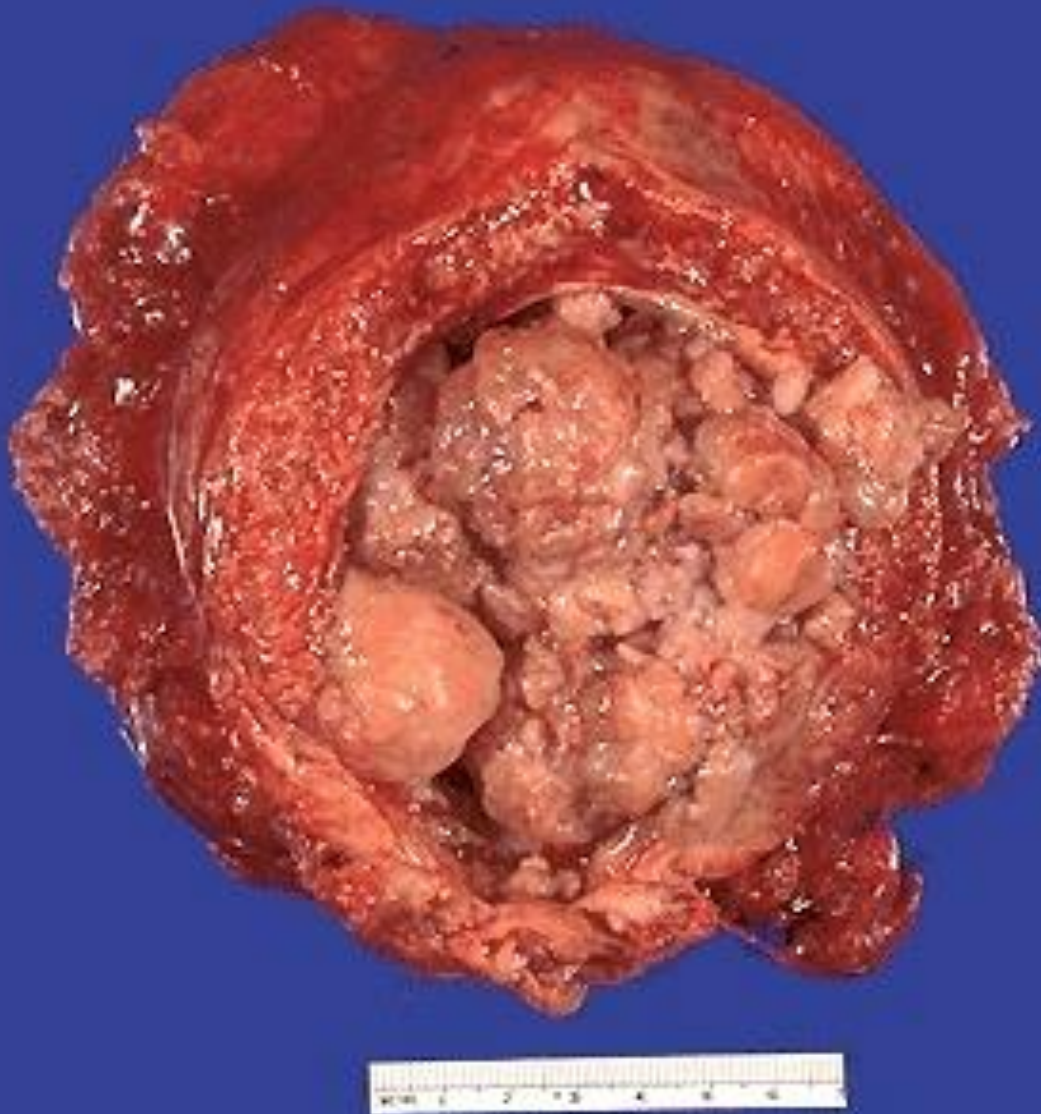In urinary bladder is a tumor node, which has exophytic type of growth in the bladder cavity, up to 10 cm in diameter of rough surface.

Histologically, the absolute majority of cases of urinary bladder carcinomas (90%) are urothelial carcinoma (old name - "carcinoma from transitional epithelium").

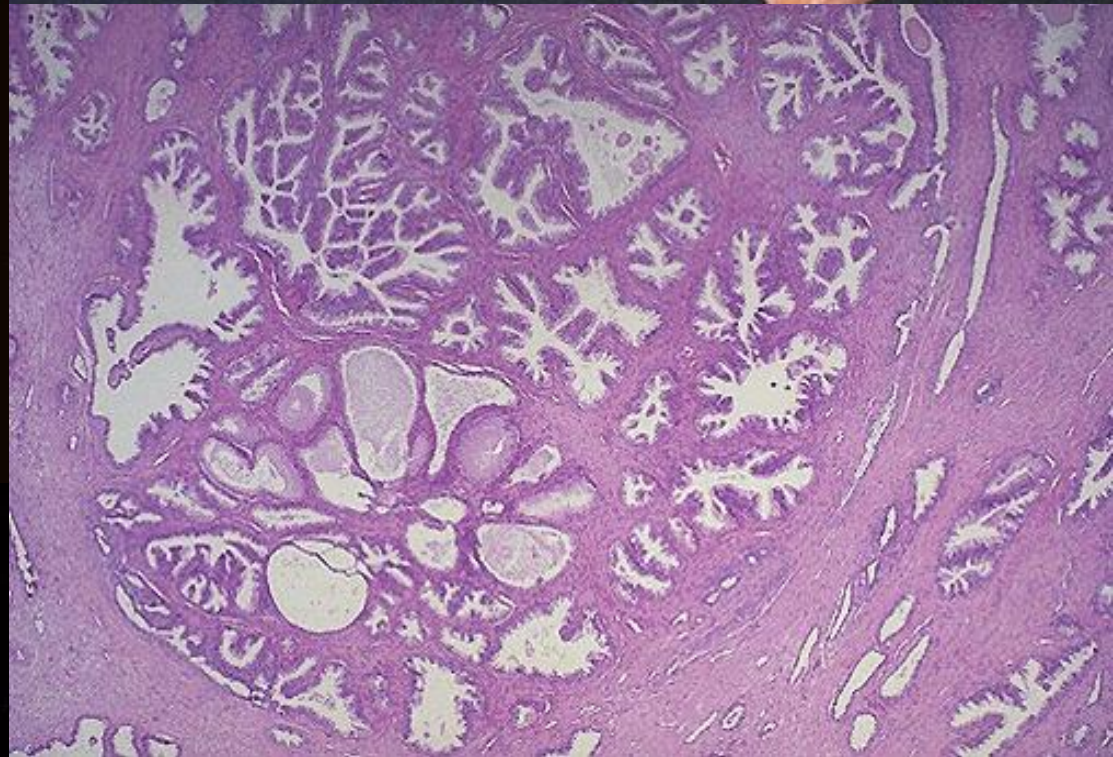
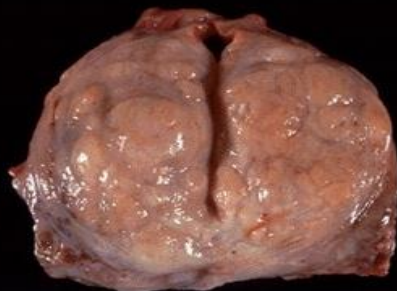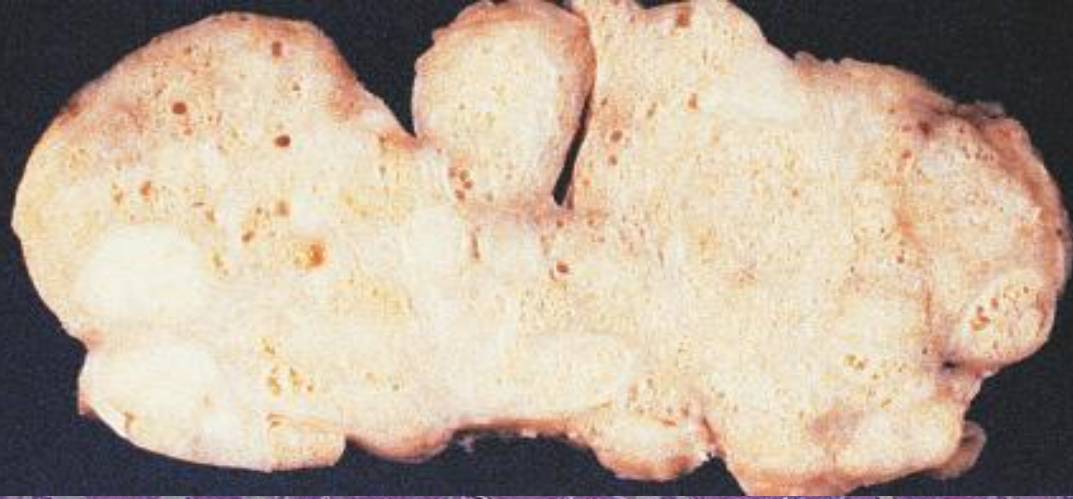
It constitutes ~ 7% of the total number of cancers, being 3-4 times more frequent in men than in women. The main clinical symptoms are hematuria and dysuria. The most important risk factors are: a) smoking (the risk is 2-4 times higher than in non-smokers), b) occupational or environmental exposure to carcinogenic chemical factors (aniline dyes, arsenic), c) some drugs (phenacetin, cyclophosphamide), d) radiation therapy for prostate cancer, uterus, e) chronic cystitis, including infectious origin, f) urinary bladder extrusion (congenital anomaly).

Complications: ulceration, bleeding, purulent inflammation, invasion of adjacent organs - prostate, seminal vesicles, uterus, vagina, pelvic walls.

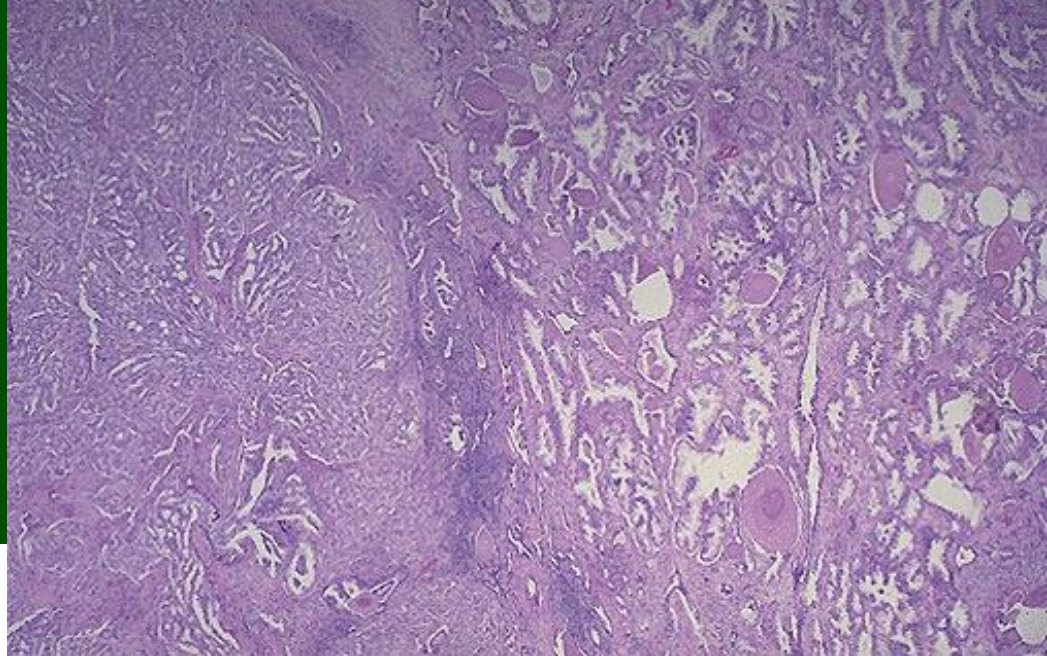
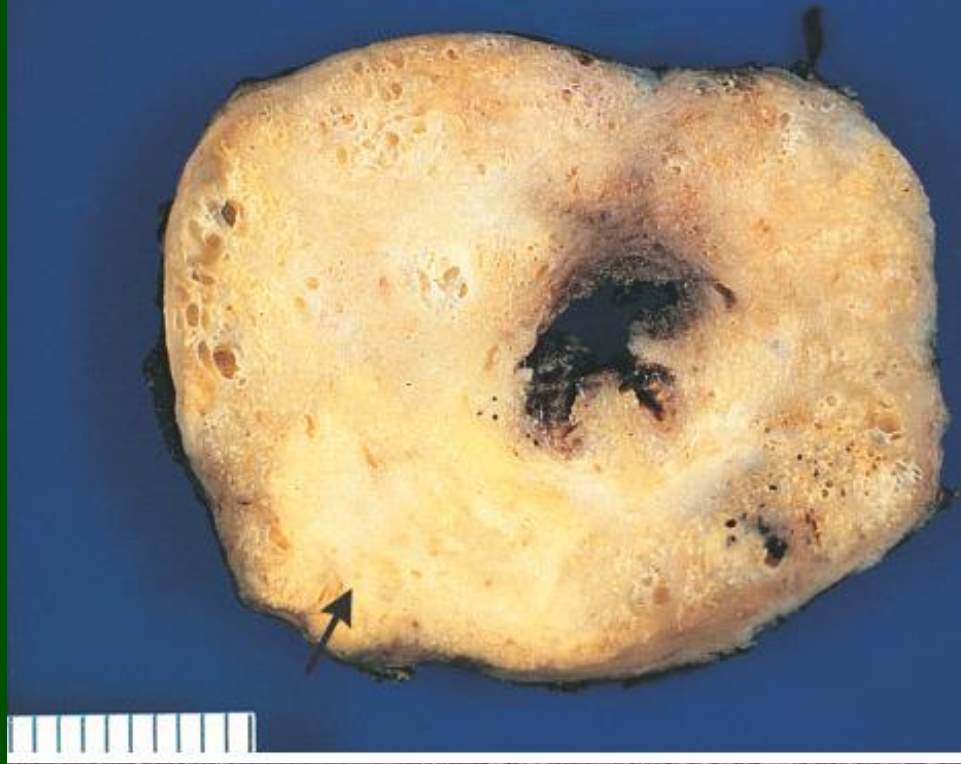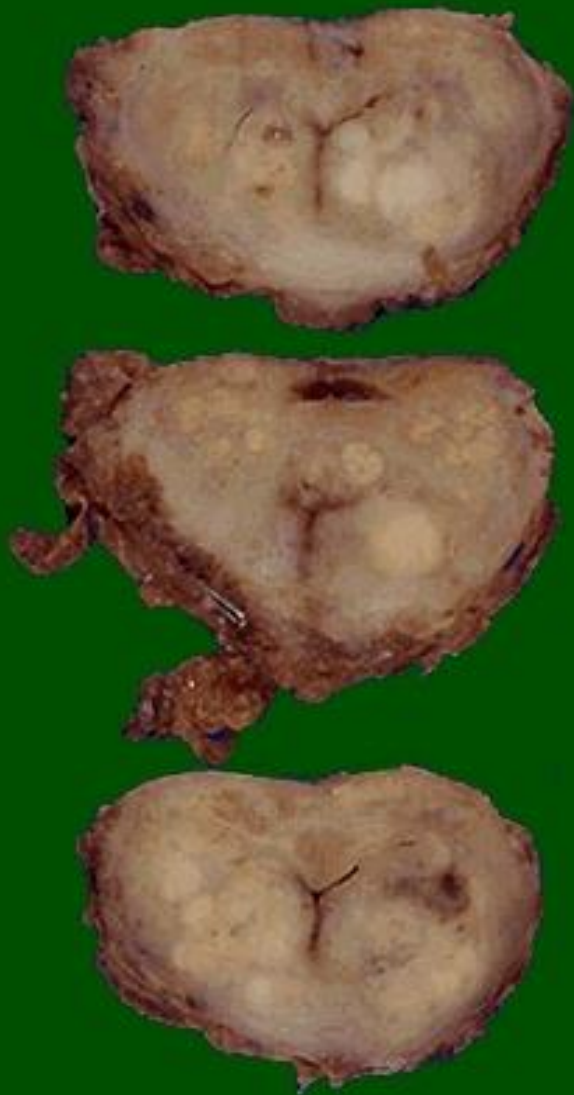
Metastases: lymphogenous - in the iliac, paraaortal, paracaval lymph nodes; hematogenous - in the liver, lungs, bones.



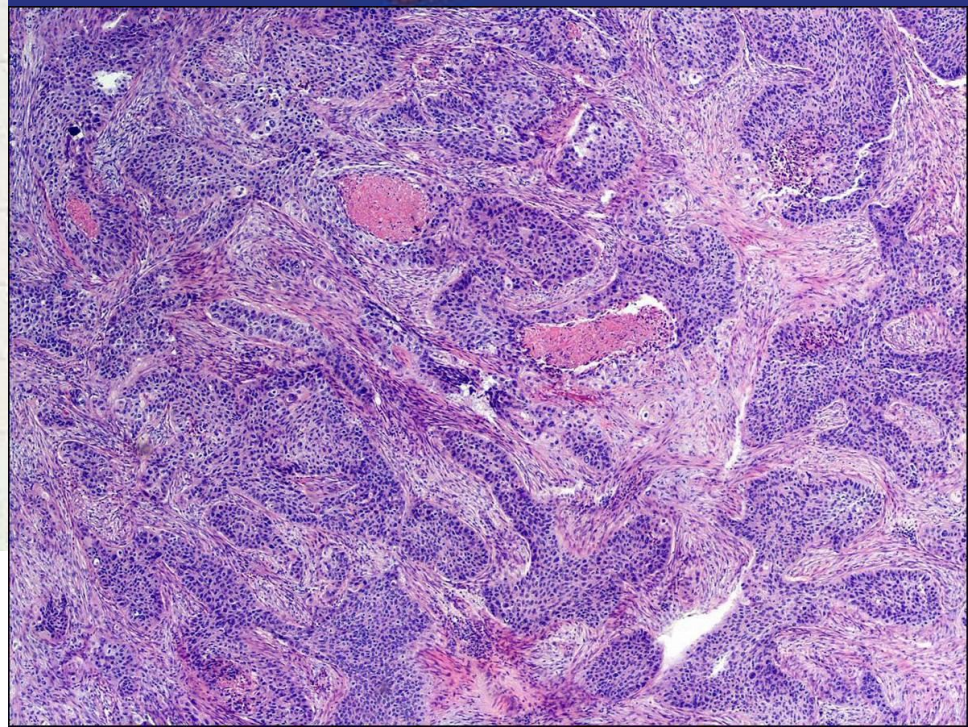
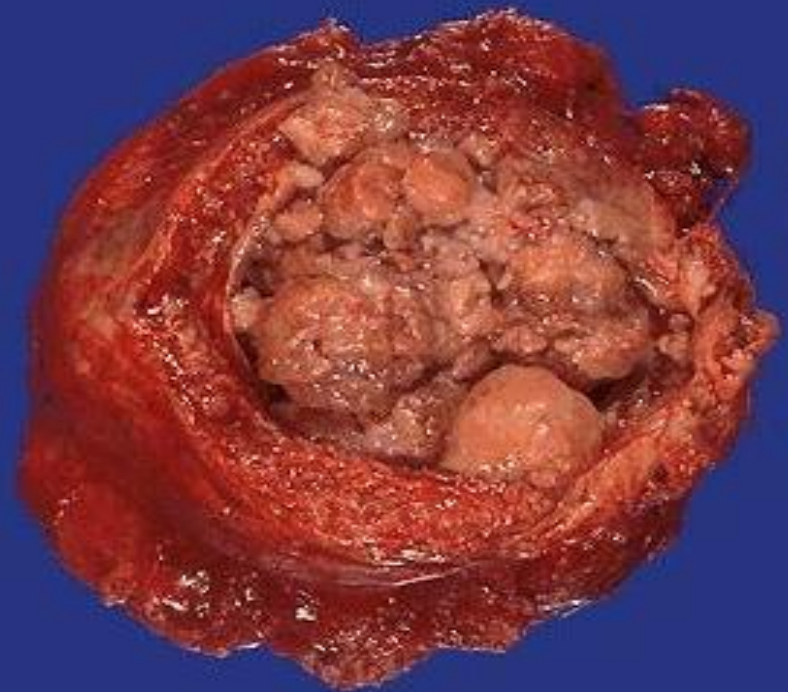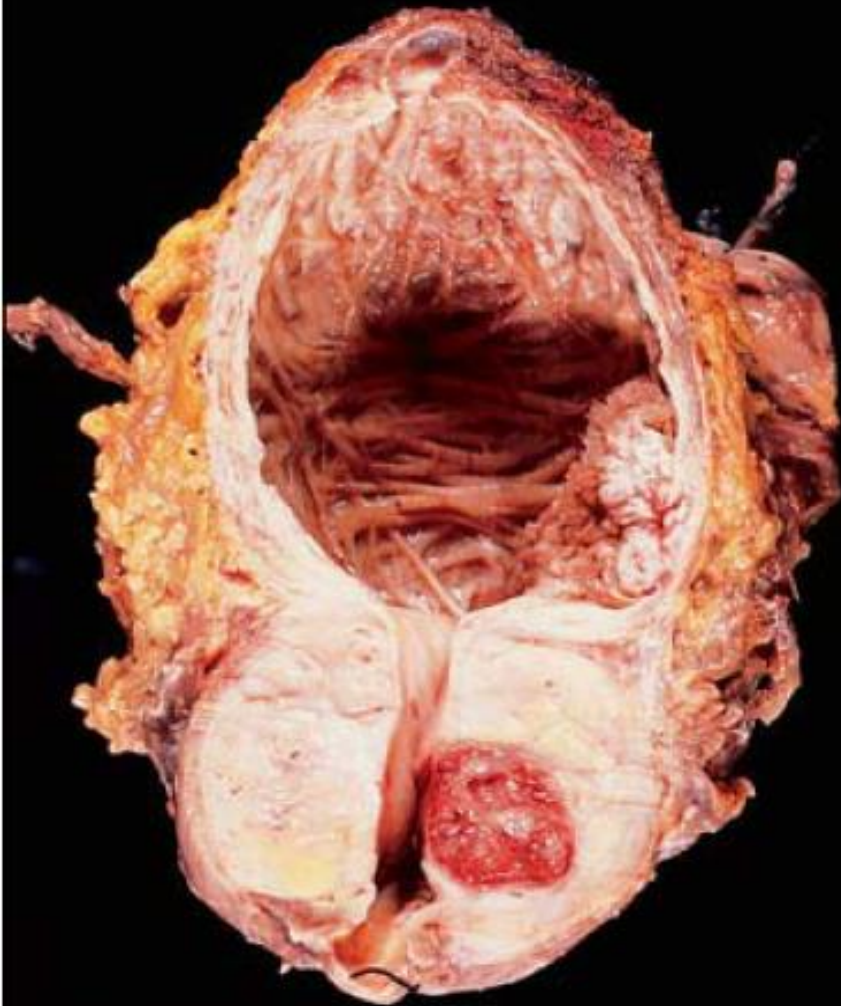
№ 91. Urinary bladder carcinoma.



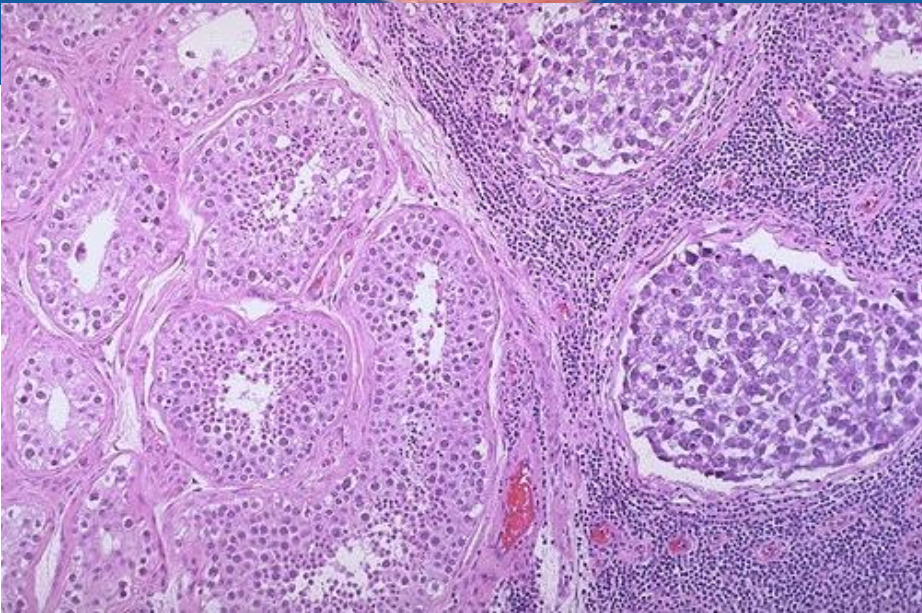
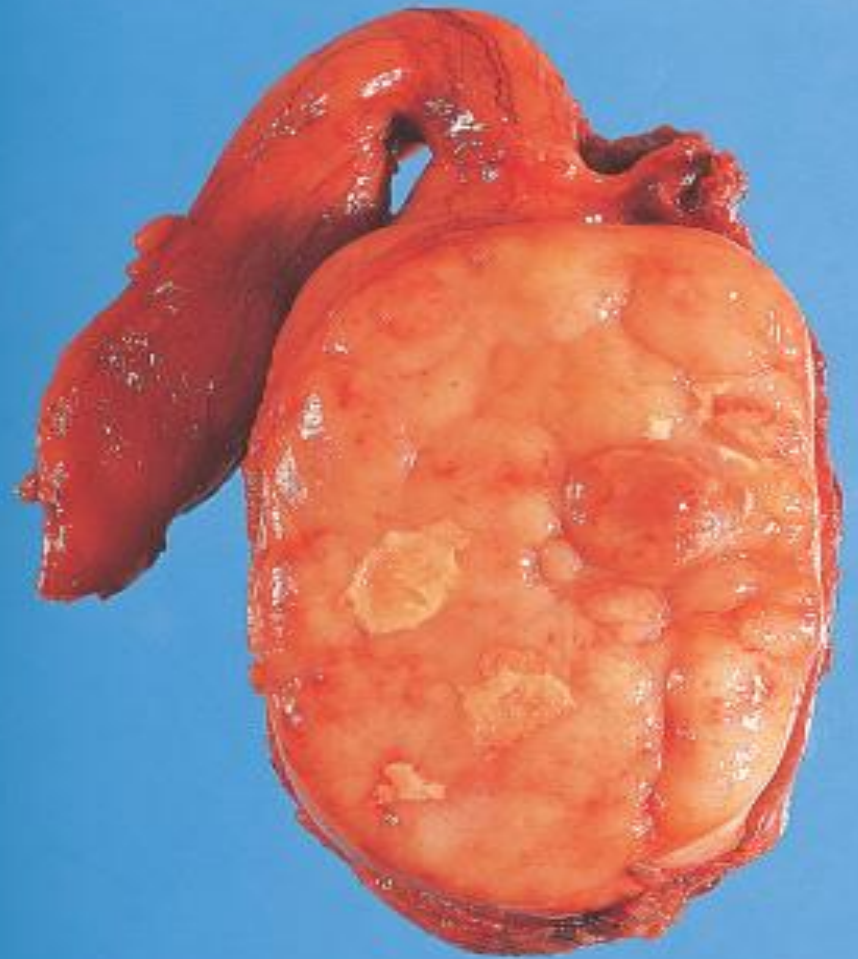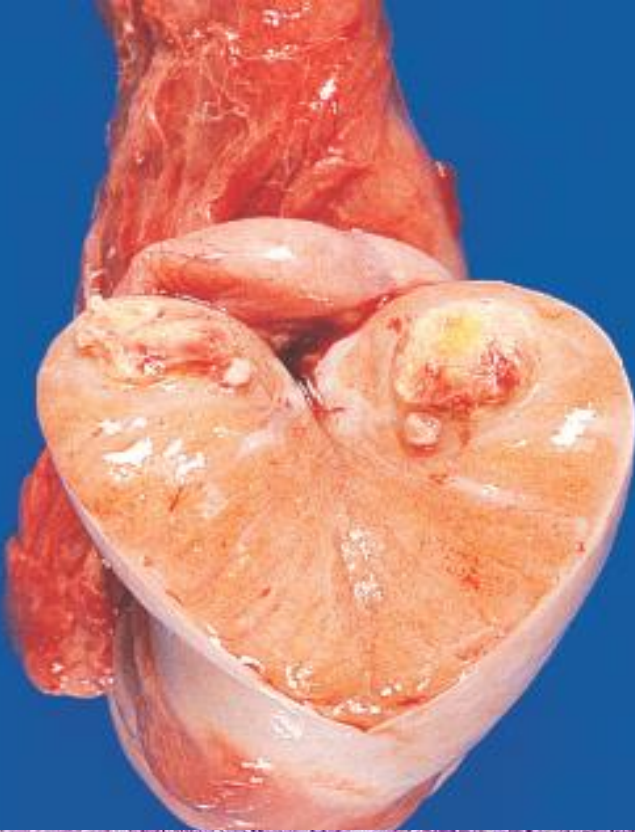
Benign prostatic hyperplasia.



Prostatic adenocarcinoma on benign prostatic hyperplasia background.

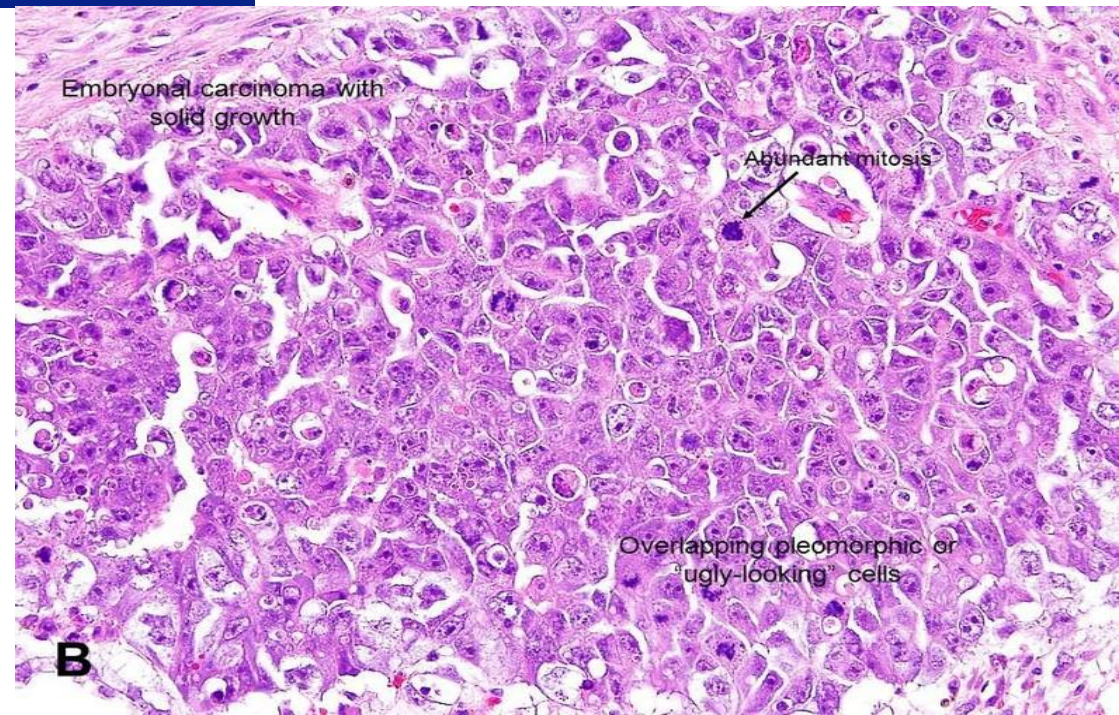
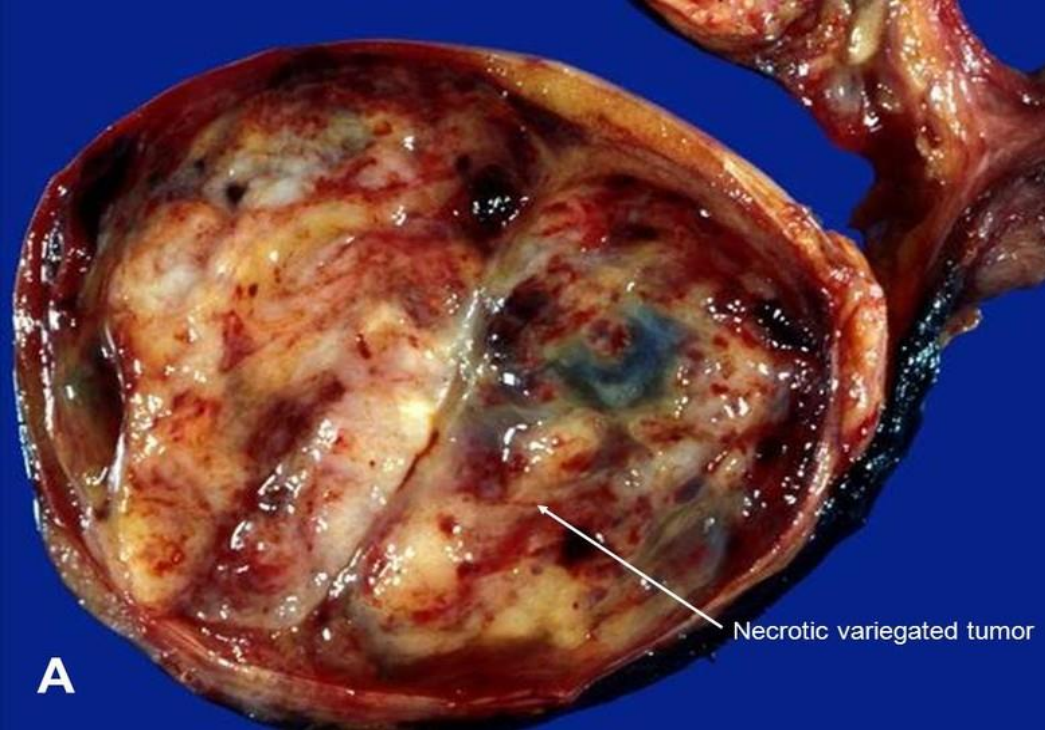

**Urothelial carcinoma of the urinary bladder
with exophytic, papillary growth
(*infarction in prostate*)**


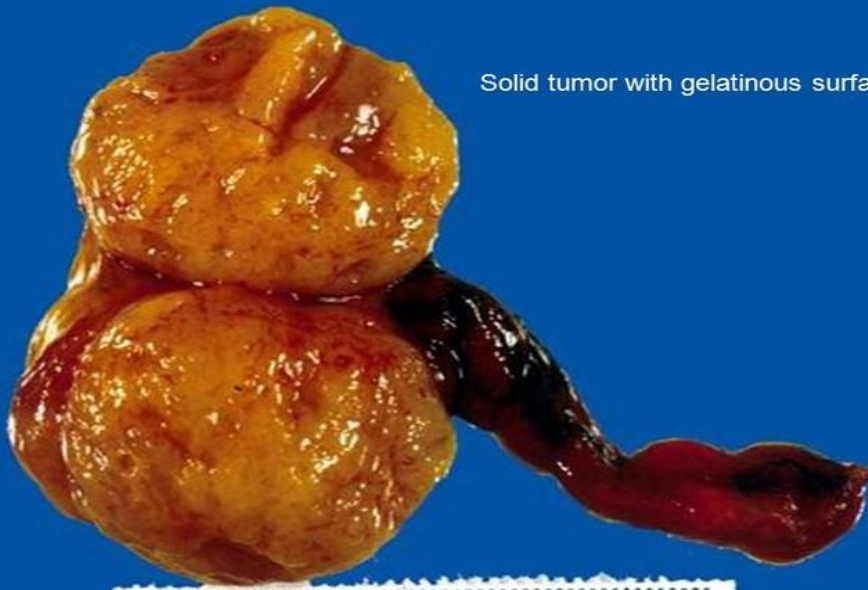


**Testicular
seminoma.**

Testicular embryonal carcinoma (solid pattern).



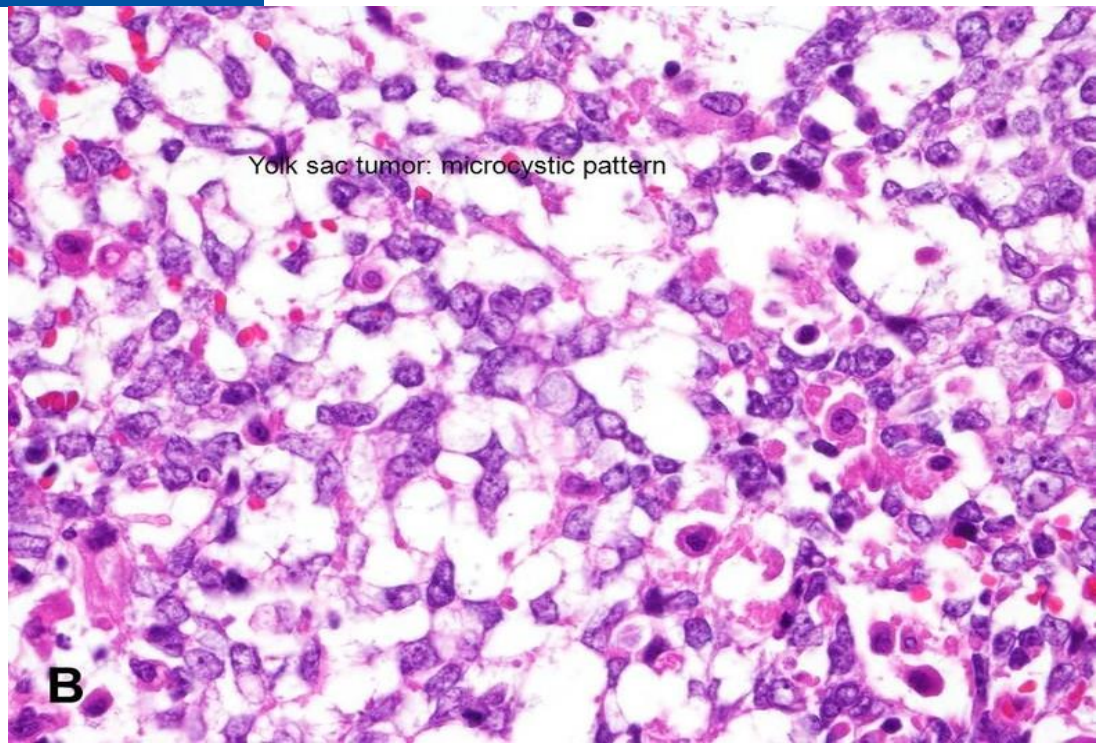
Solid tumor with gelatinous surface



A

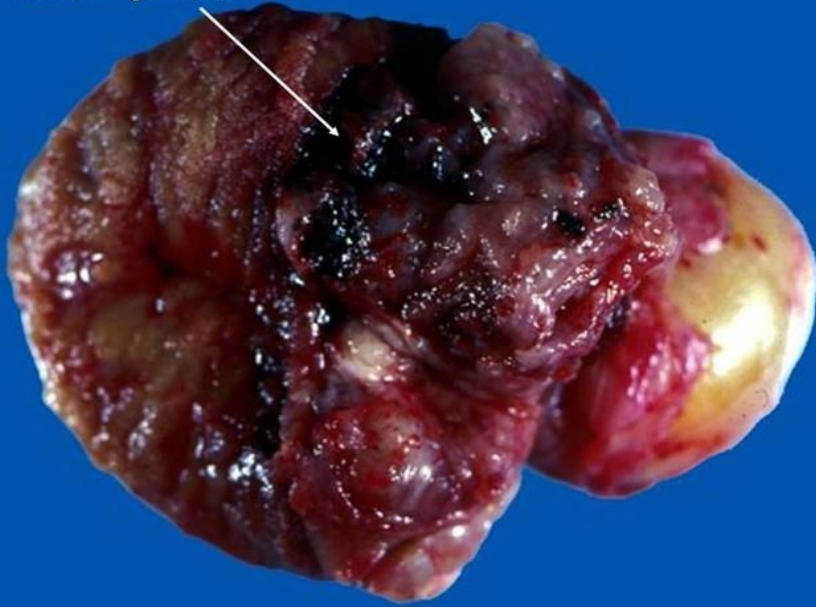Testicular yolk sac tumor (microcystic pattern).

Yolk sac tumor: microcystic pattern



B

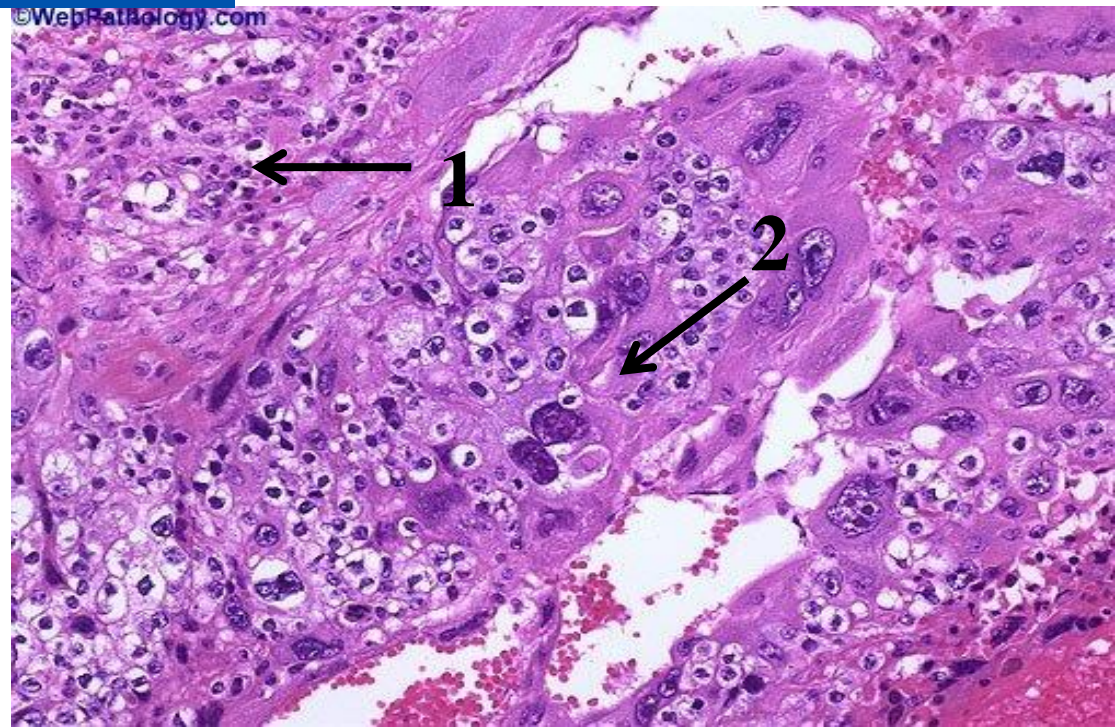
Hemorrhagic tumor

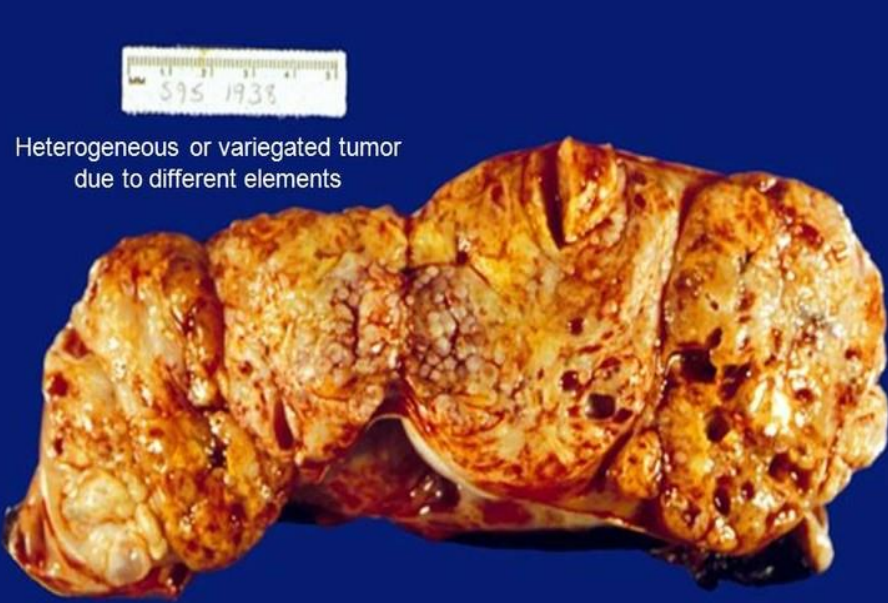
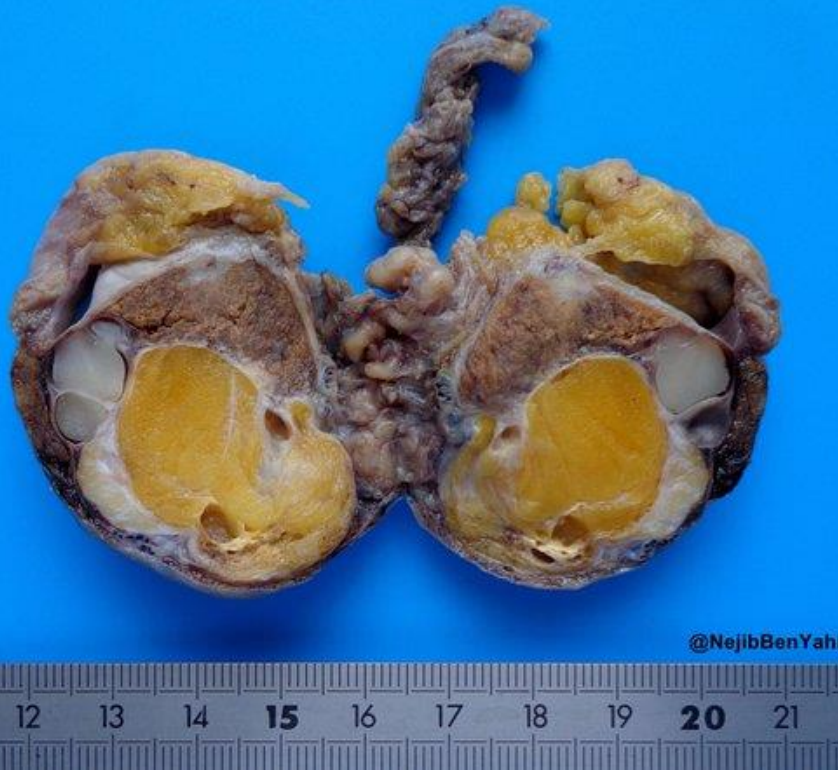

A

Testicular choriocarcinoma.

1. Cytotrophoblast.
2. Syncytiotrophoblast.

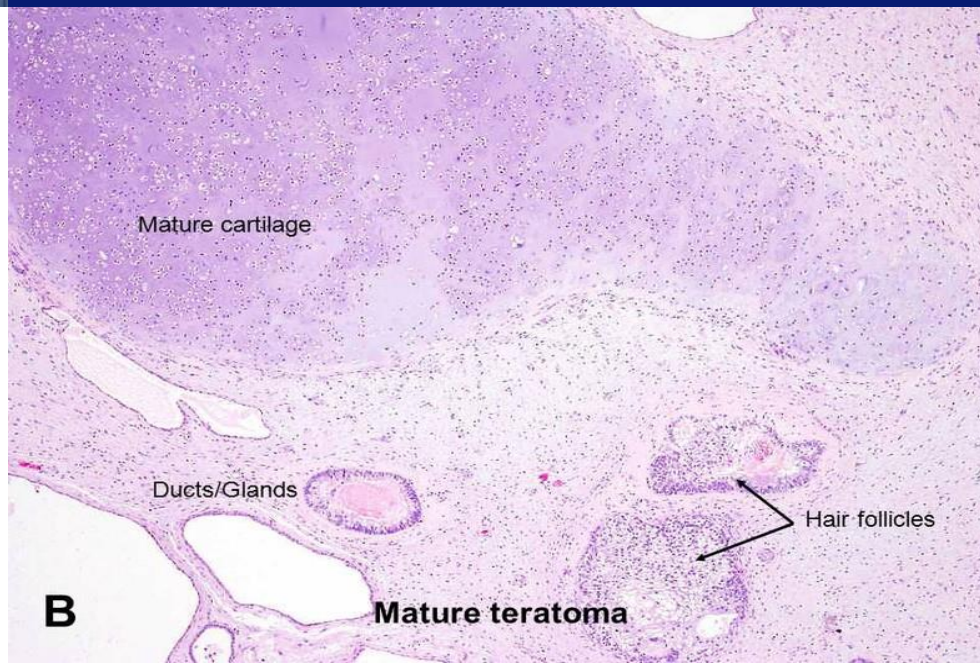




Heterogeneous or variegated tumor due to different elements

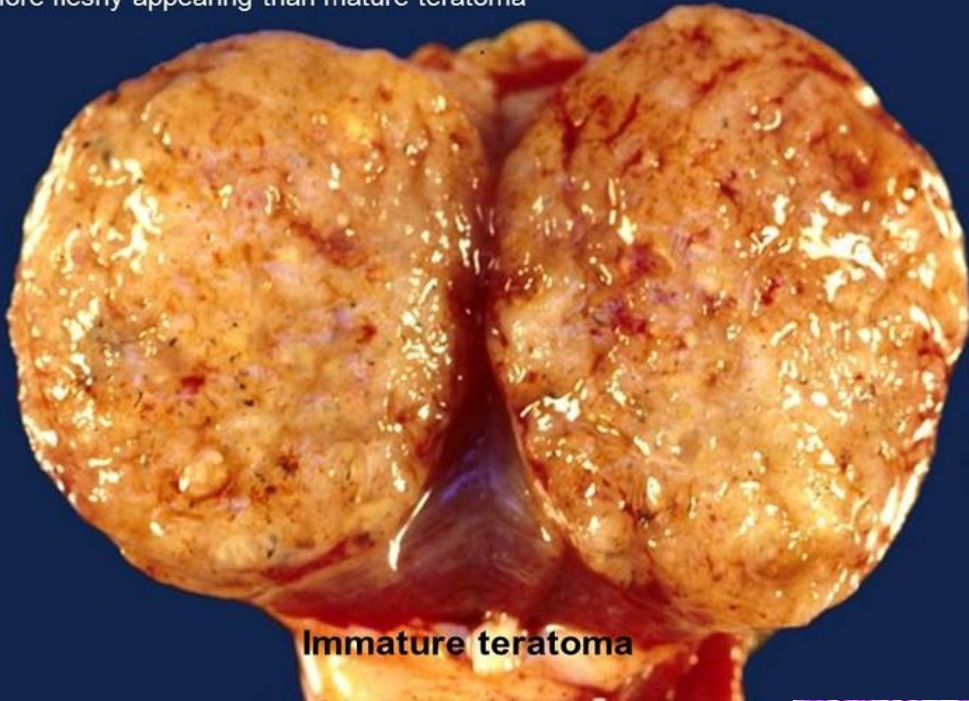
A Mature teratoma

Mature testicular teratoma.



B Mature teratoma

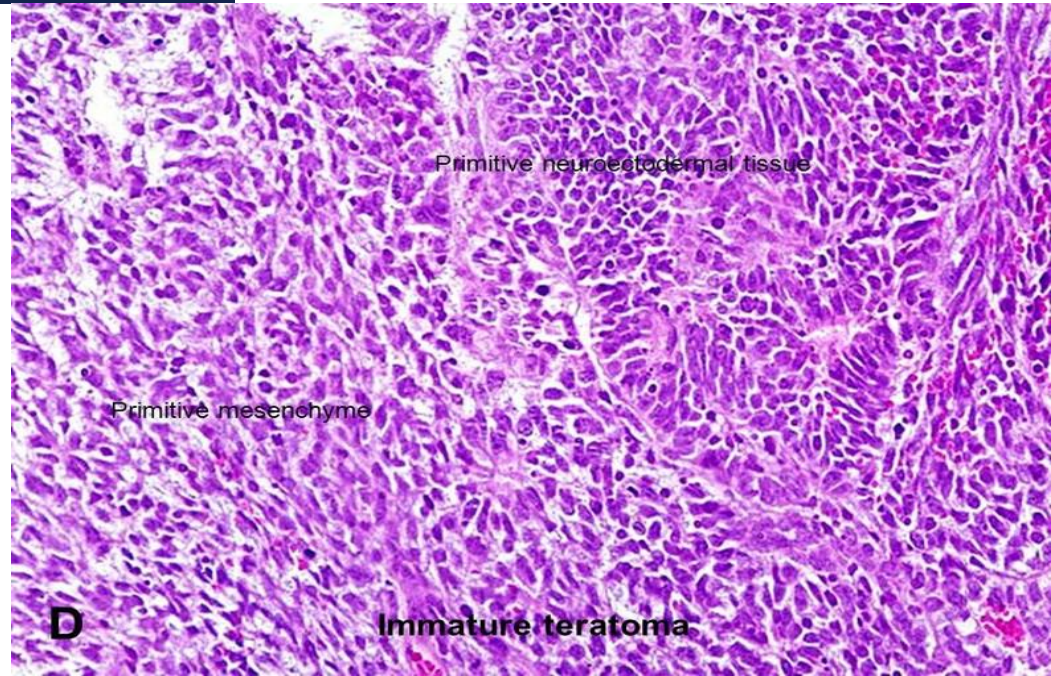
More fleshy appearing than mature teratoma



C

Immature teratoma

Immature testicular teratoma.



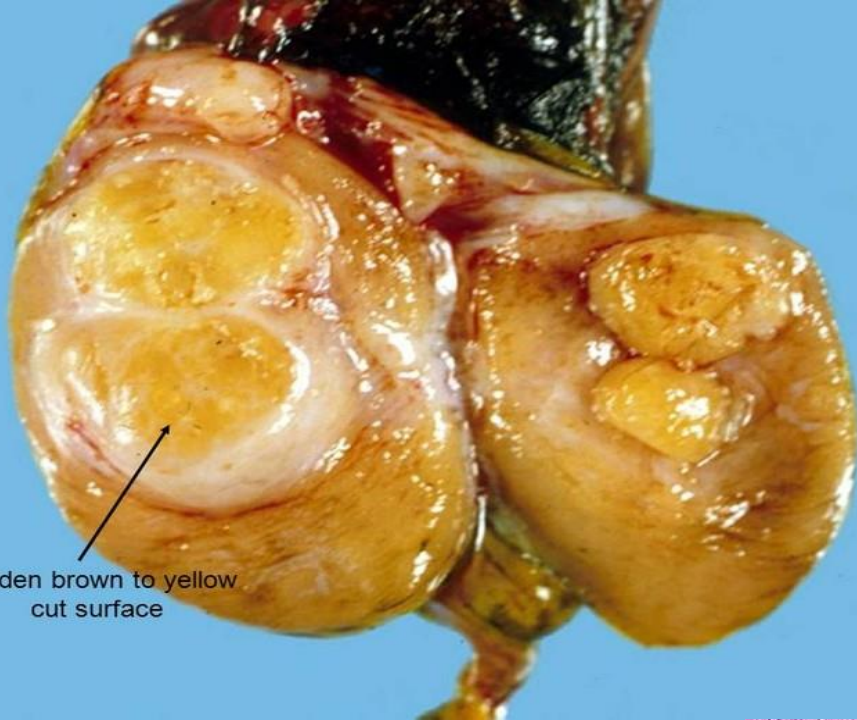Primitive neuroectodermal tissue

Primitive mesenchyme

D

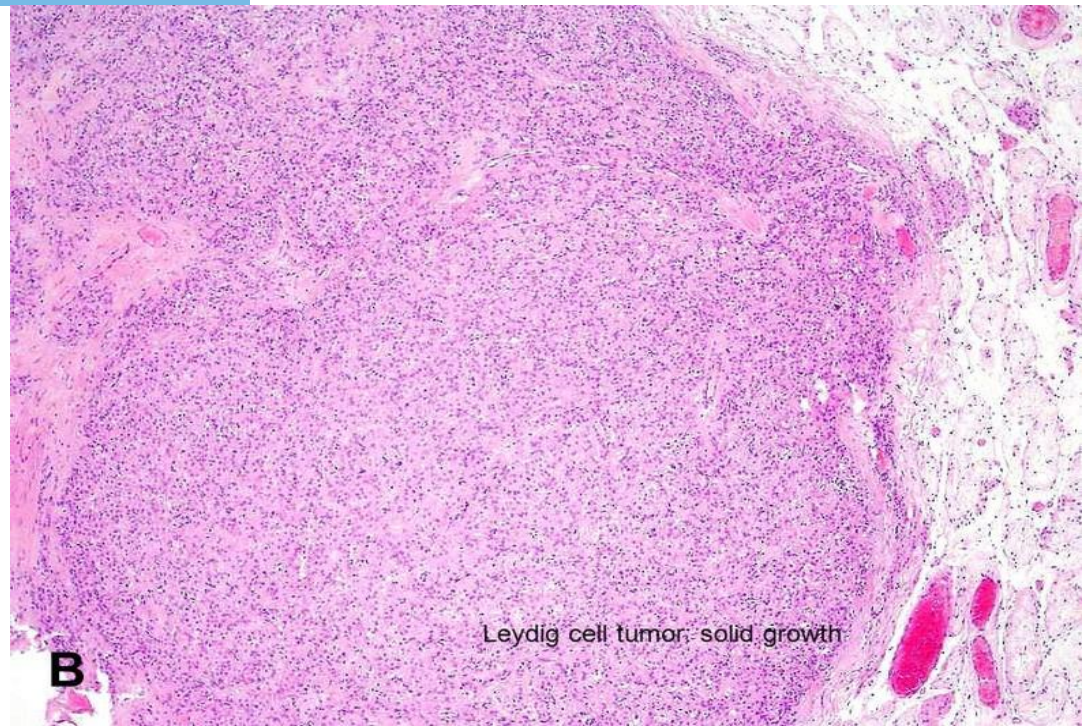
Immature teratoma

Testicular Leydig cell tumor. (solid pattern).



Golden brown to yellow
cut surface

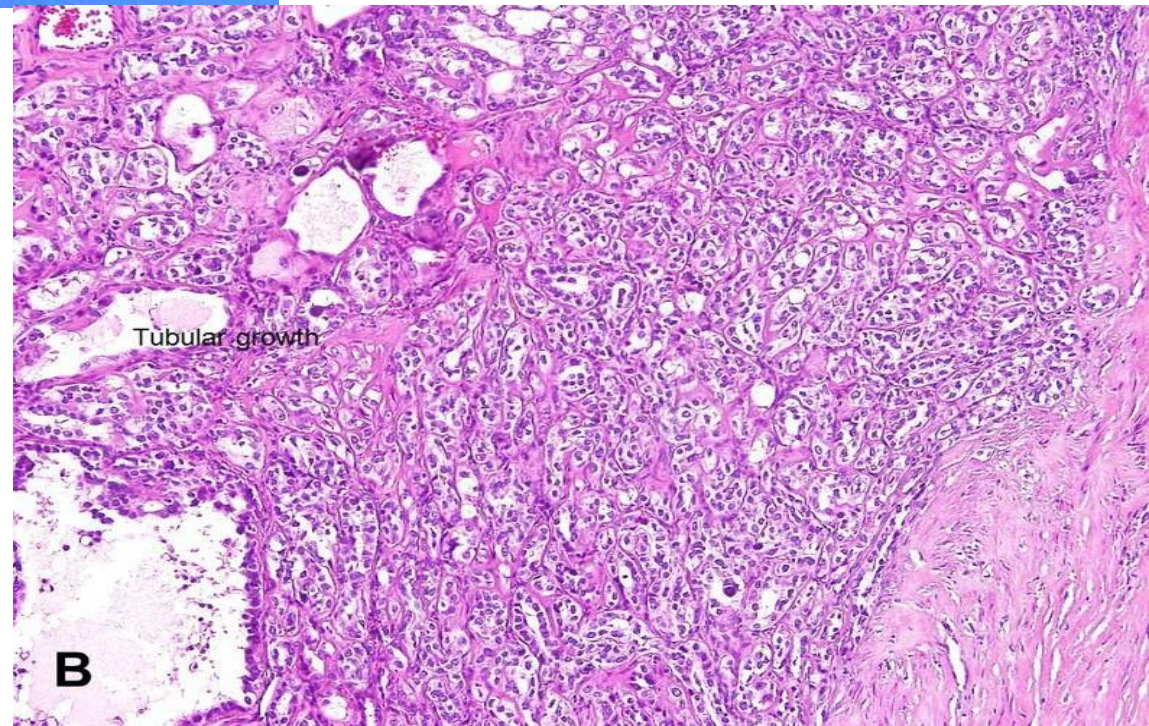
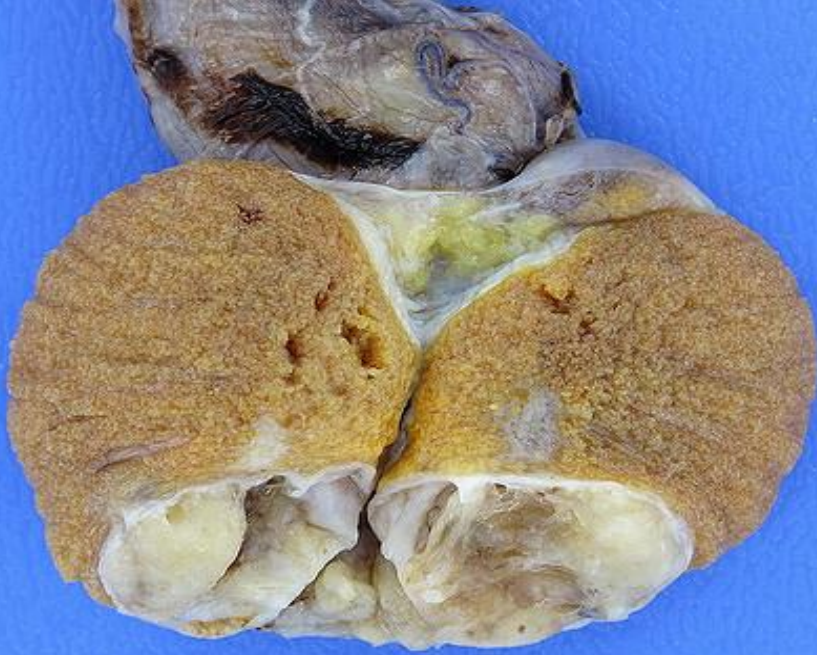A

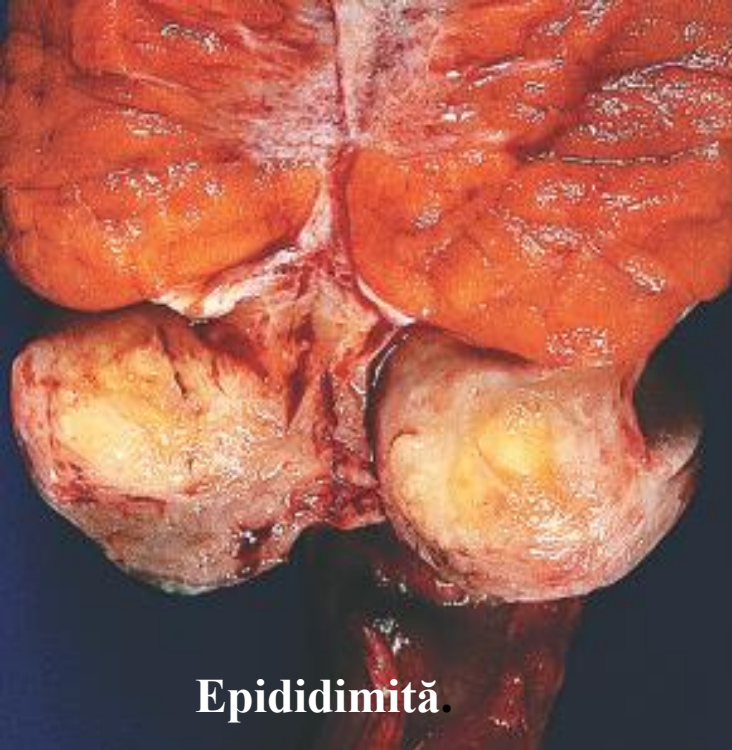


Leydig cell tumor: solid growth

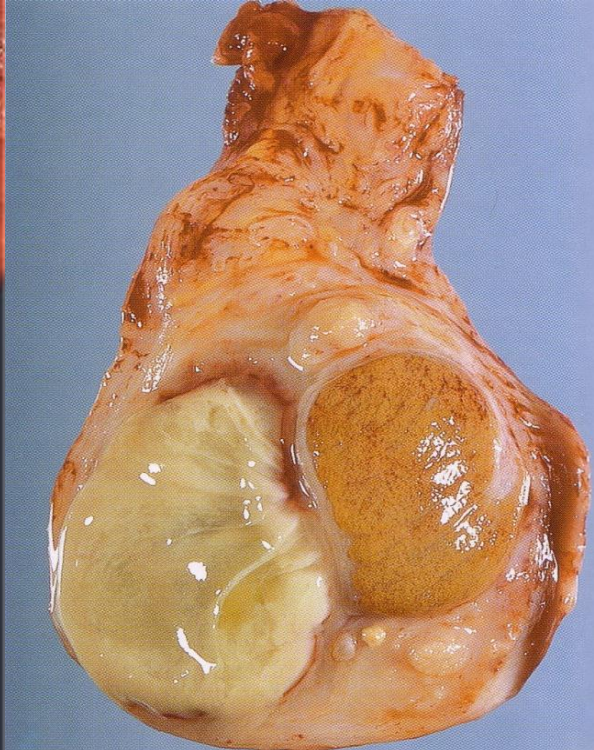
B

Testicular Sertoli cell tumor (tubular pattern).

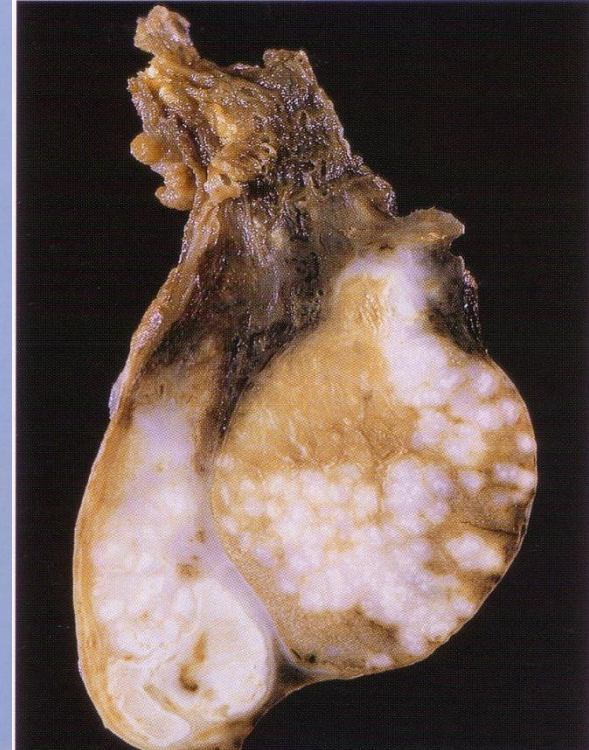



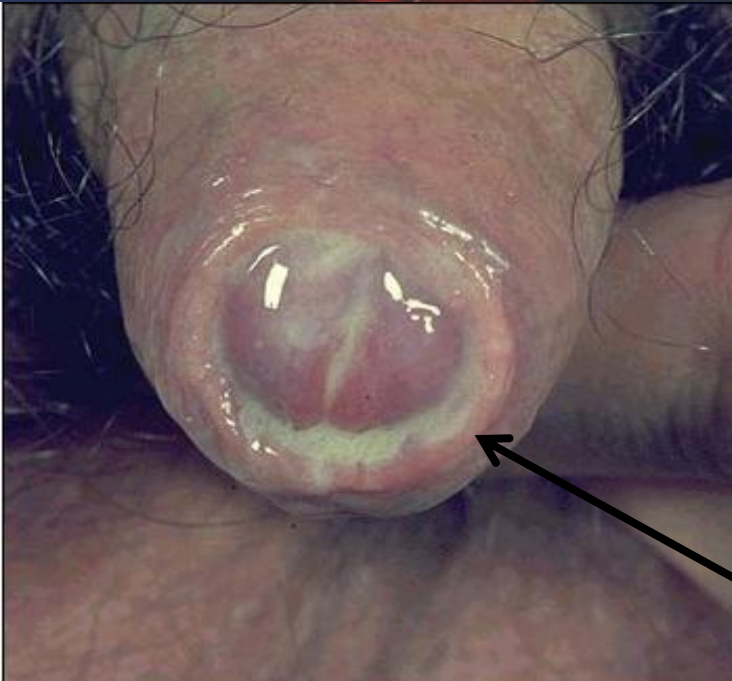Epididimită.



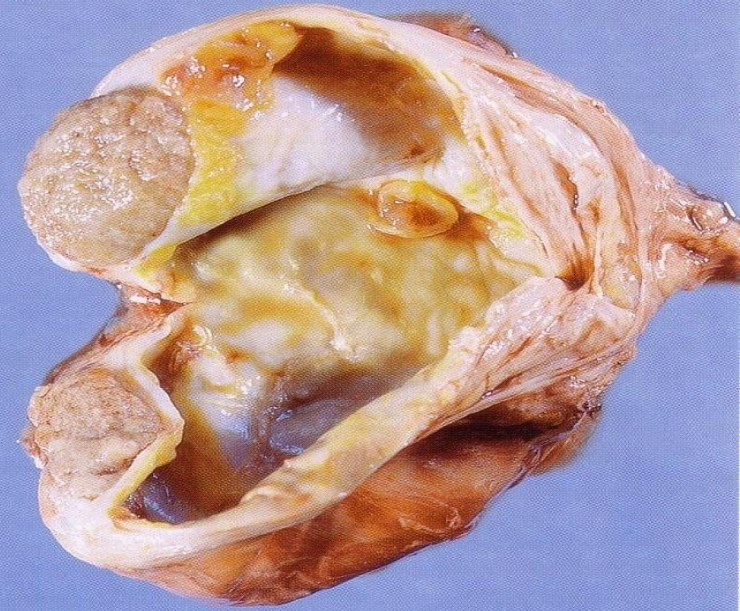
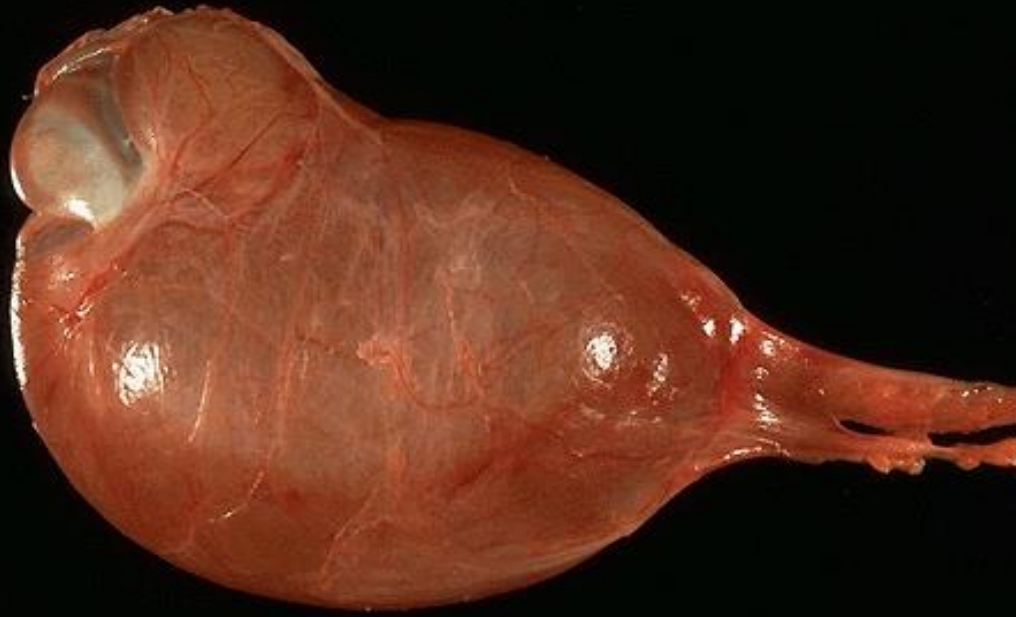
Epididymal abscess.



**Tuberculous
orchiepididimitis**

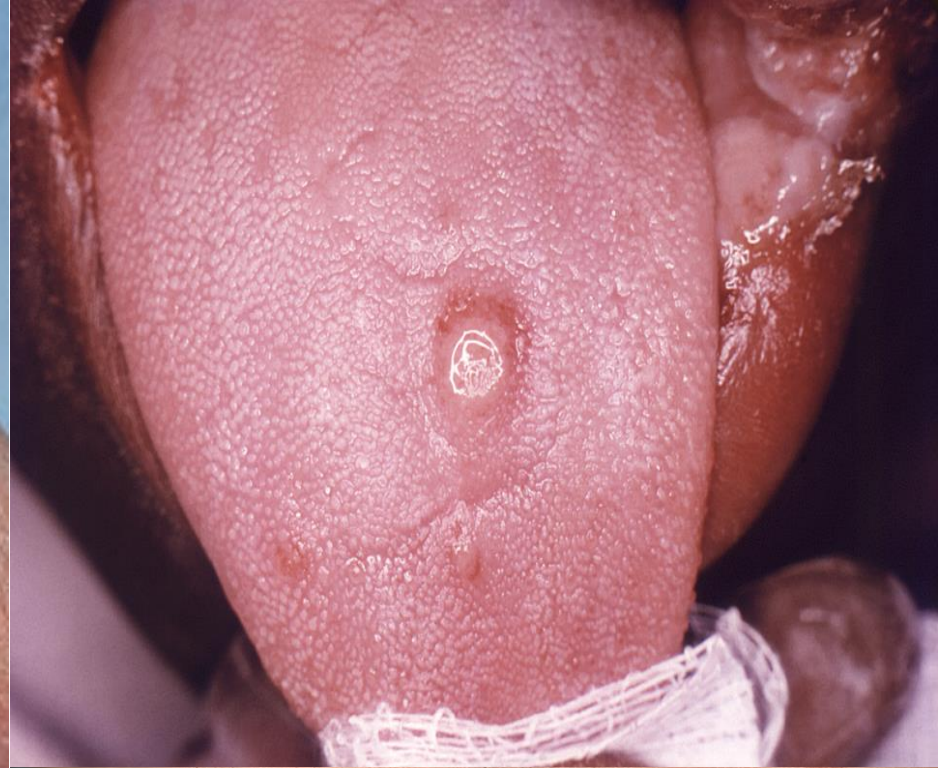
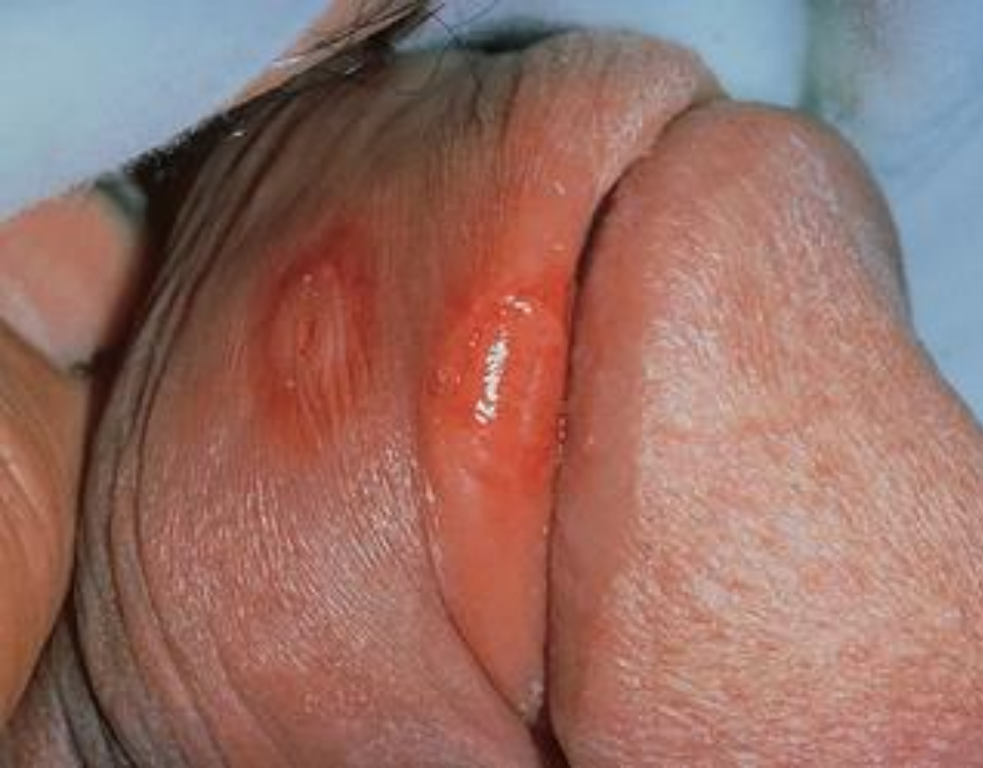
Purulent urethritis (*gonorrhoea*).

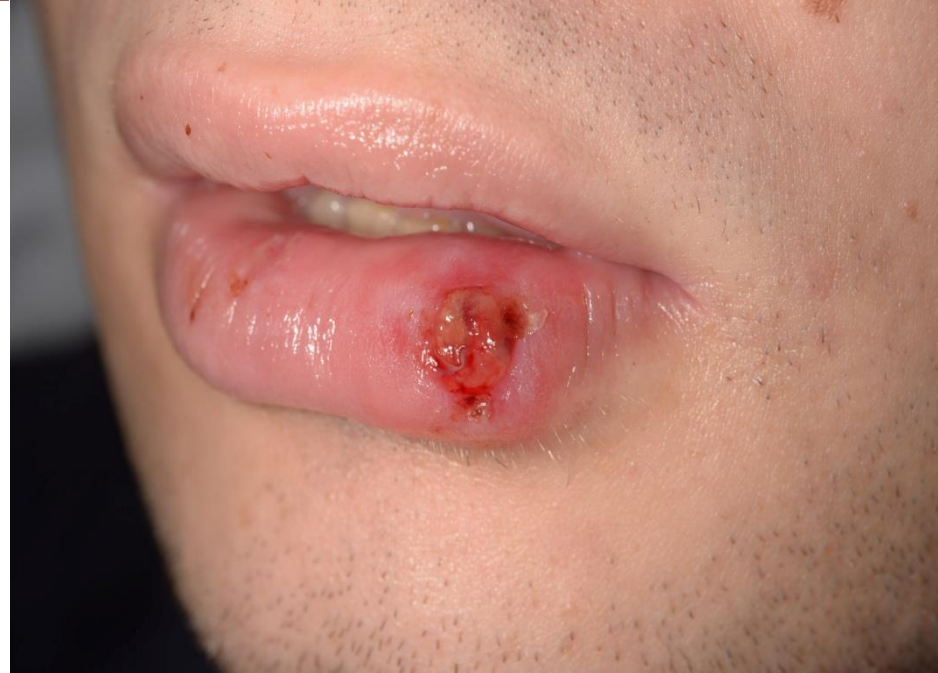

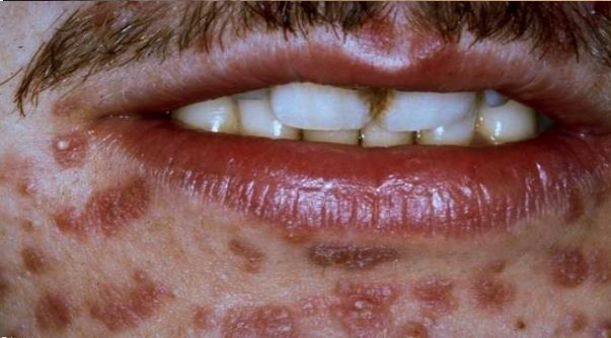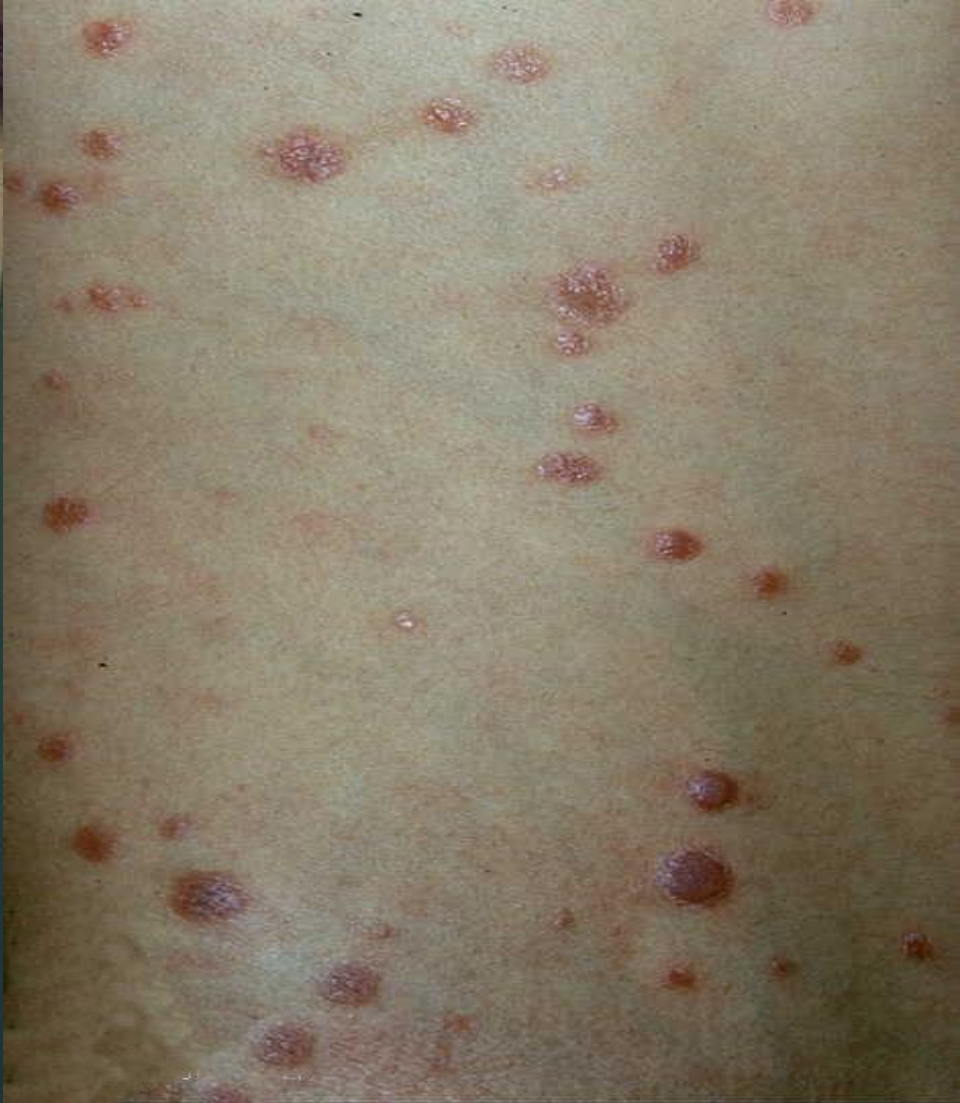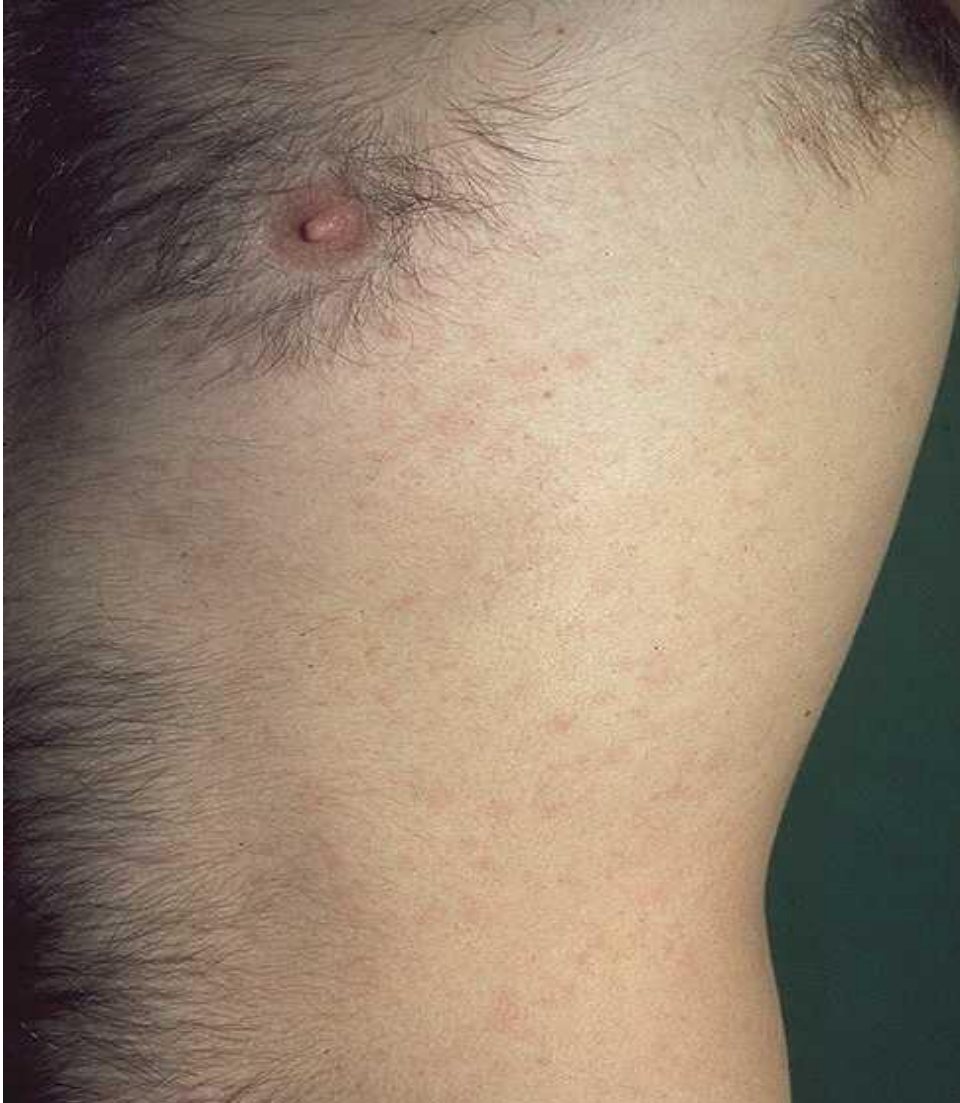Hydrocele ↑↑

← Epididymal cyst

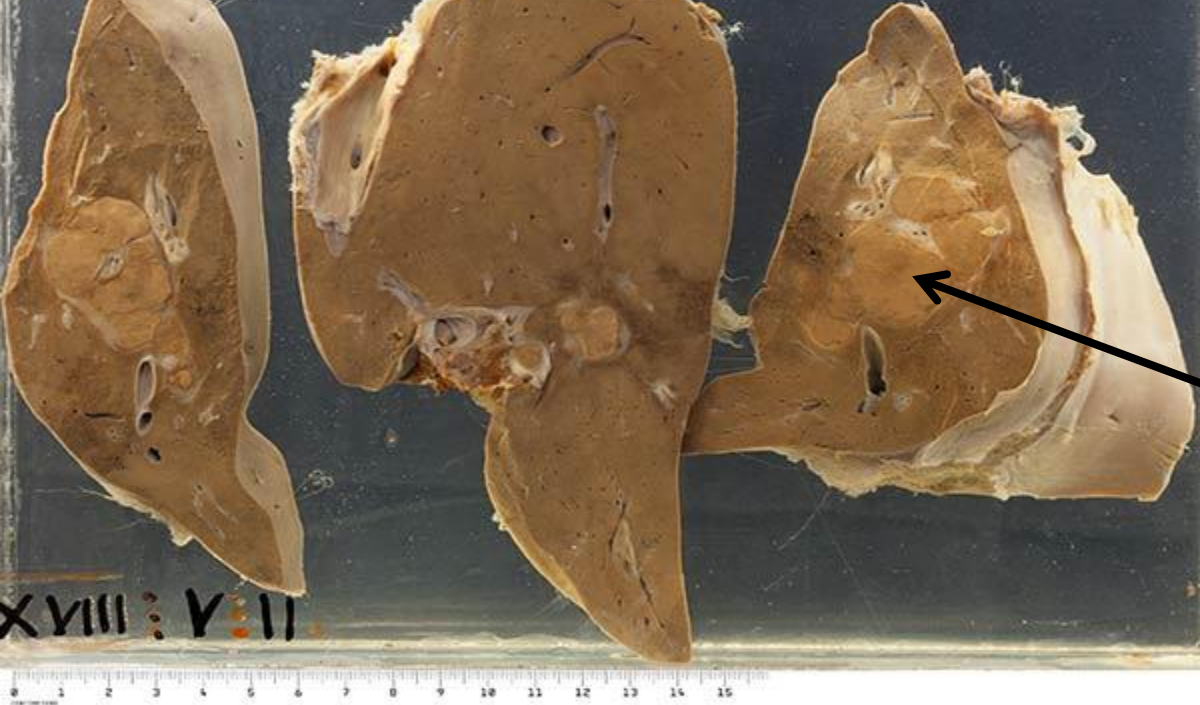

Primary syphilis, *chancre*.



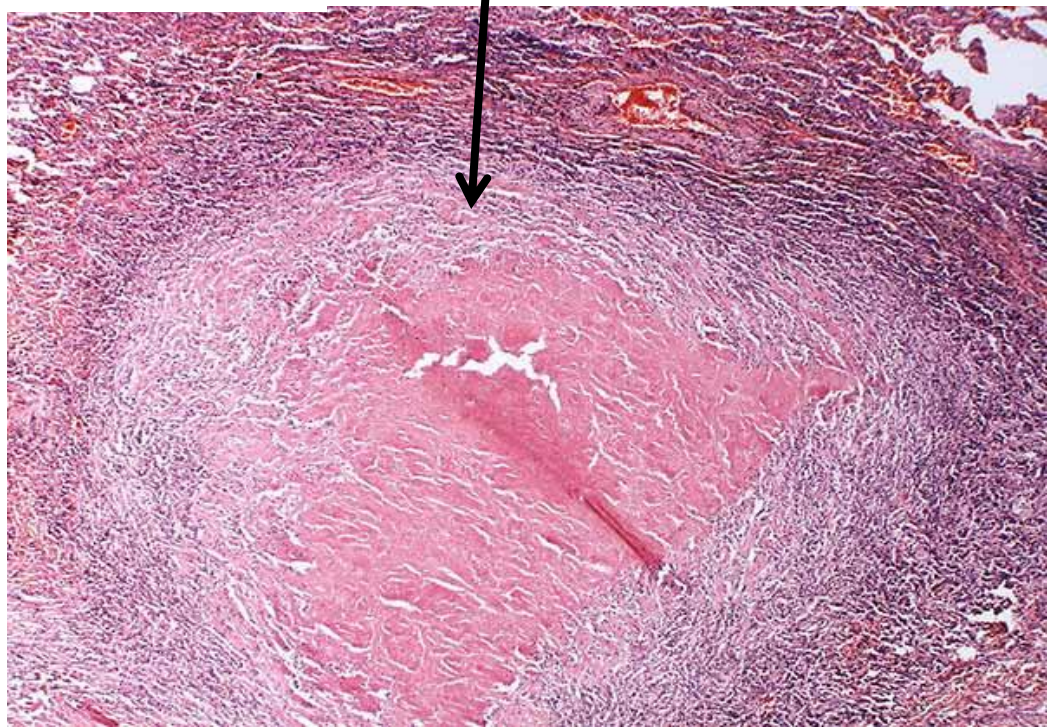


Secondary syphilis, *syphilids*.



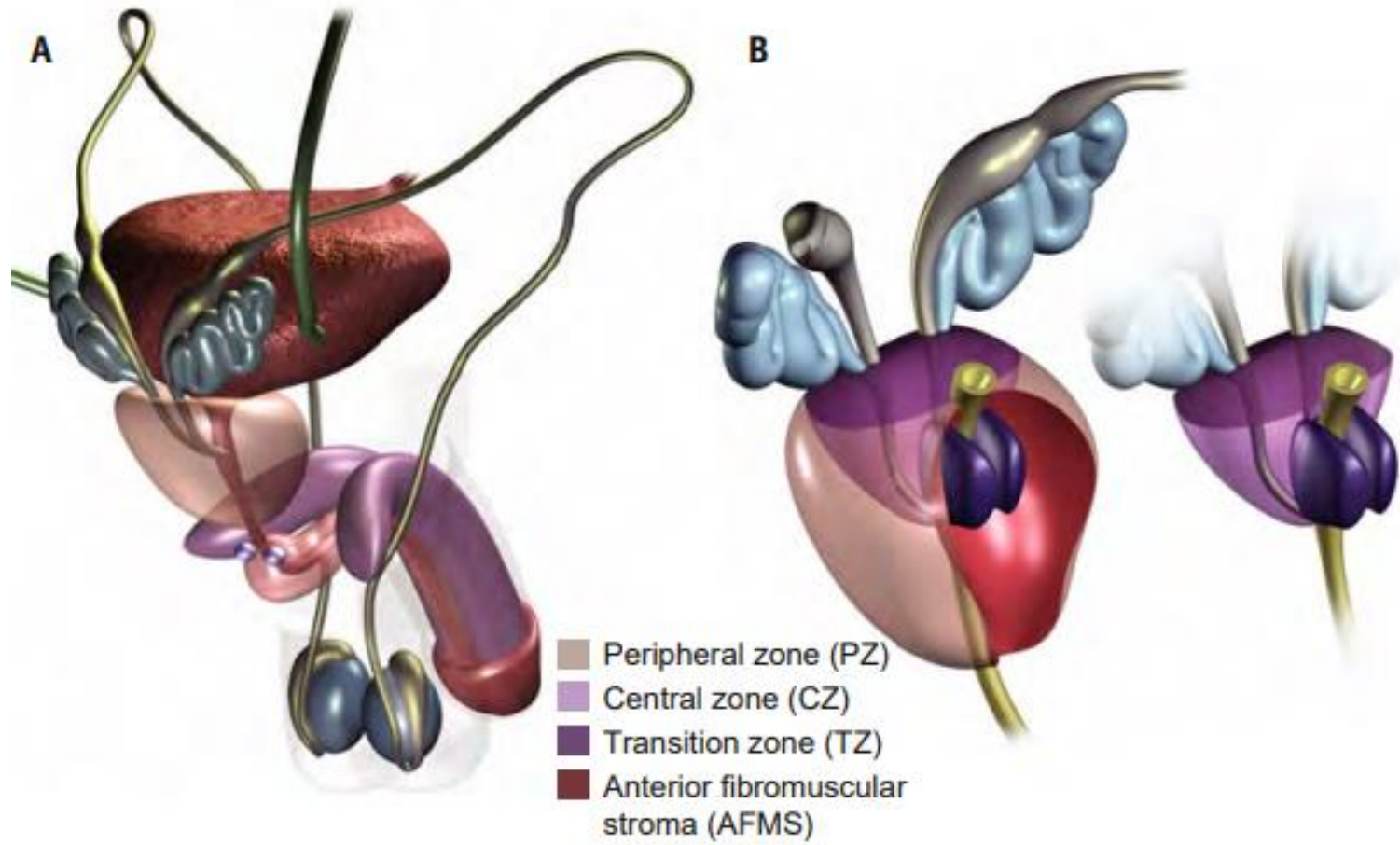
Syphilitic gumma.

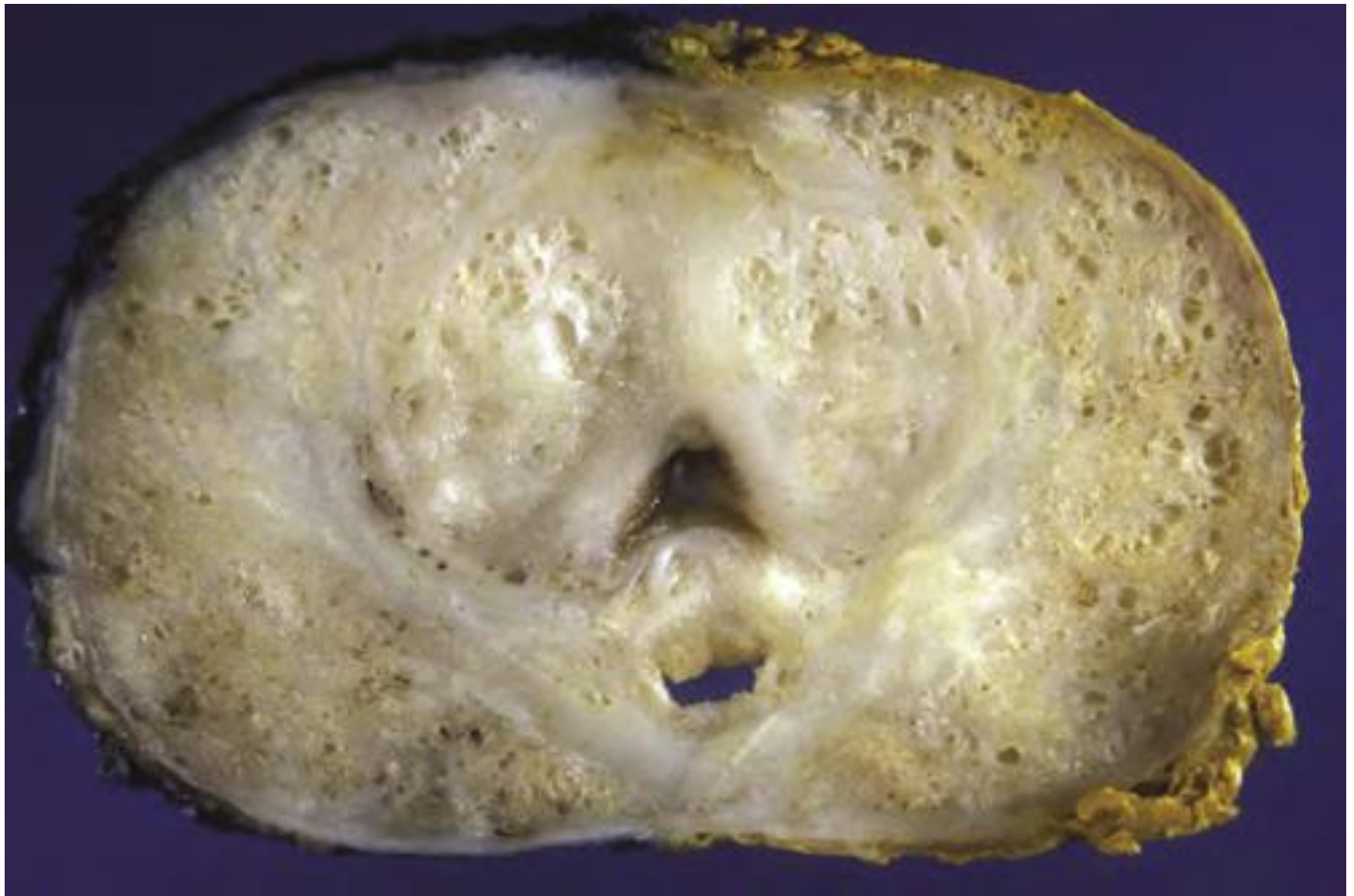Liver.



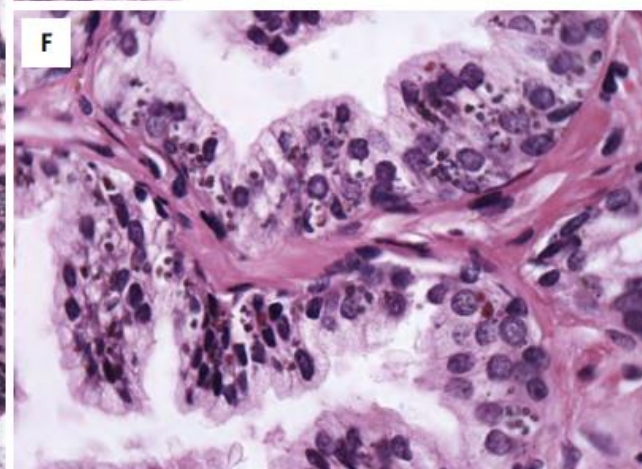
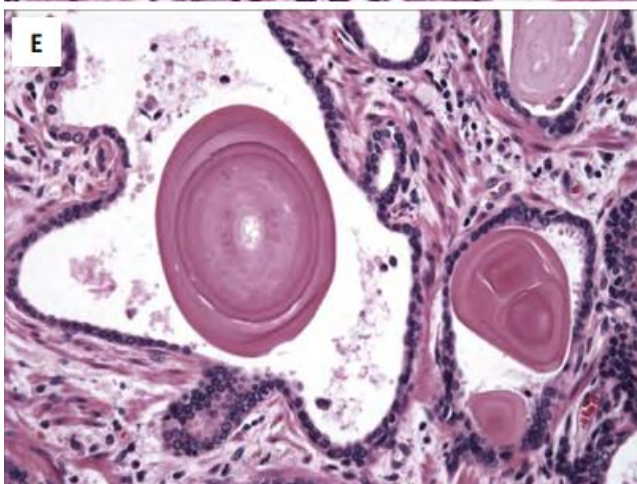
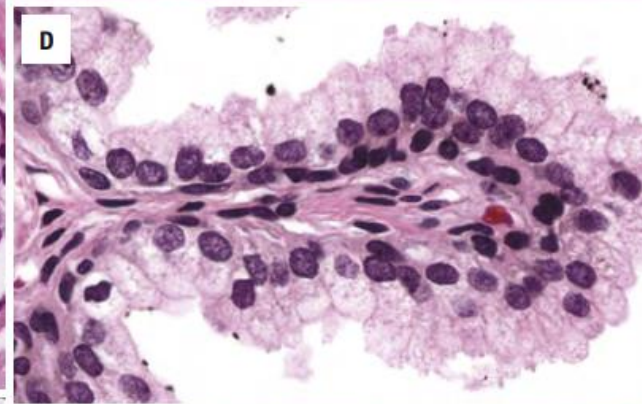
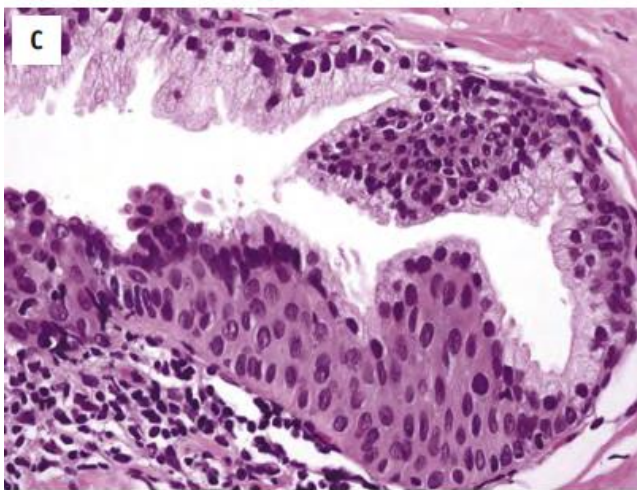
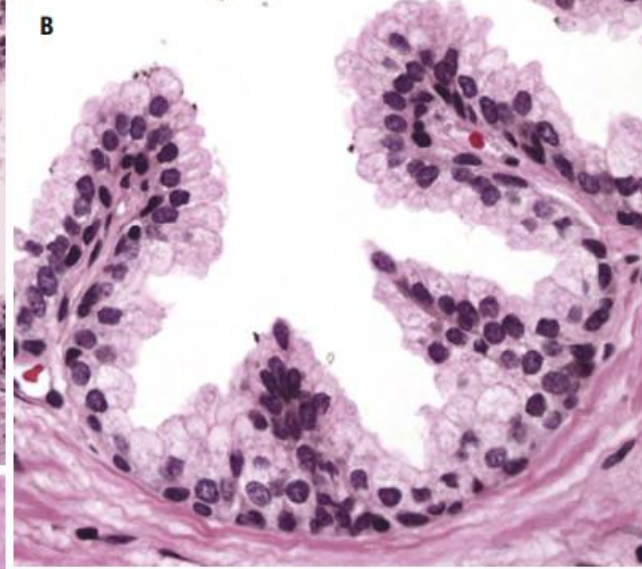
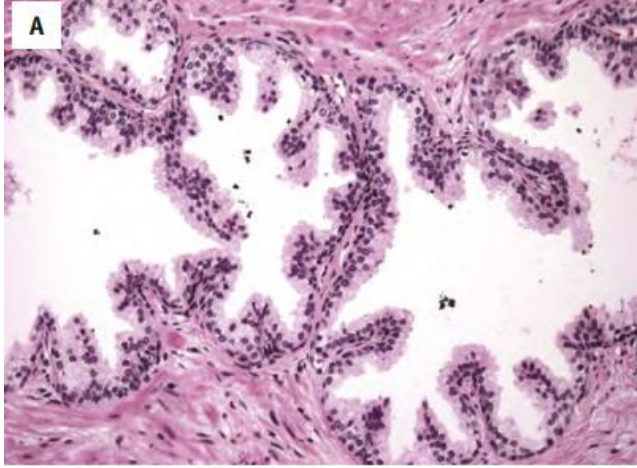
THE PROSTATE GLAND

Anatomy and Histology





Cross section of the prostate of an adult man at the level of the utricle. The nodular periurethral area represents the transition zone (TZ). The white-gray fibrous tissue surrounding the utricle divides the TZ from the peripheral zone₃₁



Prostate

Only three significant pathologies

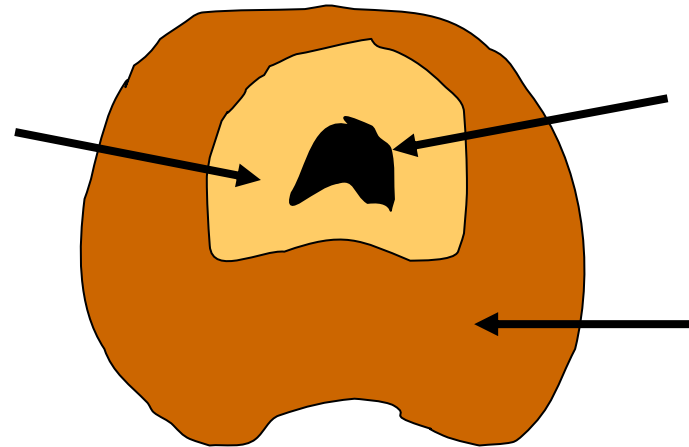
- **benign nodular enlargement**
 - **carcinoma***
 - **inflammation**
-
- ***PIN**

PROLIFERATIVE LESIONS OF THE PROSTATE


PERIURETHRAL AND
TRANSITIONAL ZONES

URETHRA

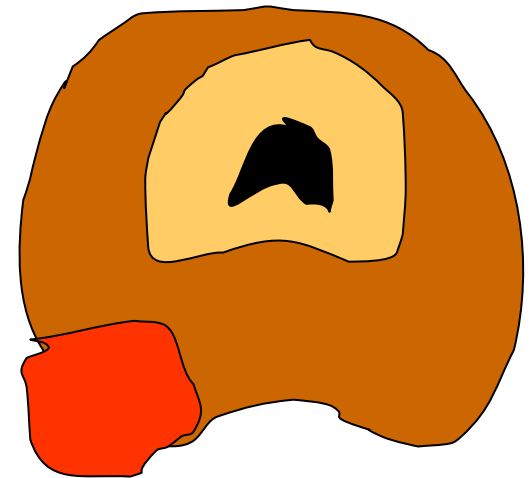
PERIPHERAL
ZONE



NORMAL PROSTATE



NODULAR HYPERPLASIA



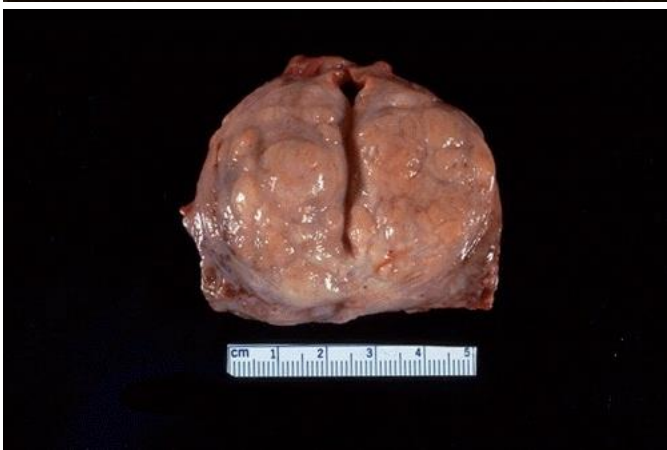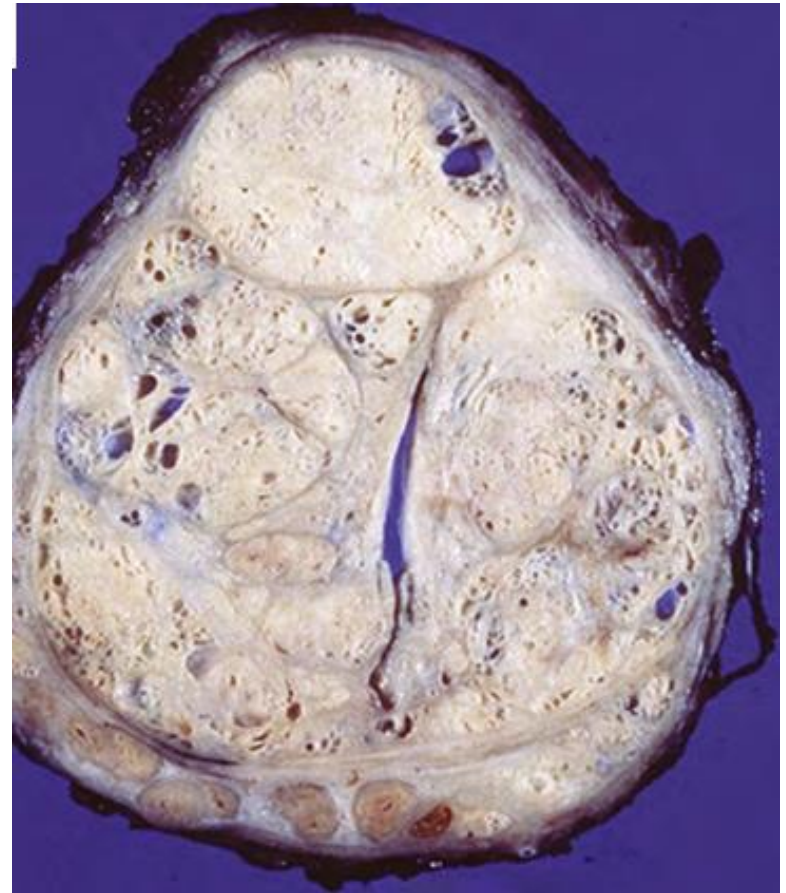
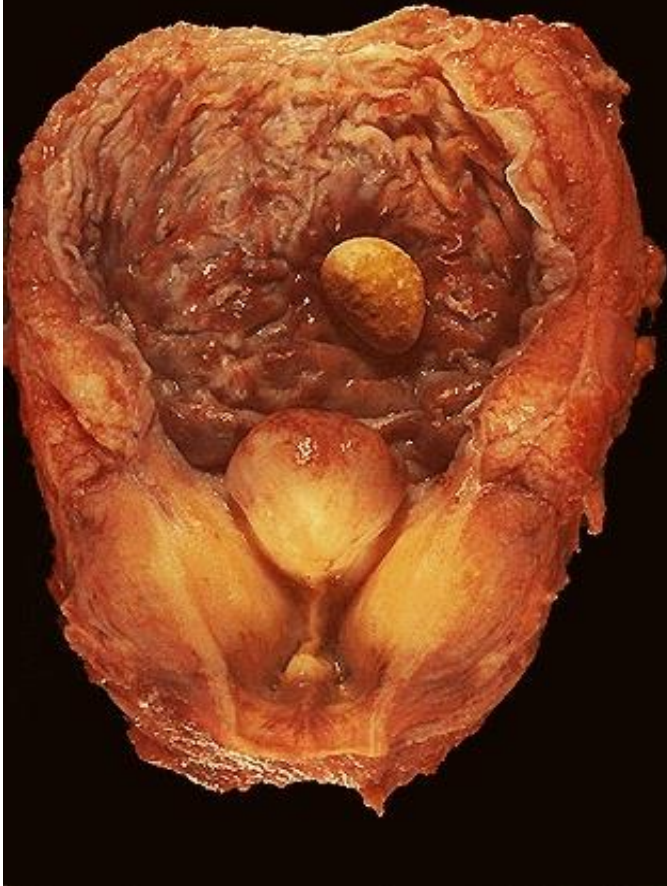CARCINOMA

NODULAR HYPERPLASIA

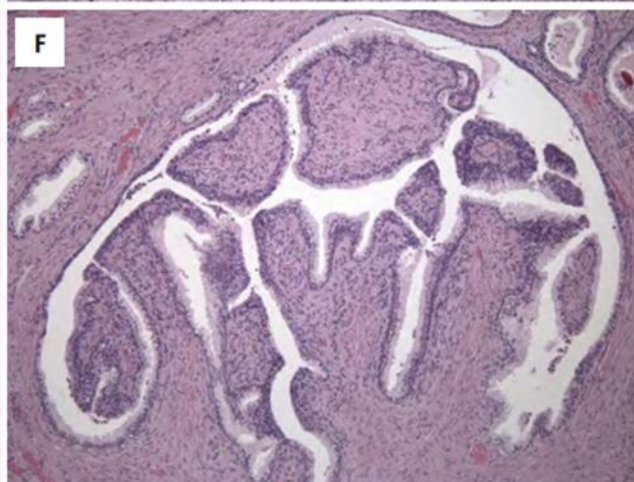
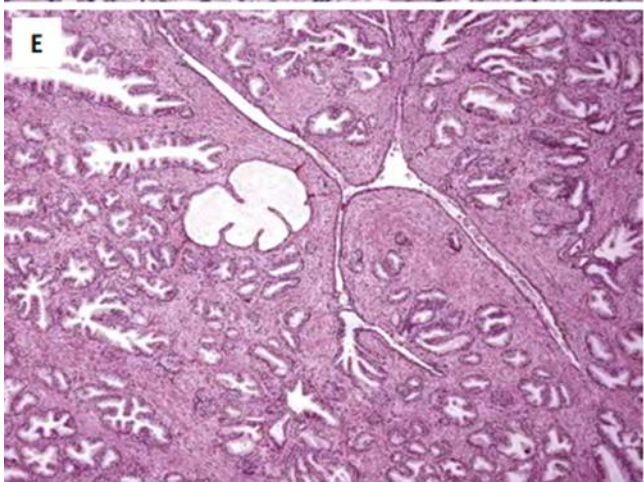
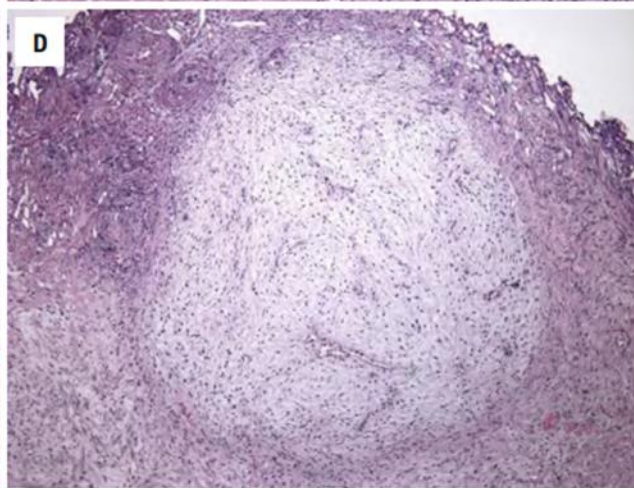
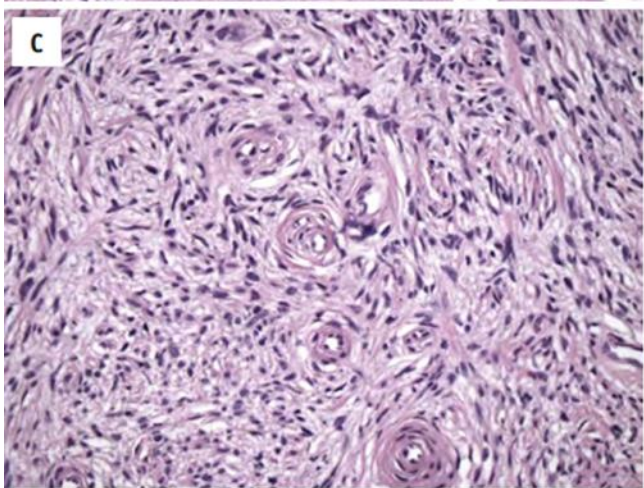
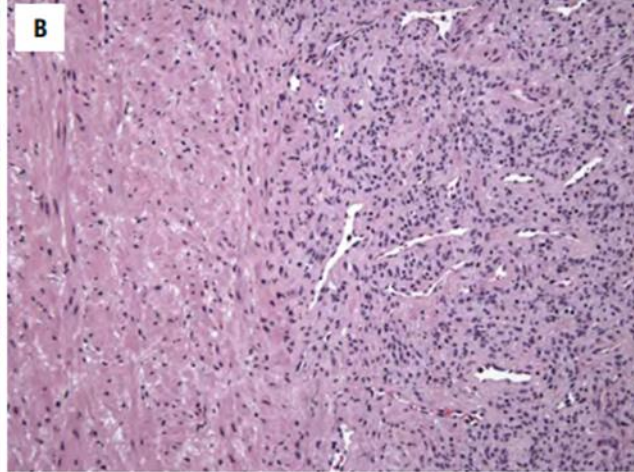
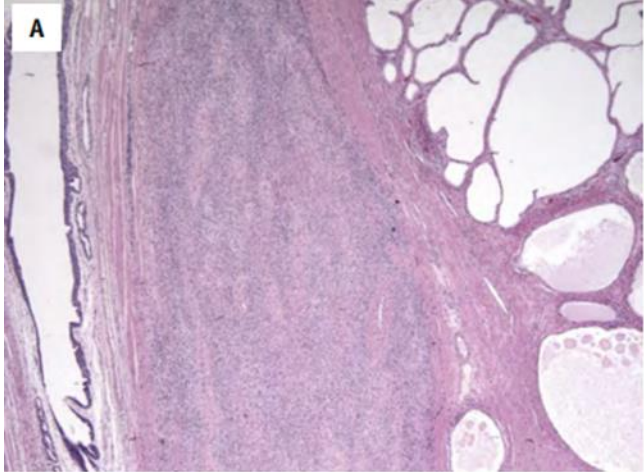
- OTHER TERMS USED
 - GLANDULAR AND STROMAL HYPERPLASIA
 - BENIGN PROSTATIC HYPERTROPHY (HYPERPLASIA)
- EPIDEMIOLOGY
 - OCCURS IN 20% OF MEN OVER 40
 - OCCURS IN 90% OF MEN OVER 80

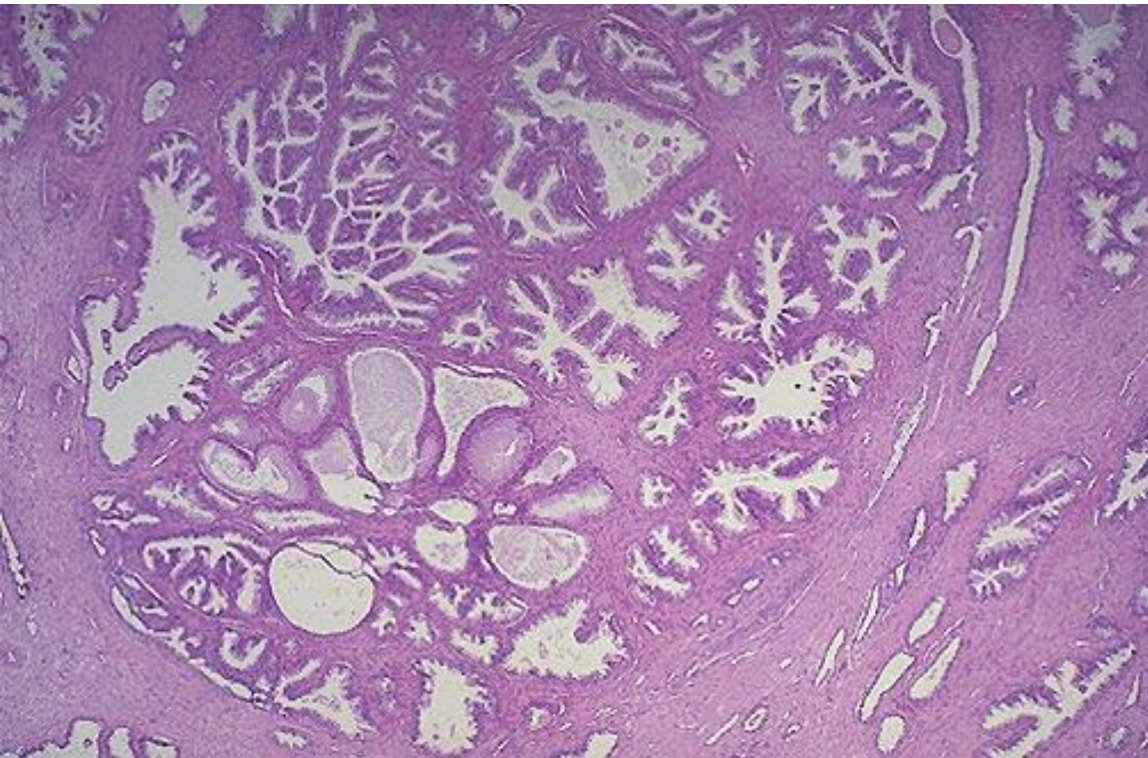
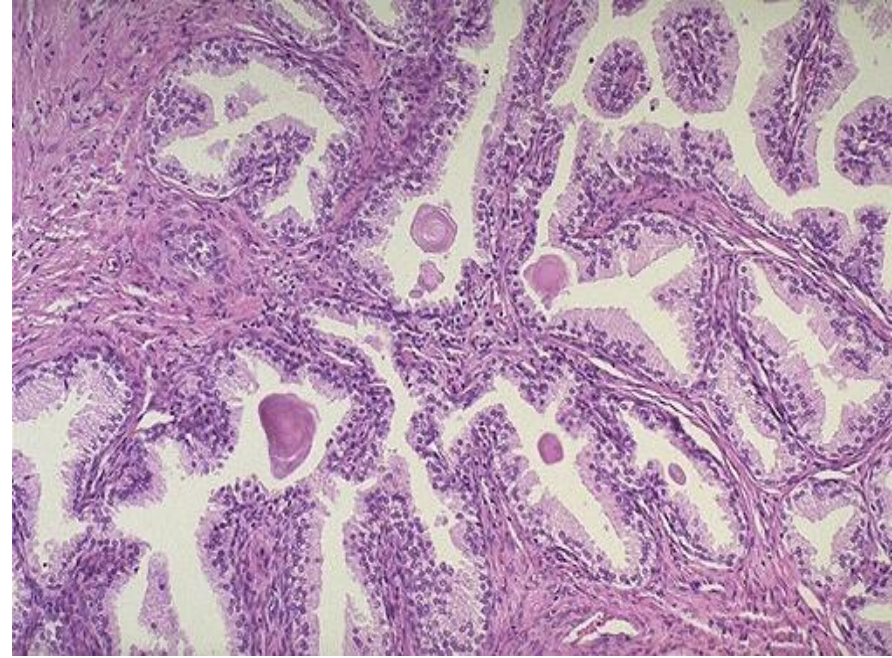
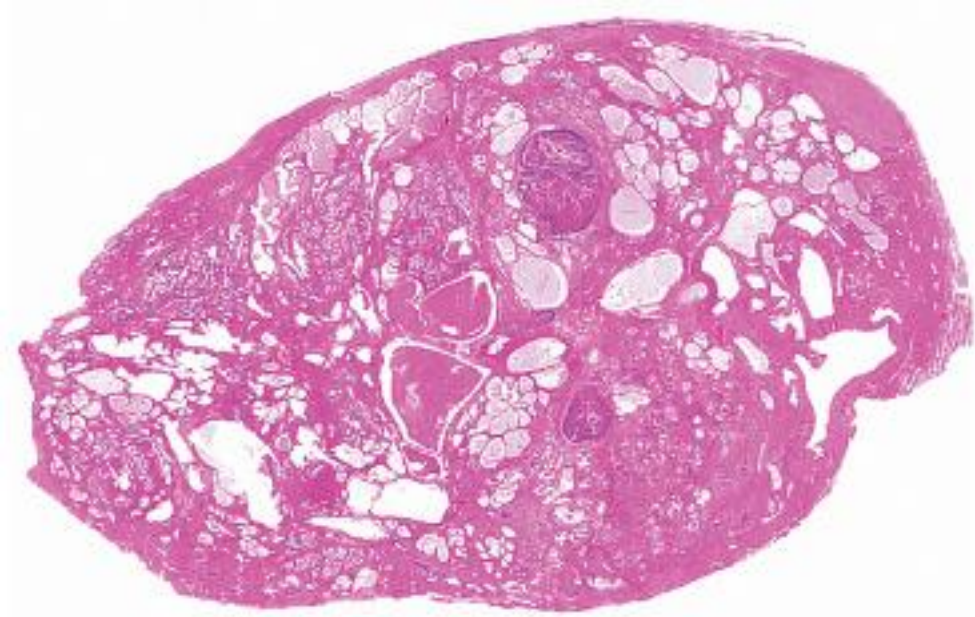
PATHOGENESIS OF NODULAR HYPERPLASIA

- PROLIFERATION OF BOTH EPITHELIAL AND STROMAL ELEMENTS
- BOTH ANDROGENS AND ESTROGENS MAY PLAY A ROLE
 - NOT SEEN IN MALES CASTRATED BEFORE PUBERTY
 - INHIBITORS OF TESTOSTERONE METABOLISM USEFUL IN TREATMENT
 - RELATIVE INCREASE IN ESTROGENS IN OLDER MEN MAY INCREASE DHT RECEPTORS IN PROSTATE



NODULAR HYPERPLASIA



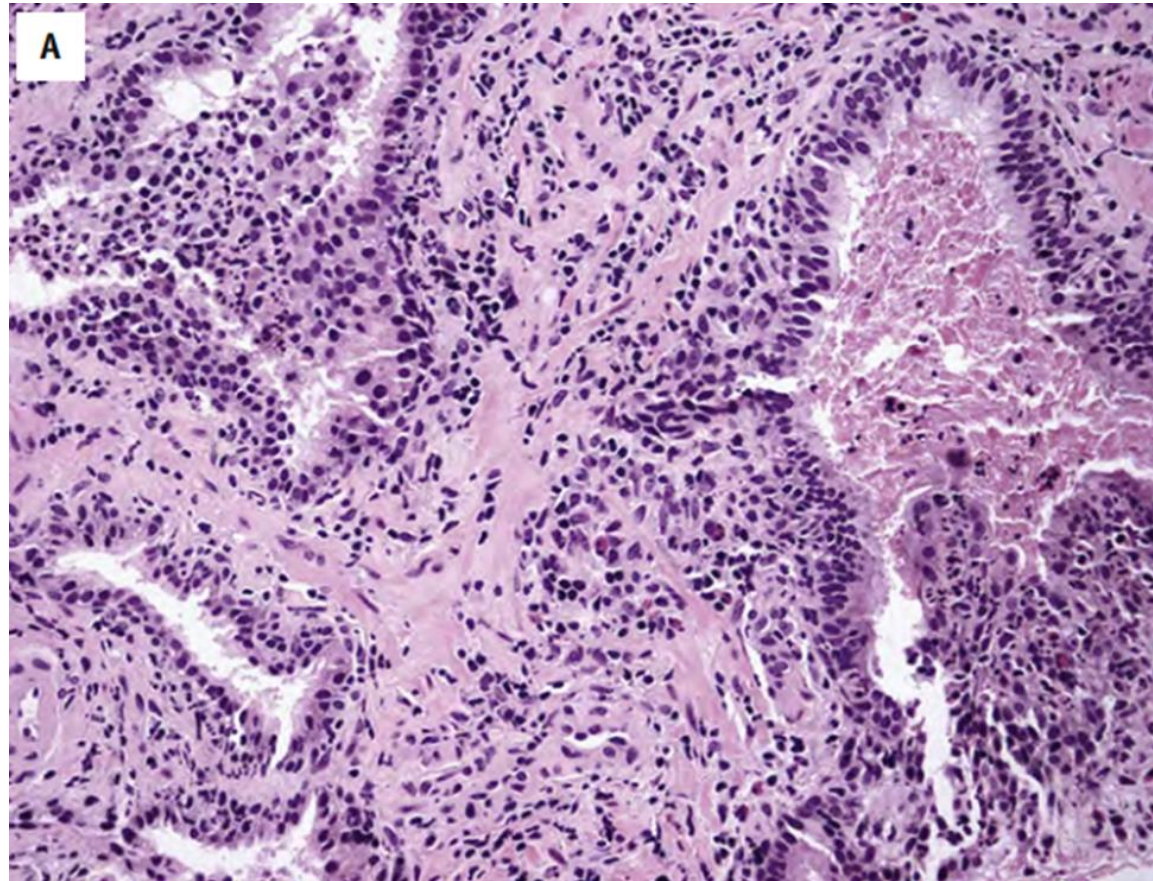


BENIGN PROSTATIC
HYPERTROPHY (HYPERPLASIA)

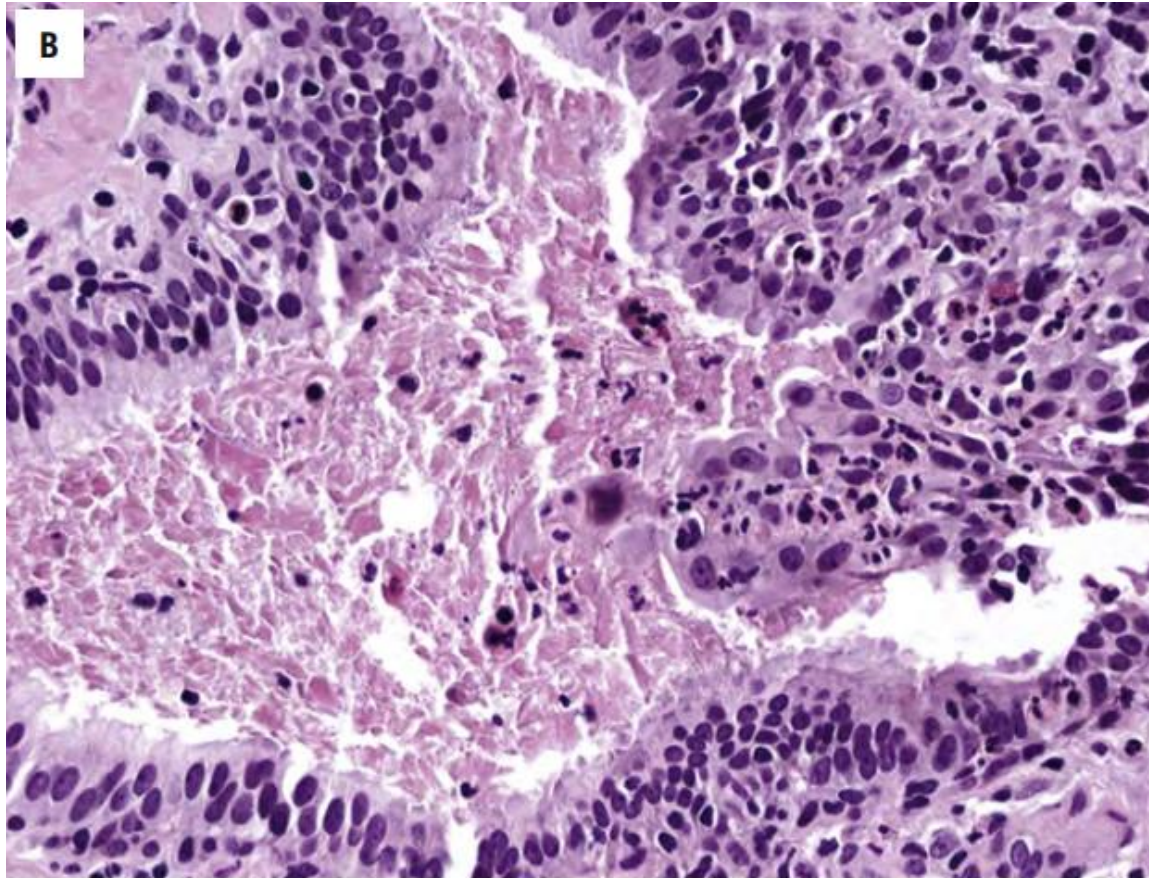
INFLAMMATORY AND INFLAMMATORY-LIKE LESIONS OF THE PROSTATE

- The classification of prostatitis syndrome includes
- (1) acute bacterial prostatitis (ABP);
- (2) chronic bacterial prostatitis (CBP);
- (3) chronic nonbacterial prostatitis, also known as chronic pelvic pain syndrome (CPPS), divided into inflammatory and noninflammatory type;
- (4) asymptomatic inflammatory prostatitis (AIP).

ACUTE AND CHRONIC BACTERIAL PROSTATITIS

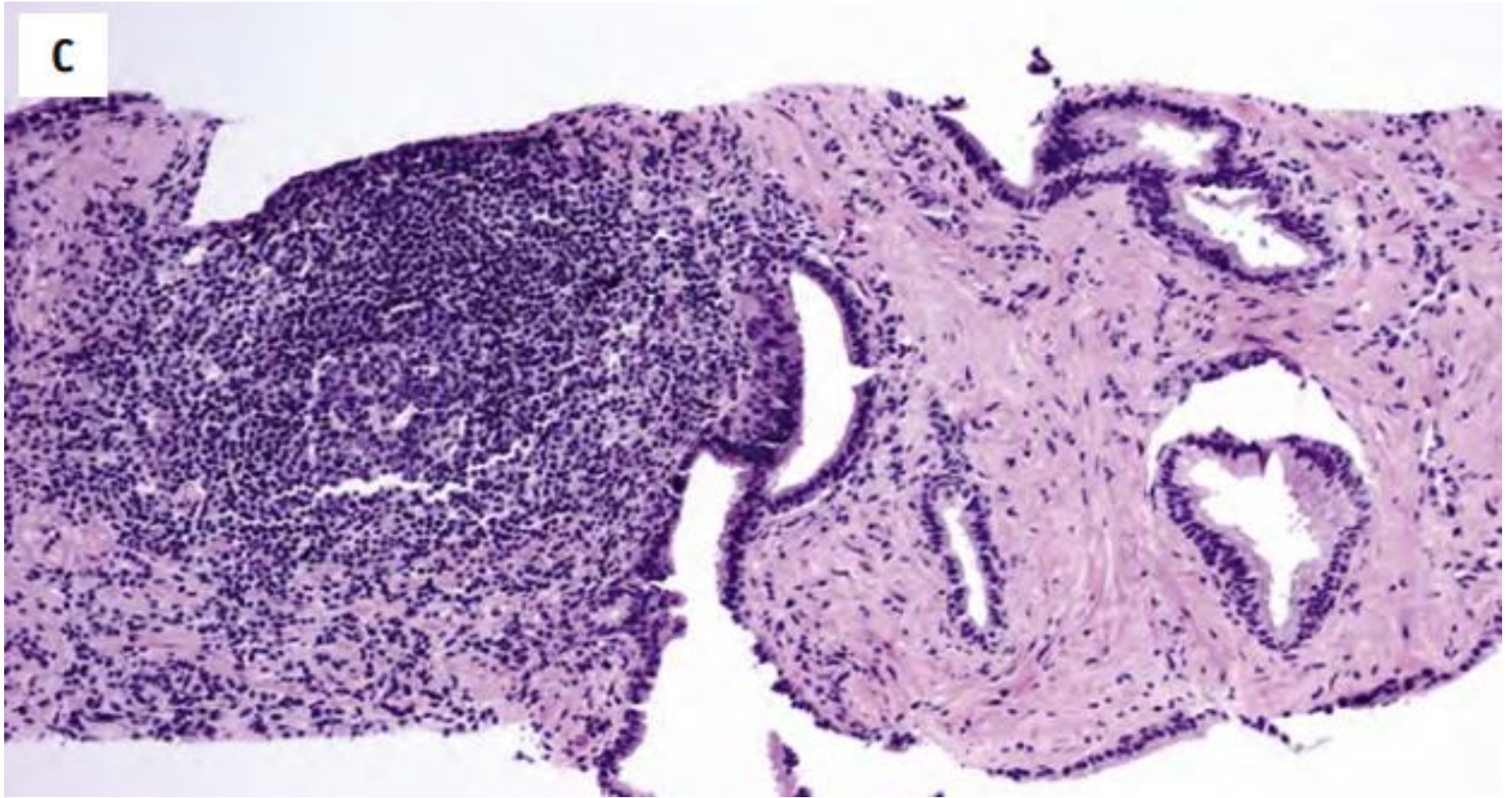


Acute bacterial prostatitis consists of neutrophils within and around acini. A stromal chronic inflammatory infiltrate is also frequently present.



The neutrophils are present within the columnar epithelium and inside ducts and acini filled with desquamated cellular debris.

CHRONIC BACTERIAL PROSTATITIS



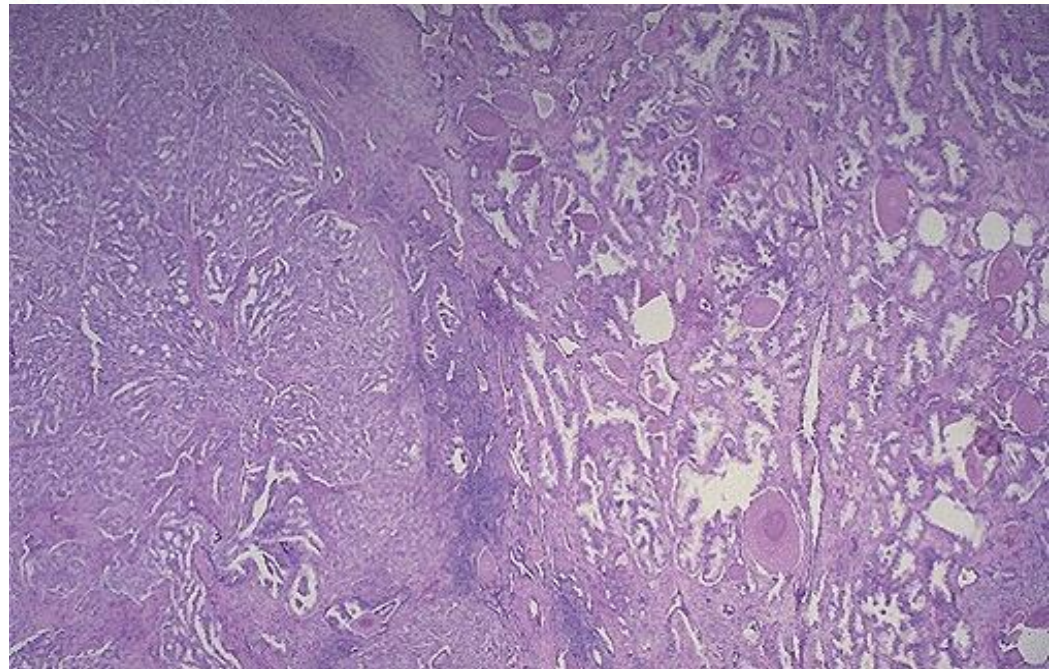
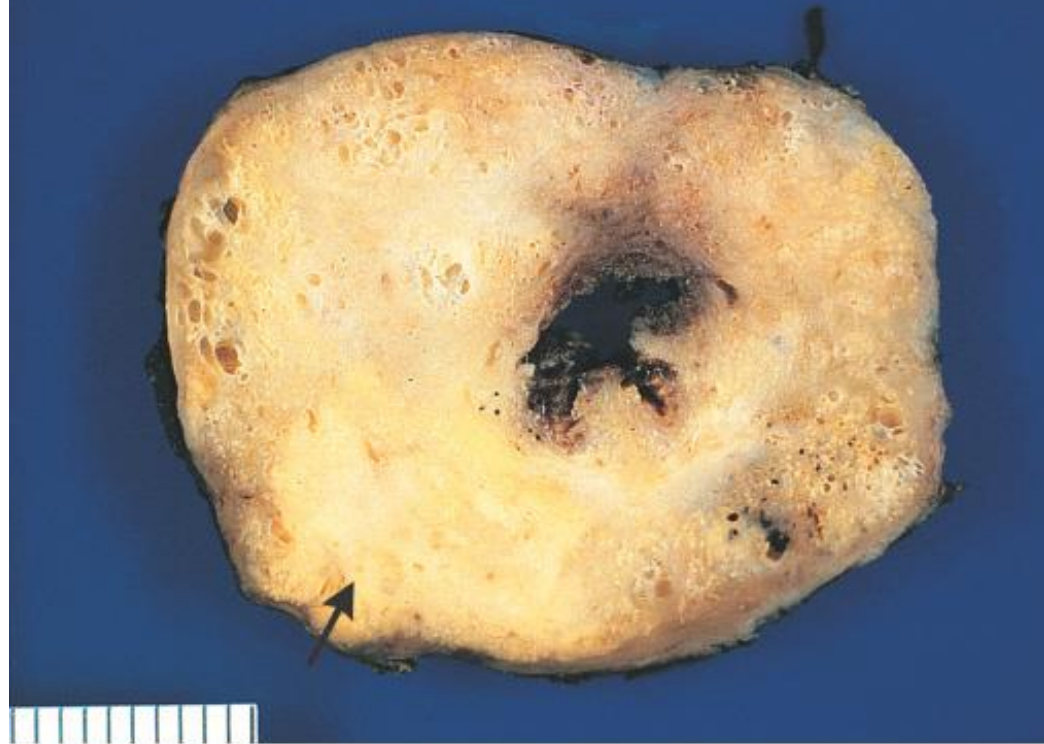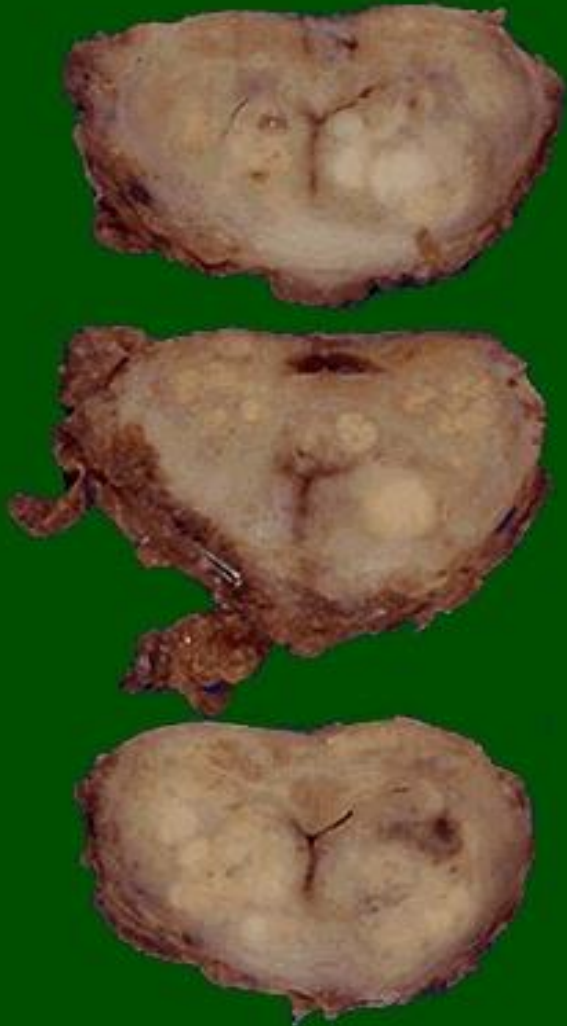
Chronic inflammation typically has a periglandular distribution and contains an admixture of lymphocytes and plasma cells.

CARCINOMA OF THE PROSTATE

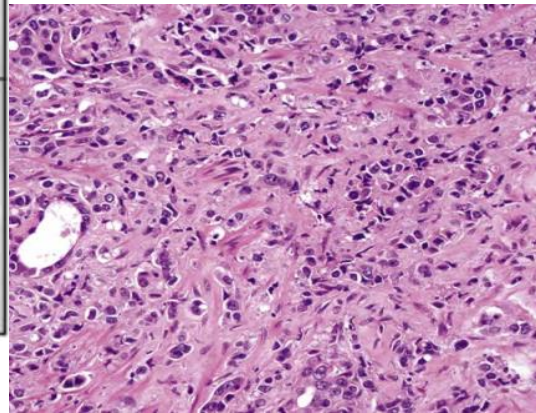
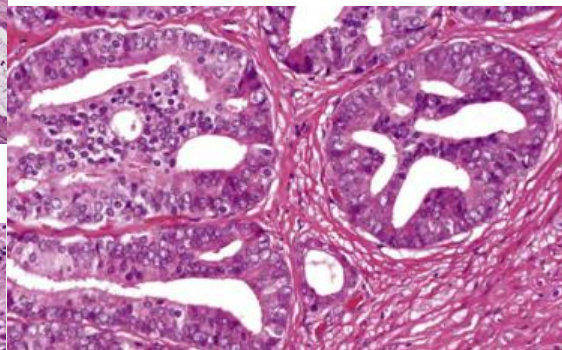
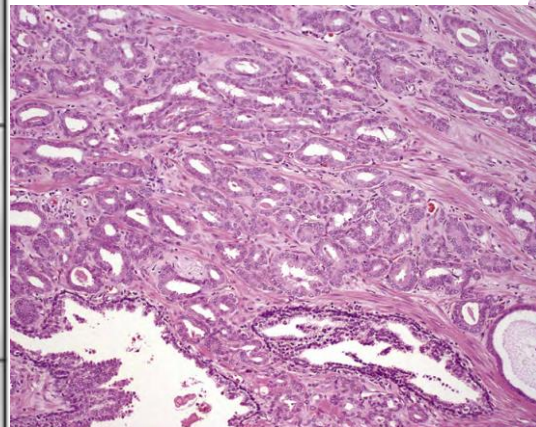
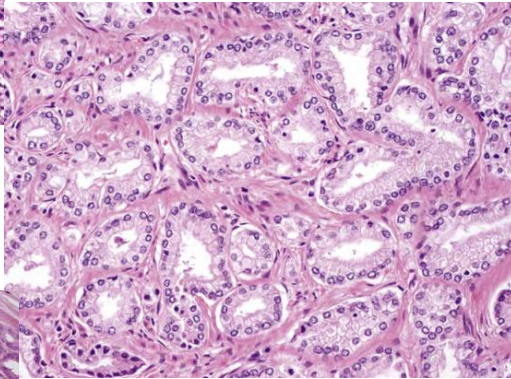
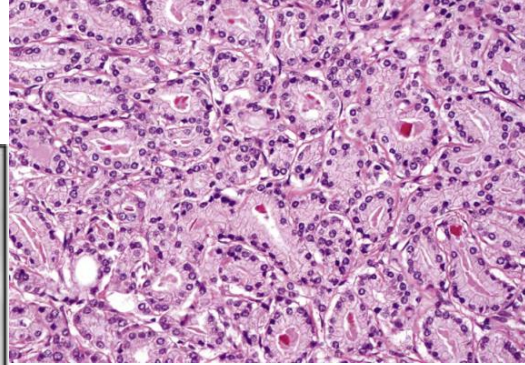
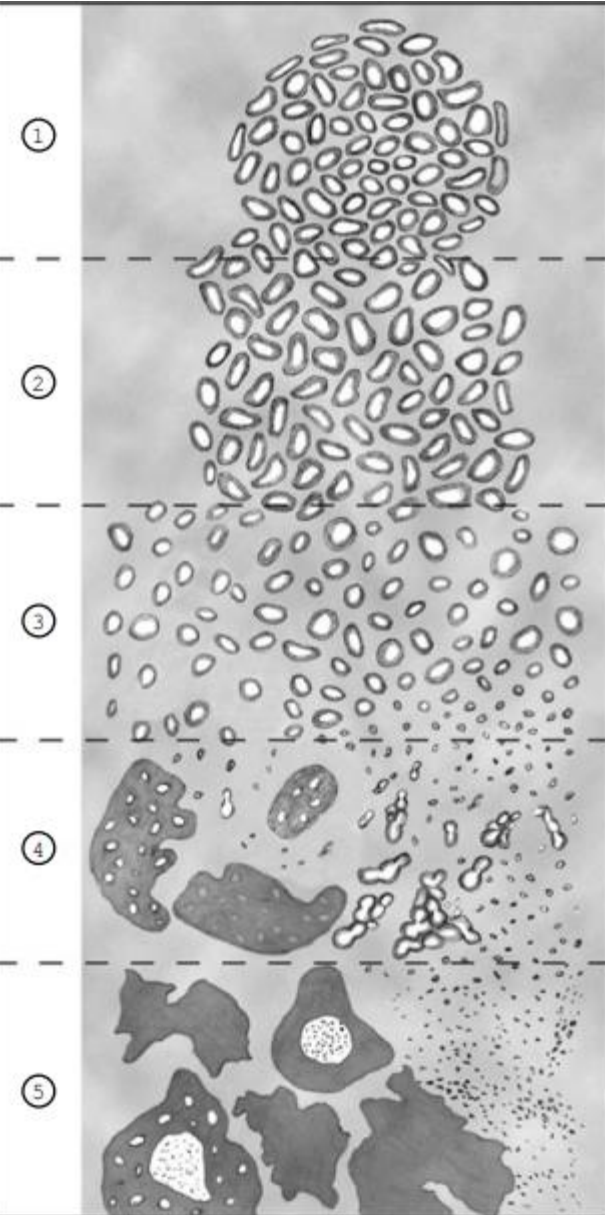
- EPIDEMIOLOGY

- MOST COMMON VISCERAL CANCER
 - ABOUT 70/100,000 MEN IN US
 - 200,000 NEW CASES/YR IN US
 - 20% ARE LETHAL
- SECOND MOST COMMON CAUSE OF CANCER DEATH IN MEN
- PEAK INCIDENCE OF CLINICAL CANCER IS 65-75 YO
- LATENT CA IS EVEN MORE PREVALENT
 - >50% IN MEN > 80 YO

Carcinoma of the prostate



Gleason Grading System



TESTICULAR NEOPLASMS

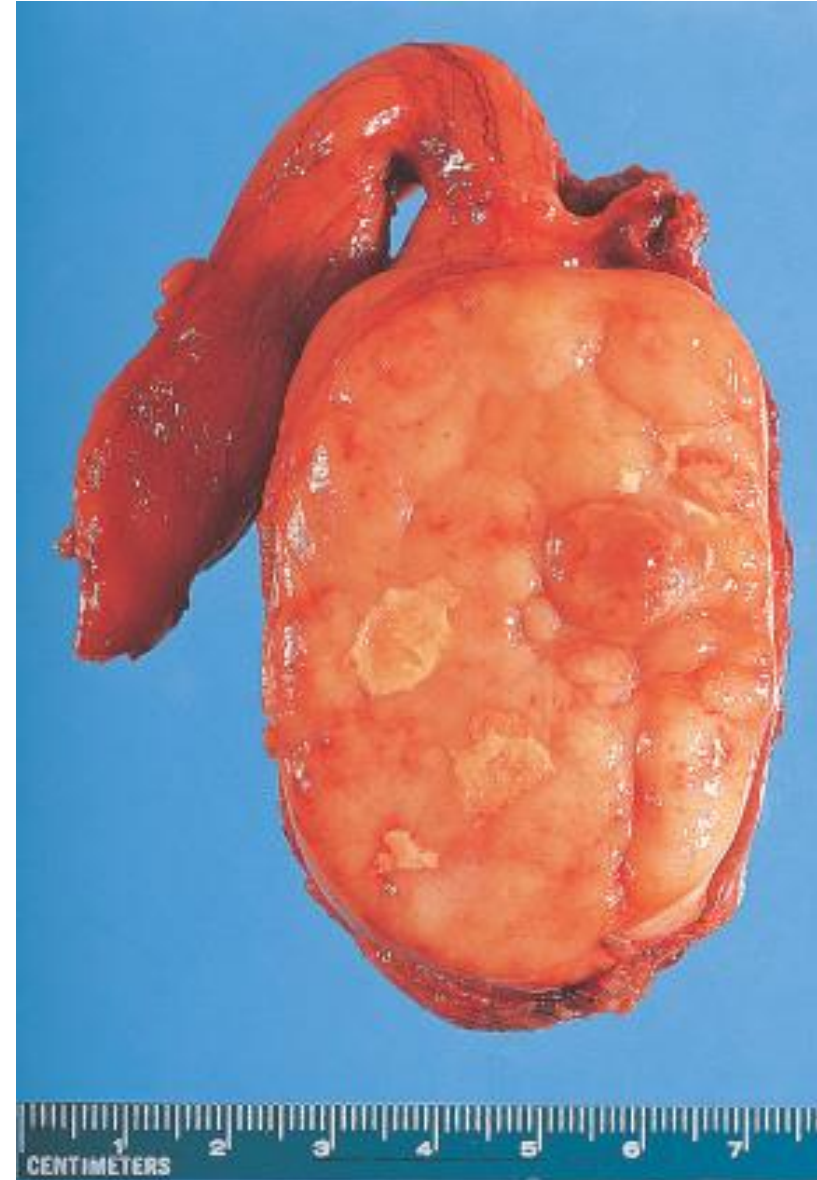
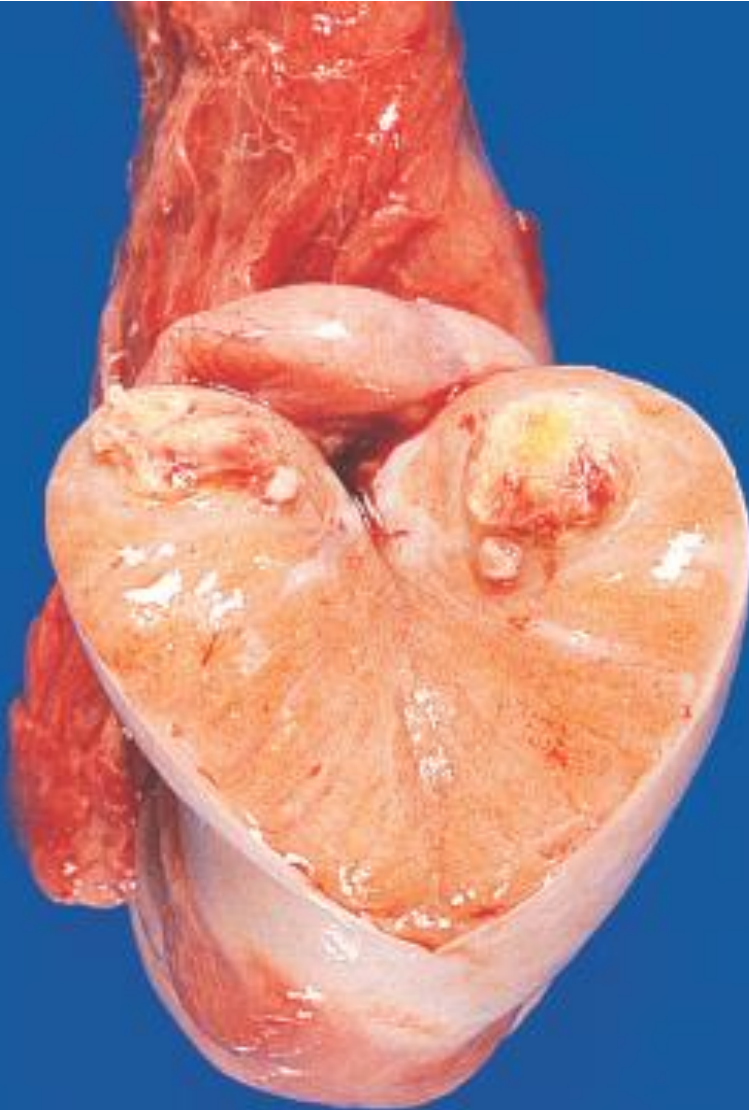
- EPIDEMIOLOGY

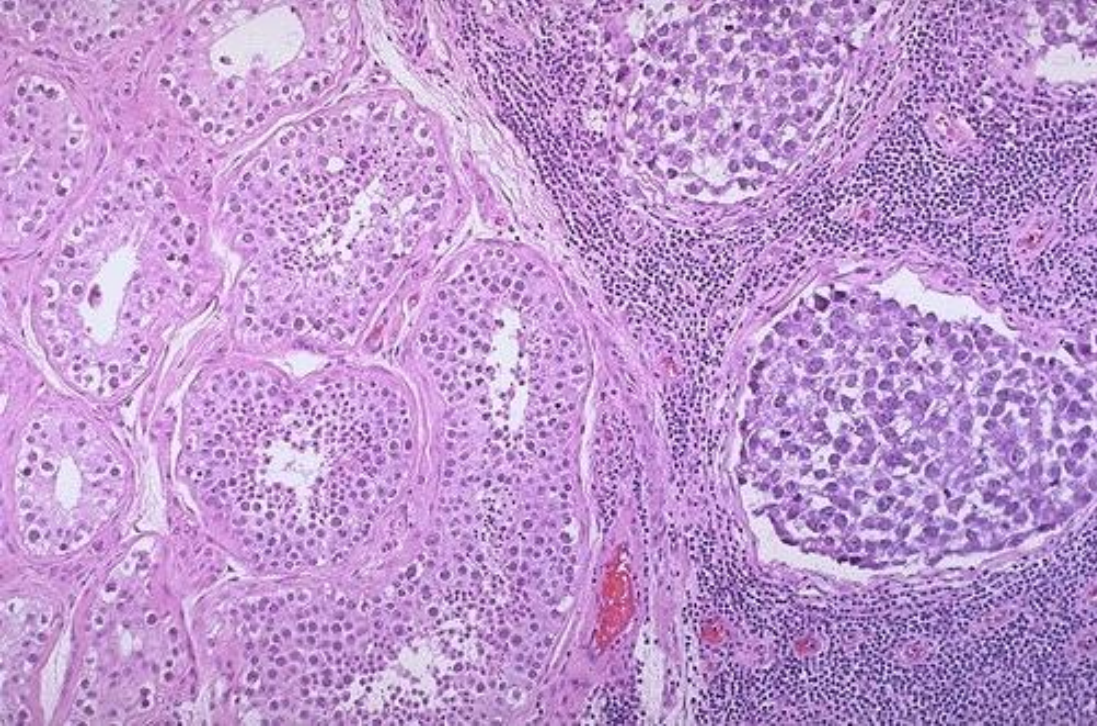
- MOST IMPORTANT CAUSE OF PAINLESS ENLARGEMENT OF TESTIS
- 2/100,000 MALES, WHITES > BLACKS (US)
- INCREASED FREQUENCY IN SIBLINGS
- PEAK INCIDENCE 15-34 YRS
- MOST ARE MALIGNANT
- ASSOCIATED WITH GERM CELL MALDEVELOPMENT
 - CRYPTORCHIDISM
 - TESTICULAR DYSGENESIS(XXY)

WHO CLASSIFICATION OF TESTICULAR TUMORS

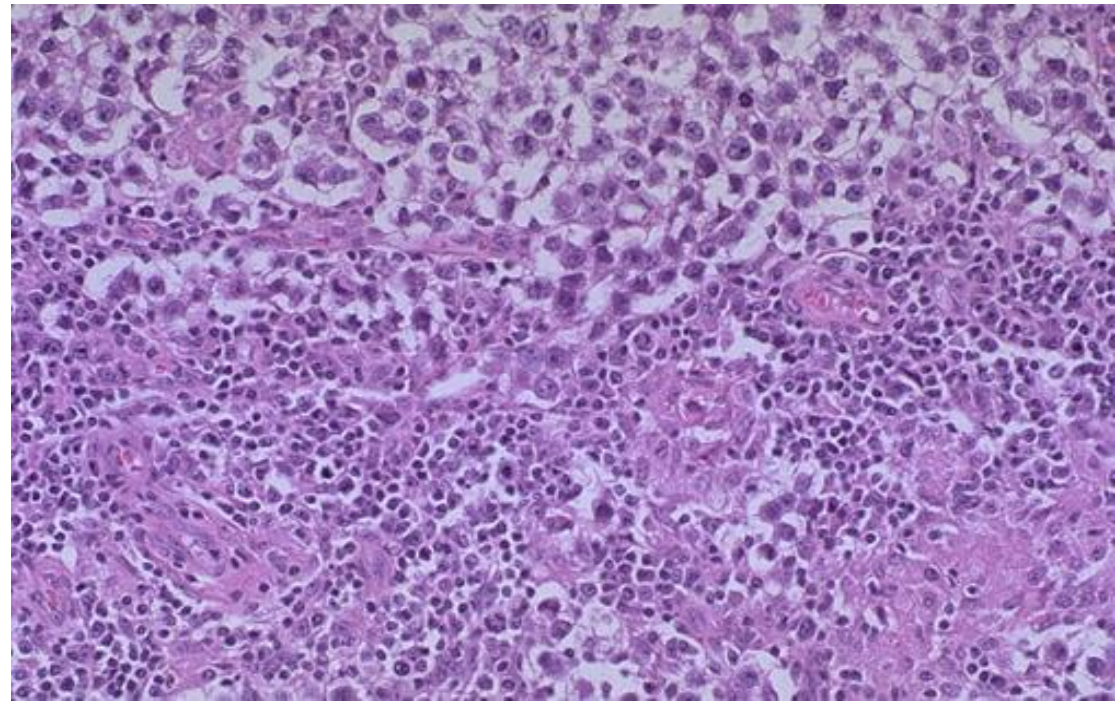
- ONE HISTOLOGIC PATTERN (40%)
 - SEMINOMAS (30%)
 - EMBRYONAL CARCINOMA
 - YOLK SAC TUMOR
 - CHORIOCARCINOMA
 - TERATOMA
- MULTIPLE HISTOLOGIC PATTERNS (60%)
 - EMBRYONAL CA + TERATOMA
 - CHORIOCARCINOMA + OTHER
 - OTHER COMBINATIONS

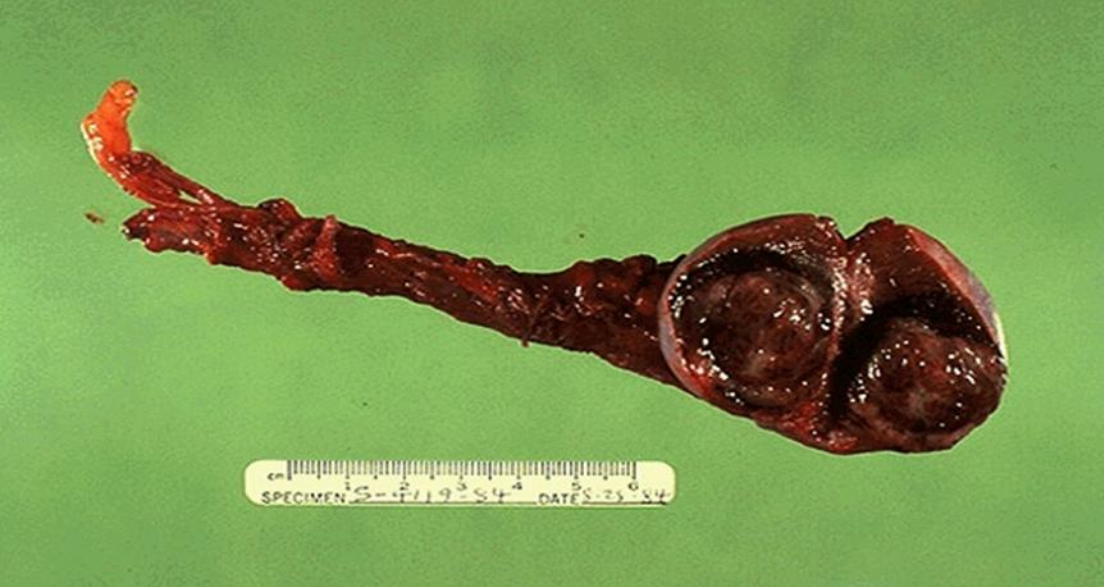Testicular seminomas



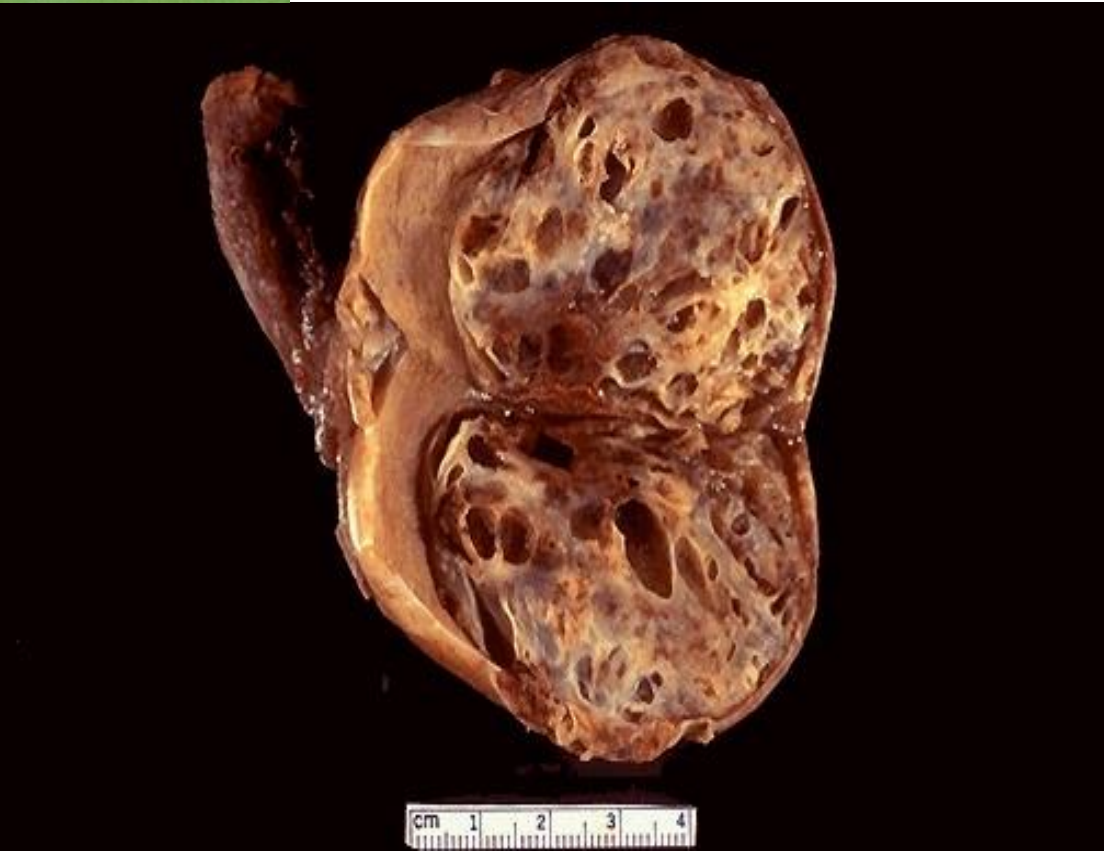

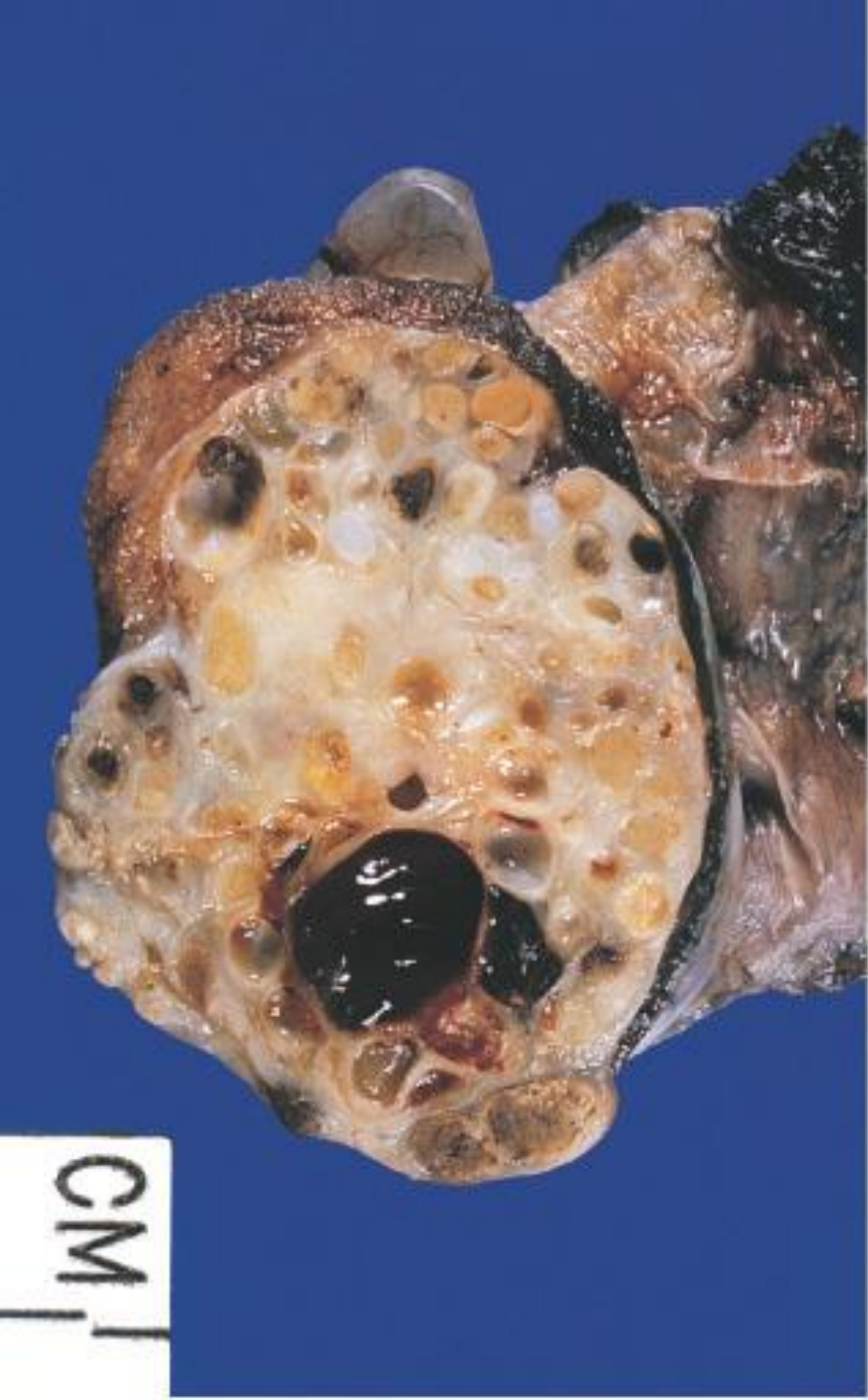
Testicular seminomas





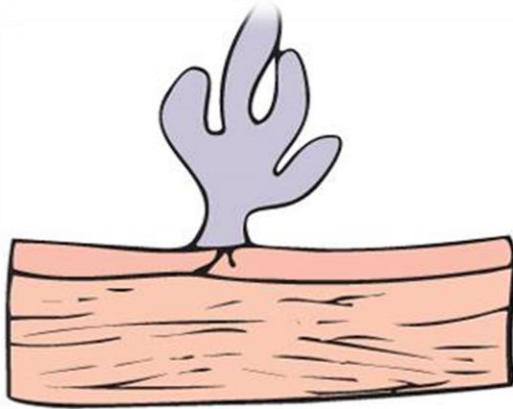
Embryonal carcinoma



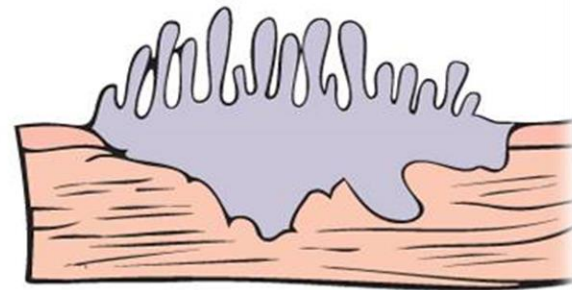

Teratoma

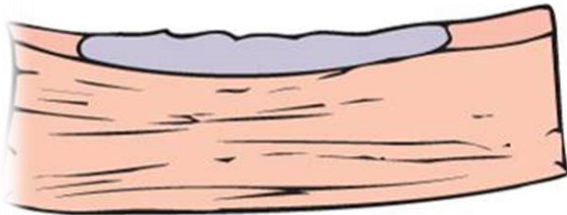
RENAL CARCINOMAS



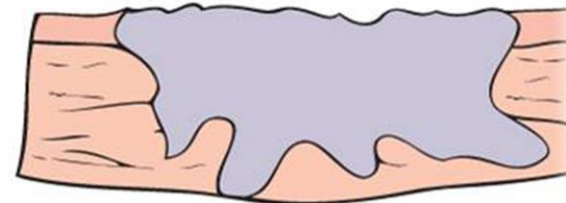
Papilloma-
papillary carcinoma



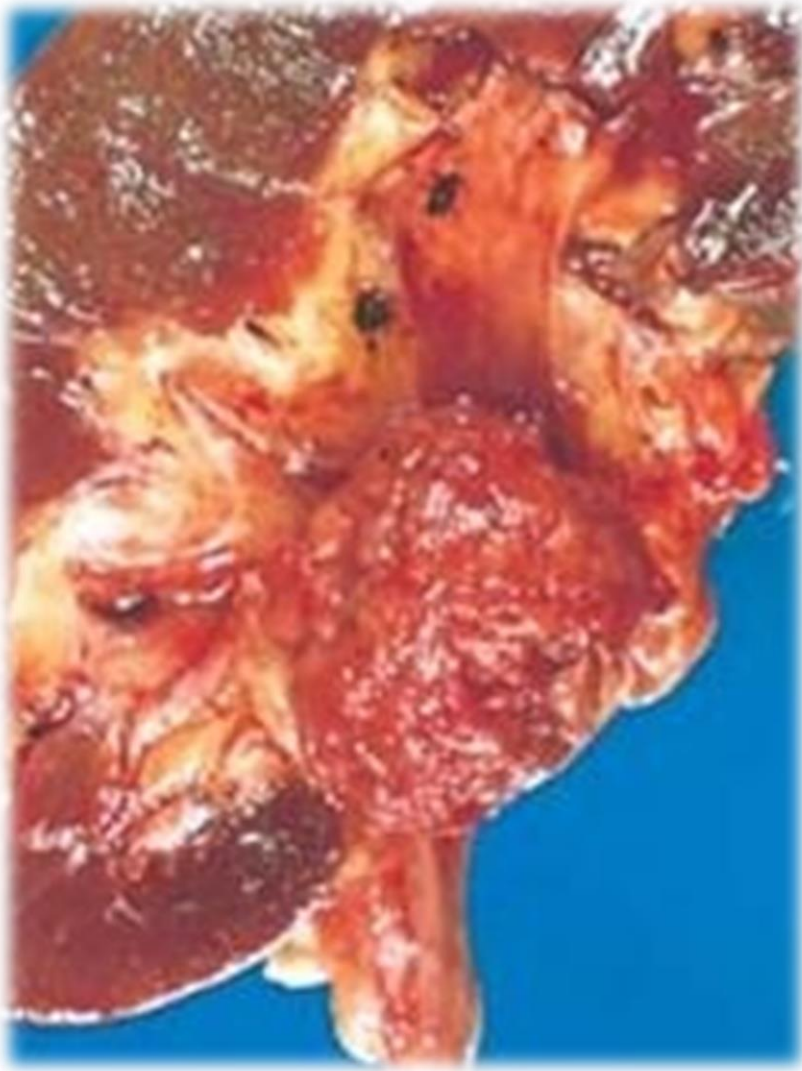Invasive
papillary carcinoma



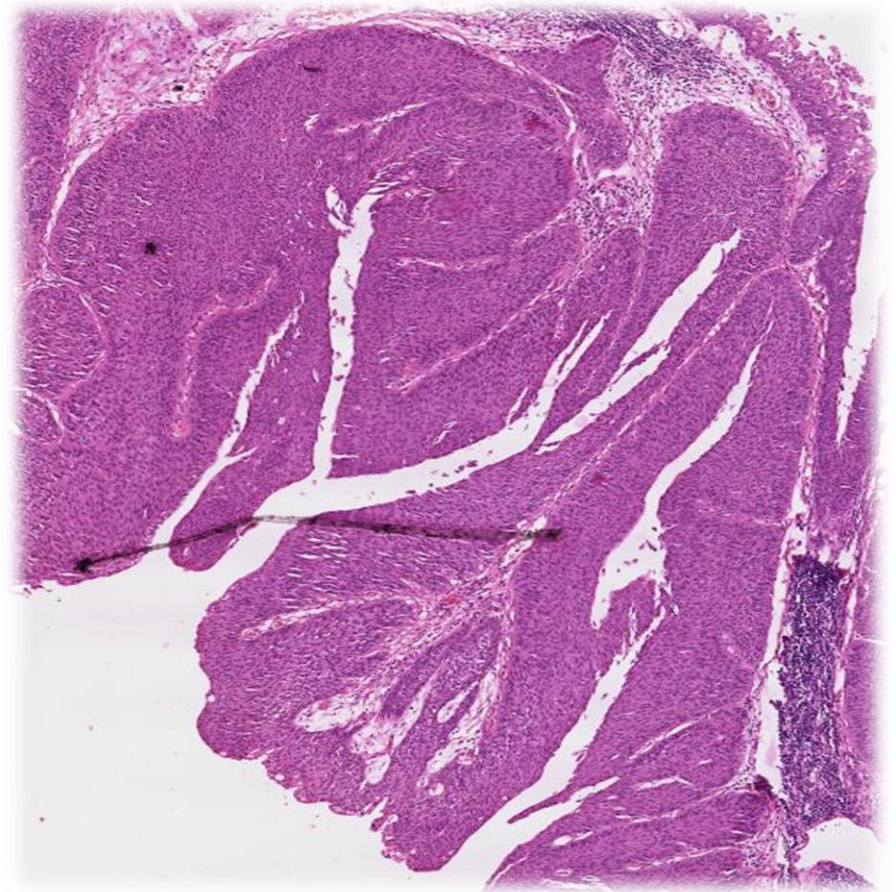
Flat noninvasive
carcinoma



Flat invasive
carcinoma



The most likely place for a transitional (urothelial) carcinoma, is smack dab in the HILUM



SYPHILIS

SYPHILIS INTRODUCTION

- Caused by *Treponema pallidum*.
- Transmission: sexual; maternal-fetal, and rarely by other means.
- Primary and secondary syphilis in the US dropped by ~ 90 %t from 1990 to 2000, the number of cases have gone up since then.
- A dramatic increase in cases in men from 2000 to 2002 reflected syphilis in MSM.
- Syphilis increases the risk of both transmitting and getting infected with HIV.
- Do HIV testing in all patients with syphilis.

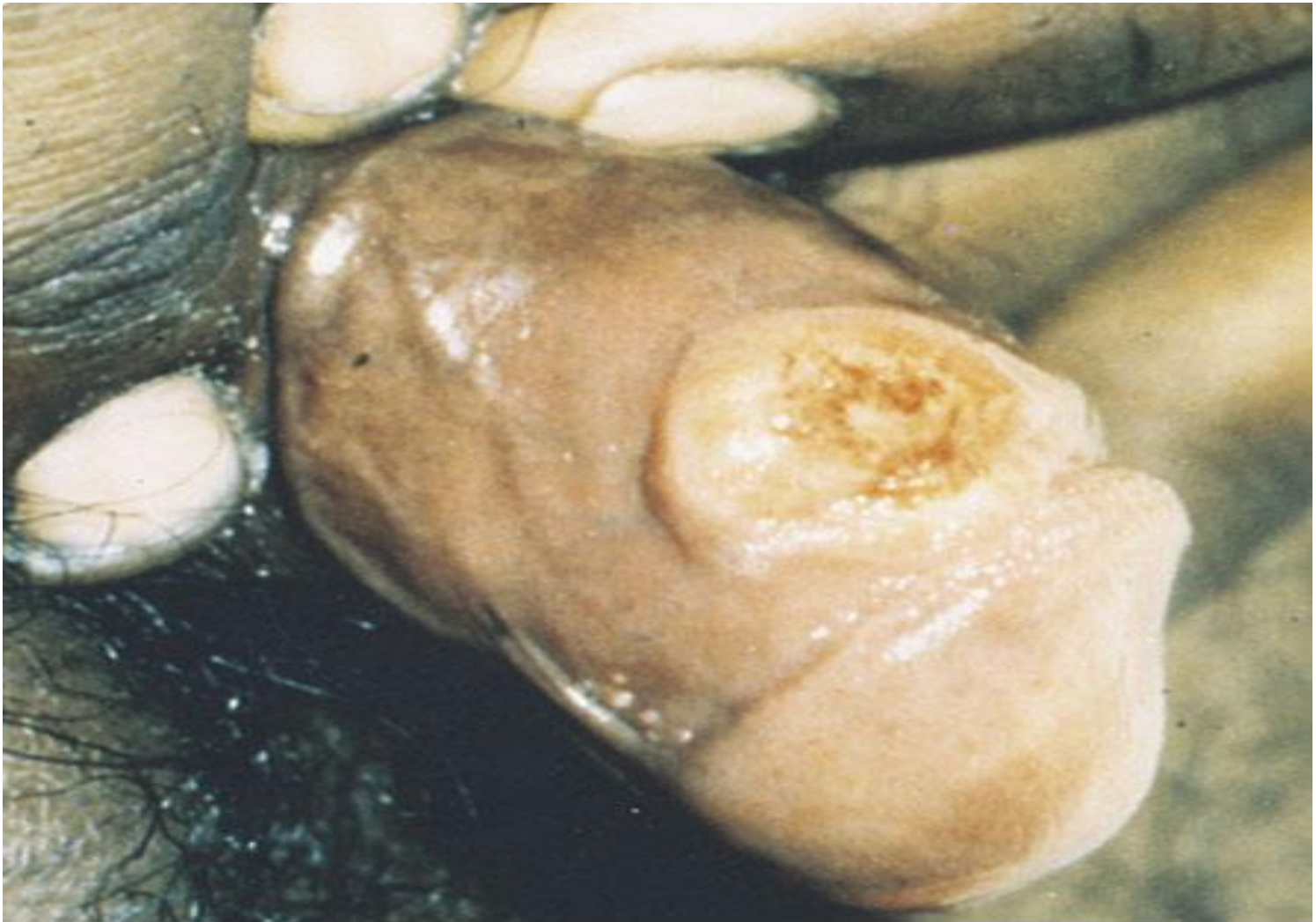STAGES OF SYPHILIS

1. Primary
2. Secondary
3. Latent
 - Early latent
 - Late latent
4. Late or tertiary
 - May involve any organ, but main parts are:
 - Neurosyphilis
 - Cardiovascular syphilis
 - Late benign (gumma)

PRIMARY SYPHILIS (The Chancre)

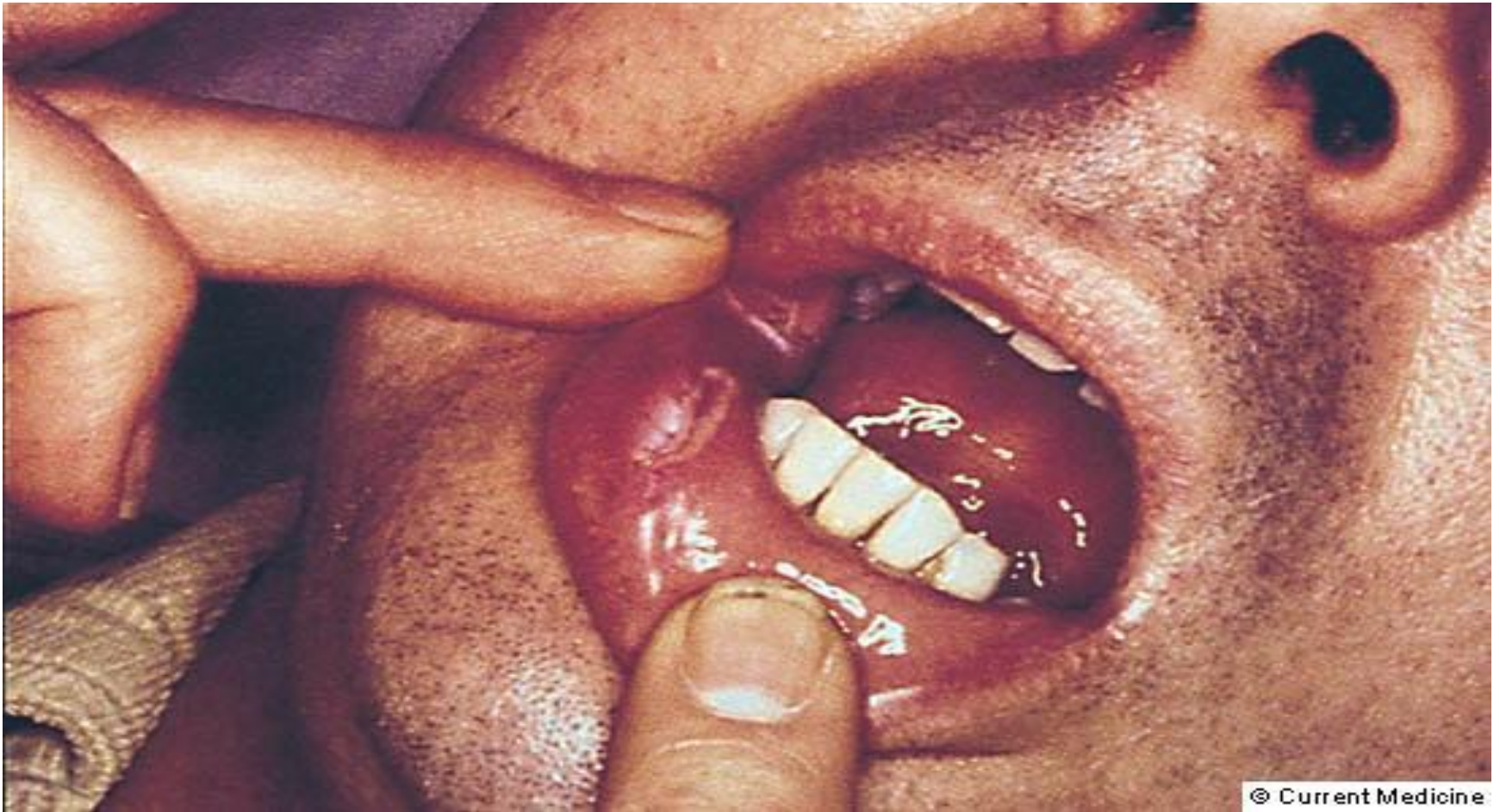- Incubation period 9-90 days, usually ~21 days.
- Develops at site of contact/inoculation.
- Classically: single, painless, clean-based, indurated ulcer, with firm, raised borders. Atypical presentations may occur.
- Mostly anogenital, but may occur at any site (tongue, pharynx, lips, fingers, nipples, etc...)
- Non-tender regional adenopathy
- Very infectious.
- May be darkfield positive but serologically negative.
- Untreated, heals in several weeks, leaving a faint scar.

The Chancre



Copyright ©2006 by The McGraw-Hill Companies, Inc.
All rights reserved.

Oral chancres in primary syphilis



SECONDARY SYPHILIS

- Seen 6 wks to 6 mos after primary chancre
- Usually w diffuse non-pruritic, indurated rash, including palms & soles.
- May also cause:
 - Fever, malaise, headache, sore throat, myalgia, arthralgia, generalized lymphadenopathy
 - Hepatitis (10%)
 - Renal: an immune complex type of nephropathy with transient nephrotic syndrome
 - Iritis or an anterior uveitis
 - Bone: periostitis
 - CSF pleocytosis in 10 - 30% (but, symptomatic meningitis is seen in <1%)

SECONDARY SYPHILIS (Cont.)

- **The skin rash:**

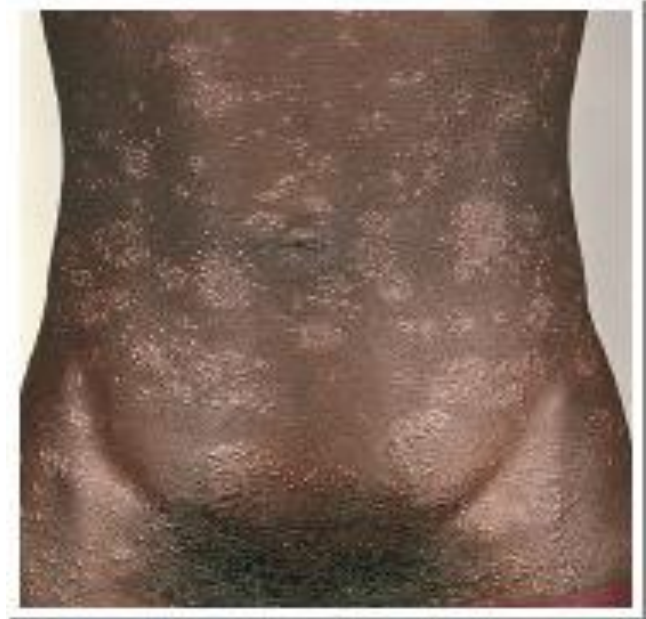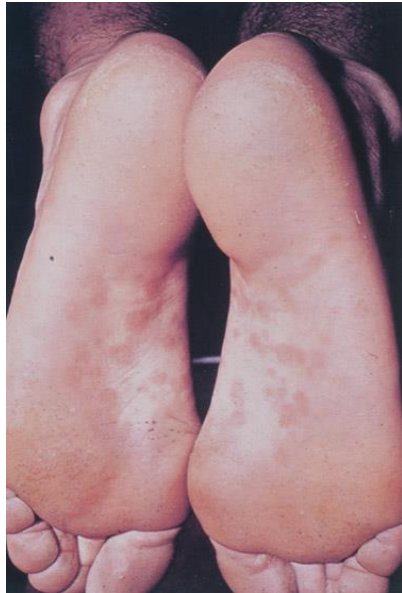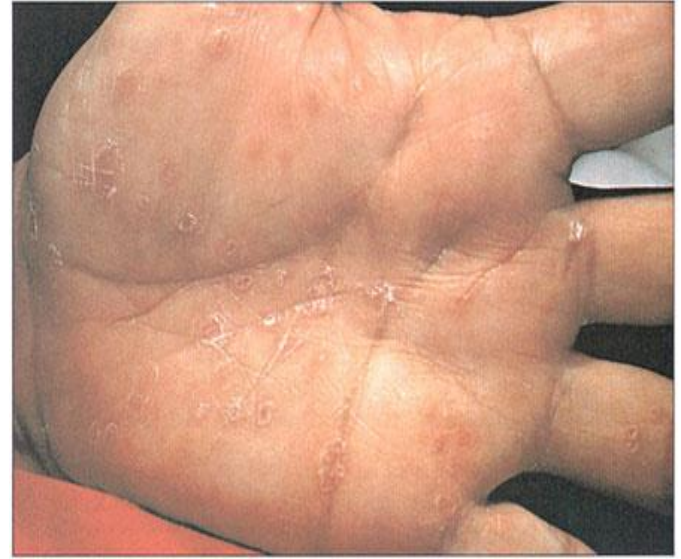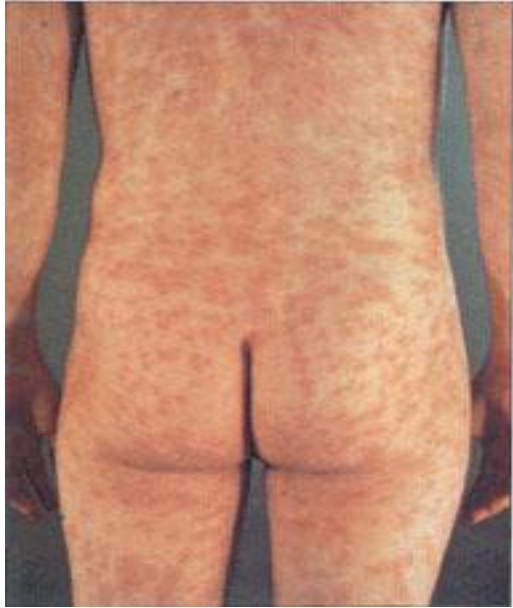
- **Diffuse,**
- **often with a superficial scale (papulosquamous).**
- **May leave residual pigmentation or depigmentation.**

- **Condylomata Lata:**

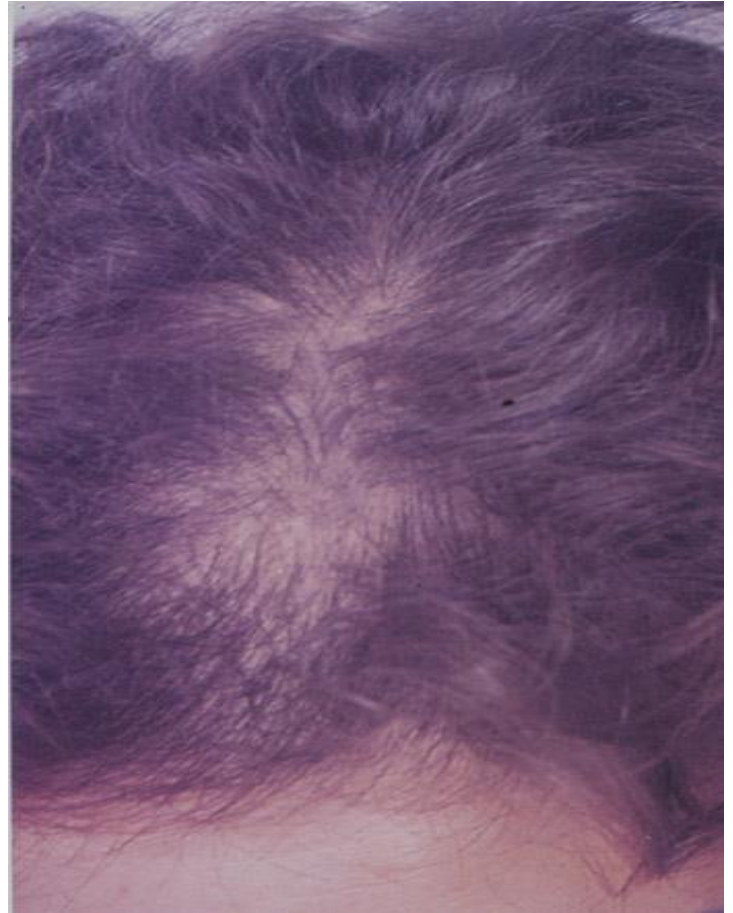
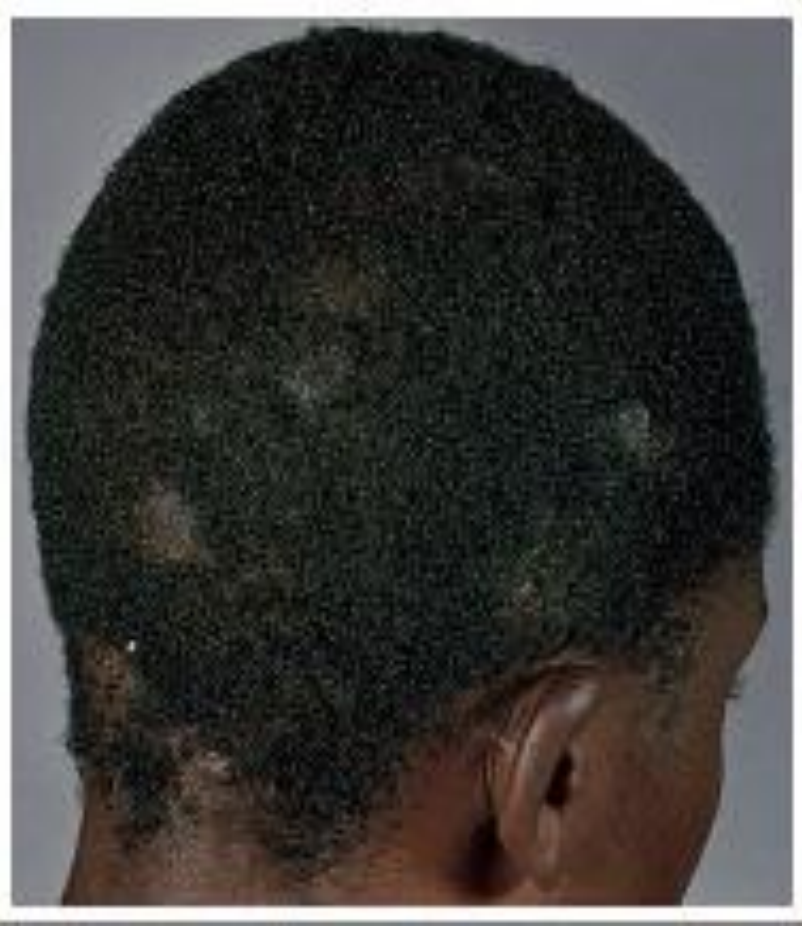- **Formed by coalescence of large, pale, flat-topped papules.**
- **Occur in warm, moist areas such as the perineum.**
- **Highly infectious.**

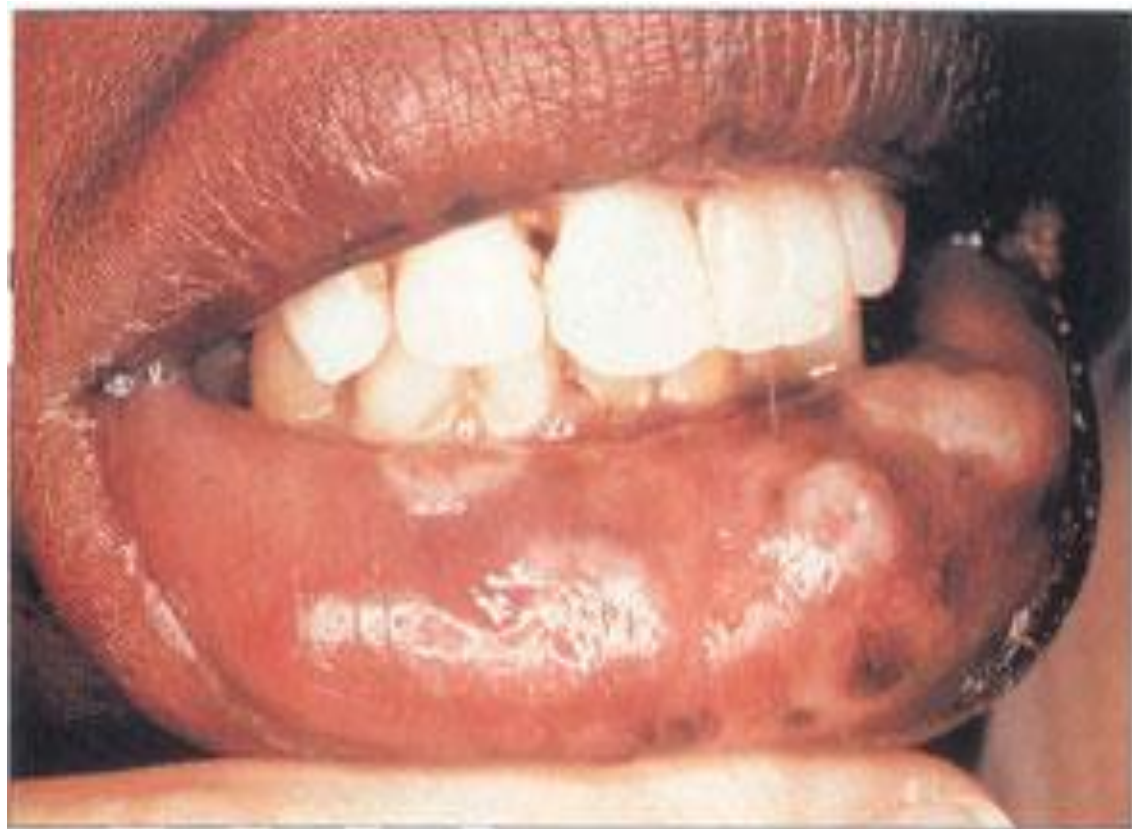- **Mucosal lesions:**

- **~ 30% of secondary syphilis patients develop mucous patch (slightly raised, oval area covered by a grayish white membrane, with a pink base that does not bleed).**
- **Highly infectious**



Alopecia areata





LATENT SYPHILIS

Positive syphilis serology without clinical signs of syphilis (& has normal CSF).

- It begins with the end of secondary syphilis and may last for a lifetime.
- Pt may or may not have a h/o primary or secondary syphilis.
- *Diseases known to cause occasional false-positive nontreponemal test reactions for syphilis, such as systemic lupus erythematosus (SLE), and congenital syphilis must be excluded before the diagnosis of latent syphilis can be made.*
- Is divided into early and late latency.

LATENT SYPHILIS

1. Early latent:

- **The first year after the resolution of primary or secondary lesions, or**
- **A reactive serologic test for syphilis in an asymptomatic individual who has had a negative serologic test within the preceding year.**
- **Infectious.**

2. Late latent:

- **Usually not infectious, *except for the pregnant woman, who may transmit infection to her fetus.***

LATE SYPHILIS

'Tertiary Syphilis'

- **Is the destructive stage of the disease.**
- **Lesions develop in skin, bone, & visceral organs (any organ).**
- **The main types are:**
 - **Late benign (gummatous)**
 - **Cardiovascular &**
 - **Neurosyphilis**
- **Can be crippling and life threatening**
- **Blindness, deafness, deformity, lack of coordination, paralysis, dementia may occur**
- **It is usually very slowly progressive, barring certain neurologic syndromes which may develop suddenly due to endarteritis and thrombosis in the CNS**
- **Late syphilis is noninfectious.**