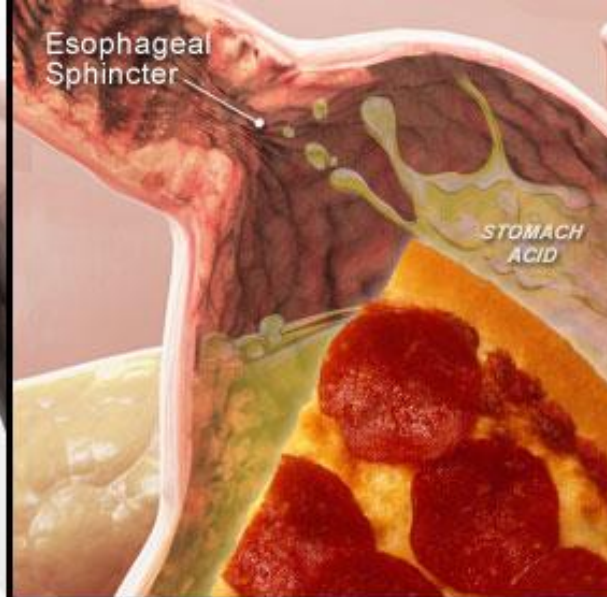
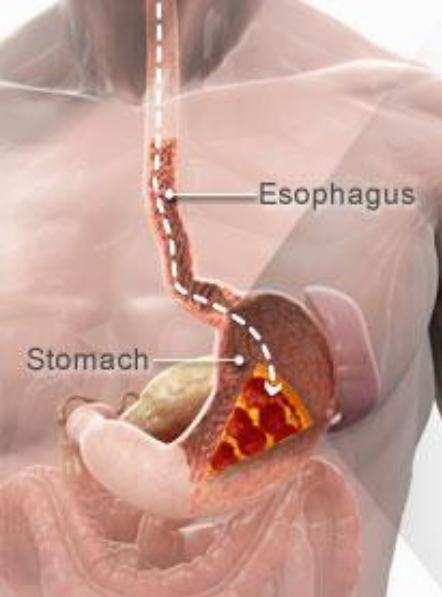
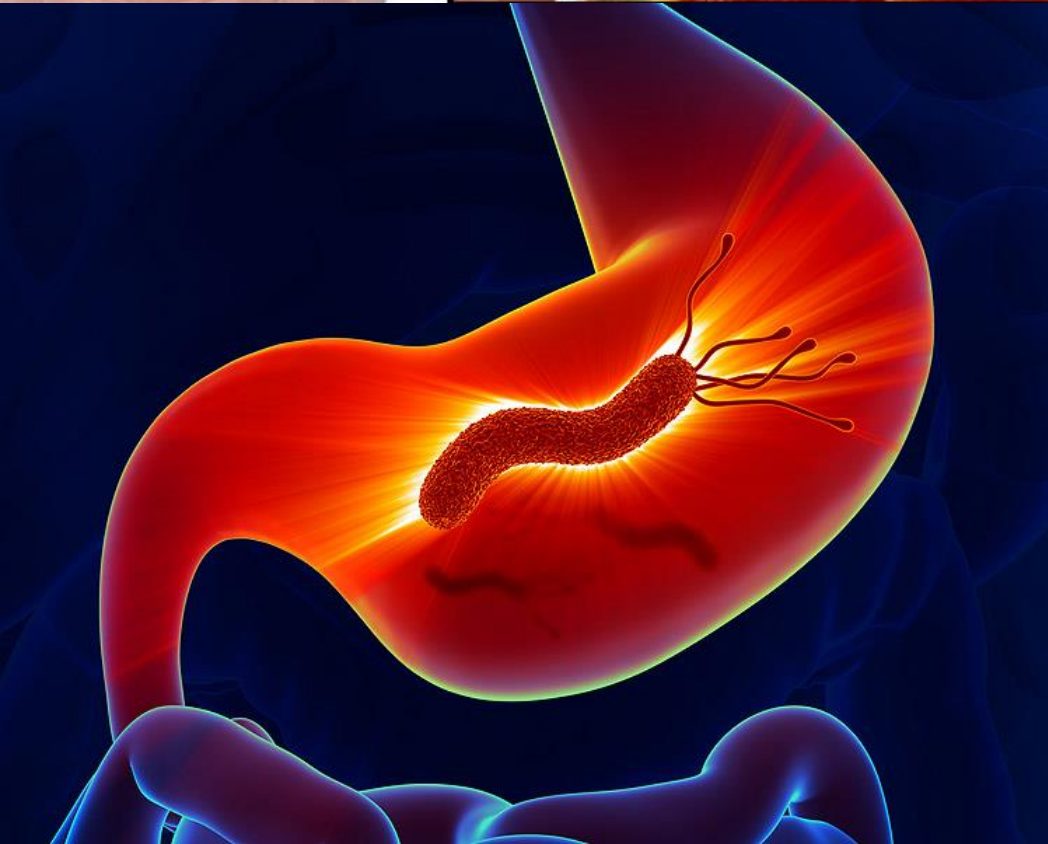**Patologia amigdalelor,
esofagului, stomacului.**

**Болезни зева и
глотки, пищевода и
желудка.**



**Pathology of tonsils,
esophagus, stomach.**

Tema: Patologia amigdalelor, esofagului, stomacului.

I. Micropreparate:

№ 176. Ulcer gastric acut. (*colorație H-E.*). Indicații:

1. Stratul superficial al fundului ulcerului, constituit din leucocite și eritrocite.
2. Mase necrotice și detritus tisular în regiunea fundului ulcerului.
3. Focare de necroză în stratul muscular al peretelui gastric.
4. Infiltrație leucocitară în marginile și fundul ulcerului.

№ 87. Ulcer gastric cronic în acutizare. (*colorație H-E.*). Indicații:

1. Marginea distală (“în terasă”) a ulcerului.
2. Marginea proximală, (“săpată”) a ulcerului.
3. Fundul ulcerului:
 - a. stratul fibrino-purulent;
 - b. stratul de necroză fibrinoidă;
 - c. stratul de țesut de granulație;
 - d. stratul de țesut fibroconjunctiv cicatriceal

№ 192. Adenocarcinom gastric tubular – de tip intestinal. (*colorație H-E.*). Indicații:

1. Aglomerări de celule canceroase în mucoasa gastrică.
2. Structuri canceroase glandulare în grosimea stratului muscular
3. Zone nemodificate ale mucoasei.

№ 192a. Metastază de carcinom gastric în ganglion limfatic. (*colorație H-E.*). Indicații:

1. Aglomerări de celule canceroase în sinusurile marginal și medular ale limfoganglionului.
2. Foliculi limfoizi nemodificați.

II. Macropreparate:

№ 59. Carcinom esofagian.

№ 51. Polip gastric.

№ 52. Ulcer gastric cronic.

№ 53. Ulcer gastric cronic perforant.

№ 54. Ulcer duodenal cronic.

№ 60. Carcinom gastric.

Тема: Болезни зева и глотки, пищевода и желудка.

I. Микропрепараты:

№ 176. Острая язва желудка. (Окраска Г-Э.). Обозначения:

1. Поверхностный слой дна язвы, состоящий из лейкоцитов и эритроцитов.
2. Некротические массы и тканевой детрит в области дна язвы.
3. Очаги некроза мышечного слоя стенки желудка.
4. Лейкоцитарная инфильтрация в области краев и дна язвы.

№ 87. Хроническая язва желудка в стадии обострения. (Окраска Г-Э.) Обозначения:

1. Дистальный (*пологий*) край язвы.
2. Проксимальный (*подрытый*) край язвы.
3. Дно язвы:
 - а. фибринозно-гнойный экссудат;
 - б. некротический слой;
 - в. грануляционная ткань;
 - г. грубоволокнистая рубцовая ткань.

№ 192. Тубулярная аденокарцинома желудка – кишечный тип. (Окраска Г-Э.) Обозначения:

1. Скопления атипичных раковых клеток в слизистой оболочке.
2. Железистые раковые структуры в толще мышечного слоя.
3. Неизмененные зоны слизистой оболочки.

№ 192а. Метастаз рака желудка в лимфатический узел. (Окраска Г-Э.) Обозначения:

1. Скопления раковых клеток в краевом и мозговых синусах лимфоузла.
2. Неизмененные лимфоидные фолликулы.

II. Макропрепараты:

№ 59. Рак пищевода.

№ 51. Полип желудка.

№ 52. Хроническая язва желудка.

№ 53. Перфоративная хроническая язва желудка.

№ 54. Хроническая язва 12-перстной кишки.

№ 60. Рак желудка.

Pathology of tonsils, esophagus, stomach.

I. Microspecimens:

№ 176. Acute gastric ulcer. (*H.E. stain*). **Indications:**

1. The superficial layer of the ulcer, consisting of leukocytes and erythrocytes.
2. Necrotic masses and tissue debris in the area of the ulcer.
3. Foci of necrosis in the muscular layer of the gastric wall.
4. Leukocyte infiltration in the edges and bottom of the ulcer.

№ 87. Active chronic gastric ulcer. (*H.E. stain*). **Indications:**

1. The distal edge of the ulcer.
2. The proximal edge of the ulcer.
3. The ulcer base:
 - a. zone of necrotic fibrinoid debris;
 - b. zone of infiltration with neutrophils;
 - c. zone of granulation tissue;
 - d. zone of fibrous, collagenous scar.

№ 192. Gastric tubular adenocarcinoma – intestinal type. (*H.E. stain*). **Indications:**

1. Agglomerations of cancer cells in the gastric mucosa.
2. Cancerous glandular structures in the thickness of the muscular layer.
3. Unmodified mucosal areas.

№ 192a. Metastasis of gastric carcinoma into lymph node. (*H.E. stain*). **Indications:**

1. Agglomerations of cancer cells in the marginal and medullary sinuses of lymph node.
2. Unmodified lymphoid follicles.

II. Macrospecimens:

№ 59. Esophageal carcinoma.

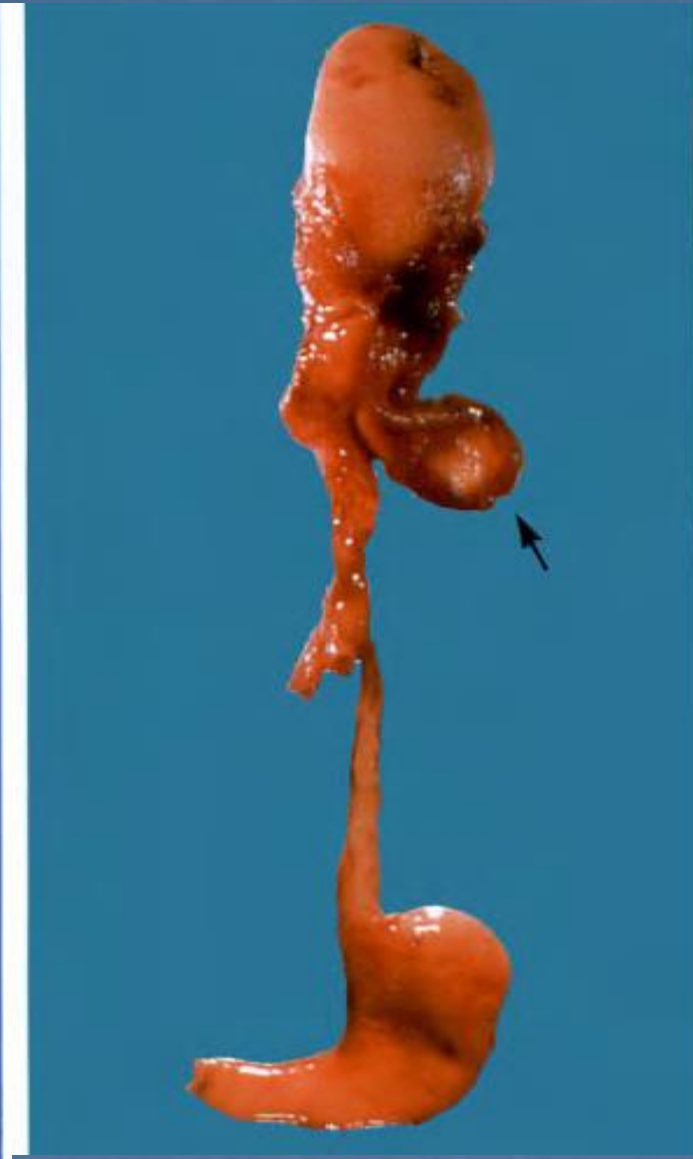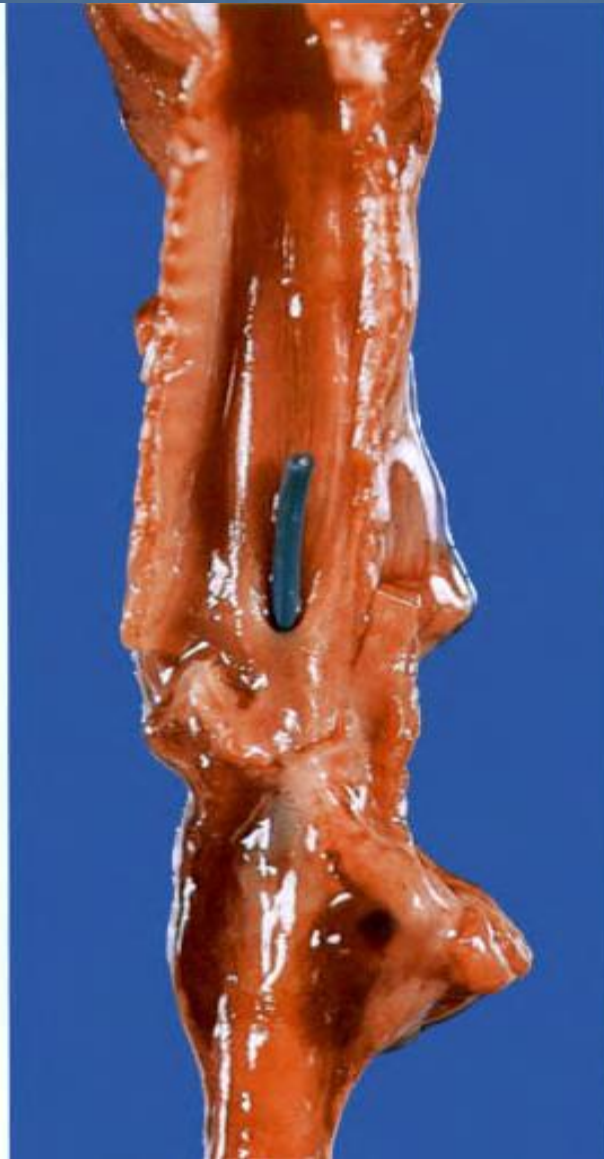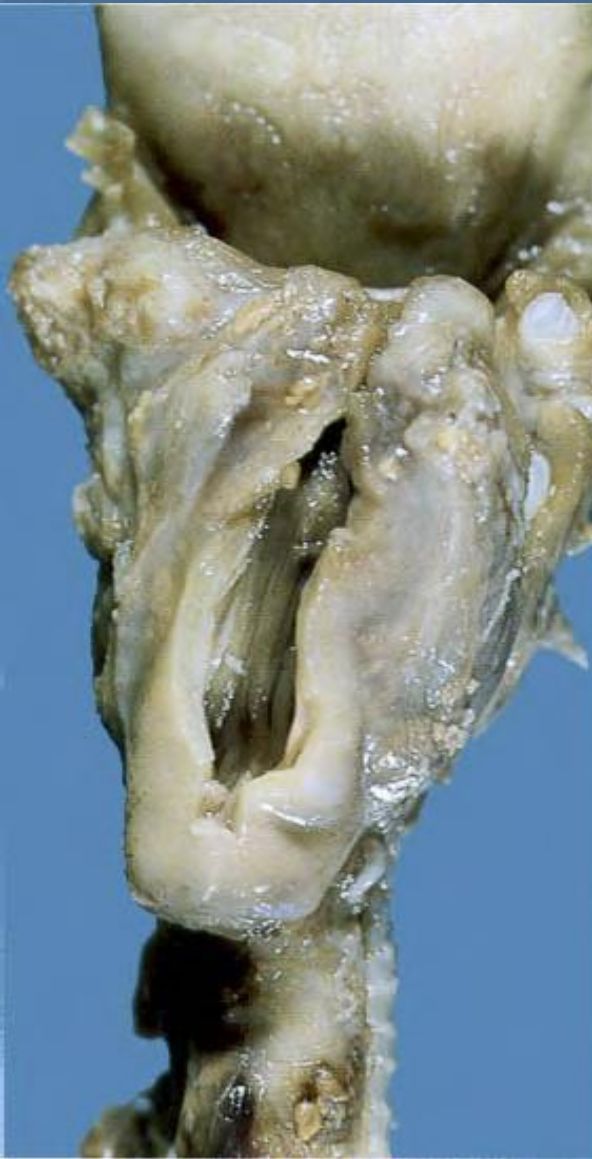№ 51. Gastric polyp.

№ 52. Chronic gastric ulcer.

№ 53. Chronic gastric ulcer with perforation.

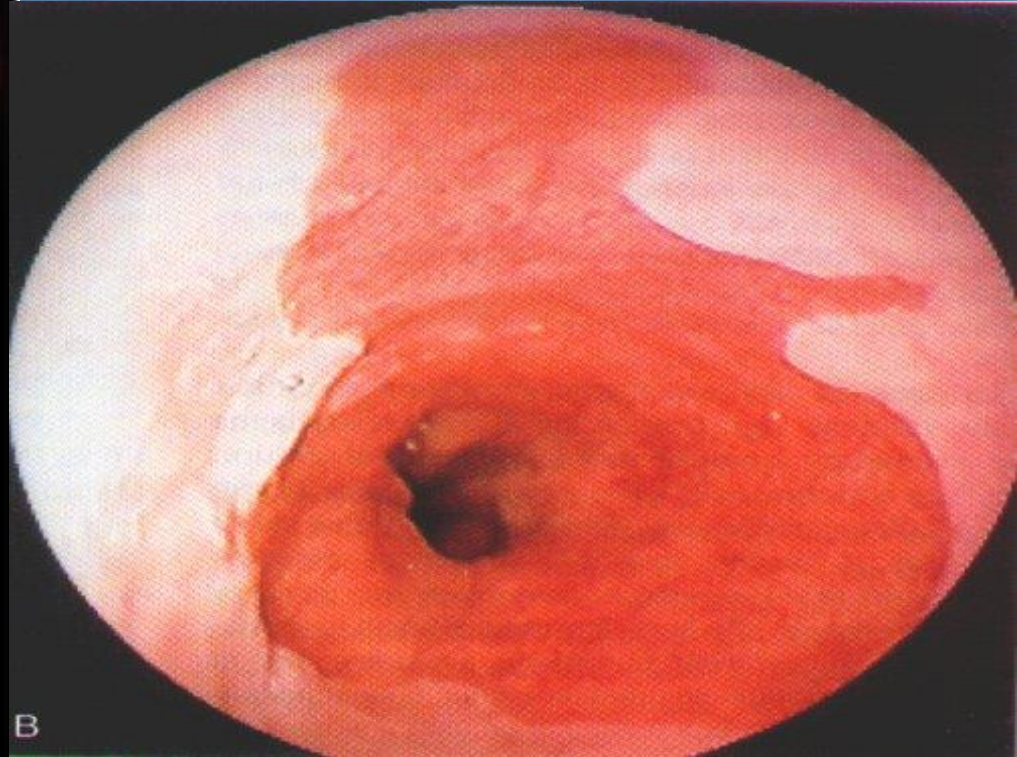
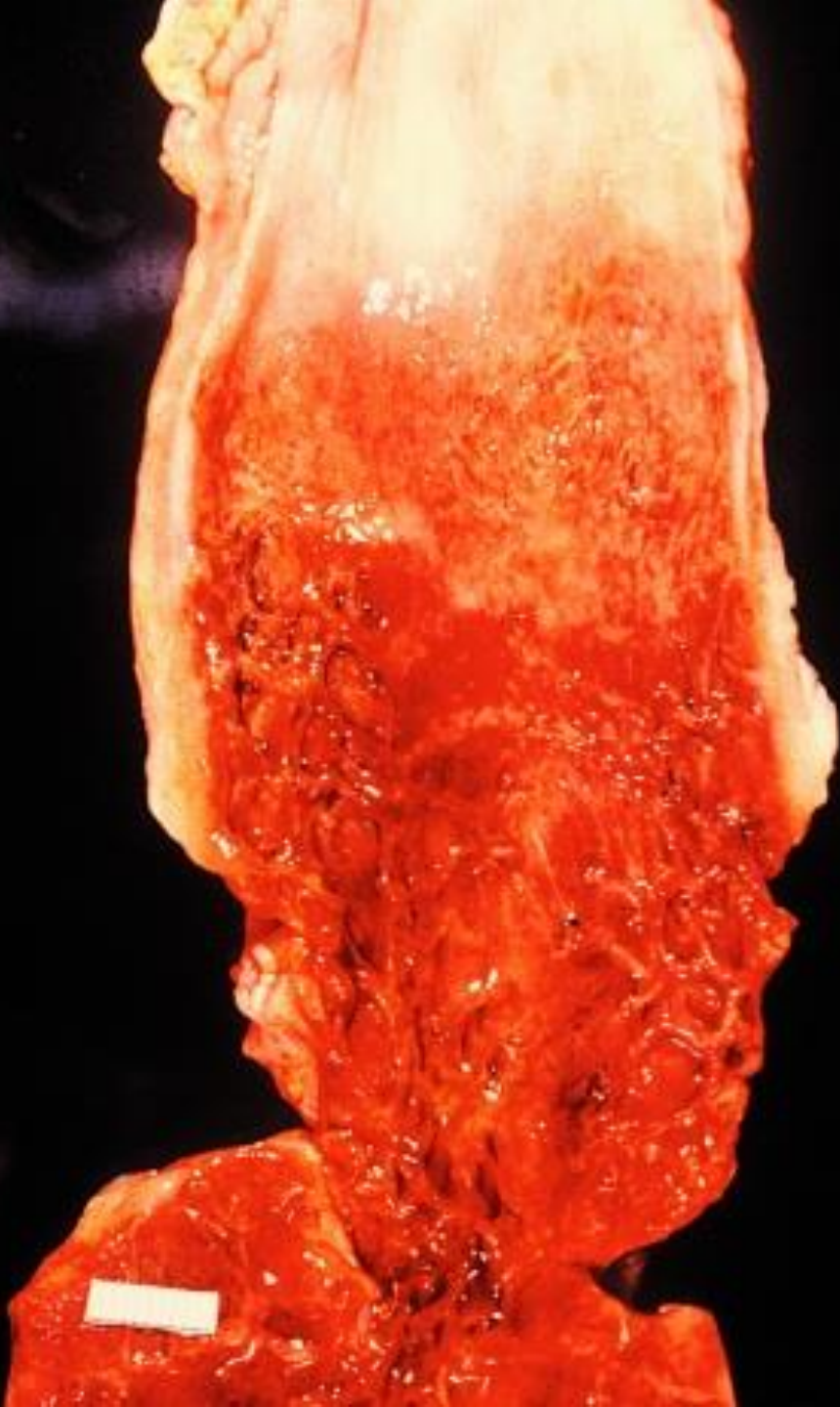№ 54. Chronic duodenal ulcer.

№ 60. Gastric adenocarcinoma.

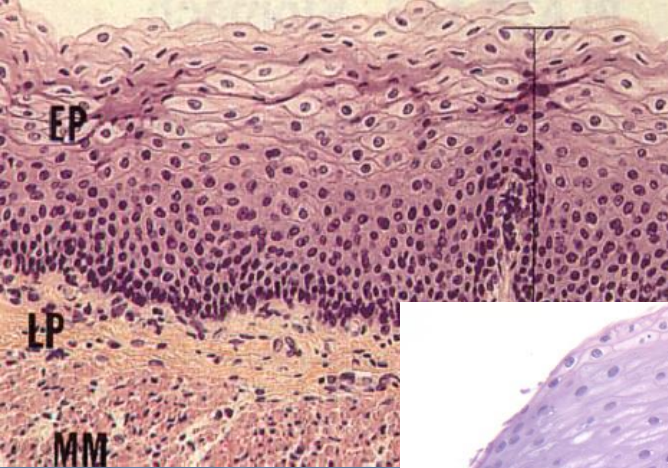


Anomalii de dezvoltare a esofagului (atrezia esofagiană, fistule esofagotraheale).

**Esofagita de reflux: tablou
macroscopic și endoscopic.**



Morfopatogeneza adenocarcinomului esofagian.



Reflux
Esofagita.

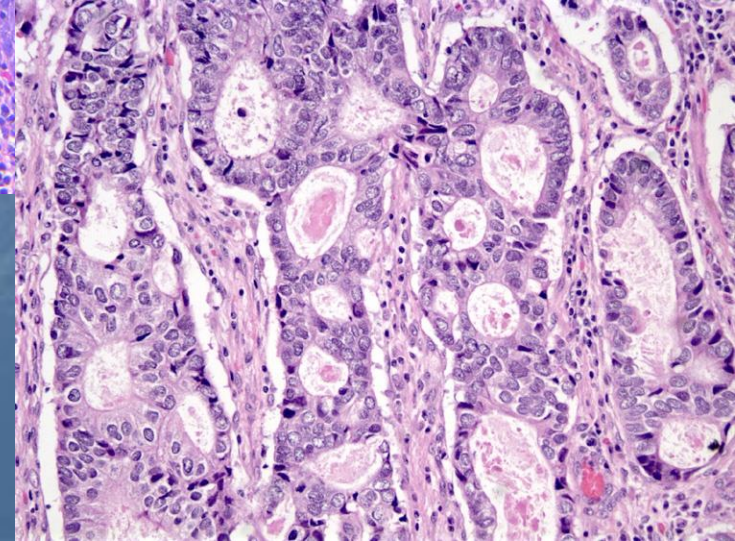
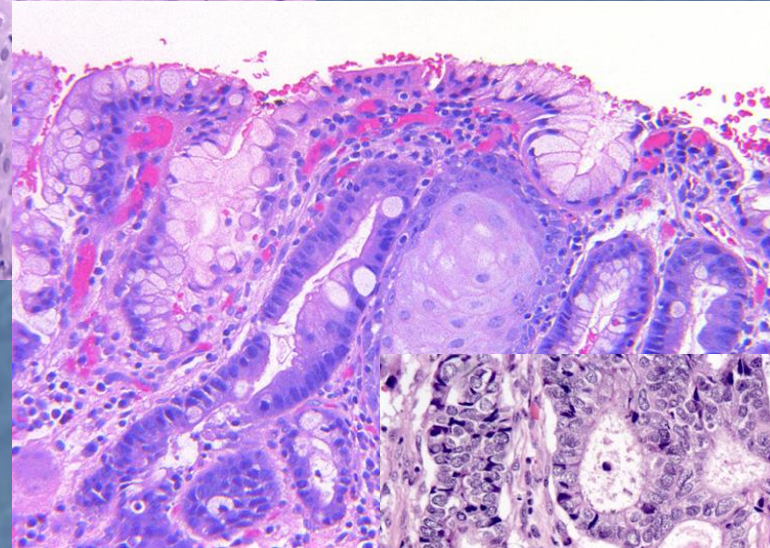
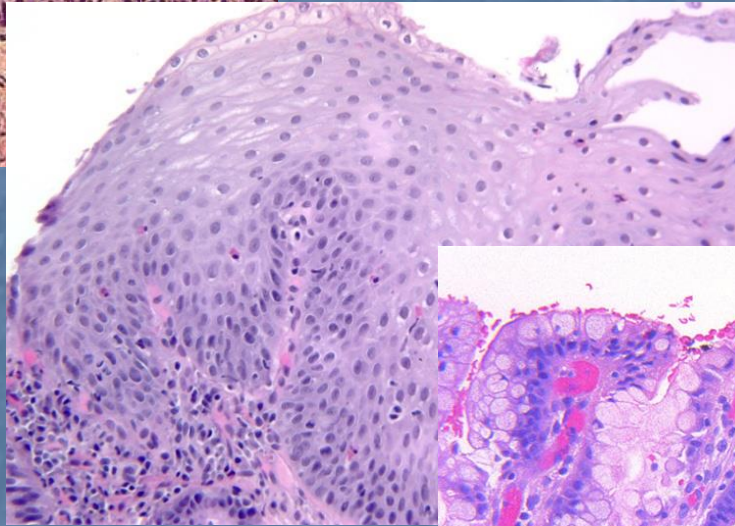


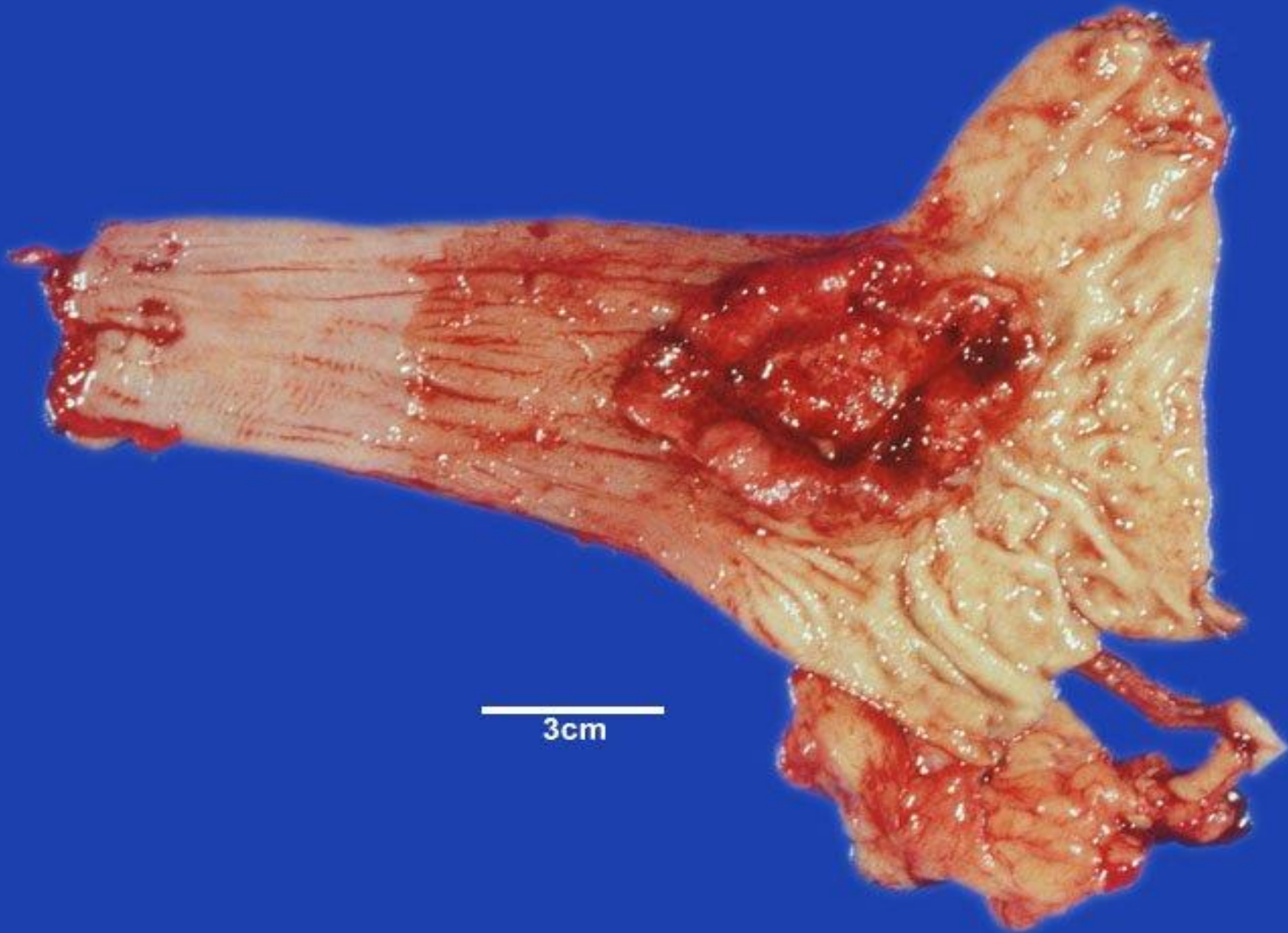
Esofagul
Barrett
(tip intestinal).



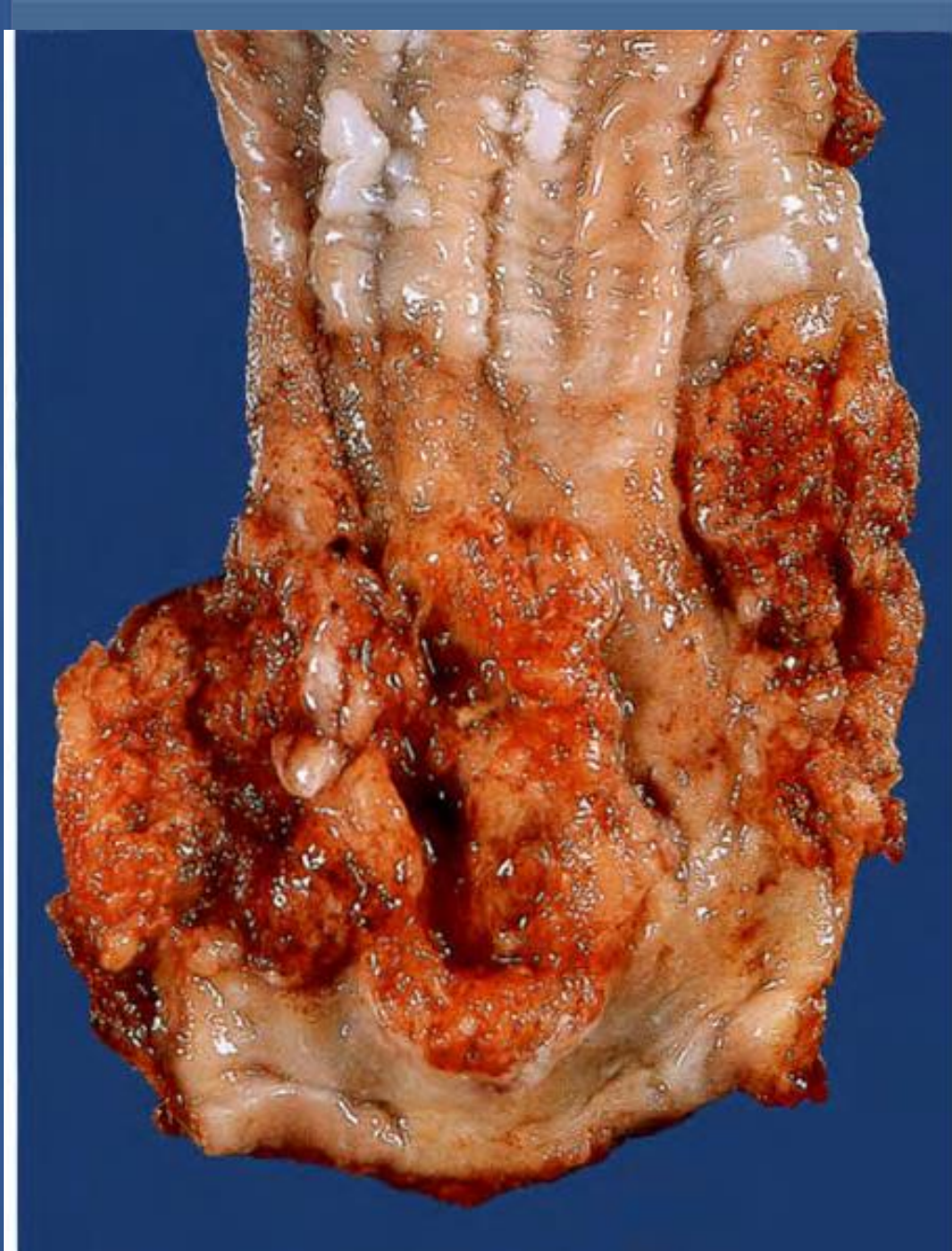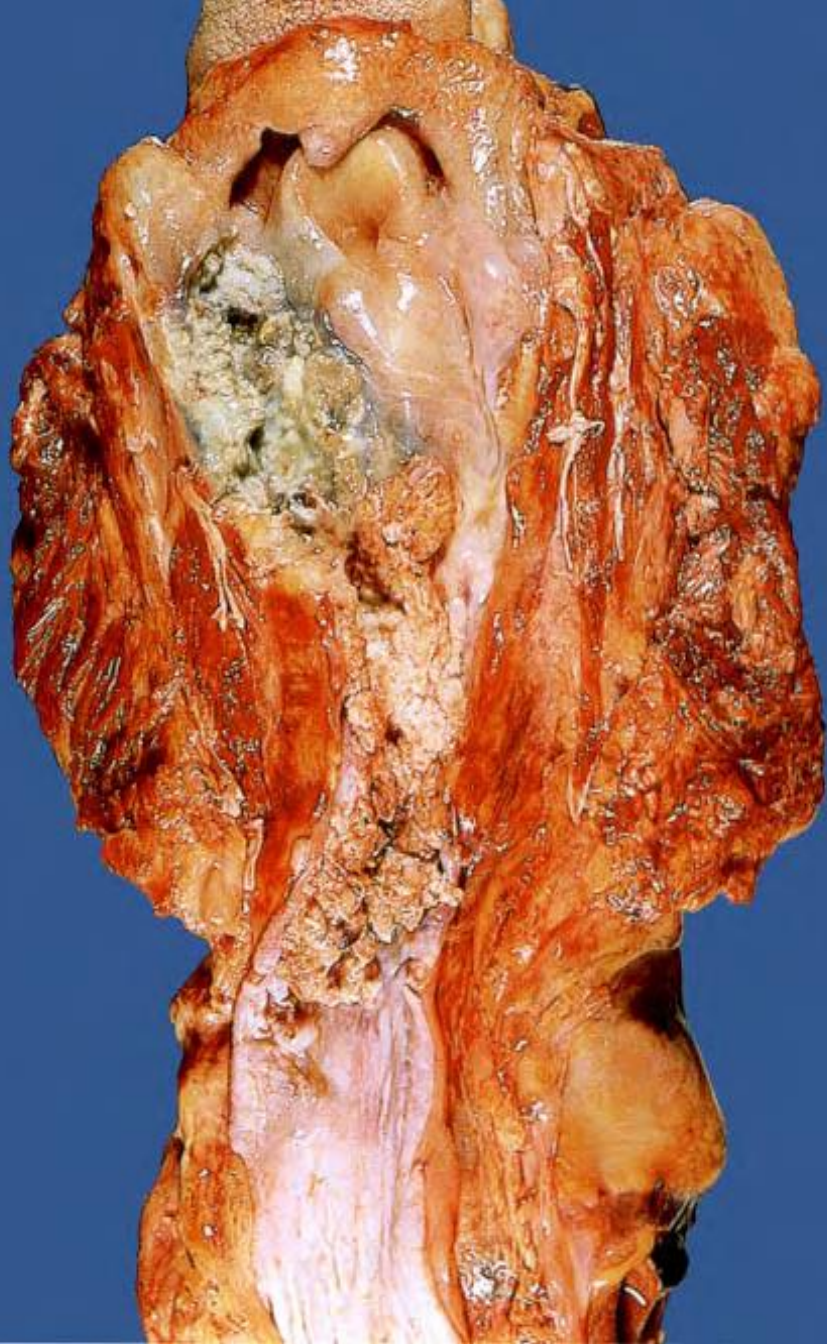Barrett cu displazie
(carcinom in-situ).

Adenocarcinom invaziv.

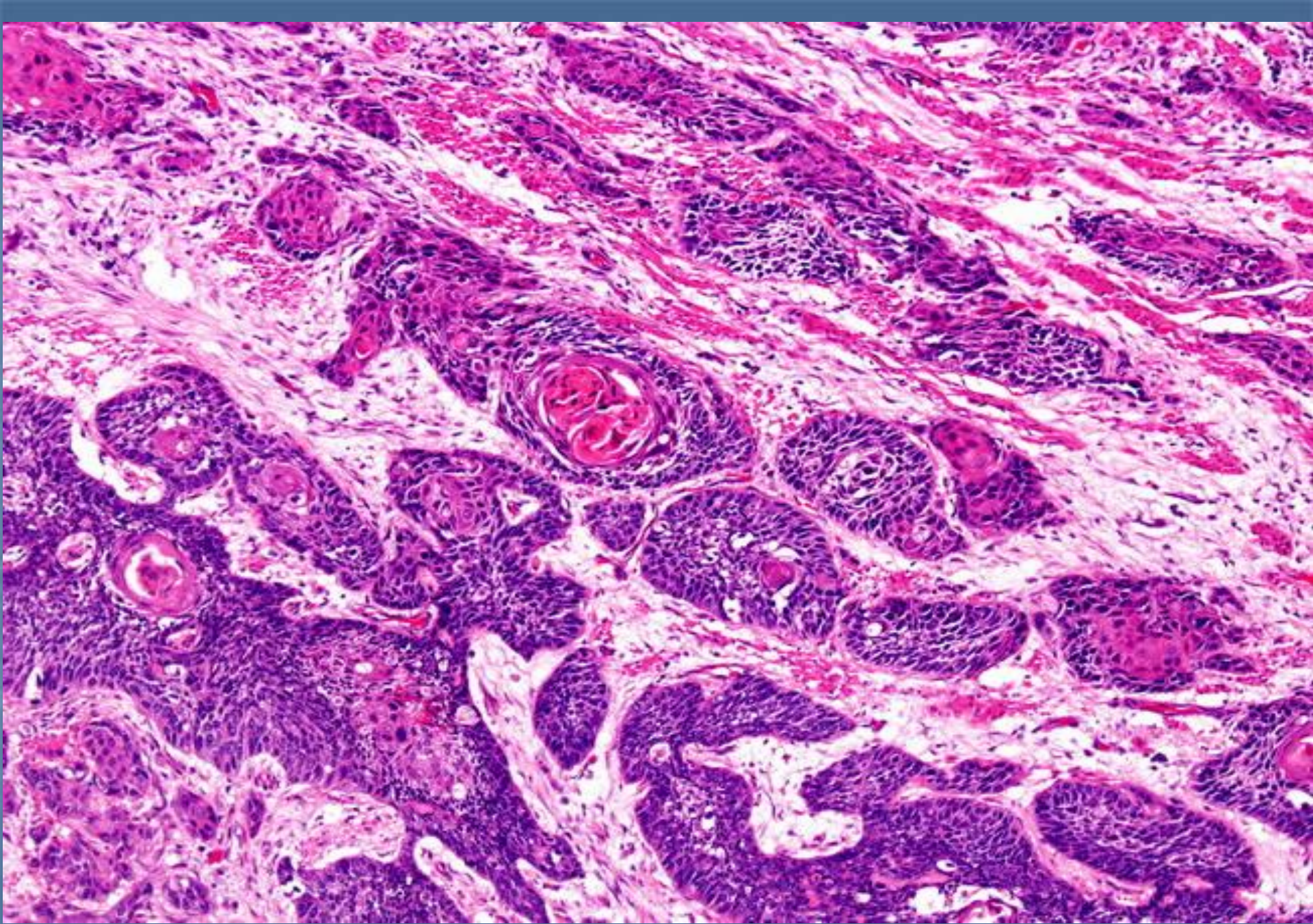




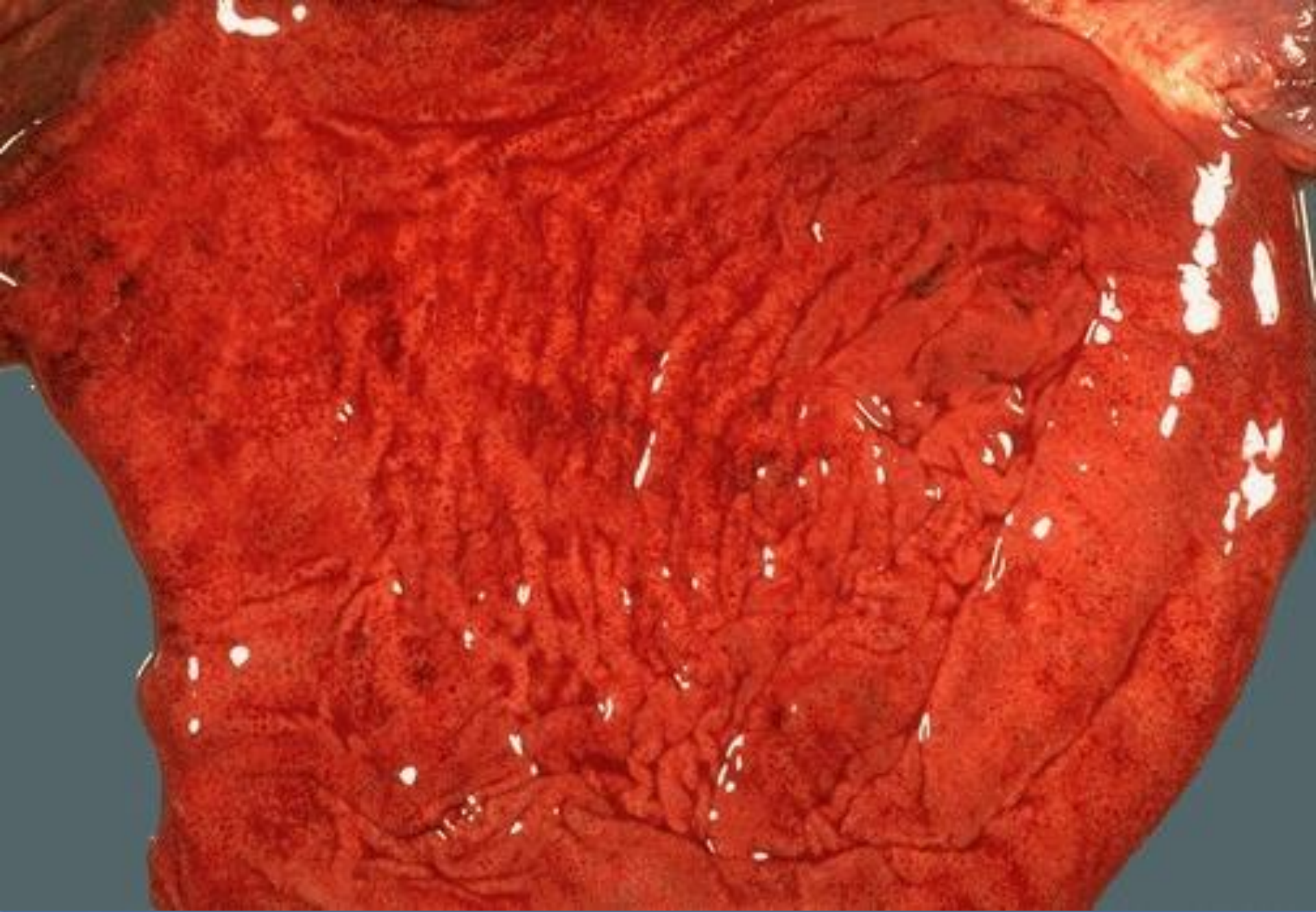
Adenocarcinom esofagian.



Carcinom scuamos esofagian.

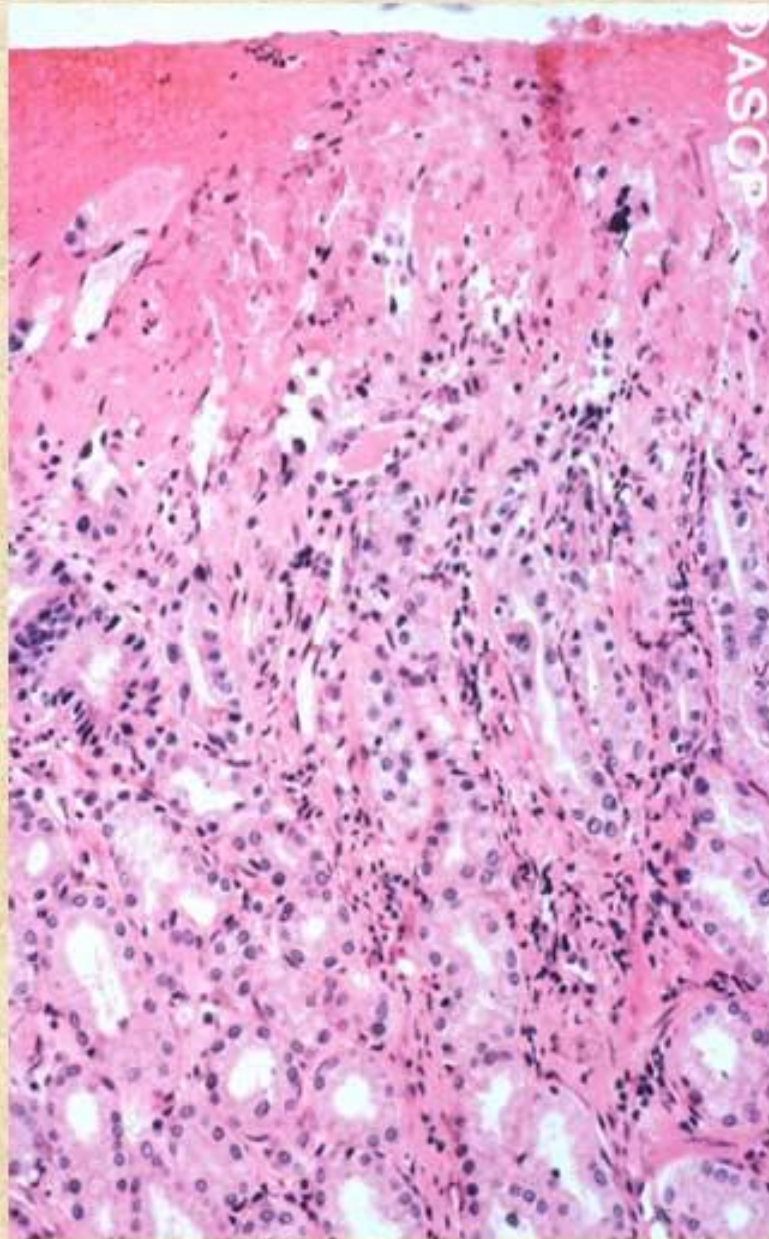


Carcinom scuamos cheratinizat esofagian.

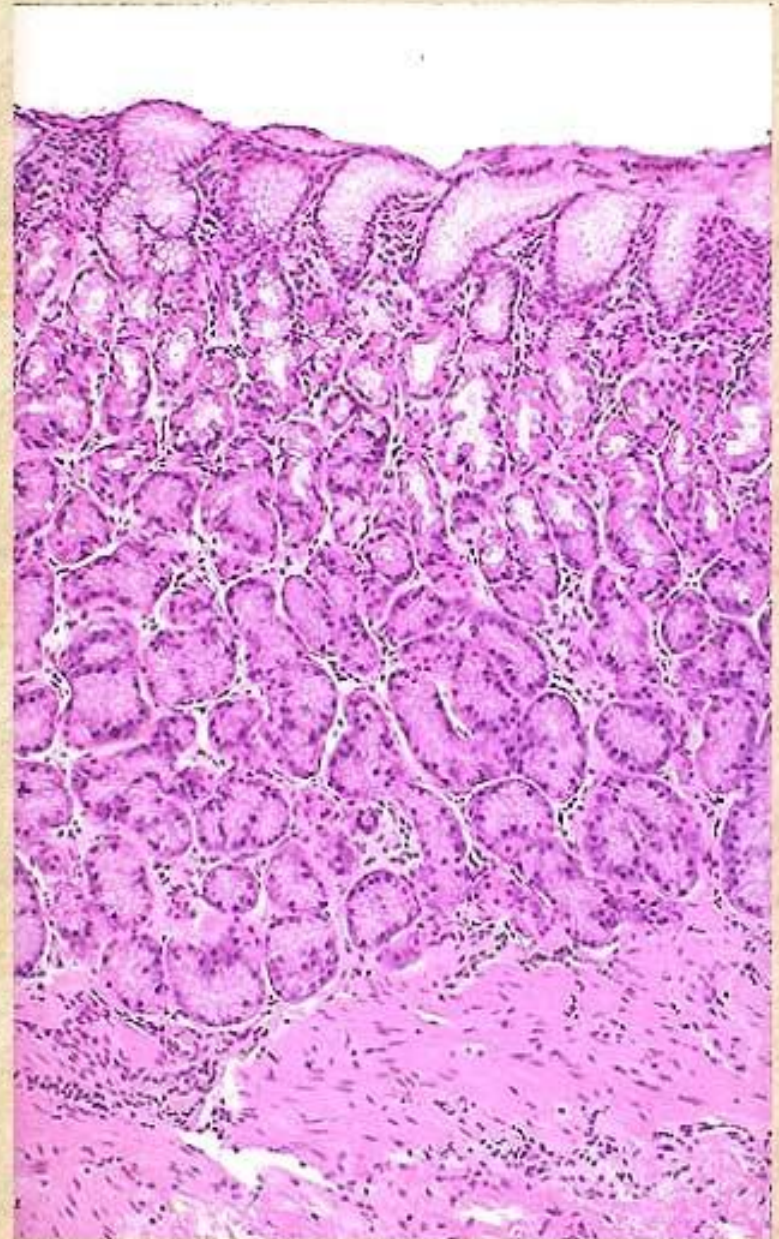


Gastrita acută.

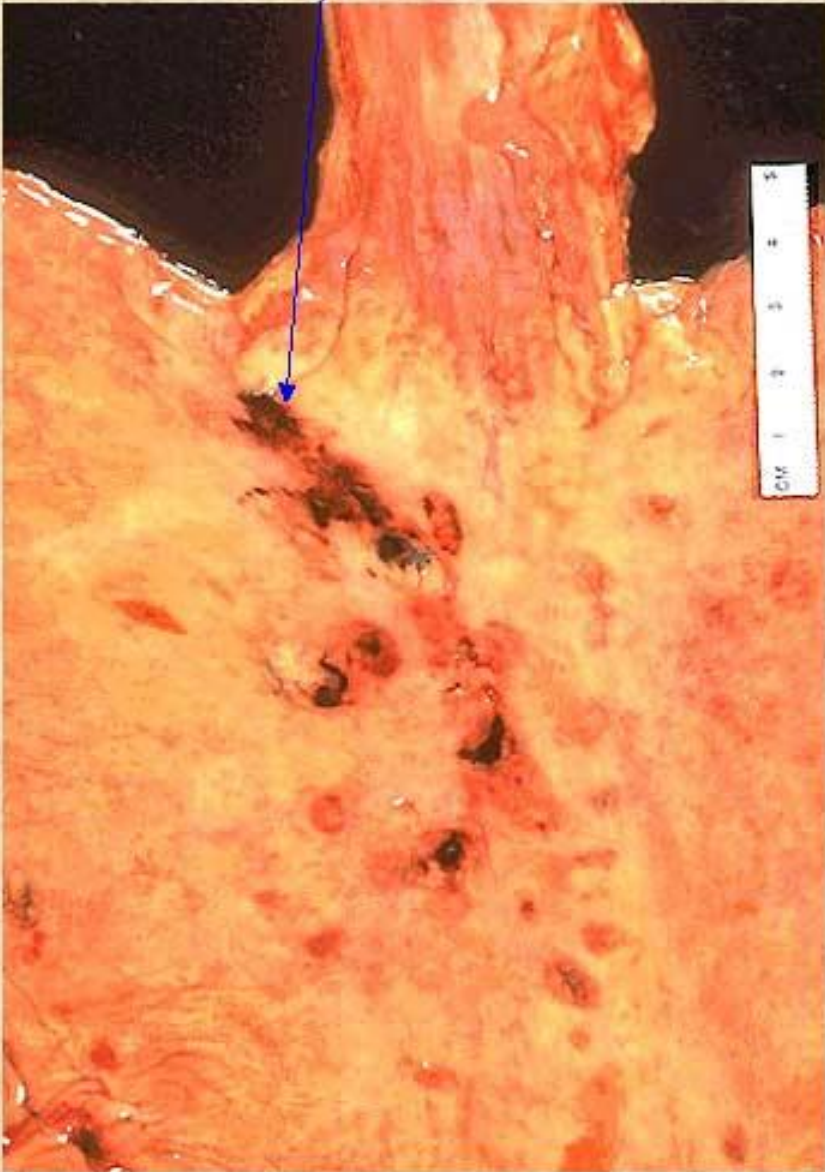
Acute erosive gastritis



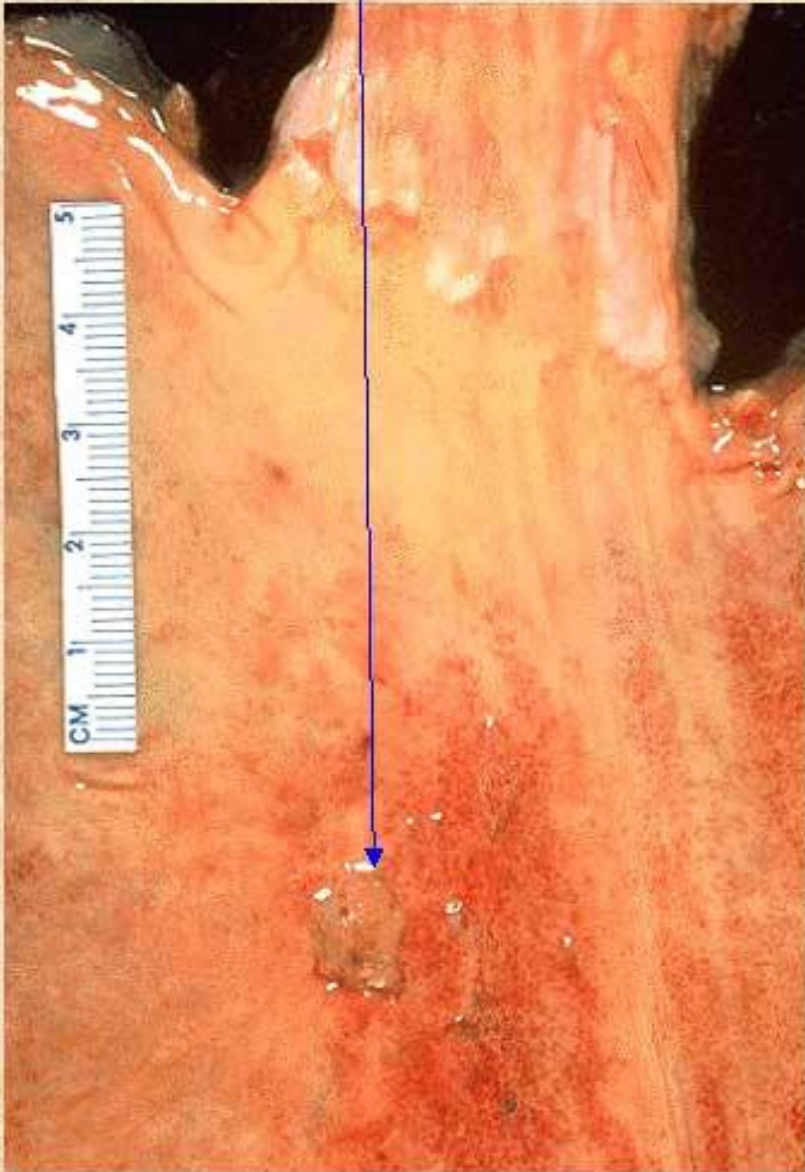Normal fundus



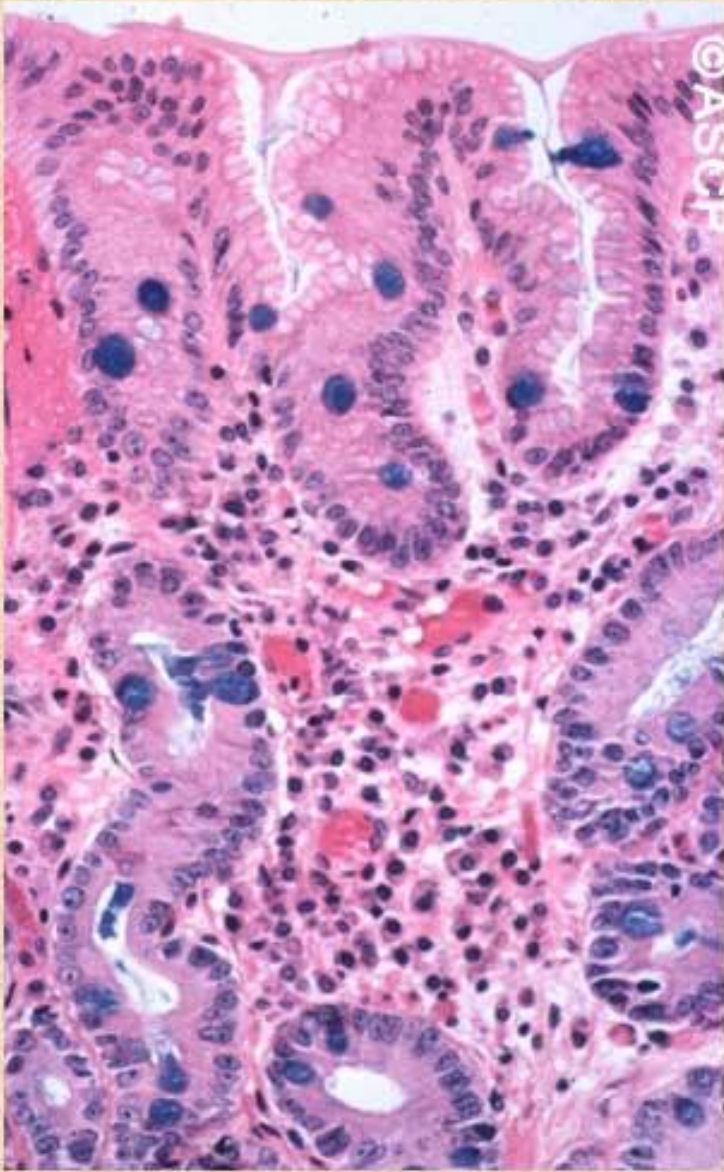
Acute erosion



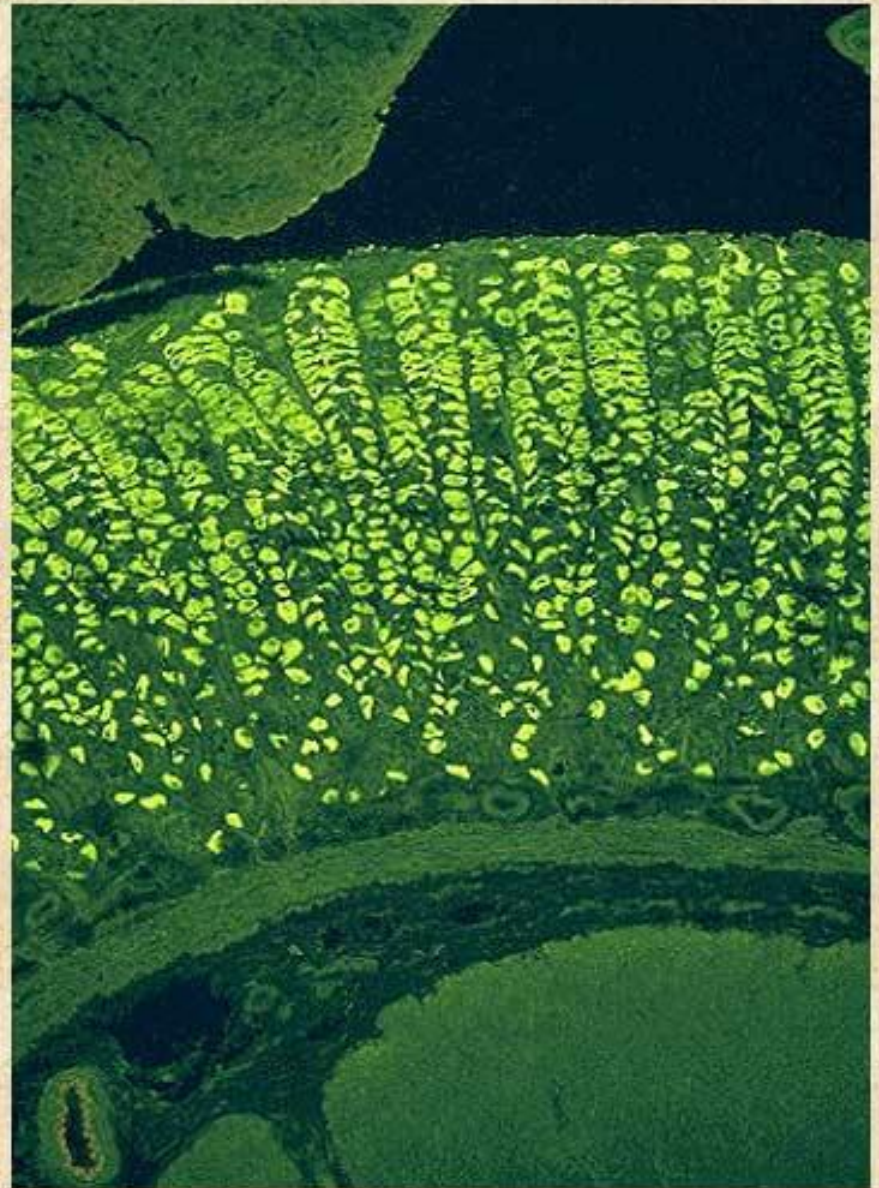
Acute ulcer



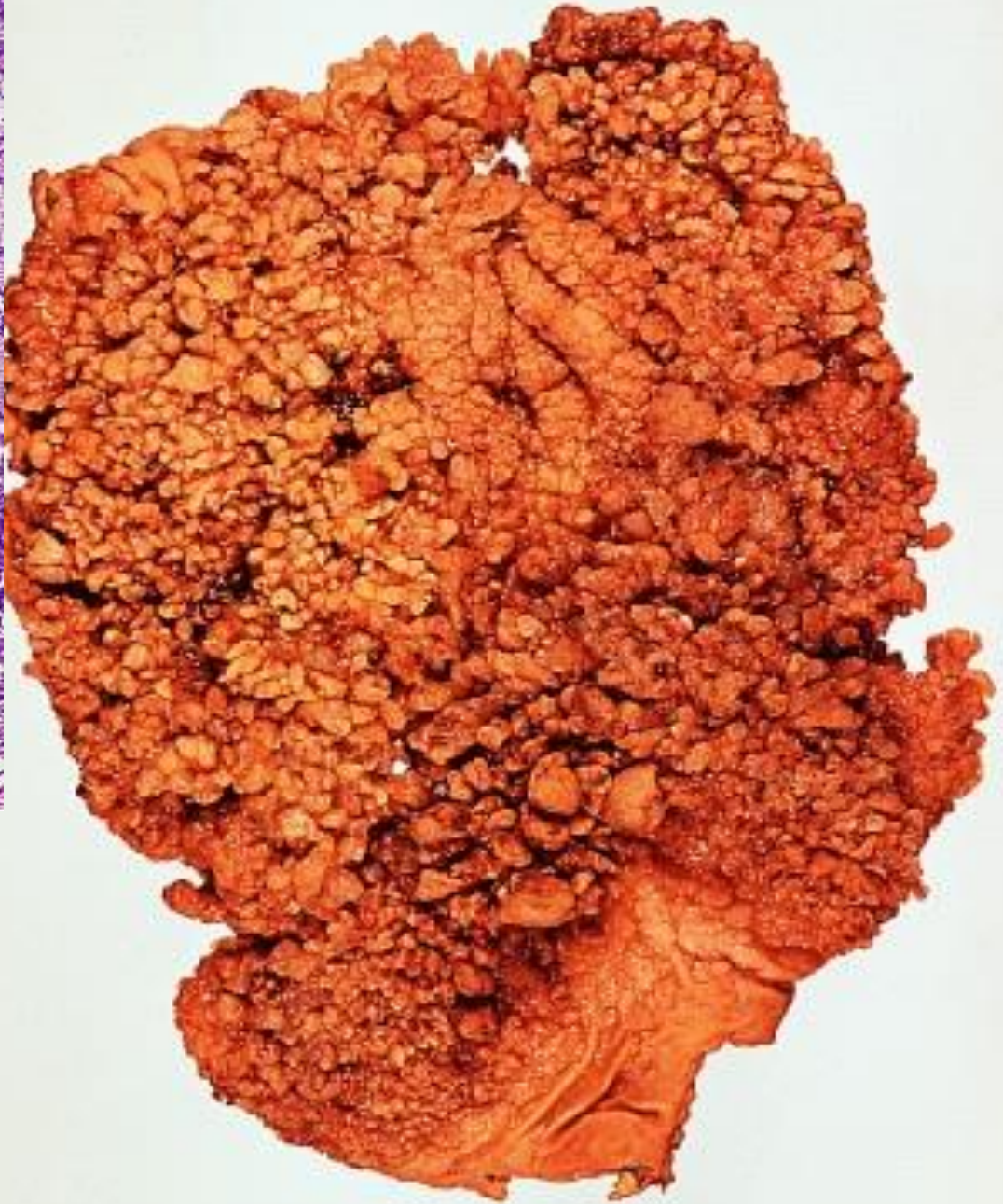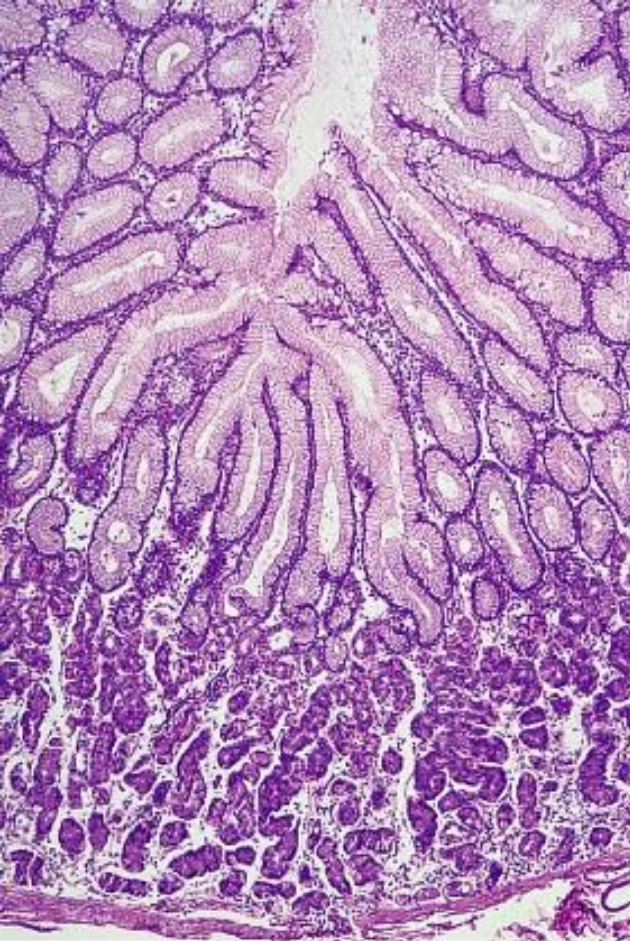
Autoimmune chronic gastritis



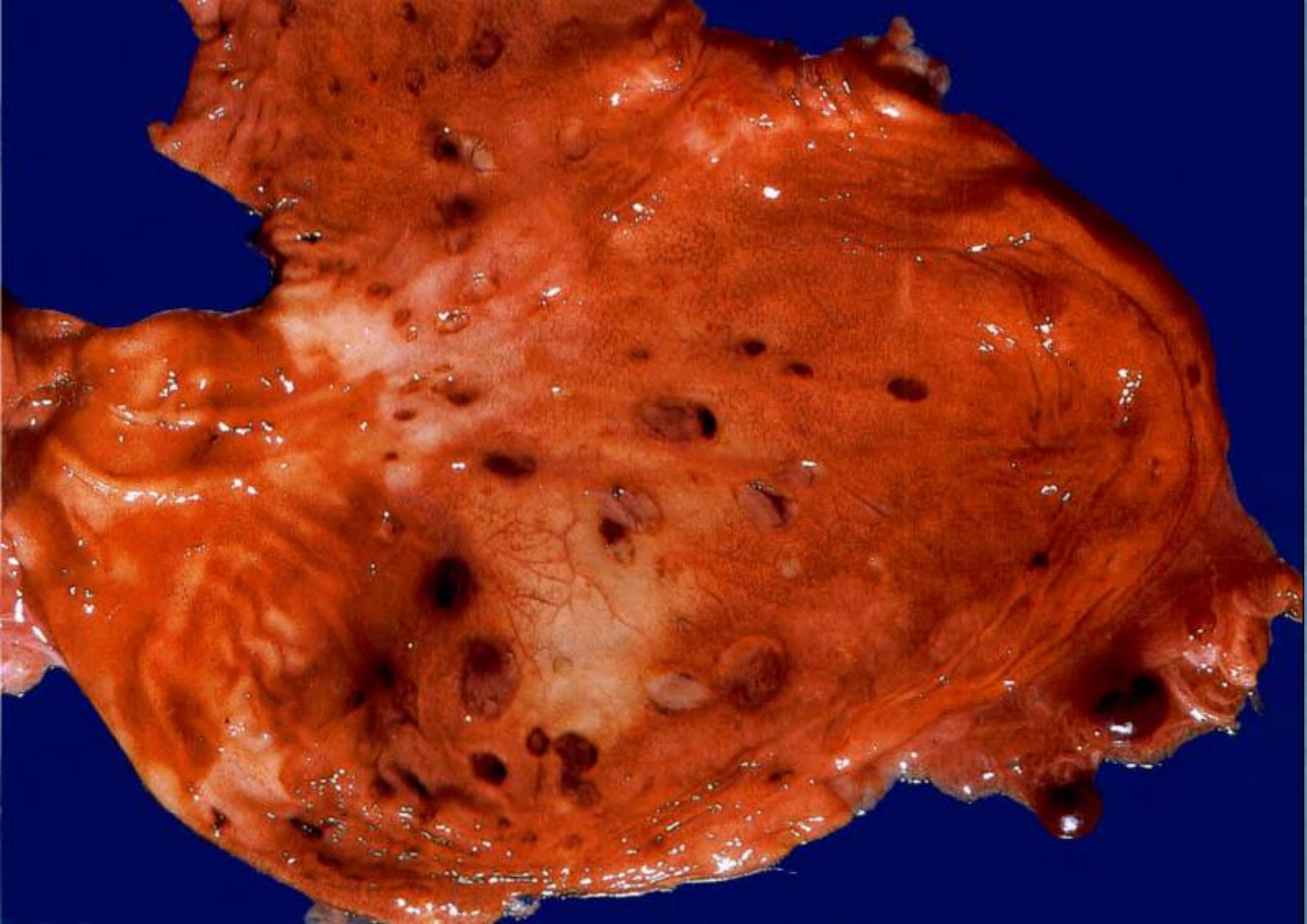
H & E



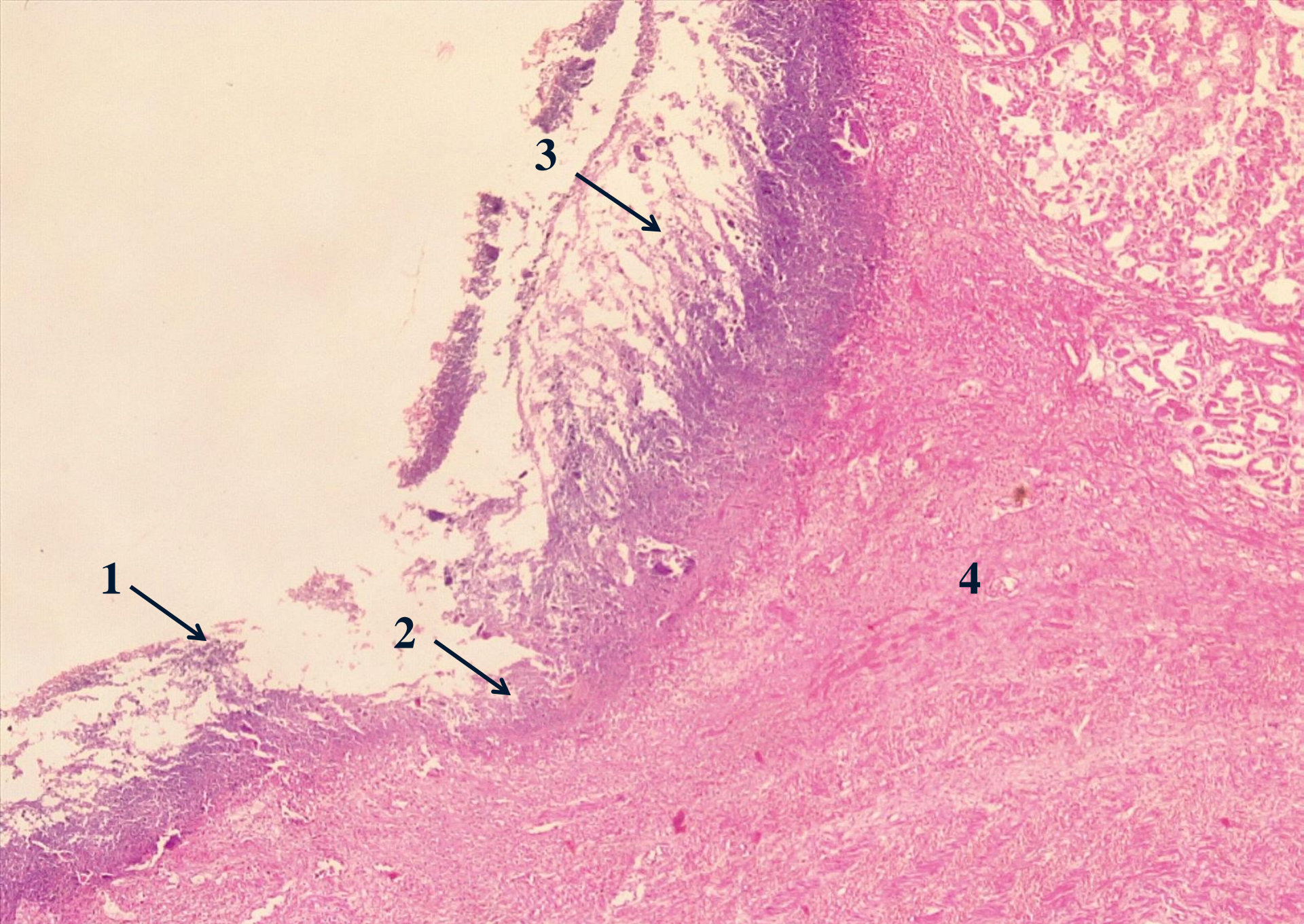
IF Anti-parietal cell Ab



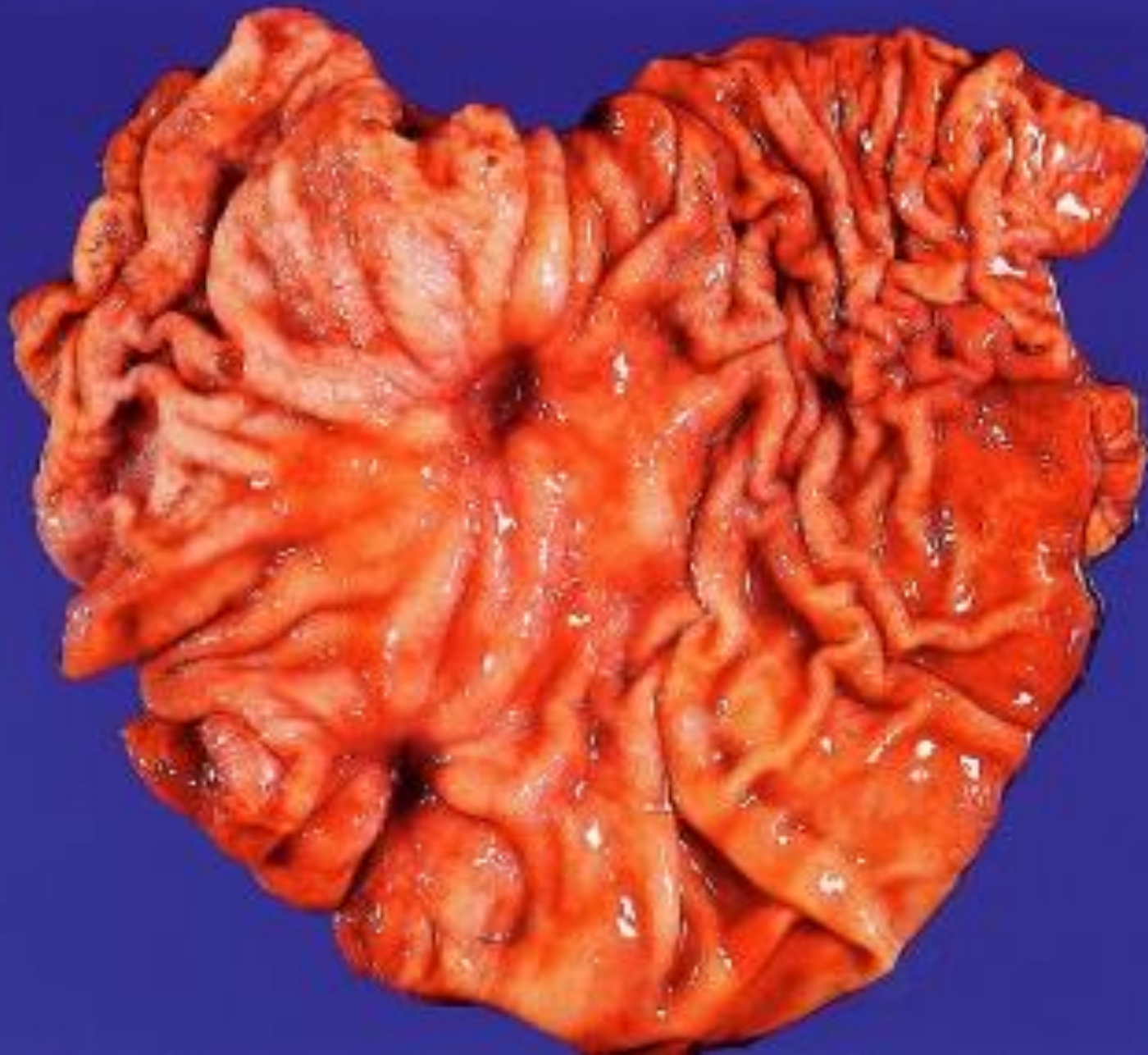**GASTRITA
MENETRIER.**



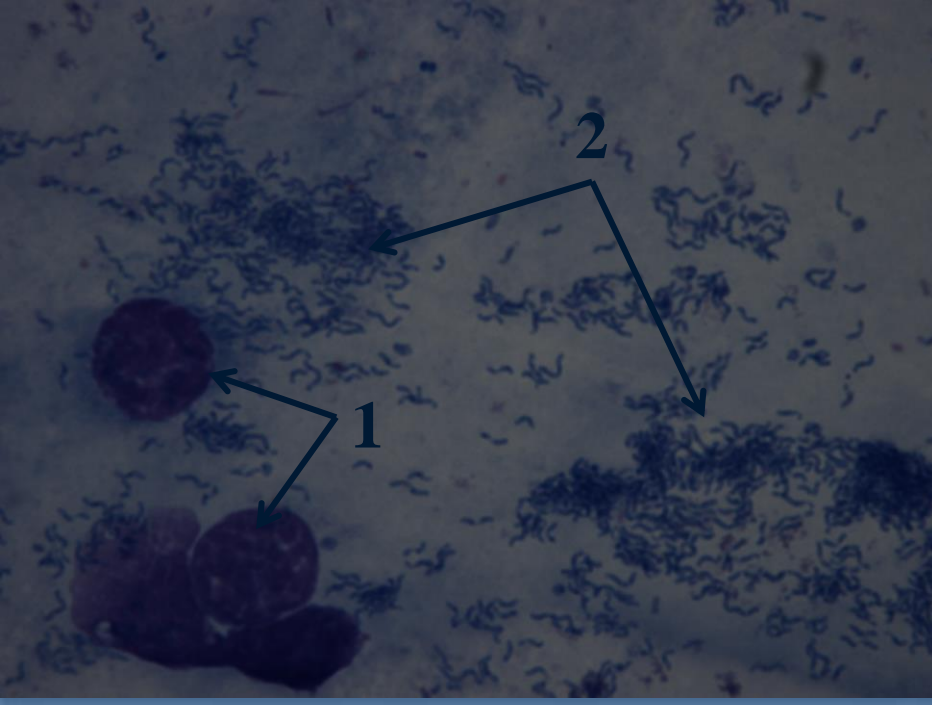
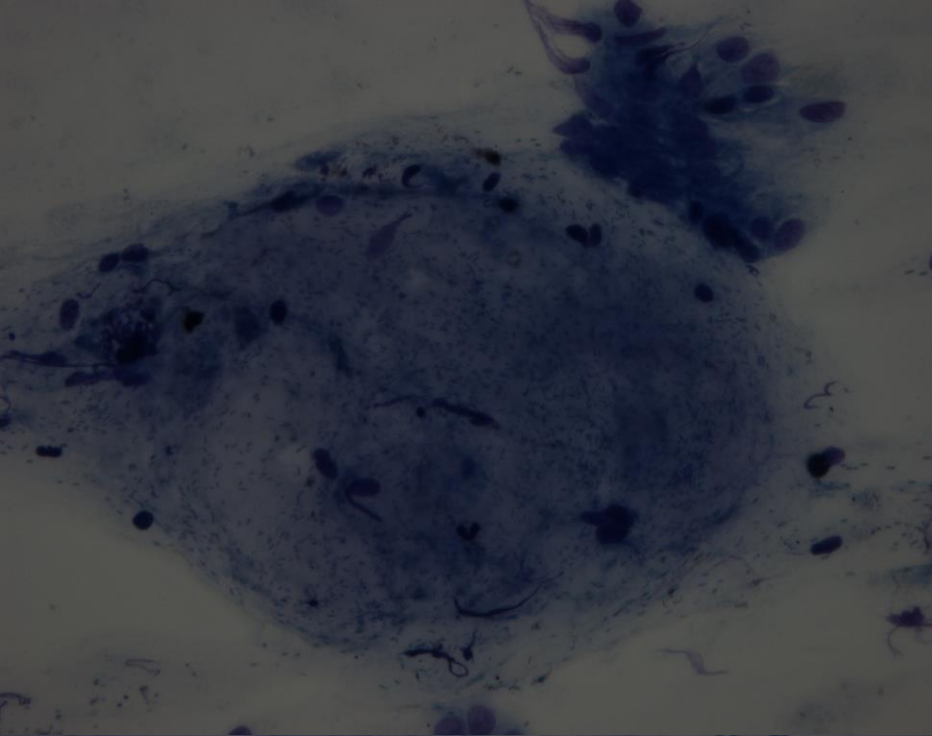
Eroziuni acute gastrice.



No 176. Ulcer gastric acut. (colorație H-E).

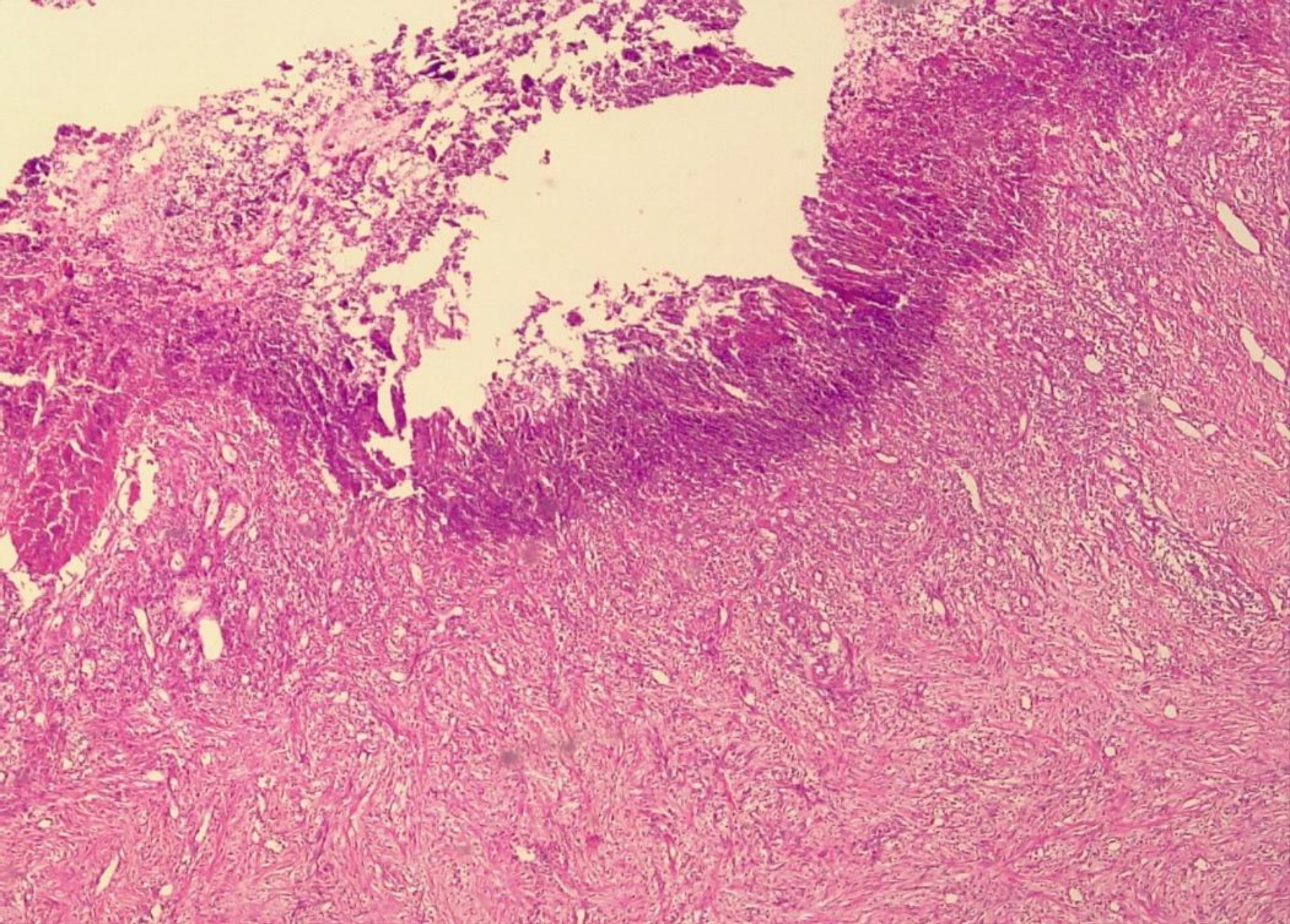


Ulcer gastric cronic în acutizare.

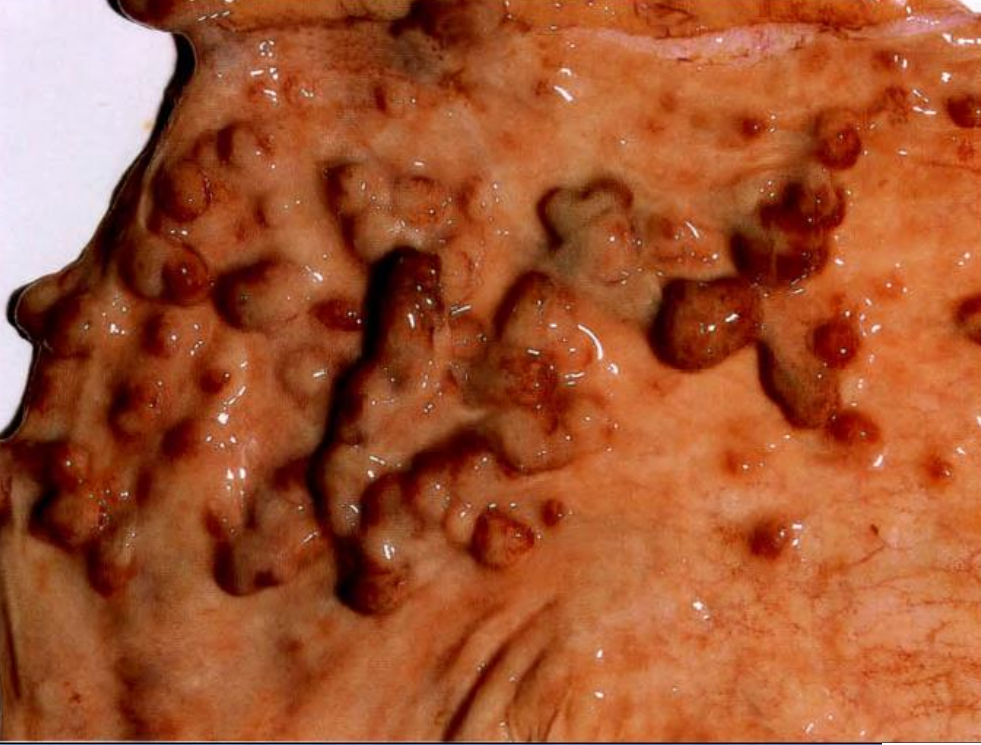

Citologia mucoasei gastrice (frotiu).

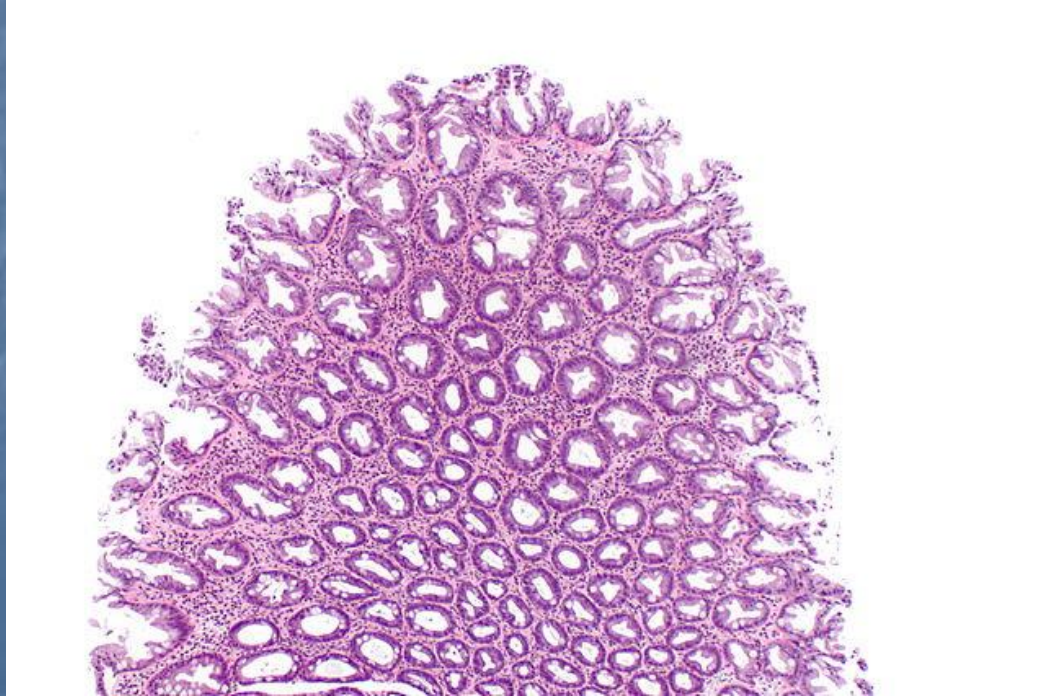
- 1. Celule principale.**
- 2. Helicobacter pylori.**

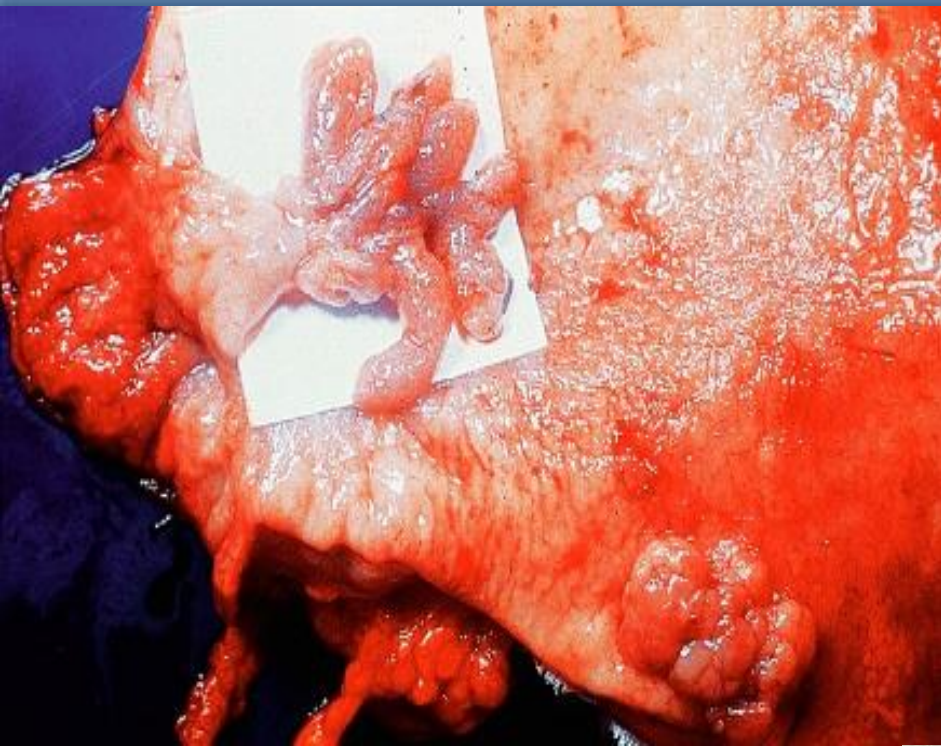

№ 87. Ulcer gastric cronic în acutizare. (colorație H-E.).

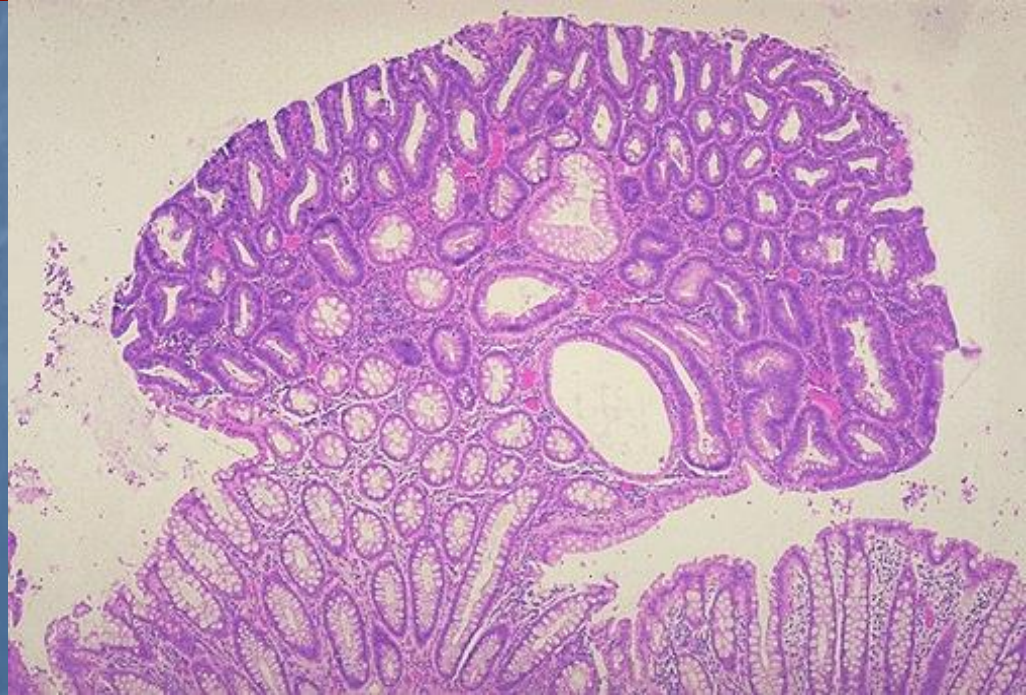


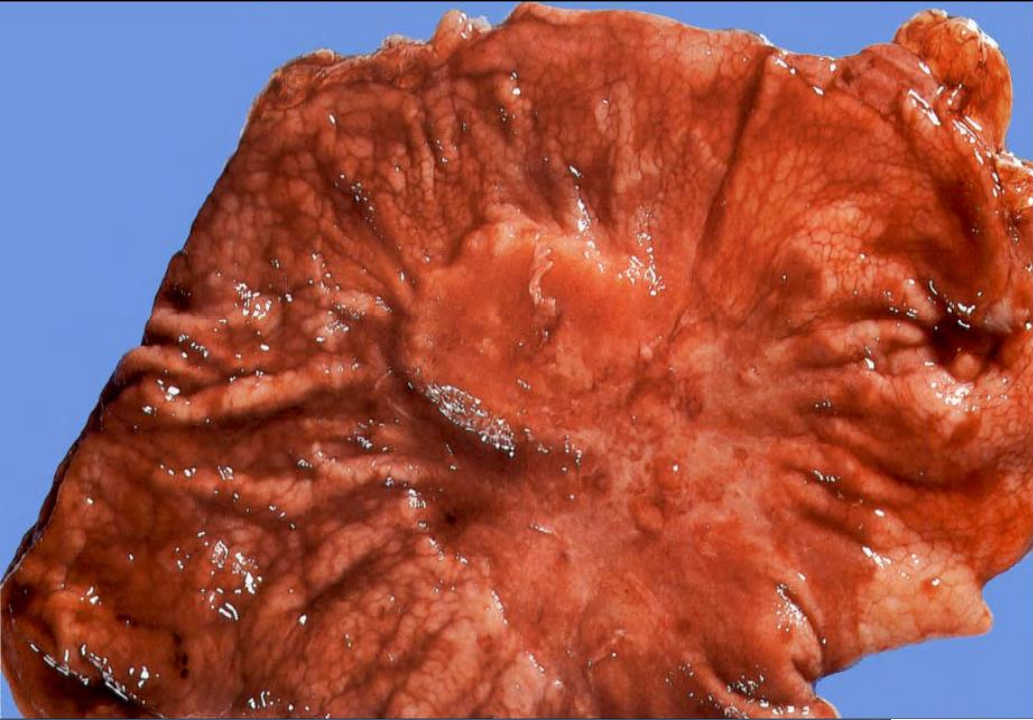
Polipi hiperplastici gastrici.





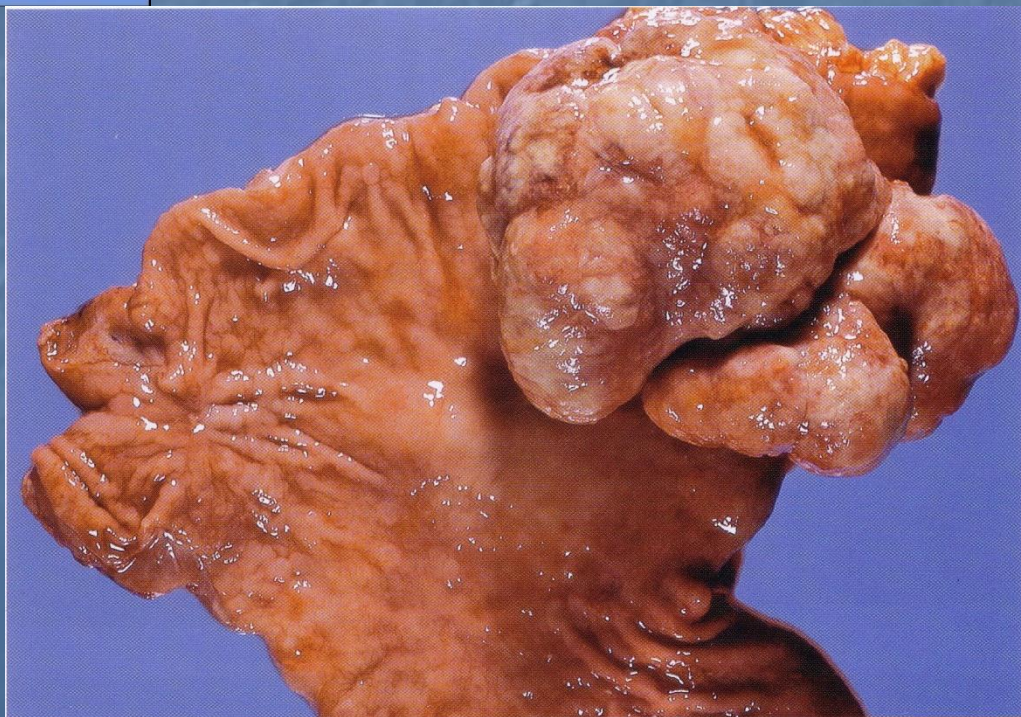Adenom gastric.

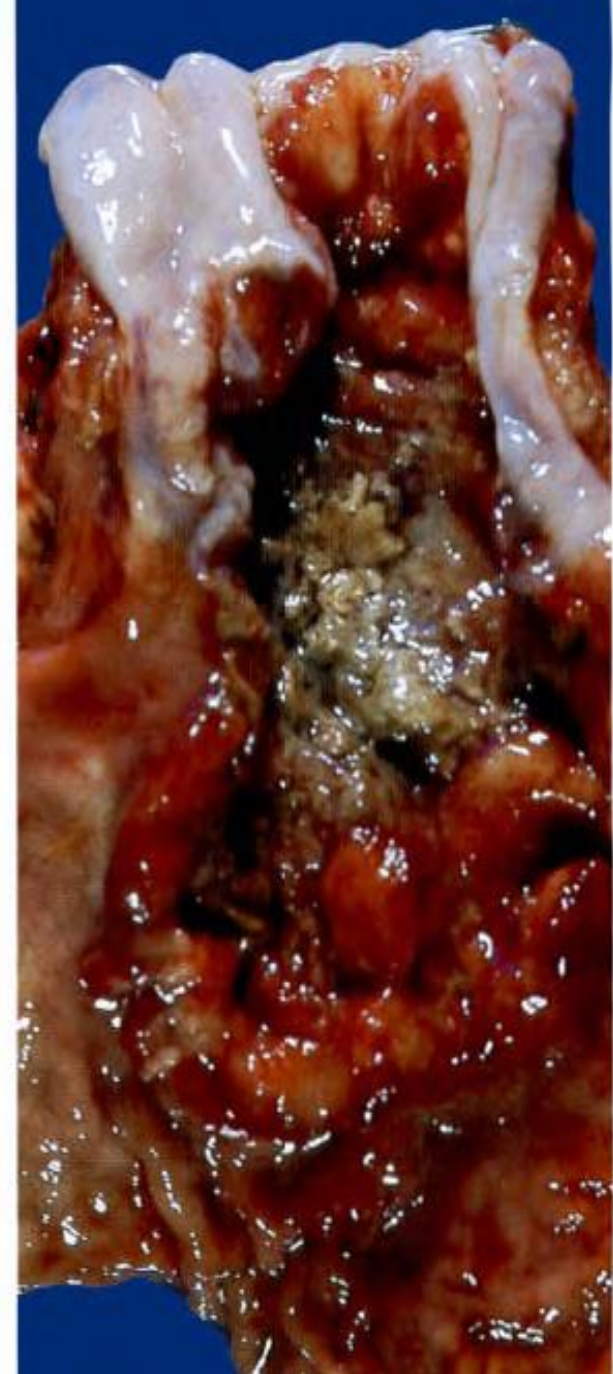
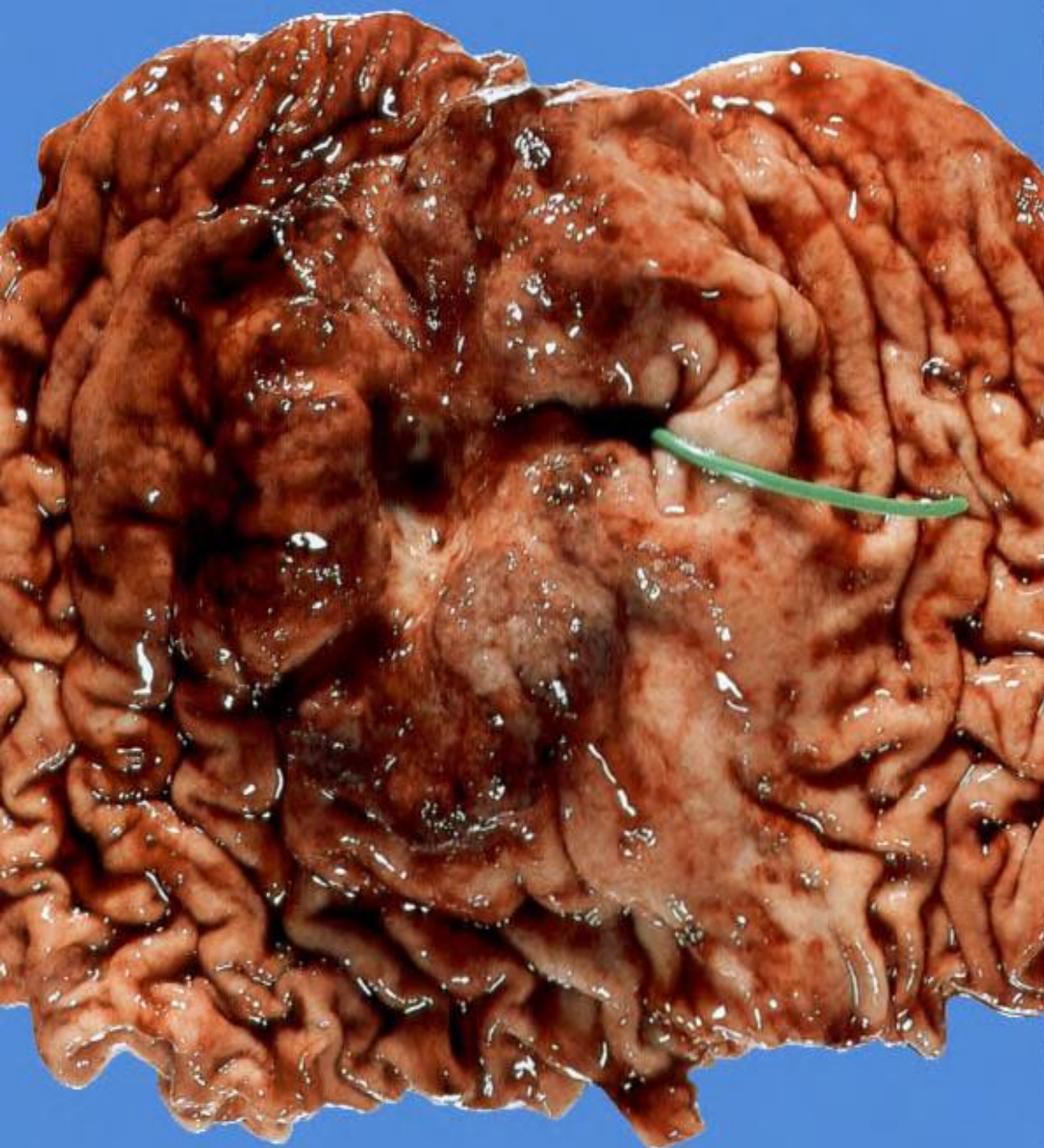




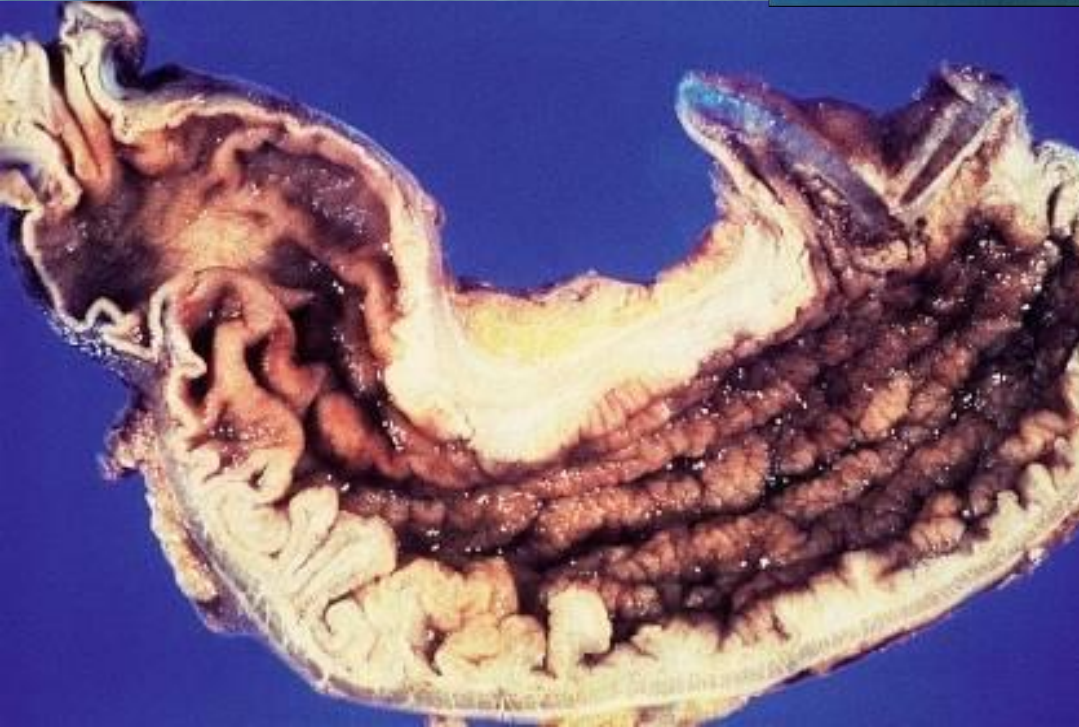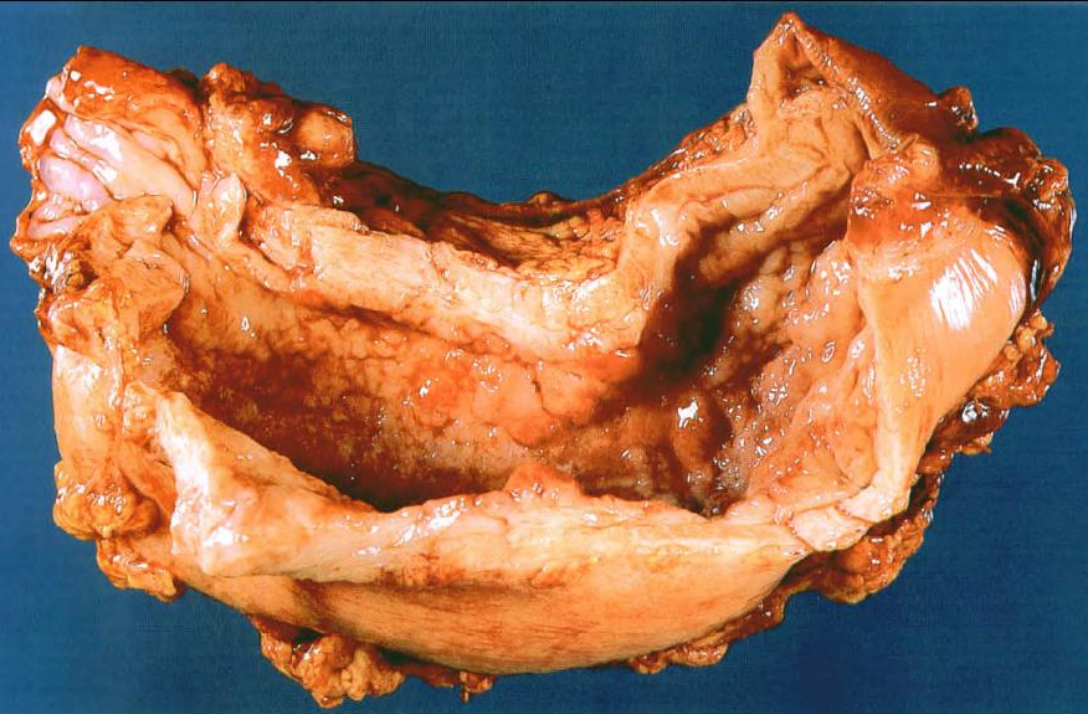
Cancer gastric polipos.

**Cancer gastric
în forma de placă.**

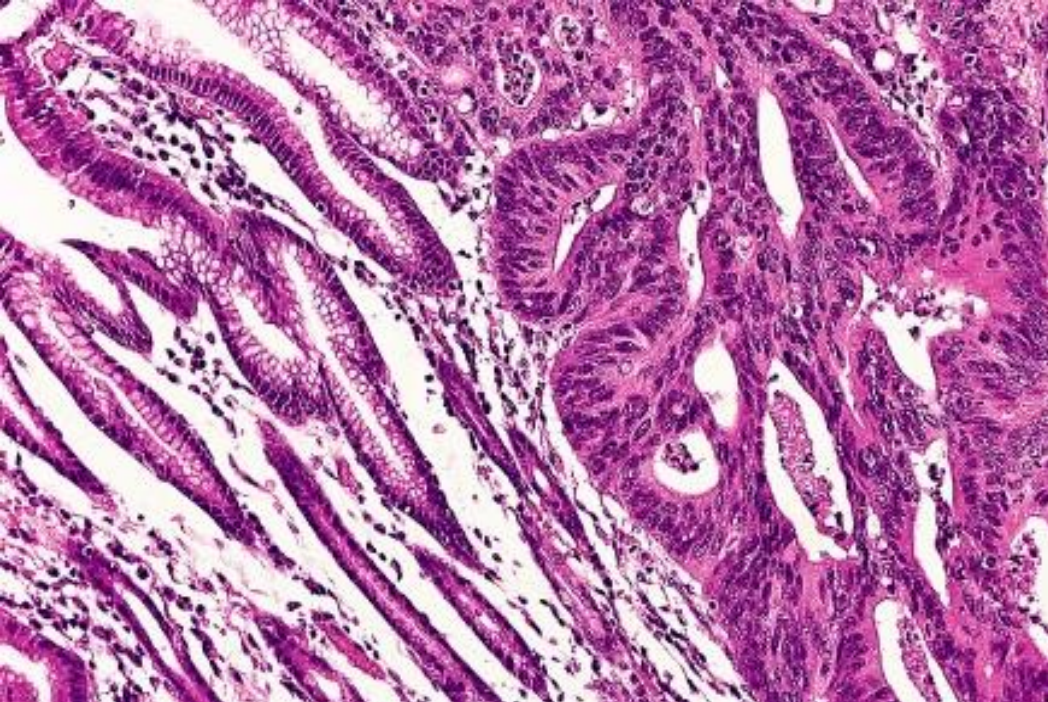




Cancer gastric exulcerat.

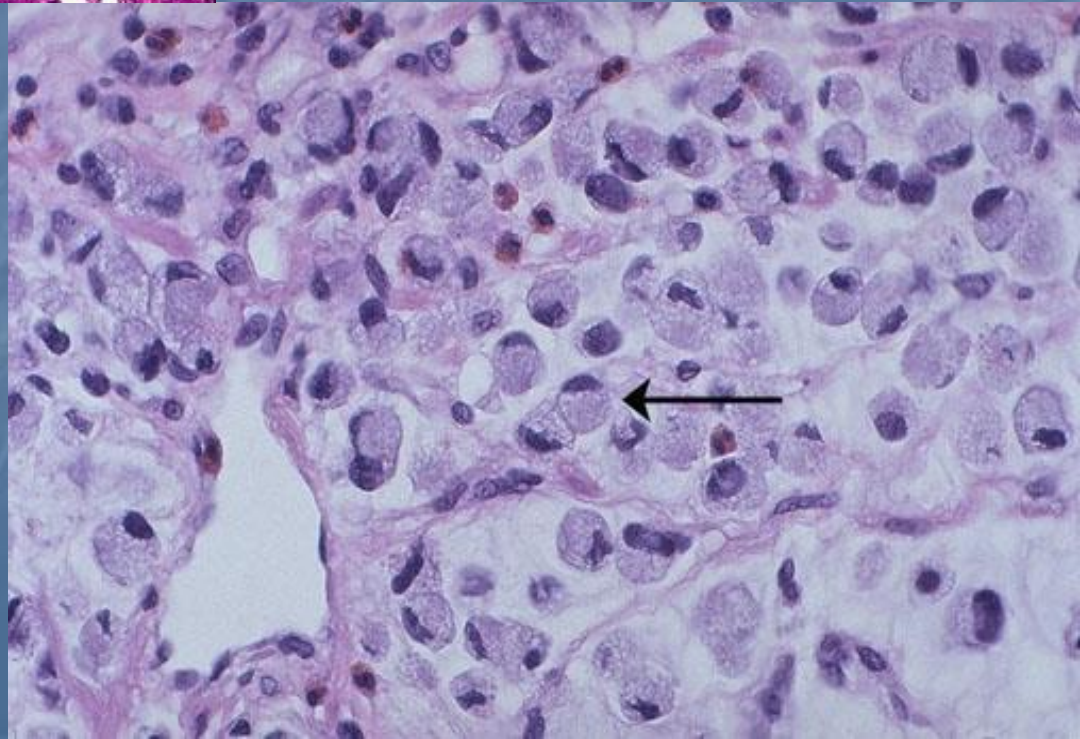


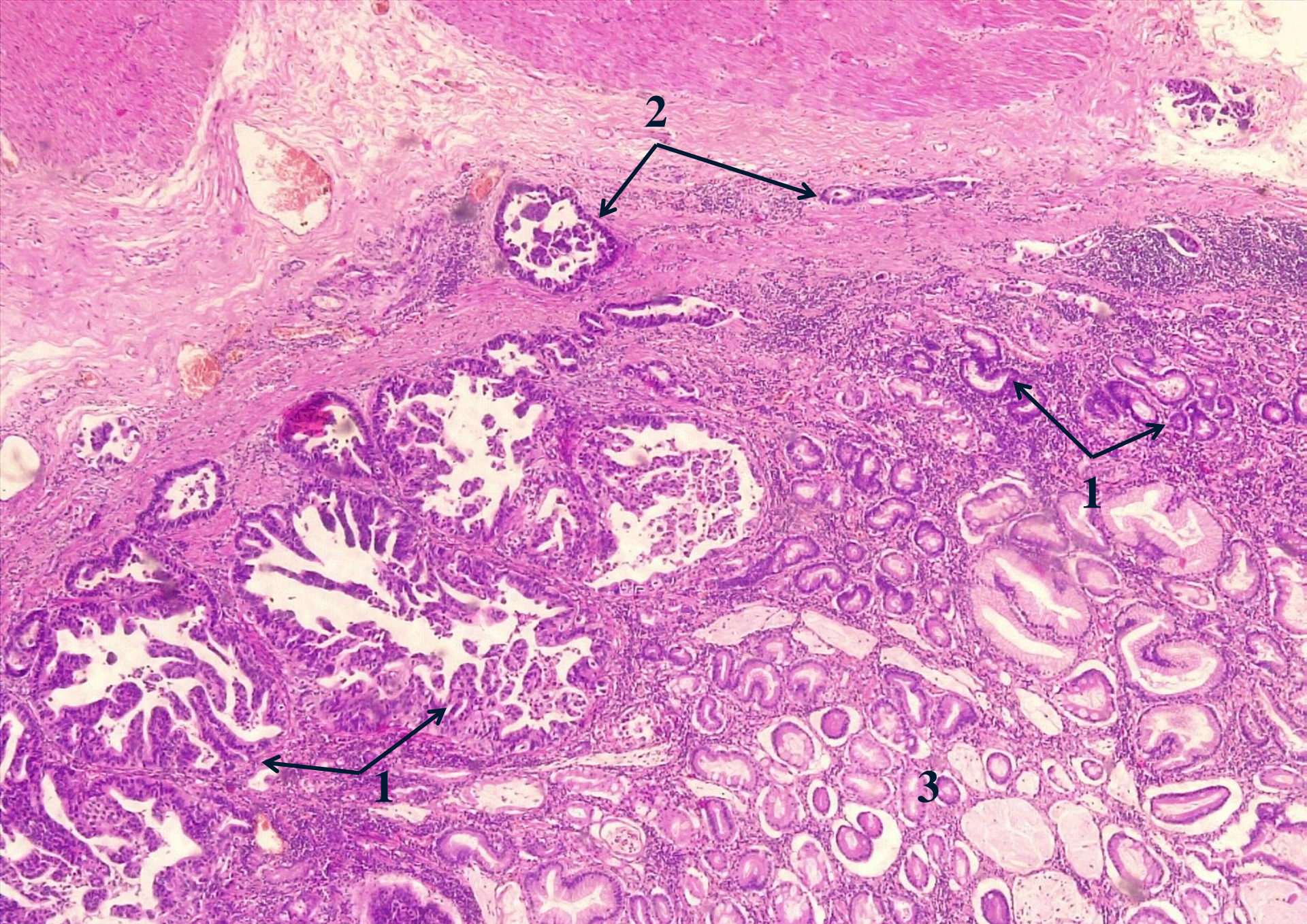
Cancer gastric infiltrativ.



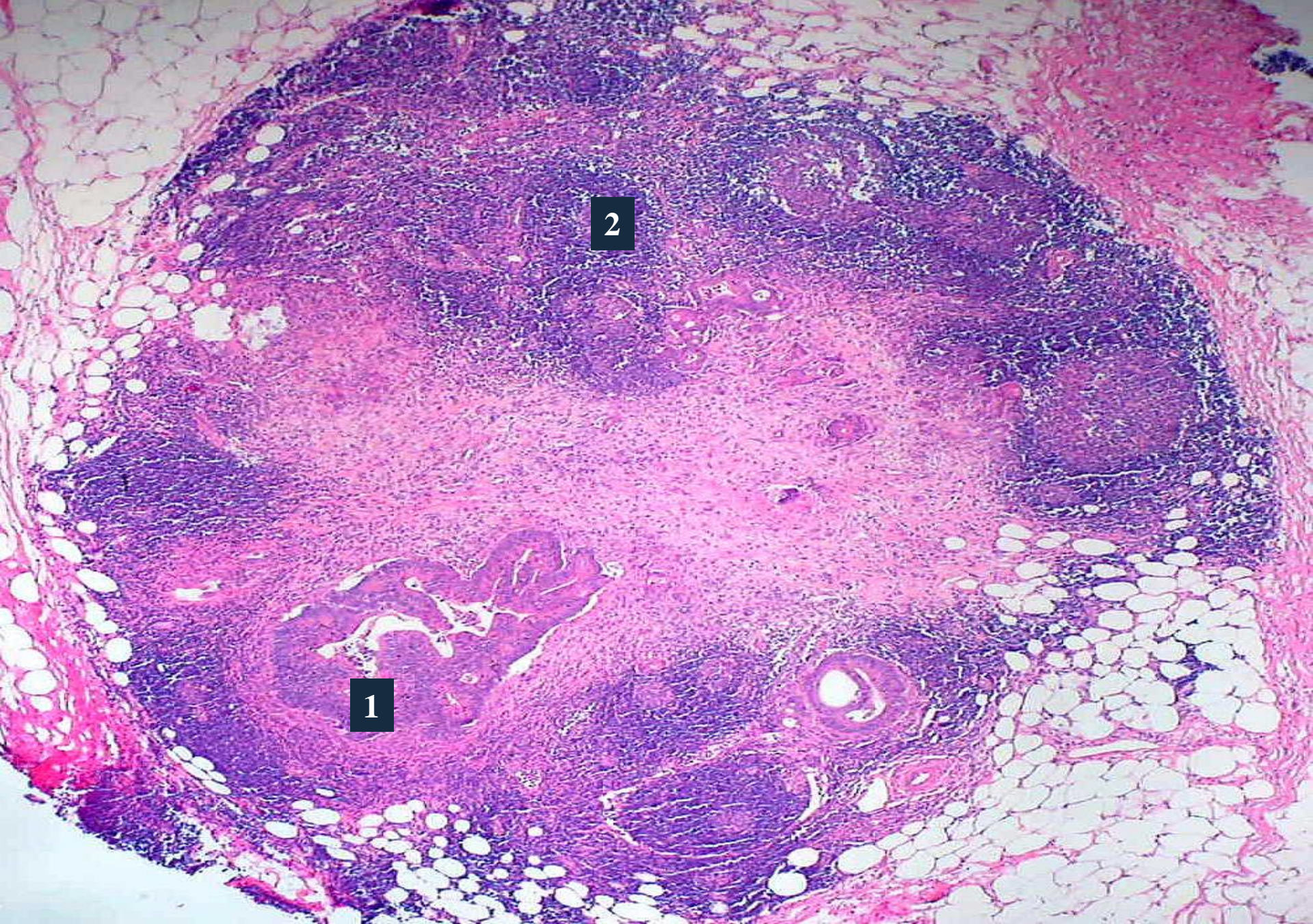
**Carcinom gastric, tip cu celule
în inel cu pecete.**

**Adenocarcinom
papilar gastric.**





No 192. Adenocarcinom gastric tubular – de tip intestinal. (colorație H-E.).



№ 192a. Metastaze de carcinom gastric în ganglion limfatic. (*colorație H-E.*)