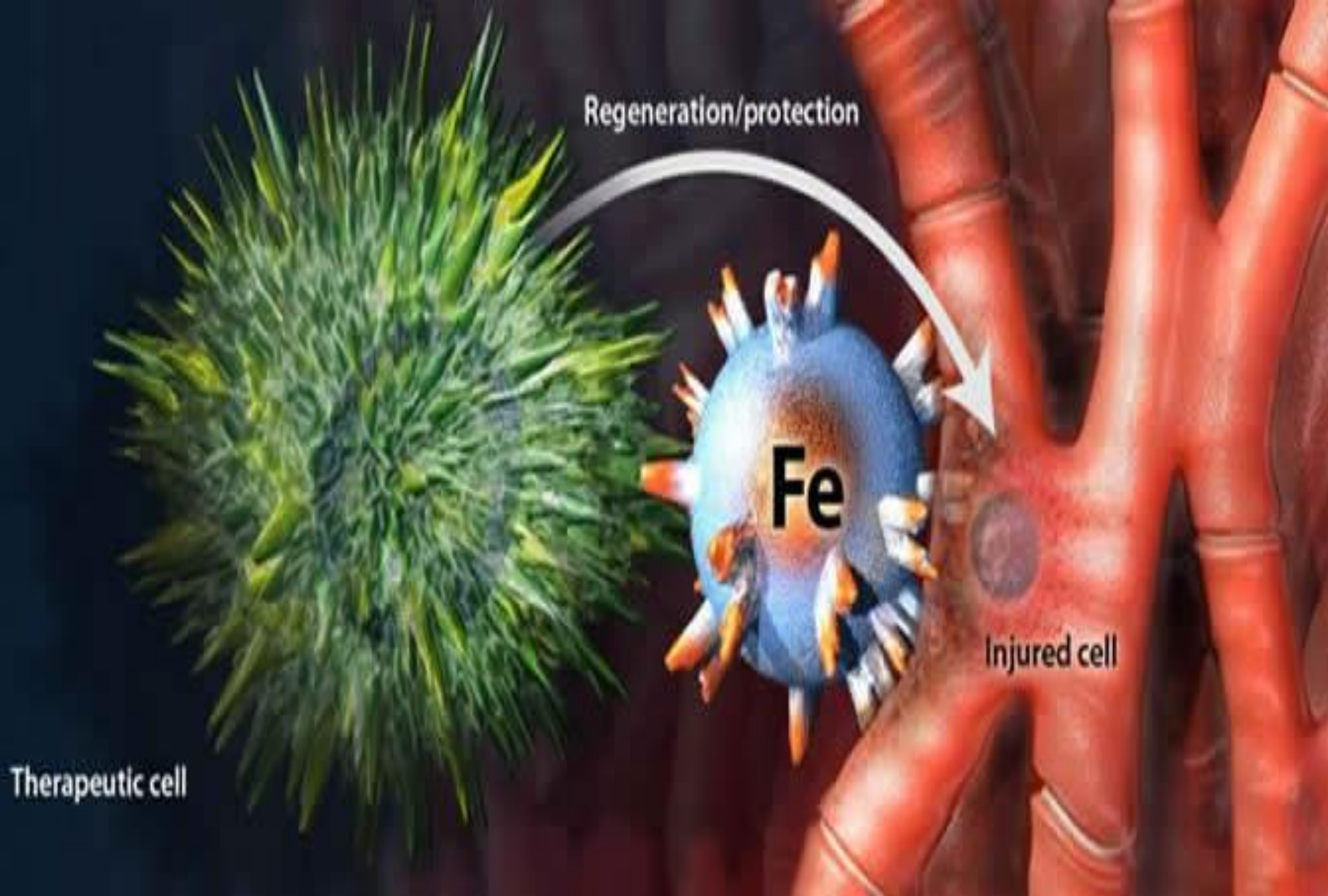

Adaptation and compensation. Regeneration.

Adaptation and compensation. Regeneration.

I. Microspecimens:

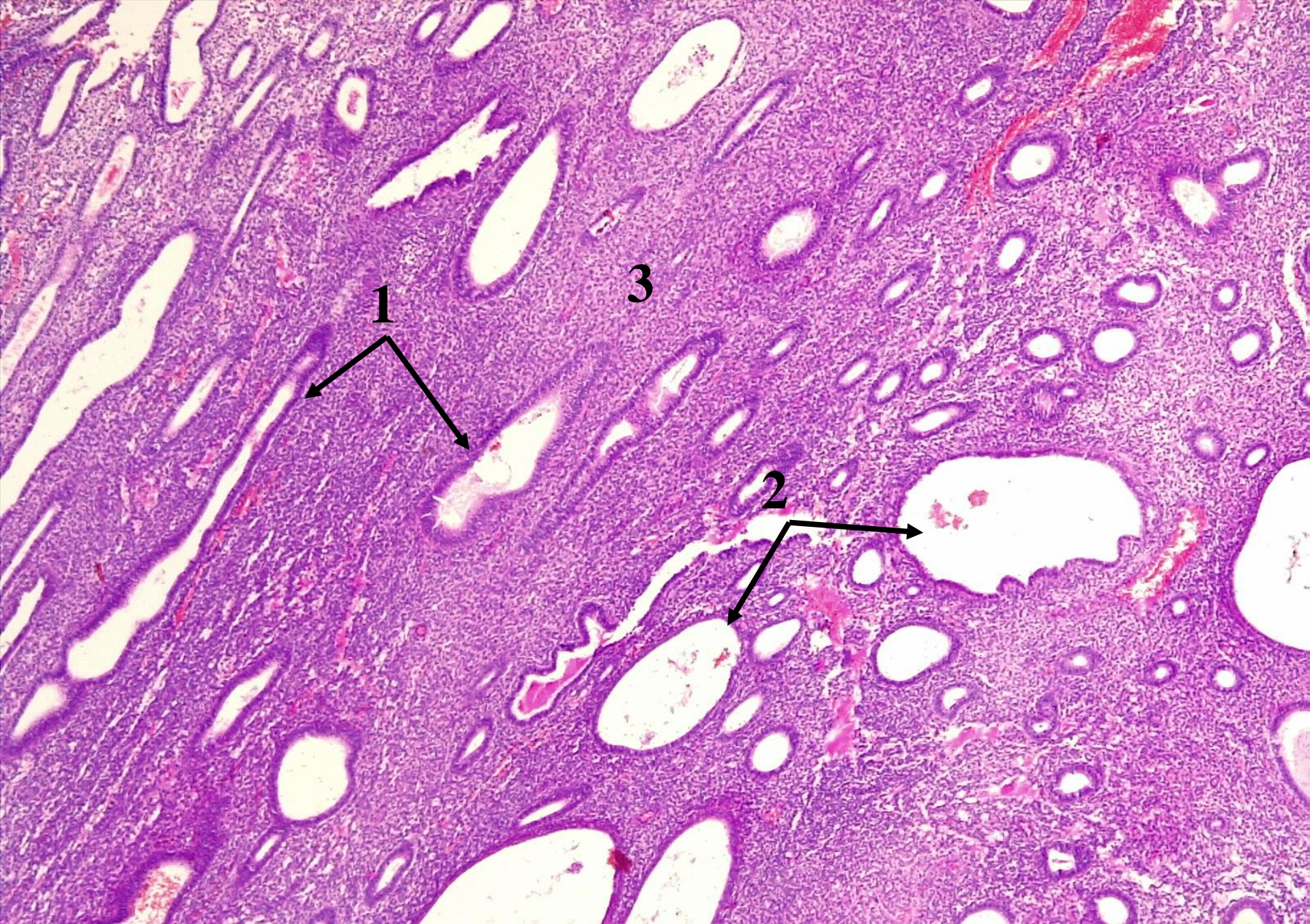
№ 38. Simple hyperplasia of the endometrium. (H-E. stain).

Indications:

1. Elongated endometrial glands with meandering appearance.
2. Cystically dilated glands.
3. Endometrial stroma.

The endometrium is thickened, contains numerous glands which differ in size and have irregular shape, some are small, others elongated, having a serpentine appearance or are cystically dilated; glandular epithelial cells are columnar, with elongated nuclei, hyperchromatic, the stroma is rich in fibroblasts, the glandular component predominates over the stroma.

Glandular hyperplasia of the endometrium is a manifestation of hormonal disorders and occurs in the case of hypersecretion of estrogen. There is an imbalance between estrogen and progesterone, which stimulates proliferative processes in the endometrium. The severity of the hyperplasia depends on the duration of the excess estrogen. It is found in some ovarian tumors, in the long administration of estrogen, in obesity. Clinically it is manifested by irregular and persistent uterine bleeding, posthemorrhagic anemia can develop. It is considered a precursor of the uterine cancer.



№ 38. Simple hyperplasia of the endometrium. (H-E. stain)

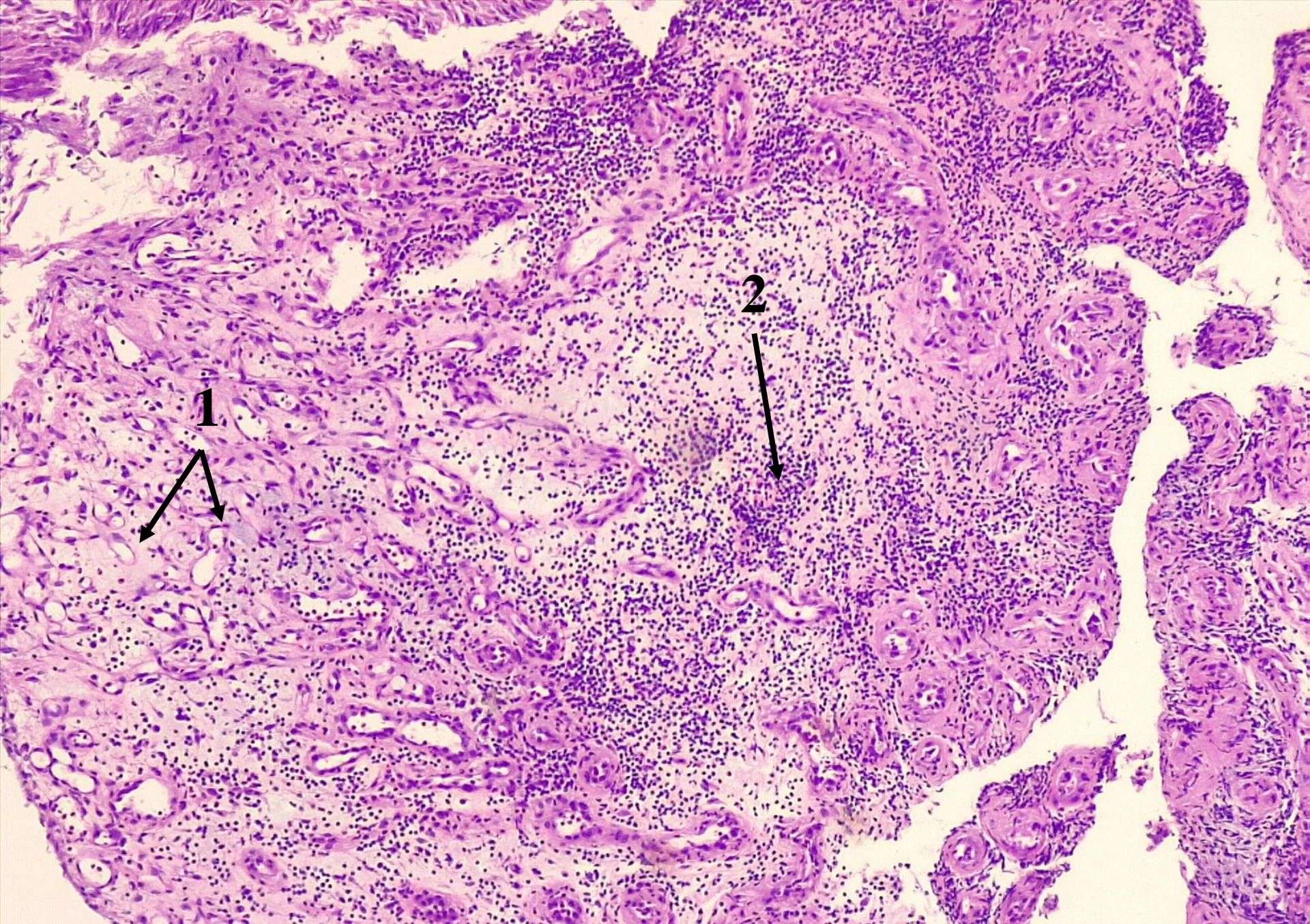
№ 35. Granulation tissue. (*H-E. stain*).

Indications:

1. Thin-walled vessels.
2. Granulation tissue cells (macrophages, leukocytes, lymphocytes, plasma cells, fibroblasts).

In microspecimen is a section of granular tissue, rich in small blood vessels, with thin walls, including capillaries, among which are multiple cellular elements: macrophages, polymorphonuclear leukocytes, lymphocytes, plasma cells, fibroblasts. Blood vessels are dilated, hyperemic.

Granulation tissue is the initial phase of connective tissue regeneration, being, in fact, a young connective tissue, rich in blood cells and vessels and poor in collagen fibers. It is a typical example of complete, cellular regeneration. The formation of granulation tissue begins with the proliferation (division) of young mesenchymal cells and the neoformation of blood microvessels. Macroscopically it is a fine, juicy, reddish tissue, with a granular surface (hence the name), the granules being made up of unformed vessels. It bleeds slightly due to the large number of capillaries. In dynamics, the number of cells and blood vessels gradually decreases, mesenchymal cells turn into epithelioid cells, and the last - into fibroblasts. Fibroblasts predominate in the maturing granulation tissue, and the number of vessels is progressively reduced. At the same time, there is an increase in the activity of fibroblasts and the intense production of collagen fibers, the vessels turn into arteries and veins. The maturation process of the granulation tissue ends with the formation of a fibrous (scar) connective tissue, in which an insignificant number of fibrocytes and vessels are encountered. Neoformation of granulation tissue occurs not only in the regeneration of connective tissue itself, but also in cases of incomplete regeneration of other organs (when the defect is replaced with connective tissue), as well as in the processes of organization, encapsulation, wound healing and in productive inflammation.



№ 35. Granulation tissue. (H-E. stain).

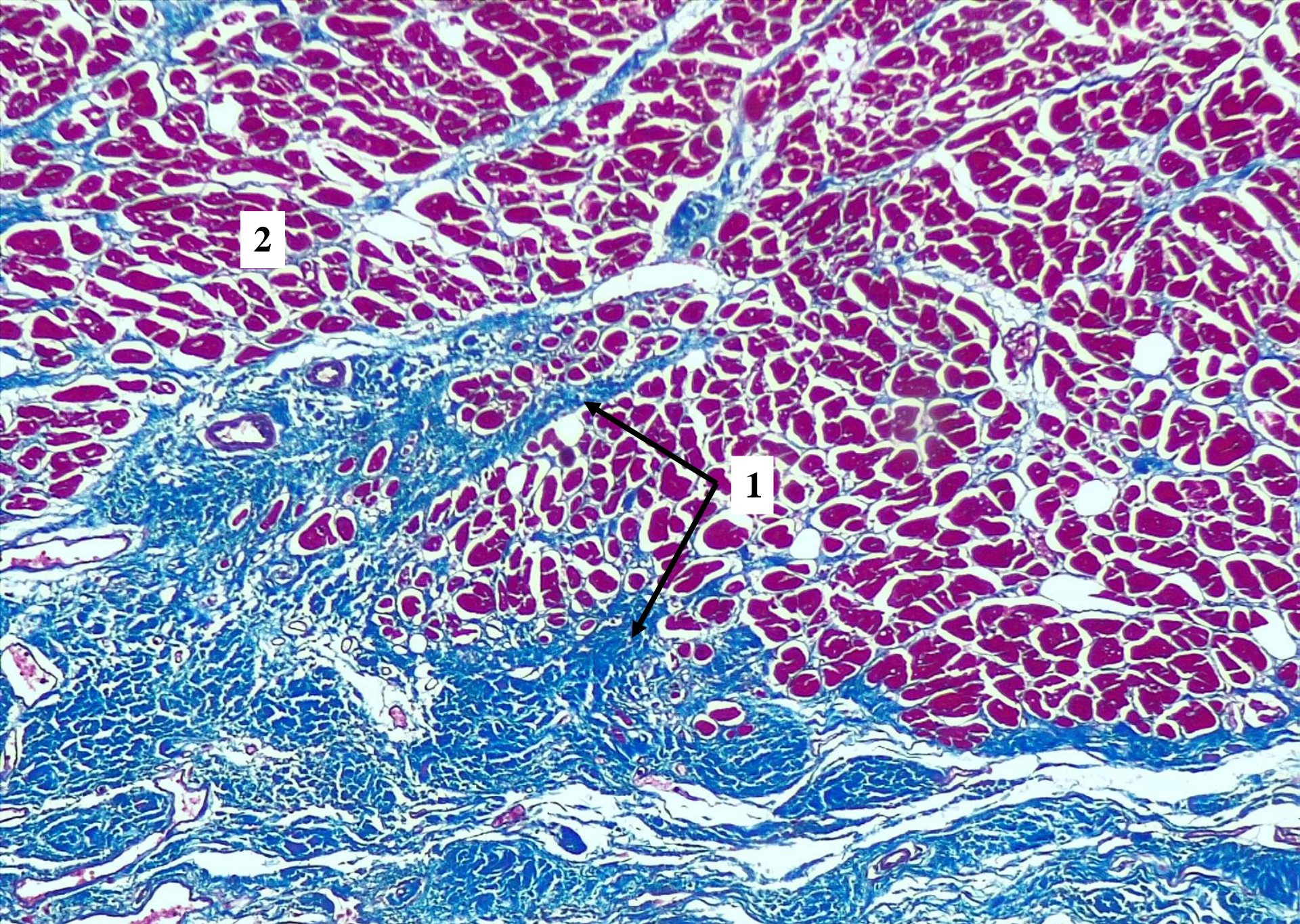
№ 150. Macrofocal postinfarction cardiosclerosis. (*Masson's trichrome stain*).

Indications:

1. Connective tissue bundles.
2. Hypertrophied cardiomyocytes.

Extensive foci of scar fibrocollagenous tissue are observed in the microspecimen, the collagen fibers are stained in blue, cardiomyocytes - in red, nuclei – in black; connective tissue is poor in blood vessels and cellular elements, focally homogenized, hyalinised. The cardiomyocytes located immediately around the scar are hypertrophied, the diameter is increased, the nuclei are large, irregular in shape, intensely stained with hematoxylin.

Post-infarct macrofocal cardiosclerosis develops as a result of the organization - replacement with connective tissue of the infarct (necrosed) area. Organization is the most common consequence of an infarct of any location. Necrotic masses are subjected to phagocytosis by leukocytes and macrophages, and the immature connective tissue fills the area of necrosis - granulation tissue, which gradually turns into mature, scar fibrocollagenous tissue. This process takes an average of 5-7 weeks from the onset of myocardial infarction. The contractile potential of the heart after healing of the infarction is restored by regenerative hypertrophy of the remaining portions of the myocardium, primarily perifocal, but also at a distance. Possible complications: congestive heart failure, heart rhythm disturbances and conduction disorders, chronic postinfarction heart aneurysm.



№ 150. Macrofocal postinfarction cardiosclerosis. (*Masson's trichrome stain*).

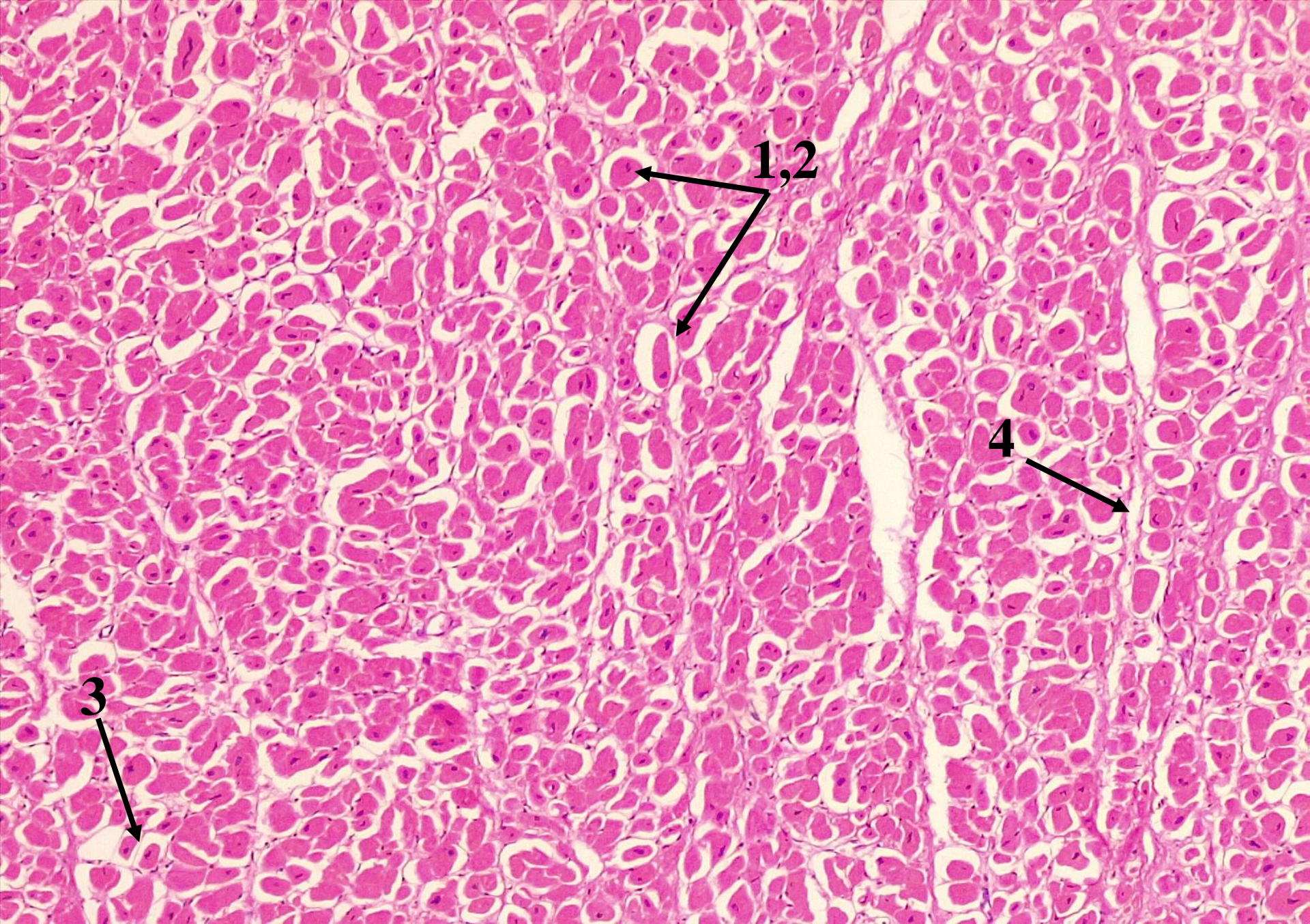
№ 36. Compensatory myocardial hypertrophy. (H-E. stain).

Indications:

1. Hypertrophied cardiomyocytes.
2. Increased in size and intense stained nuclei.
3. Unchanged cardiomyocytes.
4. Myocardial stroma.

Most cardiomyocytes are enlarged in volume, the nuclei are also enlarged, intensely basophilic (hyperchromatosis), have an irregular shape, thin bundles of fibrillar connective tissue are seen among the cardiomyocytes.

Myocardial hypertrophy occurs not by means of cellular hyperplasia, but by hyperplasia and hypertrophy of intracellular organelles, which leads to an increase in the volume of pre-existing cardiomyocytes. At the same time, proliferation of the fibrillar structures of the stroma, of the intramiocardial branches of the coronary arteries and the elements of intramural nervous system of the heart takes place.



№ 36. Compensatory myocardial hypertrophy. (*H-E. stain*).

II. Macrospecimens:

№ 4. Left ventricular hypertrophy.

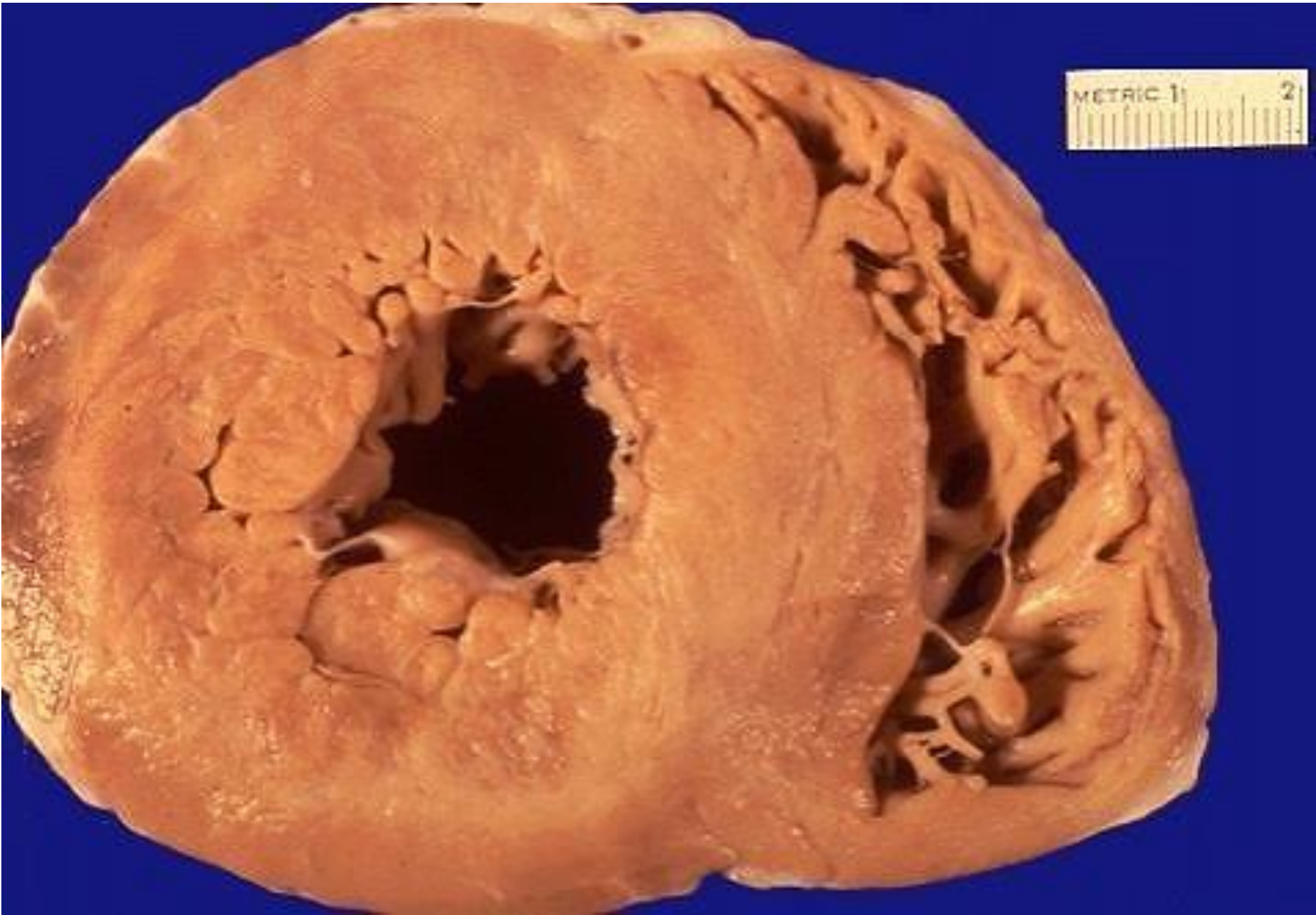The size and mass of the heart are increased, the wall of the left ventricle considerably thickened, the thickness up to 2.0- 2.5 cm (normal thickness 1.0-1.2 cm); papillary and trabecular muscles are enlarged (hypertrophied), the heart mass can reach 600-1000 g (normal mass 260-280 g).

Left ventricular hypertrophy is associated with high blood pressure, aortic stenosis and other heart valvulopathies. Hypertrophy occurs due to functional overload of the left ventricular myocardium under conditions of aortic stenosis or hypertension (due to resistance). During the compensation period, the concentric hypertrophy of the heart is observed, when its cavities are narrowed and the tone of the heart muscle is increased. Excentric hypertrophy occurs during the decompensation period, when the heart cavities are dilated, the consistency of the myocardium is flaccid, on the cut section it is opaque due to dystrophic lesions, myocardial steatosis ("tiger heart") is observed. Hypertrophy can reach an extent until it can't compensate the increased functional overload and heart failure develops. Dilation of the heart in the compensating stage is called active or tonogenic, and in decompensation - passive or myogenic. Decompensation of the left heart is manifested by pulmonary congestion.

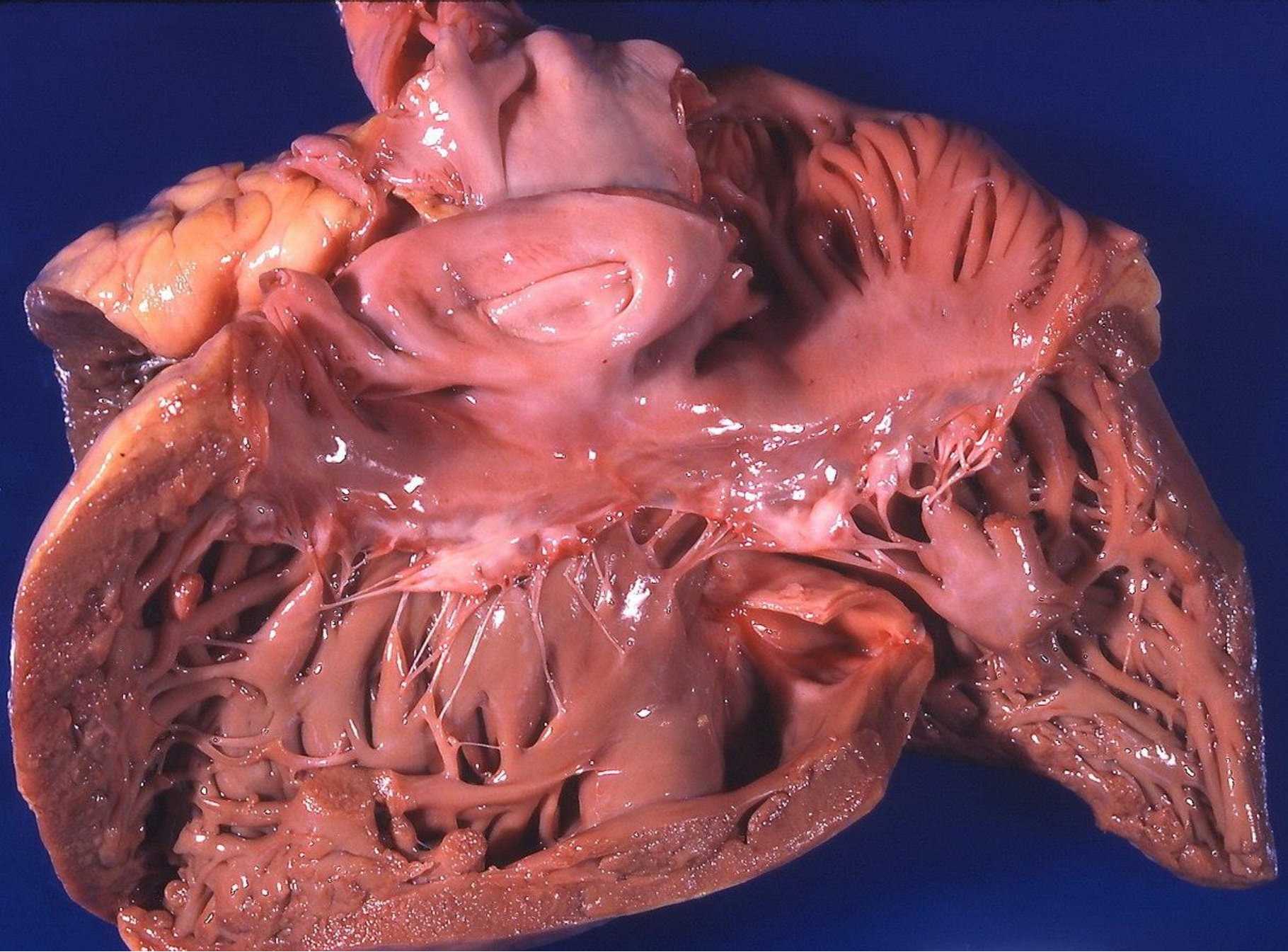
№ 5. Right ventricular hypertrophy.

The wall of the right ventricle is thickened, has a thickness of up to 1-1.5 cm (norm - 2-3 mm), dense-elastic consistency, papillary and trabecular muscles are increased in volume.

Right ventricular hypertrophy develops as a result of long-term pulmonary hypertension, which happens in various chronic lung diseases, eg in pulmonary emphysema, bronchiectatic disease, interstitial pneumonia, secondary pulmonary tuberculosis, pneumoconiosis (hence the name "Cor Pulmonale"), as well as in cardiac valvular lesions, e.g. pulmonary artery stenosis or insufficiency. Decompensation of the right heart is manifested by generalized peripheral edema and congestion of internal organs.



№ 4. Left ventricular hypertrophy.



№ 5. Right ventricular hypertrophy.

№ 90. Urinary bladder wall hypertrophy in benign prostatic hyperplasia.

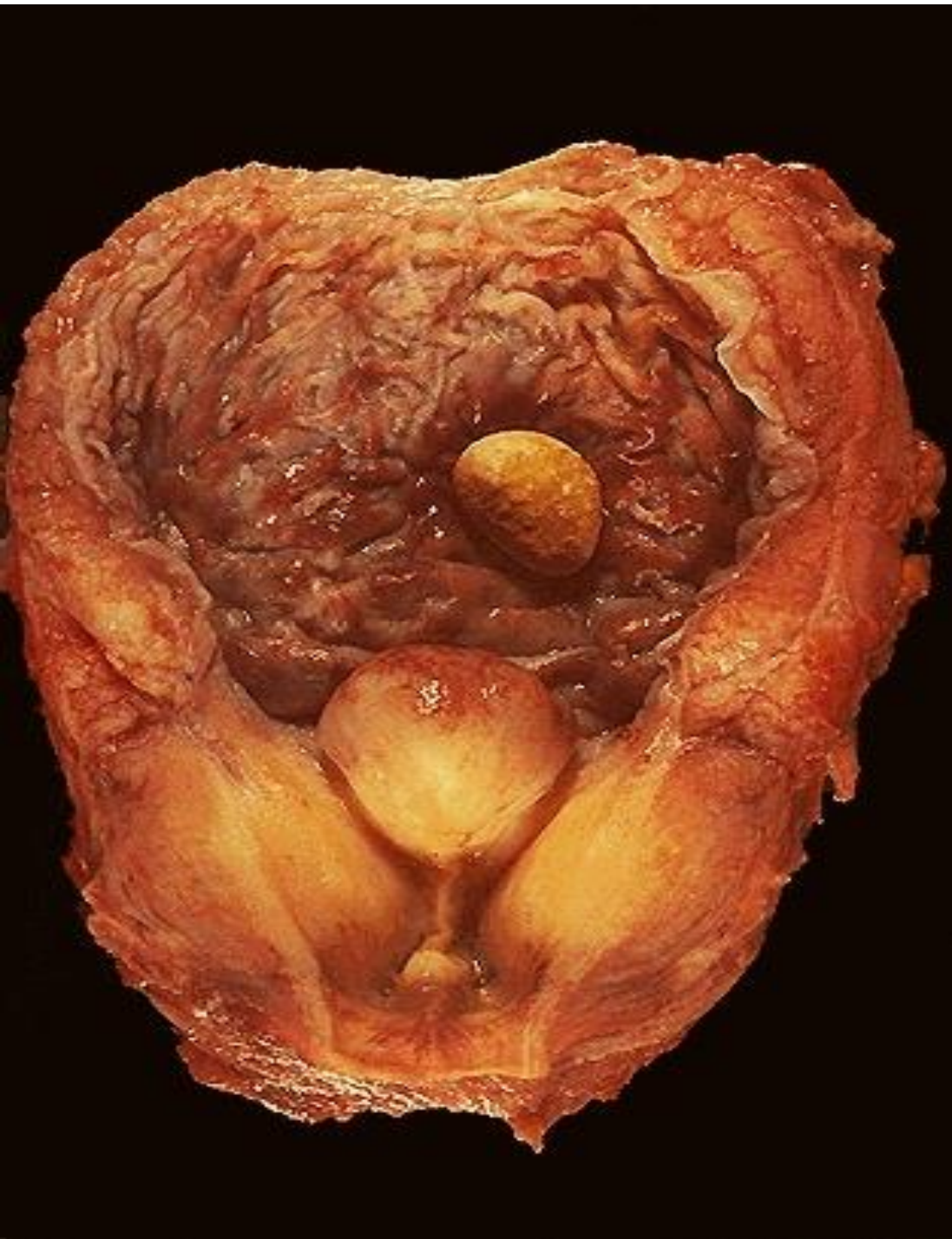
The wall of the bladder is thickened, hypertrophied, the mucosa has a trabecular appearance; the prostate is enlarged in size, has nodular surface, dense consistency, protrudes into the bladder cavity.

Bladder wall hypertrophy is compensatory due to compression of the prostatic portion of the urethra and urinary retention. It is observed in benign prostatic hyperplasia (dishormonal process). Urinary tract infections may be associated with the development of cystitis, ureteritis and ascending pyelonephritis, hydroureter. In cases of prolonged urinary stasis, stones may appear in the bladder.

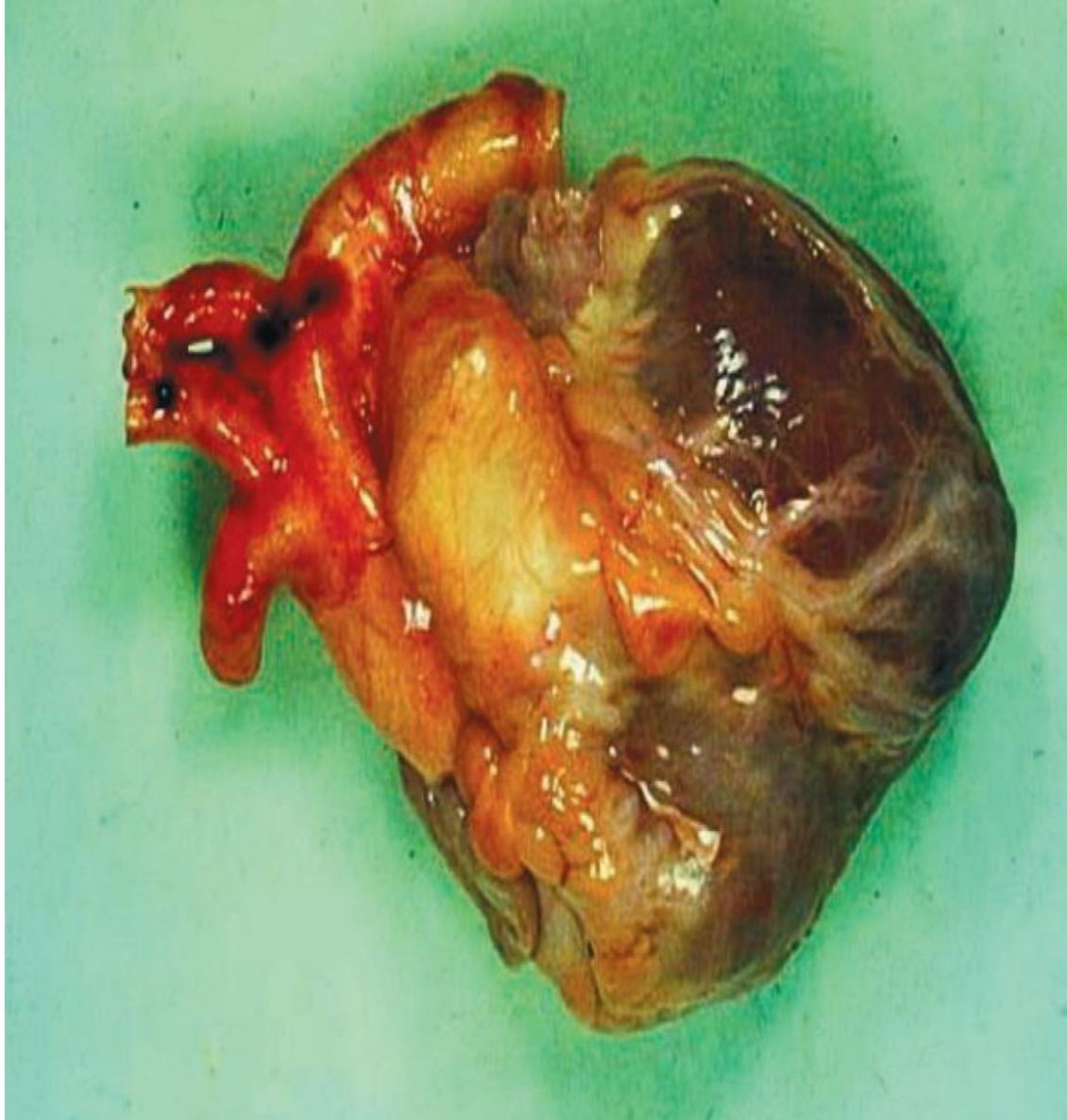
№ 20. Brown atrophy of the heart.

The heart is reduced in size and mass, has a brown color, the epicardium does not contain adipose tissue, the coronary arteries protrude under the epicardium, having a serpentine appearance; there is a discrepancy between the small dimensions of the heart compared to the main vessels (aorta and pulmonary artery).

Brown atrophy of the heart can be observed in some diseases that lead to cachexia / wasting syndrome and in the aging process as an expression of general atrophy. The brown color is due to the accumulation of the lipofuscin pigment, which is called "wear and tear pigment or senility pigment" and accumulates predominantly in the heart, liver and brain.



№ 90. Urinary bladder wall hypertrophy in benign prostatic hyperplasia.



№ 20. Brown atrophy of the heart.

№ 88. Hydronephrosis.

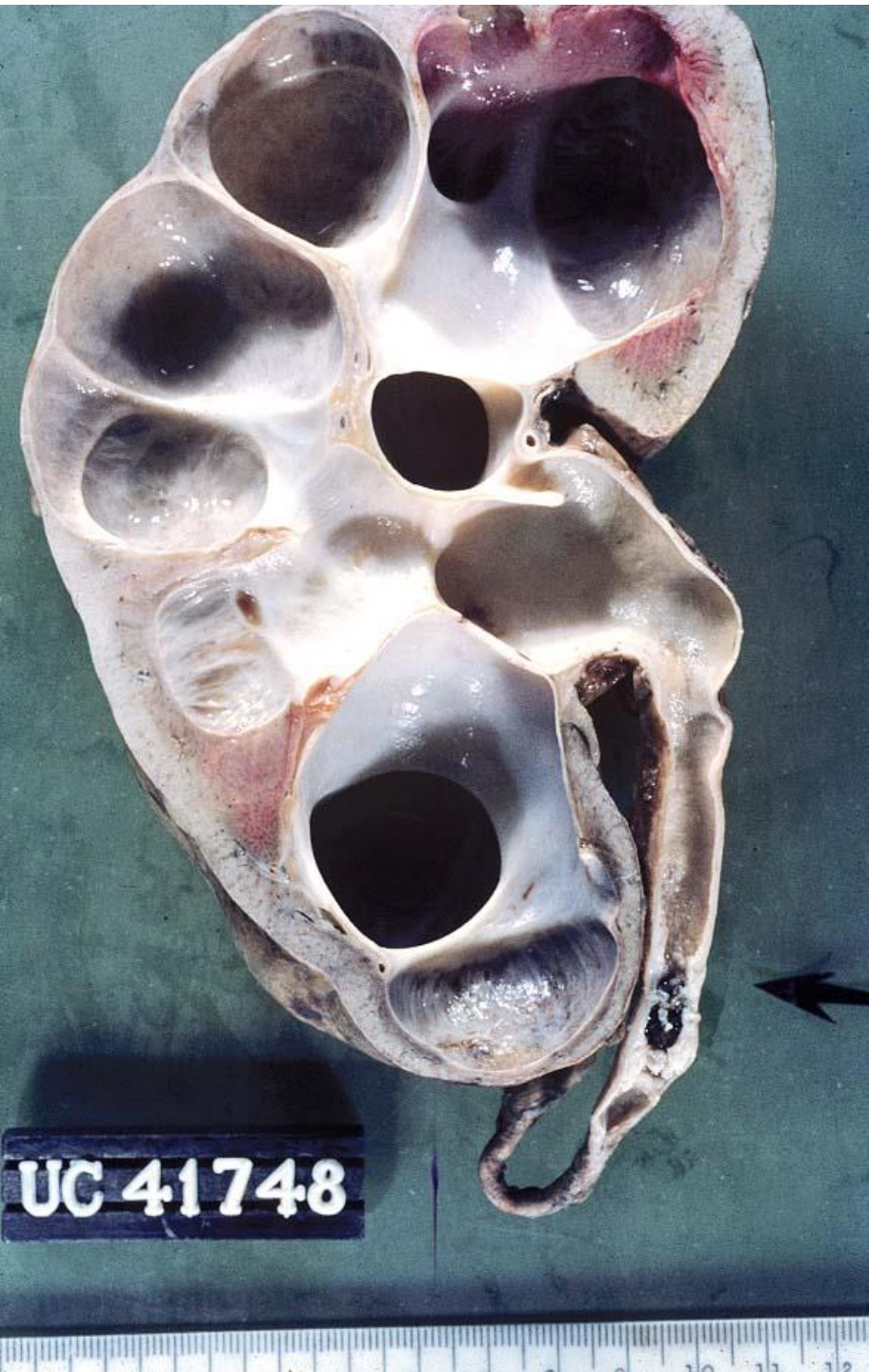The renal pelvis and calyces are dilated, the mucosa thickened, sclerosed, the renal parenchyma tapered, atrophied.

Hydronephrosis (uronephrosis) - excessive accumulation of urine in the renal pelvis, which leads to compression atrophy of the renal tissue. If the process is unilateral, the atrophy can advance to the total disappearance of the renal parenchyma, the kidney turning into a bag with thin walls, only on microscopic examination in the walls can be found some remnants of atrophied and sclerosed kidney tissue. The main cause of hydronephrosis are kidney stones (urolithiasis / nephrolithiasis), which cause obstruction of the ureter, retention of urine and dilation of the pelvis and calyces. It can be observed in the case of compression of the ureter by tumors, adhesions.

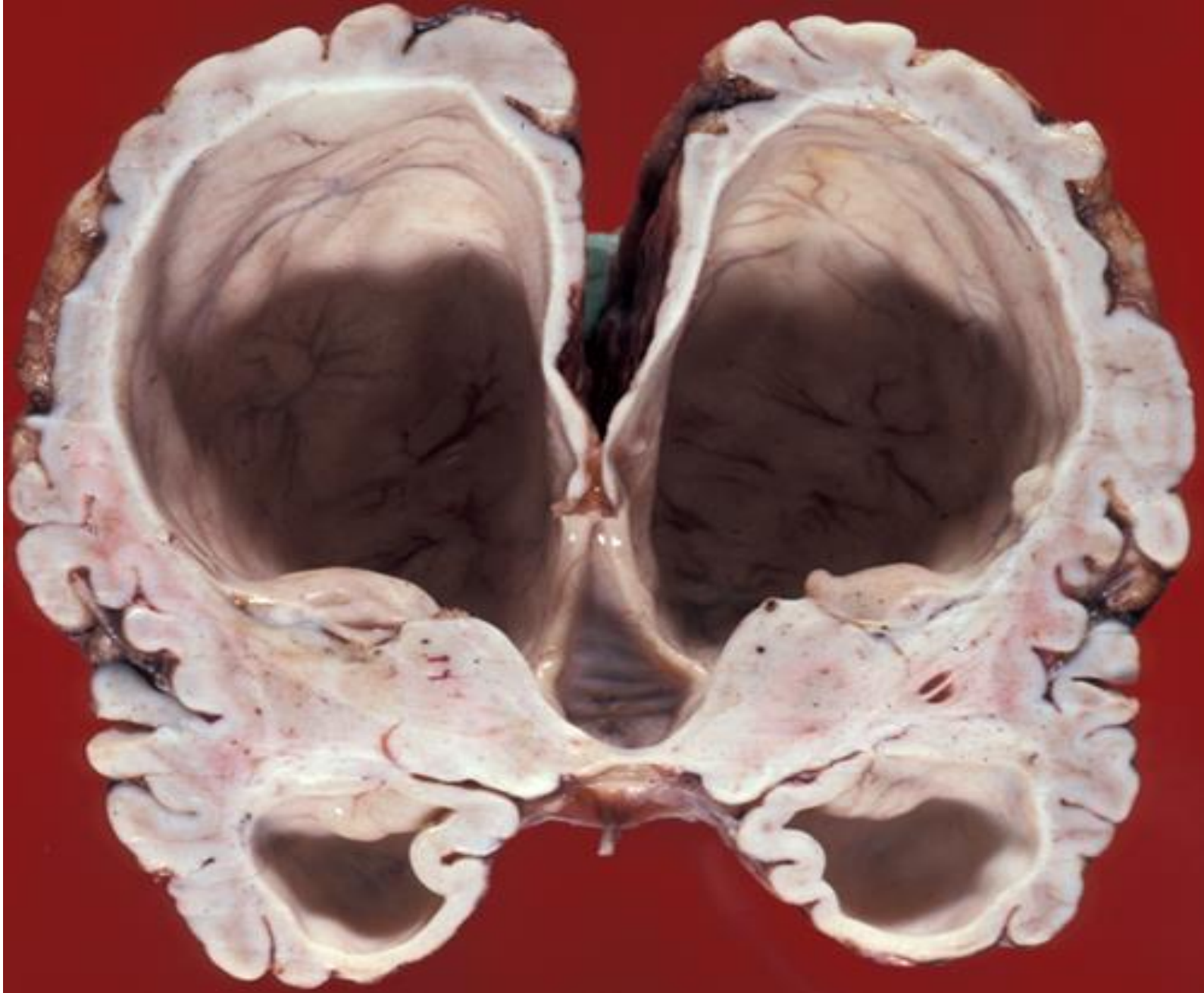№ 123. Hydrocephaly.

The brain is enlarged, the lateral ventricles considerably dilated, the brain tissue atrophied.

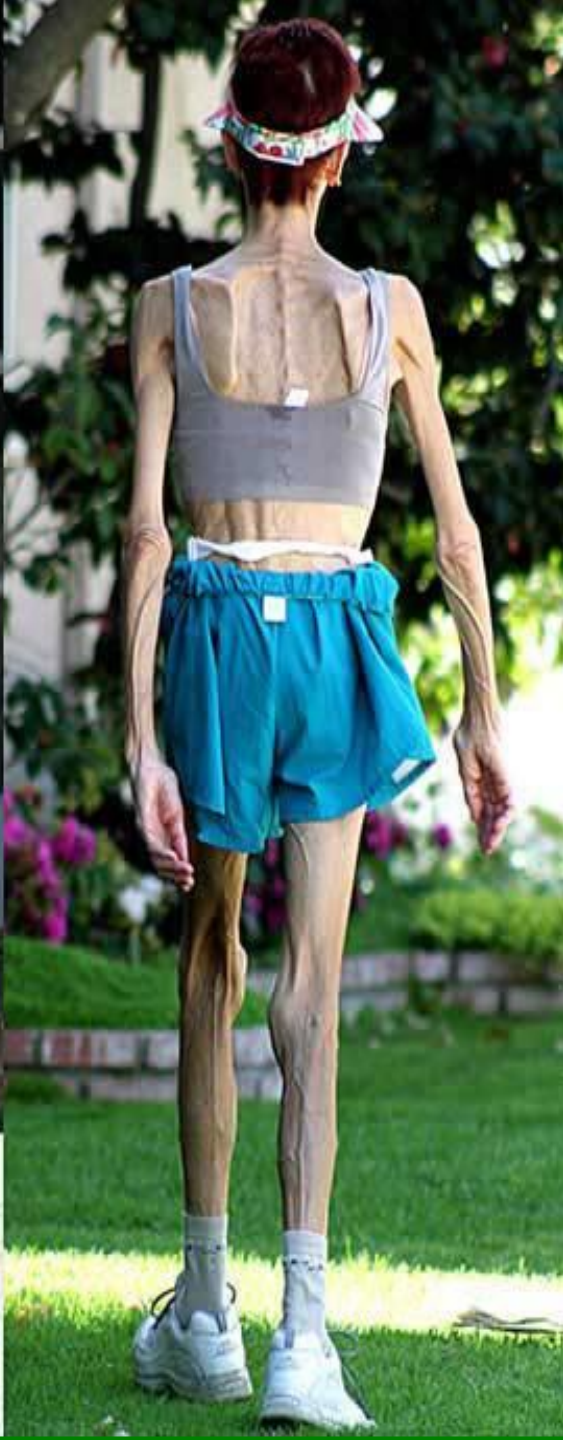Hydrocephalus - excessive accumulation of cerebrospinal fluid in the ventricular system, the cause being the stenosis of the foramina of Monro and the Sylvius aqueduct, the Magendie and Luschka foramina. In such cases, the ventricular system does not communicate with the subarachnoid space (non-communicating hydrocephalus), retention of cerebrospinal fluid in the ventricles, increase in intraventricular and intracranial pressure and compression atrophy of brain tissue. It can develop as a result of leptomeningitis, brain tumors, CNS trauma. There is also communicating hydrocephalus, caused by hyperproduction of cerebrospinal fluid, eg in papilloma of choroid plexuses or reduced fluid reabsorption due to leptomeningitis, subarachnoid hemorrhage. Hydrocephalus may be a congenital malformation of the central nervous system.



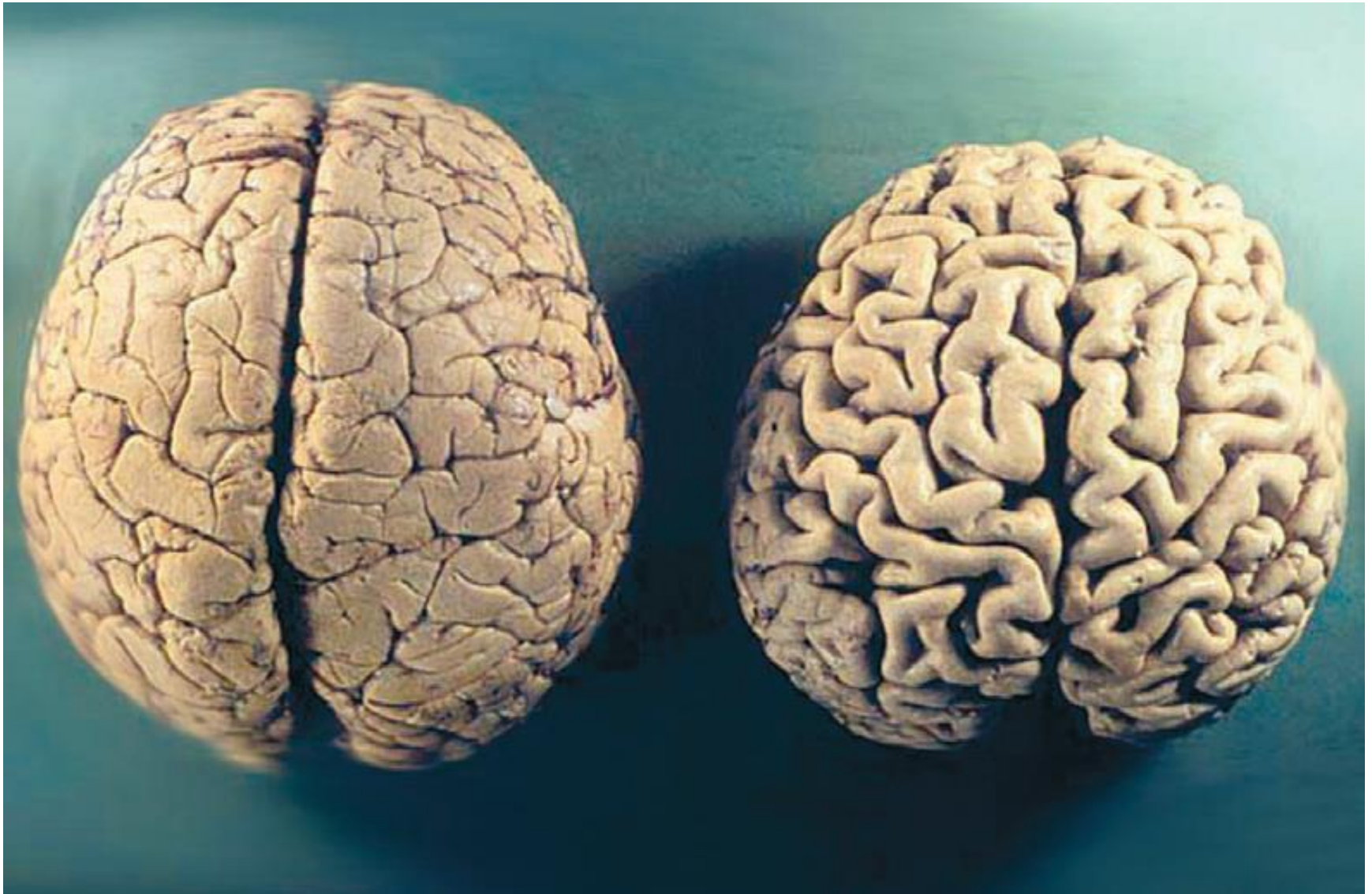
№ 88. Hydronephrosis.



№ 123. Hydrocephaly.



Cachexia.

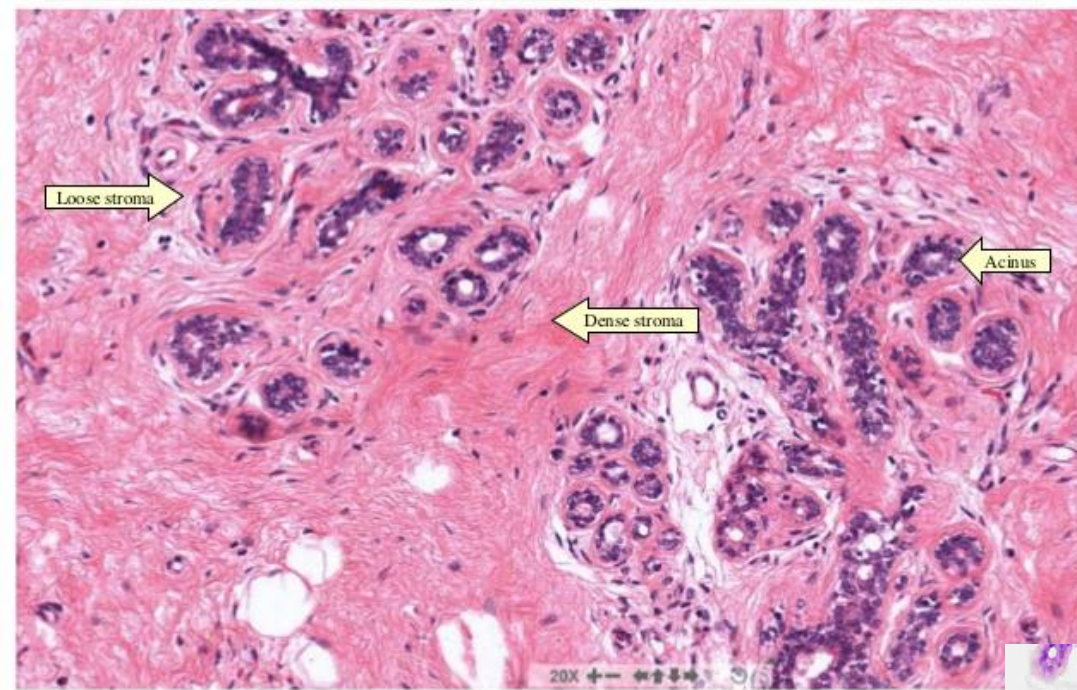


Normal

Atrophied

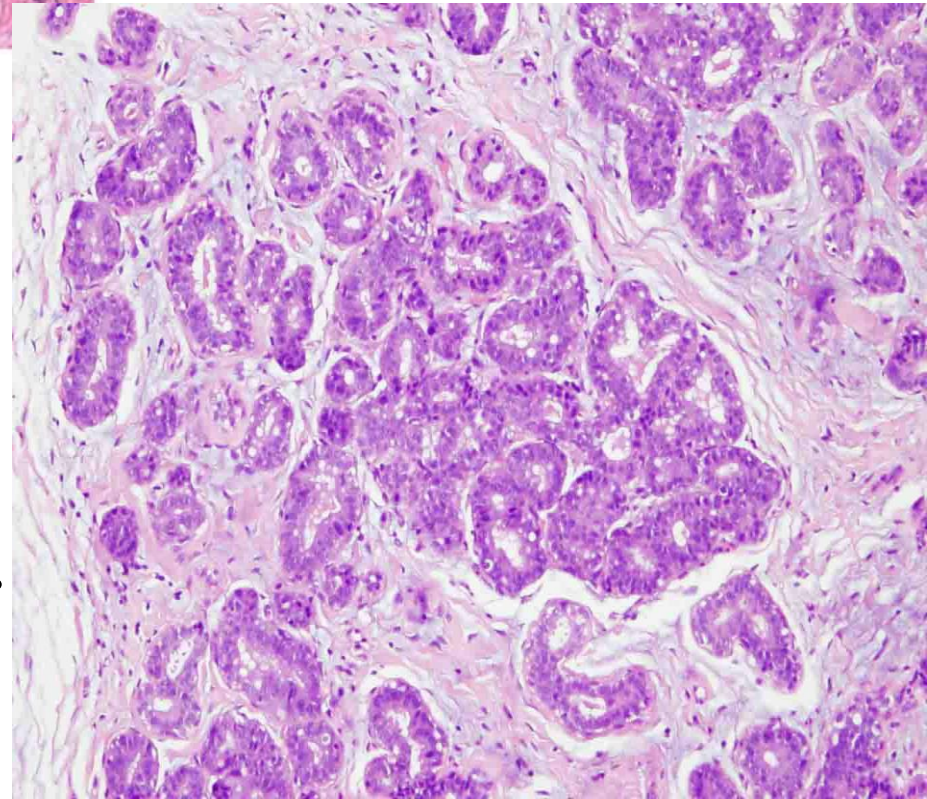
Bilateral ischemic atrophy of the brain.

Mammary gland.

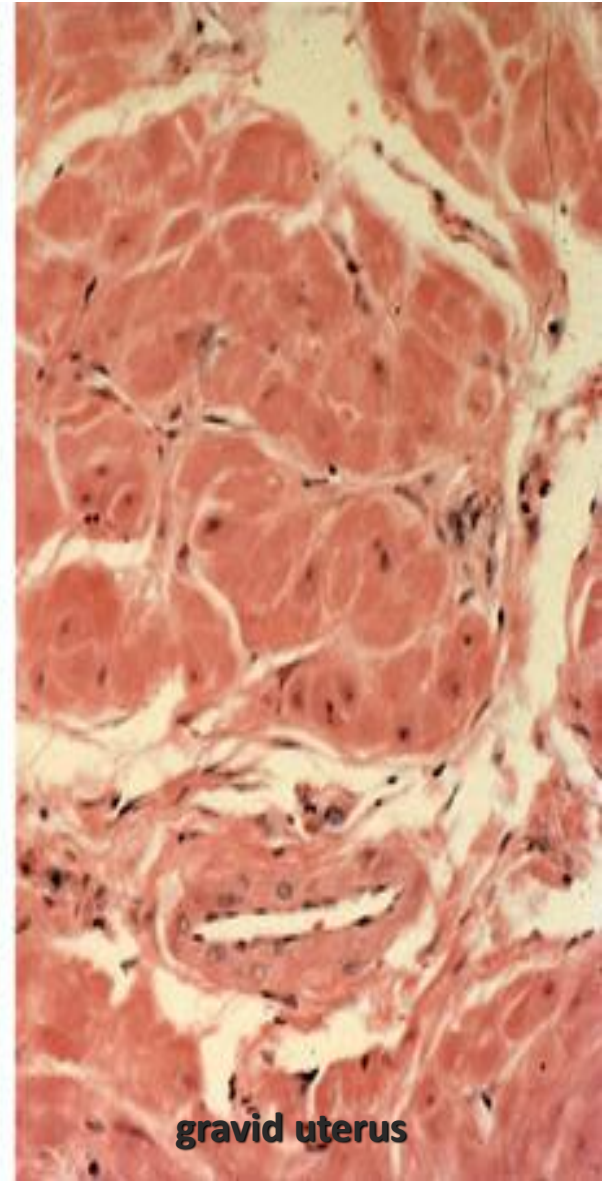
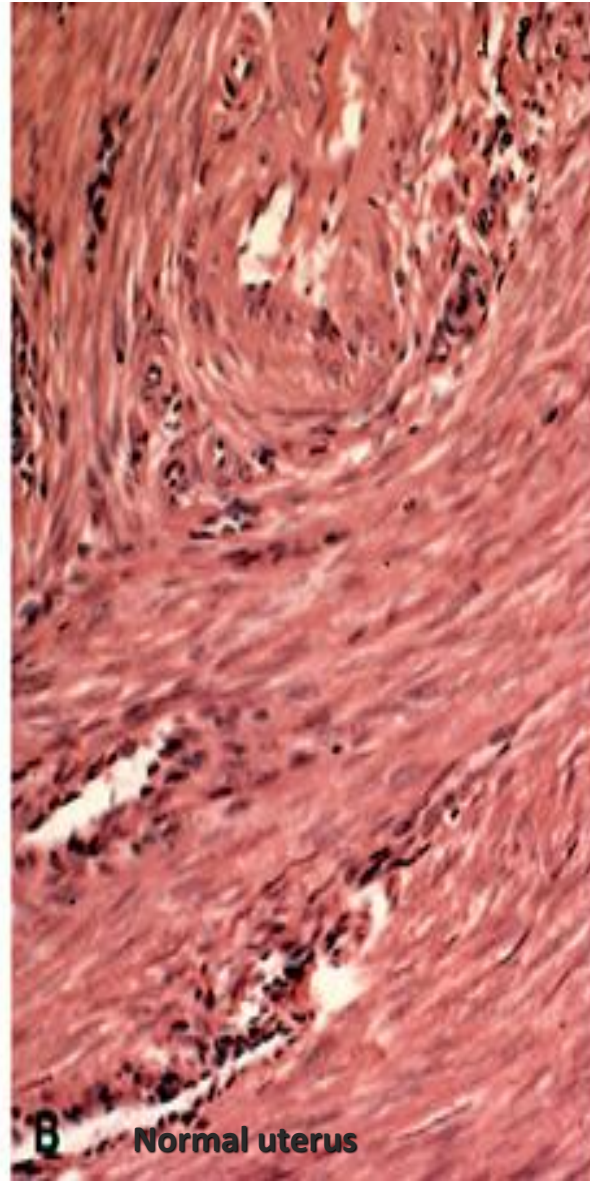
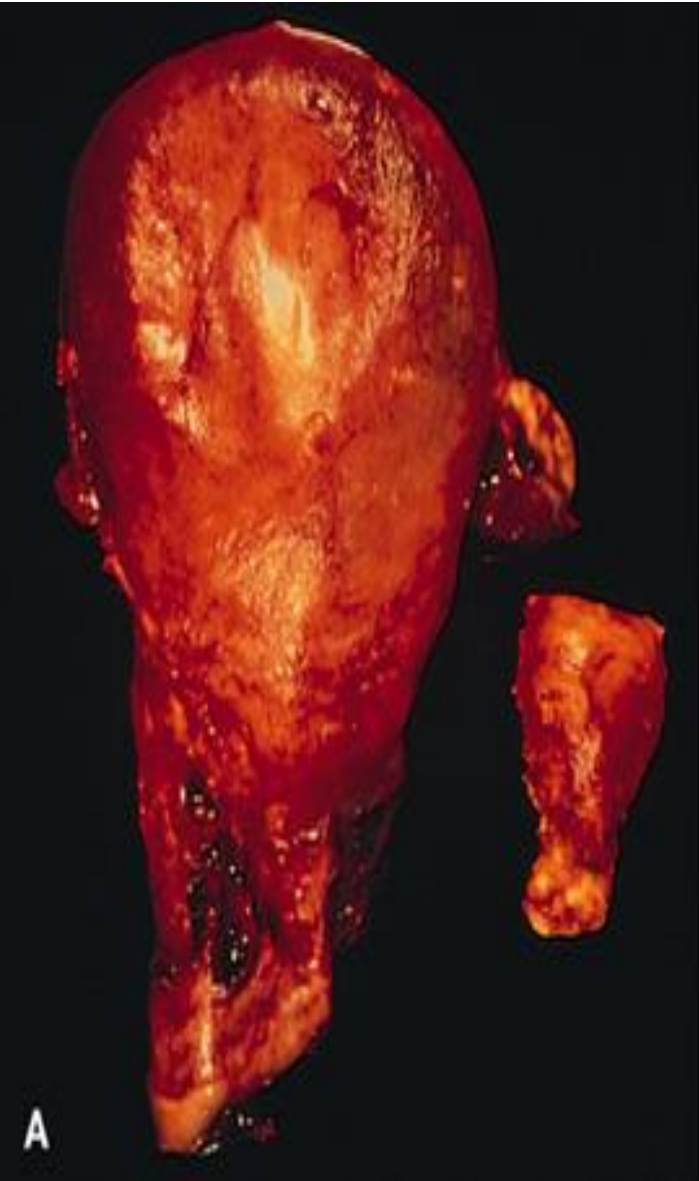

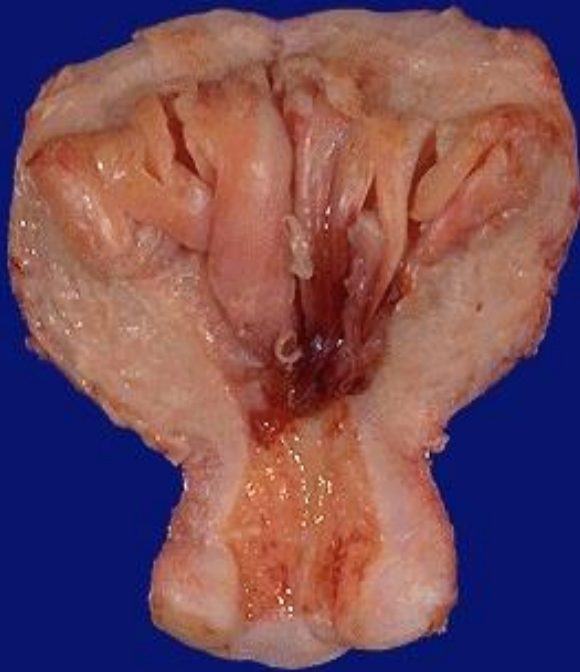Norm.

Hyperplasia.

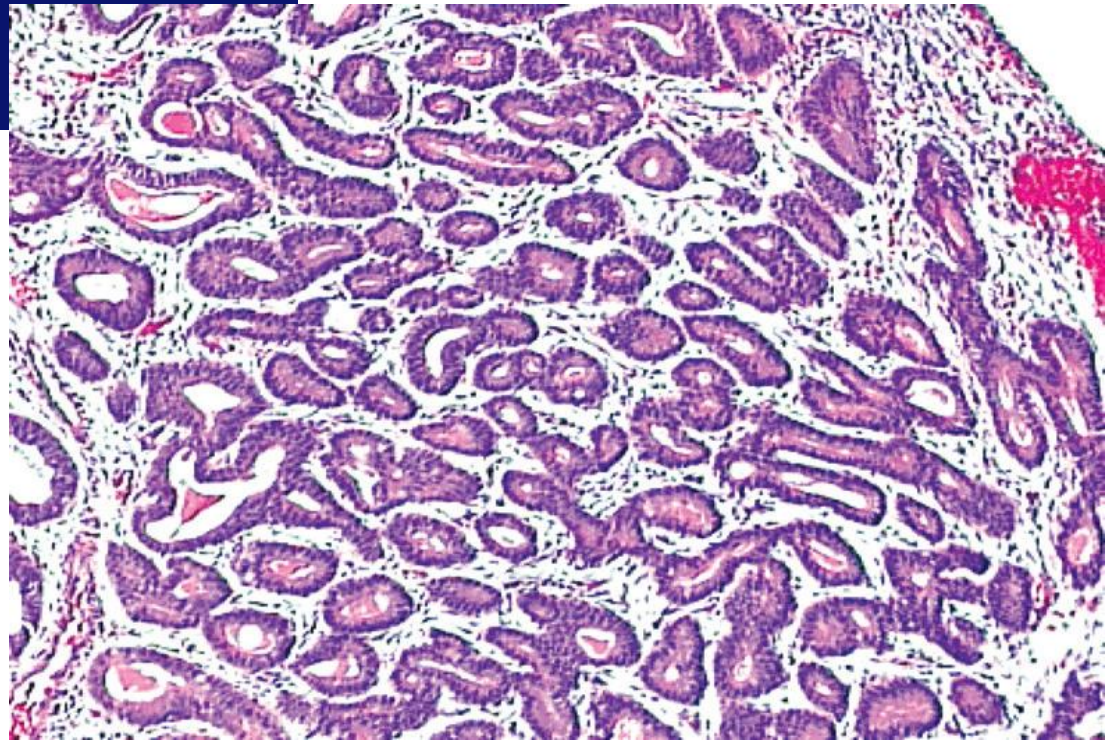


Physiological hypertrophy of the uterus.

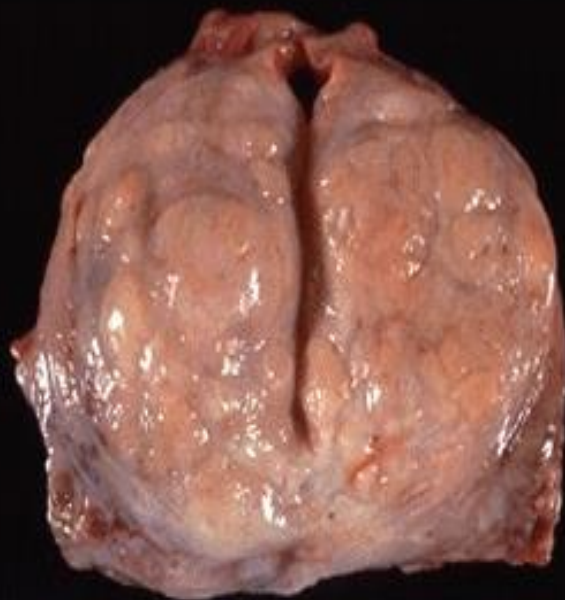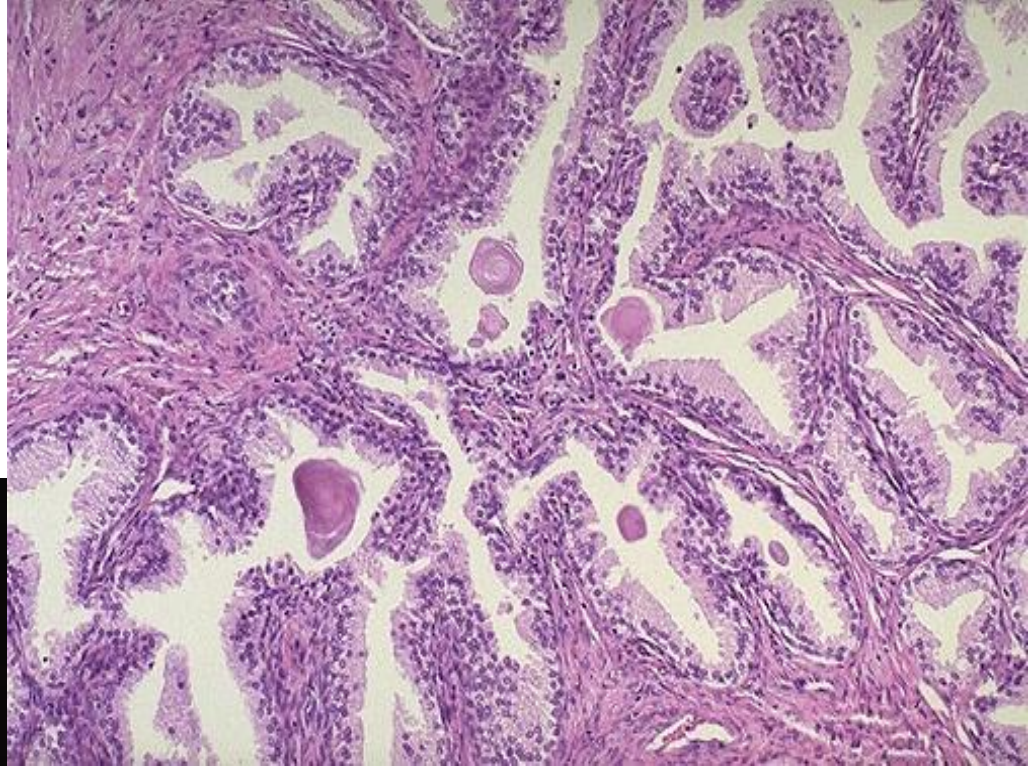


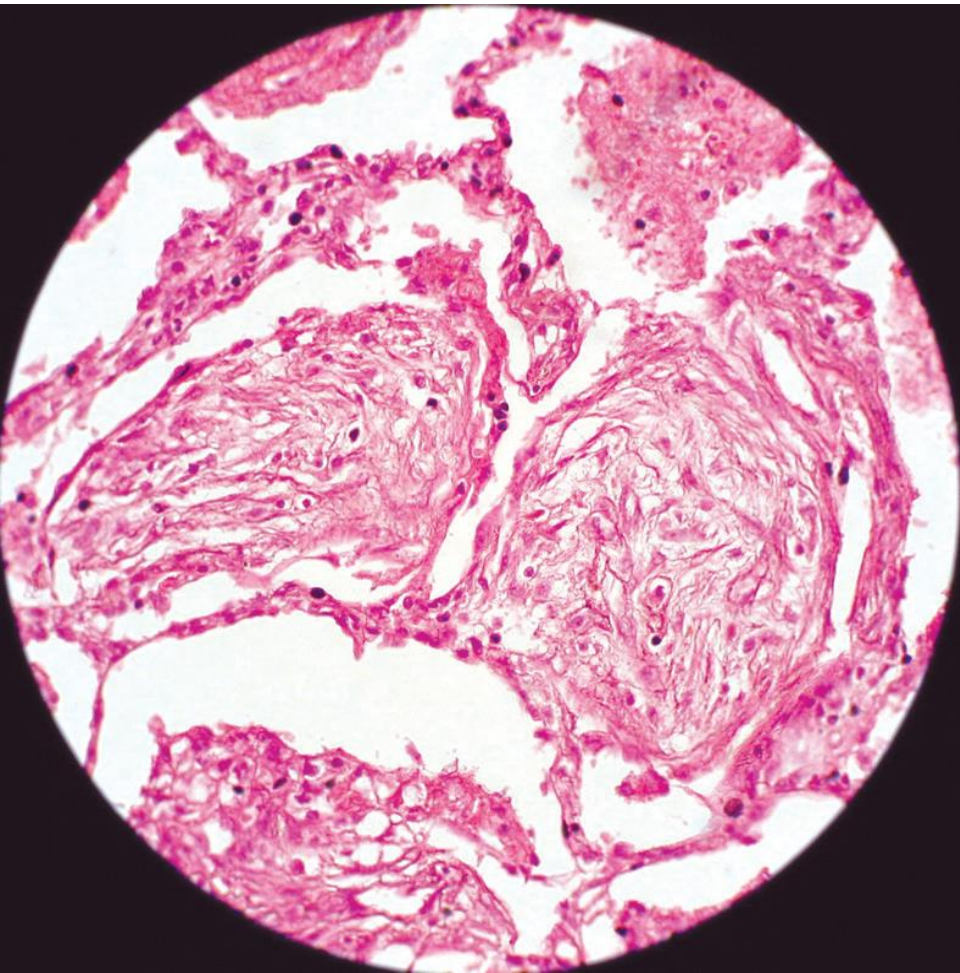


**Endometrial hyperplasia
(H-E stain).**

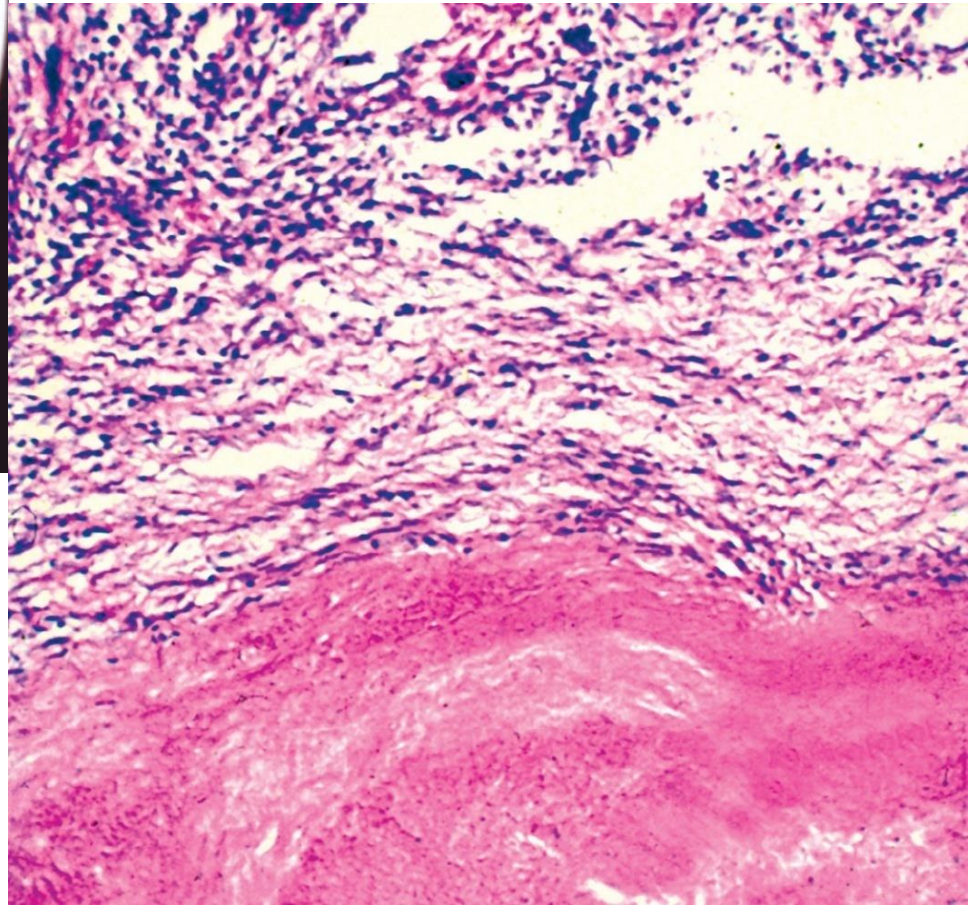


Benign Prostatic Hyperplasia

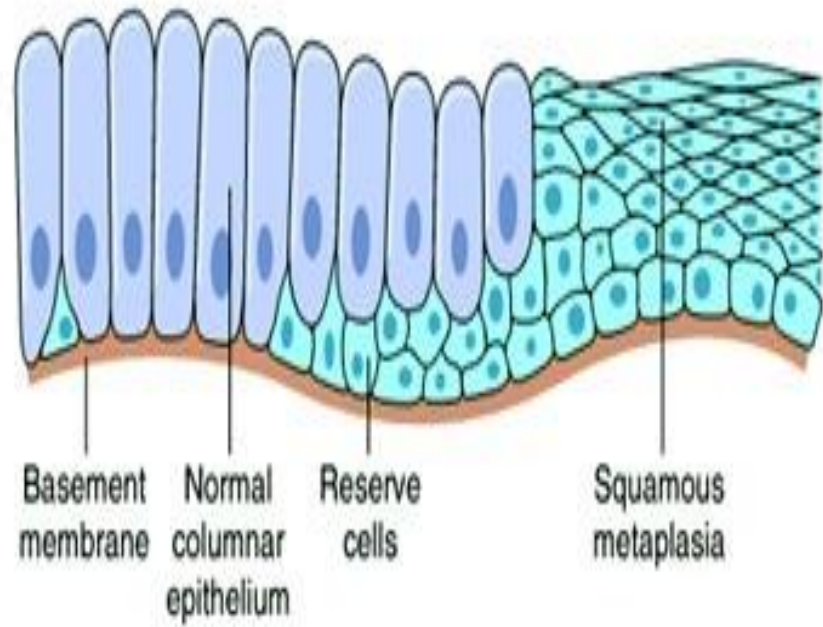
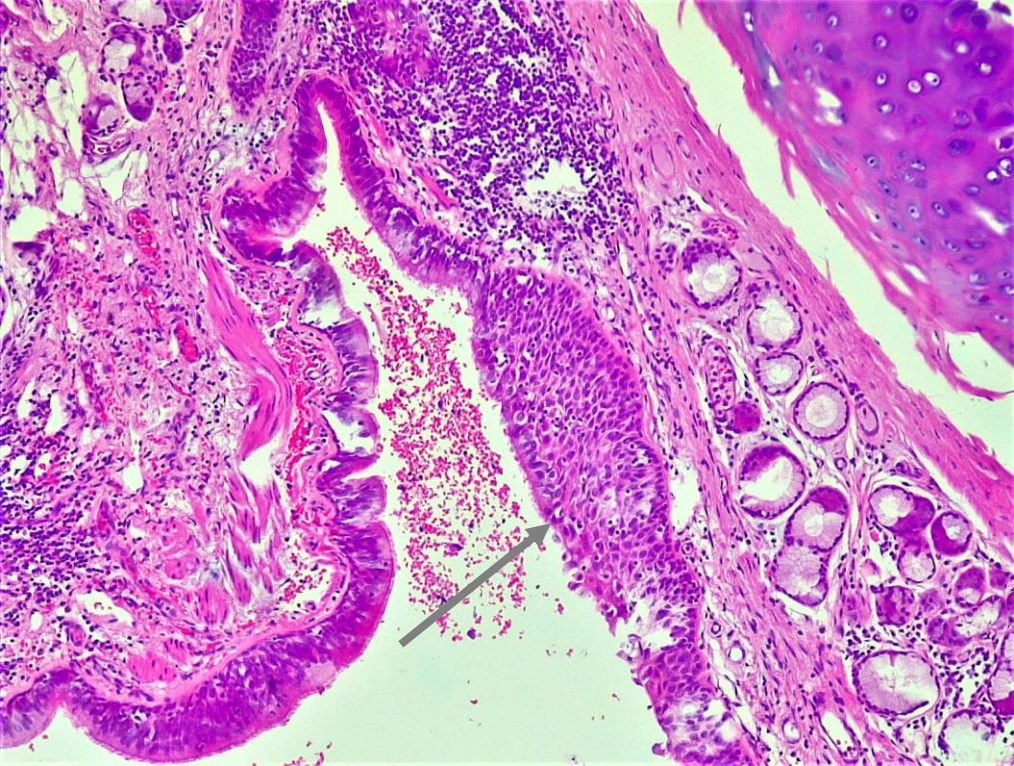




Encapsulation of the focus of caseous necrosis in tuberculosis.

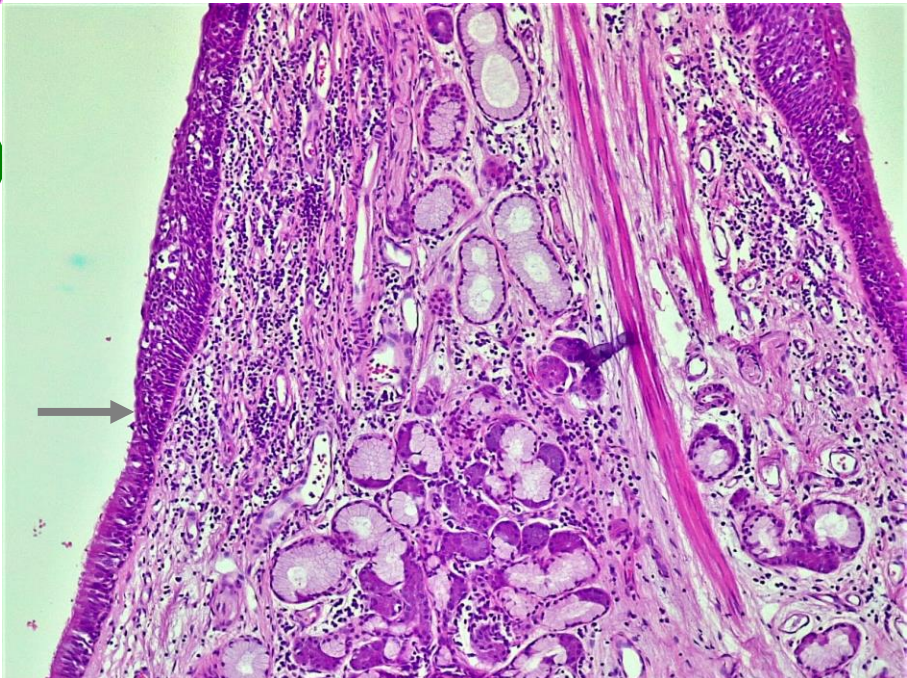


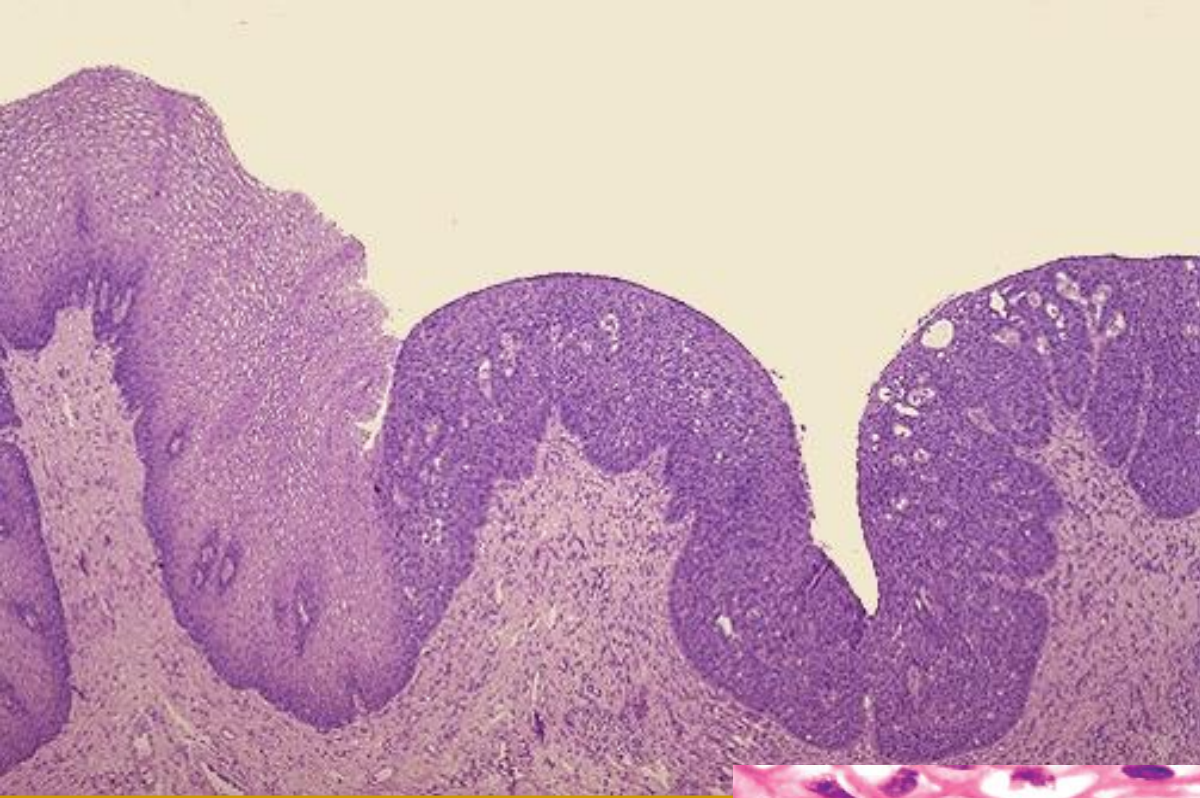
Organization of exudate in lungs alveoli.



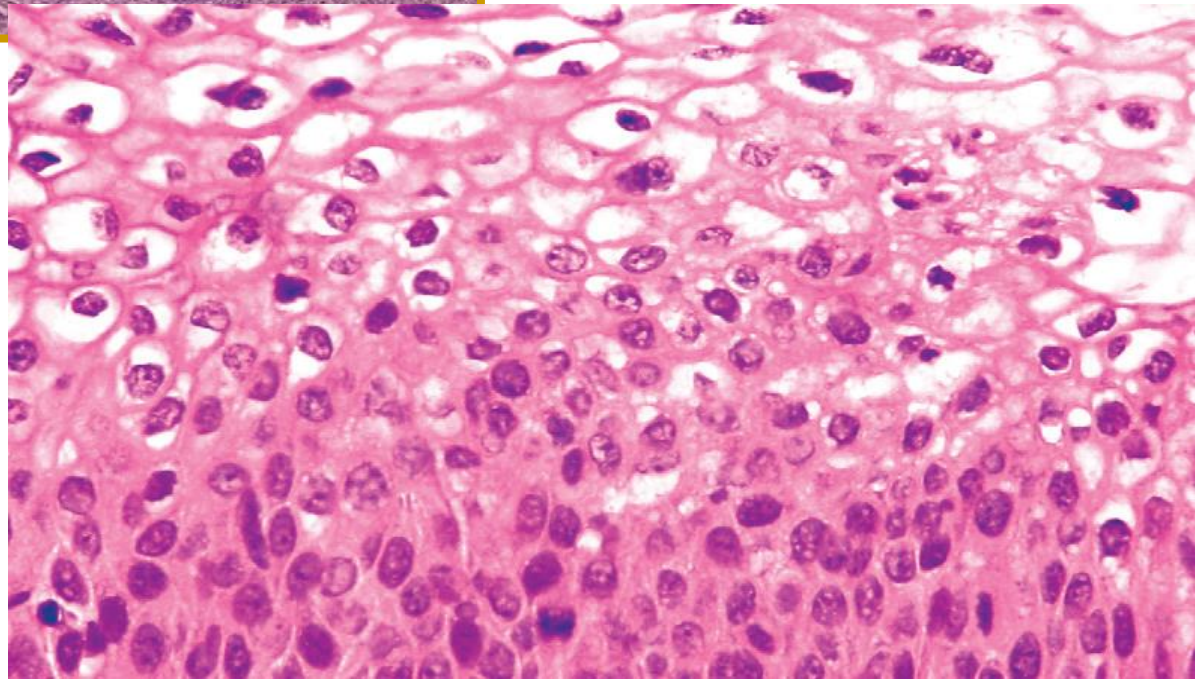
A

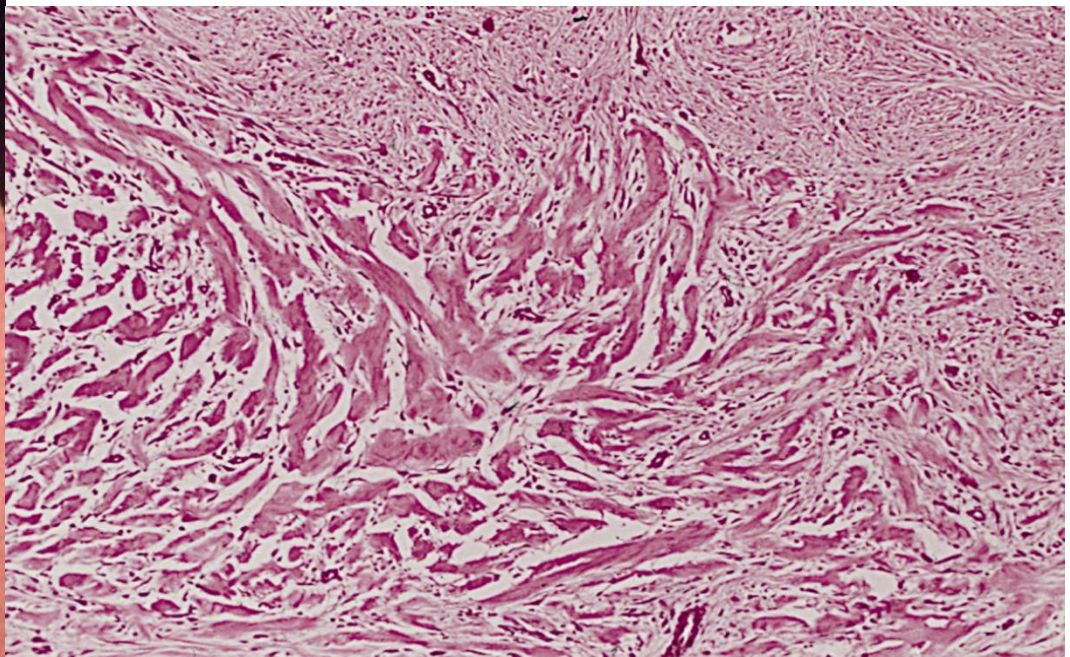
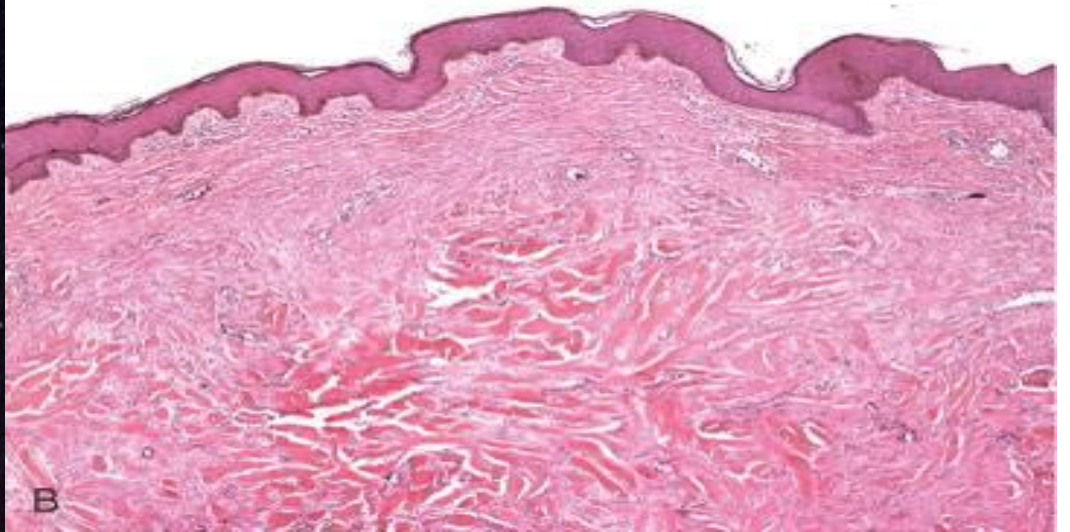
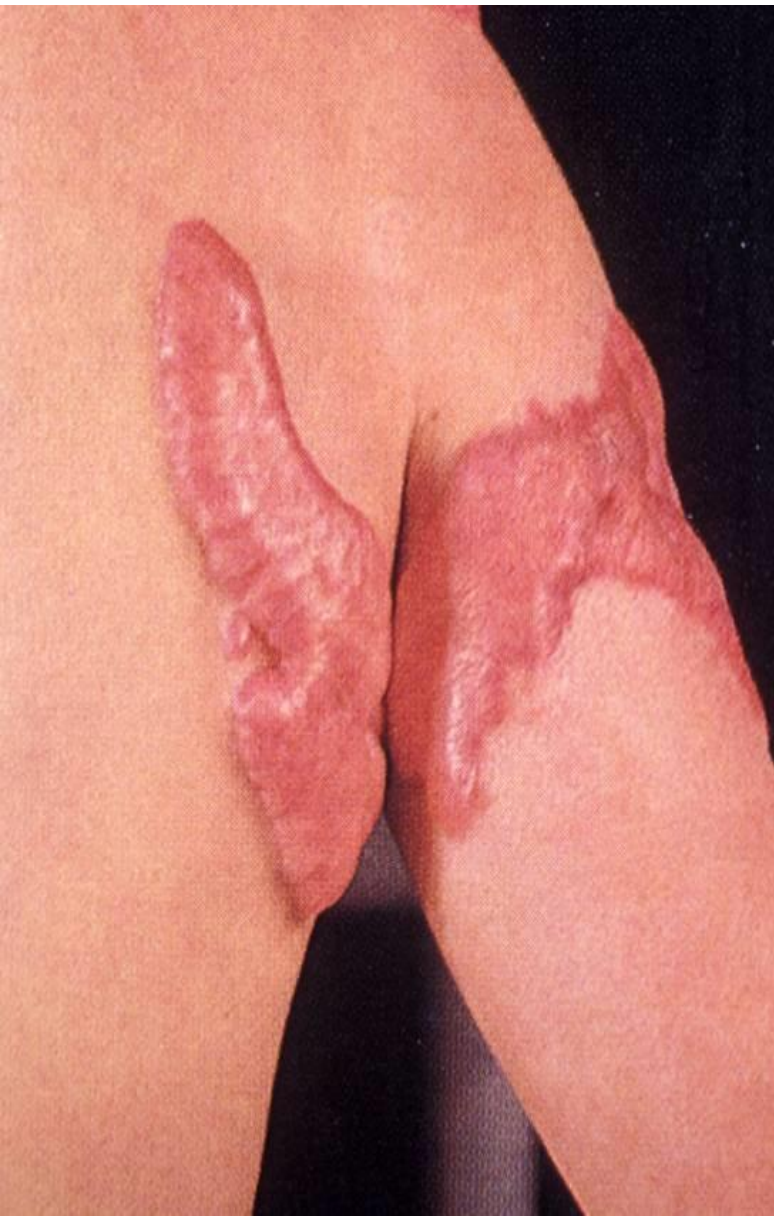Metaplasia of respiratory epithelium



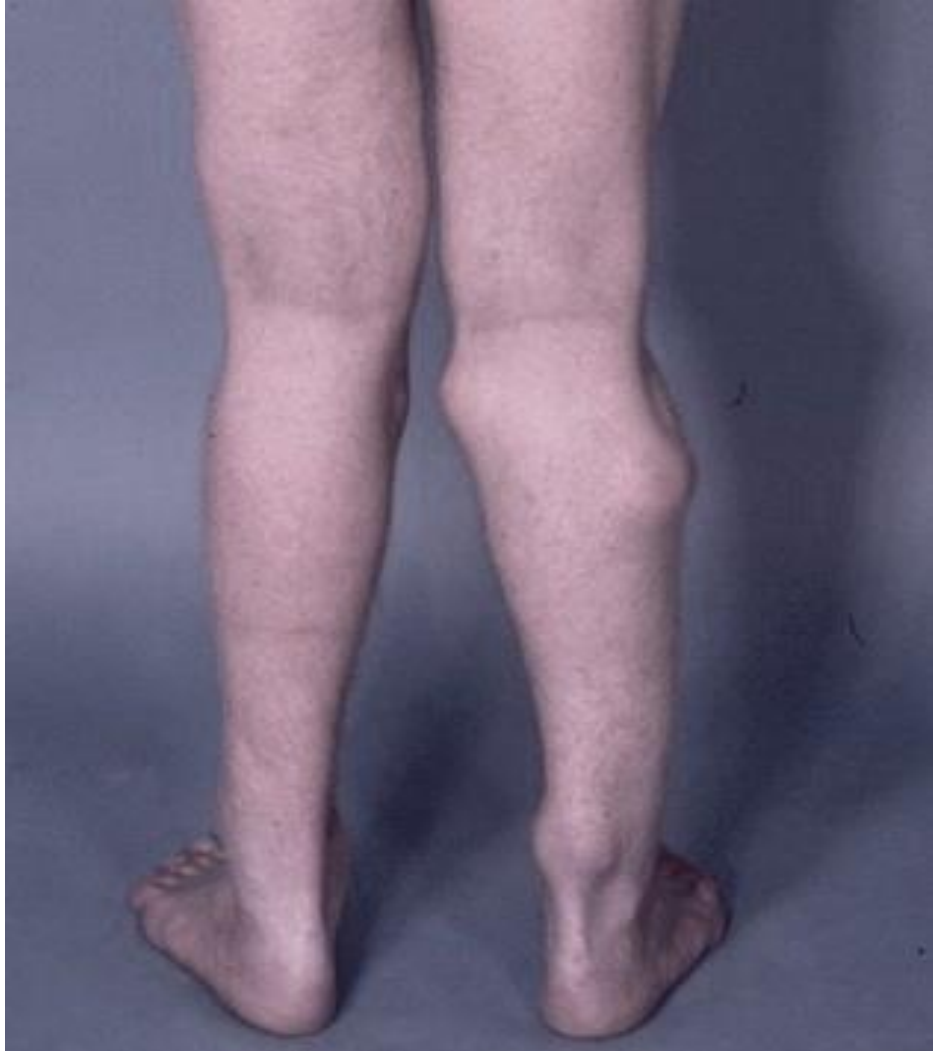

**Dysplasia of the
ectocervical
epithelium.**

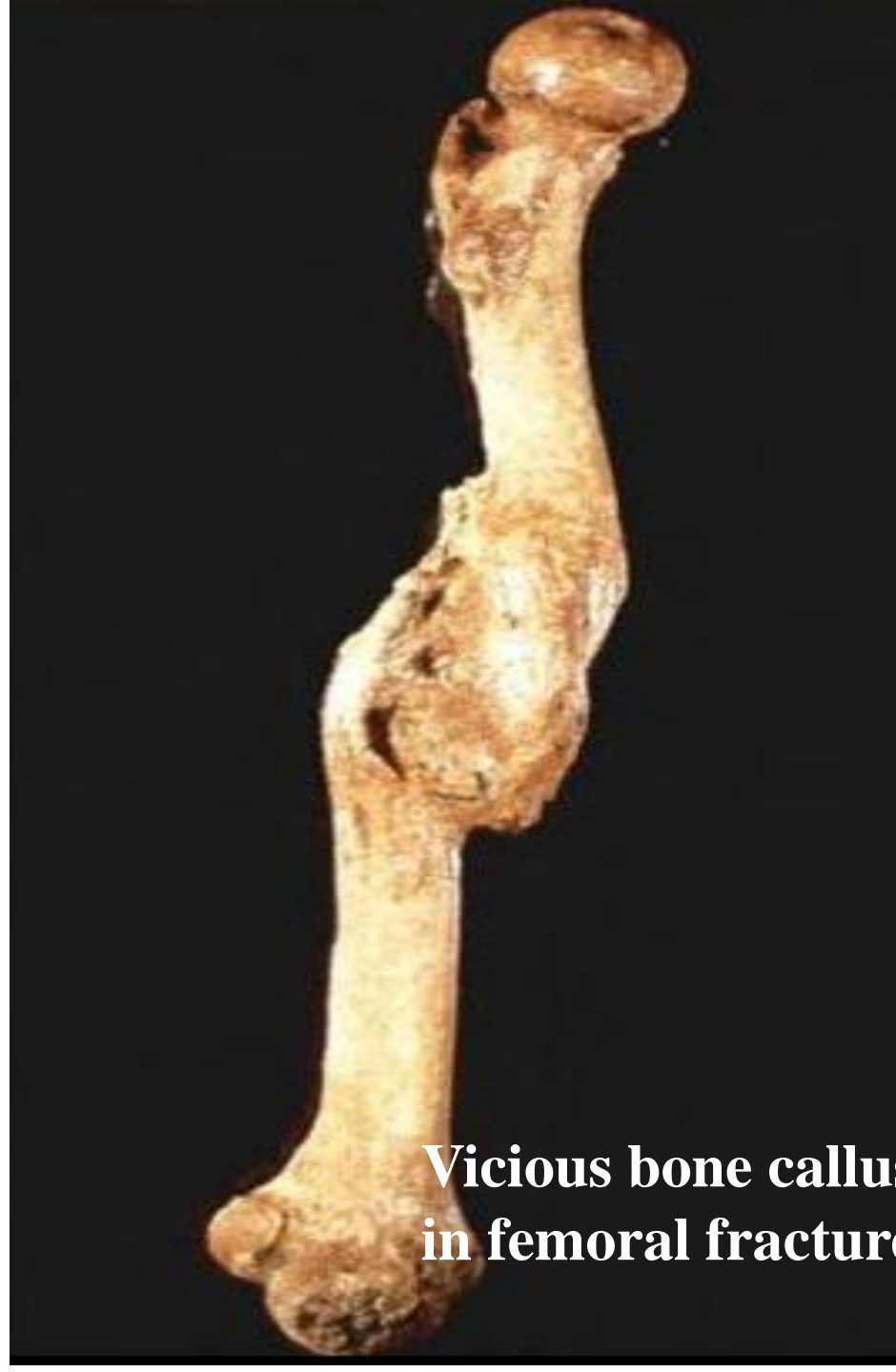



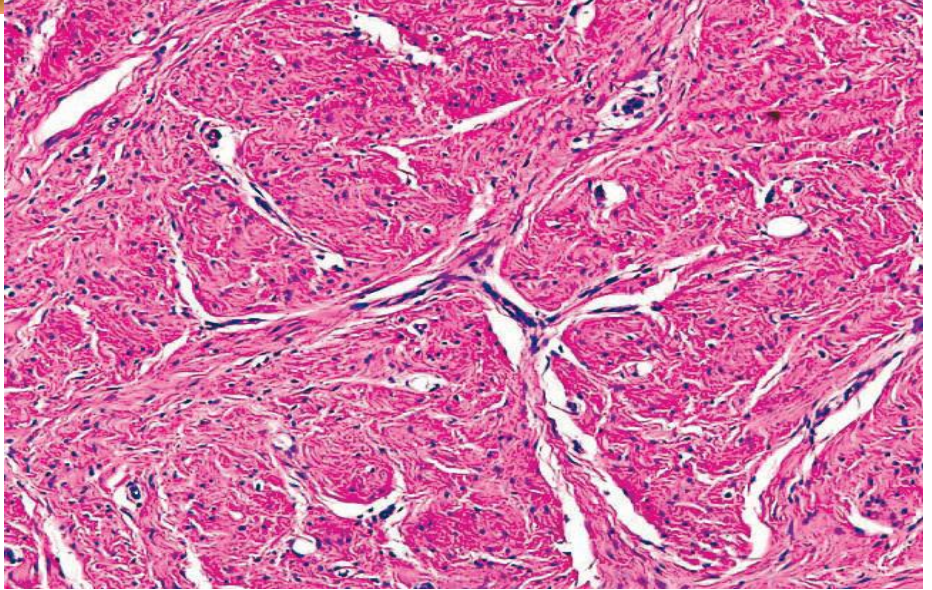
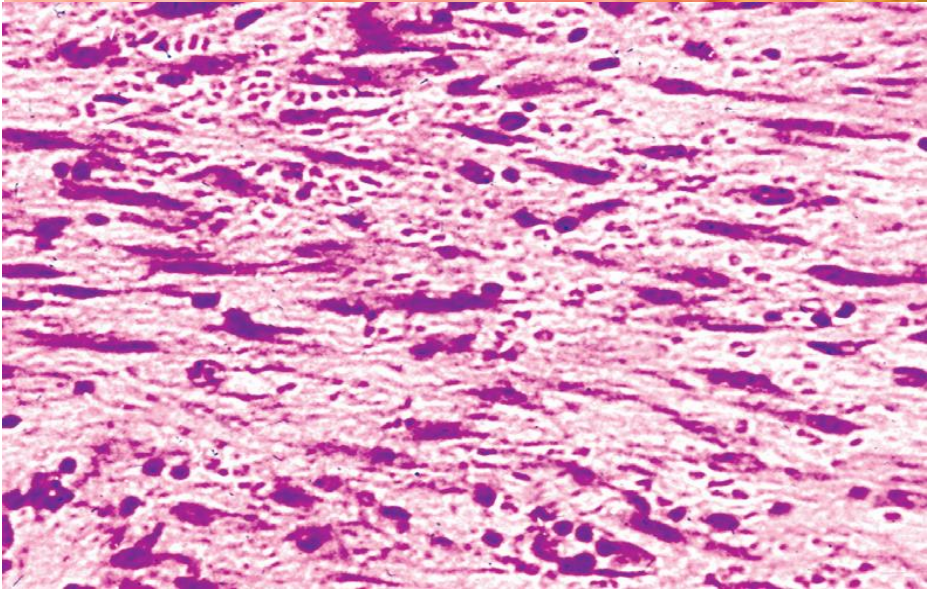
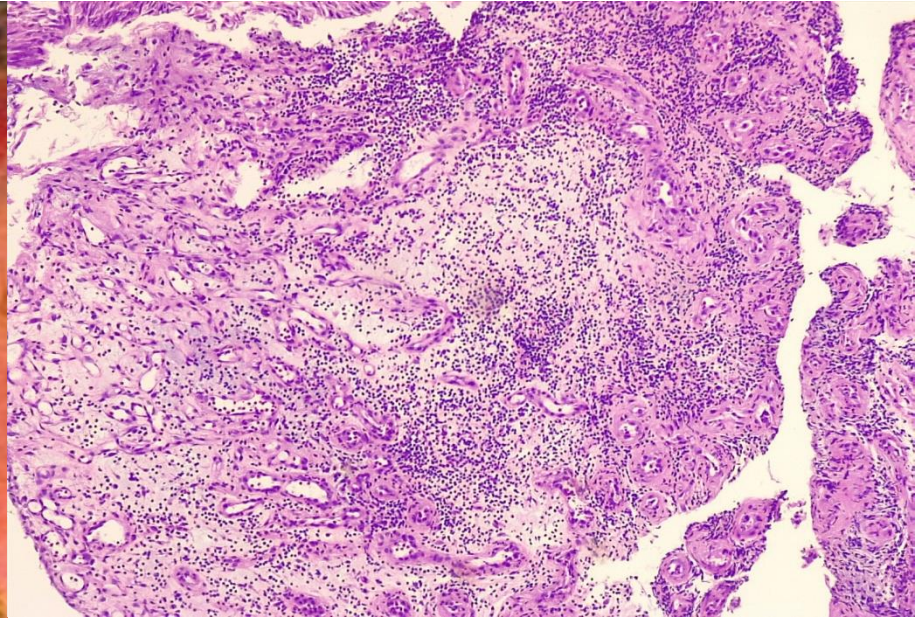
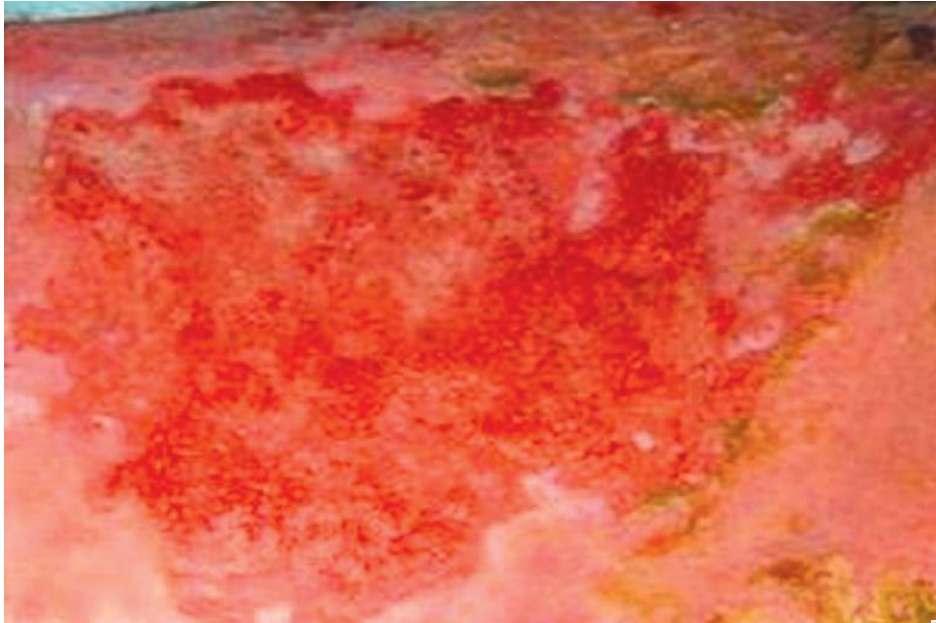Keloid scars.



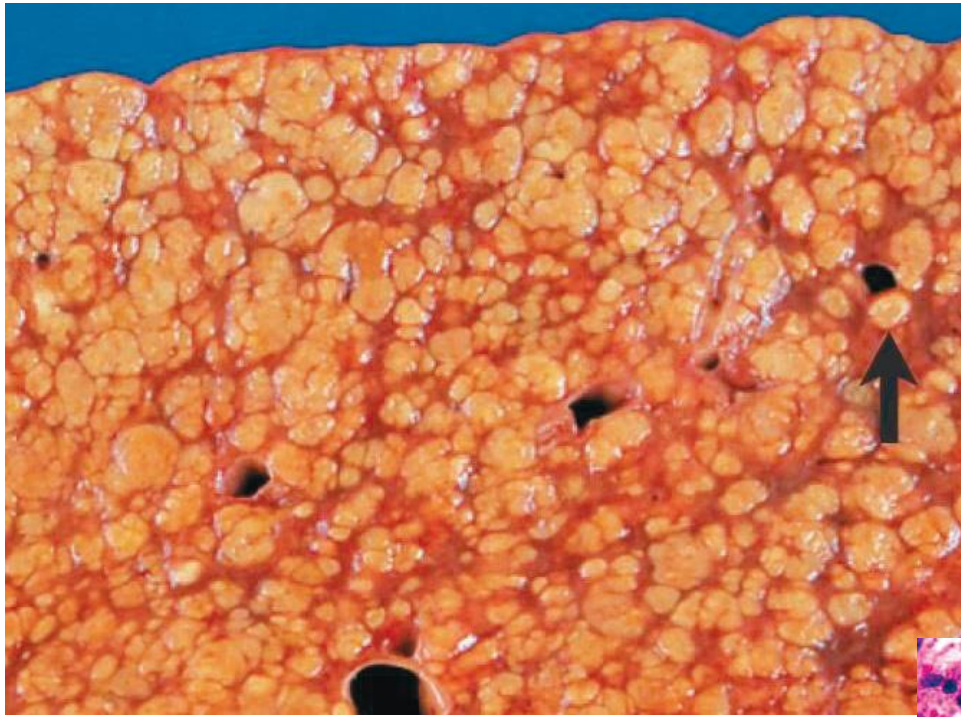
Bone exostosis



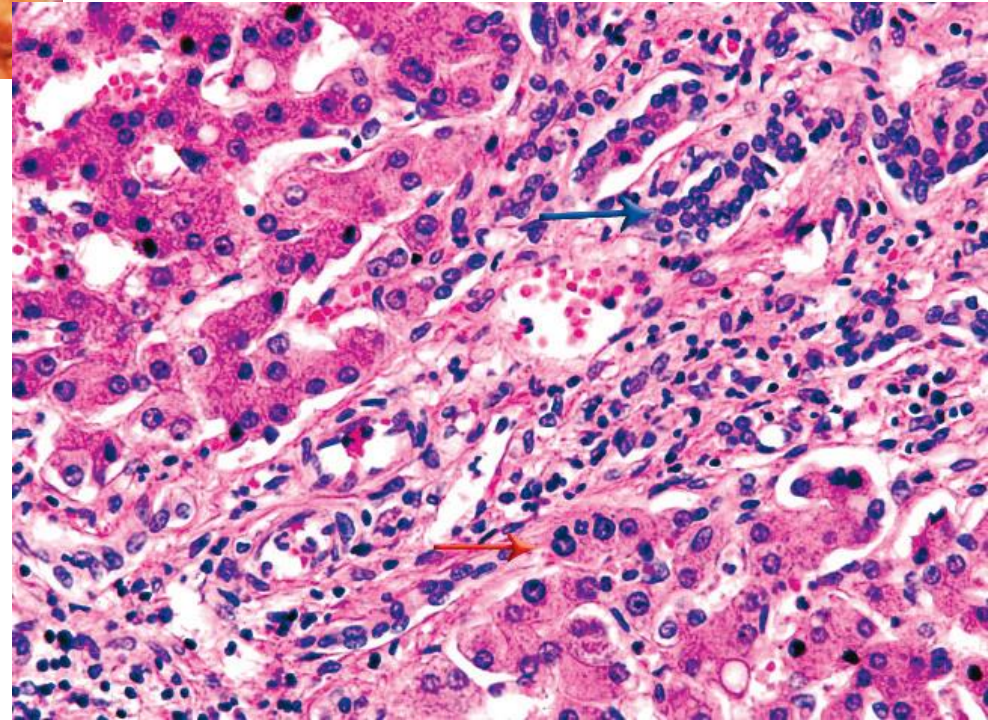
**Vicious bone callus
in femoral fracture**

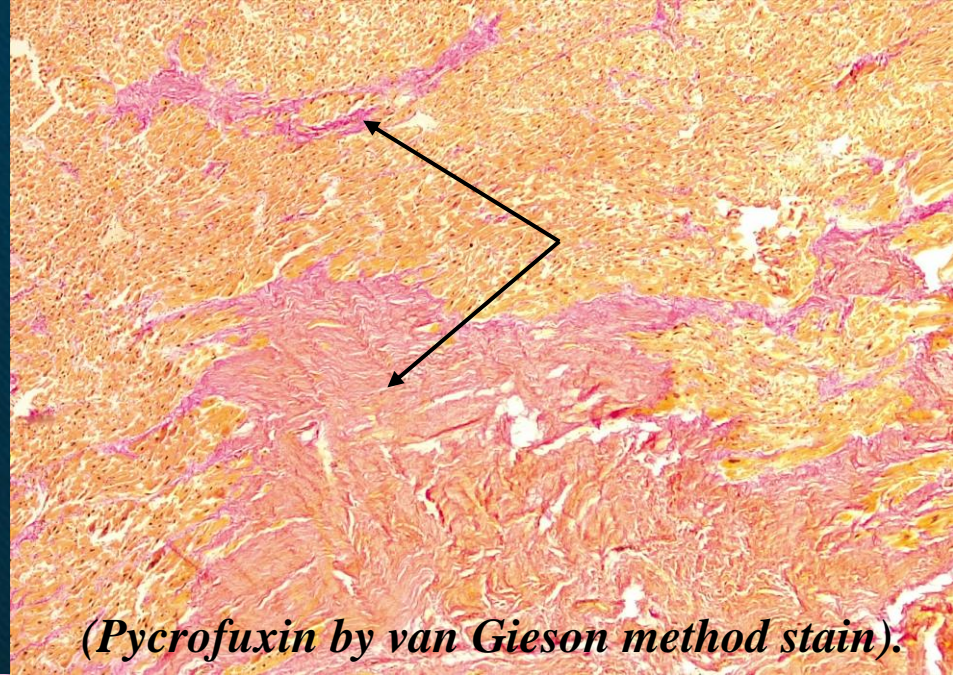
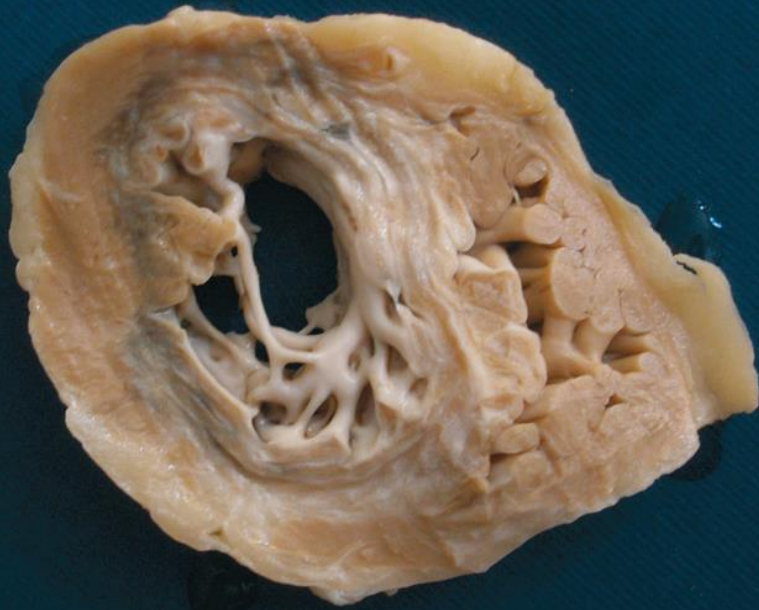
Granulation tissue.



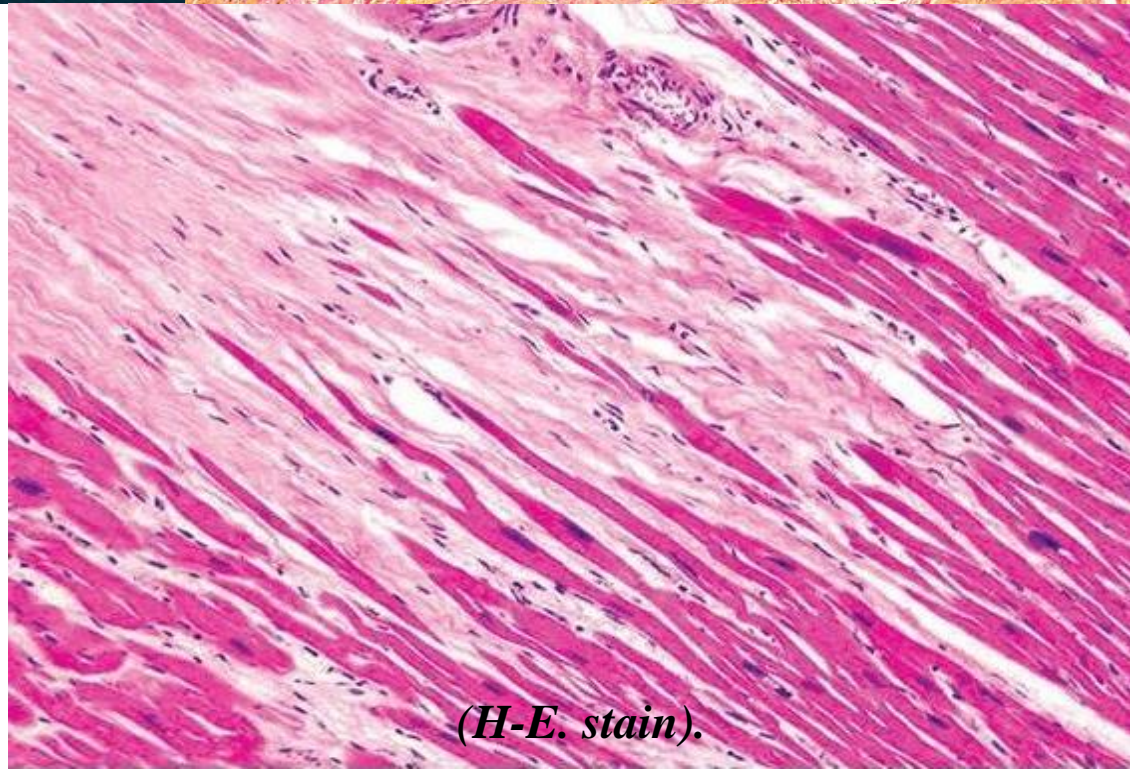
Liver regeneration in cirrhosis





(Picrofuxin by van Gieson method stain).

**Postinfarction macrofocal
cardiosclerosis.
Regenerative hypertrophy.**



(H-E. stain).



Hypertrophy

Physiological

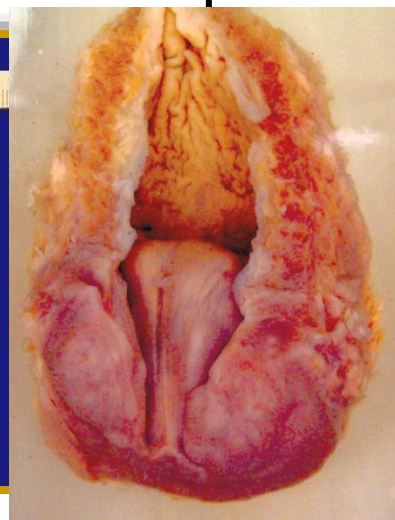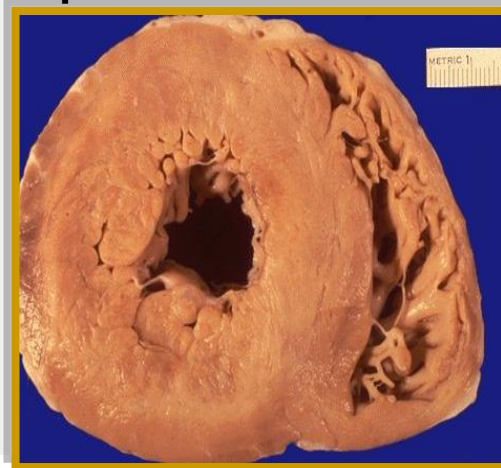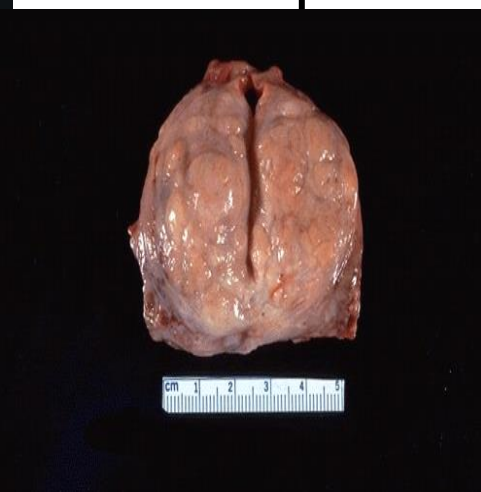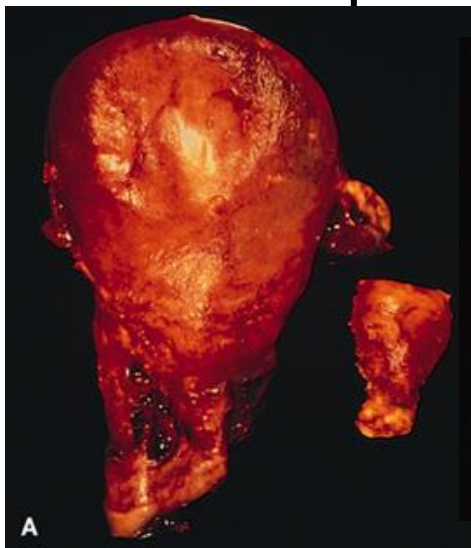Pathological

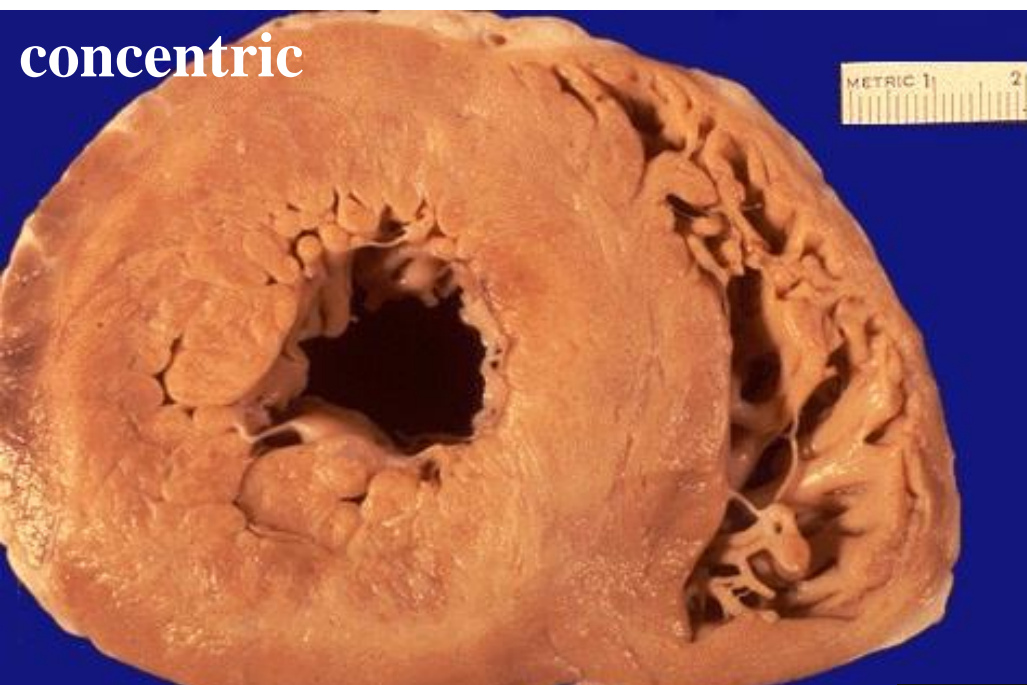
Physical exercises

Adaptive

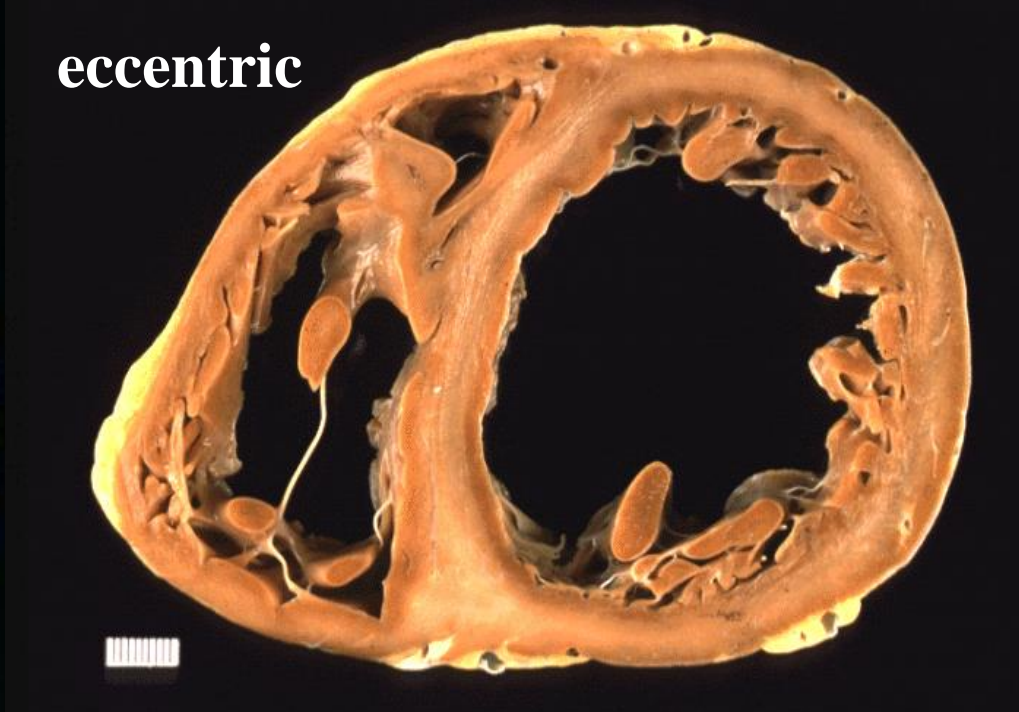
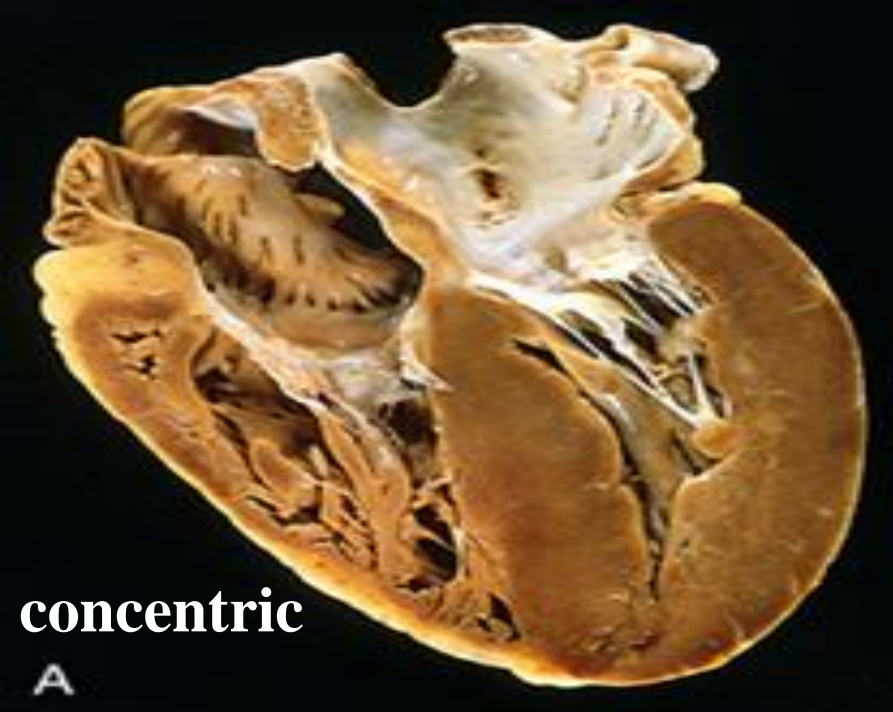
Adaptive

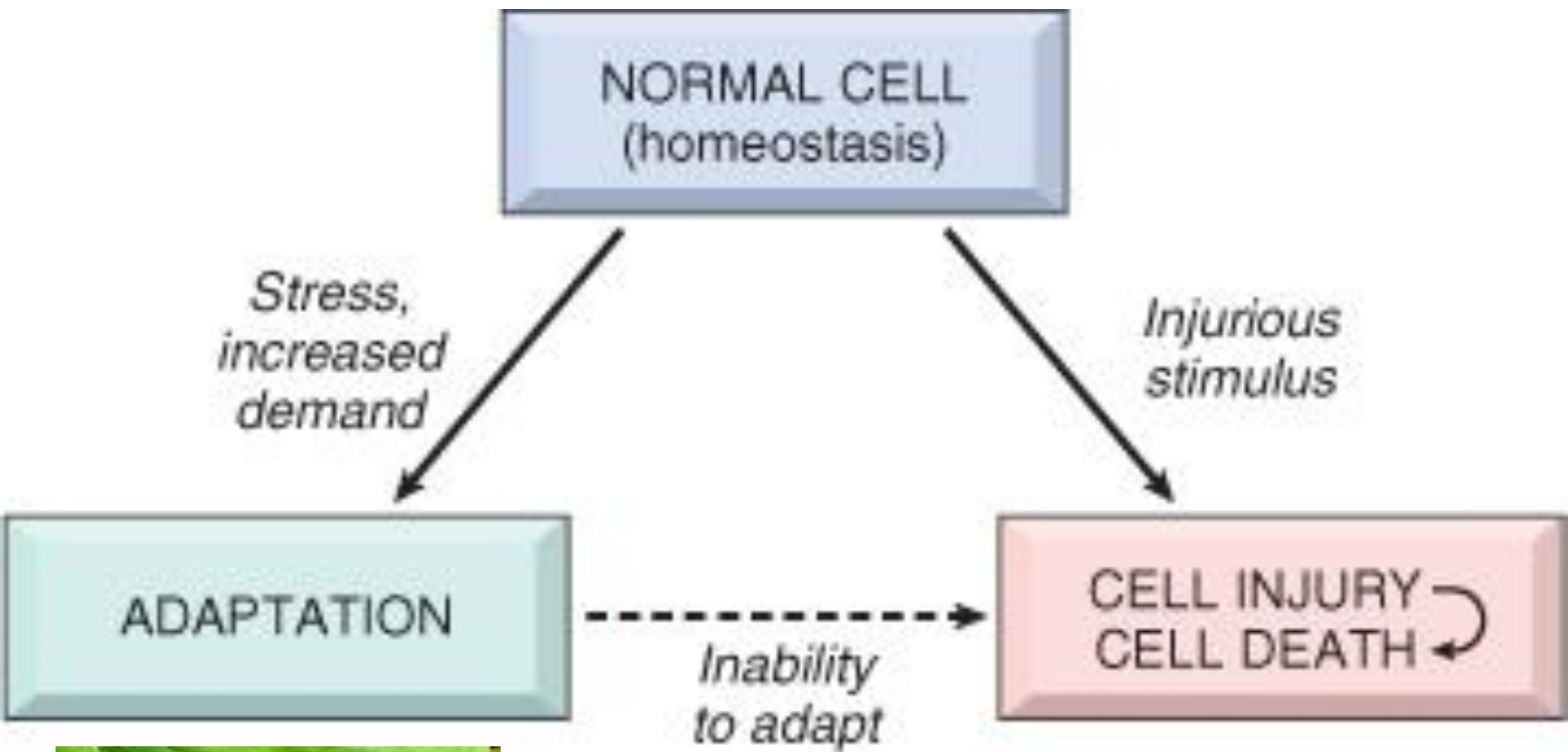
Compensatory





**Left ventricular
hypertrophy
of the heart.**





© Elsevier 2005



Cellular adaptations

Result from stress or pathologic stimuli

Give the cell better chance to survive

Change in number, size and differentiation

Is related w/cell growth or protein synth.

Cells must constantly adapt, even under normal conditions, to changes in their environment.

These physiological adaptations usually represent responses of cells to normal stimulation by hormones or endogenous chemical substances. For example, as in the enlargement of the breast and induction of lactation by pregnancy.

Pathologic adaptations may share the same underlying mechanisms, but they provide the cells with the ability to survive in their environment and perhaps escape injury.

Then cellular adaptation is a state that lies intermediate between the normal, unstressed cell and the injured, overstressed cell.

There are numerous types of cellular adaptations: some involve up or down regulation of specific cellular receptors involved in metabolism of certain components.

Others are associated with the induction of new protein synthesis by the target cell.

Other adaptations involve a switch by cells from producing one type of a family of proteins to another or markedly overproducing one protein.

These adaptations then involve all steps of cellular metabolism of proteins—receptor binding, signal transduction, transcription, translation, or regulation of protein packaging and release.

In this section we consider some common adaptive changes in cell growth, size, and differentiation that underlie many pathologic processes.

■ Cellular Adaptations

Size

- Atrophy**
1. Disuse
 2. Loss of endocrine stimulation
 3. Denervation
 4. Inadequate nutrition
 5. Ischemia

Hypertrophy

Number

Hyperplasia

Intracellular Accumulations

Calcifications

Dystrophic

Metastatic

Type

Metaplasia

Dysplasia

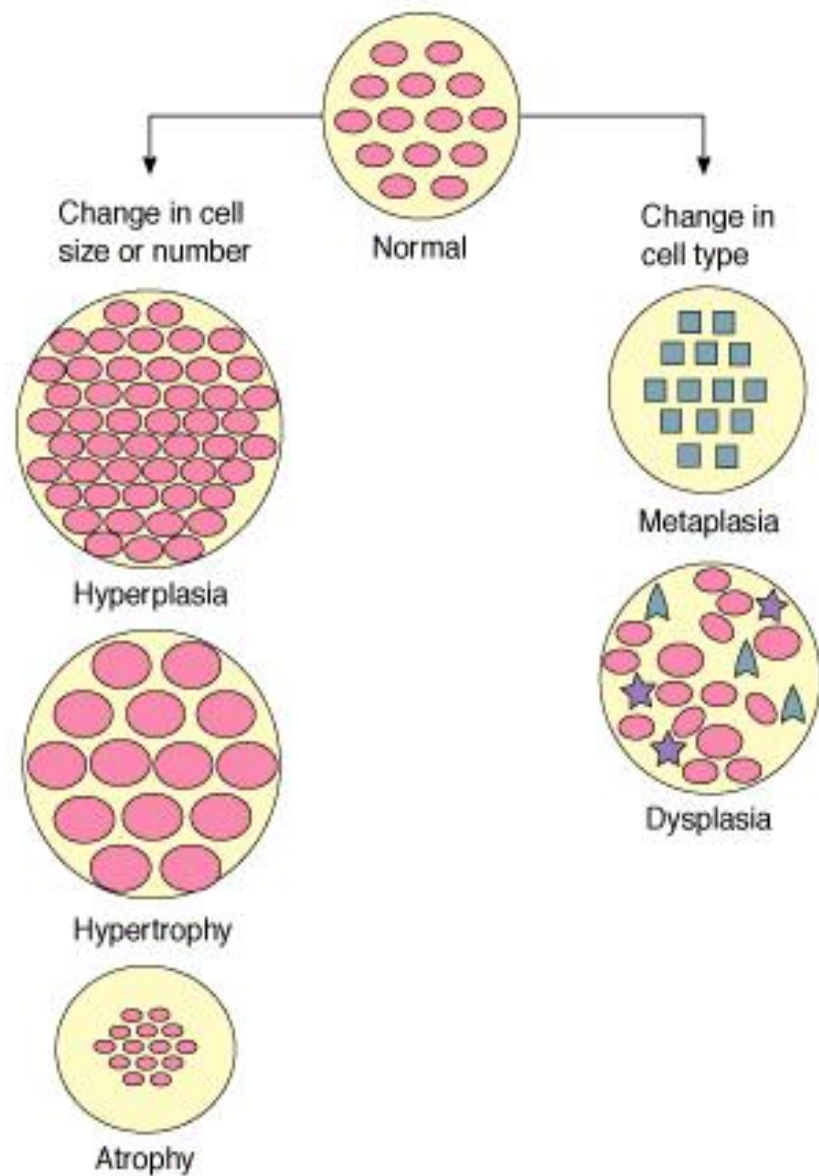


Figure 5-1 Adaptive tissue (*large circles*) and cell responses involving a change in number (hyperplasia), cell size (hypertrophy and atrophy), cell type (metaplasia), or size, shape, and organization (dysplasia).

INCREASED DEMAND OR INCREASED
TROPIC STIMULATION.

HYPERPLASIA – PHYSIOLOGIC
- PATHOLOGIC

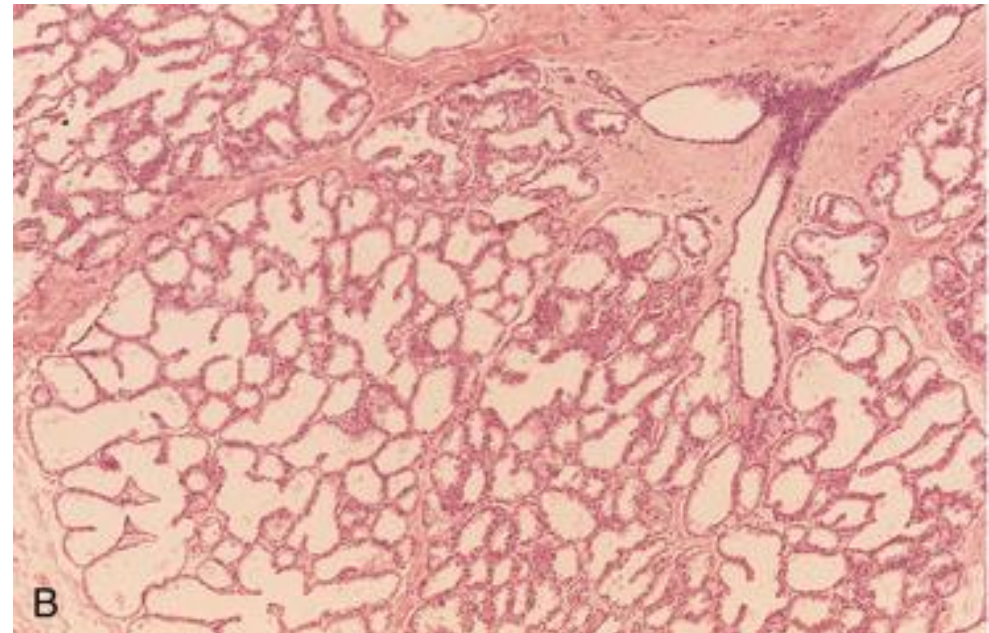
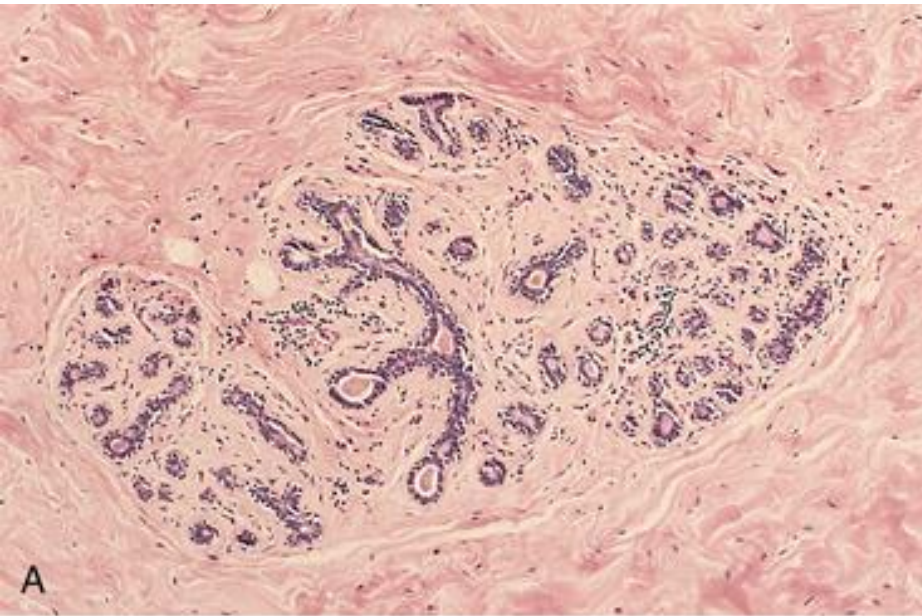
HYPERTROPHY.

1. Hyperplasia

(1) **Definition:** An increase in the number of cells in an organ or tissue, which may then have increased volume.

(2) **Types:**

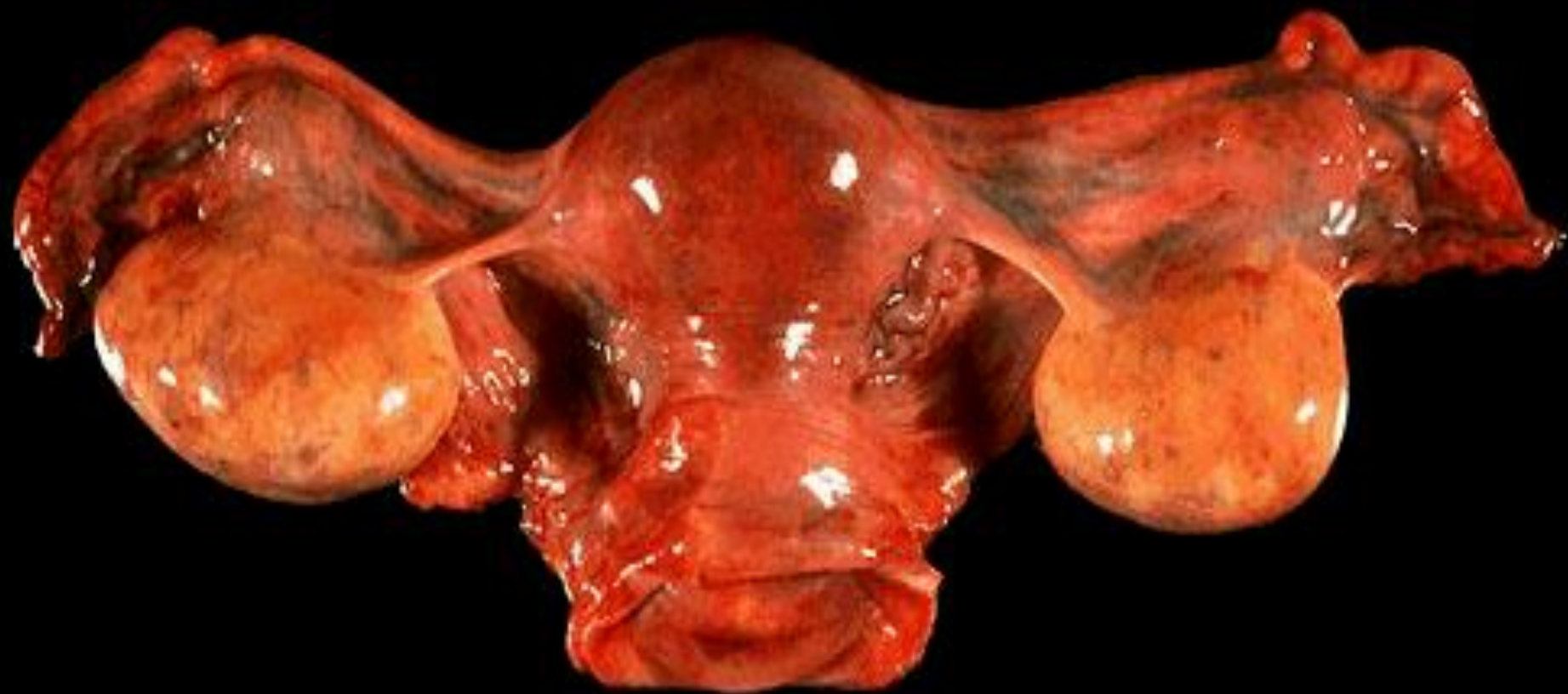
- **Physiologic:** Response to need, e. g. hyperplasia of the female breast epithelium at puberty or in pregnancy.



Left Normal breast

Right Hyperplasia

(From ROBBINS BASIC PATHOLOGY, 2003)



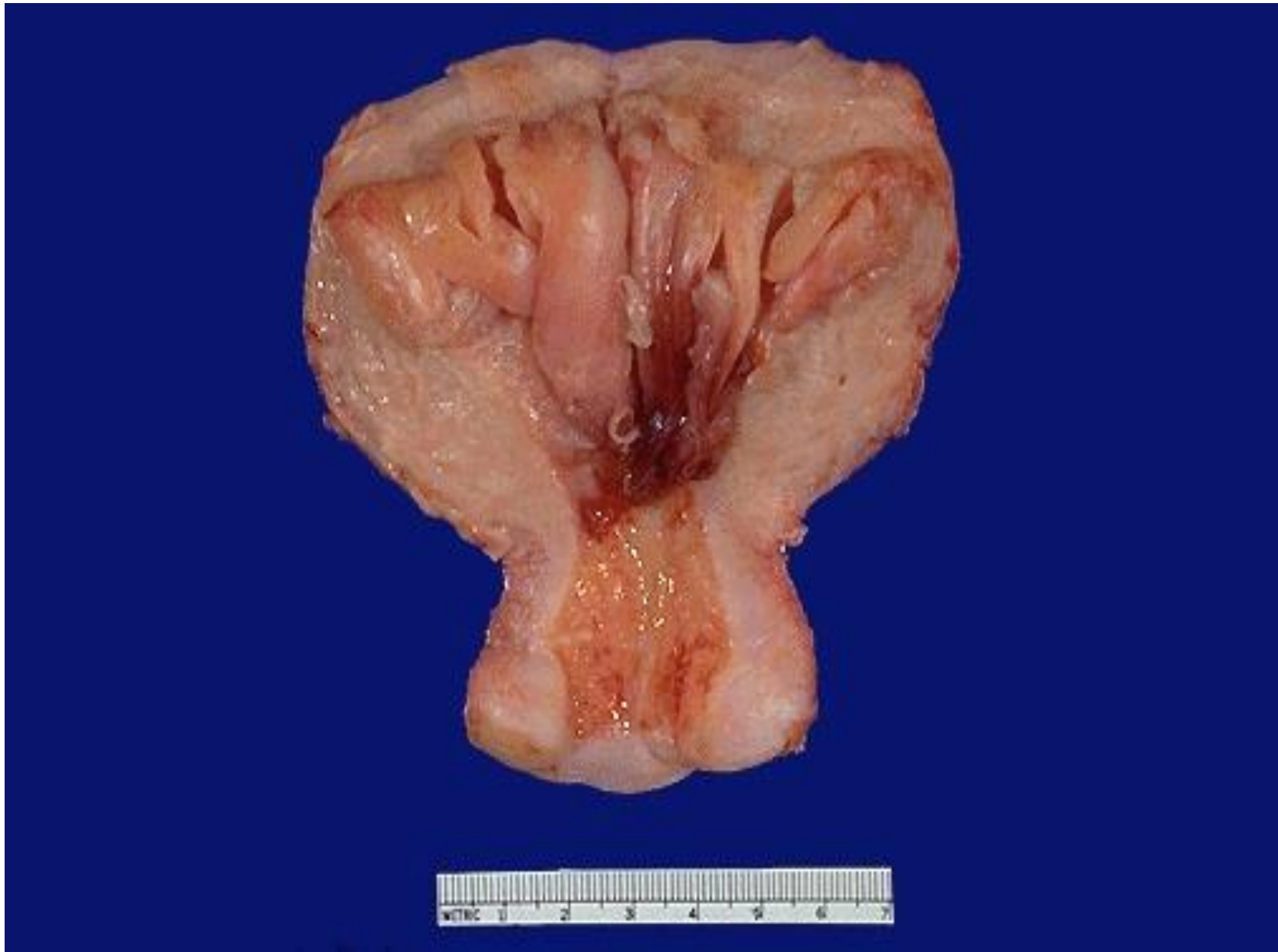- Compensatory: Response to deficiency, e. g. Hyperplasia following surgical removal of part of liver or of one kidney; hyperplasia of the bone marrow in anemia.
- Excessive stimulation: **Pathologic**: as in ovarian tumor producing estrogen and stimulating endometrial hyperplasia; pancreatic islet hyperplasia in infants of a diabetic mother (stimulated by high glucose level).

- Failure of regulation: **Pathologic**, as in hyperthyroidism or as in hyperparathyroidism resulting from renal failure or vitamin D deficiency.
- Neoplastic: Total loss of normal control mechanism. Should not be termed hyperplasia.
- Hyperplasia is also an important response of connective tissue cells in wound healing, in which proliferating fibroblasts and blood vessels aid in repair.

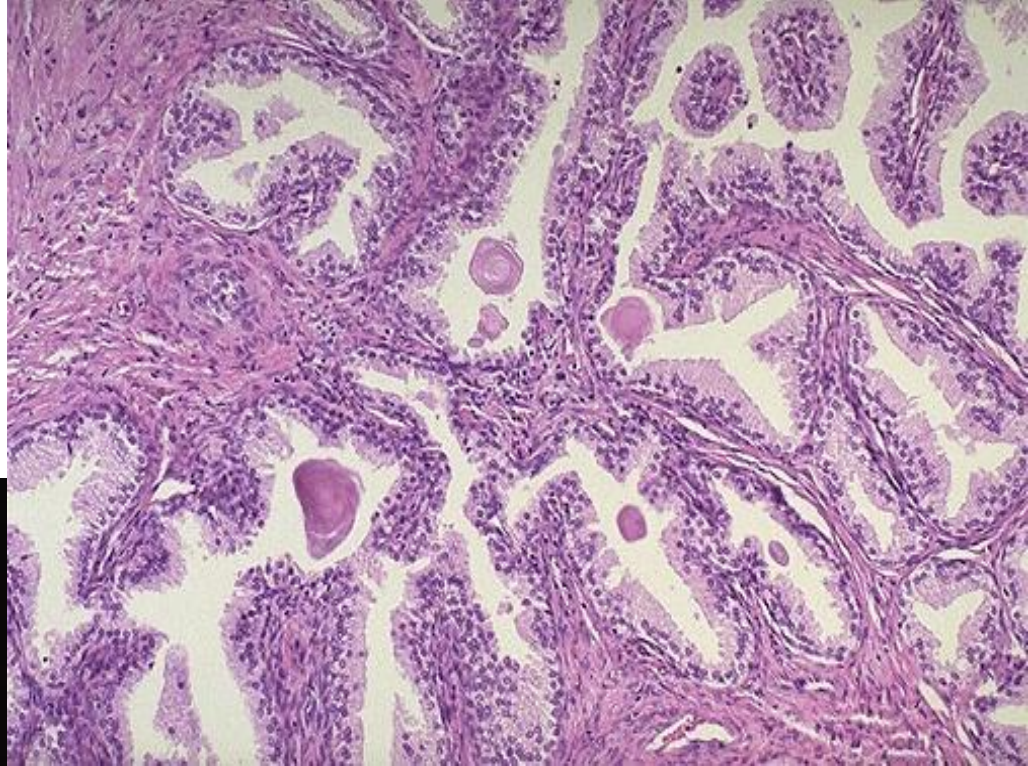
Pathologic hyperplasia

Increased G. F. stimuli & particularly....
HORMONES.

UTERUS



PROSTATE



(3) *Mechanisms:*

Most forms of pathologic hyperplasia are instances of excessive hormonal stimulation or are the effects of growth factors on target cells.

2. Hypertrophy:

(1) **Definition:** An increase in the size of cells, and with such change, an increase in the size of the organ.



Hypertrophy

- Non-dividing cells
- Synthesis of structural components
- Mechanisms:
 - TGF- β , IGF-1, FGF.
 - Epinephrin, angiotensin II, endothelin-1.
 - Other.

(2) Types:

- **Physiologic:** i. e. the physiologic growth of the uterus during pregnancy involves both hypertrophy and hyperplasia. The cellular hypertrophy is stimulated by estrogenic hormones through smooth muscle estrogen receptors.

- *Pathologic: causes:*

- increased workload, hormonal stimulation and growth factors stimulation.

i.e. hypertrophy of heart the most common stimulus is chronic hemodynamic overload, due either to hypertension or to faulty valves. It eventually reaches a limit beyond which enlargement of muscle mass is no longer able to compensate for the increased burden, and cardiac failure ensues.

Hypertrophy

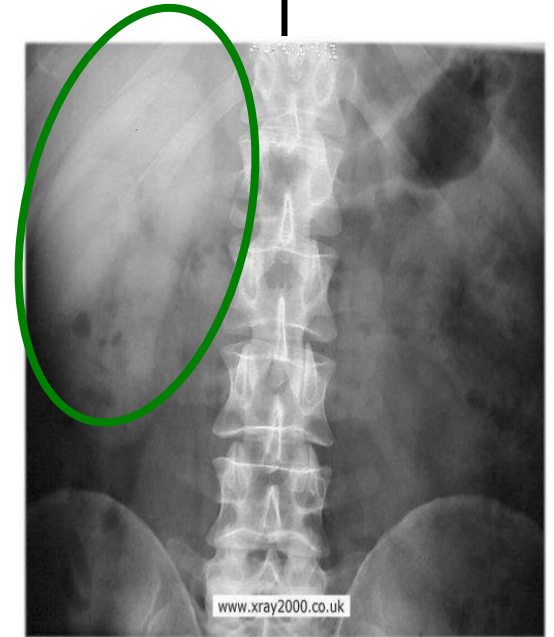
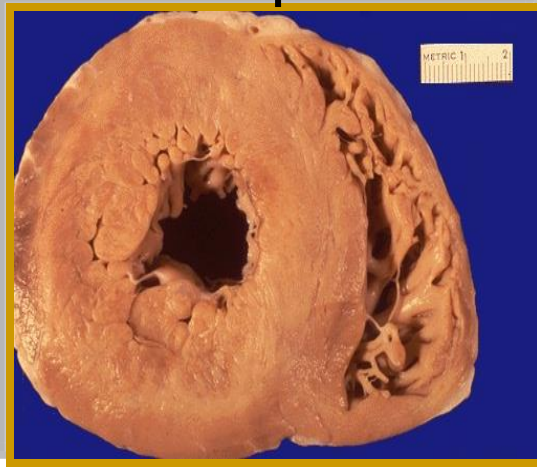Physiologic

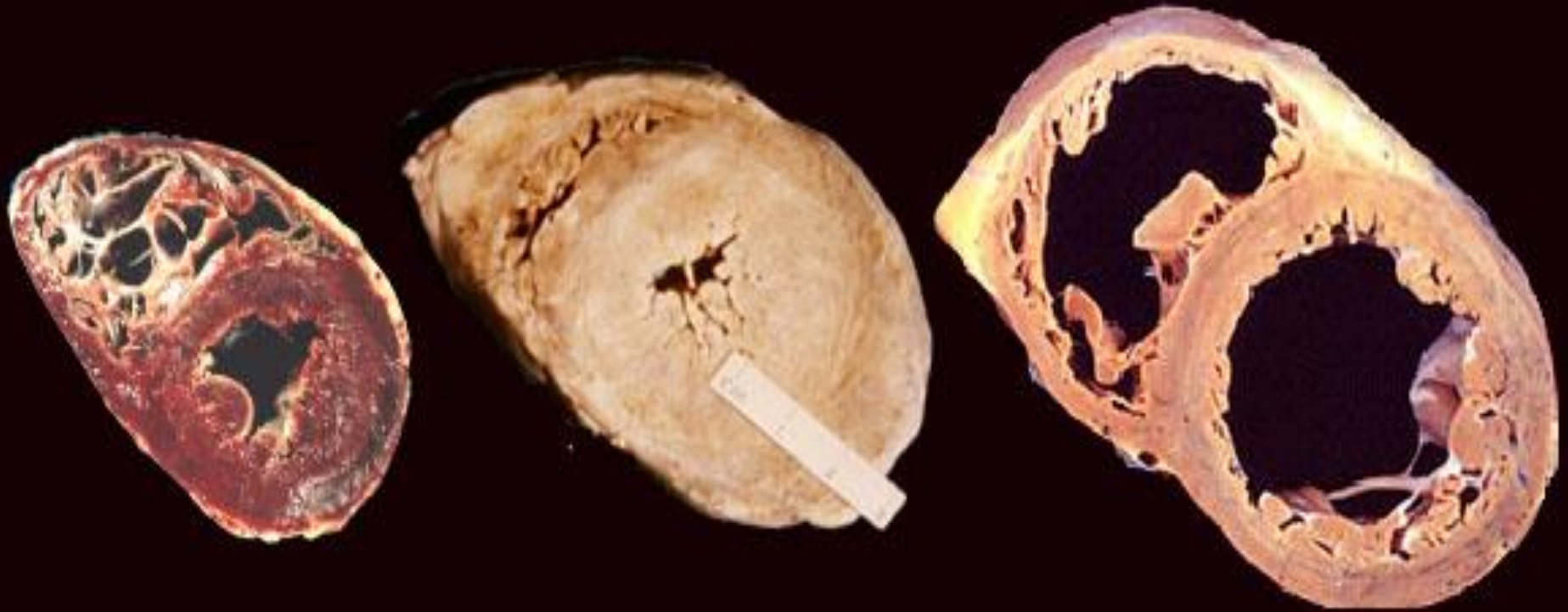
Pathologic

Exercise

Adaptive

Compensatory

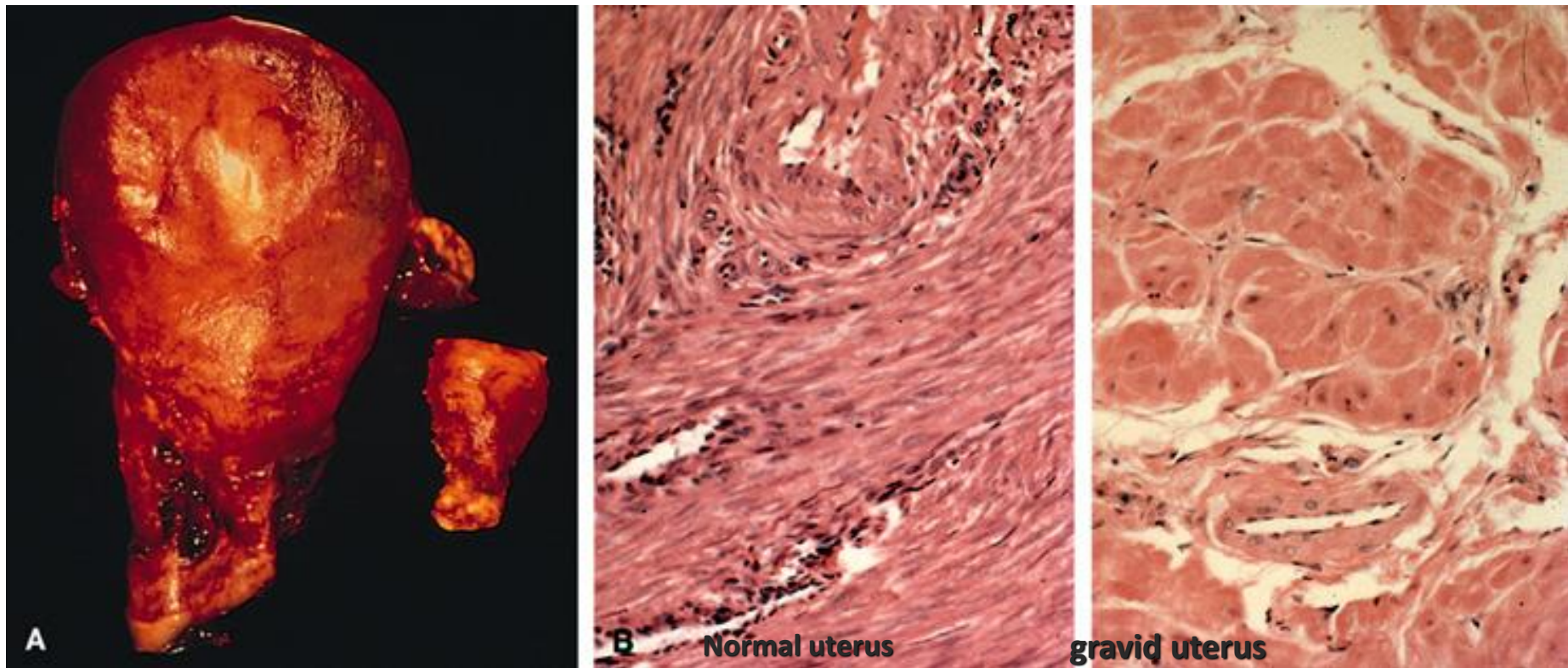




Left Normal heart

center Hypertrophied heart

Right Hypertrophied and dilated heart



Physiologic hypertrophy of the uterus during pregnancy. A, gross appearance of a normal uterus (right) and a gravid uterus (left) that was removed for postpartum bleeding,

(From ROBBINS BASIC PATHOLOGY, 2003)

The relationship between hyperplasia and hypertrophy:

Although hypertrophy and hyperplasia are two distinct processes, frequently both occur together, and they will be triggered by the same mechanism.

Atrophy

Physiologic

Pathologic

Disuse

**Loss of
endocrine
stimulation**

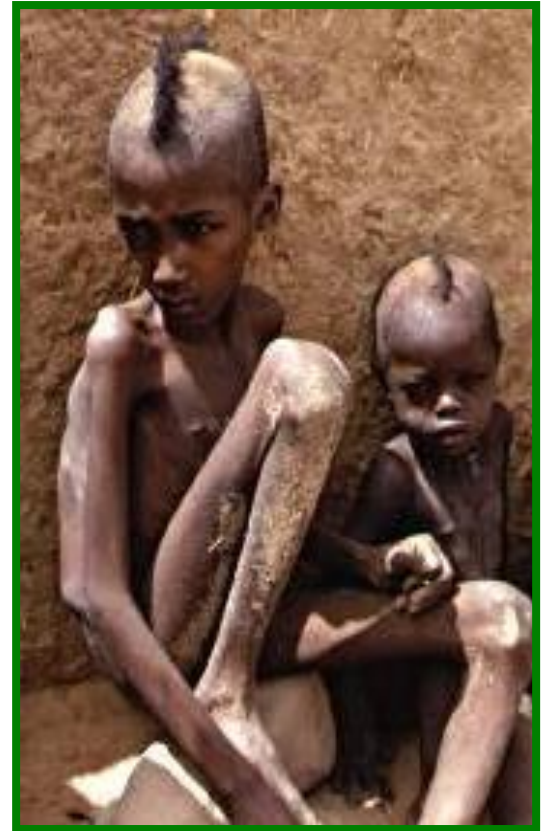Denervation

**Inadequate
nutrition**

Ischemia

- Diminished blood supply:
- Loss of nerve stimulus:
- Loss of endocrine stimulation:
- Inadequate nutrition:
- pressure:

WWW.STILEPROJECT.COM



**Atrophy associated
with Malnutrition**

3. Atrophy

(1) **Definition:** Acquired loss of size due to reduction of cell size or number of parenchyma cells in an organ.

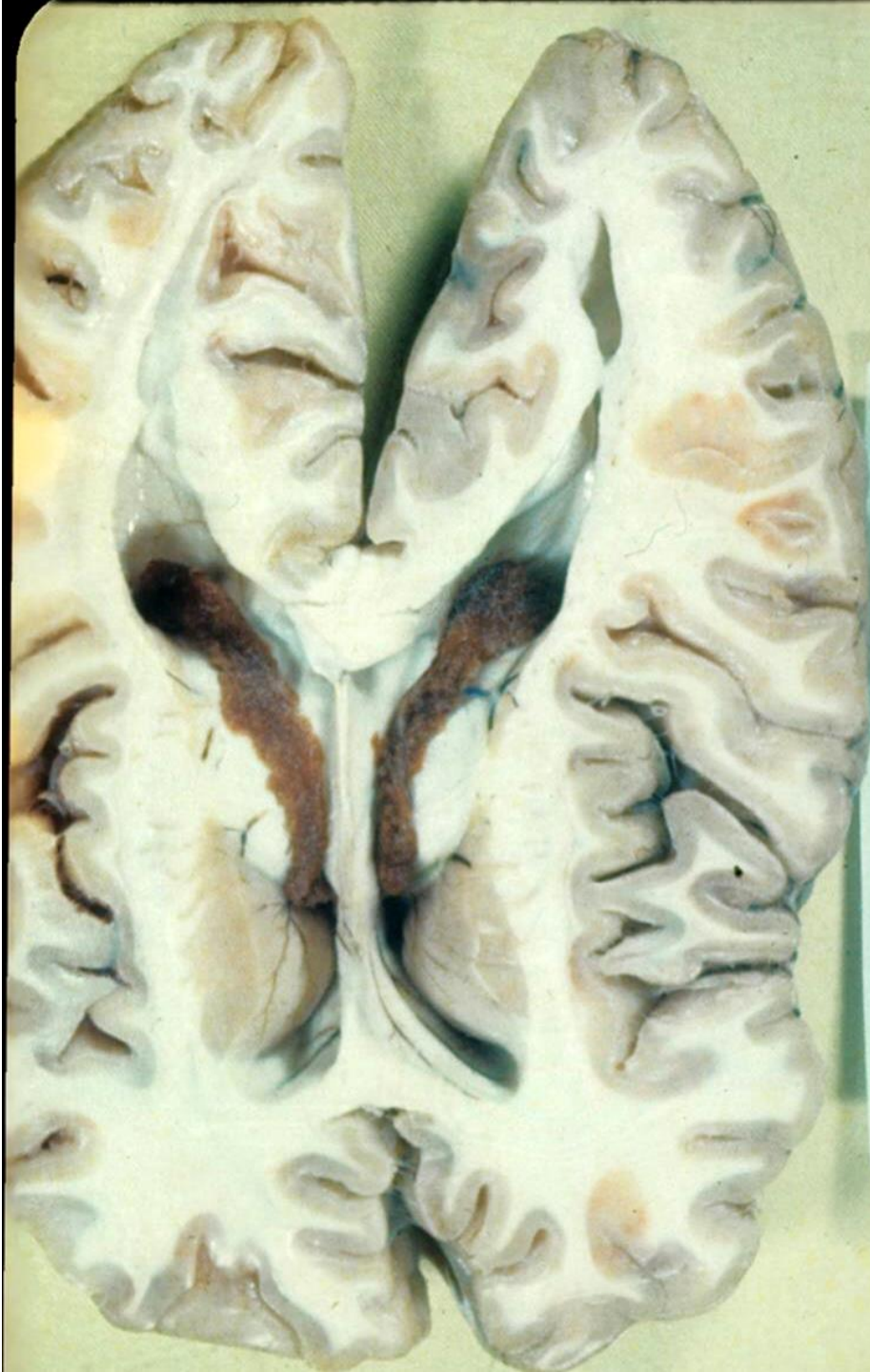(2) **Types:**

- Physiologic: i. e. Aging; shrinking mammary gland after lactation; the uterus after delivery or in old age.

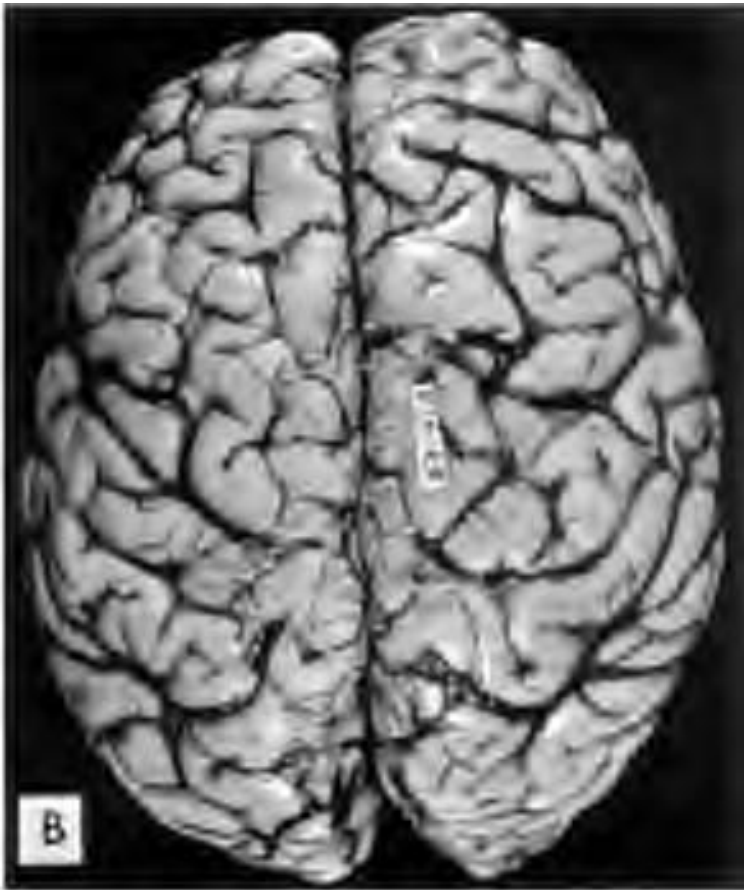The fundamental cellular change is identical in all, representing a retreat by the cell to a smaller size at which survival is still possible.

Although atrophic cells may have diminished function, they are not dead.

Atrophy represents a reduction in the structural components of the cell. The cell contains fewer mitochondria, myofilaments, a lesser amount of endoplasmic reticulum, and increasing in the number of autophagy vacuoles.

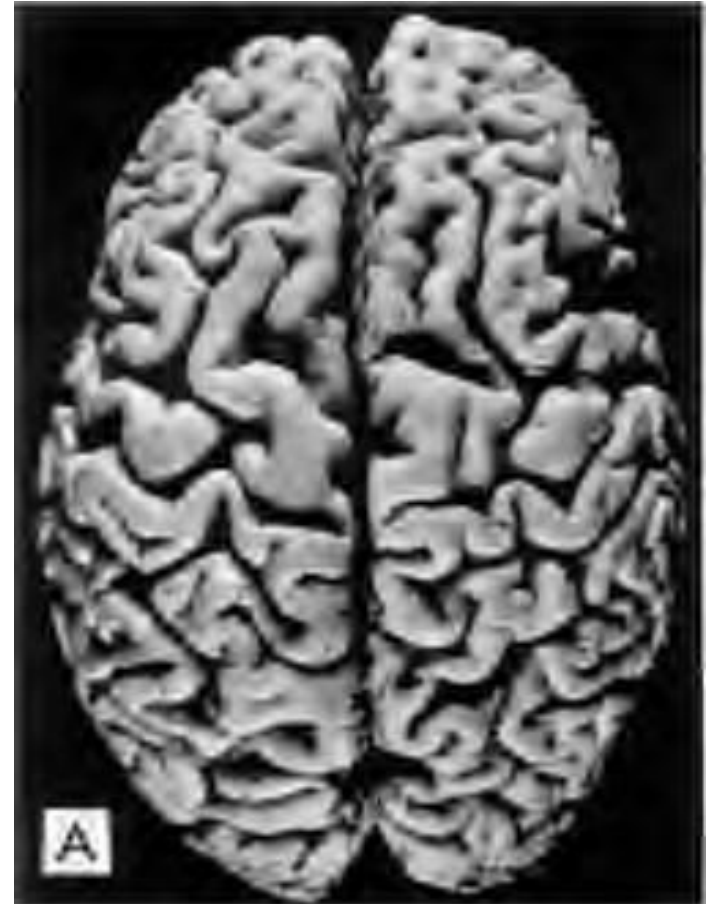

Atrophy of the brain (offered by Prof. Orr)



© Elsevier 2005

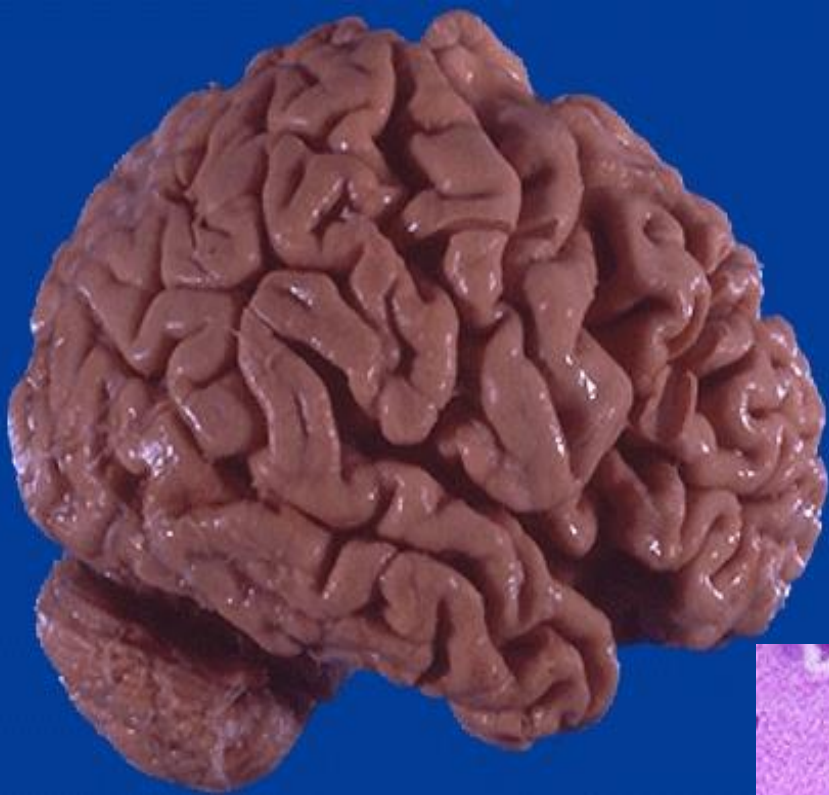Normal



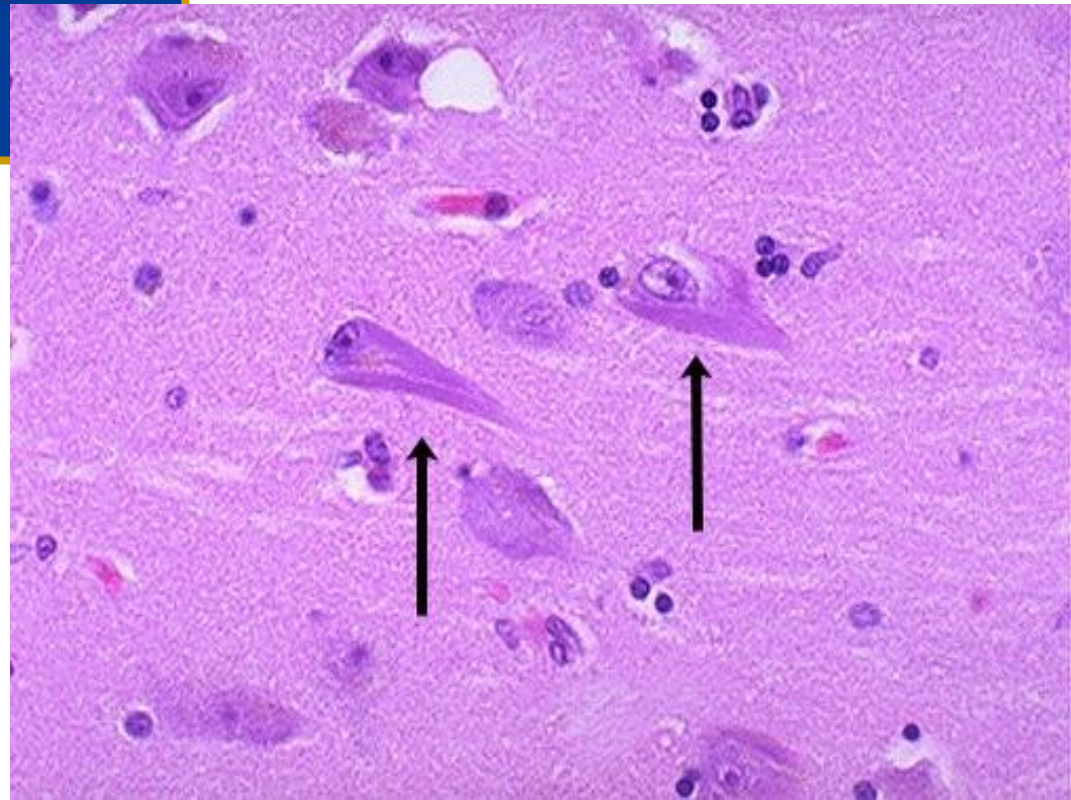
© Elsevier 2005

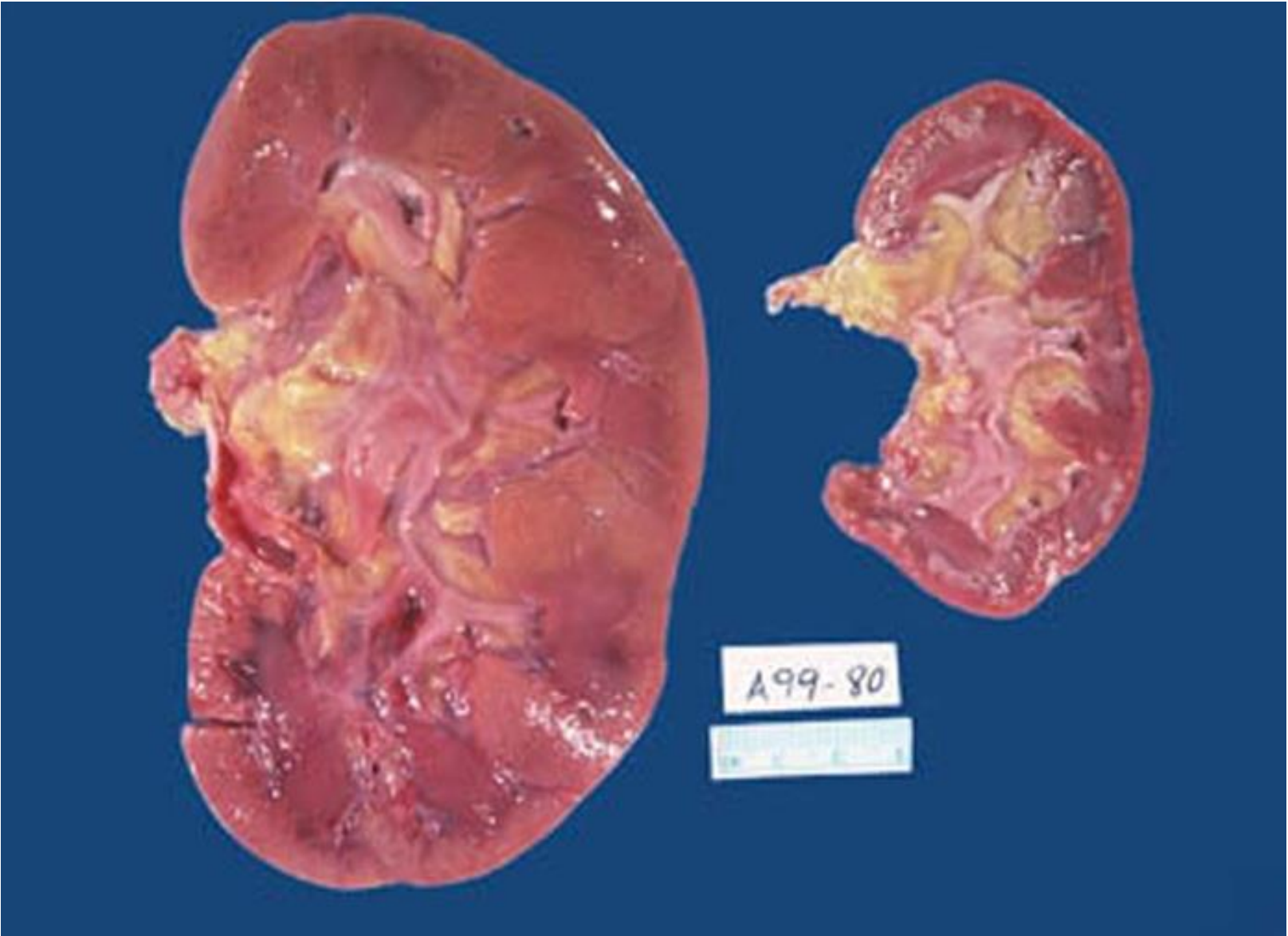
Atrophied

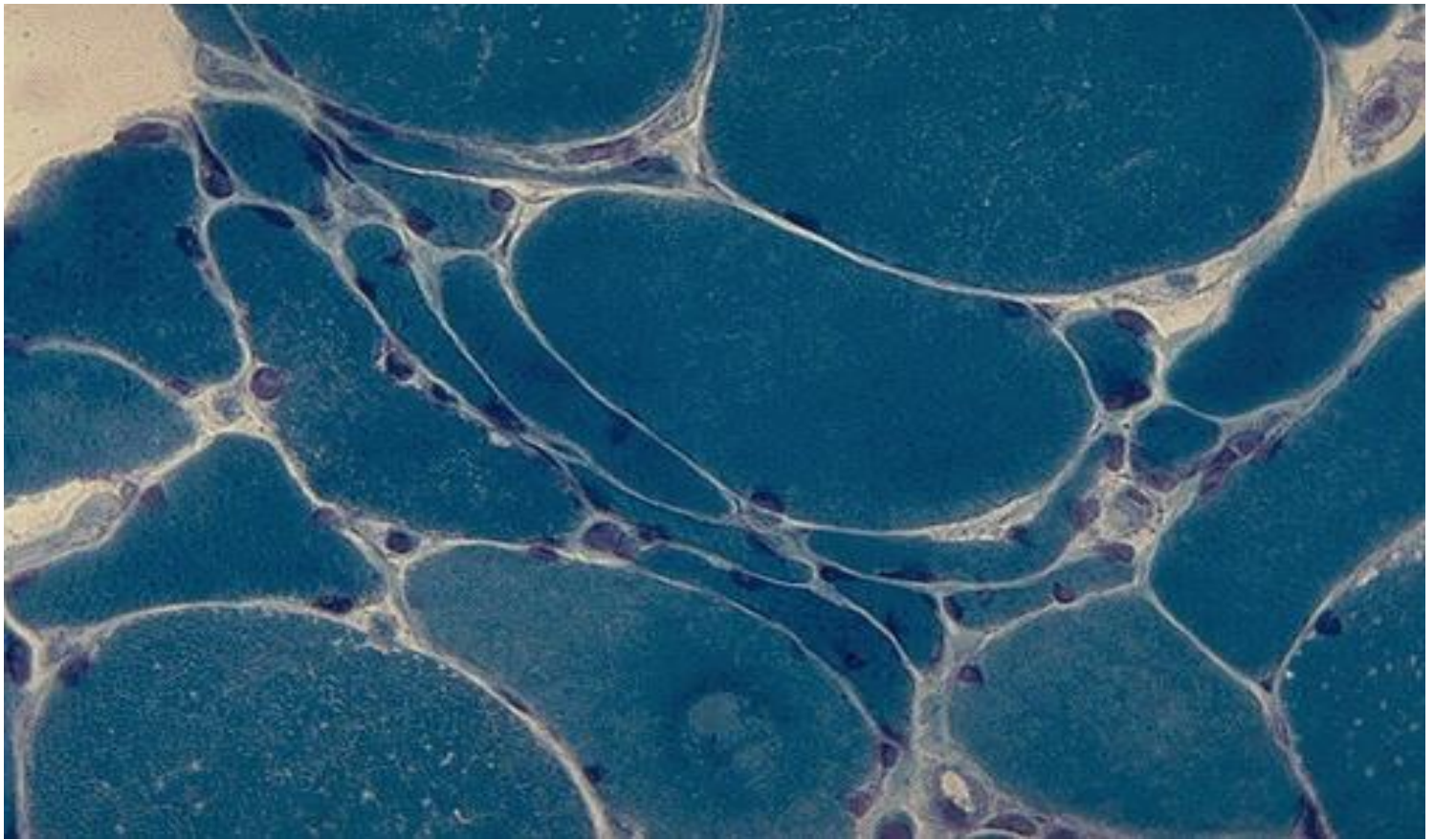
Brain atrophy



**Atrophy
associated
with Alzheimer's
Disease**







Muscle fiber atrophy. The number of cells is the same as before the atrophy occurred, but the size of some fibers is reduced. This is a response to injury by "downsizing" to conserve the cell. In this case, innervation of the small fibers in the center was lost. This is a trichrome stain.

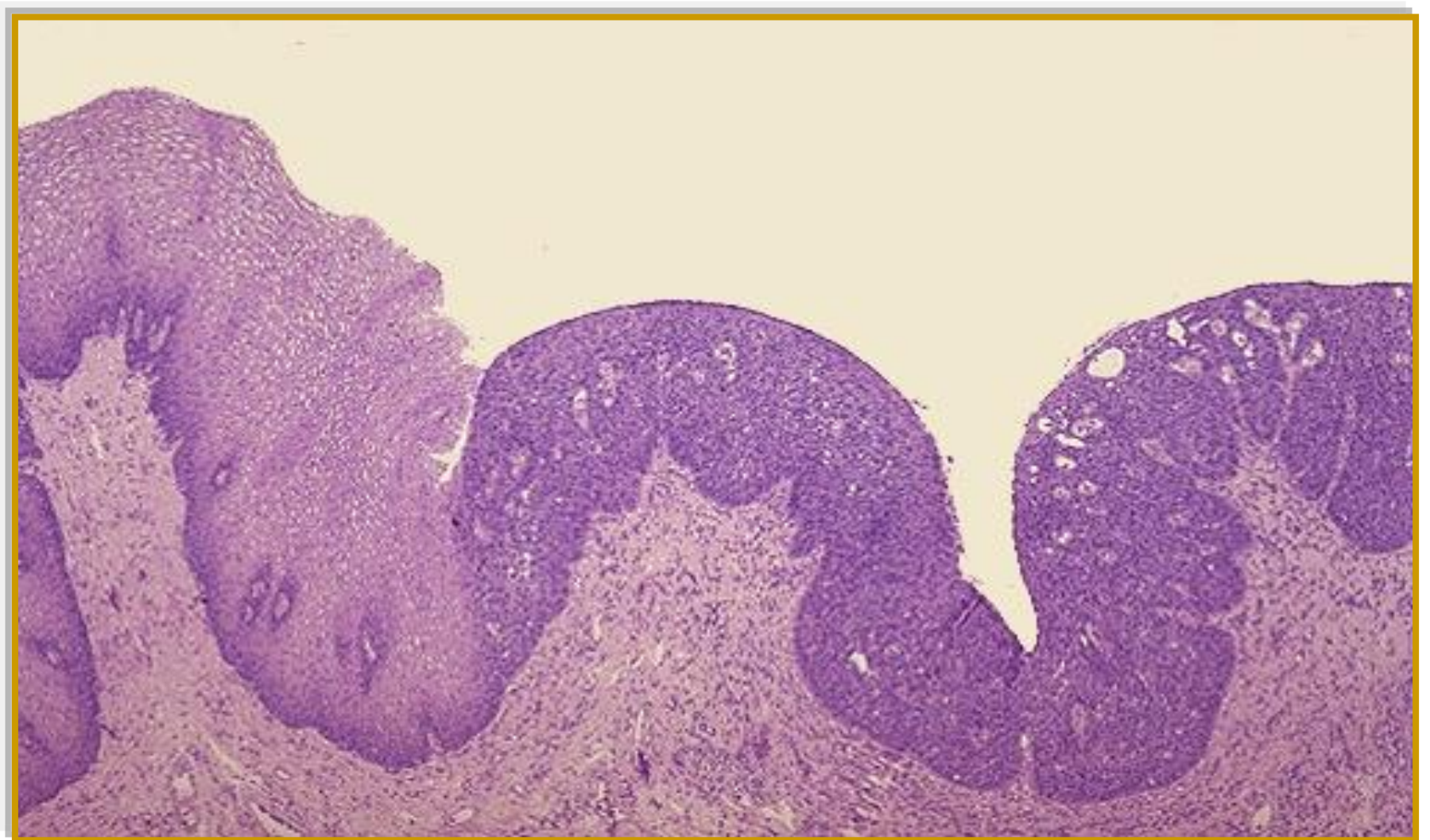
4. Metaplasia

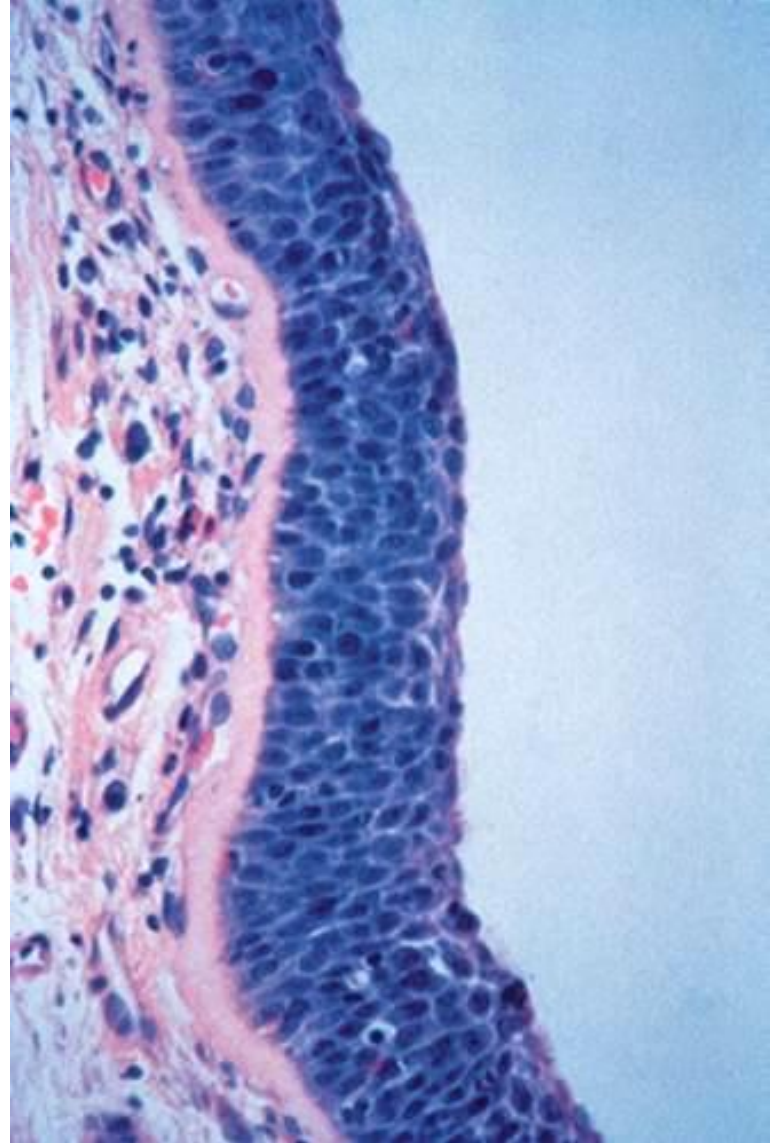
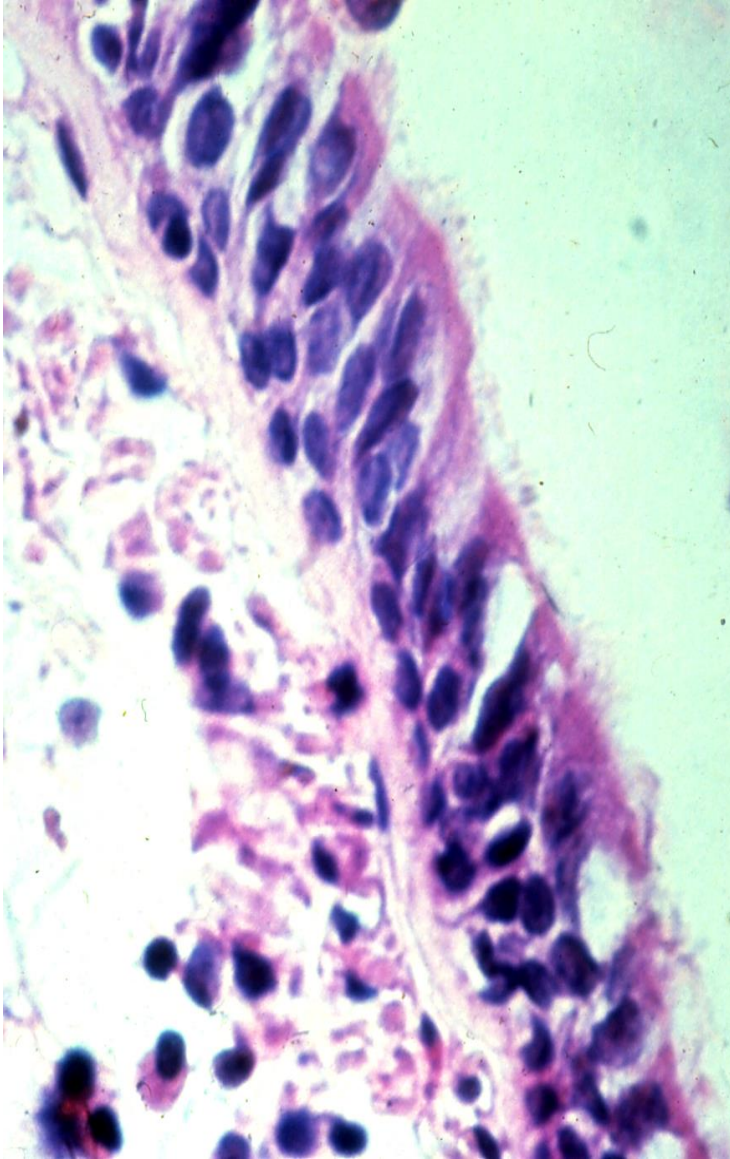
(1) **Definition:** Metaplasia is a reversible change in which one adult cell type is replaced by another adult cell type.

(2) **Causes:**

- **Changes in environment:** i. e. stones in excretory ducts of salivary gland, pancreas, or bile duct lead to change from columnar epithelium to stratified squamous epithelium.

Metaplasia of Uterine Cervix

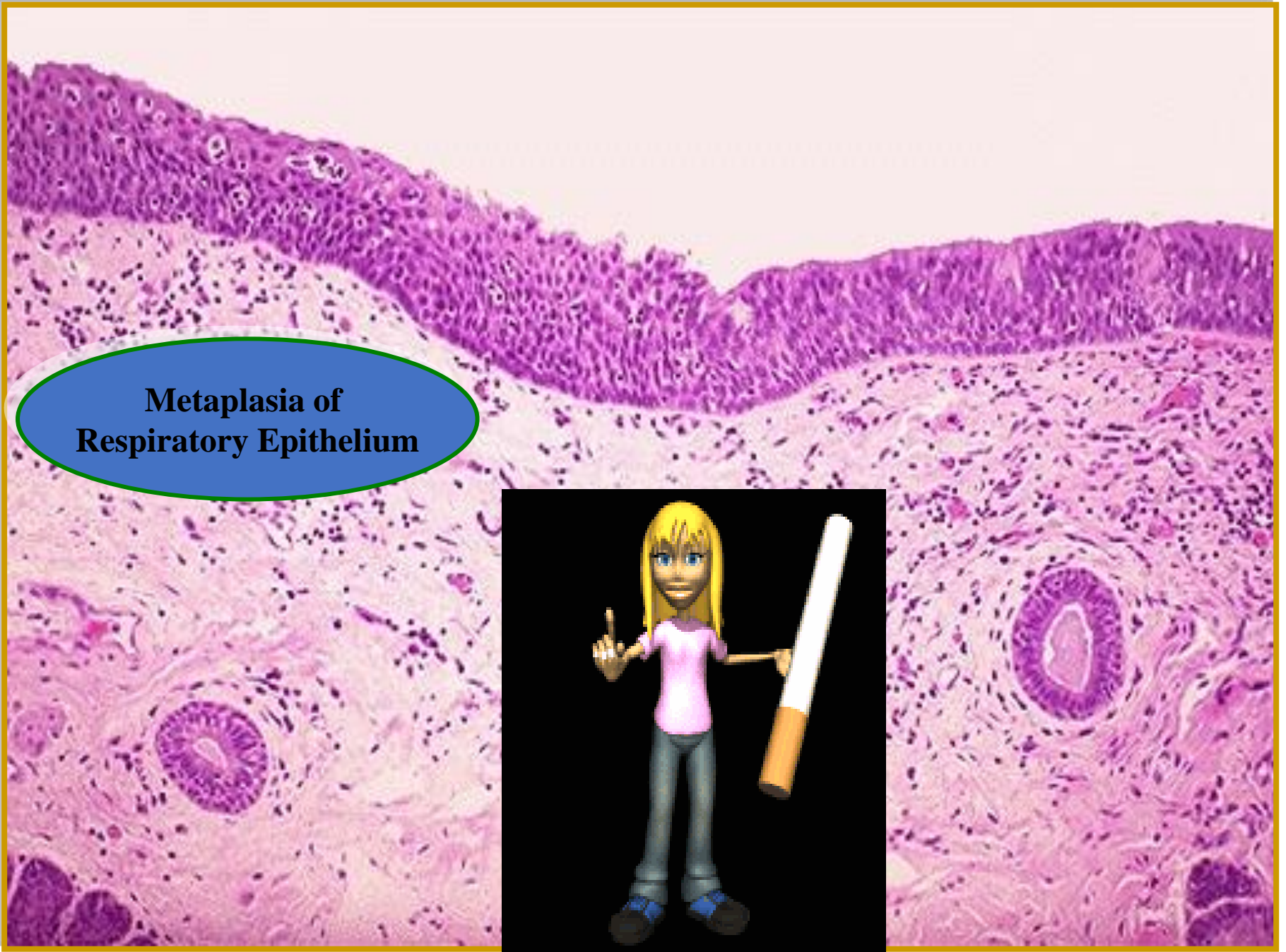


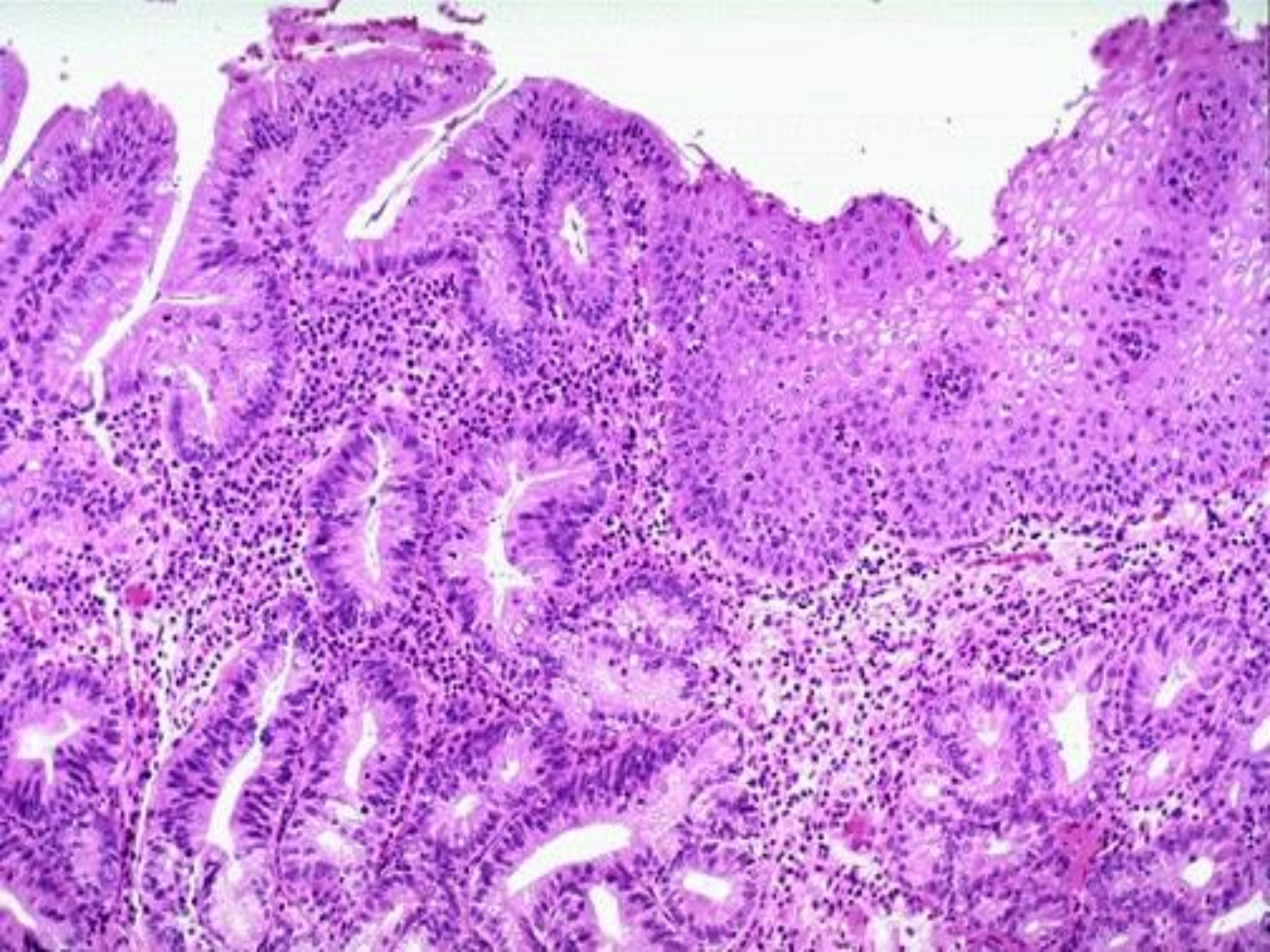


Squamous metaplasia in bronchitis

(offered by Prof.Orr)

**Metaplasia of
Respiratory Epithelium**



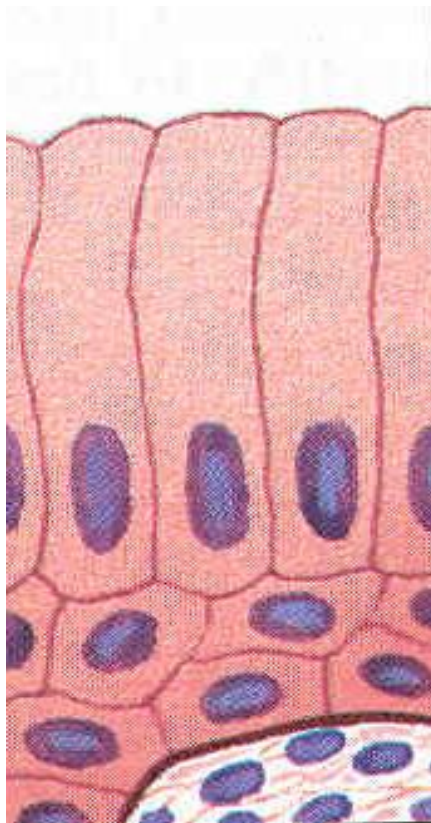


- **Irritation or inflammation:** i. e. In the habitual cigarettes smoker, the normal columnar ciliated epithelial cells of the trachea and bronchi are often replaced focally or widely by stratified squamous epithelial cells.
- **Nutritional:** vitamin A deficiency causing squamous metaplasia.

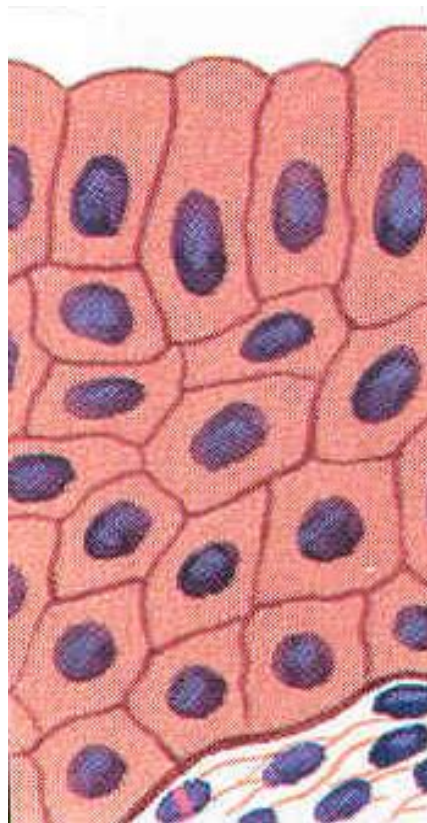
Epithelial metaplasia is a two-edged sword and, in most circumstances, represents an undesirable change. Moreover, the influences that predispose to such metaplasia, if persistent, may induce cancer transformation in metaplastic epithelium. Thus, the common form of cancer in the respiratory tract is composed of squamous cells.

Metaplasia may also occur in mesenchymal cells but less clearly as an adaptive response. i. e. fibrous connective tissue cells may become transformed to osteoblast chondroblasts to produce bone or cartilage where it is normally not encountered.

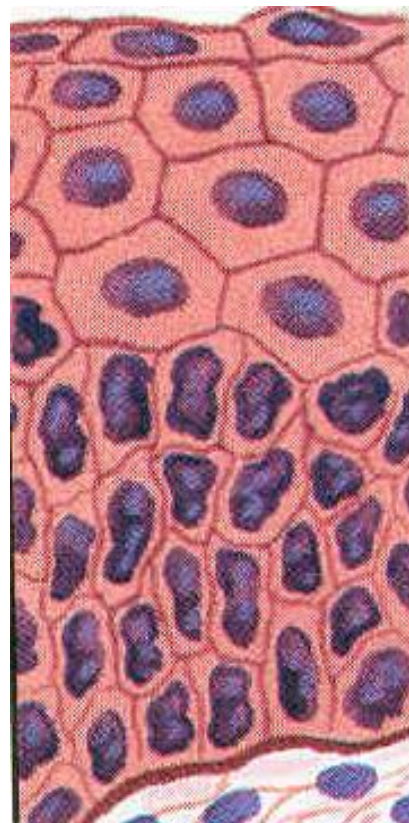Normal



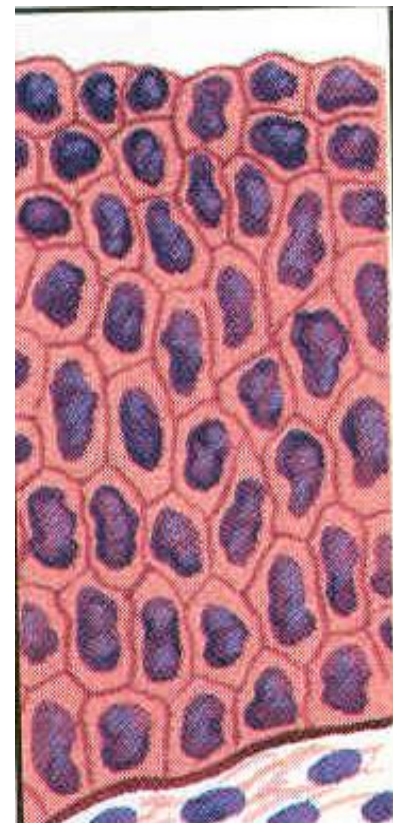Metaplasia

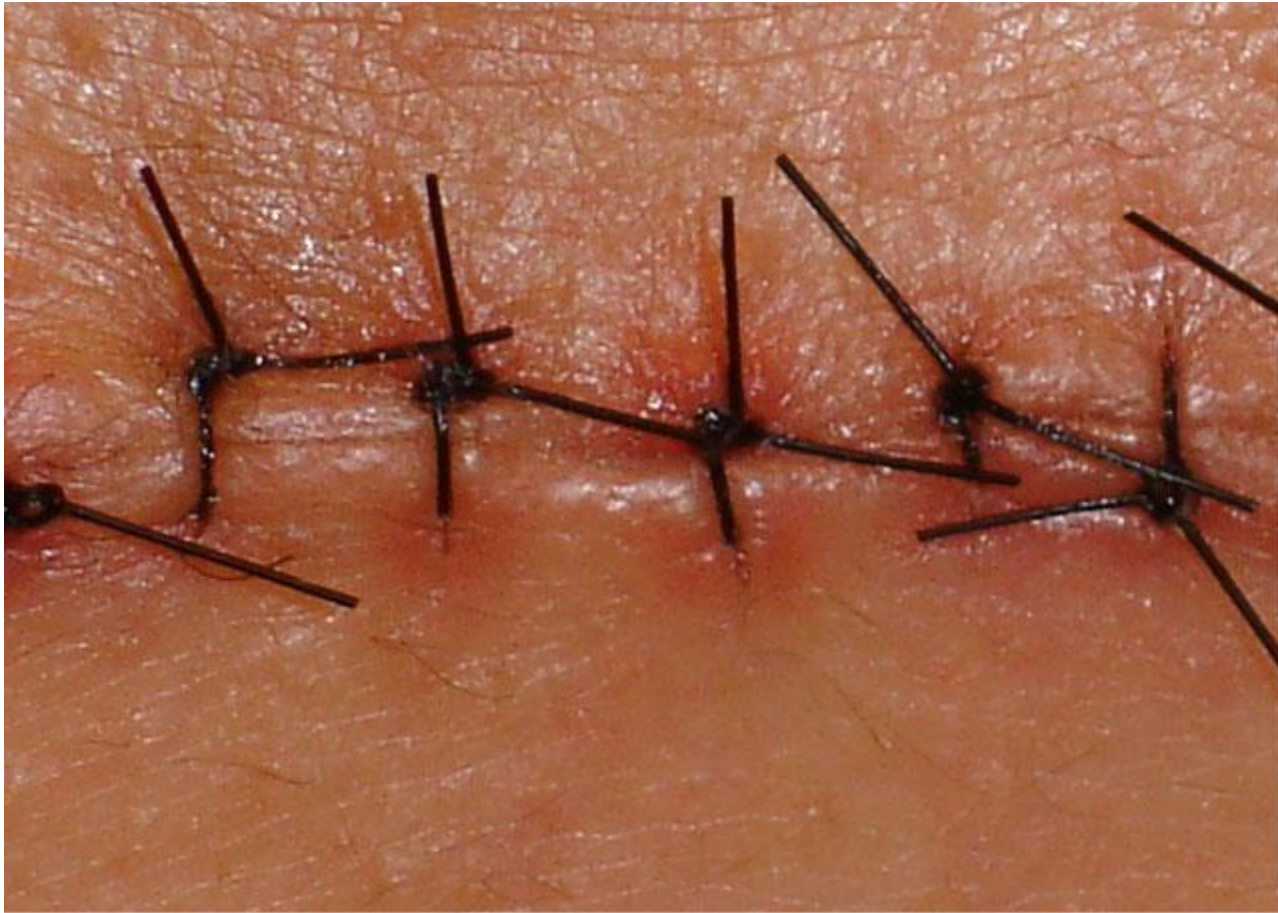

Displasia



Carcinoma
in situ





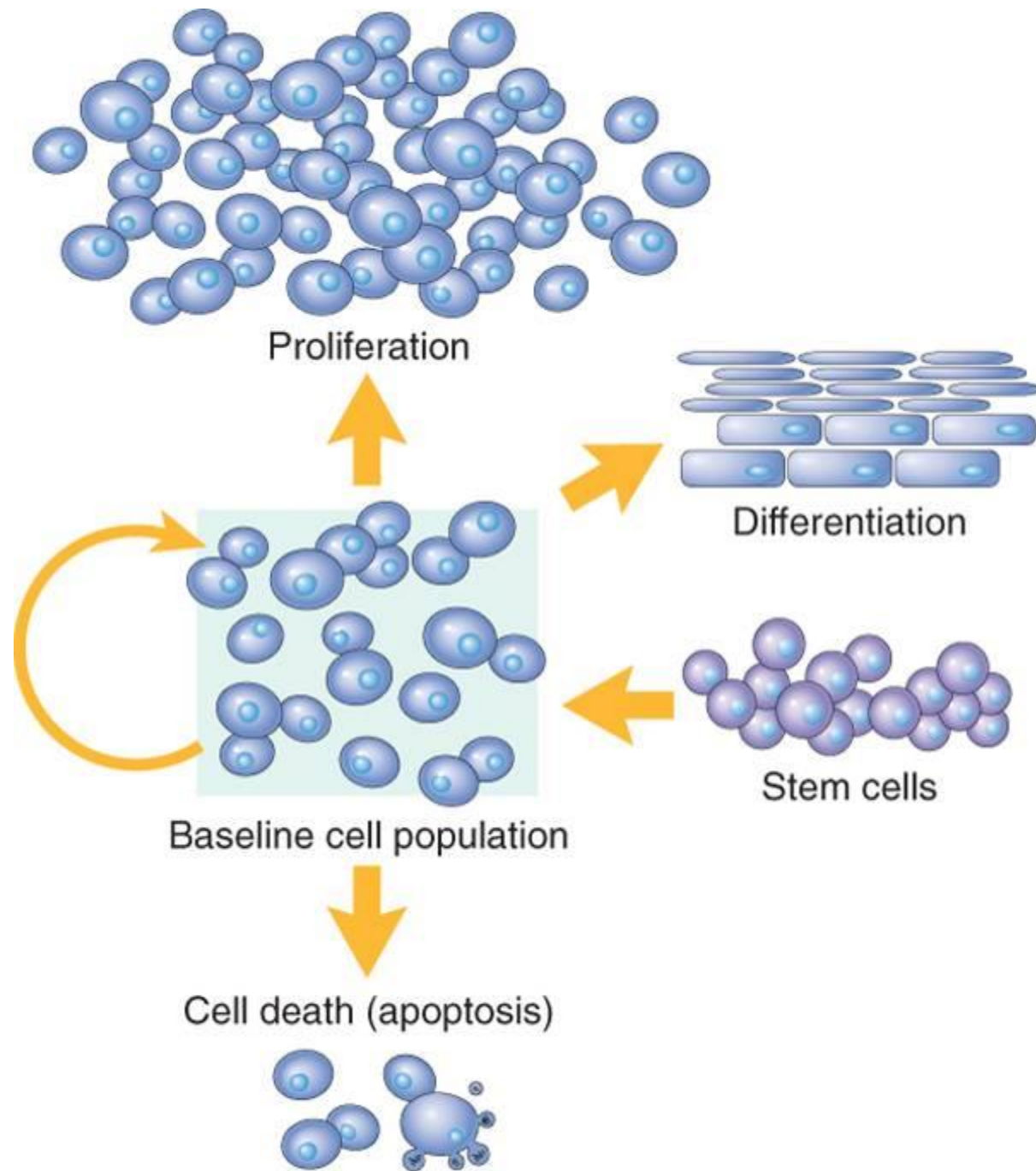
Tissue Renewal and Repair: Regeneration, Healing, and Fibrosis

TISSUE REPAIR

- Tissue repair = restoration of tissue architecture and function after an injury
- Occurs in two ways:
 - Regeneration of injured tissue
 - Replacement by connective tissue (scarring)
- Usually, tissue repair involves both processes
- Involves cell proliferation, and interaction between cells and extracellular matrix

CELLULAR PROLIFERATION

- **Lots of cells proliferate during tissue repair:**
 - **injured tissue remnants**
 - **vascular endothelial cells**
 - **fibroblasts**
- **You need to know a few things about:**
 - **the cell cycle**
 - **the proliferative capacities of different tissues**
 - **stem cells**
 - **growth factors**
 - **the extracellular matrix**



Proliferation

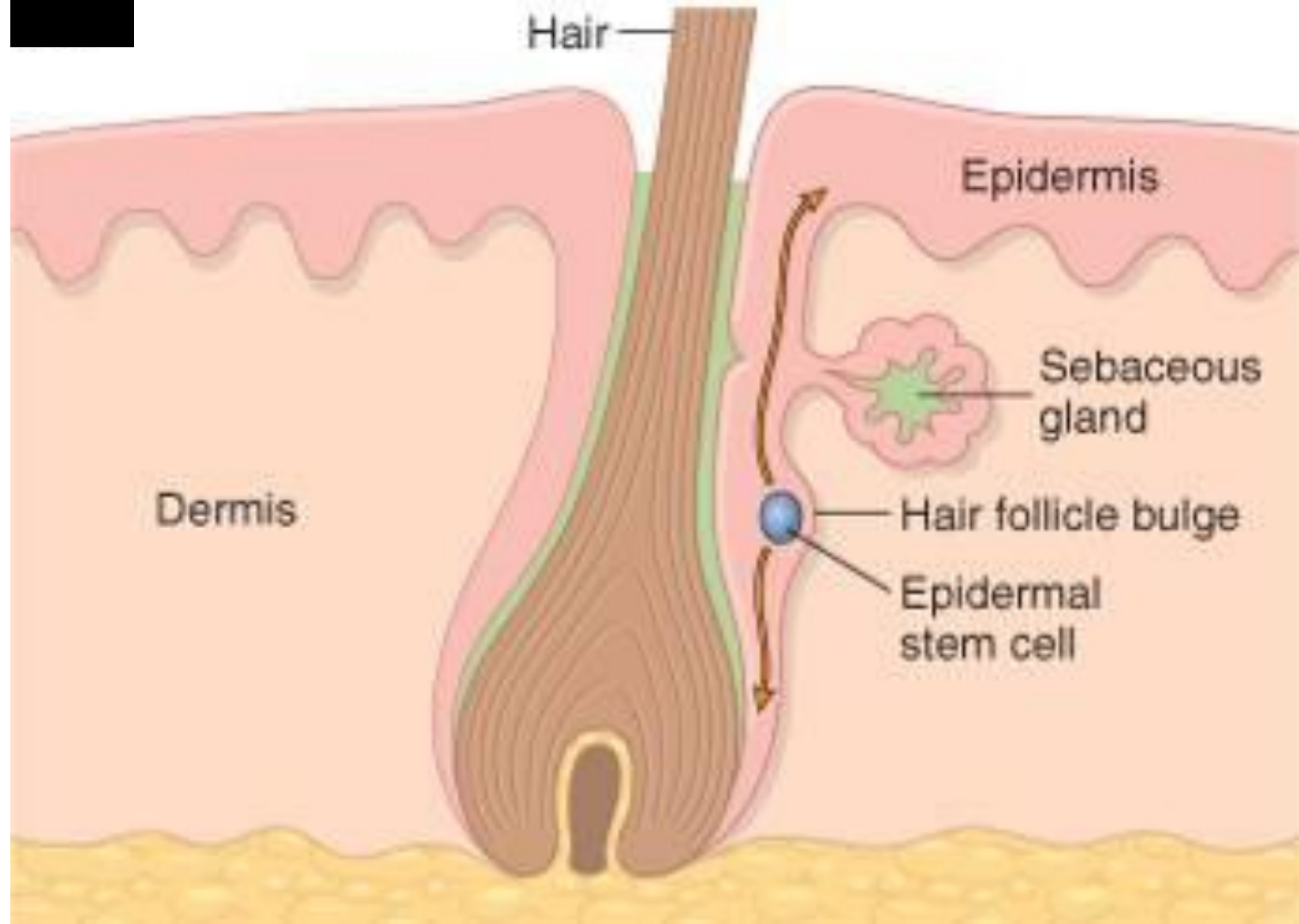
Differentiation

Stem cells

Baseline cell population

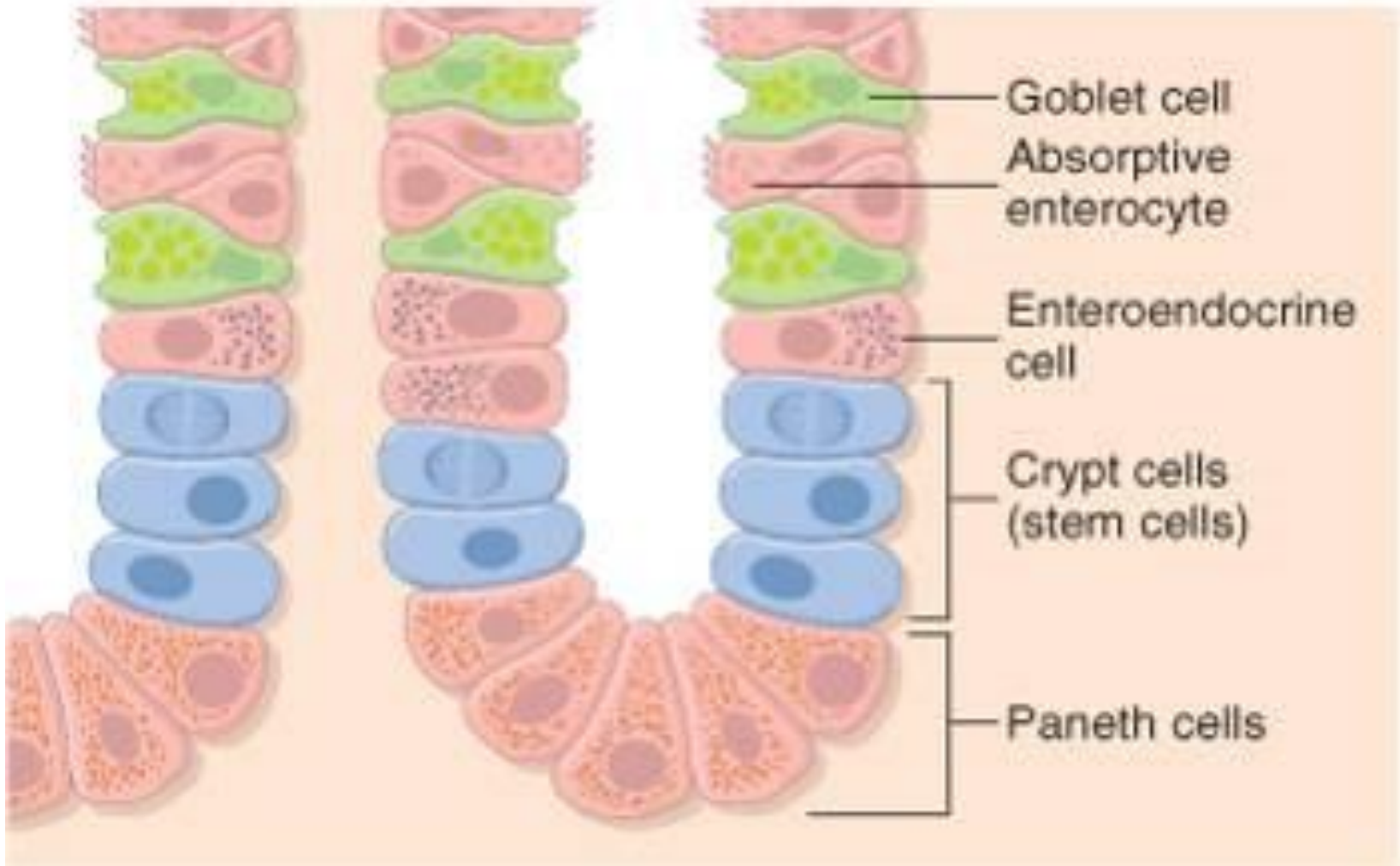
Cell death (apoptosis)

Stem cells in skin



Stem cells in GI epithelium

Intestine



CELLULAR PROLIFERATION

Tissues of the body are divided into three groups:

- **Continuously dividing (labile) tissues**
- **Stable tissues**
- **Permanent tissues**
 - **cells can't proliferate**
 - **can't regenerate (so injury always leads to scar)**
 - **examples: neurons, cardiac muscle**

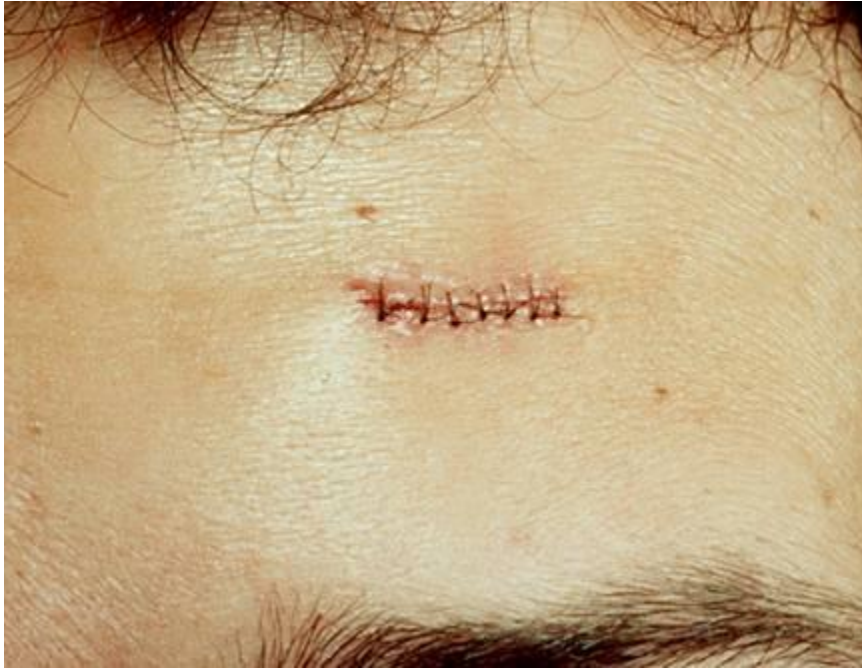CELLULAR PROLIFERATION

Tissues of the body are divided into three groups:

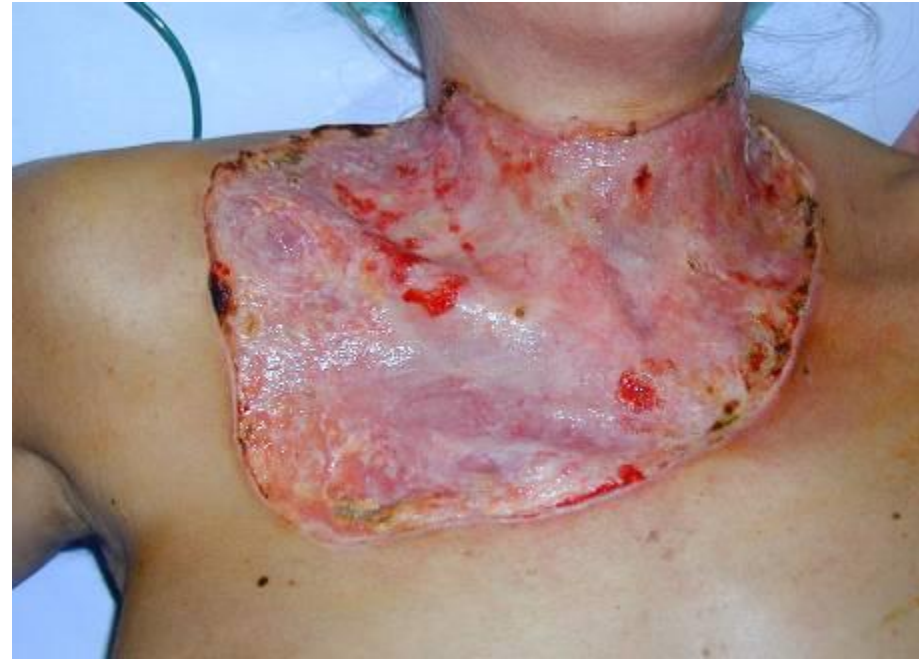- **Continuously dividing (labile) tissues**
- **Stable tissues**
- **Permanent tissues**
 - **cells can't proliferate**
 - **can't regenerate (so injury always leads to scar)**
 - **examples: neurons, cardiac muscle**

SKIN WOUND HEALING

- First intention
- Second intention



first intention healing



second intention healing

SKIN WOUND HEALING

Healing by First Intention

- Occurs in small wounds that close easily
- Epithelial regeneration predominates over fibrosis
- Healing is fast, with minimal scarring/infection
- Examples:
 - Paper cuts
 - Well-approximated surgical incisions
 - Replaced periodontal flaps

SKIN WOUND HEALING

Healing by First Intention: Timeline

- By 24 hours
- By 3-7 days
- Weeks later

SKIN WOUND HEALING

Healing by First Intention: Timeline

- By 24 hours
 - clot forms
 - neutrophils come in
 - epithelium begins to regenerate

SKIN WOUND HEALING

Healing by First Intention: Timeline

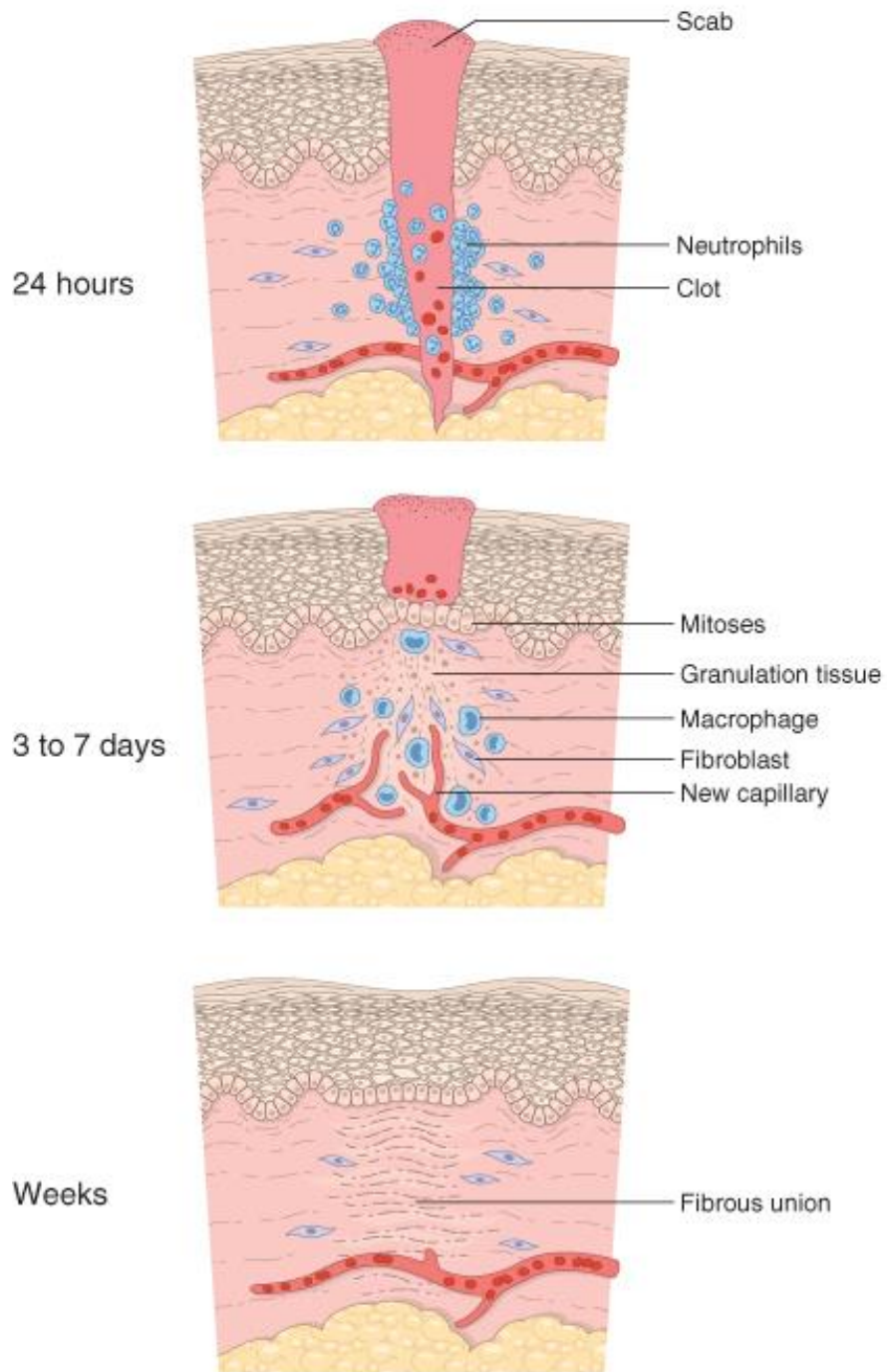
- By 24 hours
- By 3-7 days
 - macrophages come in
 - granulation tissue is formed
 - new blood vessels
 - fibroblasts
 - collagen begins to bridge incision
 - epithelium increases in thickness

SKIN WOUND HEALING

Healing by First Intention: Timeline

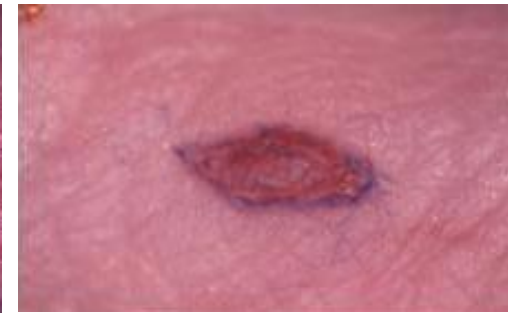
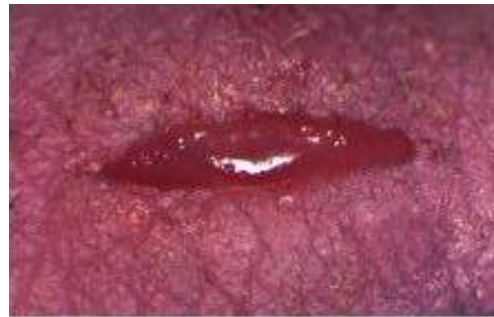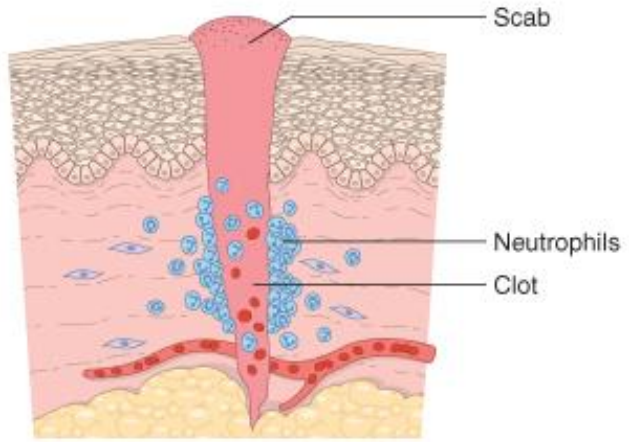
- By 24 hours
- By 3-7 days
- Weeks later
 - granulation tissue gone
 - collagen is remodeled
 - epidermis full, mature
(but without dermal appendages!)
 - eventually, scar forms

HEALING BY FIRST INTENTION

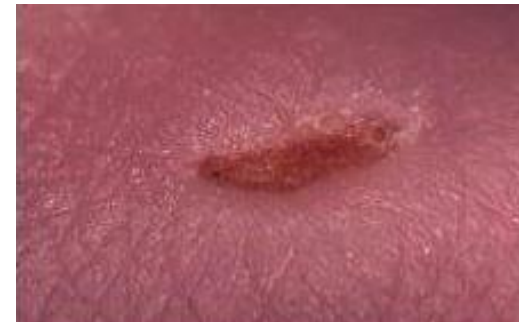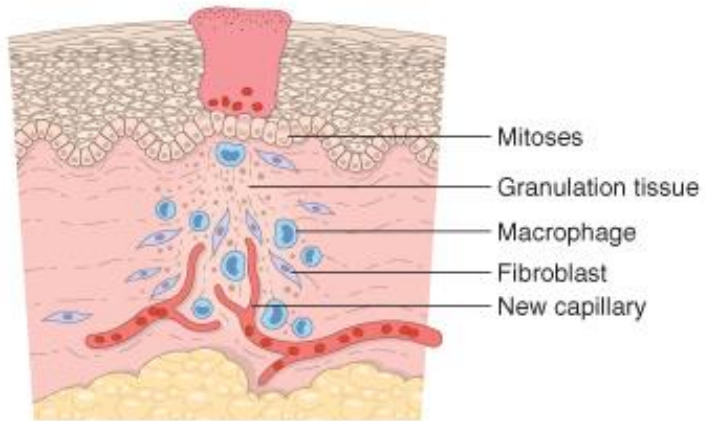


HEALING BY FIRST INTENTION

24 hours

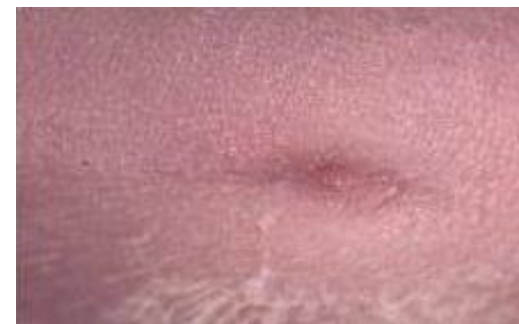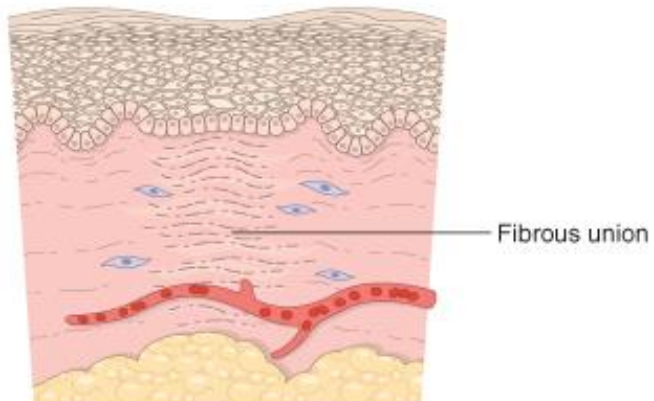


3 to 7 days



2 days

Weeks



1 week

SKIN WOUND HEALING

Healing by Second Intention

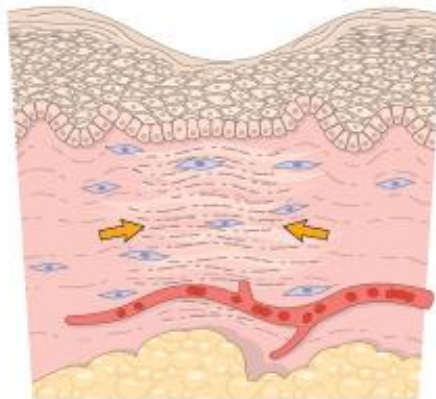
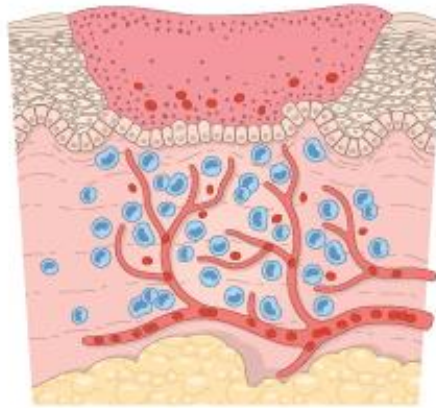
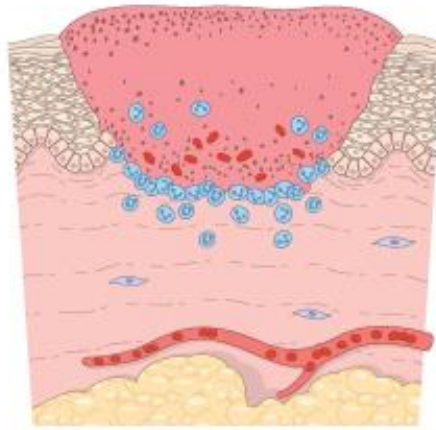
- Occurs in larger wounds that have gaps between wound margins
- Fibrosis predominates over epithelial regeneration
- Healing is slower, with more inflammation and granulation tissue formation, and more scarring
- Examples:
 - Infarction
 - Large burns and ulcers
 - Extraction sockets
 - External-bevel gingivectomies

SKIN WOUND HEALING

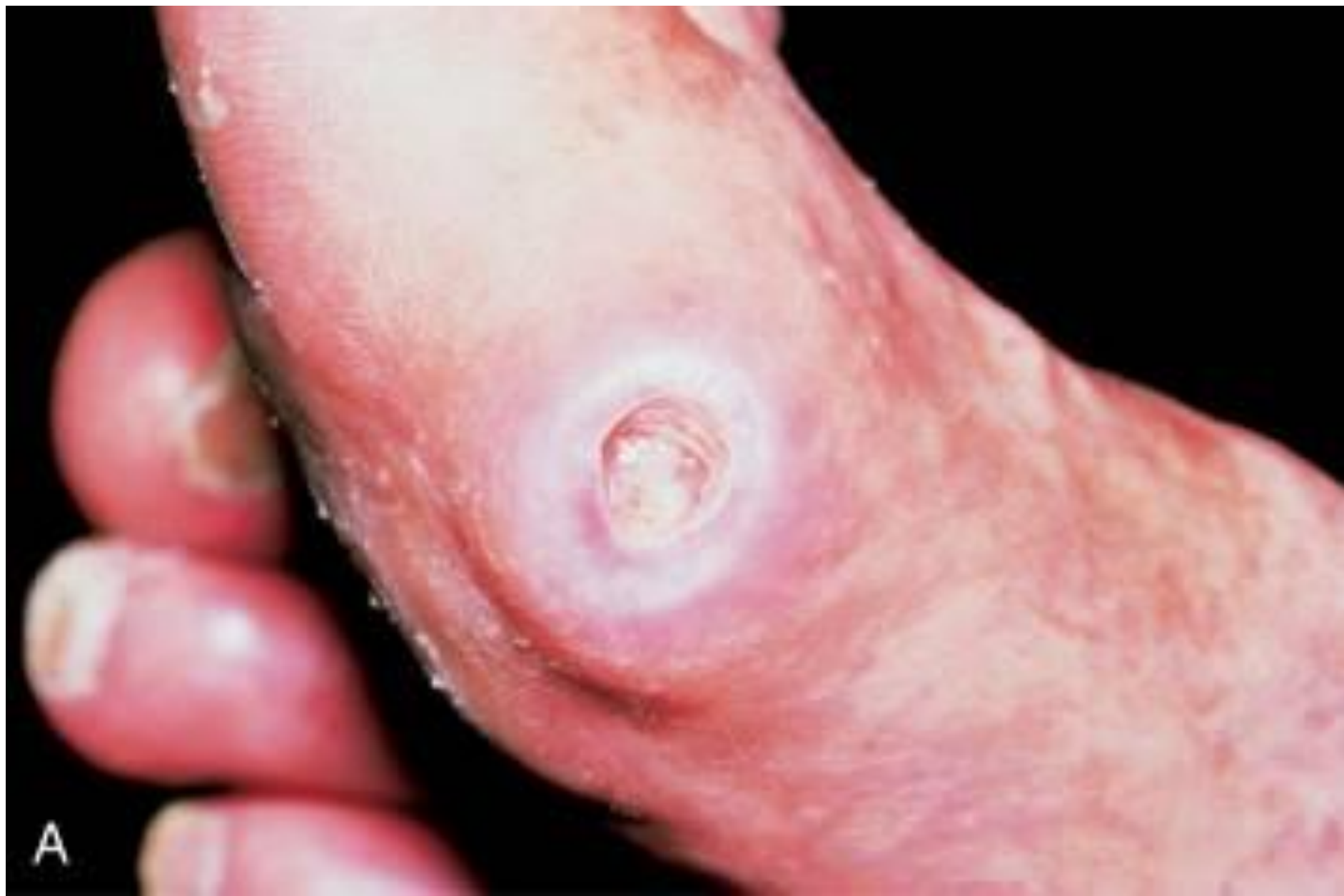Differences from healing by first intention:

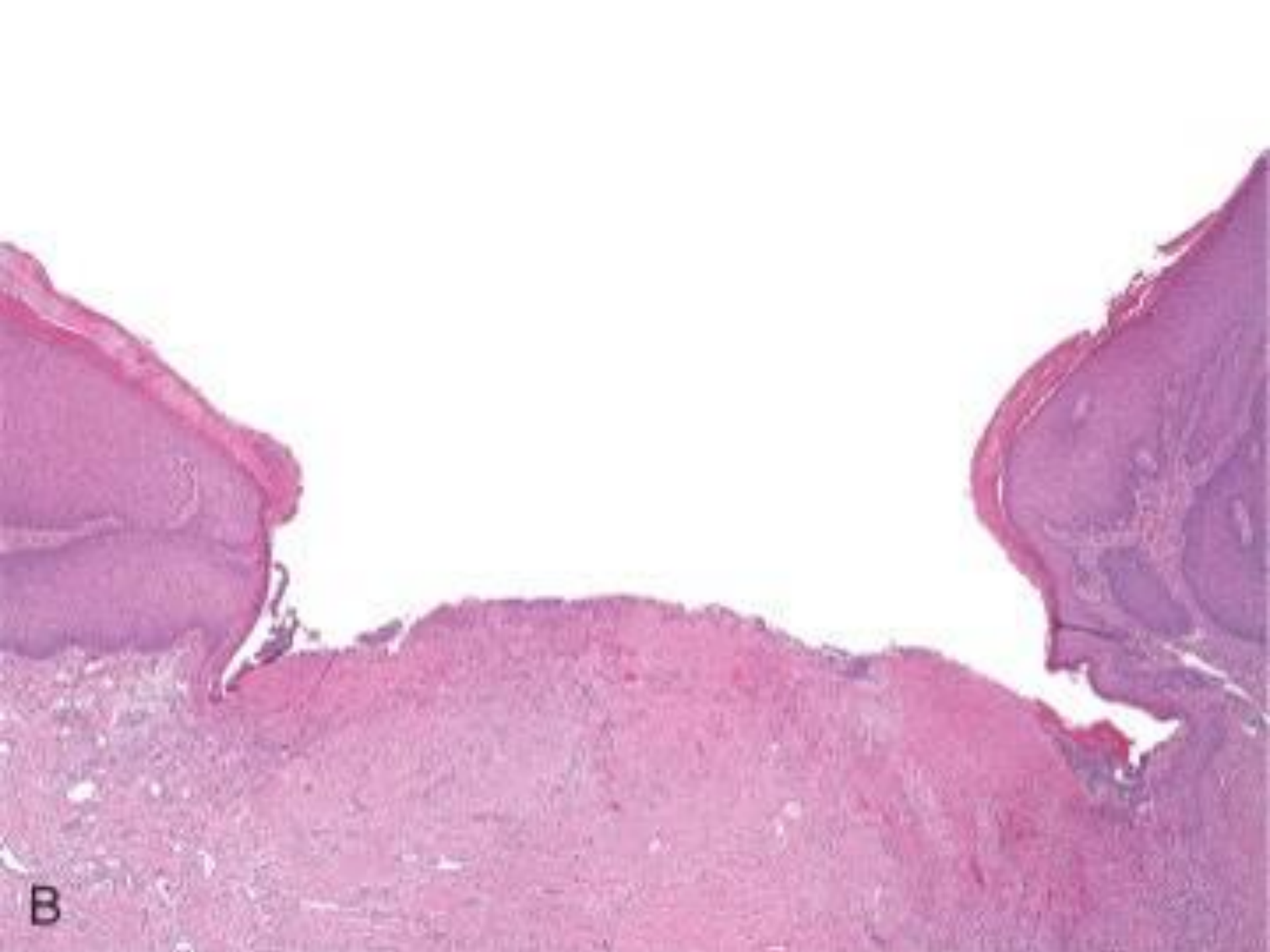- More inflammation
- More granulation tissue
- Wound contraction

HEALING BY SECOND INTENTION

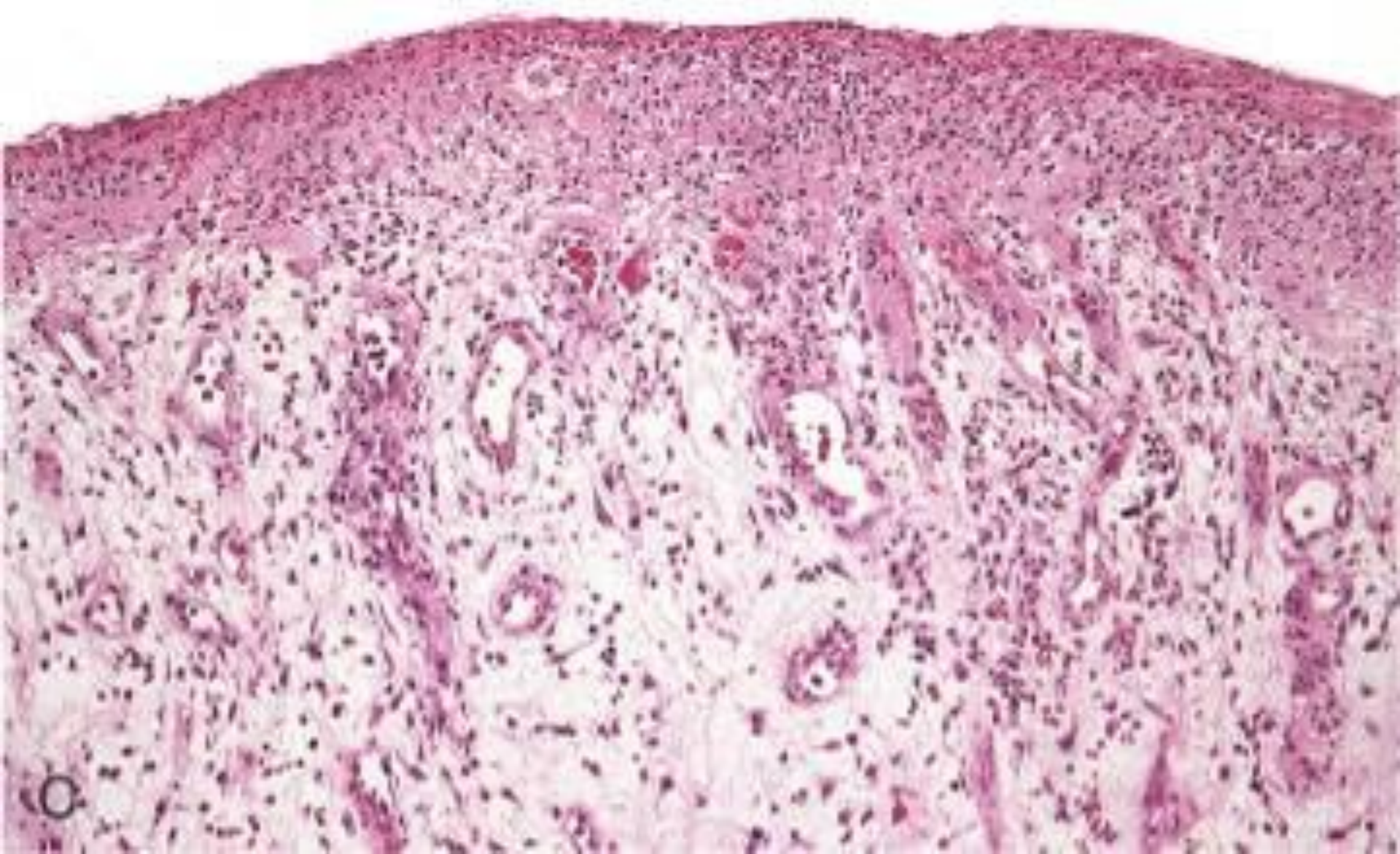


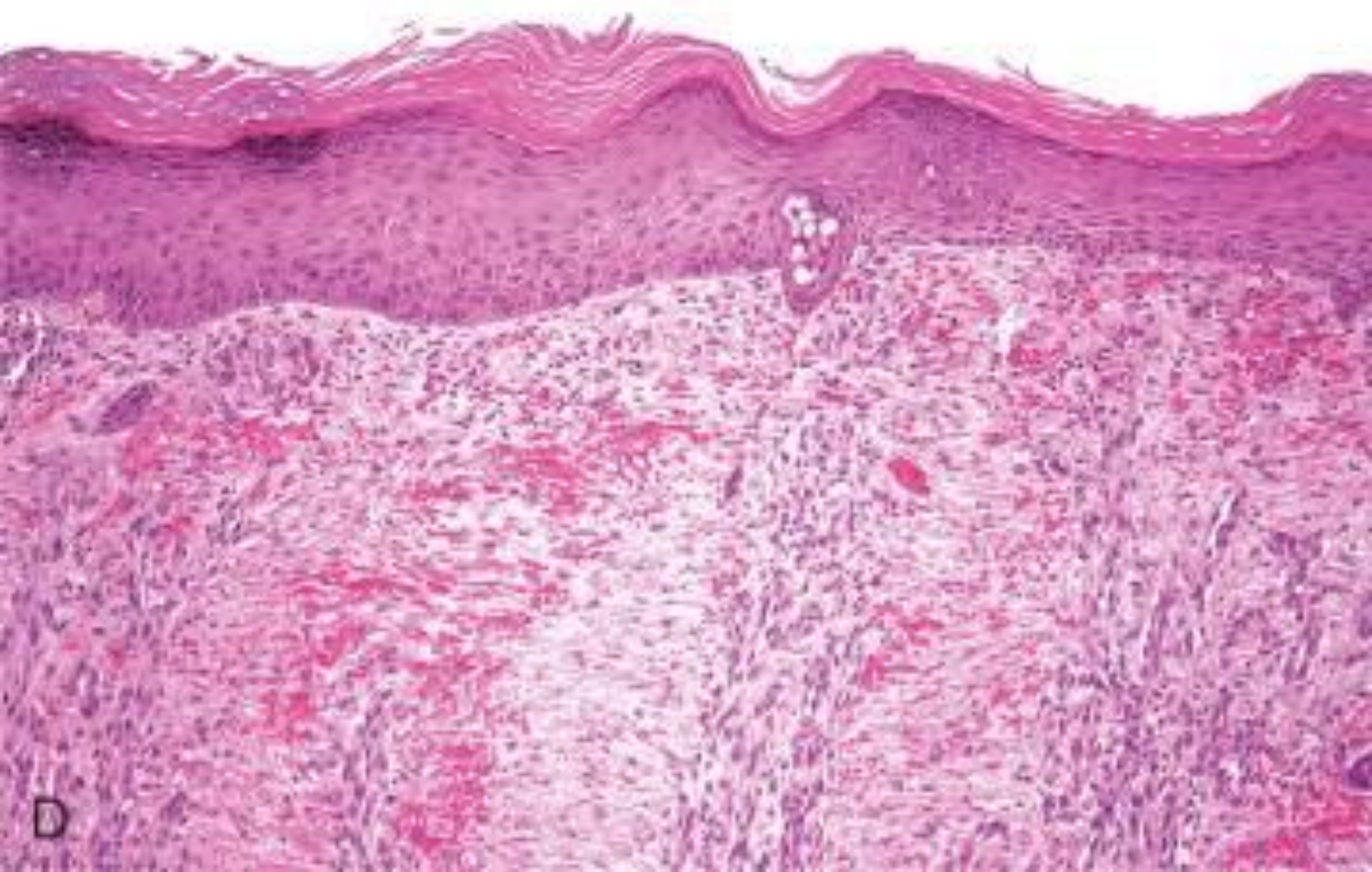
Wound contraction





B





D

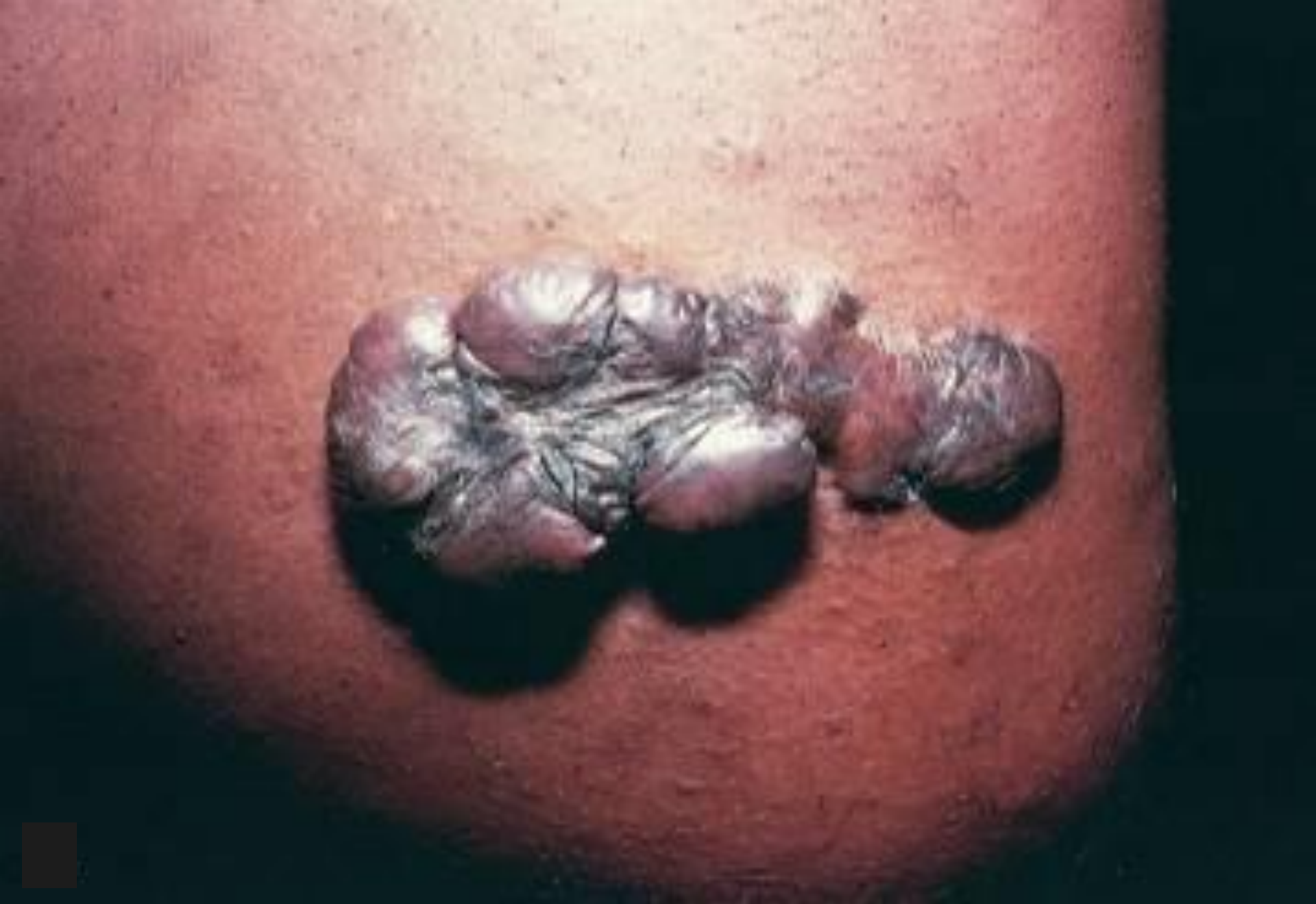SKIN WOUND HEALING

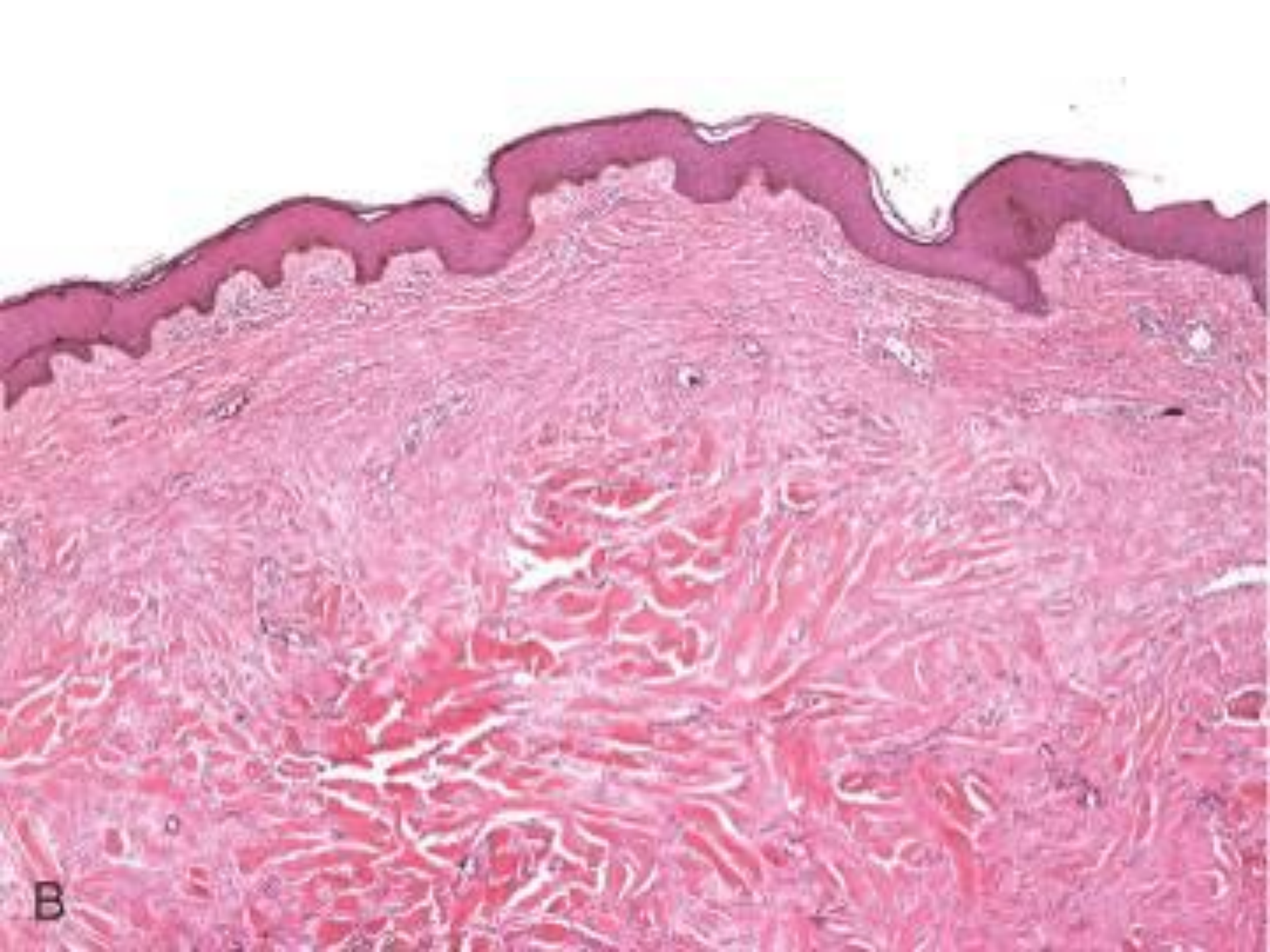
Wound Strength

- At suture removal: 10%
- Rapid increase over next 4 weeks
- At third month: 70-80%

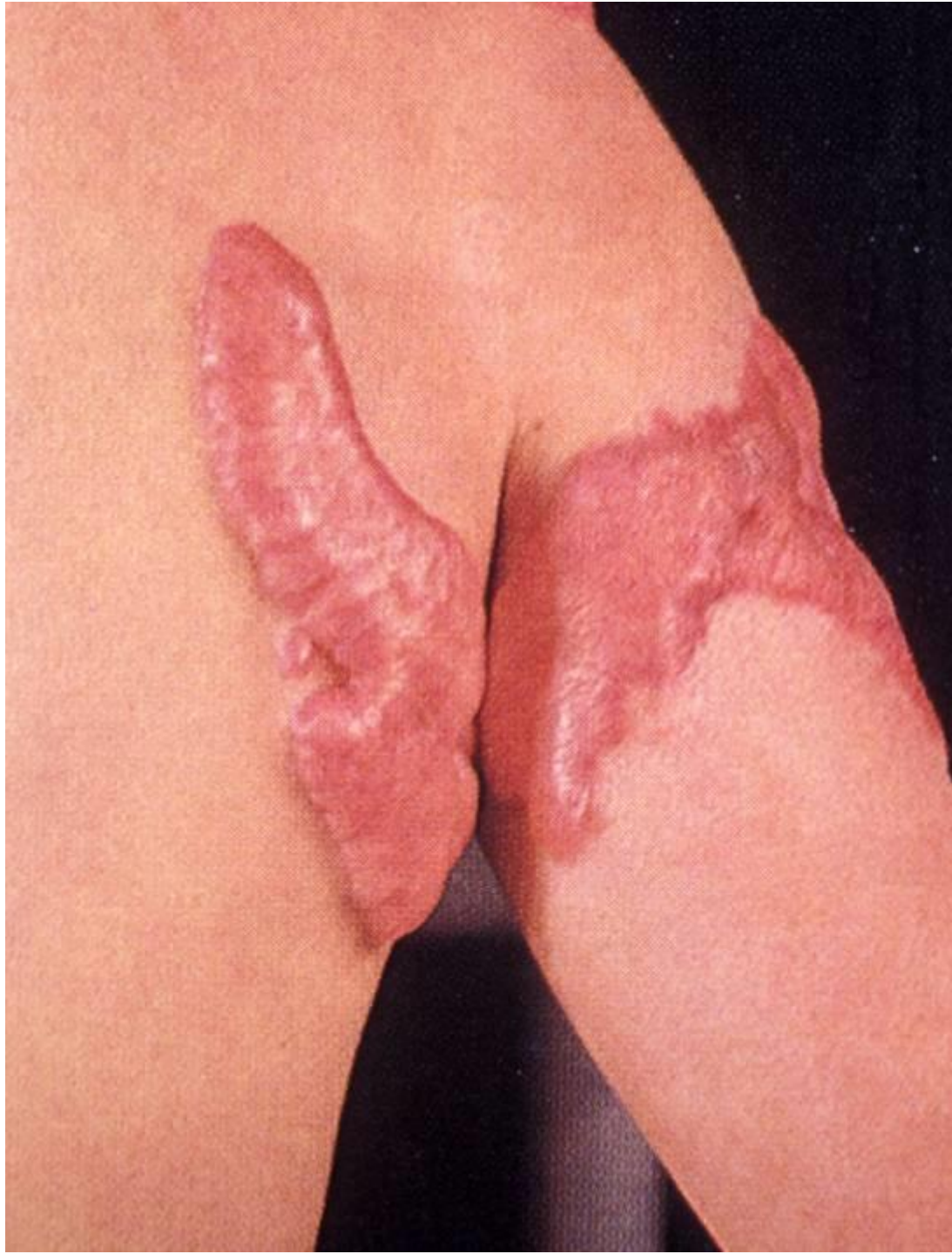WHY DO GOOD WOUNDS GO BAD?

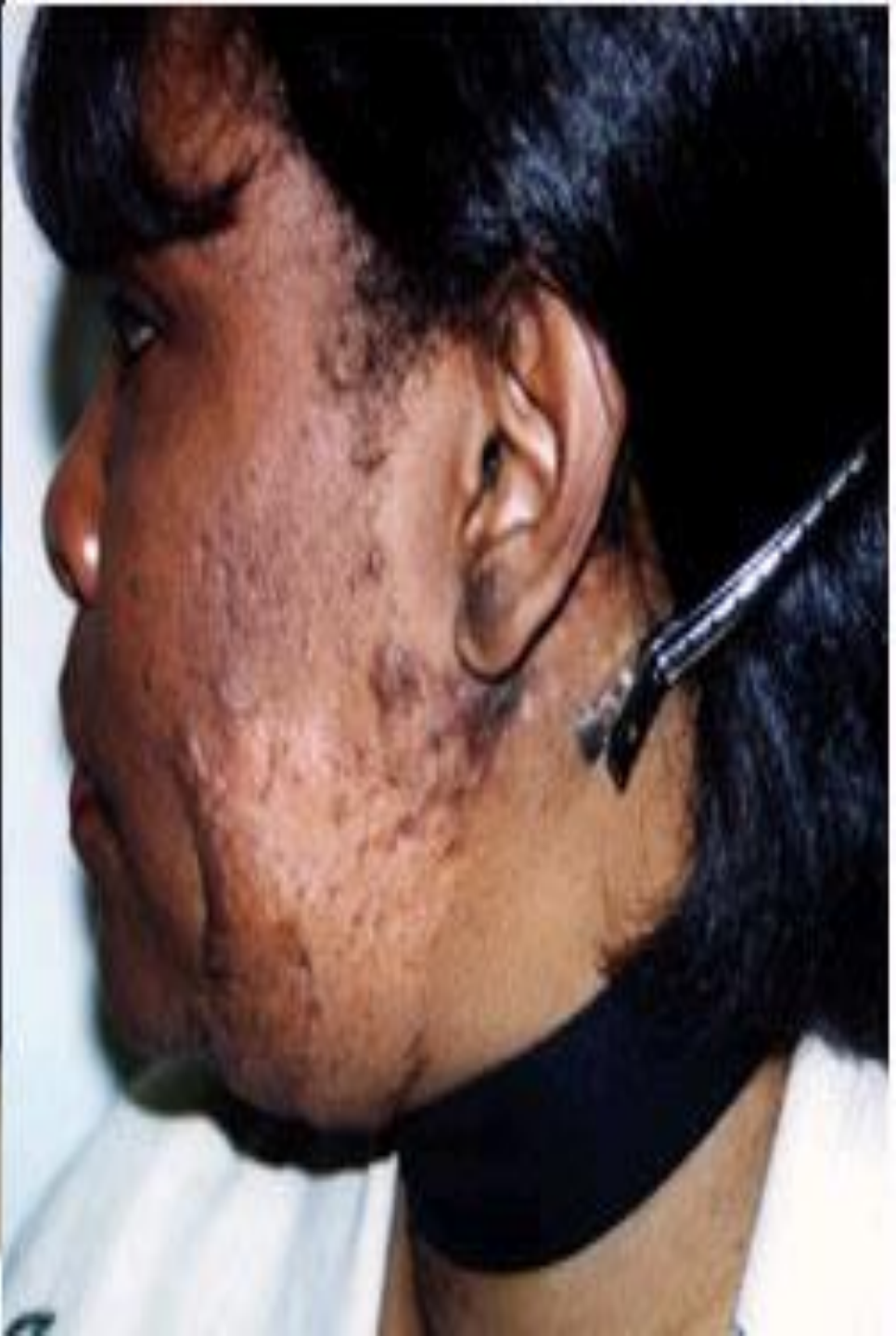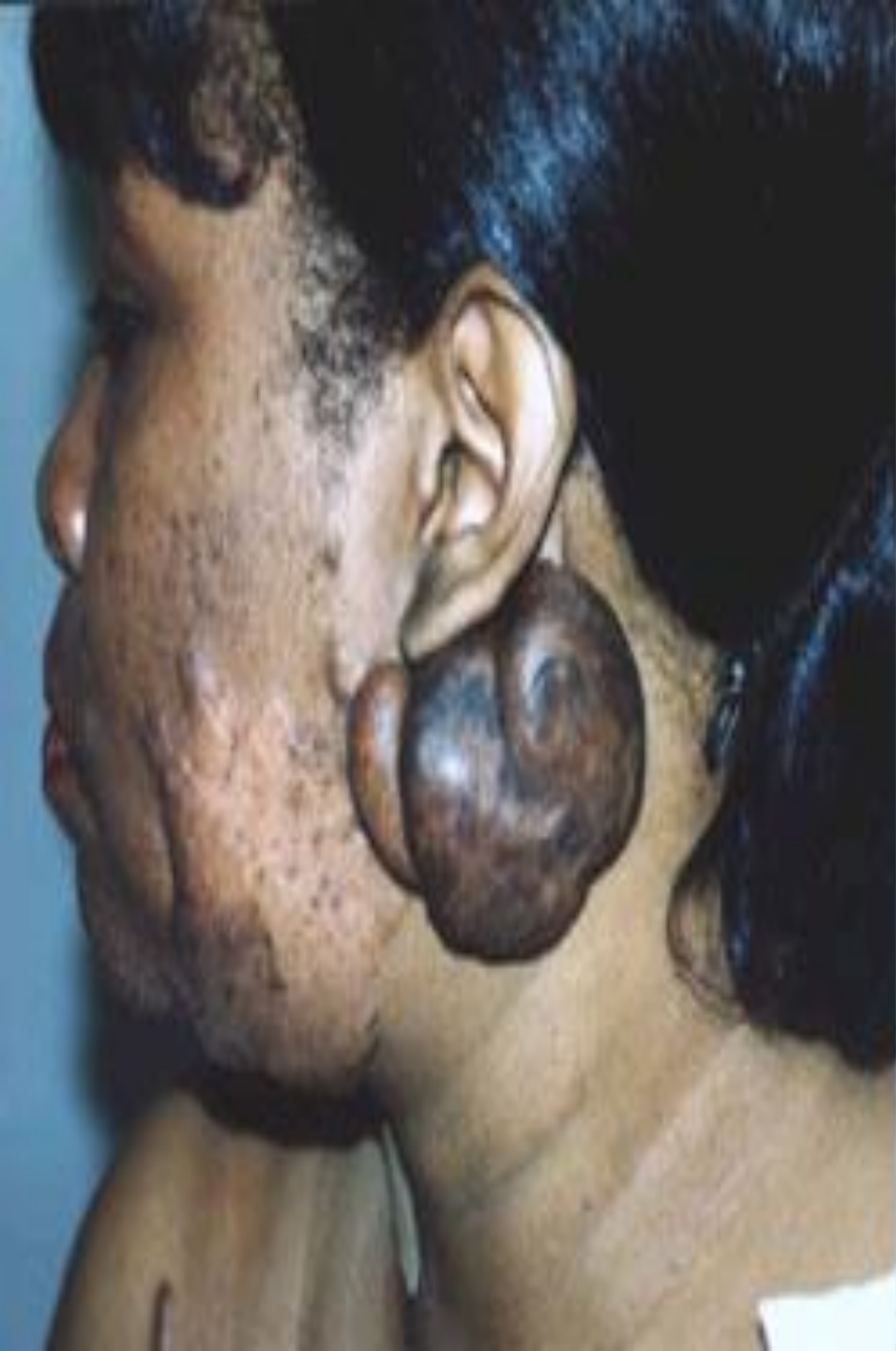- **Extrinsic factors**
 - **Infection**
 - **Diabetes**
 - **Steroids**
- **Type of tissue injured (labile vs. permanent)**
- **Aberrant cell growth or ECM production**
 - **Keloid scars**
 - **Proud flesh**

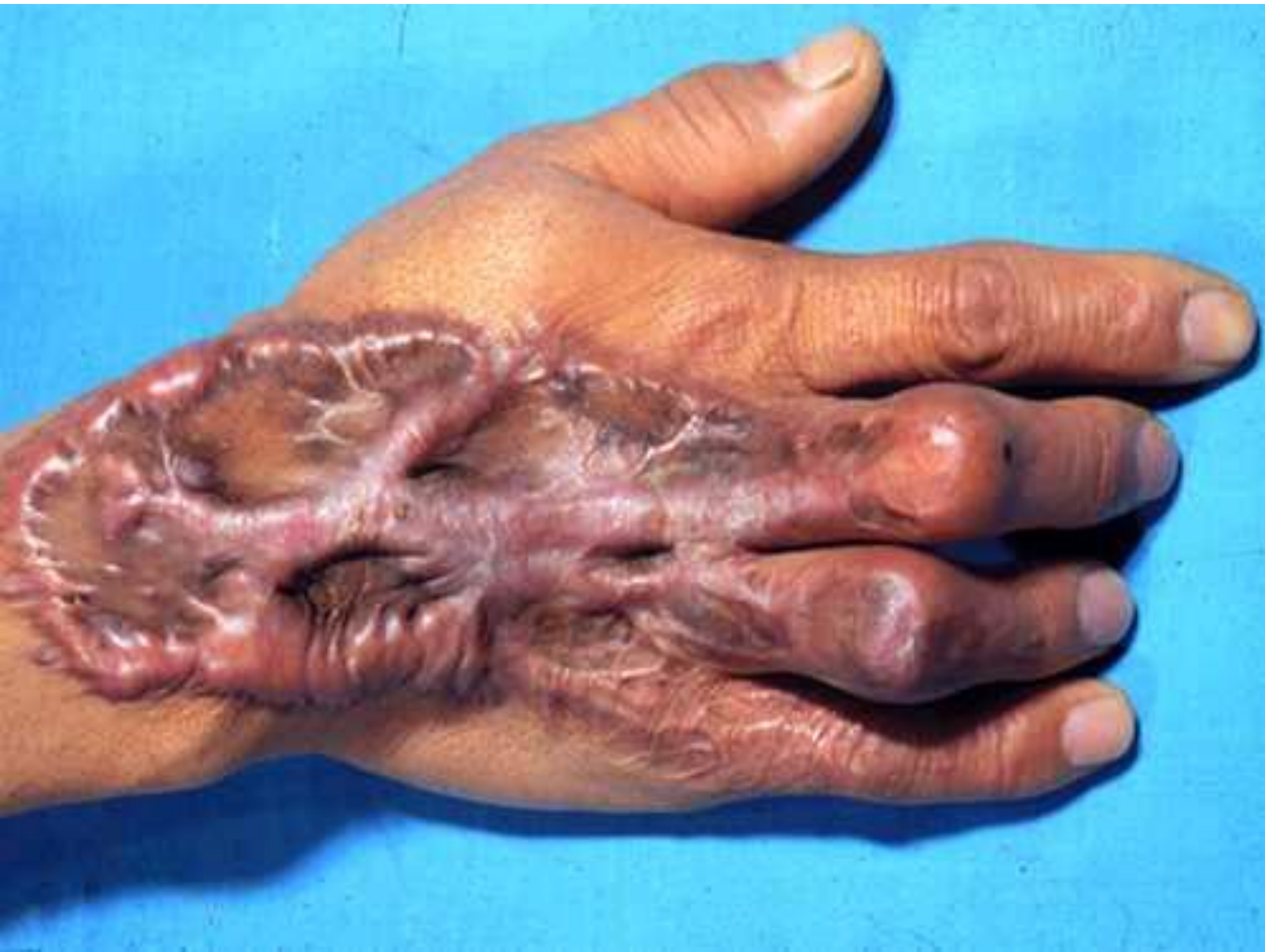


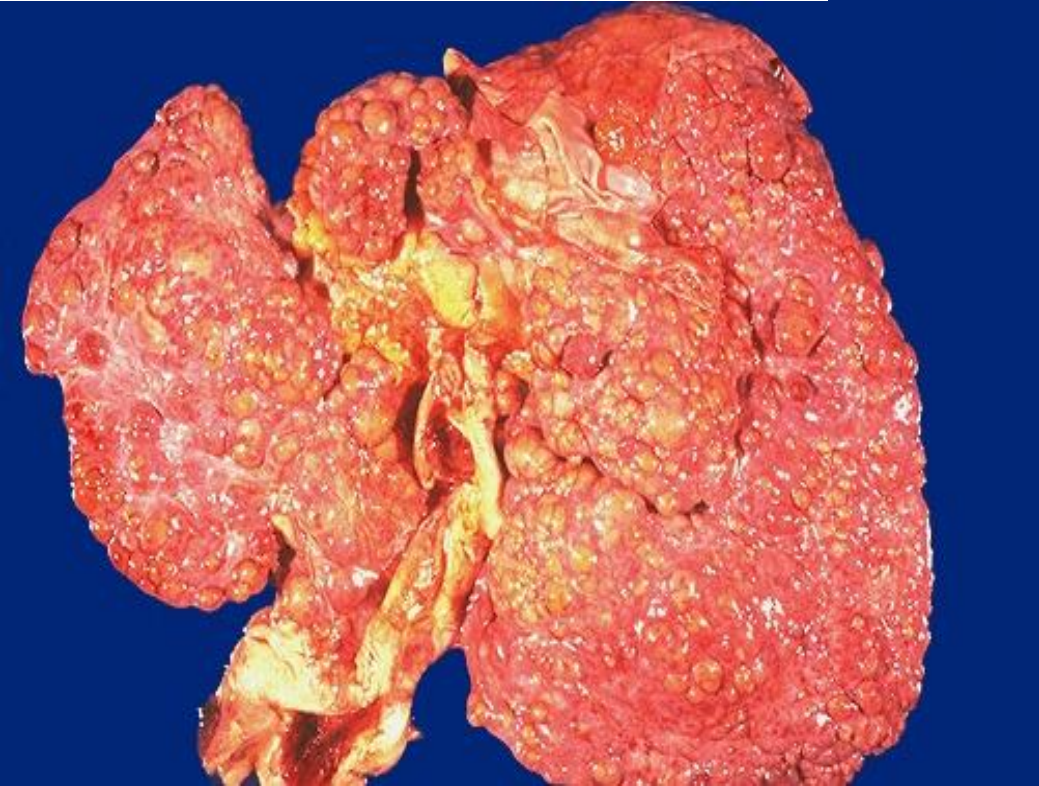
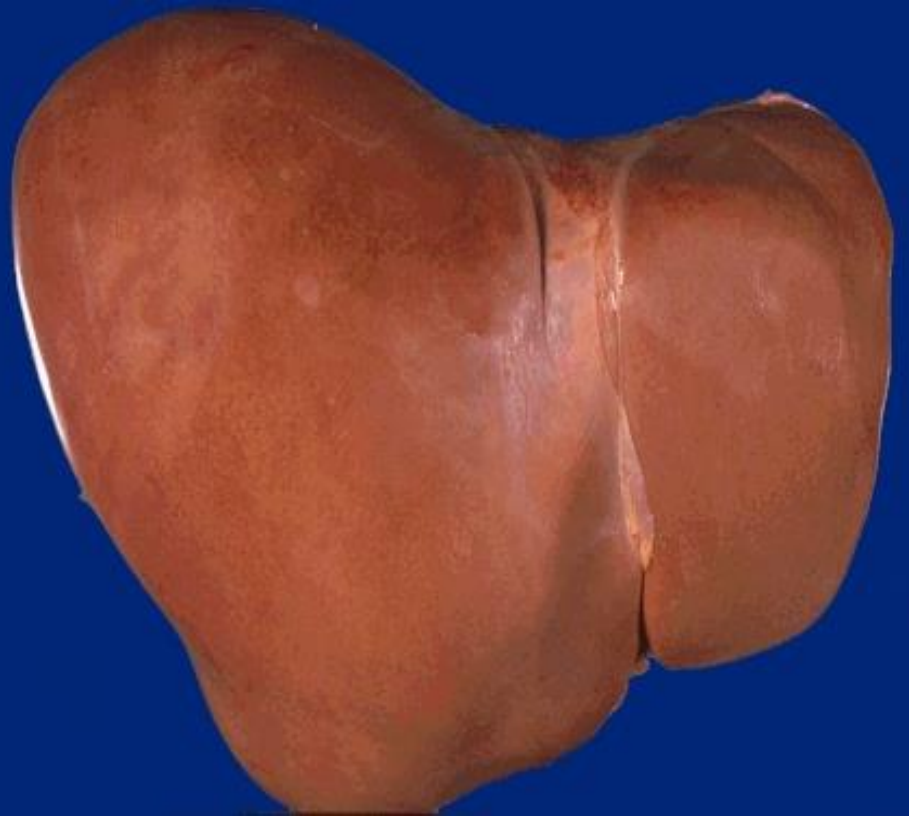

B

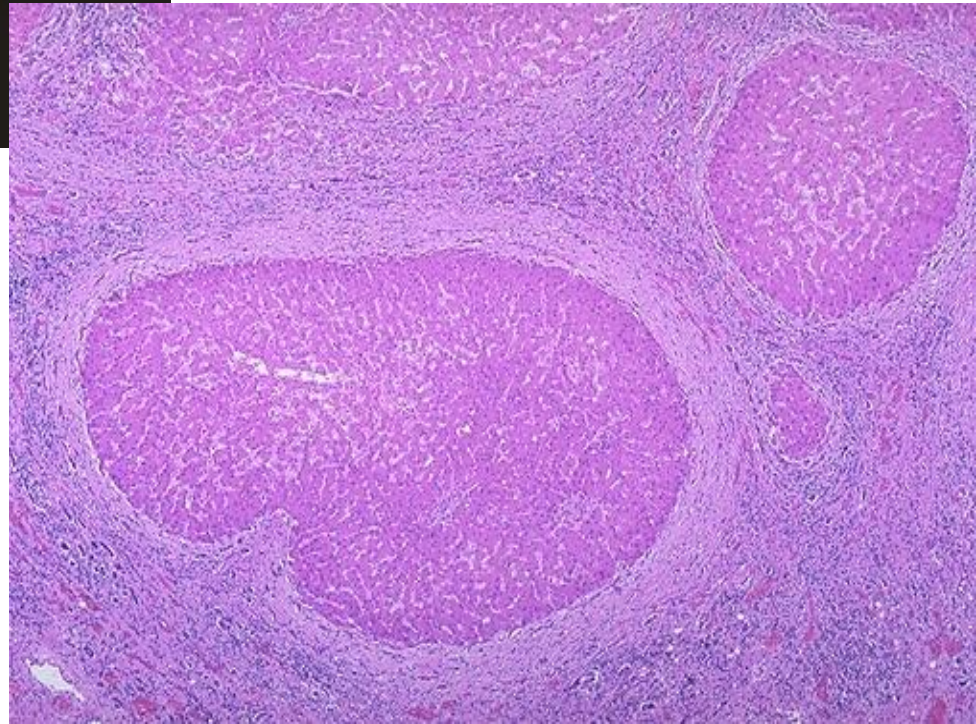
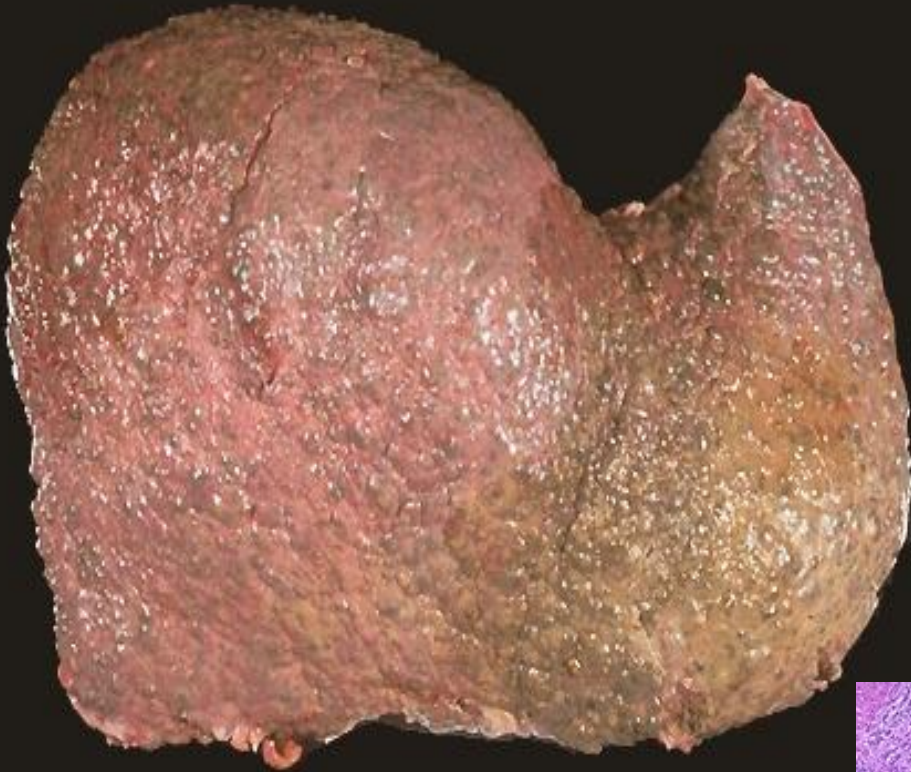







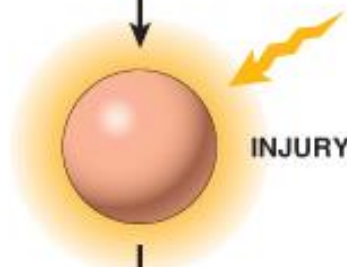
cirrhosis



TISSUE REPAIR SUMMARY

- Not all injuries result in permanent damage; some are resolved almost completely
- More often, there is some degree of scarring
- Scar is usually good (provides a resilient patch) but occasionally bad (can cause permanent dysfunction)

NORMAL HOMEOSTASIS
(balance of proliferation and apoptosis)



REGENERATION

HEALING

Renewing tissues

Stable tissues

Wound

Chronic inflammation

Epidermis, GI tract epithelium, hematopoietic system

