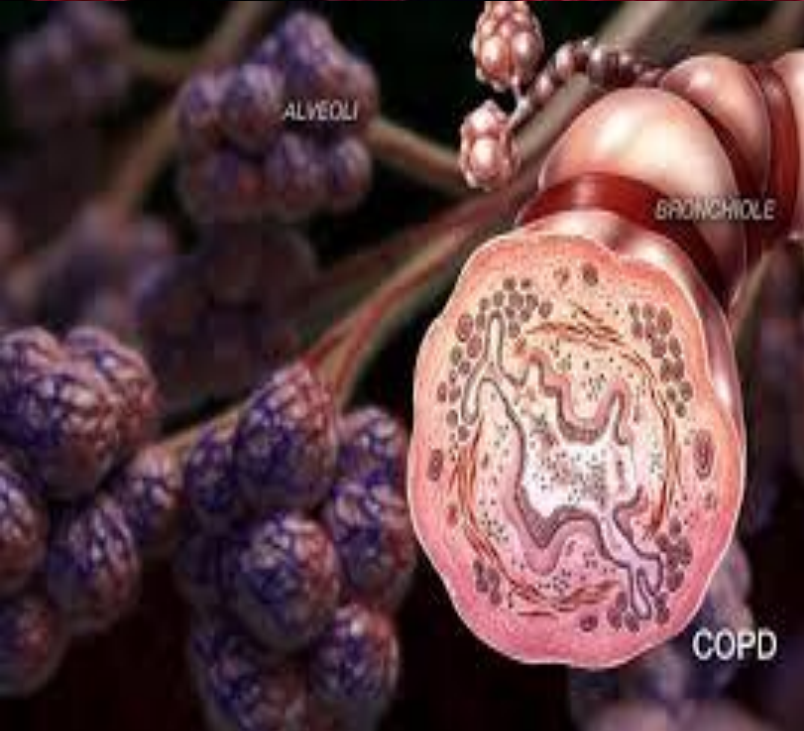
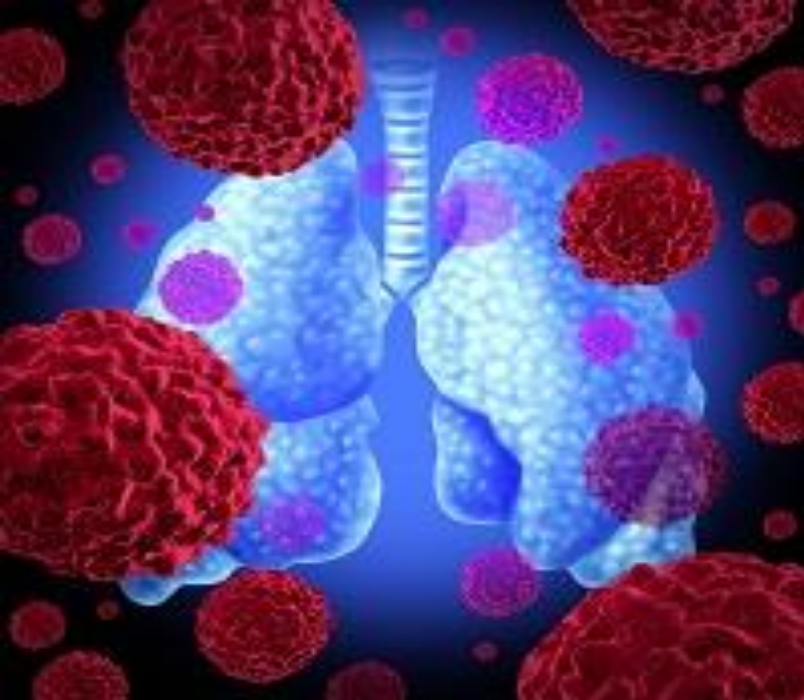
**Acute pulmonary pathology.
Chronic pulmonary pathology.
Lung carcinoma.**

Acute pulmonary pathology. Chronic pulmonary pathology. Lung carcinoma.

I. Microspecimens:

№ 73. Lobar pneumonia (grey hepatization stage). (H-E stain).

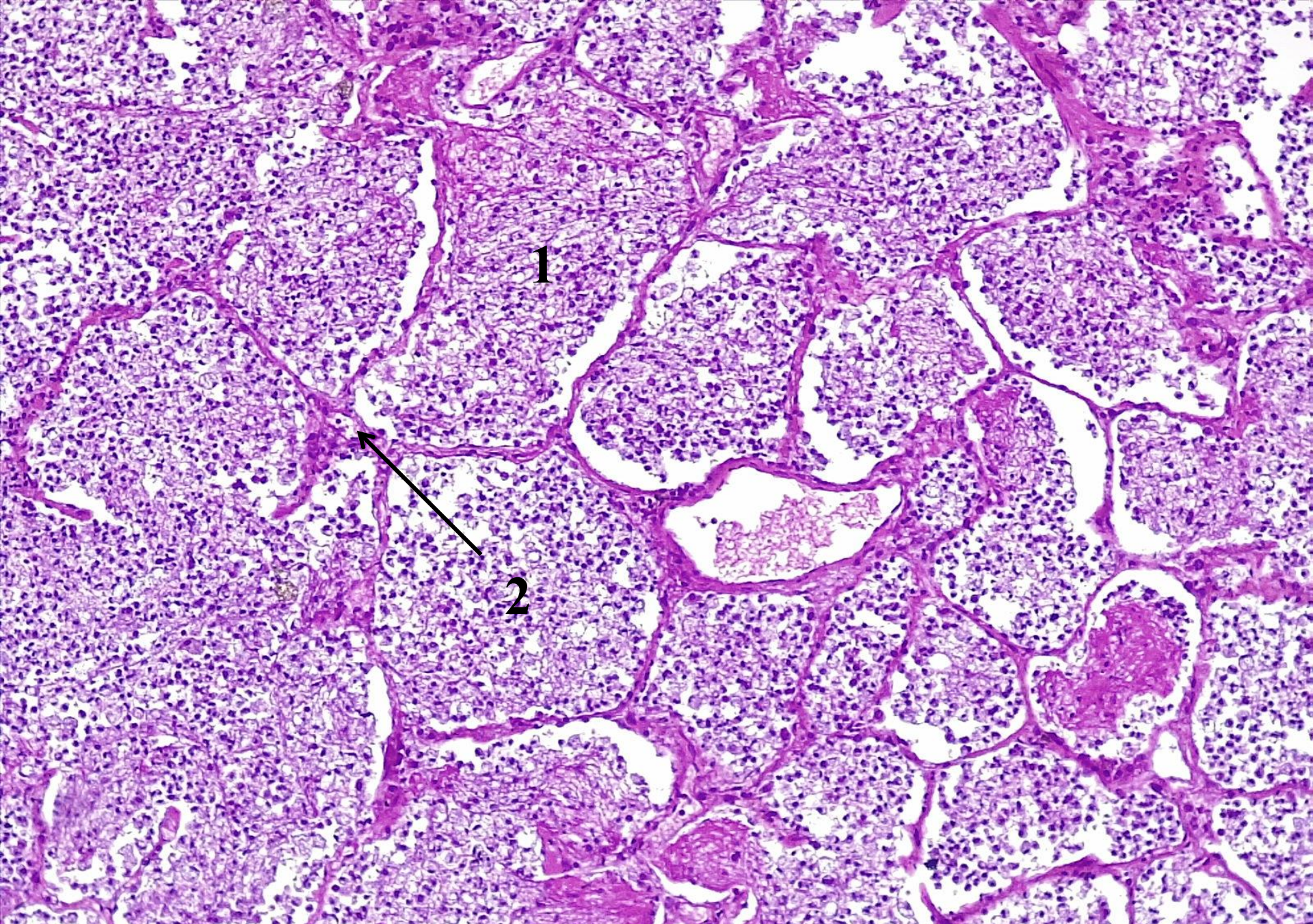
Indications:

1. Exudate into lumen of alveoli:
 - a. fibrin strands; b. neutrophils; c. alveolar macrophages.
2. Hyperemic vessels in interalveolar septa.

In microspecimen it is observed that all alveoli are dilated, unventilated, filled with an exudate consisting of eosinophilic colored fibrin filaments, neutrophilic leukocytes and an insignificant number of alveolar macrophages; the interalveolar septa are thickened, the blood vessels are dilated, hyperemic.

The gray hepatization stage of lobar pneumonia (macroscopic appearance - macrospecimen № 33) is installed over 4-5 days from the onset of the disease. Subsequently, in uncomplicated cases, on the 8-9th day begins the lysis of the exudate by the fibrinolytic action of leukocytes and macrophages and its elimination by lymphatic drainage and sputum. Finally, there is purification of the affected lung and restoration of aeration, which can last 1-3 weeks.

Pleural fibrinous exudate is resorbed or organized with the formation of fibrous adhesions between the pleural sheets. In about 3% of cases the alveolar exudate does not liquefy and is replaced by granulation tissue, which turns into mature fibrillar connective tissue - post-pneumonic fibrosis. Other possible lung complications are pulmonary abscess and pleural empyema. Extrapulmonary complications: purulent pericarditis, mediastinitis, bacterial endocarditis, hematogenous spread of infection with the development of otitis media, meningitis, brain abscess, purulent arthritis. Complications usually develop in patients with low immunity.



№ 73. Lobar pneumonia (*grey hepatization stage*). (*H-E stain*).

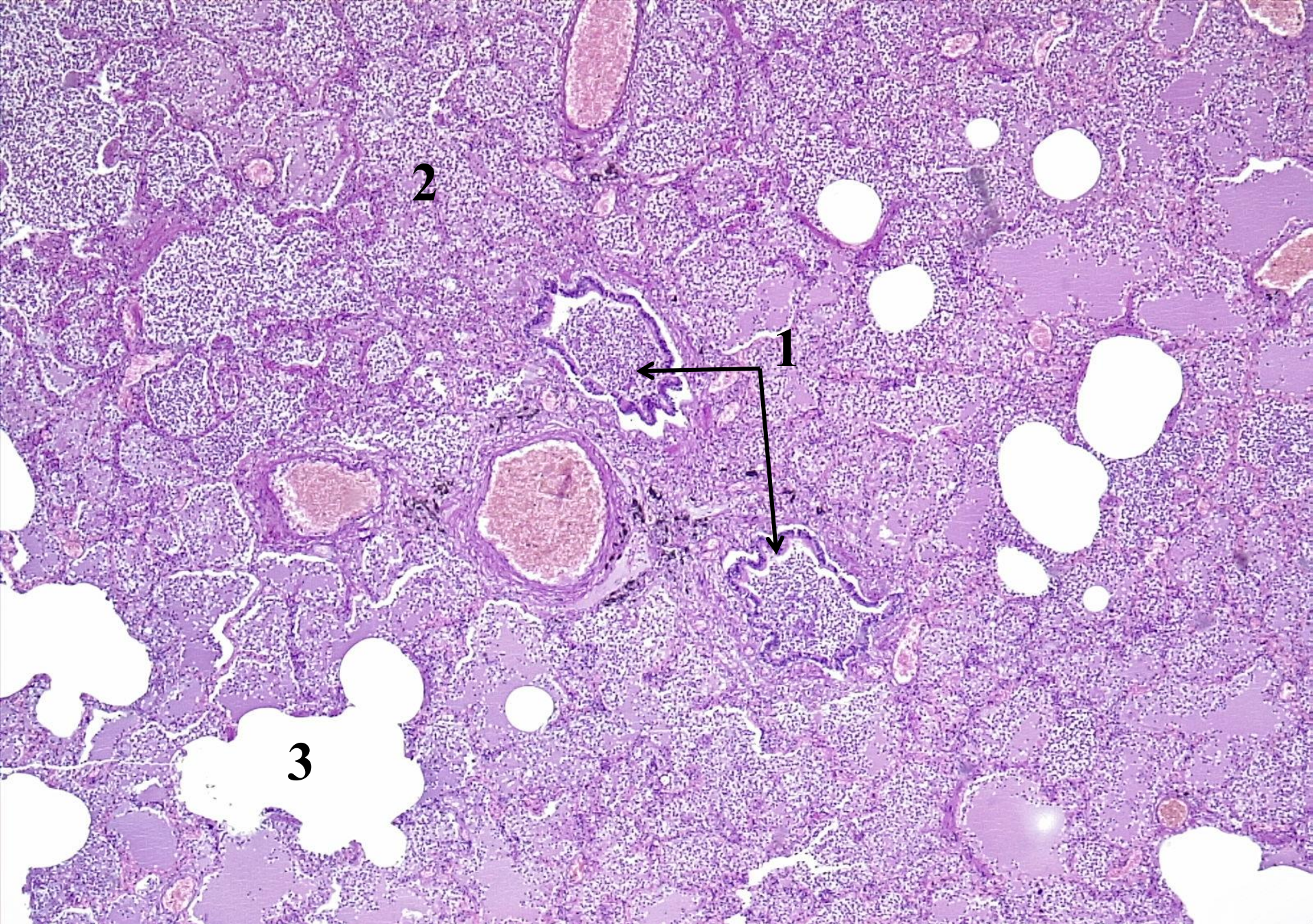
№ 74. Bronchopneumonia (*focal pneumonia*). (*H-E stain*).

Indications:

1. Exudate into the lumen of the bronchus (bronchiolus).
2. Predominantly leukocytic exudate around the bronchi into the alveoli.
3. Unchanged alveoli.

In the lumen of small caliber bronchi (bronchioles) is observed predominantly leukocytic (neutrophilic) exudate, the epithelium in some places is desquamated, the walls are thickened, in their thickness is inflammatory infiltrate rich in lymphocytes and macrophages, dilated and hyperemic blood vessels; around these bronchi or in their vicinity are unventilated foci, the alveoli contain abundant leukocytic (neutrophilic) exudate, in the adjacent areas some alveoli are dilated.

Bronchopneumonia is the most common form of pneumonia, which begins with the initial inflammation of the bronchi and bronchioles with subsequent expansion into the adjacent alveoli (broncho-alveolitis). Inflammation can spread endobronchially, e.g. in catarrhal or peribronchial bronchitis / bronchiolitis, e.g. in destructive purulent bronchitis / bronchiolitis; it can also occur hematogenously when the infection is generalized, e.g. septic pneumonia. Inflammation is unevenly distributed, there may be foci spread in several lung lobes, primarily in the lower ones. It is a polyetiological condition, the most common being of bacterial origin (staphylococci, streptococci, pneumococci, Klebsiella pneumoniae), but it can also be caused by viruses (eg, influenza, measles), fungi, mycoplasmas. Intraalveolar exudate has a polymorphic composition, containing serous fluid, mucus, neutrophil leukocytes, macrophages, erythrocytes, fibrin, desquamated epithelial cells. It is much more common in the extremes ages (the elderly and children). A favorable role is played by aspiration (aspiration pneumonia), pulmonary stasis (hypostatic pneumonia), surgery (postoperative pneumonia), immunodeficiency states (immunodeficiency pneumonia). Complications of bronchopneumonia are identical to those of lobar pneumonia (microspecimen № 73). In cases of subpleural localization of pneumonic foci, fibrinous pleuritis may develop, and bronchiectasis may occur in connection with the destruction of the walls of the bronchi / bronchioles.



№ 74. Bronchopneumonia (*focal pneumonia*). (H-E stain).

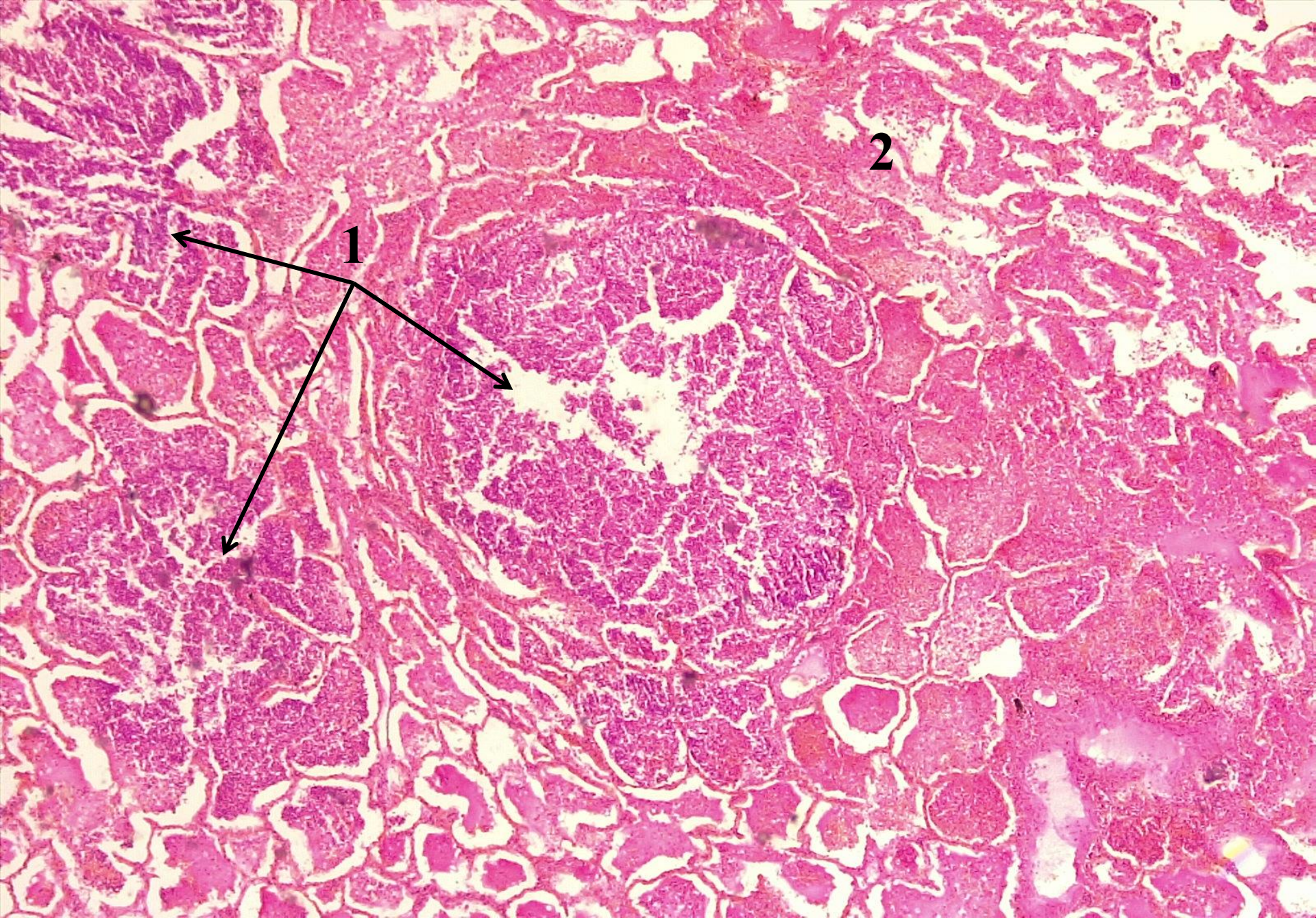
№ 126. Bronchopneumonia with abscess formation. (*H-E stain*).

Indications:

1. Focus of purulent inflammation with lysis of the lung parenchyma (abscess).
2. Adjacent alveoli with inflammatory exudate.

In microspecimen are extensive areas of pneumonia with abundant intraalveolar exudate of fibrin and neutrophilic leukocytes; in these areas there are several foci of different sizes, in which the interalveolar septa are necrotic and lysed, forming cavities with purulent content (microabscesses).

Bronchopneumonia with abscess formation is usually caused by staphylococci and streptococci. Abscesses occur as a result of necrosis, destruction and lysis of necrotic tissue. Necrosis is due to the direct harmful action on the tissues of toxins of pyogenic bacteria, as well as circulatory disorders related to vessel thrombosis and their compression by inflammatory edema. Histolysis occurs by proteolytic enzymes elimination by neutrophil leukocytes. It is more common in patients with various comorbidities, eg, congestive heart failure, chronic lung disease, diabetes, immunodeficiency, especially in elderly. It is often followed by a viral infection due to the association of the secondary bacterial infection. Consequences: organization, calcification of abscesses, chronic evolution (chronic abscess).



№ 126. Bronchopneumonia with abscess formation. (H-E stain).

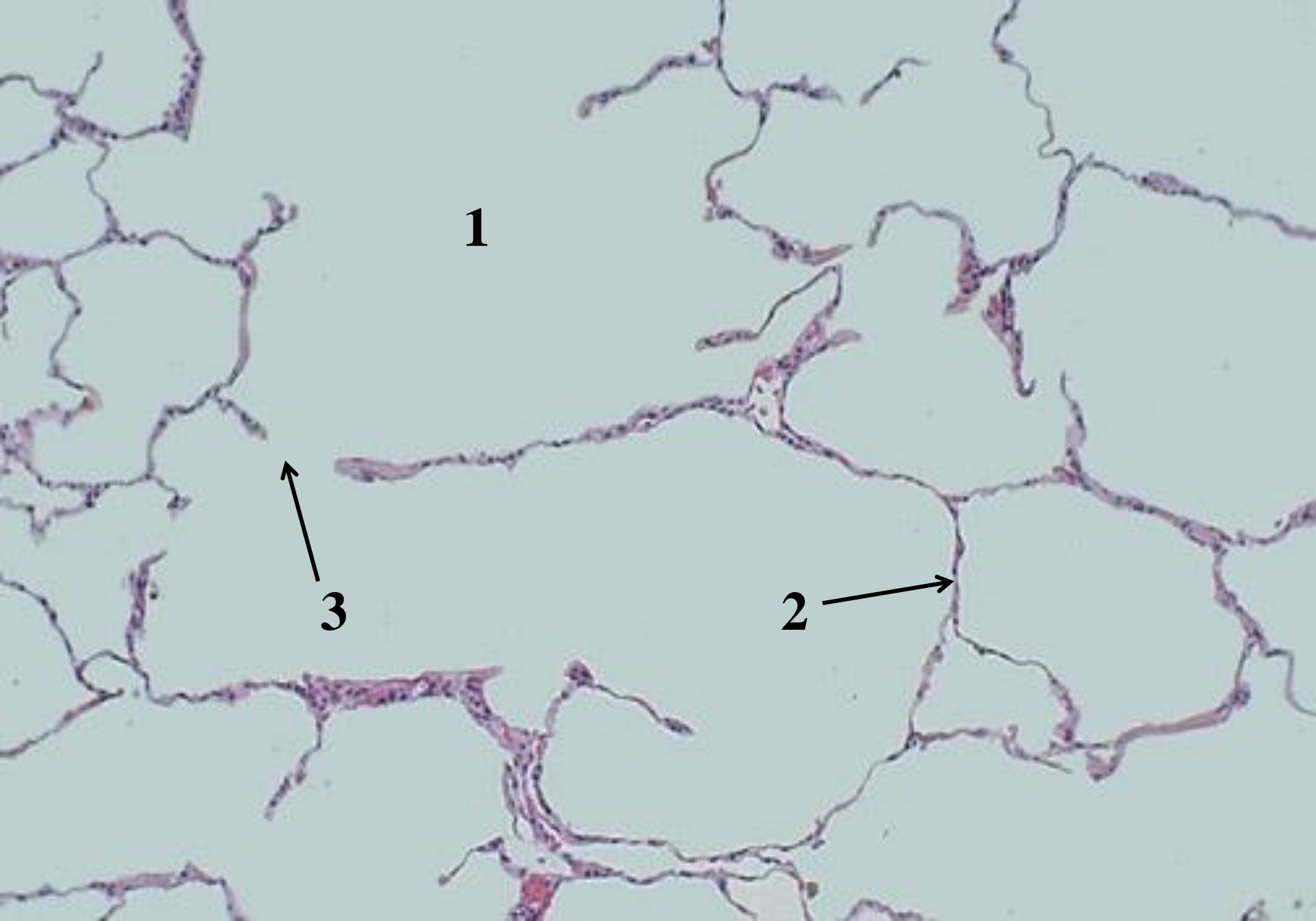
№ 75. Pulmonary emphysema. (H-E stain).

Indications:

1. Large air cavities.
2. Thinned interalveolar septa
3. Ruptures of interalveolar septa.
4. Sclerosis and reduction of blood capillaries.

The alveoli are dilated, the interalveolar septa are thin, in some places broken, some alveoli confluence, forming wide air spaces, in which the ends of the ruptured septa are observed, the number of septal capillaries is reduced.

Emphysema is a chronic obstructive disease, characterized by excessive air content in the lungs and increasing their size. There is a permanent widening of the air spaces, located distal to the terminal bronchioles. The most common form is chronic diffuse obstructive emphysema, caused by chronic bronchitis, primarily by chronic bronchitis of the smoker. In diffuse obstructive emphysema the thoracic cavity is dilated, deformed, acquires a "barrel" appearance. Depending on the distribution of the lesions within the lung lobes, there are 2 main types of emphysema: centroacinar (centrolobular) and panacinar (panlobular). In centroacinar emphysema the respiratory bronchioles are affected, they dilate but the distal alveoli are normal. It is more common in the upper lobes of the lungs. In panacinar emphysema the acini are uniformly enlarged from the respiratory bronchiole to the terminal alveoli. It is located more frequently in the lower lobes. The destruction of the walls of the bronchioles and alveoli is not accompanied by fibrosis. These lesions of the lung parenchyma lead to reduced gas diffusion capacity and respiratory failure. In addition to the destruction of the alveoli, the number of septal capillaries is also reduced, alveolo-capillary block appears, which leads to the development of hypertension in the small circulation and hypertrophy of the right ventricle of the heart (cor pulmonary).



№ 75. Pulmonary emphysema. (H-E stain).

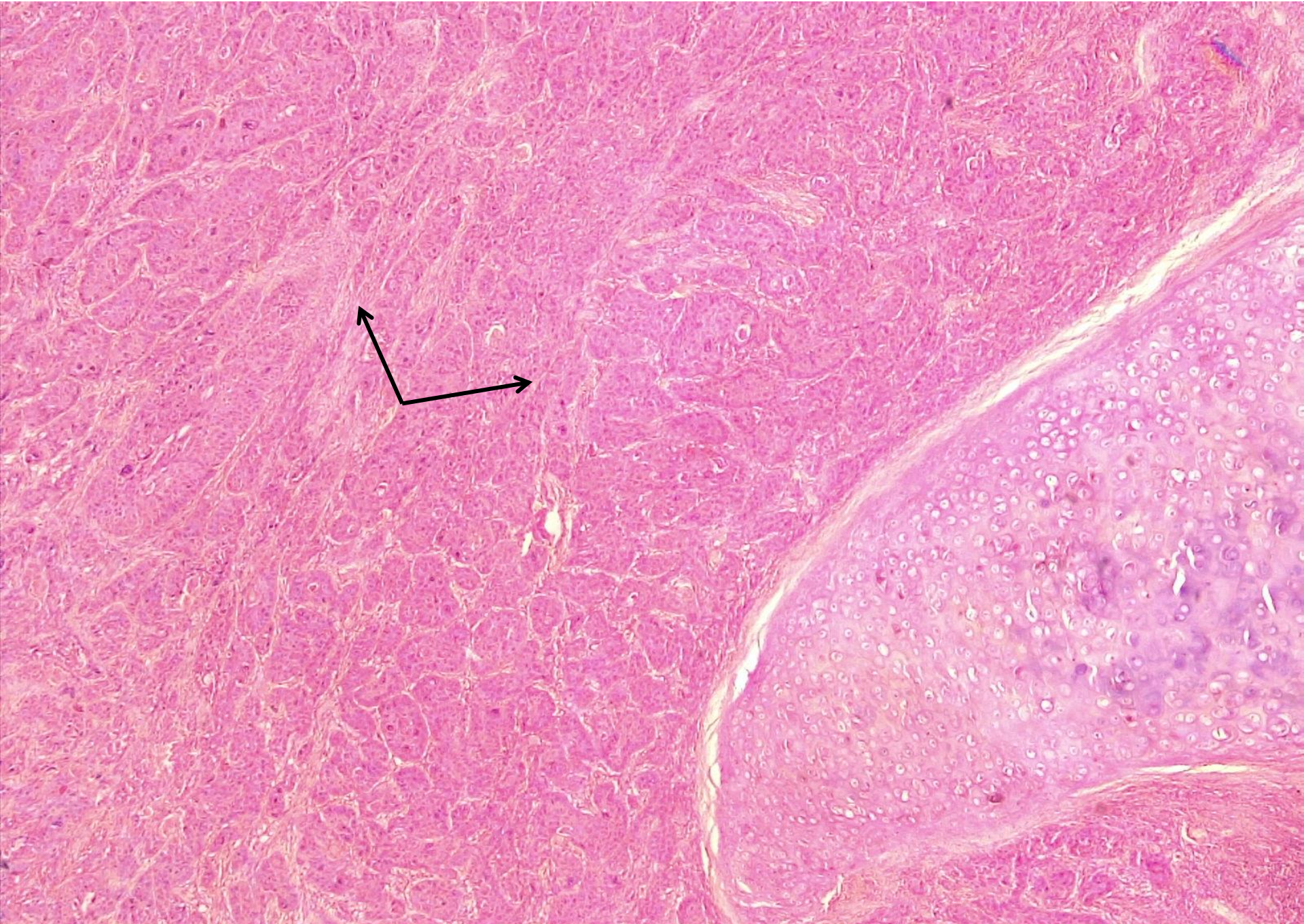
№ 50. Pulmonary nonkeratinizing squamous cell carcinoma. (H-E stain).

Indications:

1. Squamous metaplasia of the bronchial epithelium.
2. Nests of atypical polymorphic tumoral cells.

In the microspecimen a bronchus is present, in the epithelium of which foci of squamous metaplasia are observed. In the bronchial wall, around the cartilage and in the surrounding alveolar tissue, which is compact, unventilated, there are nests of different sizes of tumor cells with squamous cell appearance, polymorphic, hyperchromic nuclei, mitosis figures.

Squamous cell carcinoma develops from the epithelium of the mucosa of the main bronchi (central or parahilar carcinoma), being preceded by metaplasia and squamous dysplasia of the bronchial epithelium. It is more common in men and is associated with smoking. Keratin pearls are missing in non-keratinized squamous cell cancer. [microspecimen № 39].



№ 50. Pulmonary nonkeratinizing squamous cell carcinoma. (*H-E stain*).

II. Macrospecimens:

№ 33. Lobar pneumonia.

The affected lobe is enlarged in size, non-aerated, of firm consistency (similar to the consistency of the liver), on the section it has a granular appearance, gray color due to the storage in alveoli of fibrinous exudate with a rich content of neutrophils and macrophages; fine deposits of fibrin (parapneumonic fibrinous pleuritis) are observed on the pleura. [microscopic appearance - microspecimen № 73]

№ 31. Bronchopneumonia (focal pneumonia).

On cross section of the lung, single or multiple non-aerated foci are observed, sizes from 1-2 to 3-4 cm, slightly elevated of gray-yellow color, the adjacent lung tissue is normal or slightly edematous. [microscopic appearance - microspecimen № 74]

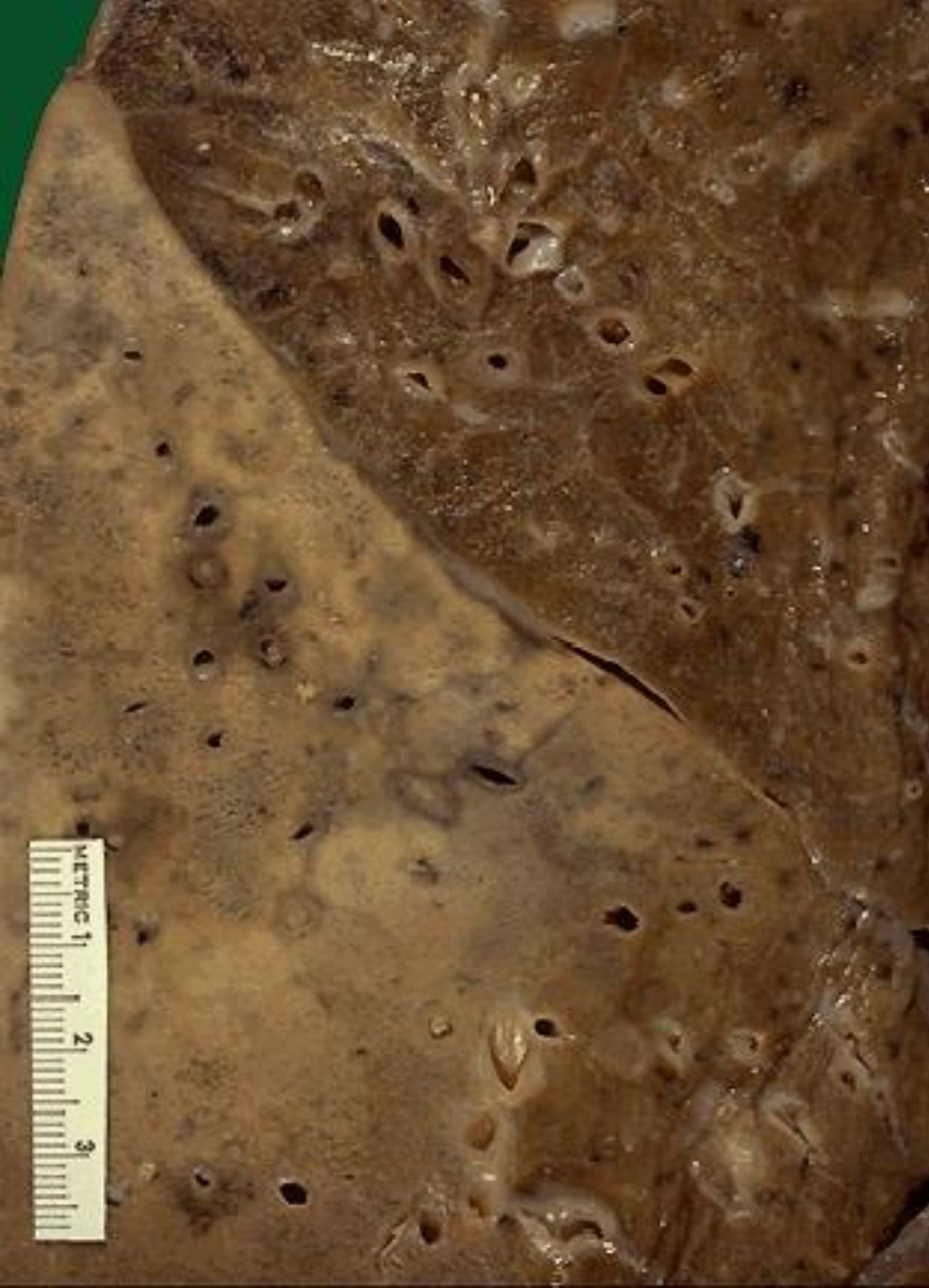
№ 32. Bronchopneumonia with abscess formation.

On the cross section disseminated foci of whitish-gray color are observed with a diameter of up to 2-3 cm, slightly elevated, separated by intact lung tissue. In some of these foci are irregularly shaped cavities, varying in size from 0.5 to 1-1.5 cm, filled with pus or without content - abscesses. In the pleura, in the case of subpleural localization of foci of pneumonia may be fibrin deposits. [microscopic appearance - microspecimen № 126]

№ 34. Fibrinous pleuritis.

The visceral sheet of the pleura is matte, covered with a thin membrane of whitish fibrin, sometimes glued to the pleura, and sometimes detached, which gives it a rough appearance.

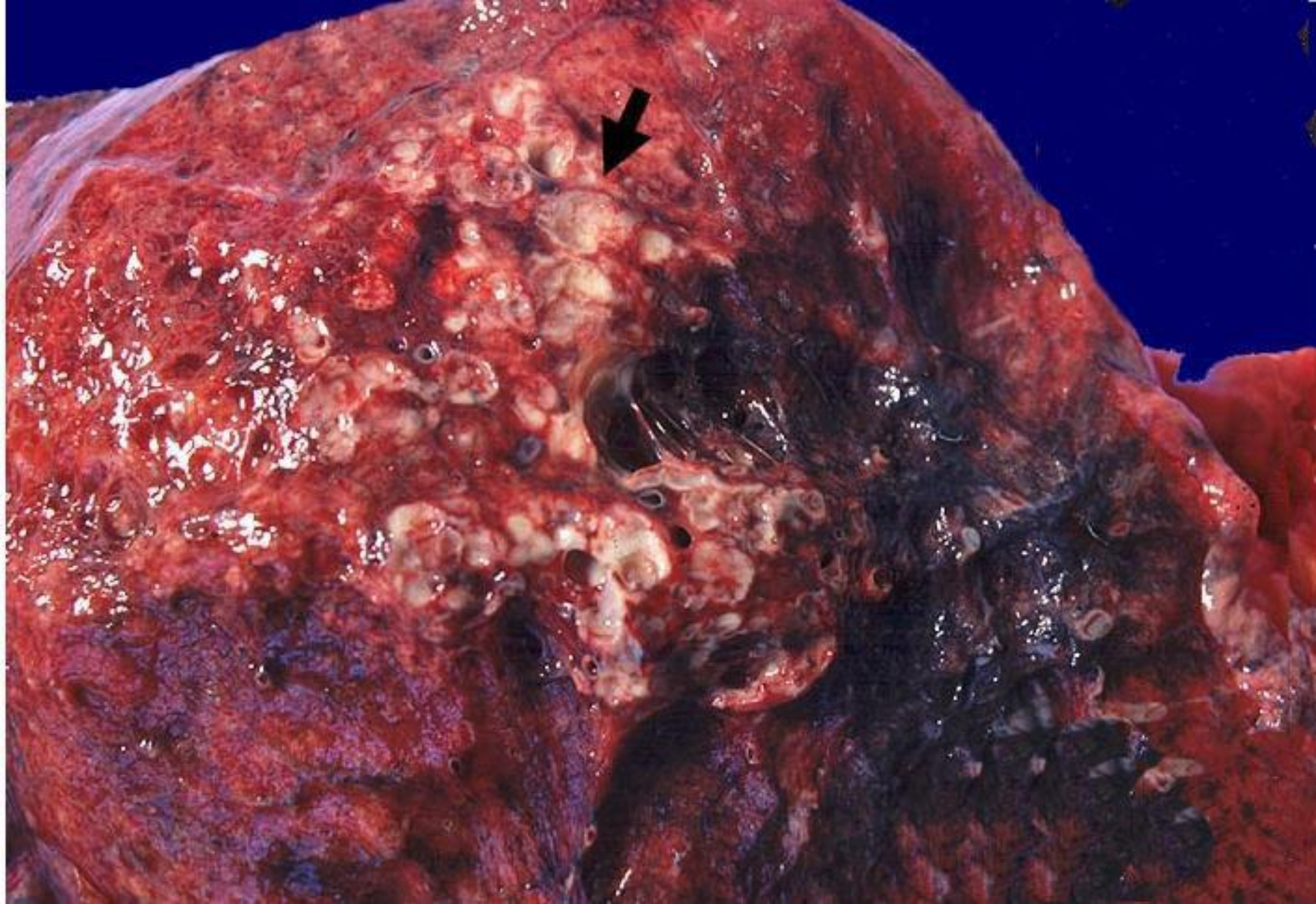
Fibrinous pleuritis in most cases is of infectious origin and is found in pneumonia, especially lobar, tuberculosis, infarction, lung abscess and bronchiectasis. It is also observed in some rheumatic diseases (rheumatoid arthritis, systemic lupus erythematosus), in uremia, cancer metastases. Manifested at auscultation by pleural rubbing noise. Consequences: resorption of exudate or fibrous organization with the appearance of adhesions between the pleural sheets with partial or total obliteration of the cavity. The formation of adhesions in the pleura reduces the amplitude of respiratory movements of the lungs.



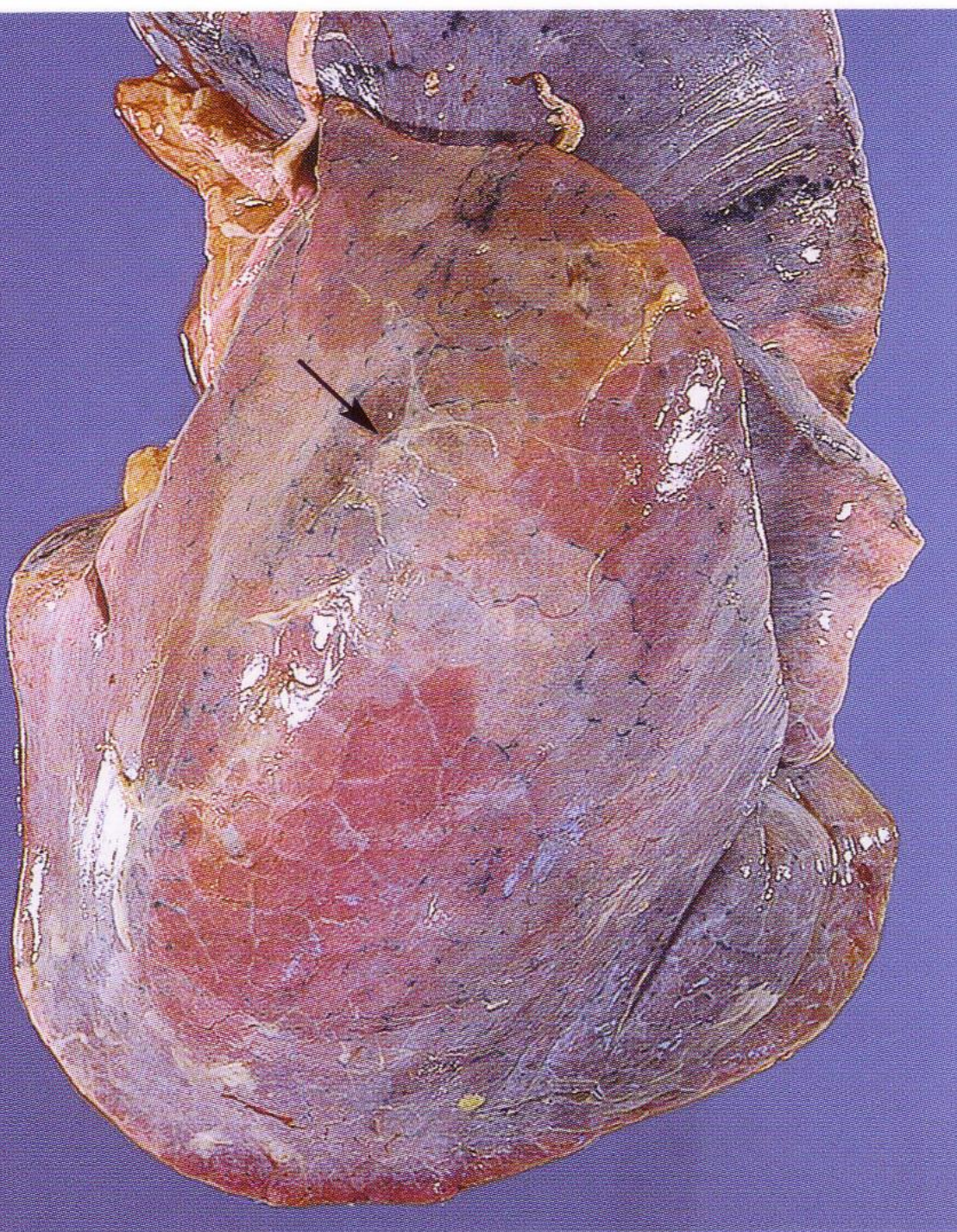
№ 33. Lobar pneumonia.



№ 31. Bronchopneumonia (focal pneumonia).



№ 32. Bronchopneumonia with abscess formation.



№ 34. Fibrinous pleuritis.

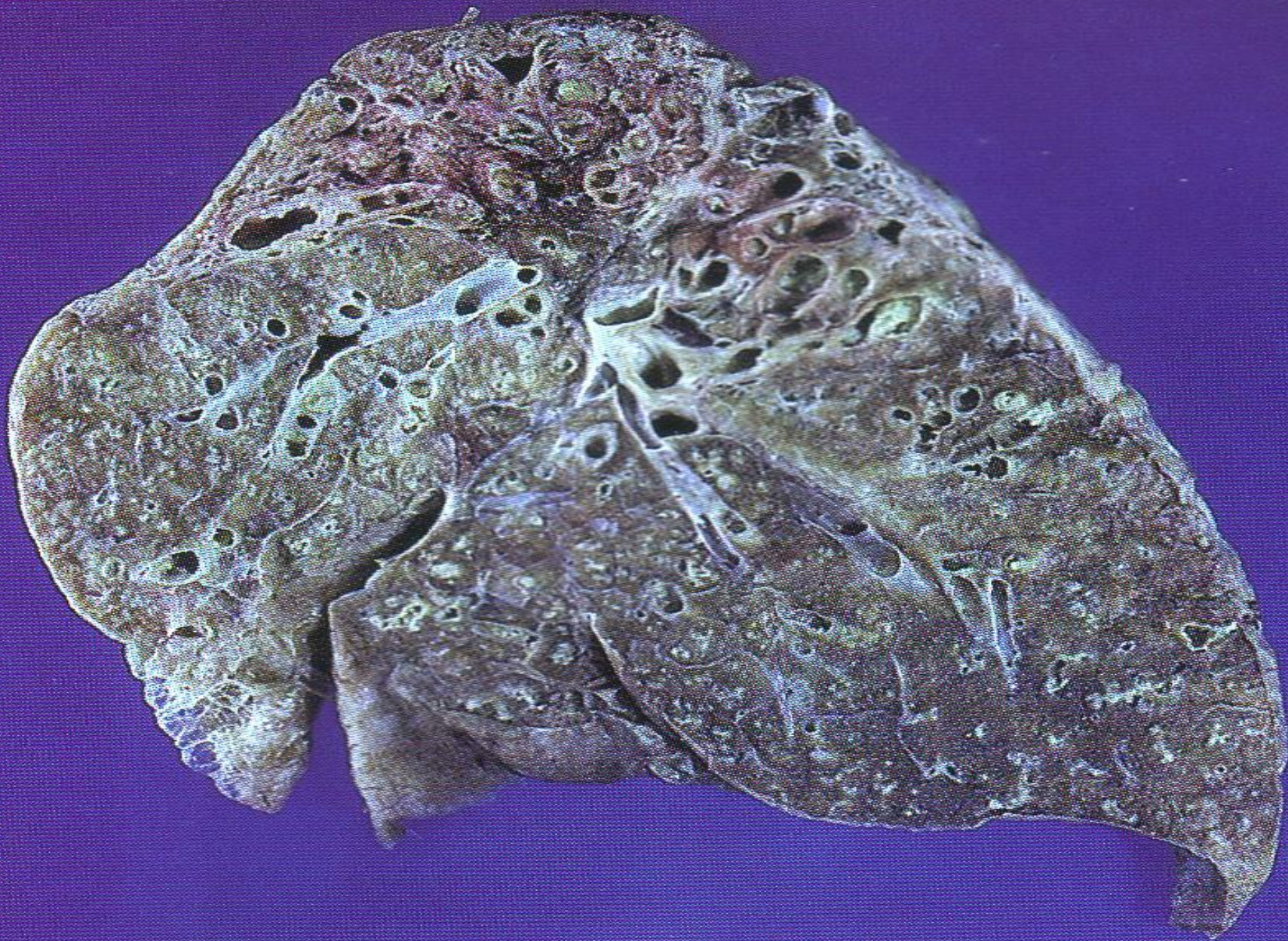№ 35. Bronchiectases with pulmonary fibrosis.

On the section of the lung, multiple dilations and deformations of the bronchi are observed, of irregular shape, the walls are thickened, sclerosed, the surrounding lung tissue is poorly aerated, sclerosed, has a whitish color.

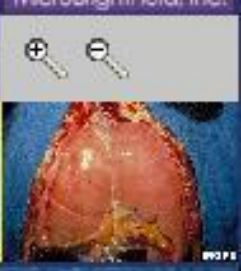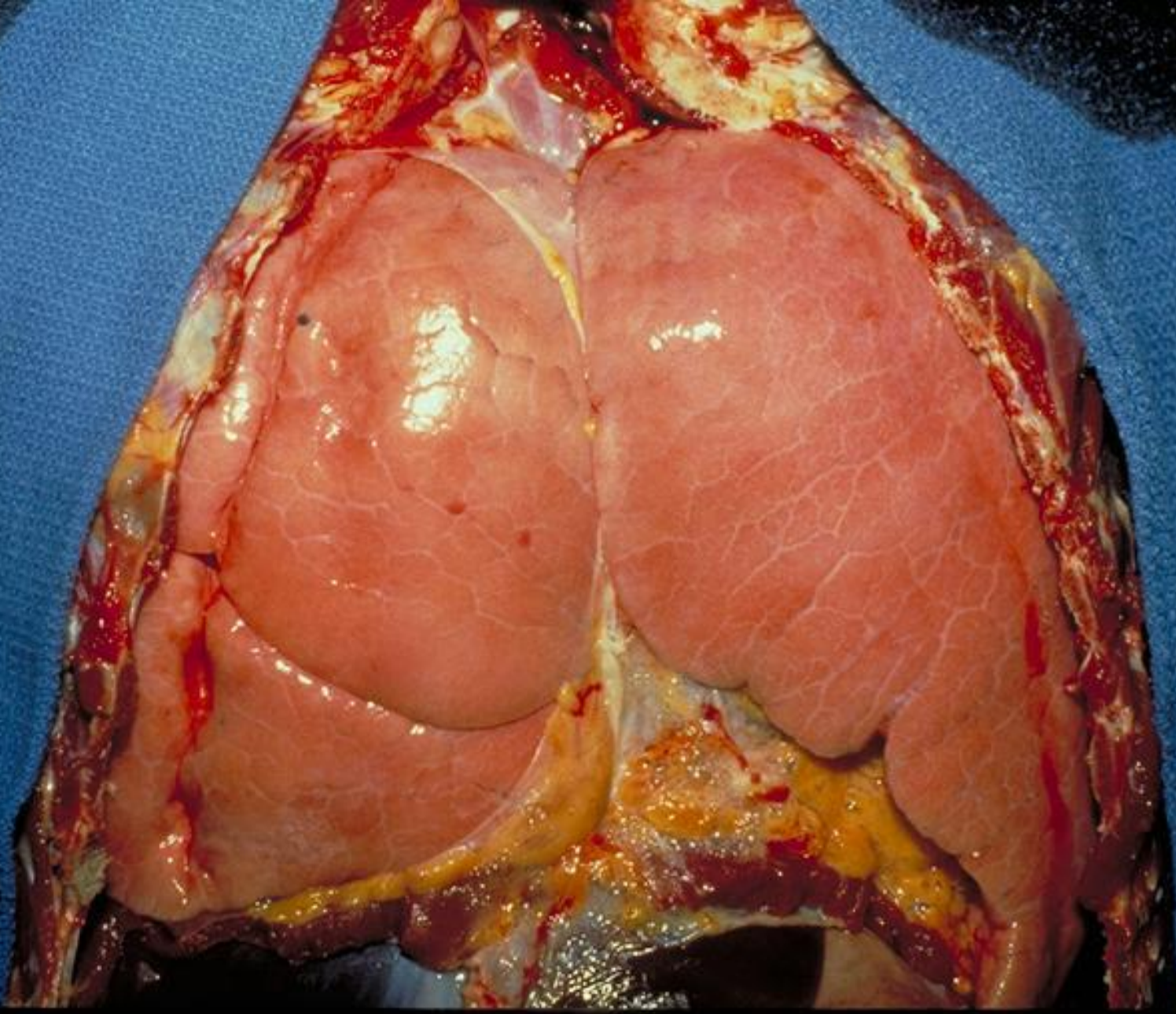
Bronchiectases is permanent dilation of the bronchi and bronchioles, caused by chronic bronchitis. Morphologically, they can be cylindrical and sacular bronchiectasis (sacciform). The wall of bronchiectasis is thickened, sclerosed, with chronic inflammatory infiltration, the lumen usually contains purulent exudate. They can be complicated by hypertension of the small circulation and hypertrophy of the right ventricle of the heart, hemorrhages, peribronchial sclerosis, lung abscess, amyloidosis, are a precancerous condition.

№ 36. Pulmonary emphysema.

The lung is enlarged in volume, over-aerated, on the surface with subpleural bullous formations, with thin walls, filled with air, on a section with a puffy, porous appearance, gray color. [microspecimen № 75]



№ 35. Bronchiectases with pulmonary fibrosis.

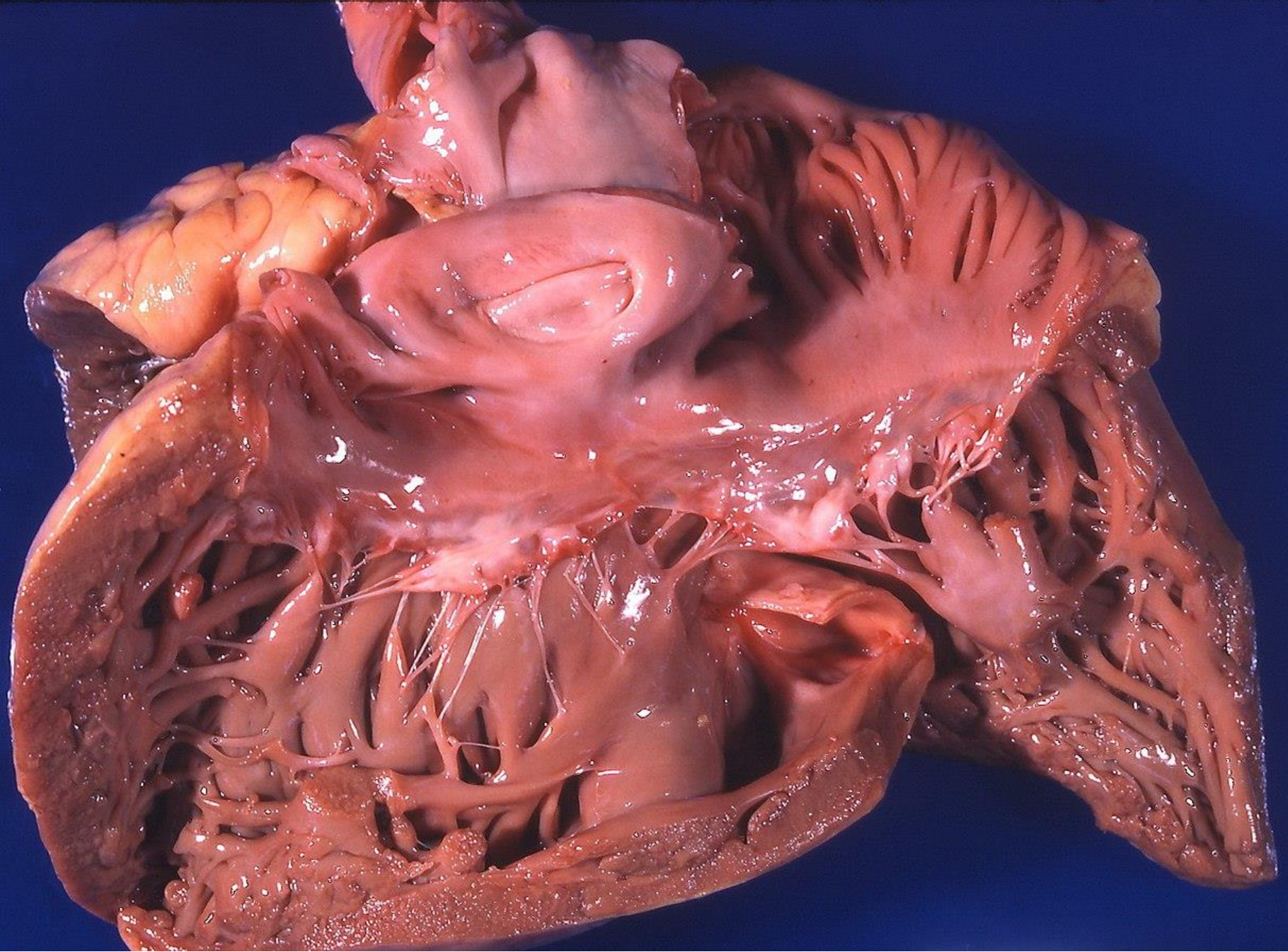


№ 36. Pulmonary emphysema.

№ 5. Right ventricular hypertrophy (cor pulmonale).

The wall of the right ventricle is thickened, has a thickness of up to 1-1.5 cm (norm 2-3 mm) of dense-elastic consistency.

Right ventricular hypertrophy develops as a result of long-term pulmonary hypertension, which is found in various chronic lung diseases, eg, pulmonary emphysema, bronchiectases, interstitial pneumonia, secondary pulmonary tuberculosis, pneumoconiosis (hence the name - cor pulmonale). Decompensation of the right heart is manifested by generalized peripheral edema and congestion of internal organs but pulmonary congestion is minimal. Right ventricular hypertrophy may be associated with left heart failure, more commonly in decompensated mitral valvulopathies, especially in mitral stenosis.



№ 5. Right ventricular hypertrophy (cor pulmonale).

№ 39. Bronchogenic carcinoma.

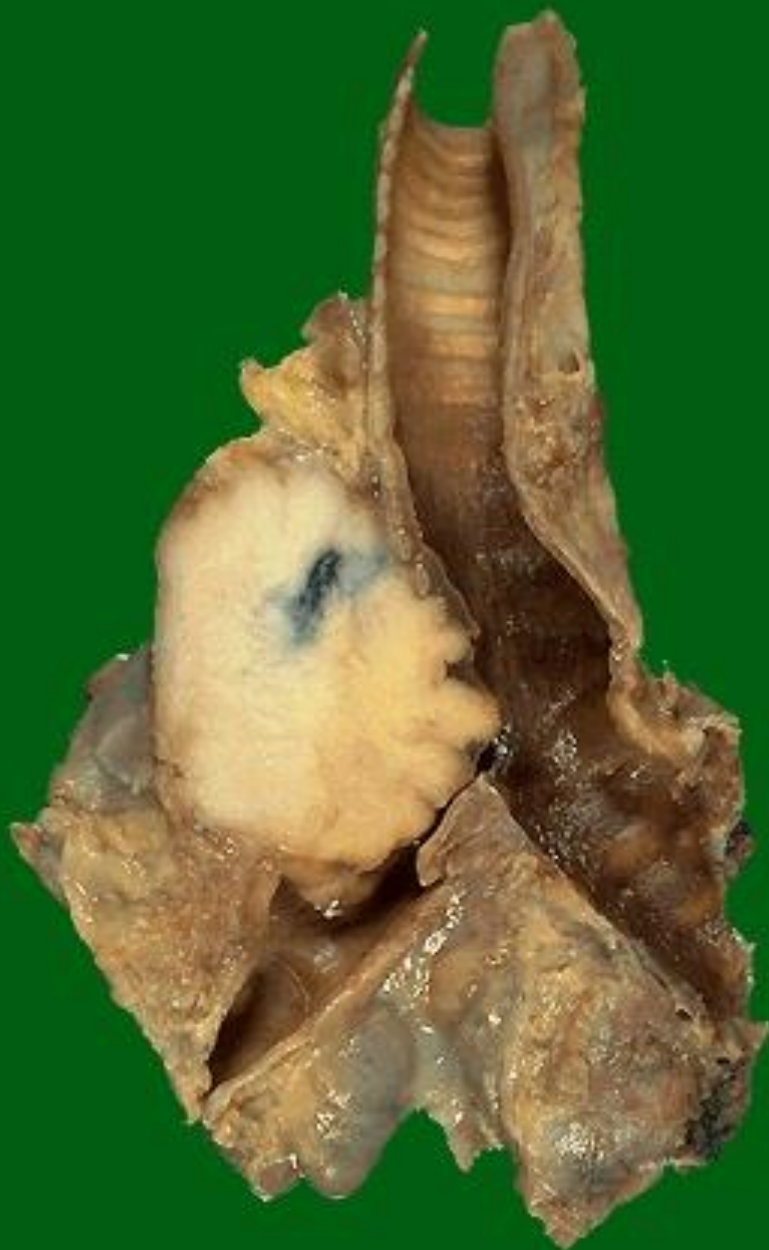In the main bronchus is a tumor node, size ~ 4-5 cm, which has exophytic type of growth with stenosing the lumen, has rough surface, of dense consistency, white-yellow color, tumor tissue infiltrates the adjacent peribronchial lung parenchyma.

It develops from the epithelium of the main bronchi and their branches, more often on the right. It is frequently complicated with atelectasis through obturation, hemorrhage, abscess, fibrino-hemorrhagic or purulent pleuritis. Infiltrative growth can occur in peribronchial lung tissue, contralateral bronchi and lungs, pleura, pericardium, and myocardium. Lymphogenic metastases occur in the mediastinal, cervical, supraclavicular, para-aortal lymph nodes, hematogenous metastases - in various organs, more commonly in the liver, adrenal glands, bones, pancreas, brain, etc. It usually occurs on the background of chronic bronchitis, especially in smokers' bronchitis, bronchiectases, chronic abscess, pneumoconiosis. The most common histological form is keratinizing or non-keratinizing squamous cell carcinoma, preceded by squamous metaplasia of the respiratory epithelium. [microspecimen № 50]

№ 40. Peripheral pulmonary carcinoma.

On the section of the lung under the pleura, there is an accurately delimited tumor node, with a diameter of up to 10 cm of white-gray color and dense consistency.

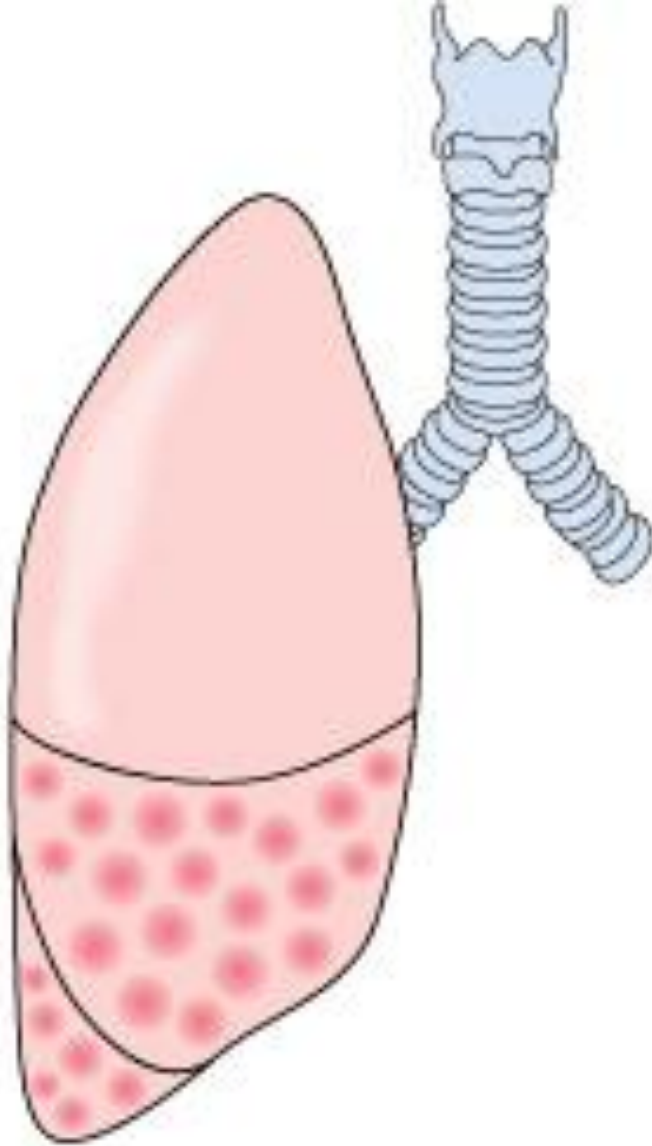
Peripheral lung carcinoma develops from the epithelium of the distal ramification of segmentary bronchus, bronchiolar and alveolar epithelium. It is located subpleural, can reach large sizes, often in the center is a scar (healed foci of tuberculosis, infarcts or scarred abscesses, foci of organization in pneumonia). It is the most common form of pulmonary carcinoma in women and non-smokers. Histologically, it is usually an adenocarcinoma. It can infiltrate the pleura, the surrounding lung tissue. Sero-hemorrhagic or hemorrhagic exudate appears in the pleural cavity. It metastasizes predominantly hematogenously in various organs: liver, adrenal glands, bones, pancreas, brain, kidneys, thyroid gland.



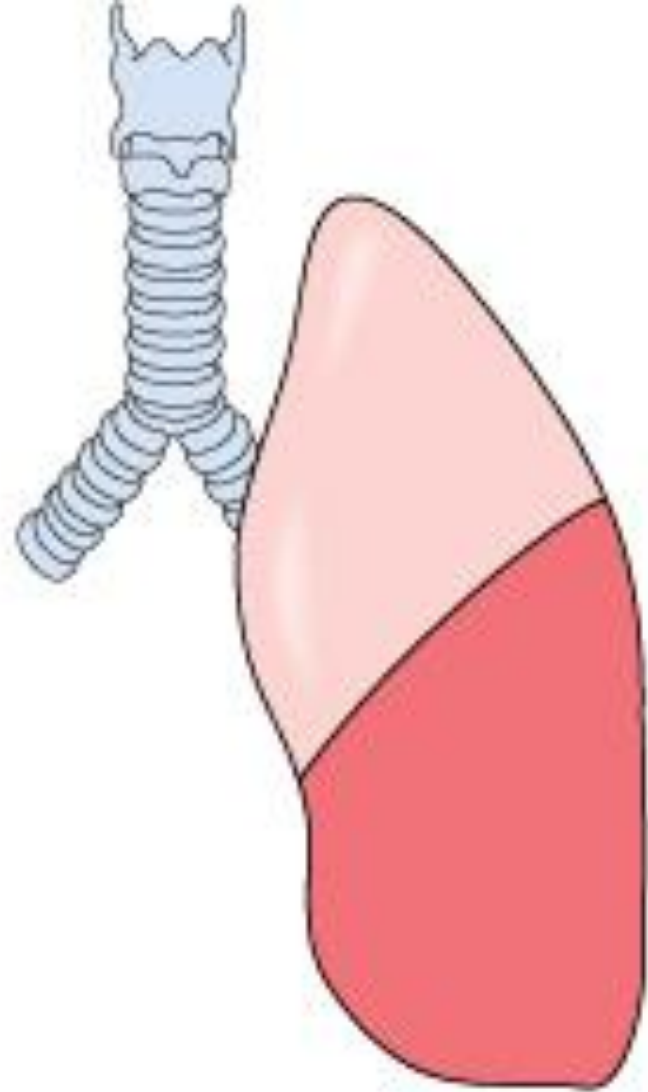
№ 39. Bronchogenic carcinoma.



№ 40. Peripheral pulmonary carcinoma.

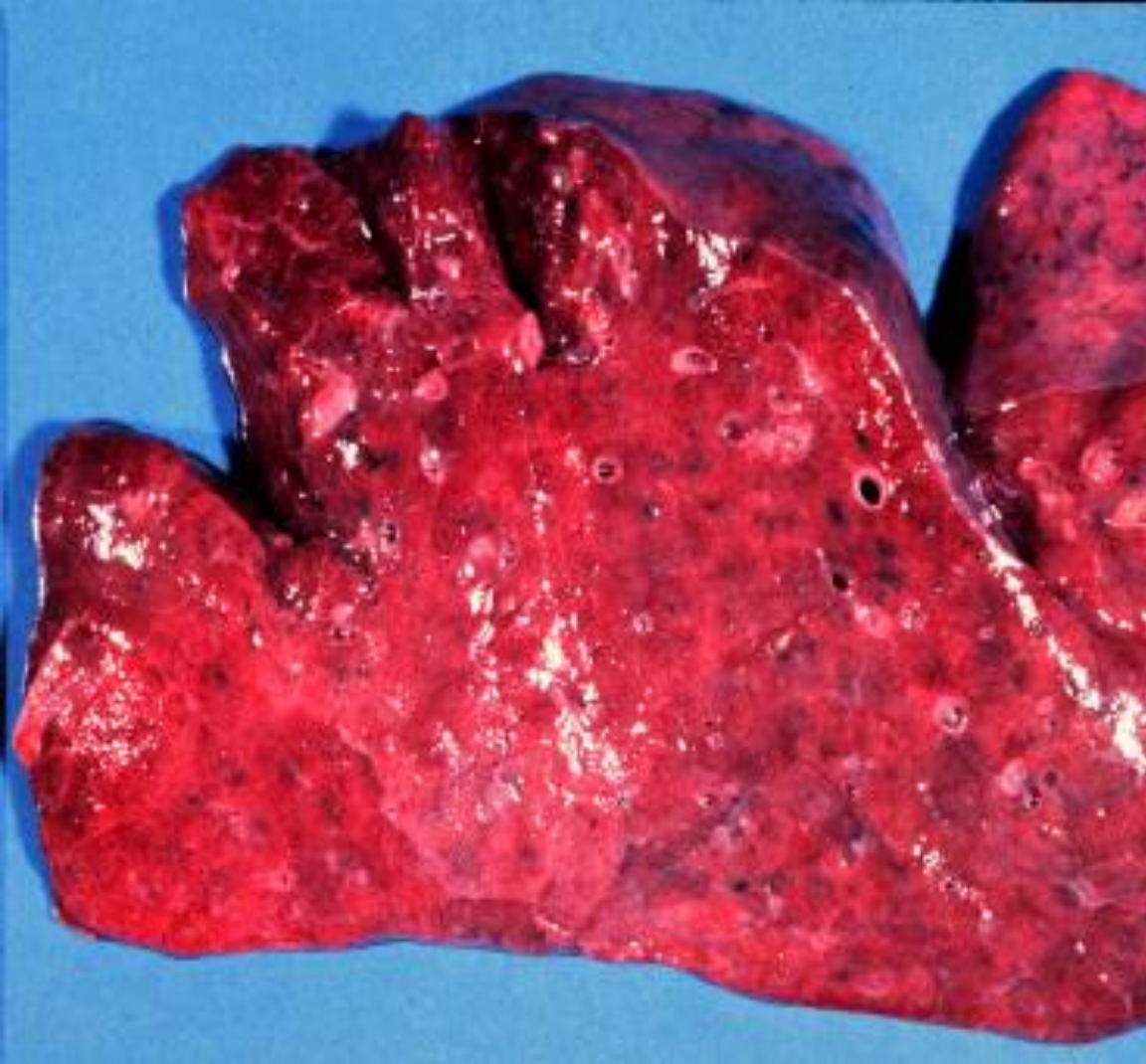

Bronchopneumonia

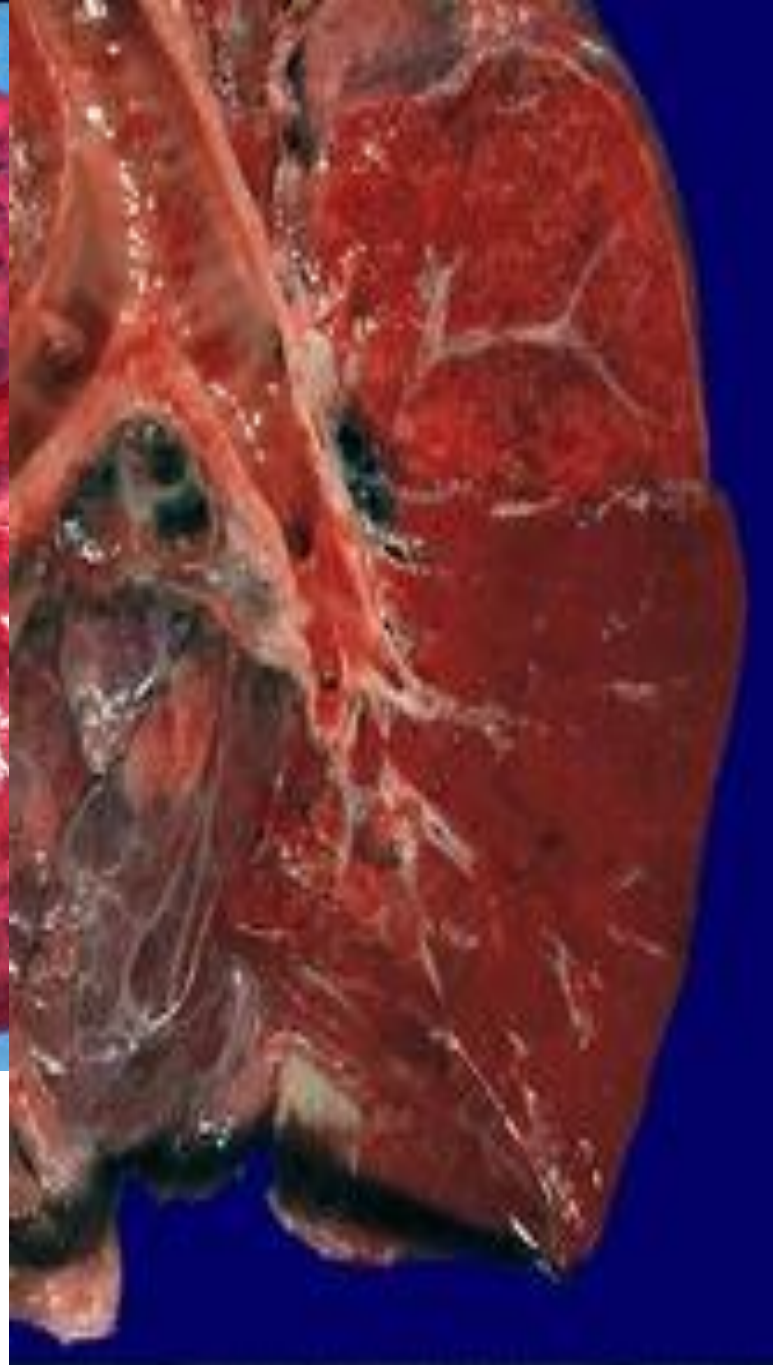

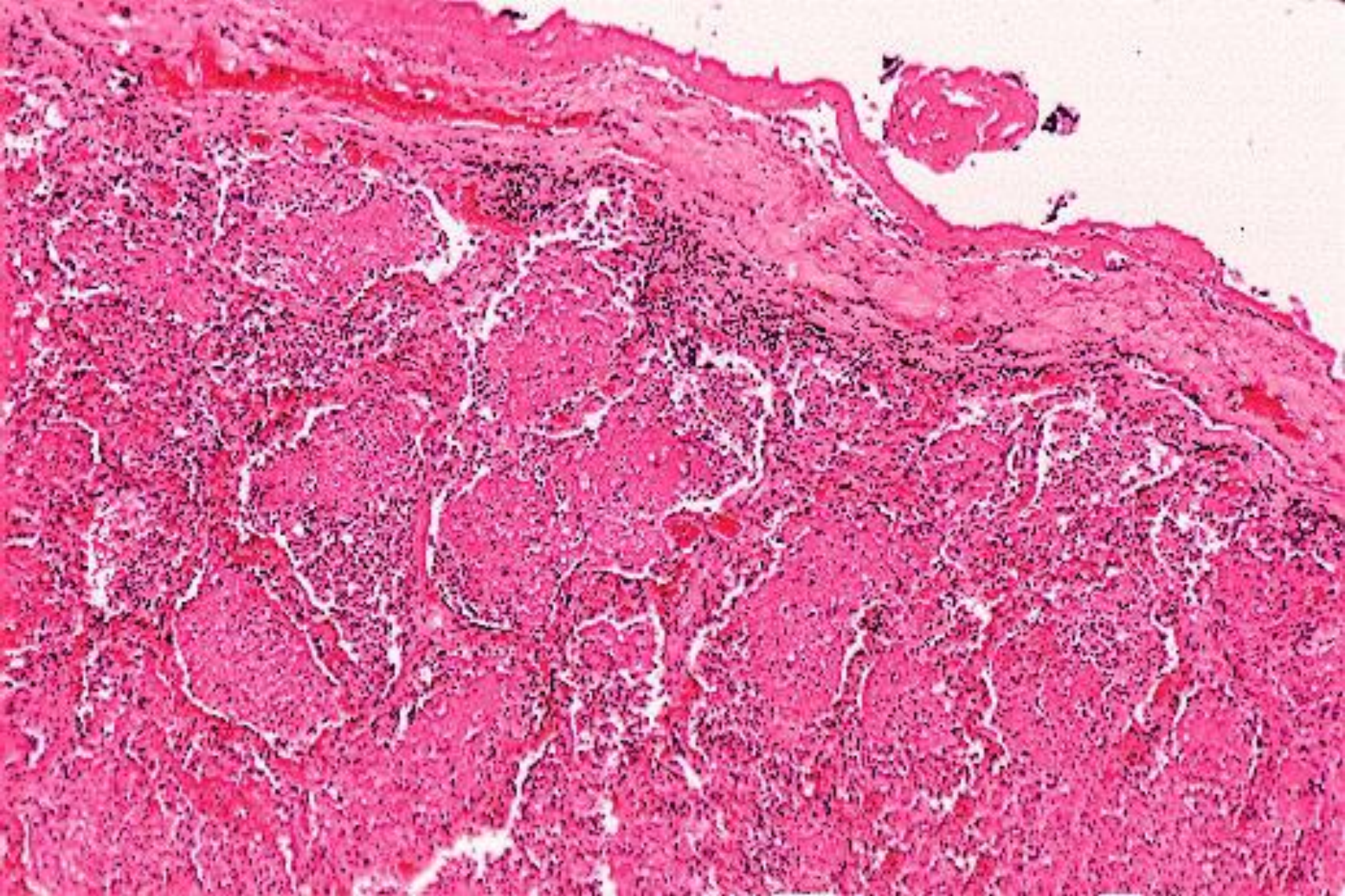
Lobar pneumonia

Schematic representation of bronchopneumonia and lobar pneumonia.

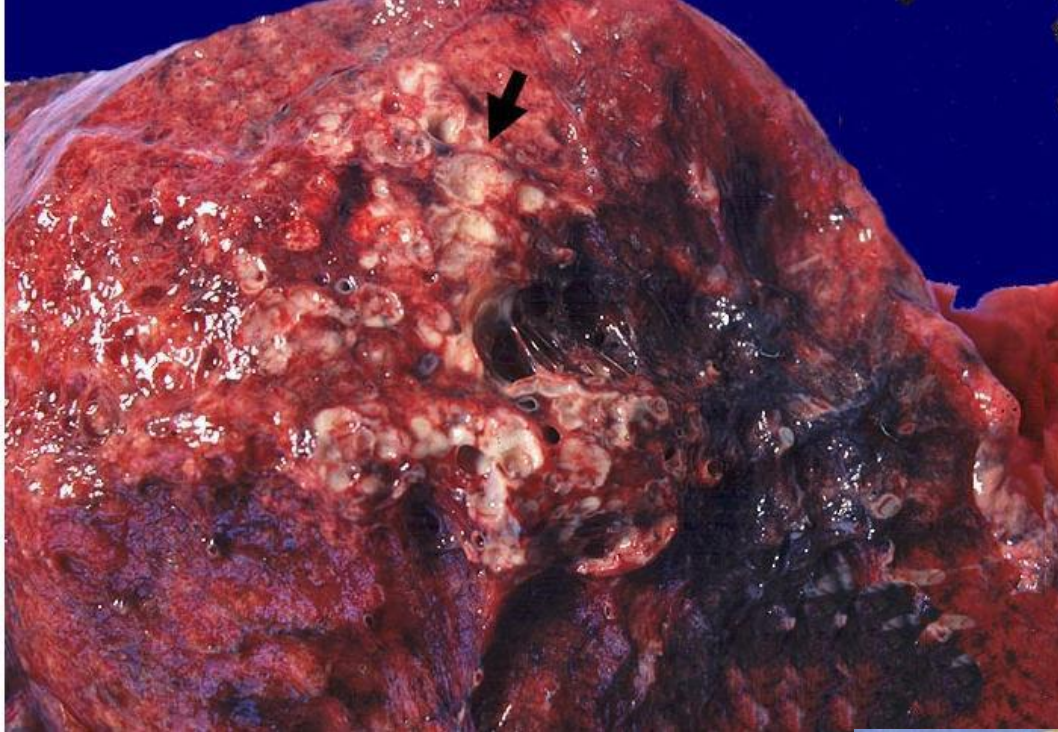


**Lobar pneumonia,
red hepatization stage.**

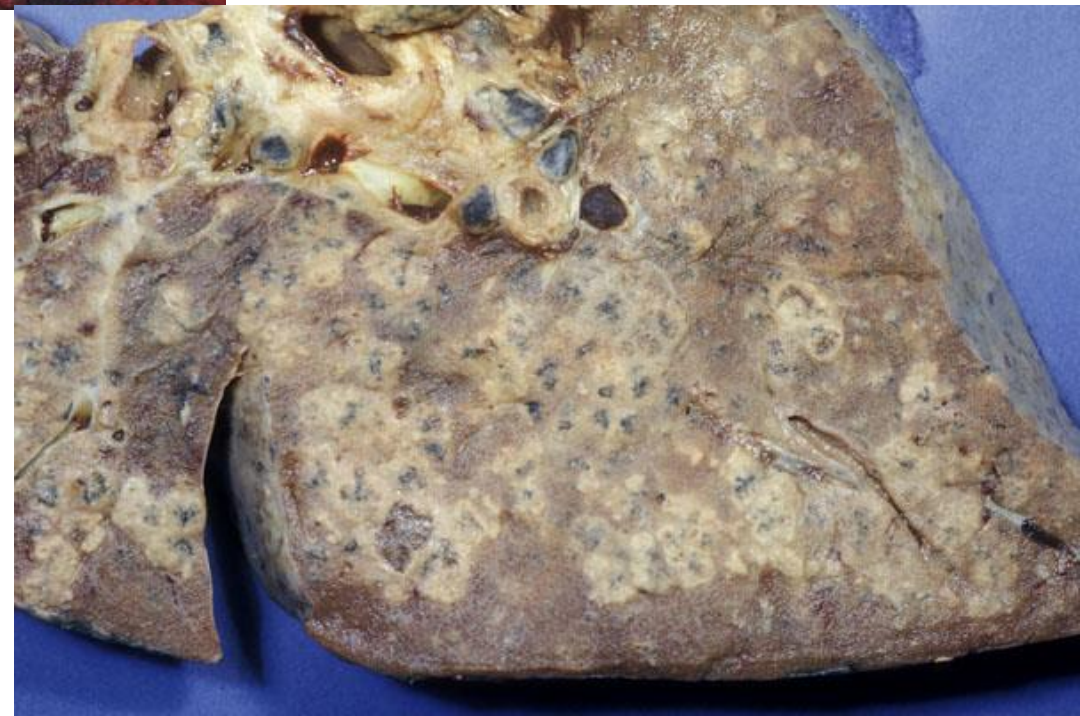

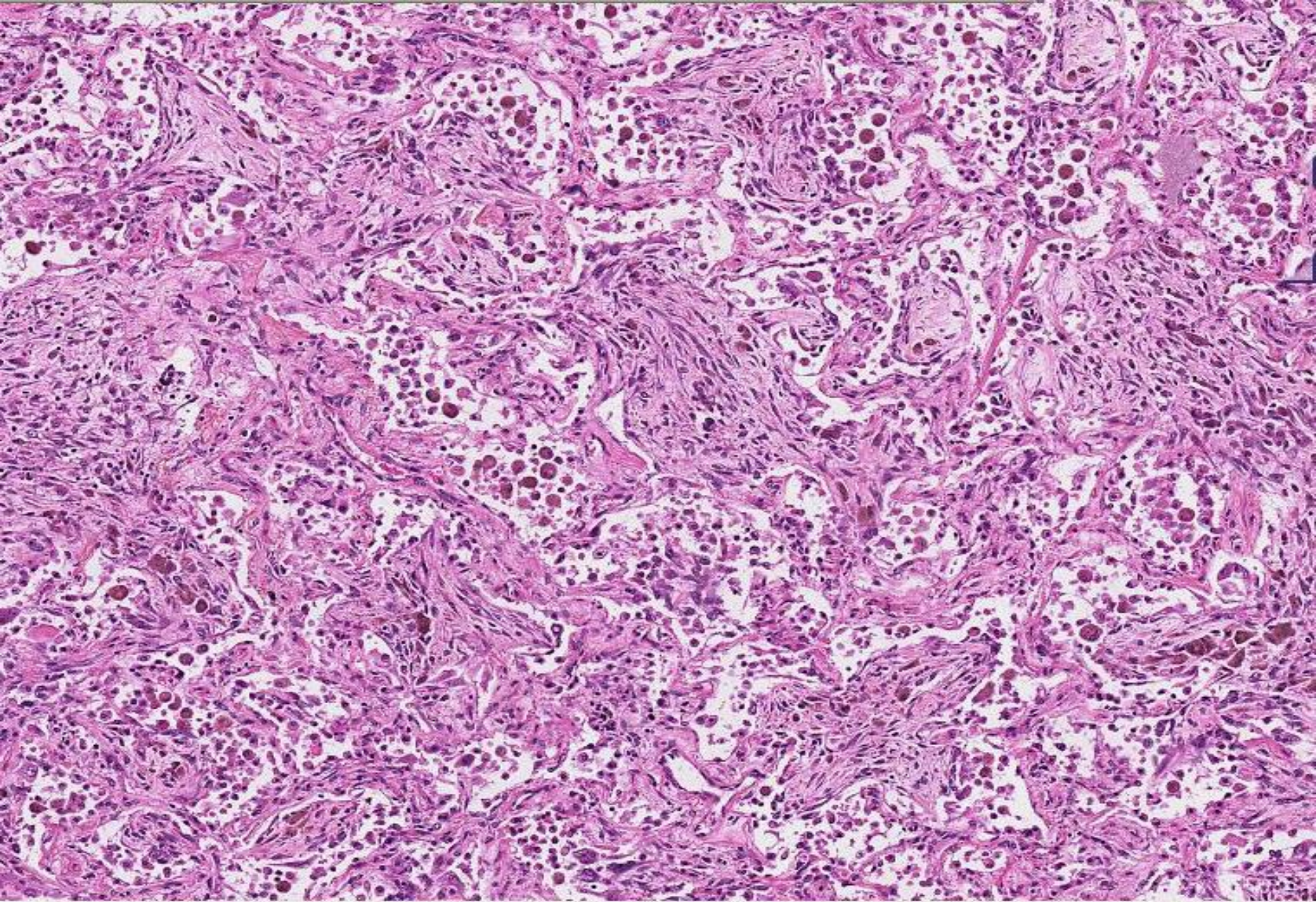


Lobar pneumonia, fibrino-leukocytic exudate in the alveoli, fibrinous pleurisy. (*H-E stain*).

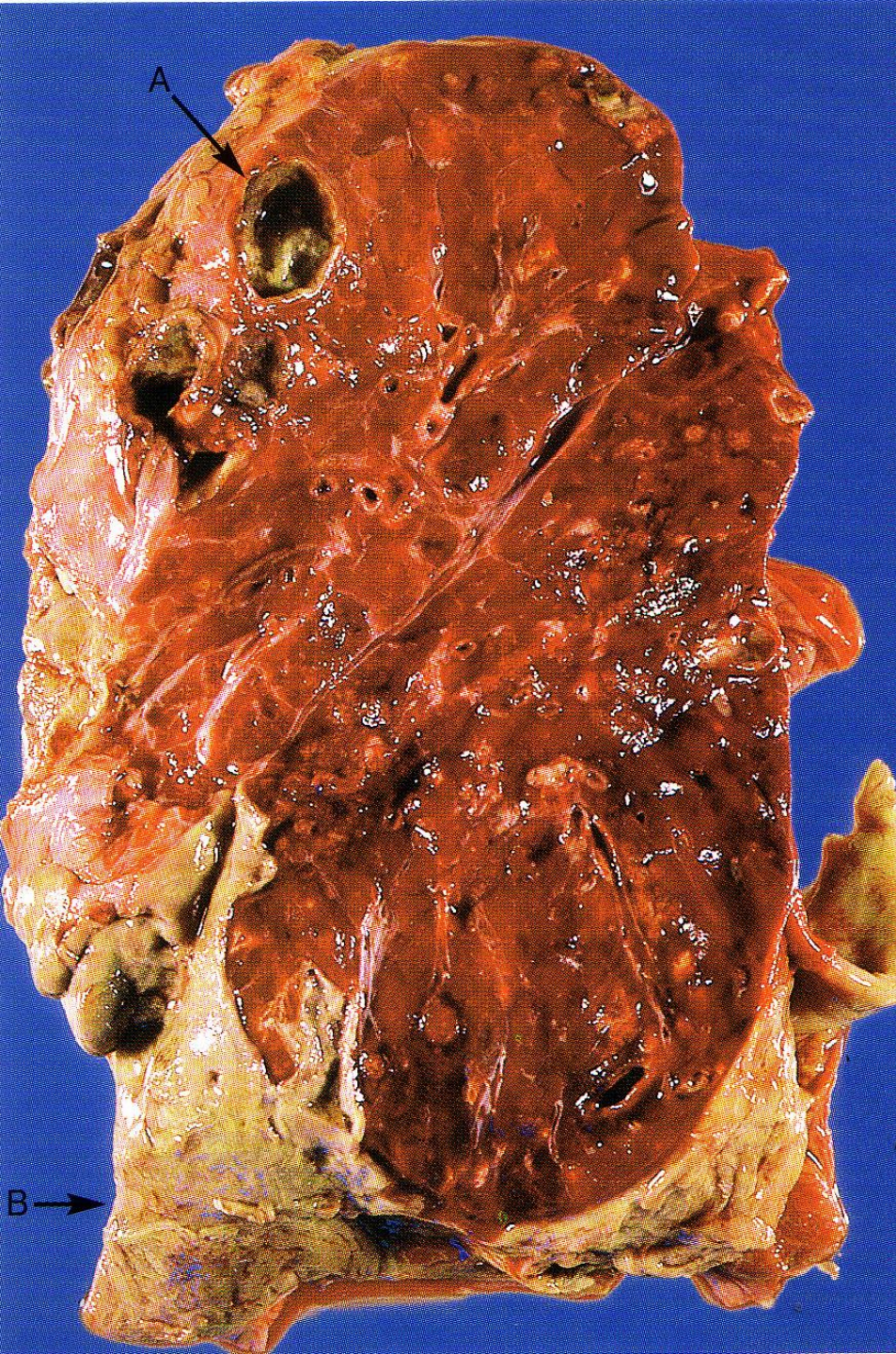

**Bronchopneumonia
with abscess formation.**

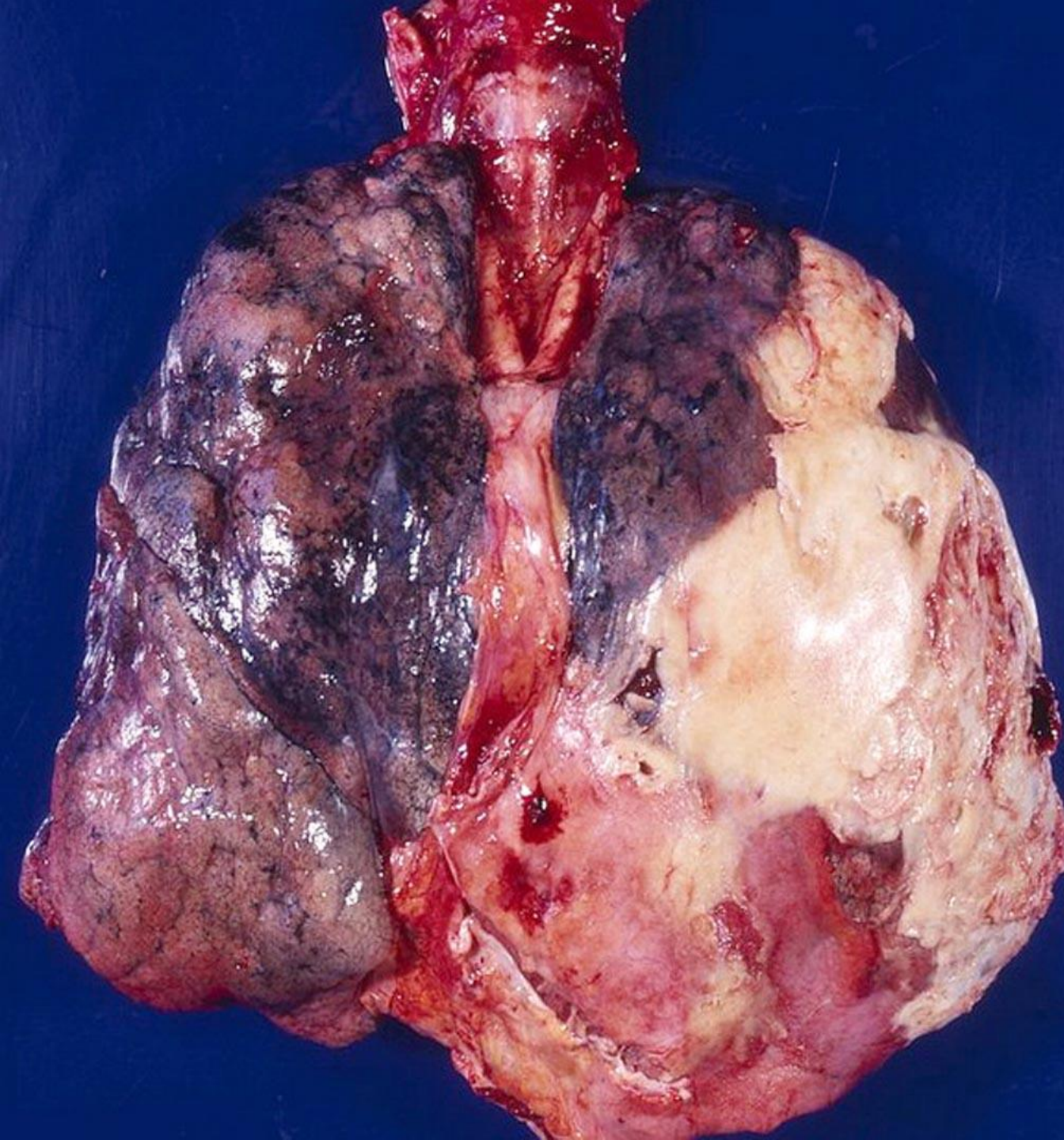




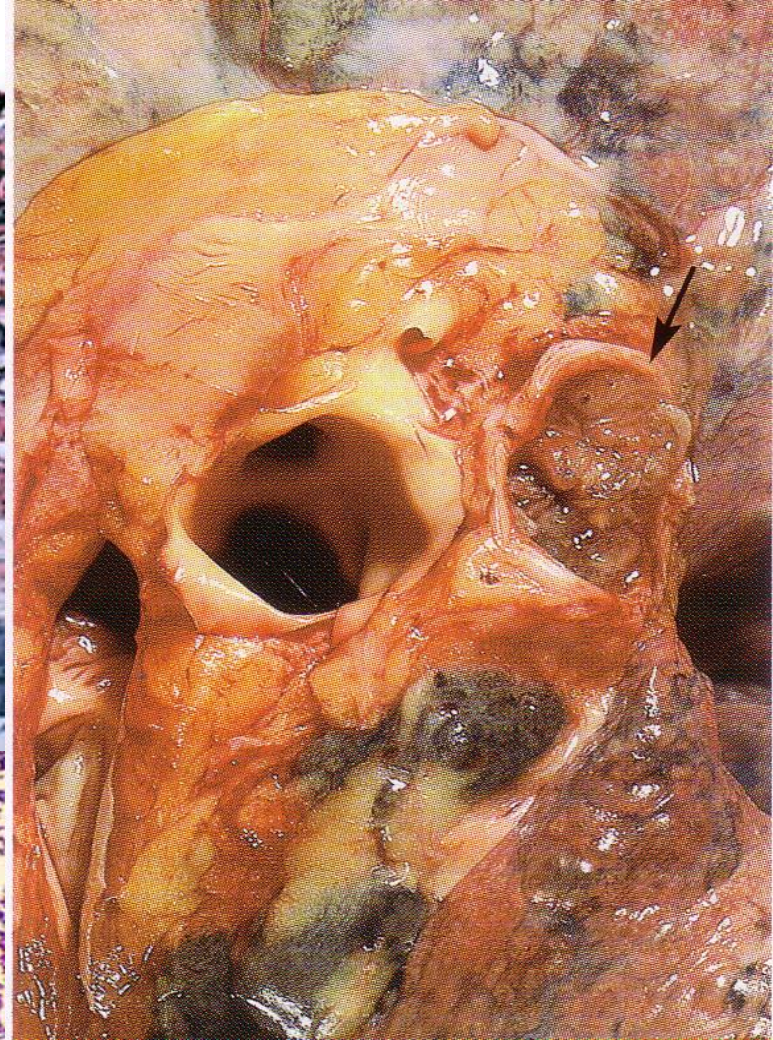
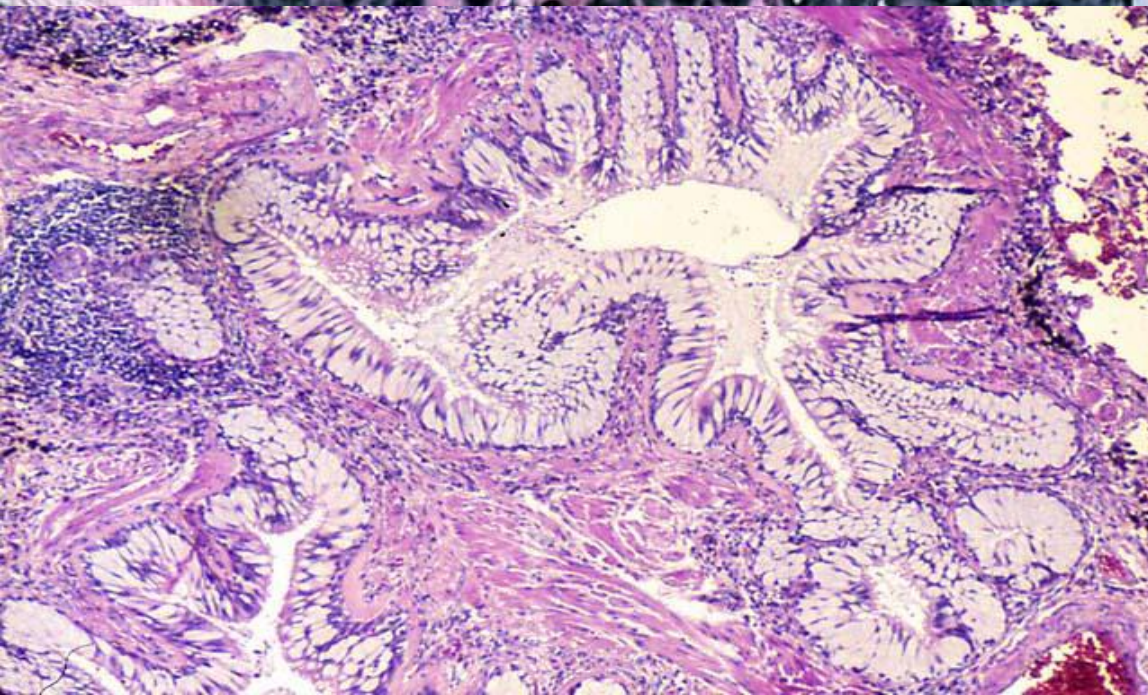
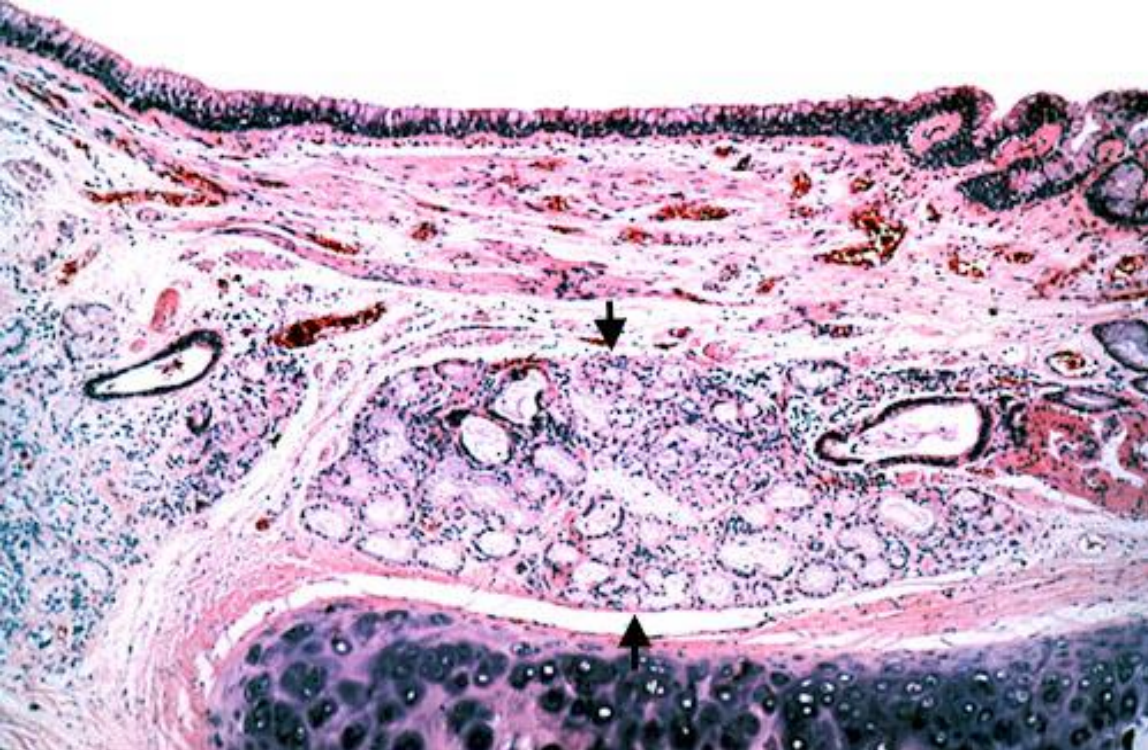
Pneumonia with exudate organization. (*H-E stain*).



**Lung abscess (A),
Purulent pleurisy (B).**



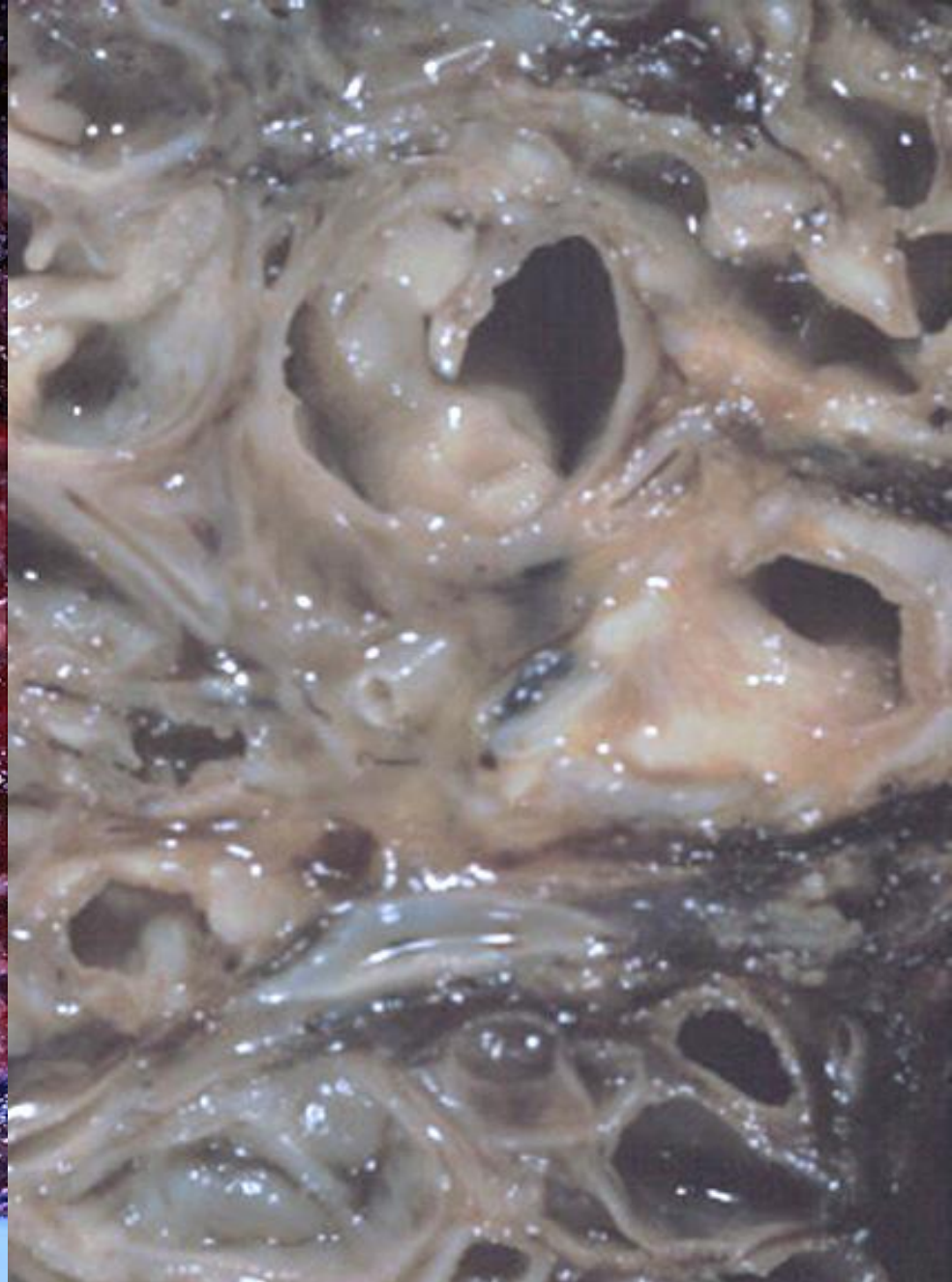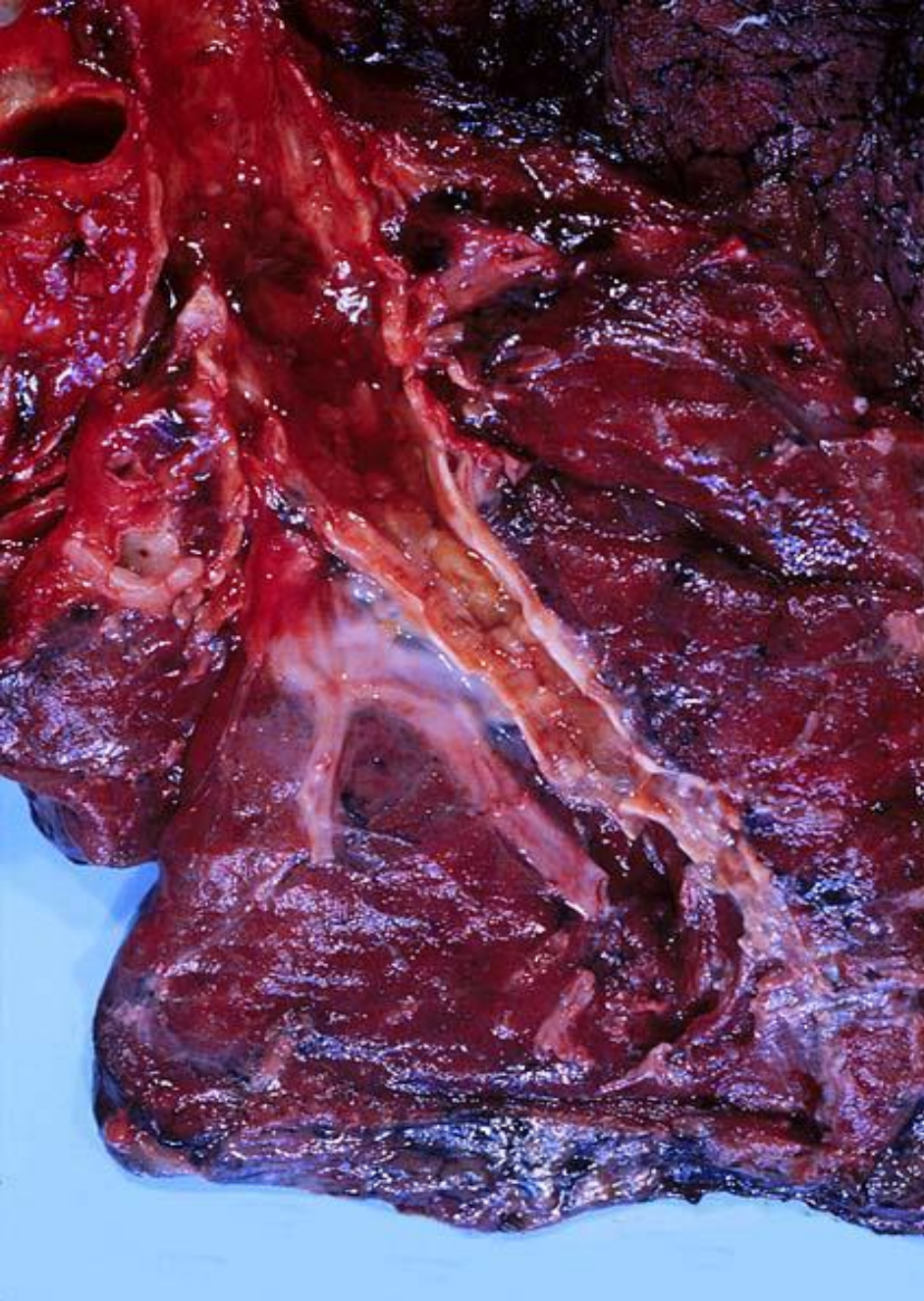**Purulent pleurisy,
pleural empyema.**



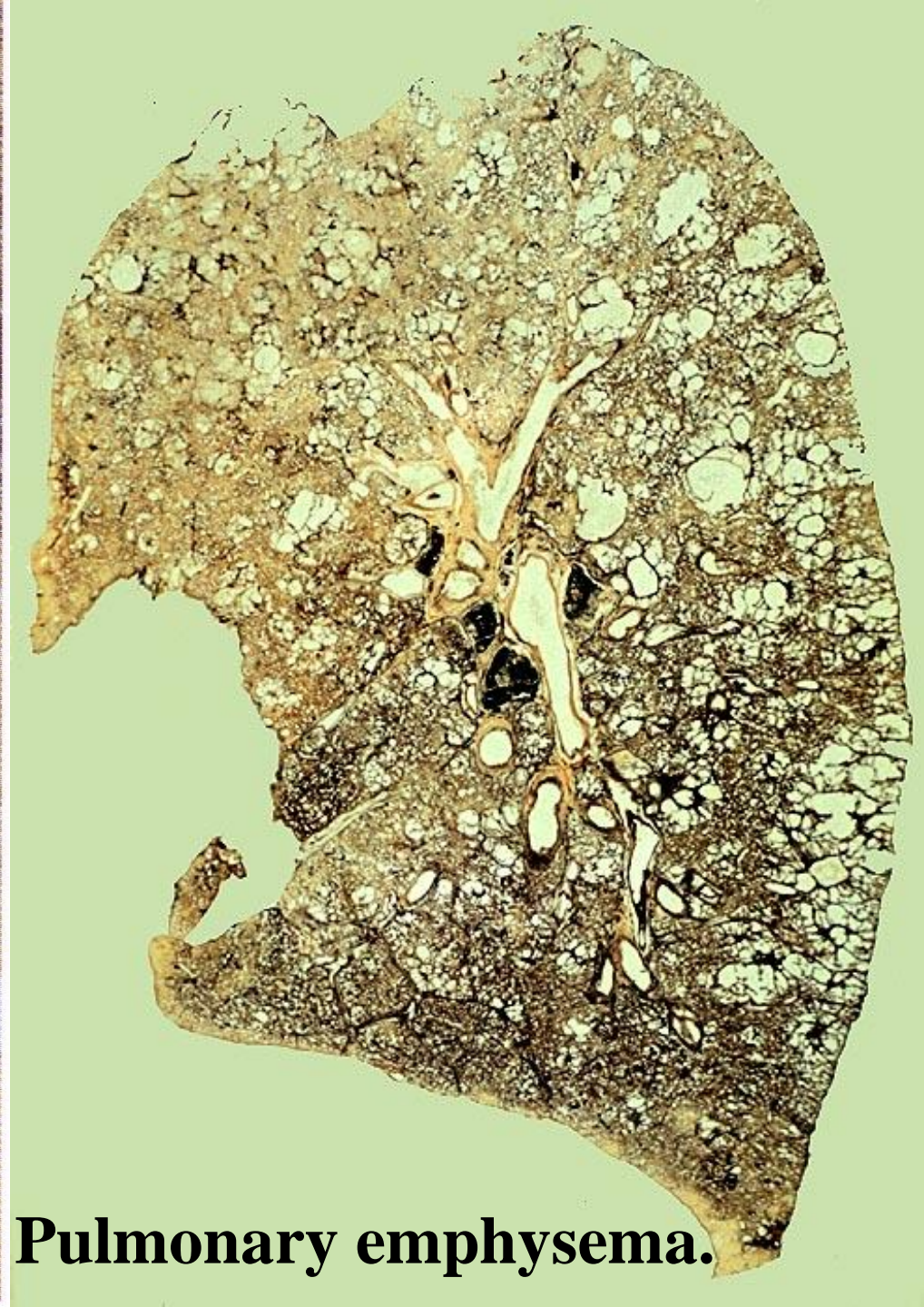
Chronic bronchitis:

**a) - inflammatory infiltration,
hyperplasia of the submucosal
glands, myocyte hypertrophy;**

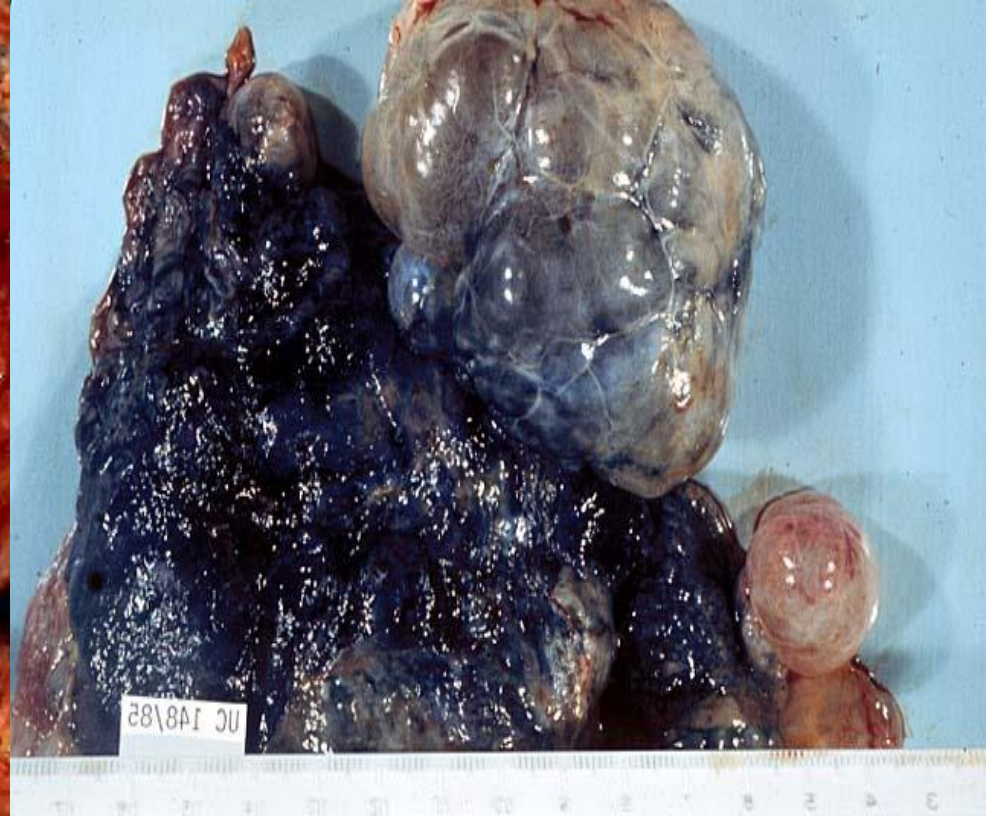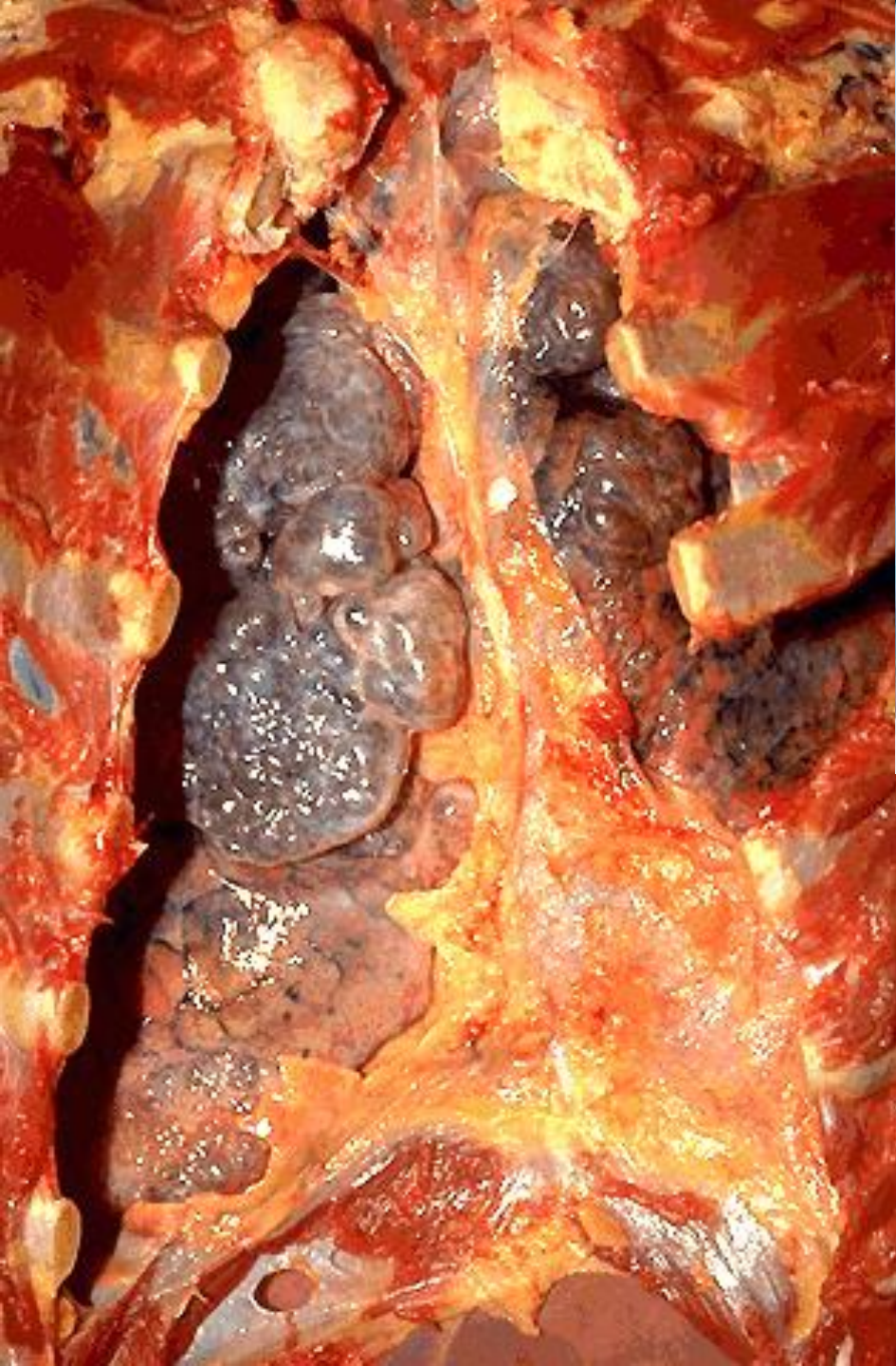**b) - mucosecreting cell hyperplasia
(H-E).**



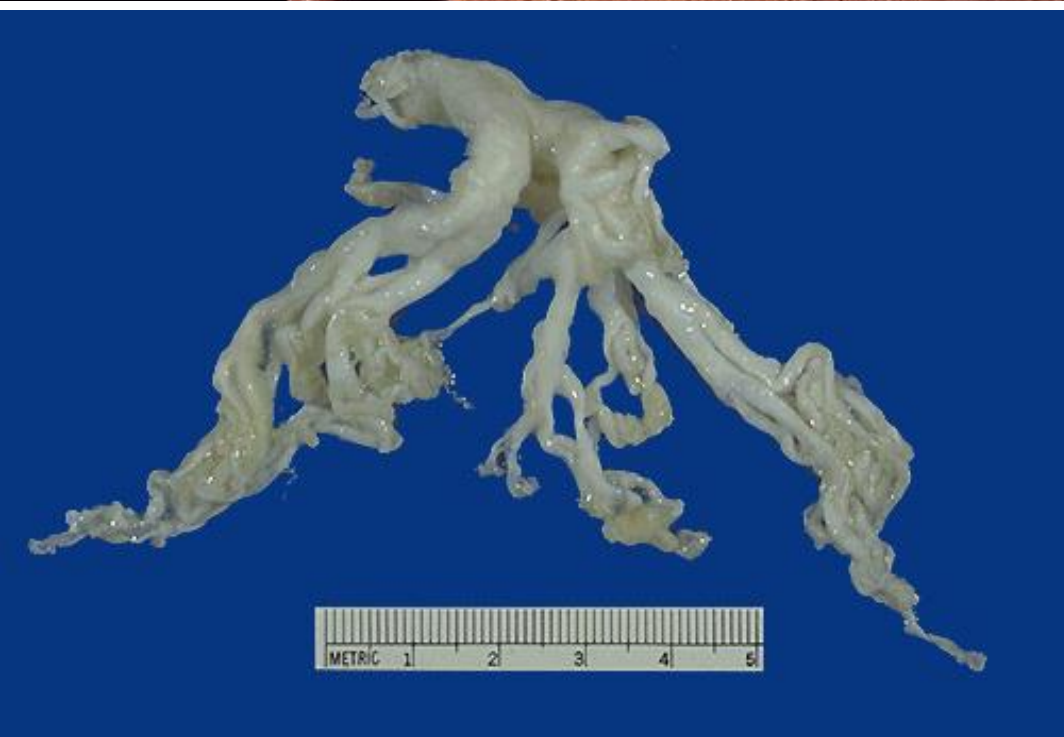Cylindrical and sacular bronchiectasis.



Pulmonary emphysema.



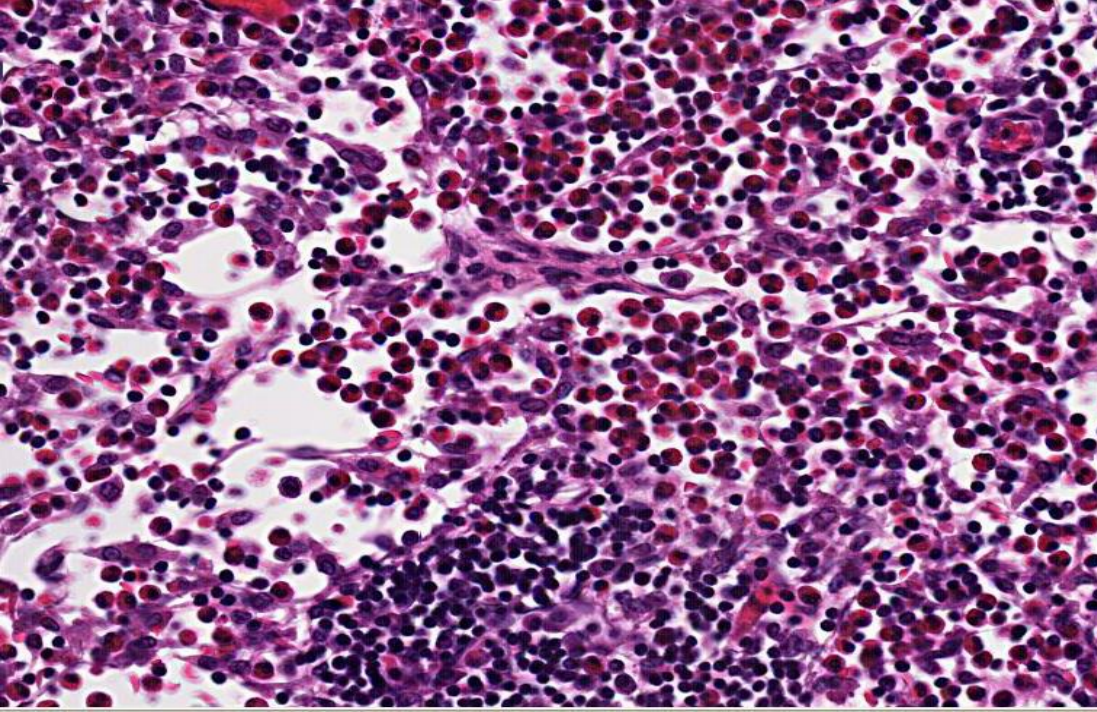
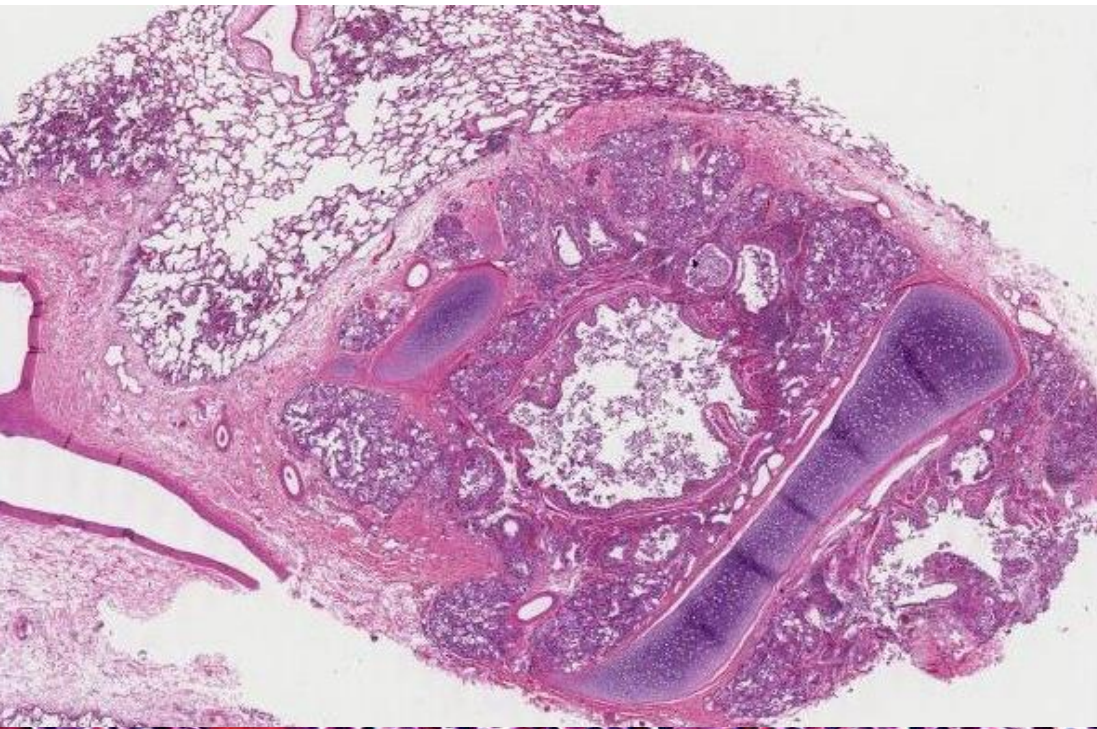
**Bullous pulmonary
emphysema.**



Bronchial asthma

a – hypersecretion of mucus in the lumen of the bronchi;

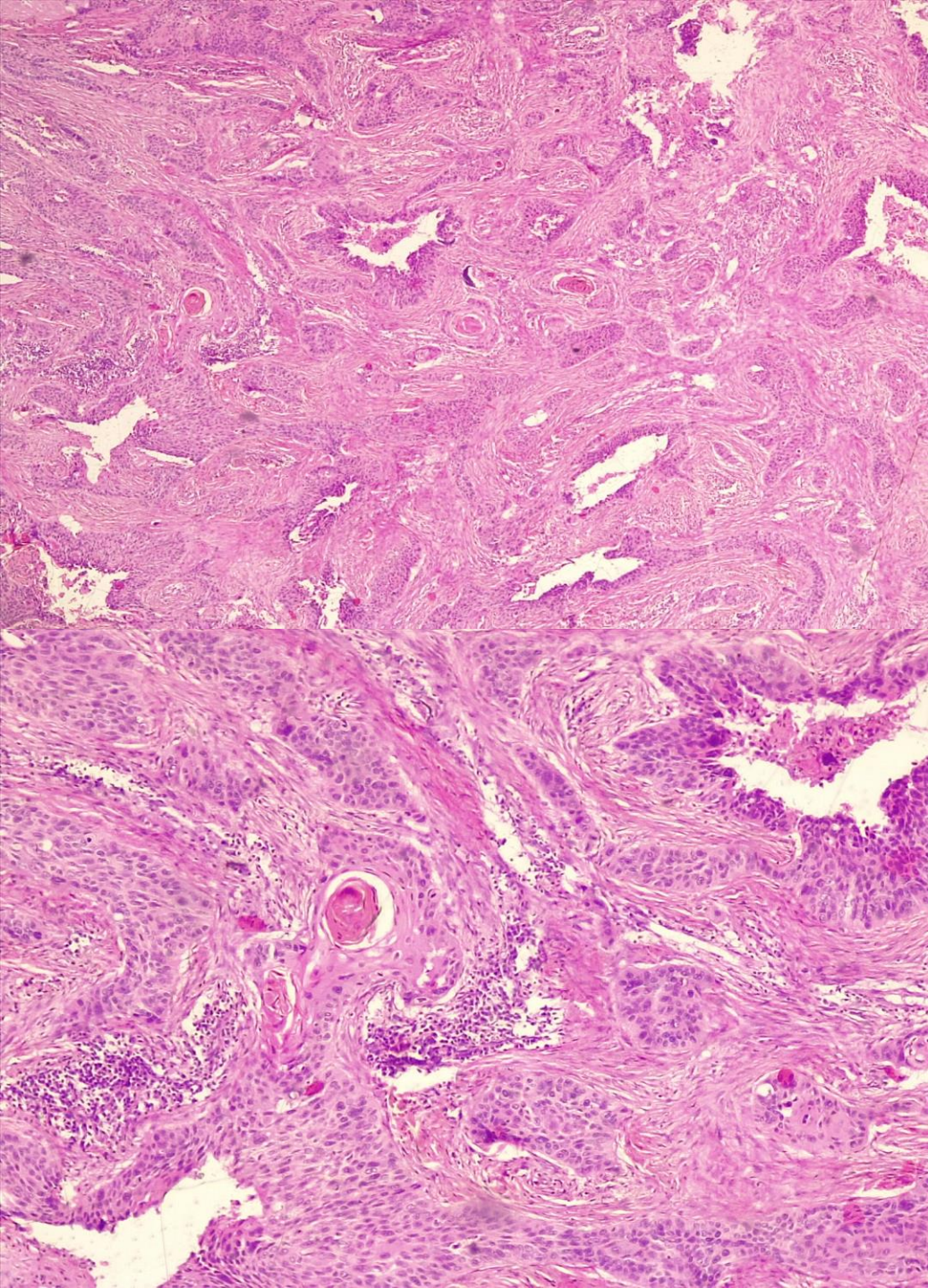
b - mucus plugs in the bronchi in asthma (in status asthmaticus).



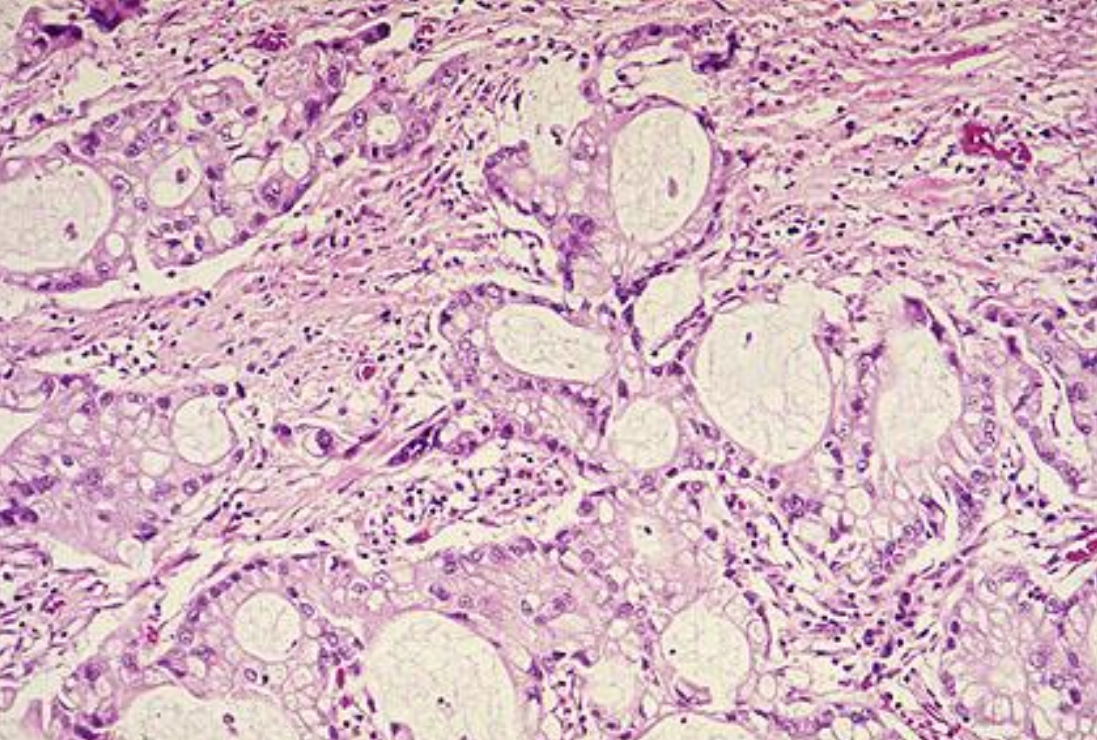
Bronchial asthma.

a – myocyte hypertrophy, hyperplasia of the submucosal glands, inflammatory infiltration, mucus in the lumen (H-E stain).

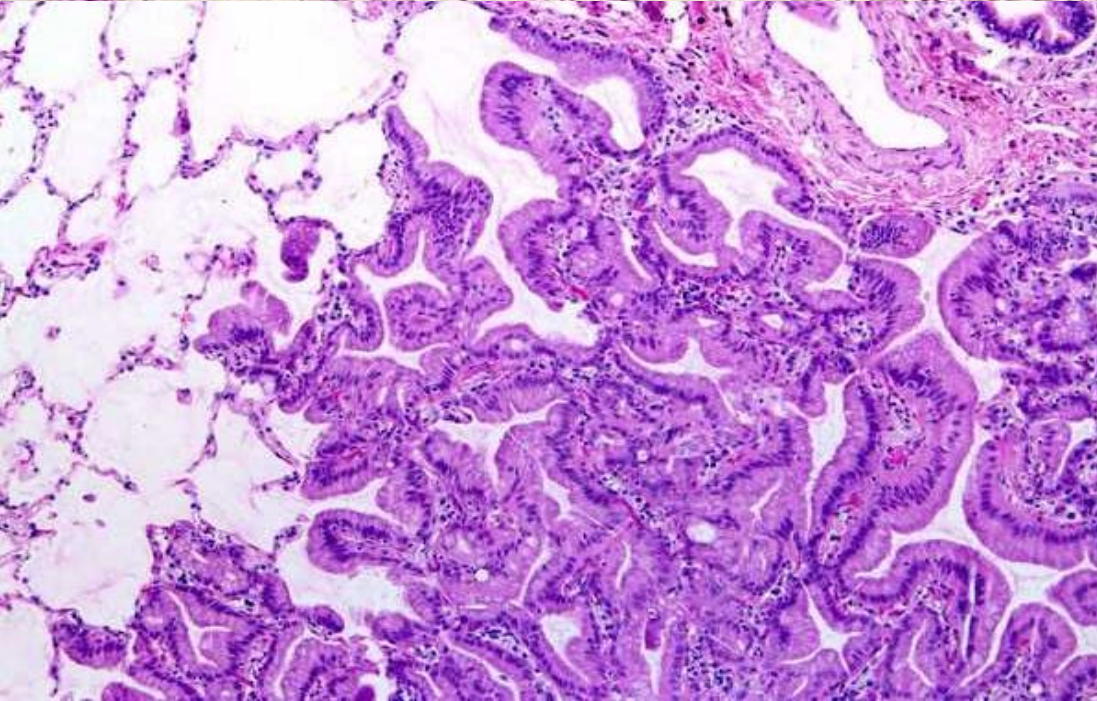
b – eosinophilic infiltration into the hilum lymph node in bronchial asthma(H-E stain).



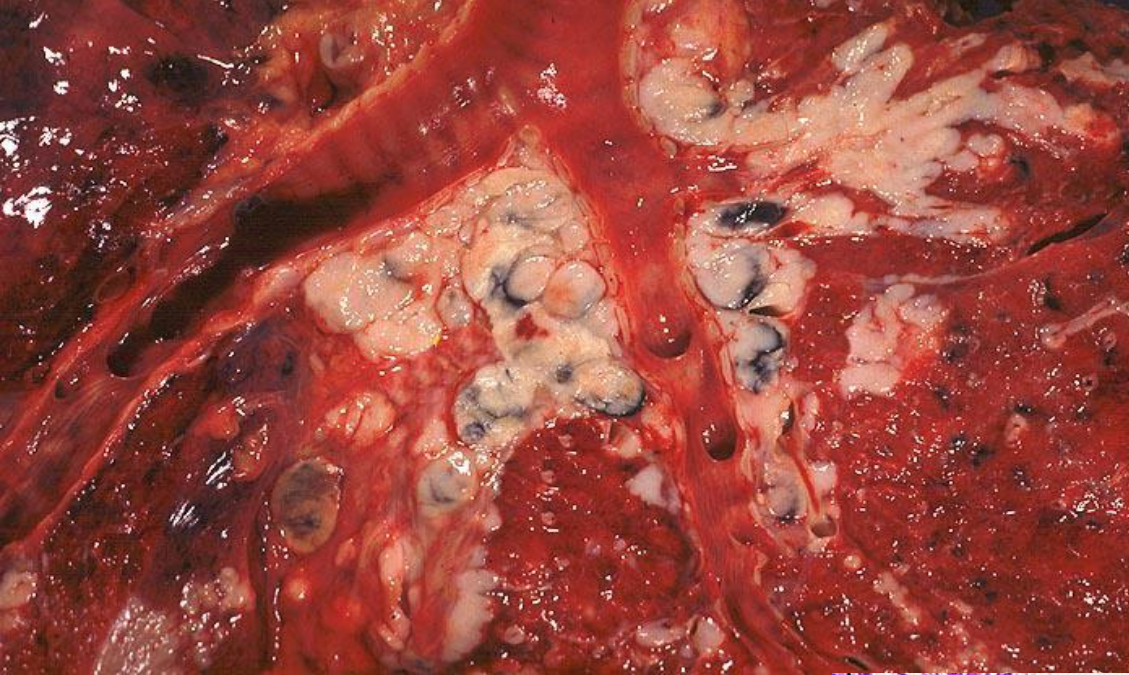Keratinized squamous cell lung carcinoma. (*H-E stain*).



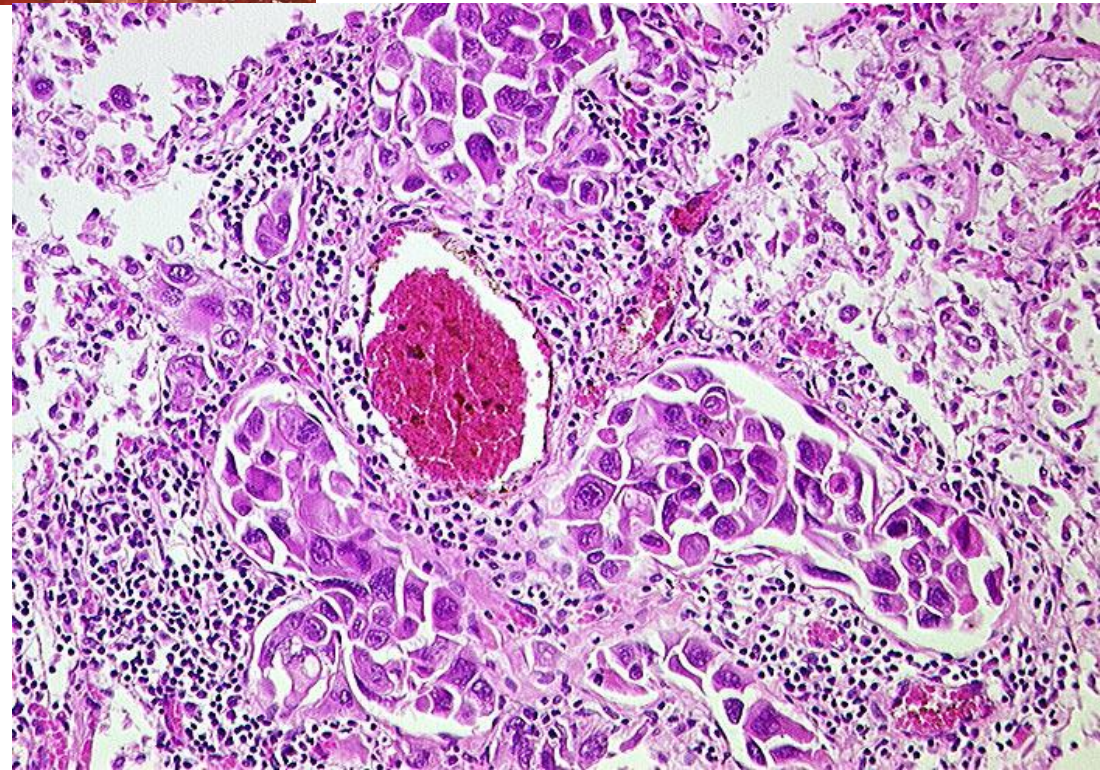
a. Pulmonary adenocarcinoma. (*H-E stain*).



b. Bronchioloalveolar carcinoma. (*H-E stain*).

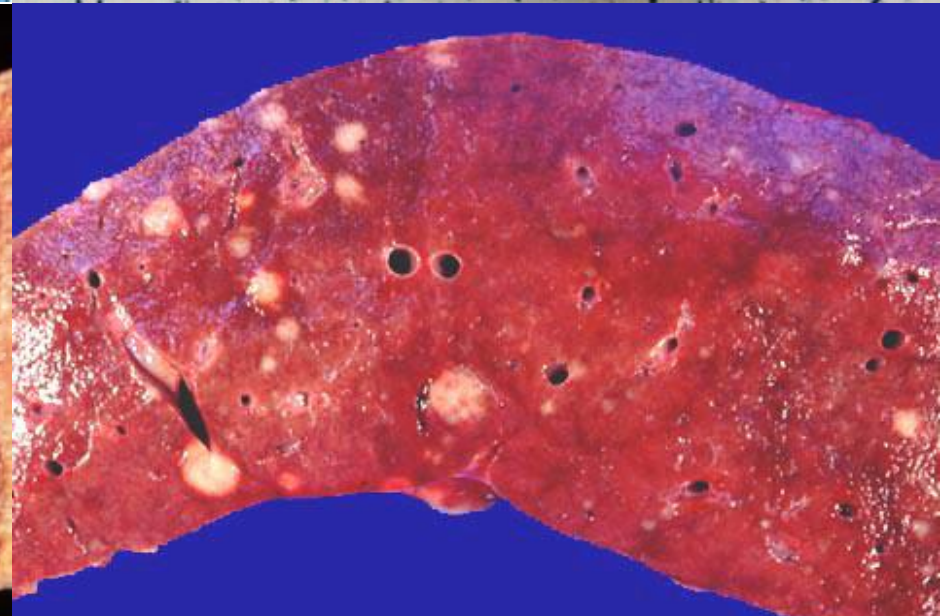
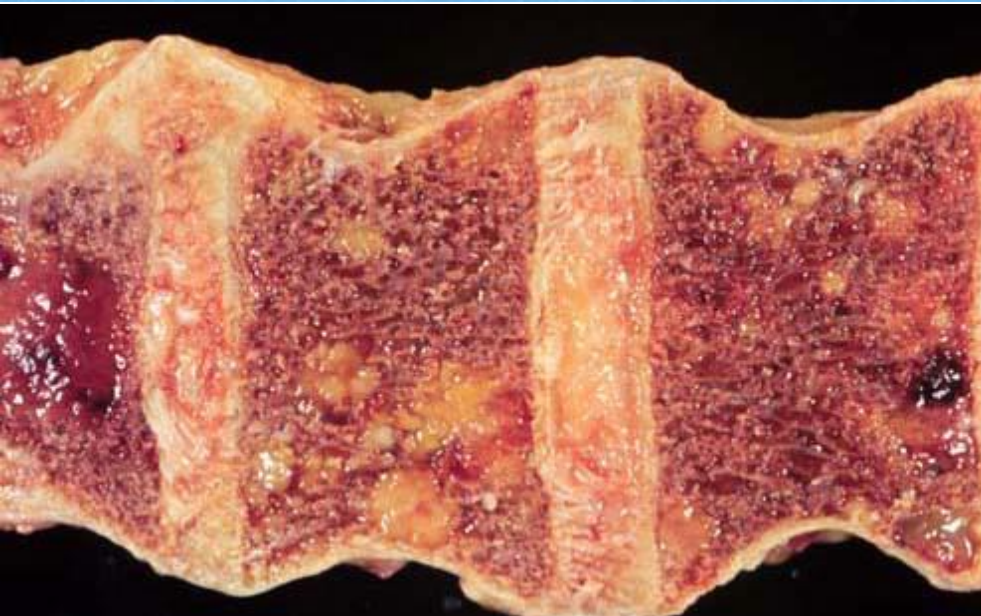
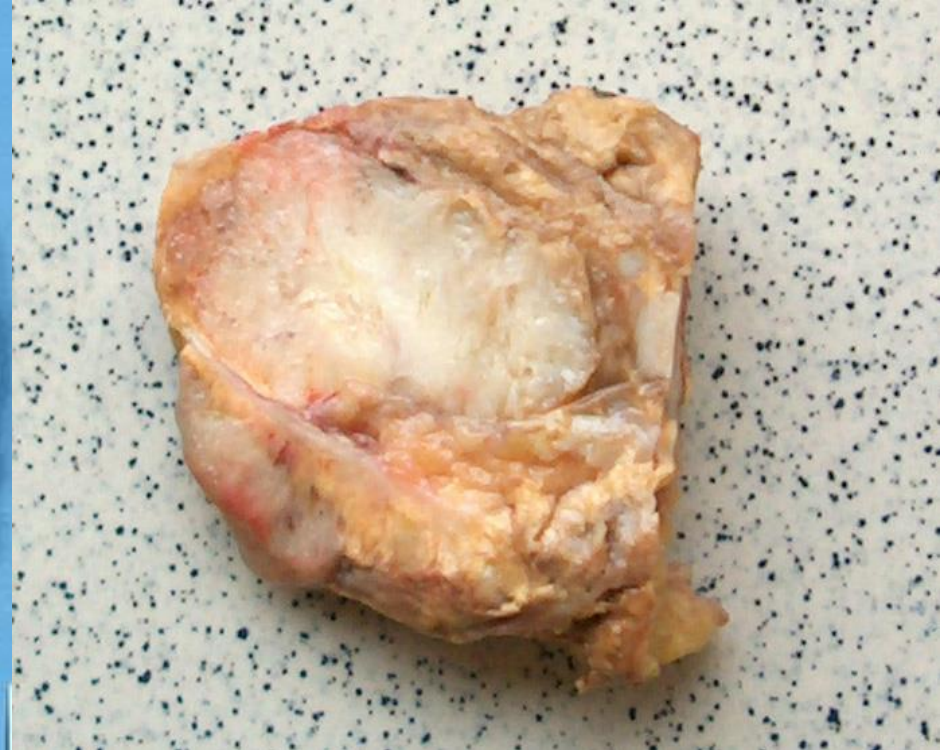
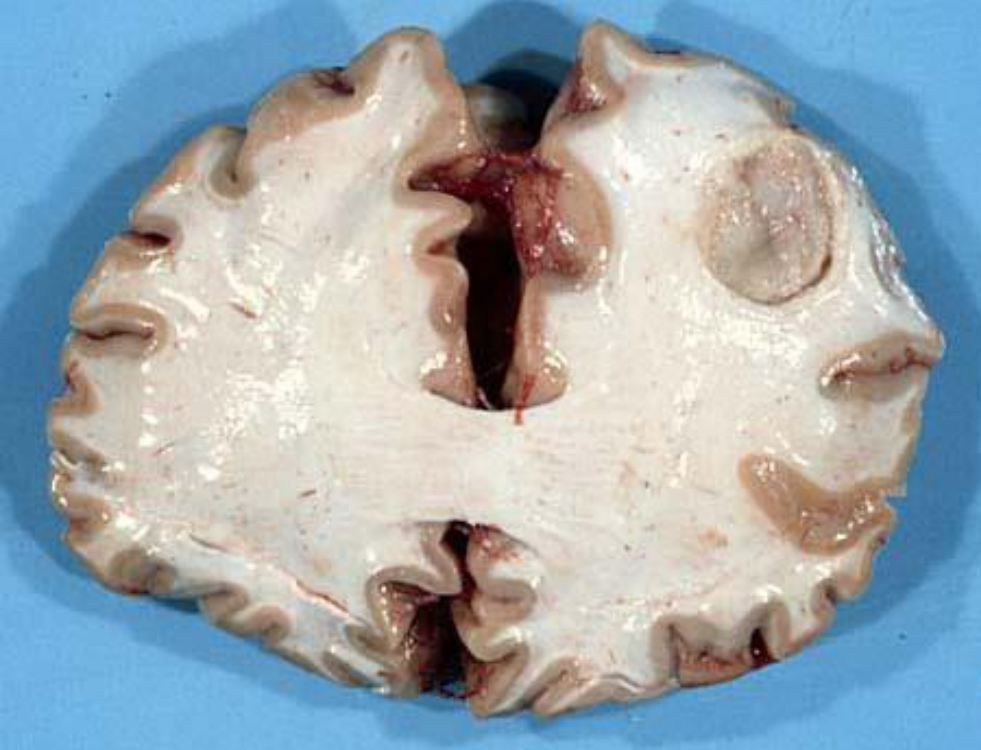**Cancerous
embolism of
lymphatic vessels.**



**Pulmonary carcinoma
metastases
in the mediastinal
lymph nodes.**

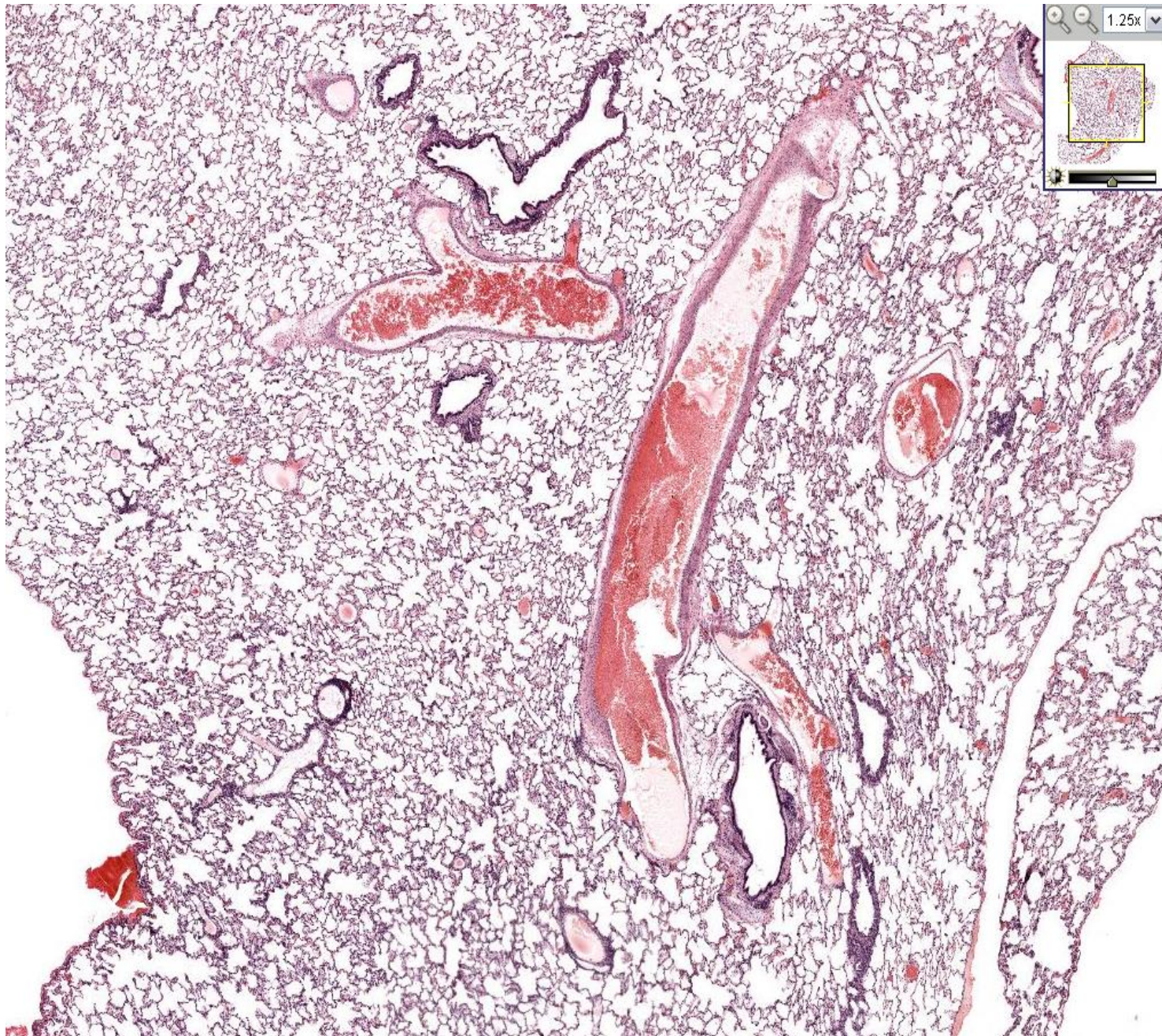




Metastases in the brain, vertebrae, adrenal glands and liver

Function of the Respiratory System

- Oversees gas exchanges (oxygen and carbon dioxide) between the blood and external environment
- Exchange of gasses takes place within the lungs in the alveoli(only site of gas exchange, other structures passageways
- Passageways to the lungs purify, warm, and humidify the incoming air
- Shares responsibility with cardiovascular system



Bronchi

Bronchioles

**Terminal
bronchioles**

Alveolar ducts

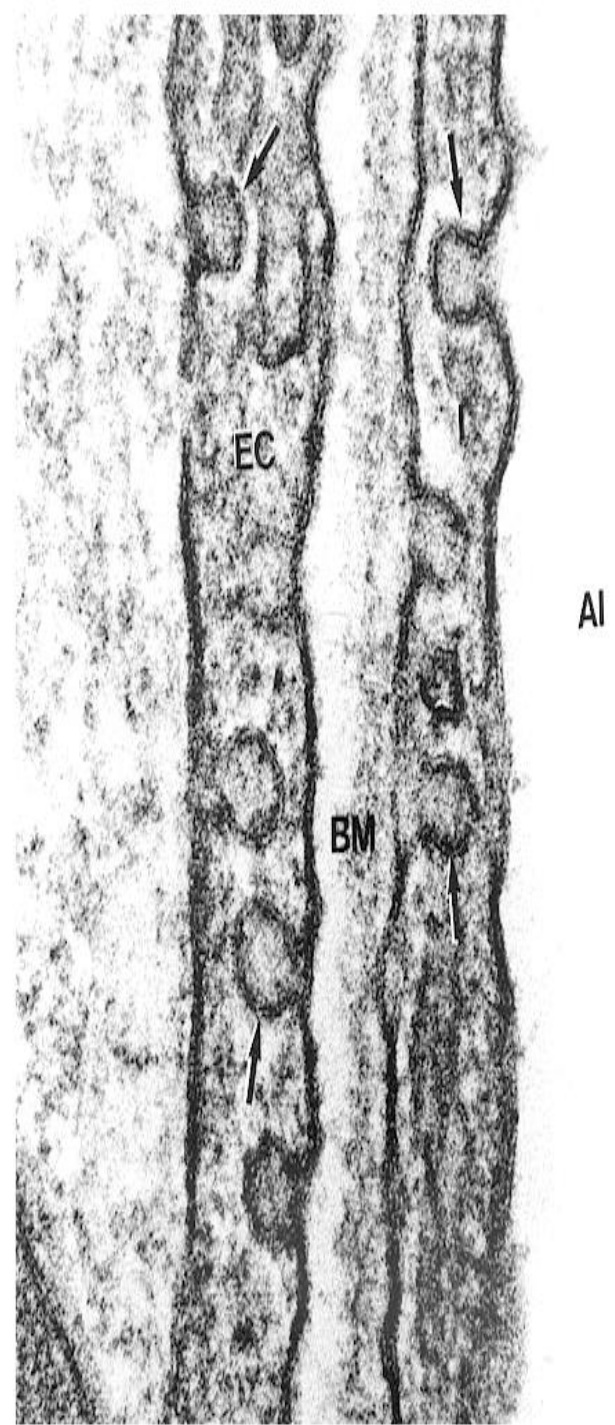
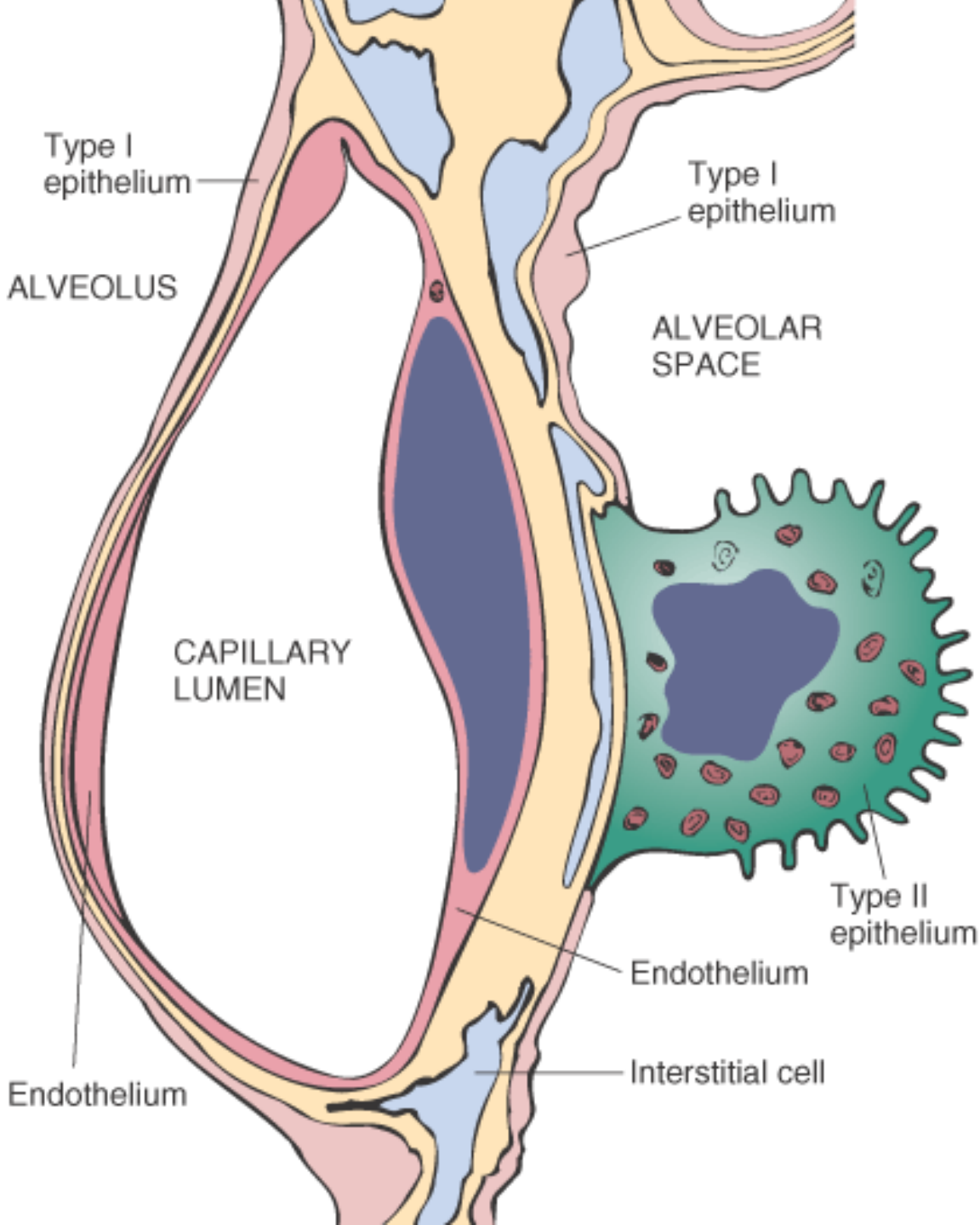
Alveoli

**Type 1
pneumocytes**

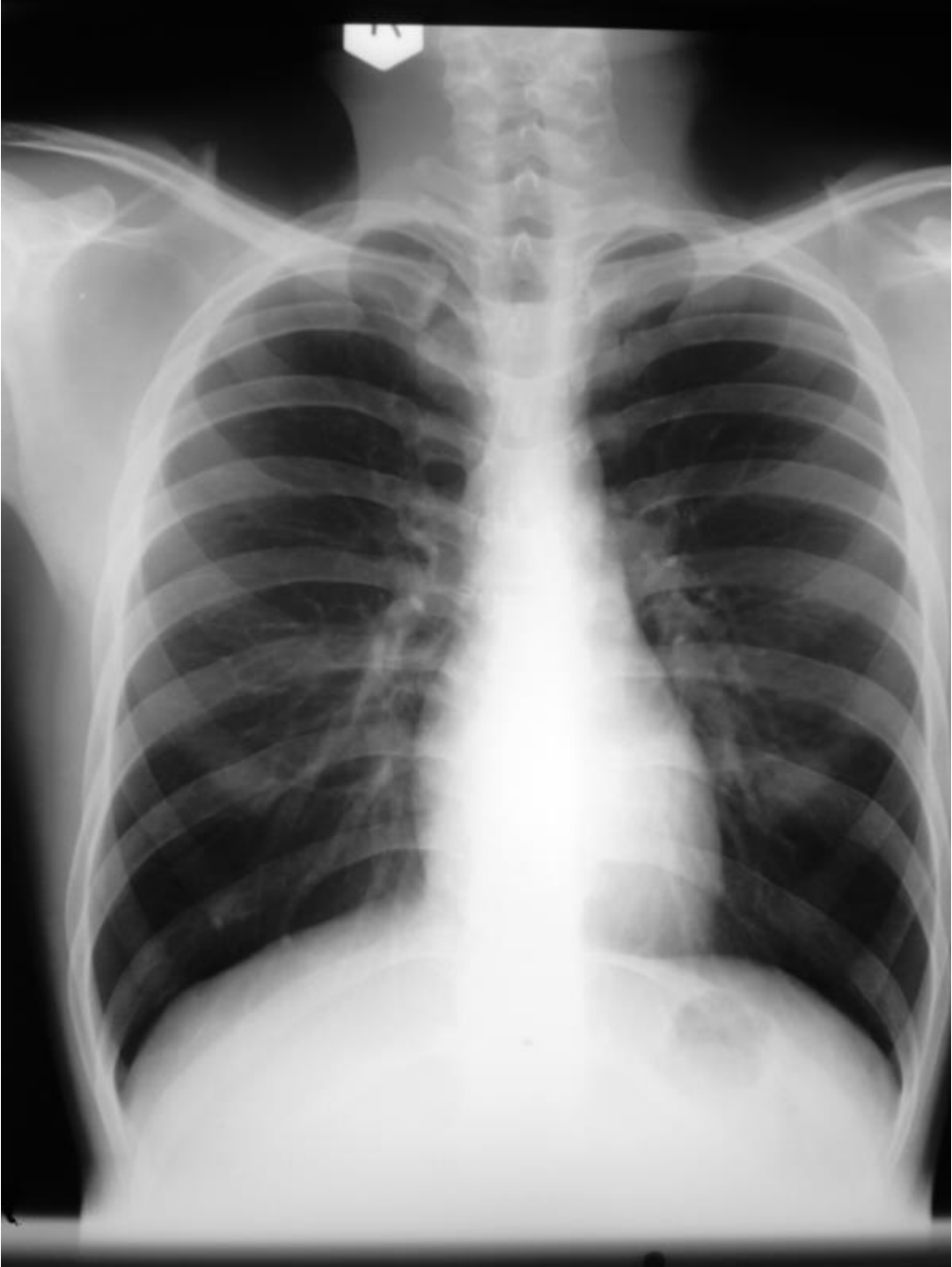**Type 2
pneumocytes**

Macrophages

Capillaries



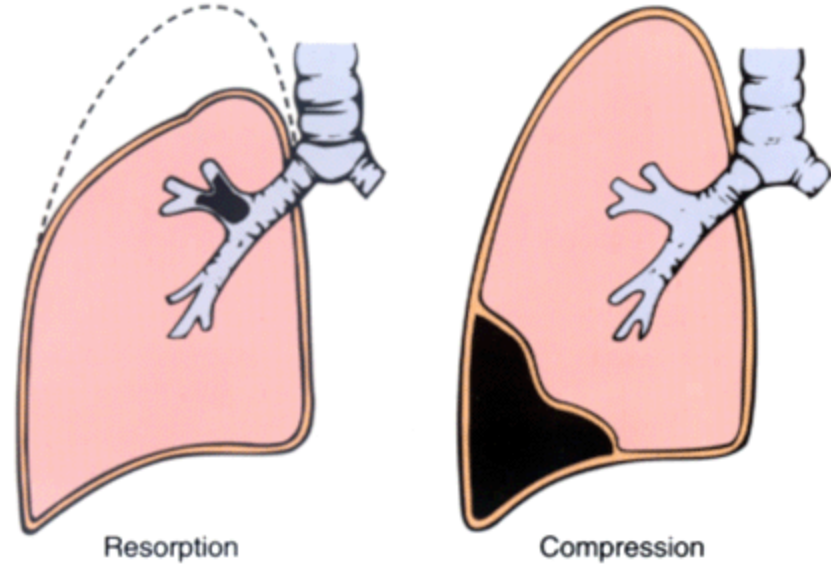
**N
O
R
M
A
L**



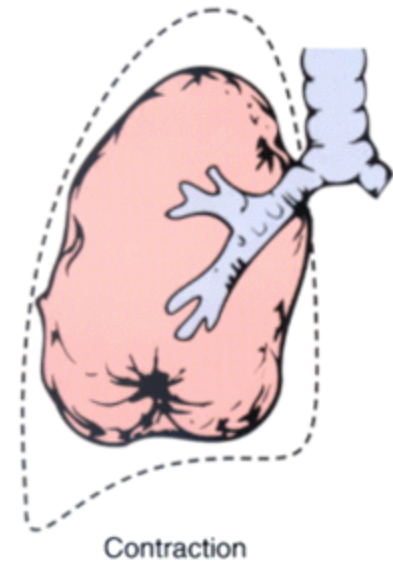
**C
X
R**

ATELECTASIS

- **INCOMPLETE EXPANSION**

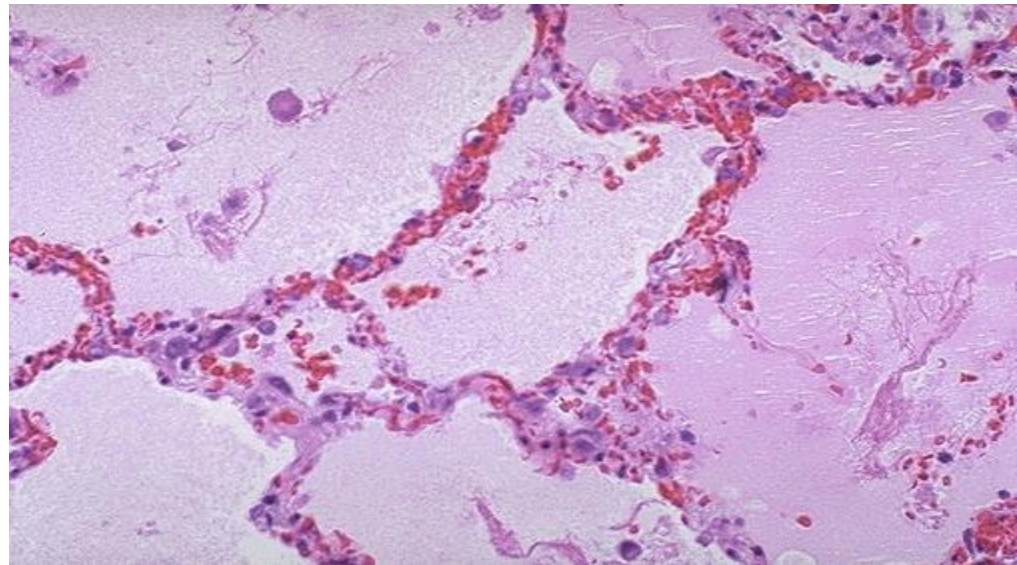
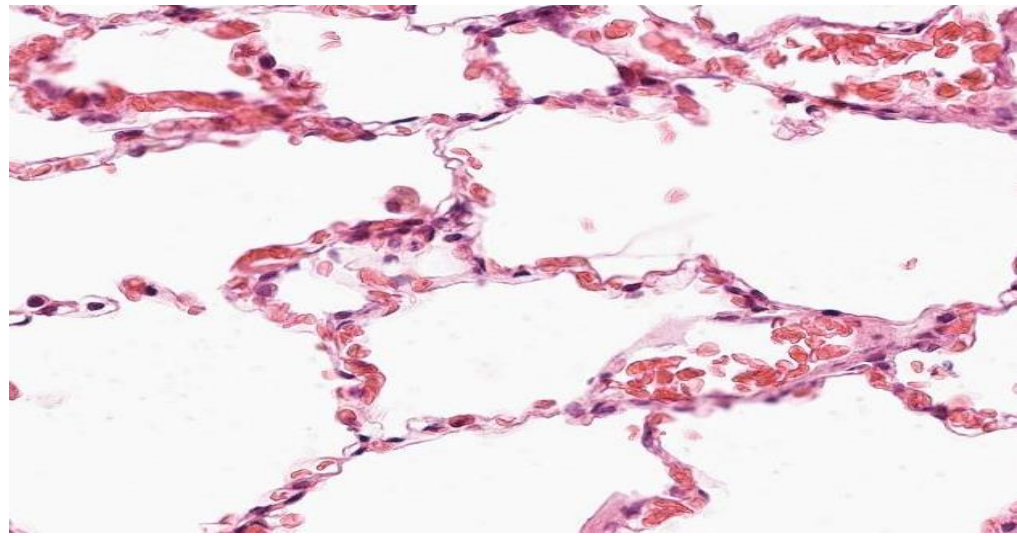


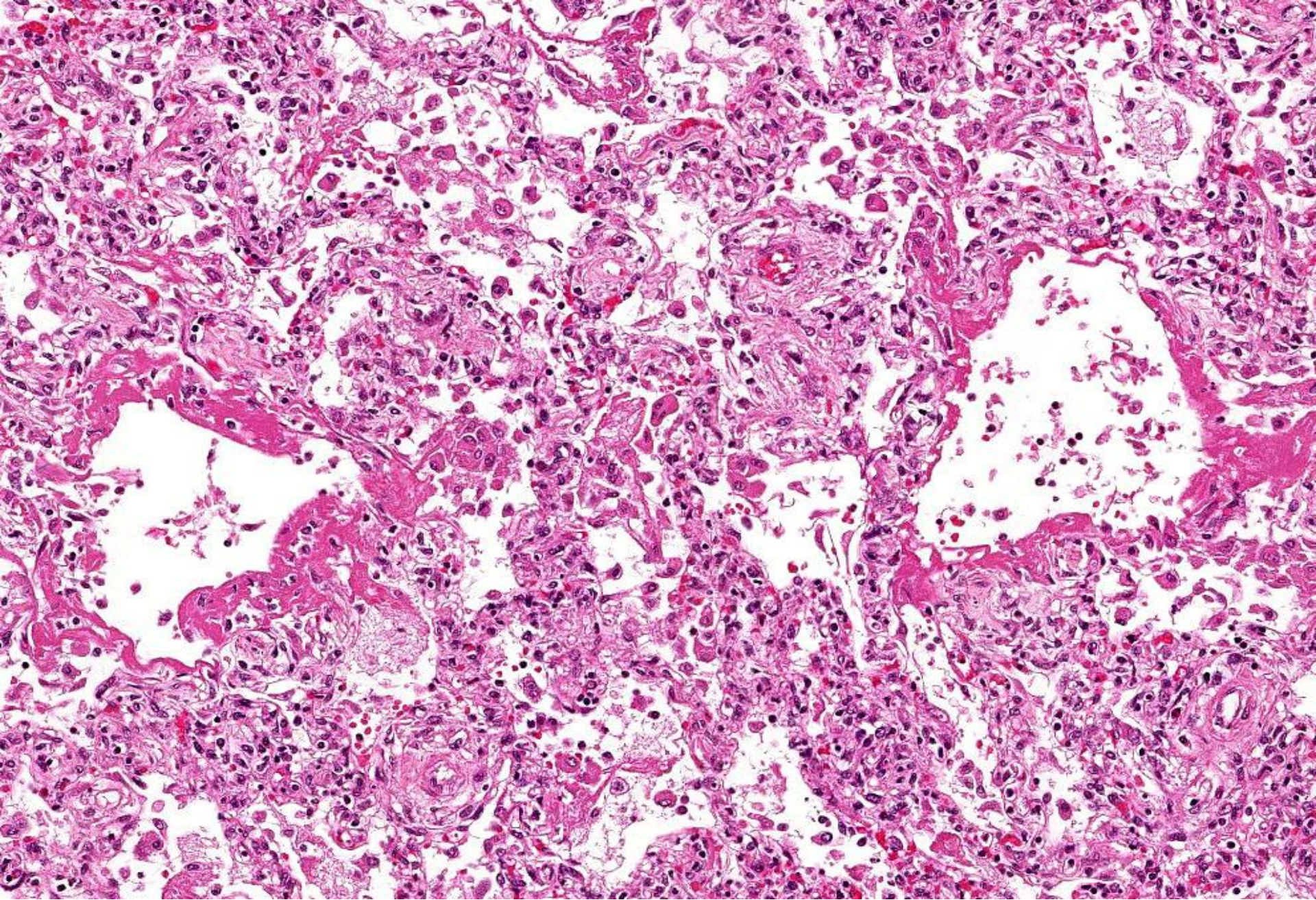
- **COLLAPSE**



PULMONARY EDEMA

- **IN-creased venous pressure**
- **DE-creased oncotic pressure**
- **Lymphatic obstruction**
- **Alveolar injury**





ARDS

ACUTE INTERSTITIAL PNEUMONIA

- **Think of it as ARDS with NO known etiology!**

OBSTRUCTION v. RESTRICTION

- **OBSTRUCTION**

- Air or blood?
- Large or small?
- Inspiration or Expiration?
- **Obstruction is SMALL AIRWAY EXPIRATION**
obstruction, i.e., wheezing
- **HYPEREXPANSION** on CXR

- **RESTRICTION**

“Compliance”

“Infiltrative”

REDUCED lung VOLUME, DYSPNEA, CYANOSIS

REDUCED GAS TRANSFER

“GROUND GLASS” on CXR

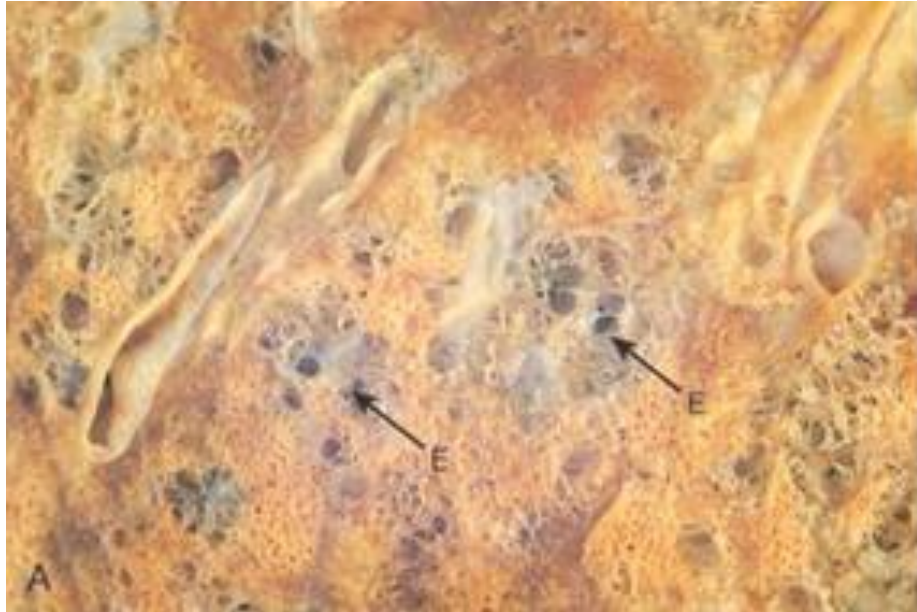
OBSTRUCTION (cOPD)

- **EMPHYSEMA** (almost always chronic)
- **CHRONIC BRONCHITIS** → emphysema
- **ASTHMA**
- **BRONCHIECTASIS**


EMPHYSEMA

- **COPD, or “END-STAGE” lung disease**
- **Centri-acinar, Pan-acinar, Paraseptal, Irregular**
- **Like cirrhosis, thought of as END-STAGE of multiple chronic small airway obstructive etiologies**
- **NON-specific**
- **IN-creased crepittance, BULLAE (BLEBS)**
- **Clinically linked to recurrent pneumonias, and progressive failure**

EMPHYSEMA

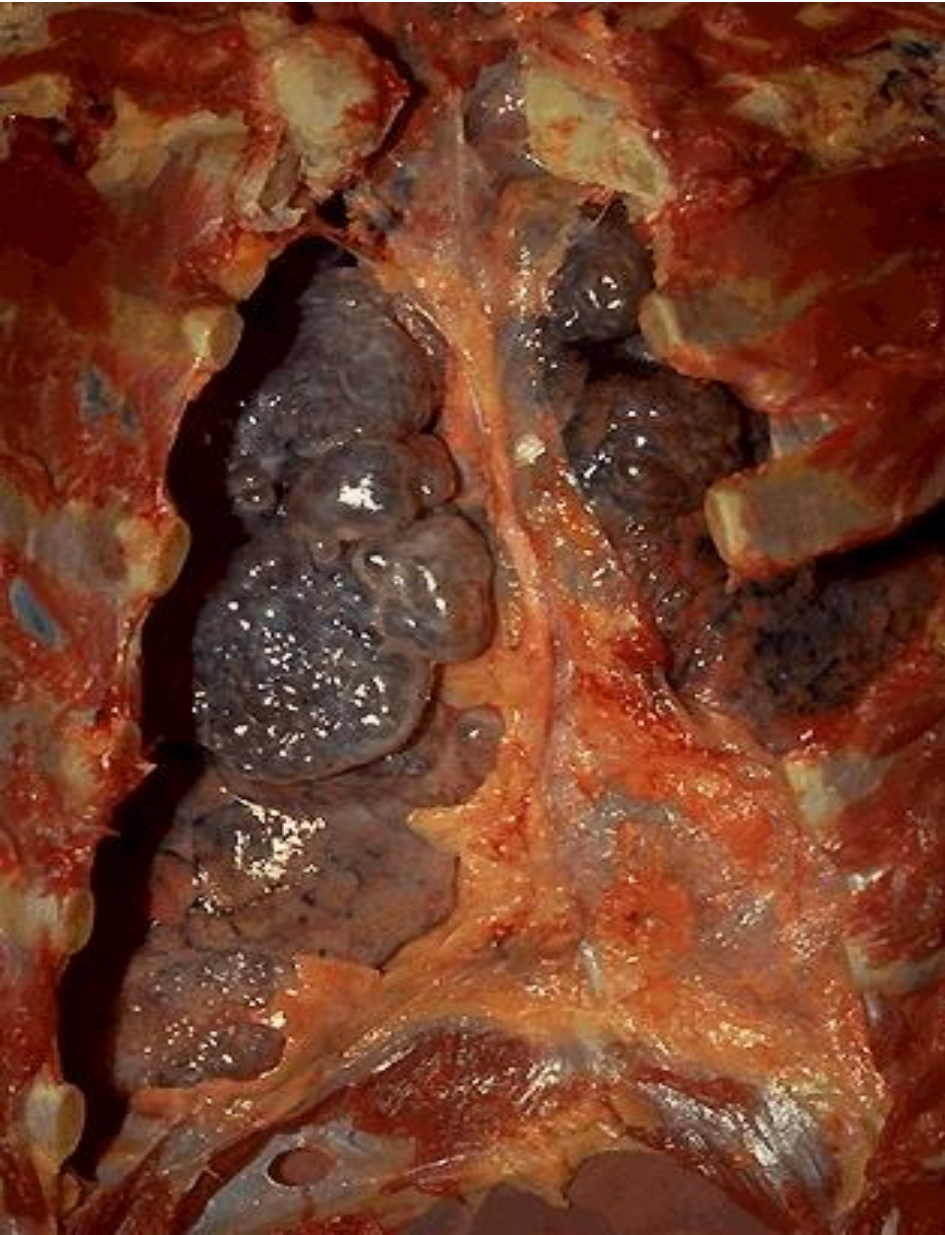


CENTRO-acinar



PAN-acinar

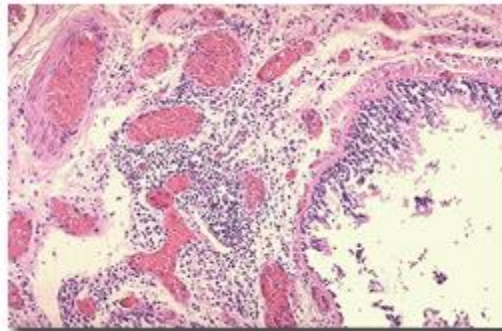
Bullae, or “peripheral blebs” are hallmarks of chronic obstructive lung disease, COPD.



CHRONIC BRONCHITIS

- **INHALANTS, POLLUTION, CIGARETTES**
- **CHRONIC COUGH**
- **CAN OFTEN PROGRESS TO EMPHYSEMA**

- **MUCUS hypersecretion, early, i.e. goblet cell increase**
- **CHRONIC bronchial inflammatory infiltrate**



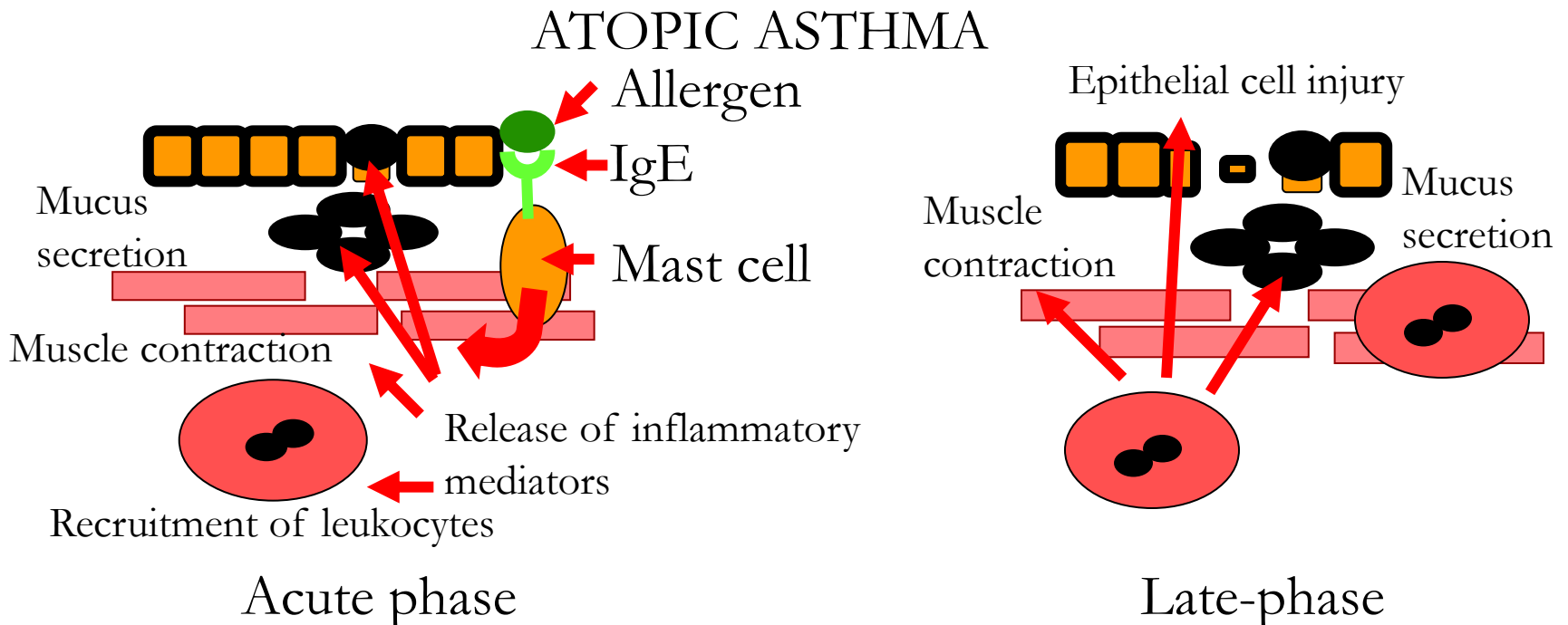
ASTHMA

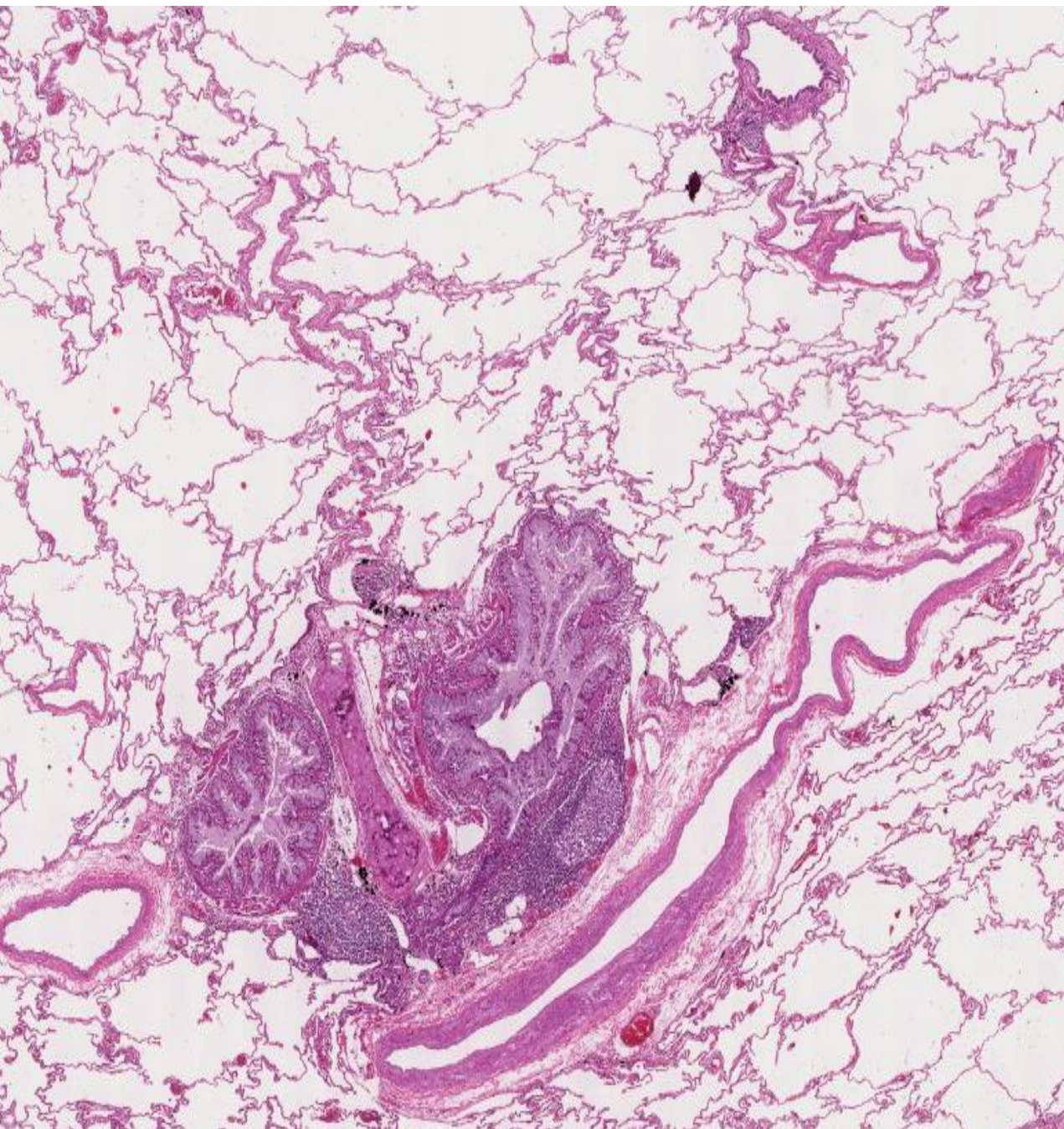
Similar to chronic bronchitis but:

- Wheezing is hallmark (**bronchospasm, i.e. “wheezing”**)
- **STRONG allergic role**, i.e., eosinophils, IgE, allergens
- Often starting in **CHILDHOOD**
- **ATOPIC (allergic) or NON-ATOPIC (infection)**
- Chronic small airway obstruction and infection
- **1) Mucus hypersecretion with plugging, 2) lymphocytes/eosinophils, 3) lumen narrowing, 4) smooth muscle hypertrophy**

Bronchial Asthma

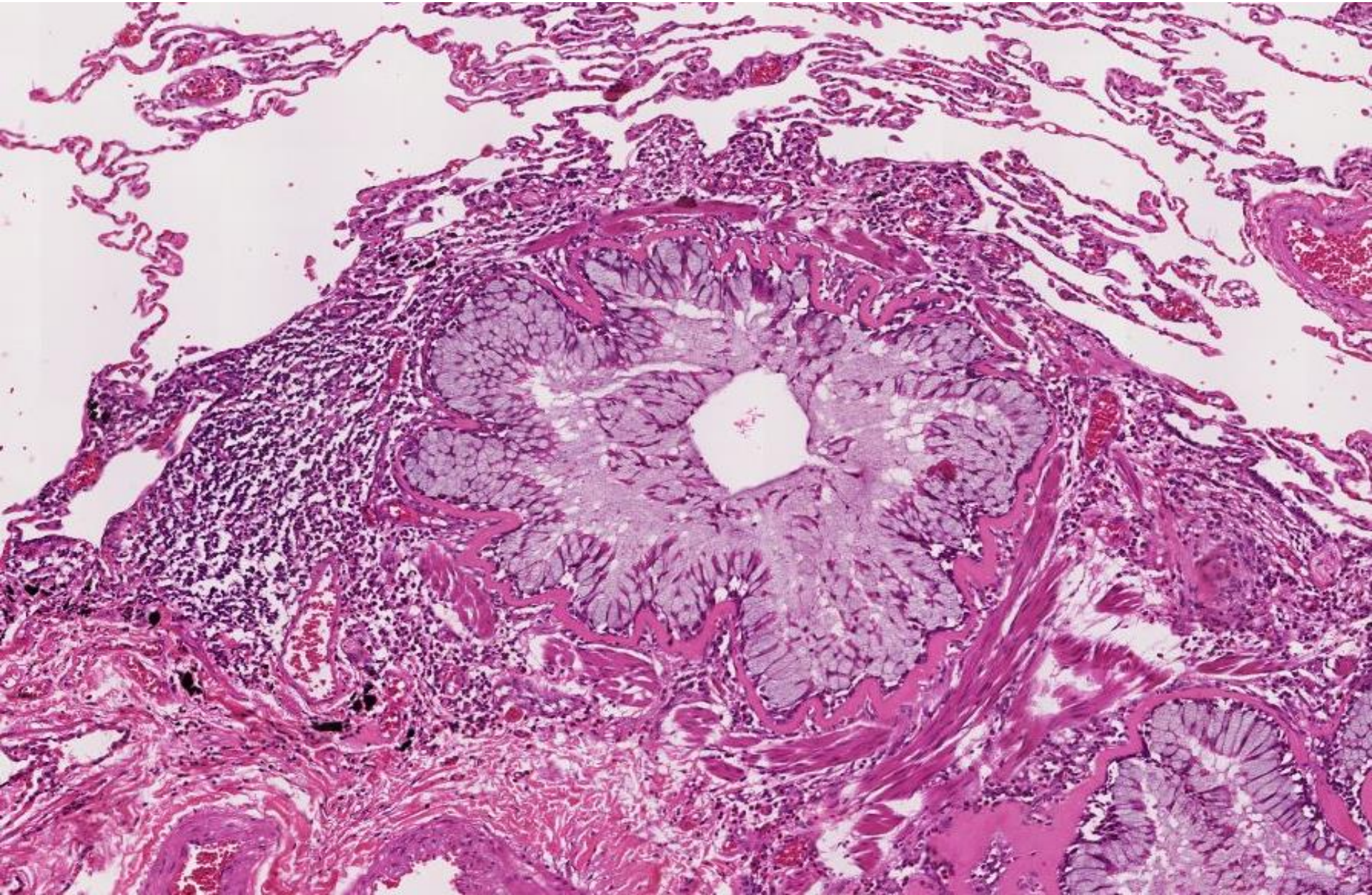
- **Chronic inflammatory disorder of the airways resulting in contraction of bronchial muscle**
- **Types**
 - **Extrinsic (atopic, allergic).**
 - Allergens: food, pollen, dust, etc.
 - **Intrinsic (non-atopic)**
 - Initiated by infections, drugs, pollutants, chemical irritants





Note the heavy inflammatory cell infiltrate around bronchioles and small bronchi.

What are the 4 classical histologic findings in bronchial asthma?



BRONCHIECTASIS

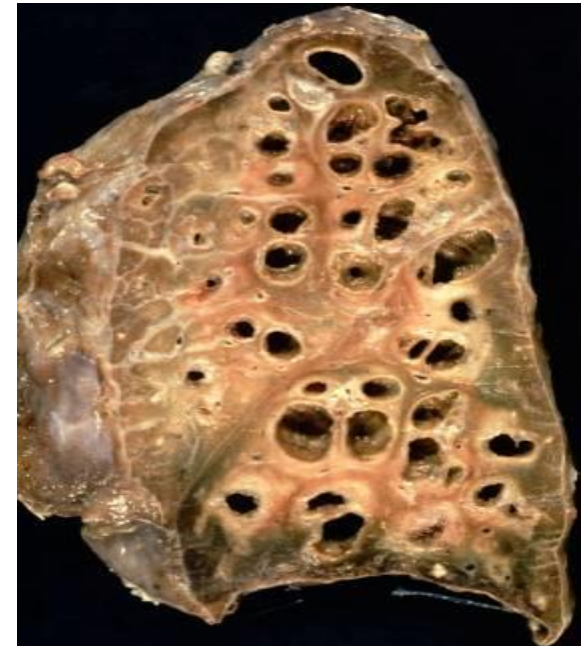**DILATATION of the
BRONCHUS, associated with,
often, necrotizing
inflammation**

– **CONGENITAL**

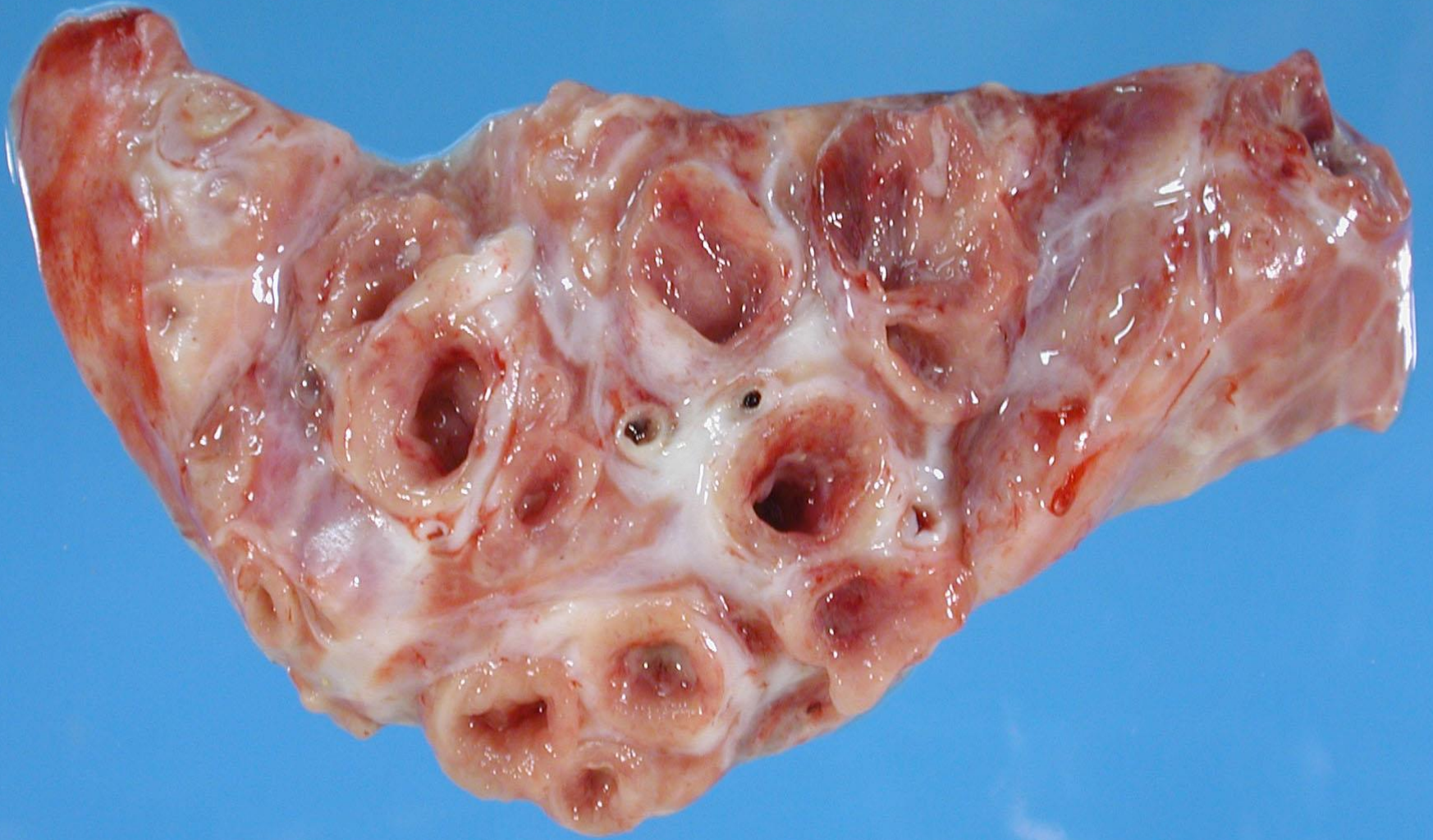– **TB**, other bacteria, many
viruses

– **BRONCHIAL OBSTRUCTION
(i.e., LARGE AIRWAY, NOT
SMALL AIRWAY)**

Rheumatoid Arthritis, SLE, IBD

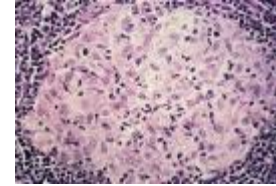
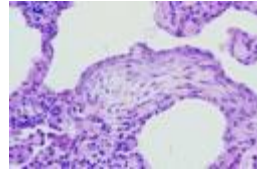


BRONCHIECTASIS



RESTRICTIVE (INFILTRATIVE)

- REDUCED COMPLIANCE, reduced gas exchange)
- Are also DIFFUSE
- HETEROGENEOUS



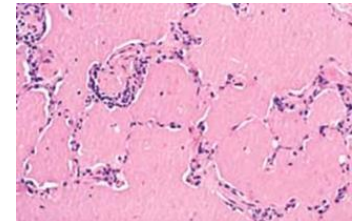
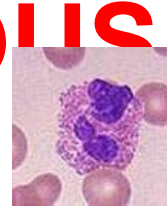
• FIBROSING

• GRANULOMATOUS

• EOSINOPHILIC

• SMOKING RELATED

• PAP (Pulmonary Alveolar

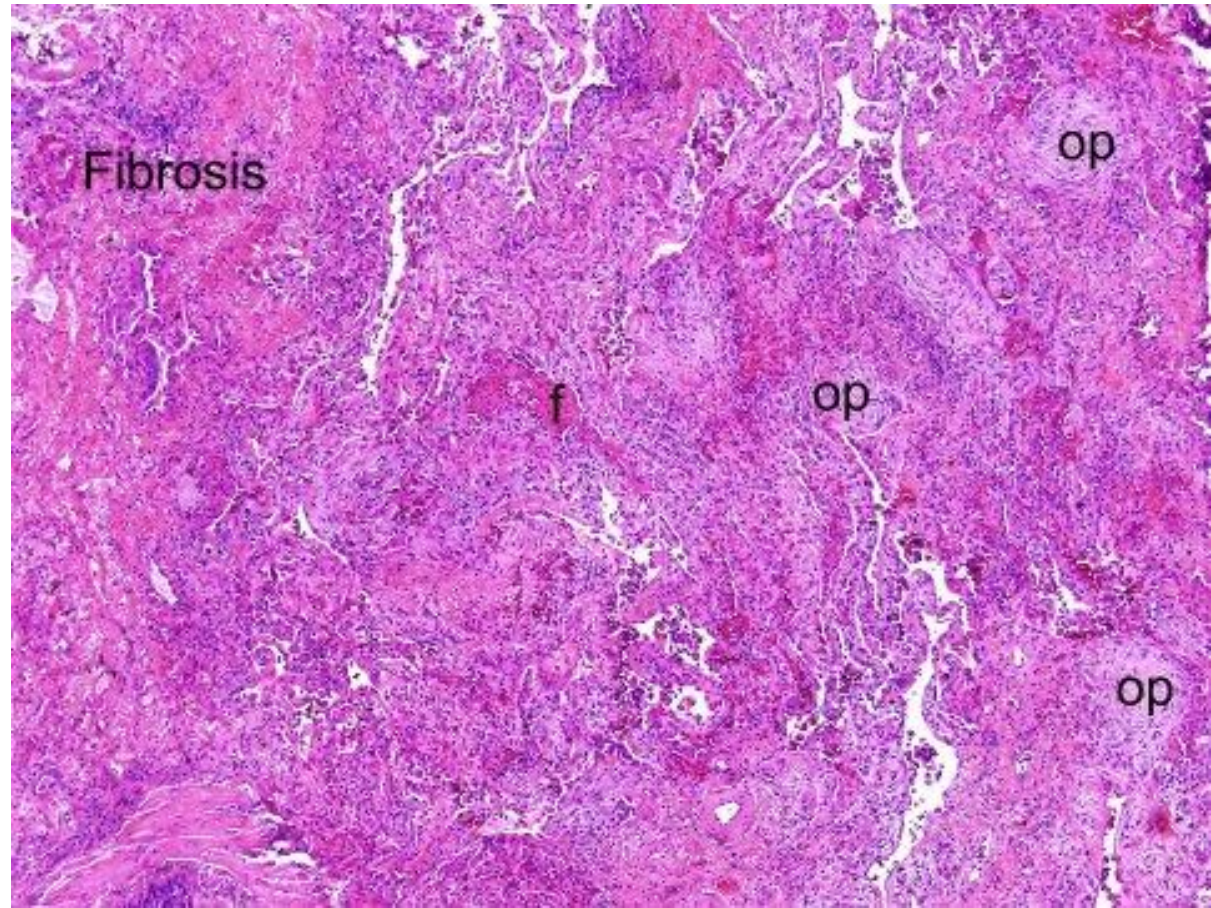


FIBROSING

- **“IDIOPATHIC” PULMONARY FIBROSIS (IPF)**
- **NONSPECIFIC INTERSTITIAL FIBROSIS**
- **“CRYPTOGENIC” ORGANIZING PNEUMONIA**
- **“COLLAGEN” VASCULAR DISEASES**
- **PNEUMOCONIOSES**
- **DRUG REACTIONS**
- **RADIATION CHANGES**

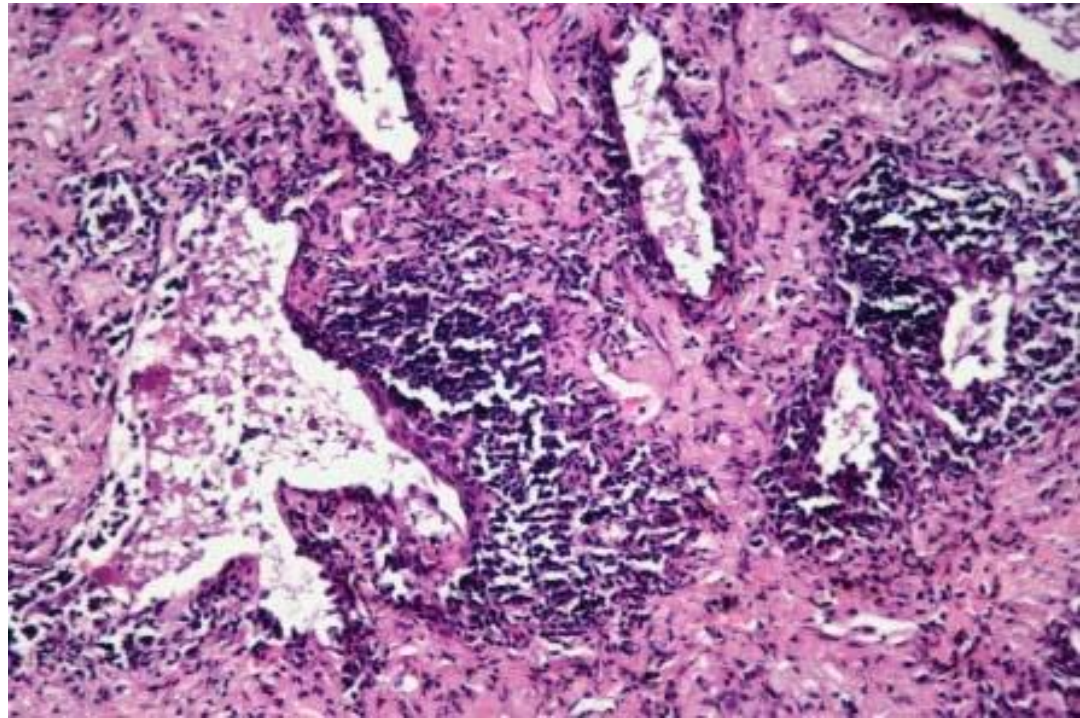
IPF (UIP)

- **IDIOPATHIC**, i.e., not from any usual cause, like lupus, scleroderma
- **FIBROSIS**



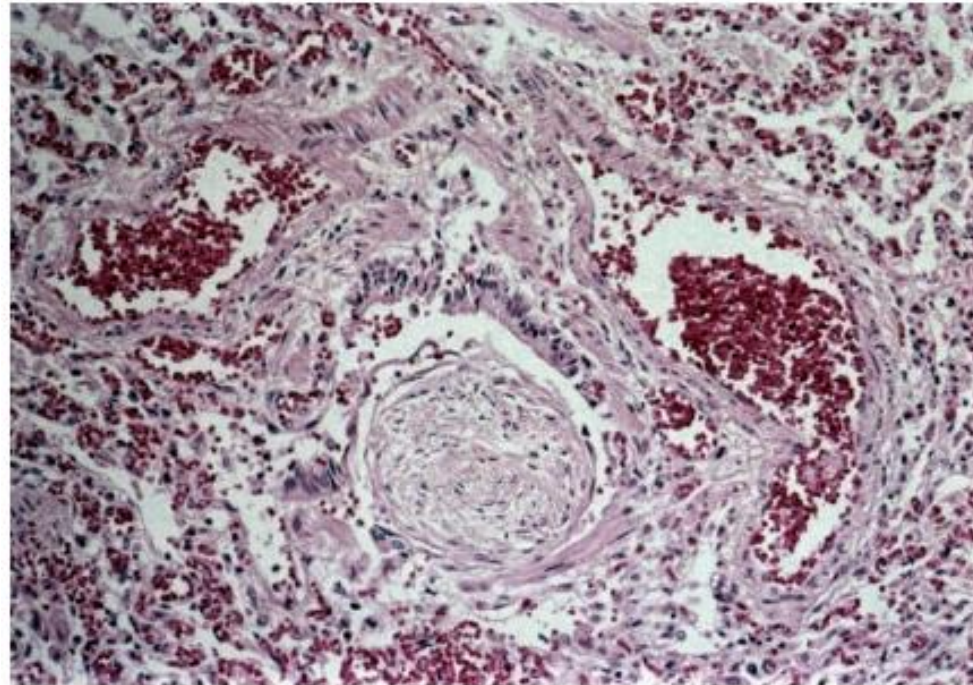
NON-SPECIFIC INTERSTITIAL PNEUMONIA

- **WASTEBASKET DIAGNOSIS, of ANY pneumonia (pneumonitis) of any known or unknown etiology**
 - **FIBROSIS**
 - **CELLULAR INFILTRATE (LYMPHS & PLASMA CELLS)**



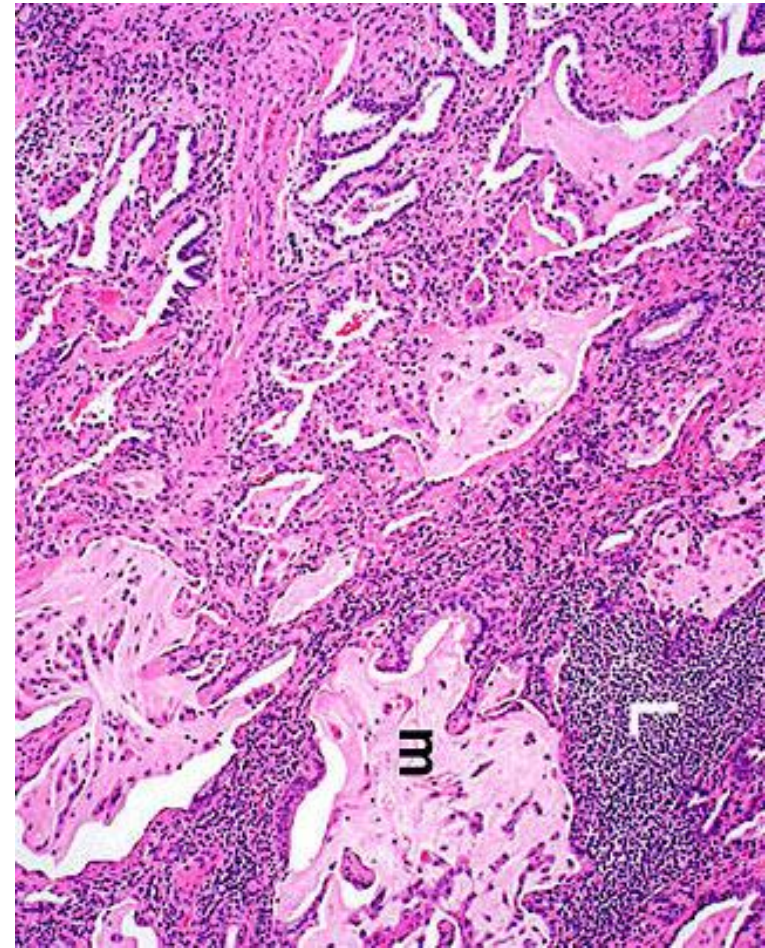
CRYPTOGENIC ORGANIZING PNEUMONIA (COP)

- **IDIOPATHIC**
- **“BRONCHIOLITIS
OBLITERANS”**



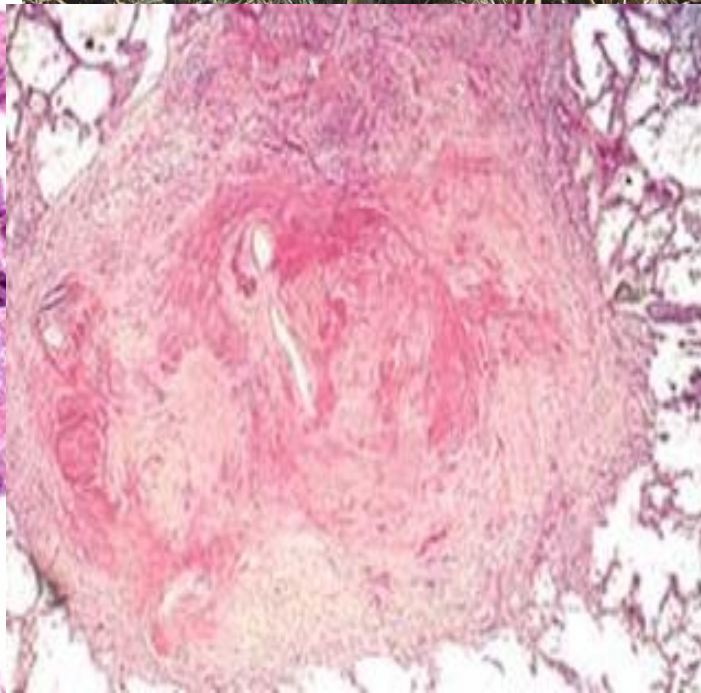
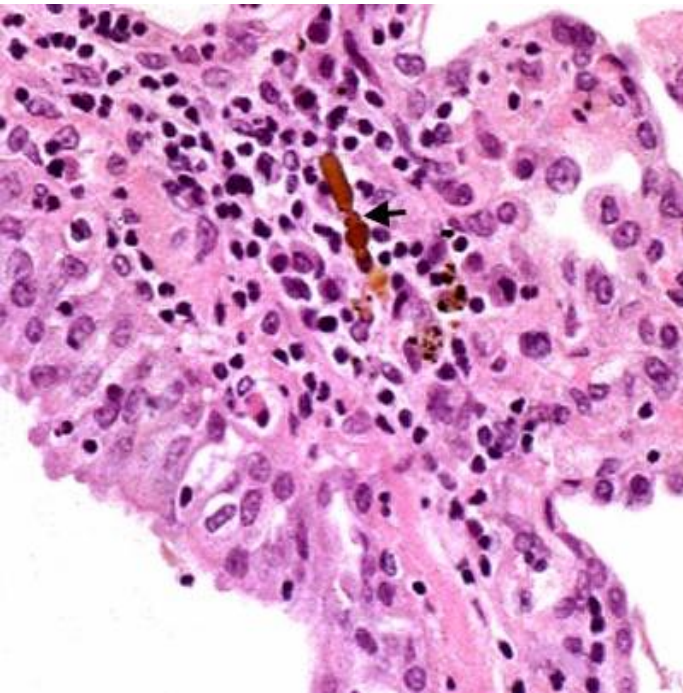
“COLLAGEN” VASCULAR DISEASES

- **Rheumatoid Arthritis**
- **SLE (“Lupus”)**
- **Progressive Systemic Sclerosis (Scleroderma)**



PNEUMOCONIOSES

- **“OCCUPATIONAL”**
- **“COAL MINERS LUNG”**
- **DUST OR CHEMICALS OR ORGANIC MATERIALS**
 - **Coal (anthracosis)**
 - **Silica**
 - **Asbestos**
 - **Be, FeO, BaSO₄, CHEMO**
 - **HAY, FLAX, BAGASSE, INSECTICIDES, etc.**



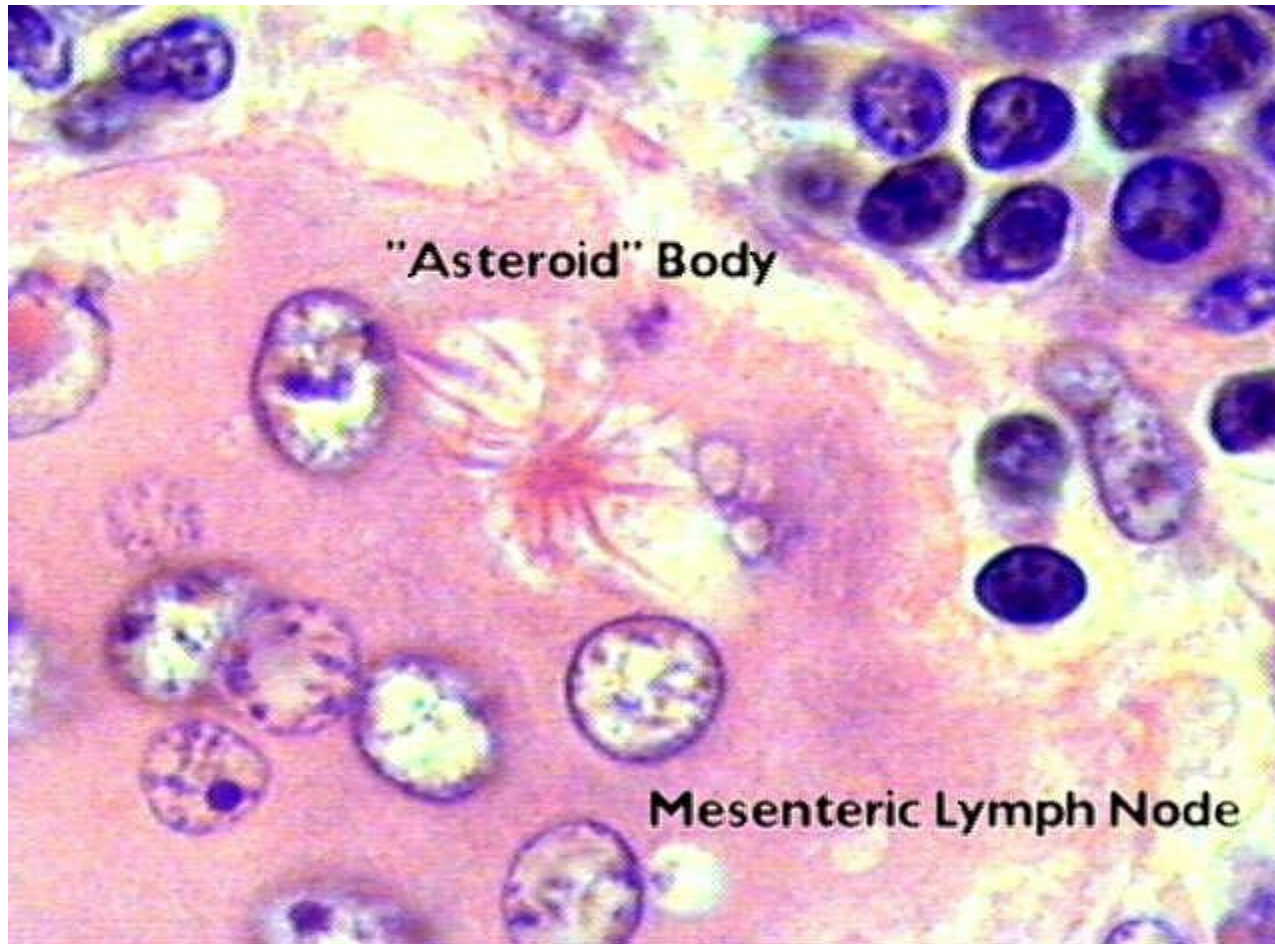
**Coal,
“bagasse”,
asbestos,
silica
nodules,
and
asbestos,
going
clockwise.**

GRANULOMATOUS

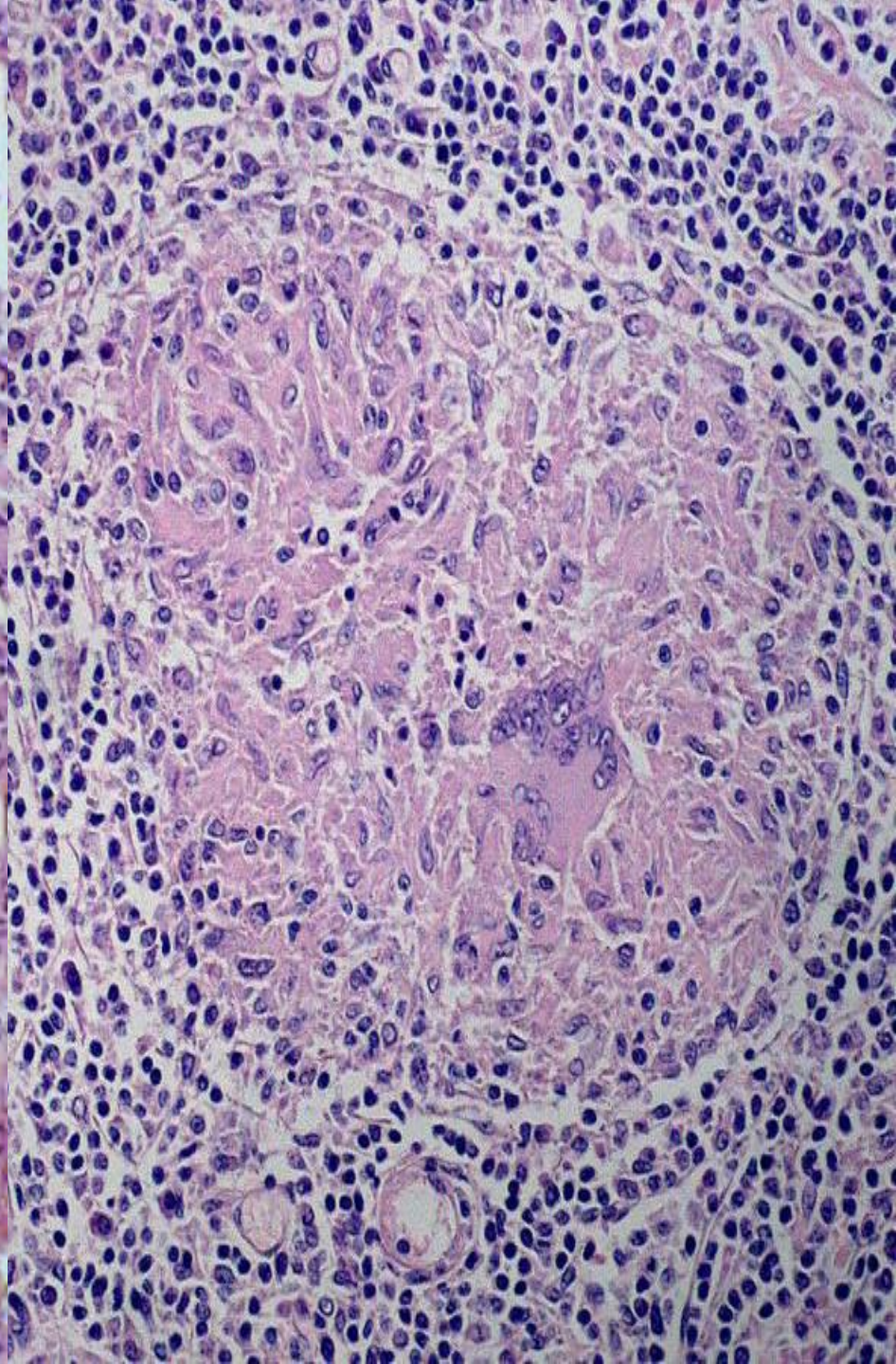
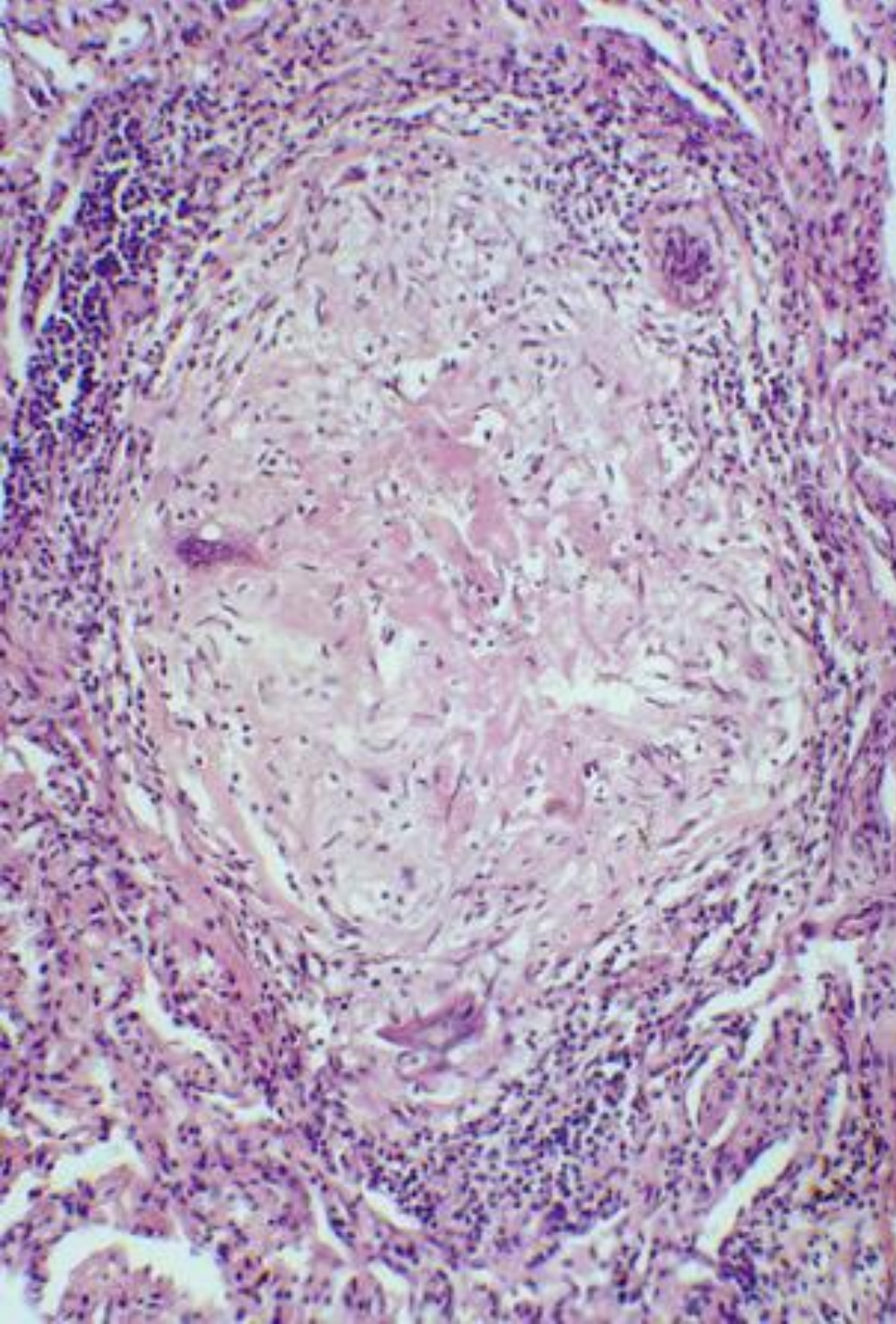
- **SARCOIDOSIS**, i.e., **NON-caseating granulomas (IDIOPATHIC)**
- **HYPERSENSITIVITY** (DUSTS, bacteria, fungi, **Farmer's Lung**, **Pigeon Breeder's Lung**)

SARCOIDOSIS

- **Mainly LUNG, but eye, skin or ANYWHERE**
- **UNKNOWN ETIOLOGY**
- **IMMUNE, GENETIC factors**
- **F>>M**
- **B>>W**
- **YOUNG ADULT BLACK WOMEN**



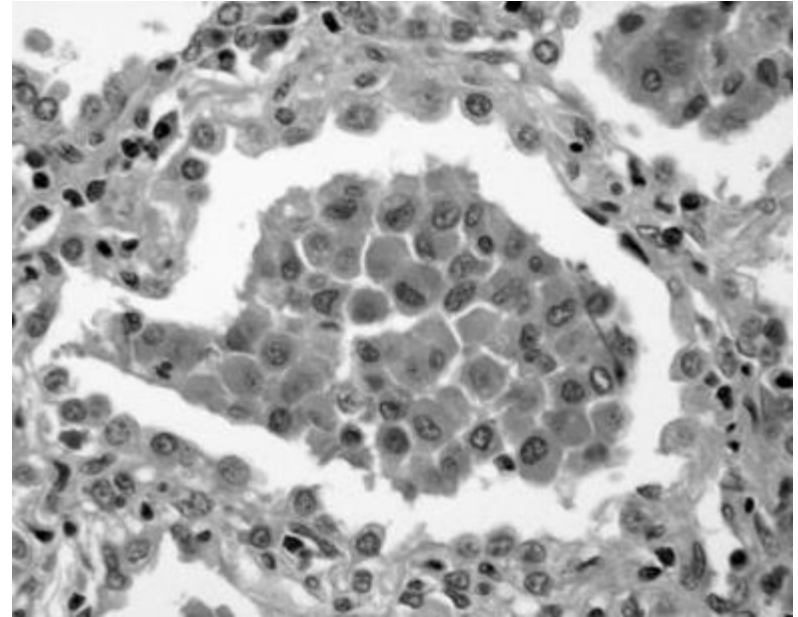
NON-Caseating Granulomas are the RULE
“Asteroid” bodies within these granulomas
are virtually diagnostic



SMOKING RELATED

- **DIP**
(**D**esquamative
Interstitial
Pneumonia)

- M>>F
- CIGARETTES
- 100% Survival



**Alveolar
Macrophages**

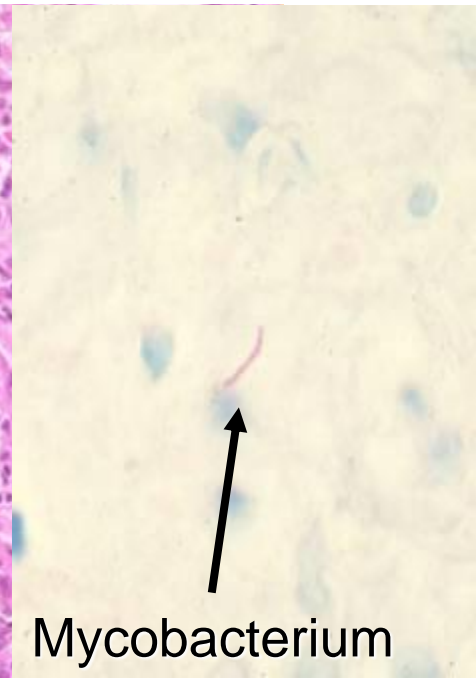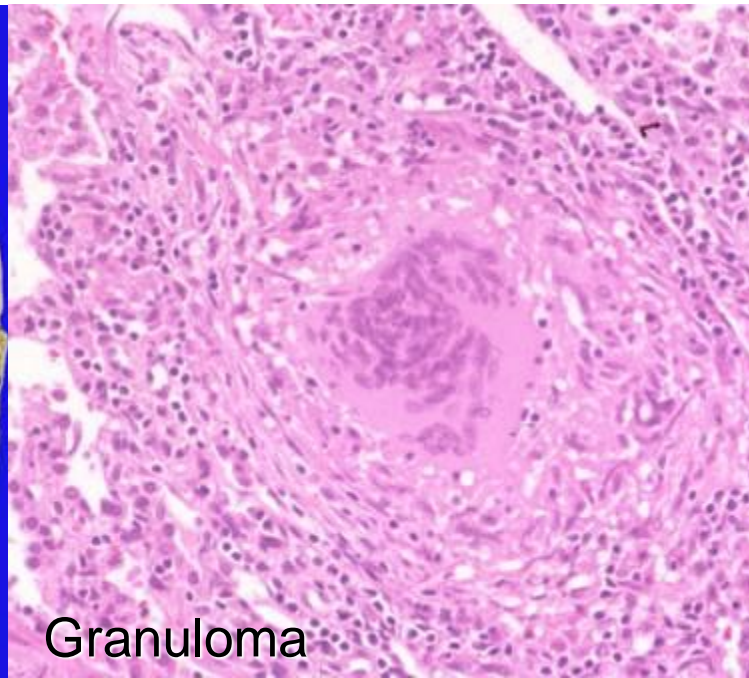
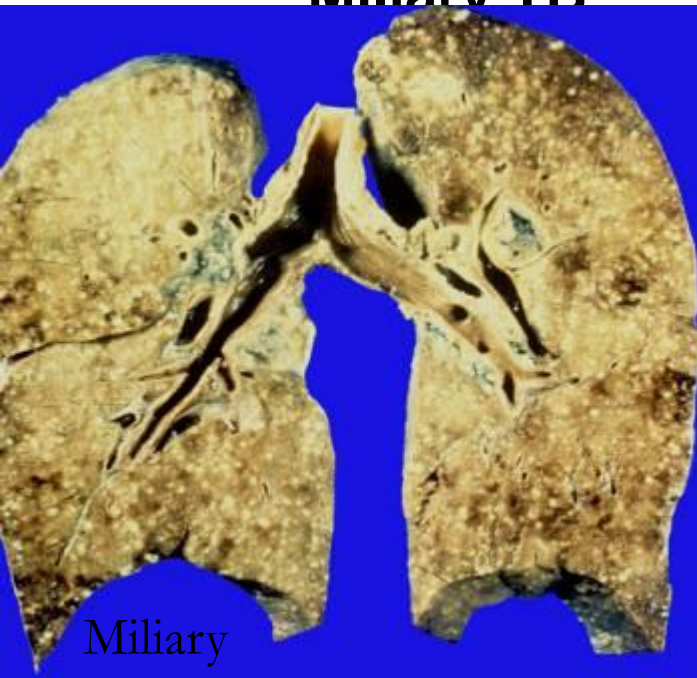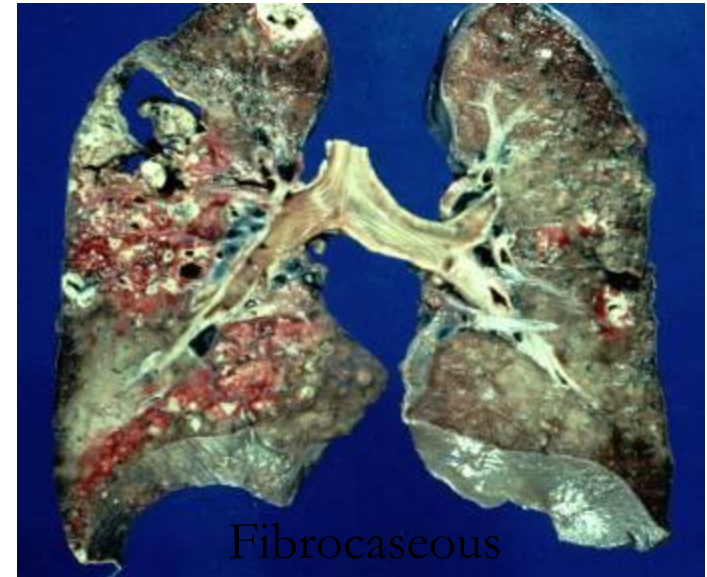
Pulmonary tuberculosis

- Caused by *Mycobacterium tuberculosis*.
- Transmitted through inhalation of infected droplets
- Primary
 - Single granuloma within parenchyma and hilar lymph nodes (Ghon complex).
 - Infection does not progress (most common).
 - Progressive primary pneumonia
 - Miliary dissemination (blood stream).



Pulmonary tuberculosis

- **Secondary**
 - Infection (mostly through reactivation) in a previously sensitized individual.
 - Pathology
 - Cavitory fibrocaseous lesions
 - Bronchopneumonia
 - Miliary TB

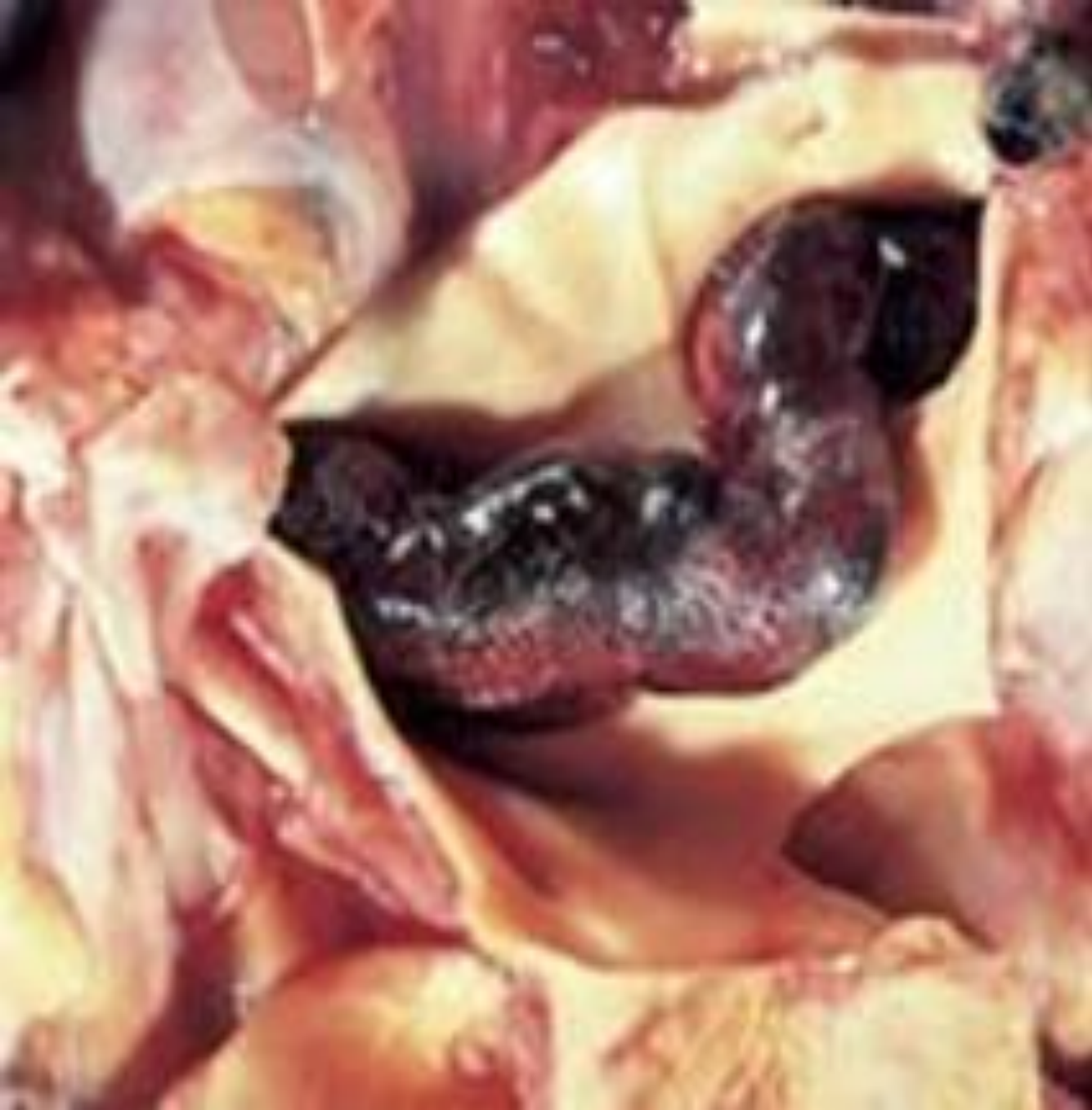

VASCULAR PULMONARY DISEASES

- **PULMONARY EMBOLISM** (with or usually WITHOUT infarction)
- **PULMONARY HYPERTENSION**, leading to cor pulmonale
- **HEMORRHAGIC SYNDROMES**
 - **GOODPASTURE SYNDROME**
 - **HEMOSIDEROSIS**, idiopathic
 - **WEGENER GRANULOMATOSIS**

P.E.

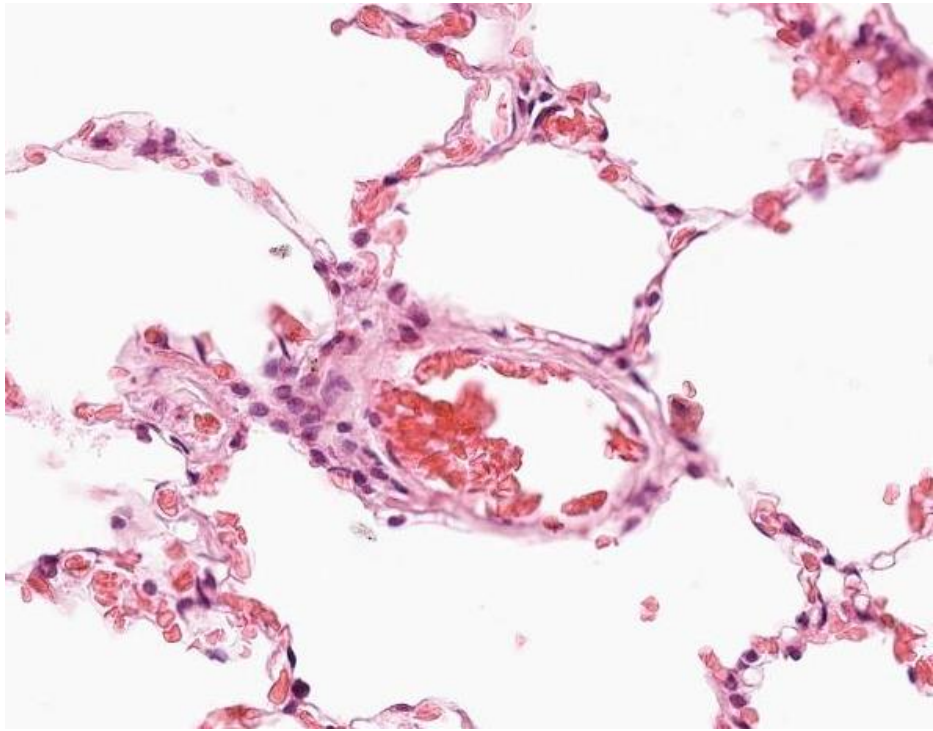
- Usually secondary to debilitated states with immobilization, or following surgery
- Usually deep leg and deep pelvic veins (DVT), NOT superficial veins
- Follows Virchow's triad, i.e., 1) flow problems, 2) endothelial disruption, 3) hypercoagulability
- Usually do NOT infarct, usually ventilate
- When they DO infarct, the infarct is hemorrhagic
- Decreased PO₂, acute chest pain, V/Q MIS-match



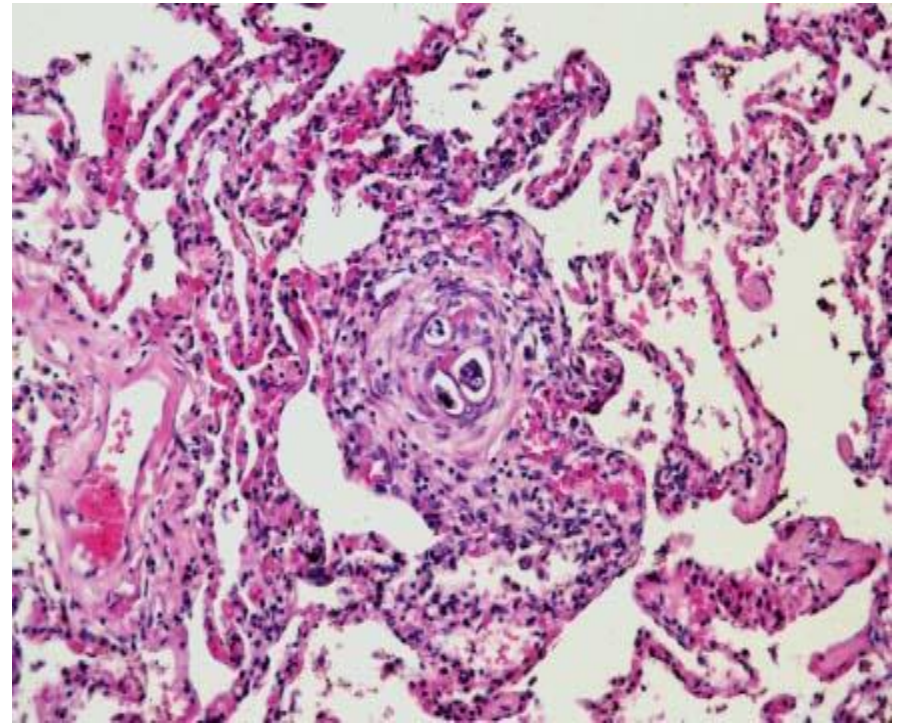
**GROSS
“saddle”
embolism**

PULMONARY HYPERTENSION

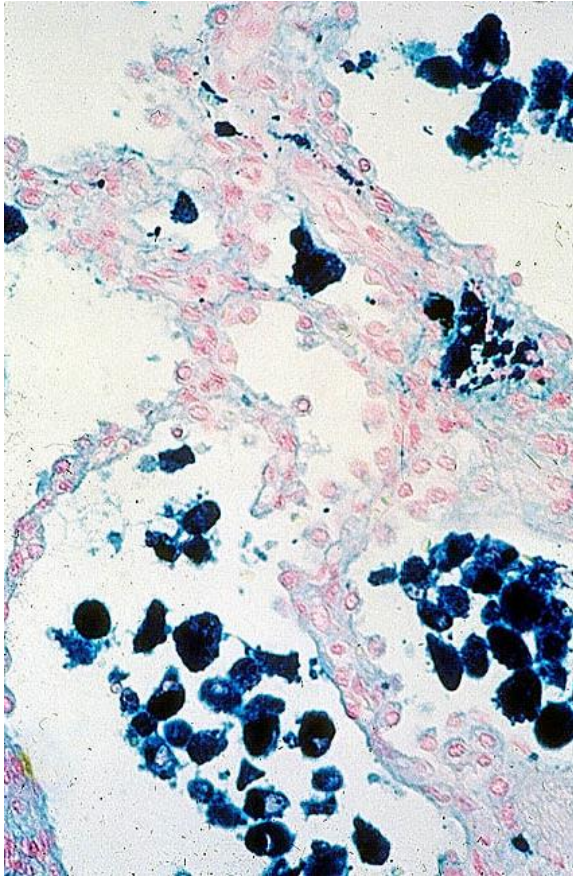
- **COPD, C"IPD** (vicious cycle)
- **CHD** (Congenital HD, increased left atrial pressure)
- Recurrent **PEs**
- Autoimmune, e.g., PSS (**Scleroderma**), i.e., fibrotic pulmonary vasculature



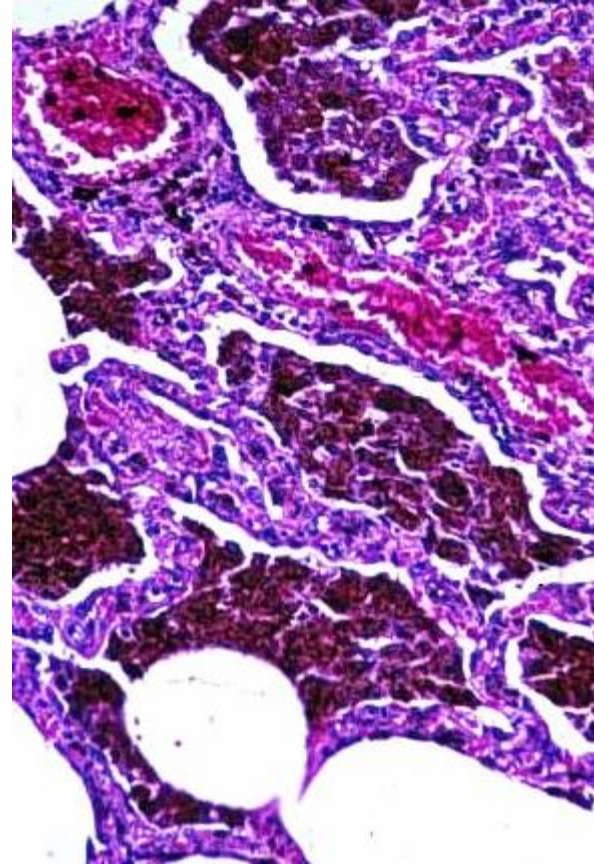
NORMAL pulmonary arteriole



VERY thickened arteriole in pulmonary hypertension

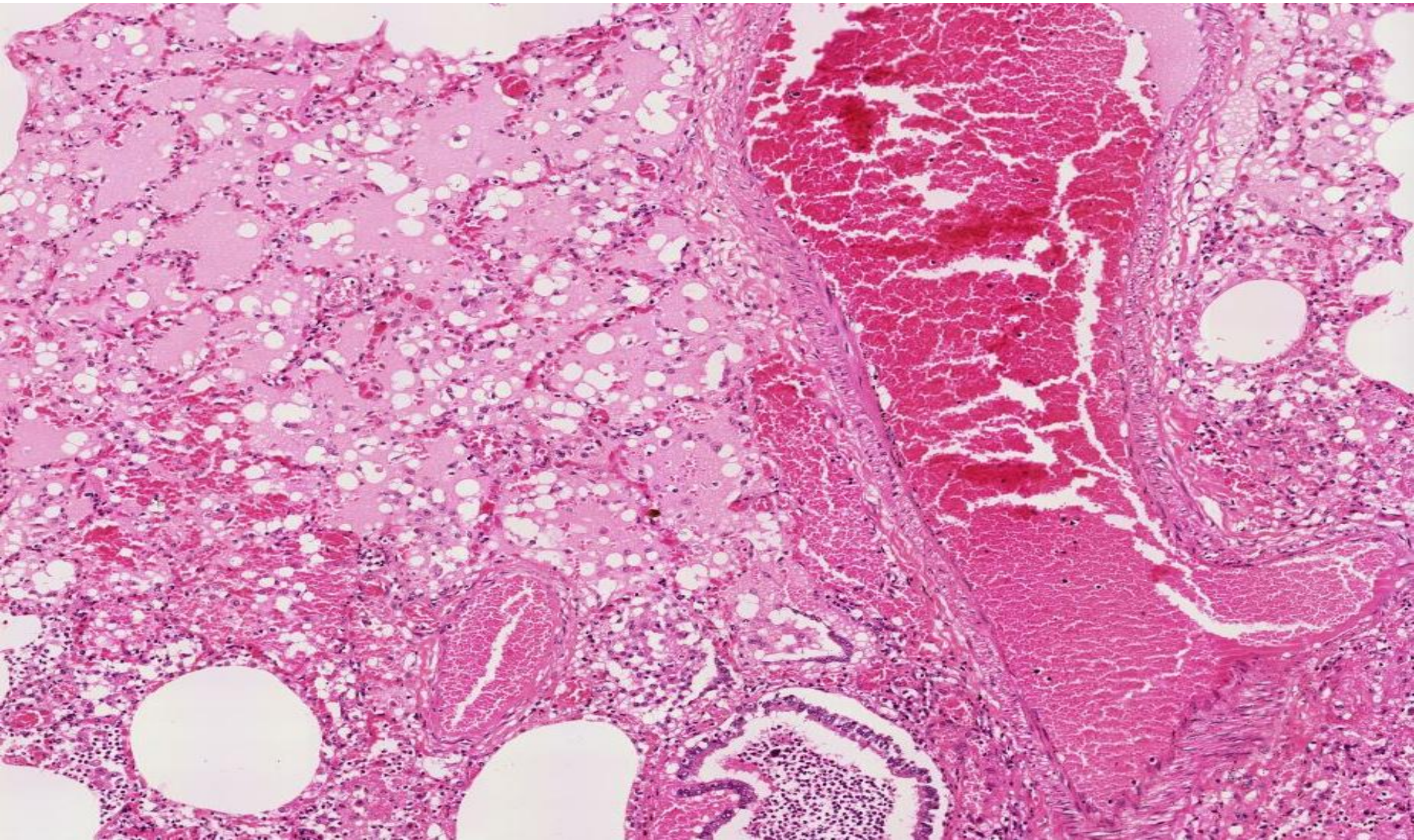


CHF, **CHRONIC**



IDIOPATHIC
PULMONARY
HEMOSIDEROSIS

PNEUMONIA



PULMONARY INFECTIONS

COMMUNITY-ACQUIRED BACTERIAL ACUTE PNEUMONIAS

Streptococcus Pneumoniae

Haemophilus Influenzae

Moraxella Catarrhalis

Staphylococcus Aureus

Klebsiella Pneumoniae

Pseudomonas Aeruginosa

Legionella Pneumophila

COMMUNITY-ACQUIRED ATYPICAL (VIRAL AND MYCOPLASMAL) PNEUMONIAS

Morphology.

Clinical Course.

Influenza Infections

Severe Acute Respiratory Syndrome (SARS)

NOSOCOMIAL PNEUMONIA

ASPIRATION PNEUMONIA

LUNG ABSCESS

Etiology and Pathogenesis.

CHRONIC PNEUMONIA

Histoplasmosis, Morphology

Blastomycosis, Morphology

Coccidioidomycosis, Morphology

PNEUMONIA IN THE IMMUNOCOMPROMISED HOST

PULMONARY DISEASE IN HUMAN IMMUNODEFICIENCY VIRUS INFECTION

BASIC CONSIDERATIONS

- **PNEUMONIA vs. PNEUMONITIS**
- **DIFFERENTIATION from INJURIES, OBSTRUCTIVE DISEASES, RESTRICTIVE DISEASES, VASCULAR DISEASES**
- **DIFFERENTIATION FROM NEOPLASMS**
- **CLASSICAL STAGES of INFLAMMATION**
- **LOBAR- vs. BRONCHO-**
- **INTERSTITIAL vs. ALVEOLAR**
- **COMMUNITY vs. NOSOCOMIAL**
- **ETIOLOGIC AGENTS vs. HOST IMMUNITY**
- **2 PRESENTING SYMPTOMS**
- **2 DIAGNOSTIC METHODS**
- **ANY ORGANISM CAN CAUSE PNEUMONIA!!!**

PREDISPOSING FACTORS

- **LOSS OF COUGH REFLEX**
- **DIMINISHED MUCIN or CILIA FUNCTION**
- **ALVEOLAR MACROPHAGE INTERFERENCE**
- **VASCULAR FLOW IMPAIRMENTS**
- **BRONCHIAL FLOW IMPAIRMENTS**

Although pneumonia is one of the most common causes of death, it usually does **NOT occur in healthy people spontaneously**

Classifications of PNEUMONIAS

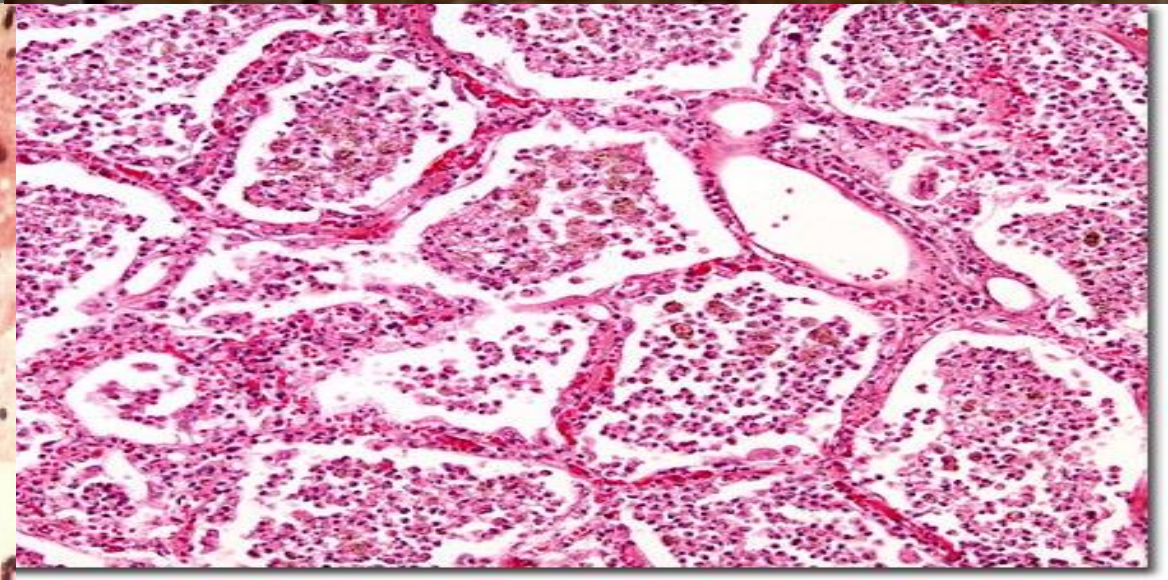
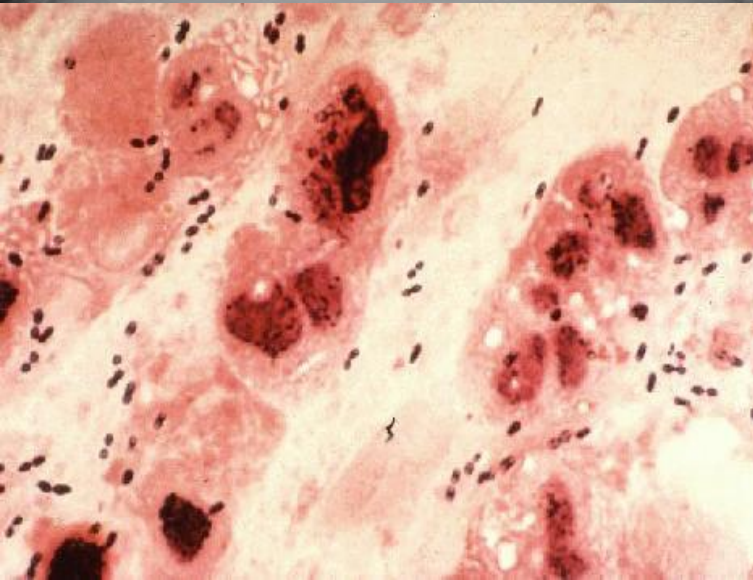
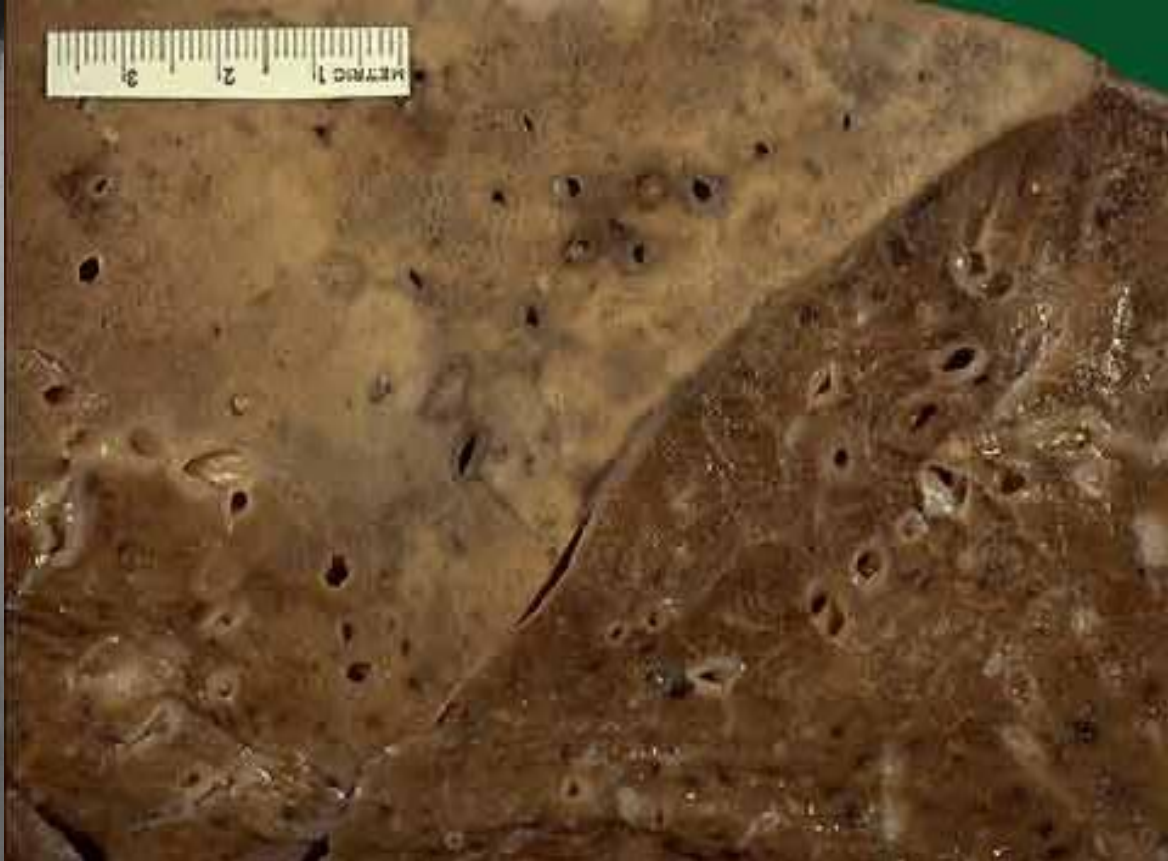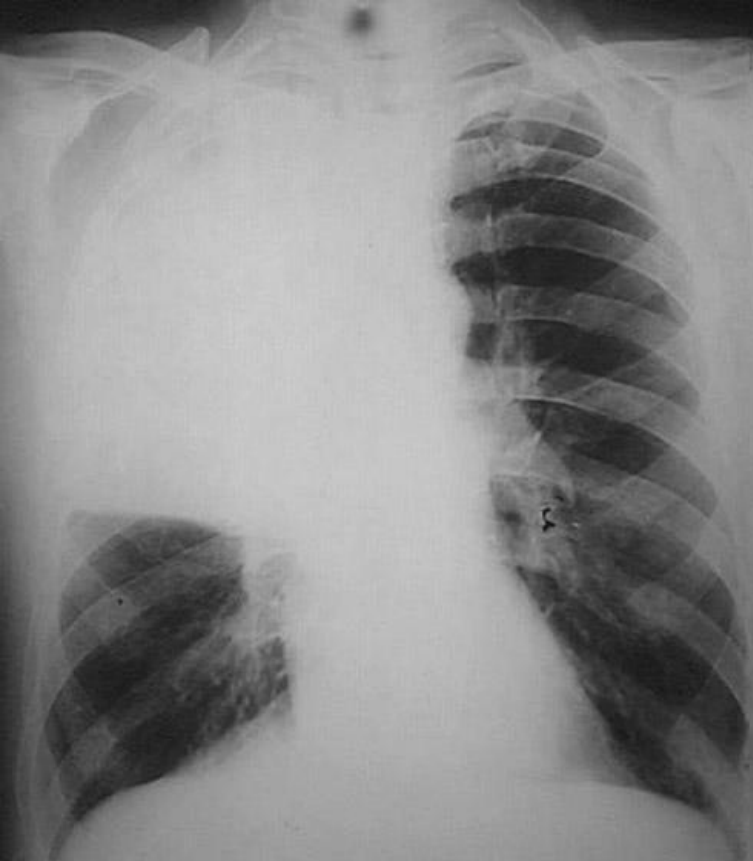
- **COMMUNITY ACQUIRED**
- **COMMUNITY ACQUIRED, ATYPICAL**
- **NOSOCOMIAL**
- **ASPIRATION**
- **CHRONIC**
- **NECROTIZING/ABSCESS FORMATION**
- **PNEUMONIAS in IMMUNOCOMPROMISED HOSTS**

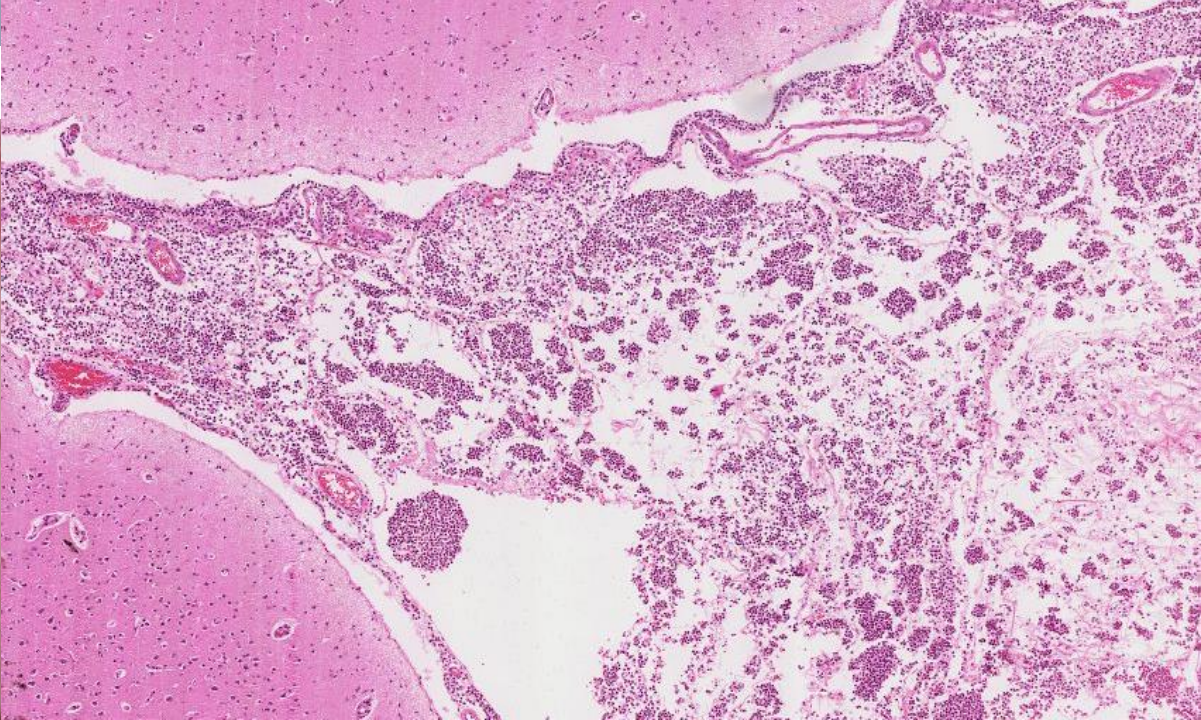
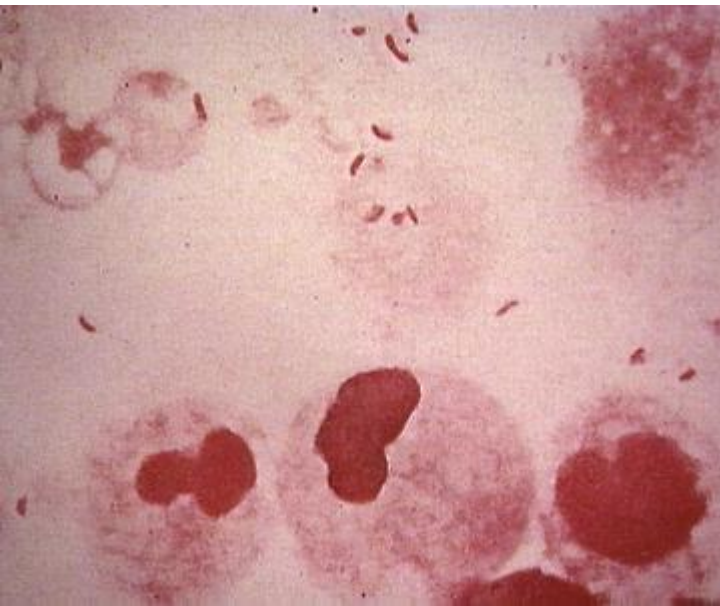
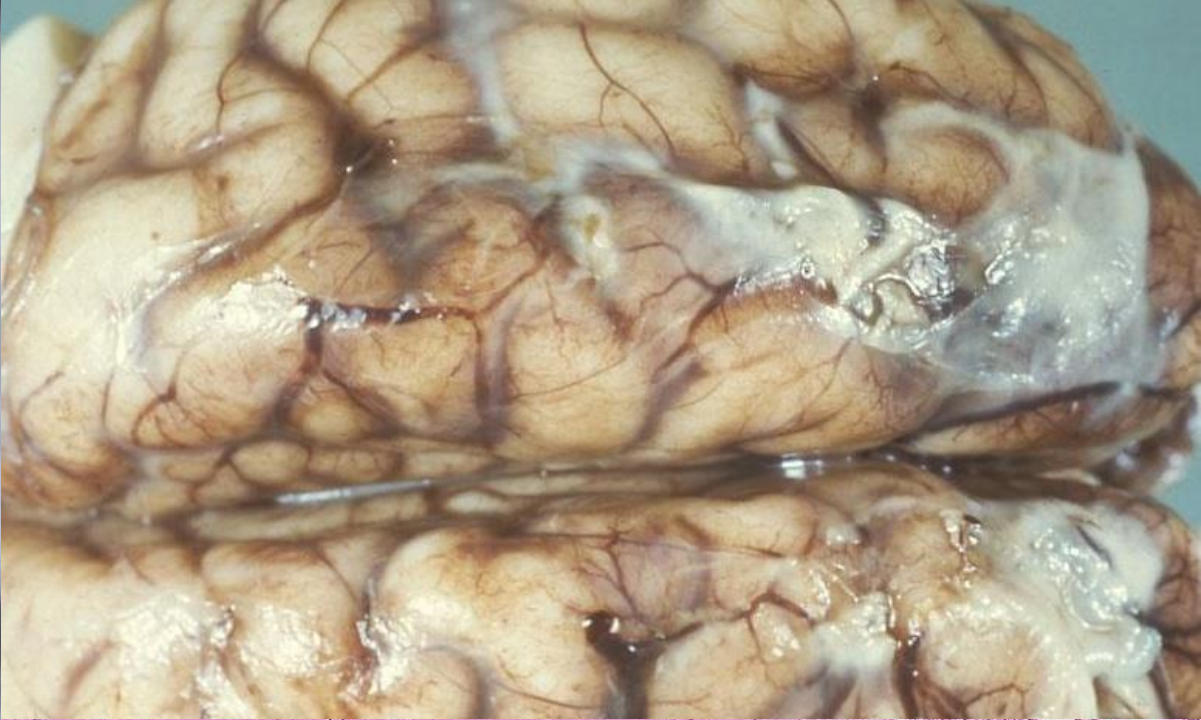
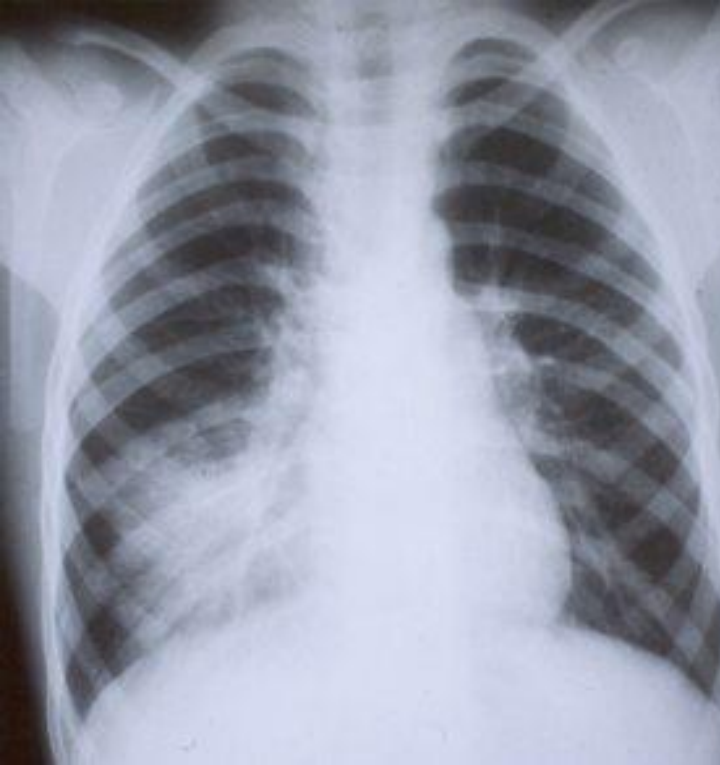COMMUNITY ACQUIRED

- **STREPTOCOCCUS PNEUMONIAE (i.e., “diplococcus”)**
- **HAEMOPHILUS INFLUENZAE (“H-Flu”)**
- **MORAXELLA**
- **STAPHYLOCOCCUS (STAPH)**
- **KLEBSIELLA PNEUMONIAE**
- **PSEUDOMONAS AERUGINOSA**
- **LEGIONELLA PNEUMOPHILIA**

STREPTOCOCCUS

- **The classic LOBAR pneumonia**
- **Normal flora in 20% of adults**
- **Only 20% of victims have + blood cultures**
- **“Penicillins” are often 100% curative**
- **Vaccines are often 100% preventive**





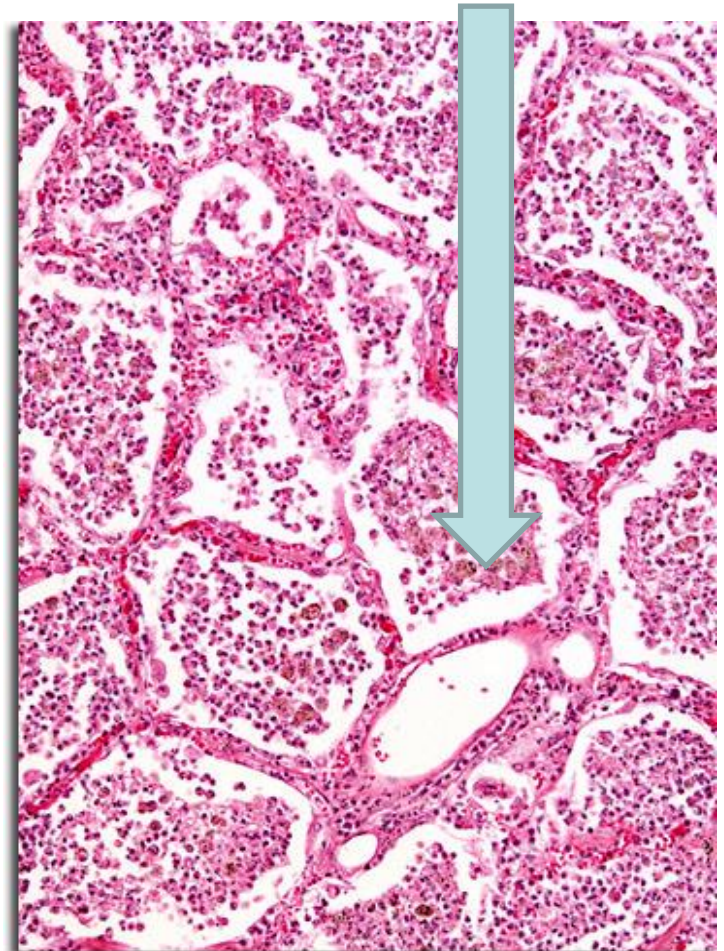
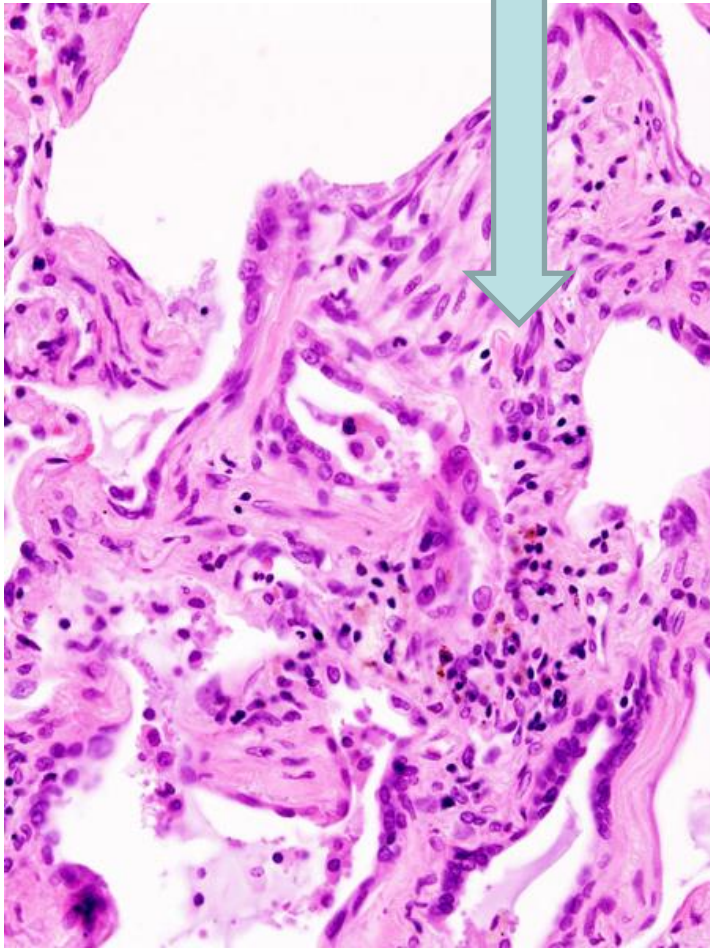
MORPHOLOGY

- ACUTE
- ORGANIZING
- CHRONIC
- FIBROSIS vs. FULL RESOLUTION

- “HEPATIZATION”, RED vs. GREY
- CONSOLIDATION
- “INFILTRATE”, XRAY vs. HISTOPATH
- Loss of “CREPITANCE”

VIRAL PNEUMONIAS

- Frequently “interstitial”, NOT alveolar



ASPIRATION PNEUMONIAS

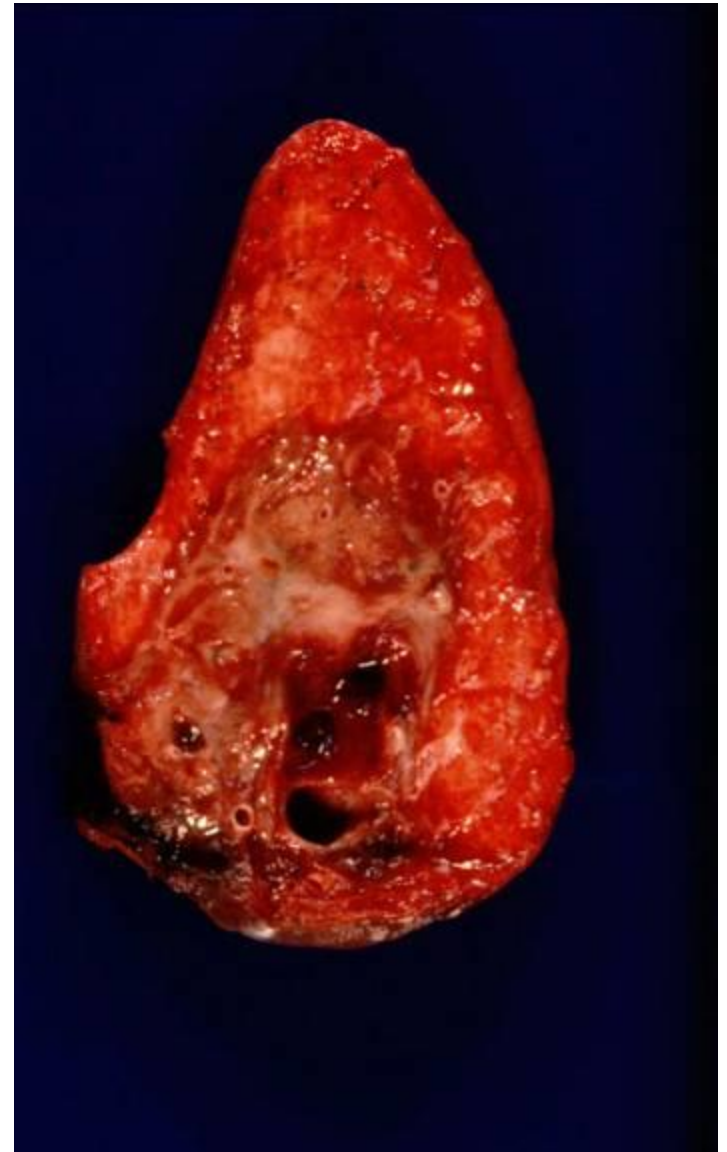- UNCONSCIOUS PATIENTS
- PATIENTS IN PROLONGED BEDREST
- LACK OF ABILITY TO SWALLOW OR GAG
- USUALLY CAUSED BY **ASPIRATION OF GASTRIC CONTENTS**
- POSTERIOR LOBES (gravity dependent) MOST COMMONLY INVOLVED, ESPECIALLY THE **SUPERIOR SEGMENTS of the LOWER LOBES**
- Often lead to **ABSCESSSES**

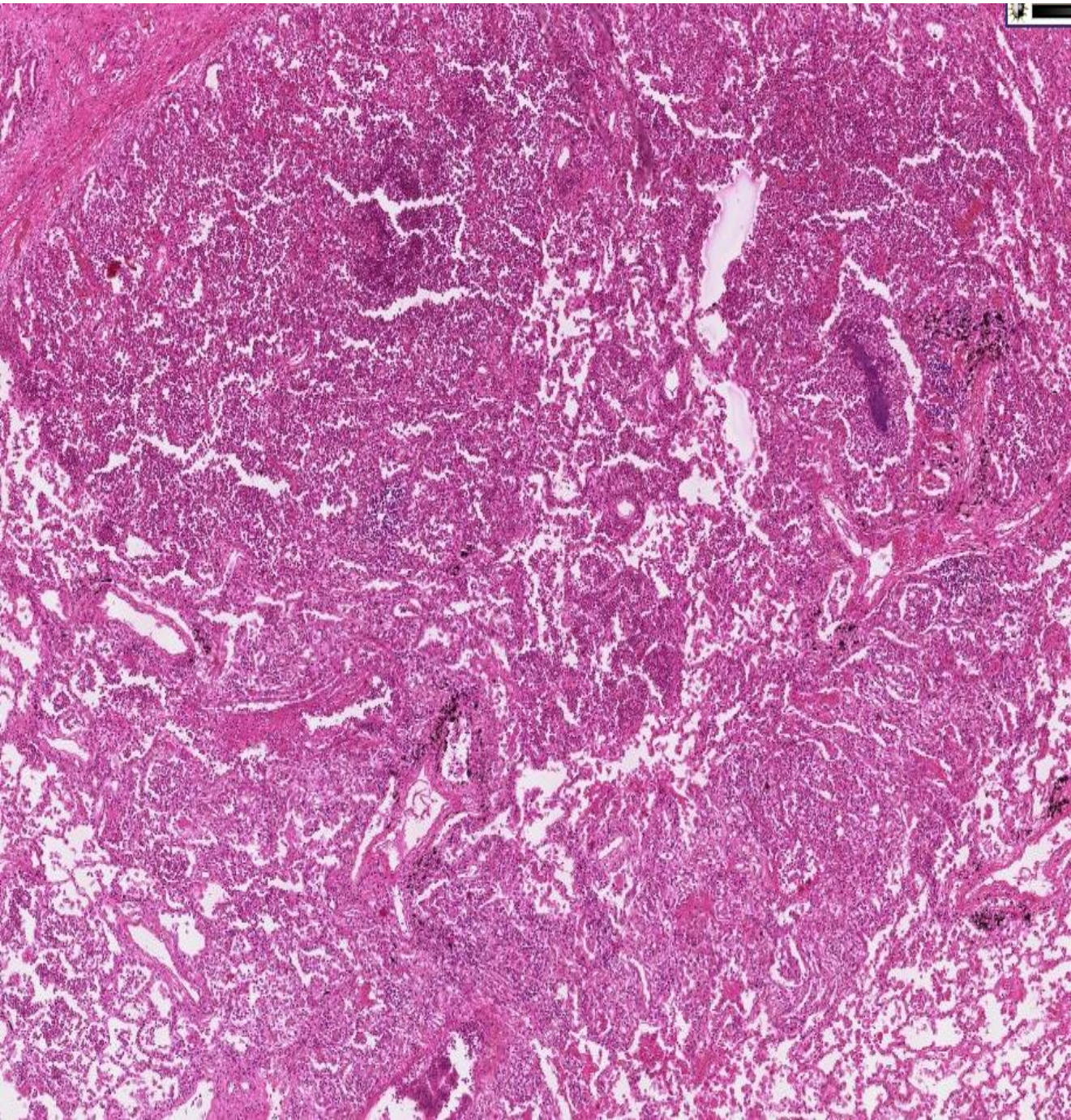
LUNG ABSCESSSES

- **ASPIRATION**
- **SEPTIC EMBOLIZATION**
- **NEOPLASIA**
- From **NEIGHBORING** structures:
 - **ESOPHAGUS**
 - **SPINE**
 - **PLEURA**
 - **DIAPHRAGM**
- **ANY pneumonia** which is severe and destructive, and UN-treated enough

Lung abscess

- **Localized suppurative necrosis**
- **Organisms commonly cultured:**
 - Staphylococci
 - Streptococci
 - Gram-negative
 - Anaerobes
 - Frequent mixed infections
- **Pathogenesis:**
 - Aspiration
 - Pneumonia
 - Septic emboli
 - Tumors
 - Direct infection





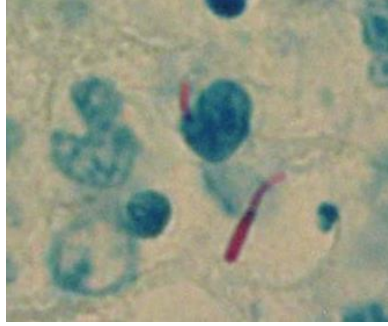
An abscess can be thought of as a pneumonia in which all of the normal lung outline can no longer be seen, and there is 100% pus.

CHRONIC Pneumonias

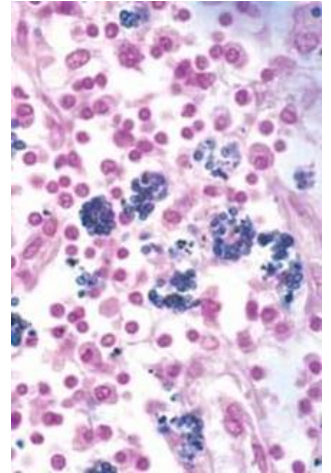
- **USUALLY NOT** persistences of the community or nosocomial bacterial infections, but **CAN BE**, at least histologically
- Often **SYNONYMOUS** with the 4 classic fungal or **granulomatous** pulmonary infections infections, i.e., TB, Histo-, Blasto-, Coccidio-
- If you see pulmonary granulomas, think of a **CHRONIC** process, often years

CHRONIC Pneumonias

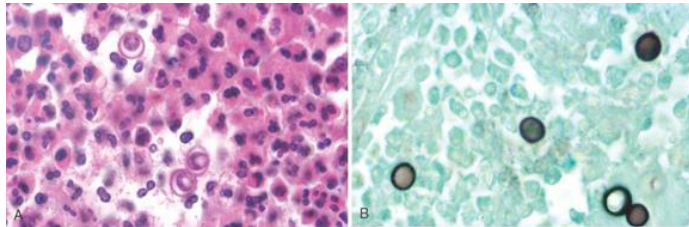
- TB



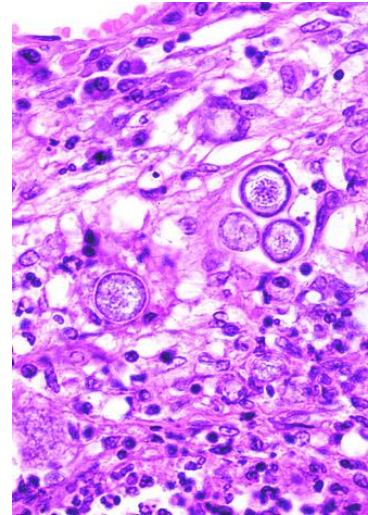
- HISTO-PLASMOSIS

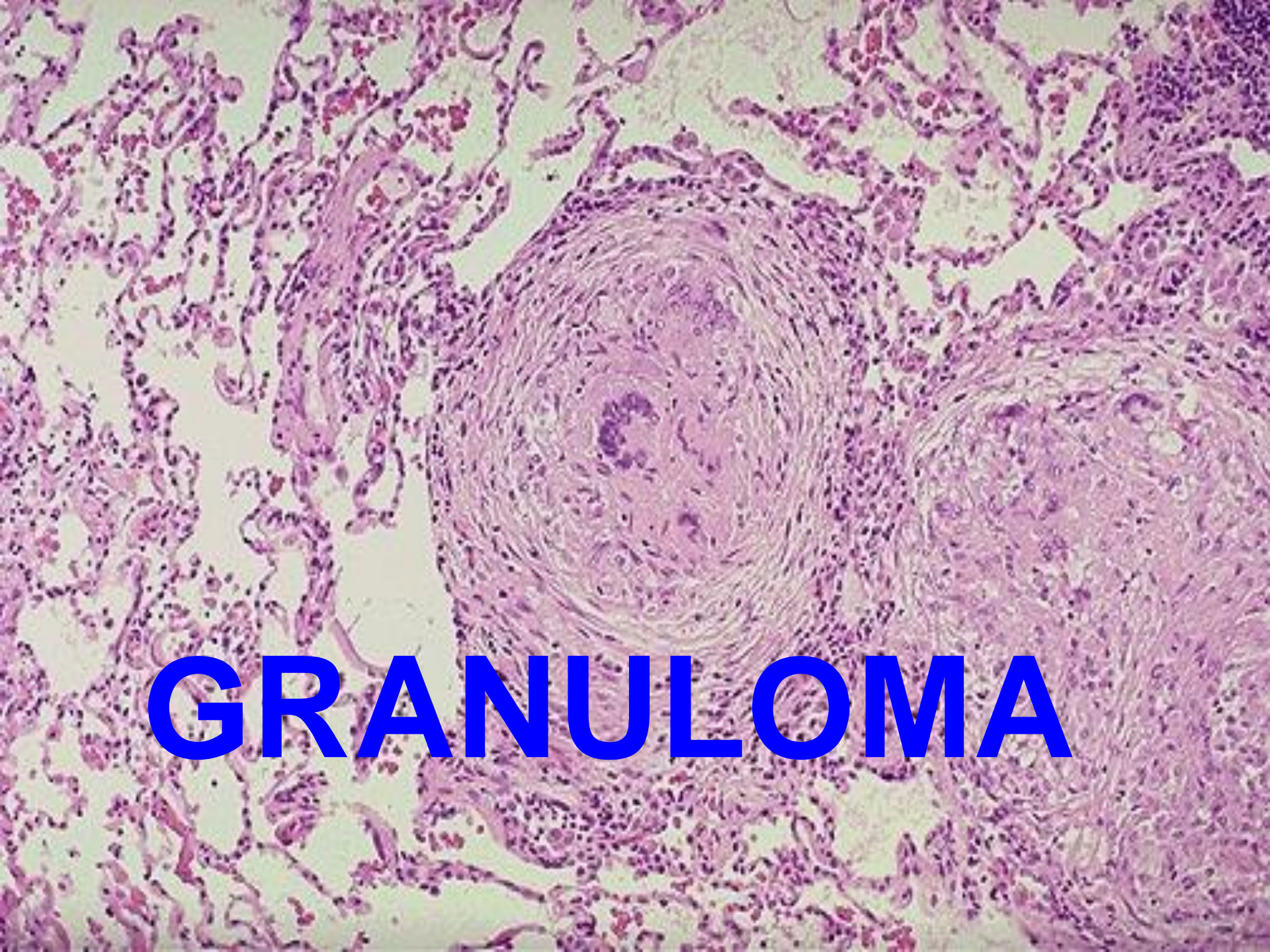


- BLASTO-MYCOSIS



- COCCIDIO-MYCOSIS





GRANULOMA

LUNG TUMORS

- Benign, malignant, epithelial, mesenchymal, but 90% are **CARCINOMAS**
- **BIGGEST USA killer. Why? Ans: Prevalence not as high as prostate or breast but mortality higher. Only 15% 5 year survival.**
- **TOBACCO** has polycyclic aromatic hydrocarbons, such as benzopyrene, anthracenes, radioactive isotopes
- Radiation, asbestos, radon
- C-MYC. K-RAS. EGFR. HER-2/neu

PATHOGENESIS

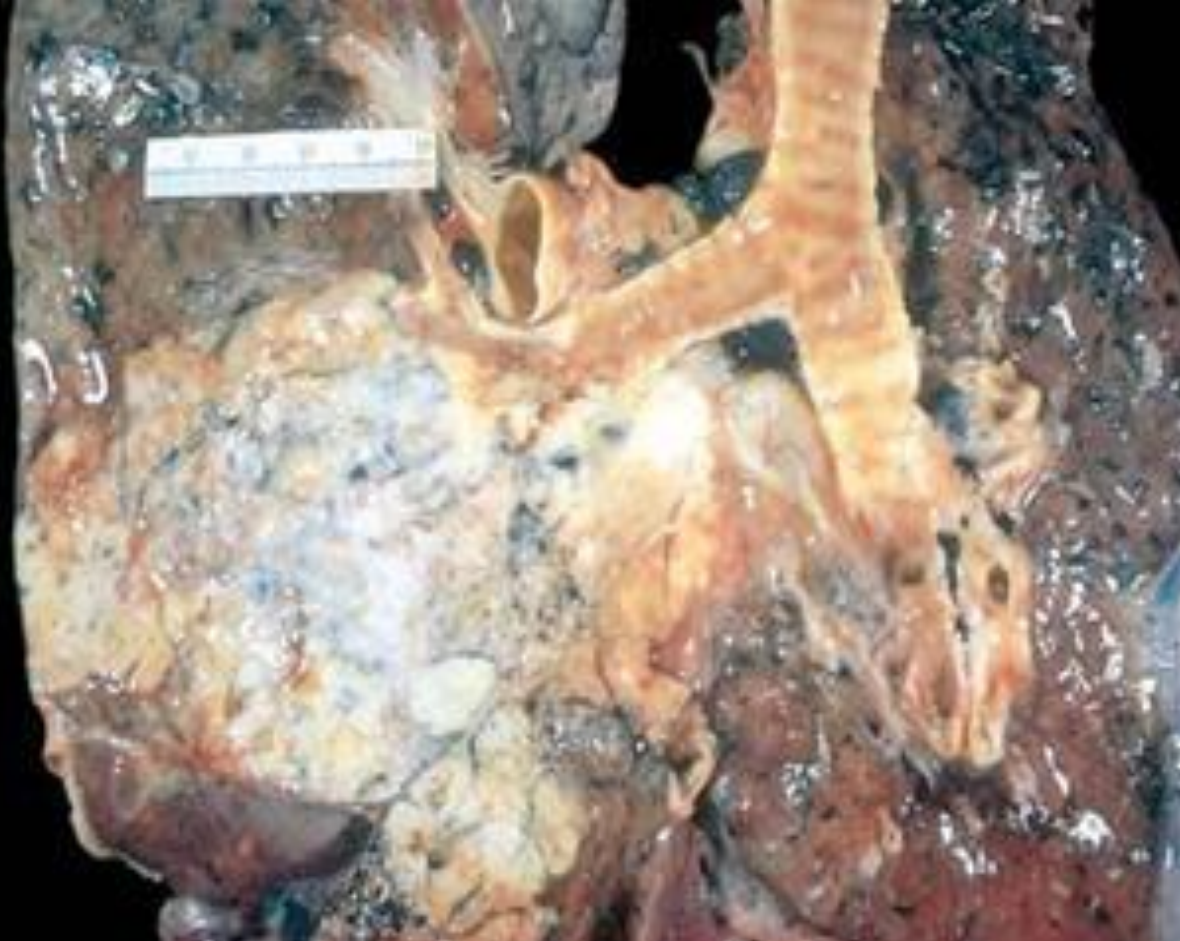- **NORMAL BRONCHIAL MUCOSA**
- **METAPLASTIC/DYSPLASTIC MUCOSA**
- **CARCINOMA-IN-SITU (squamous, adeno)**
- **INFILTRATING (i.e., “INVASIVE”) cancer**

TWO TYPES

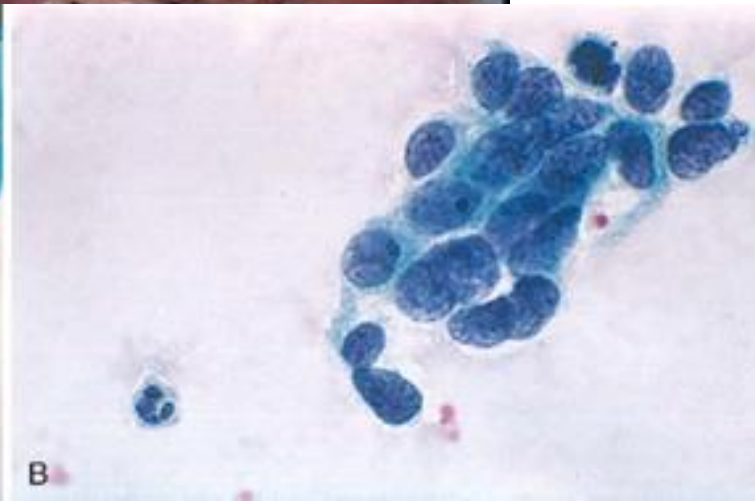
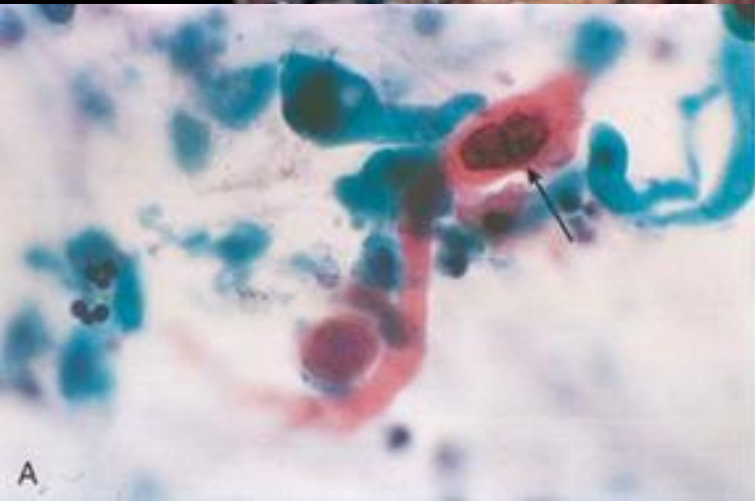
- **NON-SMALL CELL**
 - SQUAMOUS CELL CARCINOMA
 - ADENOCARCINOMA
 - LARGE CELL CARCINOMA
- **SMALL CELL CARCINOMA**

The BIG list

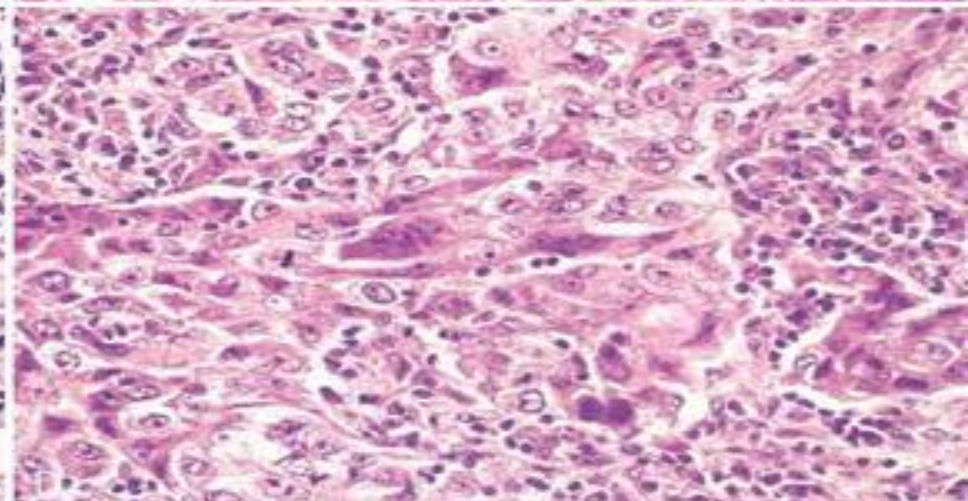
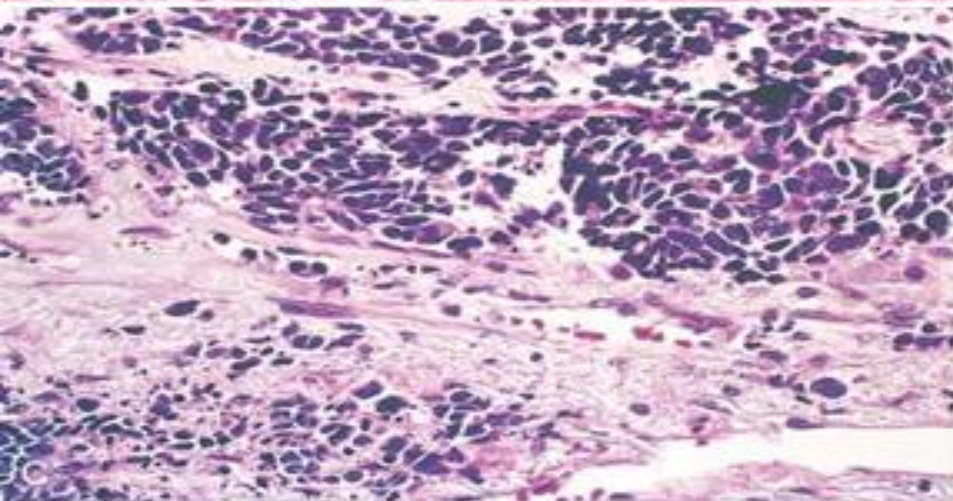
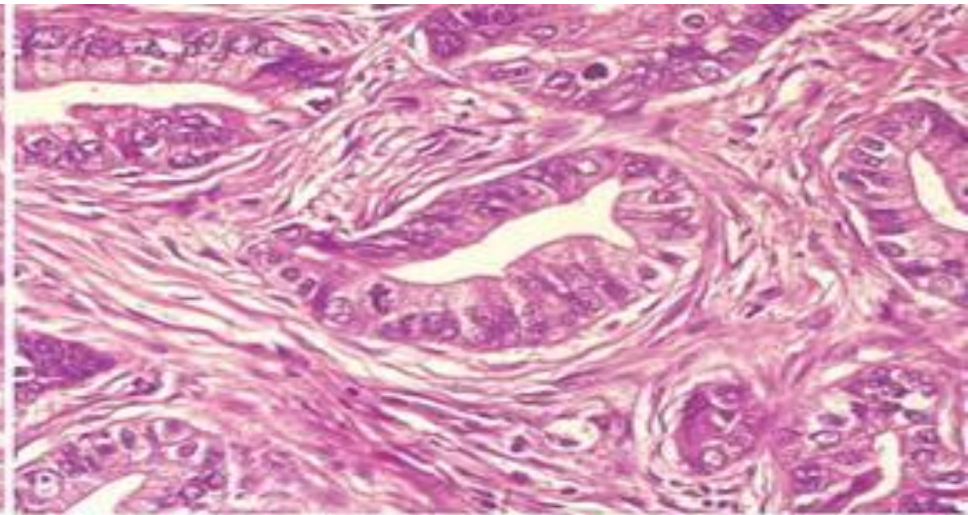
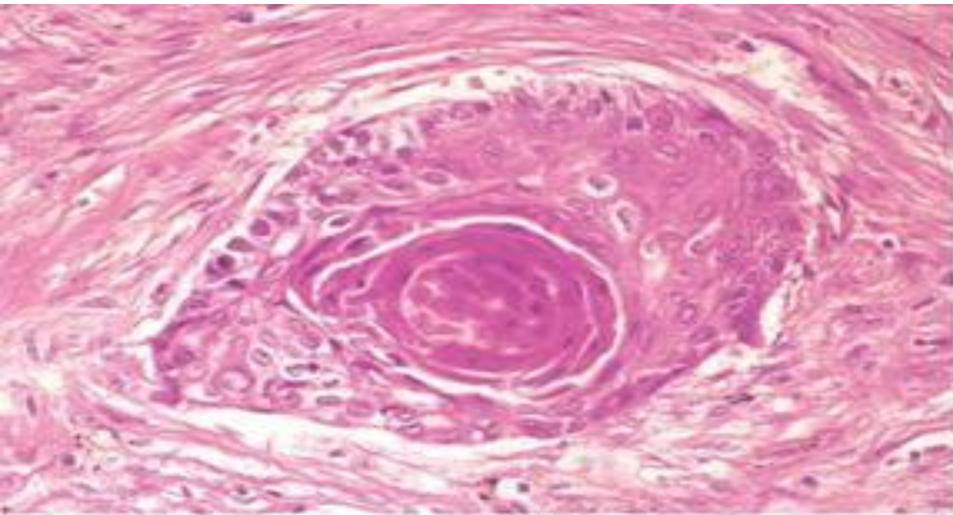
- **Squamous cell carcinoma**
- **Small cell carcinoma**
- **Combined small cell carcinoma**
- **Adenocarcinoma: Acinar, papillary, bronchioloalveolar, solid, mixed subtypes**
- **Large cell carcinoma**
- **Large cell neuroendocrine carcinoma**
- **Adenosquamous carcinoma**
- **Carcinomas with pleomorphic, sarcomatoid, or sarcomatous elements**
- **Carcinoid tumor: Typical, atypical**
- **Carcinomas of salivary gland type**
- **Unclassified carcinoma**



The classical squamous cell carcinoma starting in a large bronchus centrally, with bronchial obstruction. Adenocarcinomas tend to be more peripheral. Note the features of malignant cells on sputum cytology.



**Name the four most common histologic patterns of lung carcinoma and explain why!
Squamous, adeno, large, small.**



LOCAL effects of LUNG CANCER

Clinical Feature	Pathologic Basis
Pneumonia, abscess, lobar collapse	Tumor obstruction of airway
Lipid pneumonia	Tumor obstruction; accumulation of cellular lipid in foamy macrophages
Pleural effusion	Tumor spread into pleura
Hoarseness	Recurrent laryngeal nerve invasion
Dysphagia	Esophageal invasion
Diaphragm paralysis	Phrenic nerve invasion
Rib destruction	Chest wall invasion
SVC syndrome	SVC compression by tumor
Horner syndrome	Sympathetic ganglia invasion
Pericarditis, tamponade	Pericardial involvement
SVC, superior vena cava.	

METASTATIC TUMORS

- **LUNG** is the **MOST COMMON** site for all metastatic tumors, regardless of site of origin
- It is the site of **FIRST CHOICE** for metastatic sarcomas for purely anatomic reasons!

PLEURA

- **PLEURITIS**
- **PNEUMOTHORAX**
- **EFFUSIONS**
 - **HYDROTHORAX**
 - **HEMOTHORAX**
 - **CHYLOTHORAX**
- **MESOTHELIOMAS**

PLEURITIS

- **Usual bacteria, viruses, etc.**
- **Infarcts**
- **Lung abscesses, empyema**
- **TB**
- **“Collagen” diseases, e.g., RA, SLE**
- **Uremia**
- **Metastatic**

PNEUMOTHORAX

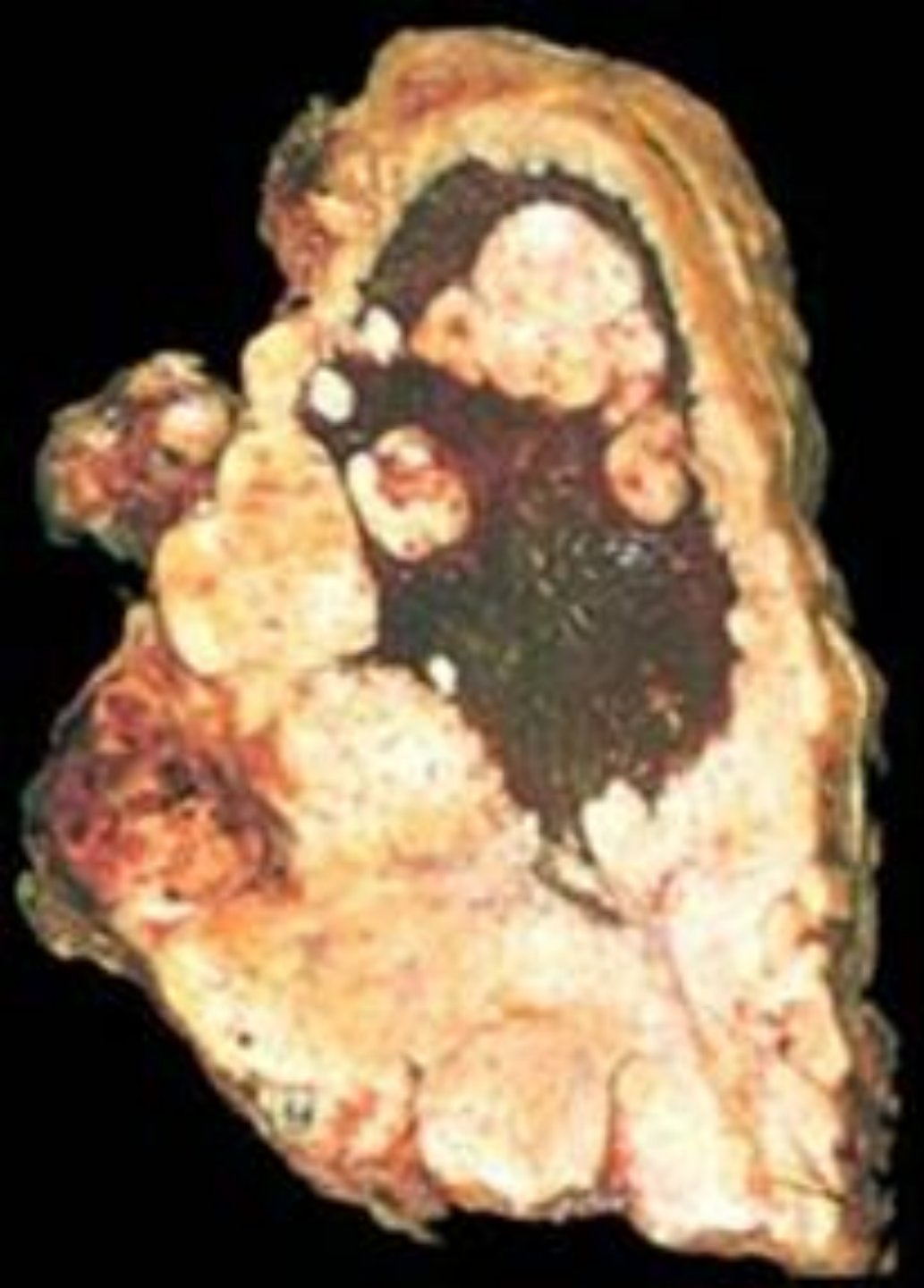- **SPONTANEOUS, TRAUMATIC, THERAPEUTIC**
- **OPEN or CLOSED**
- **“TENSION” pneumothorax, “valvular” effect**
- **“Bleb” rupture**
- **Perforating injuries**
- **Post needle biopsy**

EFFUSIONS

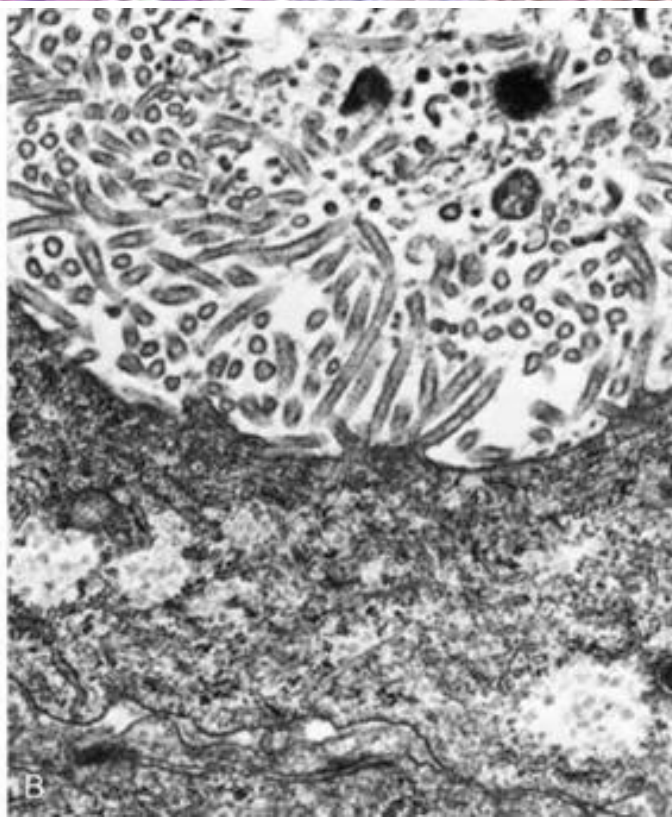
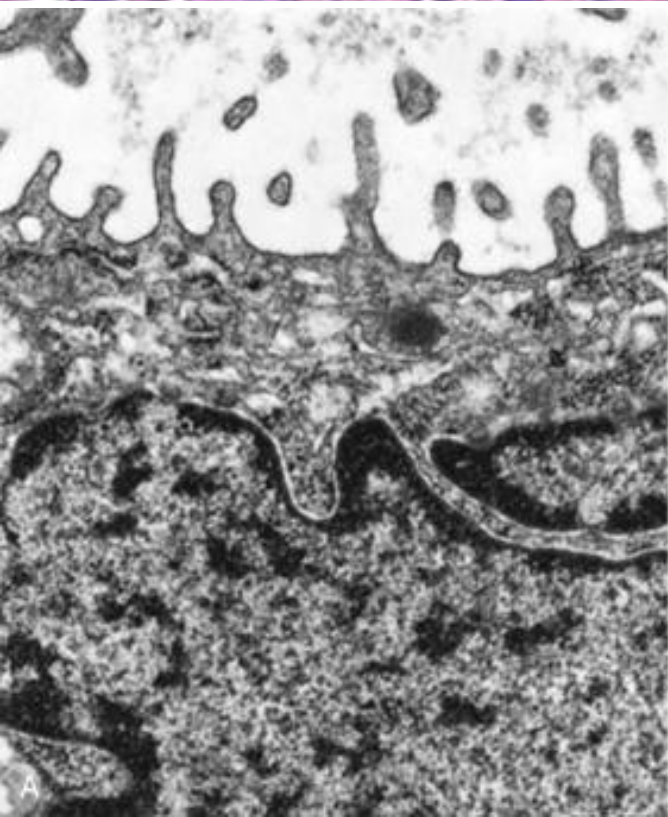
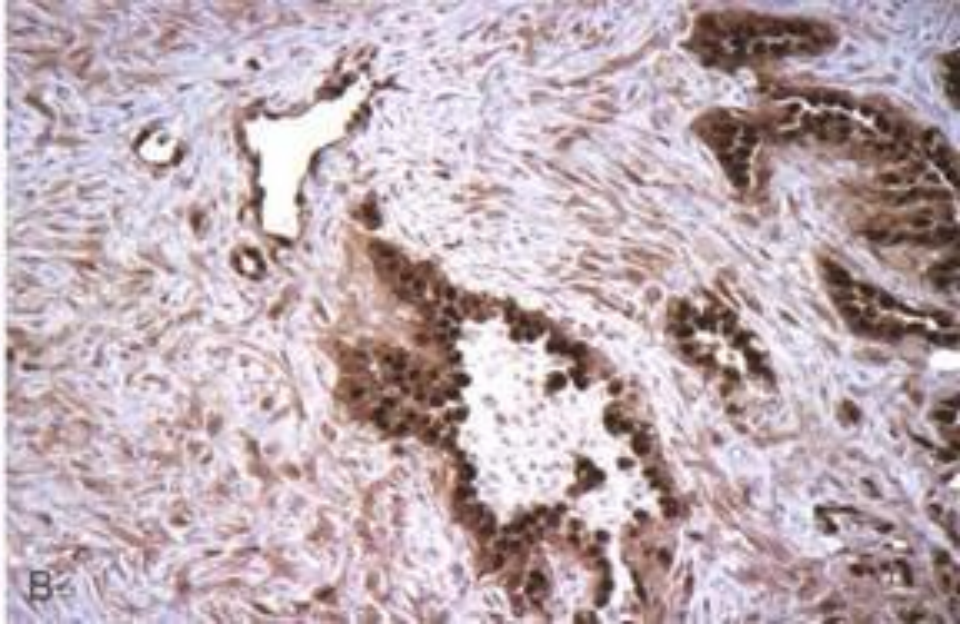
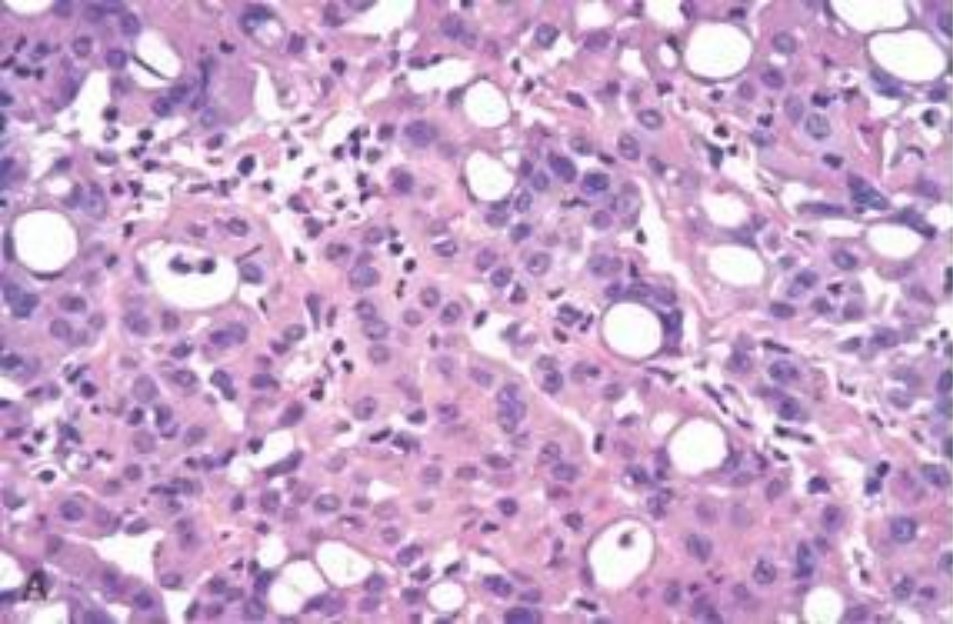
- **TRANSUDATE (HYDROTHORAX)**
- **EXUDATE (HYDROTHORAX)**
- **BLOOD (HEMOTHORAX)**
- **LYMPH (CHYLOTHORAX)**

MESOTHELIOMAS

- **“Benign” vs. “Malignant” differentiation does not matter, but a self limited localized nodule can be regarded as benign, and a spreading tumor can be regarded as malignant**
- **Visceral or parietal pleura, pericardium, or peritoneum**
- **Most are regarded as asbestos caused or asbestos “related”**



Typical growth appearance of a malignant mesothelioma, it compresses the lung from the **OUTSIDE**.



H&E,
IMMUNOCHEMISTRY

← EM