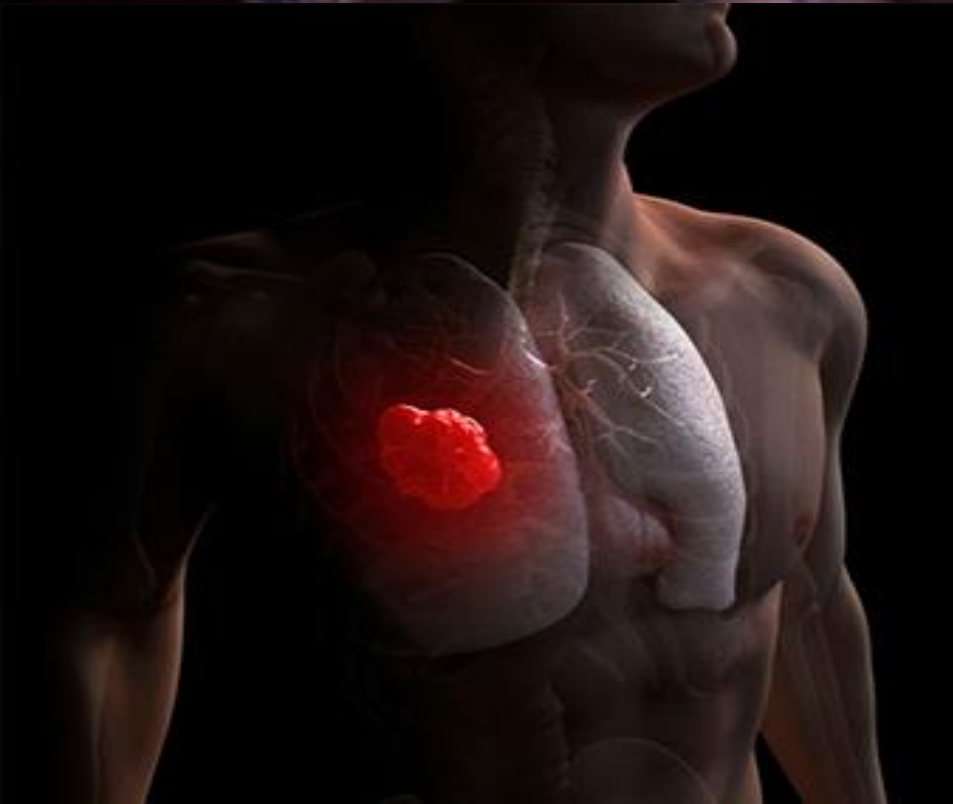



**Chronic pulmonary
pathology.
Lung cancer.**

Chronic pulmonary pathology. Lung cancer.

I. Microspecimens:

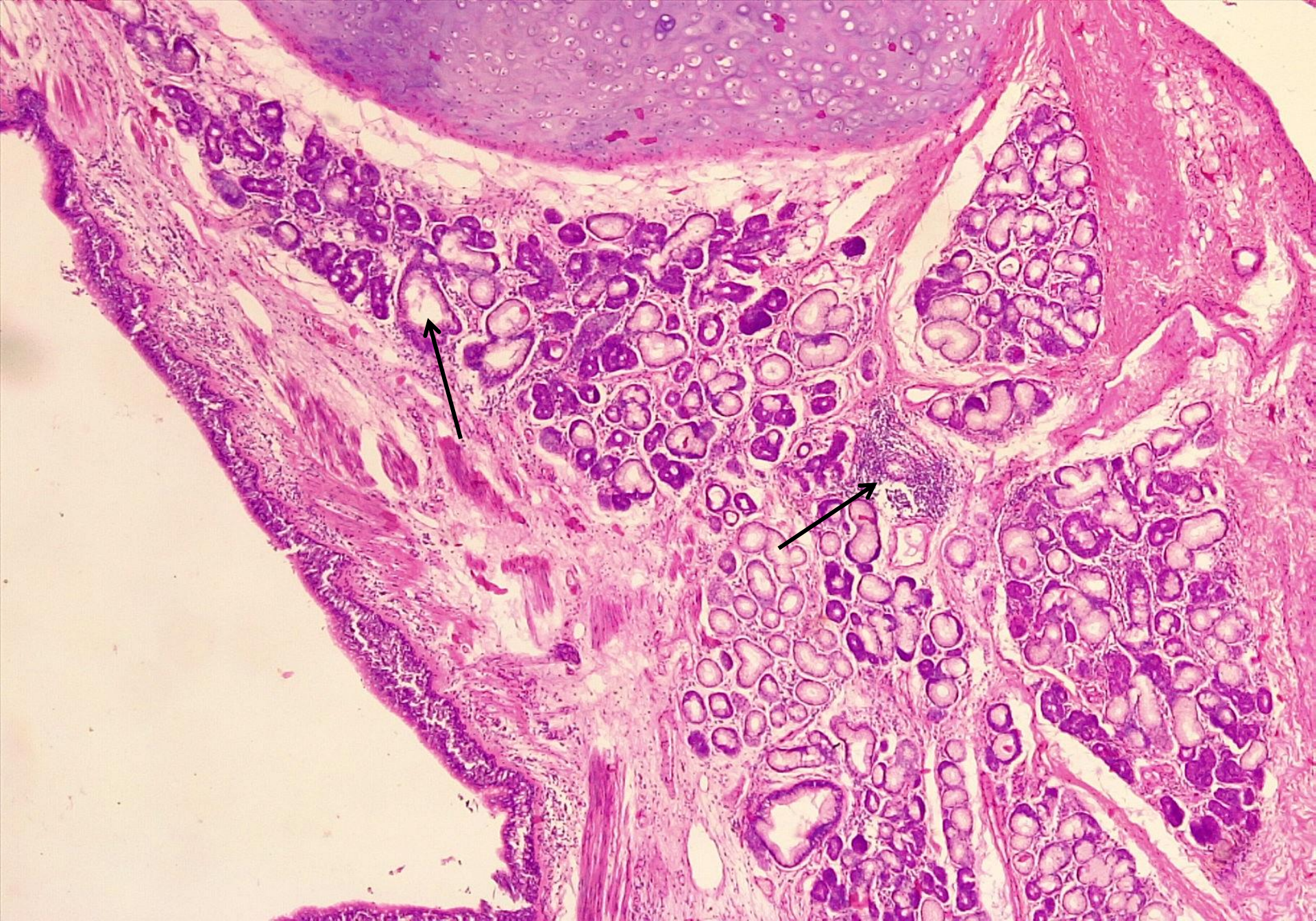
№ 211. Chronic bronchitis. (*H-E stain*).

Indications:

1. Inflammatory infiltrate into the bronchial wall.
2. Hyperemic, dilated vessels.

The bronchial wall is thickened, there are foci of chronic inflammatory infiltration, predominantly lymphocytic, hyperplasia of the superficial epithelium and submucosal glands, some glands are cystic dilated.

The most common causes of chronic bronchitis are smoking and other air pollutants (smog), as well as various infectious agents. Morphological variants: serous cathar, purulent cathar, polypous and deforming bronchitis. Chronic inflammation leads to goblet cell hyperplasia, hyperplasia of muco-secretory glands, hypersecretion of mucus, wall thickening, fibrosis, which is more pronounced in the submucosal layer and squamous metaplasia of the bronchial epithelium. These lesions lead to impaired bronchial drainage function. It can be complicated by obstructive emphysema, bronchiectasis, peribronchial pneumosclerosis. Squamous metaplasia is a precancerous process, which precedes the development of squamous cell lung carcinoma.



№ 211. Chronic bronchitis. (*H-E stain*).

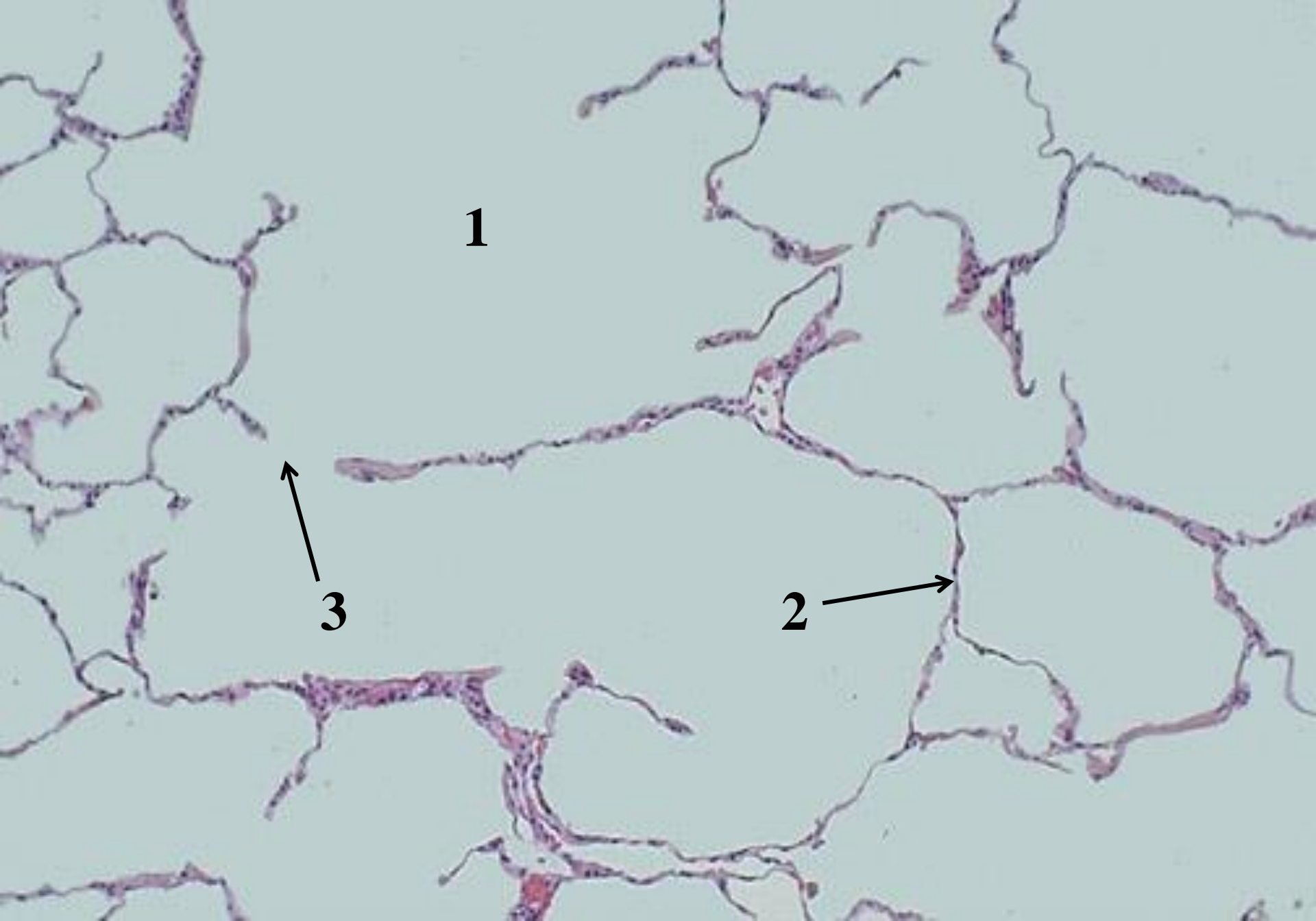
№ 75. Pulmonary emphysema. (H-E stain).

Indications:

1. Large air cavities.
2. Thinned interalveolar septa
3. Ruptures of interalveolar septa.
4. Sclerosis and reduction of blood capillaries.

The alveoli are dilated, the interalveolar septa are thin, in some places broken, some alveoli confluence, forming wide air spaces, in which the ends of the ruptured septa are observed, the number of septal capillaries is reduced.

Emphysema is a chronic obstructive disease, characterized by excessive air content in the lungs and increasing their size. There is a permanent widening of the air spaces, located distal to the terminal bronchioles. The most common form is chronic diffuse obstructive emphysema, caused by chronic bronchitis, primarily by chronic bronchitis of the smoker. In diffuse obstructive emphysema the thoracic cavity is dilated, deformed, acquires a "barrel" appearance. Depending on the distribution of the lesions within the lung lobes, there are 2 main types of emphysema: centroacinar (centrolobular) and panacinar (panlobular). In centroacinar emphysema the respiratory bronchioles are affected, they dilate but the distal alveoli are normal. It is more common in the upper lobes of the lungs. In panacinar emphysema the acini are uniformly enlarged from the respiratory bronchiole to the terminal alveoli. It is located more frequently in the lower lobes. The destruction of the walls of the bronchioles and alveoli is not accompanied by fibrosis. These lesions of the lung parenchyma lead to reduced gas diffusion capacity and respiratory failure. In addition to the destruction of the alveoli, the number of septal capillaries is also reduced, alveolo-capillary block appears, which leads to the development of hypertension in the small circulation and hypertrophy of the right ventricle of the heart (cor pulmonary).



№ 75. Pulmonary emphysema. (*H-E stain*).

№ 50. Pulmonary nonkeratinizing squamous cell carcinoma. (*H-E stain*).

Indications:

1. Squamous metaplasia of the bronchial epithelium.
2. Nests of atypical polymorphic tumoral cells.

In the microspecimen a bronchus is present, in the epithelium of which foci of squamous metaplasia are observed. In the bronchial wall, around the cartilage and in the surrounding alveolar tissue, which is compact, unventilated, there are nests of different sizes of tumor cells with squamous cell appearance, polymorphic, hyperchromic nuclei, mitosis figures.

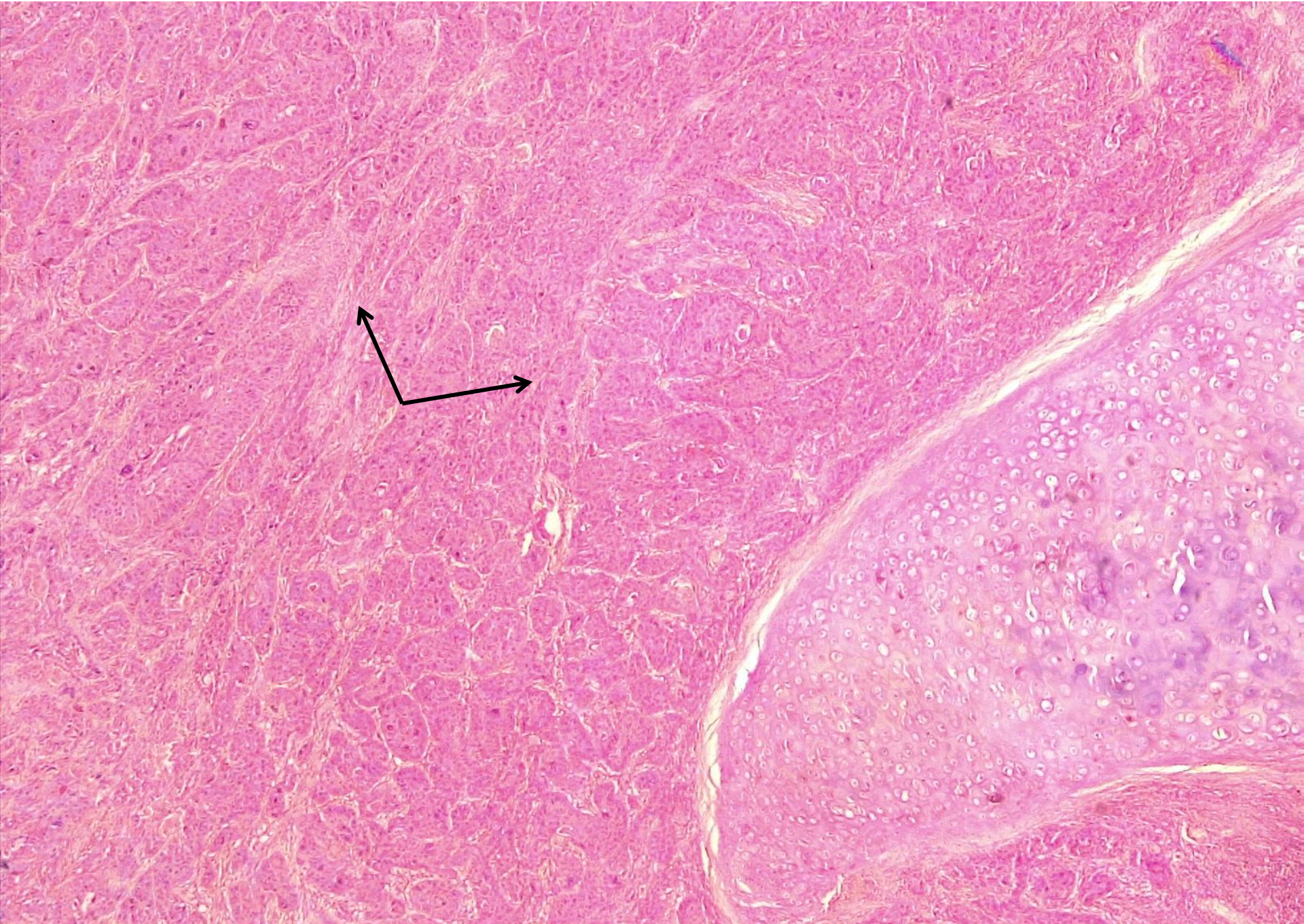
Squamous cell carcinoma develops from the epithelium of the mucosa of the main bronchi (central or parahilar carcinoma), being preceded by metaplasia and squamous dysplasia of the bronchial epithelium. It is more common in men and is associated with smoking. Keratin pearls are missing in non-keratinized squamous cell cancer. [microspecimen № 39].

№ 51. Metastases of undifferentiated lung carcinoma into the heart. (*H-E stain*).

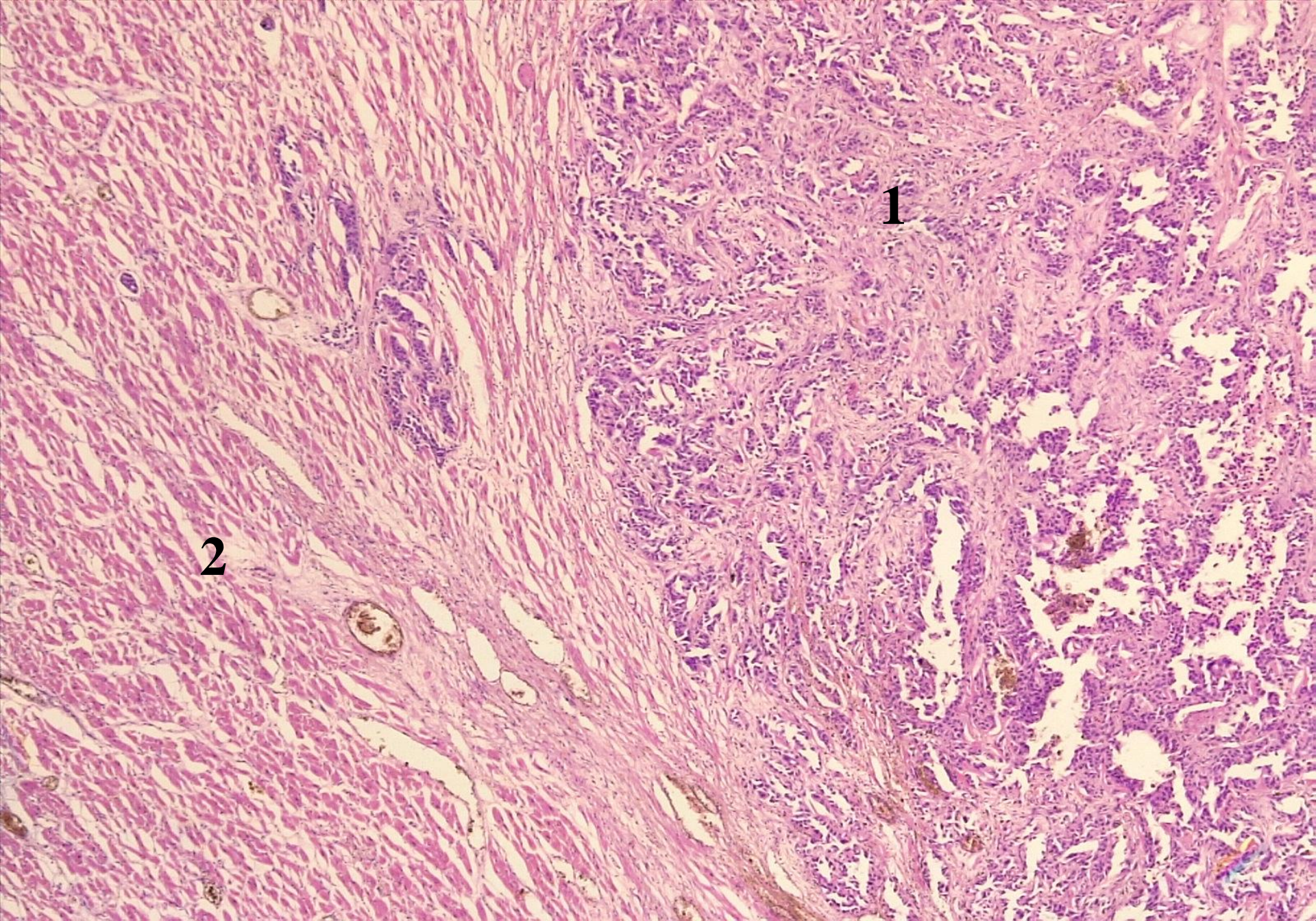
Indications:

1. Metastatic tumoral nodule.
2. Undifferentiated cancer cells.
3. Adjacent myocardium.

In the microspecimen, with the naked eye can be observed blue-purple foci, at the small objective that foci are consisting of monomorphic undifferentiated cancer cells, arranged in nests separated by connective tissue bundles, in the adjacent myocardium there is hyperemia of vessels, vascular cell emboli.



№ 50. Pulmonary nonkeratinizing squamous cell carcinoma. (*H-E stain*).



№ 51. Metastases of undifferentiated lung carcinoma into the heart. (*H-E stain*).

II. Macrospecimens:

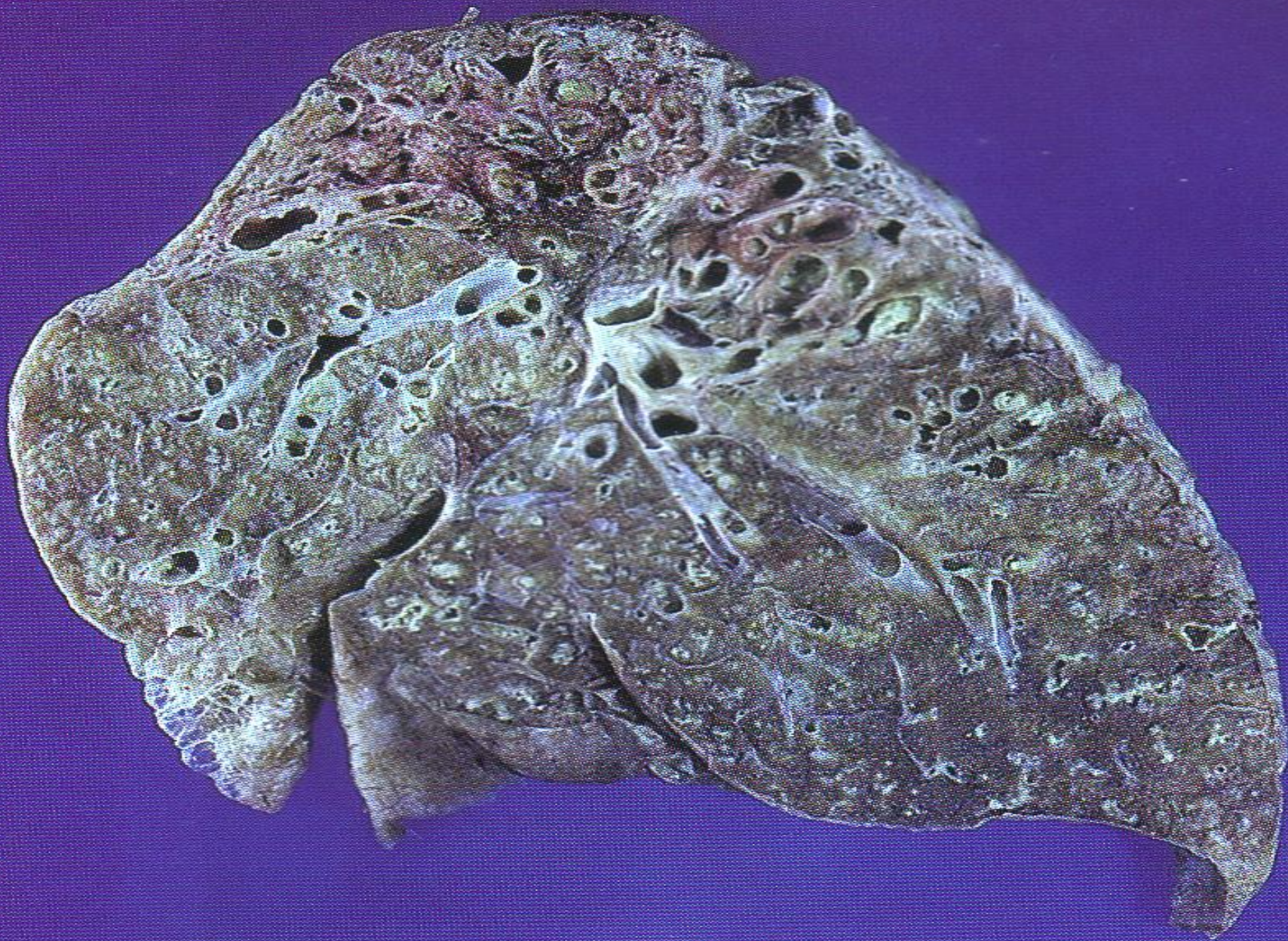
№ 35. Bronchiectases with pulmonary fibrosis.

On the section of the lung, multiple dilations and deformations of the bronchi are observed, of irregular shape, the walls are thickened, sclerosed, the surrounding lung tissue is poorly aerated, sclerosed, has a whitish color.

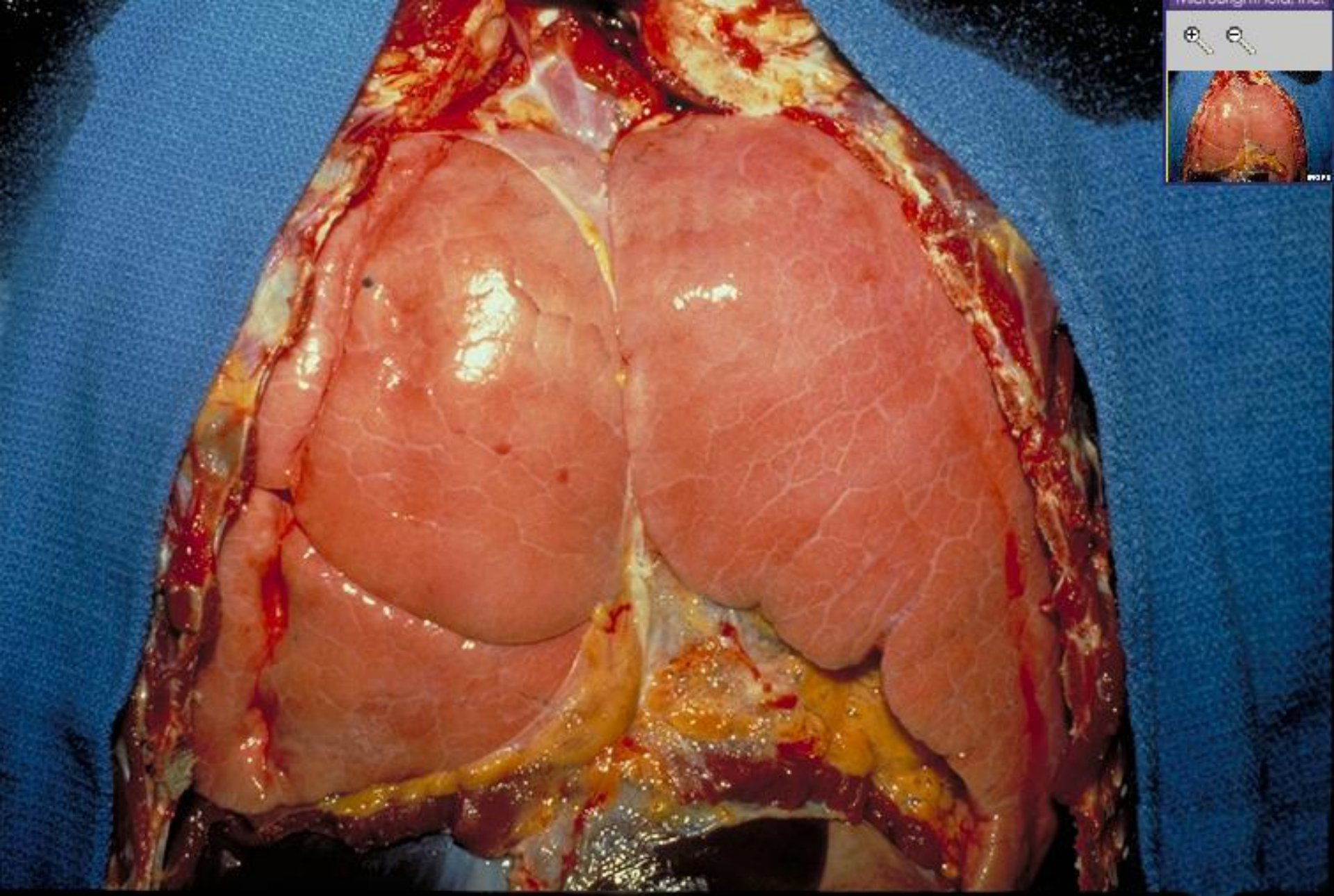
Bronchiectases is permanent dilation of the bronchi and bronchioles, caused by chronic bronchitis. Morphologically, they can be cylindrical and sacular bronchiectasis (sacciform). The wall of bronchiectasis is thickened, sclerosed, with chronic inflammatory infiltration, the lumen usually contains purulent exudate. They can be complicated by hypertension of the small circulation and hypertrophy of the right ventricle of the heart, hemorrhages, peribronchial sclerosis, lung abscess, amyloidosis, are a precancerous condition.

№ 36. Pulmonary emphysema.

The lung is enlarged in volume, over-aerated, on the surface with subpleural bullous formations, with thin walls, filled with air, on a section with a puffy, porous appearance, gray color.
[microspecimen № 75]



№ 35. Bronchiectases with pulmonary fibrosis.

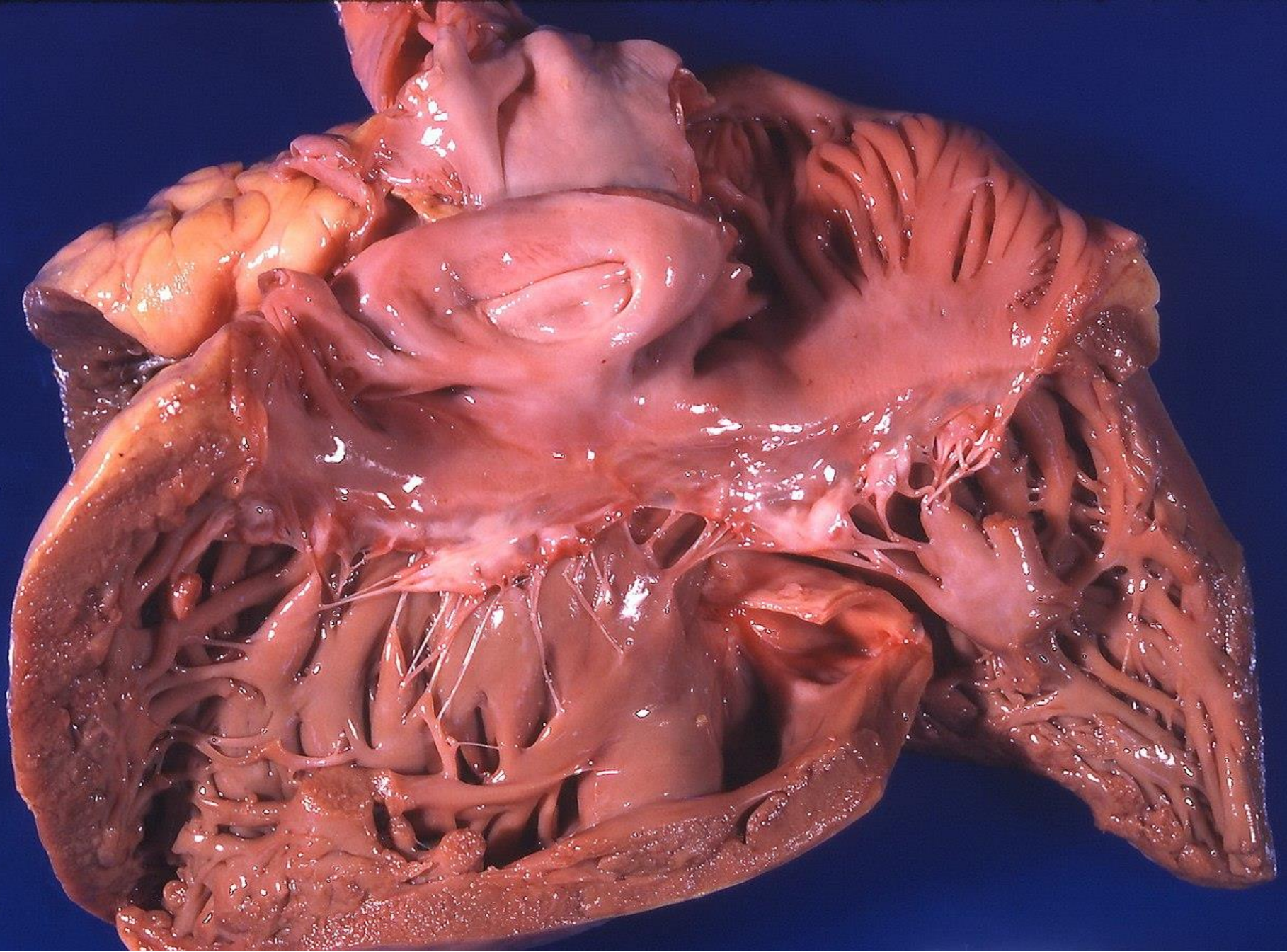


№ 36. Pulmonary emphysema.

№ 5. Right ventricular hypertrophy (cor pulmonale).

The wall of the right ventricle is thickened, has a thickness of up to 1-1.5 cm (norm 2-3 mm) of dense-elastic consistency.

Right ventricular hypertrophy develops as a result of long-term pulmonary hypertension, which is found in various chronic lung diseases, eg, pulmonary emphysema, bronchiectases, interstitial pneumonia, secondary pulmonary tuberculosis, pneumoconiosis (hence the name - cor pulmonale). Decompensation of the right heart is manifested by generalized peripheral edema and congestion of internal organs but pulmonary congestion is minimal. Right ventricular hypertrophy may be associated with left heart failure, more commonly in decompensated mitral valvulopathies, especially in mitral stenosis.



№ 5. Right ventricular hypertrophy (cor pulmonale).

№ 39. Bronchogenic carcinoma.

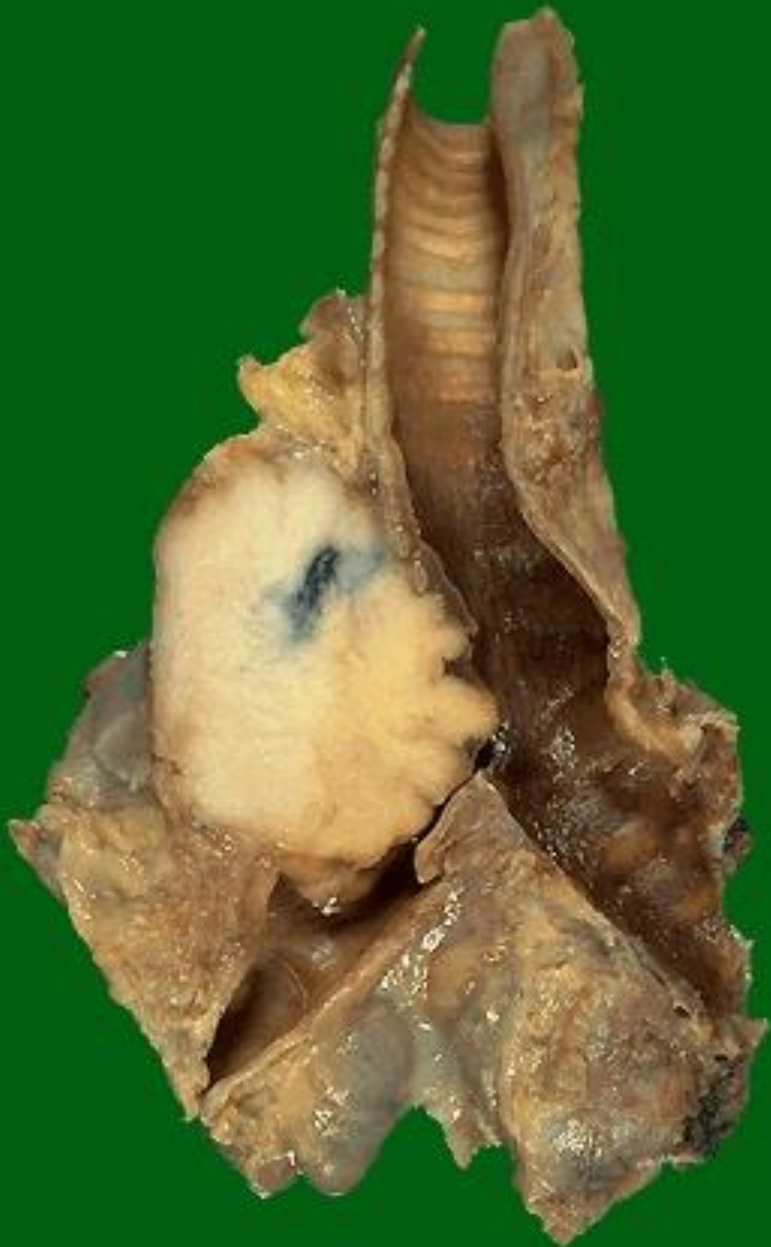In the main bronchus is a tumor node, size ~ 4-5 cm, which has exophytic type of growth with stenosing the lumen, has rough surface, of dense consistency, white-yellow color, tumor tissue infiltrates the adjacent peribronchial lung parenchyma.

It develops from the epithelium of the main bronchi and their branches, more often on the right. It is frequently complicated with atelectasis through obturation, hemorrhage, abscess, fibrino-hemorrhagic or purulent pleuritis. Infiltrative growth can occur in peribronchial lung tissue, contralateral bronchi and lungs, pleura, pericardium, and myocardium. Lymphogenic metastases occur in the mediastinal, cervical, supraclavicular, para-aortal lymph nodes, hematogenous metastases - in various organs, more commonly in the liver, adrenal glands, bones, pancreas, brain, etc. It usually occurs on the background of chronic bronchitis, especially in smokers' bronchitis, bronchiectases, chronic abscess, pneumoconiosis. The most common histological form is keratinizing or non-keratinizing squamous cell carcinoma, preceded by squamous metaplasia of the respiratory epithelium. [microspecimen № 50]

№ 40. Peripheral pulmonary carcinoma.

On the section of the lung under the pleura, there is an accurately delimited tumor node, with a diameter of up to 10 cm of white-gray color and dense consistency.

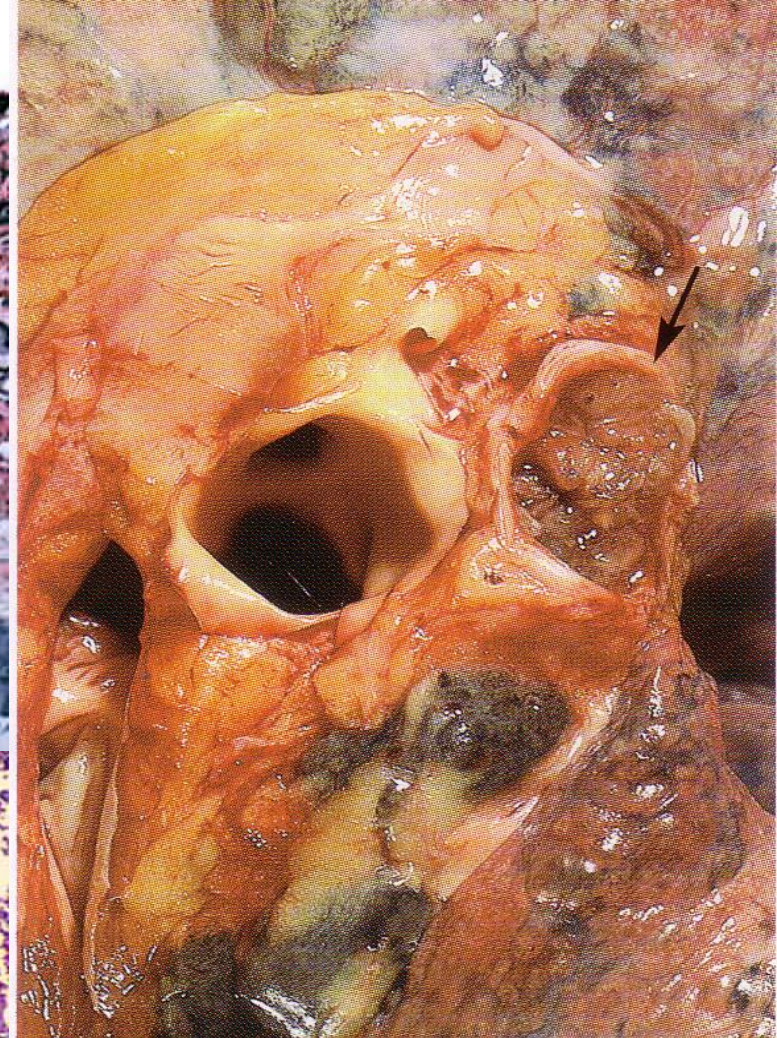
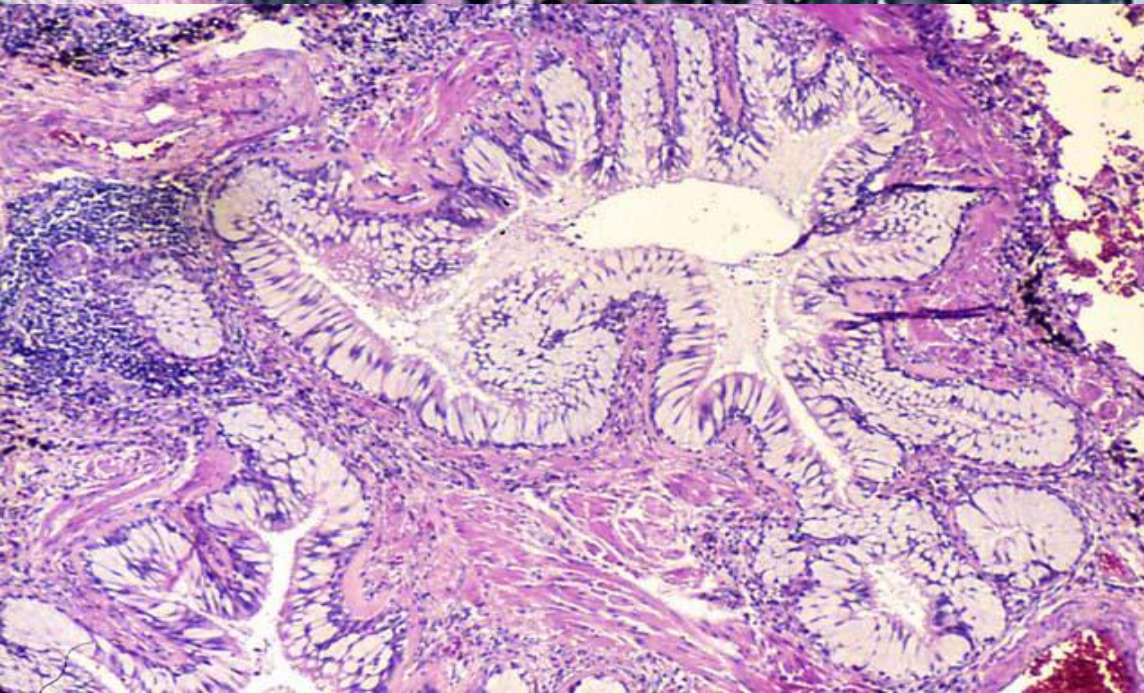
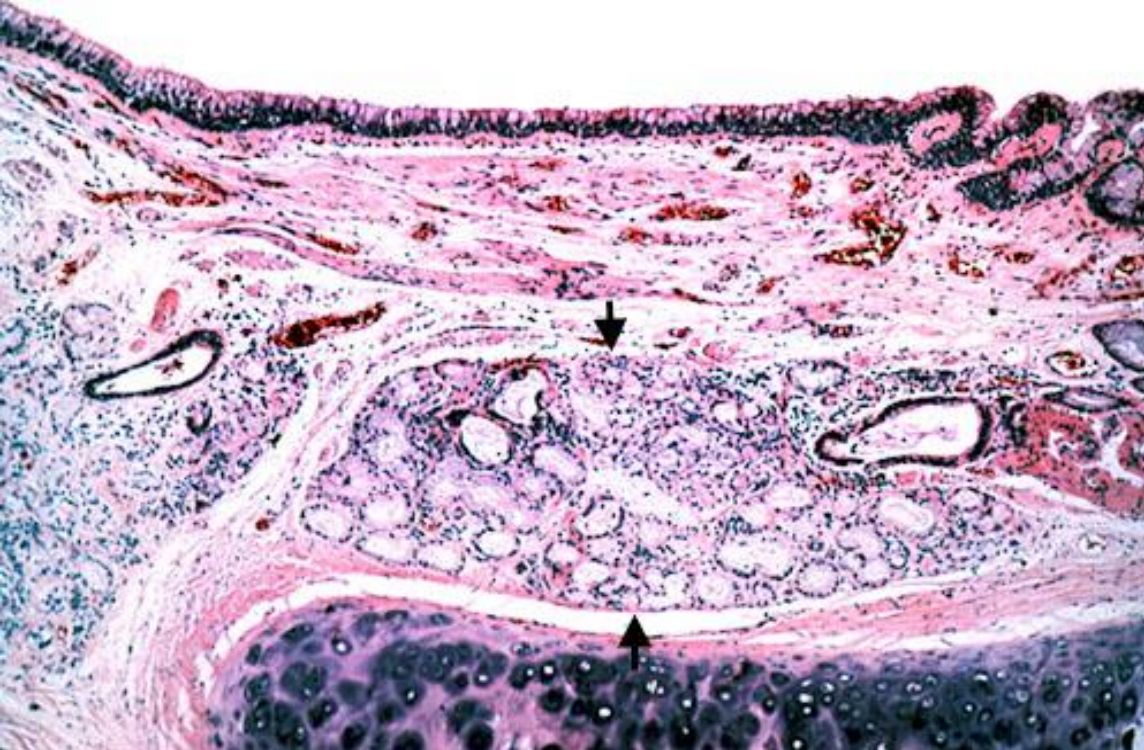
Peripheral lung carcinoma develops from the epithelium of the distal ramification of segmentary bronchus, bronchiolar and alveolar epithelium. It is located subpleural, can reach large sizes, often in the center is a scar (healed foci of tuberculosis, infarcts or scarred abscesses, foci of organization in pneumonia). It is the most common form of pulmonary carcinoma in women and non-smokers. Histologically, it is usually an adenocarcinoma. It can infiltrate the pleura, the surrounding lung tissue. Sero-hemorrhagic or hemorrhagic exudate appears in the pleural cavity. It metastasizes predominantly hematogenously in various organs: liver, adrenal glands, bones, pancreas, brain, kidneys, thyroid gland.



№ 39. Bronchogenic carcinoma.



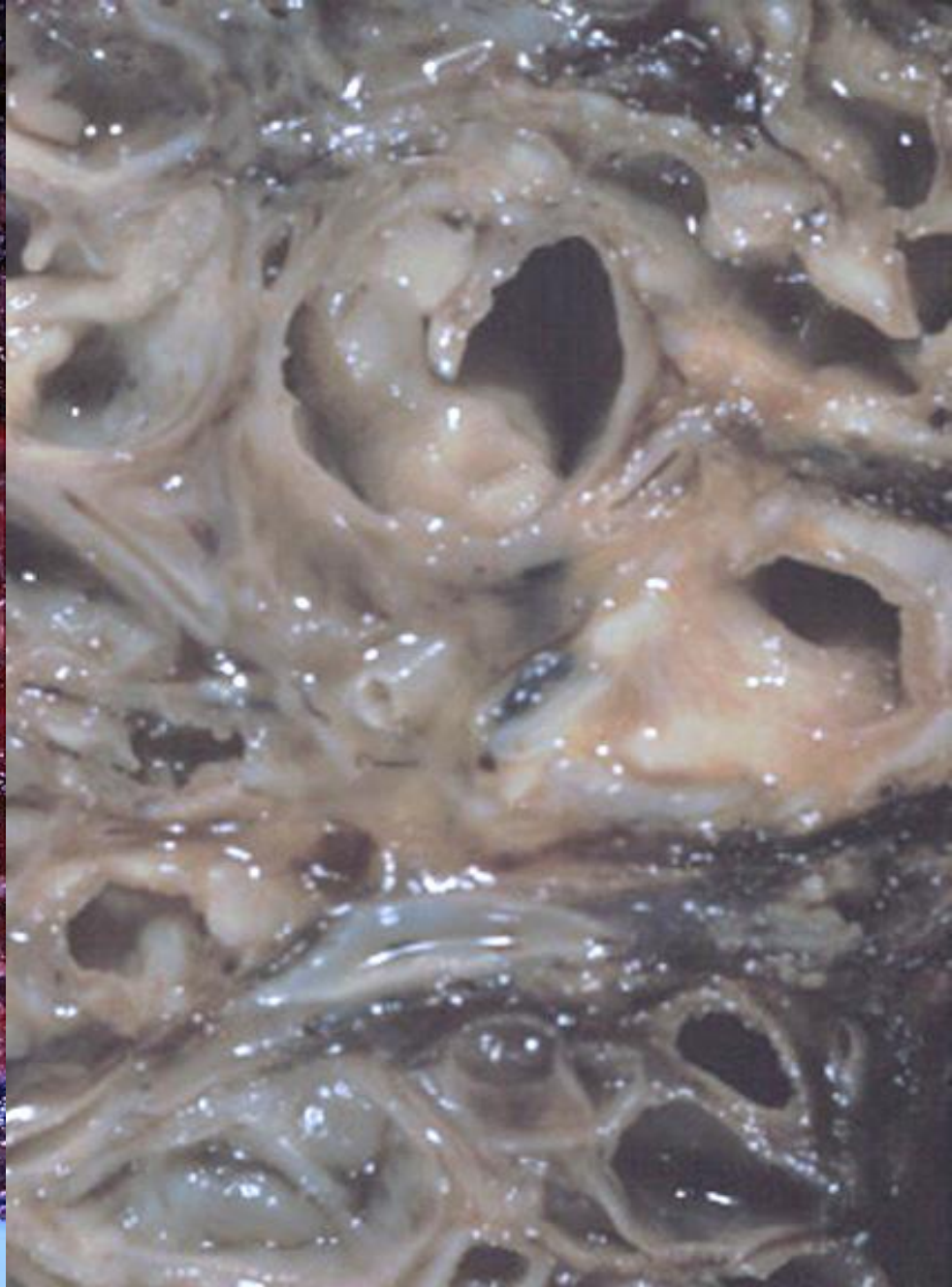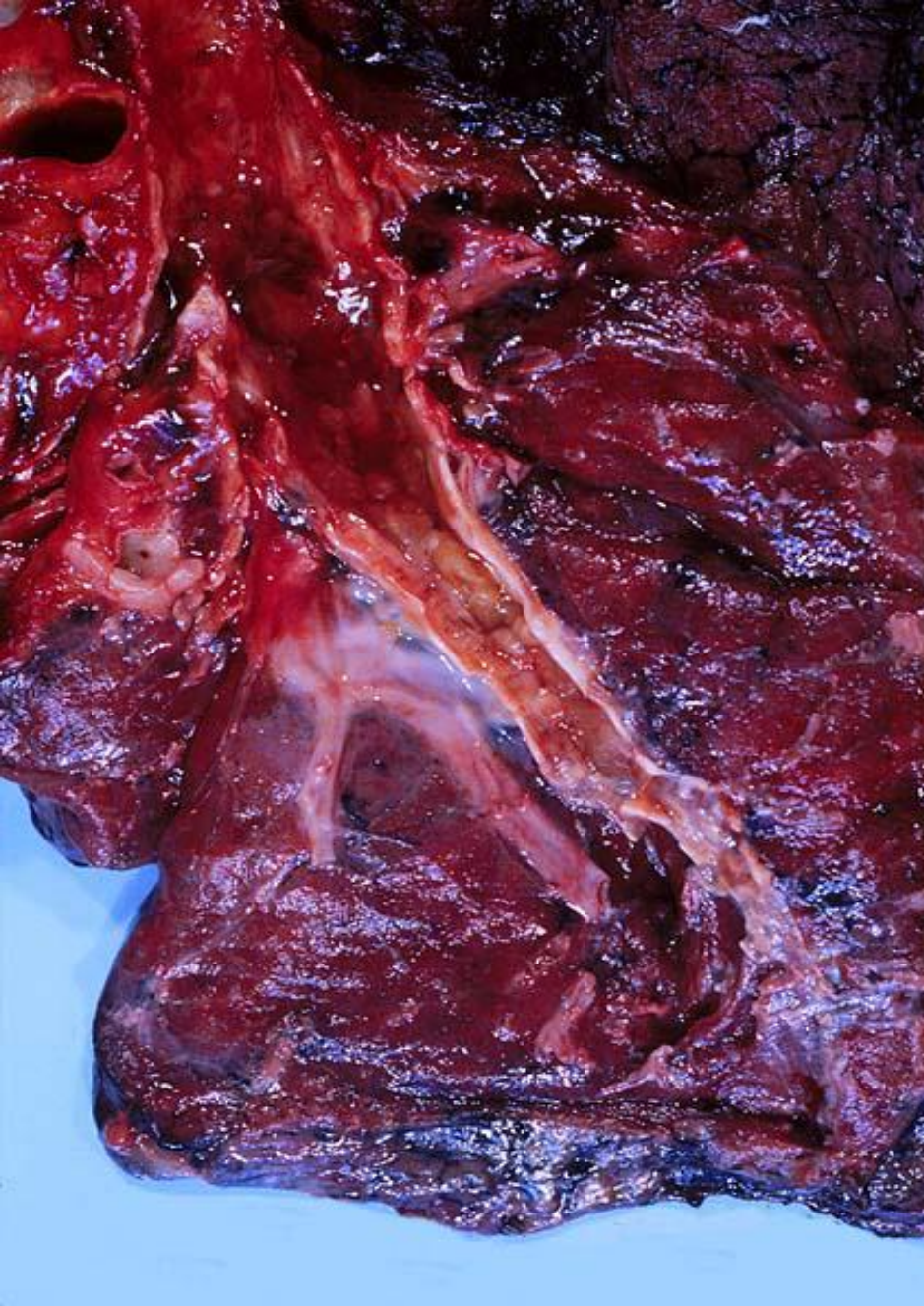№ 40. Peripheral pulmonary carcinoma.



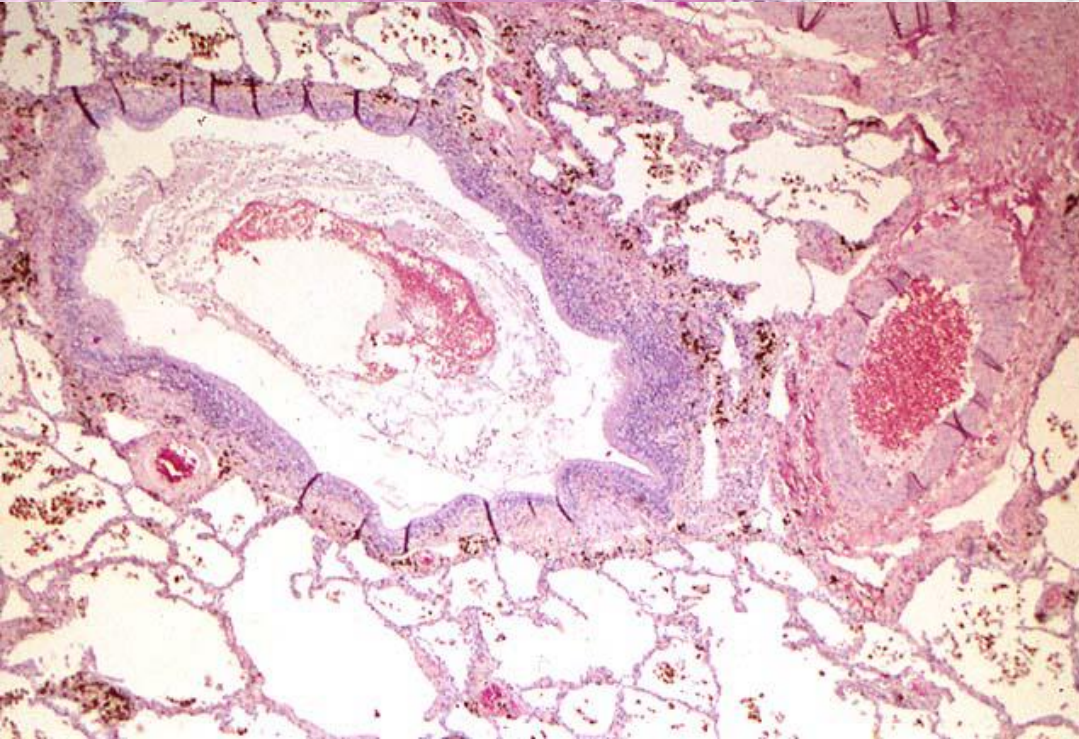
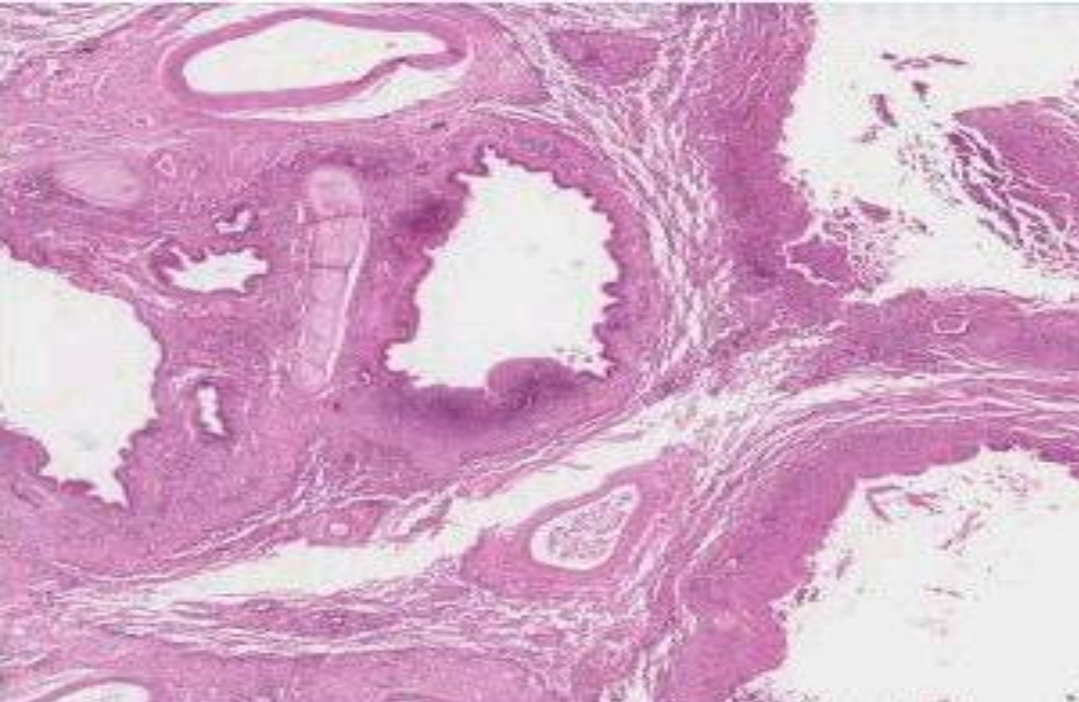
Chronic bronchitis:

**a) - inflammatory infiltration,
hyperplasia of the submucosal
glands, myocyte hypertrophy;**

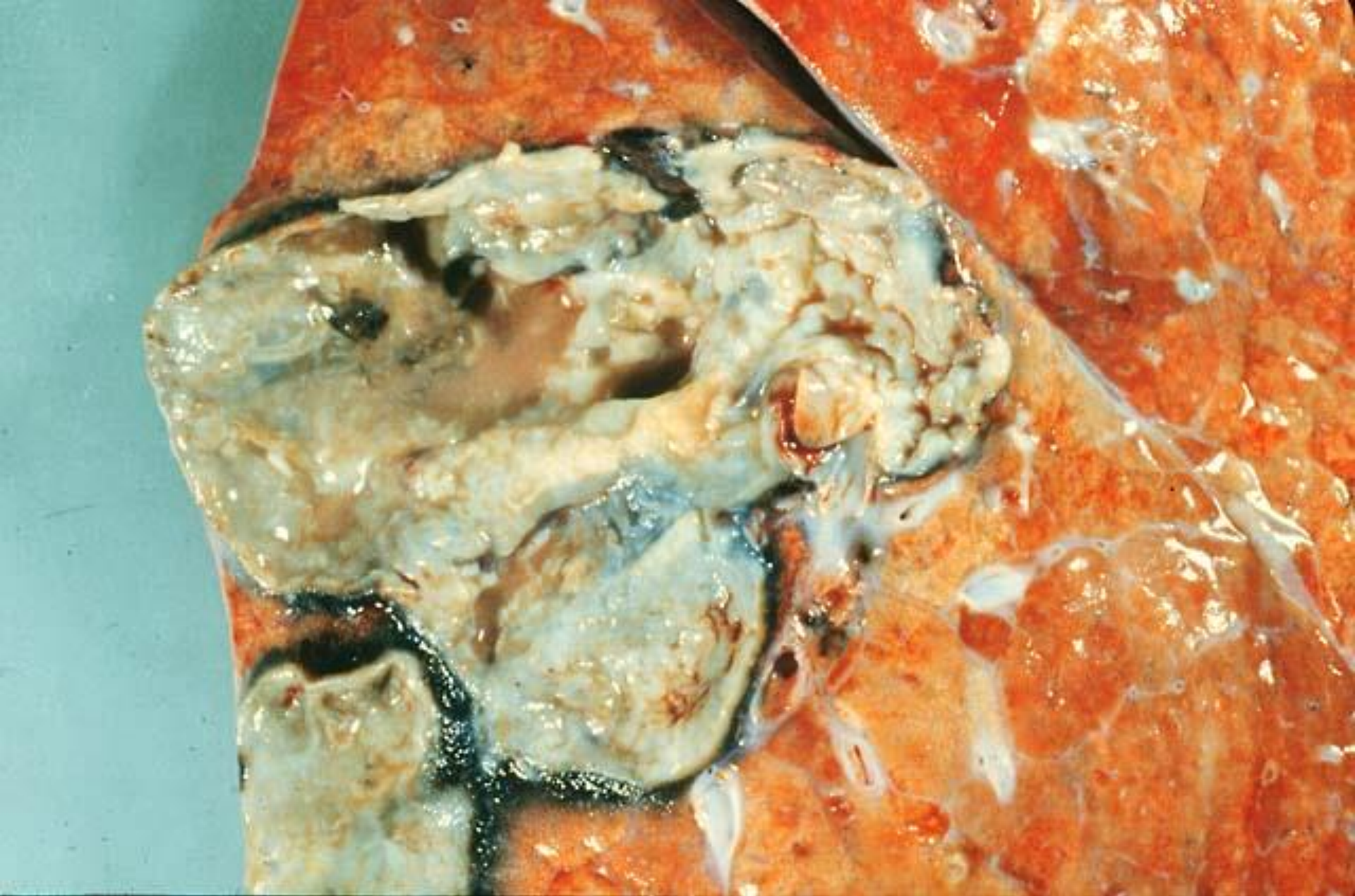**b) - mucosecreting cell hyperplasia
(H-E).**



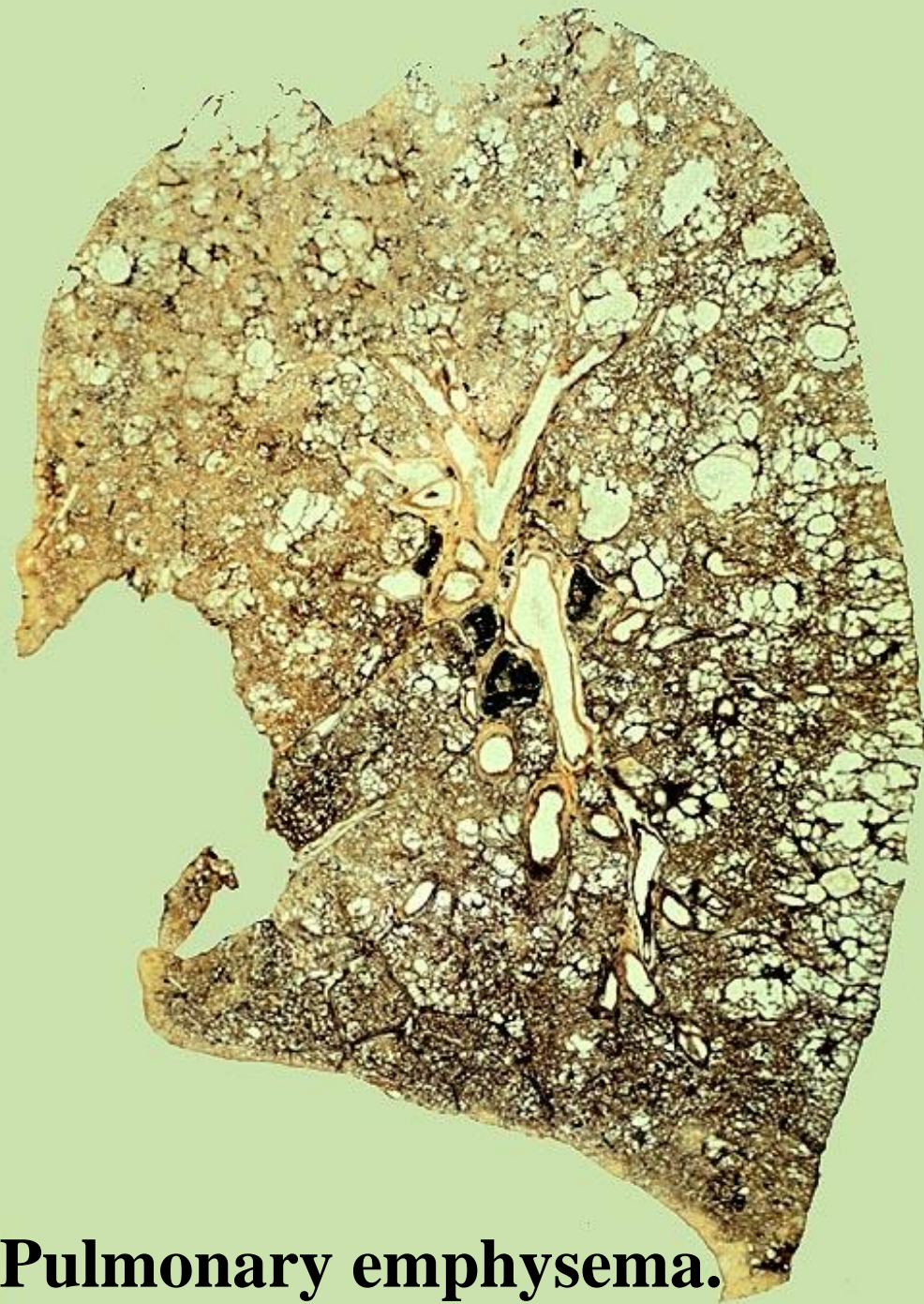Cylindrical and sacular bronchiectasis.



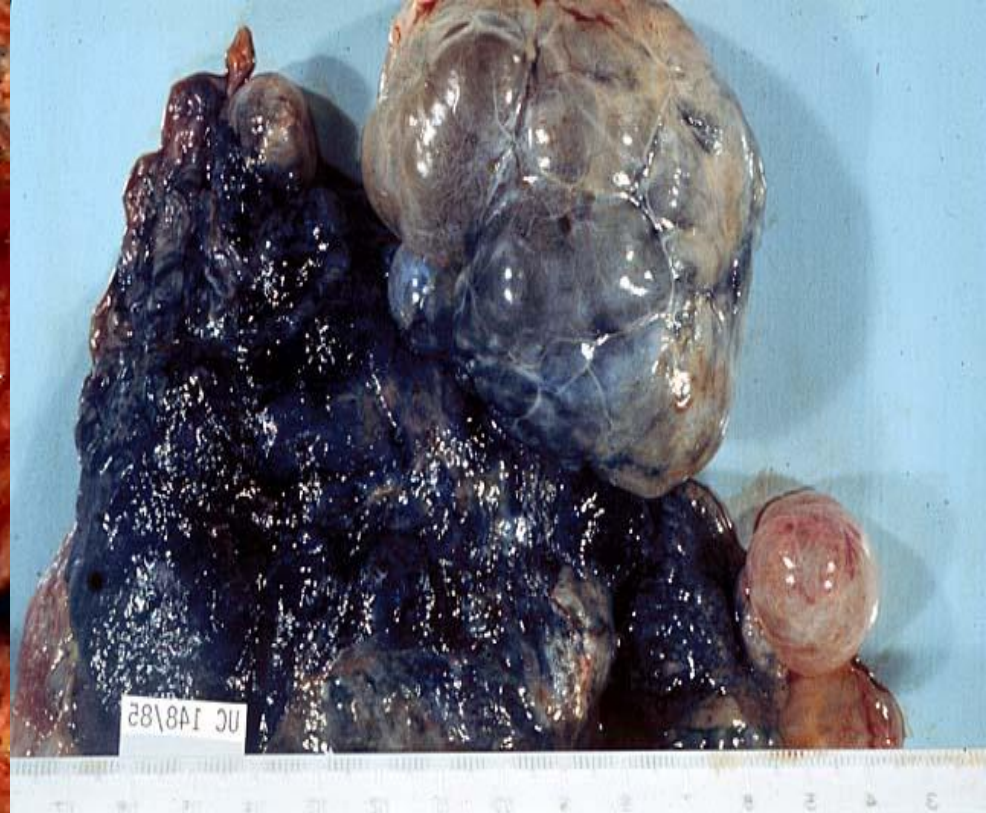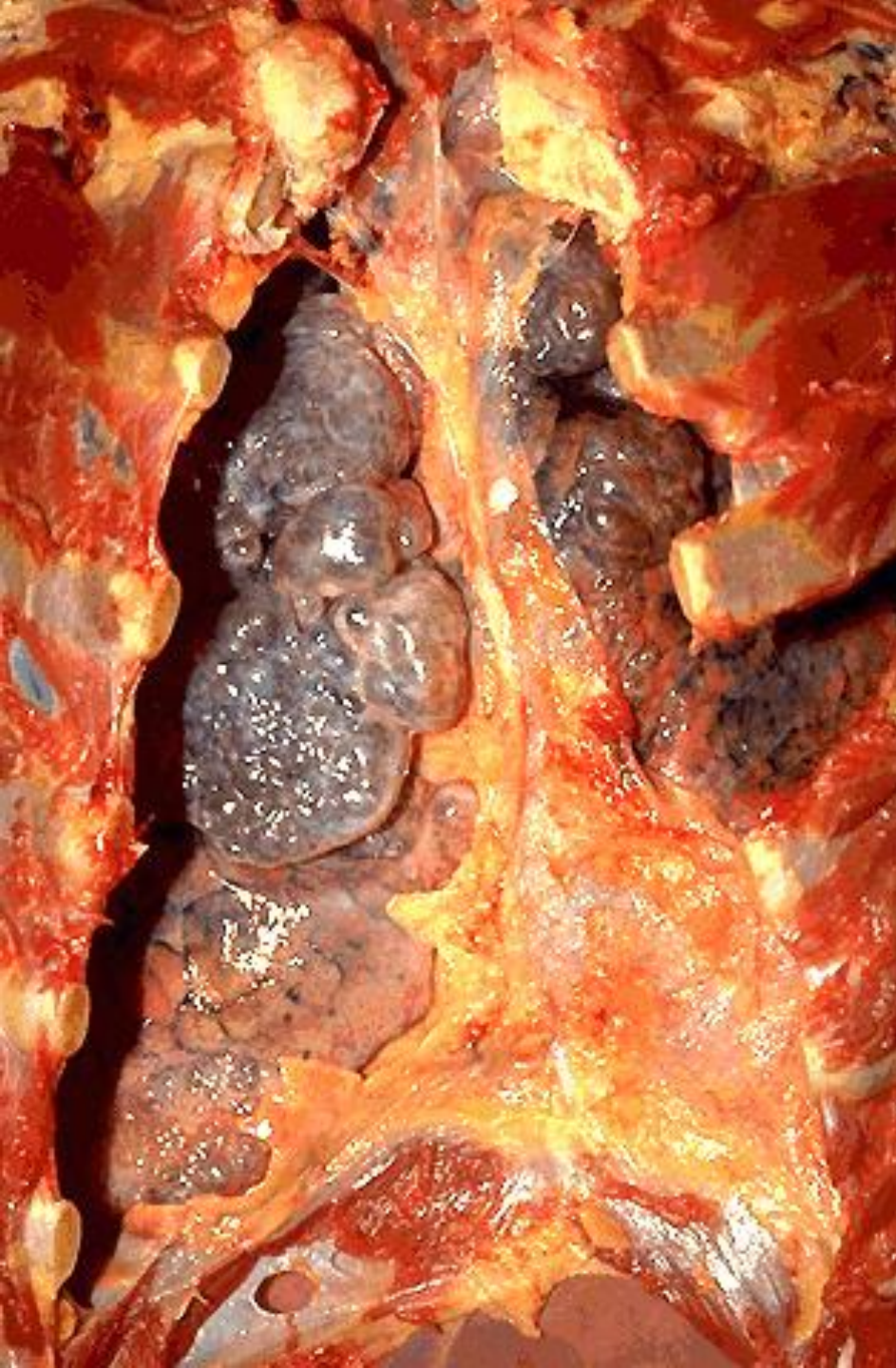a – Bronchiectases (H-E stain).
b - Bronchioloectases (H-E stain).



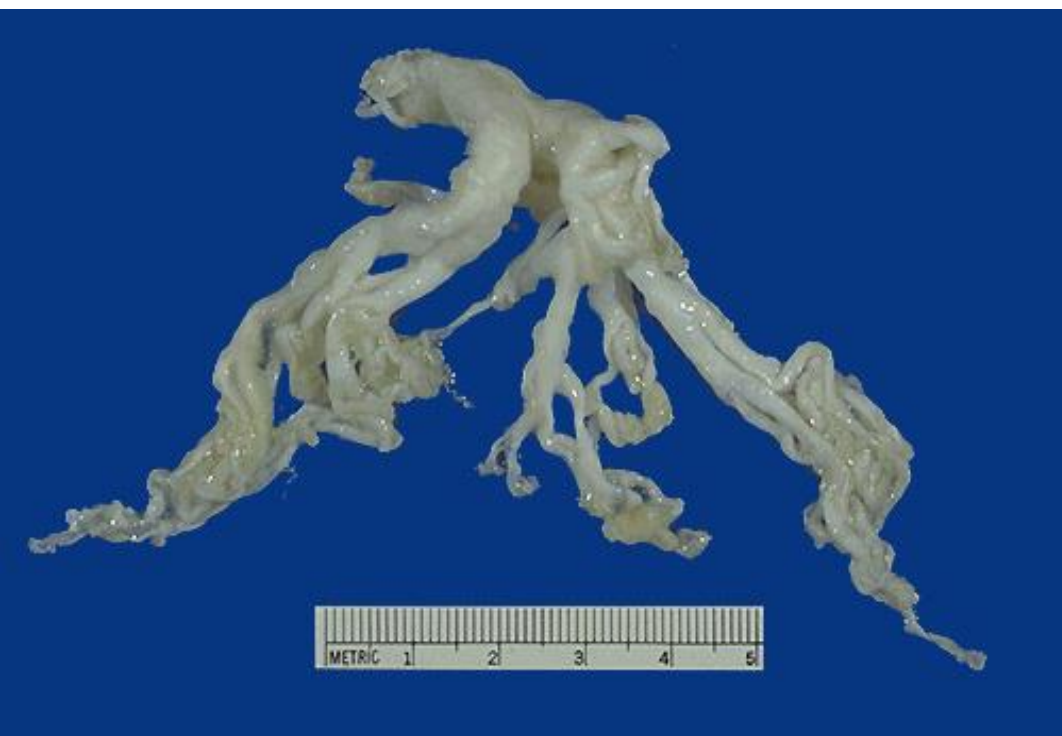Subpleural lung abscess.



Pulmonary emphysema.



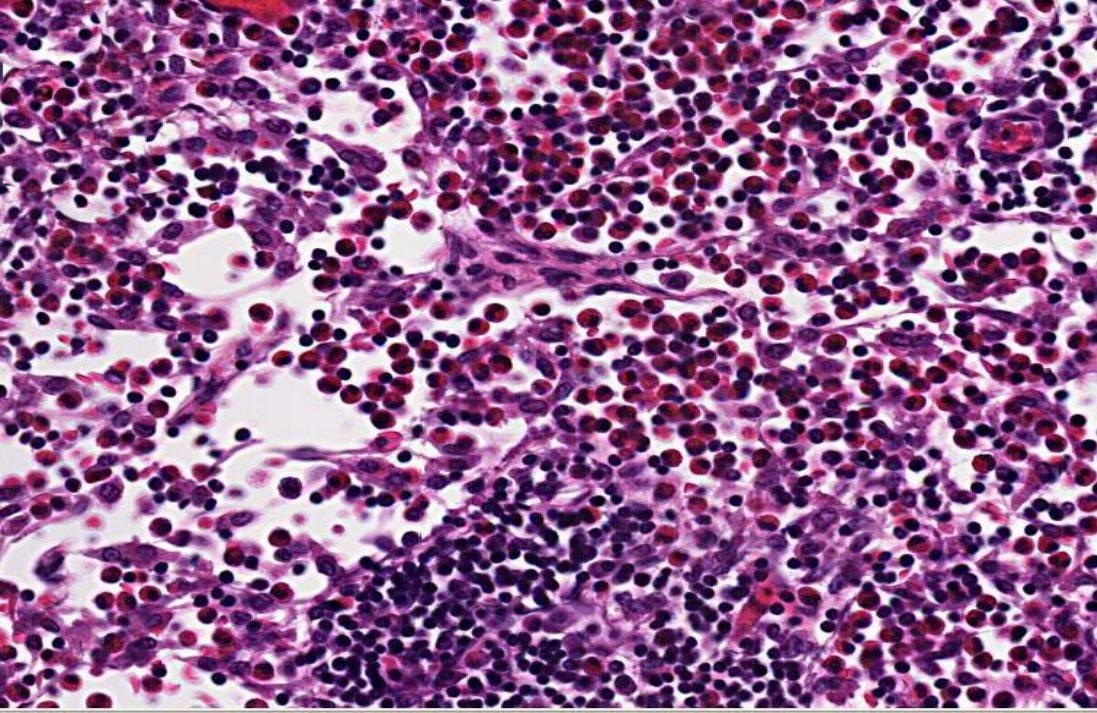
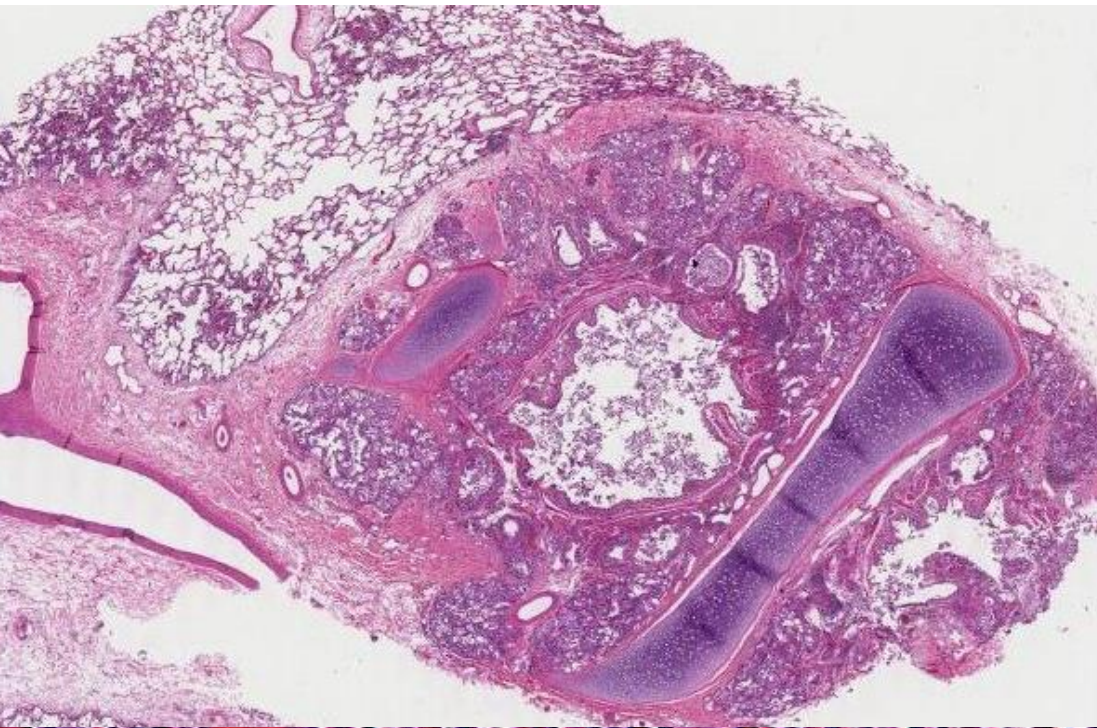
**Bullous pulmonary
emphysema.**



Bronchial asthma

a – hypersecretion of mucus in the lumen of the bronchi;

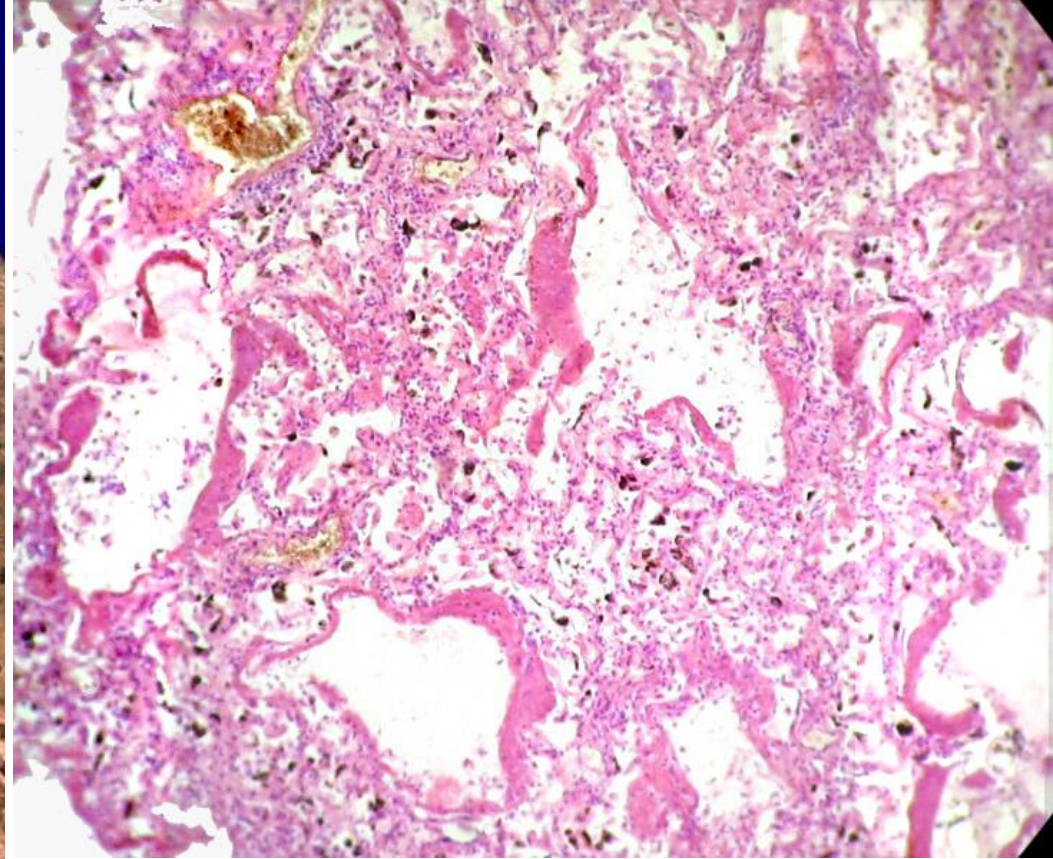
b - mucus plugs in the bronchi in asthma (in status asthmaticus).



Bronchial asthma.

a – myocyte hypertrophy, hyperplasia of the submucosal glands, inflammatory infiltration, mucus in the lumen (H-E stain).

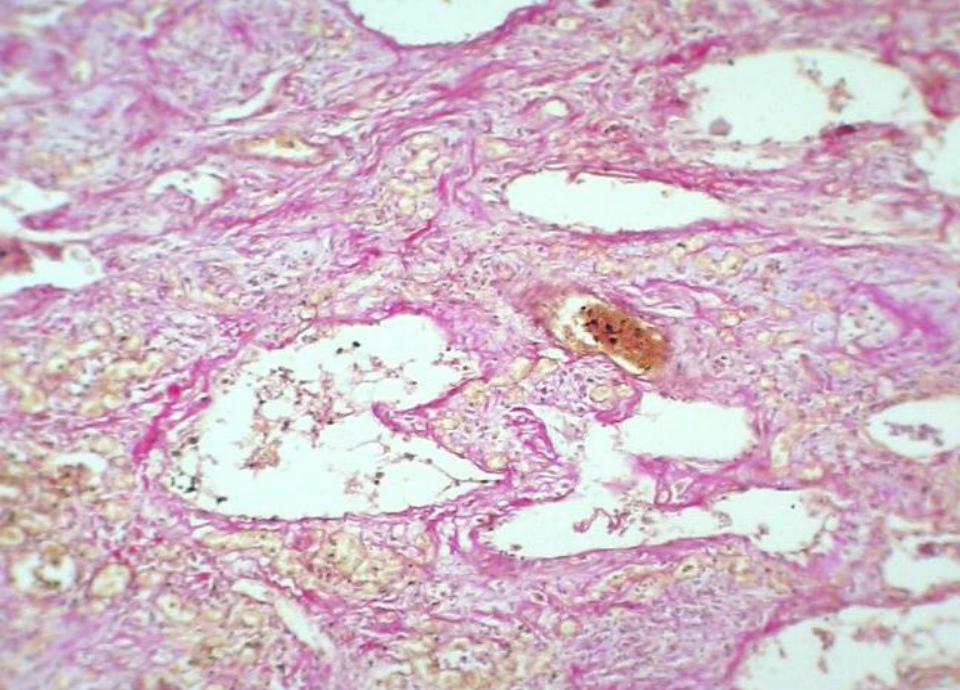
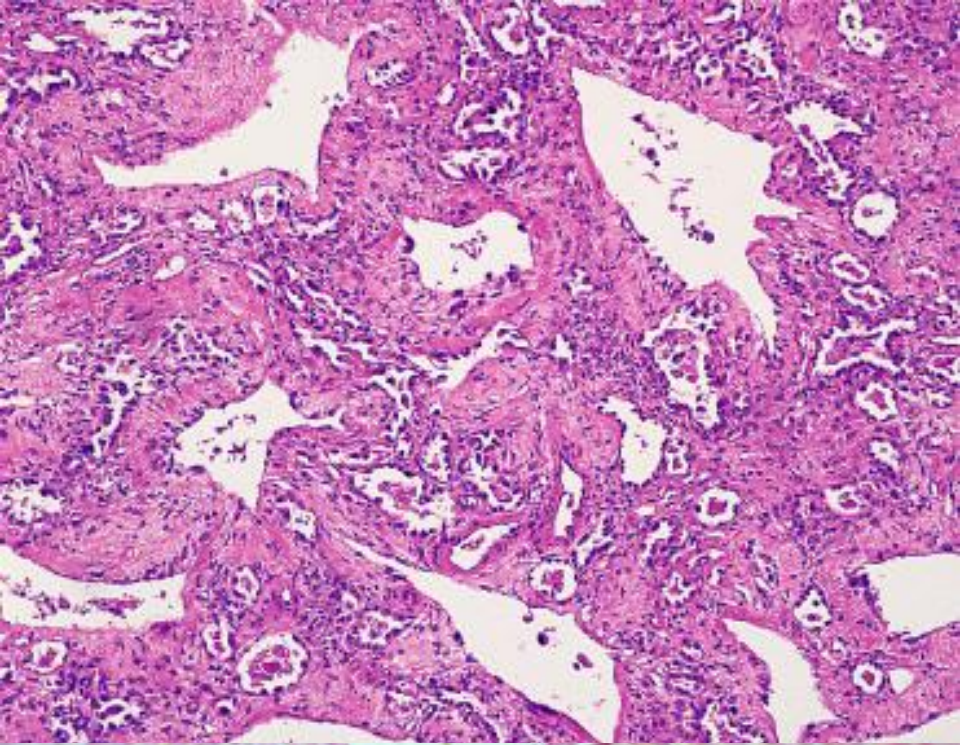
b – eosinophilic infiltration into the hilum lymph node in bronchial asthma (H-E stain).



Fibrosing alveolitis.

a – macroscopic pattern;

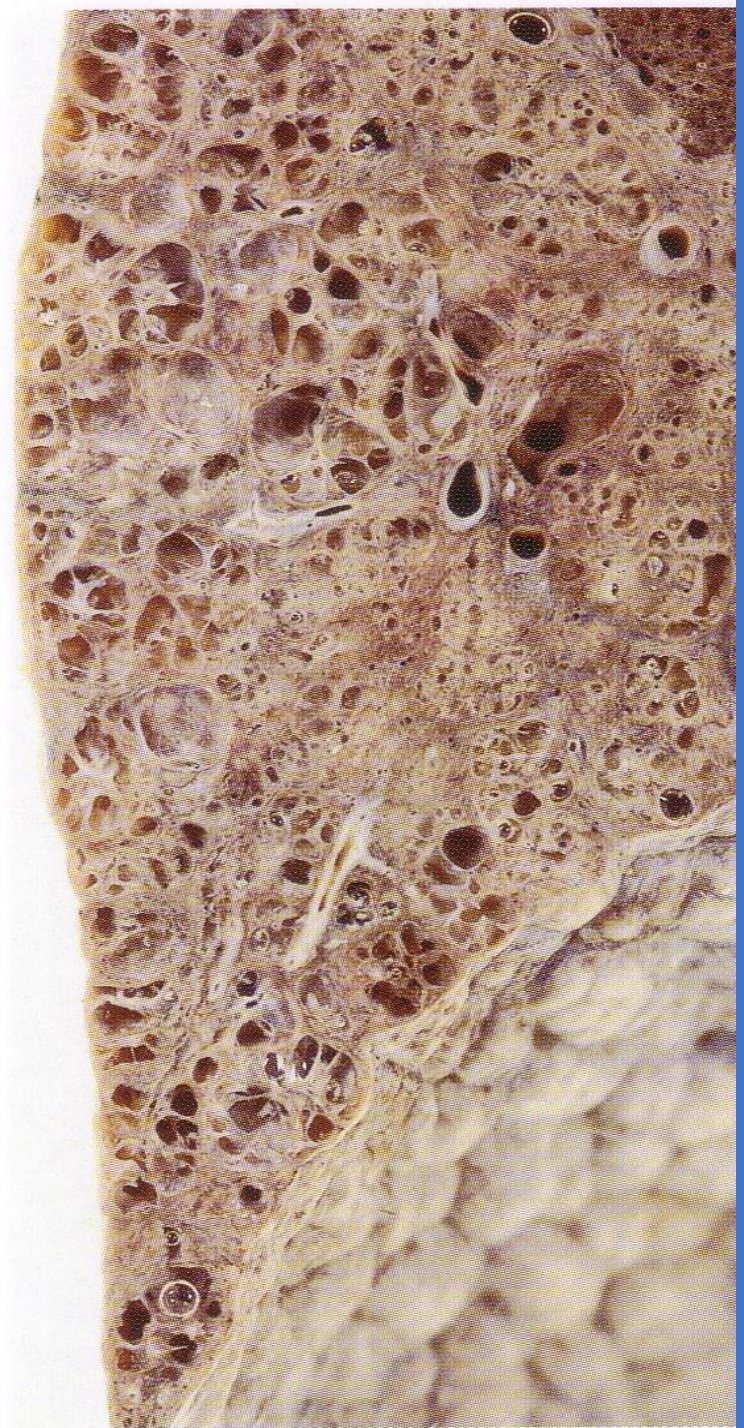b – inflammatory infiltration of interalveolar septa and hyaline membranes (H-E stain).

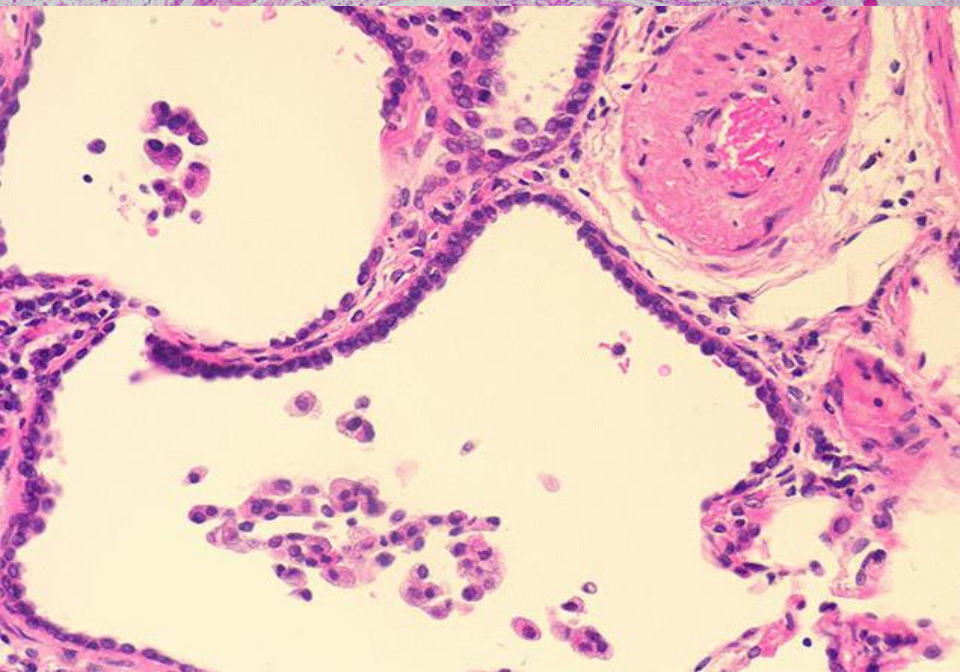
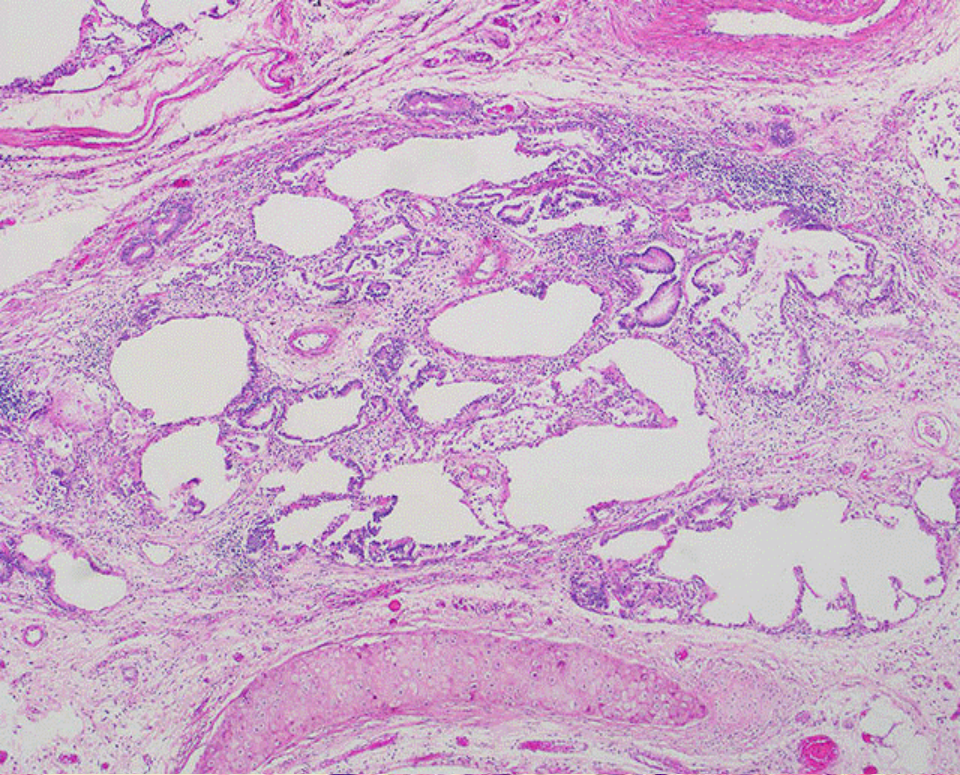


**Diffuse interstitial
pulmonary fibrosis.**
(H-E and picrofuchsin stain).

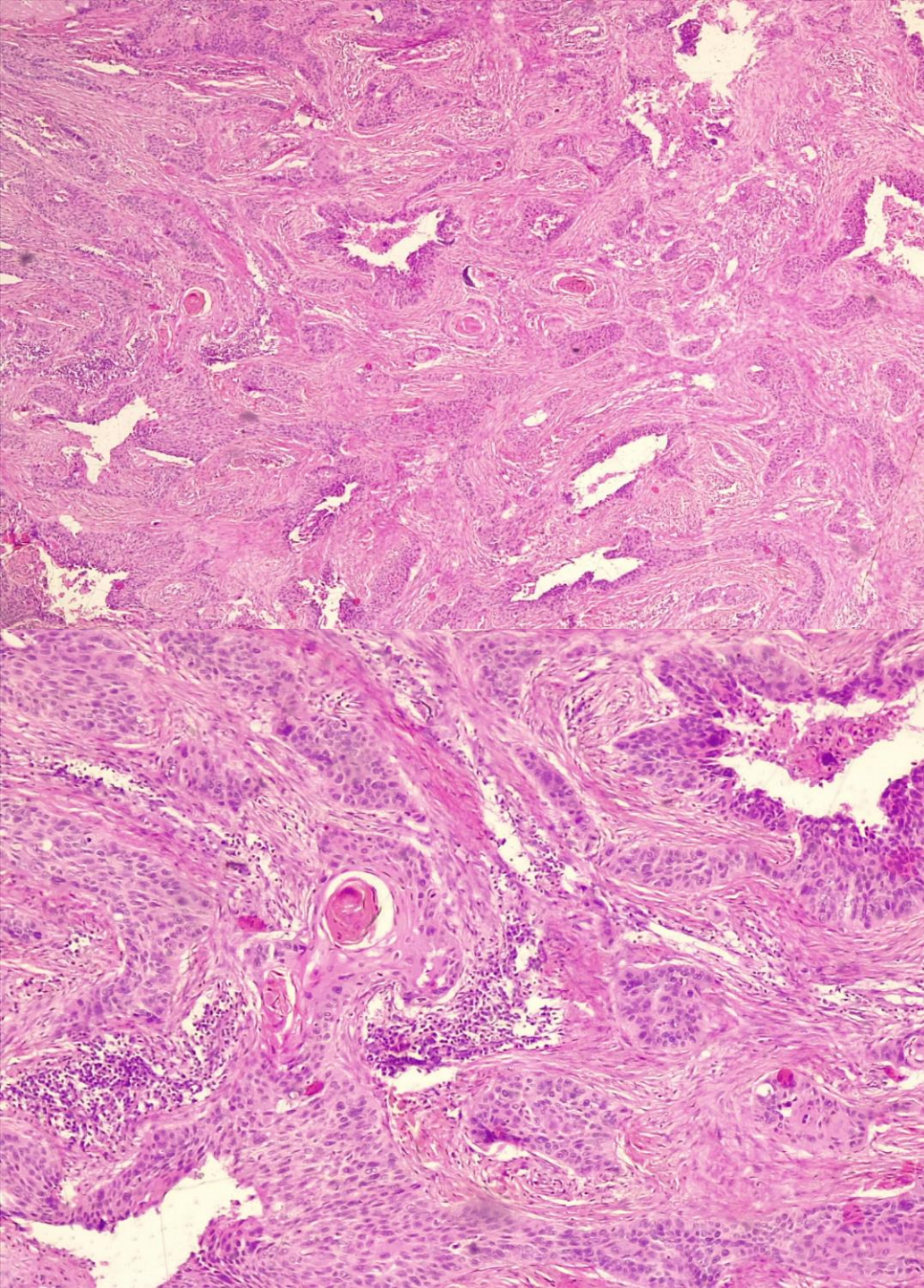


Lung "honeycomb" appearance

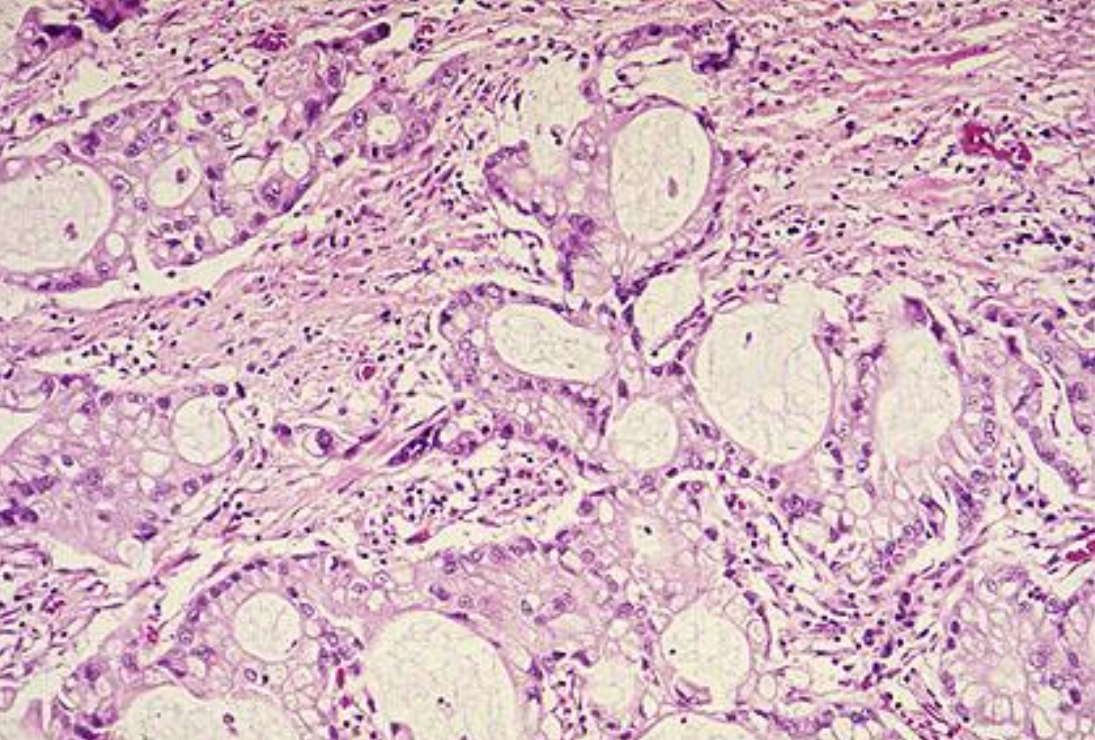




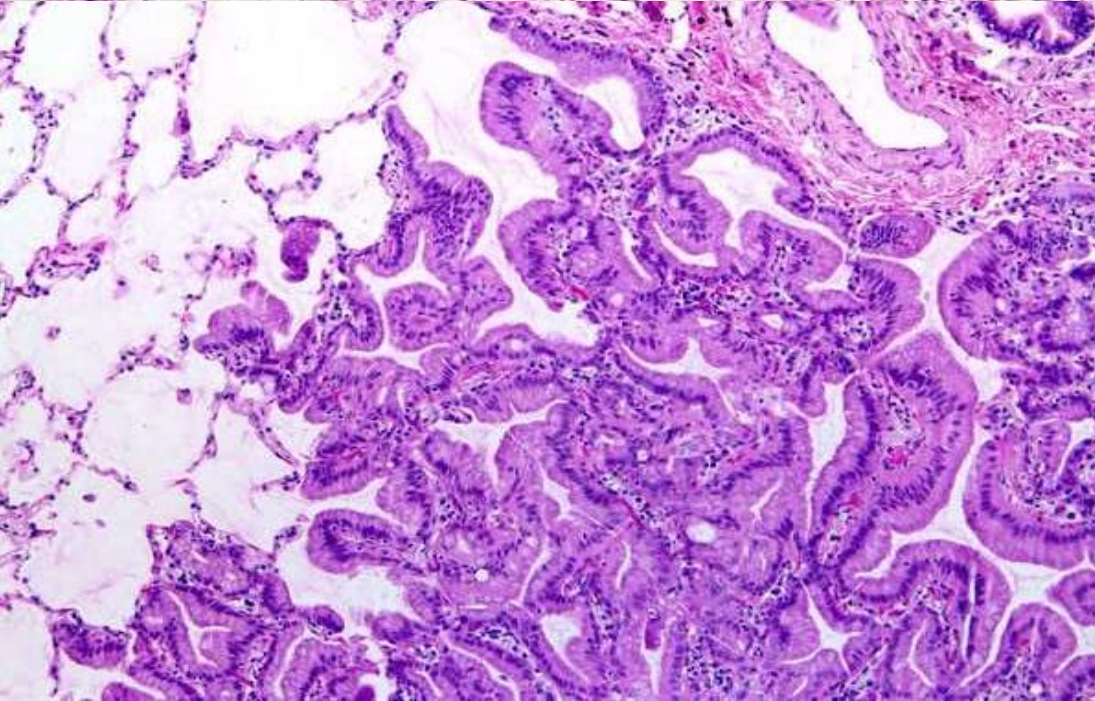
**Lung "honeycomb"
appearance (*H-E stain*)**



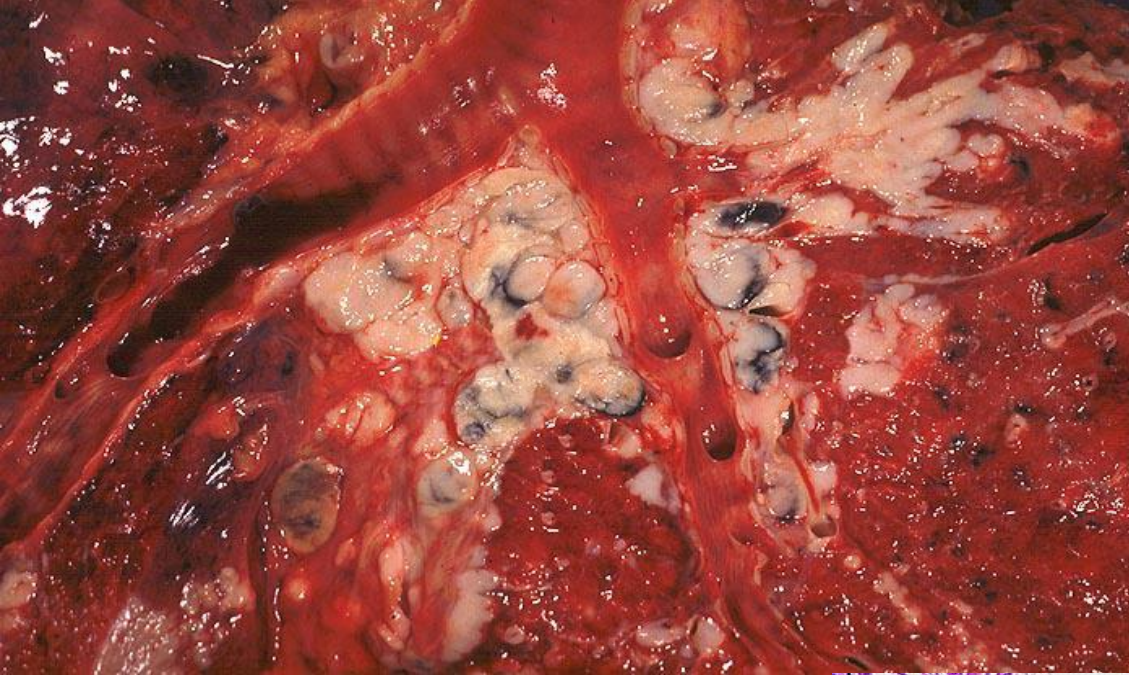**Keratinized squamous cell
lung carcinoma. (*H-E stain*).**



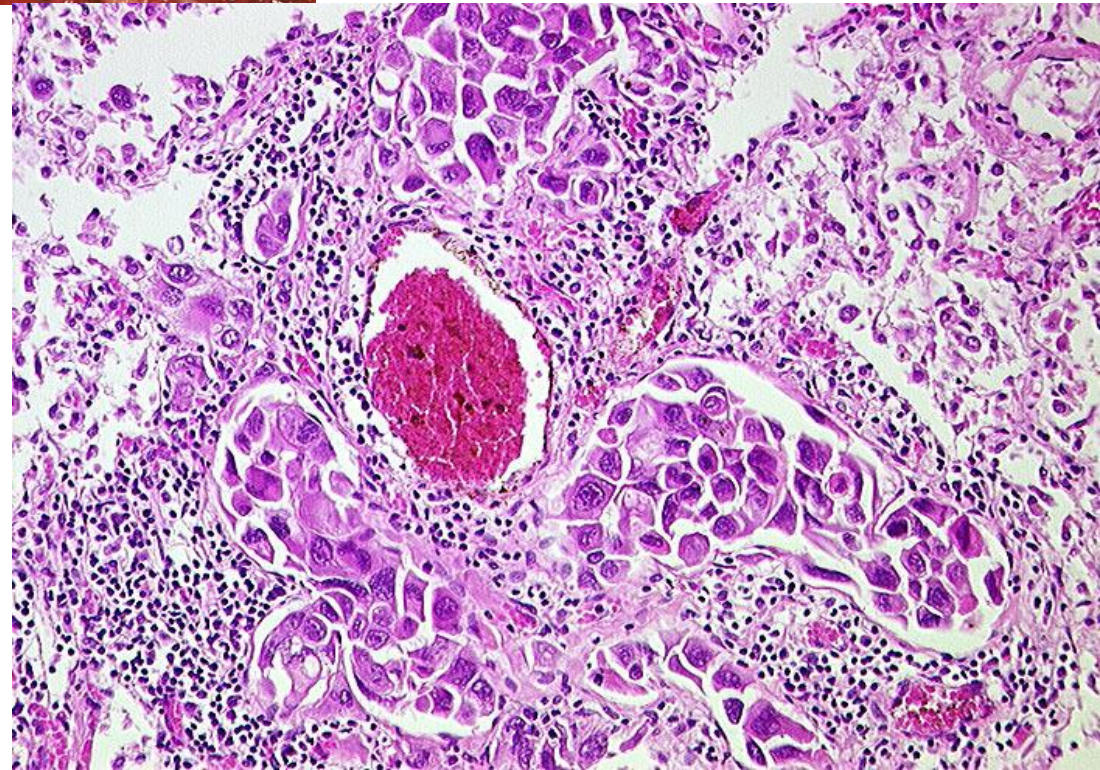
a. Pulmonary adenocarcinoma. (*H-E stain*).



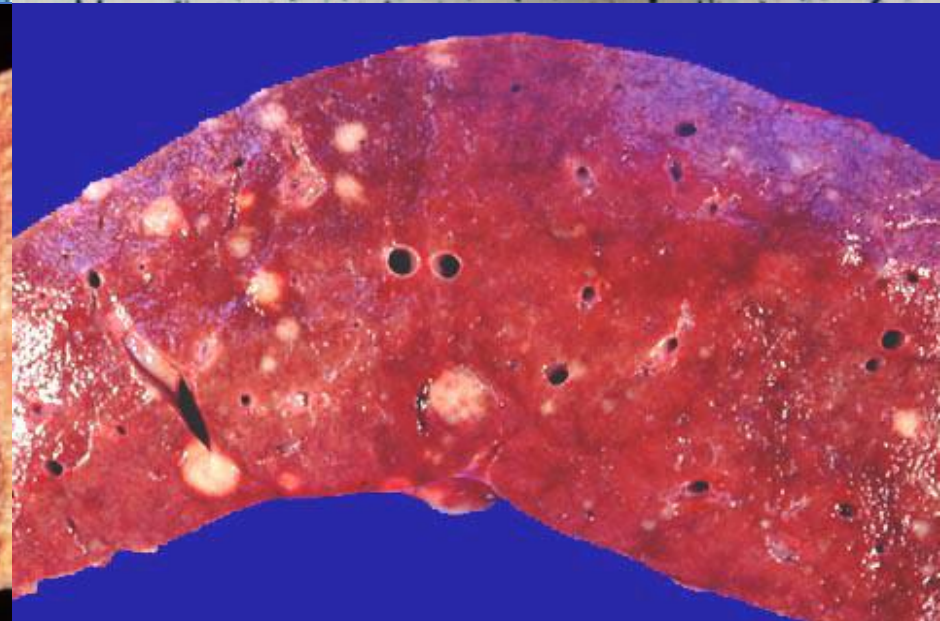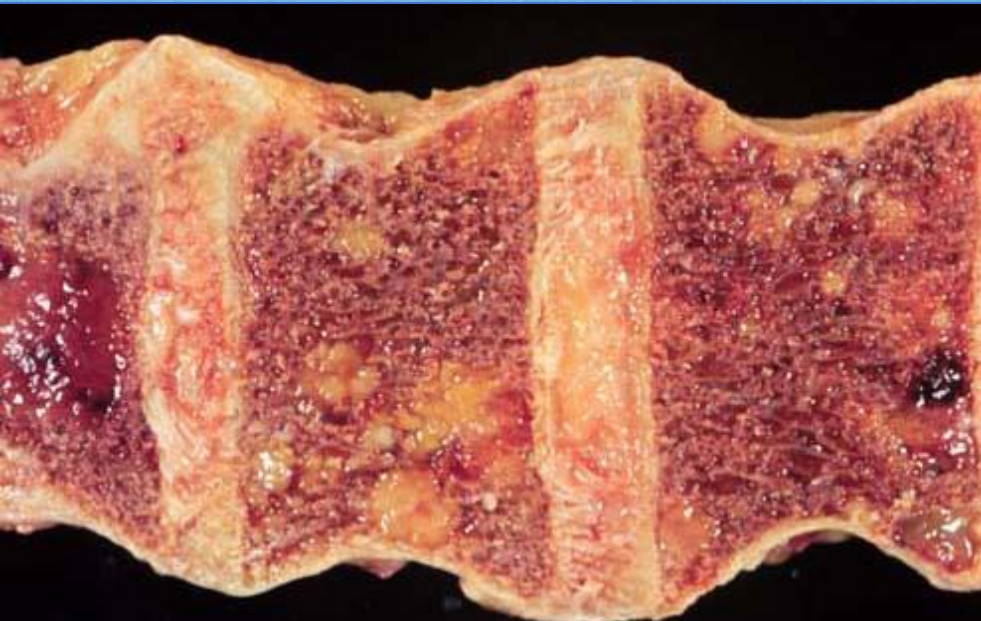
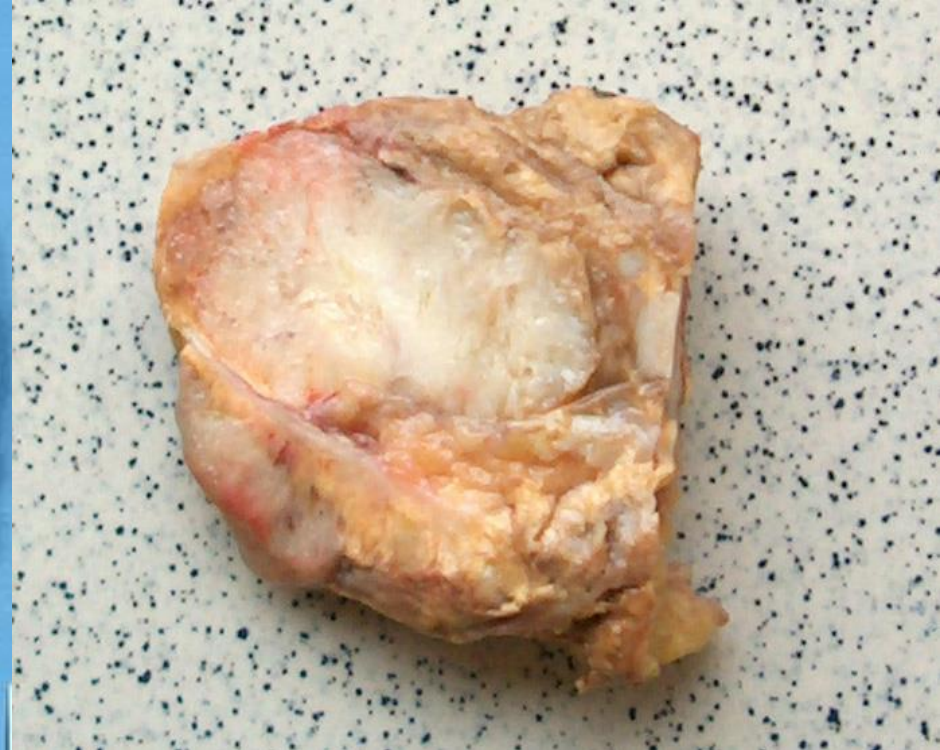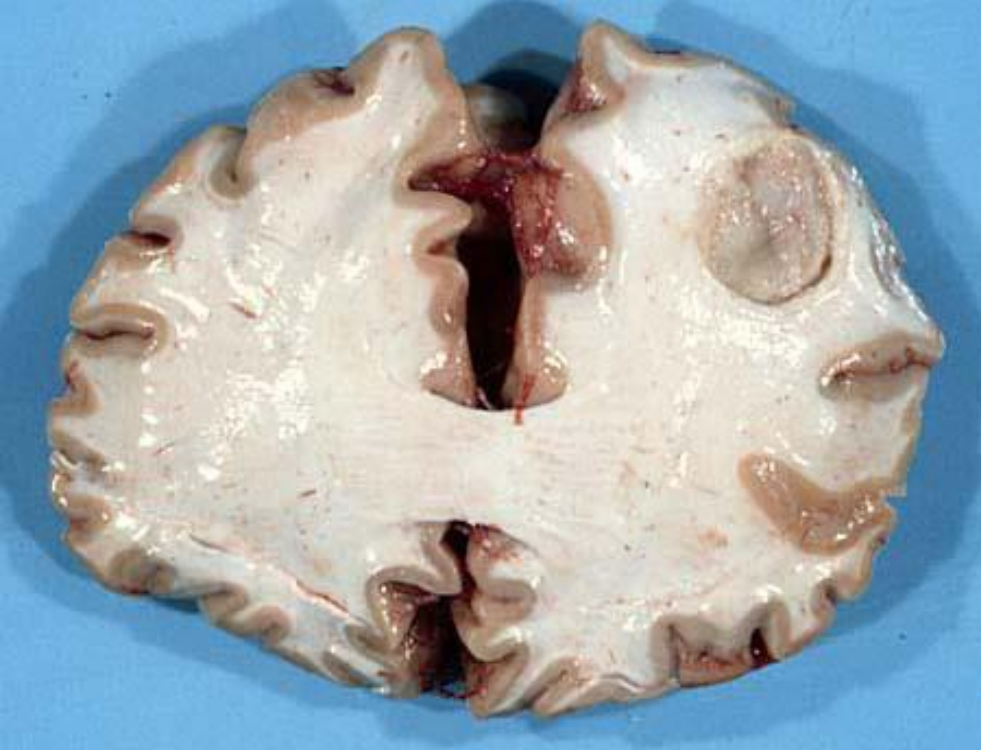b. Bronchioloalveolar carcinoma. (*H-E stain*).



**Cancerous
embolism of
lymphatic vessels.**



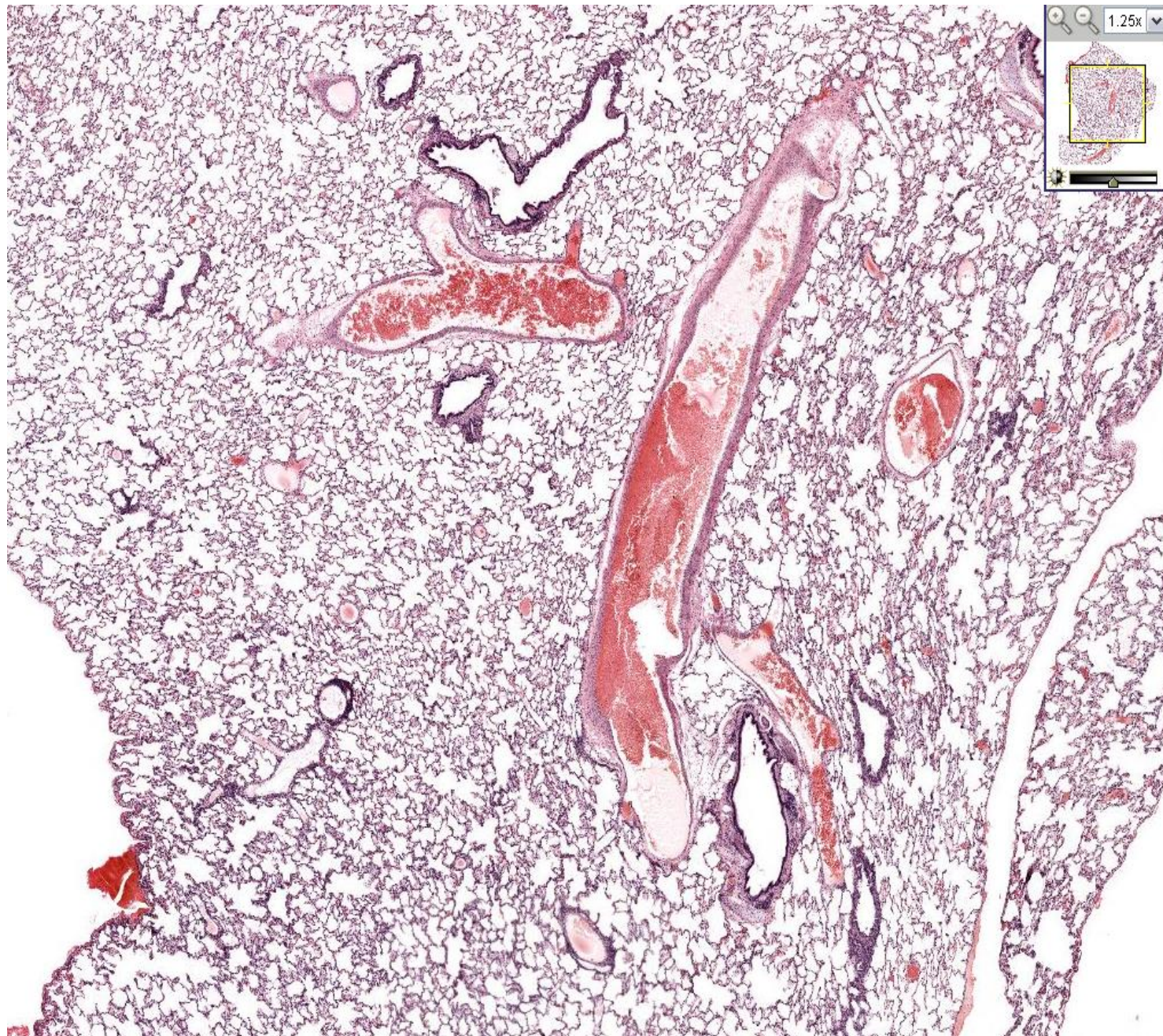
**Pulmonary carcinoma
metastases
in the mediastinal
lymph nodes.**



Metastases in the brain, vertebrae, adrenal glands and liver

Function of the Respiratory System

- Oversees gas exchanges (oxygen and carbon dioxide) between the blood and external environment
- Exchange of gasses takes place within the lungs in the alveoli(only site of gas exchange, other structures passageways
- Passageways to the lungs purify, warm, and humidify the incoming air
- Shares responsibility with cardiovascular system



Bronchi

Bronchioles

**Terminal
bronchioles**

Alveolar ducts

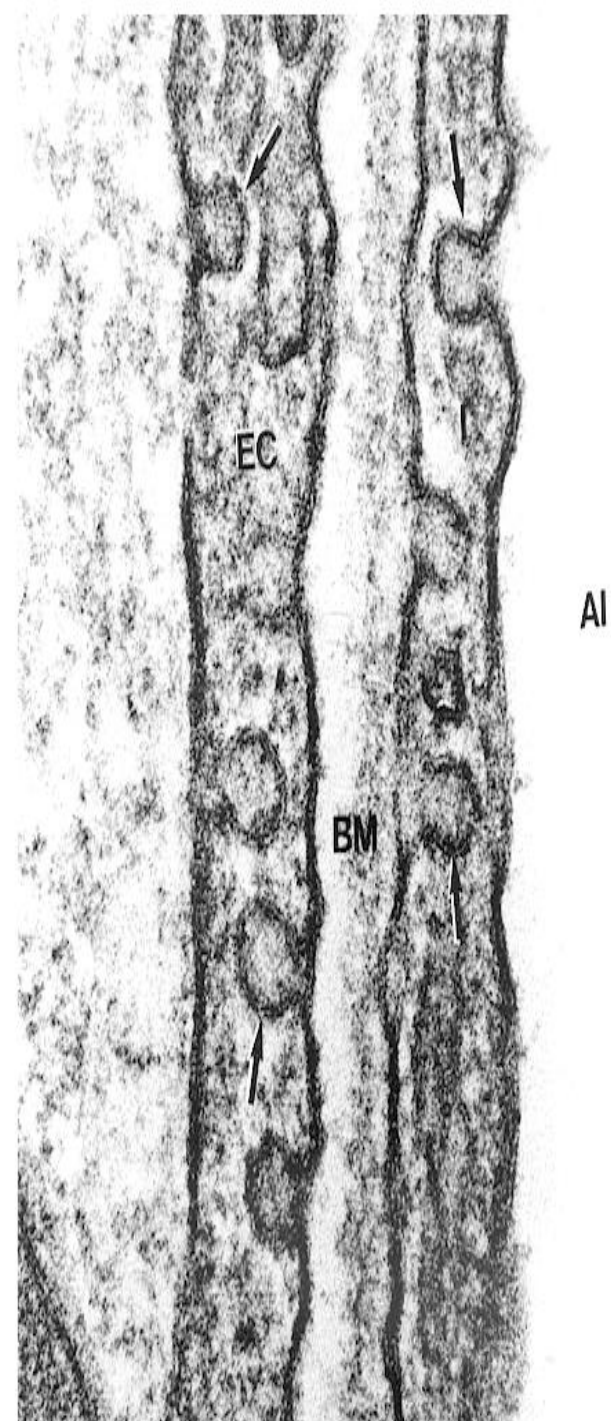
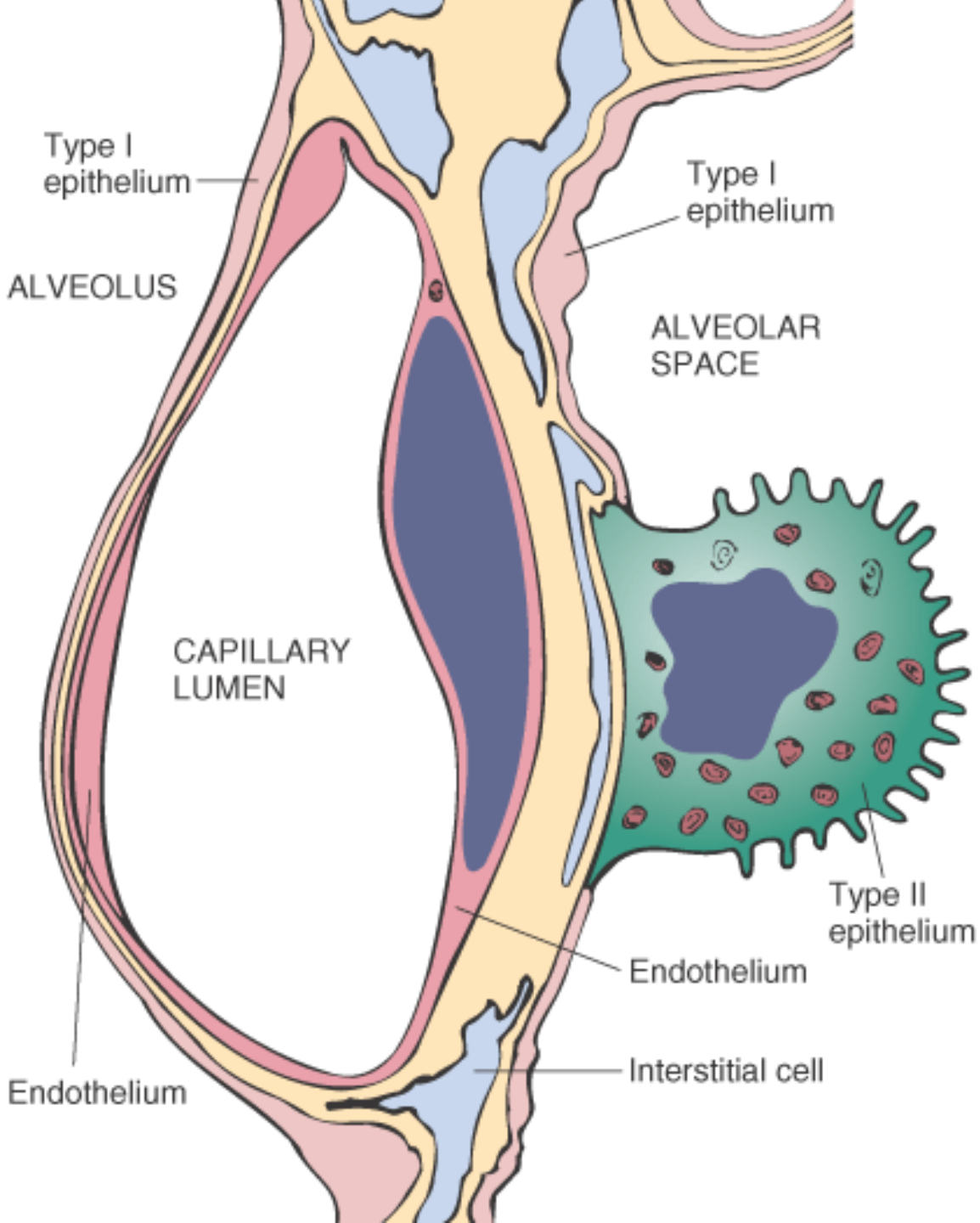
Alveoli

**Type 1
pneumocytes**

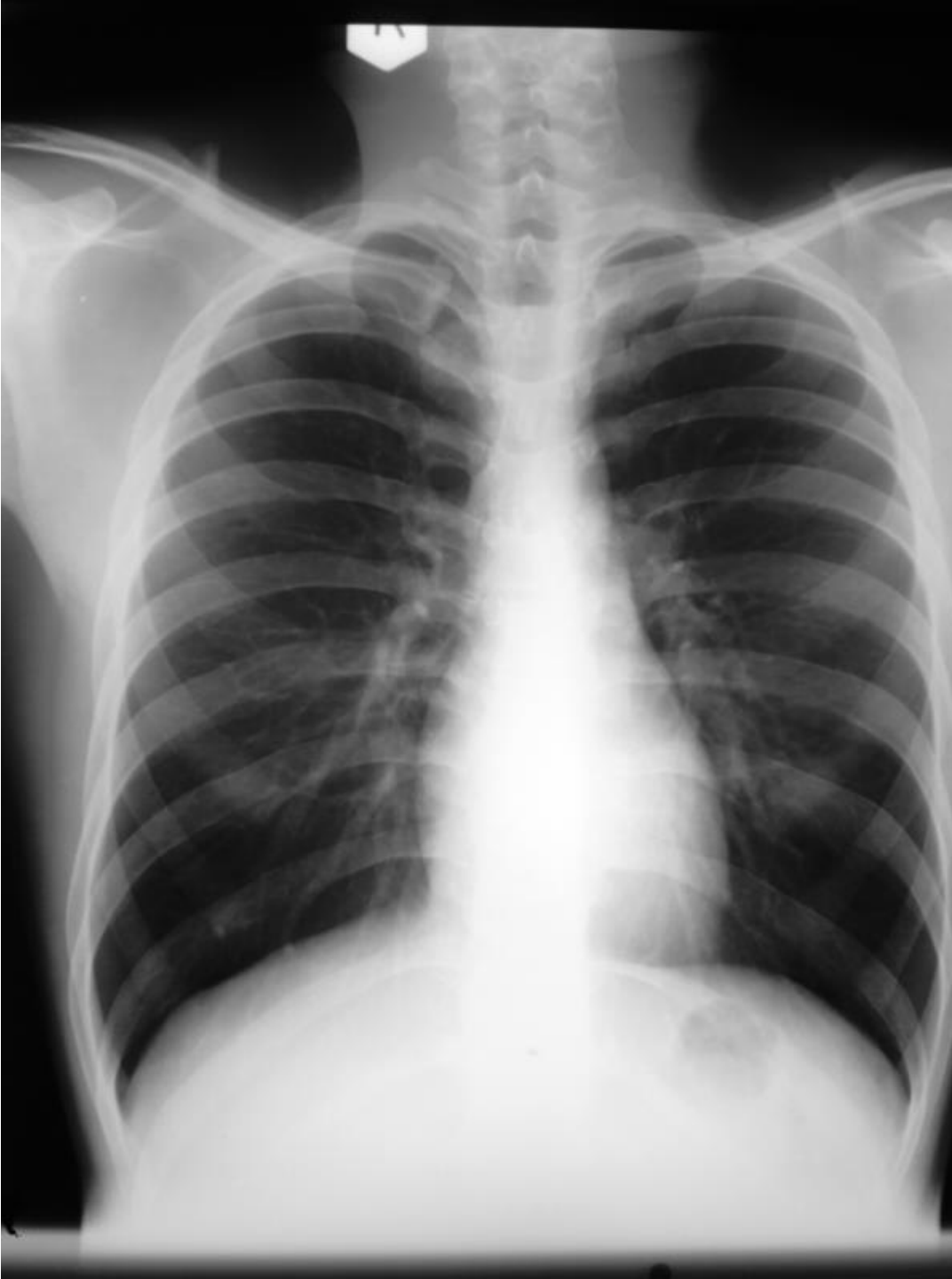**Type 2
pneumocytes**

Macrophages

Capillaries



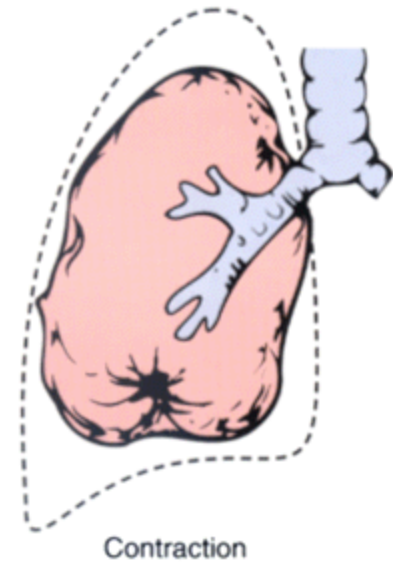
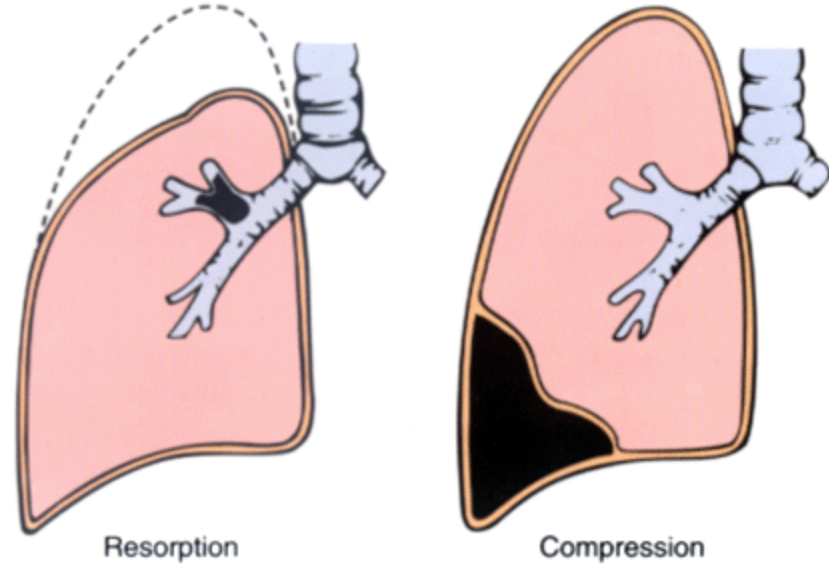
**N
O
R
M
A
L**



**C
X
R**

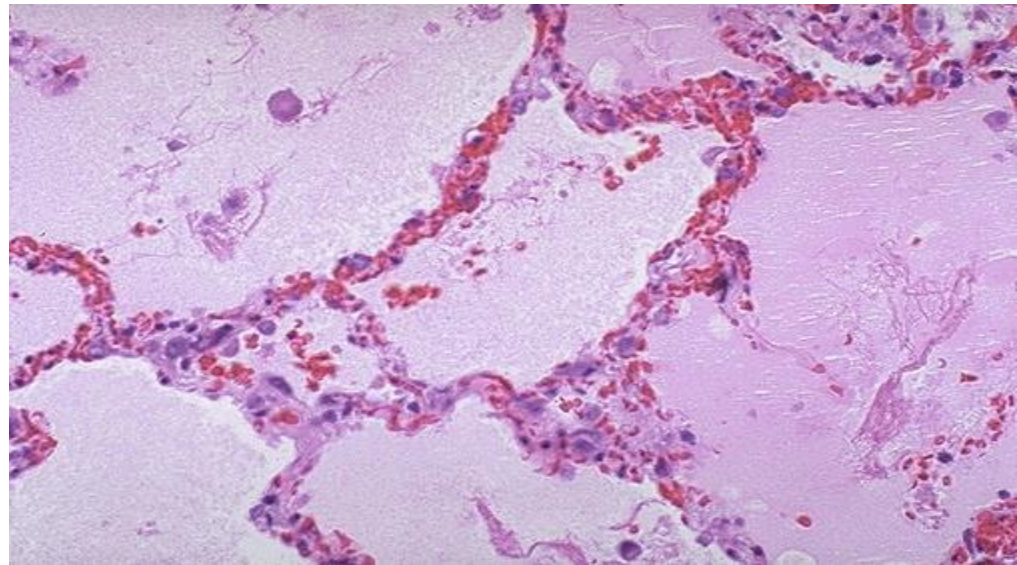
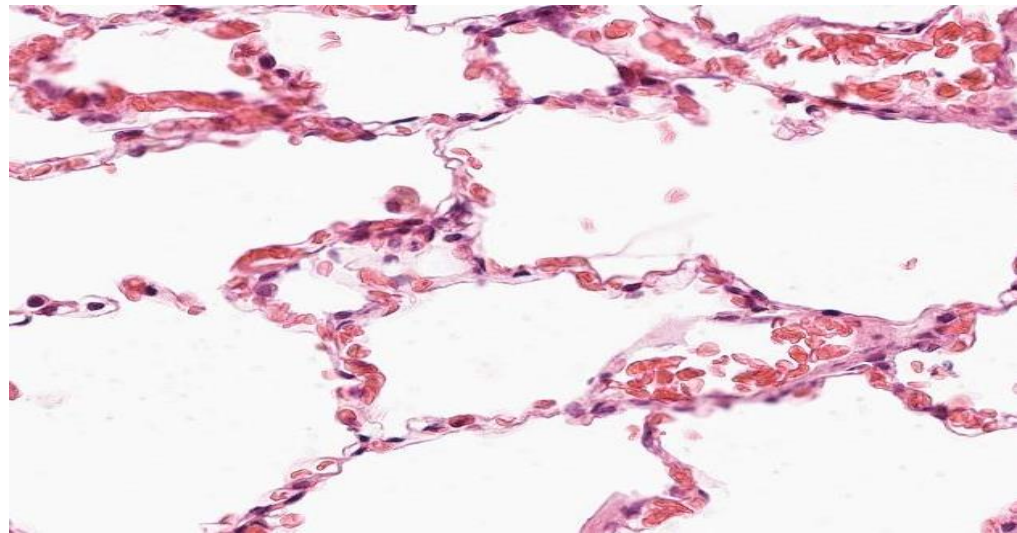
ATELECTASIS

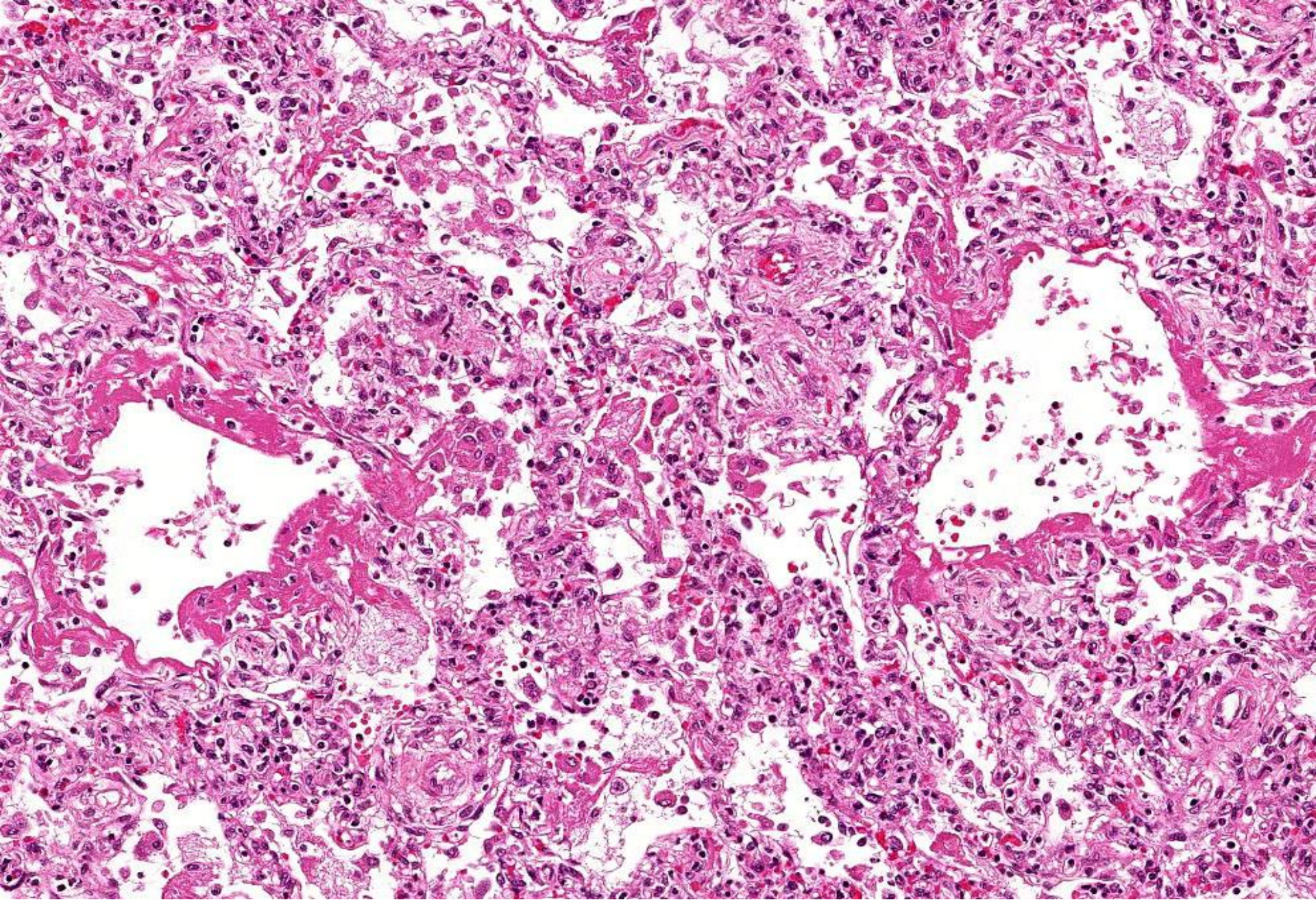
- **INCOMPLETE EXPANSION**
- **COLLAPSE**



PULMONARY EDEMA

- IN-creased venous pressure
- DE-creased oncotic pressure
- Lymphatic obstruction
- Alveolar injury





ARDS

ACUTE INTERSTITIAL PNEUMONIA

- **Think of it as ARDS with NO known etiology!**

OBSTRUCTION v. RESTRICTION

• OBSTRUCTION

- Air or blood?
- Large or small?
- Inspiration or Expiration?
- Obstruction is **SMALL AIRWAY EXPIRATION** obstruction, i.e., wheezing
- HYPEREXPANSION on CXR

• RESTRICTION

“Compliance”
“Infiltrative”

REDUCED lung VOLUME,
DYSPNEA, CYANOSIS
REDUCED GAS TRANSFER
“GROUND GLASS” on
CXR

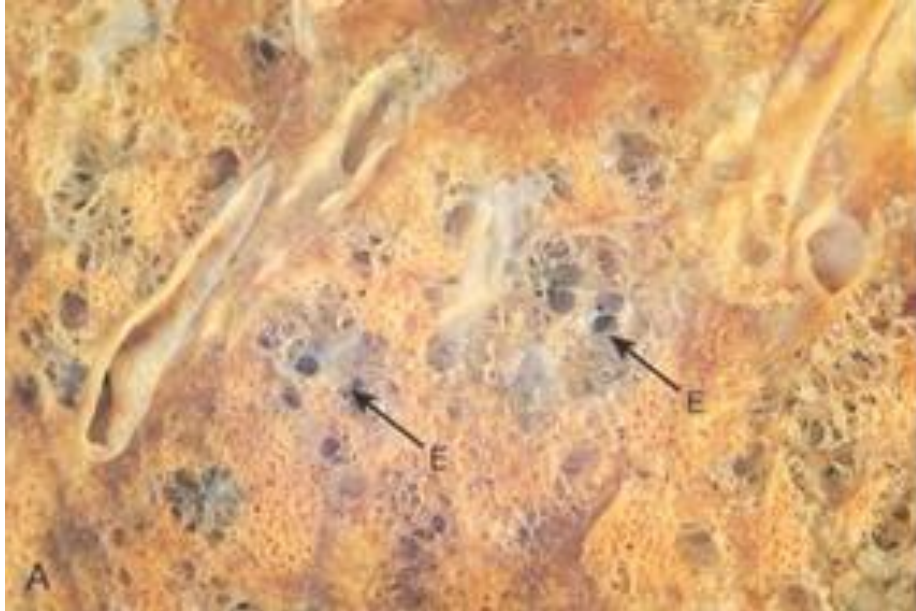
OBSTRUCTION (cOPD)

- **EMPHYSEMA** (almost always chronic)
- **CHRONIC BRONCHITIS** → emphysema
- **ASTHMA**
- **BRONCHIECTASIS**


EMPHYSEMA

- COPD, or “END-STAGE” lung disease
- Centri-acinar, Pan-acinar, Paraseptal, Irregular
- Like cirrhosis, thought of as END-STAGE of multiple chronic small airway obstructive etiologies
- NON-specific
- IN-creased crepitance, BULLAE (BLEBS)
- Clinically linked to recurrent pneumonias, and progressive failure

EMPHYSEMA

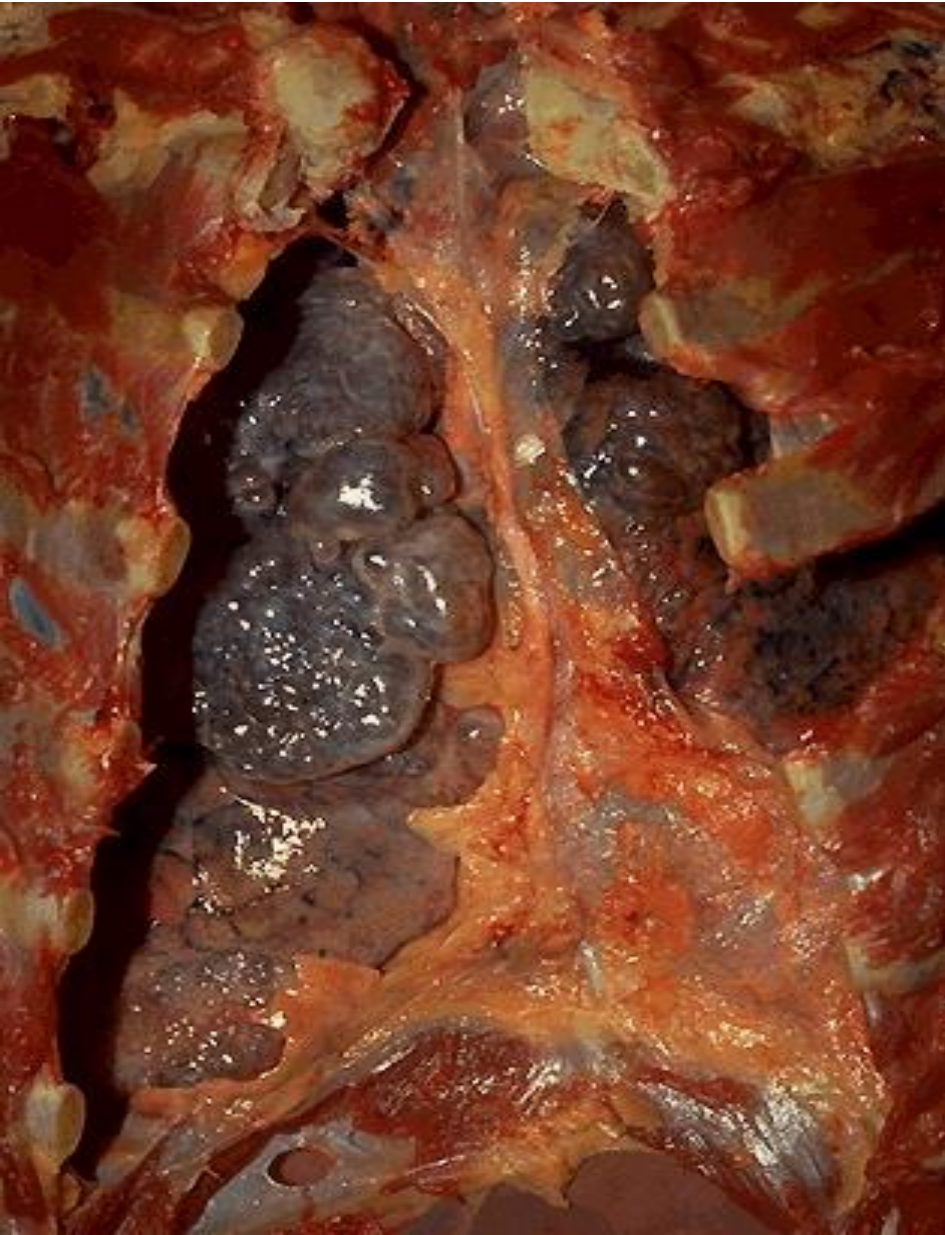


CENTRO-acinar



PAN-acinar

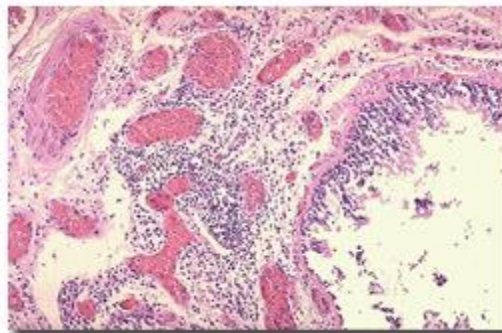
Bullae, or “peripheral blebs” are hallmarks of chronic obstructive lung disease, COPD.



CHRONIC BRONCHITIS

- **INHALANTS, POLLUTION, CIGARETTES**
- **CHRONIC COUGH**
- **CAN OFTEN PROGRESS TO EMPHYSEMA**

- **MUCUS hypersecretion, early, i.e. goblet cell increase**
- **CHRONIC bronchial inflammatory infiltrate**



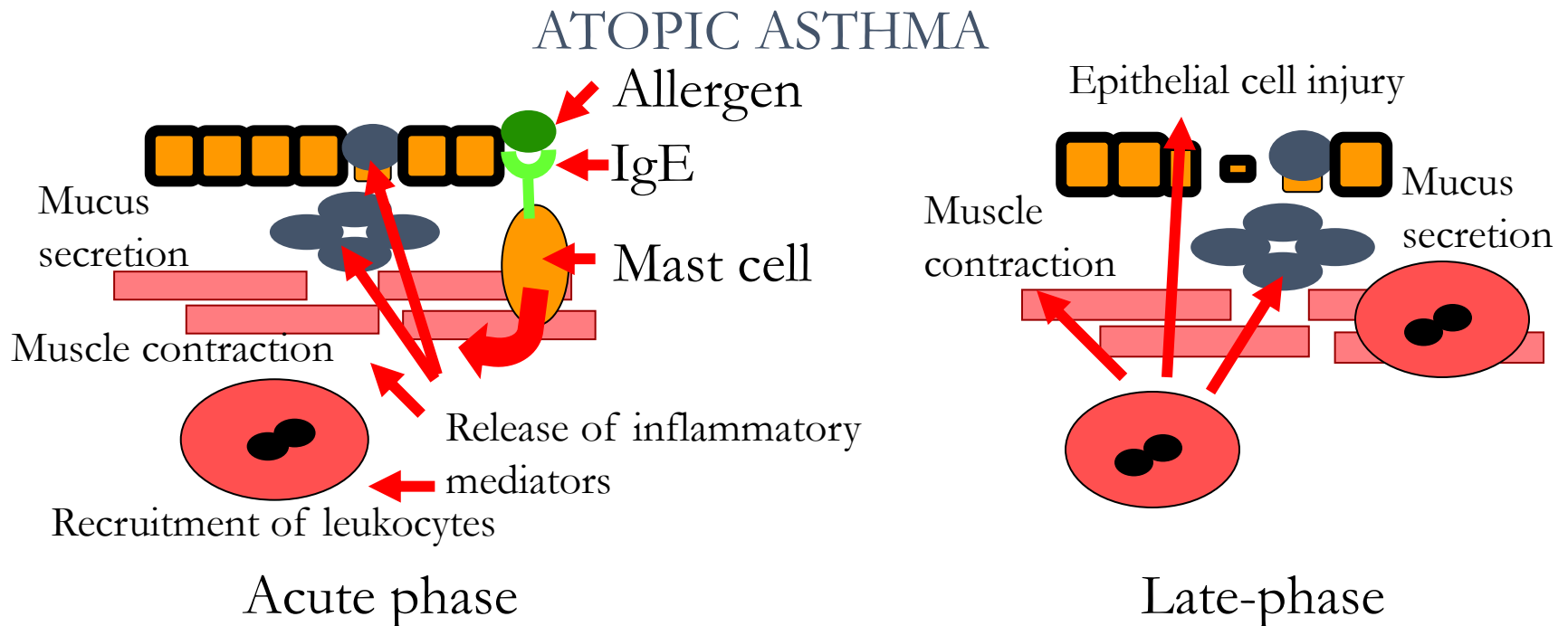
ASTHMA

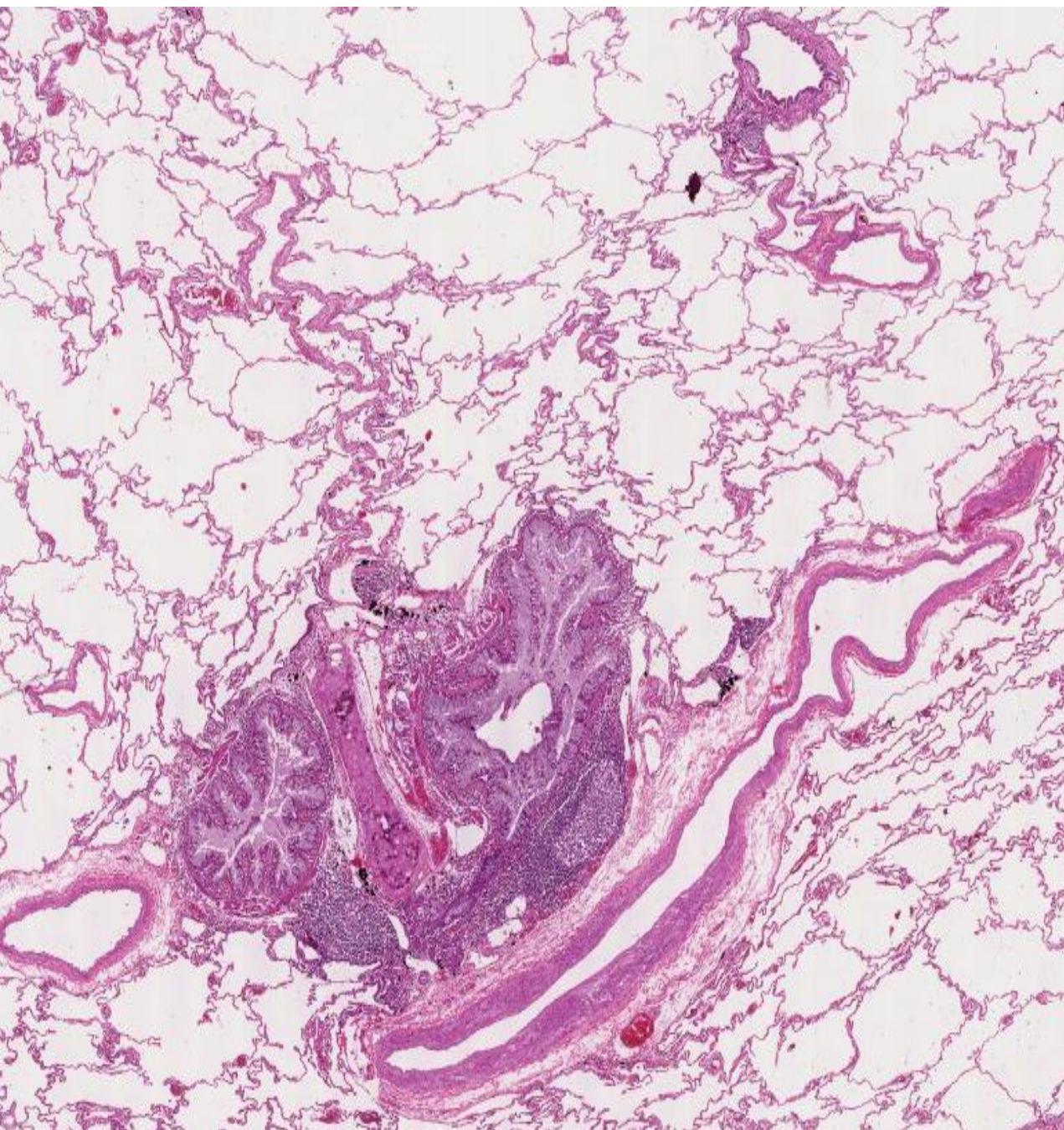
Similar to chronic bronchitis but:

- Wheezing is hallmark (**bronchospasm, i.e. “wheezing”**)
- **STRONG allergic role**, i.e., eosinophils, IgE, allergens
- Often starting in **CHILDHOOD**
- **ATOPIC (allergic) or NON-ATOPIC (infection)**
- Chronic small airway obstruction and infection
- **1) Mucus hypersecretion with plugging, 2) lymphocytes/eosinophils, 3) lumen narrowing, 4) smooth muscle hypertrophy**

Bronchial Asthma

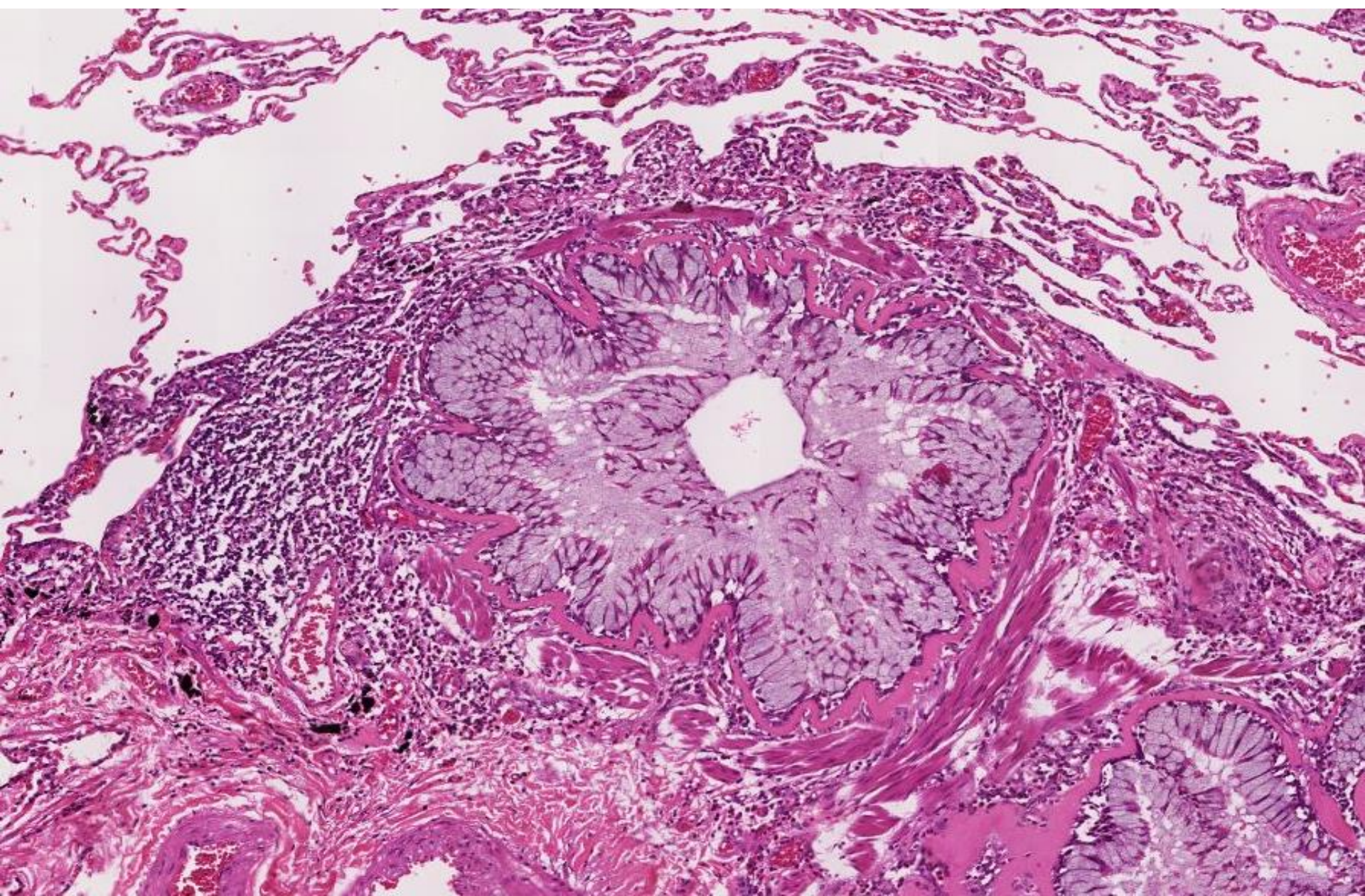
- **Chronic inflammatory disorder of the airways resulting in contraction of bronchial muscle**
- **Types**
 - **Extrinsic (atopic, allergic).**
 - Allergens: food, pollen, dust, etc.
 - **Intrinsic (non-atopic)**
 - Initiated by infections, drugs, pollutants, chemical irritants





Note the heavy inflammatory cell infiltrate around bronchioles and small bronchi.

What are the 4 classical histologic findings in bronchial asthma?



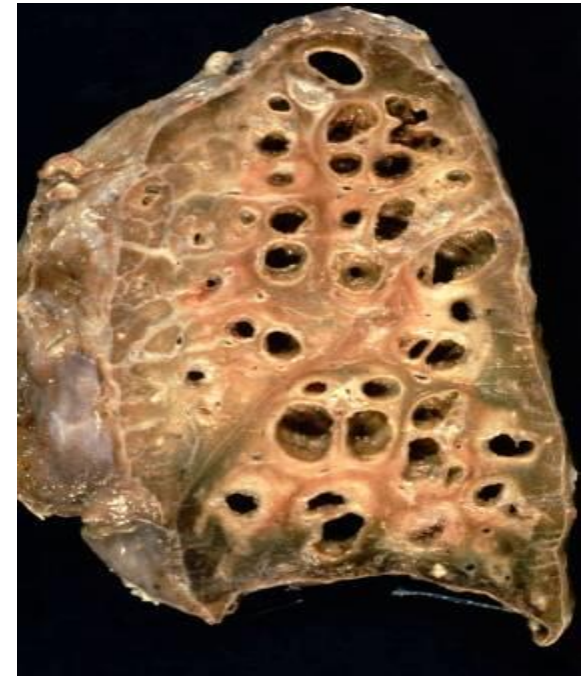BRONCHIECTASIS

DILATATION of the BRONCHUS, associated with, often, necrotizing inflammation

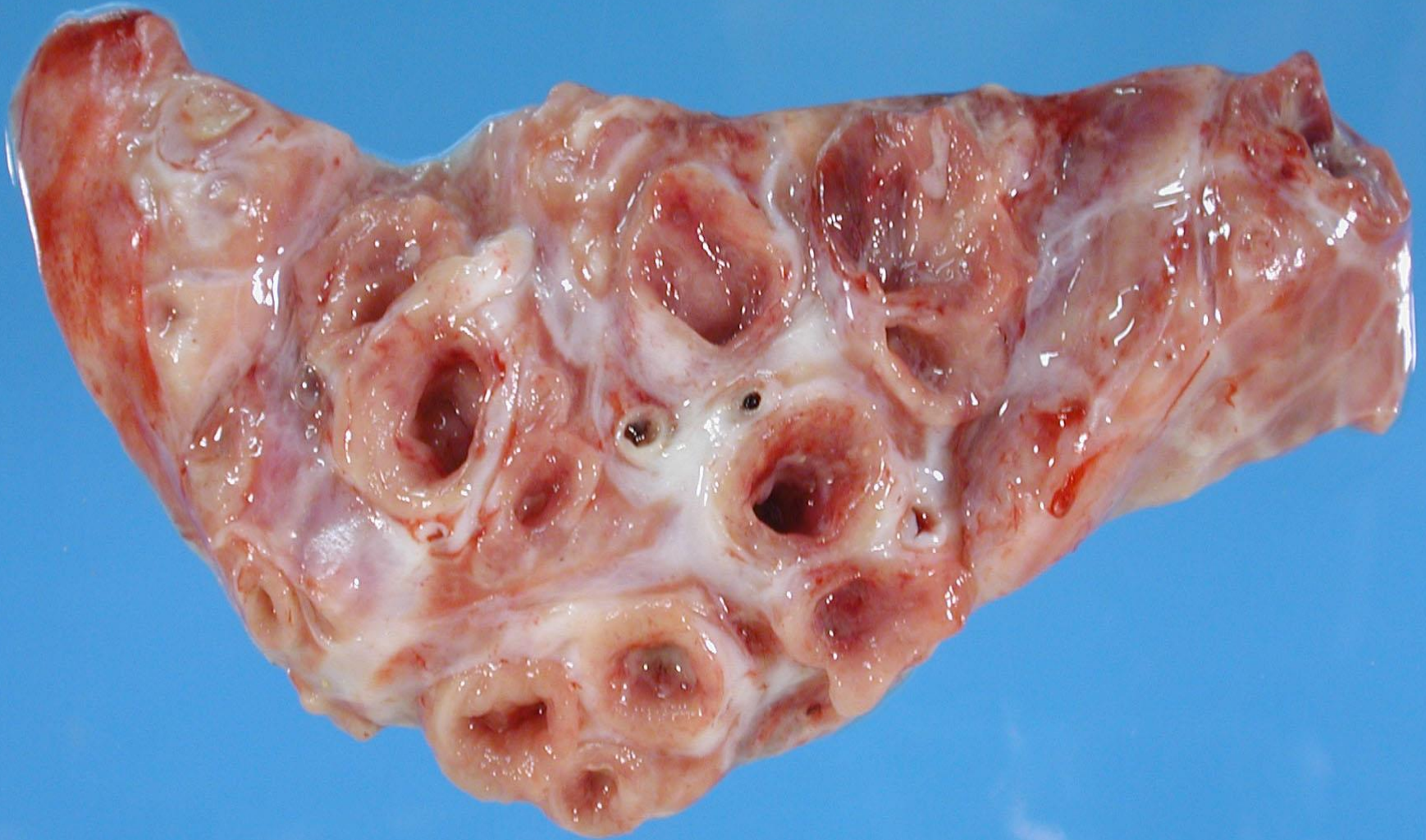- CONGENITAL

- **TB**, other bacteria, many viruses

- BRONCHIAL OBSTRUCTION (i.e., LARGE AIRWAY, NOT SMALL AIRWAY)
- Rheumatoid Arthritis, SLE, IBD (Inflammatory Bowel Disease)



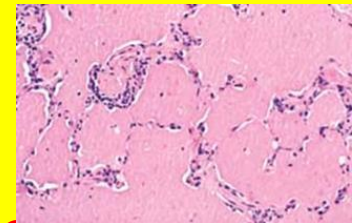
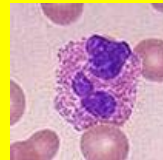
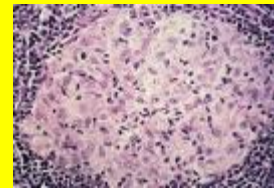
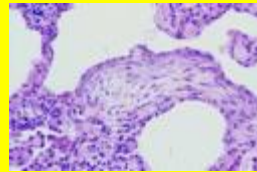
BRONCHIECTASIS



RESTRICTIVE (INFILTRATIVE)

- **REDUCED COMPLIANCE**, reduced gas exchange)
- Are also **DIFFUSE**
- **HETEROGENEOUS**

- **FIBROSING**
- **GRANULOMATOUS**
- **EOSINOPHILIC**
- **SMOKING RELATED**



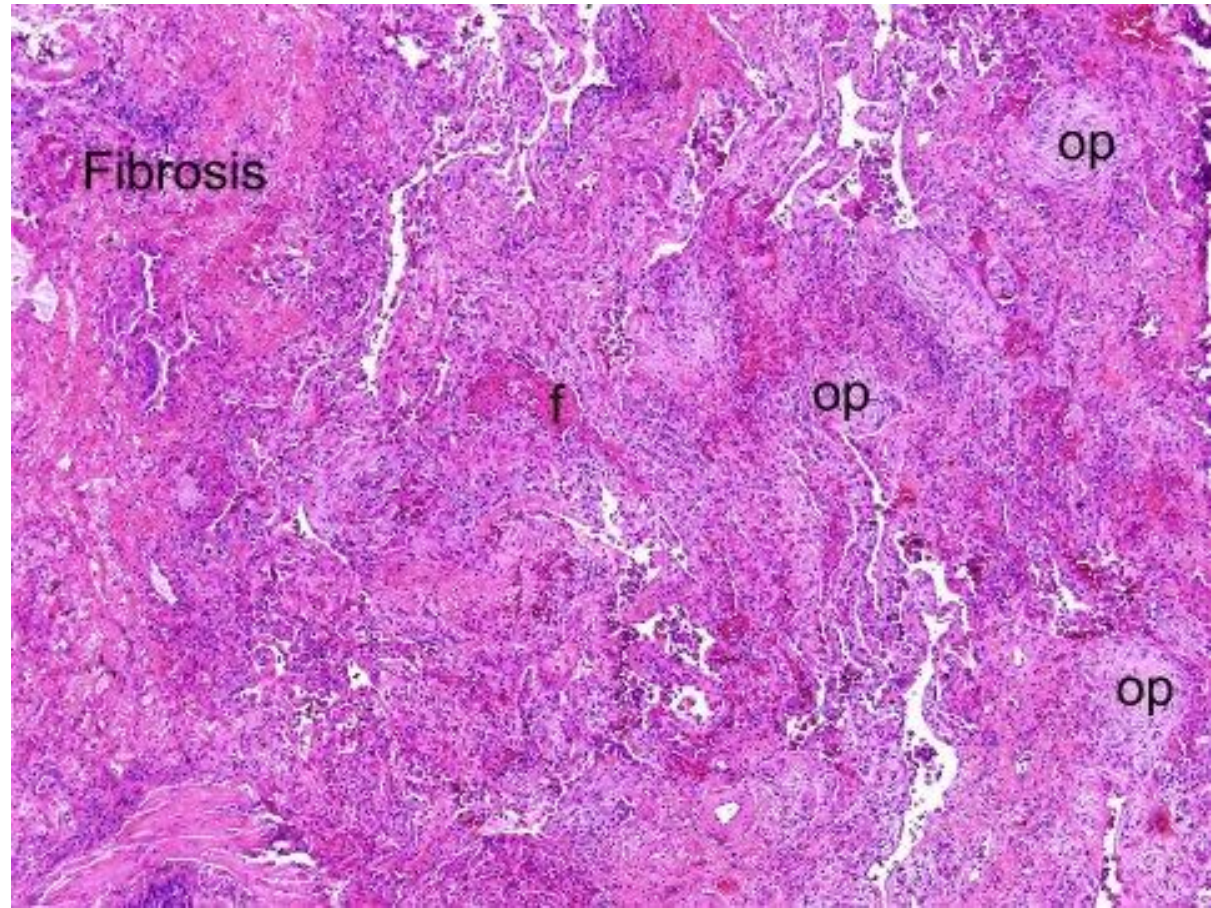
- **PAP (Pulmonary Alveolar Proteinosis)**

FIBROSING

- “IDIOPATHIC” PULMONARY FIBROSIS (IPF)
- NONSPECIFIC INTERSTITIAL FIBROSIS
- “CRYPTOGENIC” ORGANIZING PNEUMONIA
- “COLLAGEN” VASCULAR DISEASES
- PNEUMOCONIOSES
- DRUG REACTIONS
- RADIATION CHANGES

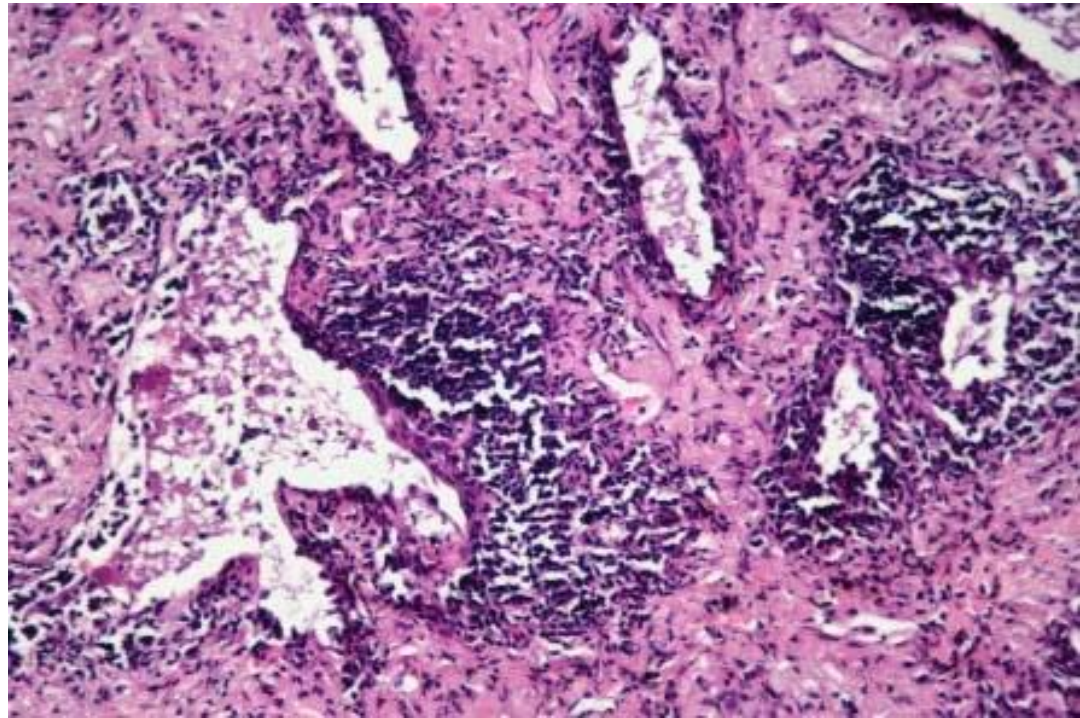
IPF (UIP)

- **IDIOPATHIC**, i.e., not from any usual cause, like lupus, scleroderma
- **FIBROSIS**



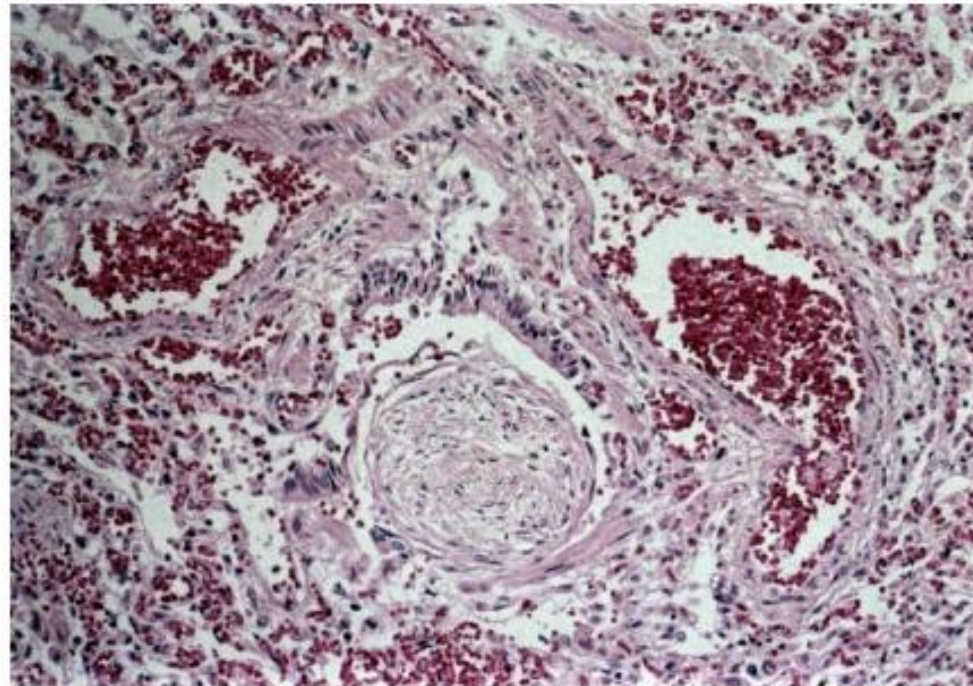
NON-SPECIFIC INTERSTITIAL PNEUMONIA

- **WASTEBASKET DIAGNOSIS**, of ANY pneumonia (pneumonitis) of any known or unknown etiology
 - **FIBROSIS**
 - **CELLULAR INFILTRATE** (LYMPHS & PLASMA CELLS)



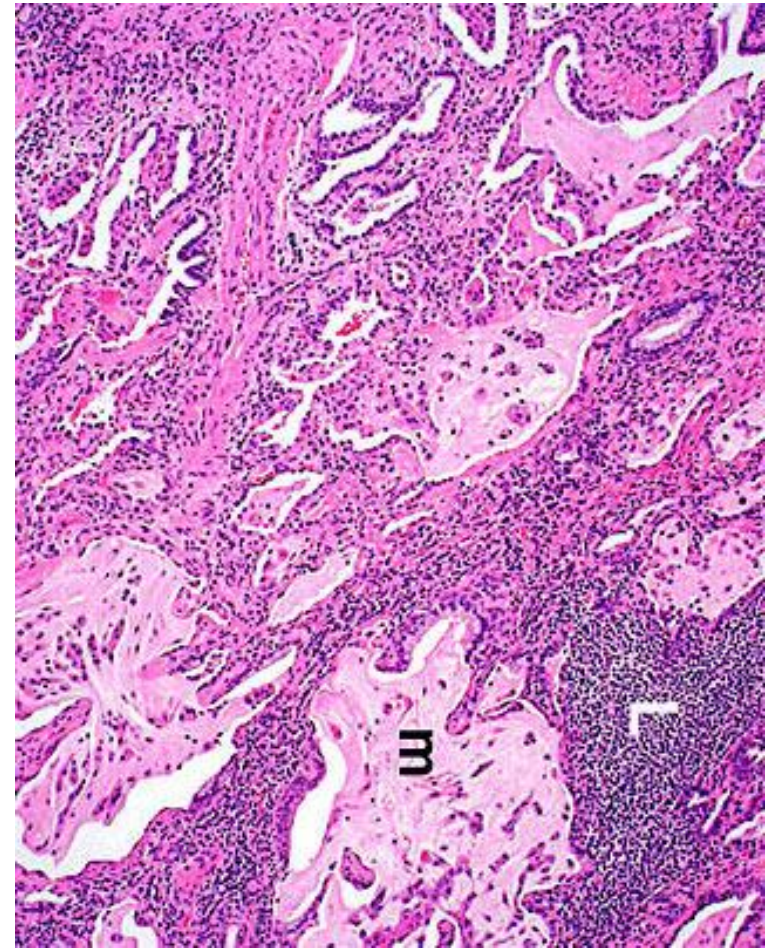
CRYPTOGENIC ORGANIZING PNEUMONIA (COP)

- IDIOPATHIC
- “BRONCHIOLITIS OBLITERANS”



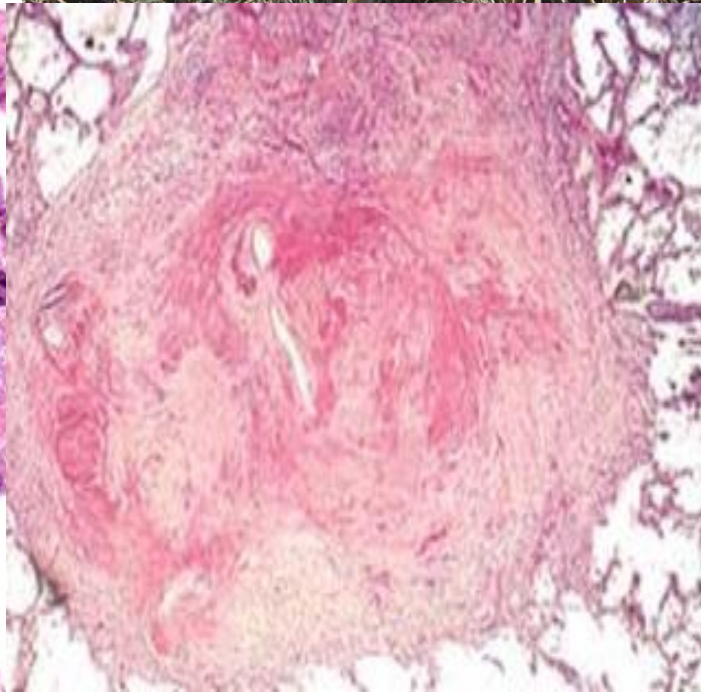
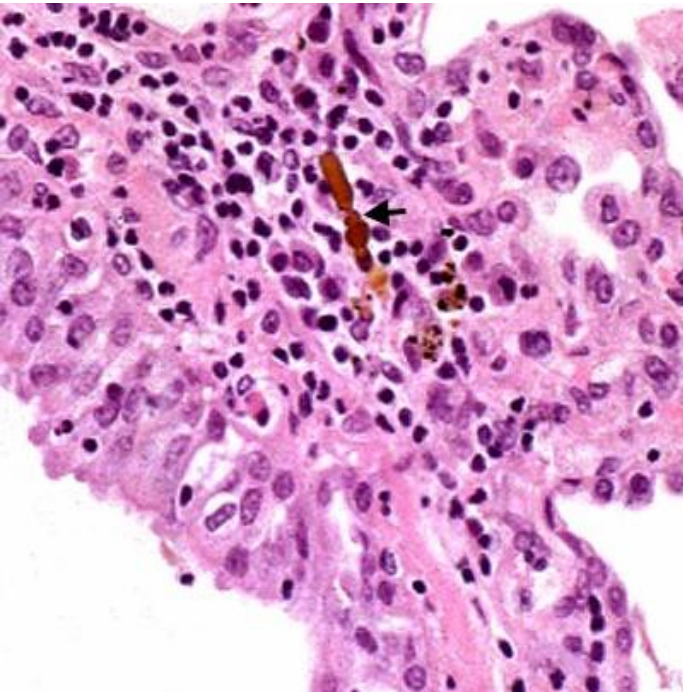
“COLLAGEN” VASCULAR DISEASES

- **Rheumatoid Arthritis**
- **SLE (“Lupus”)**
- **Progressive Systemic Sclerosis (Scleroderma)**



PNEUMOCONIOSES

- “OCCUPATIONAL”
- “COAL MINERS LUNG”
- DUST OR CHEMICALS OR ORGANIC MATERIALS
 - Coal (anthracosis)
 - Silica
 - Asbestos
- Be, FeO, BaSO₄, **CHEMO**
- HAY, FLAX, BAGASSE, INSECTICIDES, etc.



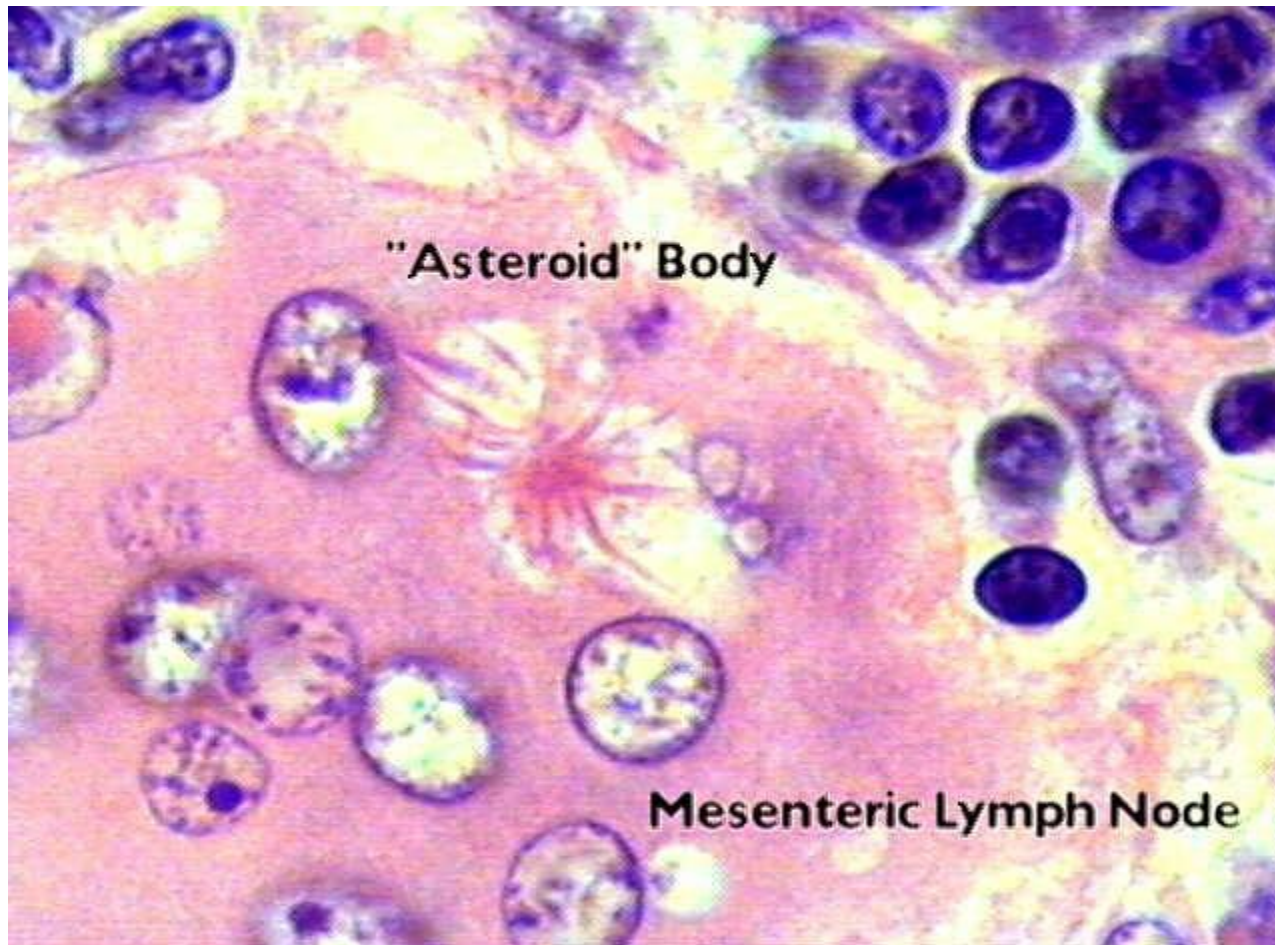
Coal,
“bagasse”,
asbestos,
silica
nodules,
and
asbestos,
going
clockwise.

GRANULOMATOUS

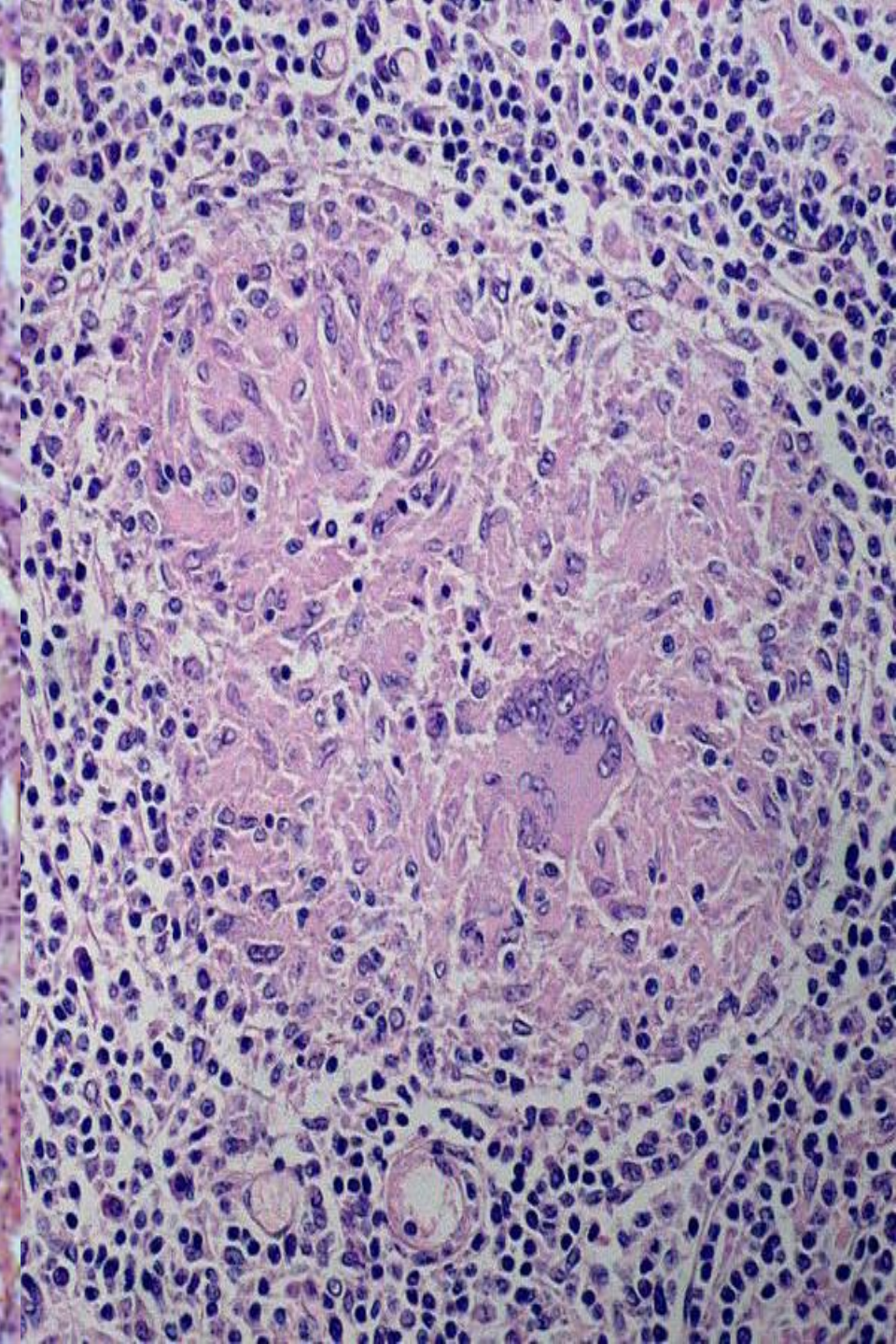
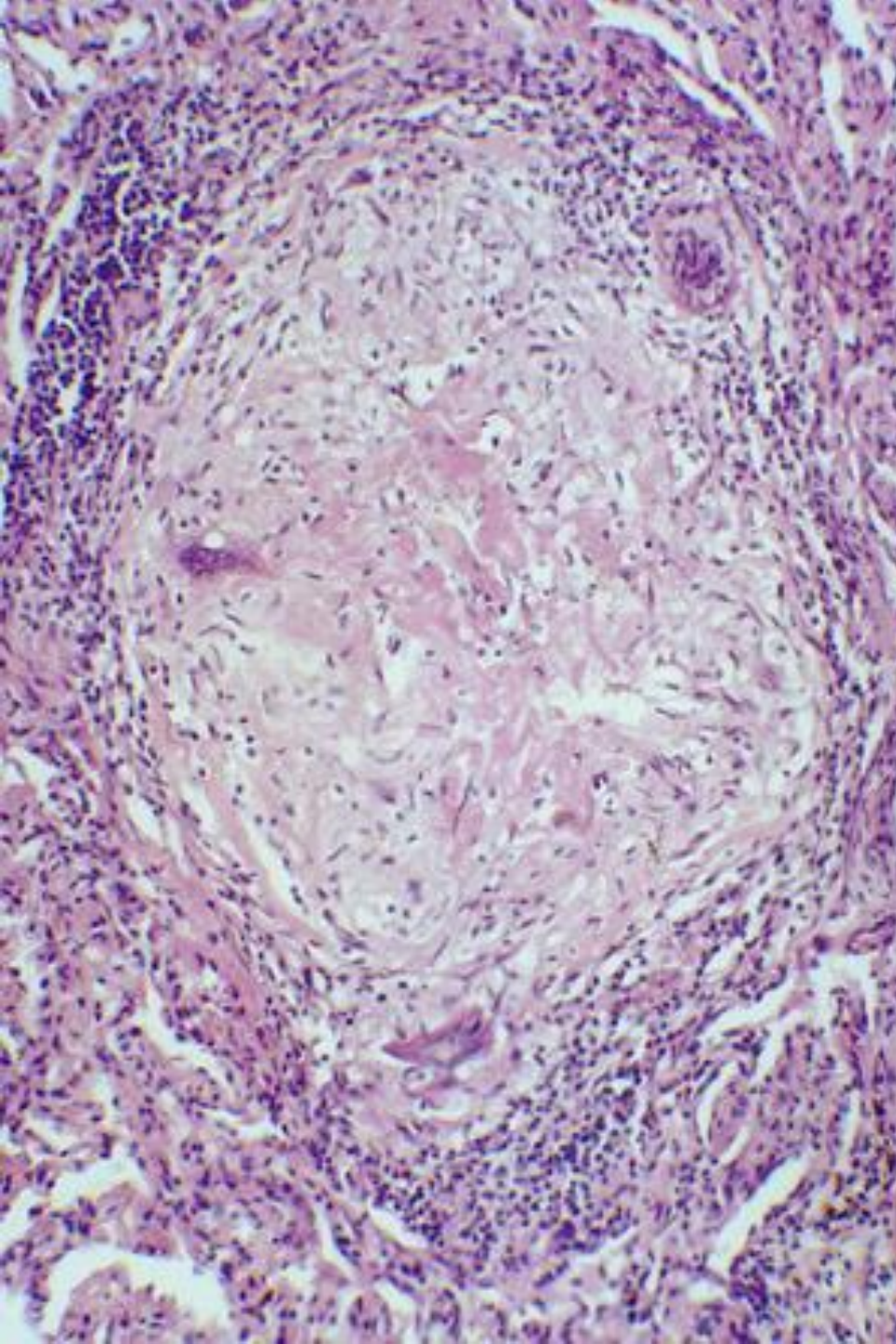
- **SARCOIDOSIS**, i.e., NON-caseating granulomas (IDIOPATHIC)
- **HYPERSENSITIVITY** (DUSTS, bacteria, fungi, Farmer's Lung, Pigeon Breeder's Lung)

SARCOIDOSIS

- **Mainly LUNG, but eye, skin or ANYWHERE**
- **UNKNOWN ETIOLOGY**
- **IMMUNE, GENETIC factors**
- **F>>M**
- **B>>W**
- **YOUNG ADULT BLACK WOMEN**



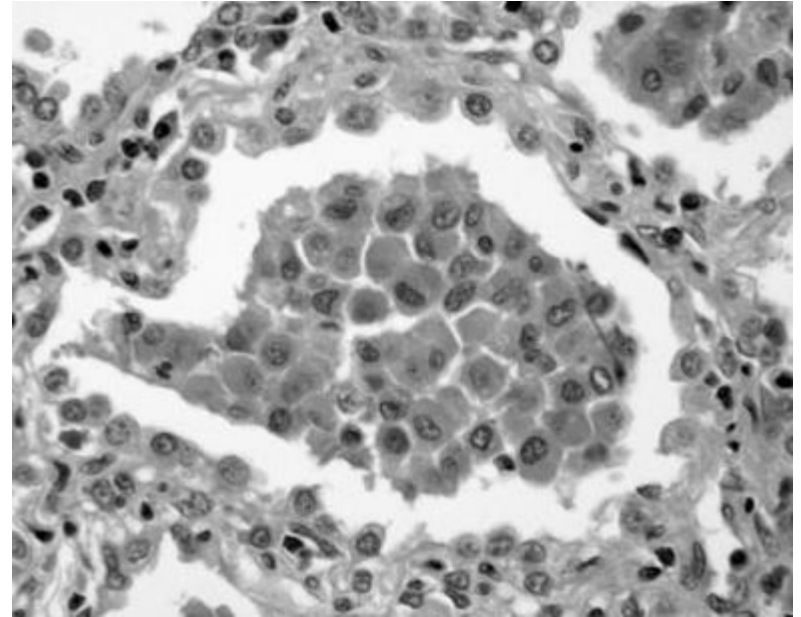
NON-Caseating Granulomas are the RULE
“Asteroid” bodies within these granulomas
are virtually diagnostic



SMOKING RELATED

- **DIP** (**D**esquamative **I**nterstitial **P**neumonia)

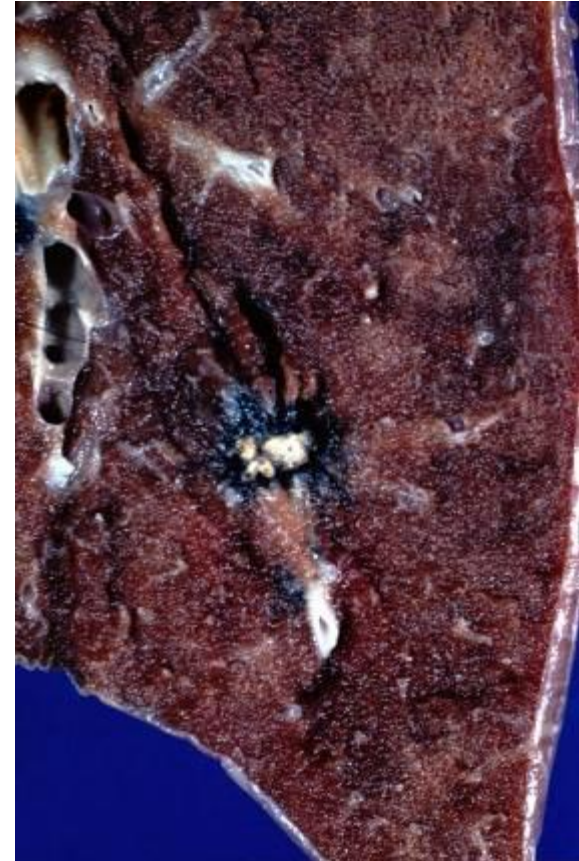- M>>F
- CIGARETTES
- 100% Survival



**Alveolar
Macrophages**

Pulmonary tuberculosis

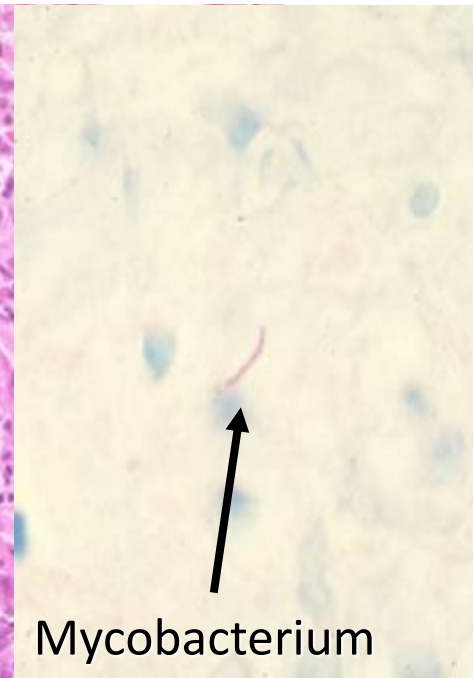
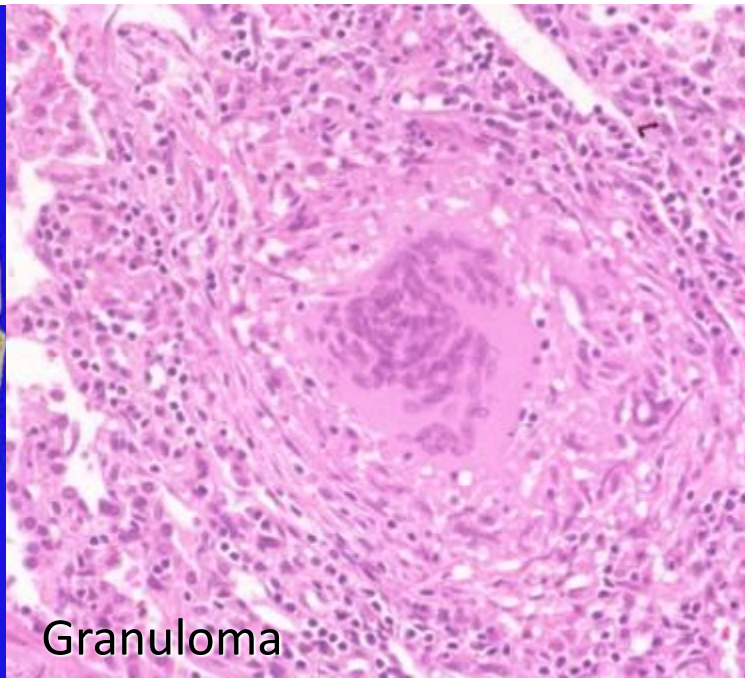
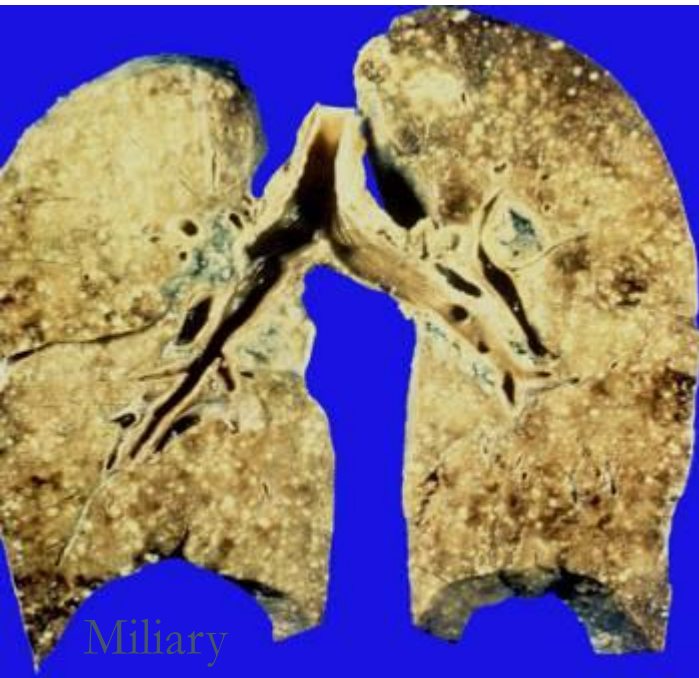
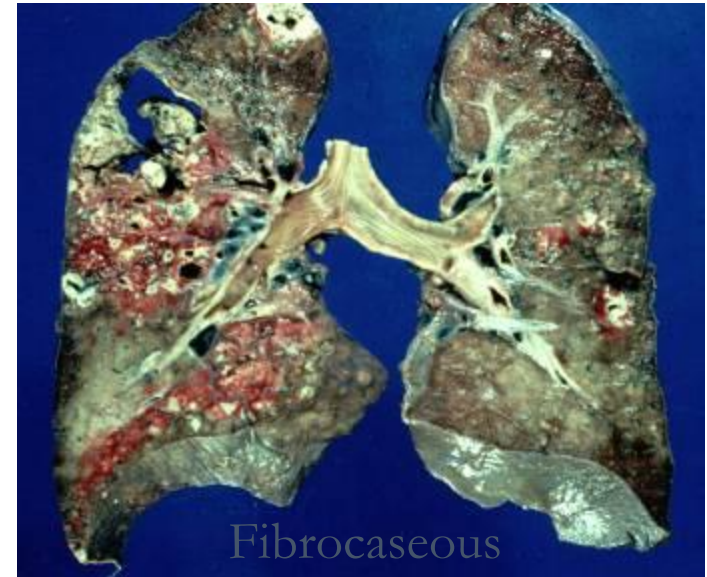
- Caused by *Mycobacterium tuberculosis*.
- Transmitted through inhalation of infected droplets
- Primary
 - Single granuloma within parenchyma and hilar lymph nodes (Ghon complex).
 - Infection does not progress (most common).
 - Progressive primary pneumonia
 - Miliary dissemination (blood stream).



Pulmonary tuberculosis

- **Secondary**

- Infection (mostly through reactivation) in a previously sensitized individual.
- **Pathology**
 - Cavitory fibrocaseous lesions
 - Bronchopneumonia
 - Miliary TB

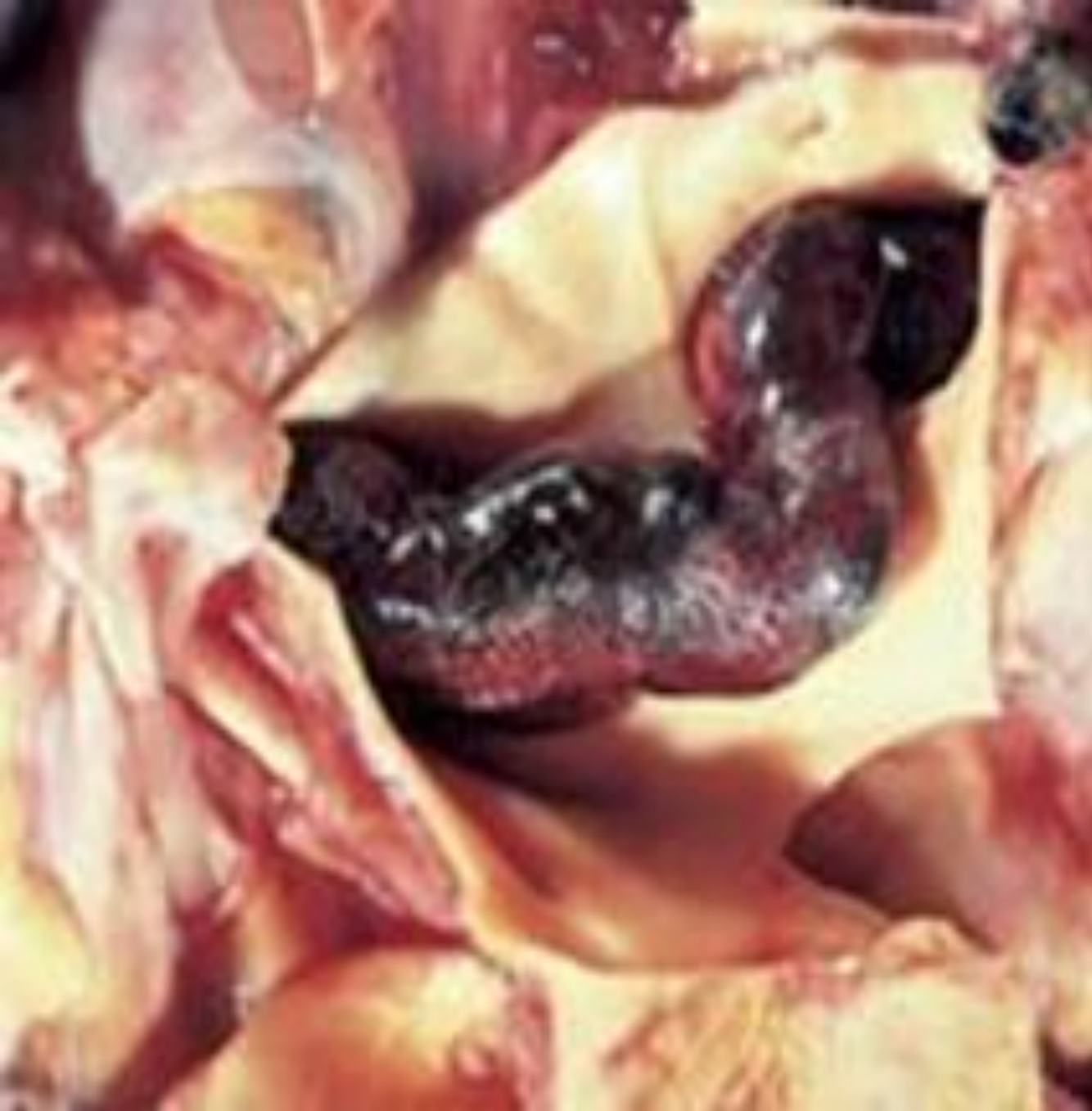

VASCULAR PULMONARY DISEASES

- **PULMONARY EMBOLISM** (with or usually WITHOUT infarction)
- **PULMONARY HYPERTENSION**, leading to cor pulmonale
- **HEMORRHAGIC SYNDROMES**
 - **GOODPASTURE SYNDROME**
 - **HEMOSIDEROSIS**, idiopathic
 - **WEGENER GRANULOMATOSIS**

P.E.

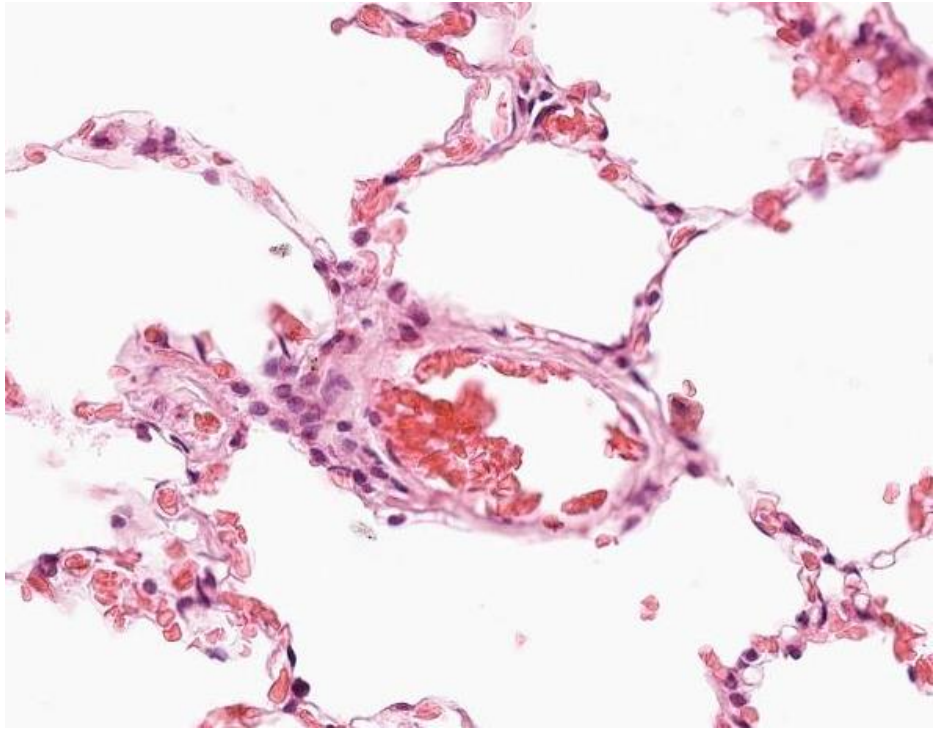
- Usually secondary to debilitated states with immobilization, or following surgery
- Usually deep leg and deep pelvic veins (DVT), NOT superficial veins
- Follows Virchow's triad, i.e., 1) flow problems, 2) endothelial disruption, 3) hypercoagulability
- Usually do NOT infarct, usually ventilate
- When they DO infarct, the infarct is hemorrhagic
- Decreased PO₂, acute chest pain, V/Q MIS-match
- DX: Chest CT, V/Q scan, angiogram
- RX: short term heparin, then long term coumadin



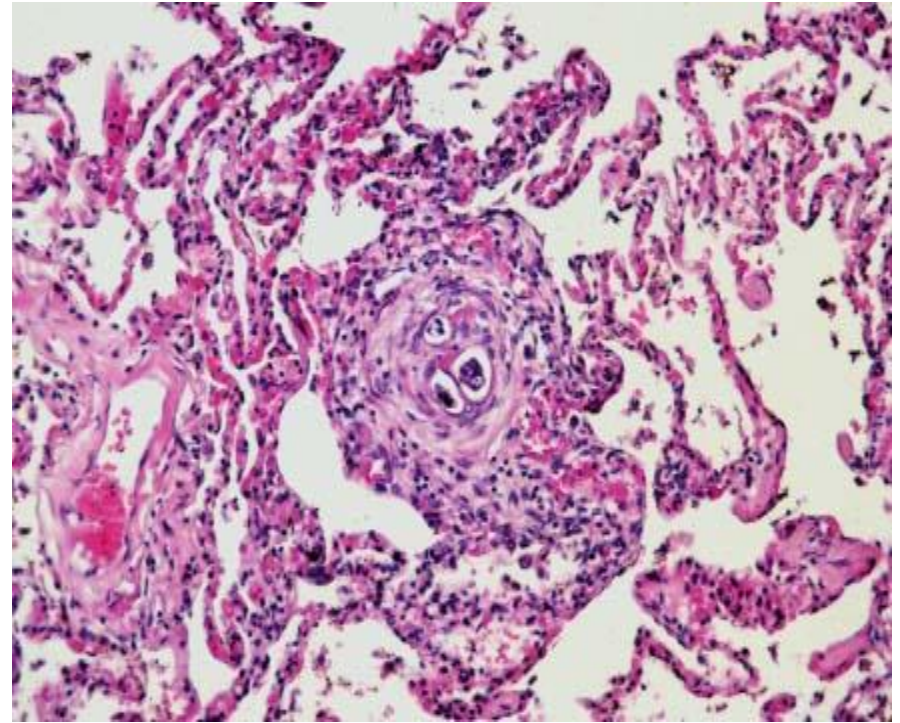
**GROSS
“saddle”
embolism**

PULMONARY HYPERTENSION

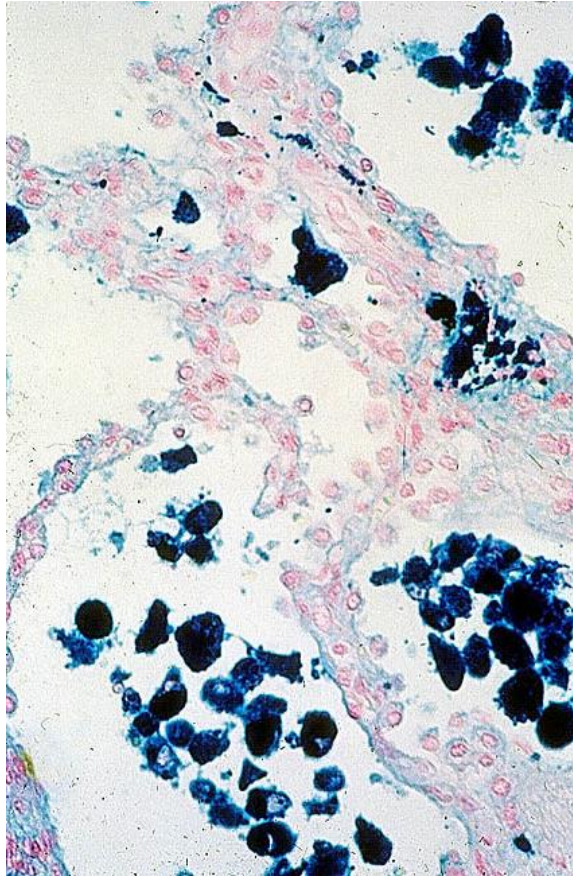
- **COPD, C"i"PD** (vicious cycle)
- **CHD** (Congenital HD, increased left atrial pressure)
- Recurrent **PEs**
- Autoimmune, e.g., PSS (**Scleroderma**), i.e., fibrotic pulmonary vasculature



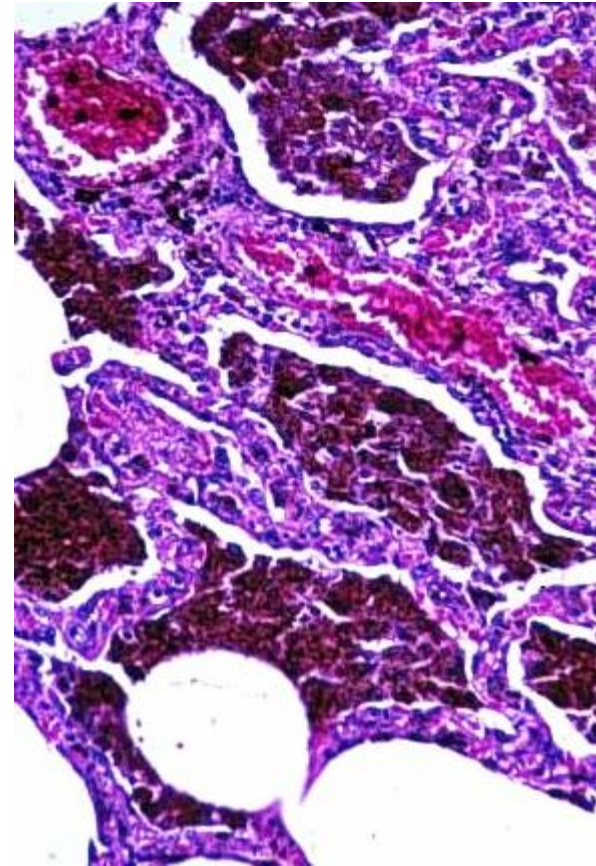
NORMAL pulmonary arteriole



VERY thickened arteriole in pulmonary hypertension

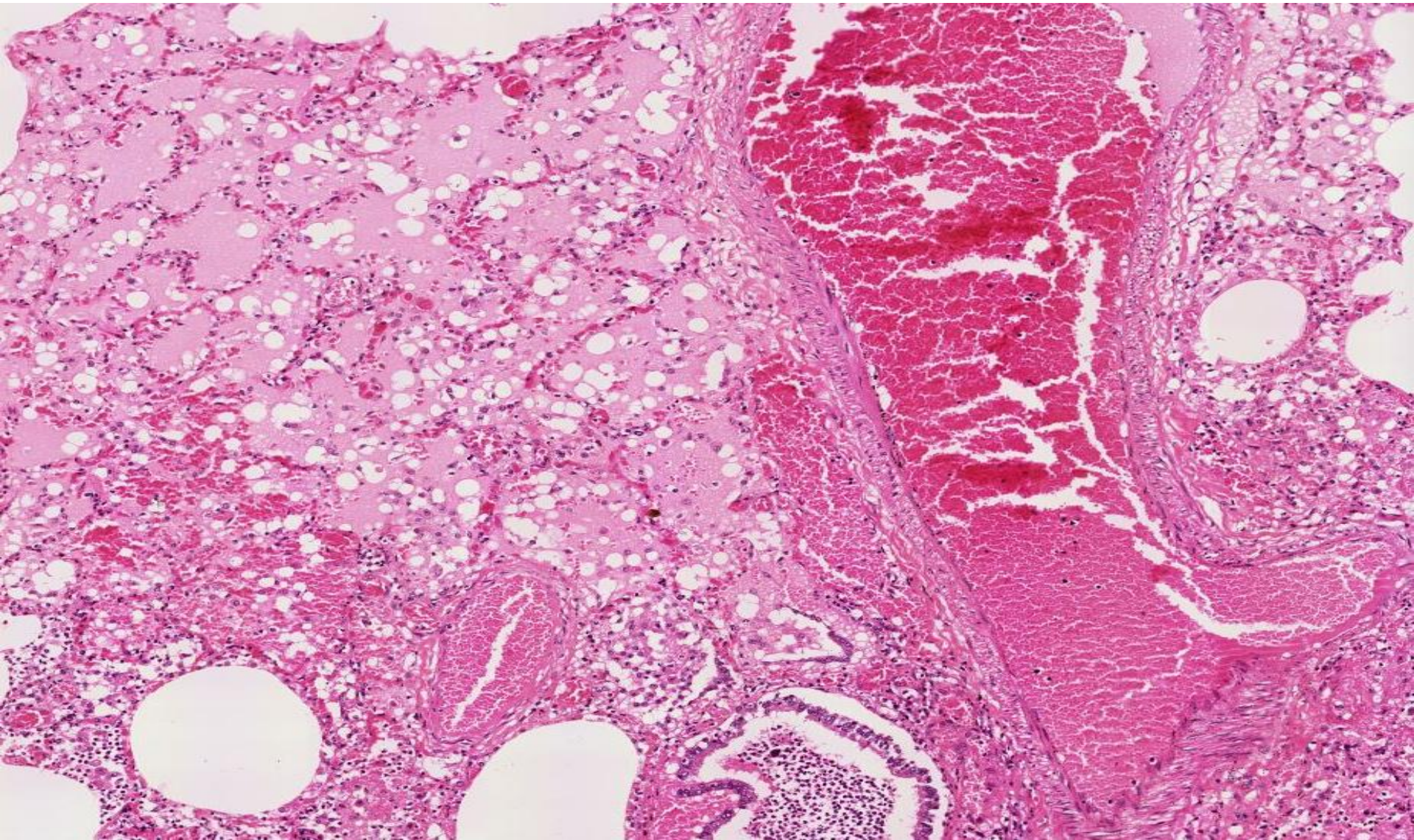


CHF, **CHRONIC**



IDIOPATHIC
PULMONARY
HEMOSIDEROSIS

PNEUMONIA



PULMONARY INFECTIONS

COMMUNITY-ACQUIRED BACTERIAL ACUTE PNEUMONIAS

Streptococcus Pneumoniae

Haemophilus Influenzae

Moraxella Catarrhalis

Staphylococcus Aureus

Klebsiella Pneumoniae

Pseudomonas Aeruginosa

Legionella Pneumophila

COMMUNITY-ACQUIRED ATYPICAL (VIRAL AND MYCOPLASMAL) PNEUMONIAS

Morphology.

Clinical Course.

Influenza Infections

Severe Acute Respiratory Syndrome (SARS)

NOSOCOMIAL PNEUMONIA

ASPIRATION PNEUMONIA

LUNG ABSCESS

Etiology and Pathogenesis.

CHRONIC PNEUMONIA

Histoplasmosis, Morphology

Blastomycosis, Morphology

Coccidioidomycosis, Morphology

PNEUMONIA IN THE IMMUNOCOMPROMISED HOST

PULMONARY DISEASE IN HUMAN IMMUNODEFICIENCY VIRUS INFECTION

BASIC CONSIDERATIONS

- PNEUMONIA vs. PNEUMONITIS
- DIFFERENTIATION from INJURIES, OBSTRUCTIVE DISEASES, RESTRICTIVE DISEASES, VASCULAR DISEASES
- DIFFERENTIATION FROM NEOPLASMS
- CLASSICAL STAGES of INFLAMMATION
- LOBAR- vs. BRONCHO-
- INTERSTITIAL vs. ALVEOLAR
- COMMUNITY vs. NOSOCOMIAL
- ETIOLOGIC AGENTS vs. HOST IMMUNITY
- 2 PRESENTING SYMPTOMS
- 2 DIAGNOSTIC METHODS
- **ANY ORGANISM CAN CAUSE PNEUMONIA!!!**

PREDISPOSING FACTORS

- **LOSS OF COUGH REFLEX**
- **DIMINISHED MUCIN or CILIA FUNCTION**
- **ALVEOLAR MACROPHAGE INTERFERENCE**
- **VASCULAR FLOW IMPAIRMENTS**
- **BRONCHIAL FLOW IMPAIRMENTS**

Although pneumonia is one of the most common causes of death, it usually does NOT occur in healthy people spontaneously

Classifications of PNEUMONIAS

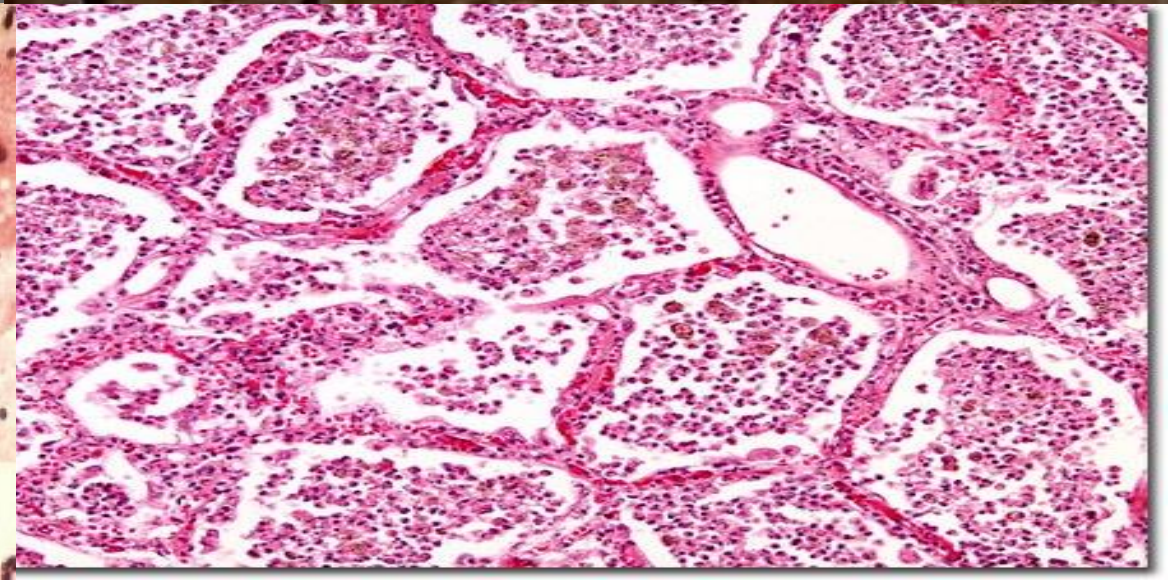
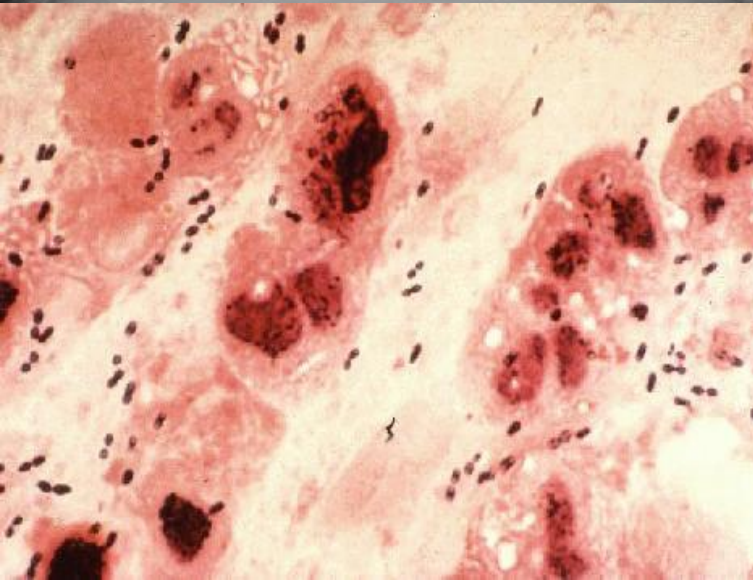
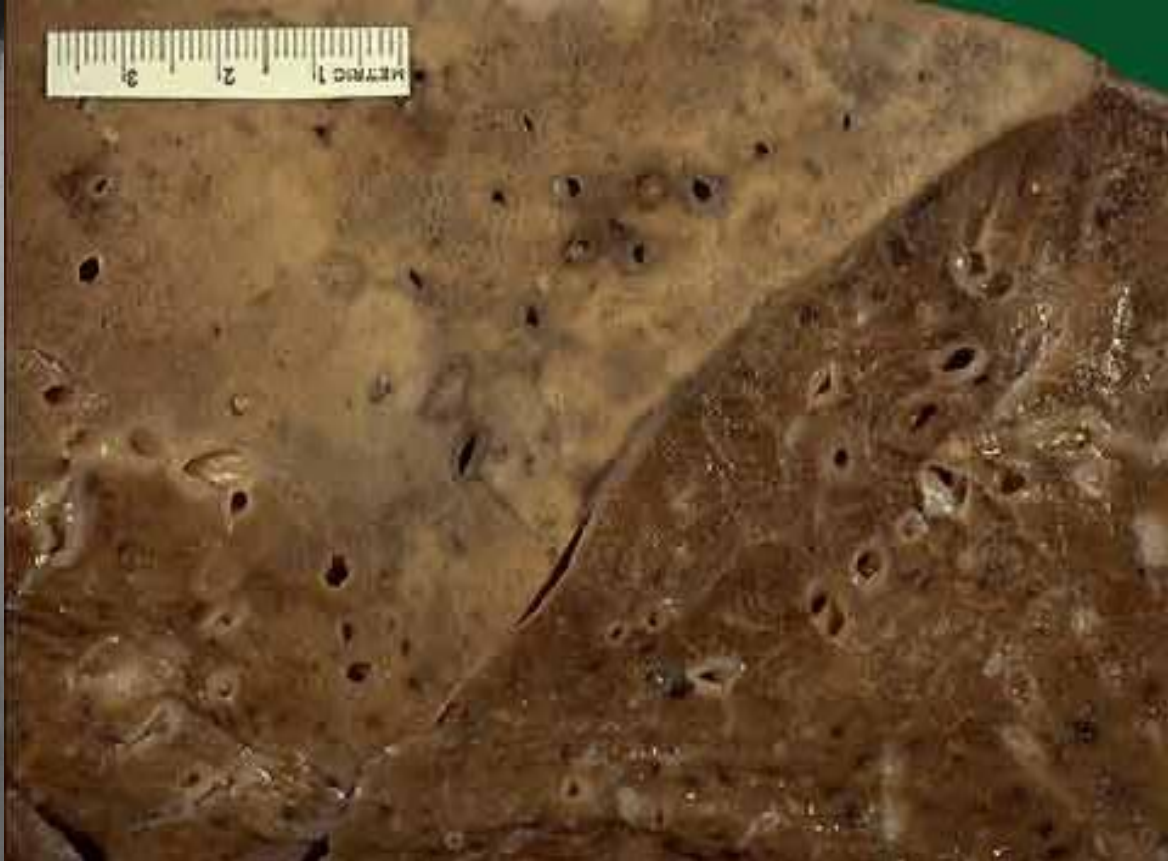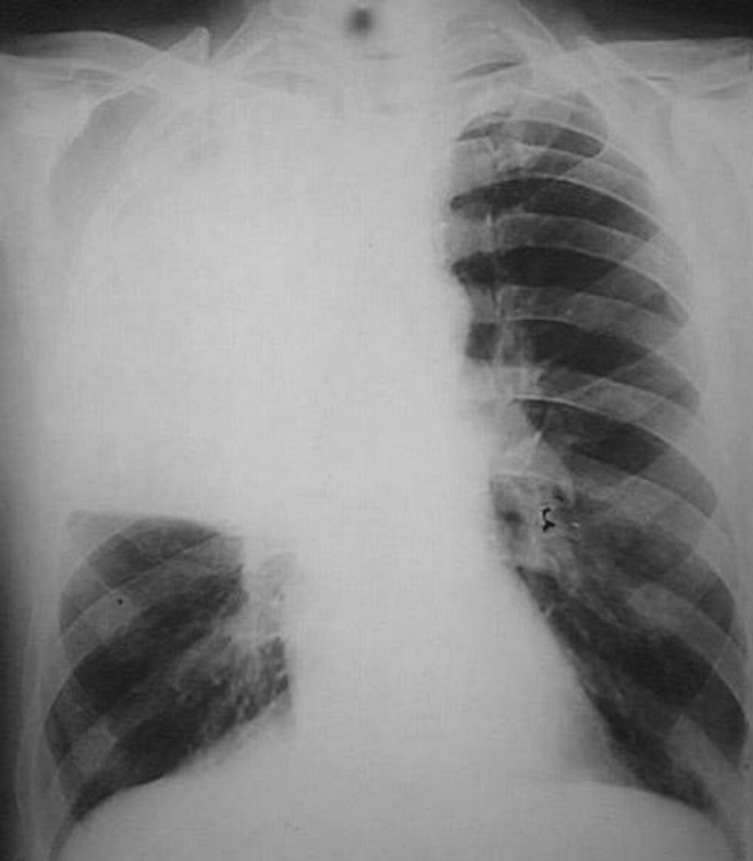
- **COMMUNITY ACQUIRED**
- **COMMUNITY ACQUIRED, ATYPICAL**
- **NOSOCOMIAL**
- **ASPIRATION**
- **CHRONIC**
- **NECROTIZING/ABSCESS FORMATION**
- **PNEUMONIAS in IMMUNOCOMPROMISED HOSTS**

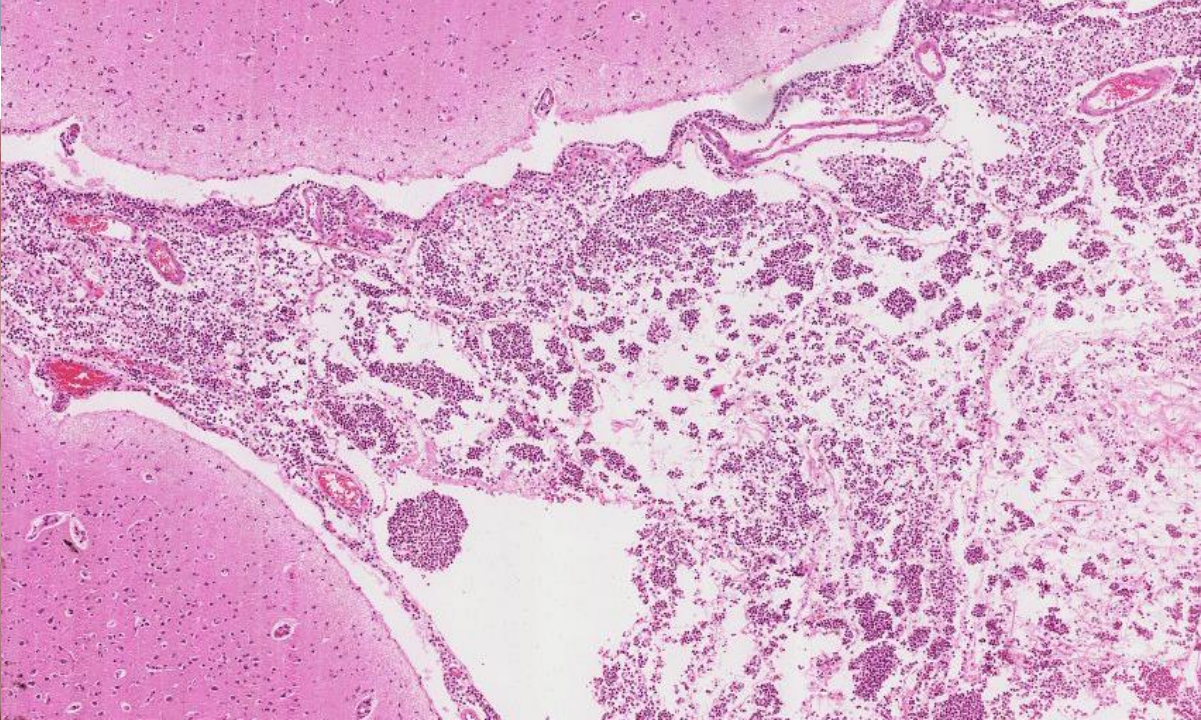
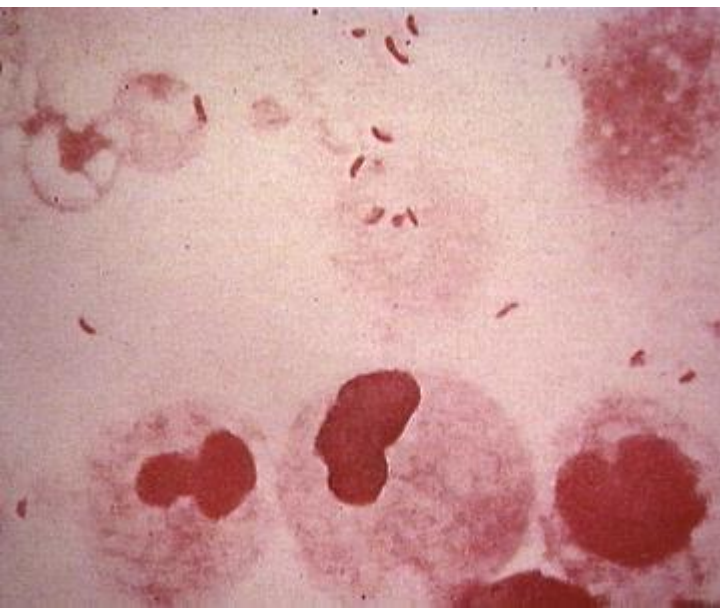
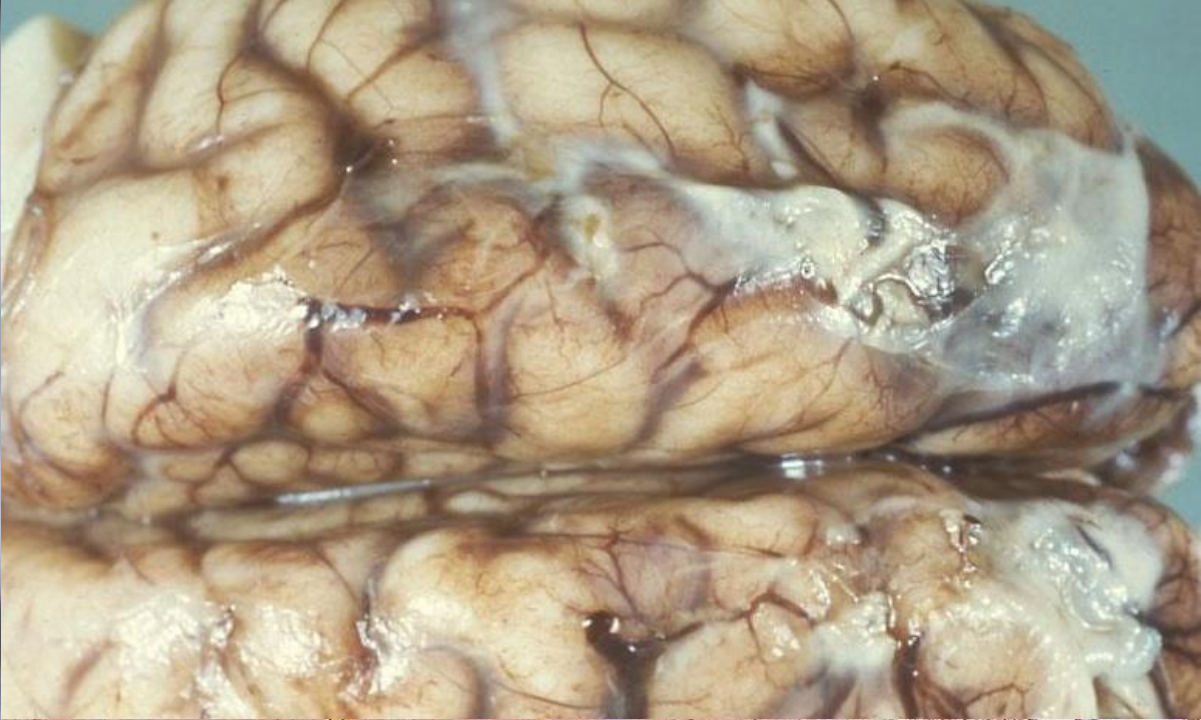
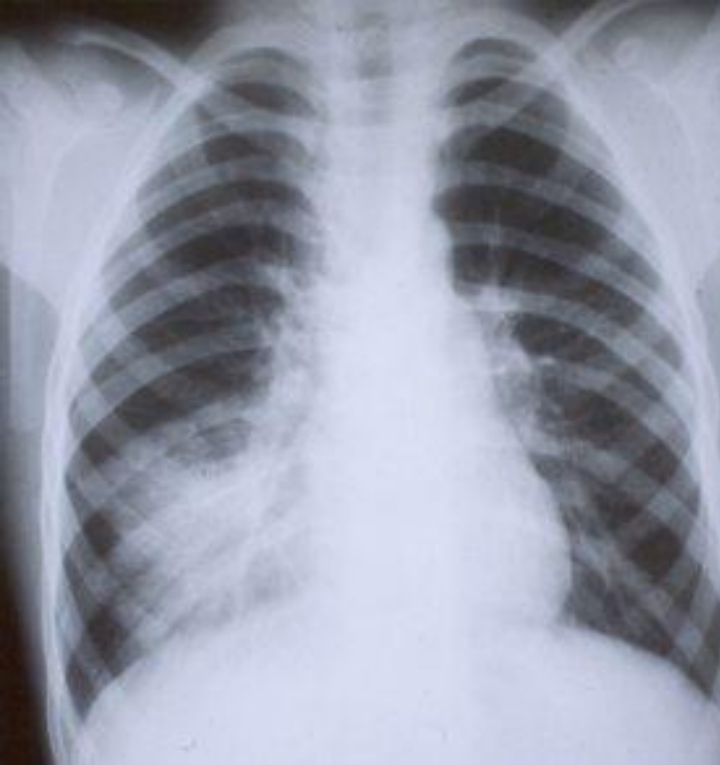COMMUNITY ACQUIRED

- **STREPTOCOCCUS PNEUMONIAE (i.e., “diplococcus”)**
- **HAEMOPHILUS INFLUENZAE (“H-Flu”)**
- **MORAXELLA**
- **STAPHYLOCOCCUS (STAPH)**
- **KLEBSIELLA PNEUMONIAE**
- **PSEUDOMONAS AERUGINOSA**
- **LEGIONELLA PNEUMOPHILIA**

STREPTOCOCCUS

- **The classic LOBAR pneumonia**
- **Normal flora in 20% of adults**
- **Only 20% of victims have + blood cultures**
- **“Penicillins” are often 100% curative**
- **Vaccines are often 100% preventive**



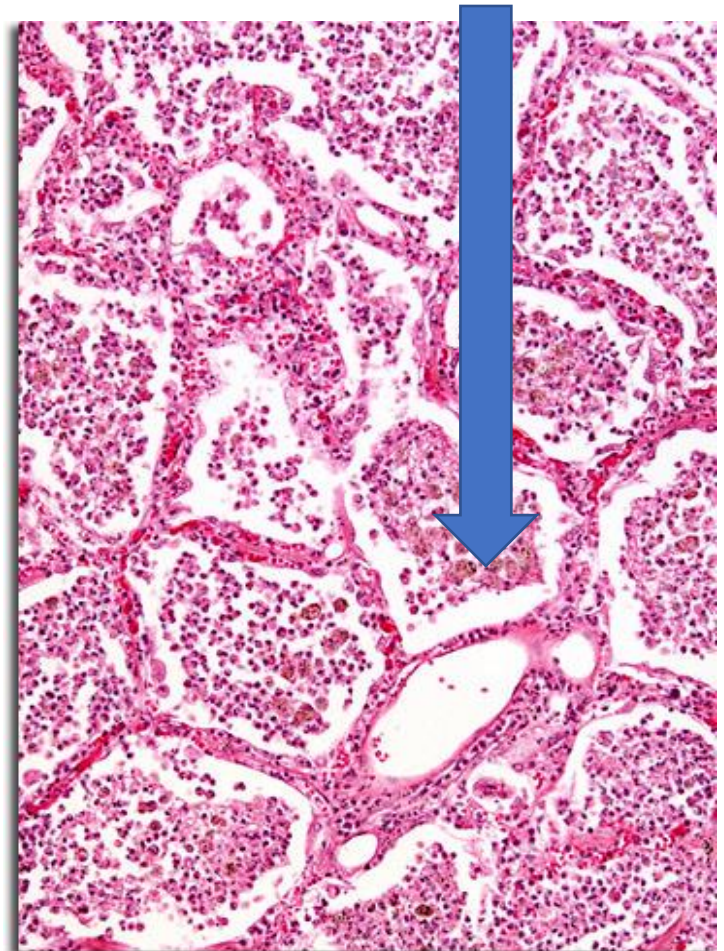
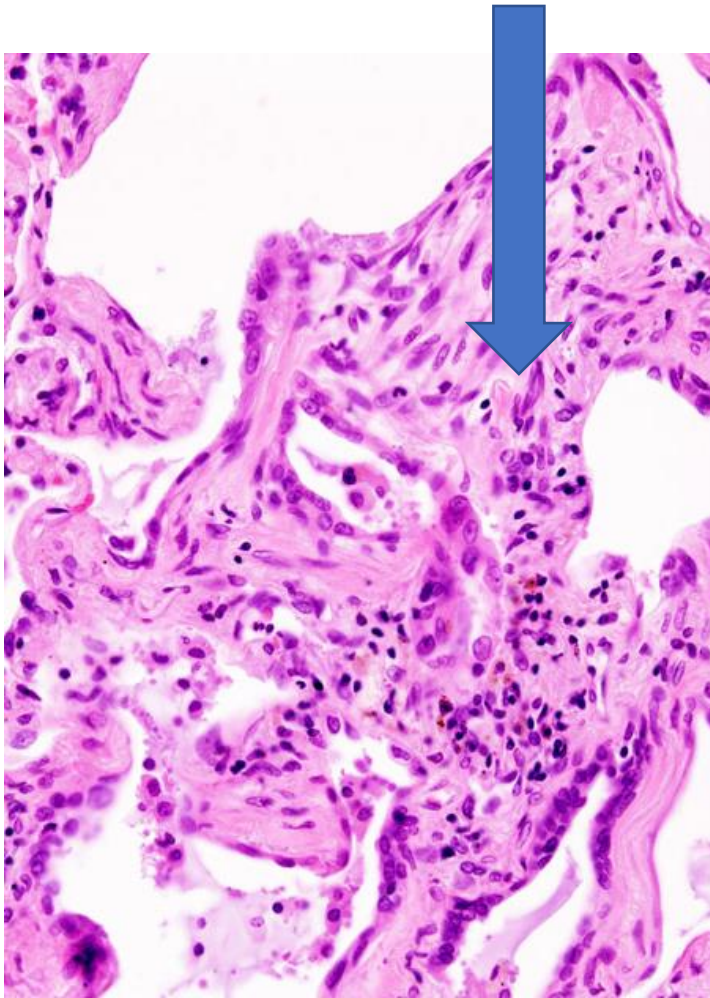


MORPHOLOGY

- ACUTE
- ORGANIZING
- CHRONIC
- FIBROSIS vs. FULL RESOLUTION
- “HEPATIZATION”, RED vs. GREY
- CONSOLIDATION
- “INFILTRATE”, XRAY vs. HISTOPATH
- Loss of “CREPITANCE”

VIRAL PNEUMONIAS

- Frequently “interstitial”, NOT alveolar



ASPIRATION PNEUMONIAS

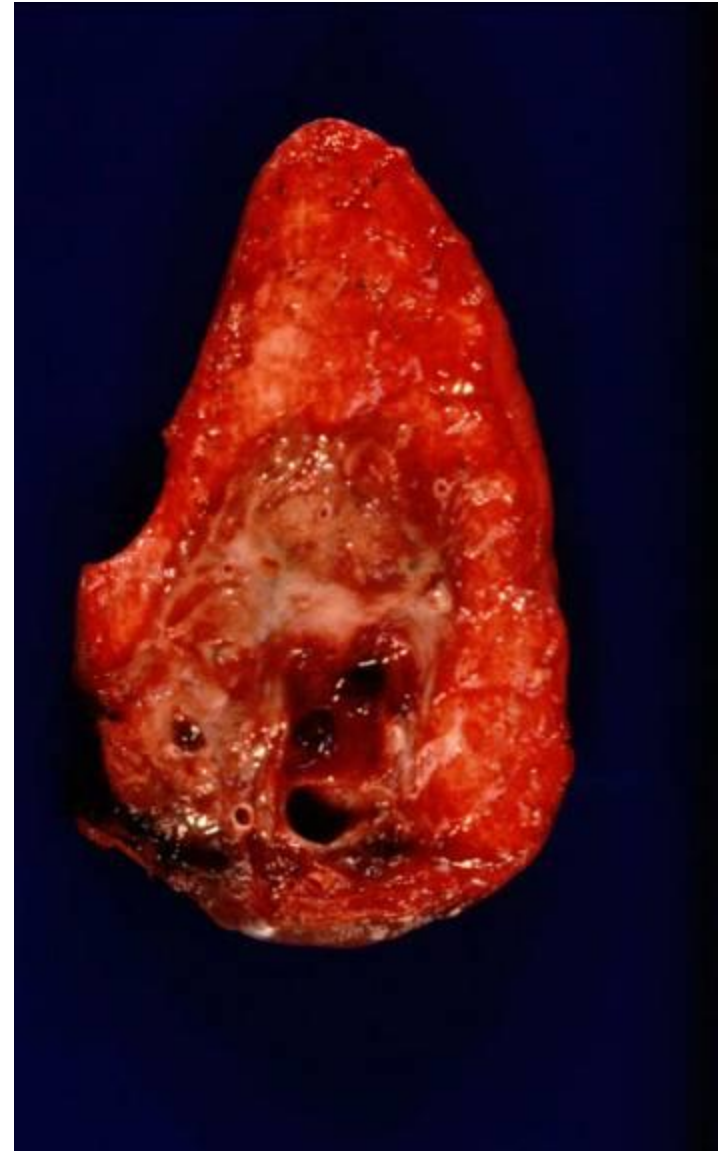- UNCONSCIOUS PATIENTS
- PATIENTS IN PROLONGED BEDREST
- LACK OF ABILITY TO SWALLOW OR GAG
- USUALLY CAUSED BY **ASPIRATION OF GASTRIC CONTENTS**
- POSTERIOR LOBES (gravity dependent) MOST COMMONLY INVOLVED, ESPECIALLY THE **SUPERIOR SEGMENTS** of the **LOWER LOBES**
- Often lead to **ABSCESSSES**

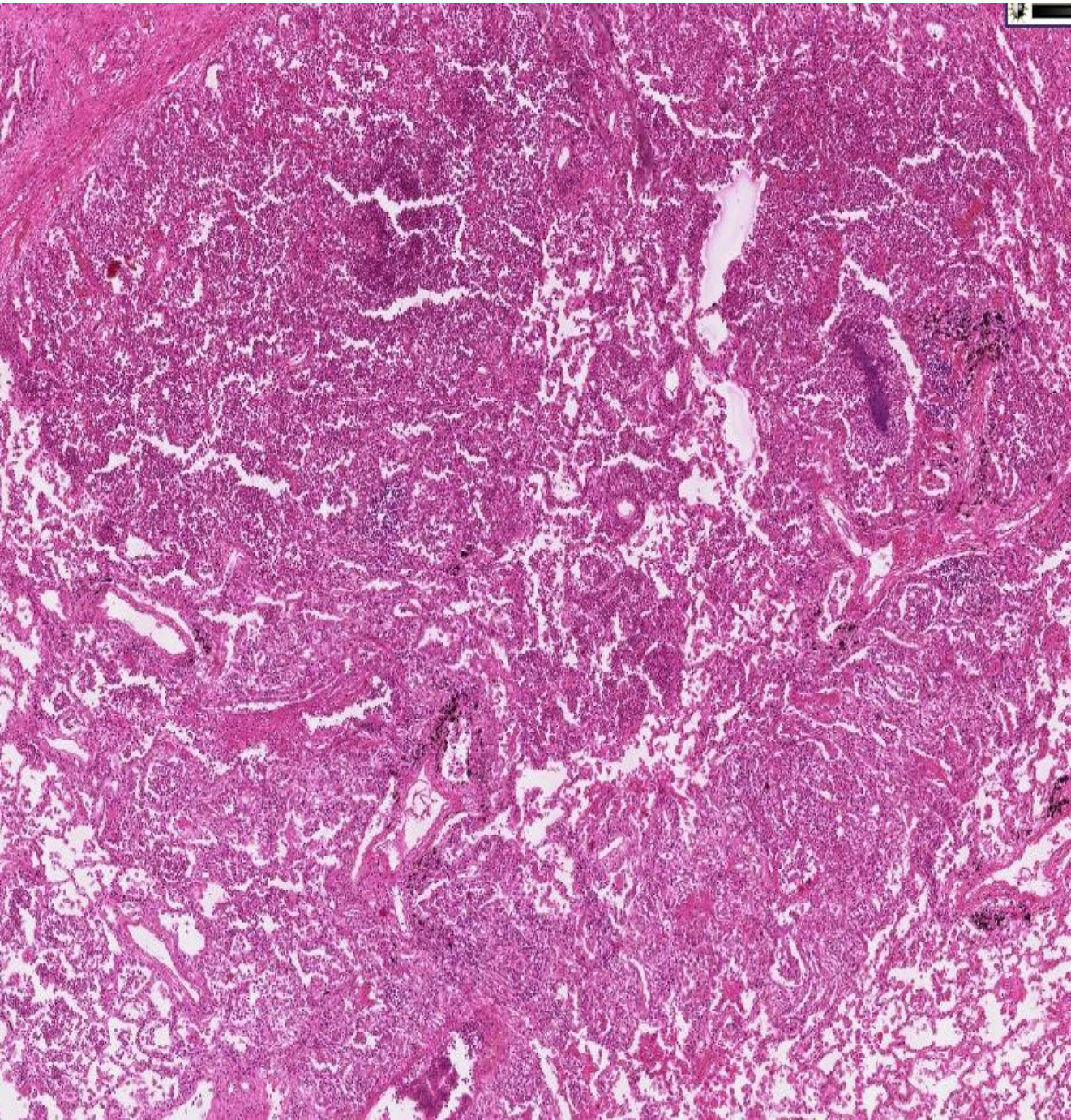
LUNG ABSCESSES

- **ASPIRATION**
- **SEPTIC EMBOLIZATION**
- **NEOPLASIA**
- From **NEIGHBORING** structures:
 - ESOPHAGUS
 - SPINE
 - PLEURA
 - DIAPHRAGM
- **ANY pneumonia** which is severe and destructive, and UN-treated enough

Lung abscess

- **Localized suppurative necrosis**
- **Organisms commonly cultured:**
 - Staphylococci
 - Streptococci
 - Gram-negative
 - Anaerobes
 - Frequent mixed infections
- **Pathogenesis:**
 - Aspiration
 - Pneumonia
 - Septic emboli
 - Tumors
 - Direct infection





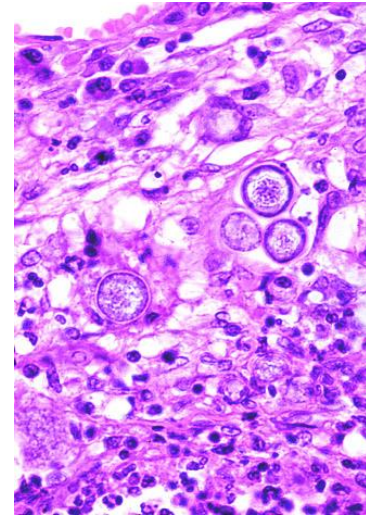
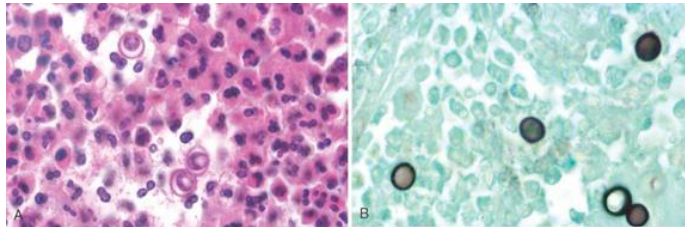
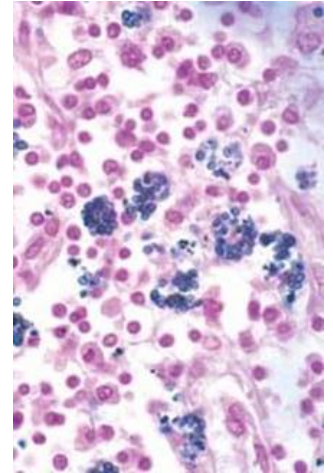
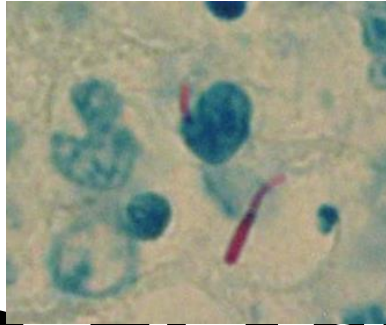
An abscess
can be
thought of
as a
pneumonia
in which all
of the
normal lung
outline can
no longer be
seen, and
there is 100%
pus.

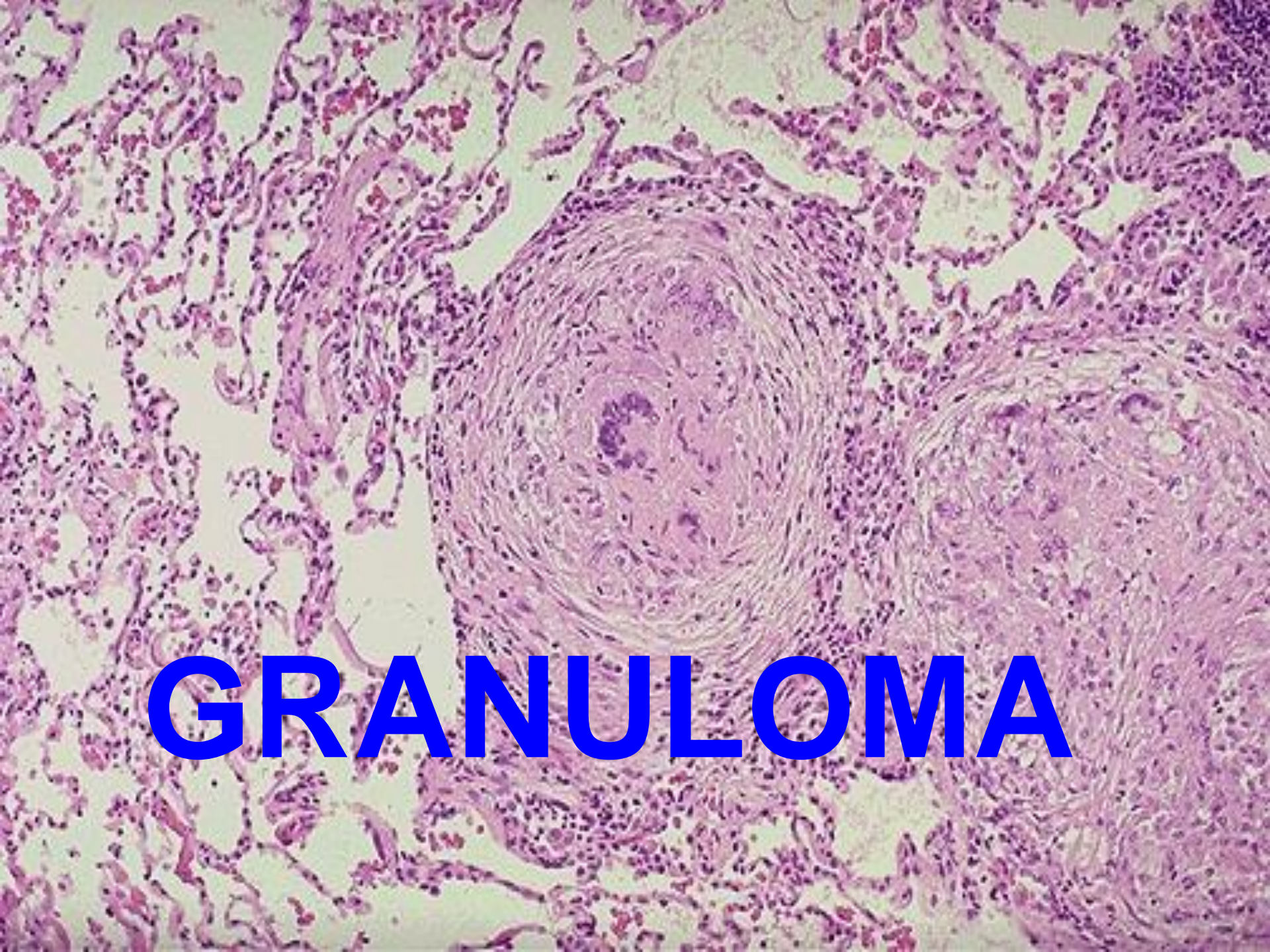
CHRONIC Pneumonias

- USUALLY NOT persistences of the community or nosocomial bacterial infections, but CAN BE, at least histologically
- Often SYNONYMOUS with the 4 classic fungal or **granulomatous** pulmonary infections infections, i.e., TB, Histo-, Blasto-, Coccidio-
- If you see pulmonary granulomas, think of a CHRONIC process, often years

CHRONIC Pneumonias

- TB
- HISTO-PLASMOSIS
- BLASTO-MYCOSIS
- COCCIDIOIDOMYCOSIS





GRANULOMA

LUNG TUMORS

- Benign, malignant, epithelial, mesenchymal, but 90% are CARCINOMAS
- BIGGEST USA killer. Why? Ans: Prevalence not as high as prostate or breast but mortality higher. Only 15% 5 year survival.
- **TOBACCO** has polycyclic aromatic hydrocarbons, such as benzopyrene, anthracenes, radioactive isotopes
- Radiation, asbestos, radon
- C-MYC, K-RAS, EGFR, HER-2/neu

PATHOGENESIS

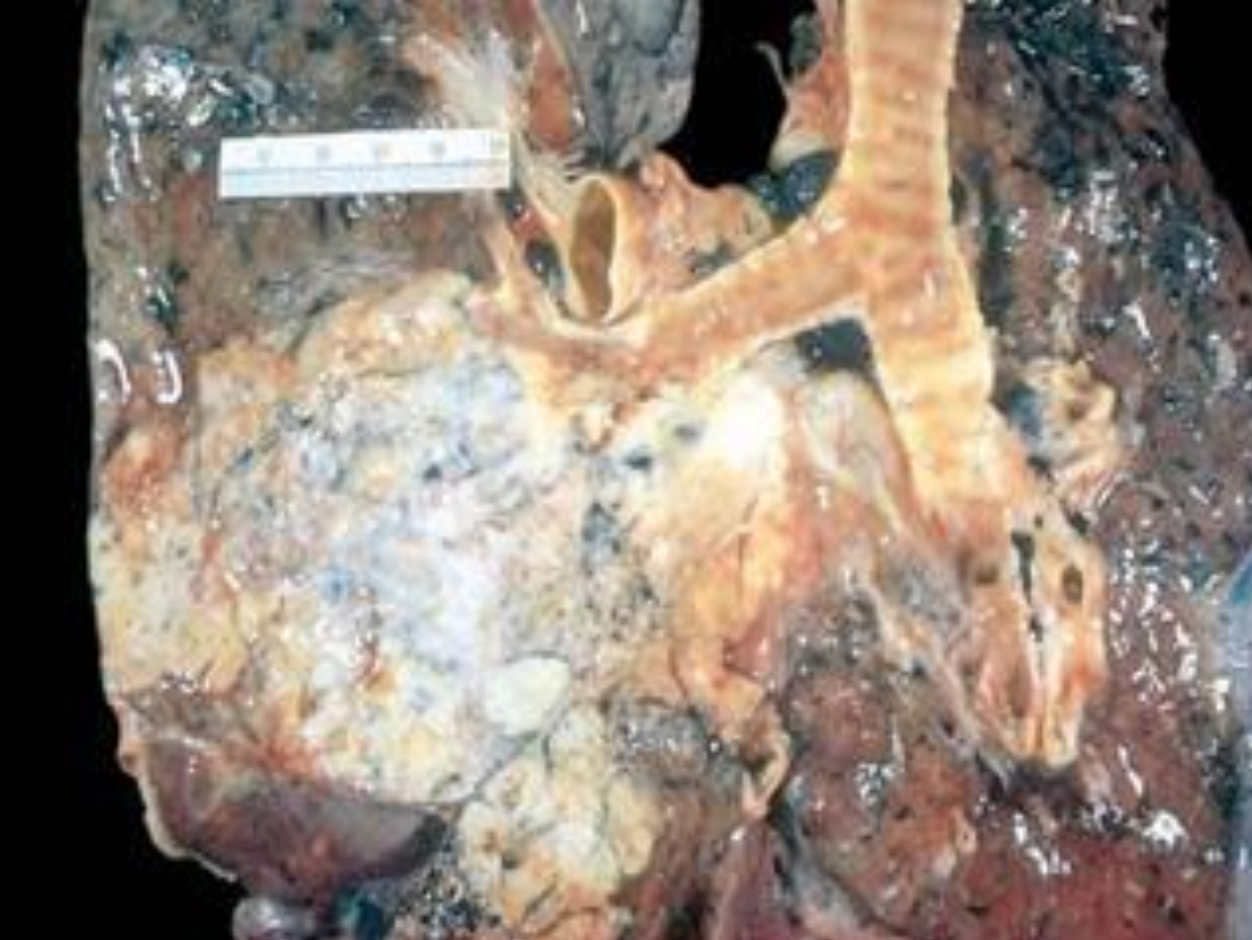- **NORMAL BRONCHIAL MUCOSA**
- **METAPLASTIC/DYSPLASTIC MUCOSA**
- **CARCINOMA-IN-SITU (squamous, adeno)**
- **INFILTRATING (i.e., “INVASIVE”) cancer**

TWO TYPES

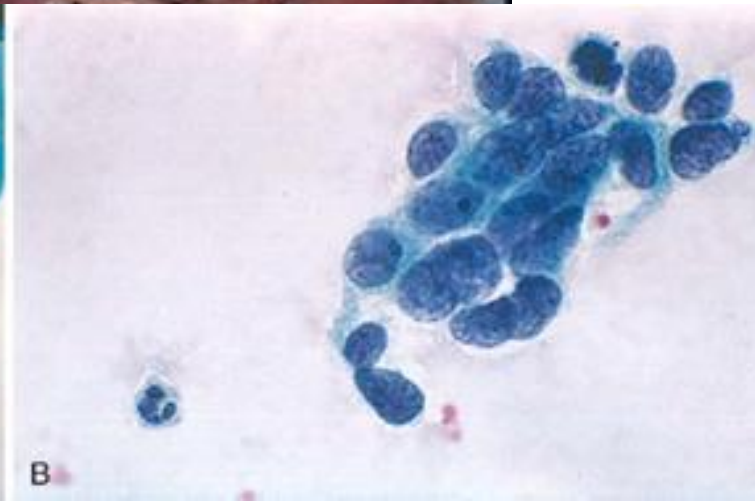
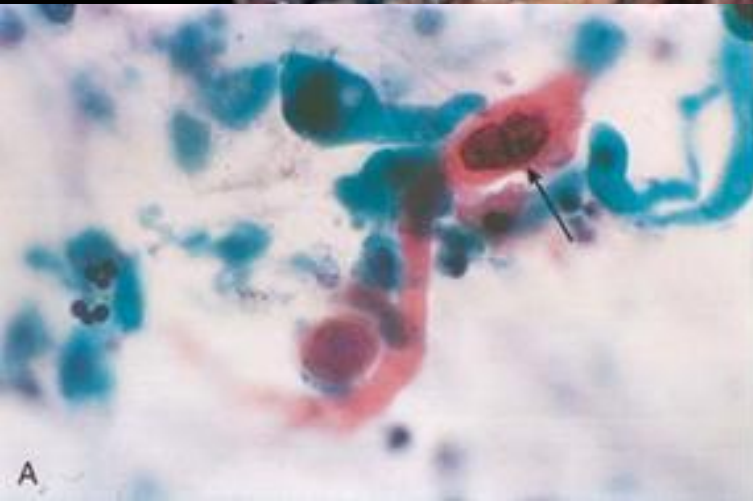
- **NON-SMALL CELL**
 - SQUAMOUS CELL CARCINOMA
 - ADENOCARCINOMA
 - LARGE CELL CARCINOMA
- **SMALL CELL CARCINOMA**

The BIG list

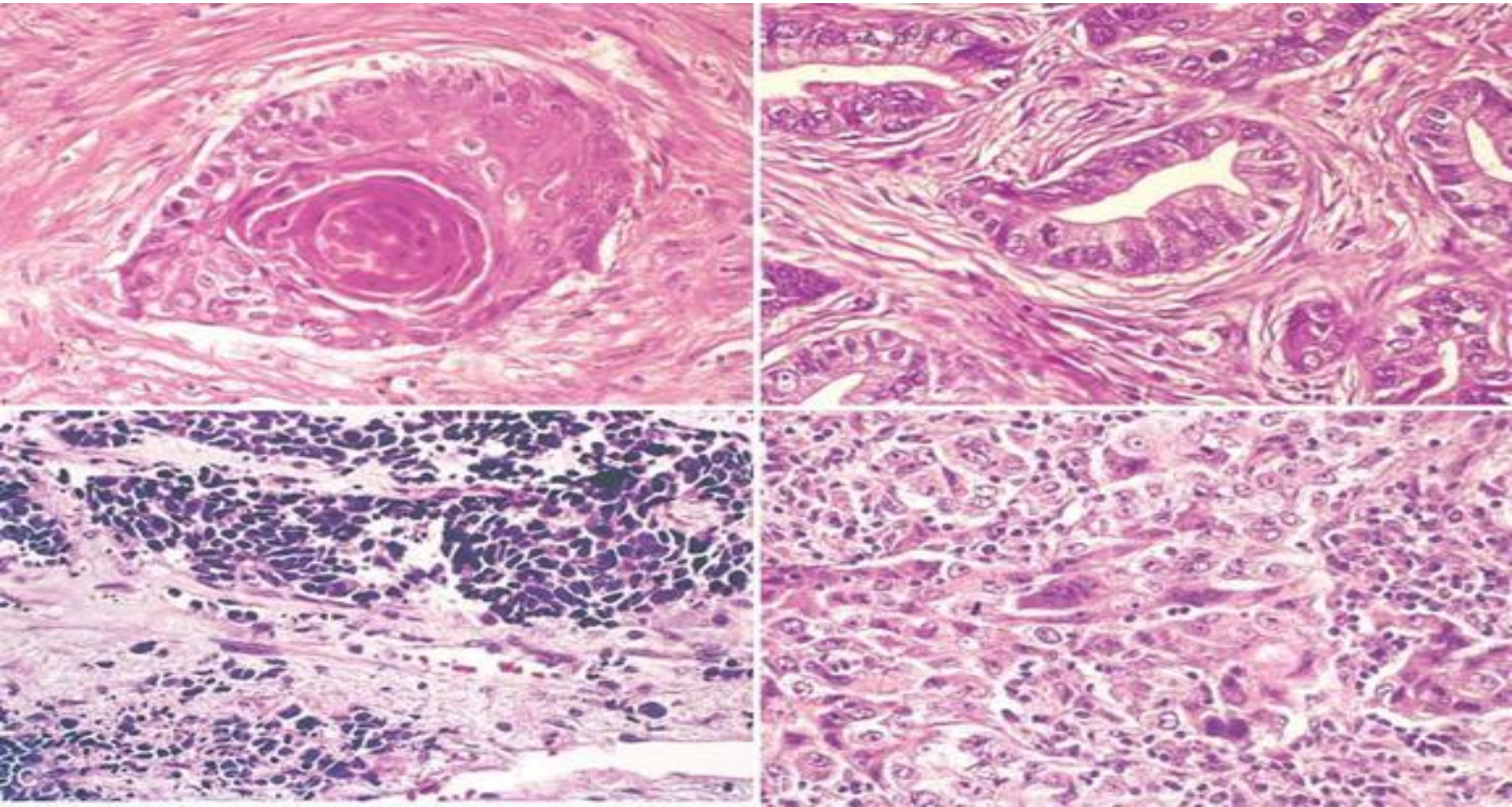
- Squamous cell carcinoma
- Small cell carcinoma
- Combined small cell carcinoma
- Adenocarcinoma: Acinar, papillary, bronchioloalveolar, solid, mixed subtypes
- Large cell carcinoma
- Large cell neuroendocrine carcinoma
- Adenosquamous carcinoma
- Carcinomas with pleomorphic, sarcomatoid, or sarcomatous elements
- Carcinoid tumor: Typical, atypical
- Carcinomas of salivary gland type
- Unclassified carcinoma



The classical squamous cell carcinoma starting in a large bronchus centrally, with bronchial obstruction. Adenocarcinomas tend to be more peripheral. Note the features of malignant cells on sputum cytology.



Name the four most common histologic patterns of lung carcinoma and explain why!
Squamous, adeno, large, small.



LOCAL effects of LUNG CANCER

Clinical Feature	Pathologic Basis
Pneumonia, abscess, lobar collapse	Tumor obstruction of airway
Lipid pneumonia	Tumor obstruction; accumulation of cellular lipid in foamy macrophages
Pleural effusion	Tumor spread into pleura
Hoarseness	Recurrent laryngeal nerve invasion
Dysphagia	Esophageal invasion
Diaphragm paralysis	Phrenic nerve invasion
Rib destruction	Chest wall invasion
SVC syndrome	SVC compression by tumor
Horner syndrome	Sympathetic ganglia invasion
Pericarditis, tamponade	Pericardial involvement
SVC, superior vena cava.	

METASTATIC TUMORS

- **LUNG** is the **MOST COMMON** site for all metastatic tumors, regardless of site of origin
- It is the site of **FIRST CHOICE** for **metastatic sarcomas** for purely anatomic reasons!

PLEURA

- **PLEURITIS**
- **PNEUMOTHORAX**
- **EFFUSIONS**
 - **HYDROTHORAX**
 - **HEMOTHORAX**
 - **CHYLOTHORAX**
- **MESOTHELIOMAS**

PLEURITIS

- Usual bacteria, viruses, etc.
- Infarcts
- Lung abscesses, empyema
- TB
- “Collagen” diseases, e.g., RA, SLE
- Uremia
- Metastatic

PNEUMOTHORAX

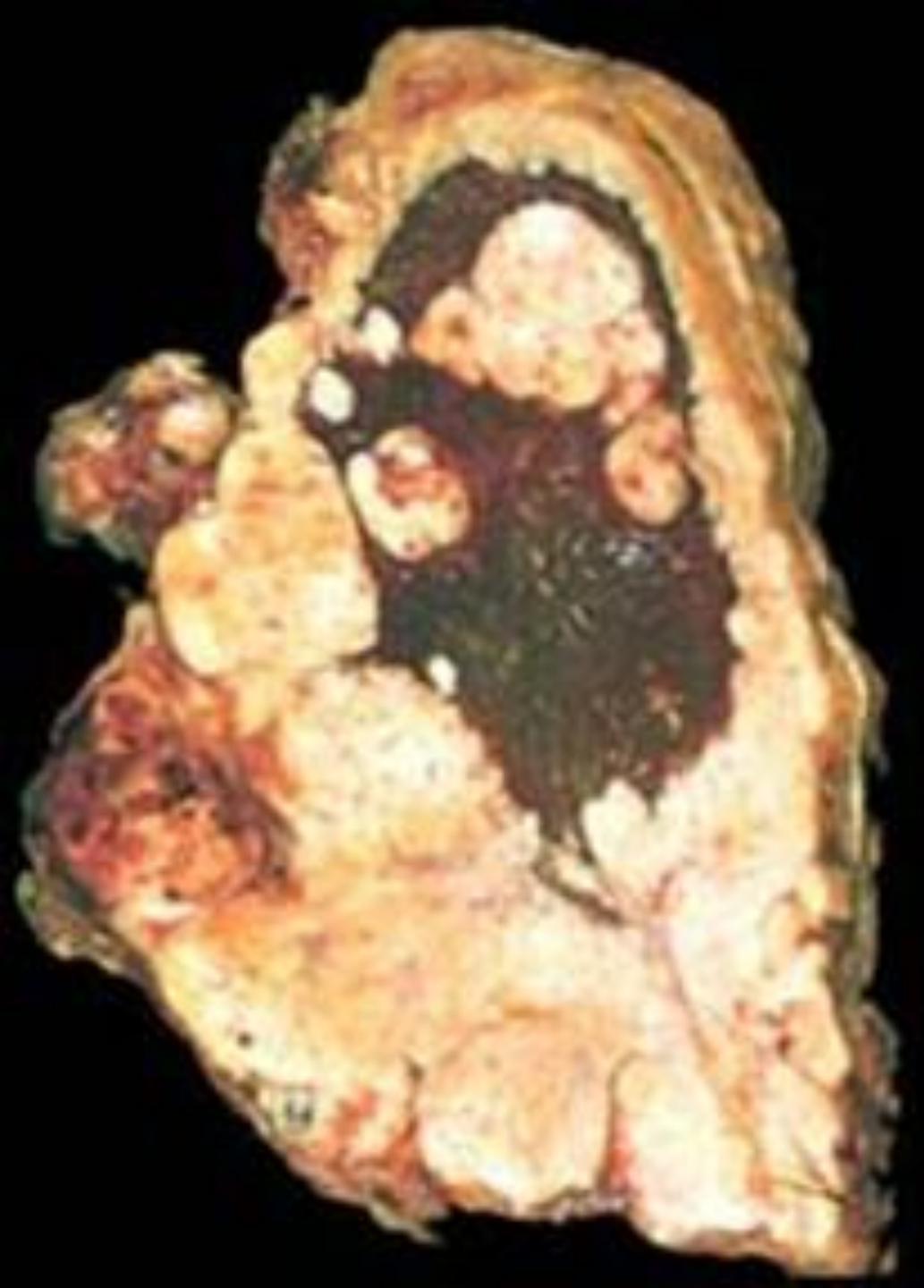- **SPONTANEOUS, TRAUMATIC, THERAPEUTIC**
- **OPEN or CLOSED**
- **“TENSION” pneumothorax, “valvular” effect**
- **“Bleb” rupture**
- **Perforating injuries**
- **Post needle biopsy**

EFFUSIONS

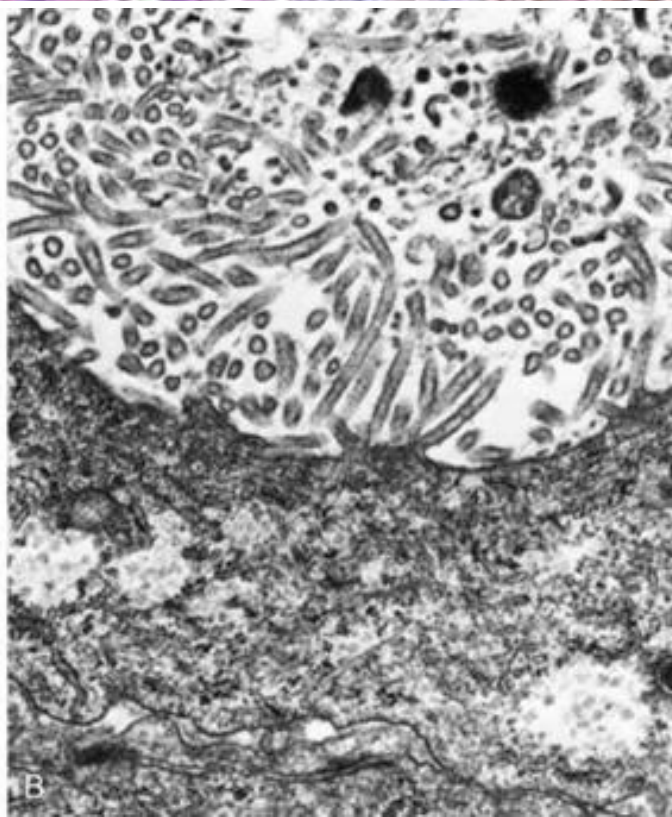
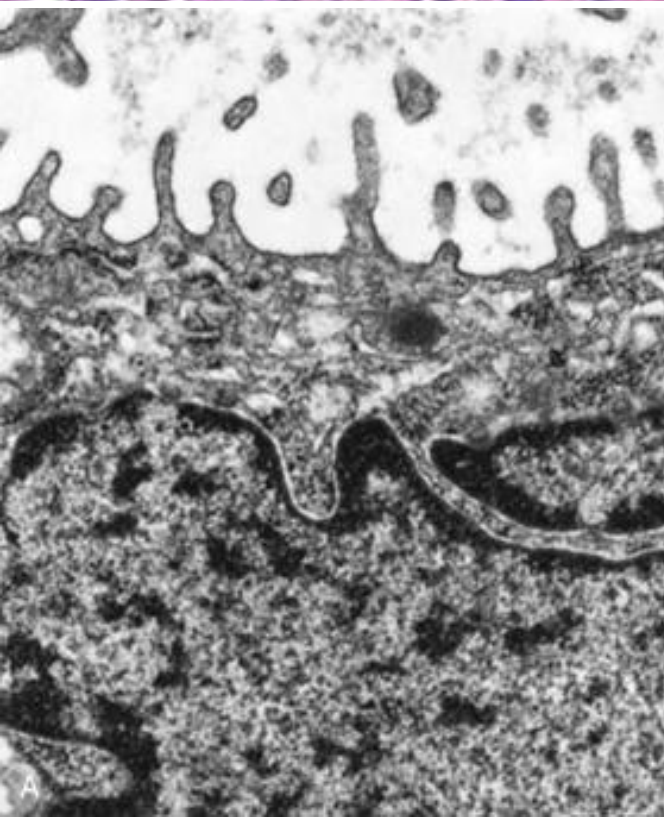
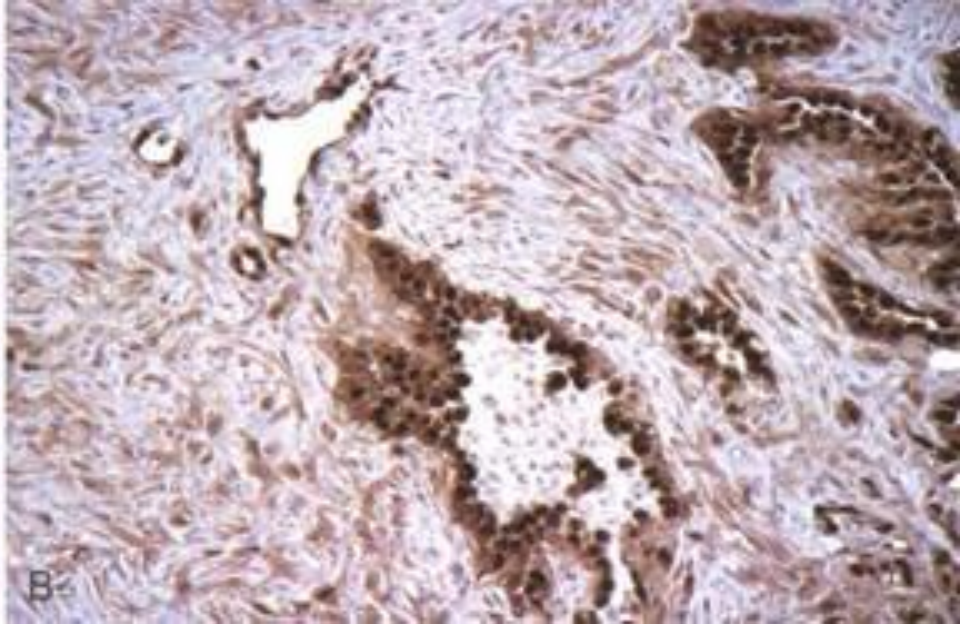
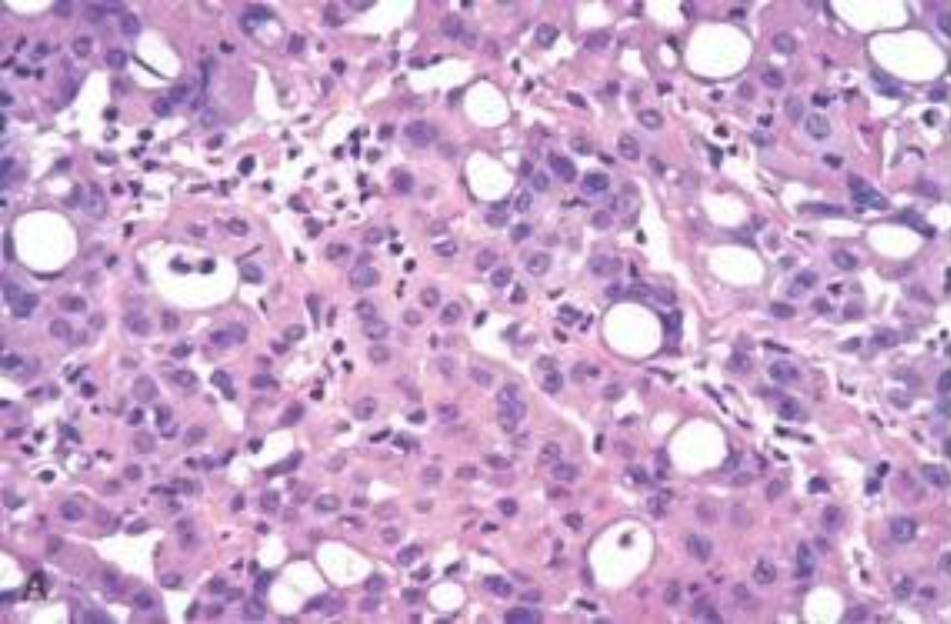
- **TRANSUDATE (HYDROTHORAX)**
- **EXUDATE (HYDROTHORAX)**
- **BLOOD (HEMOTHORAX)**
- **LYMPH (CHYLOTHORAX)**

MESOTHELIOMAS

- **“Benign” vs. “Malignant” differentiation does not matter, but a self limited localized nodule can be regarded as benign, and a spreading tumor can be regarded as malignant**
- **Visceral or parietal pleura, pericardium, or peritoneum**
- **Most are regarded as asbestos caused or asbestos “related”**



Typical growth appearance of a malignant mesothelioma, it compresses the lung from the OUTSIDE.



H&E,
IMMUNOCHEMISTRY

← EM