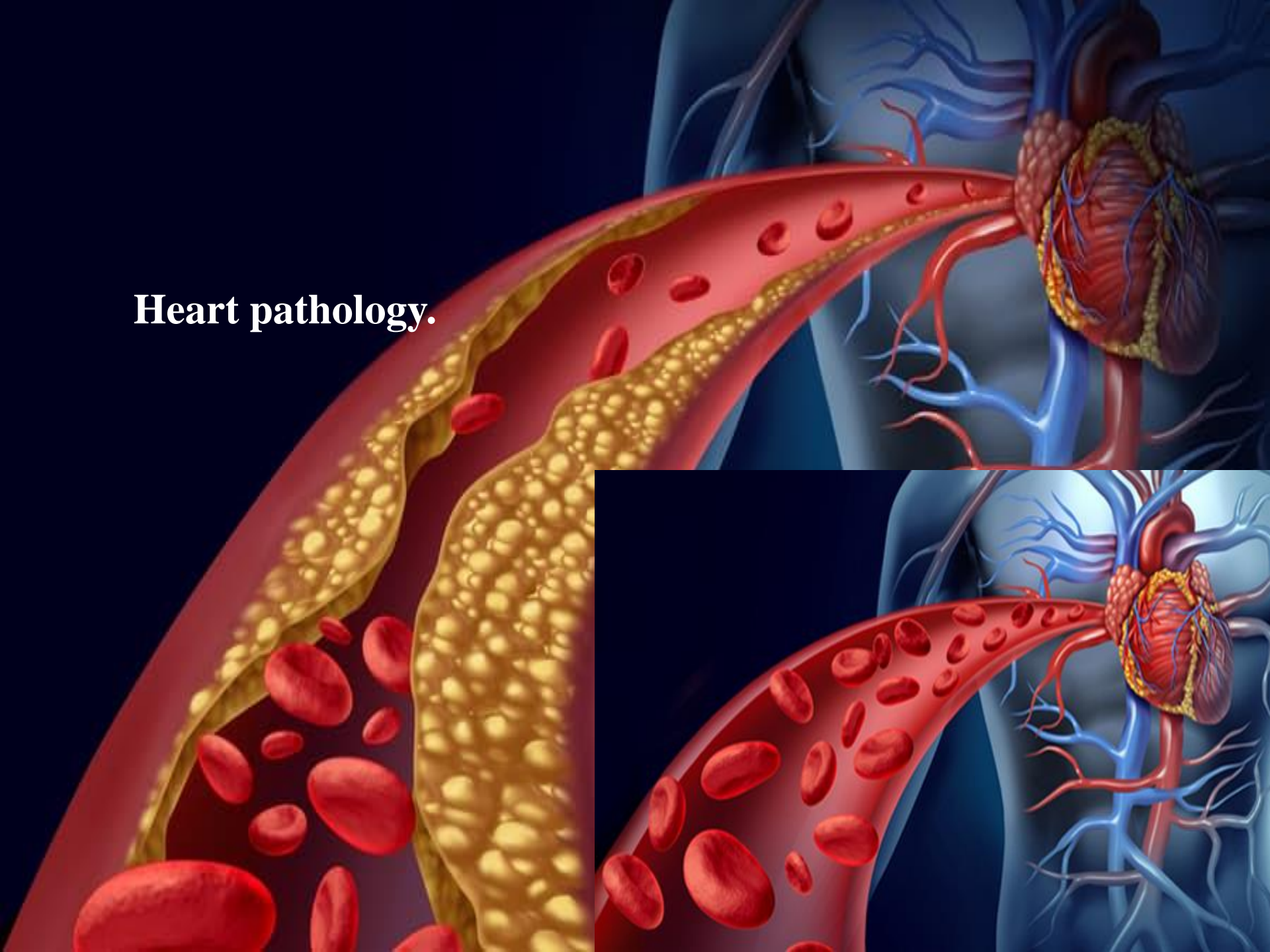


**Heart pathology.**



## Heart pathology.

### ***I. Microspecimens:***

#### **№ 181. Coronary artery thrombosis in atherosclerosis. (*H-E stain*).**

##### **Indications:**

1. Stenosing atherosclerotic plaque in the artery wall.
2. Recent red thrombus on the atherosclerotic plaque surface.
3. The adjacent heart muscle.

Cross section through the subepicardial coronary artery with the underlying myocardium. With the naked eye it can be seen that the lumen of the artery is blocked with thrombotic masses, in the wall an atherosclerotic plaque is observed, which stenoses the lumen. At lower resolution, can be observed that the thrombus is predominantly composed of fibrin and hemolyzed erythrocytes, it adheres intimately to the fibrous capsule of the atherosclerotic plaque, in the thickness of which the weaker eosinophilic colored necrotic center / nucleus is revealed, surrounded by an inflammatory cell infiltrate. In the myocardium protein dystrophy of cardiomyocytes, hemodynamic disorders in the microcirculatory system.

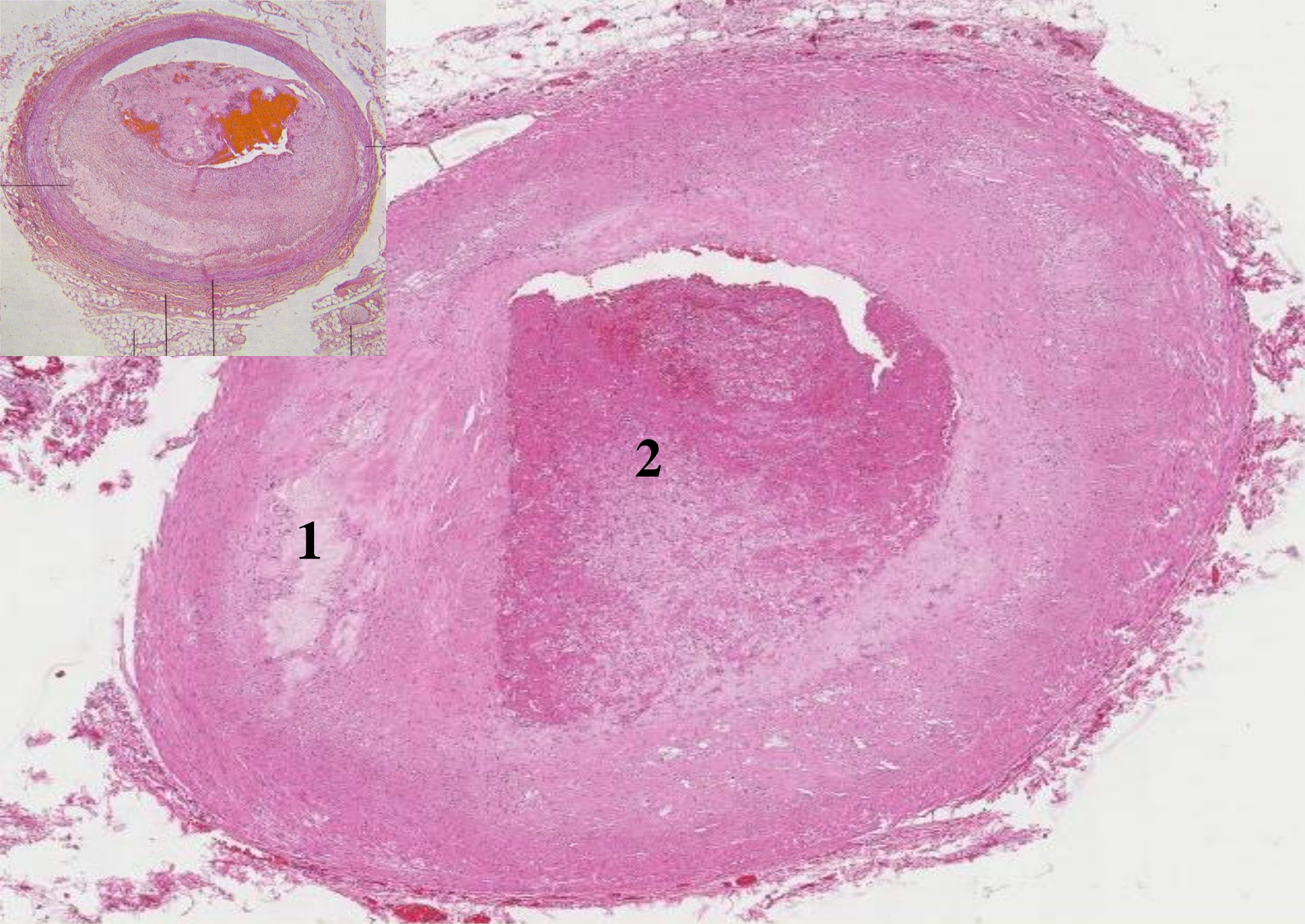
*Coronary artery thrombosis is the most common cause of myocardial infarction and occurs in the vast majority of cases due to stenotic atherosclerosis of the coronary arteries. Thrombus usually develops on so-called "unstable" or "vulnerable" atheromas, in which the fibrous capsule is thin, fine, necrotic center rich in lipids, with active inflammation, the plaques being susceptible to erosion, ulceration, rupture, intramural hemorrhage.*

#### **№ 65. Acute myocardial infarction. (*H-E stain*).**

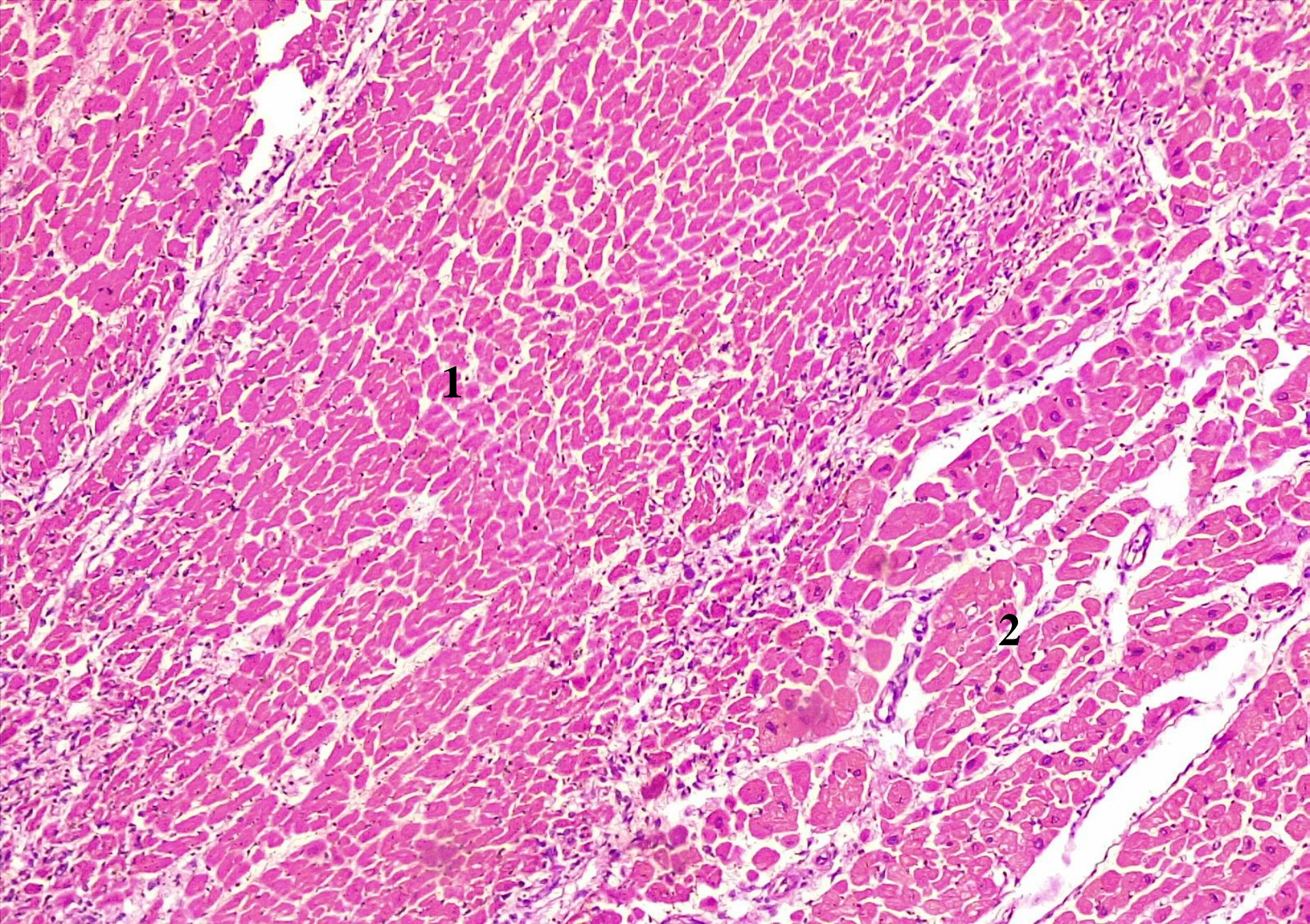
##### **Indications:**

1. Infarct area (karyolysis).
2. Adjacent myocardium.

In the myocardium there are areas of necrosis with cardiomyocyte caryolysis, sarcoplasmic eosinophilia, some cells in disintegration (plasmo-cytorexis), at the periphery of necrotic foci hemorrhages, leukocyte infiltration, in adjacent areas cardiomyocytes with stromal edema, 2 neighboring cells were detected - one necrotic, anucleated and another with a persistent nucleus.



**№ 181. Coronary artery thrombosis in atherosclerosis. (H-E stain).**



**№ 65. Acute myocardial infarction. (H-E stain).**

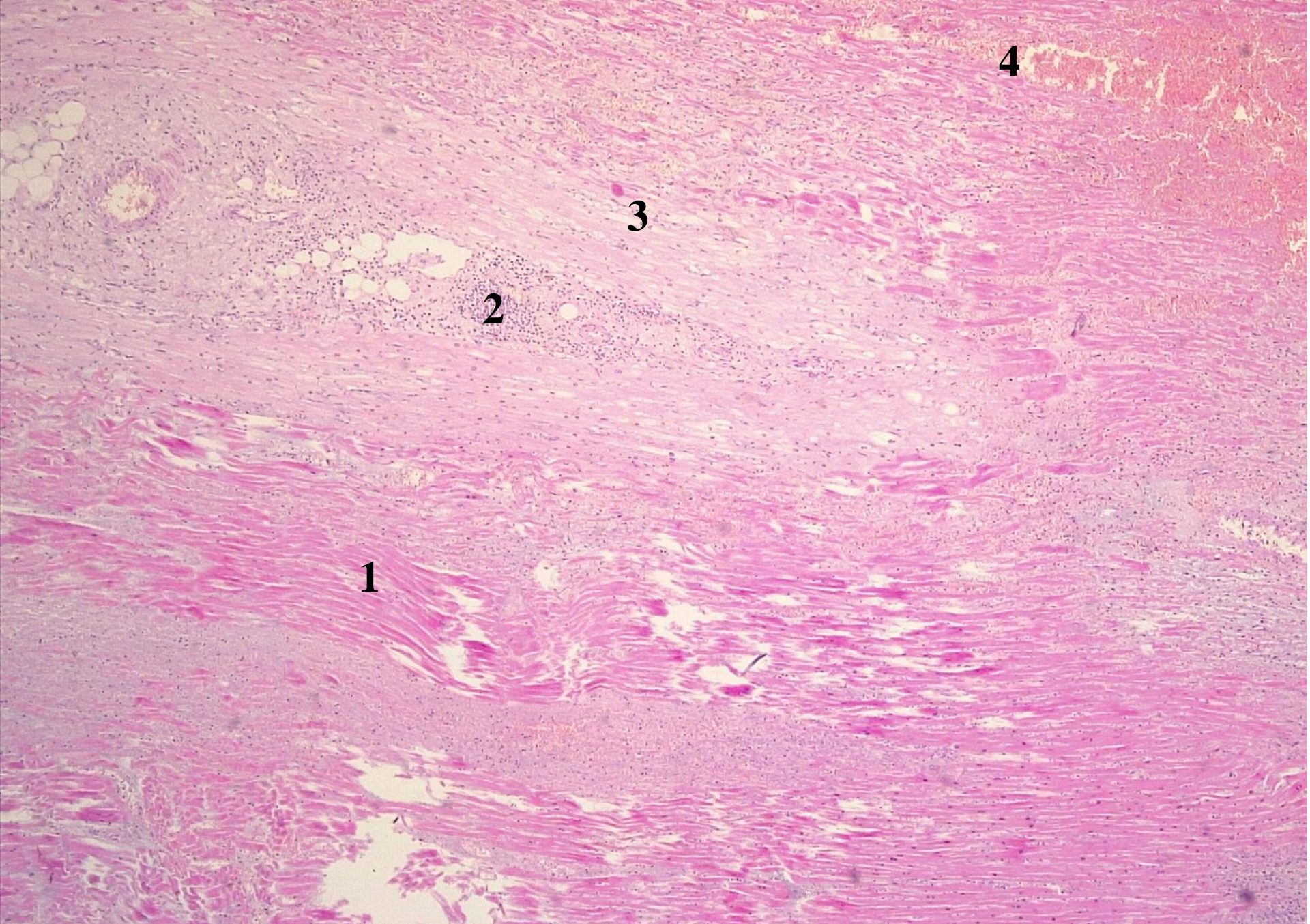
## **№ 65a. Myocardial infarction in stage of organization. (H-E stain).**

### **Indications:**

1. Infarct area.
2. Leukocyte infiltration at the periphery of the infarct area.
3. Granulation tissue around the area of necrosis.
4. Adjacent myocardium.

In the myocardium necrotic foci are detected with cardiomyocyte caryolysis, some cells with signs of plasma cytorexis, in some places form homogeneous, structured eosinophilic foci (necrotic detritus), leukocyte infiltration and hemorrhages are observed; these areas are surrounded by granular tissue rich in capillaries and cellular elements; in the adjacent heart muscle protein dystrophy of cardiomyocytes, stromal edema.

*In the temporal evolution of myocardial infarction, the stage of necrosis and the stage of organization are distinguished. The stage of necrosis is manifested microscopically by cardiomyocyte caryolysis, their fragmentation, leukocyte infiltration, which reaches a maximum 48-72 hours after the onset of infarction, hyperemia of the vessels, hemorrhagic foci. Macroscopically, the area has an irregular shape, white-yellow color in the center and red edema on the periphery - white, ischemic infarction with hemorrhagic edema. Very rarely, in 1-2%, myocardial infarction can be hemorrhagic. The organization of the infarction shows the process of substituting the necrotic focus with granulation tissue. On the 4th day after onset, macrophages begin to appear in the area of necrosis, which performs the resorption of necrotic masses and gradually replaces the necrosis with granulation tissue, which penetrates from adjacent areas of the heart muscle. Subsequently, the granulation tissue matures, collagenizes and transforms into mature, dense scar fibroconjunctival tissue. The healing process of myocardial infarction with the development of post-infarction macrofocal cardiosclerosis lasts on average 6-7 weeks, depending on the size of the infarction and the general condition of the body. Complications of acute myocardial infarction: a) cardiogenic shock, b) acute heart failure, c) pulmonary oedema, d) arrhythmias (ventricular fibrillation, asystole and a.), E) rupture of the ventricular wall with pericardial tamponade, f) fibrinous pericarditis, g) intracardiac wall thrombosis and thromboembolism and others.*



**№ 65a. Myocardial infarction in stage of organization. (H-E stain).**

**№ 59. Rheumatic granulomatous endo-myocarditis. (H-E stain).**

**Indications:**

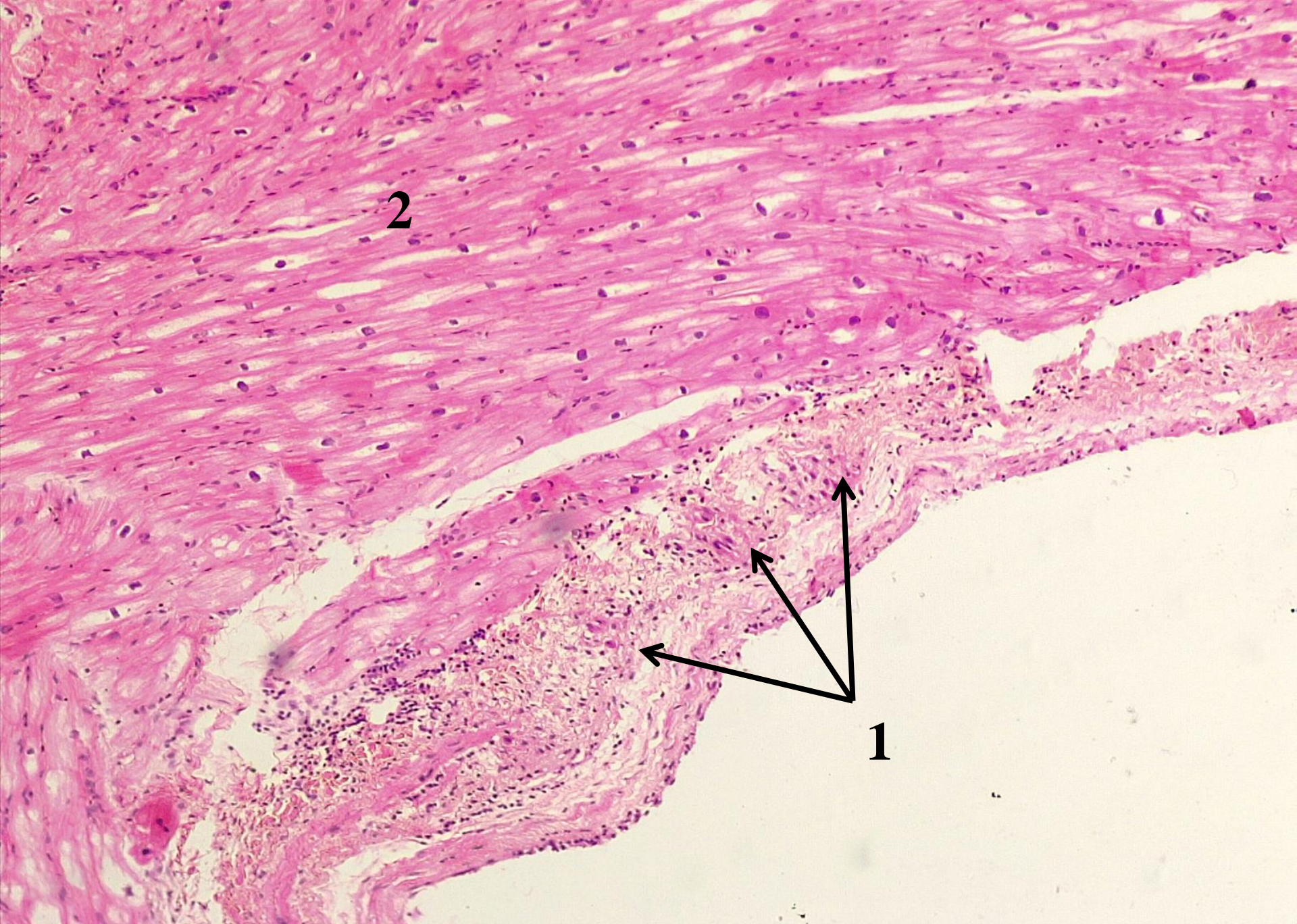
1. Aschoff rheumatic granulomas in the parietal endocardium.
2. Fibrinous necrosis in the center of the granuloma.
3. Macrophages at the periphery of the granuloma.
4. Adjacent myocardium.

There are 2 series of microspecimens:

I - cross section through the left auricle of the heart; at the lower resolution, in the parietal endocardium, which covers the auricle's wall, small focal agglomerations of polymorphic cellular elements are detected - Ashoff rheumatoid granulomas, at the large objective it is seen that they are composed of lymphocytes, macrophages and fibroblasts, in the center of some granulomas necrosis with eosinophilic colored tissue debris (fibrinoid necrosis);

II – cut section of the ventricular wall with the parietal endocardium, rheumatic granulomas are observed in the endocardium and in the subendocardial myocardium, especially perivascular.

*Aschoff's granuloma is pathognomonic for rheumatism. It is found in all layers of the heart (in rheumatic pancarditis) and in other organs and tissues. There are 3 stages in the evolution of granuloma: 1) early or degenerative, 2) intermediate or proliferative (florid) and 3) late or healing (involutive). In the first stage dystrophic changes and fibrinoid necrosis of connective tissue predominate, in the second stage - cell proliferation with the accumulation of lymphocytes, macrophages, plasma cells and Anitschkow cells, which are arranged in the palisade around fibrinoid masses, in the third stage - processes fibrosis and sclerosis. Anitschkow cells or cardiac histiocytes are macrophages with an elongated, wavy, caterpillar-shaped nucleus (cartilage cells), some of which become polynuclear, with 1-4 nuclei, which are called Ashoff cells and are considered characteristic of rheumatic carditis. The evolution of the granuloma until scarring lasts on average 3-4 months, on the place of the granuloma a fibroconjunctive scar is formed, located predominantly perivascular.*



**№ 59. Rheumatic granulomatous endo-myocarditis. (H-E stain).**



## ***II. Macrospecimens:***

### **№ 24. Heart rupture (left ventricle) in acute myocardial infarction.**

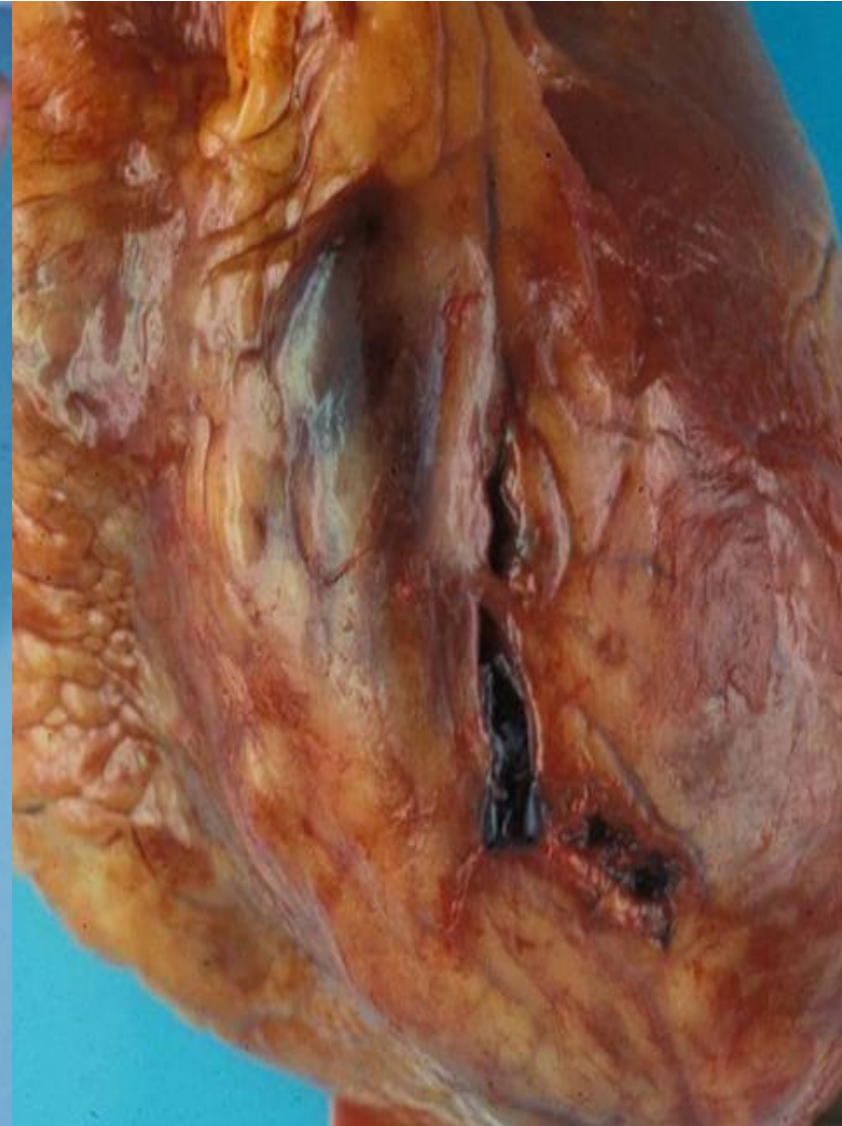
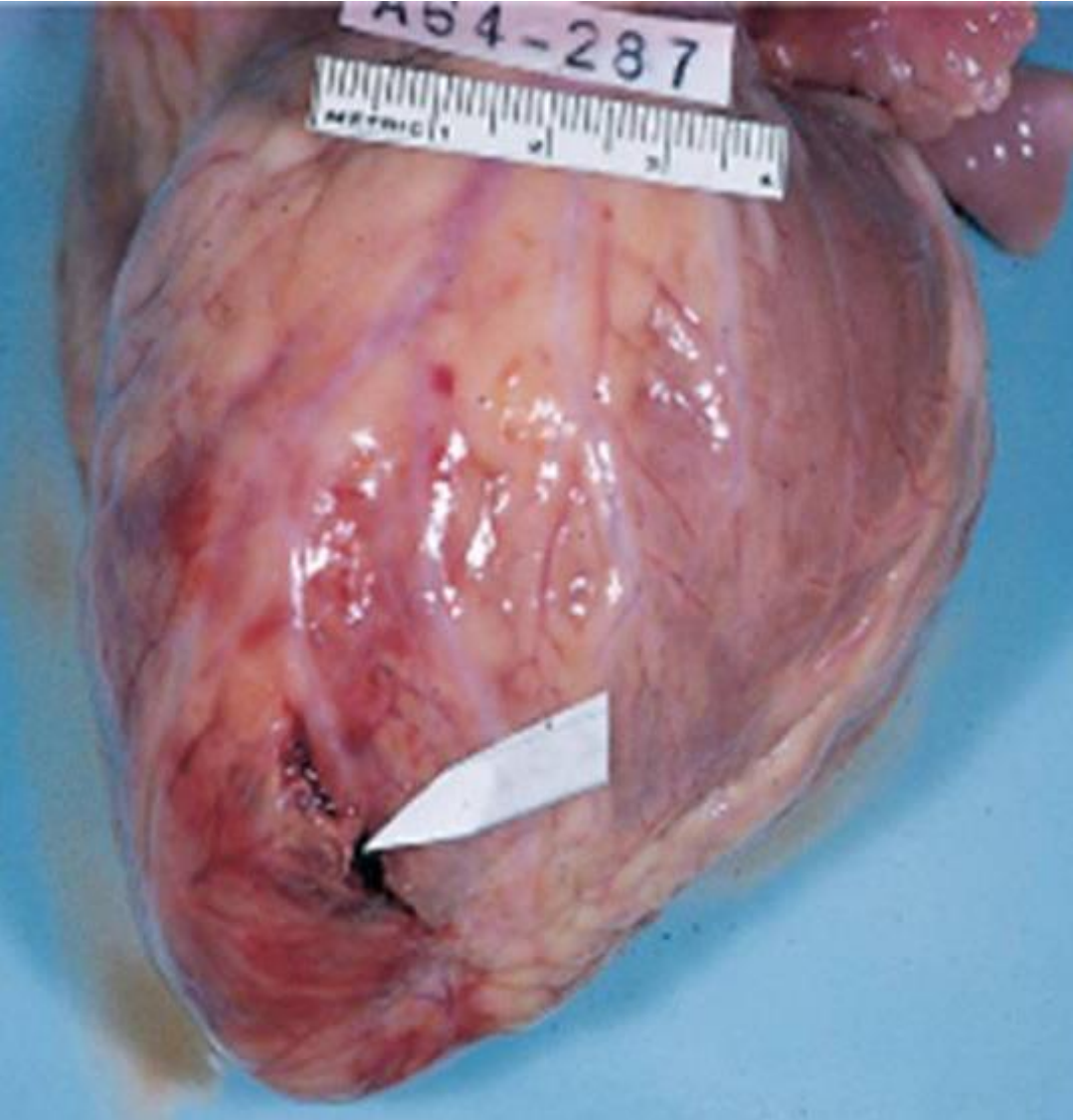In the lower third of anterior wall of the left ventricle, a fissure with a length of 1.5-2 cm is observed, on the section it is seen that the fissure comprises the entire thickness of the ventricular wall, the edges are infiltrated with blood.

*Rupture of the heart is the cause of death in 10% of the total number of patients who die from myocardial infarction. There is external and internal rupture. The rupture occurs in cases of macrofocal, transmural infarction, affecting at least 20% of the heart muscle, usually in the first days after the onset of the infarction (days 1-4), when the process of myomalacia develops - autolysis of the necrosis area under the influence of proteolytic enzymes of neutrophil leukocytes. The rupture occurs more frequently at the border between the area of necrosis and the persistent myocardium. The rupture in the center of the infarct area is observed more frequently in the second week, during the organization of the infarction. Most external ruptures of the heart occur in the left ventricle, anterior and lateral walls. Develops, hemopericardium and cardiac tamponade, which is fatal. Internal rupture refers to the interventricular septum and papillary muscles, leading to severe congestive heart failure. Heart rupture is more common in patients with primary myocardial infarction.*

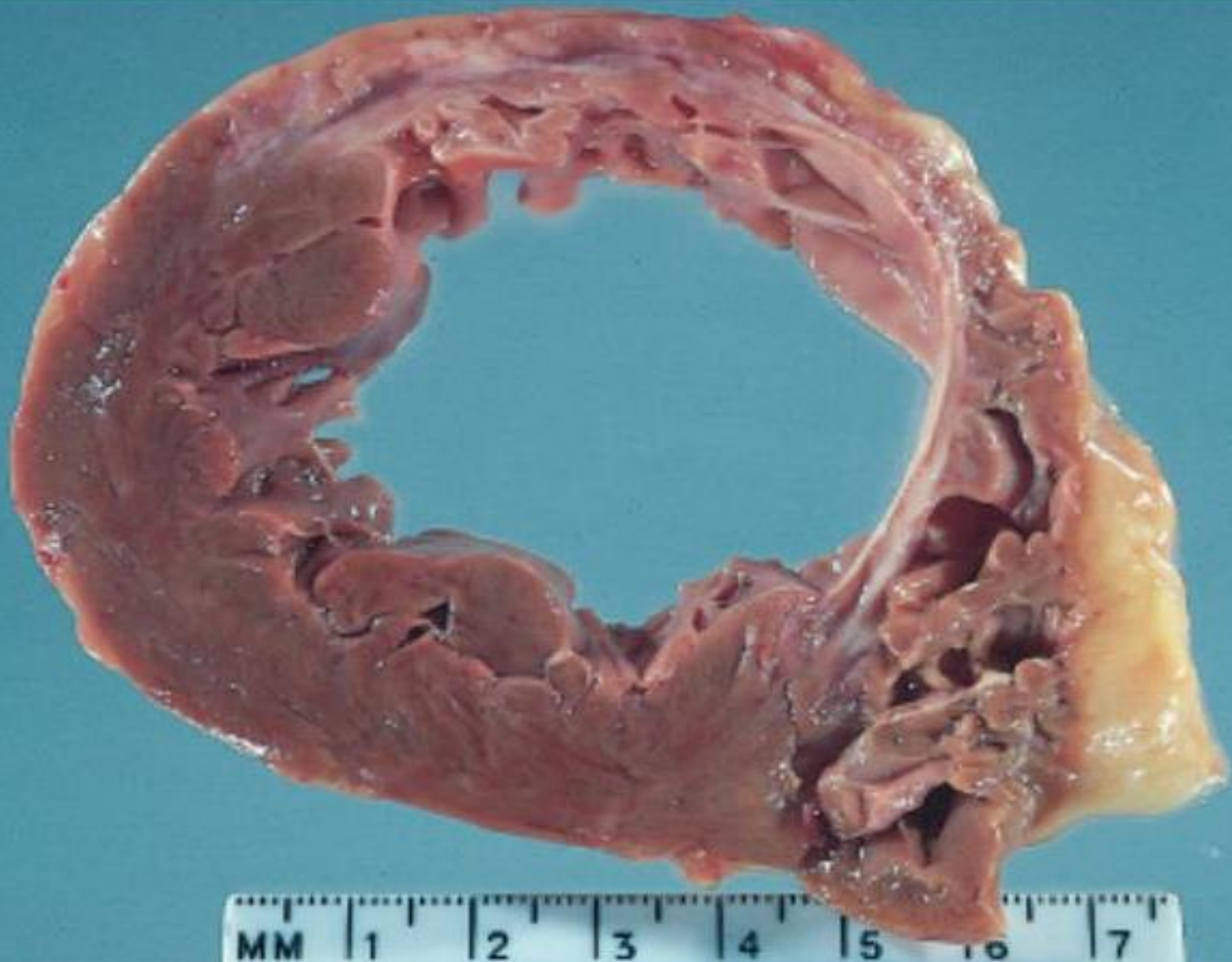### **№ 13. Macrofocal postinfarction cardiosclerosis.**

On the section of the left ventricular wall, is observed, an area of fibroconjunctive tissue (scar), white in colour, with a cartilaginous appearance, hard in consistency, the ventricular wall is hypertrophied.

*Macrofocal cardiosclerosis is the consequence of myocardial infarction, it occurs after the organization of the infarct area, which occurs within 6-7 weeks from the onset of the disease. Calcium salts can be stored in the area of the post-infarct scar, compensatory hypertrophy is observed in the adjacent heart muscle. Possible complications: congestive heart failure, rhythm and conductivity disorders, chronic heart aneurysm. In the International Classification of Diseases it is called "Old myocardial infarction".*



**№ 24. Heart rupture (left ventricle) in acute myocardial infarction.**



**№ 13. Macrofocal postinfarction cardiosclerosis.**

### **№ 18. Cardiac thrombosis.**

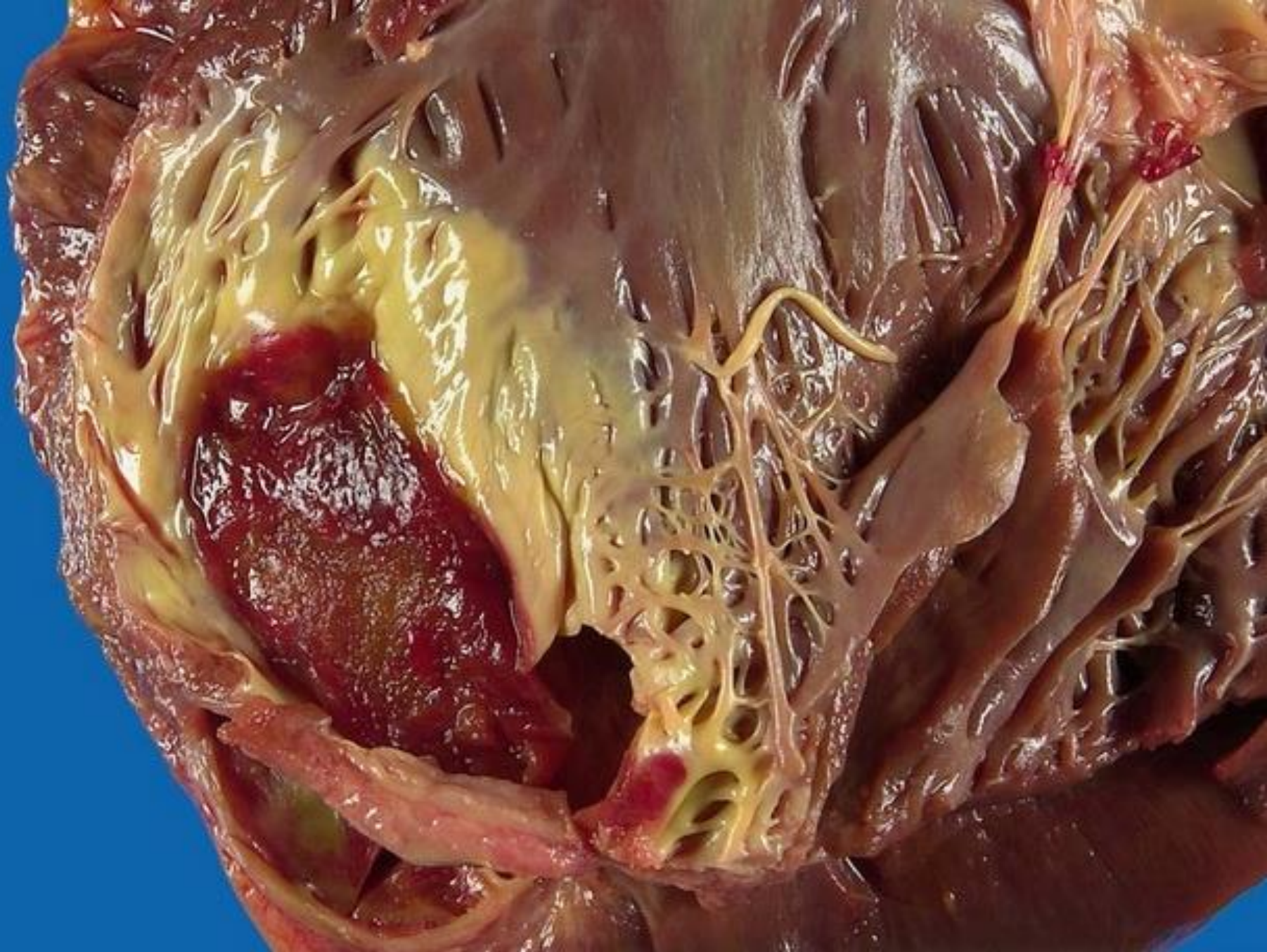
On the cross section of the heart are observed massive wall thrombi, which adhere closely to the parietal endocardium, brown in color, dense consistency, dry appearance, thickness up to 1 cm.

*Intracardiac thrombosis is found in several diseases, in which inflammation of the parietal endocardium occurs. It is observed in rheumatic parietal endocarditis, transmural or subendocardial myocardial infarction, cardiomyopathies. Thrombosis of the left atrium occurs in mitral stenosis, and of the right atrium-in chronic congestive heart failure. An important causal factor is atrial fibrillation. Left intracardiac thrombosis can lead to thromboembolism of the arteries of great circulation with infarcts in the brain, spleen, kidneys, gangrene of the extremities or intestines, and thrombosis of the right heart cavities - to pulmonary infarctions or thromboembolism of the common trunk of the pulmonary artery.*

### **№ 16. Verrucous acute endocarditis.**

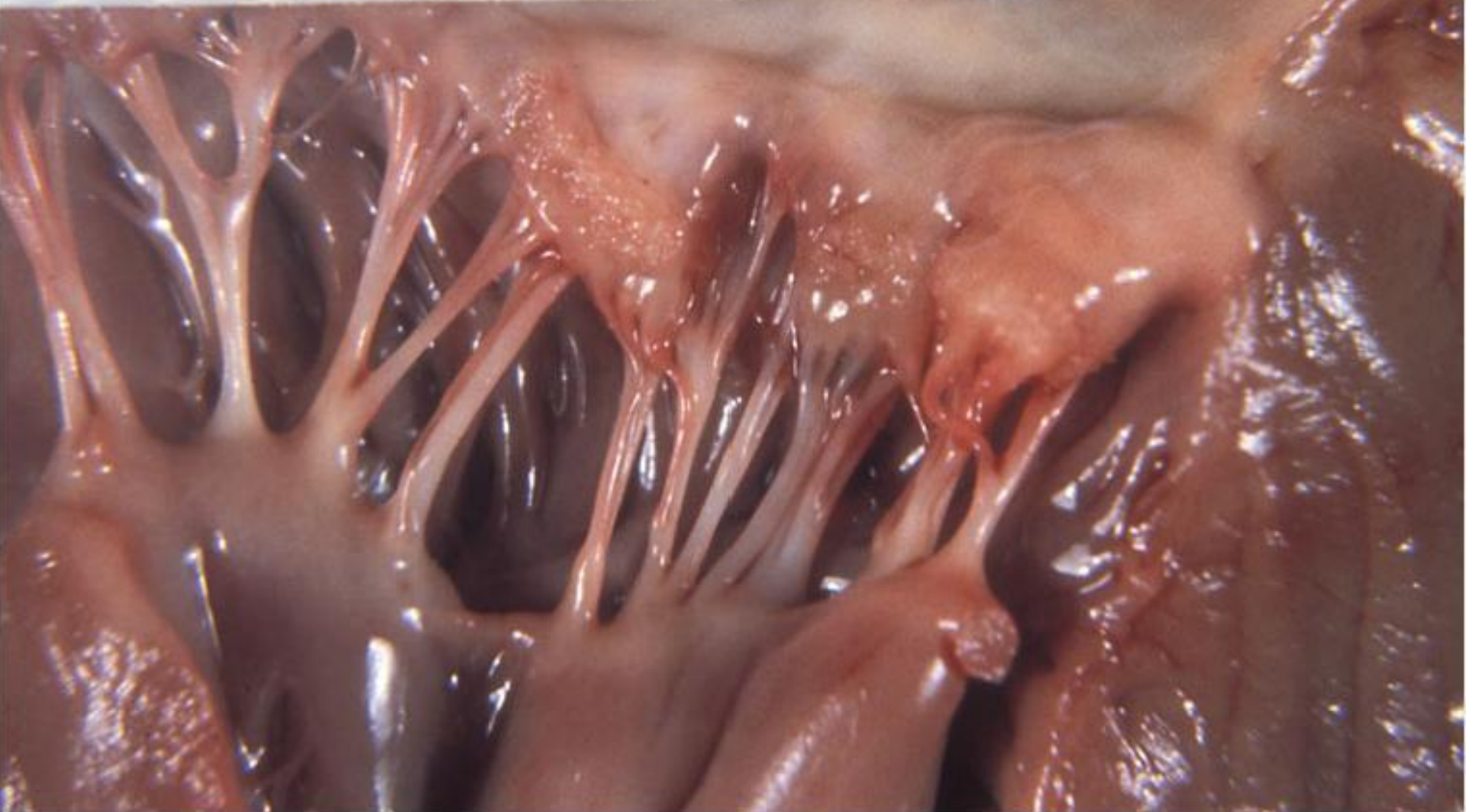On the atrial surface of the mitral valve cusps there are fine thrombotic deposits (warts), brown in color, dense in consistency, which adhere closely to the valvular endocardium, located mainly on the free edge, closing the cusps; the cusps are thickened, deformed, the tendon cords also are thickened and fused.

*Valvular endocarditis is a manifestation of rheumatic carditis. More frequently is affected mitral valve (~ 70%): concomitant mitral and aortic valve involvement occurs in (~ 25%), the tricuspid valve is less commonly involved, and the aortic valve is about (2%), and the pulmonary valve is practically not affected. Acute valvulitis develops on free valves, is manifested by fibrinoid necrosis, inflammatory cellular infiltration, Aschoff granulomas, fibrin deposits in the form of warts with a diameter of 1-2 mm, arranged in a string along the closing edges of the valves, usually on the atrial surface of the atrioventricular valves and on the ventricular surfaces of the crescent valves, in the occurrence of these lesions reflects the role of the mechanical and hemodynamic factor. Chronic valvulitis is manifested by the organization of acute inflammation and fibrinous warts, the appearance of new, larger warts on the already deformed, thickened valves, sclerosis and retraction, shortening of the cusps and crescent leaves, their concretion, calcinosis. At the same time, the mitral valve become more thick, shorten and fuse the tendon cords, which together with the concretion of the cusps leads to the installation of a mitral stenosis with the appearance of a "fish mouth" or "buttonhole". The functional consequences consist of valvular insufficiency or stenosis and the gradual development of congestive heart failure.*



№ 18. Cardiac thrombosis.

TRIC 1 SYSTEM 2 3

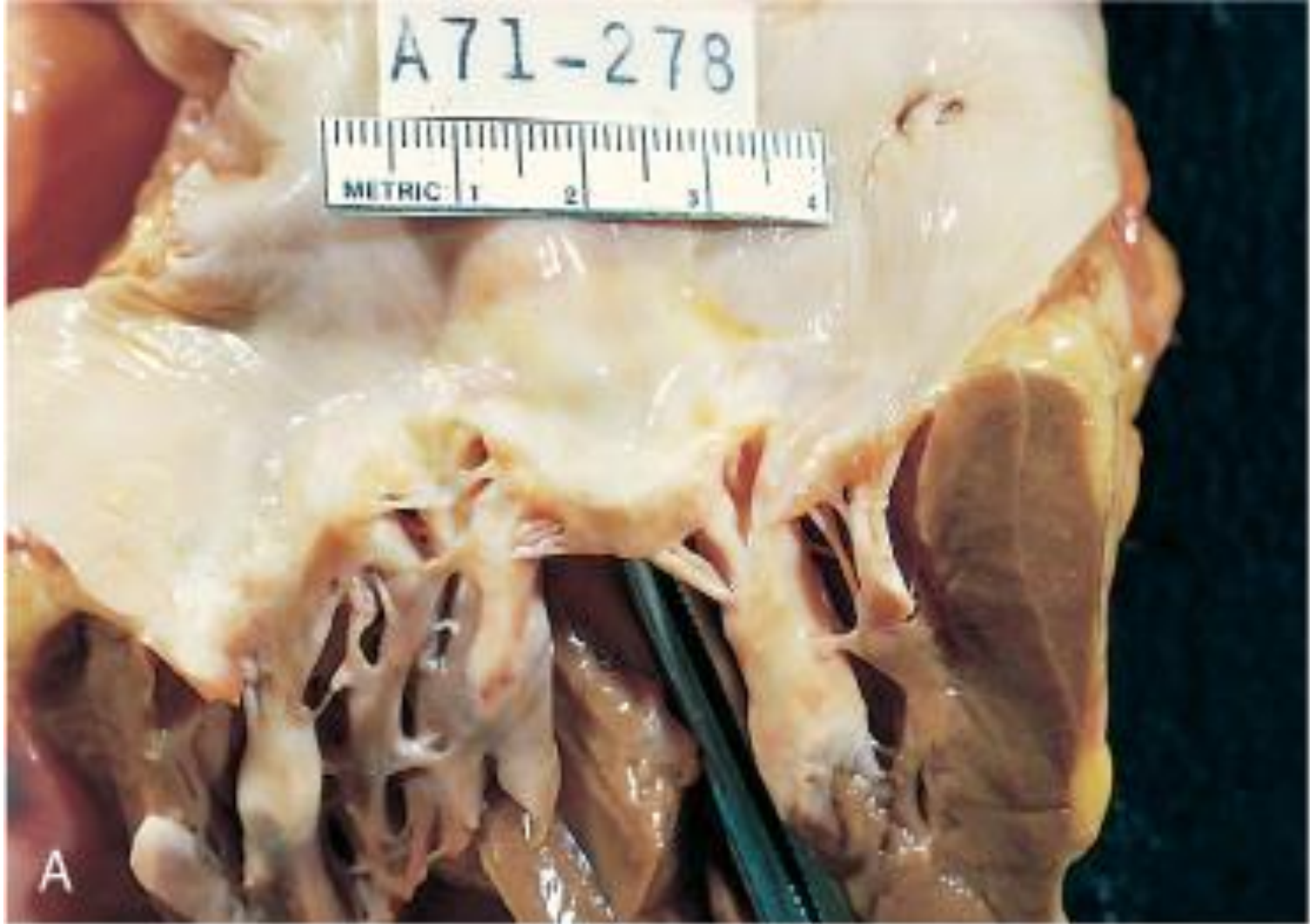


№ 16. Verrucous acute endocarditis.

## **№ 6. Rheumatic mitral valvulopathy.**

The cusps of the mitral valve are deformed, thickened, sclerosed, overgrown with each other, of dense consistency, the mitral orifice is stenotic, has the shape of a "fish mouth" or "buttonhole", the wall of the left ventricle is hypertrophied.

*Most of the acquired valvulopathies - more than 80% - are of rheumatic origin. The heart valves are deformed, sclerosed, have a dense consistency, lose elasticity and mobility, sometimes they are overgrown. Microscopically, is observed sclerosis and hyalinosis of the valvular tissue, its vascularization and calcinosis. Clinical-anatomical variants of valvulopathies are valvular insufficiency, when the cusps or crescent leaves do not close the valvular orifice and valvular stenosis, when the orifice does not open completely: are common combined valvulopathies, when the association of valvular insufficiency and stenosis occurs with the predominance of one of this. These changes in the heart valves are a consequence of valvular endocarditis. In addition to rheumatism valvulopathies are found in atherosclerosis, especially aortic valvulopathy, tertiary syphilis - aortic valve insufficiency; in some diseases can develop relative insufficiency of the heart valves due to dilation of the fibrous ring of the valves but they remain intact, for example in dilatative cardiomyopathy. Cardiac valvulopathy leads to progressive chronic congestive heart failure.*



**№ 6. Rheumatic mitral valvulopathy.**



### **№ 11. Fibrinous pericarditis.**

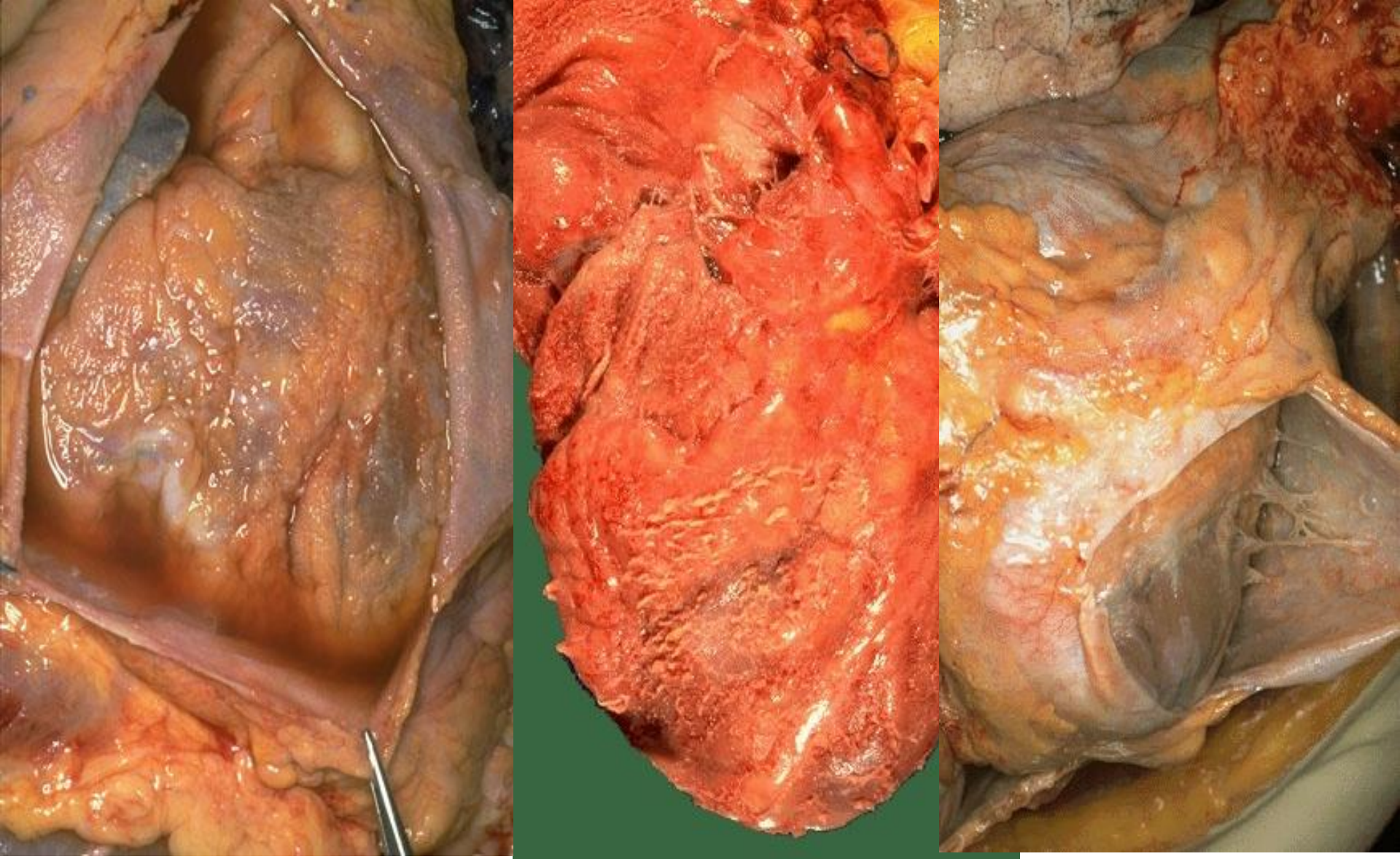
The epicardium is opaque, the surface irregular, covered with yellowish-white deposits of fibrin in the form of villi, which occur due to contractile movements, the heart has a hairy appearance or "cat tongue" (villous heart).

*Fibrinous pericarditis is found in rheumatism, tuberculosis, transmural myocardial infarction, uremia, etc. On auscultation it is manifested by a breath of pericardial rubbing. Consequences: resorption of fibrinous exudate or its organization with the formation of adhesions between the pericardial sheets and obliteration of the pericardial sac. Over time, calcium salts are deposited in the sclerotic pericardium and the "armor heart" appears, which is clinically manifested by chronic congestive heart failure.*

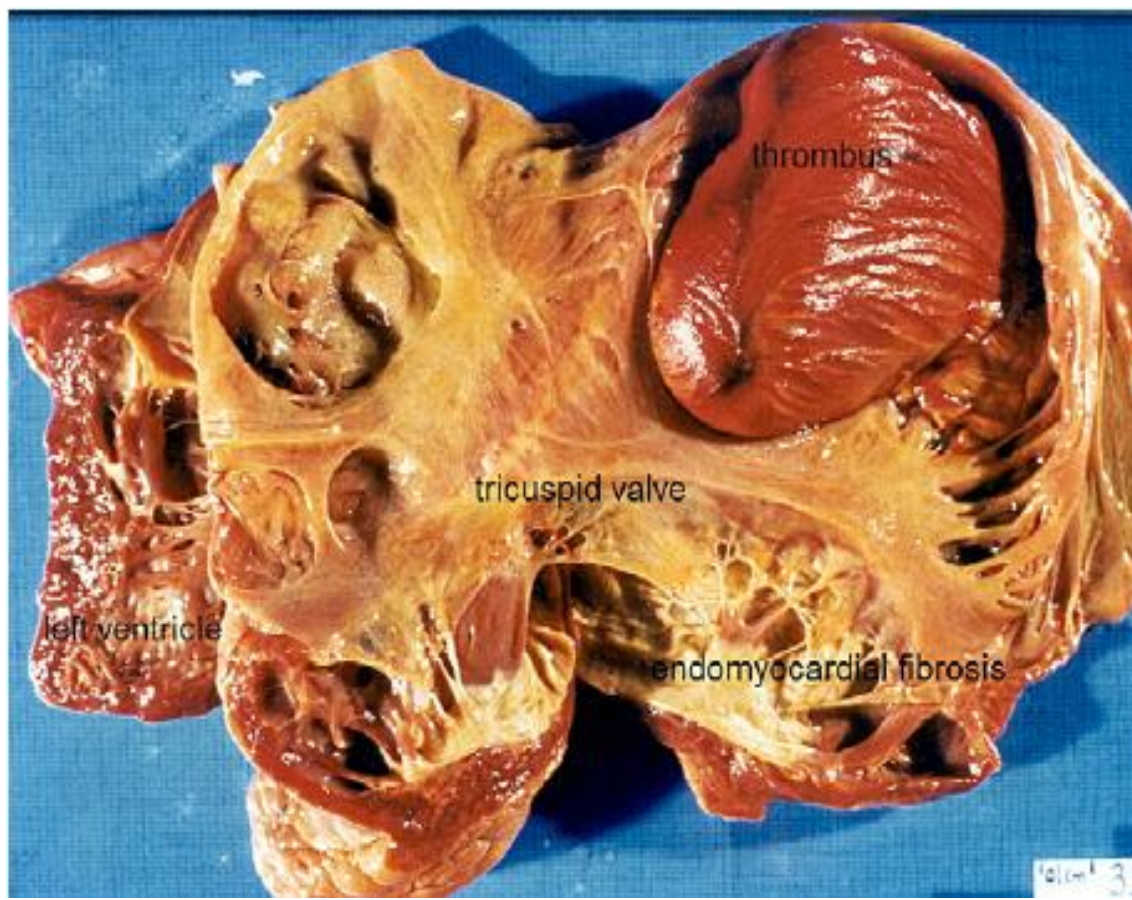
### **№ 8. Round thrombus in left atrium.**

The left atrium of the heart is dilated, a spherical thrombus is present in the cavity, diameter ~ 5-6 cm, smooth, glossy surface, dense consistency, is free in the atrial cavity, does not adhere to the wall, the mitral valve is stenotic.

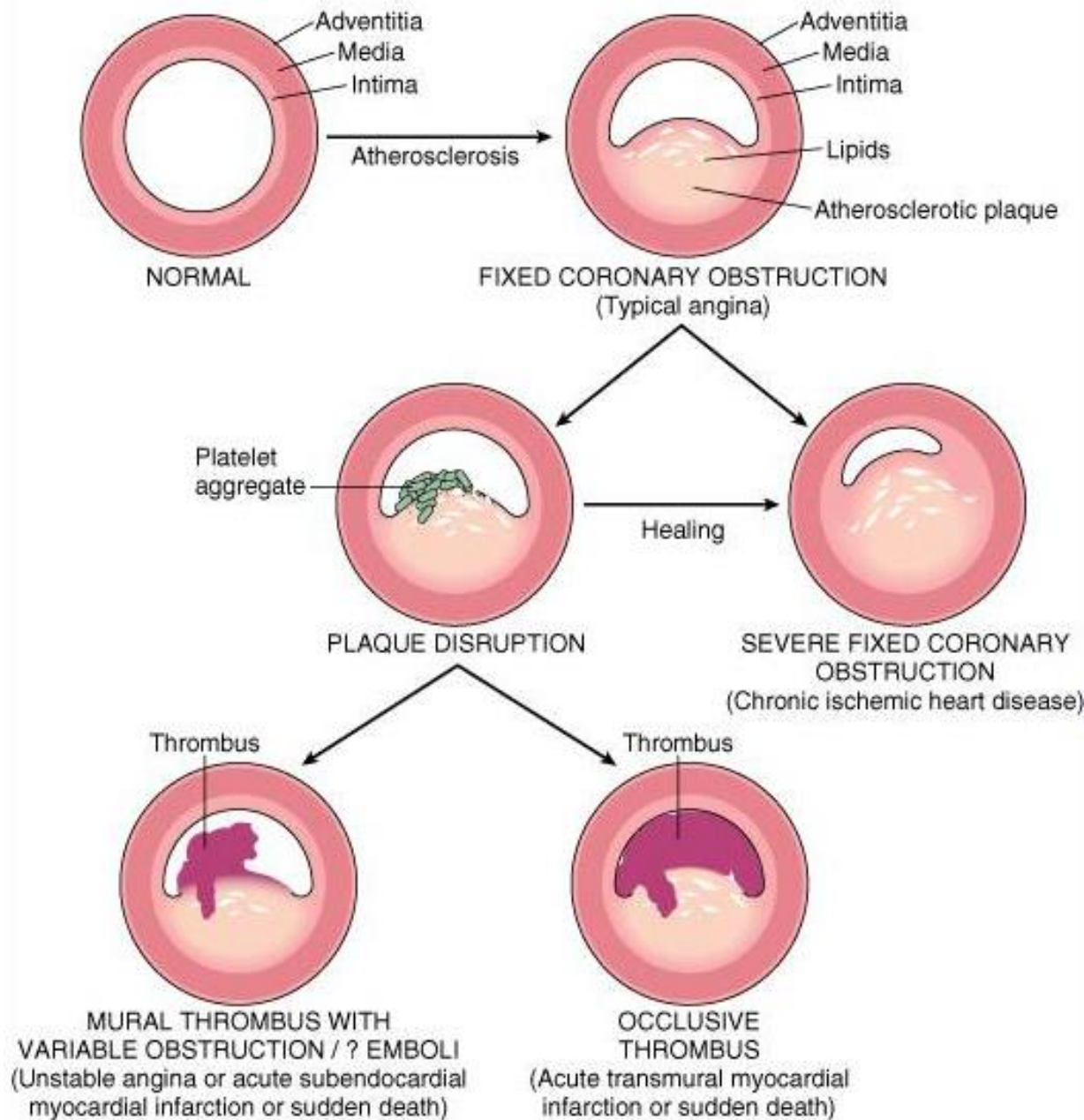
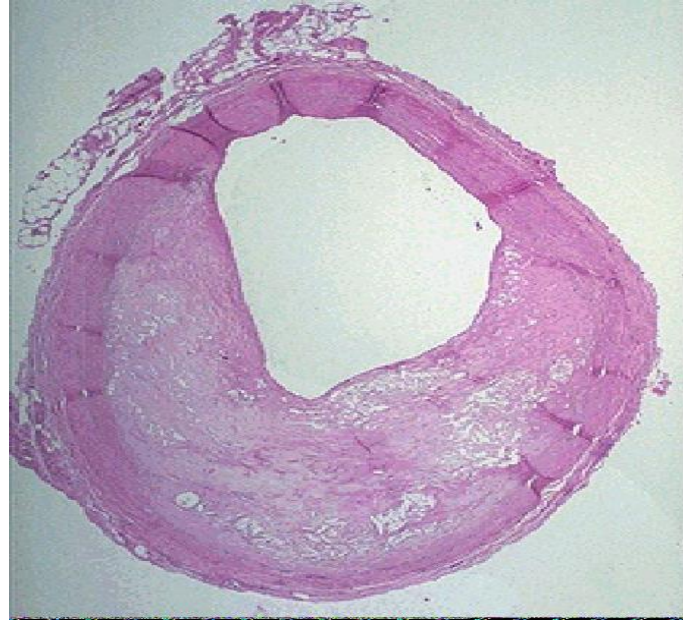*Spherical thrombus in the left atrium of the heart is very rare, more commonly seen in mitral stenosis with dilated atrium and turbulent, rotating blood circulation, which promotes the formation and increase in size of the thrombus, which gradually acquires a spherical appearance. The spherical thrombus in the left atrium can lead to sudden death.*



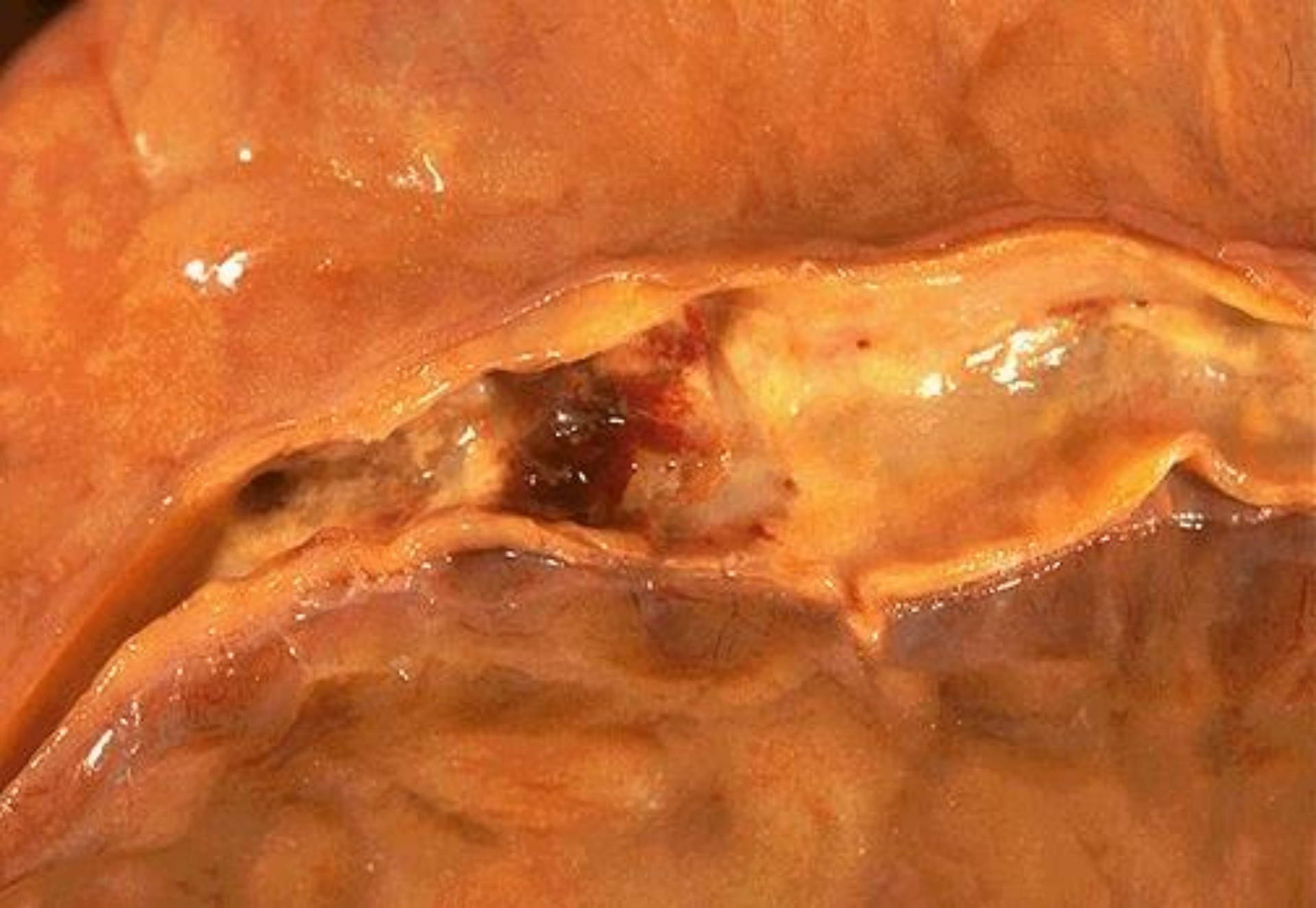**№ 11. Fibrinous pericarditis.**



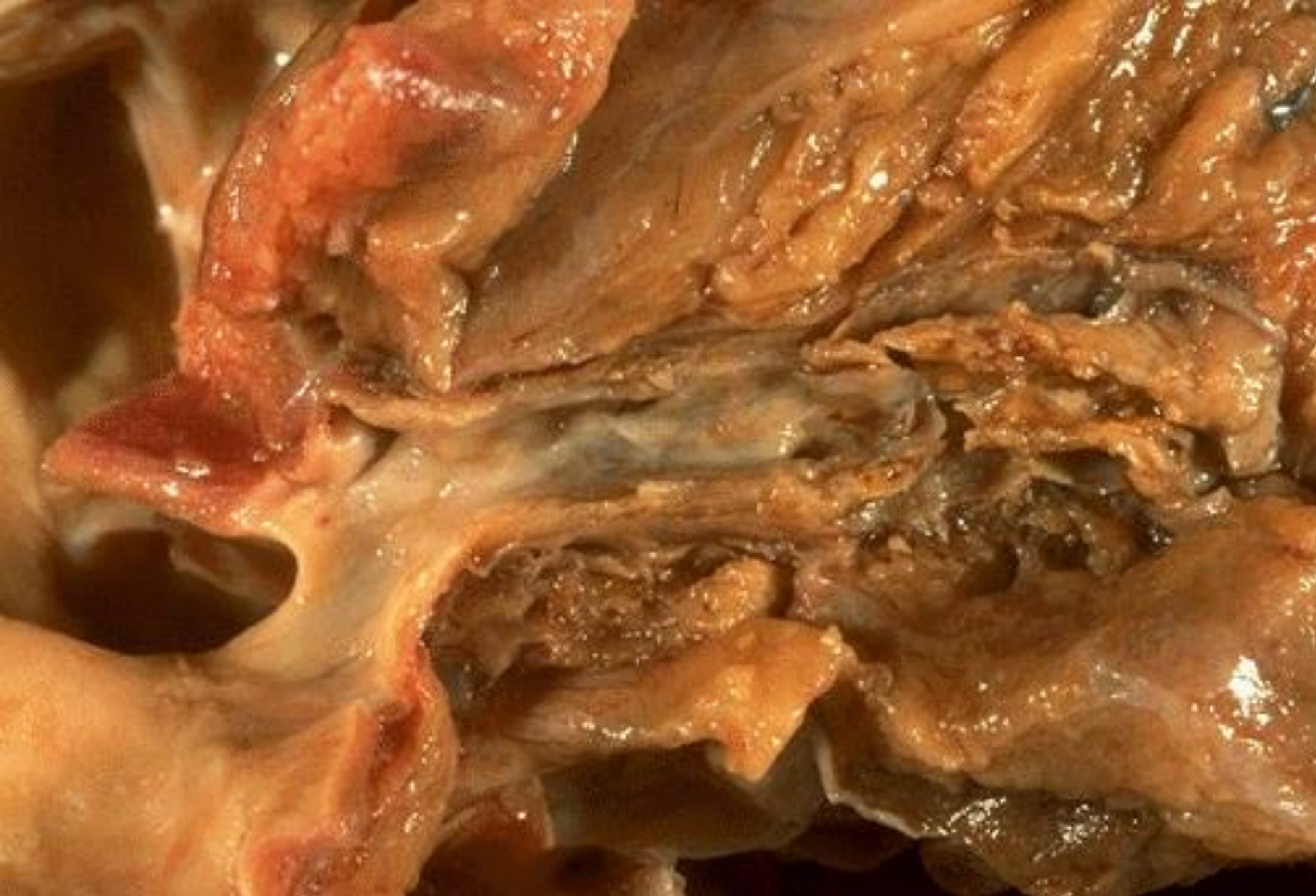**№ 8. Round thrombus in left atrium.**



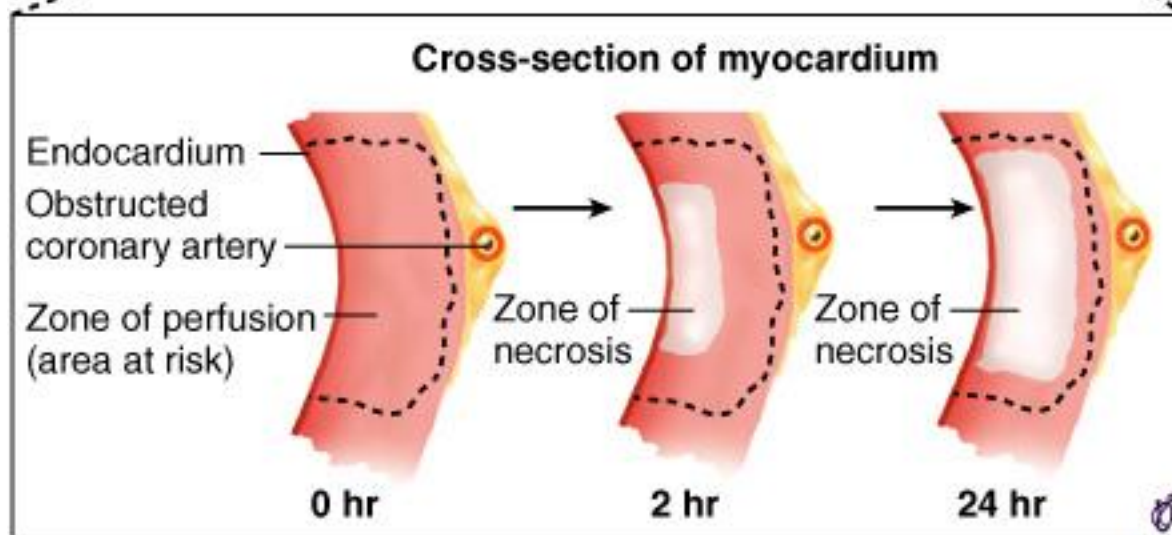
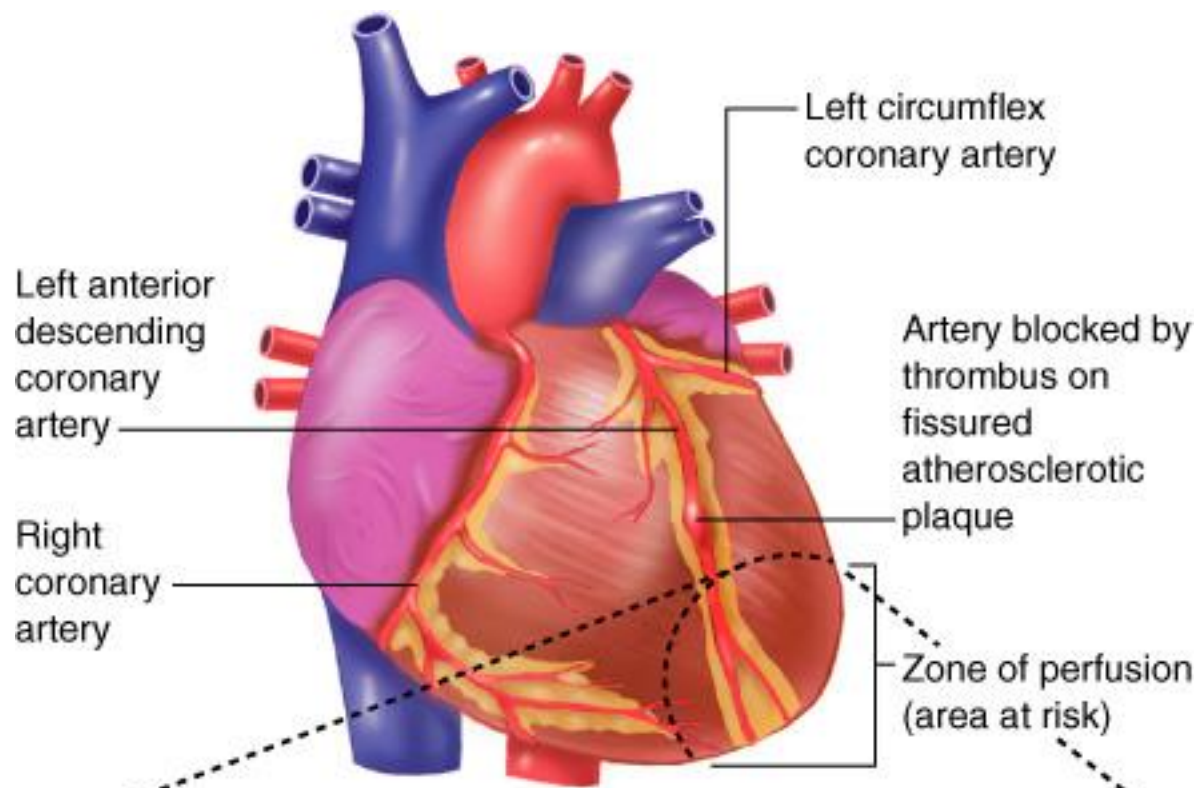
**Scheme of the evolution and complications of coronary atherosclerosis.**

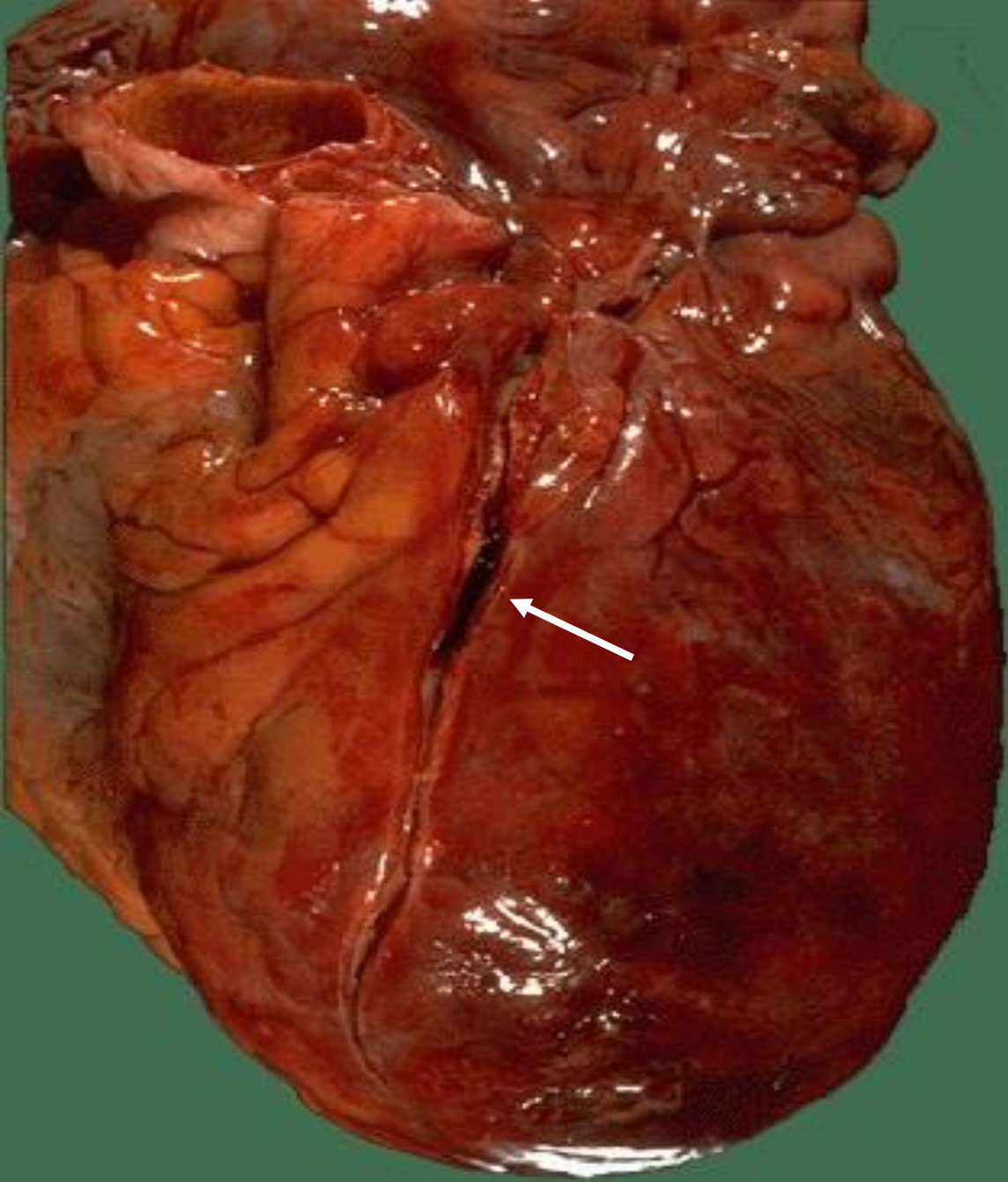


**Coronary atherosclerosis, intramural hemorrhage.**



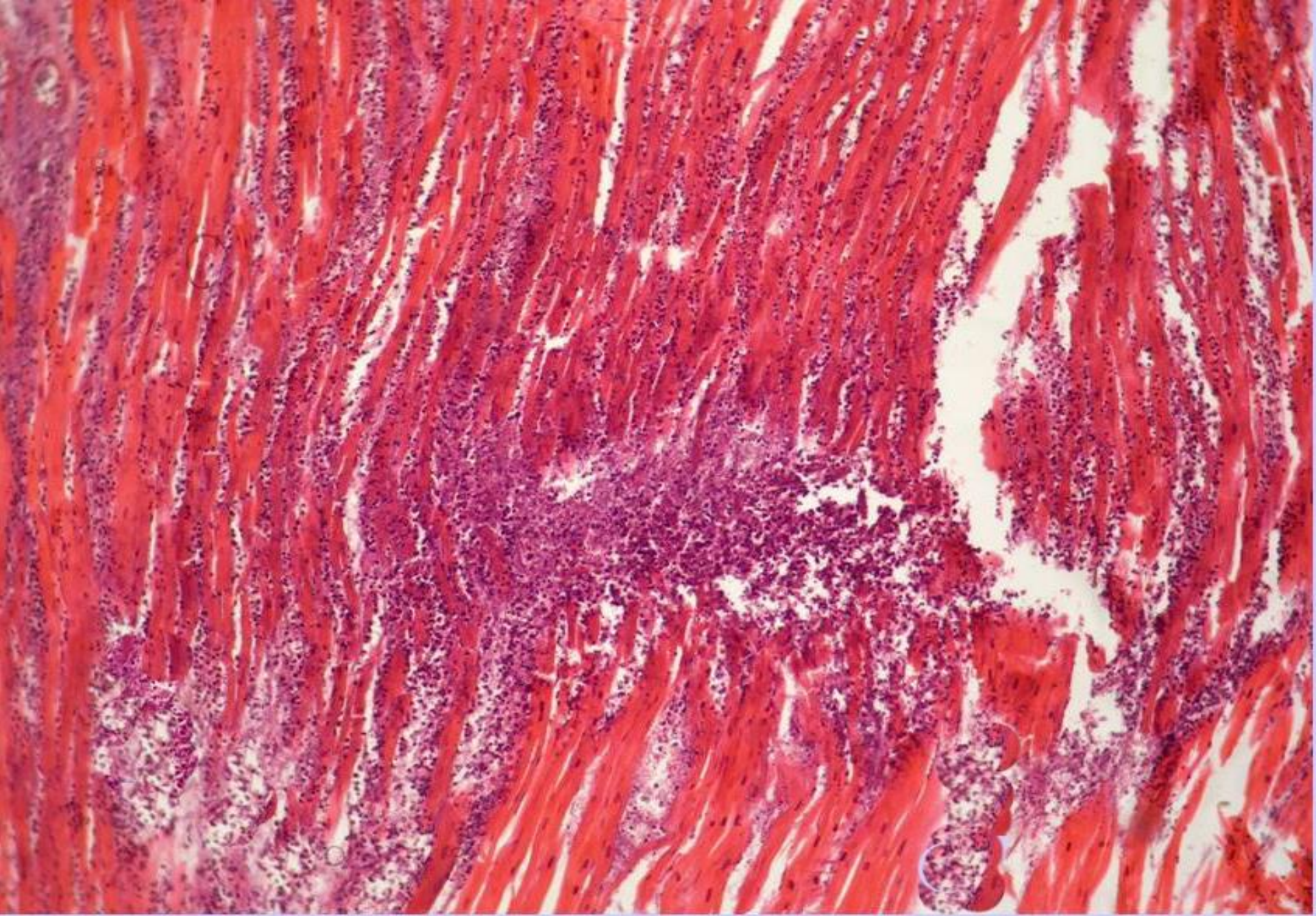
**Stenosing coronary atherosclerosis.**



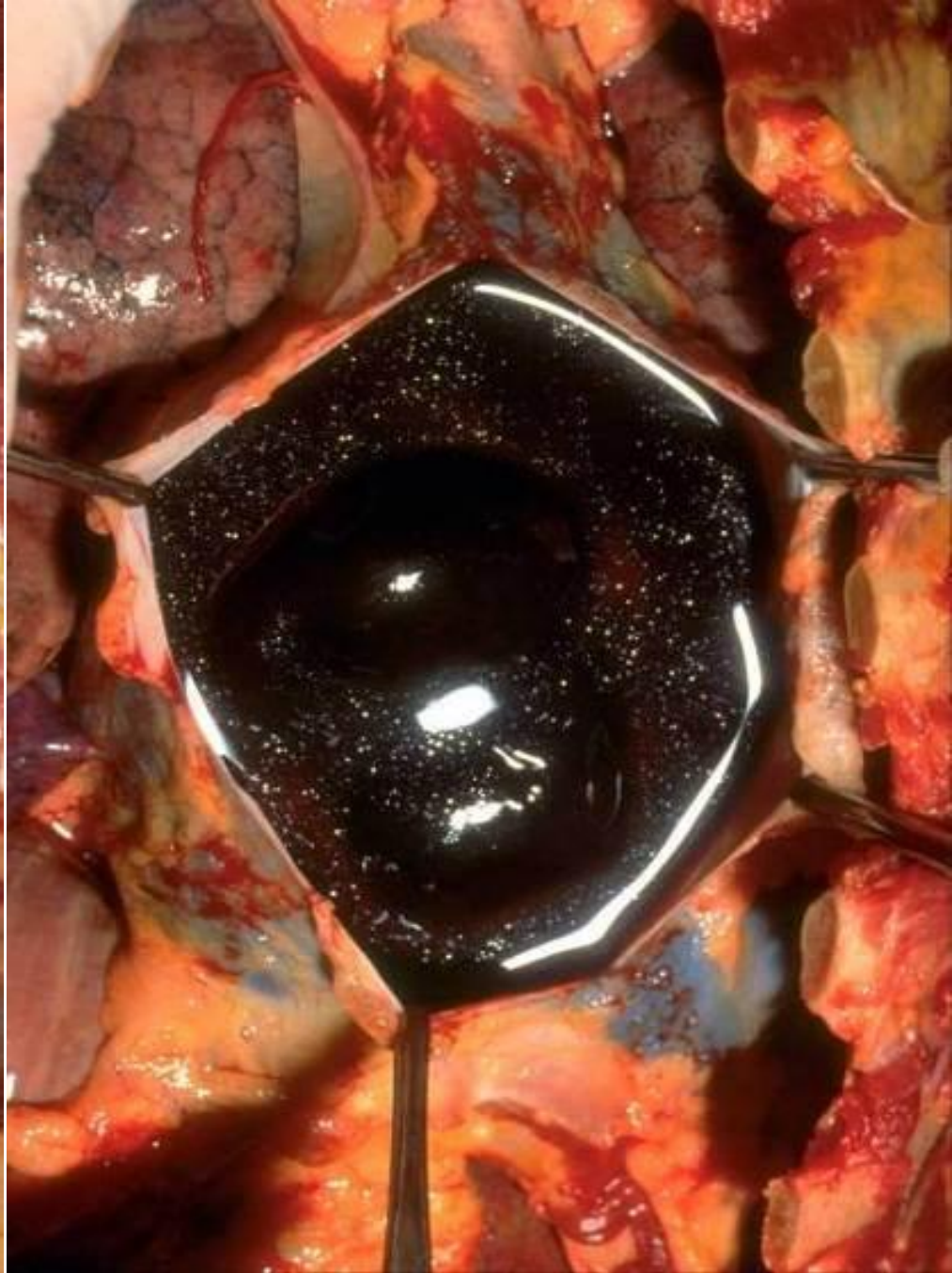
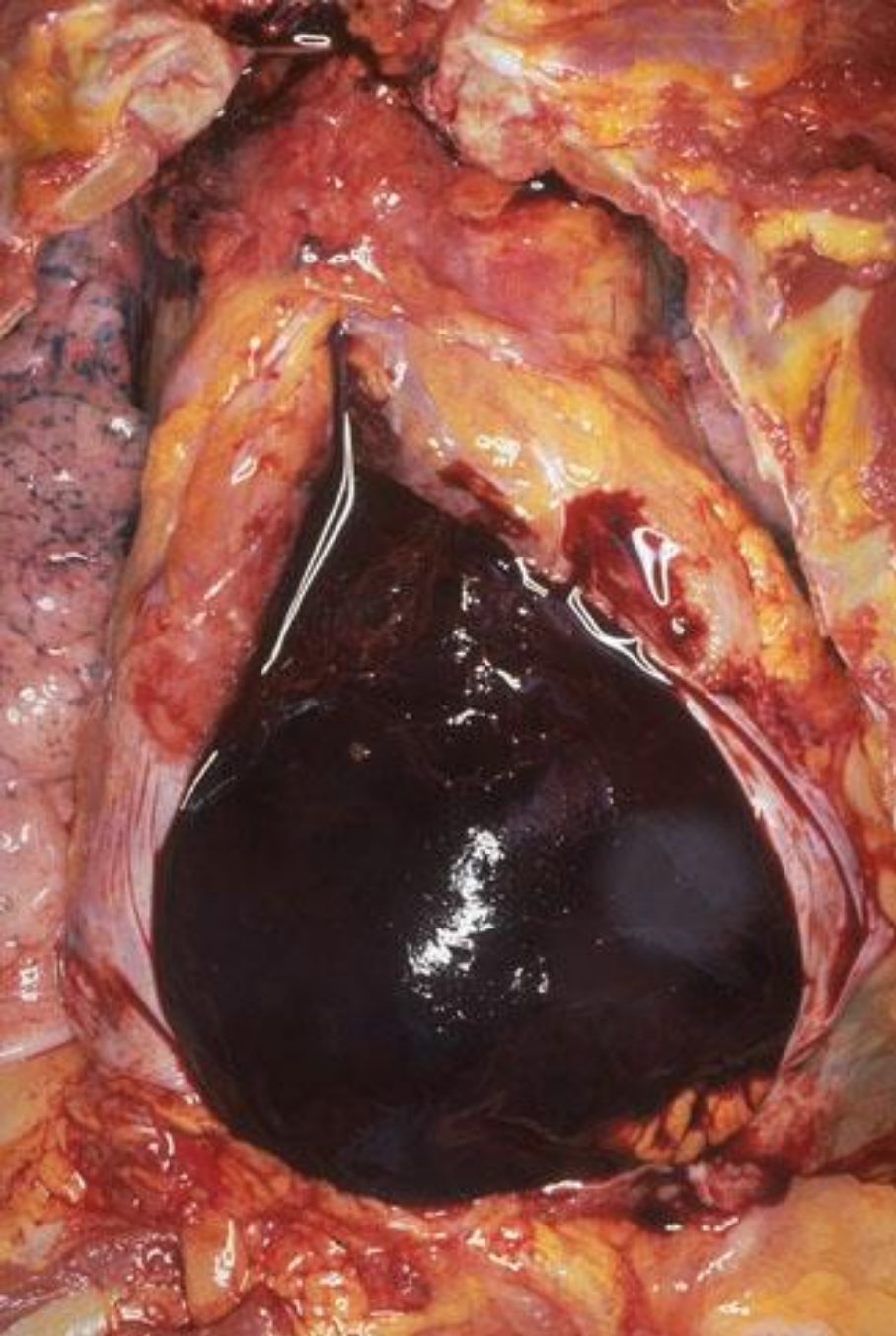
**Coronary thrombosis.**

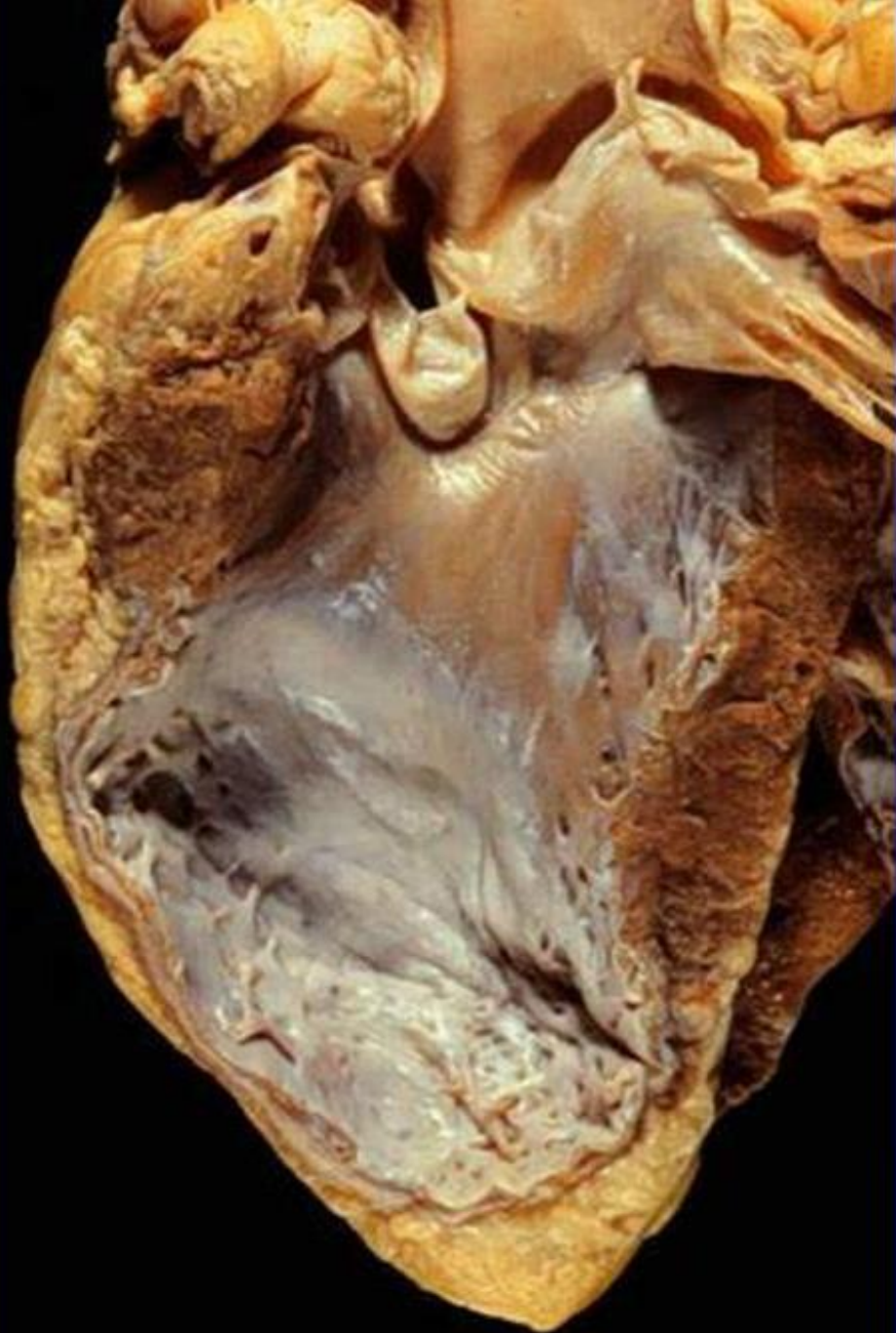




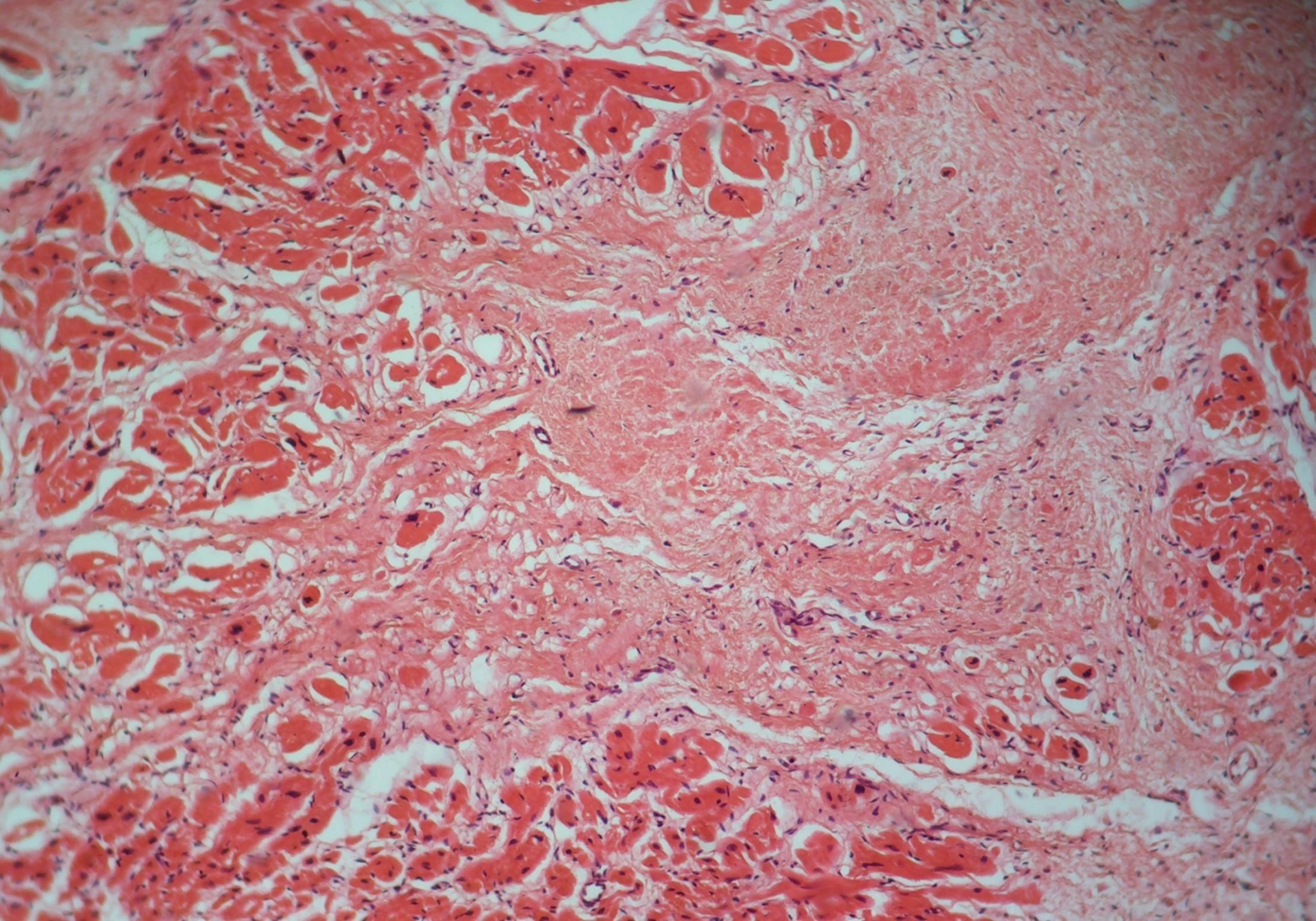
**Leukocyte infiltration in the area of heart rupture.**



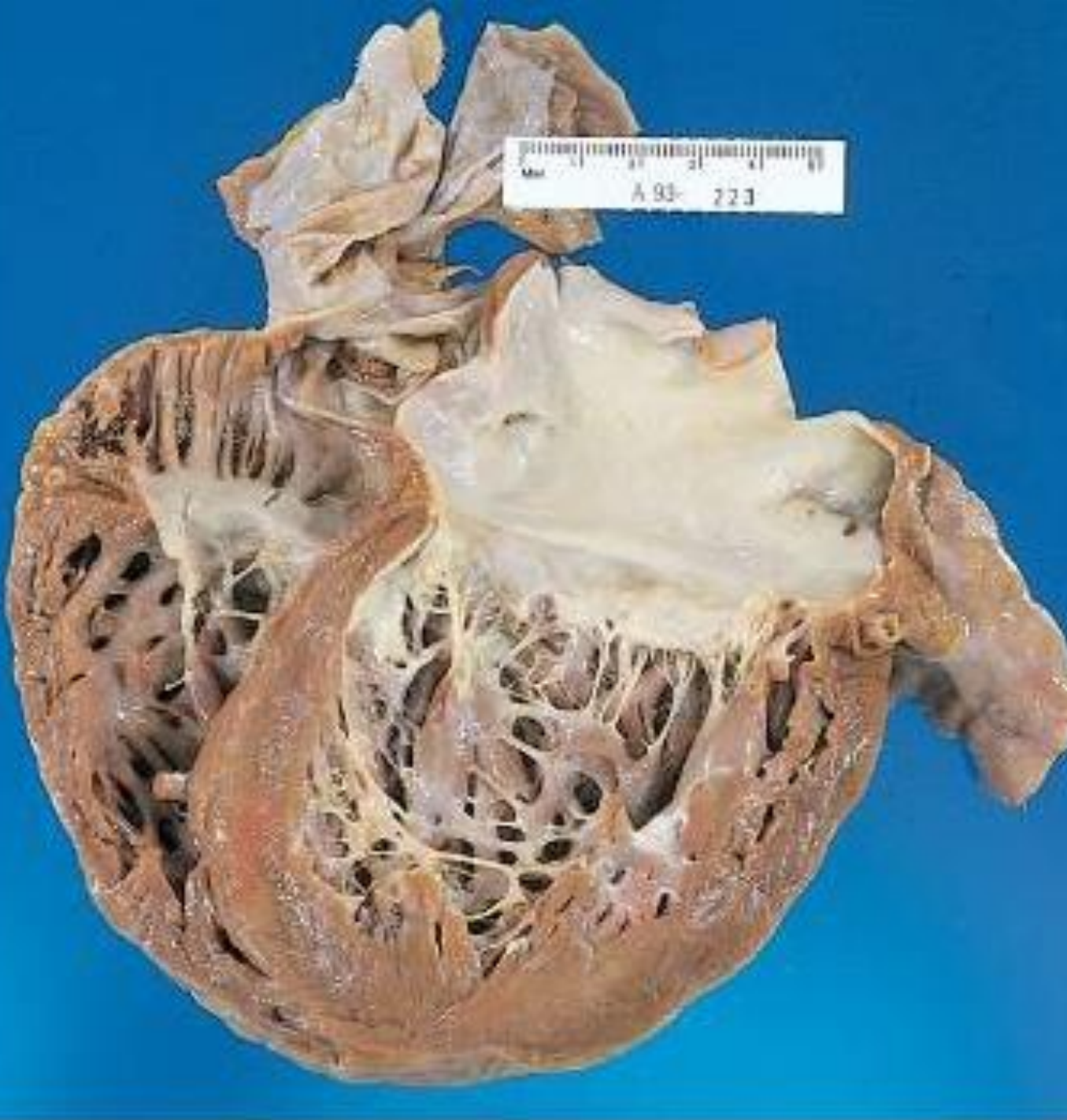
**Hemopericardium.**



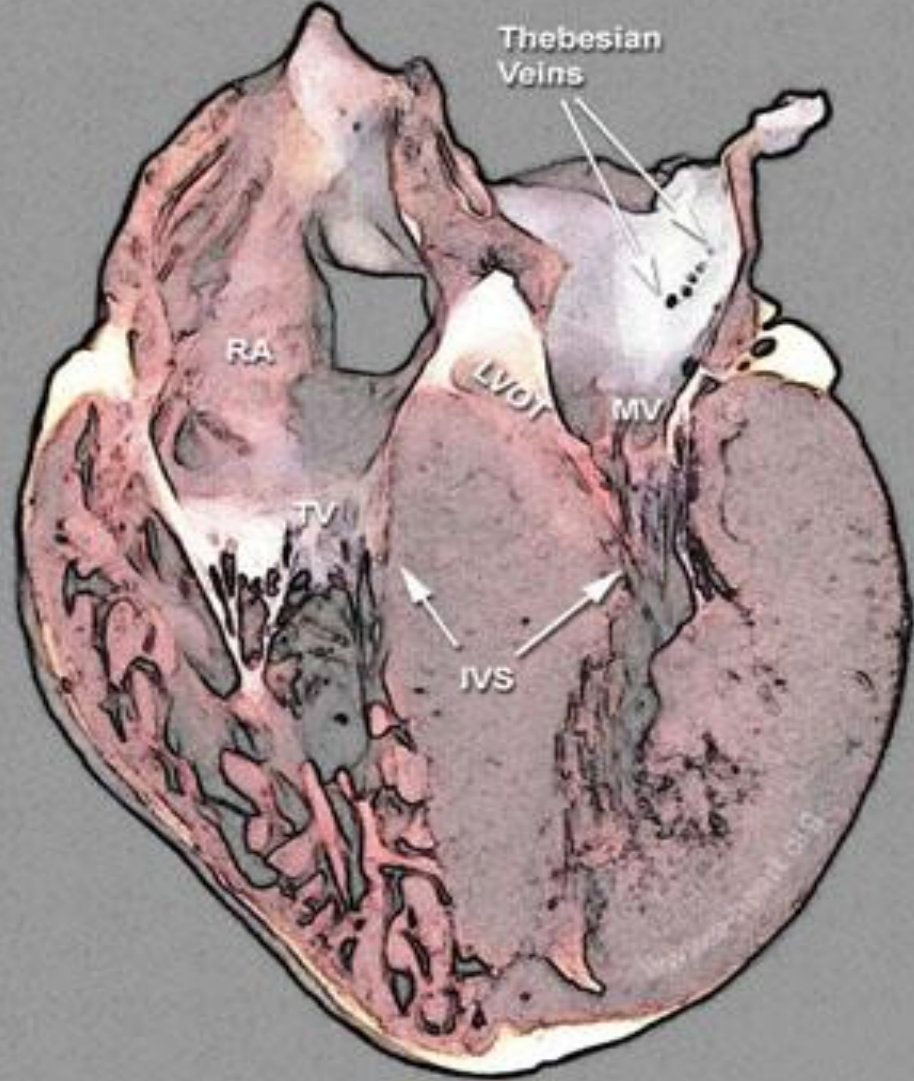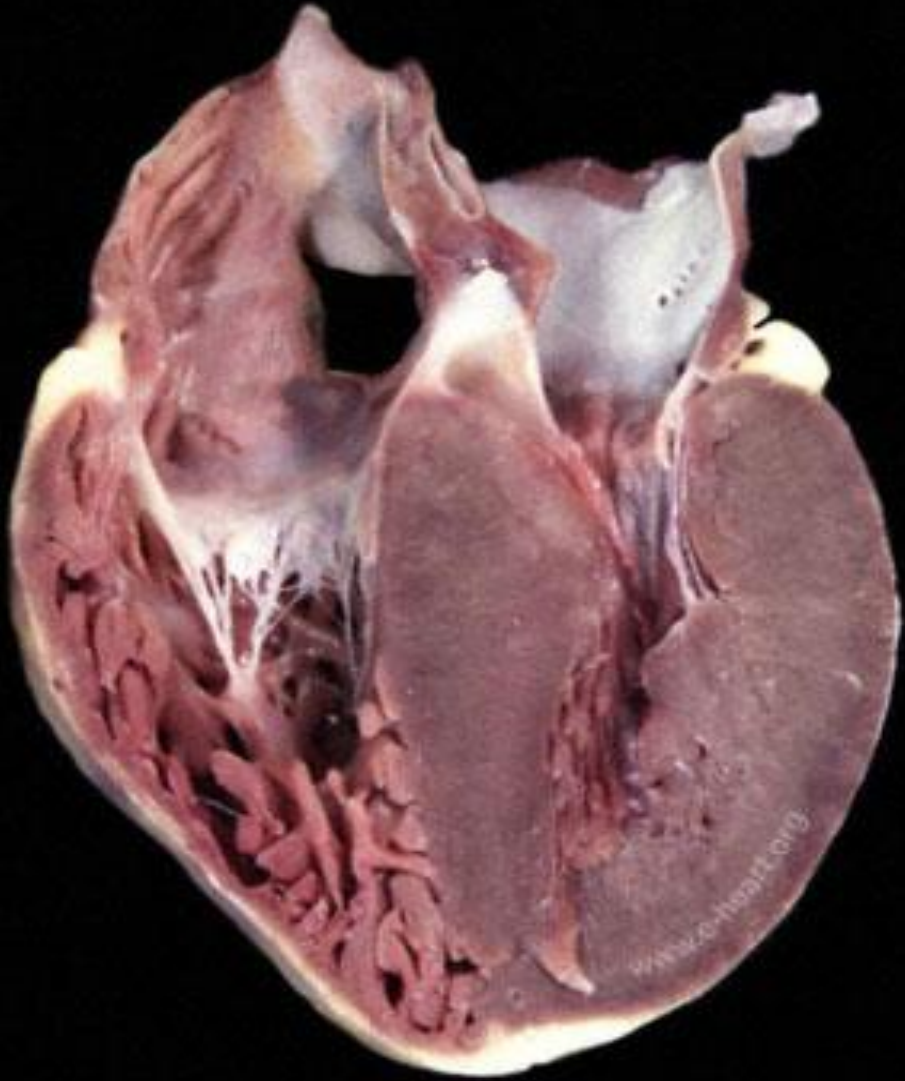
**Chronic postinfarction cardiac aneurysm.**



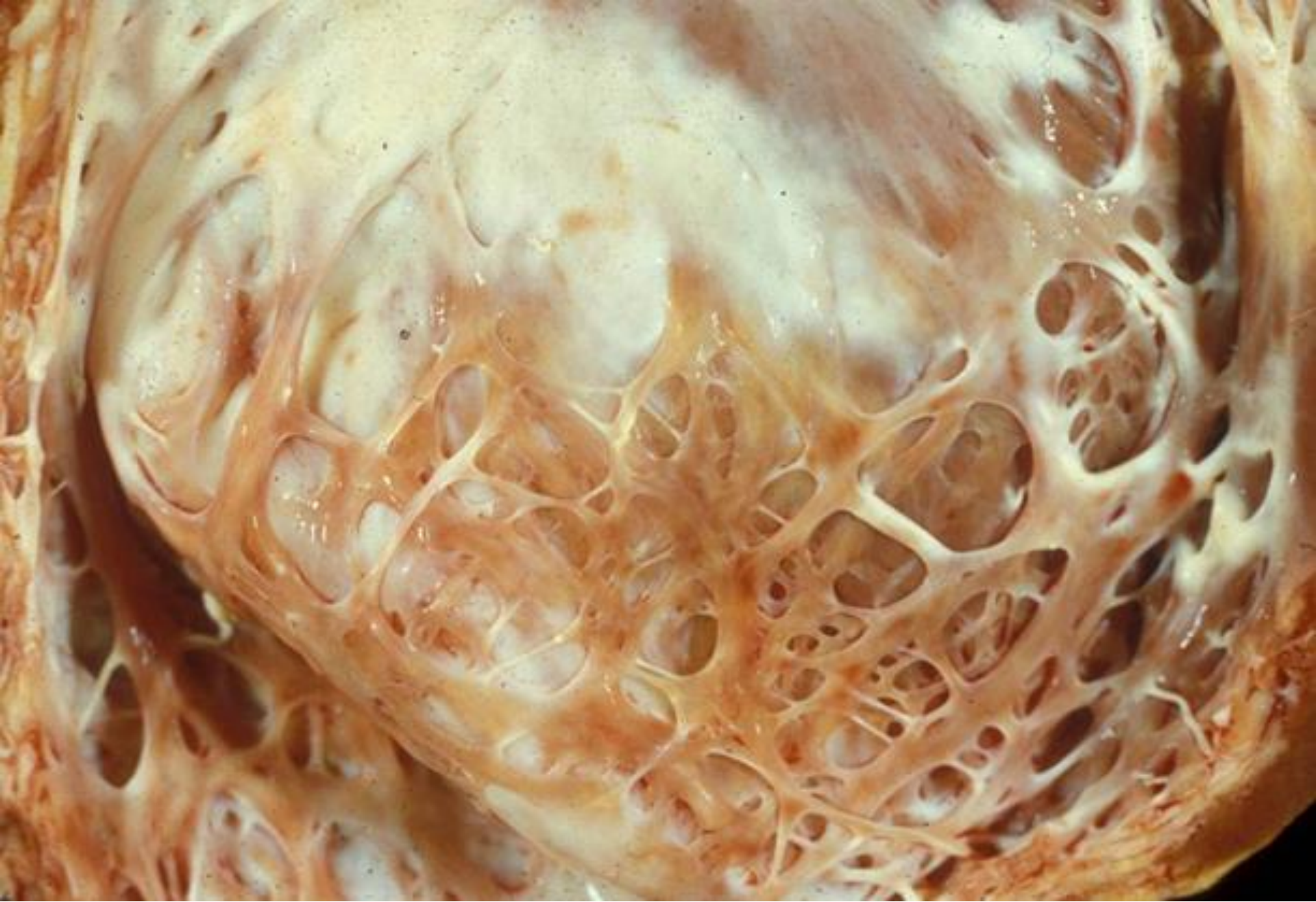**Regenerative myocardial hypertrophy.**



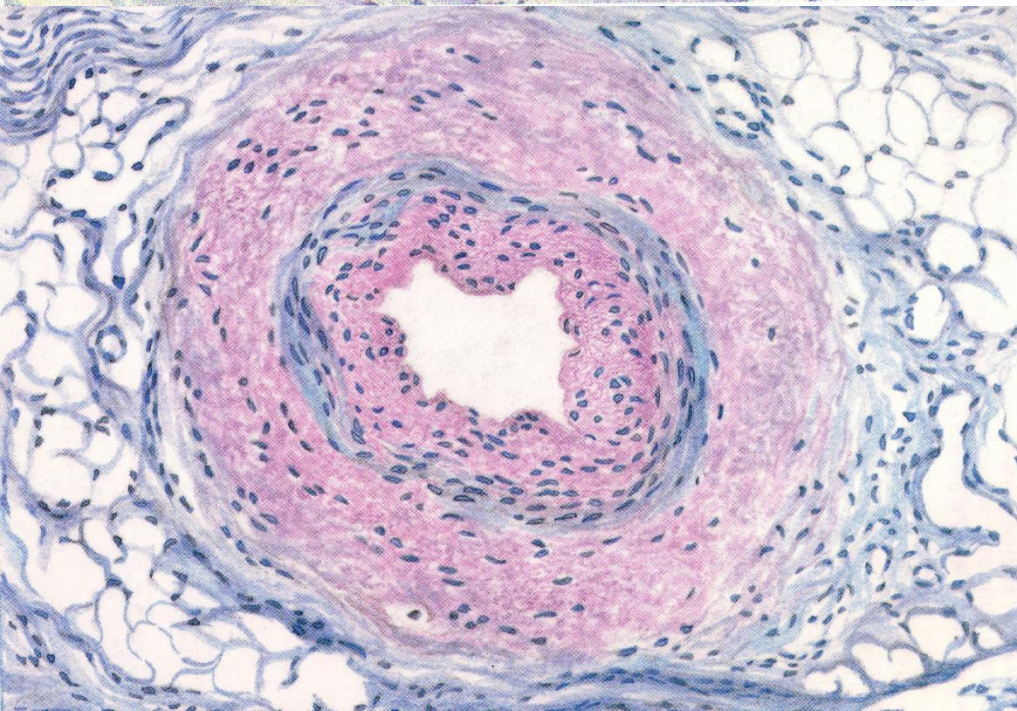
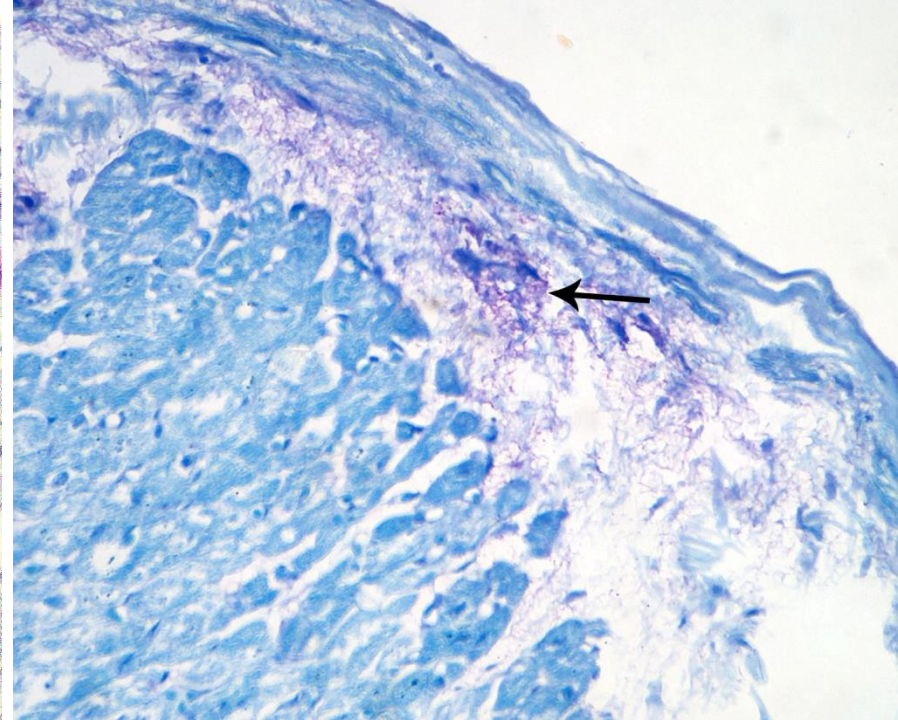
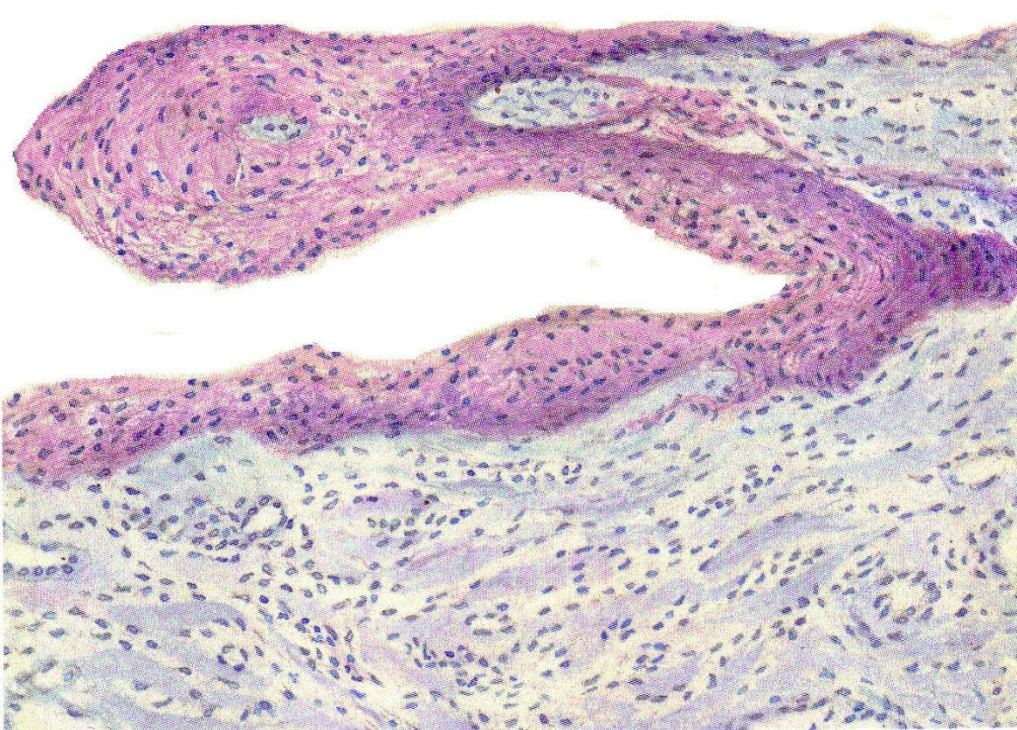
**Congestive  
cardiomyopathy  
(*dilated*).**



**Hypertrophic cardiomyopathy.**

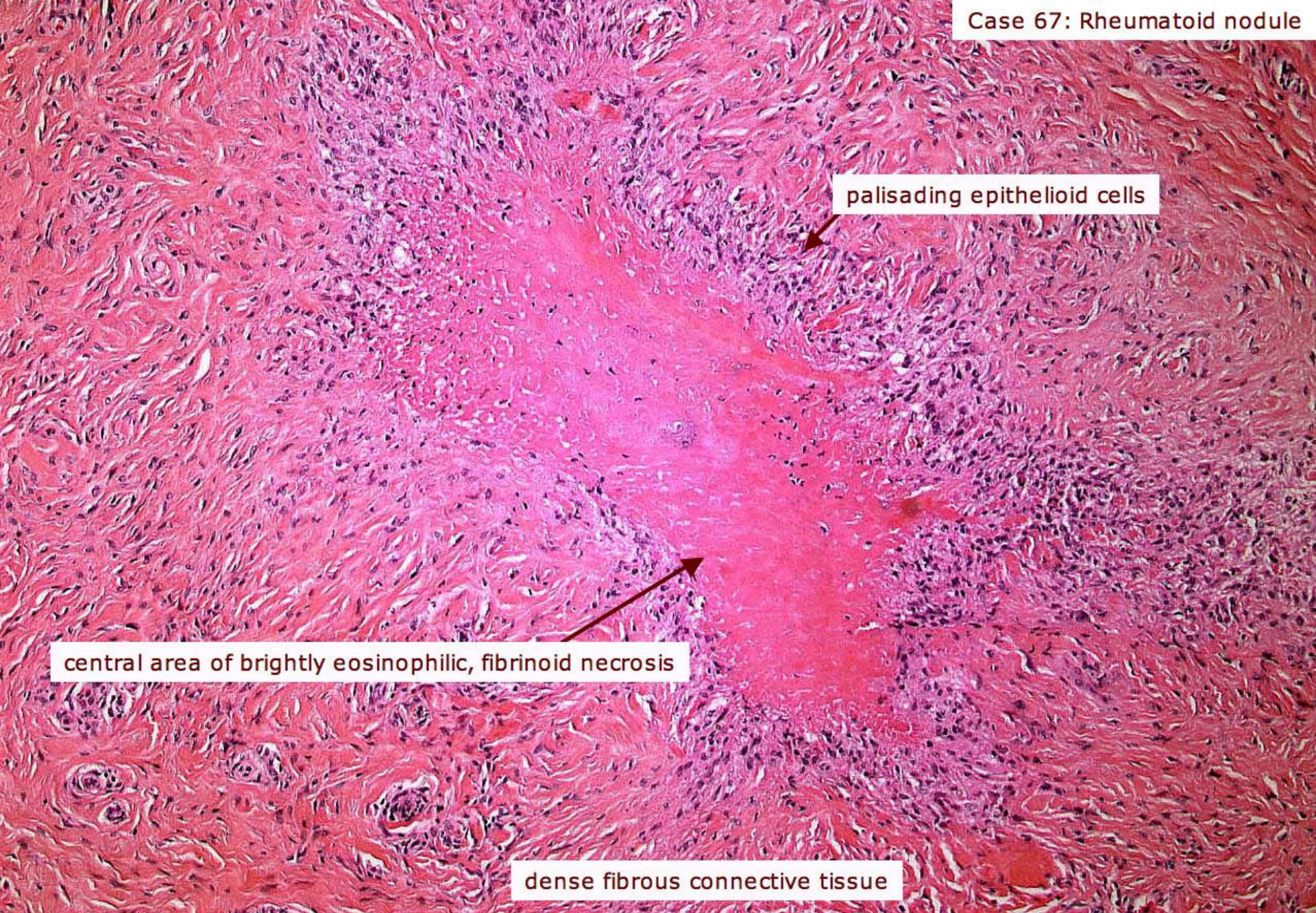


**Restrictive cardiomyopathy (endomyocardial fibrosis).**



**Mucoid intumescence  
of the endocardium and arterial wall  
in rheumatic fever  
(*metachromasia of connective tissue  
with toluidine blue staining*)**



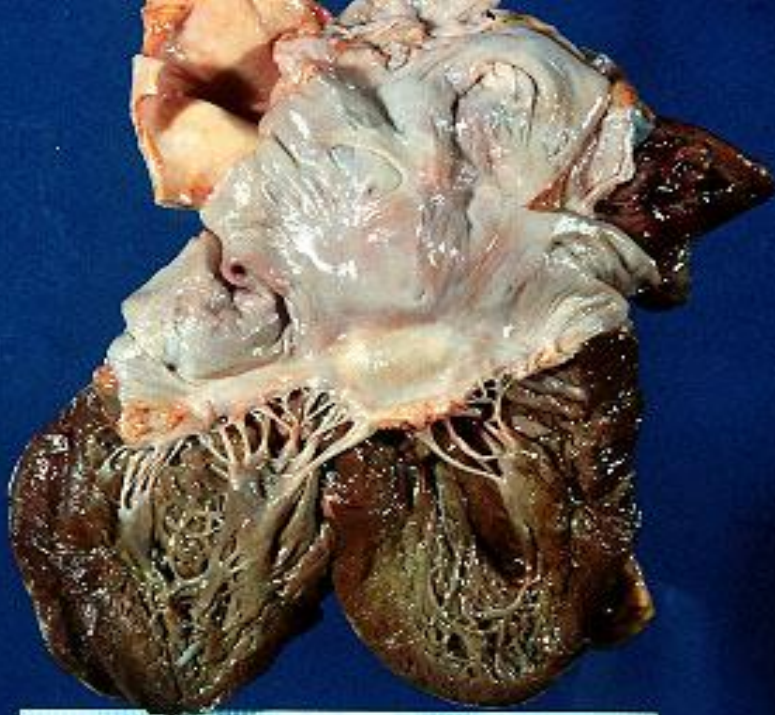

palisading epithelioid cells

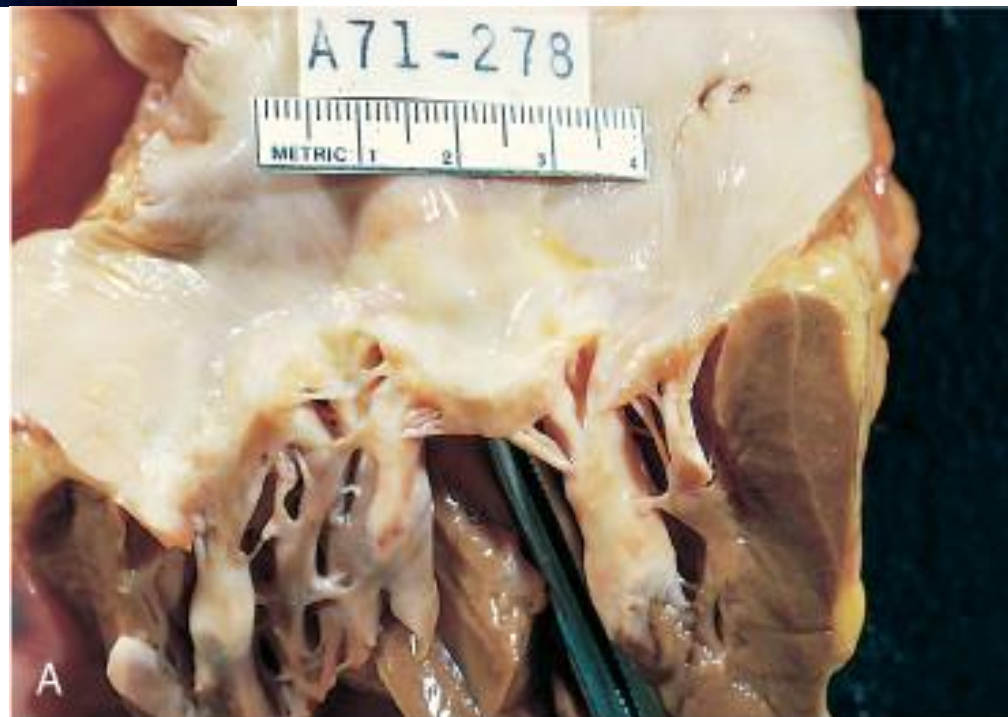
central area of brightly eosinophilic, fibrinoid necrosis

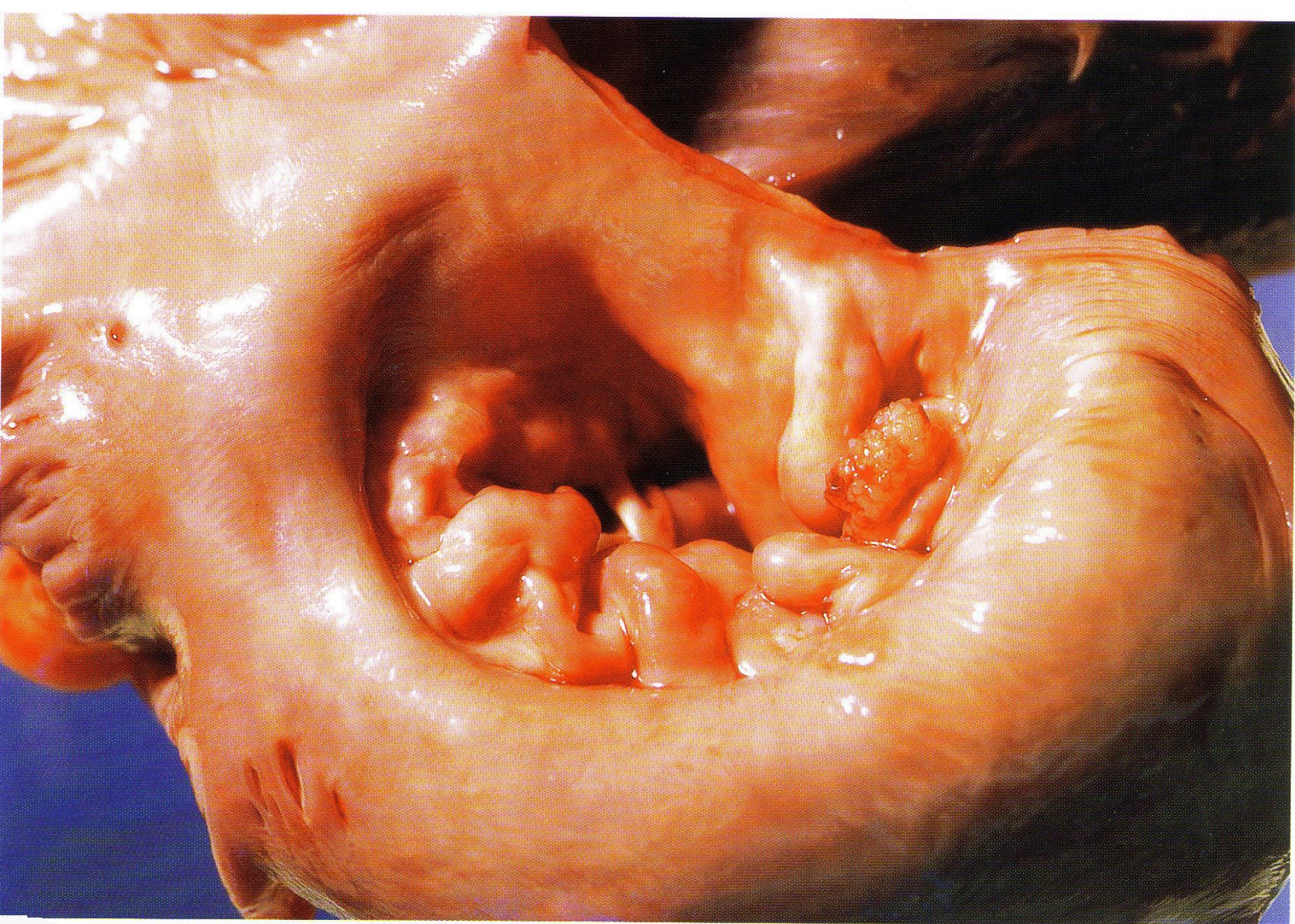
dense fibrous connective tissue

**Fibrinoid necrosis of connective tissue.**

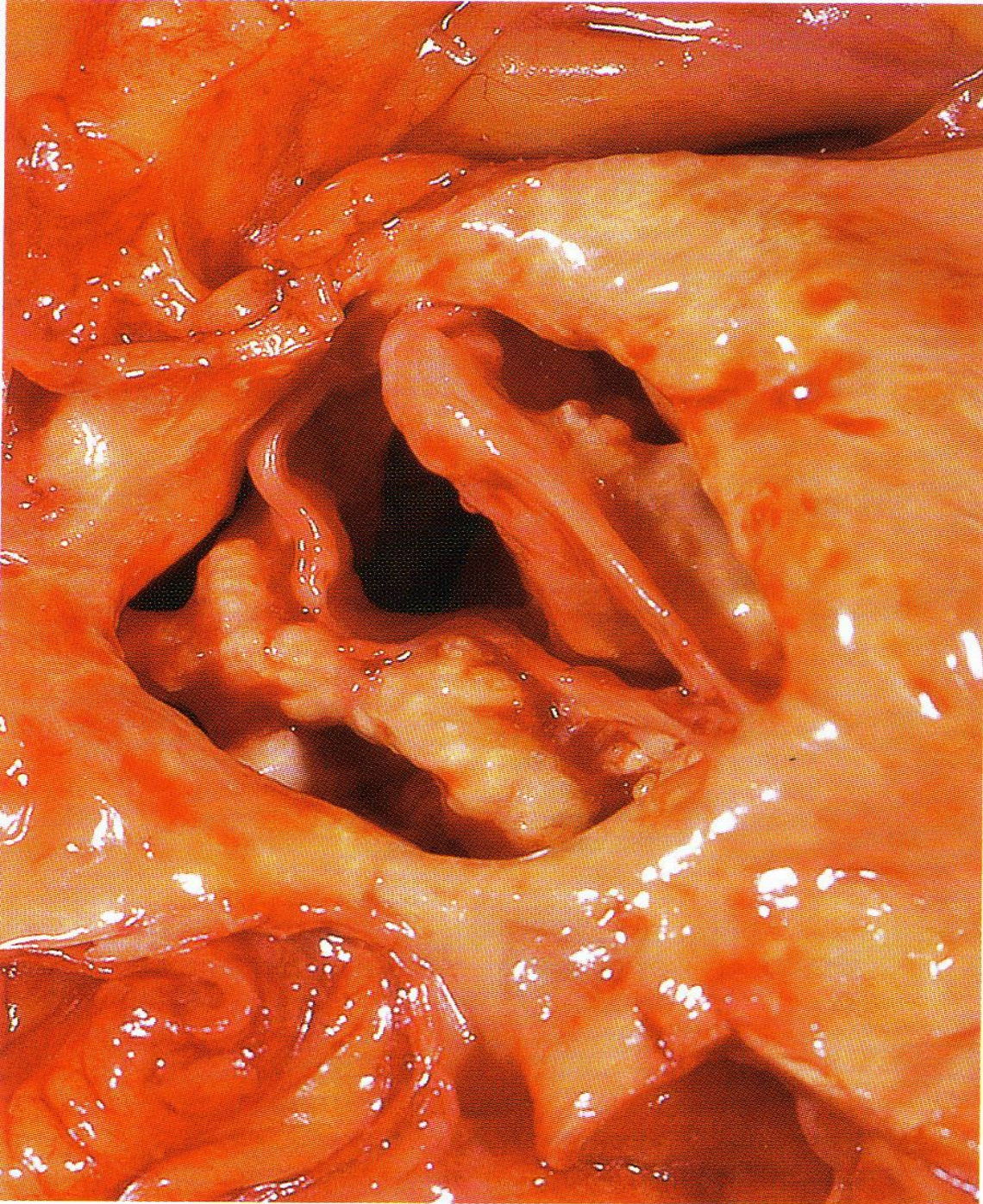


**Chronic verrucous valvular endocarditis.**





**Mitral stenosis (*view from left atrium*).**



**Aortic stenosis.**

# THE HEART

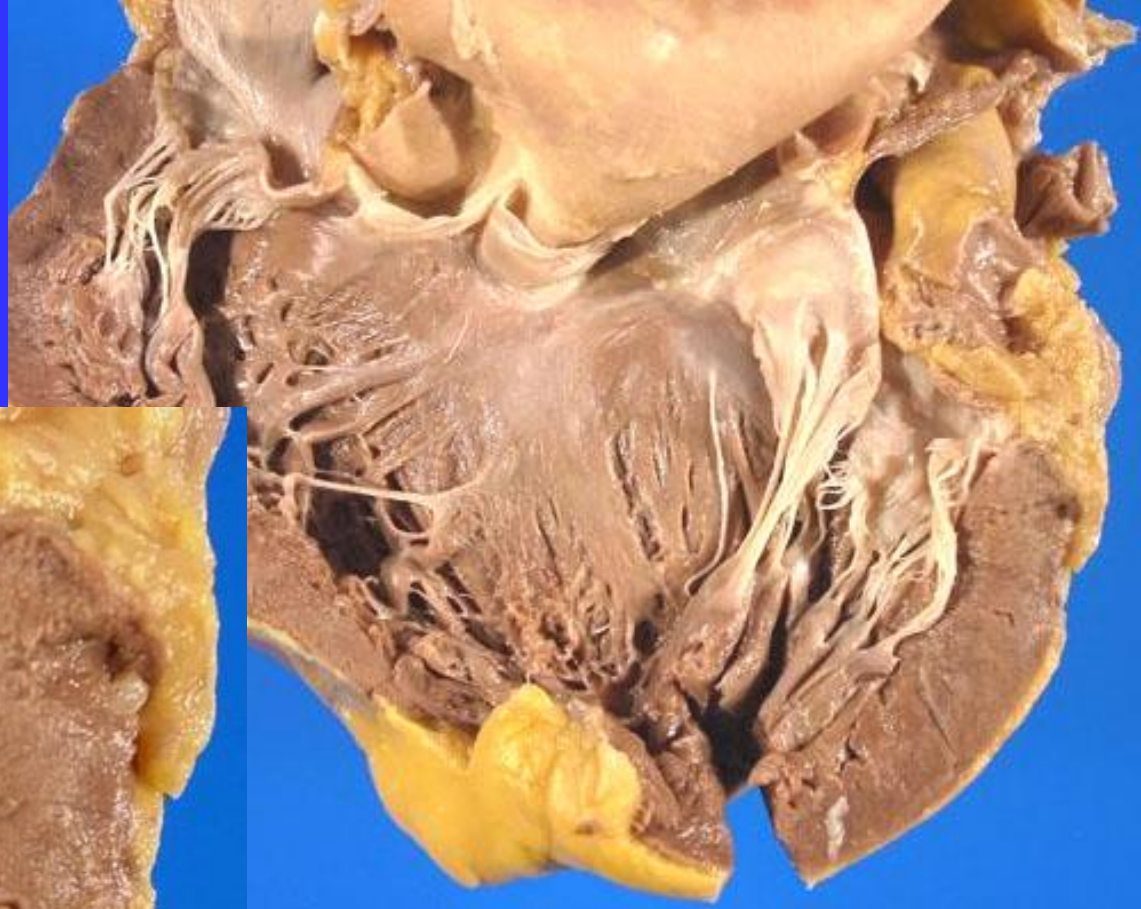
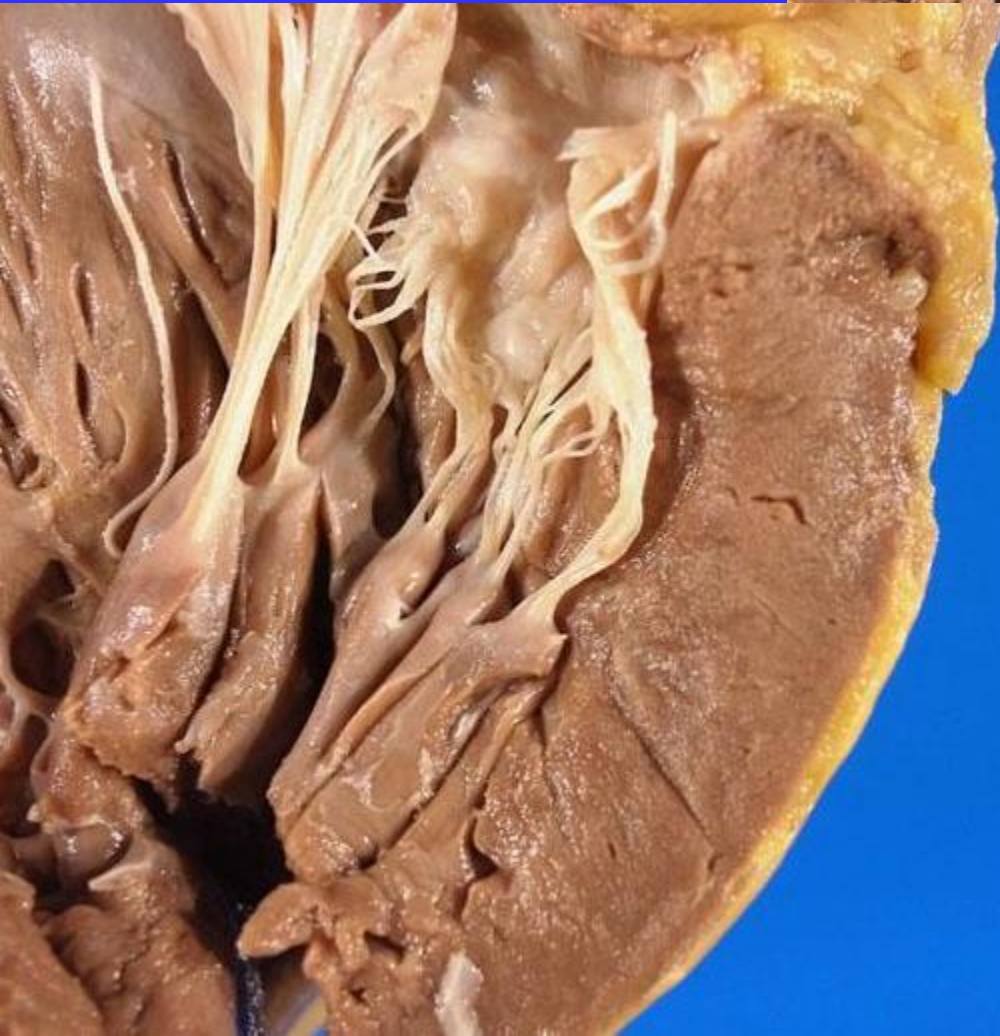- **Normal**
- **Pathology**
  - **Heart Failure: L, R**
  - **Heart Disease**
    - **Congenital: L→R shunts, R→L shunts, Obstructive**
    - **Ischemic: Angina, Infarction, Chronic Ischemia, Sudden Death**
    - **Hypertensive: Left sided, Right sided**
    - **Valvular: AS, MVP, Rheumatic, Infective, Non-Infective, Carcinoid, Artificial Valves**
    - **Cardiomyopathy: Dilated, Hypertrophic, Restrictive, Myocarditis, Other**
    - **Pericardium: Effusions, Pericarditis**
    - **Tumors: Primary, Effects of Other Primaries**
    - **Transplants**

# NORMAL Features

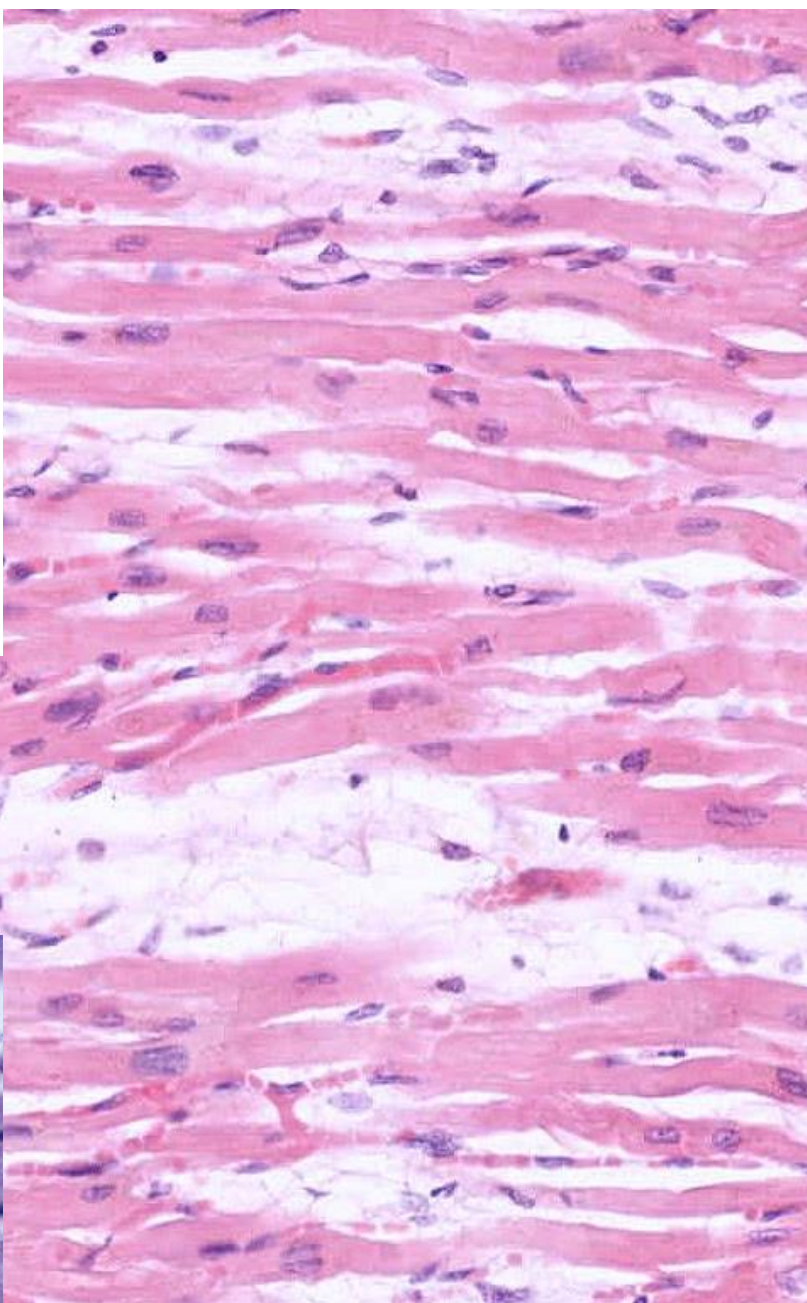
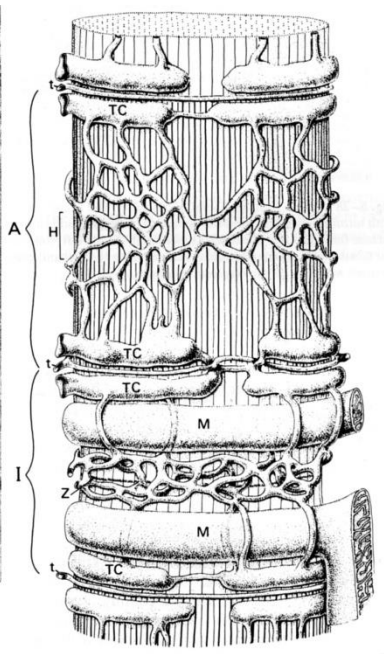
- 6000 L/day
- 250-300 grams
- 40% of all deaths (2x cancer)
- Wall thickness ~ pressure
- (i.e., a wall is only as thick as it has to be)
  - LV=1.5 cm
  - RV= 0.5 cm
  - Atria =.2 cm
- Systole/Diastole
- Starling's Law

# TERMS

- **CARDIOMEGALY**
- **DILATATION**, any chamber, or all
- **HYPERTROPHY**, and chamber, or all







**STRIATIONS**

**NUCLEUS**

**DISCS**

**SARCOLEMMA**

**SARC. RETIC.**

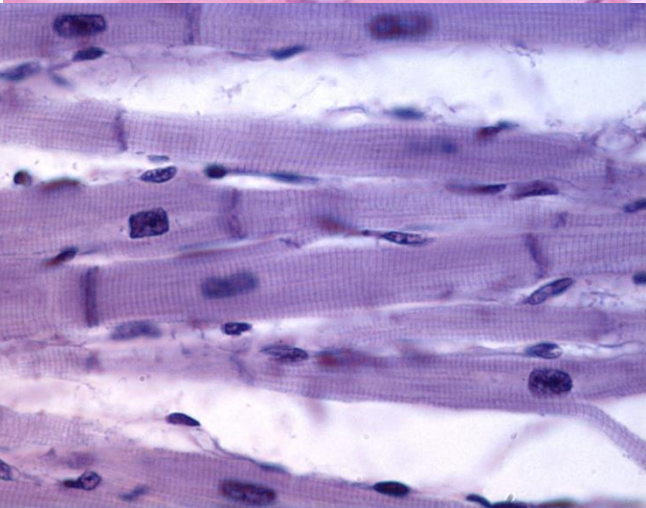
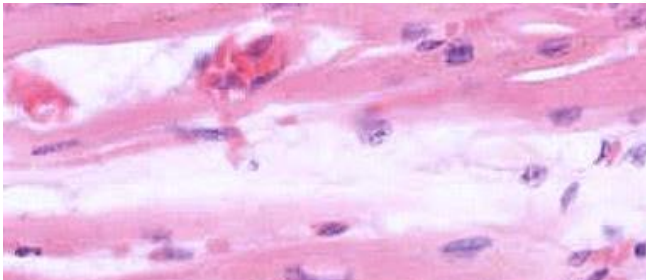
**MITOCHONDRIA**

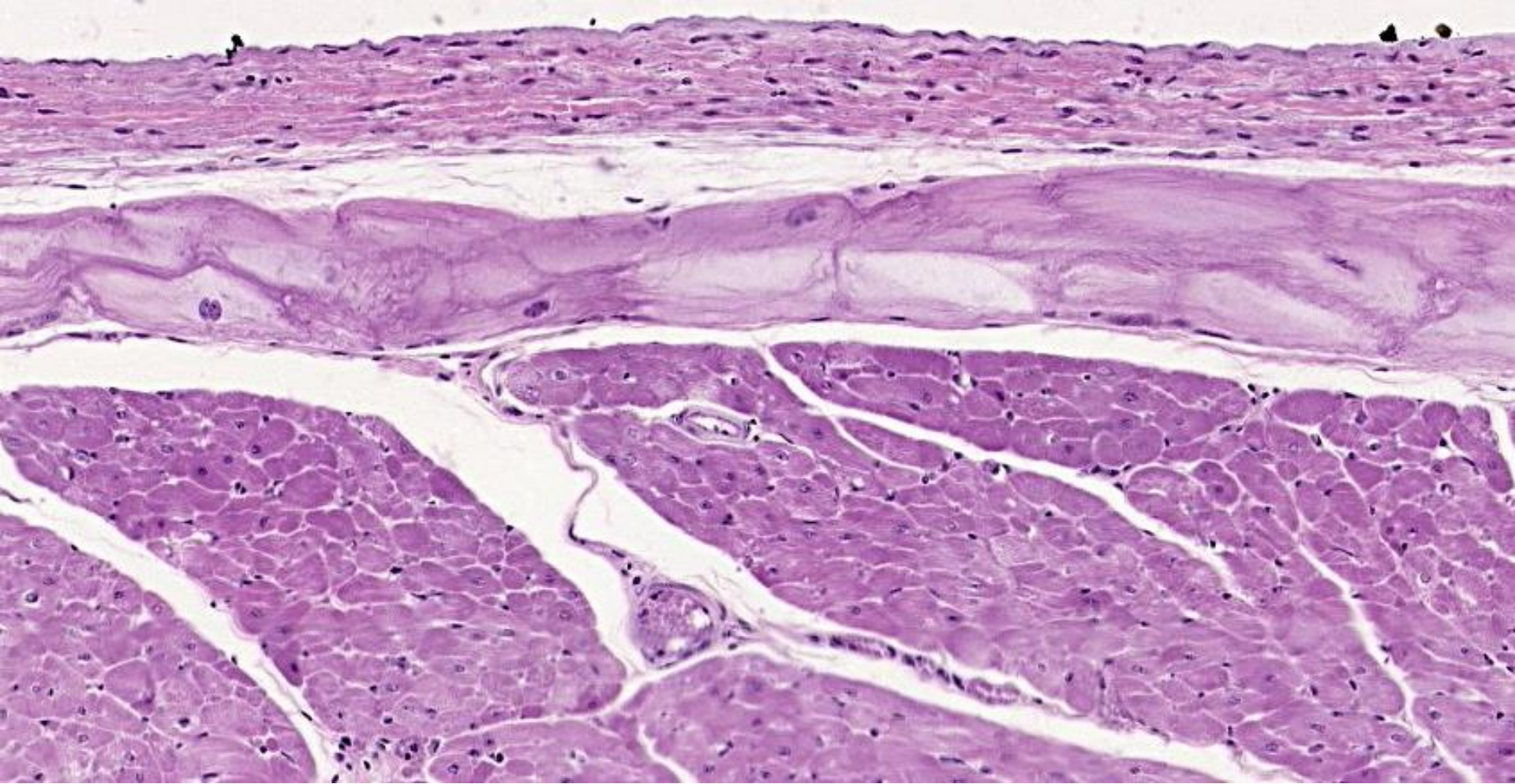
**ENDOTHELIUM**

**FIBROBLASTS**

**GLYCOGEN**

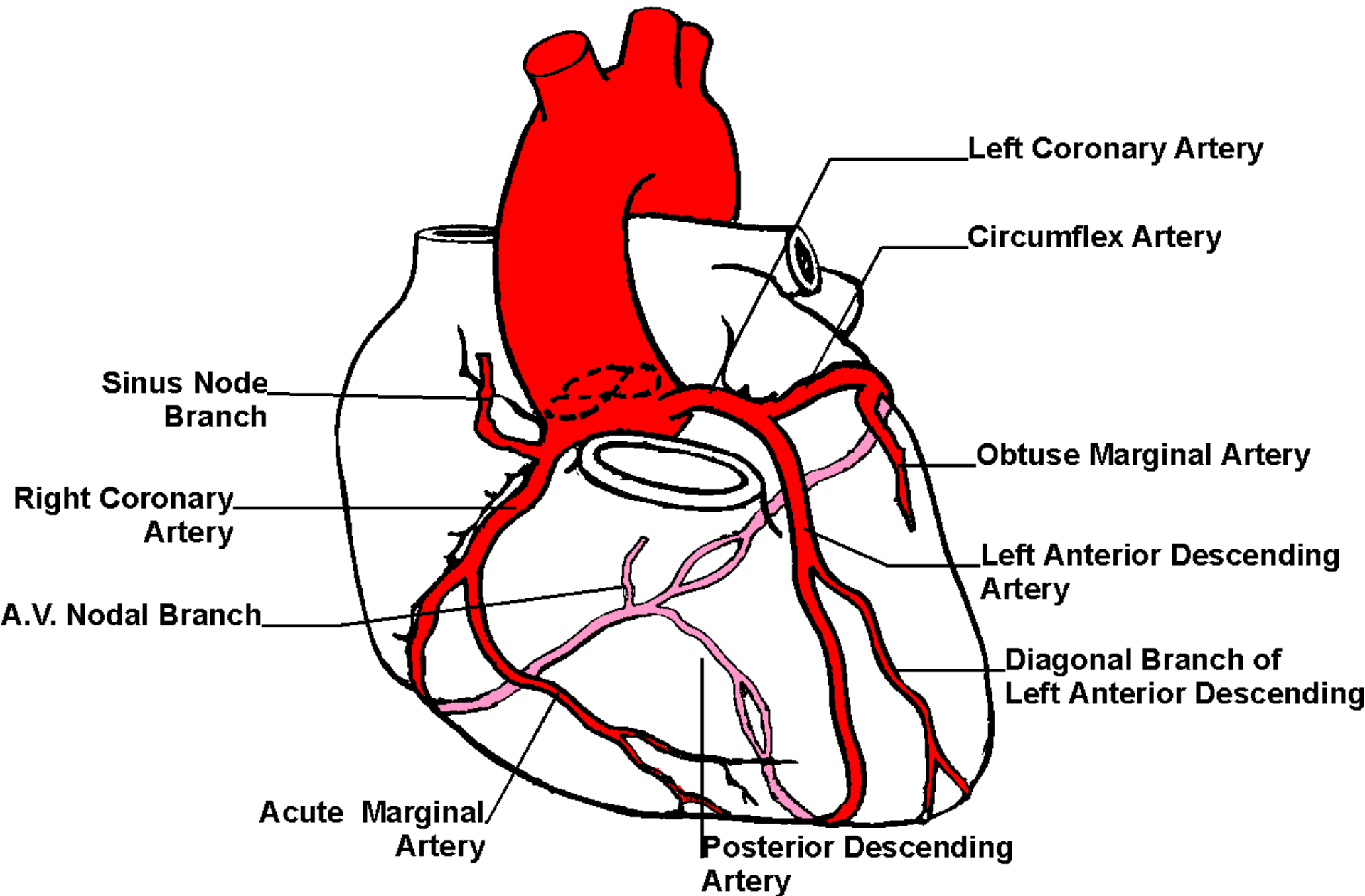
**A.N.P.**

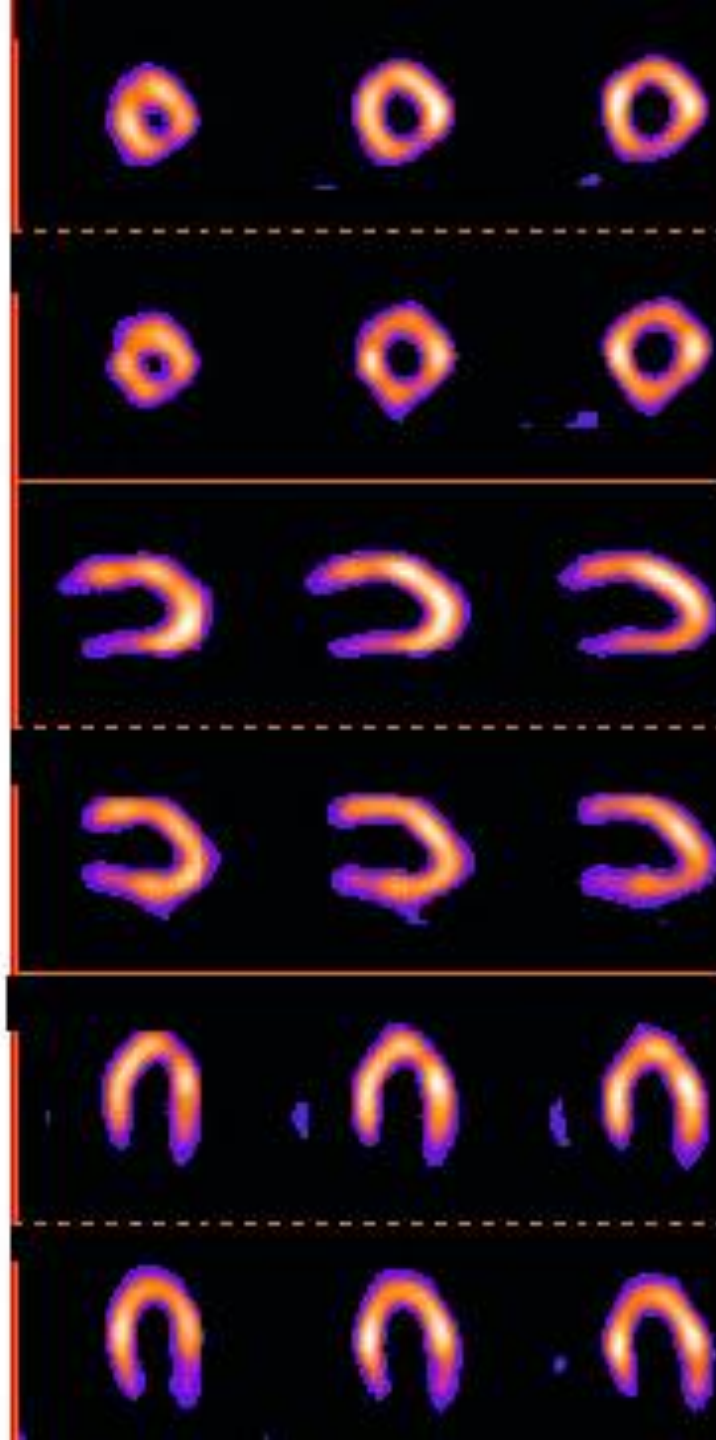
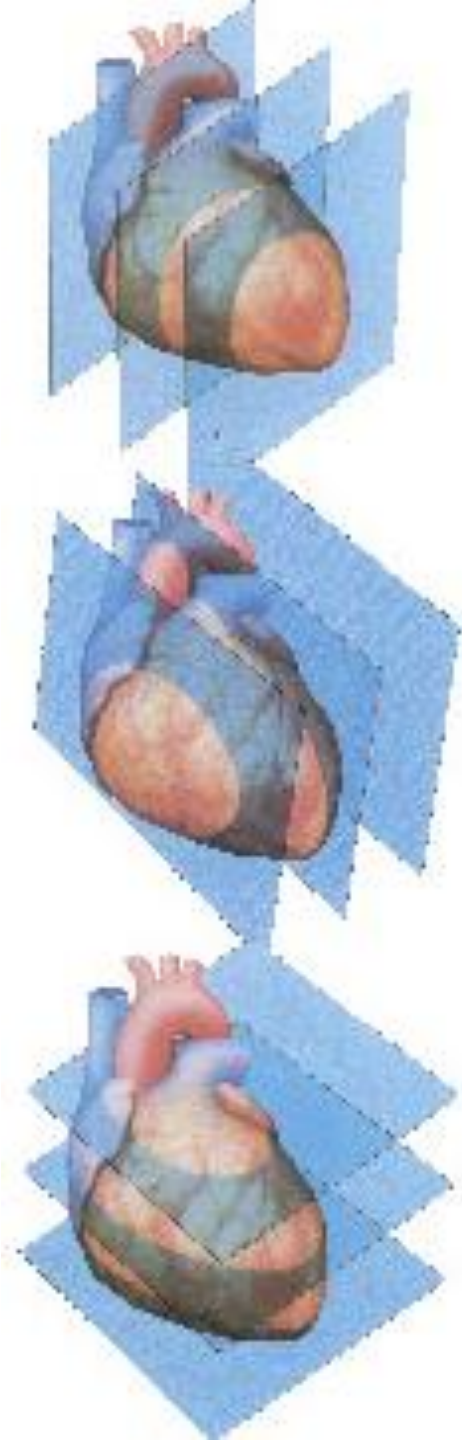




**S.A. Node → AV Node → Bundle of HIS → L. Bundle, R. Bundle**

# Coronary Arteries





**Anterior**

**Lateral**

**Posterior**

**Septal**

# VALVES

- **AV:**
  - **TRICUSPID**
  - **MITRAL**
- **SEMILUNAR:**
  - **PULMONIC**
  - **AORTIC**

# CARDIAC AGING

## Chambers

Increased left atrial cavity size

Decreased left ventricular

sigmoid-shaped ventricular  
cavity size  
septum

## Valves

Aortic valve calcific deposits

Mitral valve annular calcific deposits

Fibrous thickening of leaflets

Buckling of mitral leaflets toward

## Epicardial Coronary Arteries

Tortuosity

Increased cross-sectional

Calcific deposits

Atherosclerotic plaque

## Myocardium

Increased mass

Increased subepicardial

fat  
Brown atrophy

Lipofuscin deposition

Basophilic

Amorphous deposits

# CARDIAC AGING

## Aorta

Dilated ascending aorta with rightward shift

Elongated (tortuous) thoracic aorta

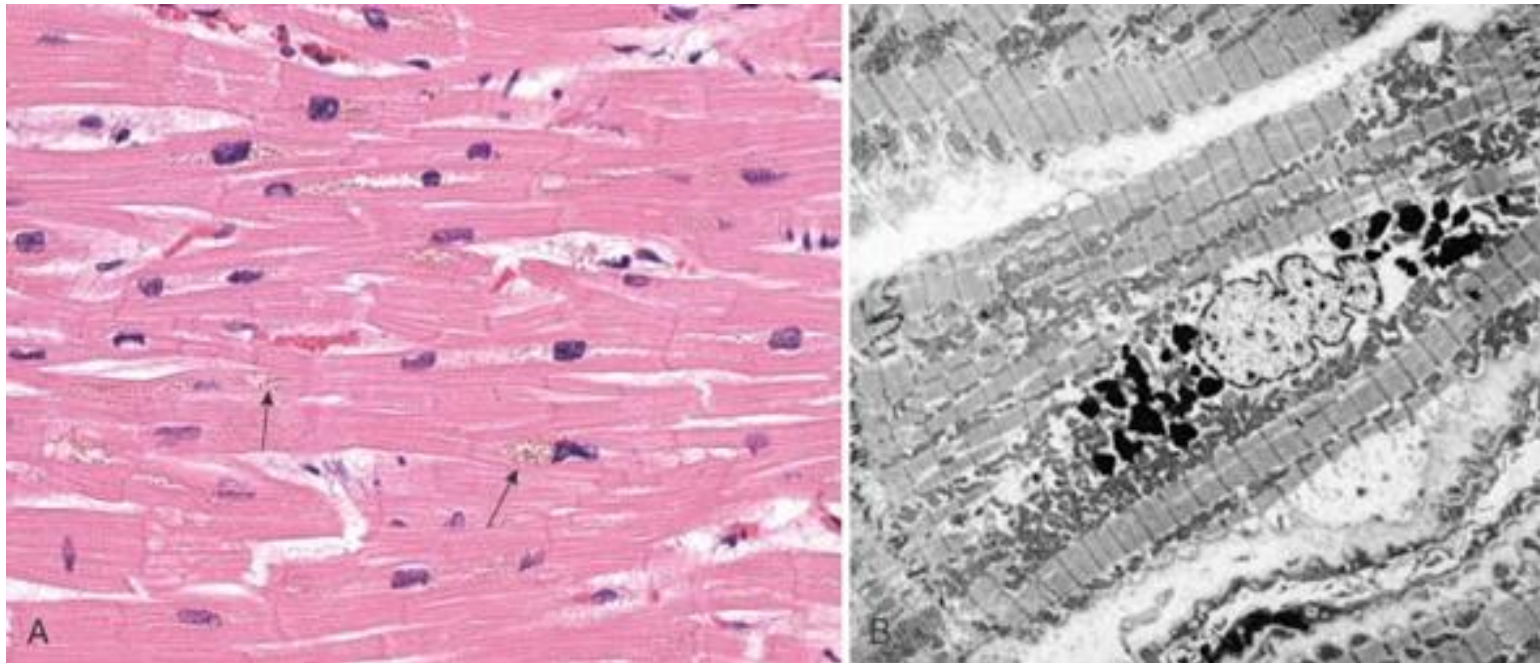
Sinotubular junction calcific deposits

Elastic fragmentation and collagen accumulation

Atherosclerotic plaque

# BROWN

ATROPHY, HEART



# LIPOFUCSIN



# Pathologic Pump Possibilities

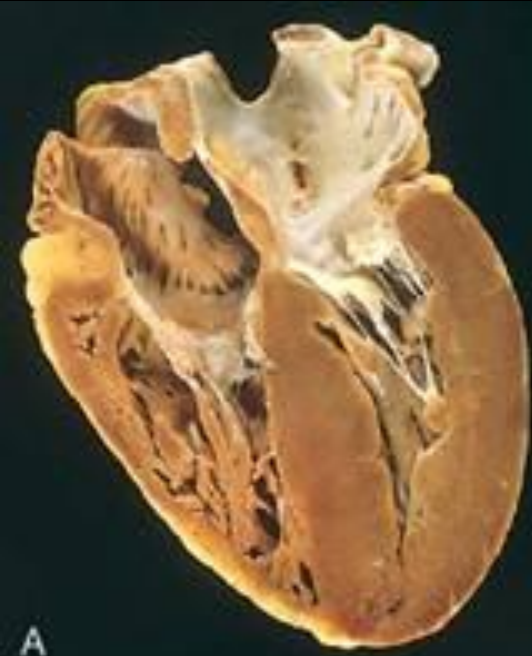- **Primary myocardial failure (MYOPATHY)**
- **Obstruction to flow (VALVE)**
- **Regurgitant flow (VALVE)**
- **Conduction disorders (CONDUCTION SYSTEM)**
- **Failure to contain blood (WALL INTEGRITY)**

# CHF

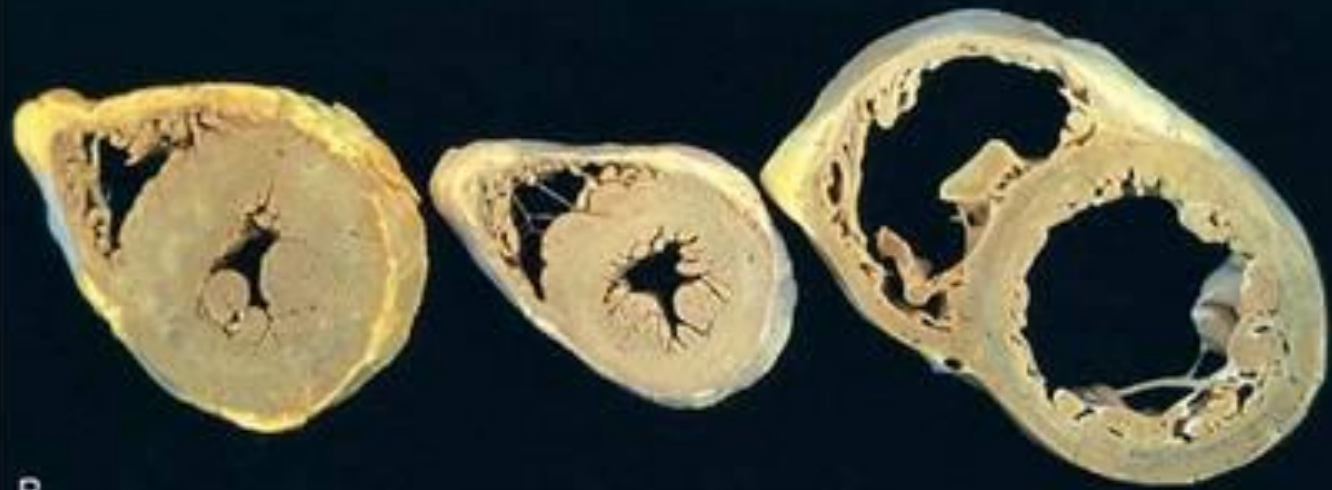- **DEFINITION**
- **TRIAD**
  - 1) **TACHYCARDIA**
  - 2) **DYSPNEA**
  - 3) **EDEMA**
- **FAILURE** of Frank Starling mechanism
- **HUMORAL FACTORS**
  - Catecholamines (nor-epinephrine)
  - Renin → Angiotension → Aldosterone
  - Atrial Natriuretic Polypeptide (ANP)
- **HYPERTROPHY** and **DILATATION**

# **HYPERTROPHY**

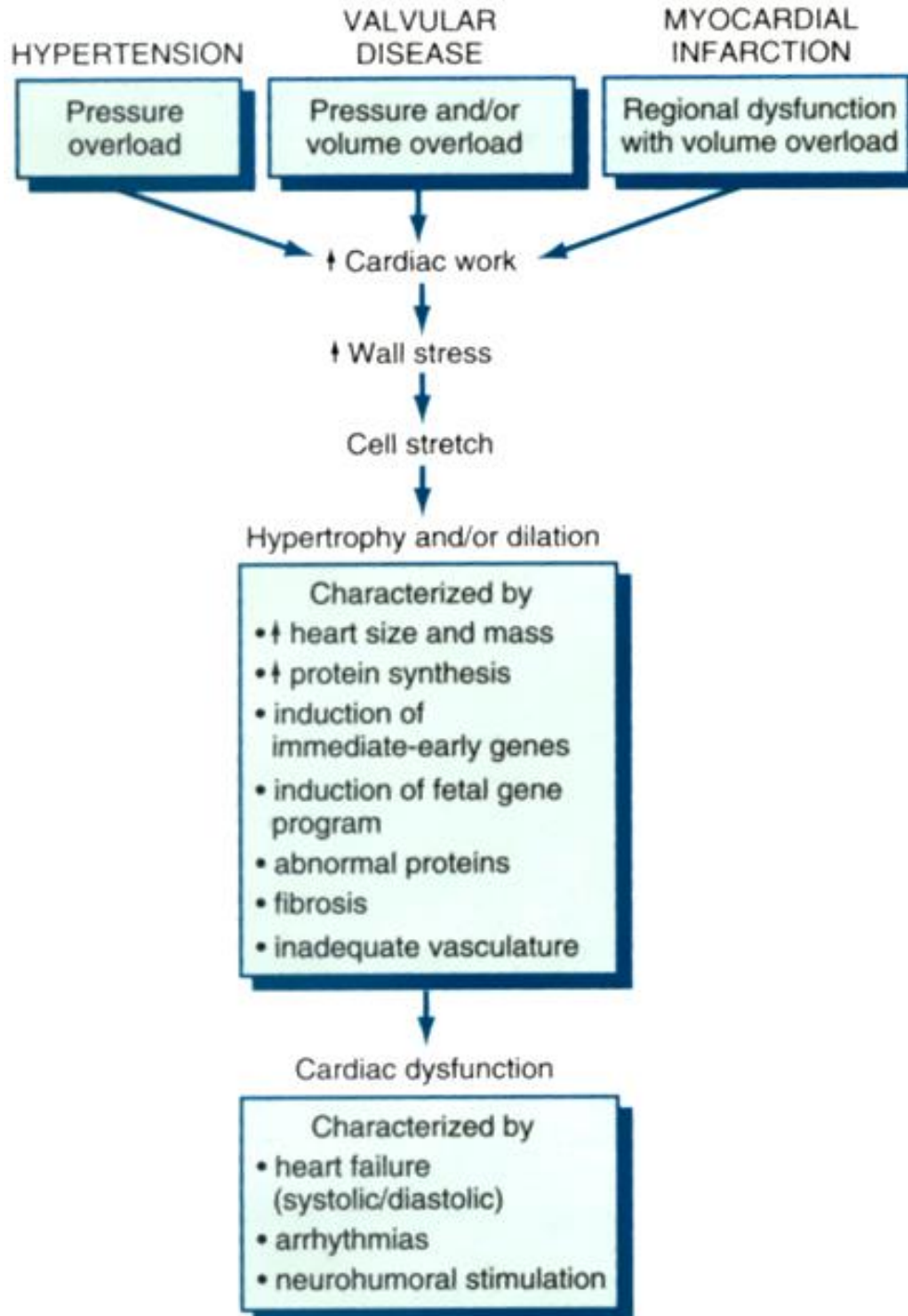
- **PRESSURE OVERLOAD (CONCENTRIC)**
- **VOLUME OVERLOAD (CHF)**
  
- **LVH, RVH, atrial, etc.**
  
- **2X normal weight → ischemia**
- **3X normal weight → HTN**
- **>3X normal weight → MYOPATHY, aortic regurgitation**



A

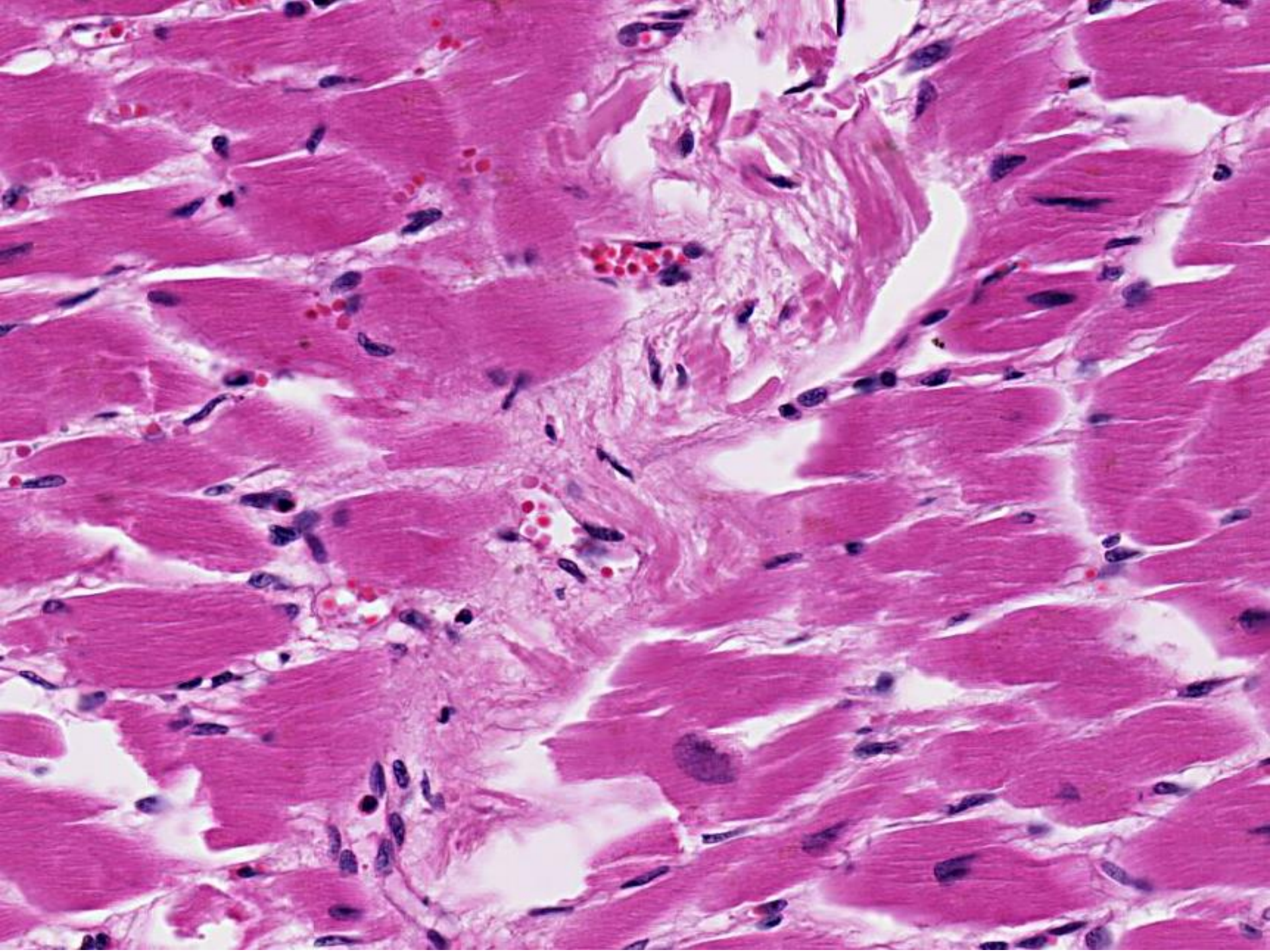


B



# CHF: Autopsy Findings

- **Cardiomegaly**
- **Chamber Dilatation**
- **Hypertrophy of myocardial fibers,  
BOXCAR nuclei**



# Left Sided Failure

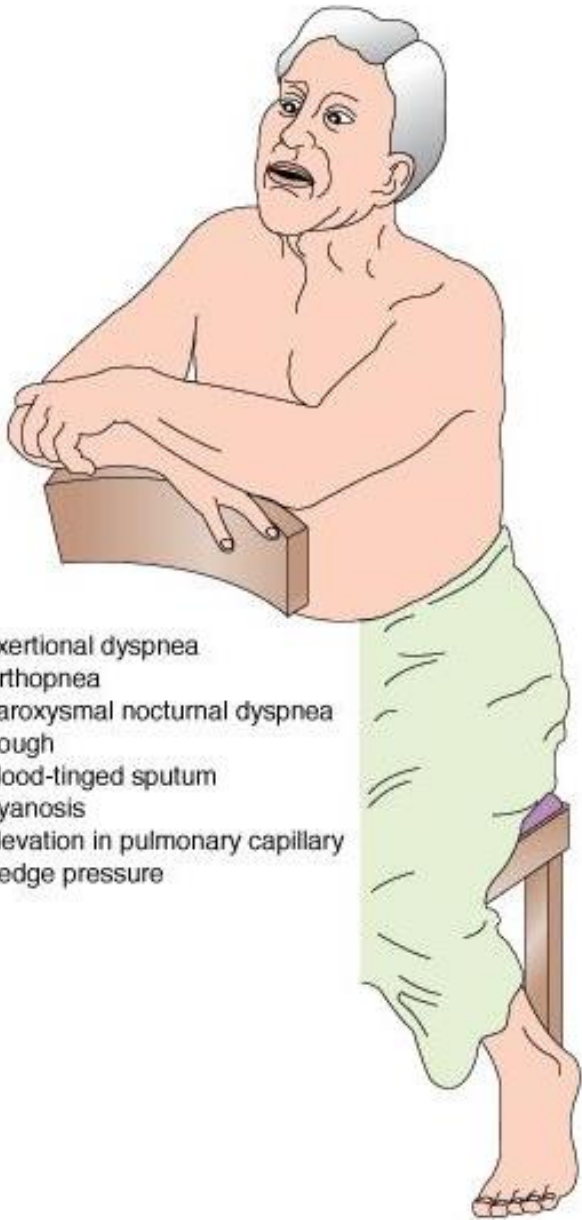
- **Low output vs. congestion**
- **Lungs**
  - pulmonary congestion and edema
  - heart failure cells
- **Kidneys**
  - pre-renal azotemia
  - salt and fluid retention
    - renin-aldosterone activation
    - natriuretic peptides
- **Brain: Irritability, decreased attention, stupor → coma**



# Left Heart Failure Symptoms

- **Dyspnea**
  - on exertion
  - at rest
- **Orthopnea**
  - redistribution of peripheral edema fluid
  - graded by number of pillows needed
- **Paroxysmal Nocturnal Dyspnea (PND)**

# LEFT Heart Failure



- Exertional dyspnea
- Orthopnea
- Paroxysmal nocturnal dyspnea
- Cough
- Blood-tinged sputum
- Cyanosis
- Elevation in pulmonary capillary wedge pressure

**Dyspnea**

**Orthopnea**

**PND (Paroxysmal Nocturnal Dyspnea)**

**Blood tinged sputum**

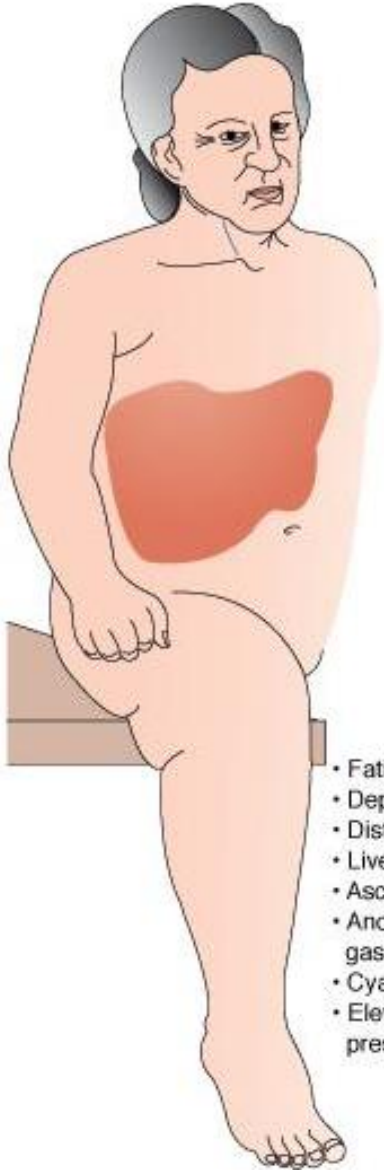
**Cyanosis**

**Elevated pulmonary  
“WEDGE” pressure (PCWP)**

# Right Sided Heart Failure

- **Etiology**
  - left heart failure
  - cor pulmonale
- **Symptoms and signs**
  - **Liver and spleen**
    - passive congestion (nutmeg liver)
    - congestive splenomegaly
    - ascites
  - **Kidneys**
  - **Pleura/Pericardium**
    - pleural and pericardial effusions
    - transudates
  - **Peripheral tissues**

# RIGHT Heart Failure



- Fatigue
- Dependent edema
- Distention of the jugular veins
- Liver engorgement
- Ascites
- Anorexia and complaints of gastrointestinal distress
- Cyanosis
- Elevation in peripheral venous pressure

**FATIGUE**

**“Dependent” edema**

**JVD**

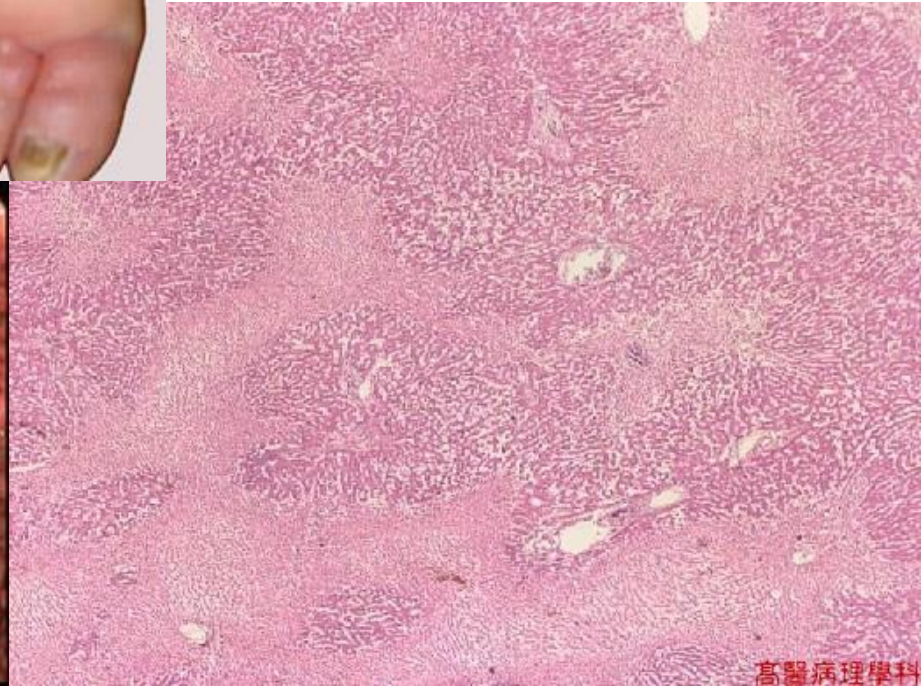
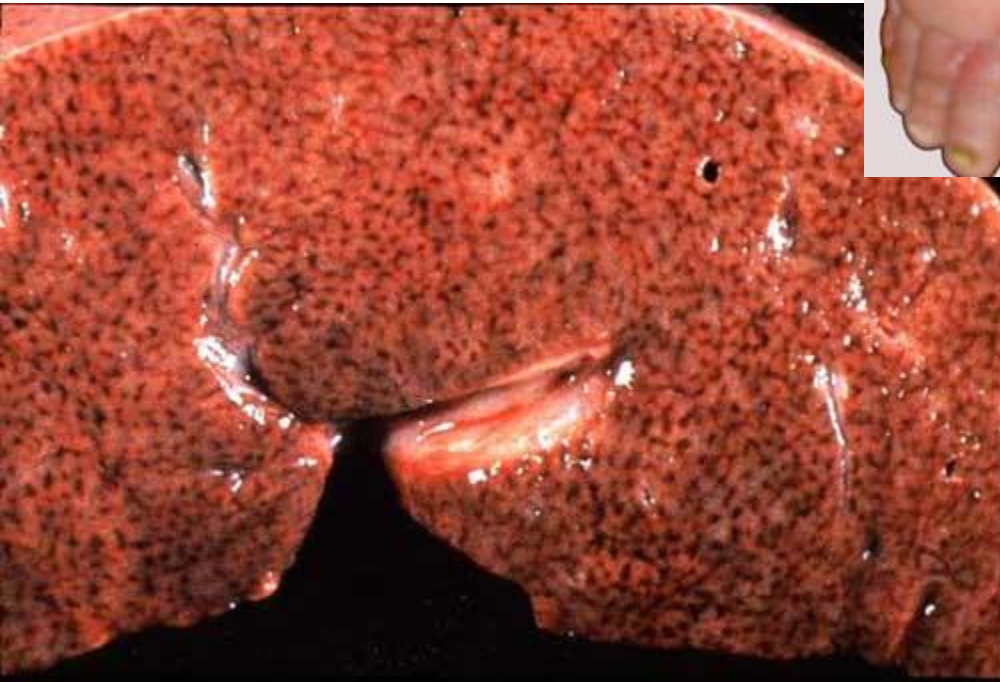
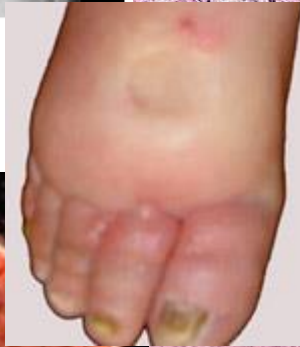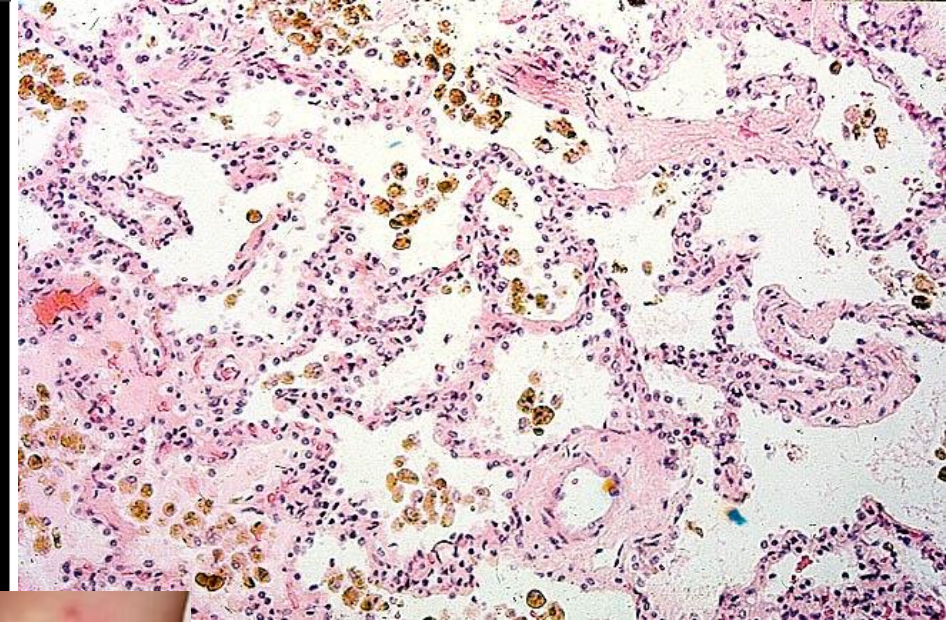
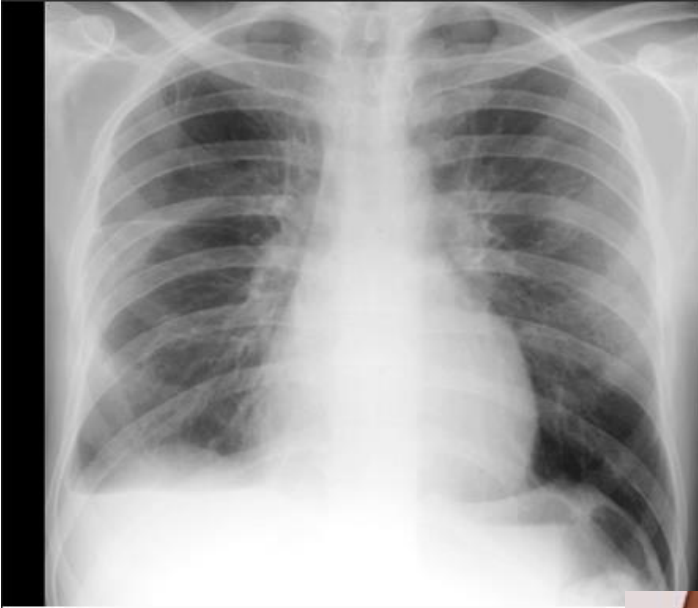**Hepatomegaly (congestion)**

**ASCITES, PLEURAL EFFUSION**

**GI**

**Cyanosis**

**Increased peripheral venous pressure (CVP)**



# HEART DISEASE

- **CONGENITAL (CHD)**
- **ISCHEMIC (IHD)**
- **HYPERTENSIVE (HHD)**
- **VALVULAR (VHD)**
- **MYOPATHIC (MHD)**

# CONGENITAL HEART DEFECTS

- **Faulty embryogenesis (week 3-8)**
- **Usually MONO-morphic (i.e., SINGLE lesion) (ASD, VSD, hypo-RV, hypo-LV)**
- **May not be evident until adult life (Coarctation, ASD)**
- **Overall incidence 1% of USA births**
- **INCREASED simple early detection via non invasive methods, e.g., US, MRI, CT, etc.**

# Malformation

Incidence per  
Million Live Births      %

**Ventricular septal defect**

4482      42

**Atrial septal defect**

1043      10

**Pulmonary stenosis**

836      8

**Patent ductus arteriosus**

781      7

**Tetralogy of Fallot**

577      5

**Coarctation of aorta**

492      5

**Atrioventricular septal defect**

396      4

**Aortic stenosis**

388      4

**Transposition of great arteries**

388      4

**Truncus arteriosus**

136      1

**Total anomalous pulmonary**

120      1

**Tricuspid atresia**



# GENETICS

- Gene abnormalities in only 10% of CHD
- Trisomies **21**, 13, 15, 18, XO
- Mutations of genes which encode for transcription factors → TBX5 → ASD, VSD
- → NKX2.5 → ASD
- Region of chromosome 22 important in heart development, 22q11.2 deletion → conotruncus, branchial arch, face

# ENVIRONMENT

- RUBELLA
- TERATOGENS

# CHD

- **L→R SHUNTS:** all “D’s” in their names
  - NO cyanosis
  - Pulmonary hypertension
  - SIGNIFICANT pulmonary hypertension is IRREVERSIBLE
- **R→L SHUNTS:** all “T’s” in their names
  - CYANOSIS (i.e., “blue” babies)
  - VENOUS EMBOLI become SYSTEMIC
- **OBSTRUCTIONS**

**L → R**

• ASD

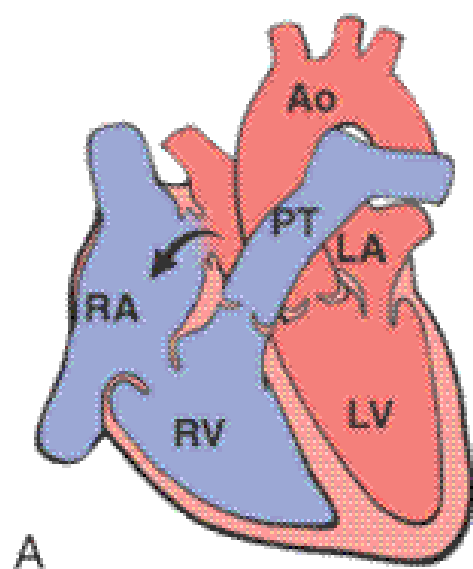
**NON CYANOTIC**

• VSD

• ASVD

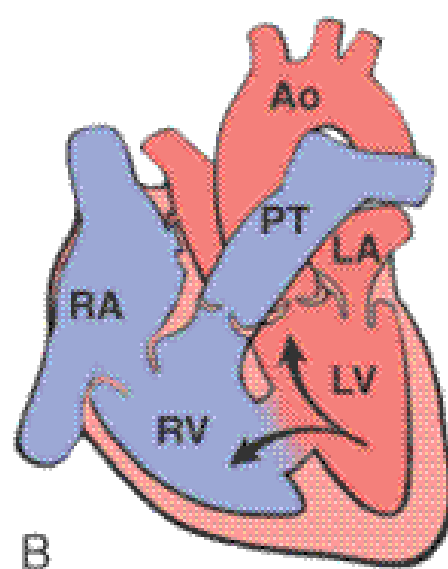
• PDA

**IRREVERSIBLE  
PULMONARY  
HYPERTENSION  
IS THE MOST  
FEARED  
CONSEQUENCE**



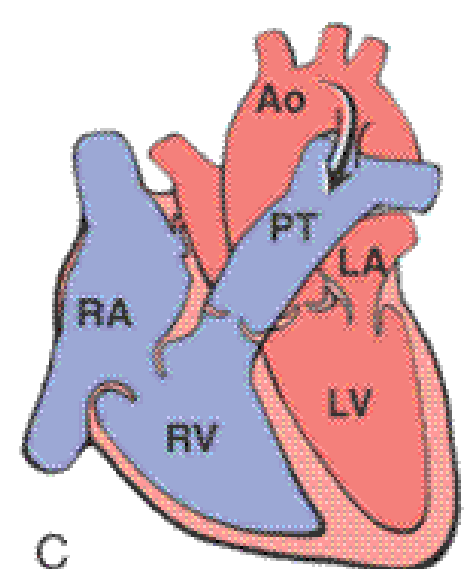
A

ASD



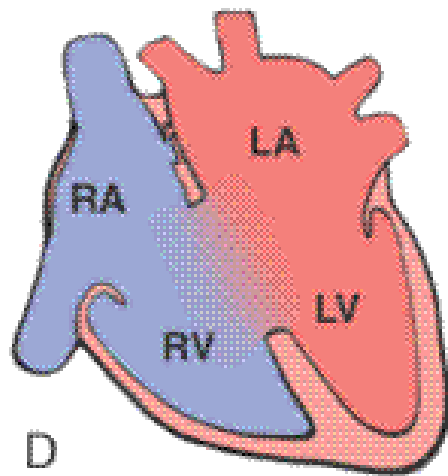
B

VSD



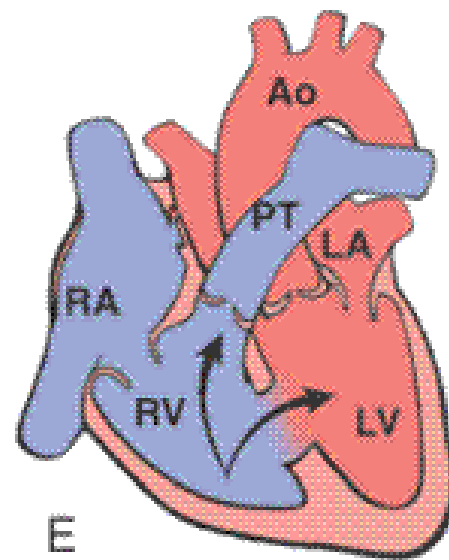
C

PDA



D

Complete Atrioventricular  
Canal Defect



E

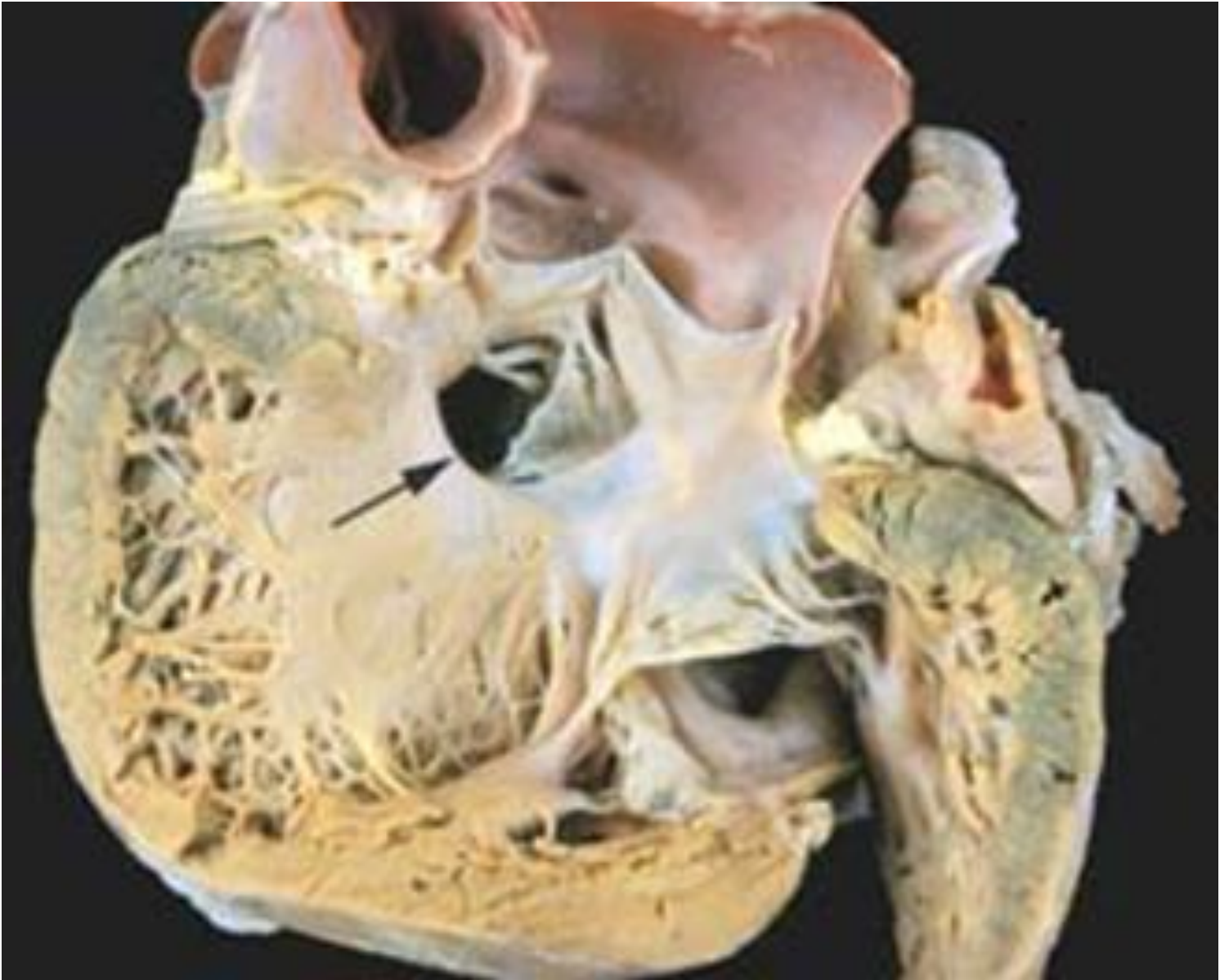
Large VSD with  
Irreversible Pulmonary  
Hypertension

# ASD

- NOT patent foramen ovale
- Usually asymptomatic until adulthood
- **SECUNDUM** (90%): Defective fossa ovalis
- **PRIMUM** (5%): Next to AV valves, mitral cleft
- **SINUS VENOSUS** (5%): Next to SVC with anomalous pulmonary veins draining to SVC or RA

# VSD

- **By far, most common CHD defect**
- **Only 30% are isolated**
- **Often with TETRALOGY of FALLOT**
- **90% involve the membranous septum**
- **If muscular septum is involved, likely to have multiple holes**
- **SMALL ones often close spontaneously**
- **LARGE ones progress to pulmonary hypertension**





# PDA

- **90% isolated**
- **HARSH, machinery-like murmur**
- **L→R, possibly R→L as pulmonary hypertension approaches systemic pressure**
- **Closing the defect may be life saving**
- **Keeping it open may be life saving (Prostaglandin E). Why?**

# AVSD

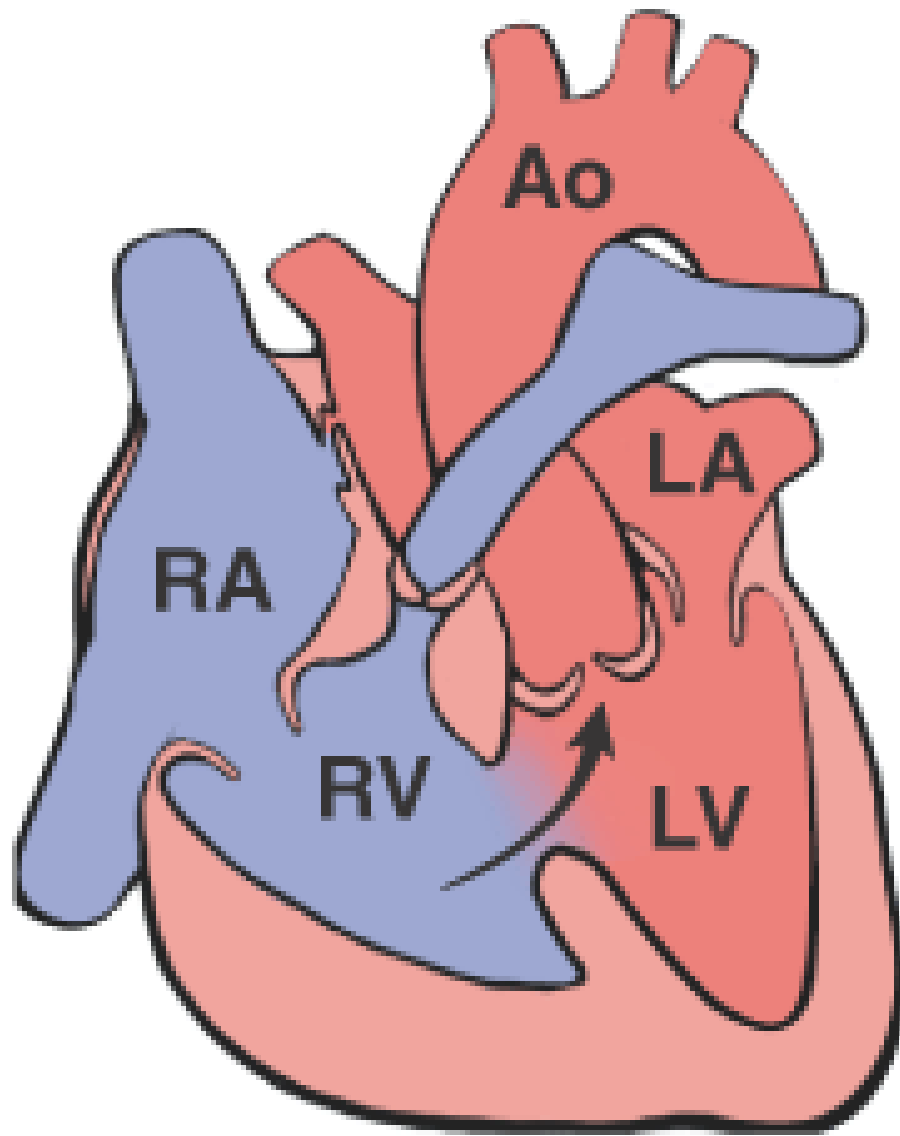
- **Associated with defective, inadequate AV valves**
- **Can be partial, or COMPLETE (ALL 4 CHAMBERS FREELY COMMUNICATE)**

# R → L

- **T**etralogy of Fallot
- **T**ransposition of great arteries
- **T**runcus arteriosus
- **T**otal anomalous pulmonary venous connection
- **T**ricuspid atresia

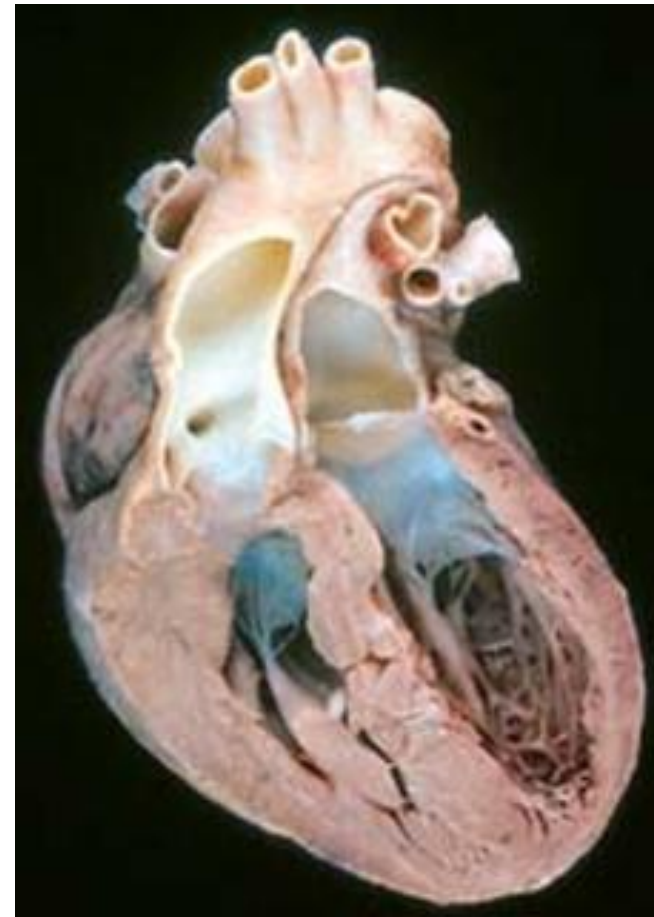
# R→L SHUNTS

- **TETRALOGY of FALLOT** most **COMMON**
  - 1) **VSD, large**
  - 2) **OBSTRUCTION to RV flow**
  - 3) **Aorta OVERRIDES the VSD**
  - 4) **RVH**
  - **SURVIVAL DEPENDS on SEVERITY of SUBPULMONIC STENOSIS**
  - **Can be a “PINK”** tetralogy if pulmonic obstruction is small, but the greater the obstruction, the greater is the R→L shunt



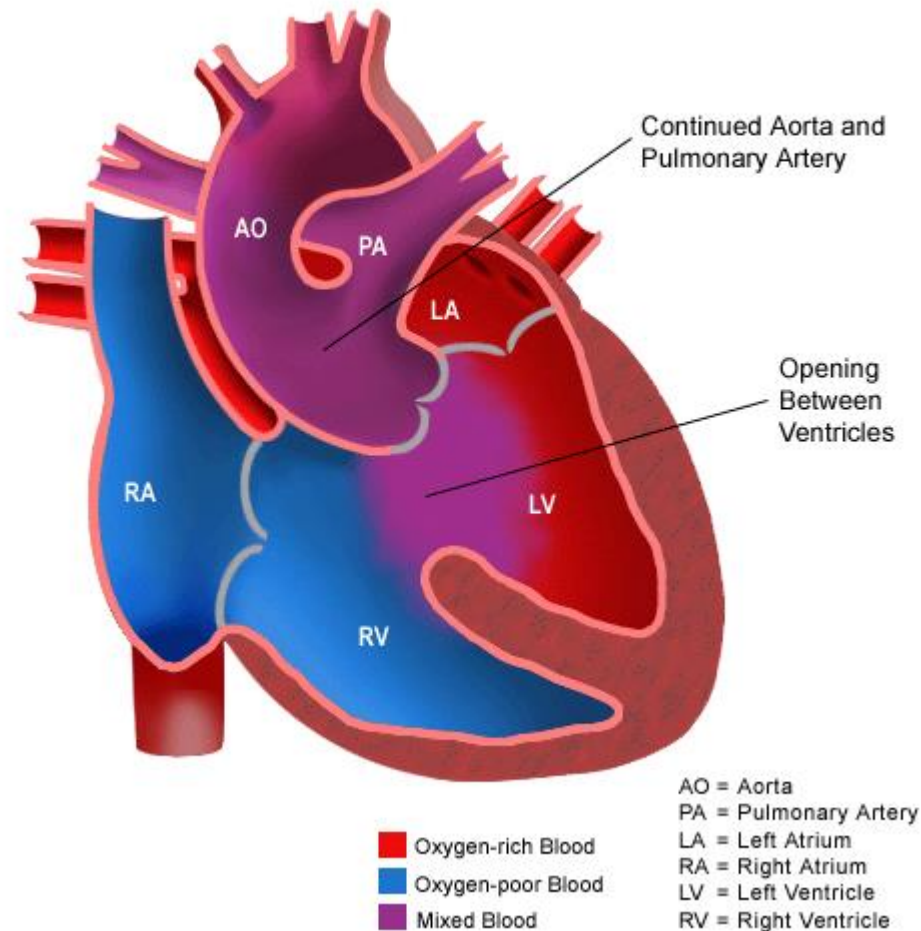
# TGA (TRANSPOSITION of GREAT ARTERIES)

- NEEDS a SHUNT for survival
  - PDA or PFO (65%), “unstable” shunt
  - VSD (35%), “stable” shunt
  - RV > LV in thickness
  - Fatal in first few months
  - Surgical “switching”



# TRUNCUS ARTERIOSUS

Truncus Arteriosus



# TRICUSPID ATRESIA

- **Hypoplastic RV**
- **Needs a shunt, ASD, VSD, or PDA**
- **High mortality**



# **Total Anomalous Pulmonary Venous Connection (TAPVC)**

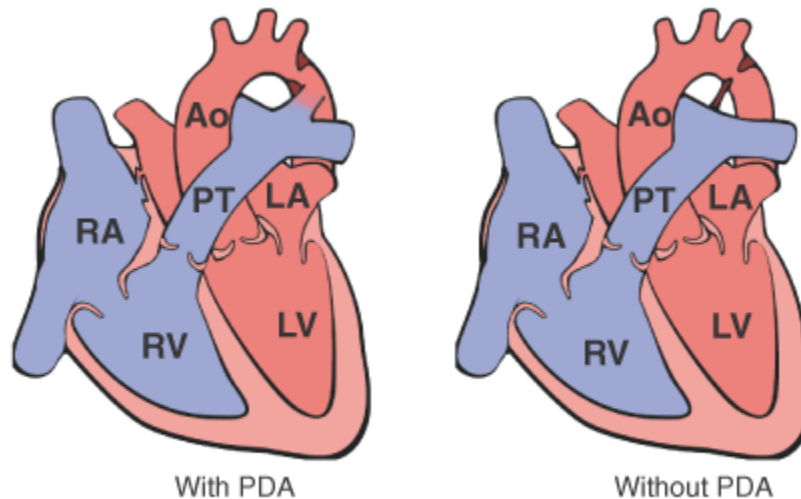
- **PULMONARY VEINS do NOT go into LA, but into L. innominate v. or coronary sinus**
- **Needs a PFO or a VSD**
- **HYPOPLASTIC LA**

# OBSTRUCTIVE CHD

- **COARCTATION of aorta**
- **Pulmonary stenosis/atresia**
- **Aortic stenosis/atresia**

# COARCTATION of AORTA

- M>F
- But XO's frequently have it
- INFANTILE FORM (proximal to PDA) (**SERIOUS**)
- ADULT FORM (CLOSED DUCTUS)
- Bicuspid aortic valve 50% of the time



Coarctation of Aorta

# PULMONIC STENOSIS/ATRESIA

- If 100% atretic, hypoplastic RV with ASD
- Clinical severity ~ stenosis severity

# AORTIC STENOSIS/ATRESIA

- **VALVULAR**
  - If severe, hypoplastic LV → fatal
- **SUB-valvular (subaortic)**
  - Aortic wall **THICK BELOW** cusps
- **SUPRA-valvular**
  - Aortic wall **THICK ABOVE** cusps in ascending aorta

# HEART DISEASE

- CONGENITAL (CHD)
- **ISCHEMIC (IHD)**
- HYPERTENSIVE (HHD)
- VALVULAR (VHD)
- MYOPATHIC (MHD)

# SYNDROMES of IHD

- **Angina Pectoris: Stable, Unstable**
- **Myocardial Infarction (MI, AMI)**
- **Chronic IHD → CHF (CIHD)**
- **Sudden Cardiac Death (SCD)**
  
- **“Acute” Coronary Syndromes:**
  - **UNSTABLE ANGINA**
  - **AMI**
  - **SCD (Sudden Cardiac Death)**

# IHD RISK

- **Number of plaques**
- **Distribution of plaques**
- **Size, structure of plaques**



# ACUTE CORONARY SYNDROMES

- *“The acute coronary syndromes are frequently initiated by an unpredictable and abrupt conversion of a stable atherosclerotic plaque to an unstable and potentially life-threatening atherothrombotic lesion through superficial erosion, ulceration, fissuring, rupture, or deep hemorrhage, usually with superimposed thrombosis.”*

# EPIDEMIOLOGY

- $\frac{1}{2}$  million die of IHD yearly in USA
- 1 million in 1963. Why?
  - Prevention of control controllable risk factors
  - Earlier, better diagnostic methods
  - PTCA, CABG, arrhythmia control
- **90%** of IHD patients have  
**ATHEROSCLEROSIS** (no surprise here)

# ACUTE CORONARY SYNDROME FACTORS

- ACUTE PLAQUE **CHANGE**

\*\*\*\*\*

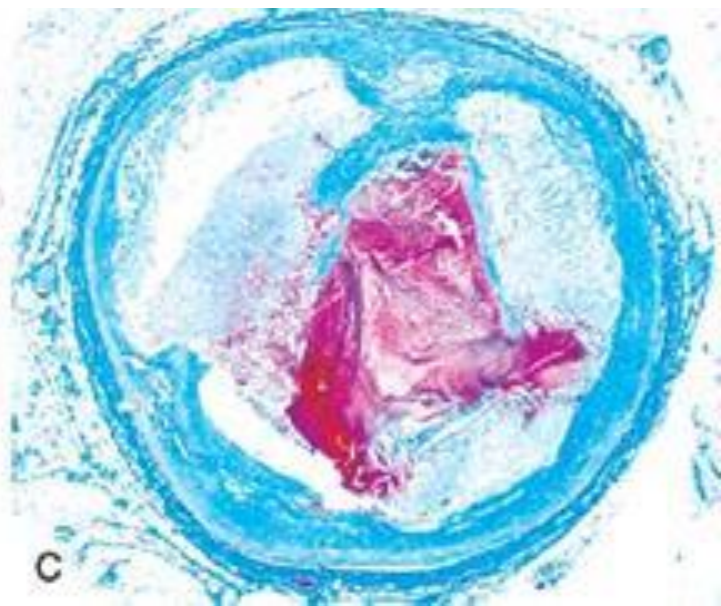
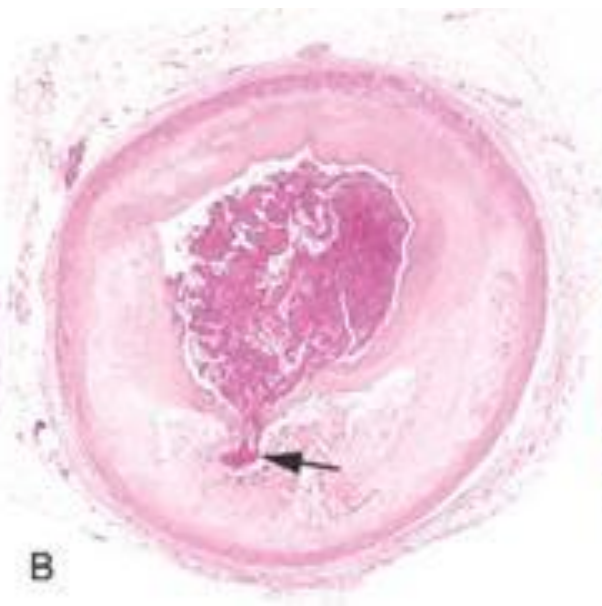
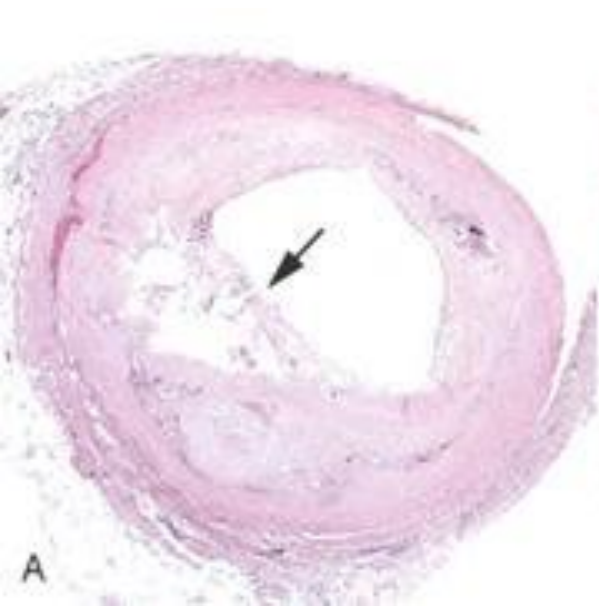
- Inflammation
- Thrombus
- Vasoconstriction

\*\*\*\*\* **MOST IMPORTANT**

# ACUTE PLAQUE CHANGE

- Rupture/Refissuring
- Erosion/Ulceration, exposing ECM
- Acute Hemorrhage

**NB:** Plaques do NOT have to be severely stenotic to cause acute changes, i.e., 50% of AMI results from thromboses of plaques showing LESS THAN 50% stenosis



# INFLAMMATION

- **Endothelial cells release CAMs, selectins**
- **T-cells release TNF, IL-6, IFN-gamma to stimulate and activate endothelial cells and macrophages**
- **CRP predicts the probability of damage in angina patients**

# THROMBUS

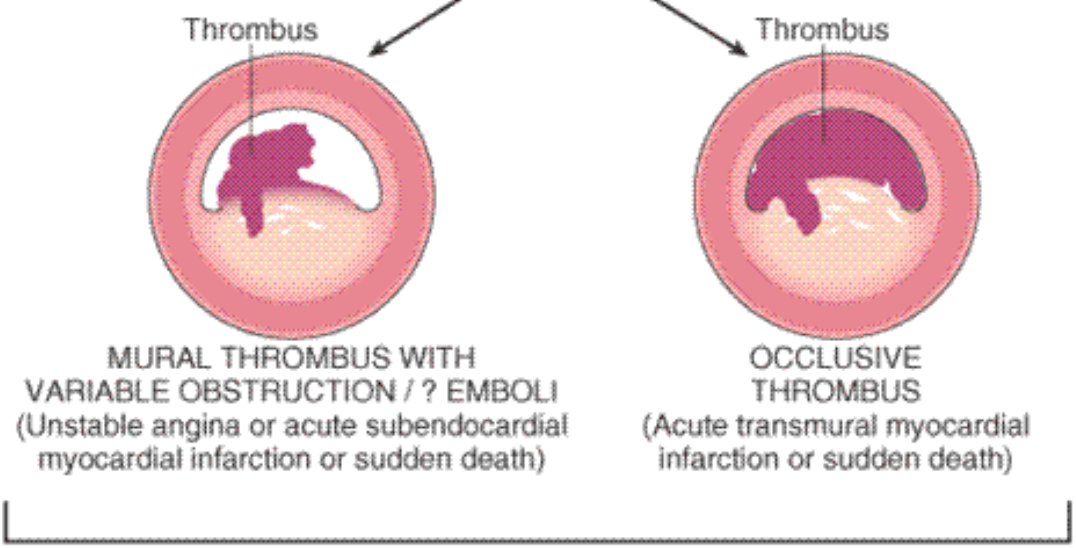
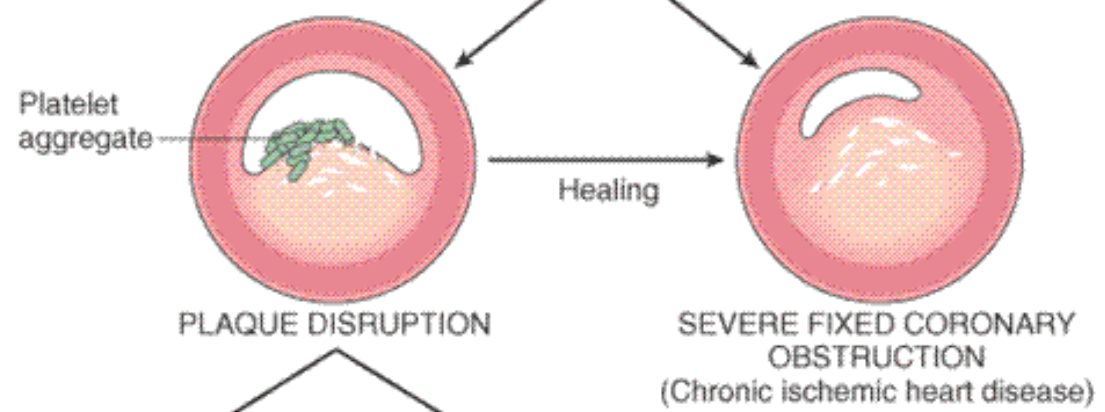
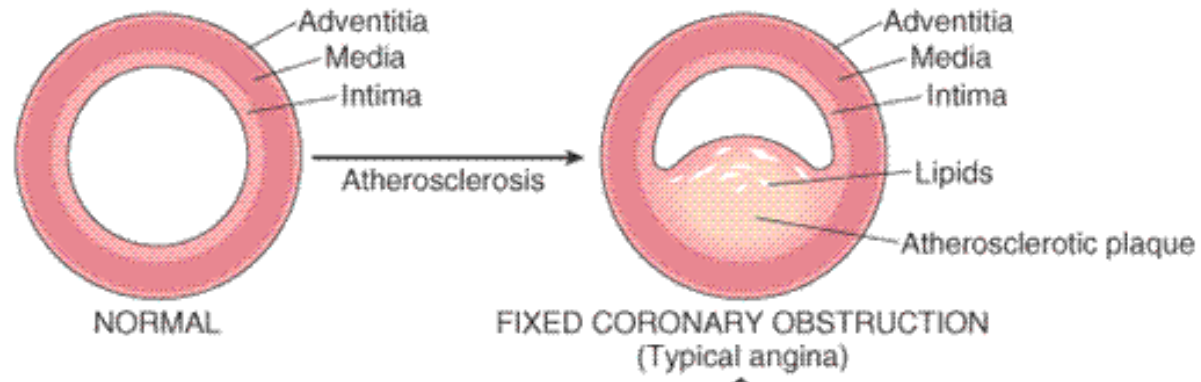
- **Total occlusion**
- **Partial**
- **Embolization**

# VASOCONSTRICTION

## N

- **Circulating adrenergic agonists**
- **Platelet release products**
- **Endothelially released factors, such as endothelin**





ACUTE CORONARY SYNDROMES

# Coronary Artery Pathology in Ischemic Heart Disease

## Plaque-Associated

## Thrombus

### Syndrome

### Stenoses

### Plaque Disruption

Stable angina

>75%

No

No

Unstable

Variab

Frequent

Nonocclusive, often with

transmural

Variab

Frequent

occlusive emboli

myocardial

le

Variable

Widely variable, may be

Subendocardial

Variab

myocardial

le

Frequent

absent, partial/complete, or

Sudden death

Usuall

Often small platelet

myocardial

y

lysed aggregates or thrombi and/or

sever

thromboemboli

e

# ANGINA PECTORIS

- Paroxysmal (sudden)
- Recurrent
- 15 sec. → 15 min.
- Reduced perfusion, but NO infarction
- **THREE TYPES**
  - **STABLE**: relieved by rest or nitro
  - **PRINZMETAL**: SPASM is main feature, responds to nitro, S-T elevation
  - **UNSTABLE** (crescendo, PRE-infarction, Q-wave angina): perhaps some thrombosis, perhaps some non transmural necrosis, perhaps some embolization, but **DISRUPTION of PLAQUE** is universally agreed upon

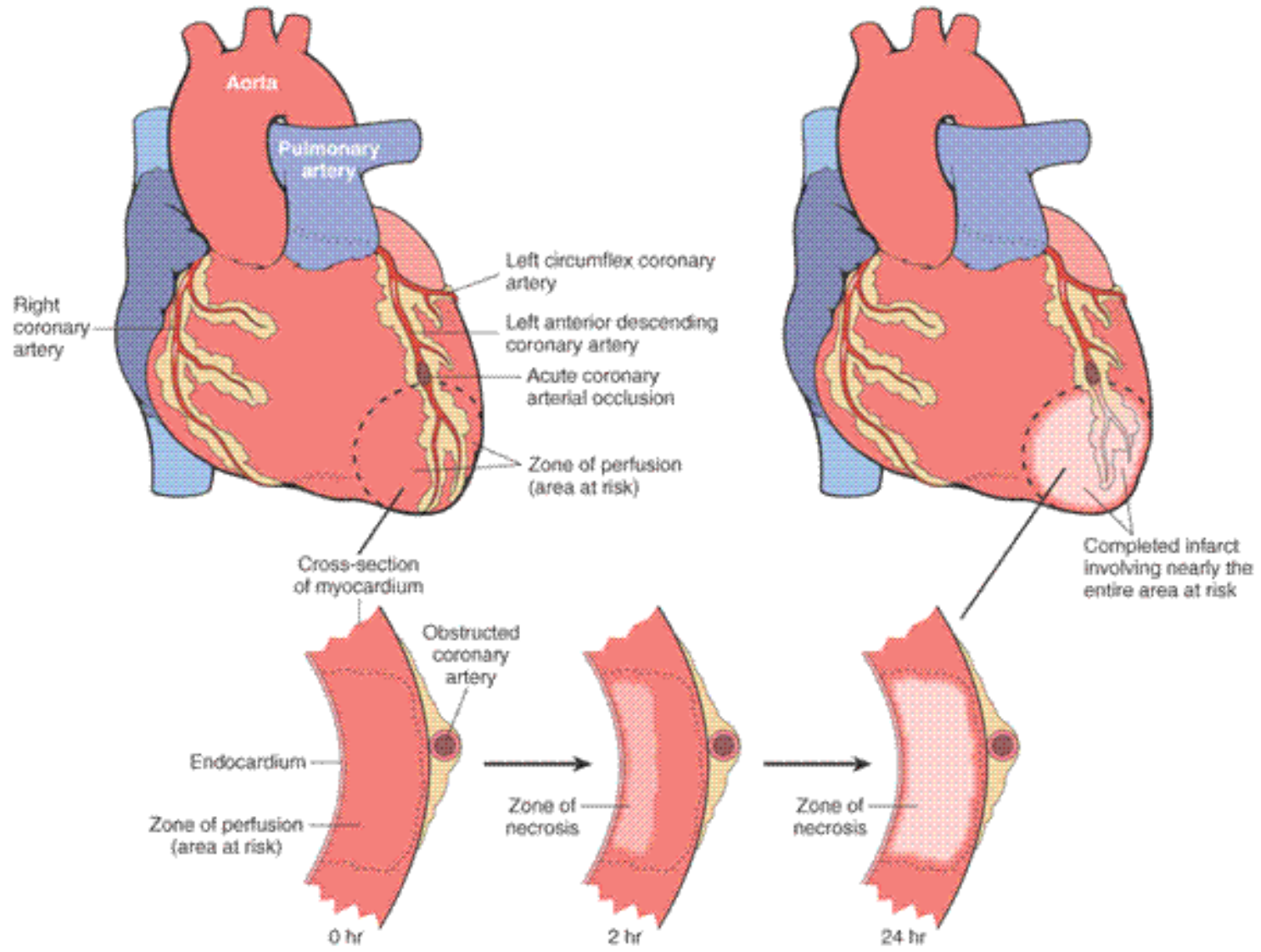
# MYOCARDIAL INFARCTION

- **Transmural vs. Subendocardial (inner 1/3)**
- **DUH! EXACT SAME risk factors as atherosclerosis**
- **Most are TRANSMURAL, and MOST are caused by coronary artery occlusion**
- **In the 10% of transmural MIs NOT associated with atherosclerosis:**
  - **Vasospasm**
  - **Emboli**
  - **UNexplained**

# MYOCARDIAL RESPONSE

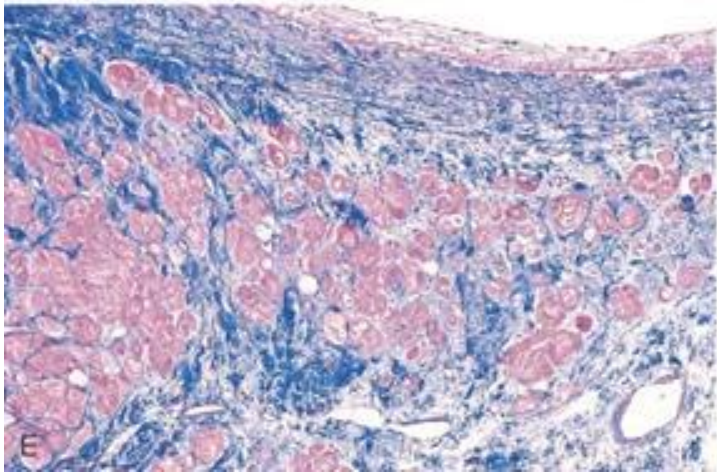
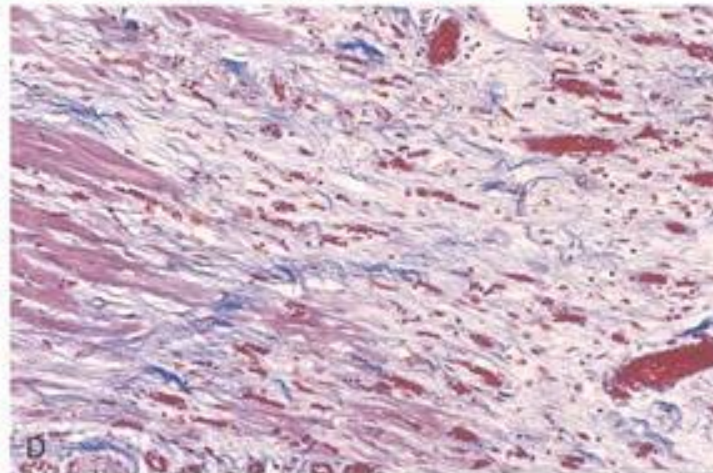
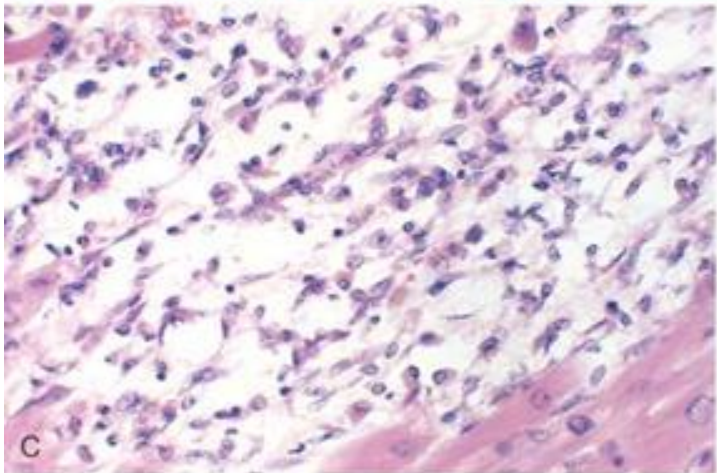
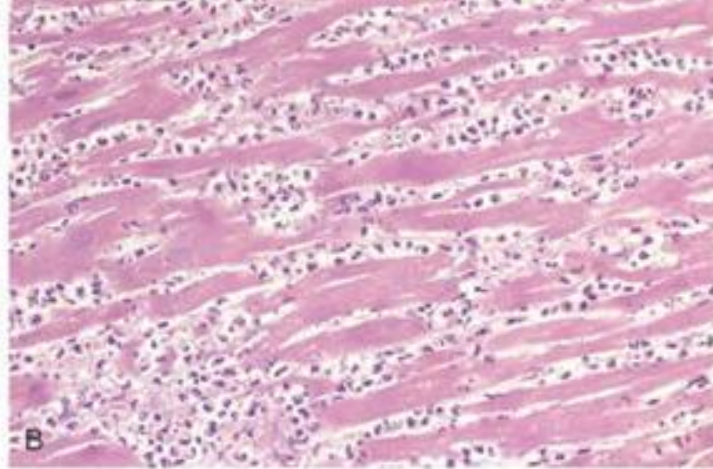
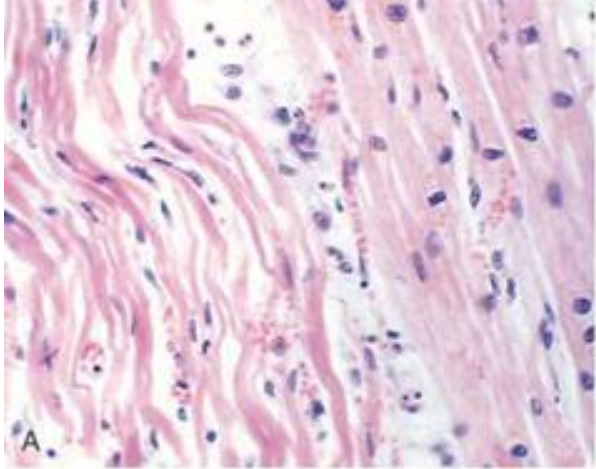
<b>Feature</b>	<b>Time</b>
Onset of ATP depletion	Seconds
Loss of contractility	<2 min
ATP reduced to 50% of normal	10 min
to 10% of normal	40 min
Irreversible cell injury	20–40 min
Microvascular injury	>1 hr

# PROGRESSION OF NECROSIS



# TIMING of Gross and Microscopic Findings

<b>½–4 hr</b>	<b>None</b>	<b>Usually none; variable waviness of fibers at border</b>
<b>4–12 hr</b>	<b>Occasionally dark mottling</b>	<b>Beginning coagulation necrosis; edema; hemorrhage</b>
<b>12–24 hr</b>	<b>Dark mottling</b>	<b>Ongoing coagulation necrosis; pyknosis of nuclei; myocyte hypereosinophilia; marginal contraction band necrosis; beginning neutrophilic infiltrate</b>
<b>1–3 days</b>	<b>Mottling with yellow-tan infarct center</b>	<b>Coagulation necrosis, with loss of nuclei and striations; interstitial infiltrate of neutrophils</b>
<b>3–7 days</b>	<b>Hyperemic border; central yellow-tan softening</b>	<b>Beginning disintegration of dead myofibers, with dying neutrophils; early phagocytosis of dead cells by macrophages at infarct border</b>
<b>7–10 days</b>	<b>Maximally yellow-tan and soft, with depressed red-tan margins</b>	<b>Well-developed phagocytosis of dead cells; early formation of fibrovascular granulation tissue at margins</b>
<b>10–14 days</b>	<b>Red-gray depressed infarct borders</b>	<b>Well-established granulation tissue with new blood vessels and collagen deposition</b>
<b>2–8 wk</b>	<b>Gray-white scar, progressive from border toward core of infarct</b>	<b>Increased collagen deposition, with decreased cellularity</b>
<b>&gt;2 mo</b>	<b>Scarring complete</b>	<b>Dense collagenous scar</b>



**1 day, 3-4 days, 7 days, weeks, months**



# RE-PERFUSION

- **Thrombolysis**
- **PTCA**
- **CABG**
  
- **Reperfusion CANNOT restore necrotic or dead fibers, only reversibly injured ones**
  
- **REPERFUSION “INJURY”**
  - **Free radicals**
  - **Interleukins**

# AMI DIAGNOSIS

- **SYMPTOMS**
- **EKG**
- **DIAPHORESIS**
- **(10% of MIs are “SILENT” with Q-waves)**
- **CKMB gold standard enzyme**
- **Troponin-I, Troponin-T better**
- **CRP predicts risk of AMI in angina patients**

# COMPLICATIONS

- **Wall motion abnormalities**
- **Arrhythmias**
- **Rupture (4-5 days)**
- **Pericarditis**
- **RV infarction**
- **Infarct extension**
- **Mural thrombus**
- **Ventricular aneurysm**
- **Papillary muscle dysfunction (regurgitation)**
- **CHF**

# **CIHD, aka, ischemic “cardiomyopathy”**

- **Progress to CHF often with no pathologic or clinical evidence of localized infarction**
  - **Extensive atherosclerosis**
  - **No infarct**
  - **H&D present**

# SUDDEN CARDIAC DEATH

- 350,000 in USA yearly from atherosclerosis
- NON-atherosclerotic sudden cardiac death includes:
  - **Congenital coronary artery disease**
  - **Aortic stenosis**
  - **MVP**
  - **Myocarditis**
  - **Cardiomyopathy** (sudden death in young athletes)
  - **Pulmonary hypertension**
  - **Conduction defects**
  - **HTN, hypertrophy of UNKNOWN etiology**

# AUTOPSY findings in SCD

- **>75% narrowing of 1-3 vessels**
- **Healed infarcts 40%**
- **“ARRHYTHMIA” is often a very convenient conclusion when no anatomic findings are present, i.e., “wastebasket” diagnosis**

# HEART DISEASE

- CONGENITAL (CHD)
- ISCHEMIC (IHD)
- **HYPERTENSIVE  
(HHD)**
- VALVULAR (VHD)
- MYOPATHIC (MHD)

# **HHD (Left)**

- **DEFINITION:** Hypertrophic adaptive response of the heart, which can progress:
  - Myocardial dysfunction
  - Cardiac dilatation
  - CHF
  - Sudden death



# **NEEDED for DIAGNOSIS:**

- **LVH (LV>2.0 and/or Heart>500 gm.)**
- **HTN (>140/90)**

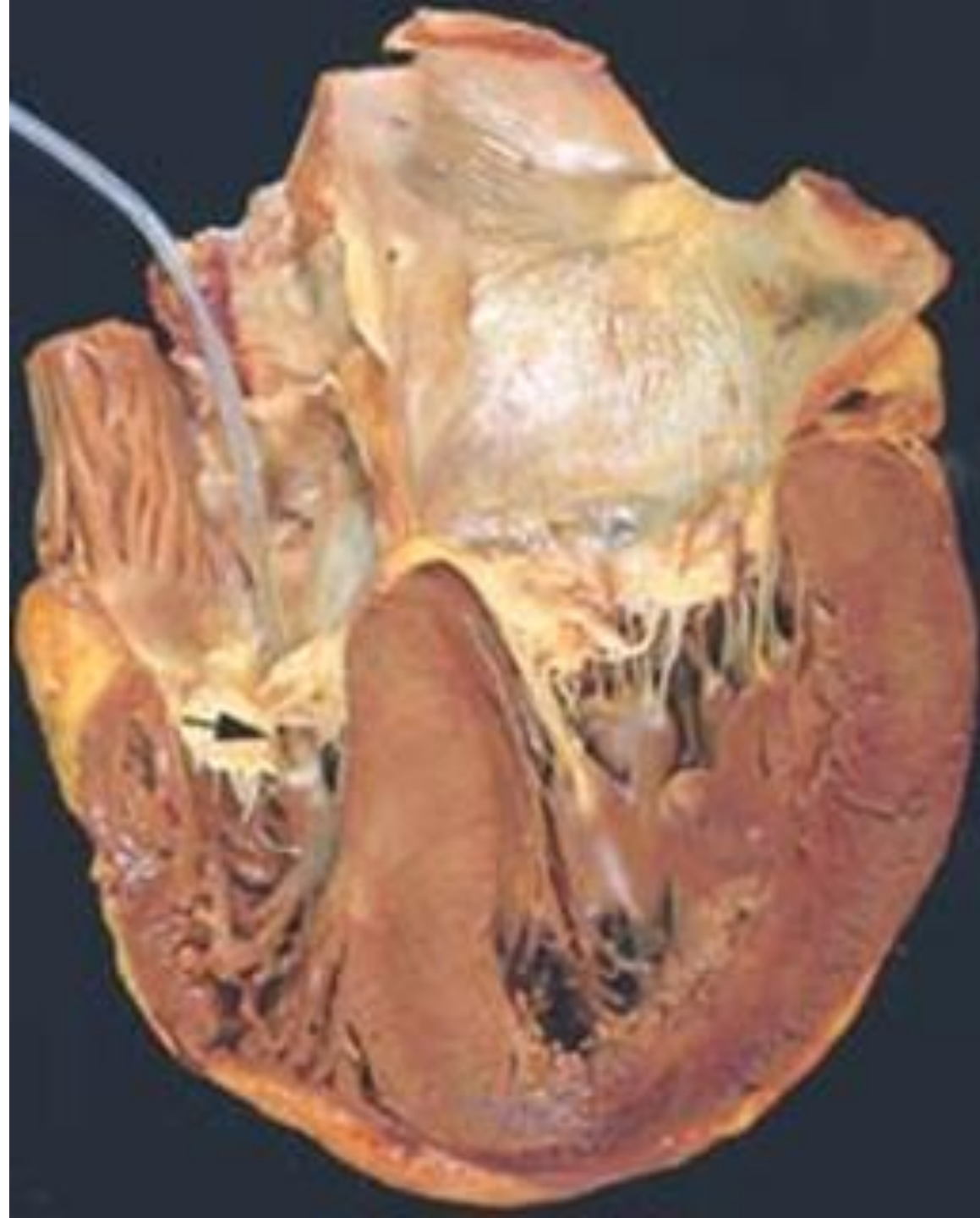# PREVALENCE:

- **WHAT % of USA people have hypertension?**

# PREVALENCE:

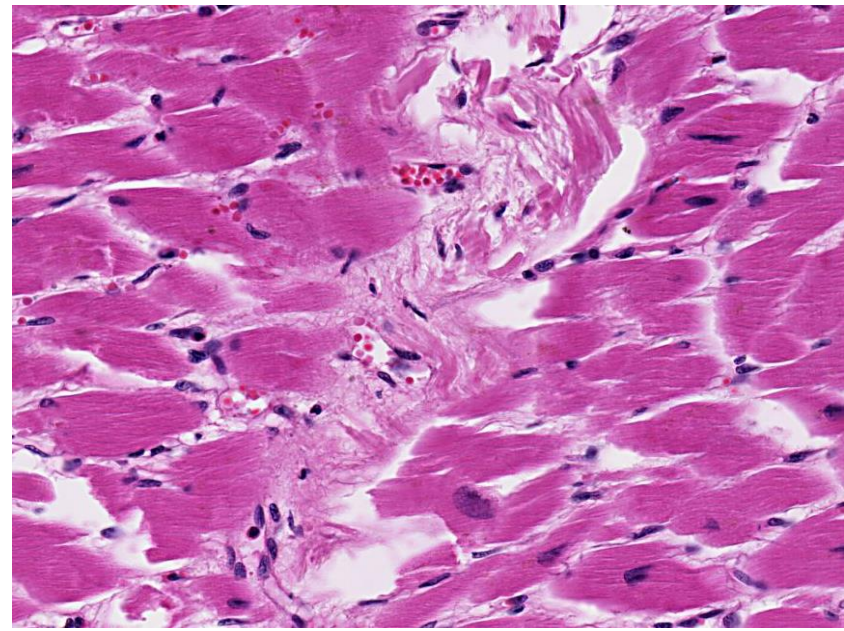
- **WHAT % of USA people have hypertension?**

- **Answer: 25%**



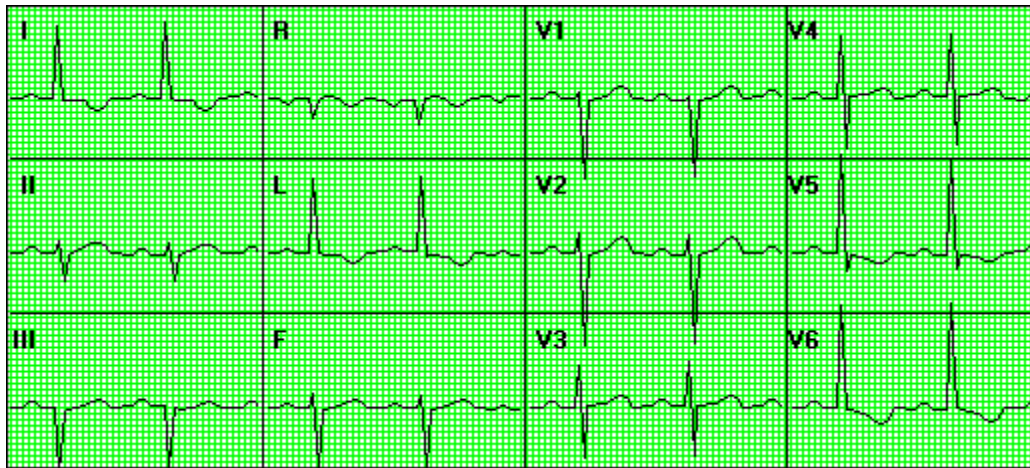
# HISTOPATHOLOG

- **INCREASED** FIBER (MYOCYTE) THICKNESS
- **INCREASED** nuclear size with increased “blockiness” (boxcar nucleus)



# CLINICAL

## • EKG



### Summary of LVH Criteria

- 1)  $R-I + S-III > 25$  mm
- 2)  $S-V1 + R-V5 > 35$  mm

3) ST-Ts in left leads

4)  $R-L > 11$  mm

5) LAE\* + other criteria

Positive Criteria:

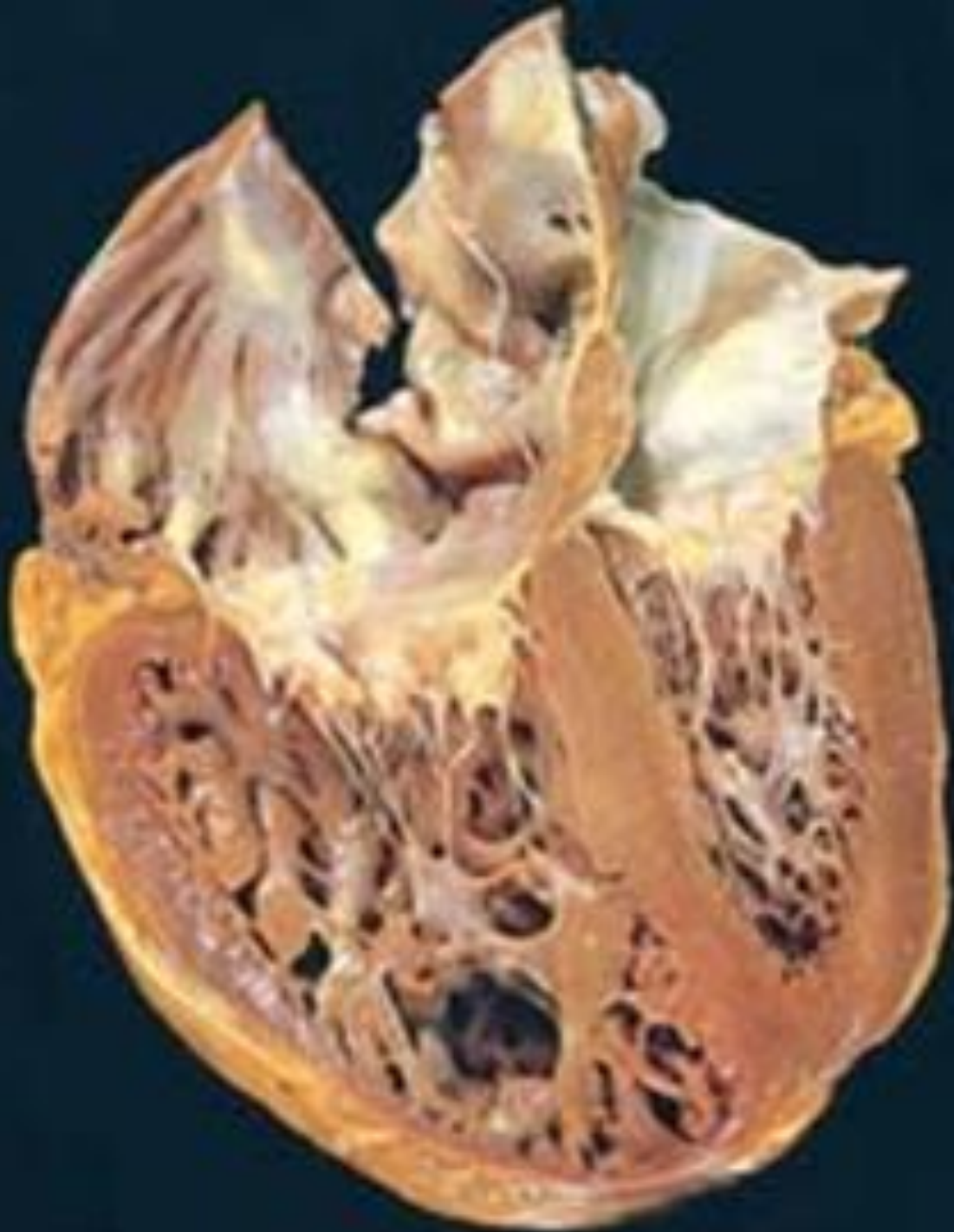1=possible

2=probable 3=definite

## ATRIAL FIBRILLATION

Why?

## CHF, cardiac dilatation, pulmonary venous congestion and dilatation



# COURSE:

- **NORMAL** longevity, death from other causes
- **Progressive IHD**
- **Progressive renal damage, hemorrhagic CVA (Which arteries?)**
- **CHF**



# **HHD (Right) = COR PULMONALE**

- **ACUTE:** Massive PE
- **CHRONIC:** COPD, CRPD,  
Pulmonary artery disease, chest wall  
motion impairment

***Diseases of the Pulmonary  
Parenchyma***

**Chronic obstructive pulmonary  
disease**

**Diffuse pulmonary interstitial  
fibrosis**

**Pneumoconioses**

**Cystic fibrosis**

**Bronchiectasis**

***Diseases of the Pulmonary Vessels***

**Recurrent pulmonary  
thromboembolism**

**Primary pulmonary**

***Disorders Affecting Chest  
Movement***

**Kyphoscoliosis**

**Marked obesity (pickwickian  
syndrome)**

**Neuromuscular diseases**

***Disorders Inducing  
Pulmonary Arterial  
Constriction***

**Metabolic acidosis**

# HEART DISEASE

- CONGENITAL (CHD)
- ISCHEMIC (IHD)
- HYPERTENSIVE (HHD)
- **VALVULAR (VHD)**
- MYOPATHIC (MHD)

# V<sub>alvular</sub>HD

- **Opening problems: Stenosis**
- **Closing problems: Regurgitation or Incompetence**

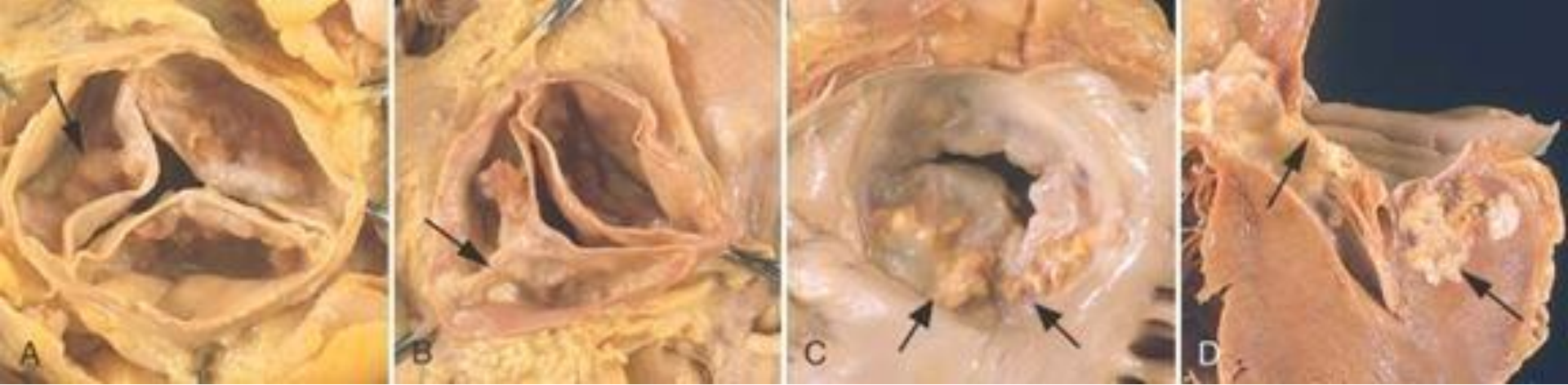
**70% of all VHD**

- **AS**

- **Calcification of a deformed valve**
- **“Senile” calcific AS**
- **Rheum, Heart Dis.**

- **MS**

- **Rheumatic Heart Disease**



## **AORTIC STENOSIS**

**2X gradient pressure**

**LVH, ischemia**

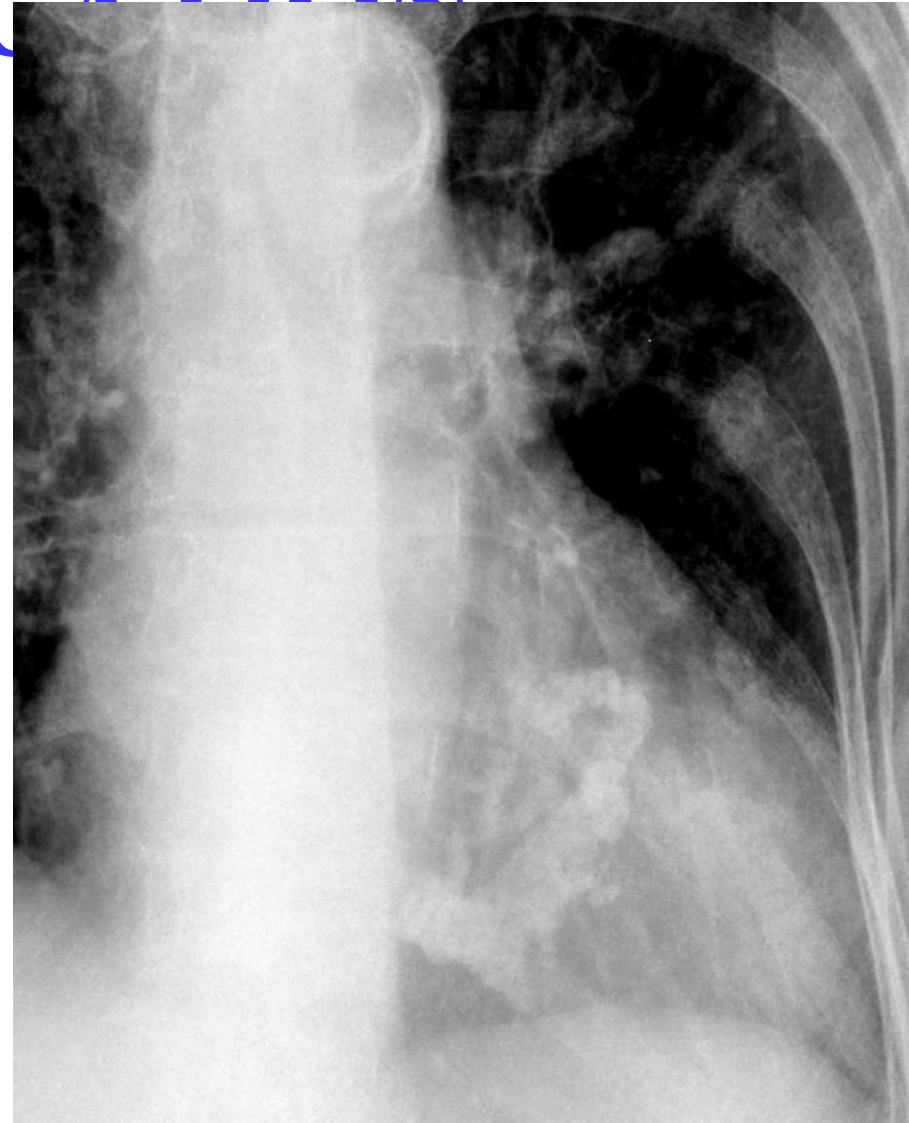
**Cardiac decompensation, angina, CHF**

**50% die in 5 years if angina present**

**50% die in 2 years if CHF present**

# MITRAL ANNULAR CALCIFICATION

- Calcification of the mitral “skeleton”
- Usually NO dysfunction
- Regurgitation or Stenosis possible
- F>>M



# REGURGITATIONS

## • AR

- Rheumatic
- Infectious
- Aortic dilatations
  - Syphilis
  - Rheumatoid Arthritis
  - Marfan

## • MR

- MVP
- Infectious
- Fen-Phen
- Papillary muscles, chordae tendinae
- Calcification of mitral ring (annulus)

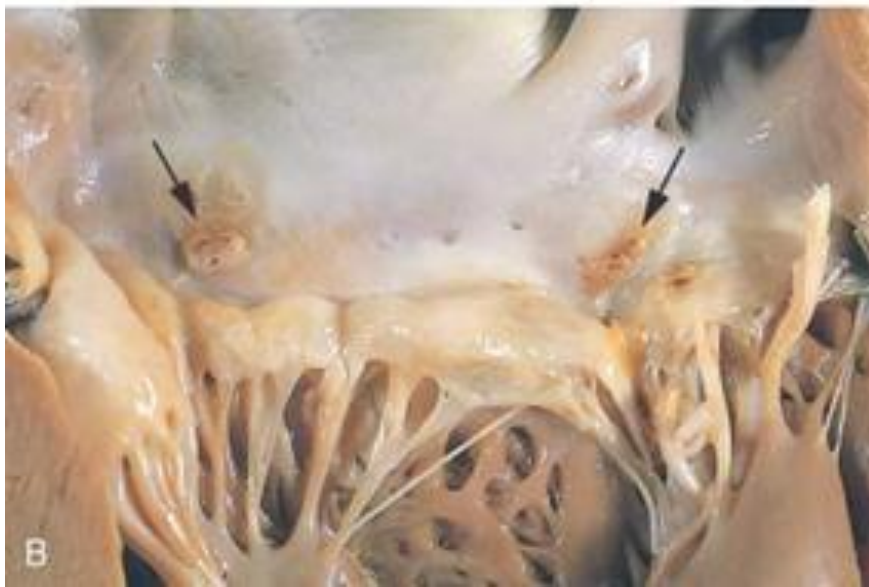
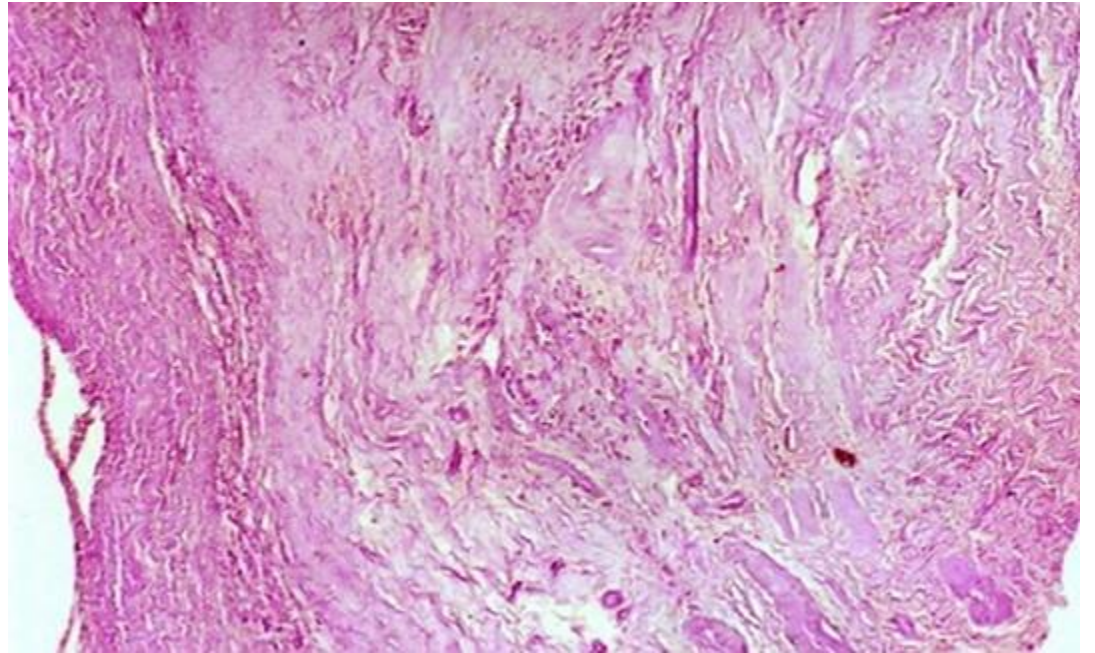
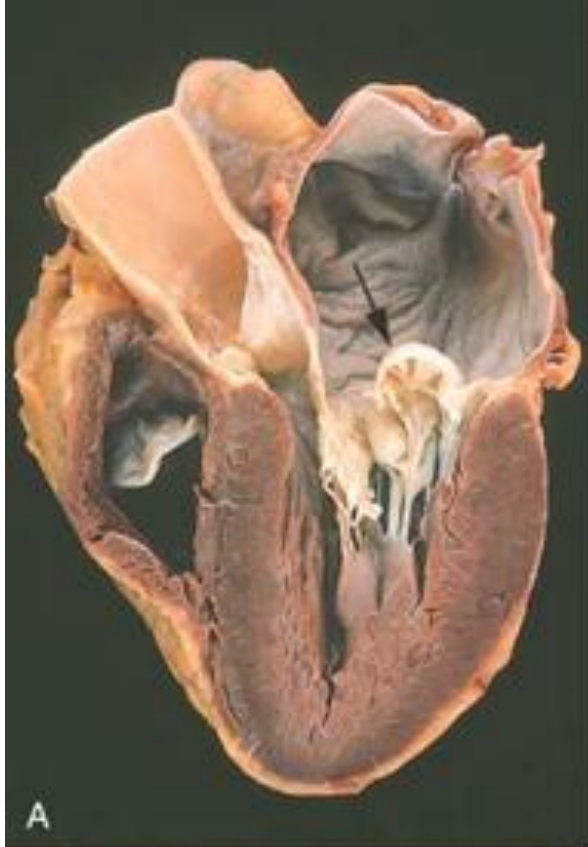

# **Mitral Valve Prolapse (MVP)**

- **MYXOMATOUS** degeneration of the mitral valve
- **Associated with connective tissue disorders**
- **“Floppy” valve**
- **3% incidence, F>>M**
- **Easily seen on echocardiogram**

# MVP: CLINICAL FEATURES

- Usually asymptomatic
- Mid-systolic “click”
- Holosystolic murmur if regurg. present
- Occasional chest pain, dyspnea
- 97% NO untoward effects
- 3% Infective endocarditis, mitral insufficiency, arrhythmias, sudden death



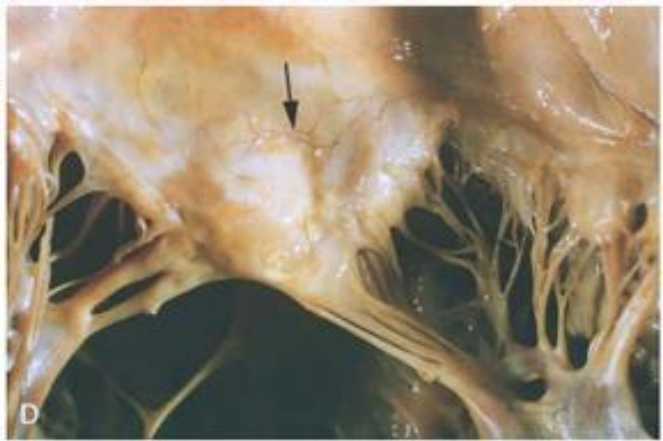
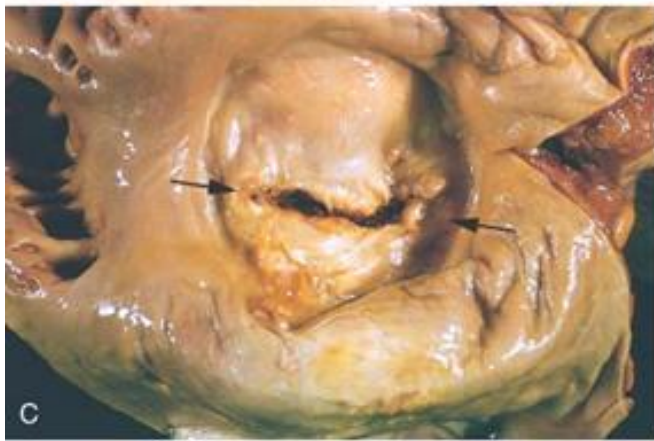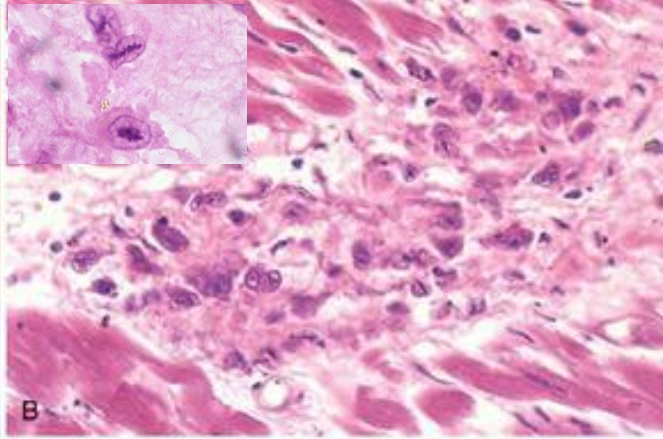
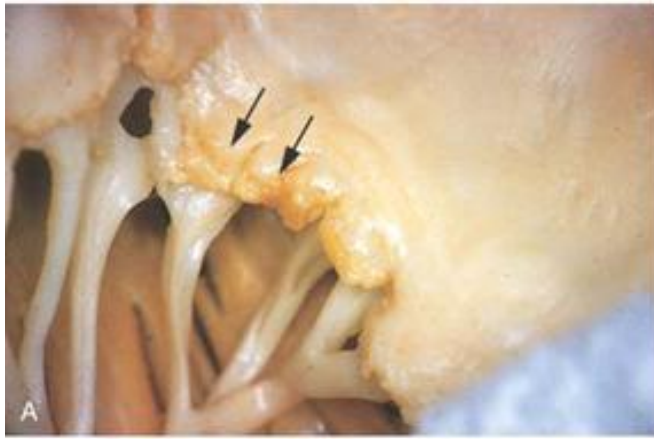
B

# **RHEUMATIC Heart Disease**

- **Follows a group A strep infection, a few weeks later**
- **DECREASE in “developed” countries**
- **PANCARDITIS**

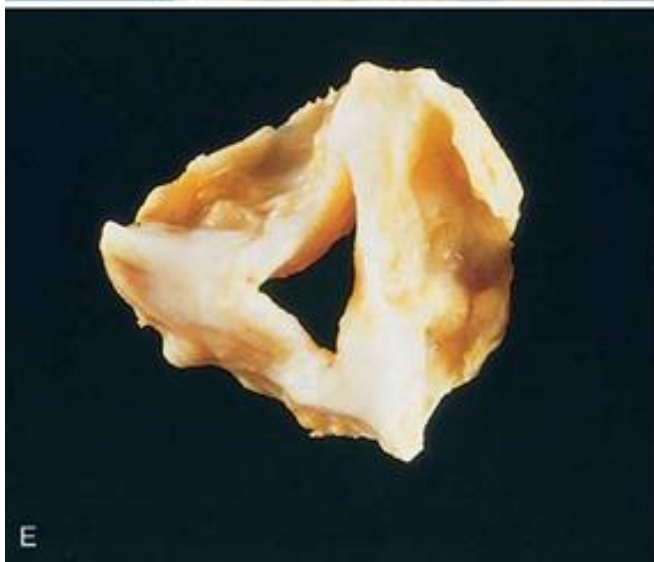
**ACUTE:**

- Inflammation
- Aschoff bodies
- Anitschkow cells
- Pancarditis
- Vegetations on chordae tendinae at leaflet junction



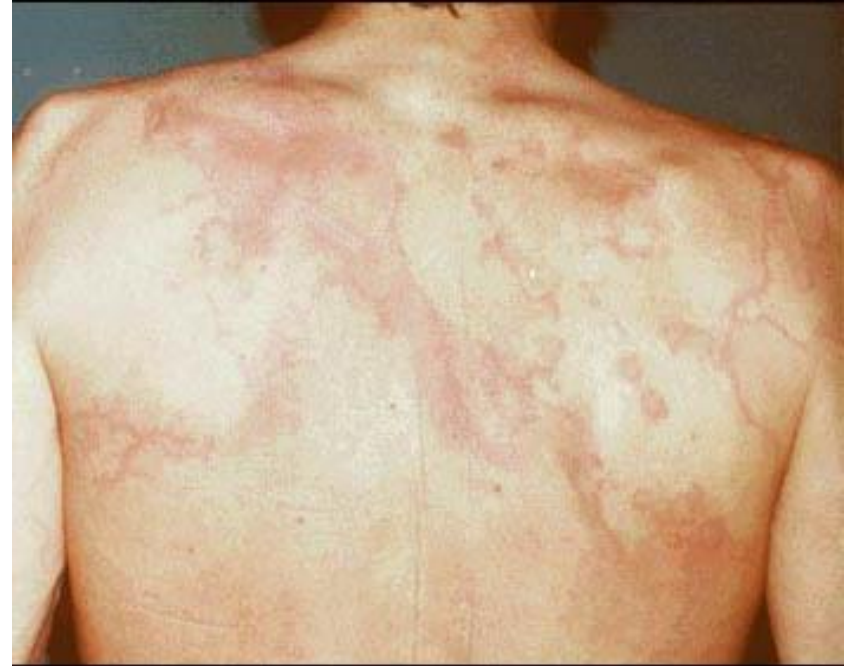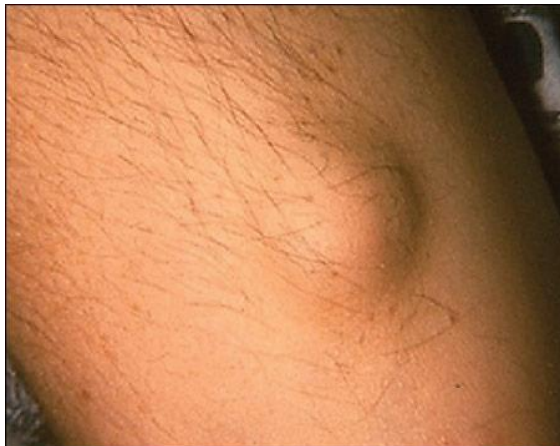**CHRONIC:**

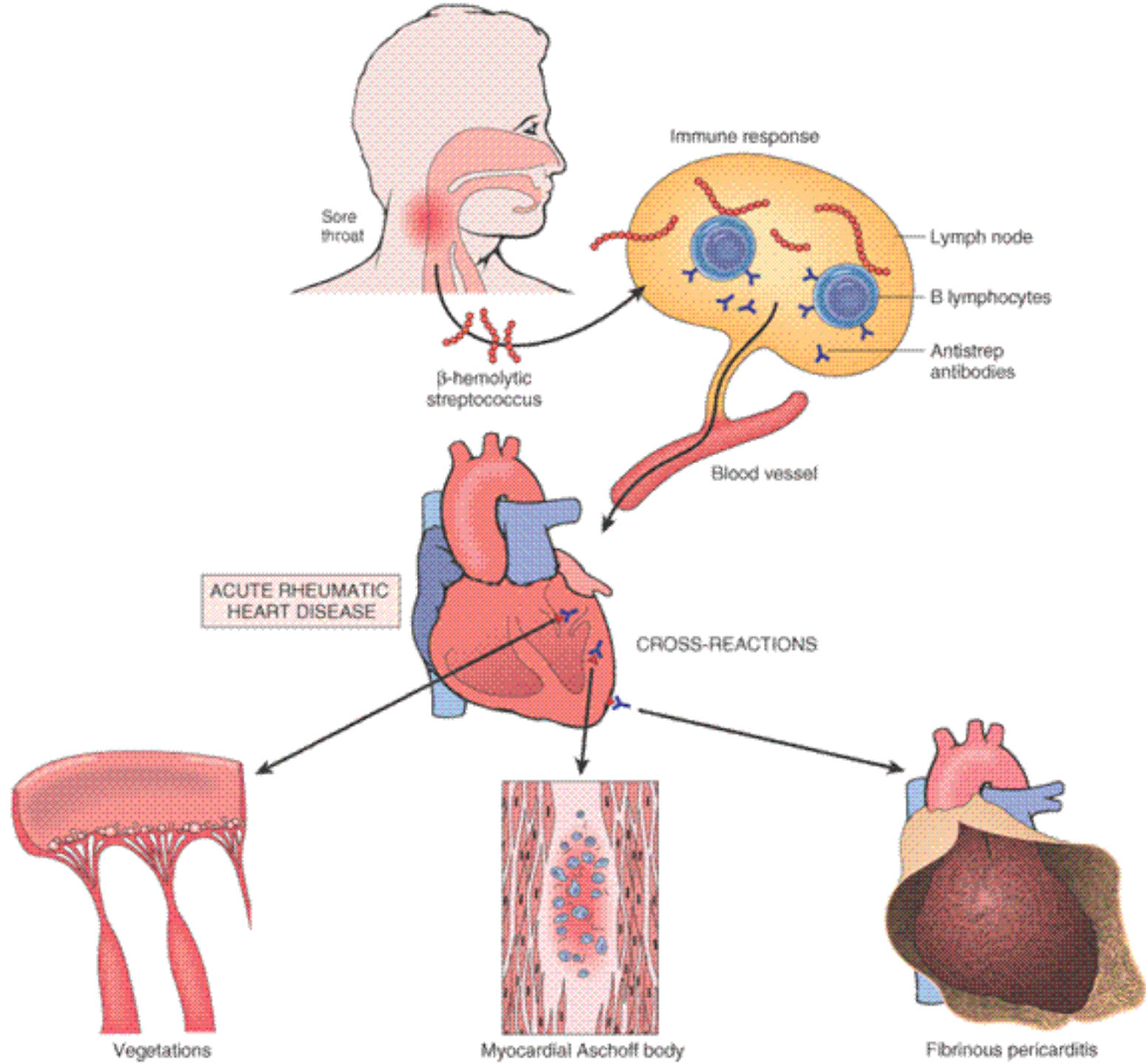
- THICKENED VALVES
- COMMISURAL FUSION
- THICK, SHORT, CHORDAE



# CLINICAL FEATURES

- **Migratory Polyarthritits**
- **Myocarditis**
- **Subcutaneous nodules**
- **Erythema marginatum**
- **Sydenham chorea**





# INFECTIOUS

## • Microbes ENDOCARDITIS

– Usually **strep viridans**

– Often Staph aureus in IVD users

– Enterococci

– **HAČEK** (normal oral flora)

- Hemophilus influenzae

- Actinobacillus

- Cardiobacterium

- Eikenella

- Kingella

– Fungi, rickettsiae, chlamydia



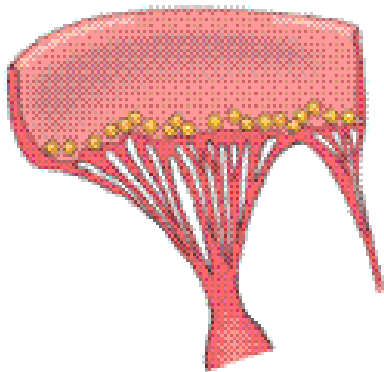
# INFECTIOUS

## ENDOCARDITIS

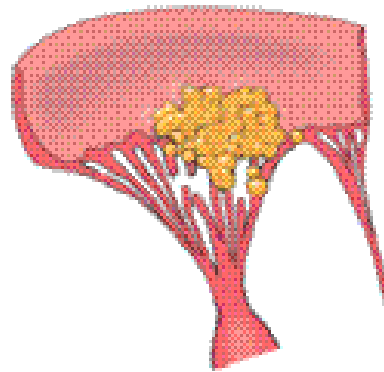
- Acute: 50% mortality (course=days)
- **SUB**-acute: LOW mortality (course=weeks)

# VEGETATIONS

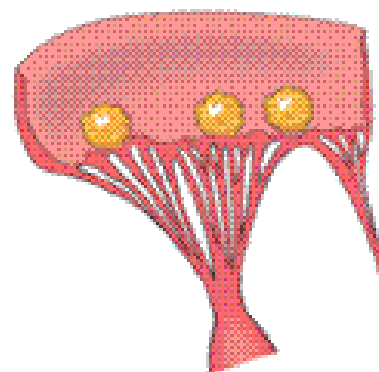
- **INFECTIVE** >5mm
- **NON-Infective** <5mm



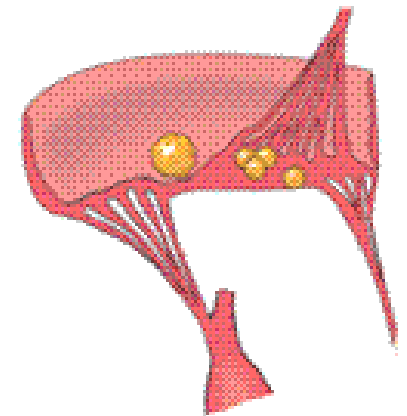
RHD



IE



NBTE



LSE

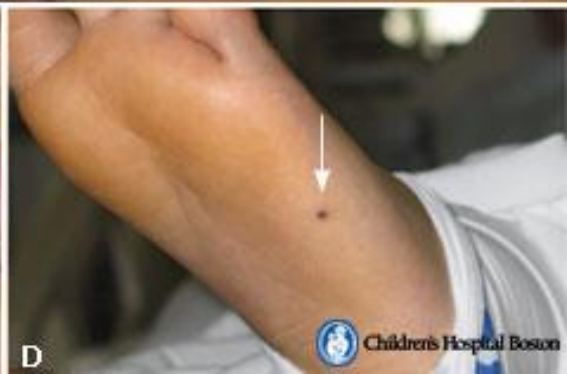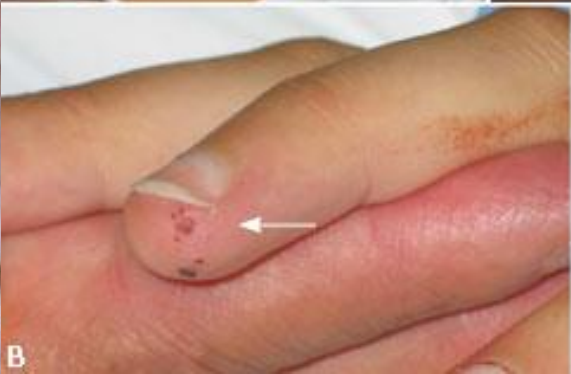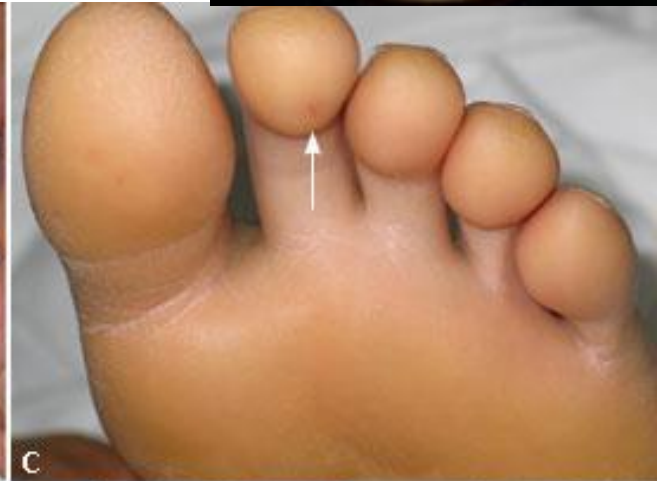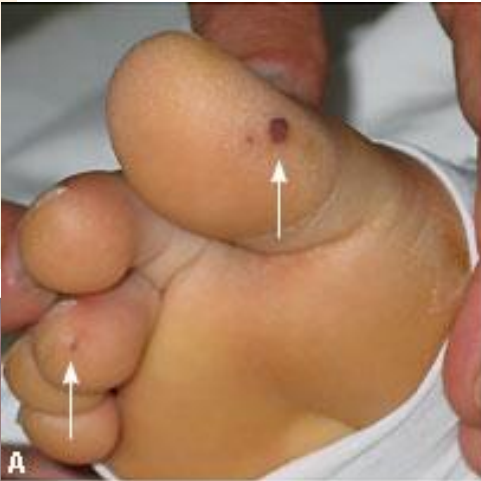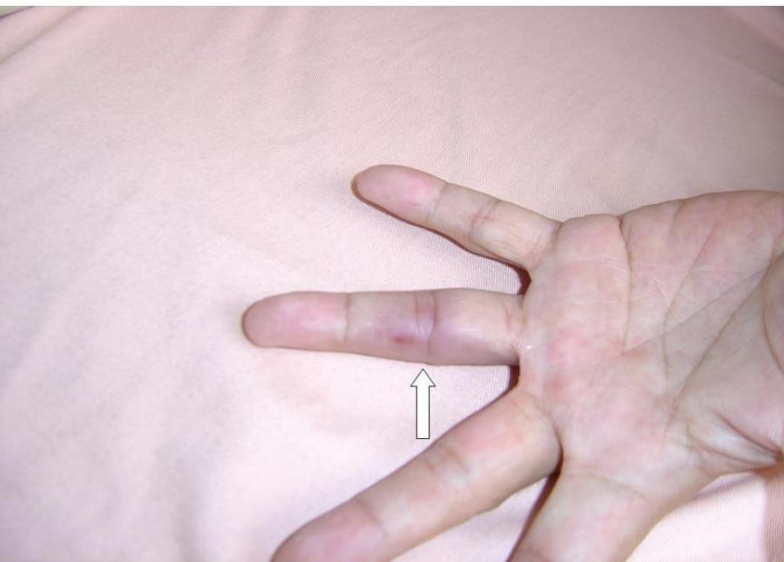
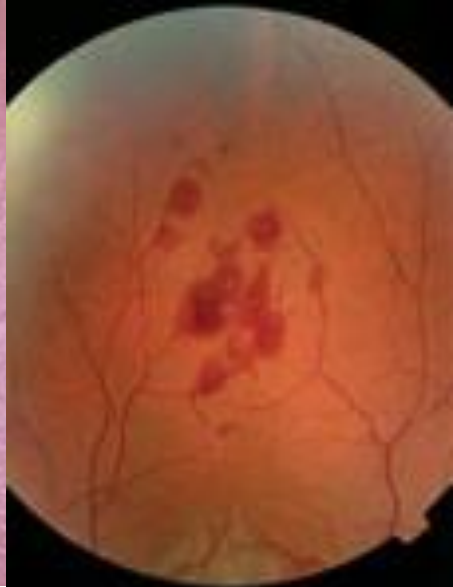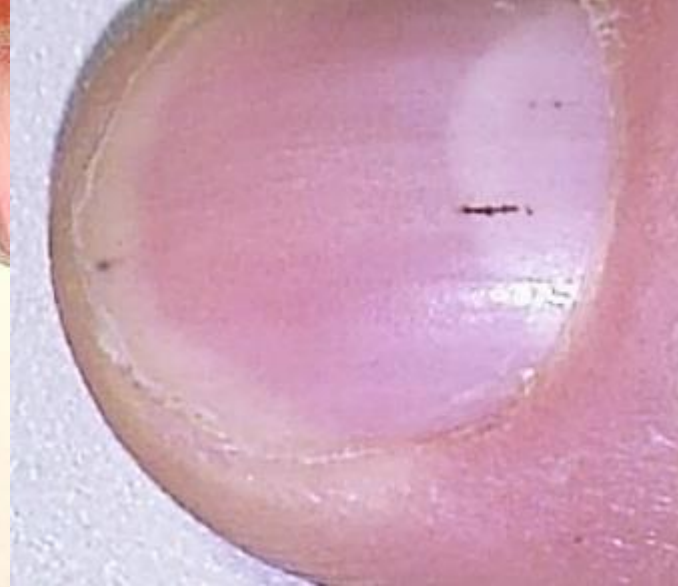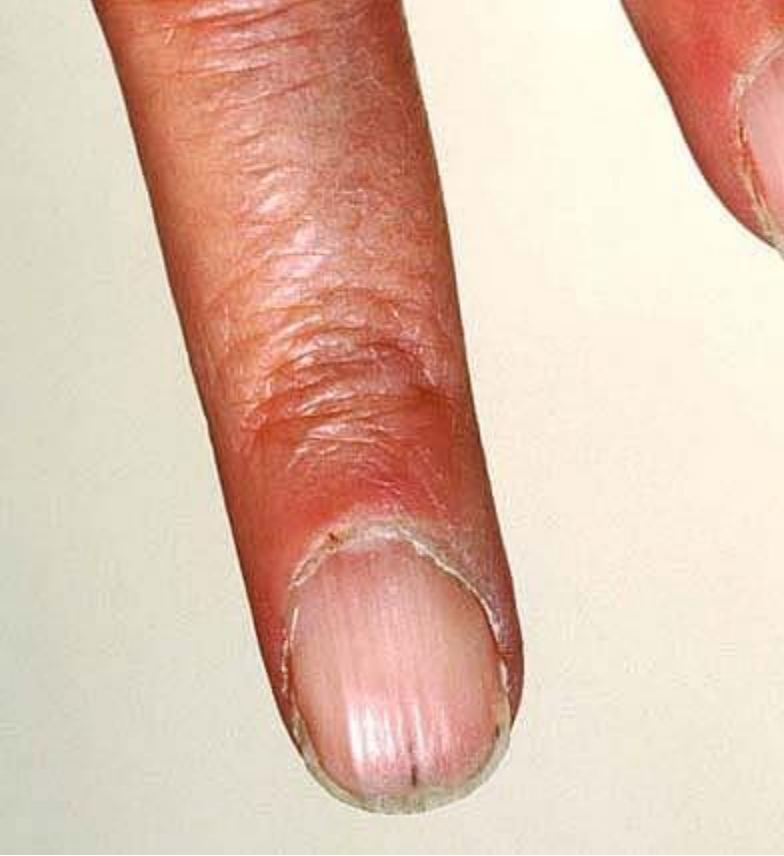# DIAGNOSIS=MM<sub>m</sub>, M<sub>mmm</sub>, mmmmm

## • MAJOR

- Positive blood culture(s) indicating characteristic organism or persistence of unusual organism
- Echocardiographic findings, including valve-related or implant-related mass or abscess, or partial separation of artificial valve
- New valvular regurgitation

## • minor

- Predisposing heart lesion or intravenous drug use
- Fever
- Vascular lesions, including arterial petechiae, subungual/splinter hemorrhages, emboli, septic infarcts, mycotic aneurysm, intracranial hemorrhage, Janeway lesions
- Immunologic phenomena, including glomerulonephritis, Osler nodes, Roth spots, rheumatoid factor
- Microbiologic evidence, including single culture showing uncharacteristic organism
- Echocardiographic findings consistent with but not diagnostic of endocarditis, including new valvular regurgitation, pericarditis

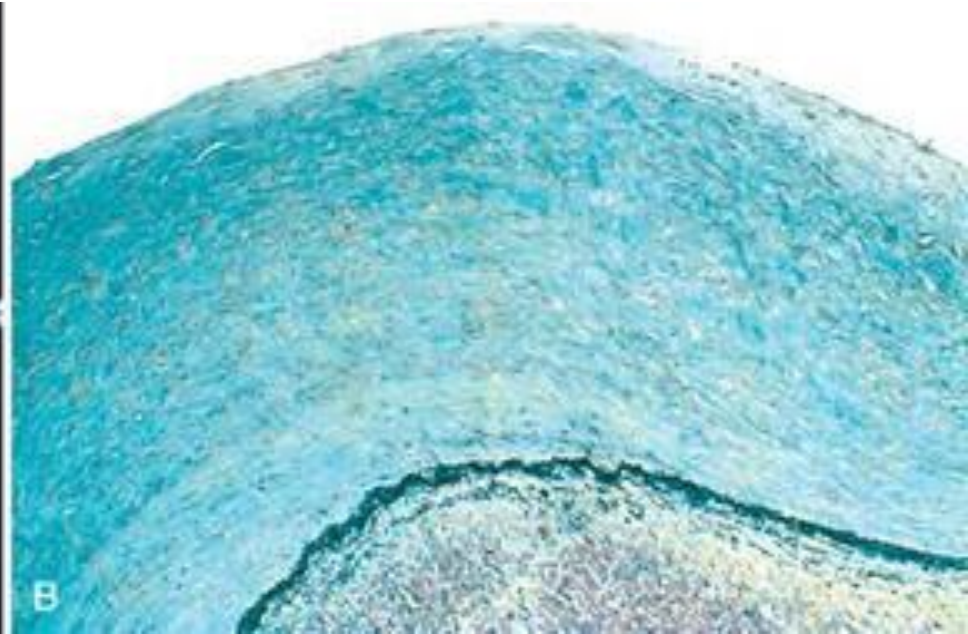
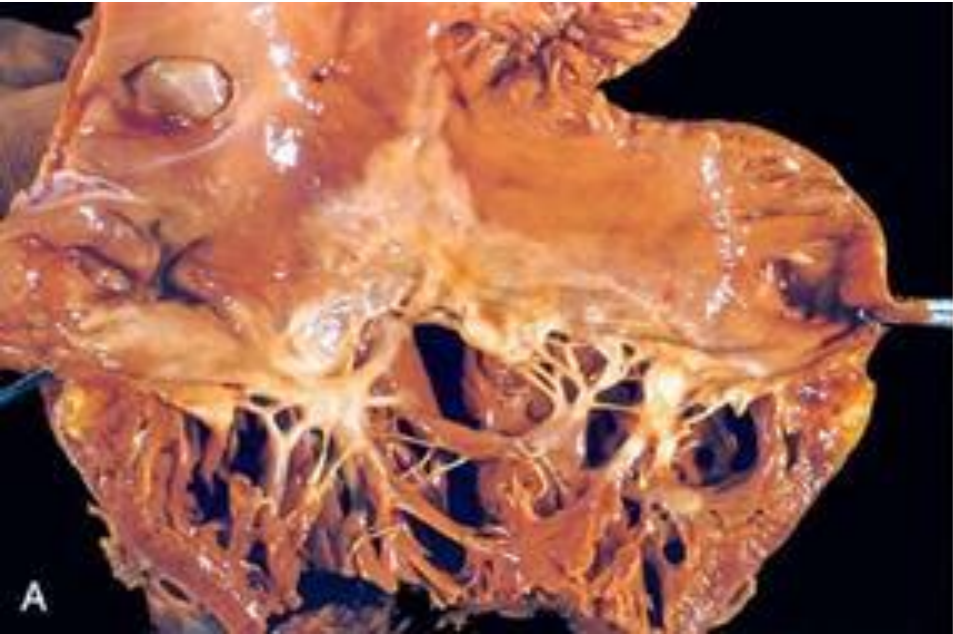


# NON-infective VEGETATIONS

- **<5 mm**
- **PE**
- **Trousseau syndrome (migratory thrombophlebitis with malignancies)**
- **s/p Swan-Ganz**
- **Libman-Saks with SLE (both sides of valve)**

# Carcinoid Syndrome

- Episodic skin flushing
- Cramps
- Nausea & Vomiting
- Diarrhea
- ↑ serotonin, ↑ 5HIAA in urine
- **FIBROUS INTIMAL THICKENING**
  - RV, Tricuspid valve, Pulmonic valve (all RIGHT side)
  - Similar to what Fen-Phen does on the LEFT side

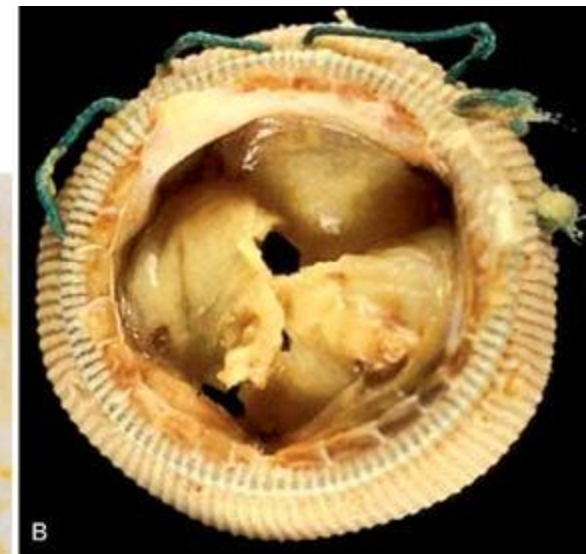
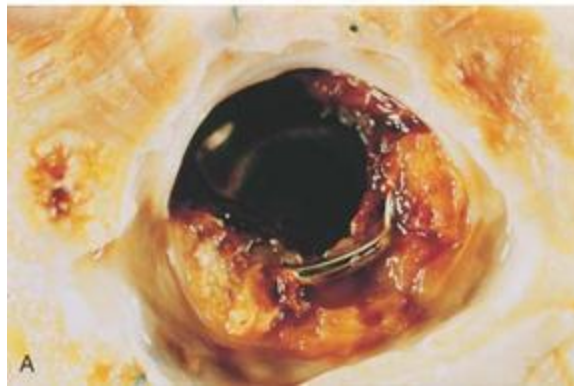

# ARTIFICIAL

## • Mechanical VALVES

- Xenografts (porcine)

- 60% have complications within 10 years





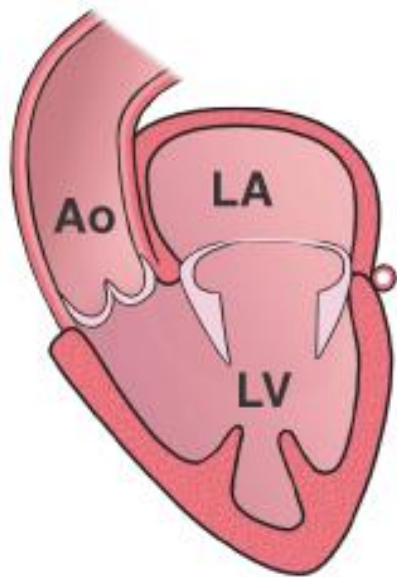
# HEART DISEASE

- CONGENITAL (CHD)
- ISCHEMIC (IHD)
- HYPERTENSIVE (HHD)
- VALVULAR (VHD)
- **MYOPATHIC (MHD)**
- PERICARDIAL DISEASE

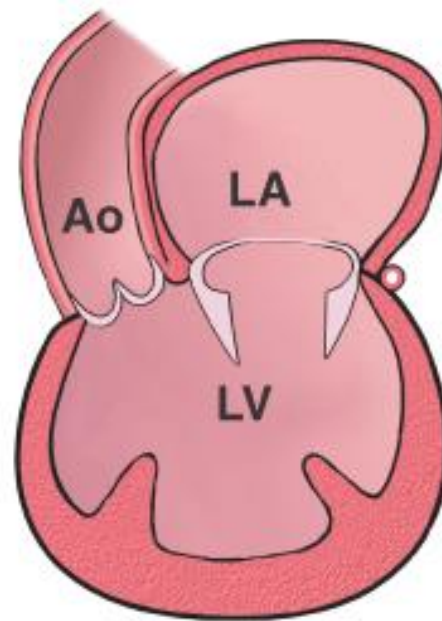
# CARDIOMYOPATHI

## ES

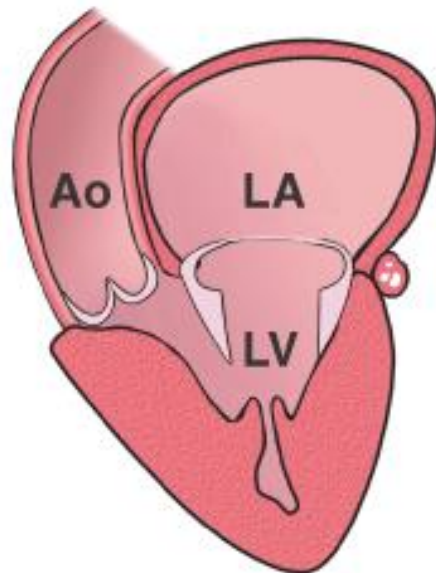
- **DILATED (DCM)**
    - SY-stolic dysfunction
  - **HYPERTROPHIC (HCM)**
    - DIA-stolic dysfunction
  - **RESTRICTIVE (RCM)**
    - DIA-stolic dysfunction
- **Inflammatory**
  - **Immunologic**
  - **Metabolic**
  - **Dystrophies**
  - **Genetic**
  - **Idiopathic**



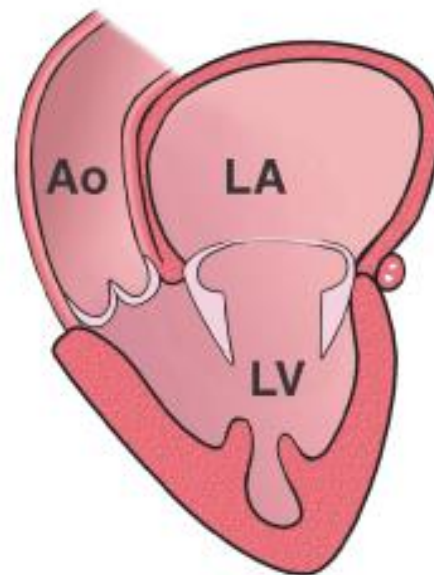
Normal



Dilated  
cardiomyopathy



Hypertrophic  
cardiomyopathy



Restrictive  
cardiomyopathy

<b>Functional Pattern</b>	<b>LVEF :</b>	<b>Mechanisms of Heart Failure</b>	<b>Causes</b>	<b>Indirect Myocardial Dysfunction (Not Cardiomyopathy)</b>
<b>Dilated</b>	<b>&lt;40%</b>	<b>Impairment of contractility (systolic dysfunction)</b>	<b>Idiopathic; alcohol; peripartum; genetic; myocarditis; hemochromatosis; chronic anemia; doxorubicin (Adriamycin); sarcoidosis</b>	<b>Ischemic heart disease; valvular heart disease; hypertensive heart disease; congenital heart disease</b>
<b>Hypertrophic</b>	<b>50–80%</b>	<b>Impairment of compliance (diastolic dysfunction)</b>	<b>Genetic; Friedreich ataxia; storage diseases; infants of diabetic mothers</b>	<b>Hypertensive heart disease; aortic stenosis</b>
<b>Restrictive</b>	<b>45–90%</b>	<b>Impairment of compliance (diastolic dysfunction)</b>	<b>Idiopathic; amyloidosis; radiation-induced fibrosis</b>	<b>Pericardial constriction</b>

## **Cardiac Infections**

Viruses  
Chlamydia  
Rickettsia  
Bacteria  
Fungi  
Protozoa

## **Neuromuscular Disease**

Friedreich ataxia  
Muscular dystrophy  
Congenital atrophies

## **Immunologic**

Myocarditis (several forms)  
Post-transplant rejection

## **Toxins**

Alcohol  
Cobalt  
Catecholamines  
Carbon monoxide  
Lithium  
Hydrocarbons  
Arsenic  
Cyclophosphamide  
Doxorubicin (Adriamycin) and daunorubicin

## **Storage Disorders and Other Depositions**

Hunter-Hurler syndrome  
Glycogen storage disease  
Fabry disease  
Amyloidosis

## **Metabolic**

Hyperthyroidism  
Hypothyroidism  
Hyperkalemia  
Hypokalemia  
Nutritional deficiency (protein, thiamine, other avitaminoses)  
Hemochromatosis

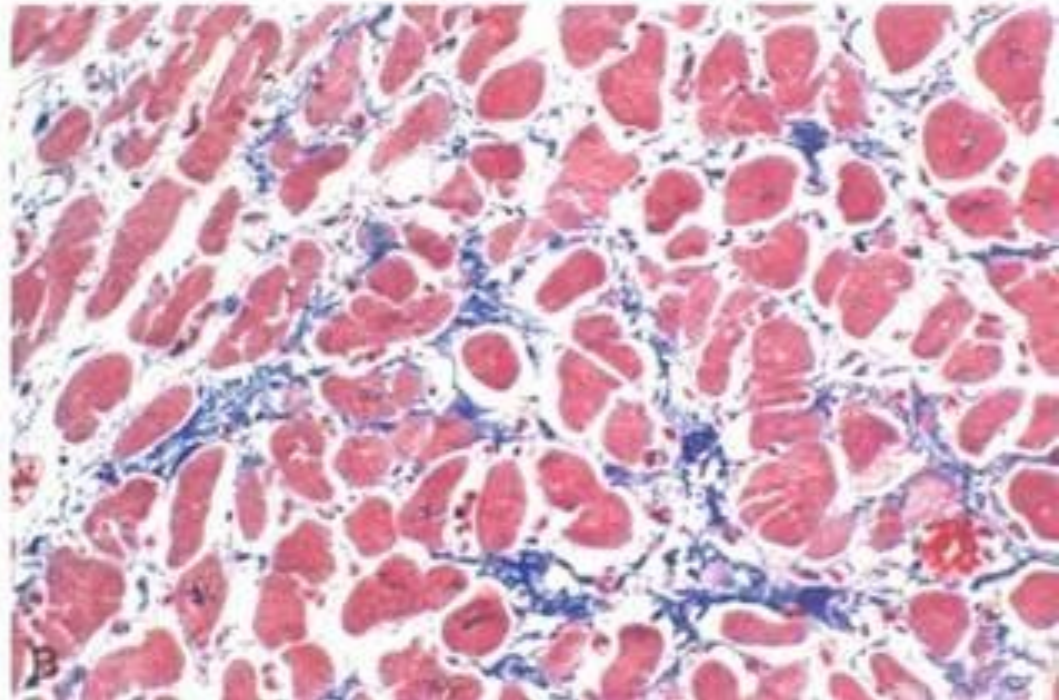
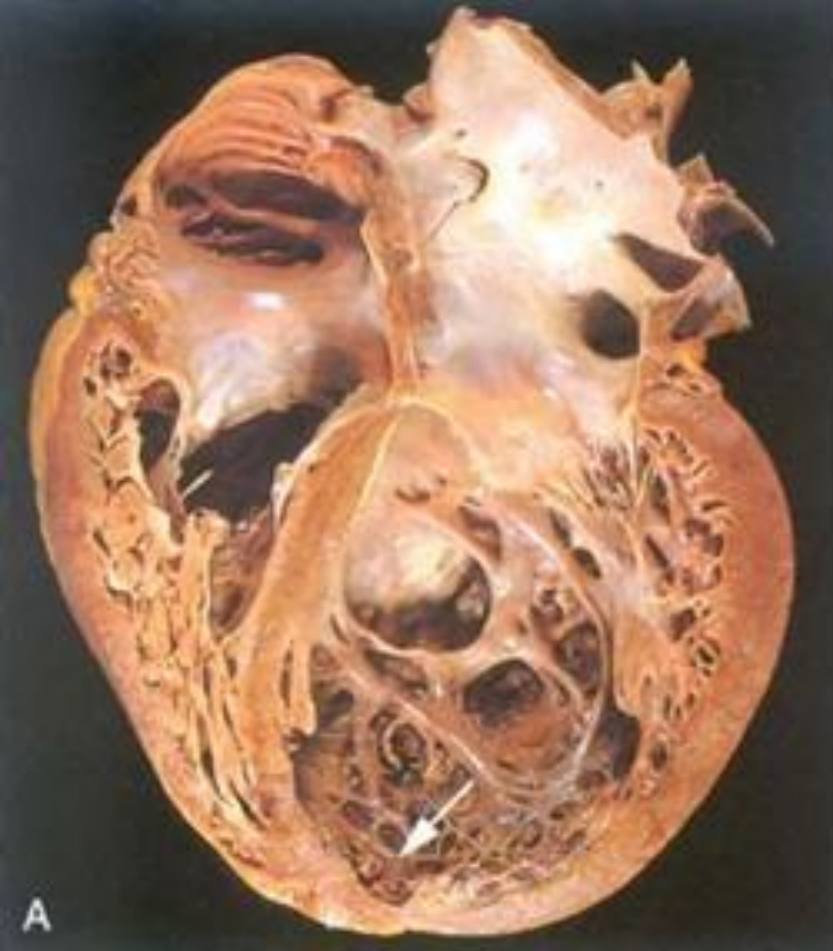## **Infiltrative**

Leukemia  
Carcinomatosis  
Sarcoidosis  
Radiation-induced fibrosis

# **DILATED** cardiomyopathy

- **Chamber thickness (not just LVH)**
- **Adults**
- **Progressively declining LVEF**
- **LVEF ~ prognosis**
- **50% die in 2 years**
- **3 Main causes**
  - **Myocarditis**
  - **ETOH**
  - **Adriamycin**

# DCM



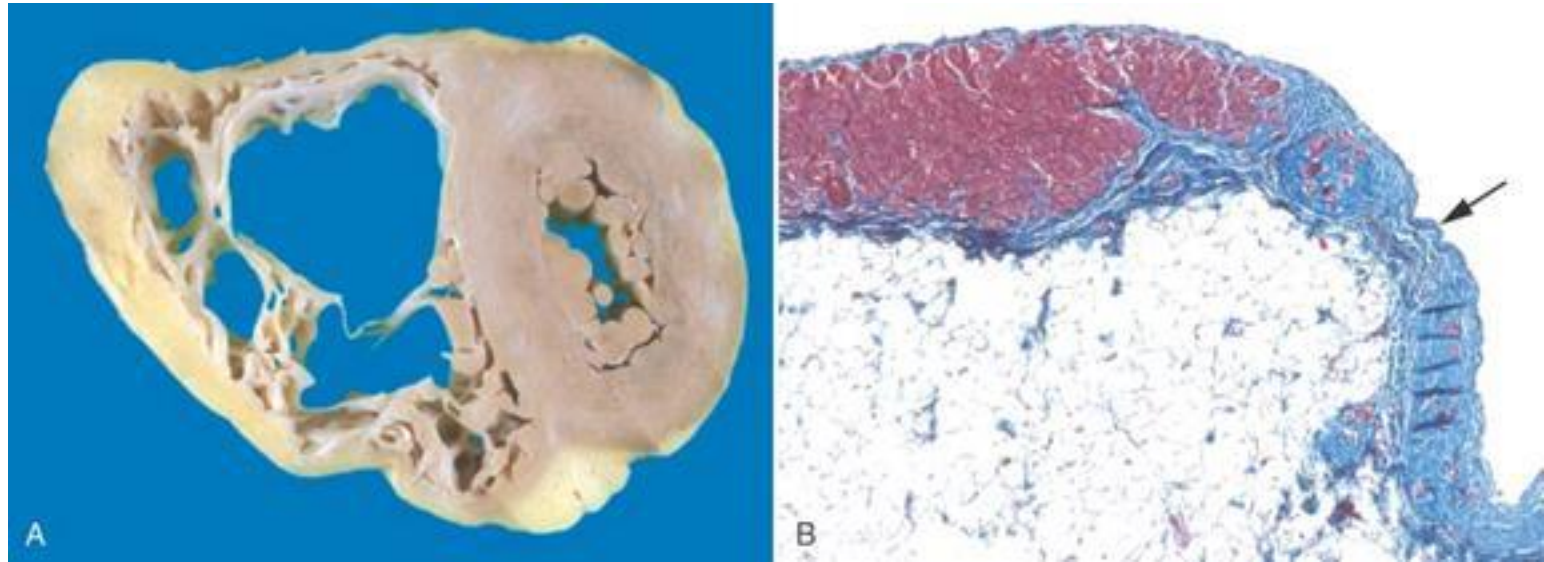
**Path:**

**4 chamber dilatation**

**Hypertrophy**

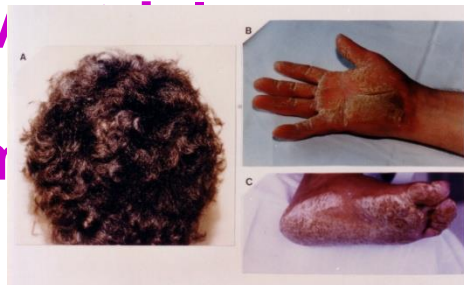**Interstitial Fibrosis**

# Arrhythmogenic Right Ventricular Cardiomyopathy (Arrhythmogenic Right Ventricular Dysplasia)



This is an uncommon dilated cardiomyopathy predominantly RIGHT ventricular

So is NAXOS syndrome





# **HYPERTROPHIC cardiomyopathy**

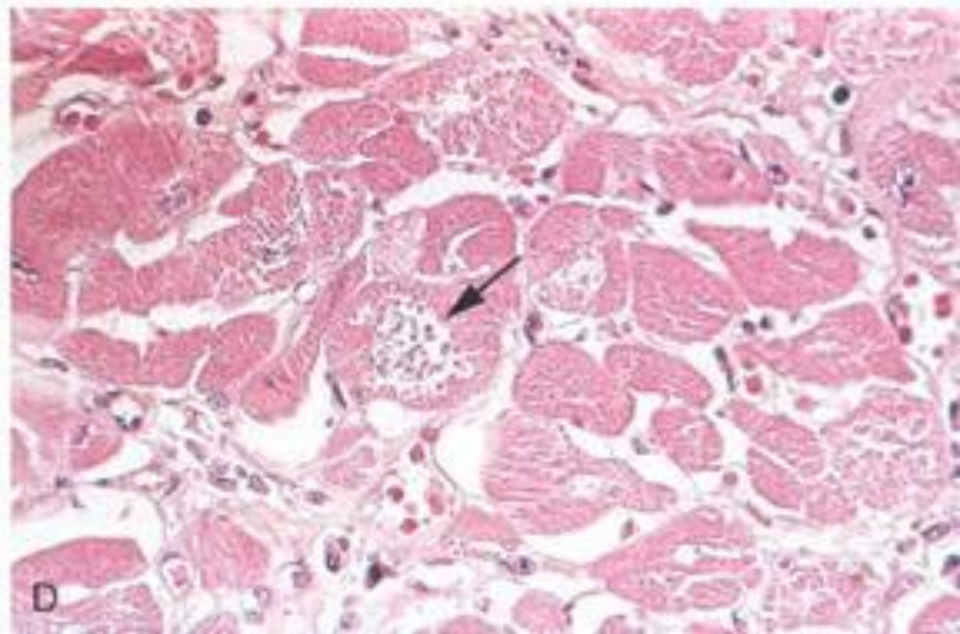
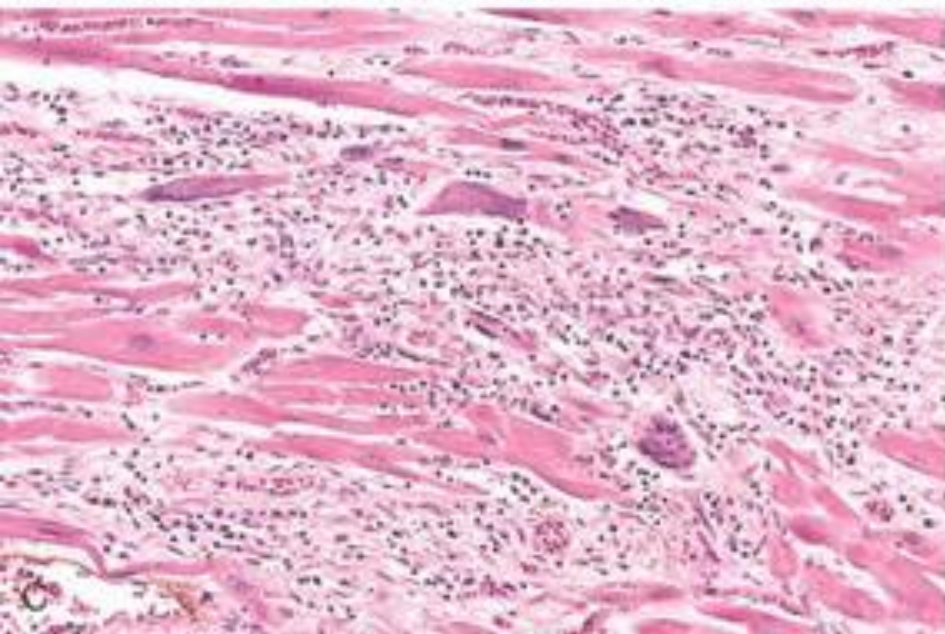
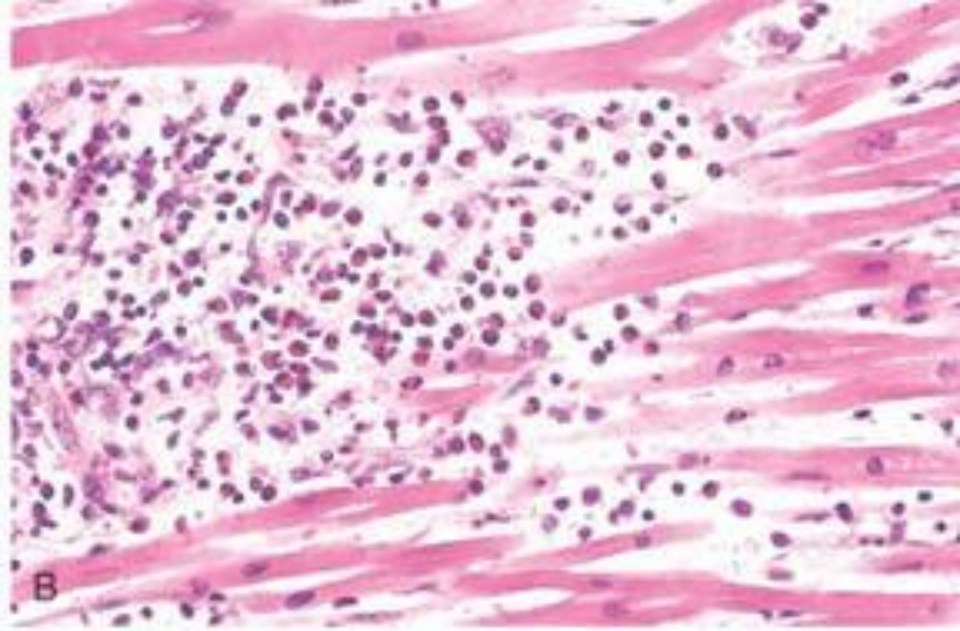
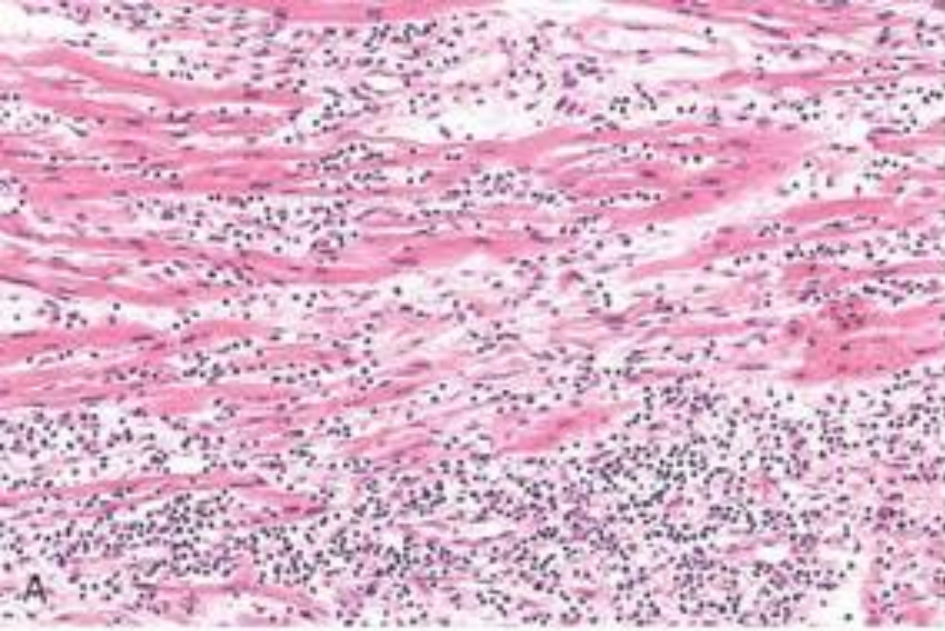
- Also called IHSS, (**Idiopathic Hypertrophic Subaortic Stenosis**)
  - **GENETIC** defects involving:
    - **Beta-myosin heavy chain**
    - **Troponin T**
    - **Alpha-tropomyosin**
    - **Myosin binding protein C**
  - **PATHOLOGY**: **Massive hypertrophy, Asymmetric septum, DISARRAY of myocytes, INTERSTITIAL fibrosis**
  - **CLINICAL**: **↓ chamber volume, ↓ SV, ↓ diastolic filling**

# **RESTRICTIVE** cardiomyopathy

- **(idiopathic)**
- **↓ ventricular compliance**
- **Chiefly affects DIASTOLE**
- **NORMAL** chamber size and wall thickness
- **THREE** similar diseases affecting predominantly the **SUBENDOCARDIAL** area:
  - **Endomyocardial Fibrosis (African children)**
  - **Loeffler Endomyocarditis (eosinophilic leukemia)**
  - **Endocardial Fibroelastosis (infants)**

# MYOCARDITIS

- **INFLAMMATION of MYOCARDIUM**
- **Chiefly microbial**
  - **COXSACKIE A & B, CMV, HIV**
  - **Trypanosoma cruzi (Chagas dis.), 80%**
  - **Trichinosis**
  - **Toxoplasmosis**
  - **Lyme disease (5%)**
  - **Diphtheria**
- **IMMUNE: Post-viral, rheumatic, SLE, drug hypersensitivity → alpha-methyl dopa, sulfas**



**LYMPHOCYTIC INFILTRATES** are the **USUAL** pattern of **ALL** myocarditis, but eosinophils, giant cells, and even

# OTHER Myocarditides

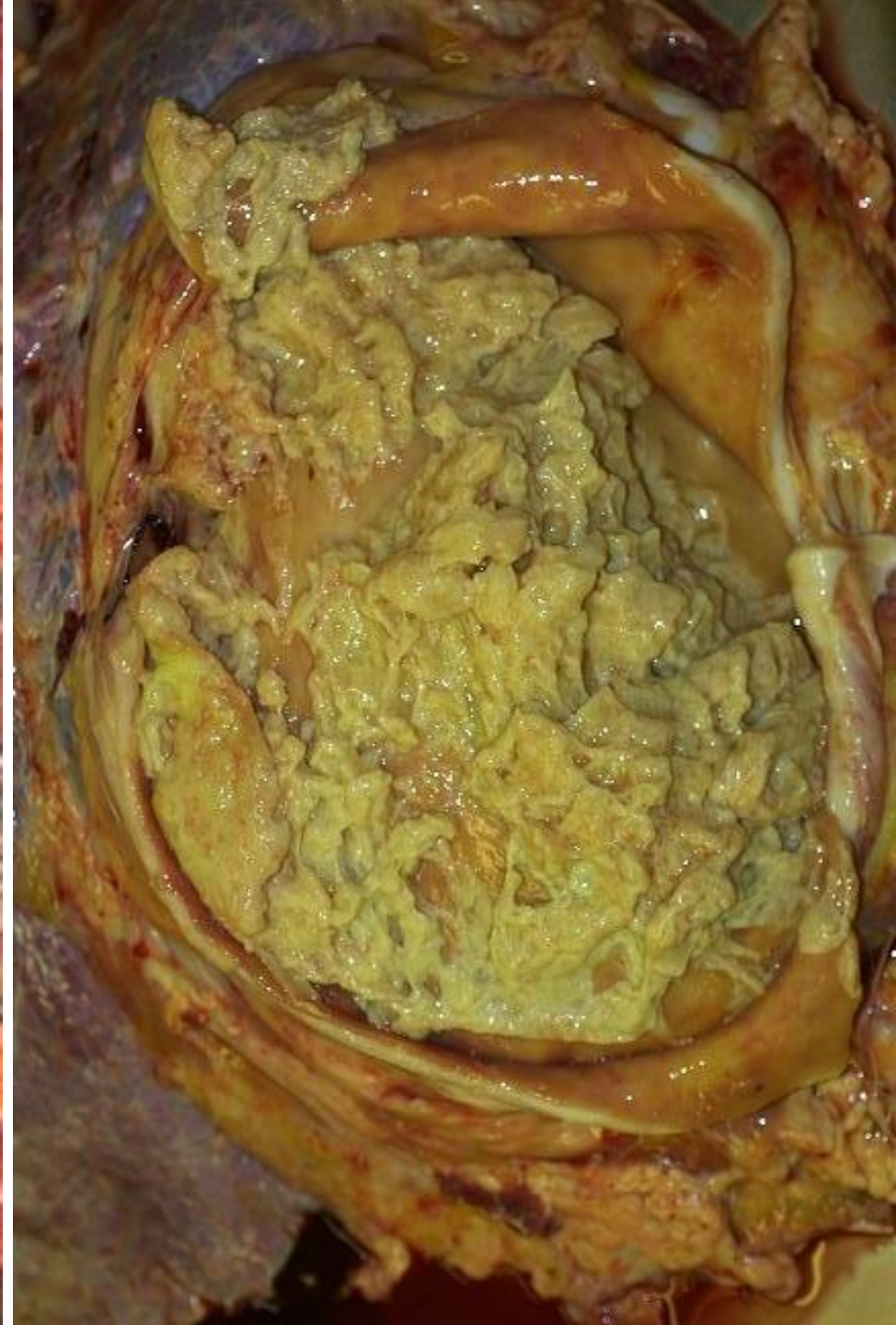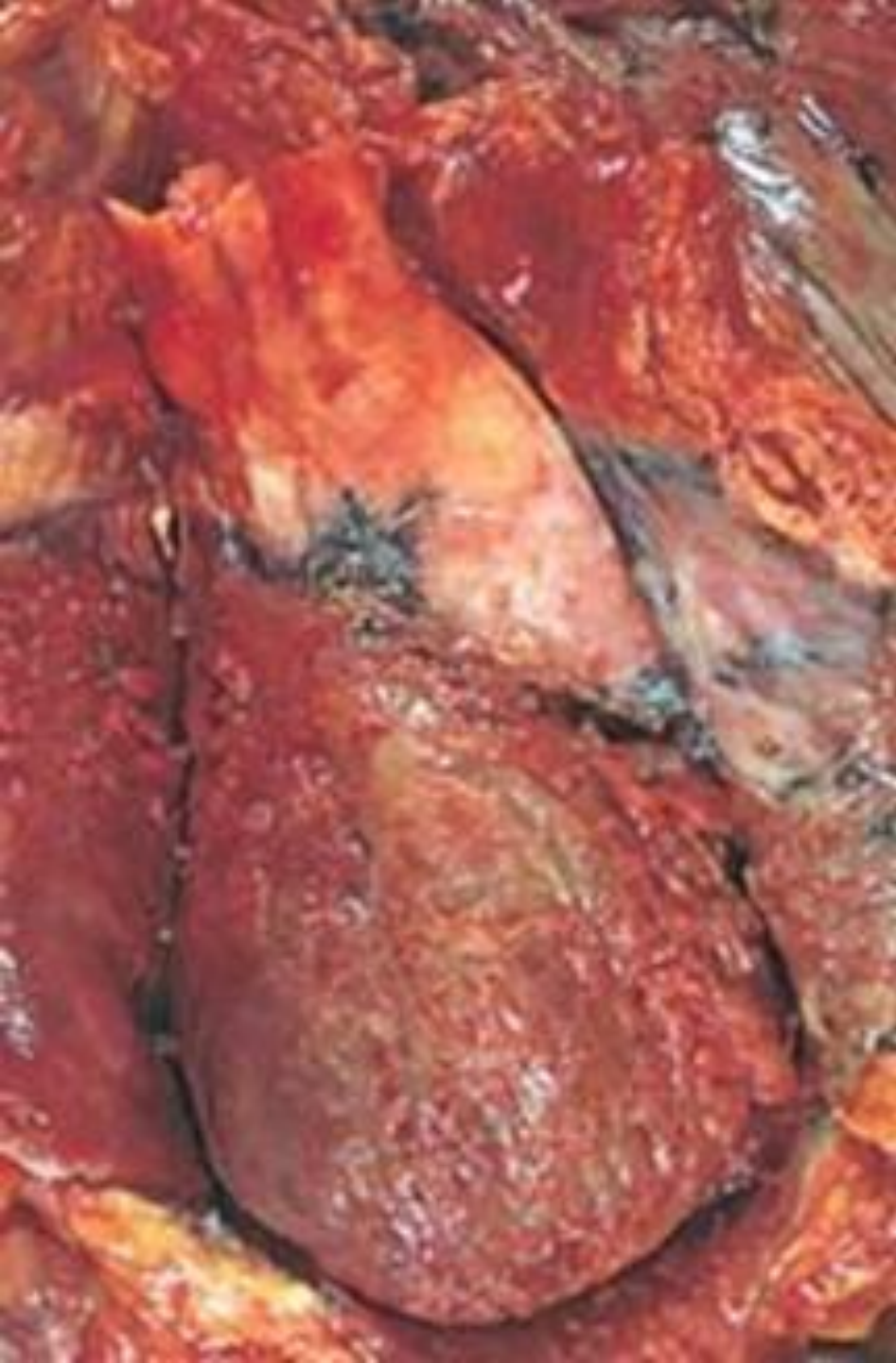- **Adriamycin**
- **Cyclophosphamide**
- **Catecholamines (Pheochromocytomas)**
- **Amyloid, systemic or primary cardiac**
  - Congo red stain: green birefringence with polarization
- **Amyloid, aging**
  - Congo red stain: green birefringence with polarization
- **Hemochromatosis (Prussian Blue)**
- **BOTH HYPER-, HYPO- -thyroidism**

# PERICARDIUM

- **Normally 30-50 ml clear serous fluid**
  - **Visceral (epicardium)**
  - **Parietal (Fibrous pericardium)**
- **PERICARDIAL EFFUSIONS → TAMPONADE**
  - **Ruptured MI**
  - **Traumatic perforation**
  - **Infective endocarditis**
  - **Ruptured aortic dissection**

# PERICARDITIS

- **SEROUS:** Rheum. Fever (RF), SLE, scleroderma, tumors, uremia
- **FIBRINOUS:** MI (Dressler), uremia, radiation, RF, SLE, s/p open heart surgery
- **PURULENT:** infective, bacterial
- **HEMORRHAGIC:** Malignancy, TB
- **CASEOUS:** TB
- **CHRONIC:** (ADHESIVE, CONSTRICTIVE)

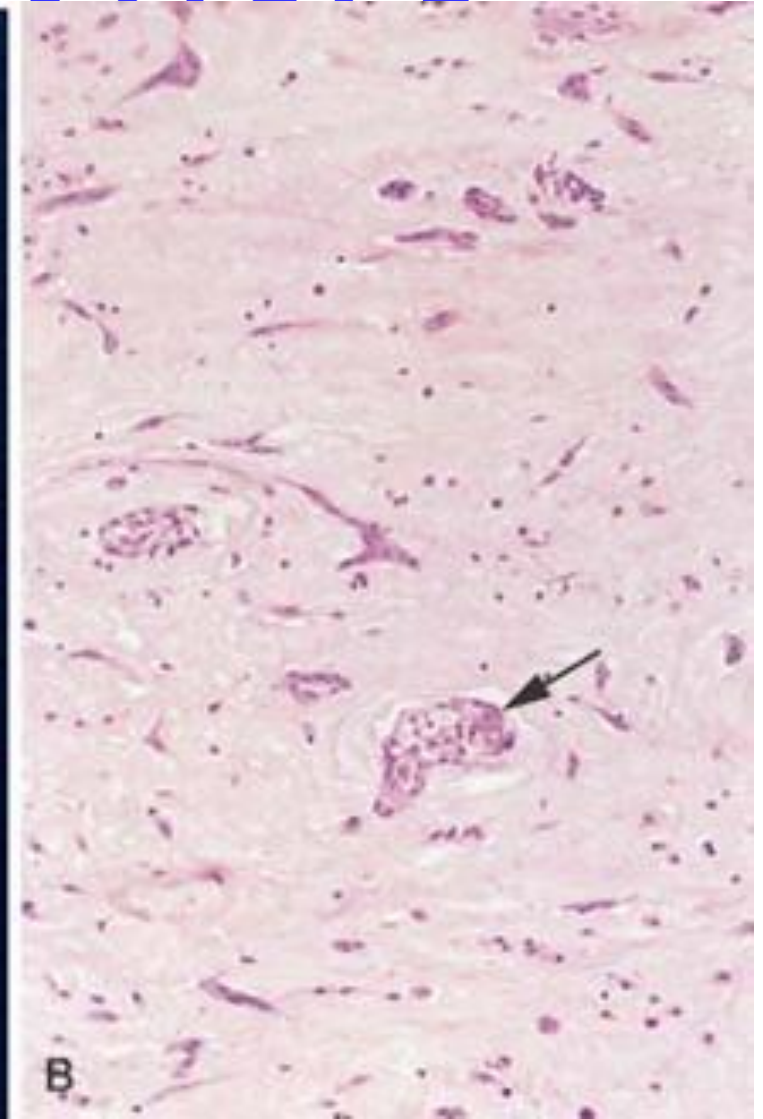
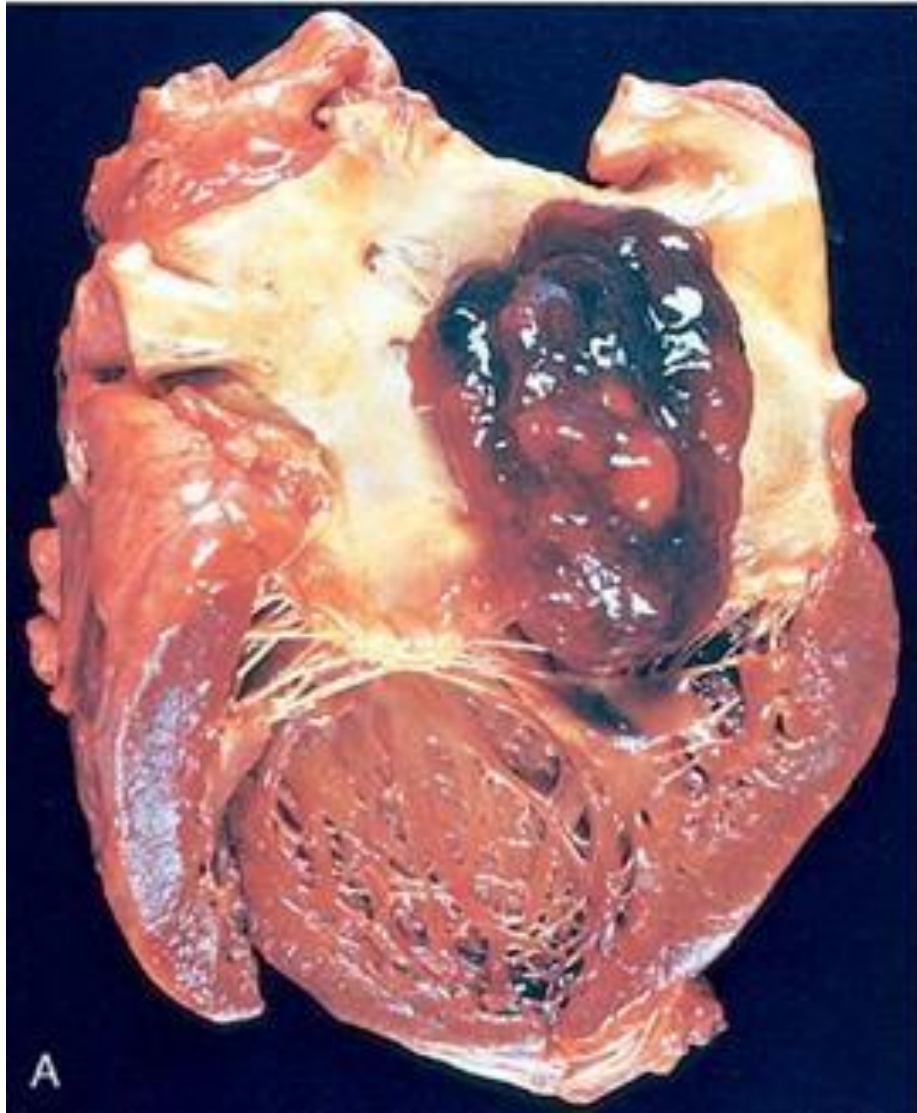




# TUMORS

- 90% benign “mesenchymal”, i.e., stromal
  - **MYXOMAS (LEFT ATRIUM MOST COMMON)**
  - FIBROMAS
  - LIPOMAS
  - FIBROELASTOMAS
  - RHABDOMYOMA (Most common cardiac tumor in children)
- 10% SARCOMAS

# MYXOMA



# Cardiac effects of NON-cardiac tumors

- *Direct Consequences of Tumor*
  - Pericardial and myocardial metastases
  - Large vessel obstruction
  - Pulmonary tumor emboli
- *Indirect Consequences of Tumor (Complications of Circulating Mediators)*
  - Nonbacterial thrombotic endocarditis (NBTE)
  - Carcinoid heart disease
  - Pheochromocytoma-associated heart disease
  - Myeloma-associated amyloidosis
- *Effects of Tumor Therapy*
  - Chemotherapy
  - Radiation therapy

# CARDIAC TRANSPLANT PATHOLOGY

- **Most patients are on immunosuppressives**
- **5 year survival >60%**

# CARDIAC TRANSPLANT PATHOLOGY

