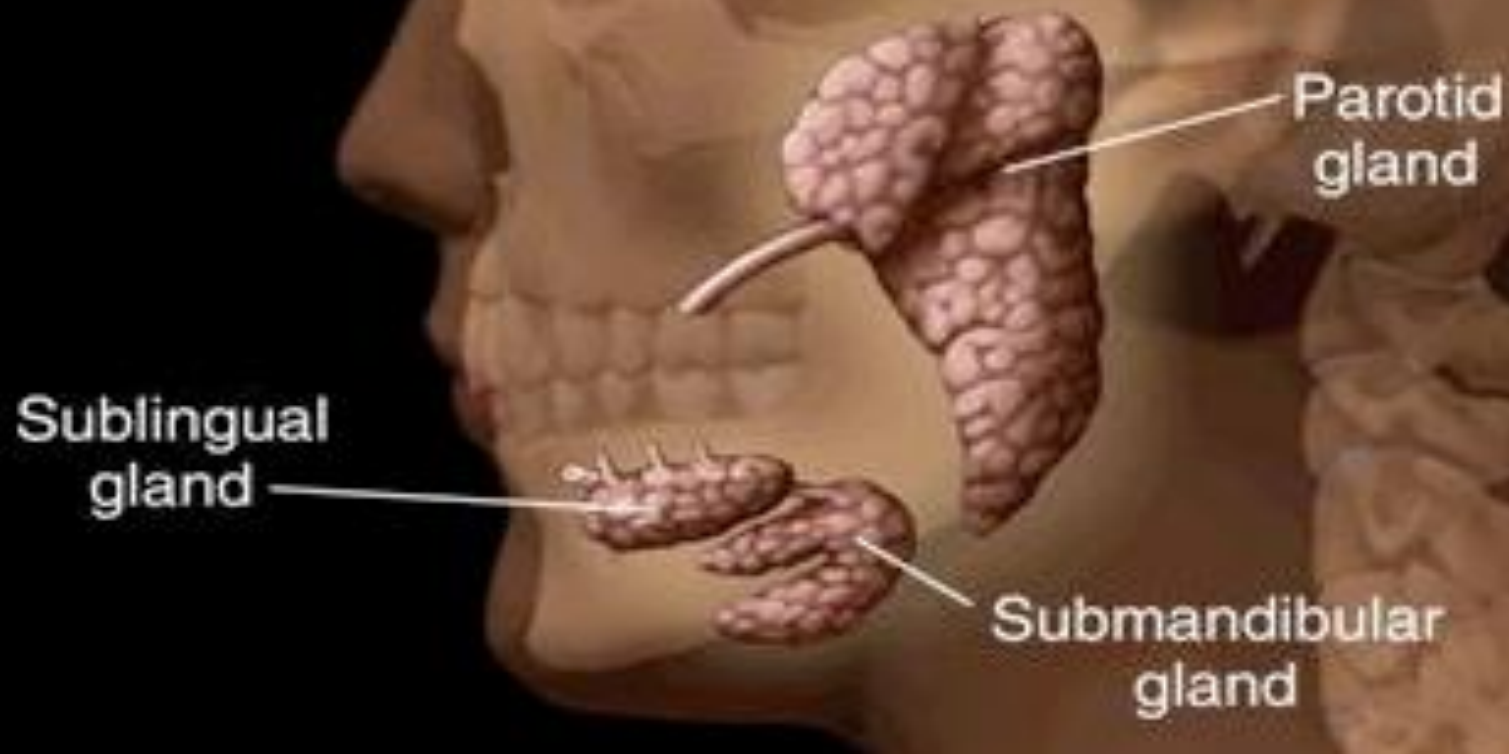


# Salivary Glands



**Salivary glands pathology.**

## Salivary glands pathology.

### Microspecimens:

**№ OP32. Mucocele of the salivary gland.** (*H-E. stain*).

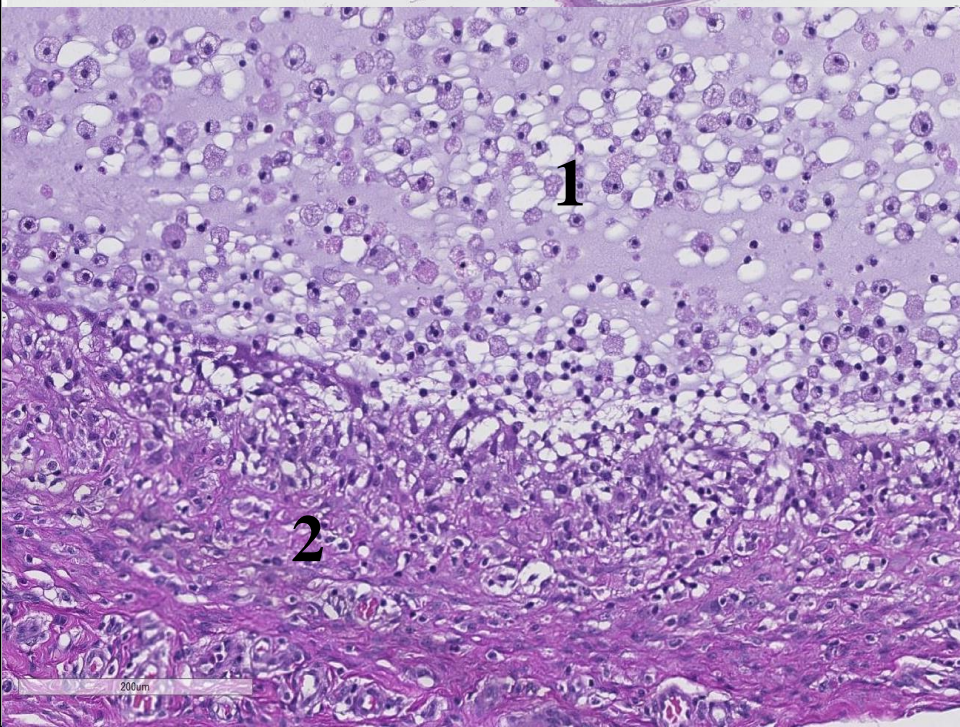
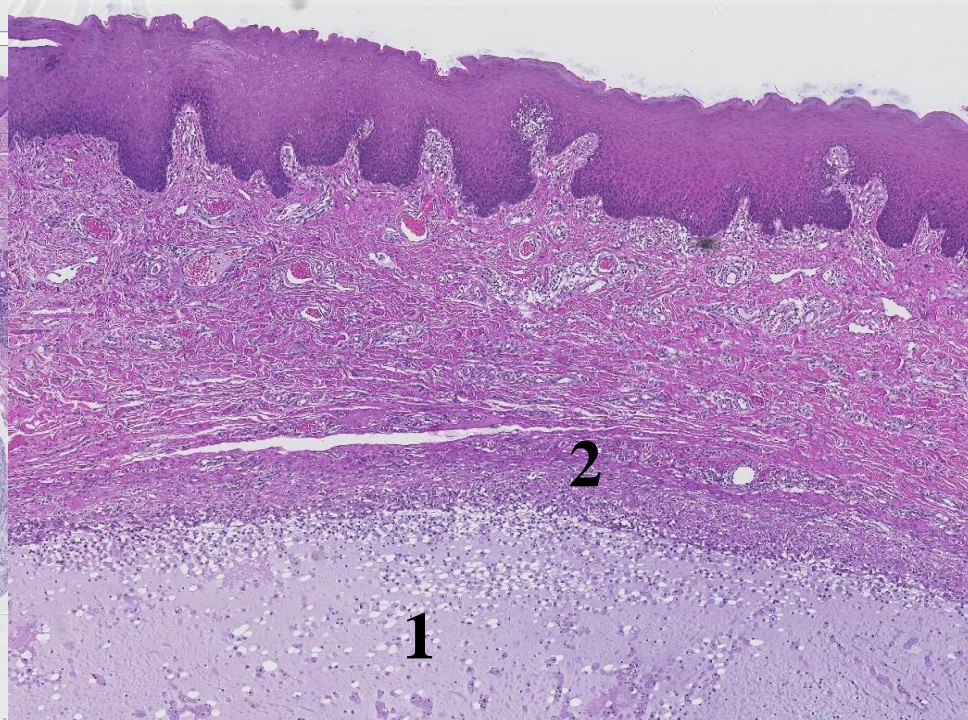
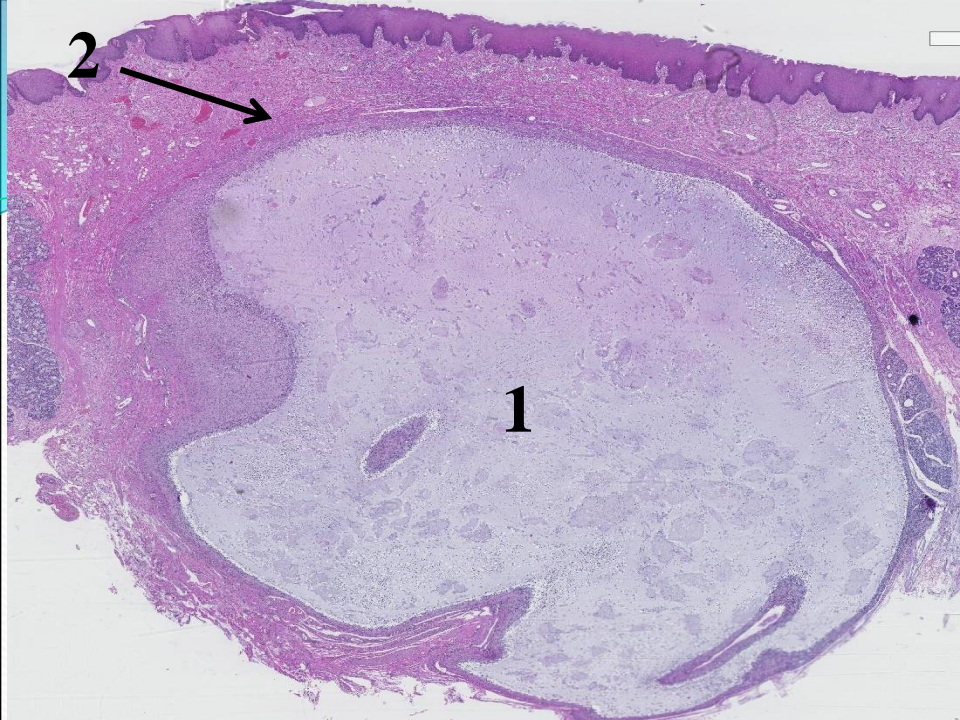### Indications:

1. Mucinous material with macrophages.
2. Fibrous capsule.

Microscopically, in the chorion of the oral mucosa or in the submucosa, a basophilic, mucinous material is observed, in which macrophages with foamy cytoplasm float and which is surrounded by granulation tissue, which over time turns into a fibrous capsule. Because it is not bounded by an epithelium, the mucocele is not a true cyst.

*Macroscopically, it appears as a well-defined, fluctuating node, which protrudes to the surface, with dimensions between 1 millimeter to a few centimeters, the surface smooth, transparent, bluish.*

*Mucocele occurs in the minor salivary glands, being located most frequently in the lower lip, but can also occur in the jugal mucosa, ventral part of the tongue, as in the sublingual region, practically wherever there are minor salivary glands. It occurs mainly in children and young adults. It is due to the interruption of the continuity of a salivary duct, most frequently following a trauma, resulting in the elimination of the secretion product in the surrounding stroma.*



**№ OP32. Mucocele of the salivary gland.**  
(*H-E. stain*).

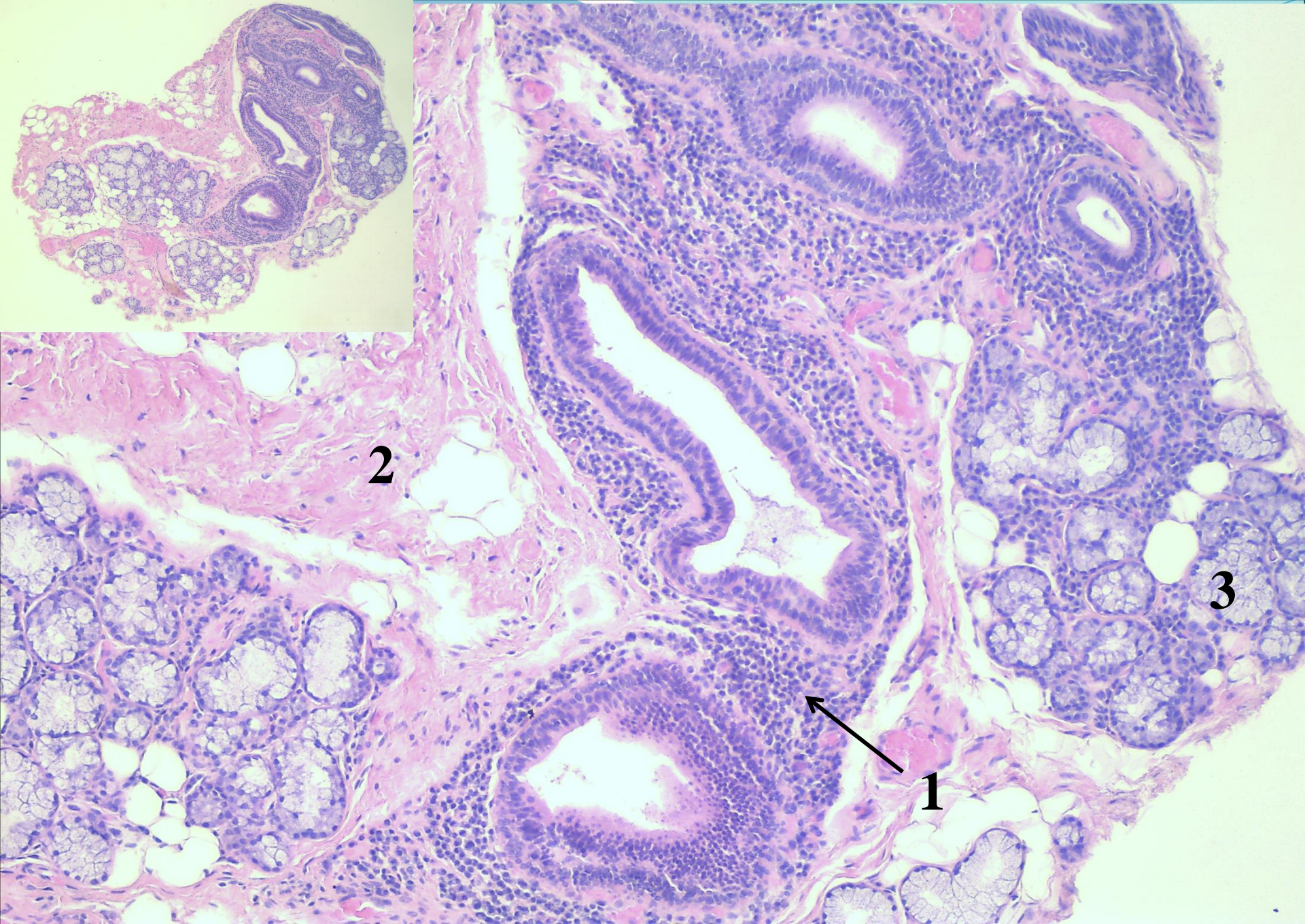
## **№ OP35. Sjögren syndrome. ( H-E. stain).**

### **Indications:**

1. Lymphoid infiltrate.
2. Interstitial fibrosis.
3. Atrophied salivary acini.

Microscopically, a diffuse inflammatory lymphocytic infiltrate is observed, which causes the destruction of salivary acini. However, the duct epithelium persists in the form of islands surrounded by myoepithelial cells, these islands being called epimioepithelial islands. Biopsy of the minor salivary glands in the lower lip is an important element in the diagnosis of Sjögren's syndrome, as it can highlight an abundant lymph-plasma inflammatory infiltrate and thus avoid biopsy of the major salivary gland affected.

Sjögren's syndrome is a systemic, chronic autoimmune condition that mainly affects the salivary and lacrimal glands, so it is associated with xerostomia and xerophthalmia. It occurs especially in adult women (the first symptoms appear around the age of 50) and more frequently affects the parotid gland. Clinically, patients have swelling that is bilateral and symmetrical, due to xerostomia (caused by decreased salivary secretion) multiple caries, periodontal lesions, as well as Candida infections of the oral cavity. Due to xerophthalmia (caused by decreased tear secretion) kerato-conjunctivitis occurs. In patients with Sjögren's syndrome, the risk of developing lymphoma of the salivary gland is increased.



**№ OP35. Sjögren syndrome. ( H-E. stain).**

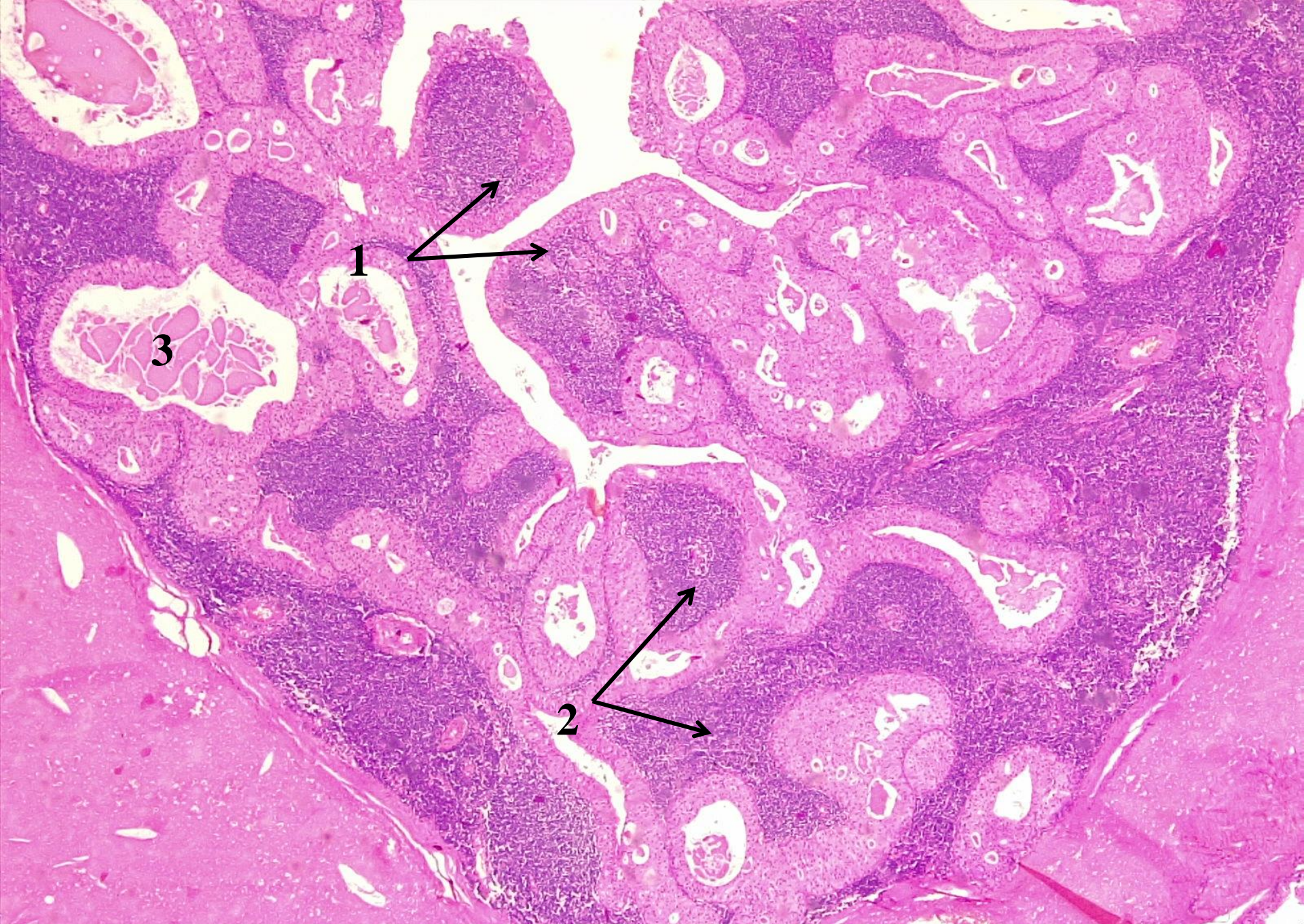
## **№ 202. Adenolymphoma (Warthin tumor) of the parotid gland. (H-E. stain).**

### **Indications:**

1. Papillary structures lined by columnar epithelium.
2. Stroma with dense lymphocytic infiltrate.
3. Cystic spaces.

Microscopically, the tumor has a capsule at the periphery and is made up of cystic spaces delimited by a bilayered epithelium, in some places with papillary growths. There is lymphoid tissue in the surrounding stroma. The epithelium is represented, in the luminal portion, by columnar, oncocytic cells, with palisade of ovoid nuclei, located centrally or at the apical pole. The cell cytoplasm is intensely eosinophilic, finely granular, with distinct cell margins. The granular appearance is due to the high content in the mitochondria. The lumen of the cysts contains a characteristic secretion, with cellular detritus and luminal corpuscles similar to amylaceous bodies. Below and between the columnar cells there are basaloid cells, less obvious and smaller, cubic or triangular in size, with a vesicular nucleus. The epithelium forms papillae of various sizes and shapes, oriented towards the cyst lumen. The fibro-vascular connective tissue forms the stroma of the papillae and contains an abundant lymphoid tissue, composed of small, uniform lymphocyte cells. The proportion between the epithelial and lymphoid elements varies from one tumor to another or even in the same tumor.

*Macroscopically, the tumor has a spherical or ovoid shape, well circumscribed by a thick capsule, if not inflamed, with dimensions of 2-4 centimeters or larger. Numerous cysts with a brown, clear or mucoid fluid content appear on the section surface.*



**No 202. Adenolymphoma (Warthin tumor) of the parotid gland. (H-E. stain).**

## **№ 196. Pleomorphic adenoma of salivary gland. (H-E. stain).**

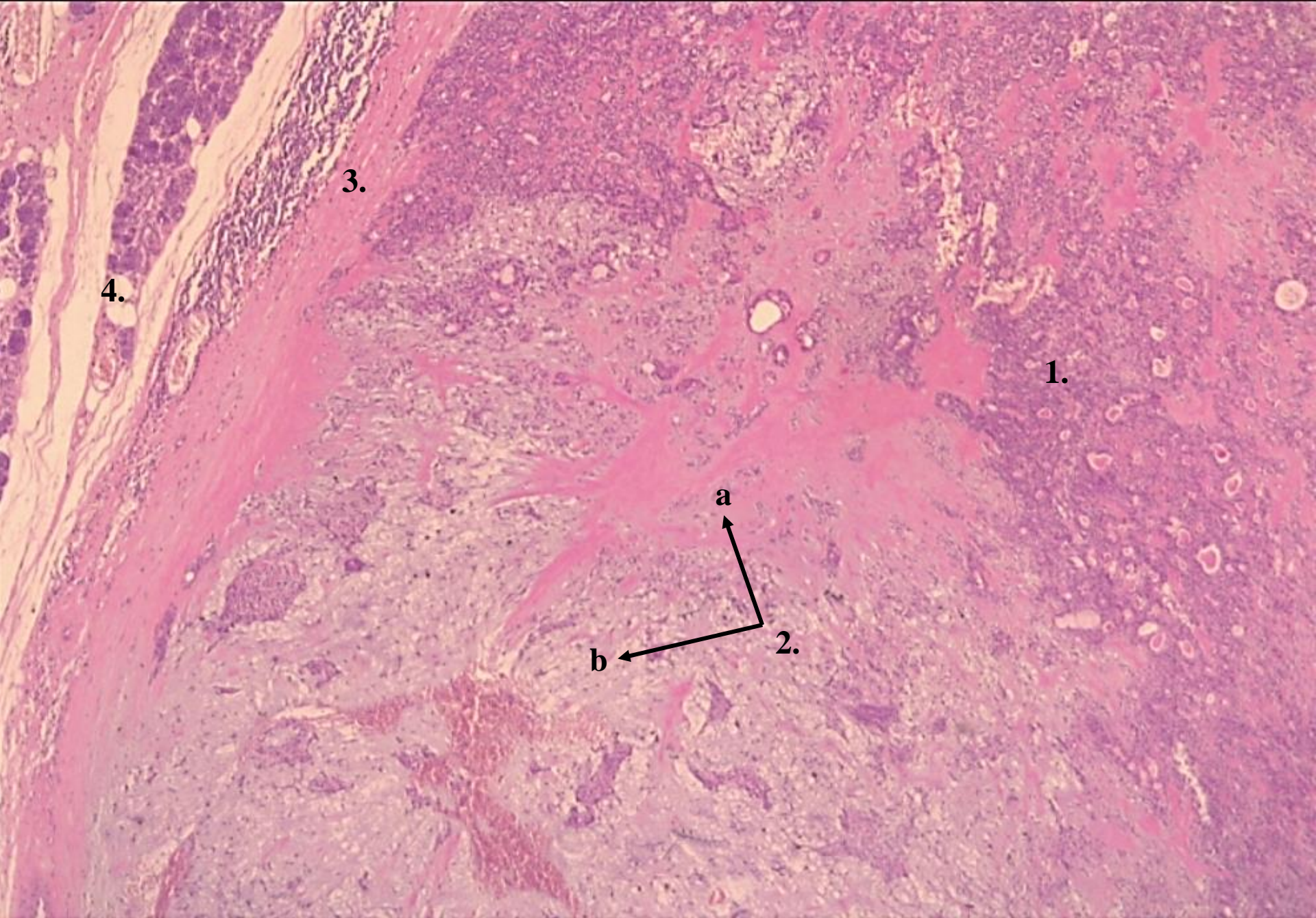
### **Indications:**

1. Epithelial component: glandular structures (ducts, tubes, microcysts), agglomerations of epithelial cells.
2. Mesenchymal component: a) hyaline connective tissue, b) myxoid areas.
3. Fibrous capsule of the tumor.
4. Adjacent tissue of the salivary gland.

Microscopically, it can have very varied aspects, with the presence of both epithelial structures and mesenchymal structures. The ratio of the two components is variable. Epithelial cells can be cuboidal, squamous, basaloid and oncocytic, while myoepithelial cells can have a fusiform and plasmocytoid appearance. The cells are uniform, with small or absent nucleoli. Tumor cells have a very varied architectural arrangement from one tumor to another, but also within the same tumors. Thus, ductal or tubular structures may appear, associated with the presence of anastomous trabeculae, solid bands or microcystic structures. The mesenchymal component is arranged among the epithelial elements, being formed of hyaline, mixoid, chondroid or bone connective tissue.

*Macroscopically, the tumor appears as a round or oval formation, sometimes with an irregular surface, but always well defined. At the level of the major salivary glands, the tumor is delimited by a fibrous capsule, sometimes incomplete and of variable thickness, while at the level of the minor glands, the tumor is not encapsulated. On the section surface, the tumor is homogeneous, gray or white, with areastranslucent where cartilaginous tissue appears. Outbreaks appear to be exacerbated during bleeding or infarction, especially after biopsy, puncture, or previous surgery.*





**№ 196. Pleomorphic adenoma of salivary gland. (*H-E. stain*).**

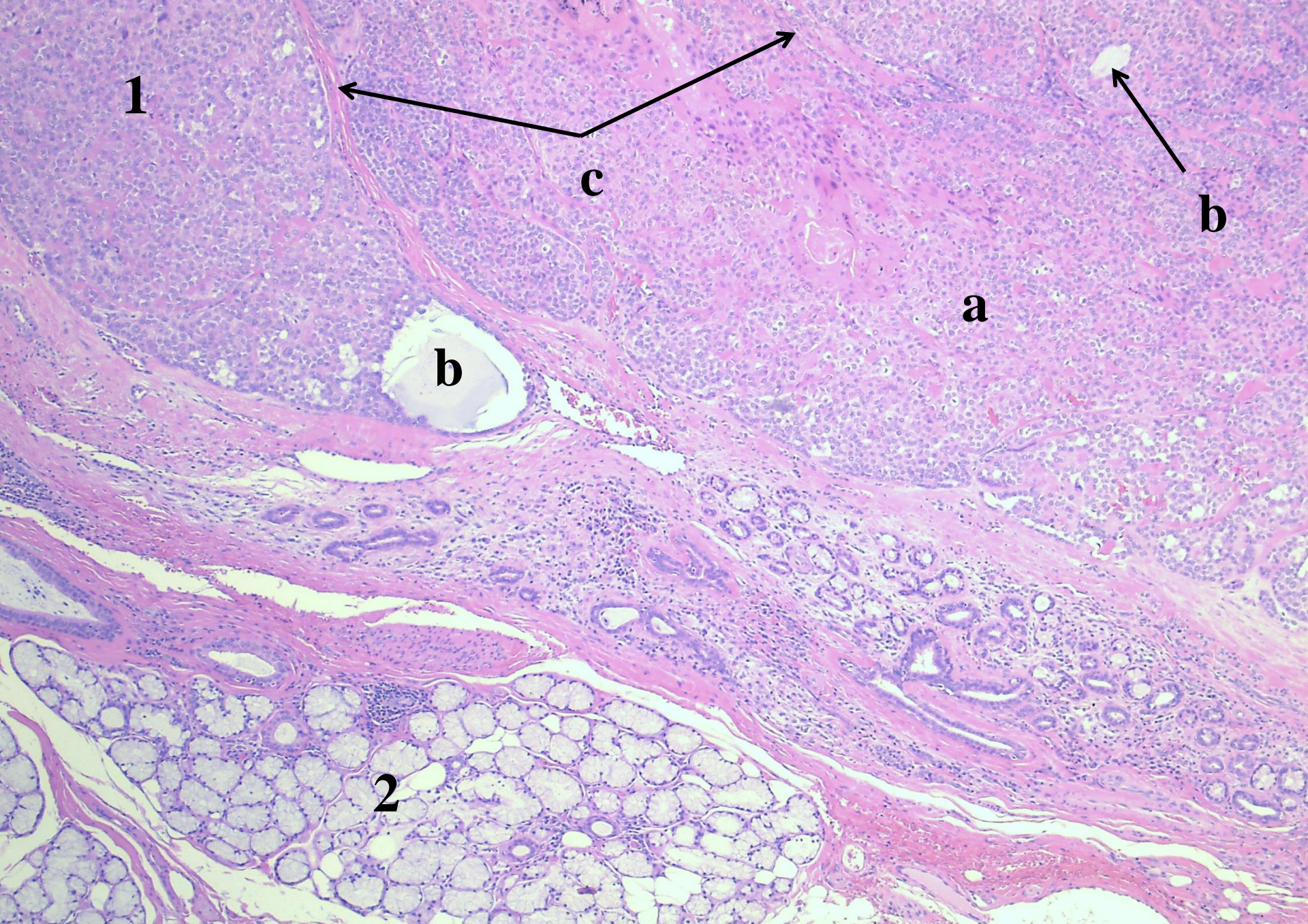
## **№ OP39. Mucoepidermoid carcinoma of the salivary gland. ( H-E. stain).**

### **Indications:**

1. Tumor node:
  - a. atypical tumor cells;
  - b. cystic cavities;
  - c. connective tissue stroma.
2. Unchanged glandular tissue.

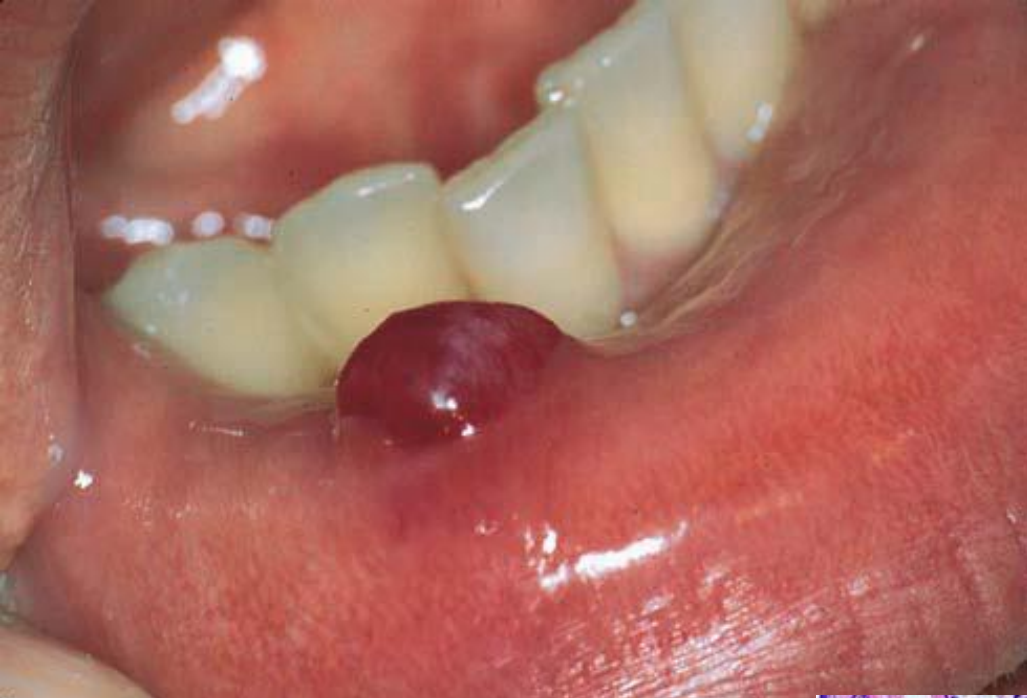Microscopically, mucoepidermoid carcinoma is actually a mixed, squamous cell carcinoma (squamous) and mucosecretory. Mucous cells are neoplastic cells, which vary in size, with abundant foamy cytoplasm, which contains mucin. Often mucin is evident only with special colors (blue-alcian or mucicarmine Mayer). The epidermoid cells are polygonal, with eosinophilic cytoplasm and round, vesicular nuclei. These cells do not form keratin beads. Between the two types of cells there is also the third type of intermediate cells, considered precursor cells of mucosal and epidermoid cells. The three types of cells can be arranged in the form of cystic plaques or cavities. Mucoepidermoid carcinoma is graded according to the proportion of cystic structures, cell atypia, the presence of perineural invasion, necrosis and the number of mitoses. According to these parameters, three degrees of malignancy are obtained: mucoepidermoid carcinoma with a low degree of malignancy (with a high number of cysts, minimal cell atypia and a large number of mucous cells), with a high degree of malignancy (predominantly consisting of solid areas, with rare mucous cells, with pleomorphism and numerous mitotic figures), and with an intermediate degree of malignancy (with features characteristic of both low- and high-grade tumors).

*Macroscopically, mucoepidermoid carcinomas are sometimes circumscribed and only partially encapsulated, except for tumors with a high degree of malignancy. On the section surface are yellowish, firm gray tumors. Cysts, with various shapes and sizes, with a viscous or hemorrhagic content, are frequently observed. The diameter of the tumor varies between 1 and 12 centimeters.*

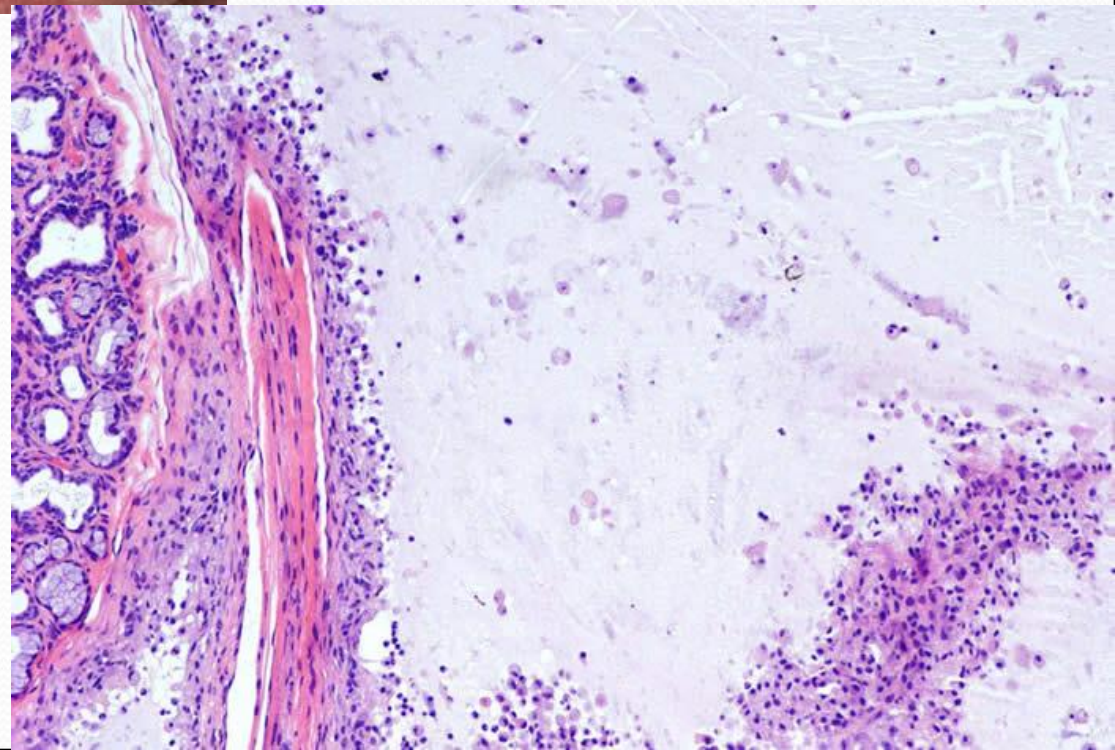


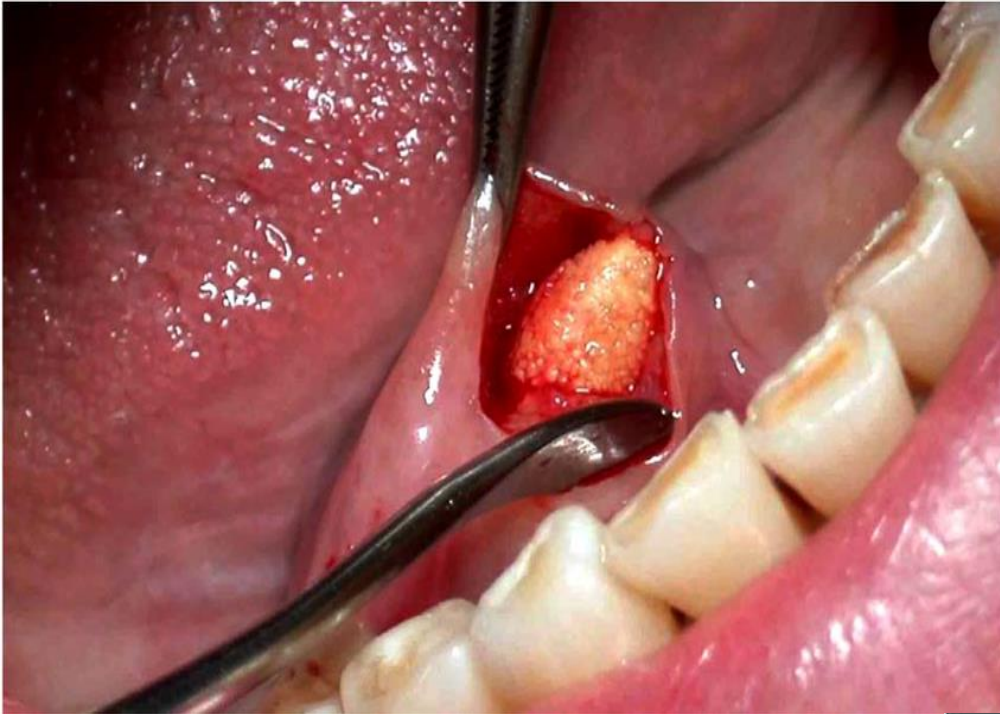**№ OP39. Mucoepidermoid carcinoma of the salivary gland. ( H-E. stain).**

# Salivary cysts.

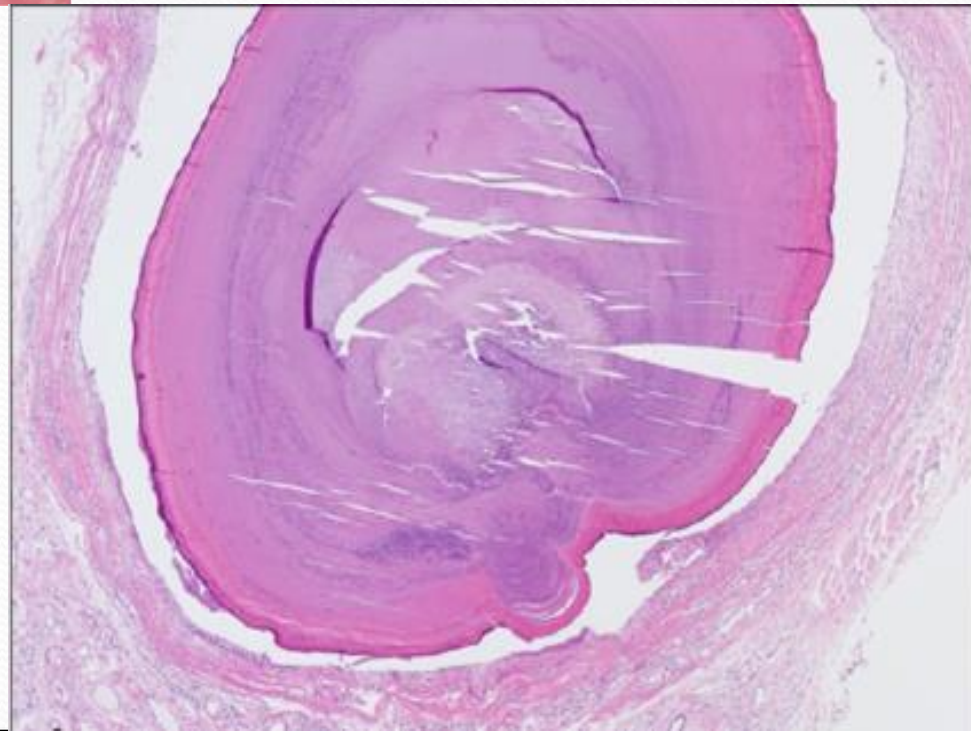


**Mucocele of the salivary gland.**

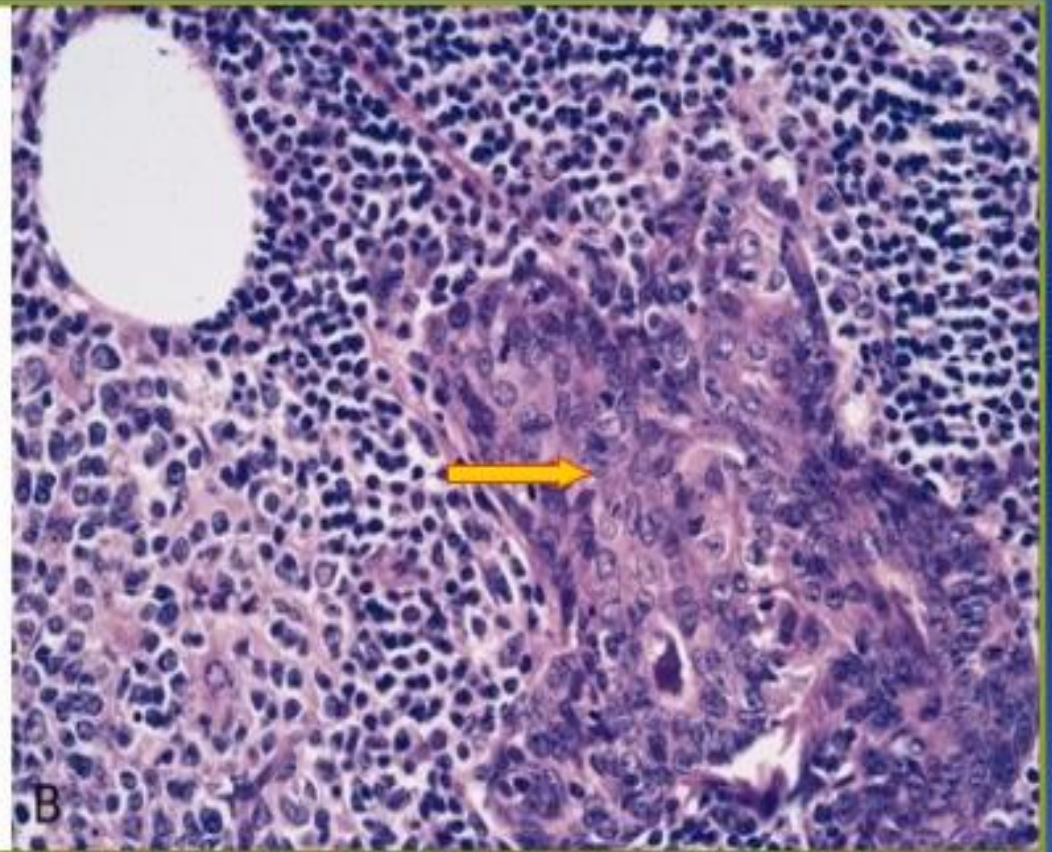
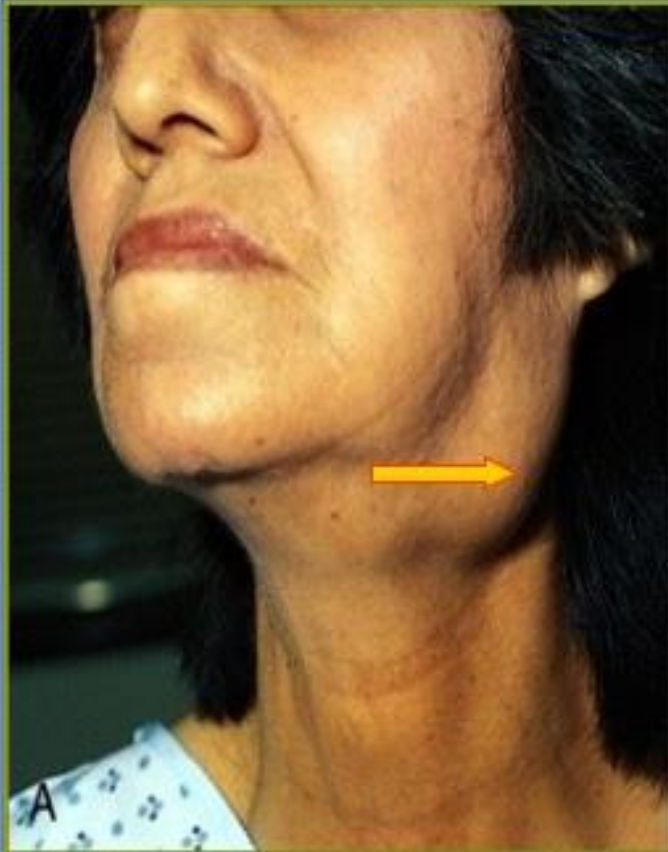



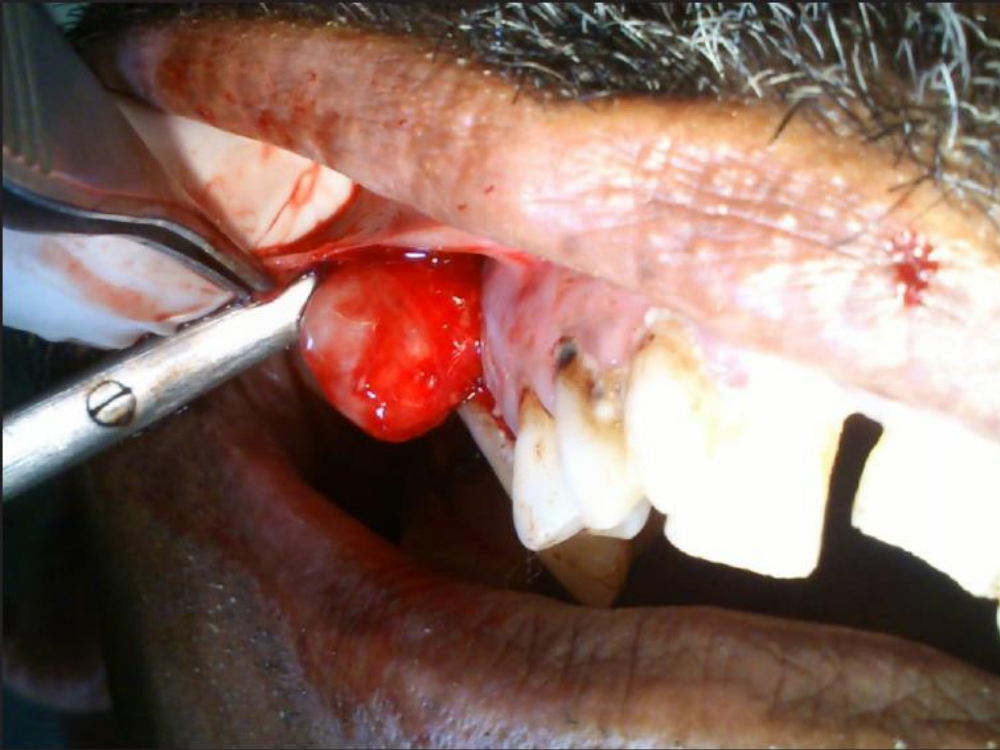
**Salivary lithiasis (sialolithiasis).**



# Sjogren's syndrome

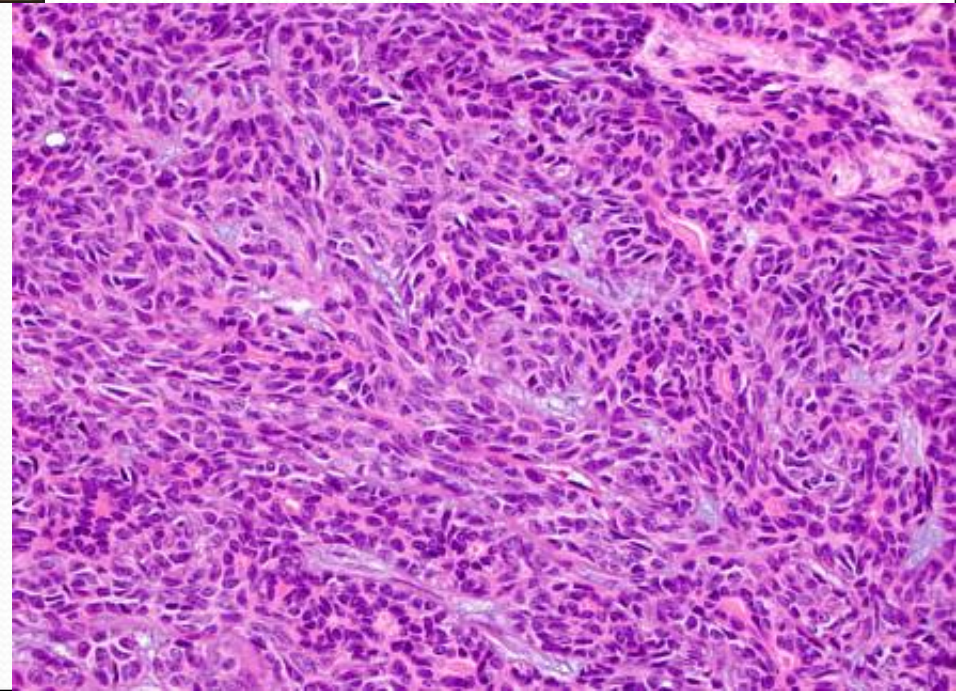


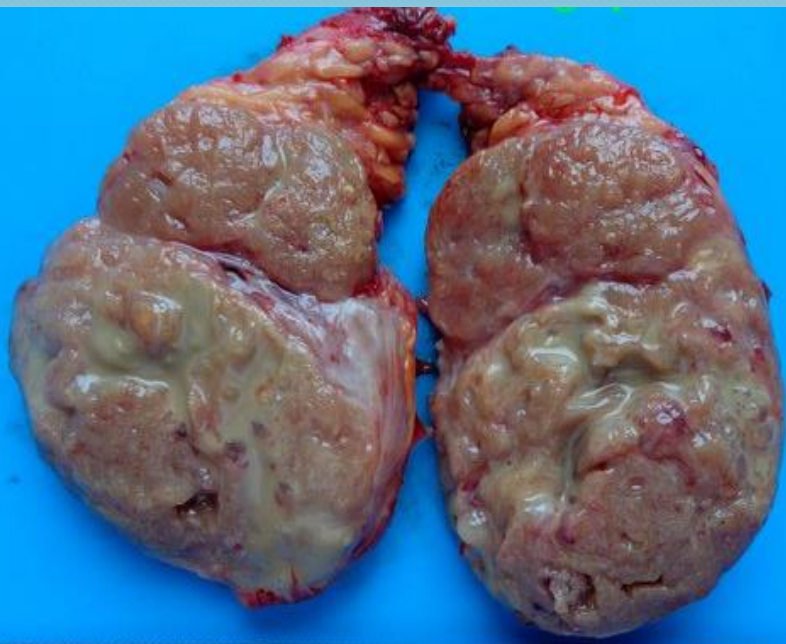Intense lymphoplasmacytic infiltrate with ductal epithelial hyperplasia



**Monomorphic basaloid cells with minimal atypia and lack of mitotic activity.**

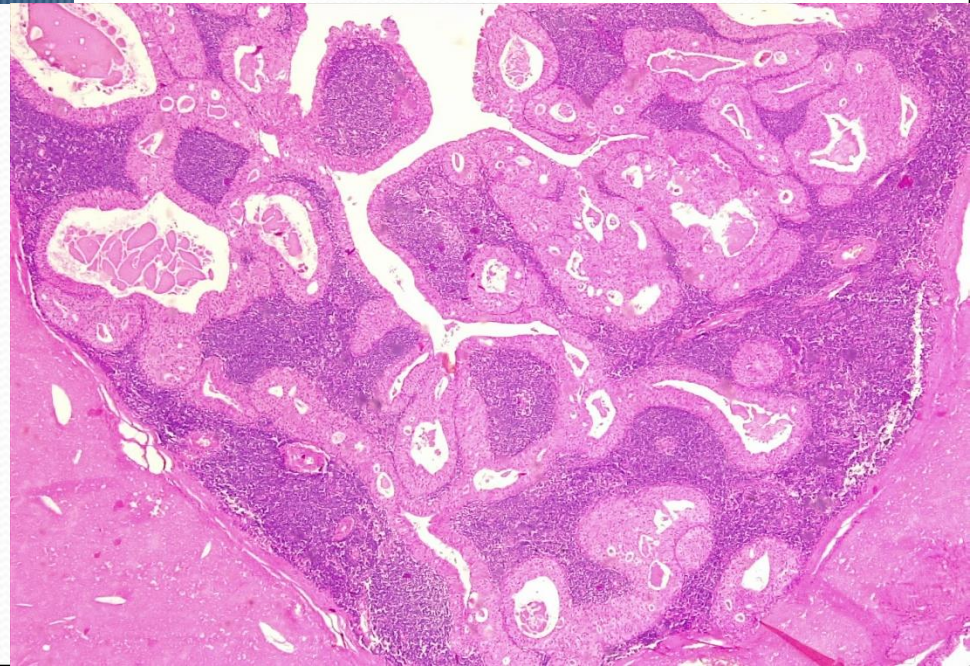
**Monomorphic adenoma of the salivary gland. (basal cell type).**





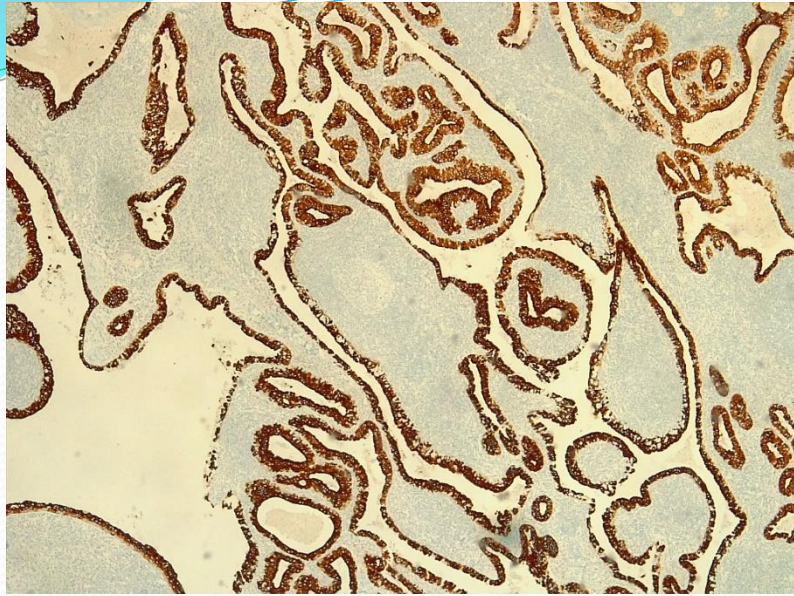
**Papillary formations lined with columnar cells surrounding the stroma abundantly infiltrated with lymphocytes, which form follicles.**

**Adenolymphoma (Warthin's tumor)  
of the parotid gland.**

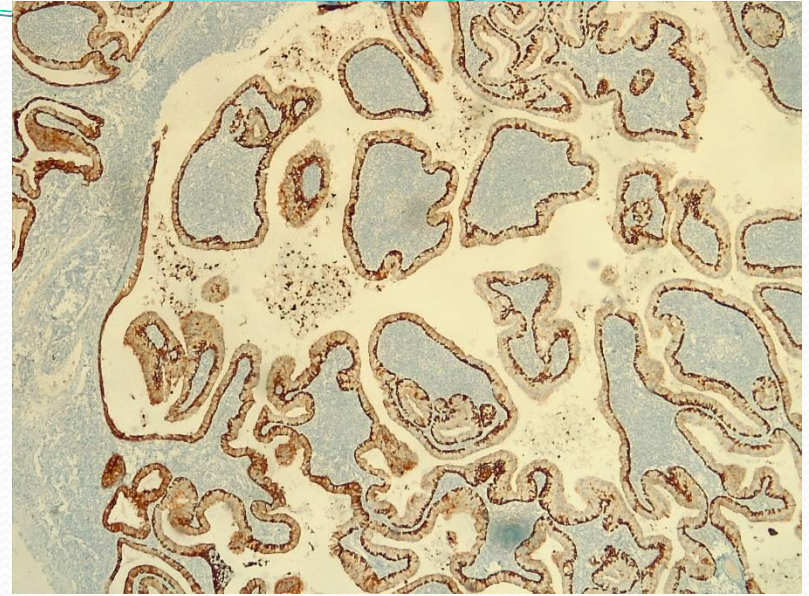




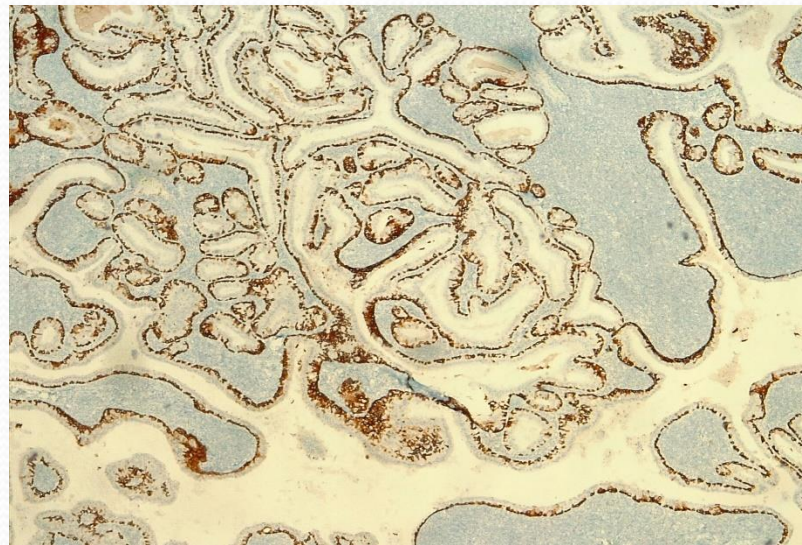
# Adenolymphoma (Warthin's tumor) of the parotid gland, IHC tests.



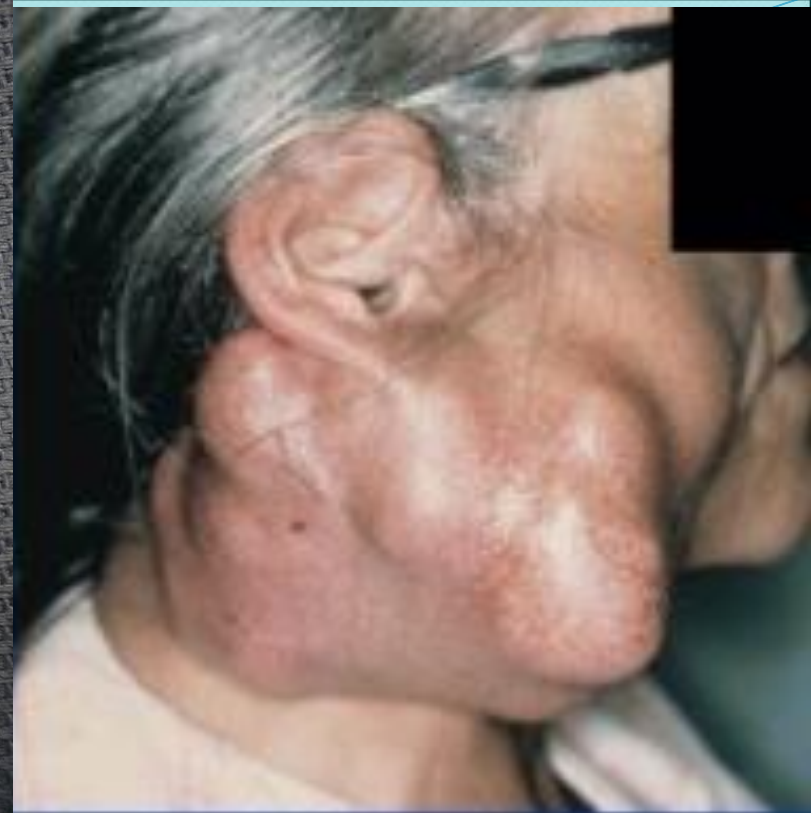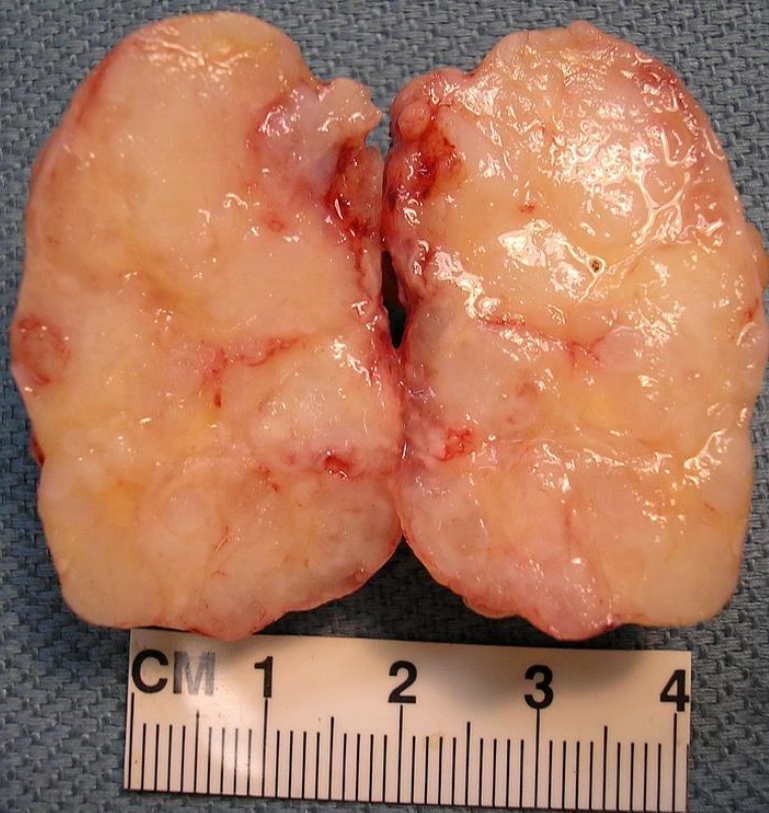**CK7 (cytoplasmic positive in basal epithelium)**



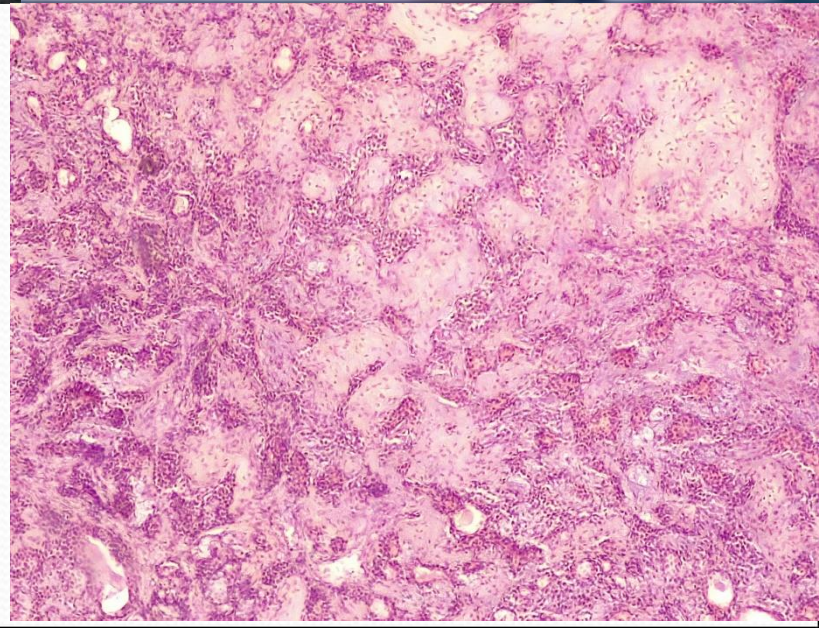
**CK34 BE12 (cytoplasmic positive in basal epithelium)**

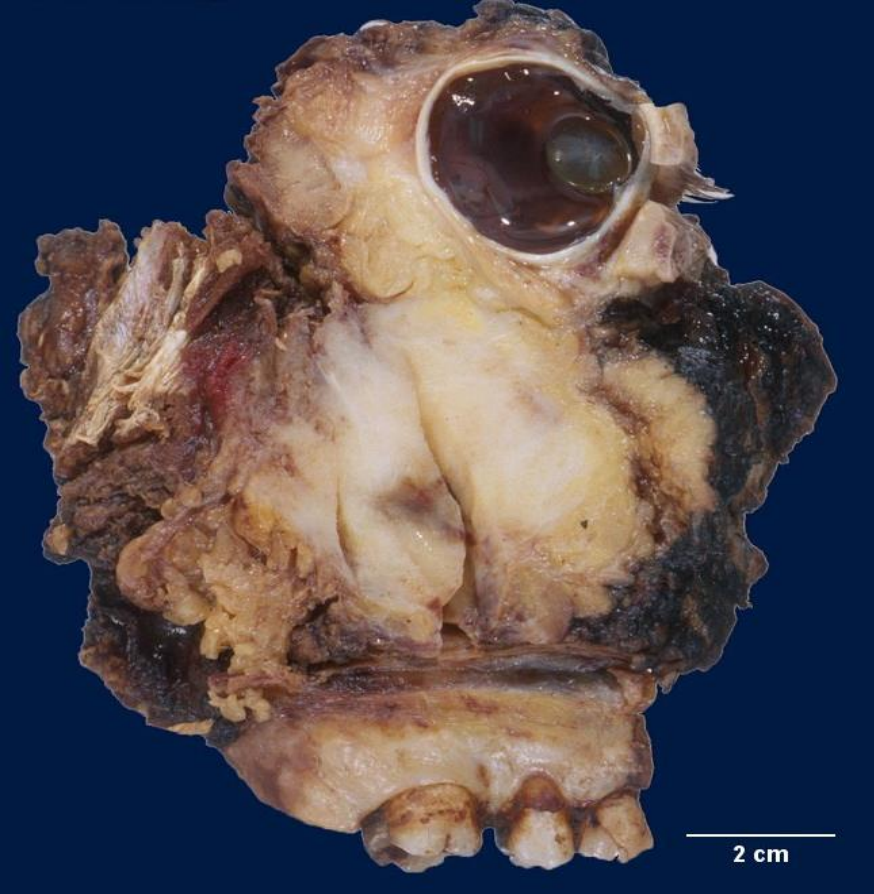


**CK5/6 (cytoplasmic positive in basal epithelium)**

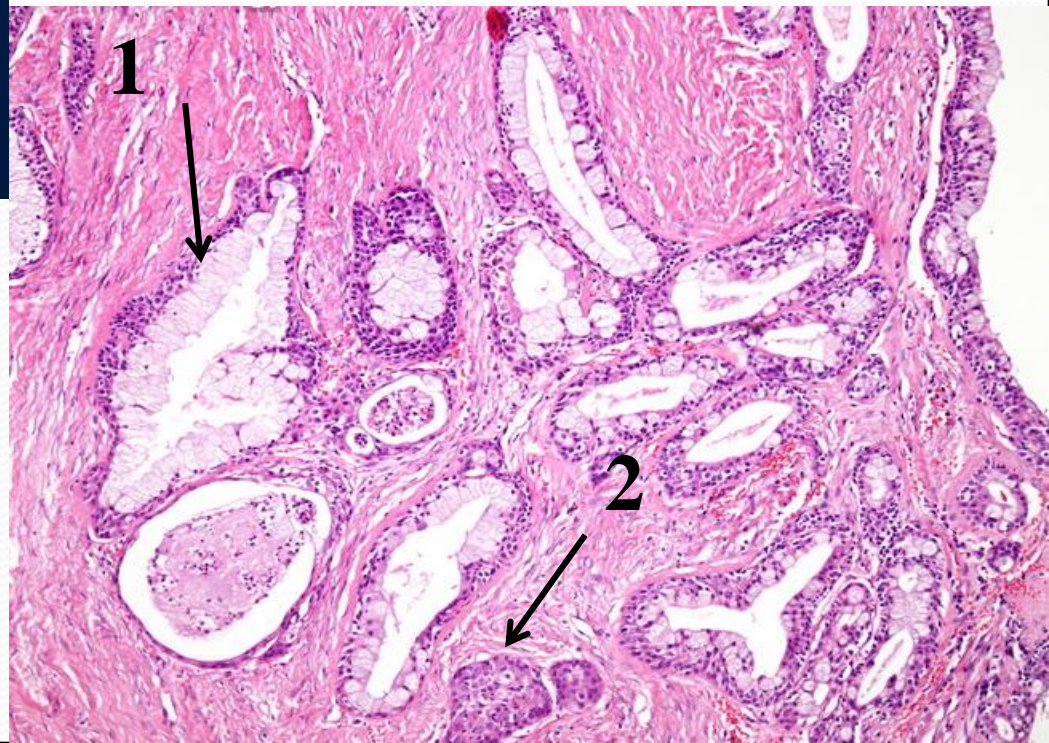


**Pleomorphic adenoma of the salivary gland.**

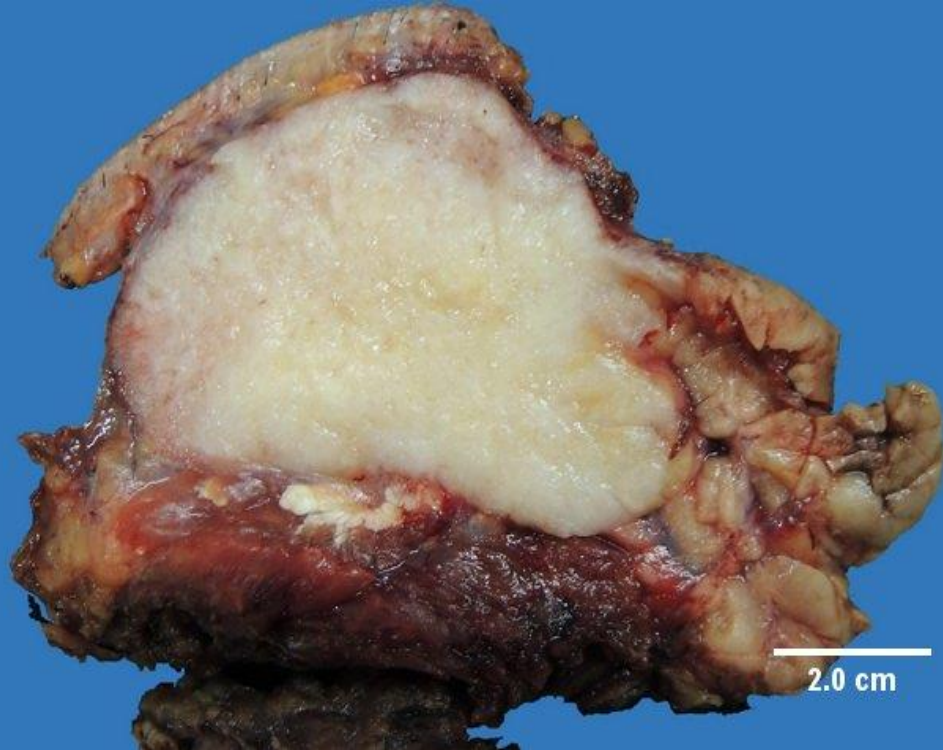



1. Mucinous cells with foamy cytoplasm and small nuclei arranged at the periphery.
2. Solid nests of epidermoid cells.

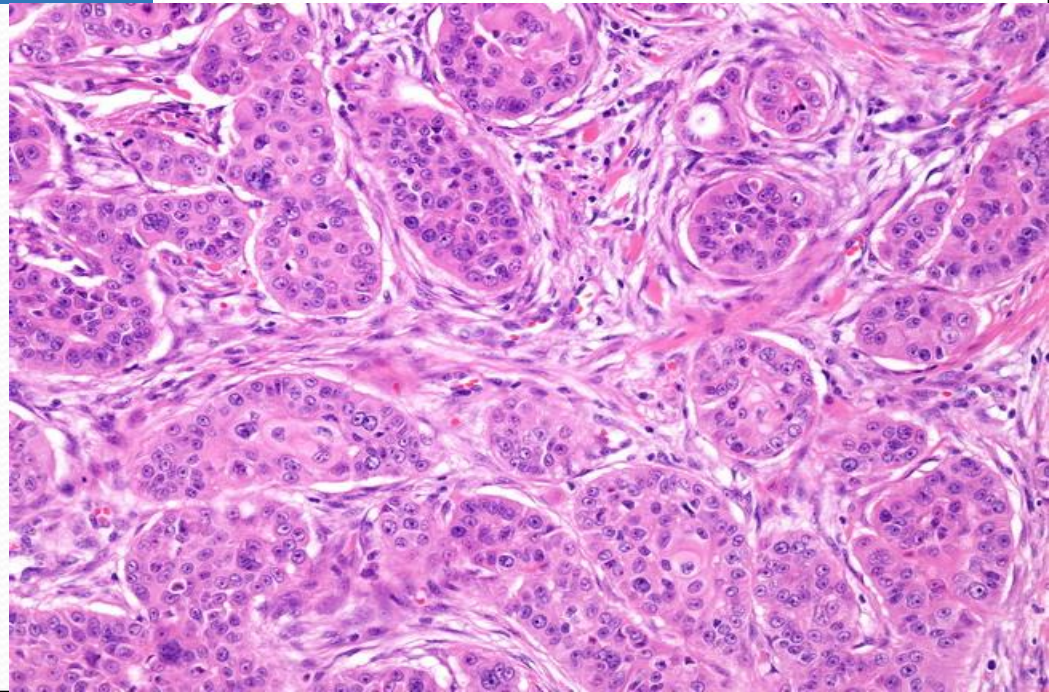


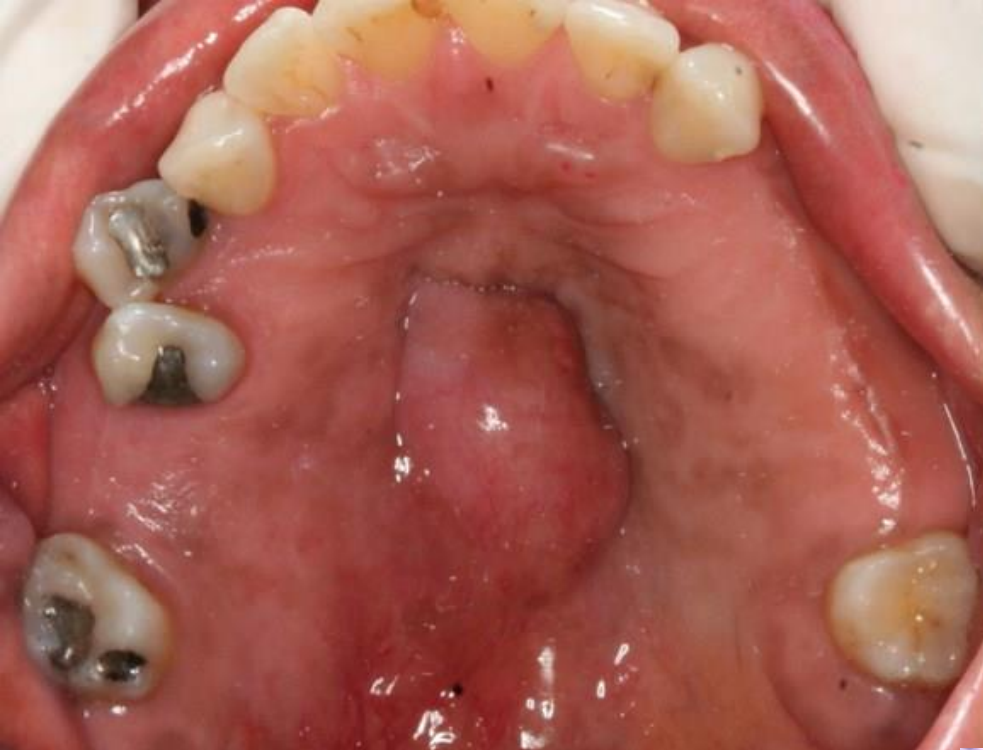**Mucoepidermoid carcinoma of the parotid gland. (low grade). It forms cysts.**



**Squamous cell nests with cellular atypia, keratinization with keratin pearls formation is not characteristic. The presence of single mucinous cells is determined by histochemical staining for mucins.**

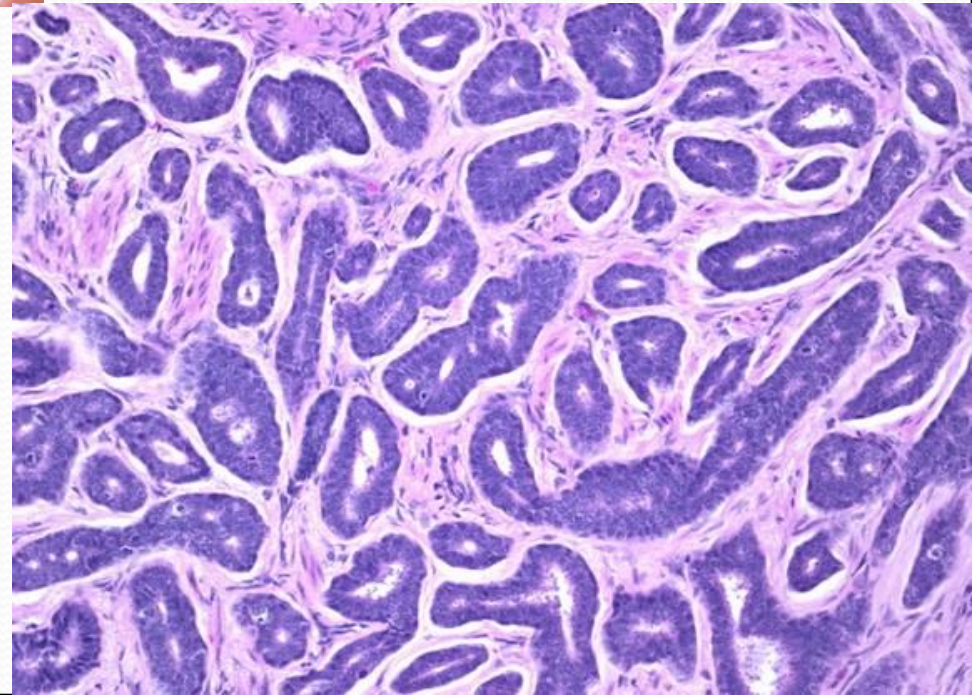
**Mucoepidermoid carcinoma of the parotid gland. (high grade). Solid tumor does not form cysts.**

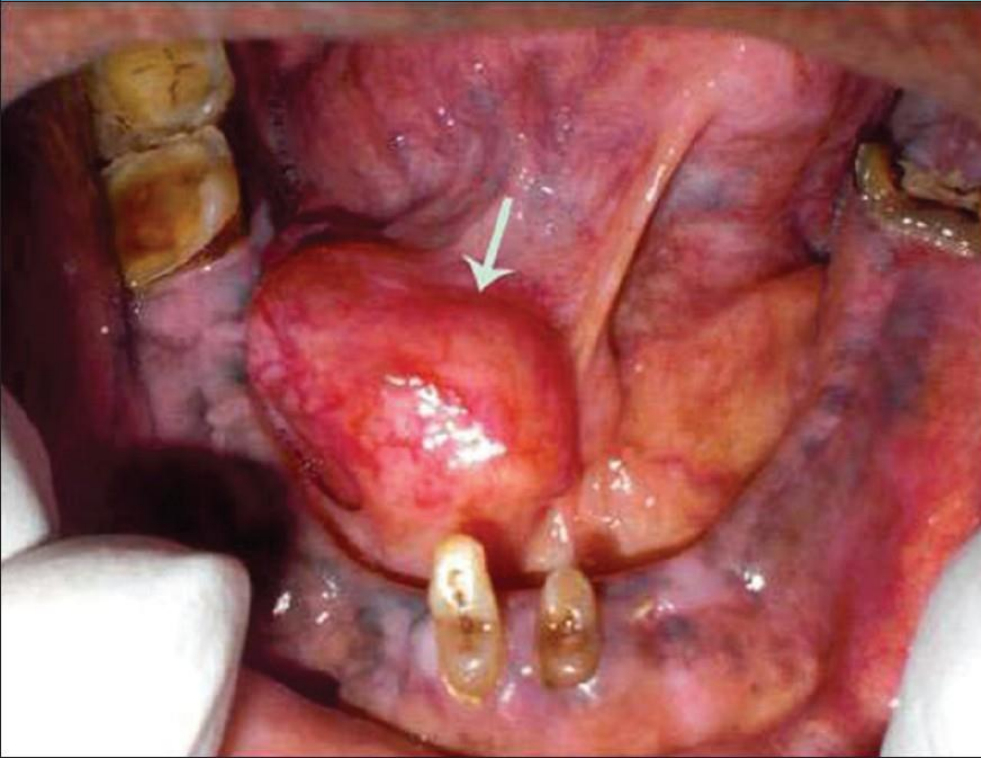



**Epithelial and myoepithelial cells arranged in a tubular pattern.**

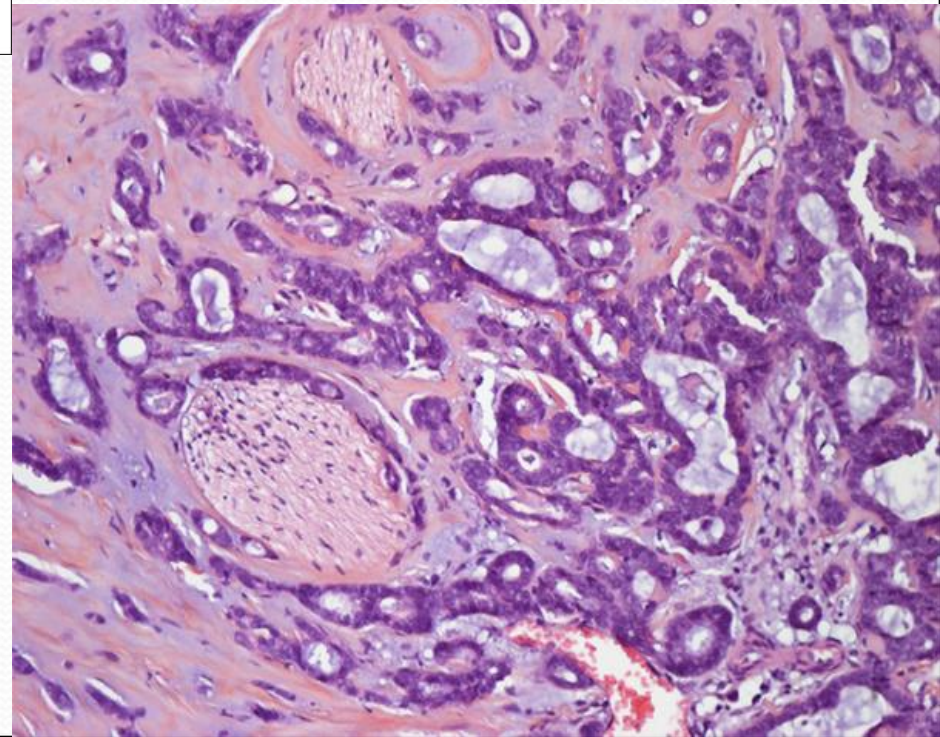
**Adenoid cystic carcinoma  
of the salivary gland.**





**Epithelial and myoepithelial  
cells arranged in a solid  
pattern.**

**Adenoid cystic carcinoma  
of the salivary gland. Solid pattern.**



# Salivary Gland Lesions

---

- Obstructive – retention
  - Sialolithiasis
  - The phenomenon of extravasation of mucus
    - Mucocele
    - Retention mucosal cyst
- Infectious
  - Viral
  - Bacterial
- Immunological
  - sarcoidosis
  - Sjögren's syndrome
- Tumors
  - benign
  - malignant

# Sialolithiasis

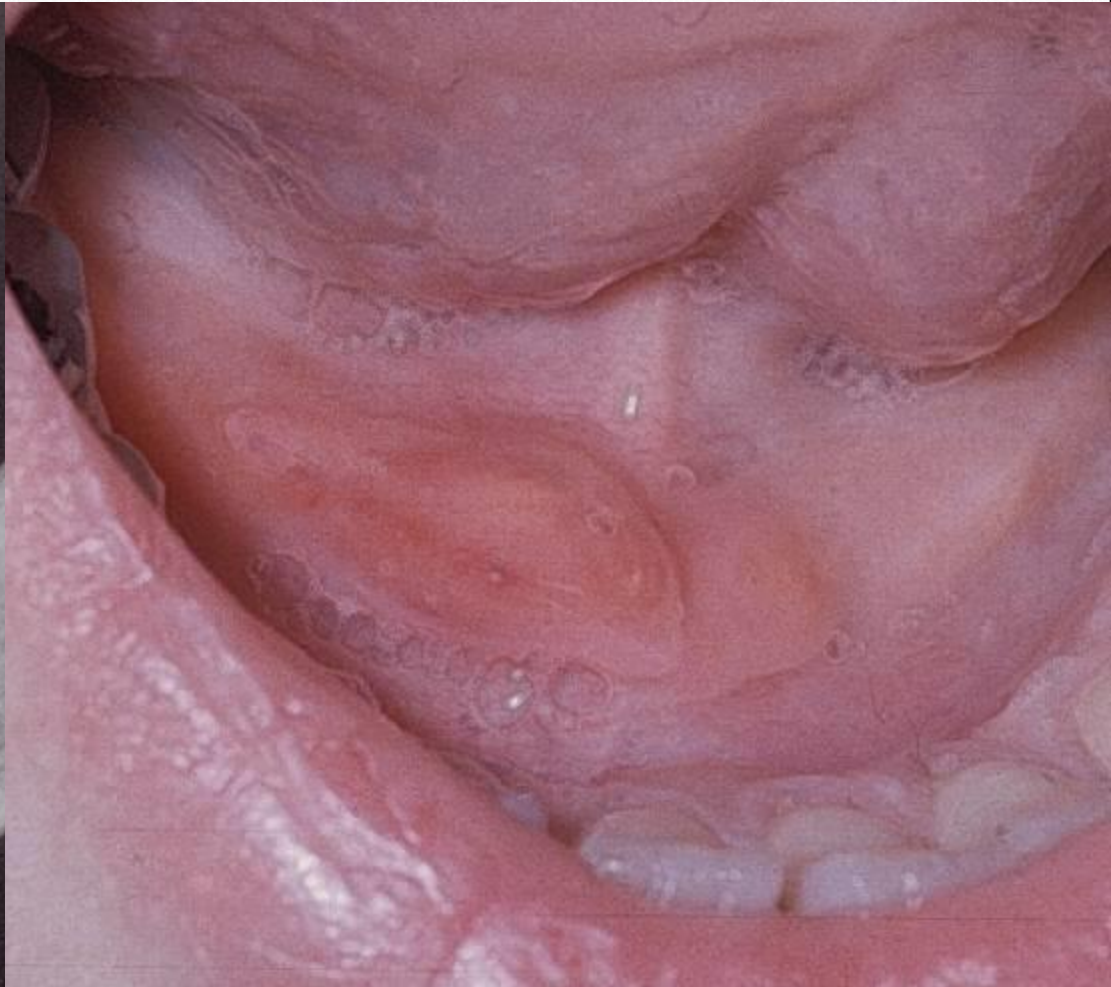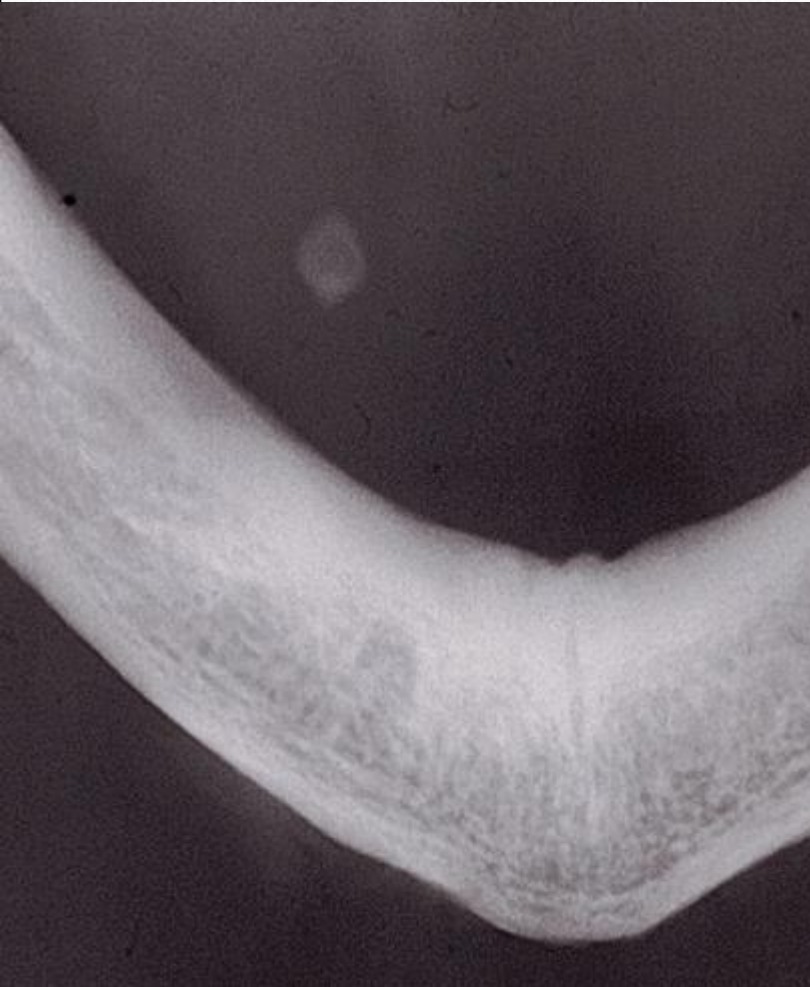
- Formation in the gland, more often in its ducts of concrements

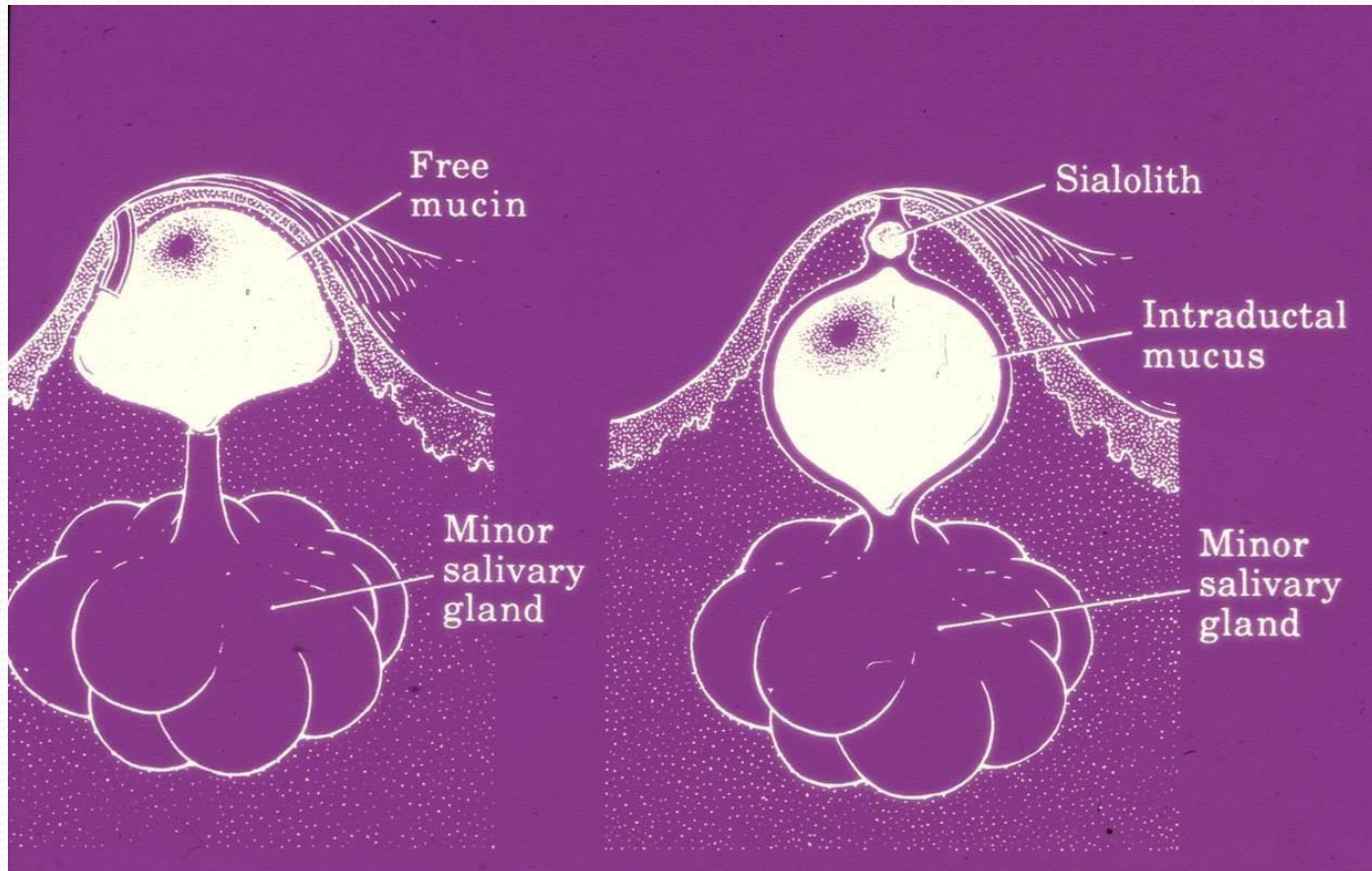
Among the local causes in the formation of concrements:

- Hypoplasia, saliva stagnation, alkalization, inflammation of the ducts.
- Stagnation of saliva contributes to the formation of stones by the deposition of superconcentrated salts on an organic basis - the matrix (desquamated cells, microbes).



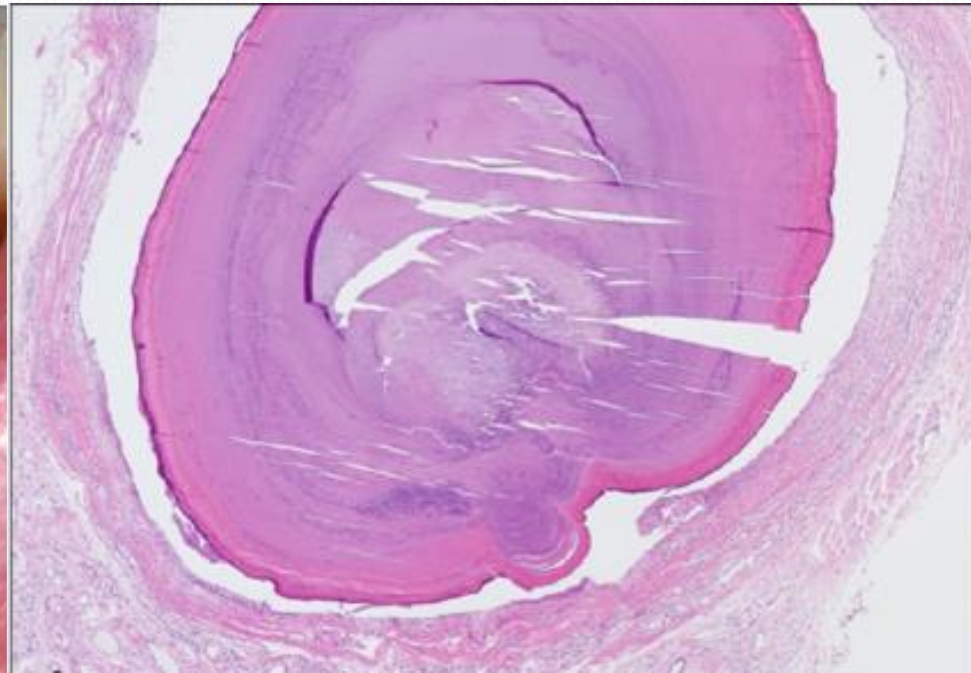
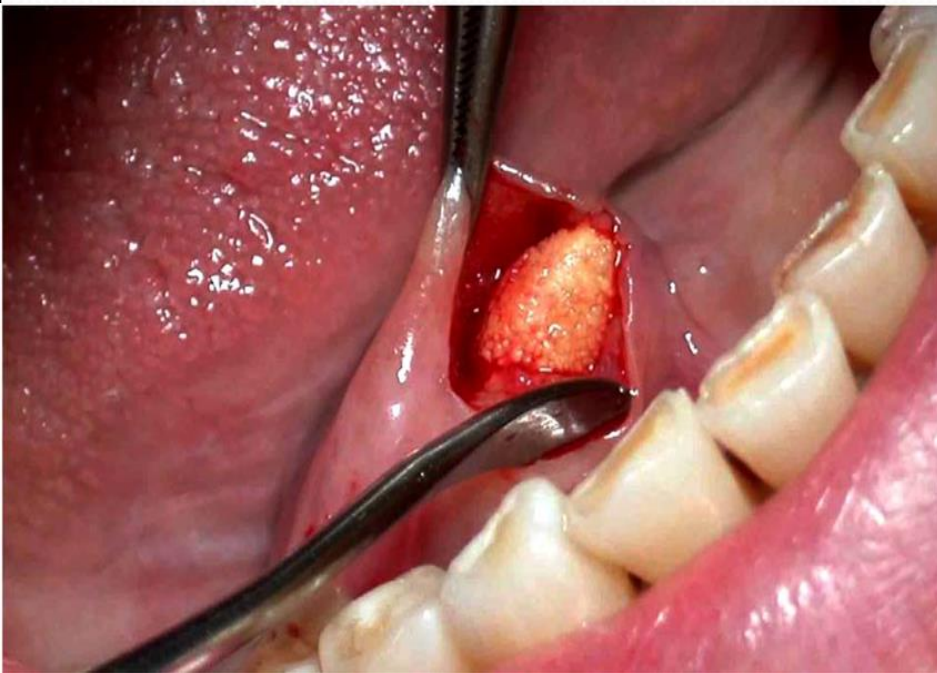# Sialolith in the anterior region of the buccal floor





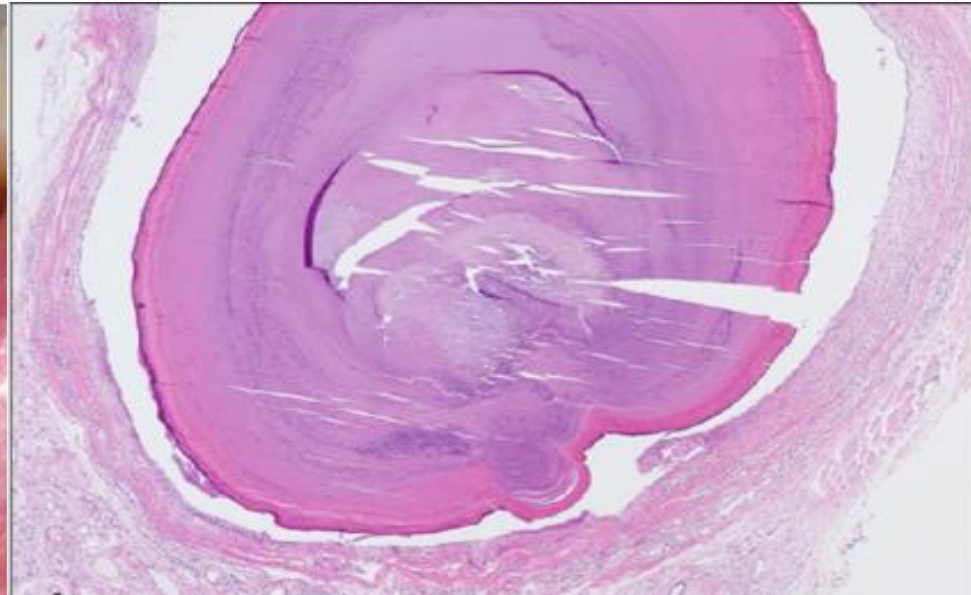
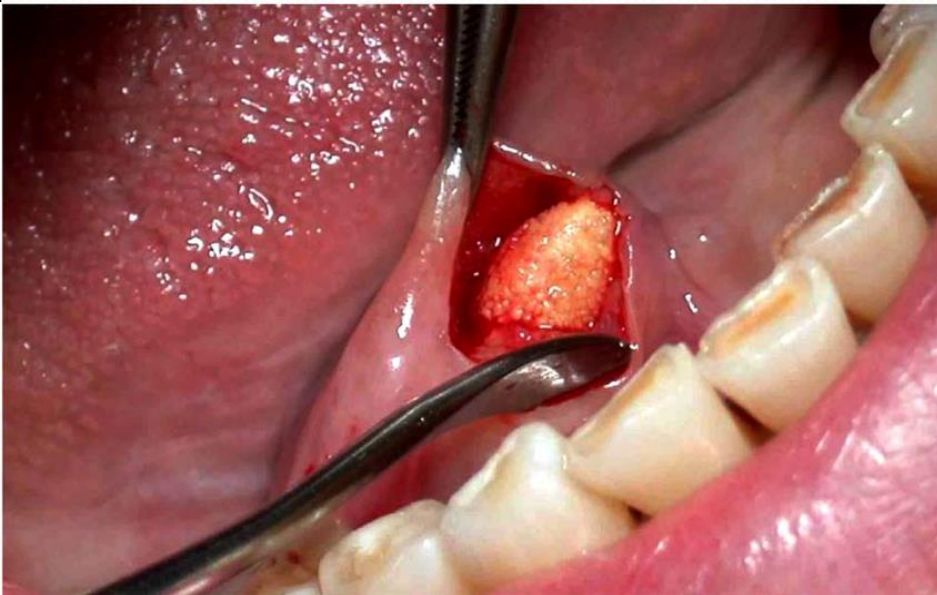
# Sialolithiasis

- Salivary concretions are more common in the external excretory duct of the submandibular glands (83%) and less common in the stensen canal (10%) or in the sublingual glands (7%).
- They are usually small, up to 1-2 cm in diameter, oval or round, with a smooth or rough surface, whitish-gray, yellow or red.



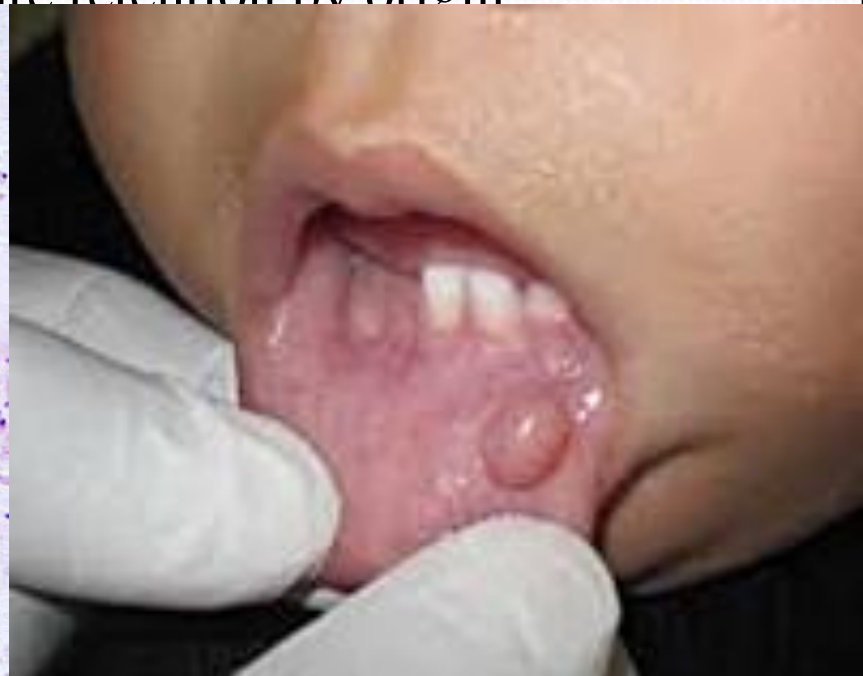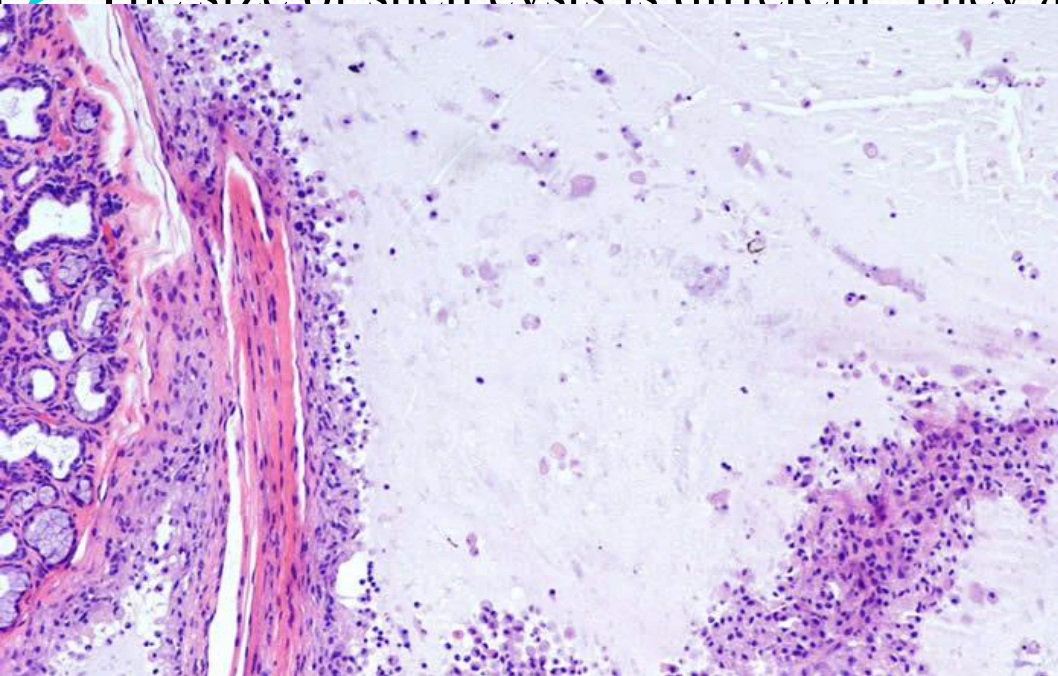
# Sialolithiasis

- Concrements consist of mineral salts, calcium phosphate (60-70%), calcium carbonate (5-10%) and organic substances (mucopolysaccharides, cholesterol, uric acid, epithelial cells, bacteria).
- It causes the expansion of the ducts with squamous metaplasia of their epithelium.
- Diffuse and peripheral fibrosis, atrophy of the secretory acini is observed in the gland tissue.
- Sialolithiasis is often combined with the inflammatory process (sialadenitis).



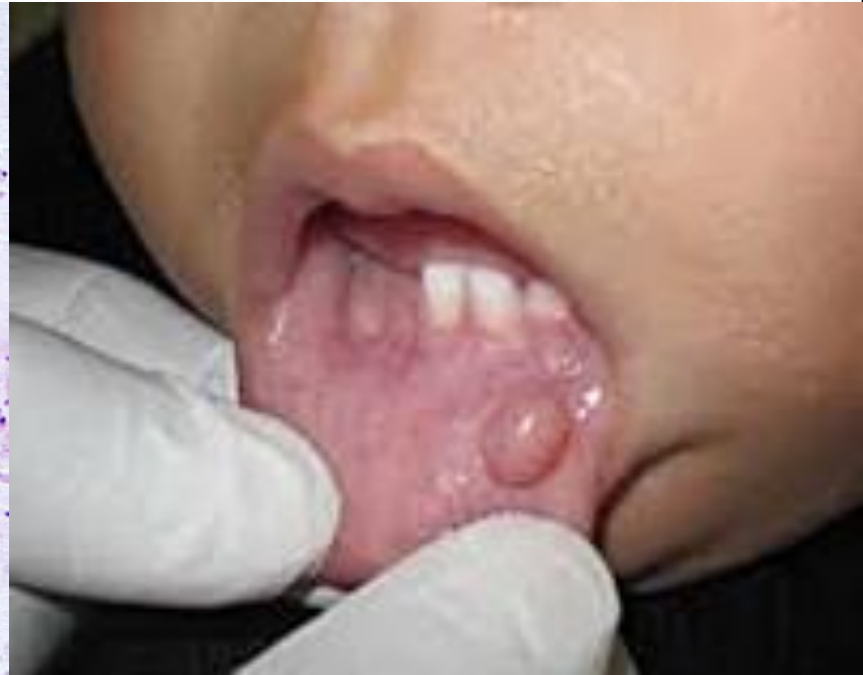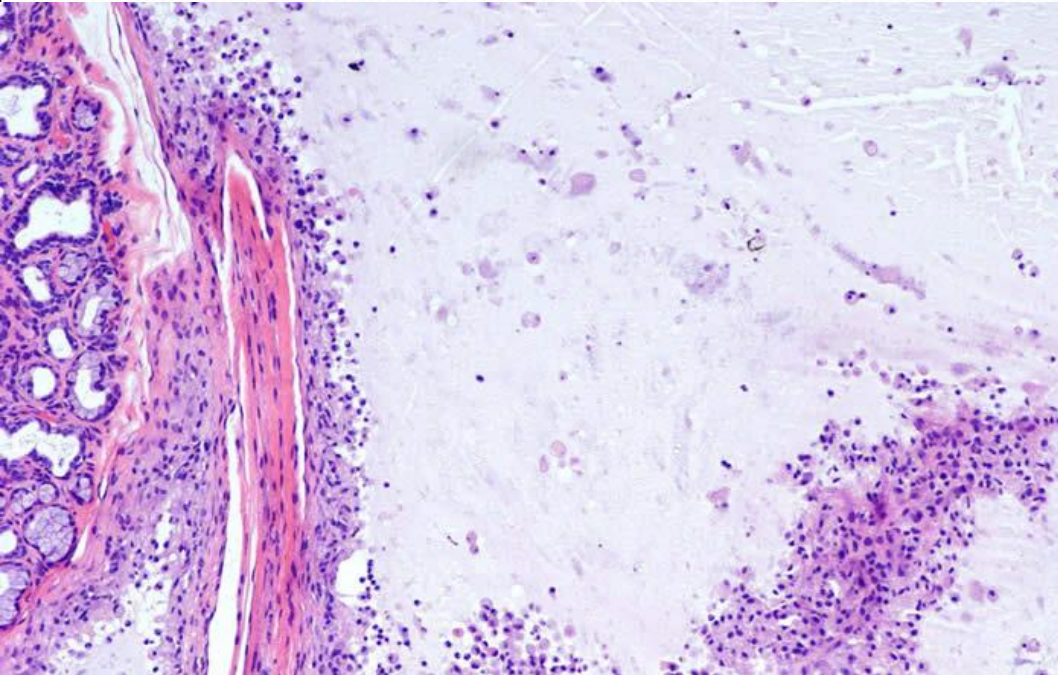
# Mucocele

- It develops from the excretory ducts of the small glands, less often from the large ones.
- Cysts form after the external excretory canal is blocked by the inflammatory process or after trauma.
- The size of such cysts is different. They are retention by origin.

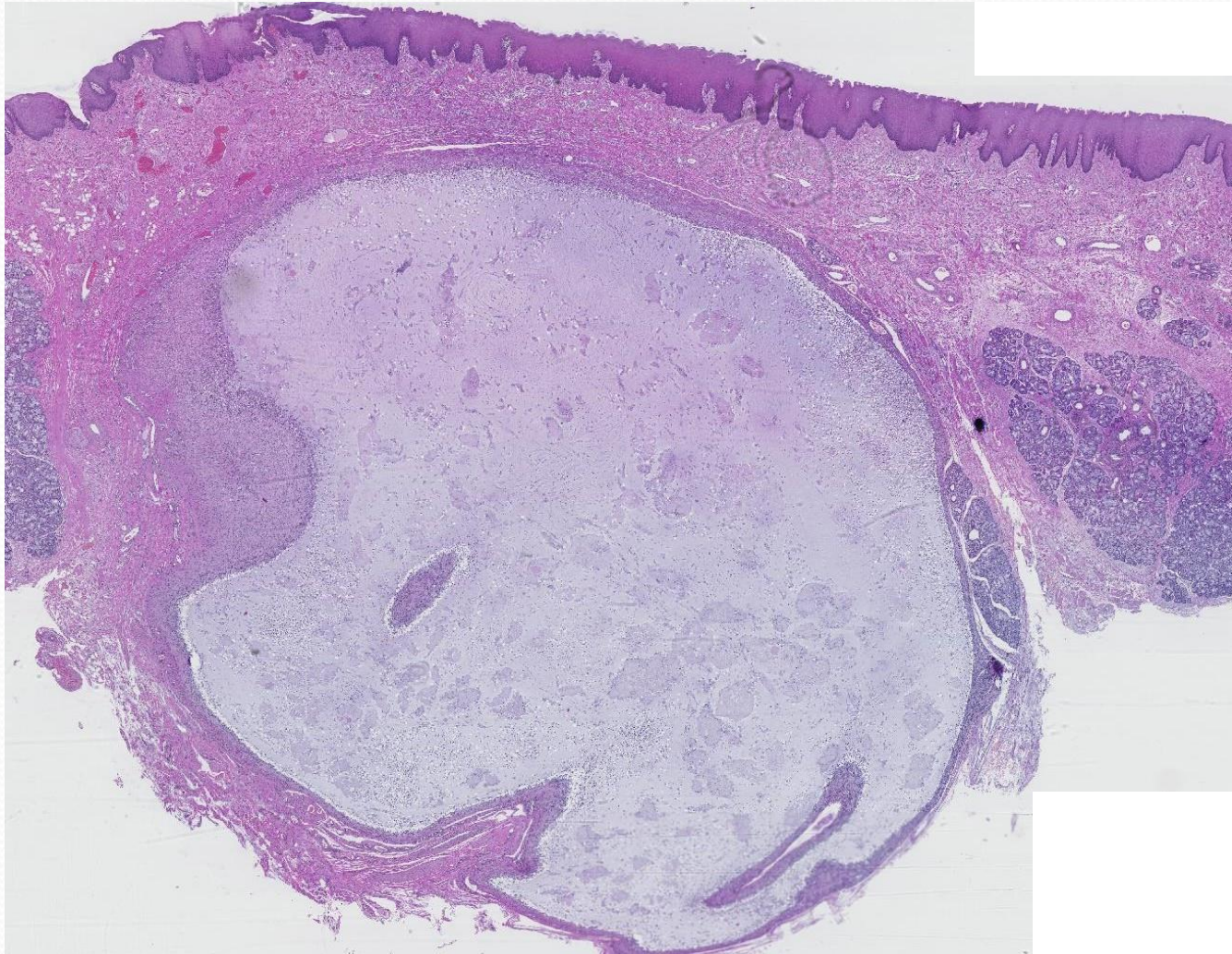


# Mucocele

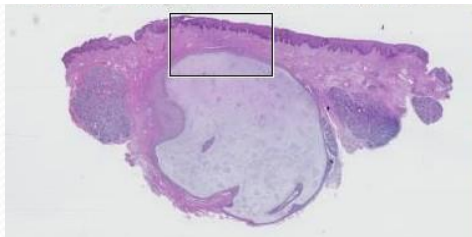
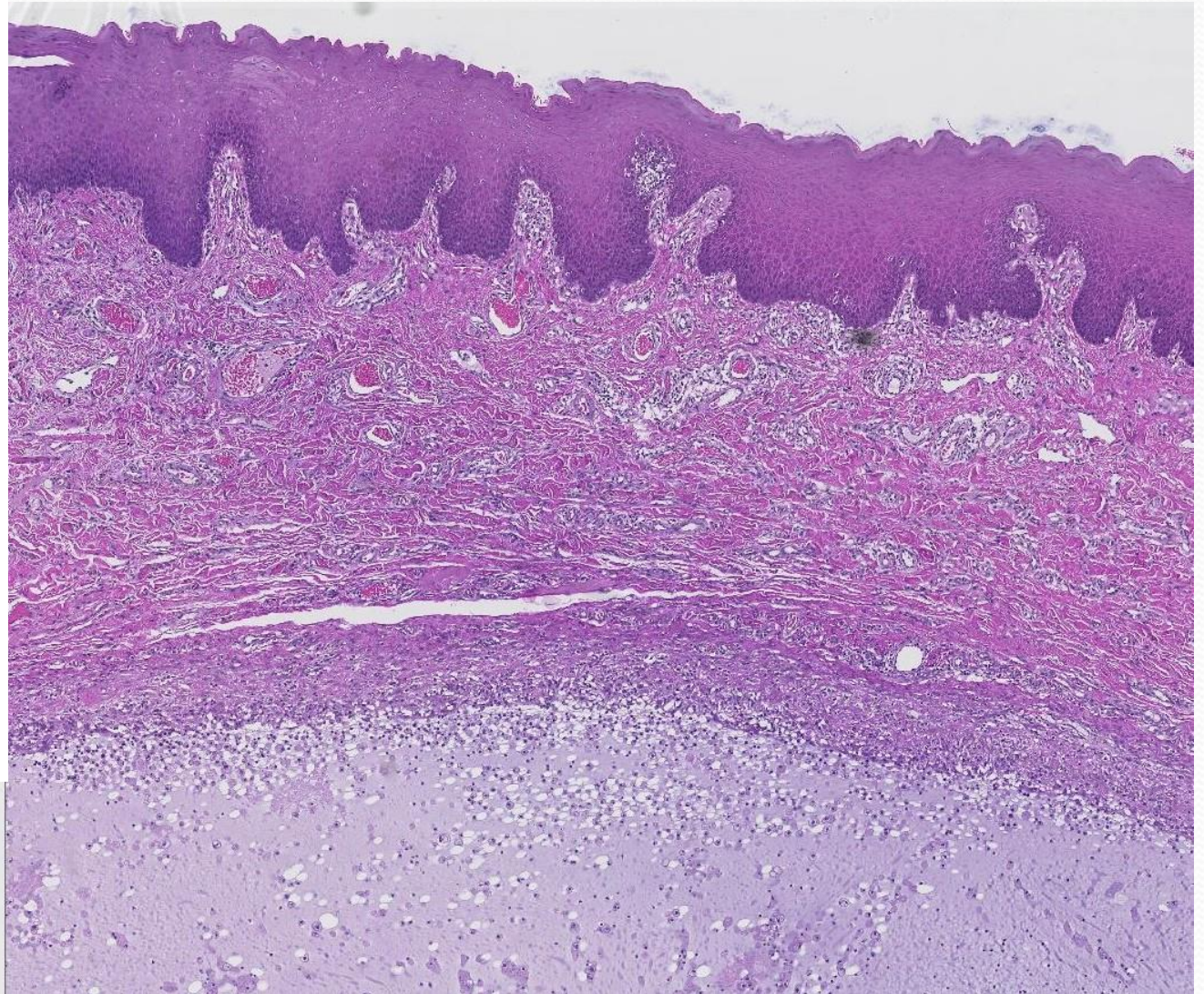
- The mucocele is often located on the lower lip in the form of a spherical node that protrudes above the surface.
- Microscopically, the inner surface of its wall is lined with cylindrical epithelium.



# Microscopic image of mucocoele

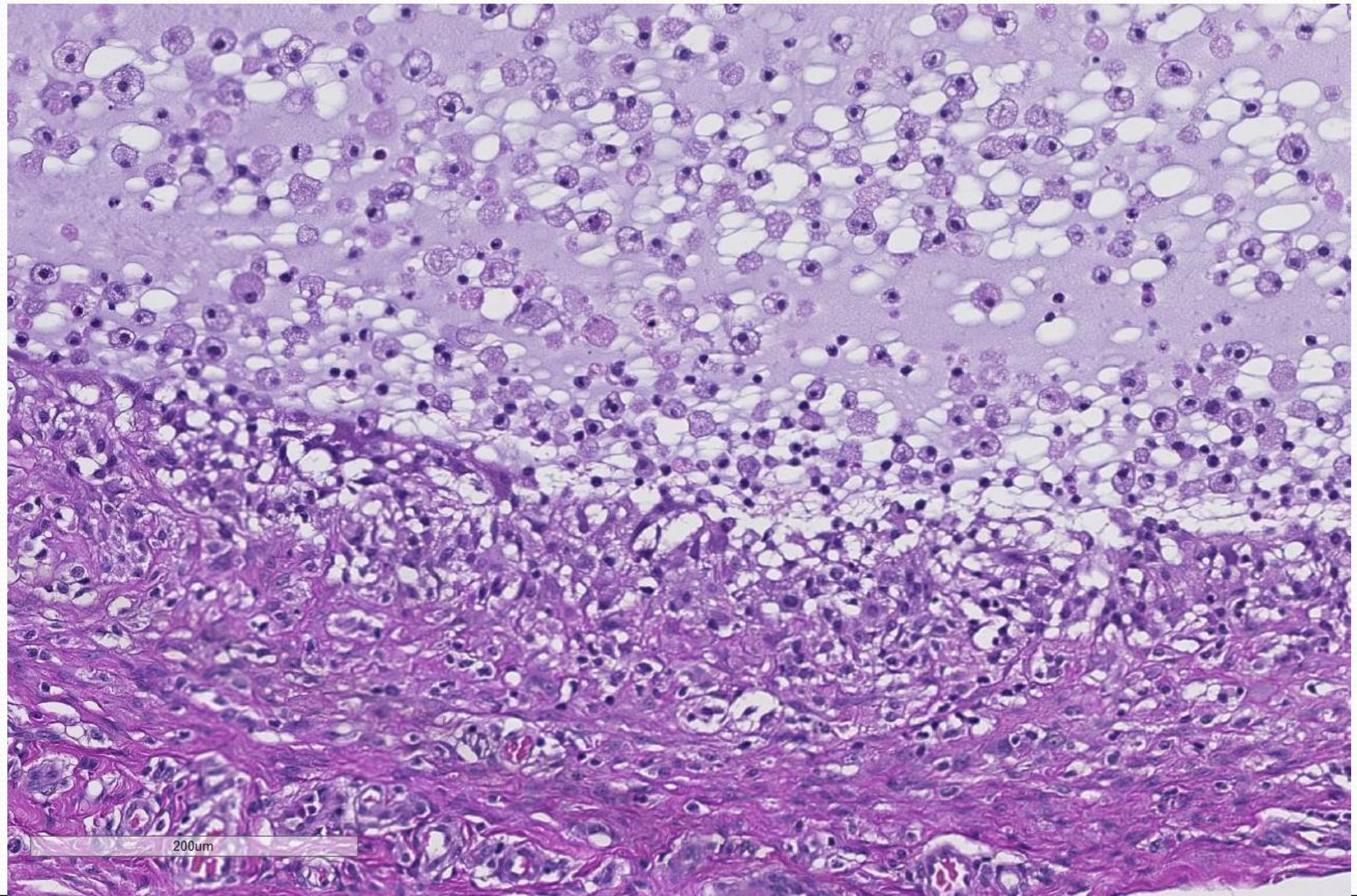


# Microscopic image of mucocoele

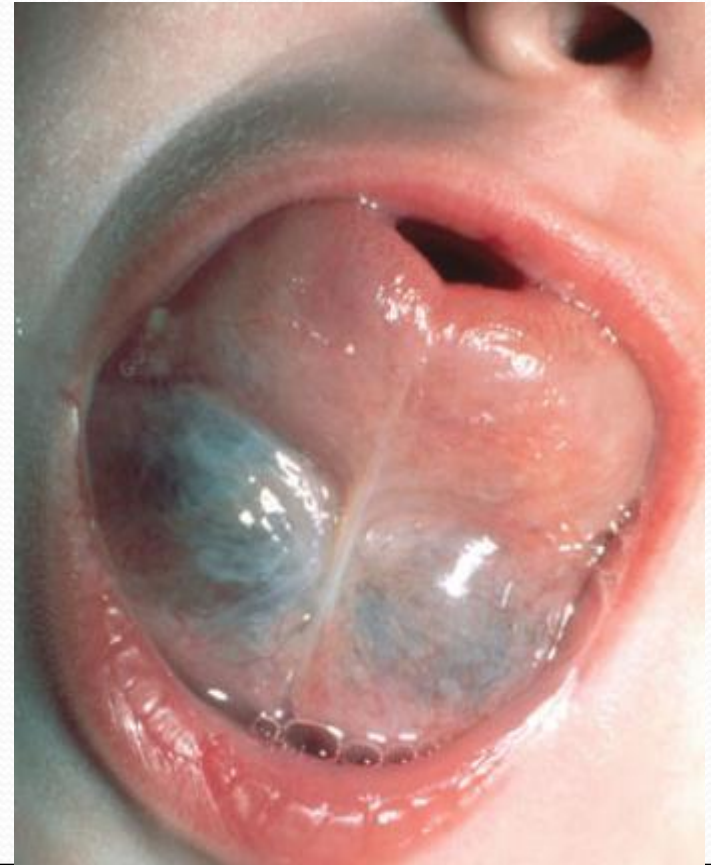
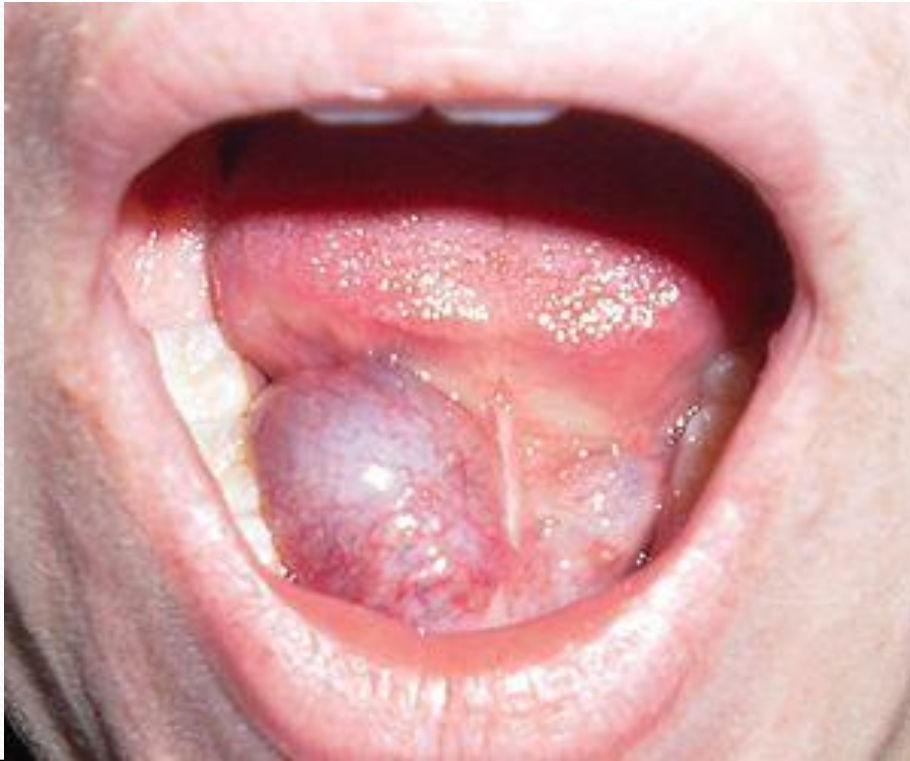


# Microscopic image of mucocele

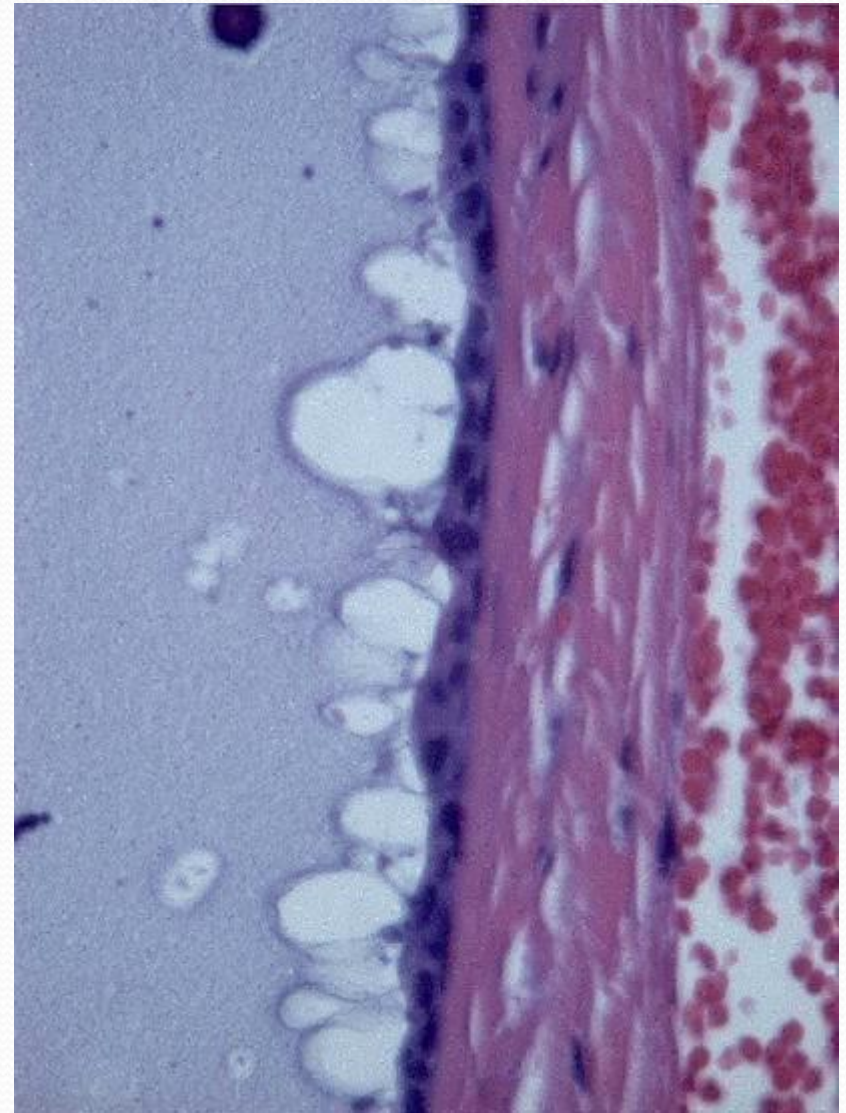
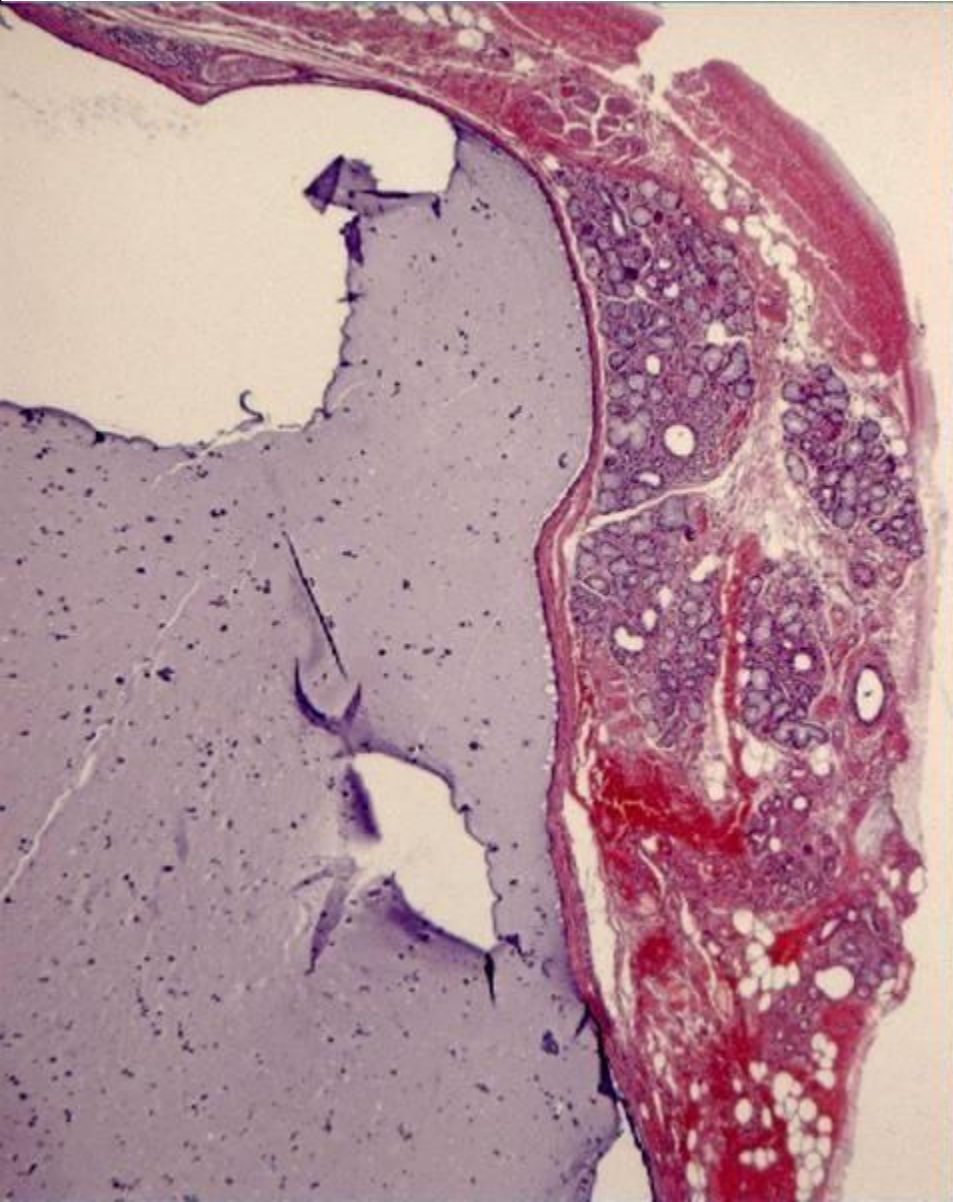


- *Ranula (retention cyst)* of the sublingual salivary gland. Sometimes, ranula extends under the buccal diaphragm muscle - submandibular variant.
- Macroscopically, it is a cystic cavity with a thin, bluish wall, associated with the salivary gland, it contains mucus. The cyst raises the tongue, making it difficult to move.
- Microscopically, the inner surface of the wall is represented by a layered squamous epithelium.



# Retention mucosal cyst

40x



## **Inflammation of the salivary glands (sialadenitis)**

Acute and chronic inflammation can develop in the salivary glands.

*Sialadenitis* rarely primary, secondary infections are more common. They arise through the ducts, hematogenously or lymphogenously, or directly when the salivary glands are injured.

Lesion of the glands through the ducts occurs in various stomatitis.

## **Inflammation of the salivary glands (sialadenitis)**

The hematogenous pathway of the spread of infection can be in sepsis, viral infections with viremia.

Rarely, the infection spreads by the lymphogenous route (in otitis media, jaw osteomyelitis, purulent pulpitis, periodontitis).

## **Inflammation of the salivary glands (sialadenitis)**

Sialadenitis is caused by various non-specific bacterial flora [streptococcus, staphylococcus, typhoid bacillus, specific agents (mycobacterium tuberculosis)], viruses with tropism for saliva (viruses of mumps, cytomegaly, influenza, measles) or viruses that are secreted through the salivary glands (poliomyelitis, viral hepatitis). Very rarely there are parasitic infections.

## **Inflammation of the salivary glands (sialadenitis)**

Of the other factors that cause sialadenitis, it is necessary to note allergies (medications), ionizing radiation, trauma, foreign bodies.

The inflammatory process is often localized in the parotid gland, due to the abundance of ducts.

# Inflammation of the salivary glands (sialadenitis)

By evolution, there are acute and chronic sialadenitis.

Acute sialadenitis are divided into primary, mainly viral (mumps, CMV) and secondary (purulent, uremic, gangrenous).

*Chronic* may have a nonspecific or specific character (tuberculosis, sarcoidosis, actinomycosis).



## Acute sialadenitis.

### **Acute primary sialadenitis.**

Epidemic Parotitis (mumps) - the epidemic and contagious disease caused by the RNA virus affects children and young people.

More common bilateral lesion. Swelling of the glands combined with a decrease in secretion.

The duration of the disease is 7-10 days. The parotid glands become swollen and painful of soft consistency.

## Acute sialadenitis.

### **Acute primary sialadenitis.**

#### *Epidemic Parotitis (mumps)*

Microscopy is observed congestion and edema of interstitium. Perivascular and peripheral lymphoid-plasmacytic infiltrate is also noted in the interstitial tissue.

The epithelium of the ducts and secretory acini is in a state of hydropic dystrophy with the vacuolazation of the cytoplasm, as well as necrosis, desquamated cells are determined.

## Acute sialadenitis.

### **Acute primary sialadenitis.**

Epidemic Parotitis (mumps) sometimes is complicated by the addition of microbial superinfection with the development of salivary abscesses.

More often, as a result of viremia, complications such as pancreatitis and orchitis with azoospermia occur.

Pancreatic lesion can lead to diabetes.

Of the rare complications, aseptic meningitis and meningoencephalitis, oophoritis and thyroiditis should be noted.

## Acute sialadenitis.

### **Acute primary sialadenitis.**

*Cytomegaly* – a viral infection, children of 2-4 months of age, especially premature, are ill. The disease can be local (only the salivary glands are affected) and generalized.

Of the salivary glands, the submandibular, parotid and less often the sublingual gland are affected. The virus is localized in the cytoplasm and nucleus of epithelial cells of the glands and excretory ducts.

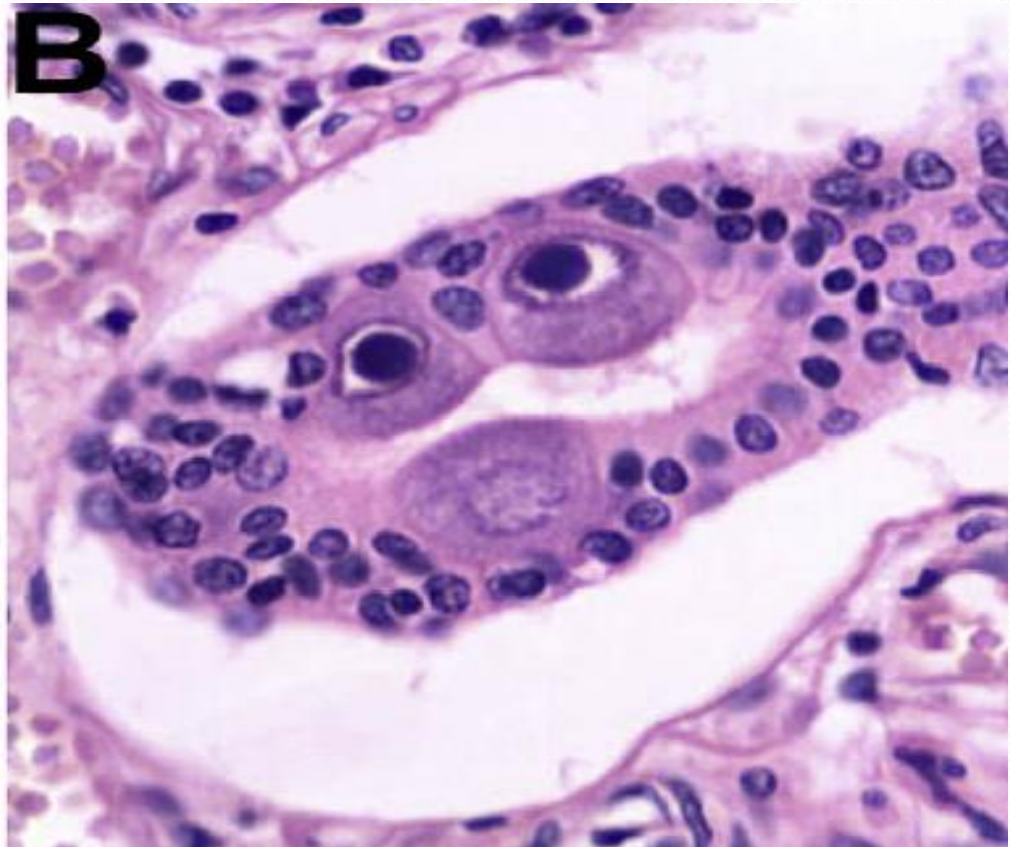
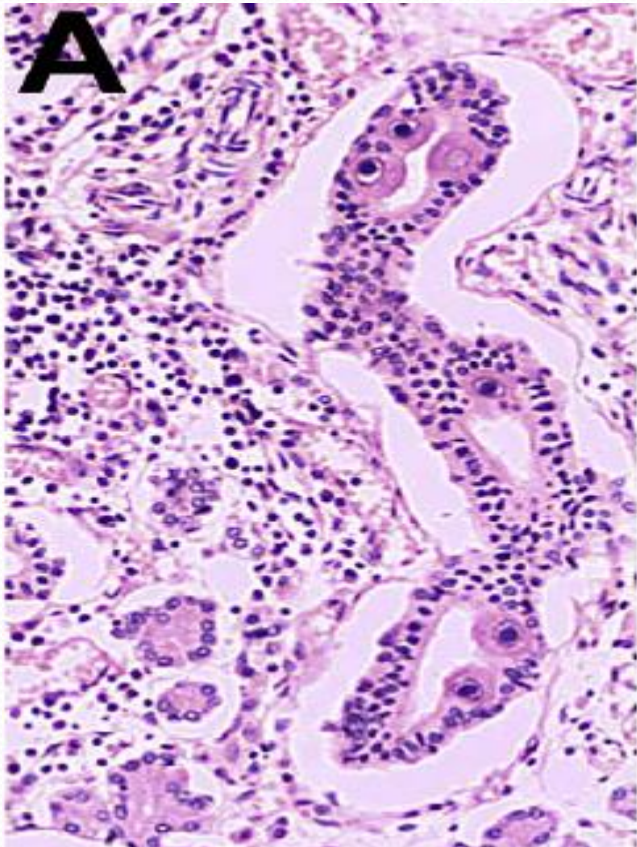
# Acute sialadenitis.

## **Acute primary sialadenitis.**

The nucleus contains a viral inclusion in the form of a basophilic mass surrounded by light zone of the nuclear membrane.

Viral inclusion nucleus resembles an owl's eye.

There is a chronic inflammatory infiltrate in the interstitial tissue..



# Acute sialadenitis.

## **Acute secondary sialadenitis.**

Acute purulent parotitis develops in the case of an ascending spread of infection from the oral cavity through the stensen duct.

May occur as a complication in conditions accompanied by high fever and dehydration, for example, during operations on the abdominal organs.

# Acute sialadenitis.

## **Acute secondary sialadenitis.**

Macroscopically, the parotid gland is swollen, painful, pus is secreted from the stensen duct.

Complications - abscesses of the gland with formation of fistulas in the skin, middle ear, ear canal. Phlegmon of the parotid salivary glands can spread to the soft tissues of the mouth, neck and mediastinum.

Thrombophlebitis of the surrounding veins and cerebral sinus thrombosis may occur on their background.

## **Chronic non-specific sialadenitis.**

Appear secondary after acute inflammation of the salivary glands or have a chronic course from the beginning.

The parotid and submandibular is most commonly affected, less often the sublingual glands are involved.

Etiology - general factors (decreased resistance, diabetes mellitus) and local factors (salivary stone disease, inflammation of the cheeks, strictures of the excretory ducts).



## **Chronic non-specific sialadenitis.**

The affected gland is enlarged and densified.

Microscopically, in the stroma, diffuse or peripheral lymphoid-plasma infiltration is observed, sometimes with the formation of reactive follicles with bright centers.

Chronic inflammation contributes to fibrosis. Microliths and viscous discharge are found in the lumen of the ducts.

# **Chronic non-specific sialadenitis.**

Forms :

- 1. chronic recurrent parotitis**
- 2. atrophic sclerosing sialadenitis (Kuttner tumor).**

# Chronic non-specific sialadenitis

*Chronic recurrent parotitis* occurs in children, more often in boys, aged 5-10 years, as well as in women in menopause.

It is characterized by a painful recurrent edema of the parotid glands and mucopurulent saliva.

Bacteriologically determined green and hemolytic streptococcus, less often staphylococcus and pneumococcus.

Microscopically is revealed interstitial or periductal lymphoid infiltrate, expansion of the salivary ducts, atrophy of the acini, fibrosis.

## Chronic non-specific sialadenitis

*Atrophic sclerosing sialadenitis (Kuttner tumor)* characterized by chronic, sclerosing, bilateral submandibular sialadenitis.

The glands become dense, resemble a tumor, hence the name.

## *Specific sialadenitis*

They are rare, parotid gland is affected.

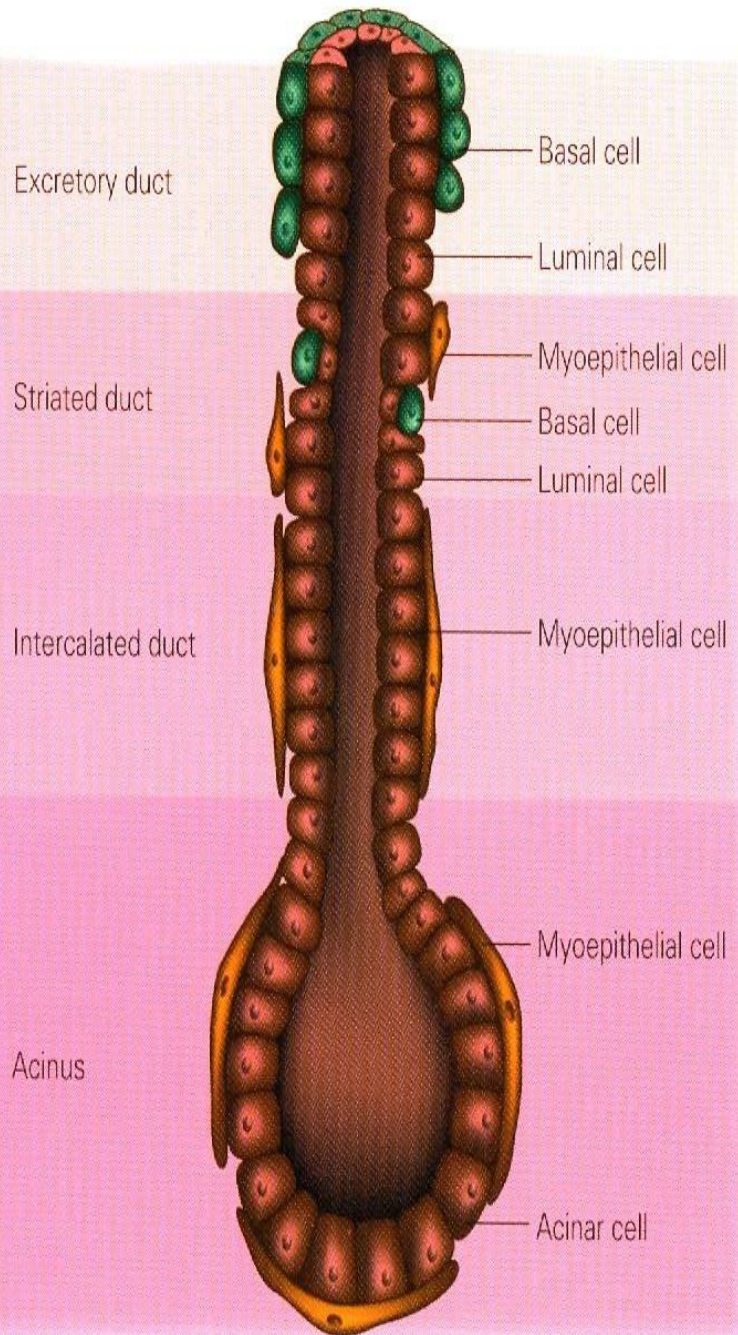
The infection spreads lymphogenously from the cervical lymph nodes and tonsils.

Histologically manifested by the presence of tuberculous granulomas and atrophy of the gland tissue.



# Salivary glands tumors

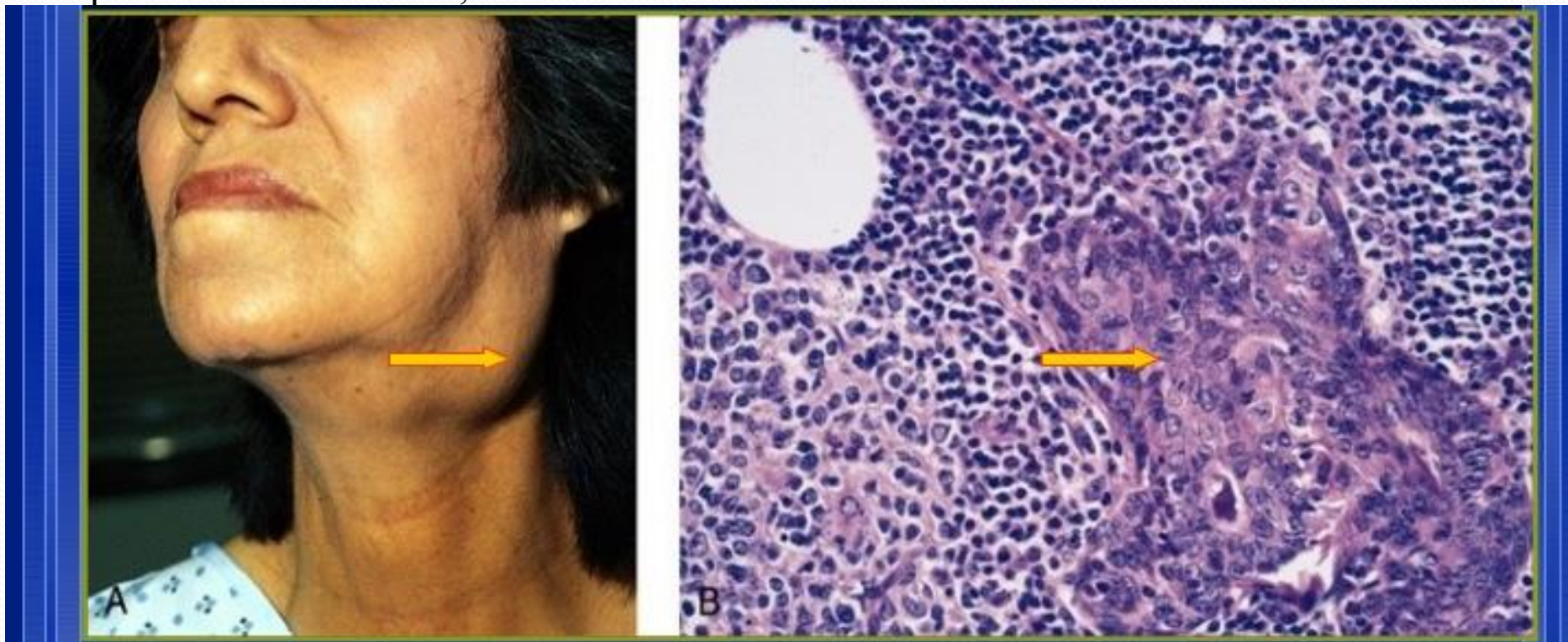
# Salivary duct and acinus



## Salivary gland.

# Sjögren Syndrome

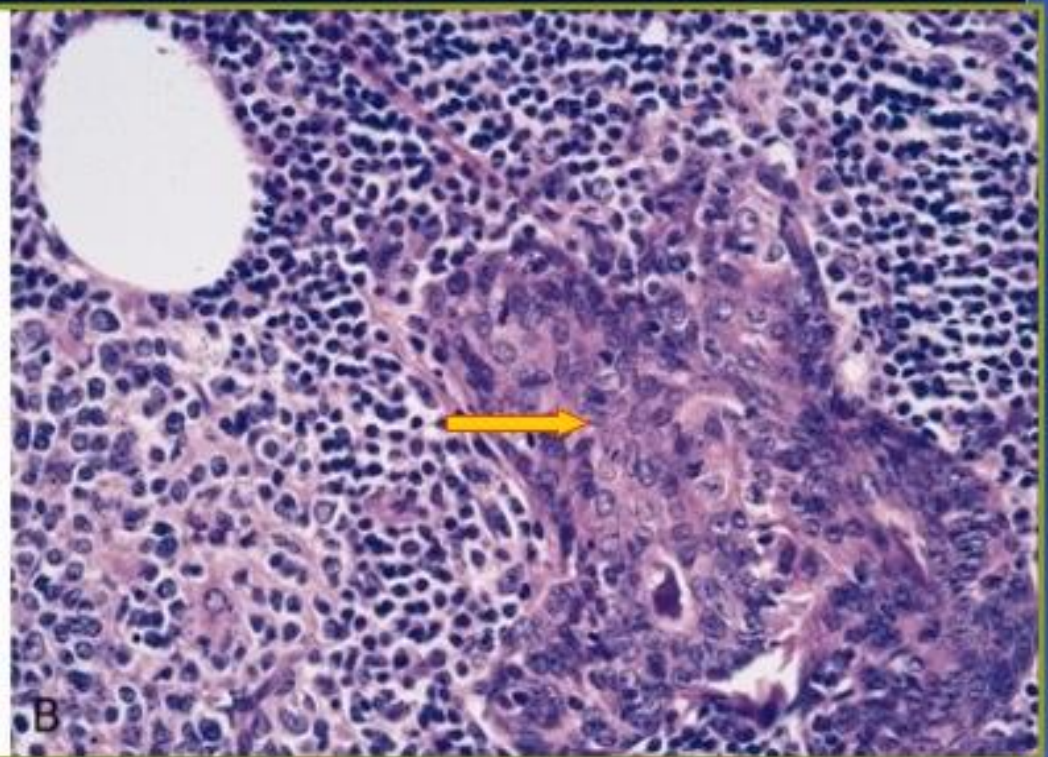
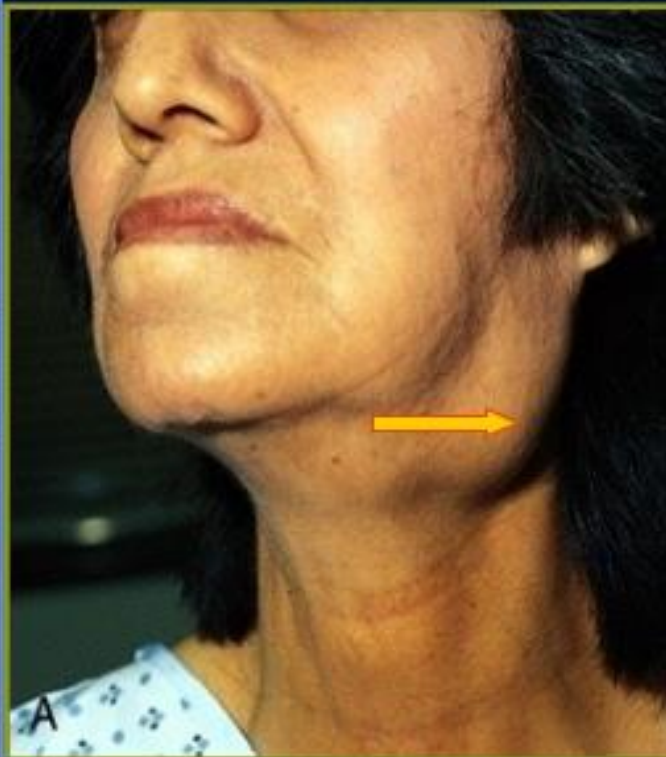- Sjögren's syndrome is the third most common rheumatic disease, after rheumatoid arthritis and systemic lupus erythematosus.
- Systemic autoimmune disease usually with xerostomia, keratoconjunctivitis, rheumatoid arthritis and hypergammaglobulinemia
- The incidence is 3-6 per 100,000 per year; estimated prevalence of up to 3% of the population
- Raportul F/M este de 9: 1, cu vârsta medie de debut între 40 - 60 de ani

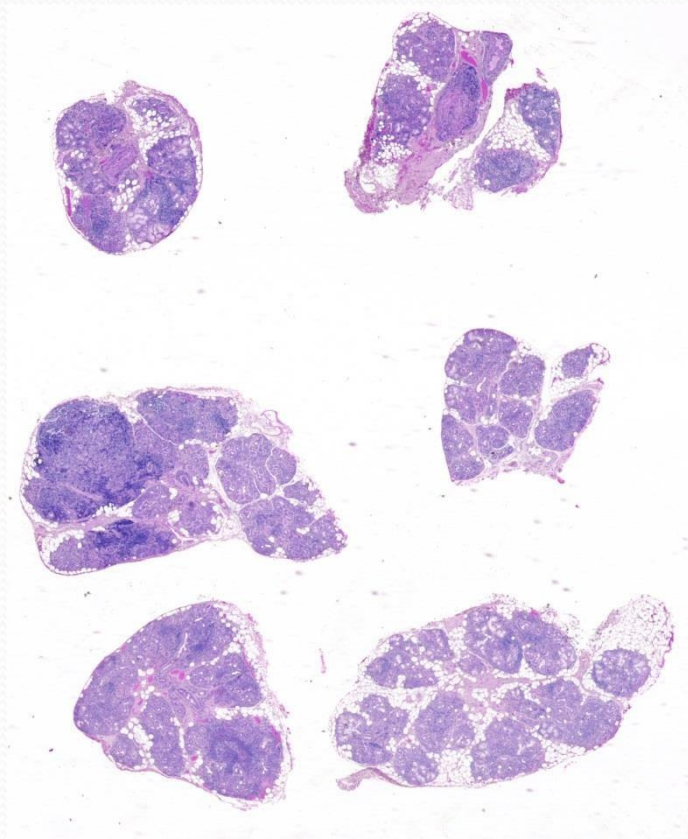


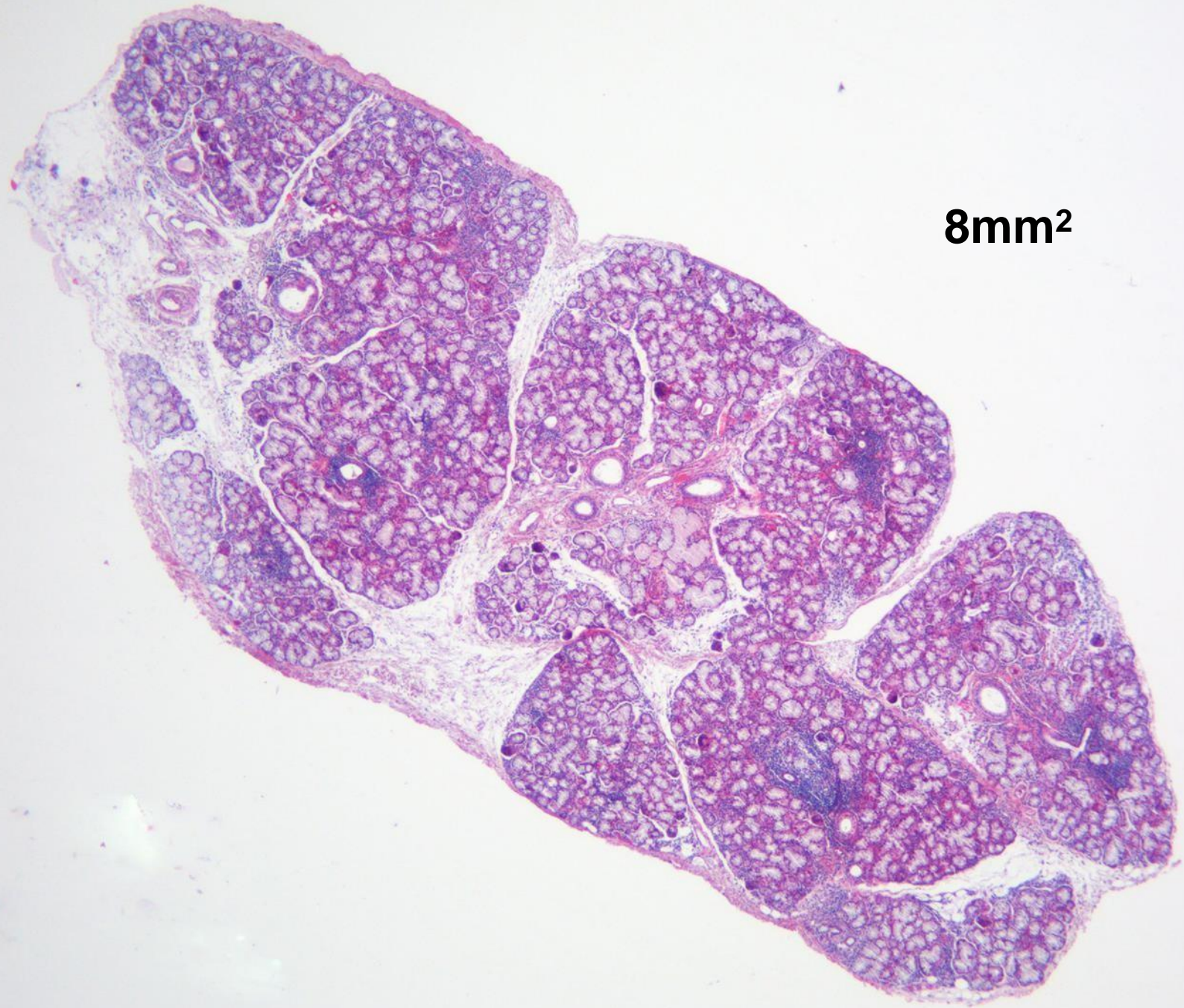


# Sjögren Syndrome

- The diagnosis requires the presence of certain number of clinical and pathological features
- Proposed diagnostic criteria: adequate biopsy of the minor salivary glands (5 or more glands) with a focus score  $> 1/4 \text{ mm}^2$
- Extended lymphoid infiltrate with germinal centers, frequent interstitial fibrosis and acinar atrophy

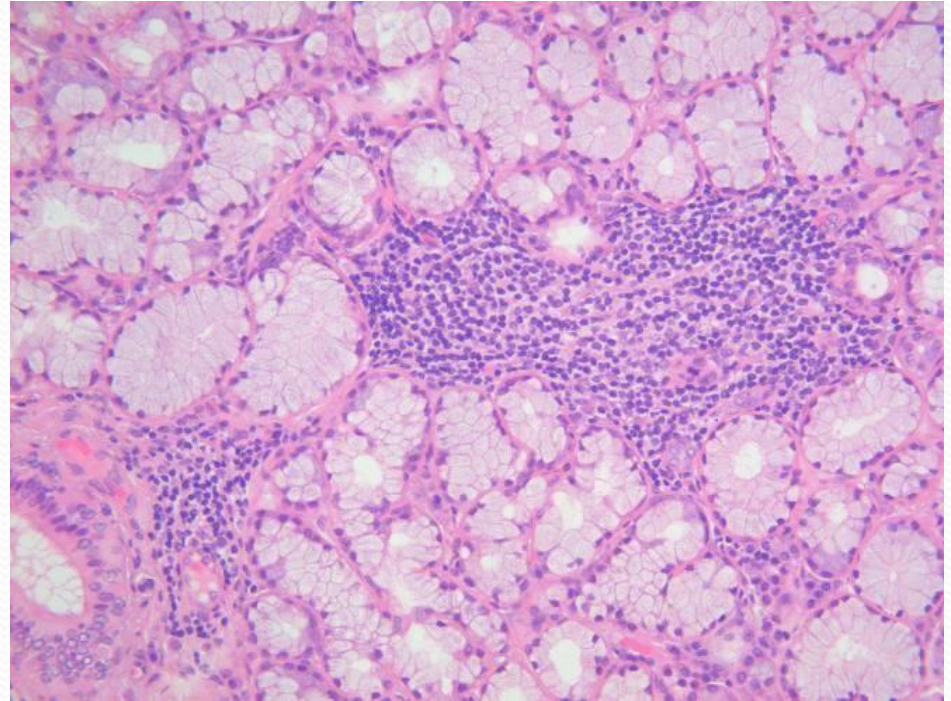
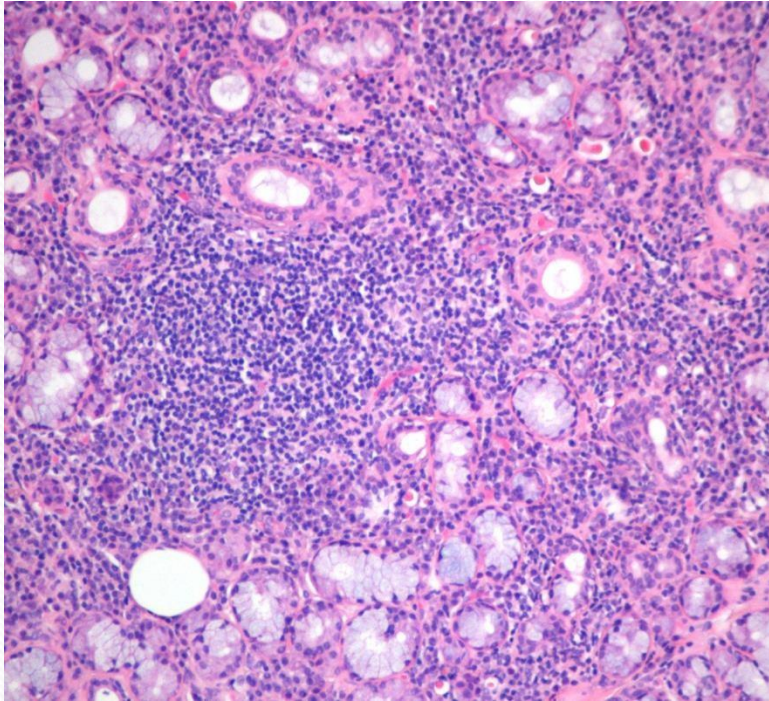






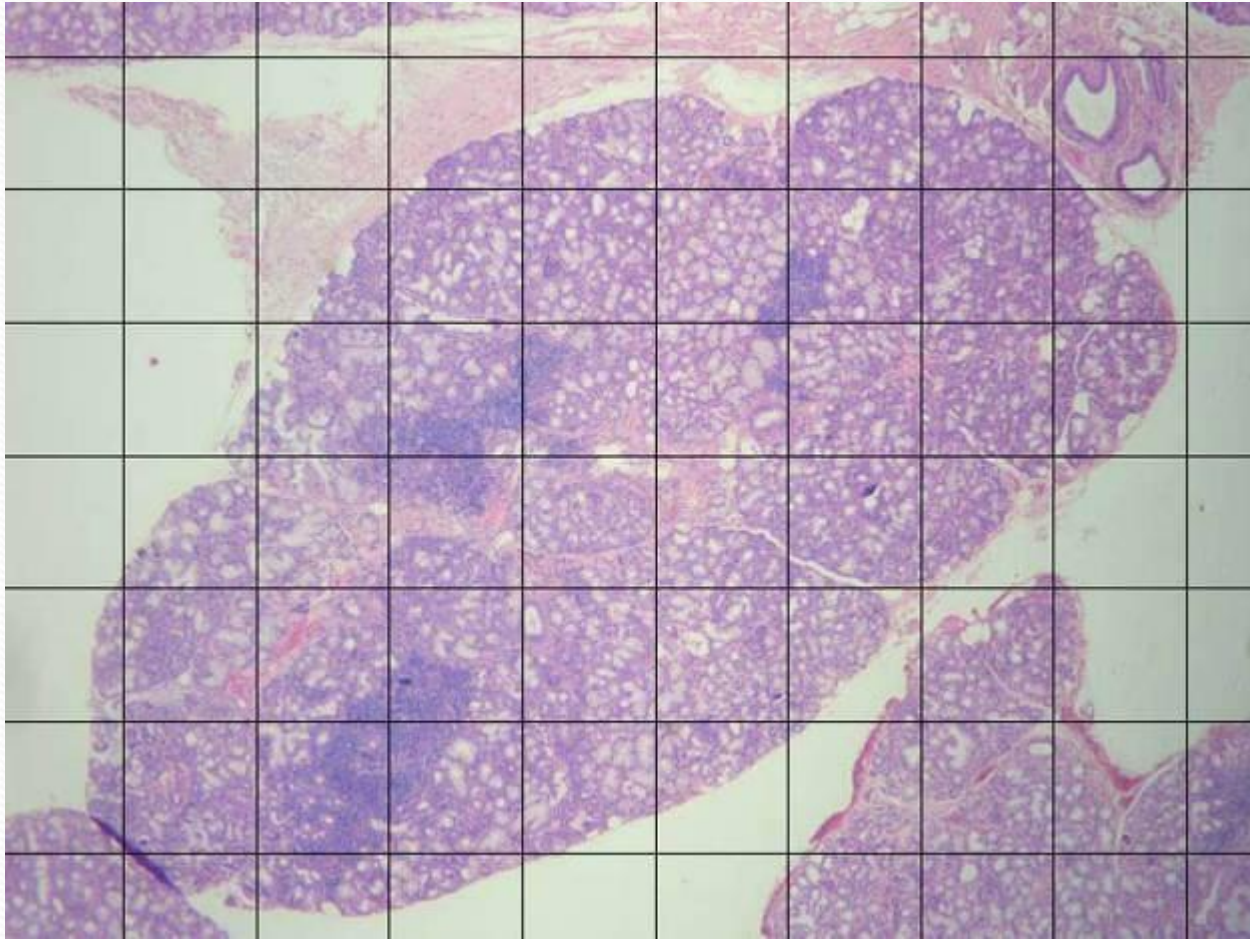
8mm<sup>2</sup>

# Lymphoid focal infiltrate



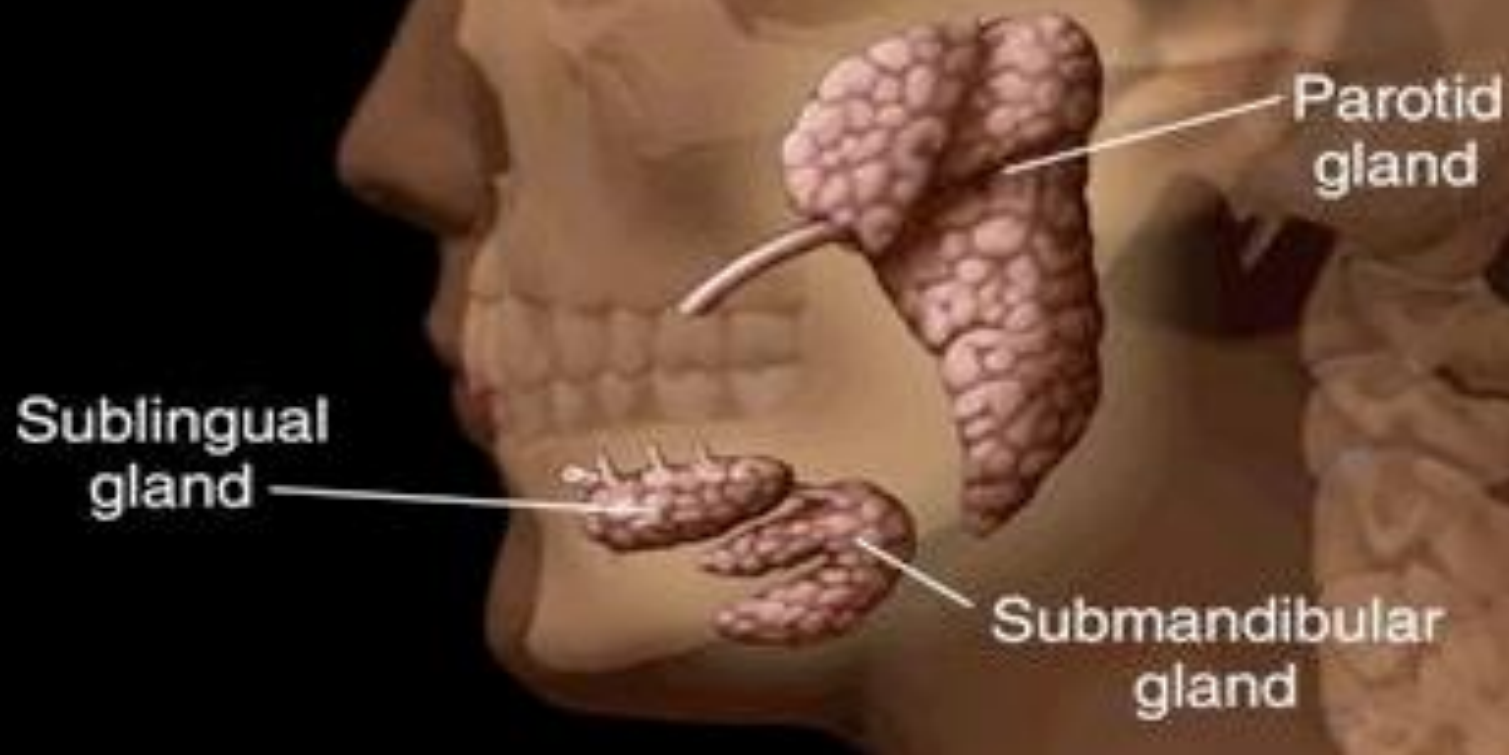
**Focal infiltrate with preservation of glandular tissue**

# Biopsy evaluation



Calculation of the focus score: a focus = with an agglomeration of at least 50 lymphocytes. The foci are counted per 4 mm<sup>2</sup> area and finally an average of the focus scores is calculated by examining at least 4 lobules. Positive result: focus score  $\geq 1$ .

# Salivary Glands



**Salivary glands pathology II.**

# Introduction

- Tumors of the salivary glands are:
  - **Most heterogeneous group of tumors.**
  - **Greatest diversity of morphologic features.**
- Relatively uncommon.
- The majority of these neoplasms are **benign 80%** and only **20% are malignant.**
- The various types of salivary gland tumors are best distinguished by their histologic patterns.

# Epidemiology

- **Uncommon neoplasms**
- **2%-6.5% of all head and neck neoplasms.**
- **Global annual incidence varies from 0.4-13.5 cases per 100000 people.**
- **Most salivary gland tumors originate in the parotid glands (64%-80%), malignancy (15%- 32%).**
- **7-11% occur in the submandibular glands, malignancy (37%- 45%).**
- **less than 1% in the sublingual glands, malignancy (70% 90%)**



- **9%-23% in the minor glands.**
- **Benign tumors account for 63% to 78% of all salivary gland neoplasms.**
- **Most common benign tumor: Pleomorphic adenoma -53%-77% of all cases occurs in parotid glands.**
- **Warthin's tumor- 6%-14% of all cases**
- **Most common malignancy- Mucoepidermoid carcinoma.**

- **Most common minor salivary gland tumor site: Palate, (42%- 54%).**
- **The proportion of malignant tumors varies significantly by site and is the greatest in the sublingual glands, tongue, floor of the mouth, and retromolar area.**
- **Most common among children: Mucoepidermoid carcinoma.**

- **RULE OF 80S**

- **80% of parotid tumors are benign**
- **80% of parotid tumors are Pleomorphic adenomas**
- **80% of salivary gland Pleomorphic adenomas occur in the parotid**
- **80% of parotid Pleomorphic adenomas occur in the superficial lobe**
- **80% of untreated Pleomorphic adenomas remain benign**

- **Viruses- EBV, CMV, Polyomavirus,**
- **Ionizing radiation.**
- **Increased occupational risks- asbestos, nickel compounds or silica dust.**
- **Employment in the woodworking, rubber industries and beauty saloons.**
- **Lifestyle- Warthin's tumors showed a strong association with cigarette smoking.**
- **Endogenous hormones.**

- **Cell differentiation results in three basic models of benign or malignant salivary gland neoplasms.**
  - **1) In one form of differentiation, tumor cell population results in a dual population that combines recognizable luminal and/or acinar cells with myoepithelial and/or basal cells**
  - **2) A second pattern results primarily in luminal/glandular cells that resemble to some extent normal duct epithelial and/or acinar cells**
  - **3) The third process produces tumor cells resembling normal myoepithelial and/or basal cells.**

# Benign tumors of the salivary glands

- Pleomorphic adenoma
- Myoepithelioma
- Basal cell adenoma
- Warthin tumour
- Oncocytoma
- Canalicular adenoma
- Sebaceous adenoma
- Lymphadenoma

## WHO classification of tumours of salivary glands

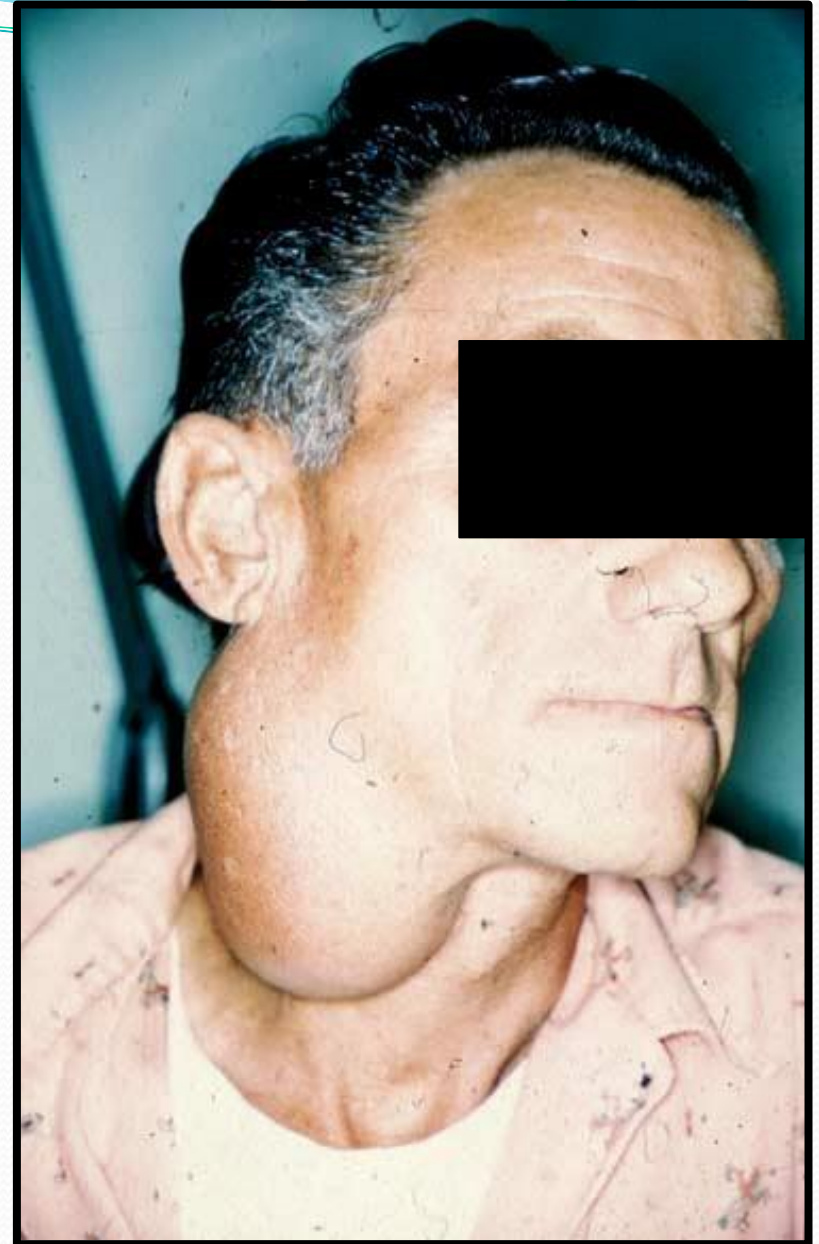
<b>Malignant tumours</b>		Lymphadenoma	8563/0*
Mucoepidermoid carcinoma	8430/3	Cystadenoma	8440/0
Adenoid cystic carcinoma	8200/3	Sialadenoma papilliferum	8406/0
Acinic cell carcinoma	8550/3	Ductal papillomas	8503/0
Polymorphous adenocarcinoma	8525/3	Sebaceous adenoma	8410/0
Clear cell carcinoma	8310/3	Canalicular adenoma and other ductal adenomas	8149/0
Basal cell adenocarcinoma	8147/3		
Intraductal carcinoma	8500/2	<b>Non-neoplastic epithelial lesions</b>	
Adenocarcinoma, NOS	8140/3	Sclerosing polycystic adenosis	
Salivary duct carcinoma	8500/3	Nodular oncocytic hyperplasia	
Myoepithelial carcinoma	8982/3	Lymphoepithelial sialadenitis	
Epithelial–myoepithelial carcinoma	8562/3	Intercalated duct hyperplasia	
Carcinoma ex pleomorphic adenoma	8941/3		
Secretory carcinoma	8502/3*	<b>Benign soft tissue lesions</b>	
Sebaceous adenocarcinoma	8410/3	Haemangioma	9120/0
Carcinosarcoma	8980/3	Lipoma/sialolipoma	8850/0
Poorly differentiated carcinoma		Nodular fasciitis	8828/0
Undifferentiated carcinoma	8020/3		
Large cell neuroendocrine carcinoma	8013/3	<b>Haematolymphoid tumours</b>	
Small cell neuroendocrine carcinoma	8041/3	Extranodal marginal zone lymphoma of mucosa-associated lymphoid tissue (MALT lymphoma)	9699/3
Lymphoepithelial carcinoma	8082/3		
Squamous cell carcinoma	8070/3		
Oncocytic carcinoma	8290/3		
<i>Uncertain malignant potential</i>			
Sialoblastoma	8974/1		
<b>Benign tumours</b>			
Pleomorphic adenoma	8940/0		
Myoepithelioma	8982/0		
Basal cell adenoma	8147/0		
Warthin tumour	8561/0		
Oncocytoma	8290/0		

The morphology codes are from the International Classification of Diseases for Oncology (ICD-O) (776A). Behaviour is coded /0 for benign tumours; /1 for unspecified, borderline, or uncertain behaviour; /2 for carcinoma in situ and grade III intraepithelial neoplasia; and /3 for malignant tumours. The classification is modified from the previous WHO classification, taking into account changes in our understanding of these lesions.

\*These new codes were approved by the IARC/WHO Committee for ICD-O.

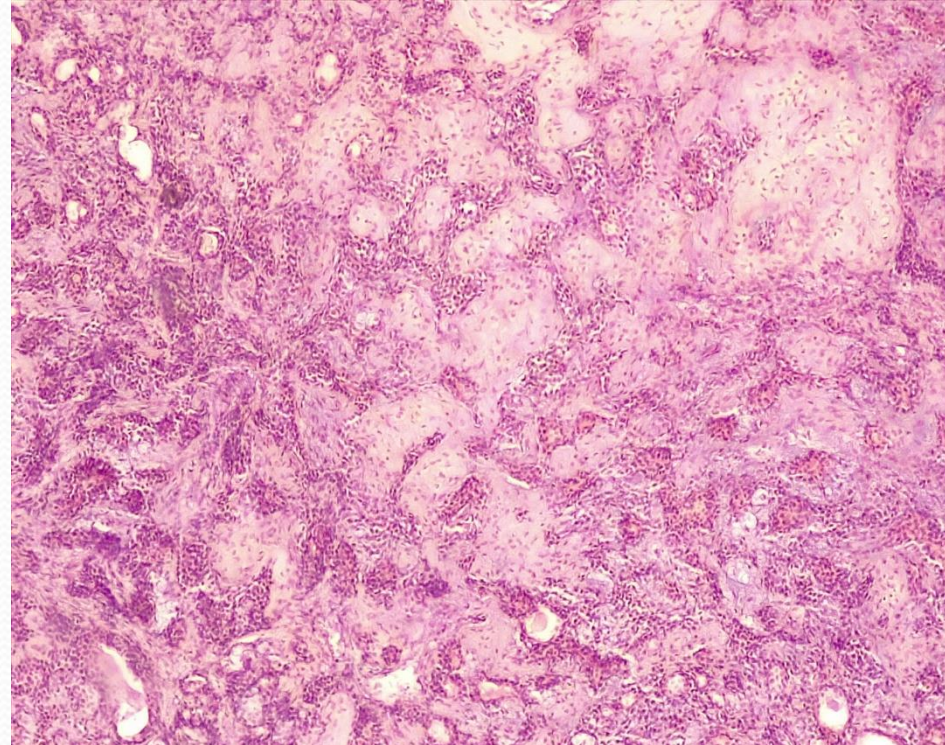
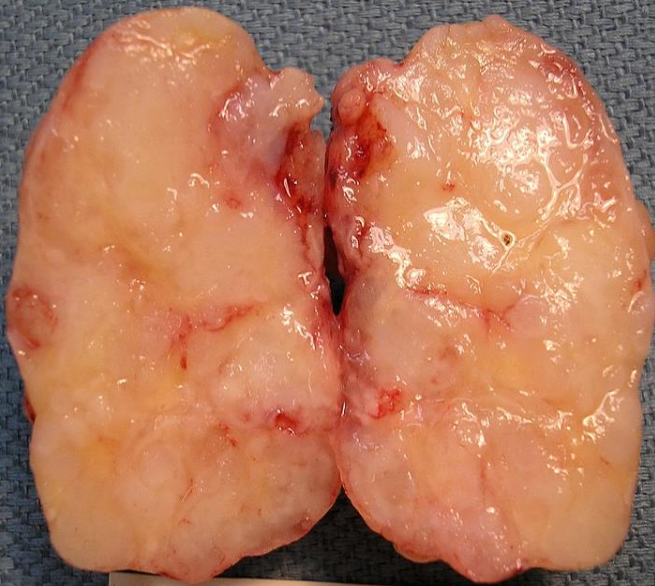## Pleomorphic adenoma

- The most common type
- Average age 46 years
- Most commonly in the parotid gland
- Encapsulated with islands of tumor cells in the capsule
- From the ductal epithelium and myoepithelial cells



## *Pleomorphic adenoma*

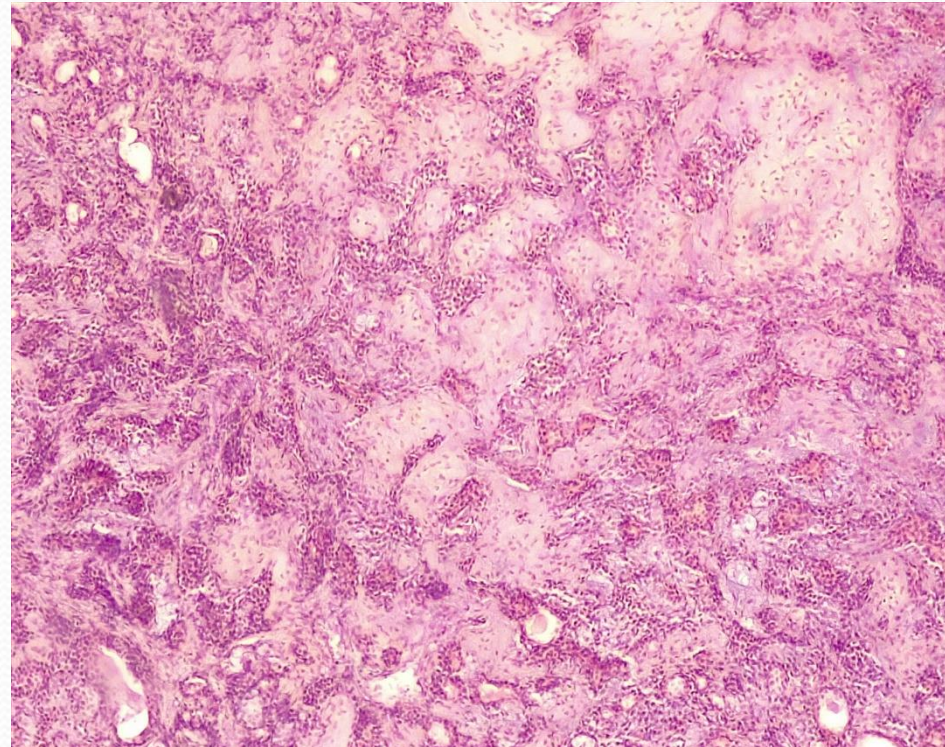
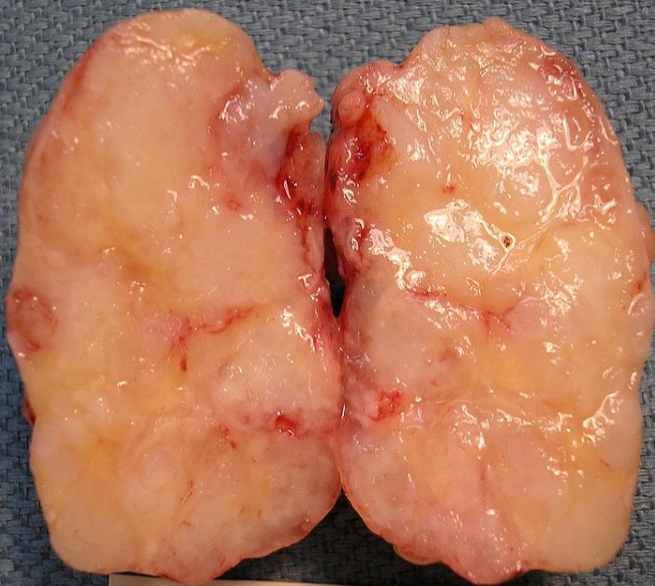- On cross section, the tumor tissue is whitish with yellowish patches and hemorrhages, often mucous with small cysts.
- Histologically, the tumor is represented by mixed epithelial and mesenchymal components, for which it received the name - pleomorphic adenoma.





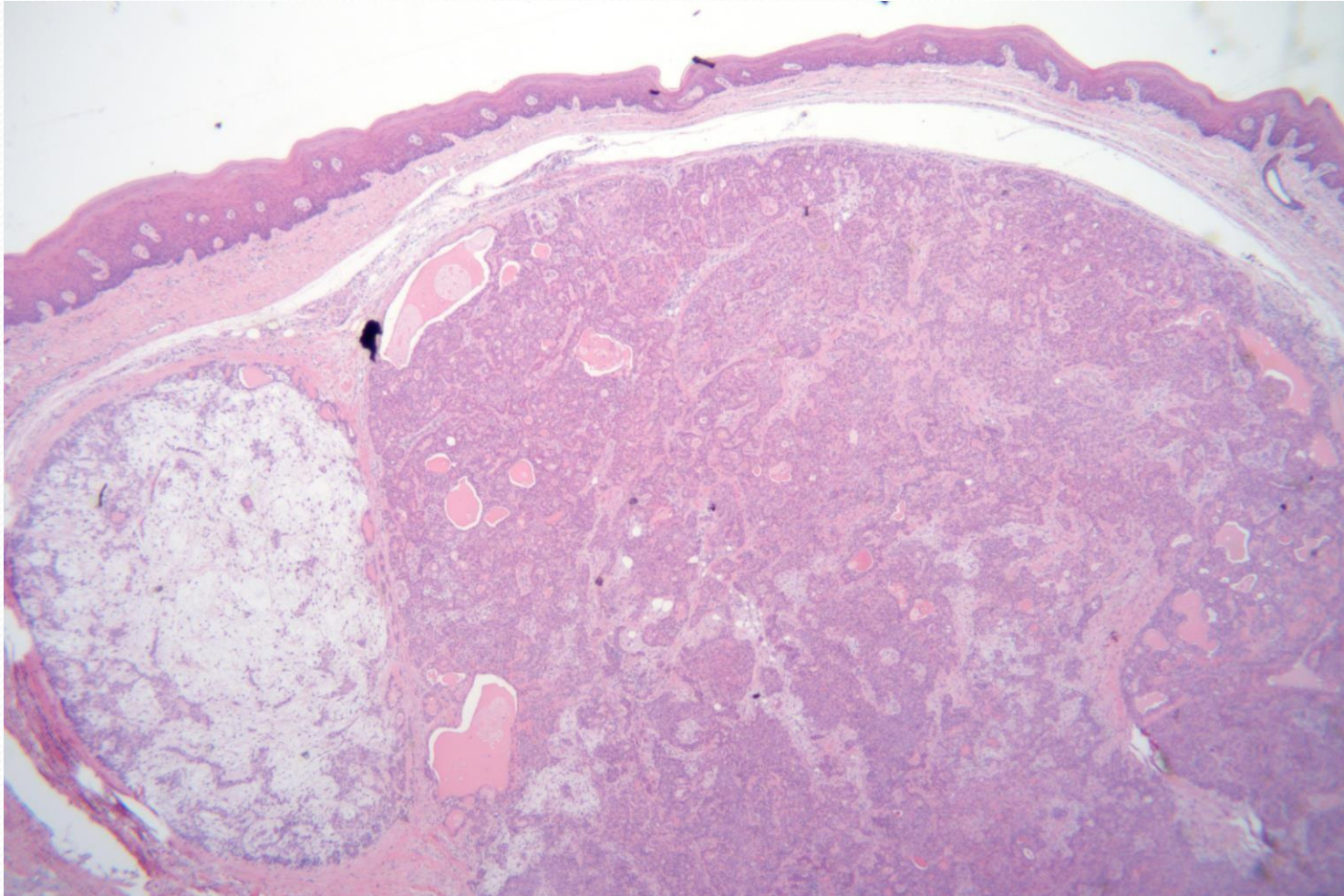
## *Pleomorphic adenoma*

- Epithelial formations have the structure of ducts, solid fields. In addition to epithelial structures, especially at the periphery, the presence of foci and fields of mucoid, myxoid, chondroid and bone material is characteristic.
- Foci of stromal hyalinosis can be found in the tumor, keratinization in epithelial areas.
- The neoplasm is benign, with a local destructive growth relapses.

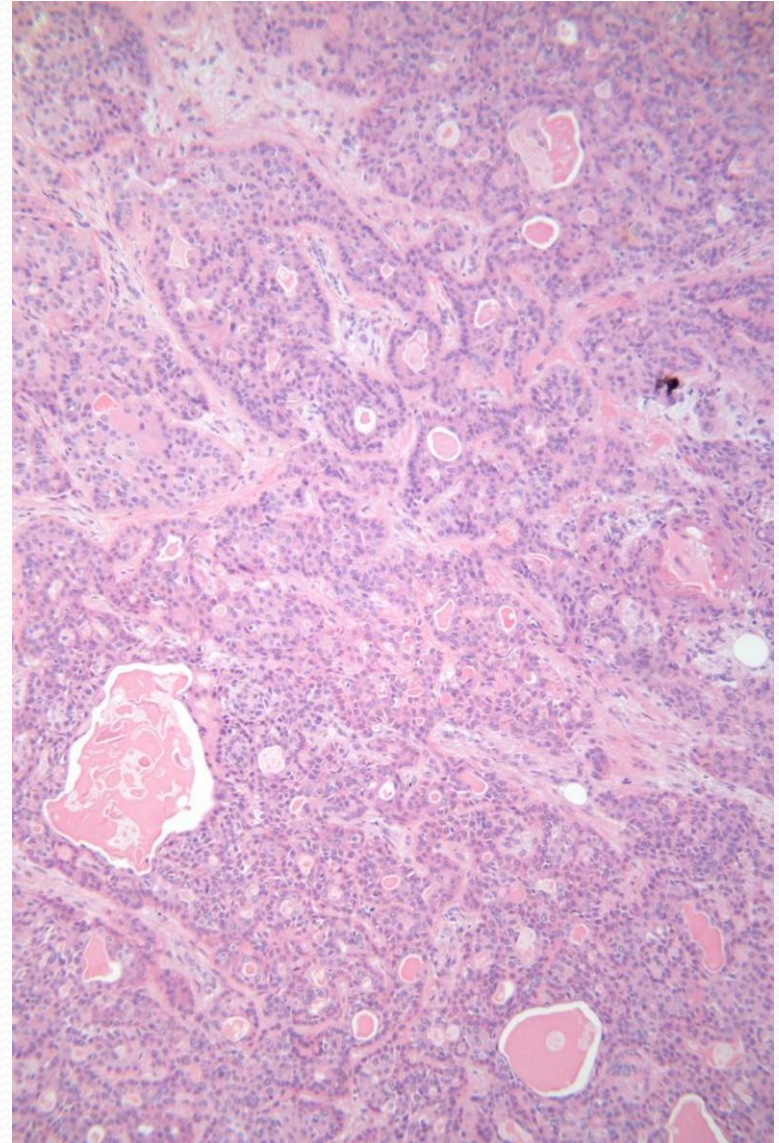
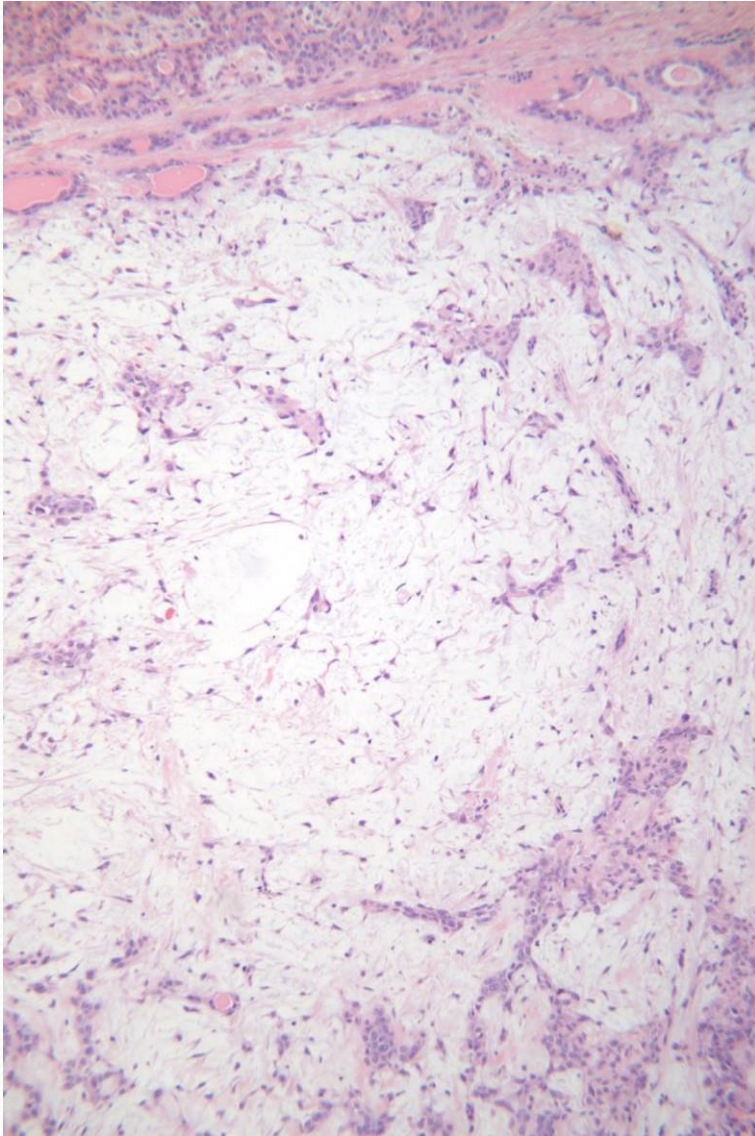


# Pleomorphic adenoma

- Encapsulated with nests of tumor cell in capsule.
- Epithelial component and mesenchymal component.



# Variable picture with epithelial tubules and myxomatous stroma






- **DIFFERENTIAL DIAGNOSIS**

- **Polymorphous low grade adenocarcinoma, PLGA**
- **Adenoid cystic carcinoma, AdCC**
- **Epithelial myoepithelial carcinoma, EMC**
- **Squamous cell carcinoma, SCC**
- **Mucoepidermoid carcinoma, MEC**

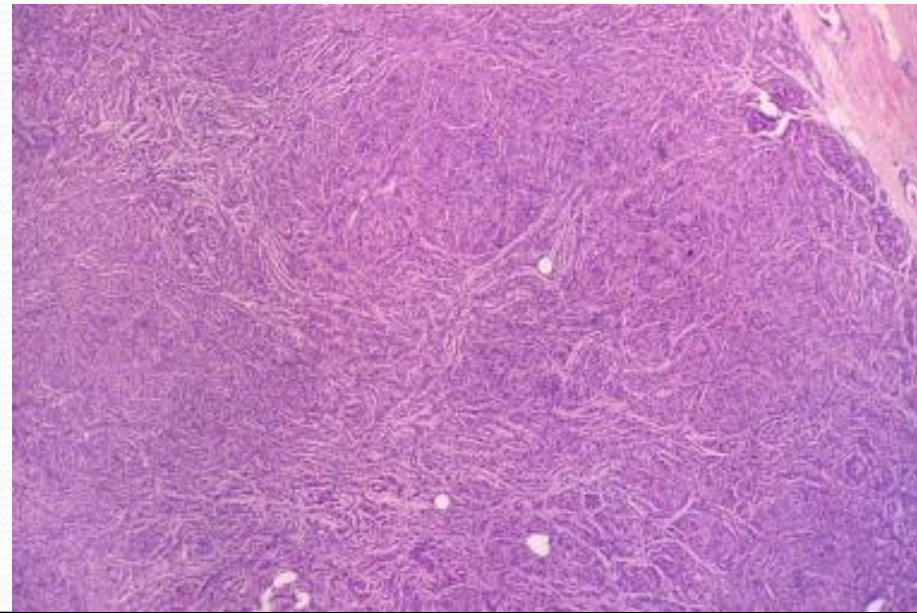
## **TREATMENT AND PROGNOSIS**

- **Surgical excision**
- **Superficial parotidectomy with preservation of the facial nerve**
- **Local enucleation should be avoided - resulting in seeding of the tumor cells.**
- **Deep lobe of the parotid- total parotidectomy is usually necessary also with preservation of the facial nerve.**

- 
- **Submandibular tumors - Total removal of the gland with the tumor.**
  - **Malignant degeneration is a potential complication, resulting in a carcinoma in pleomorphic adenoma.**
  - **The risk of malignant transformation is probably small, but it may occur in as many as 5% of all cases.**

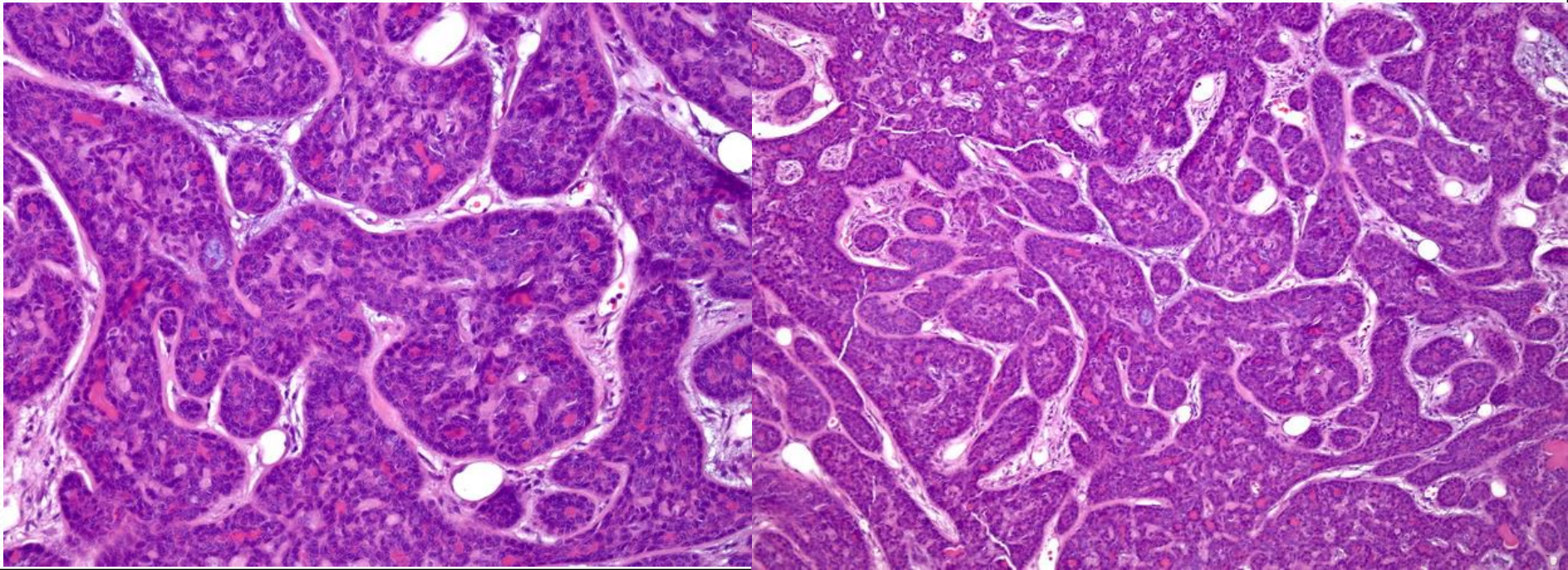
# Myoepithelioma

- Myoepithelial differentiation
- It can have different morphological patterns (fusiform, plasmacytoid, epithelioid)
- Parotid - 40%
- It develops in adults
- The tendency to relapse is lower than PA



# Basal cell adenoma

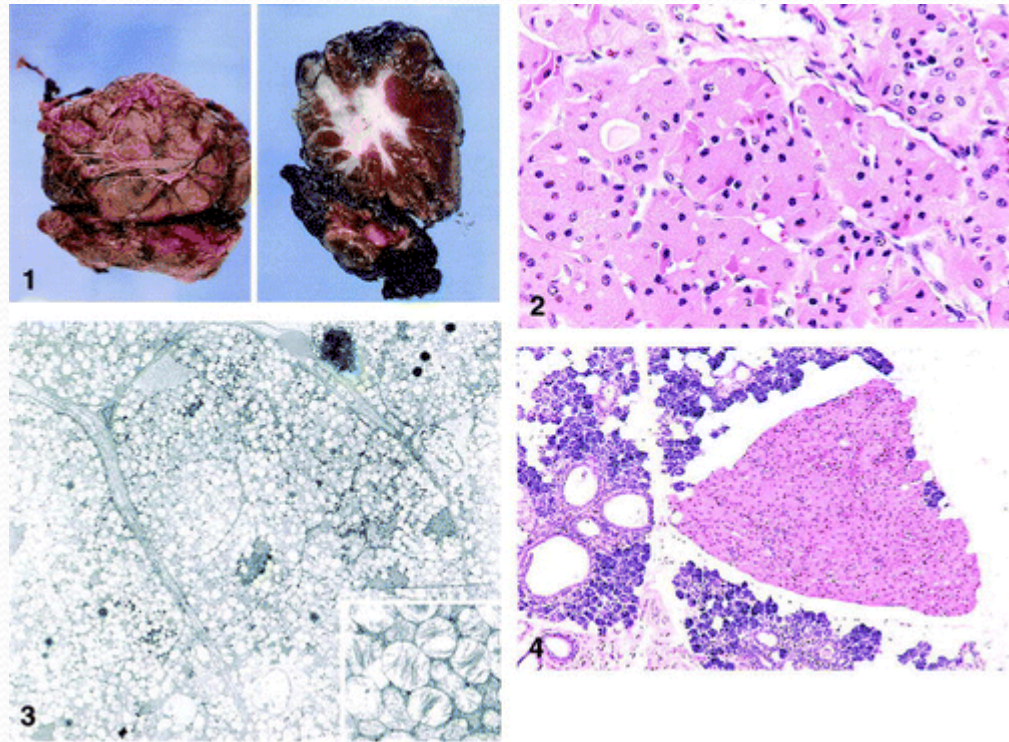
- Basal cell differentiation (anastomosing basaloid cell nests)
- Adults, average age 58 years
- Parotid
- 4% malignant transformation
- Rare recurrence





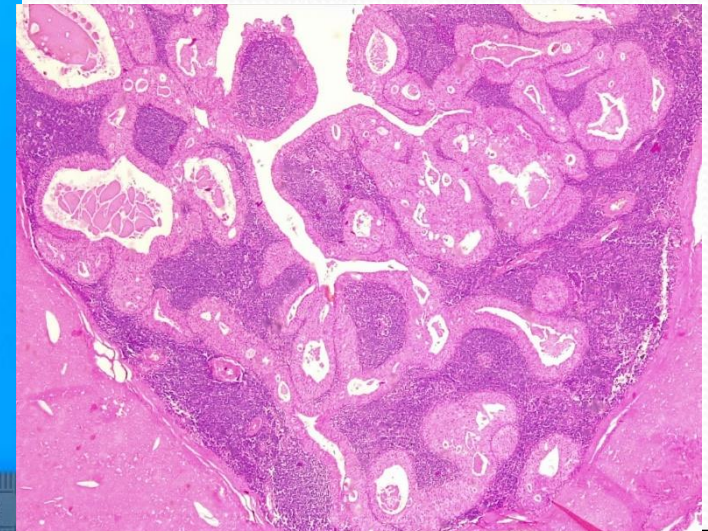
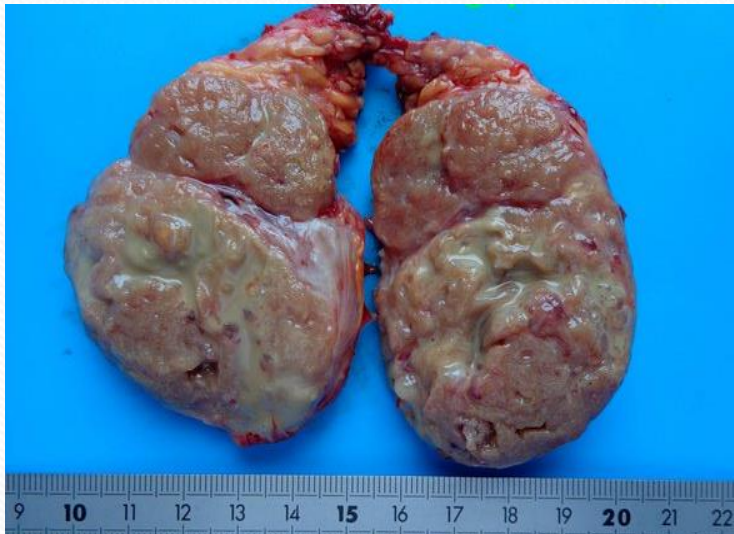# Oncocytoma

- Adults, average 60 years old
- 20% associated with radiation therapy or radiation exposure
- Usually the mass in the parotid gland
- Well circumscribed with a fibrous capsule, solid, lobed, often small, may have cystic spaces
- Excellent prognosis, but maybe had late recurrence



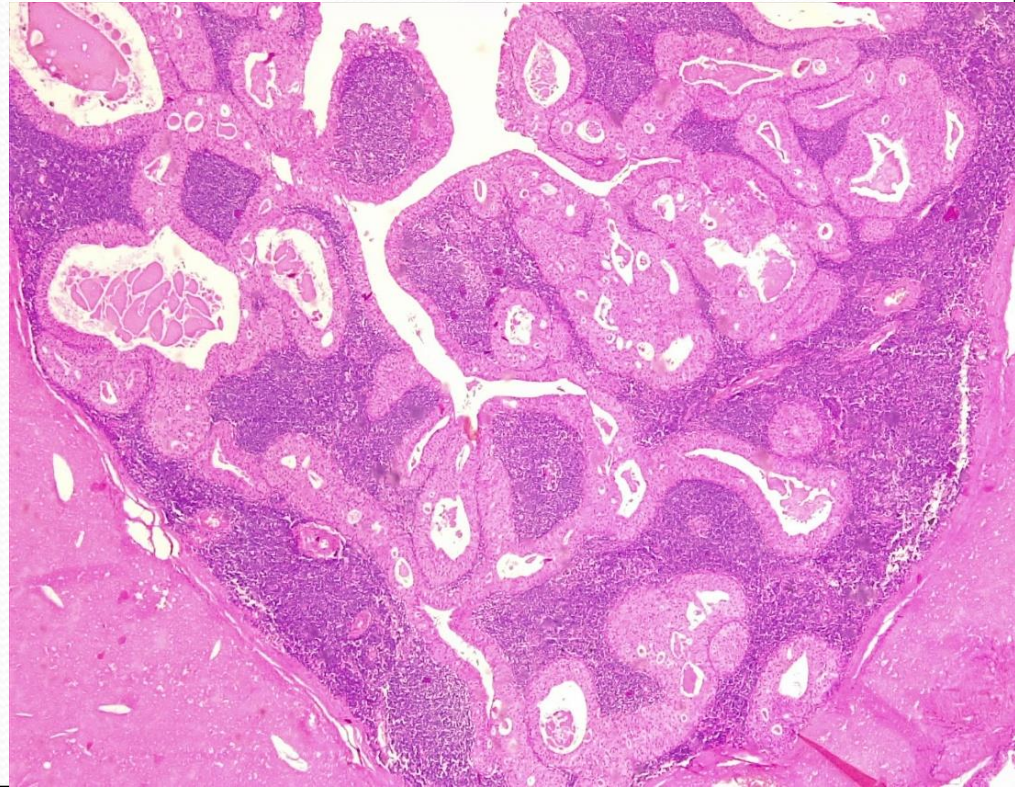
# Warthin tumor (adenolymphoma)

- Smoking men, 40+
- Occurs by incorporation of lymphoid tissue into the parotid gland or by induction of cystic and oncocytic changes by the inflammatory infiltrate
- Almost always in the parotid
- Encapsulated, lobed, pale gray, multicystic with mucinous / serous secretion, 10-15% multifocal / bilateral
- Malignant transformation - 1%
- Recurrence - 2%



# Warthin tumor (adenolymphoma)

- Double layer of epithelial cells attached to a dense lymphoid stroma with variable germinal centers
- Cystic spaces narrowed by the polypoid protrusions of the lymphoepithelial elements
- Palisade epithelial surface of oncocyte columnar cells, underlying discontinuous layer of basal cells



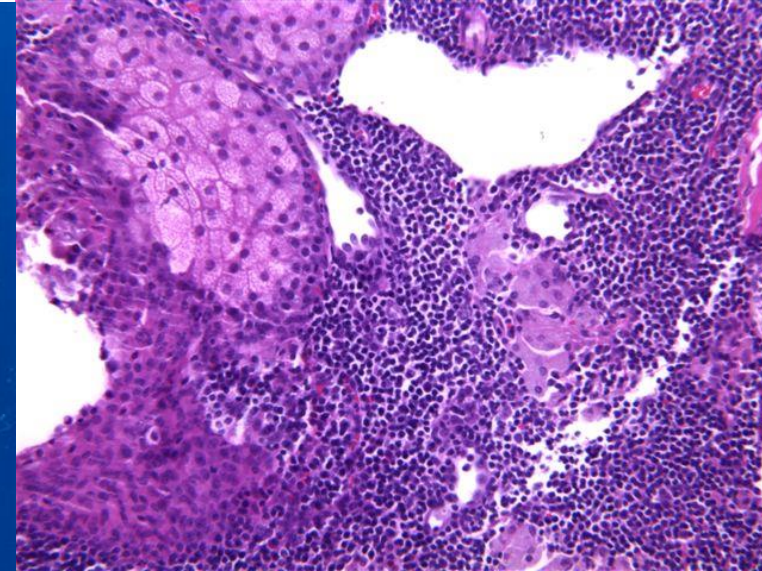
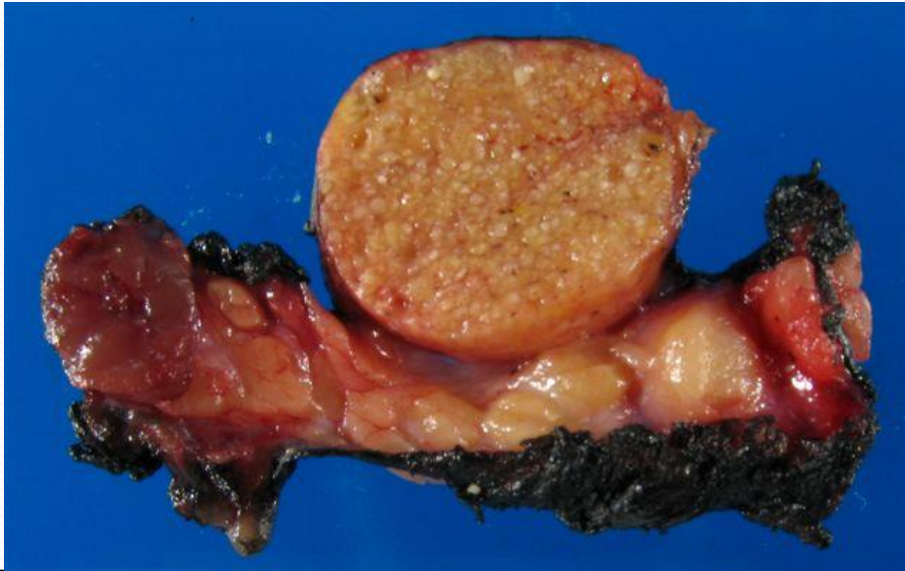
## **DIFFERENTIAL DIAGNOSIS**

- **Oncocytic papillary cystadenoma.**
- **Lymphoepithelial cystic lesions such as simple benign lymphoepithelial cyst (unrelated to AIDS),**
- **AIDS-related parotid cyst,**
- **Lymphoepithelial sialadenitis,**
- **MALT (mucosa-associated lymphoid tissue)**

- **Malignant changes in warthins tumor**
  - **Incidence – 1%**
  - **Epithelial component – squamous cell carcinoma, oncocytic carcinoma. Adenocarcinoma, undifferentiated carcinoma, mucoepidermoid carcinoma.**
  - **Lymphoid stroma - various types of non-Hodgkins lymphoma and Hodgkins lymphoma .**

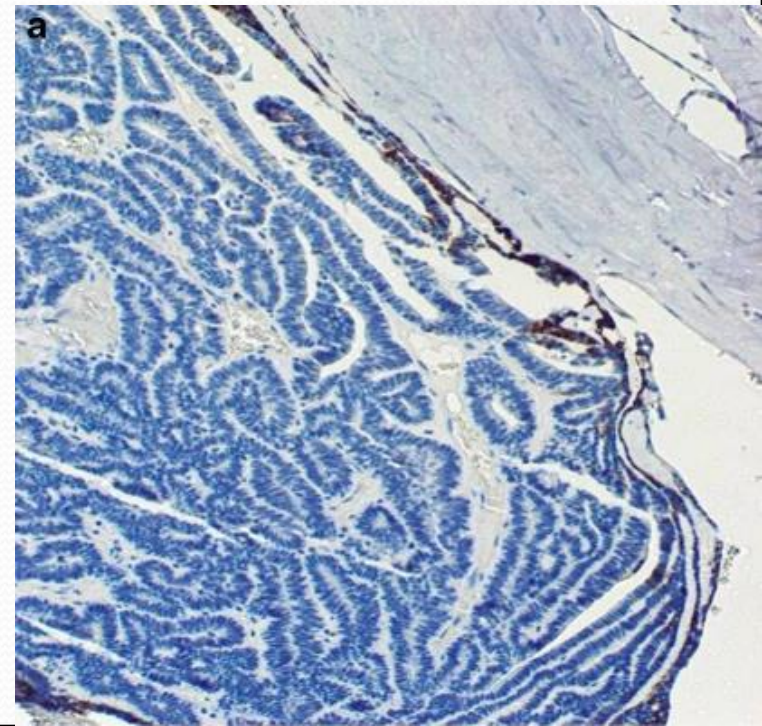
# Sebaceous adenoma

- Rare benign tumor with epithelial islands composed of sebaceous elements and lymphoid stroma
- Called sebaceous lymphadenoma if the lymphoid stroma is prominent
- Over 90% occur in or near the parotid gland
- Solid or cystic mass, well circumscribed, yellow-brown, up to 3 cm, with variable encapsulation
- Rare malignant transformation
- Rare recurrence



# Canalicular adenoma

- Monomorphic adenoma with bilayered columnar cells of luminal epithelial ductal differentiation and a poor, well-vascularized stroma
- It usually occurs in the minor salivary glands of the upper lip or palate
- 50+
- Often encapsulated, 22% multifocal
- Rare malignant transformation
- Rare recurrence



# Malignant tumors of the salivary glands

- Mucoepidermoid carcinoma
- Adenoid-cystic carcinoma
- Acinar cell carcinoma
- Polymorphic adenocarcinoma
- Clear cell carcinoma
- Adenocarcinoma

Rare (common in parotid gl.)

## - Carcinoma developed from a pleomorphic adenoma

- Myoepithelial carcinoma
- Epithelial-myoepithelial carcinoma
- Salivary duct carcinoma
- Basal cell adenocarcinoma
- Oncocytic adenocarcinoma
- Sebaceous adenocarcinoma
- Squamous cell carcinoma

## WHO classification of tumours of salivary glands

<b>Malignant tumours</b>			
Mucoepidermoid carcinoma	8430/3	Lymphadenoma	8563/0*
Adenoid cystic carcinoma	8200/3	Cystadenoma	8440/0
Acinic cell carcinoma	8550/3	Sialadenoma papilliferum	8406/0
Polymorphous adenocarcinoma	8525/3	Ductal papillomas	8503/0
Clear cell carcinoma	8310/3	Sebaceous adenoma	8410/0
Basal cell adenocarcinoma	8147/3	Canalicular adenoma and other ductal adenomas	8149/0
Intraductal carcinoma	8500/2		
Adenocarcinoma, NOS	8140/3	<b>Non-neoplastic epithelial lesions</b>	
Salivary duct carcinoma	8500/3	Sclerosing polycystic adenosis	
Myoepithelial carcinoma	8982/3	Nodular oncocytic hyperplasia	
Epithelial-myoepithelial carcinoma	8562/3	Lymphoepithelial sialadenitis	
Carcinoma ex pleomorphic adenoma	8941/3	Intercalated duct hyperplasia	
Secretory carcinoma	8502/3*		
Sebaceous adenocarcinoma	8410/3	<b>Benign soft tissue lesions</b>	
Carcinosarcoma	8980/3	Haemangioma	9120/0
Poorly differentiated carcinoma		Lipoma/sialolipoma	8850/0
Undifferentiated carcinoma	8020/3	Nodular fasciitis	8828/0
Large cell neuroendocrine carcinoma	8013/3		
Small cell neuroendocrine carcinoma	8041/3	<b>Haematolymphoid tumours</b>	
Lymphoepithelial carcinoma	8082/3	Extranodal marginal zone lymphoma of mucosa-associated lymphoid tissue (MALT lymphoma)	9699/3
Squamous cell carcinoma	8070/3		
Oncocytic carcinoma	8290/3		
<i>Uncertain malignant potential</i>			
Sialoblastoma	8974/1		
<b>Benign tumours</b>			
Pleomorphic adenoma	8940/0		
Myoepithelioma	8982/0		
Basal cell adenoma	8147/0		
Warthin tumour	8561/0		
Oncocytoma	8290/0		

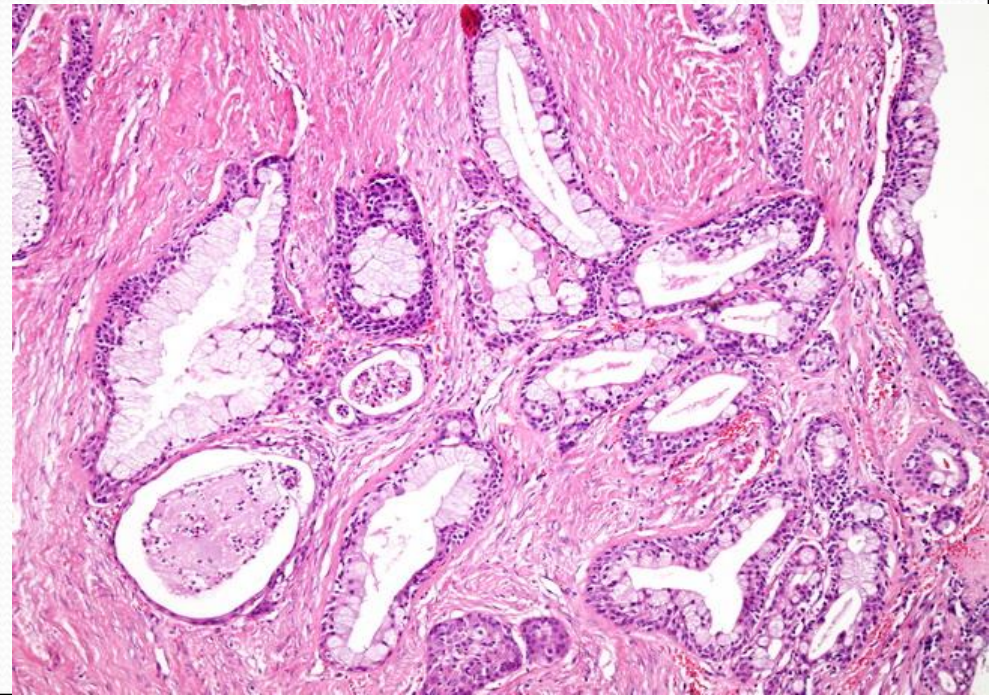
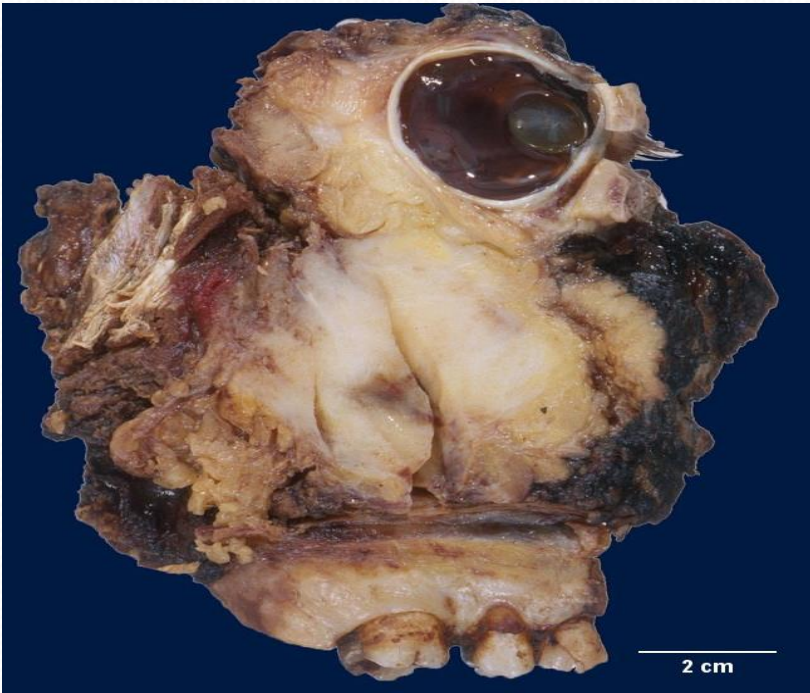
The morphology codes are from the International Classification of Diseases for Oncology (ICD-O) (776A). Behaviour is coded /0 for benign tumours; /1 for unspecified, borderline, or uncertain behaviour; /2 for carcinoma in situ and grade III intraepithelial neoplasia; and /3 for malignant tumours. The classification is modified from the previous WHO classification, taking into account changes in our understanding of these lesions.

\*These new codes were approved by the IARC/WHO Committee for ICD-O.



# Mucoepidermoid carcinoma

- Children and young adults (second decade)
- May develop secondary to radiation or chemotherapy during childhood, with an average latency of 8 years
- Most commonly in the parotid
- It can mimic a mucocele
- Circumscribed or infiltrative mass, soft or firm, often with cystic component



# Mucoepidermoid carcinoma

- It is characterized by the proliferation of 3 types of cells: squamous, mucosecreting and intermediate type
- Cystic and solid growth pattern
- G1 = cystic, well circumscribed, rich in mucous cells
- G2 = more solid, less circumscribed and has a diversified appearance including extravasation of mucin

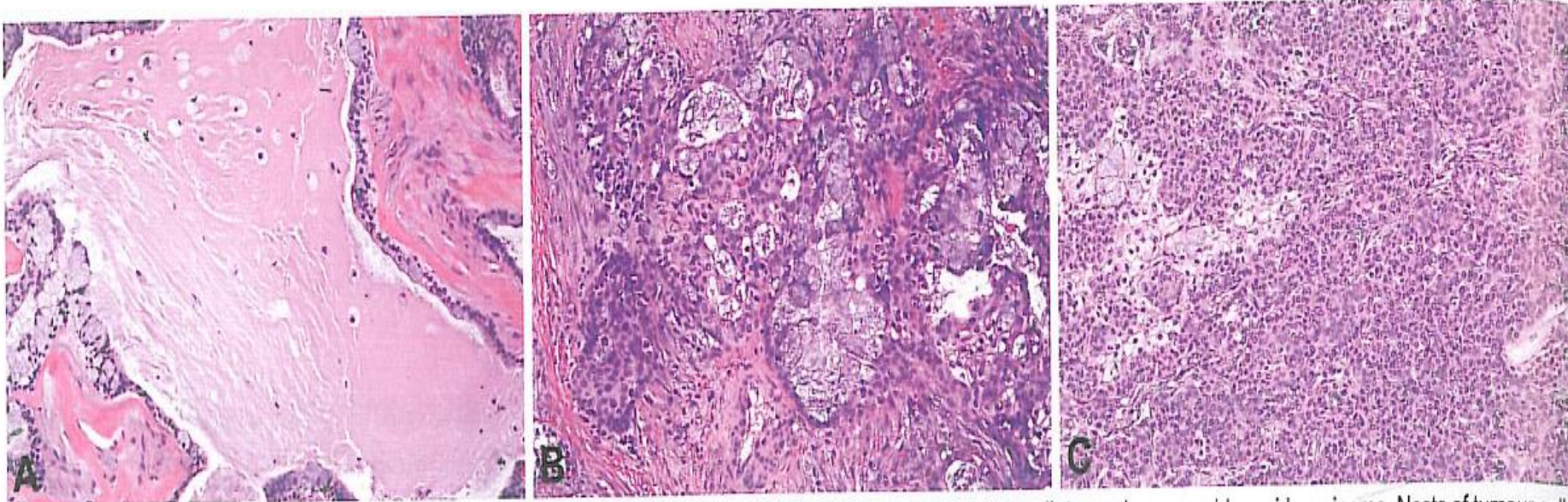


Fig. 7.02 **A** Low-grade mucoepidermoid carcinoma. Cystic ductal spaces lined by mucinous epithelial cells. **B** Intermediate-grade mucoepidermoid carcinoma. Nests of tumour cells with mucinous, clear and squamoid features with minimal cystic formation. **C** High-grade mucoepidermoid carcinoma. Poorly differentiated tumour with focal mucin-producing cells.

## **CLINICAL FEATURES:**

**Low grade: slowly enlarging, painless mass, seldom exceeds 5cm in diameter .**

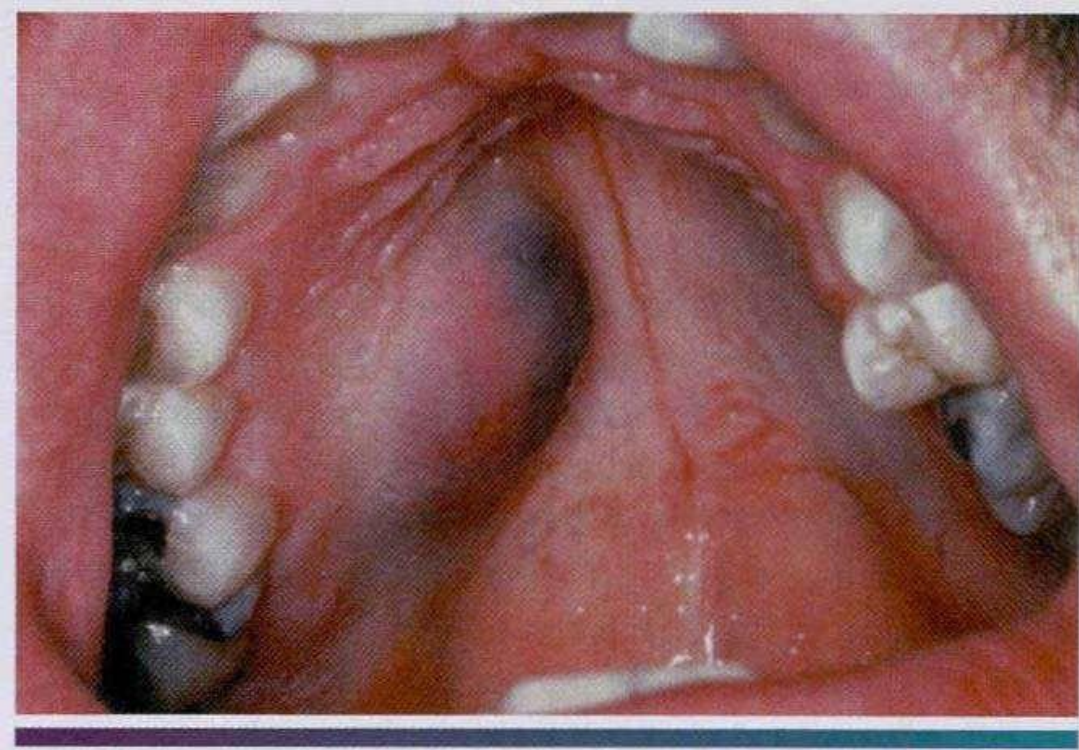
**•not completely encapsulated, often contains cysts-filled with viscid, mucoid material.**

**•may be mistaken as mucocele.**

**High grade: grows rapidly, facial nerve paralysis**

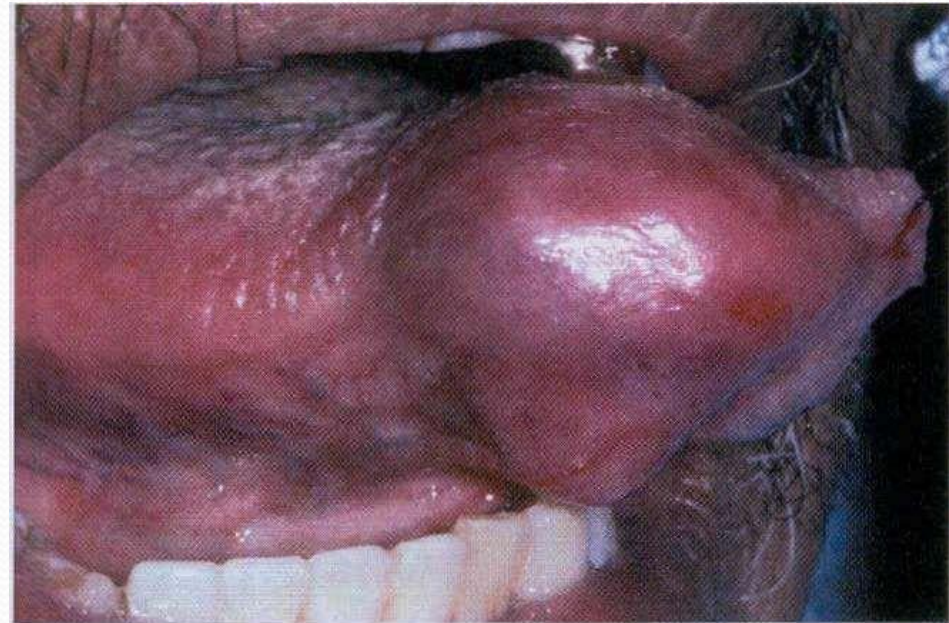**•ulceration, trismus, draining from the ear, dysphagia.**

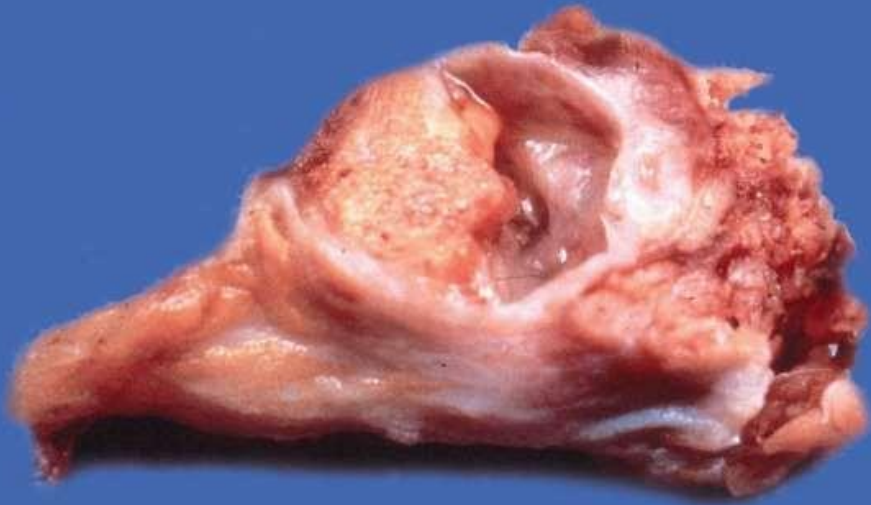**•metastasis to regional lymph node, lung, bone, brain, suncutaneous tissue.**



**Blue-pigmented mass of the posterior lateral hard palate.**

**Mucoepidermoid carcinoma.  
Mass of the tongue**

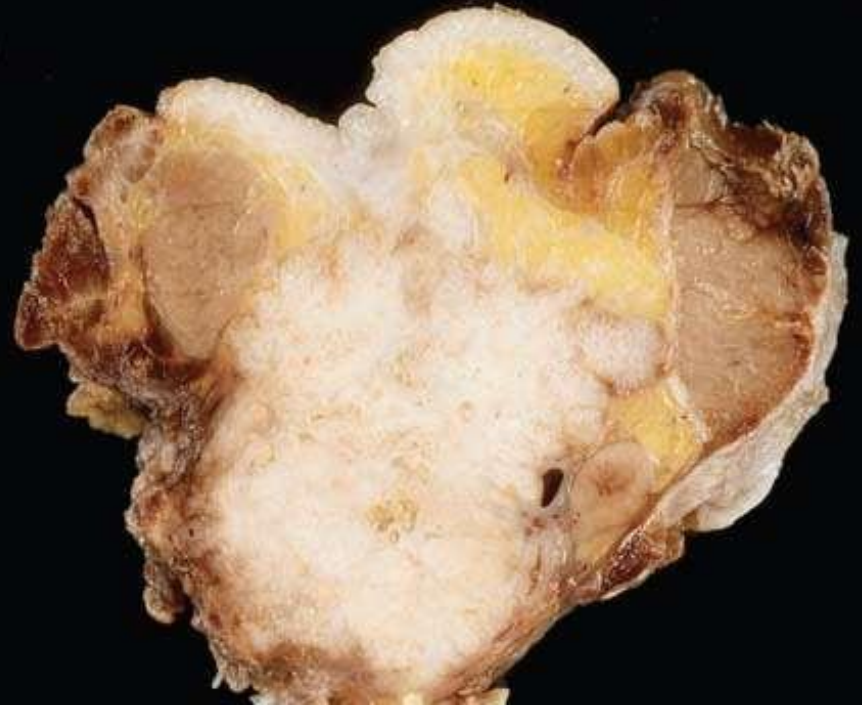



**Low-grade mucoepidermoid carcinomas may have a distinctly cystic gross appearance.**

- Cystic spaces- viscid, mucoid material**
- Areas of hemorrhage seen.**

**Cut surface of the tumor shows gray white, solid mass accompanied by multiple small cystic structures and infiltrative borders.**



# Mucoepidermoid carcinoma

- G3 = includes one or more of the following characteristics:

- nuclear anaplasia
- tumor necrosis
- increased mitotic rate
- perineural, lymphovascular or bone invasion

- Diagnosis of MEC G3 - requires at least the focal positivity of the intracellular mucin

Prognosis - Overall 10-year survival rate:

G1- 90%

G2- 70%

G3-25%

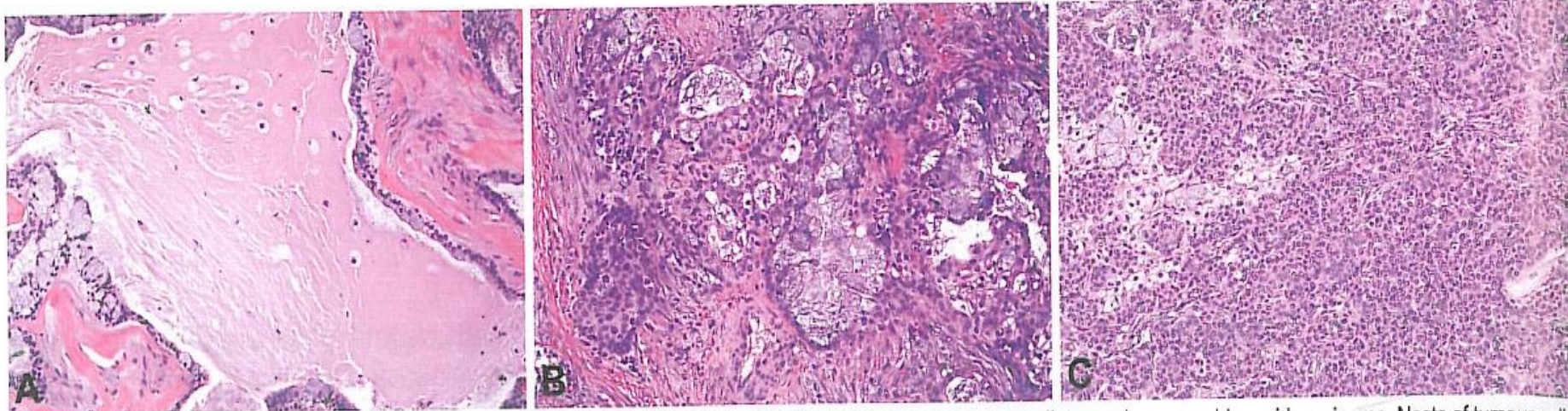
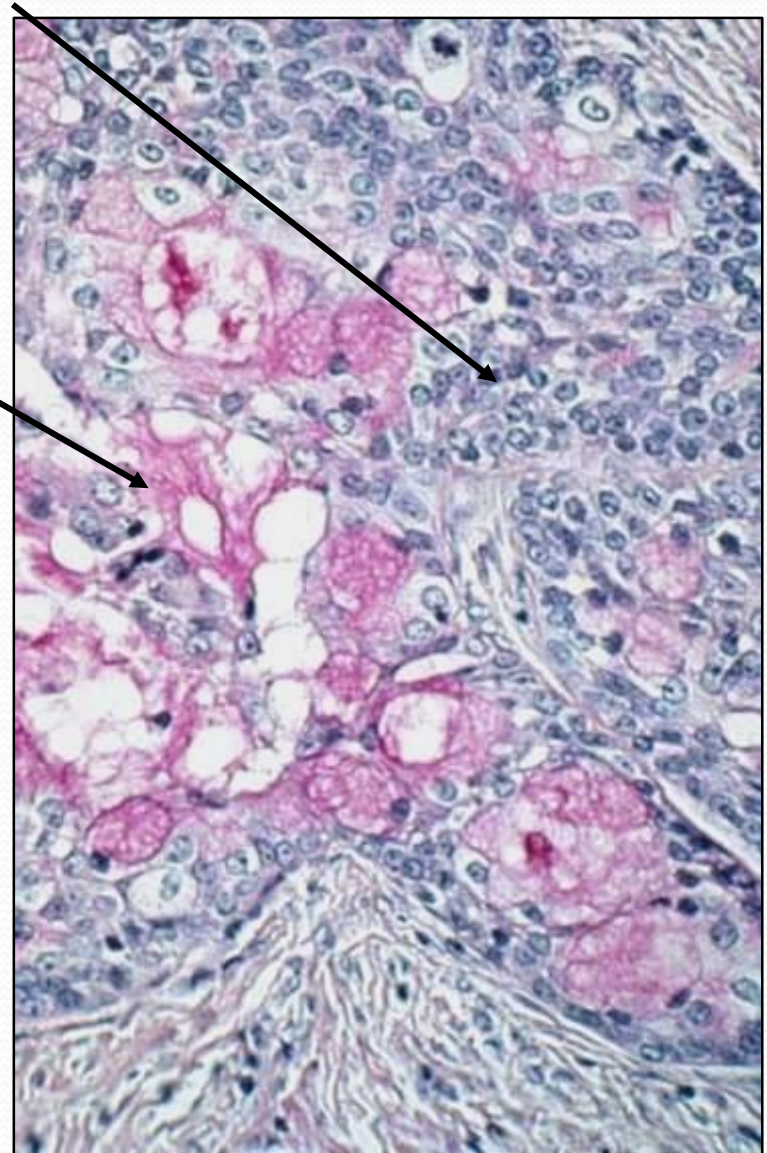
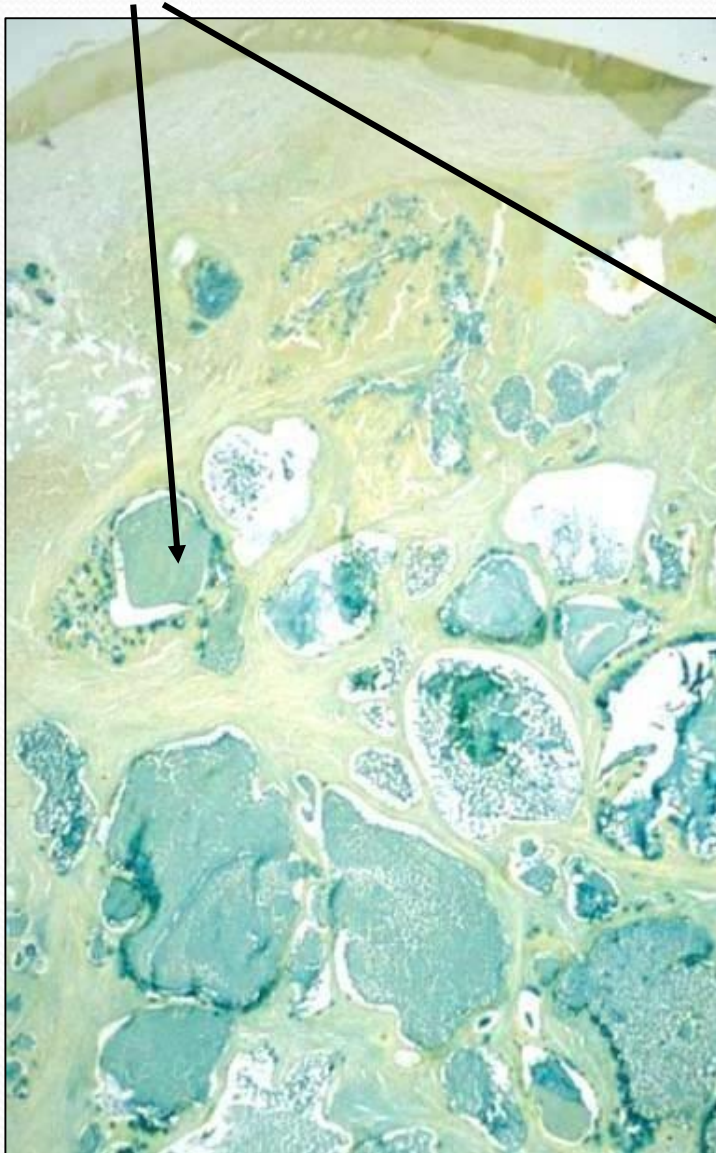
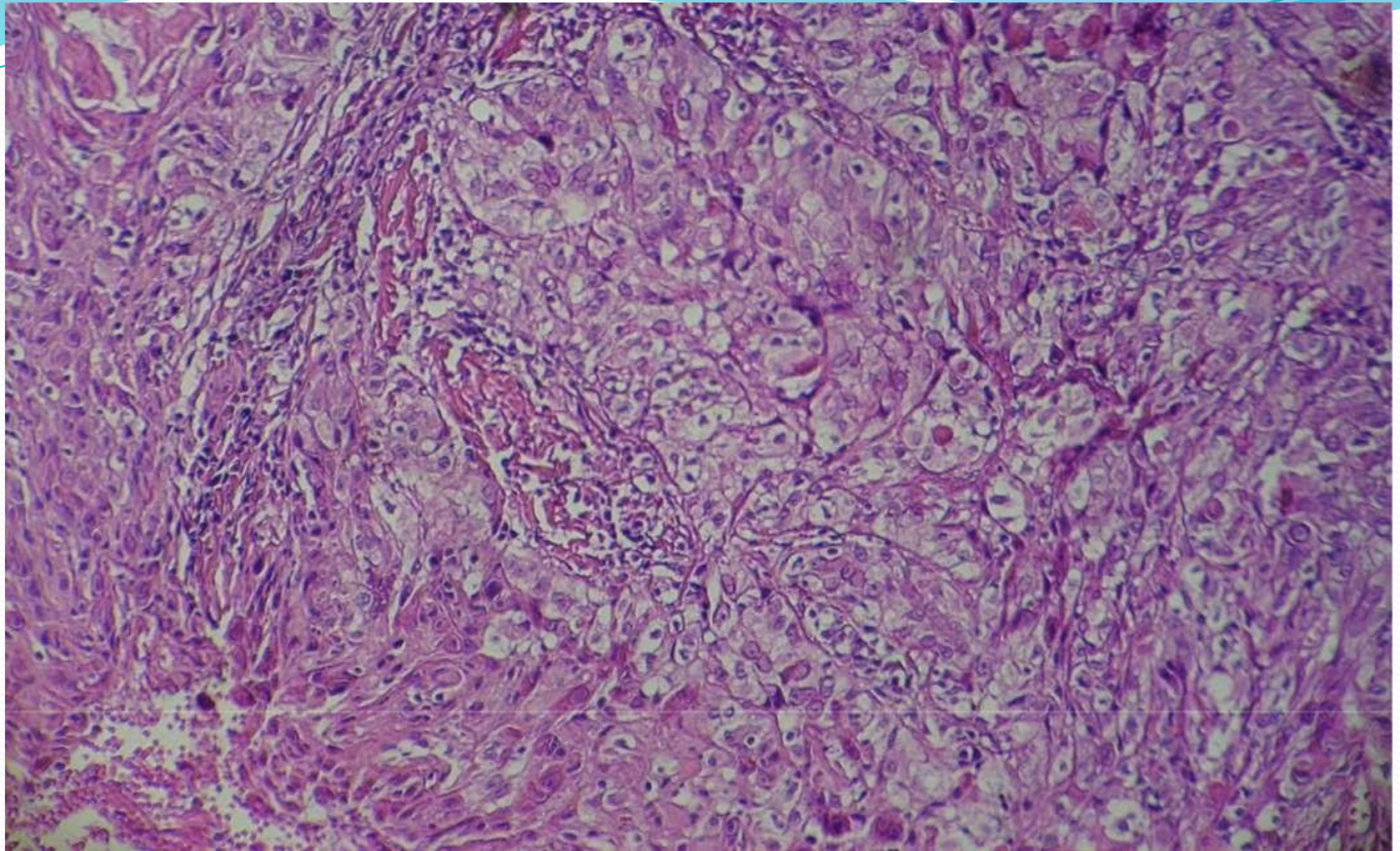


Fig. 7.02 A Low-grade mucoepidermoid carcinoma. Cystic ductal spaces lined by mucinous epithelial cells. B Intermediate-grade mucoepidermoid carcinoma. Nests of tumour cells with mucinous, clear and squamoid features with minimal cystic formation. C High-grade mucoepidermoid carcinoma. Poorly differentiated tumour with focal mucin-producing cells.

# Mucoepidermoid carcinoma

Mucus secreting cells and squamous cells





**High-grade mucoepidermoid carcinoma with poorly differentiated, irregular nests of tumor cells and very focal mucinous differentiation.**



## **DIFFERENTIAL DIAGNOSIS:**

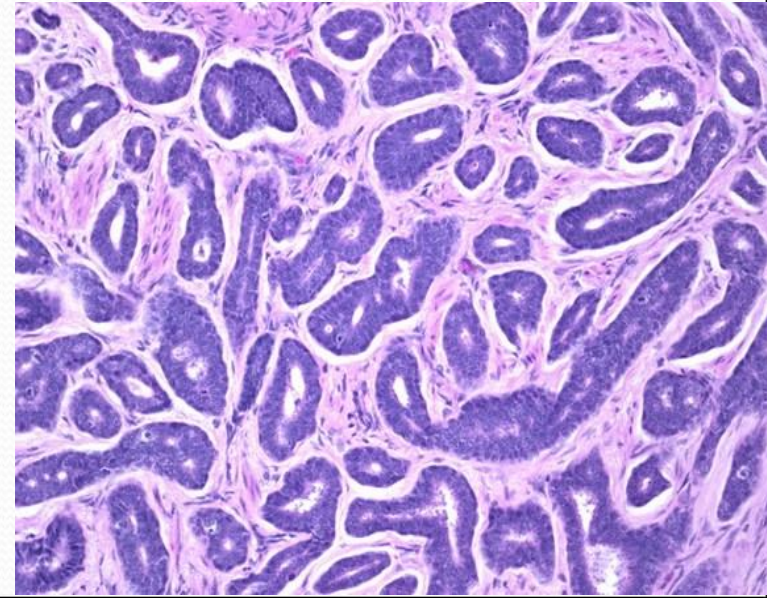
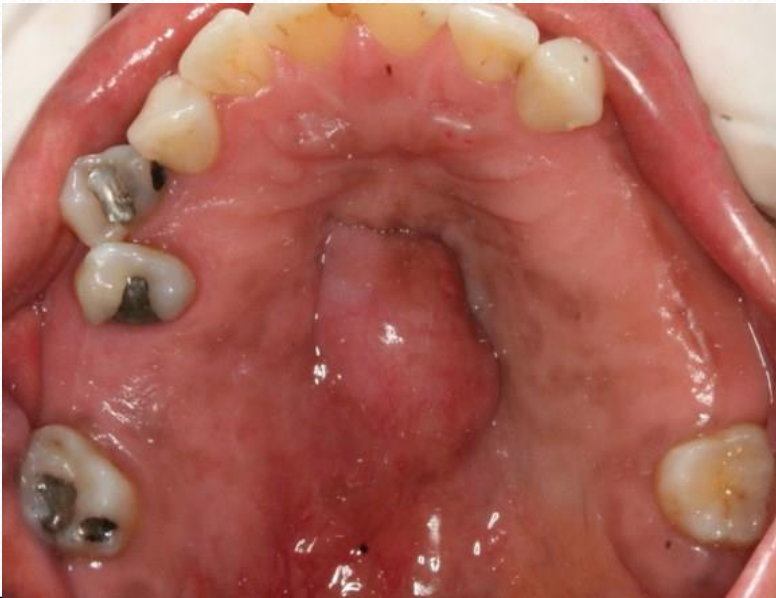- **Necrotizing sialomataplasia**
- **Pleomorphic adenoma**
- **Inverted ductal papilloma**
- **Cystadenoma**
- **Matastatic SCC**
- **Sebaceous carcinoma**
- **Clear cell tumors**
- **Adenosquamous carcinoma**

## **TREATMENT AND PROGNOSIS:**

- **Conservative excision with preservation of facial nerve**
- **Submandibular gland- removal of the gland**
- **Minor salivary gland- surgical**
- **Matastatis- 12% of cases**
- **Prognosis- fairly good.**

# Adenoid cystic carcinoma

- Average age 57 years
- Typically it is represented by a whitish gray mass, not infiltrated, encapsulated of variable size
- Major salivary glands
- Ductal and myoepithelial cells
- Tubular, cribriform and solid pattern



# Adenoid cystic carcinoma

- Prognosis - Overall 10-year survival rate: 50-70%, variable recurrence rate
- Lymph node involvement is not uncharacteristic, but is more common in the solid variant
- Distant metastases are reported in 50% of cases
- Mt in the lungs followed by bones, liver and brain
- In general, tumors with a tubular and cribriform pattern are less aggressive than those with a solid component that constitutes a 1/3.

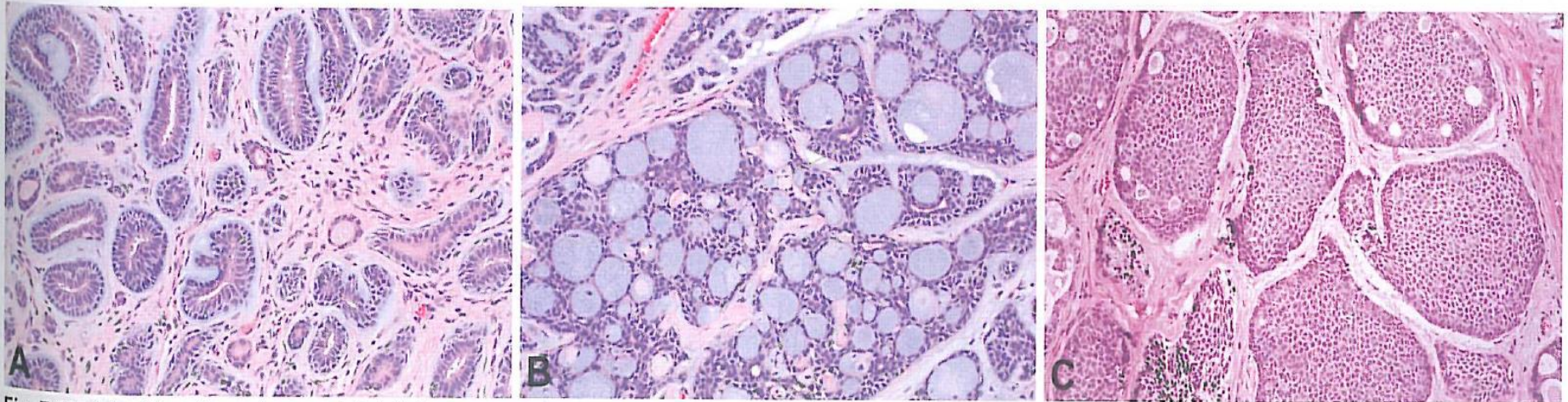


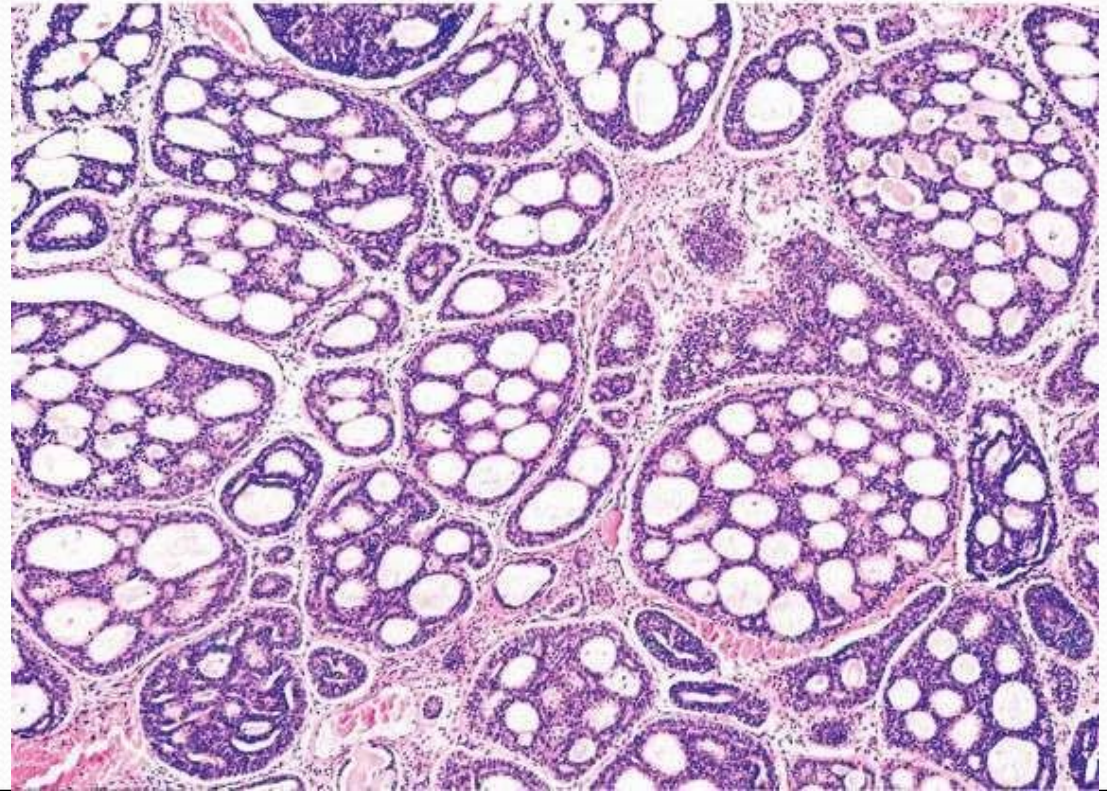

Fig. 7.05 Adenoid cystic carcinoma. A,B Cribriform type with sharply defined round spaces filled with lightly basophilic myxoid ground substance. C Cellular nodules formed of homogeneous cellular proliferation with occasional ductal formation.

## **HISTOPATHOLOGIC FEATURES:**

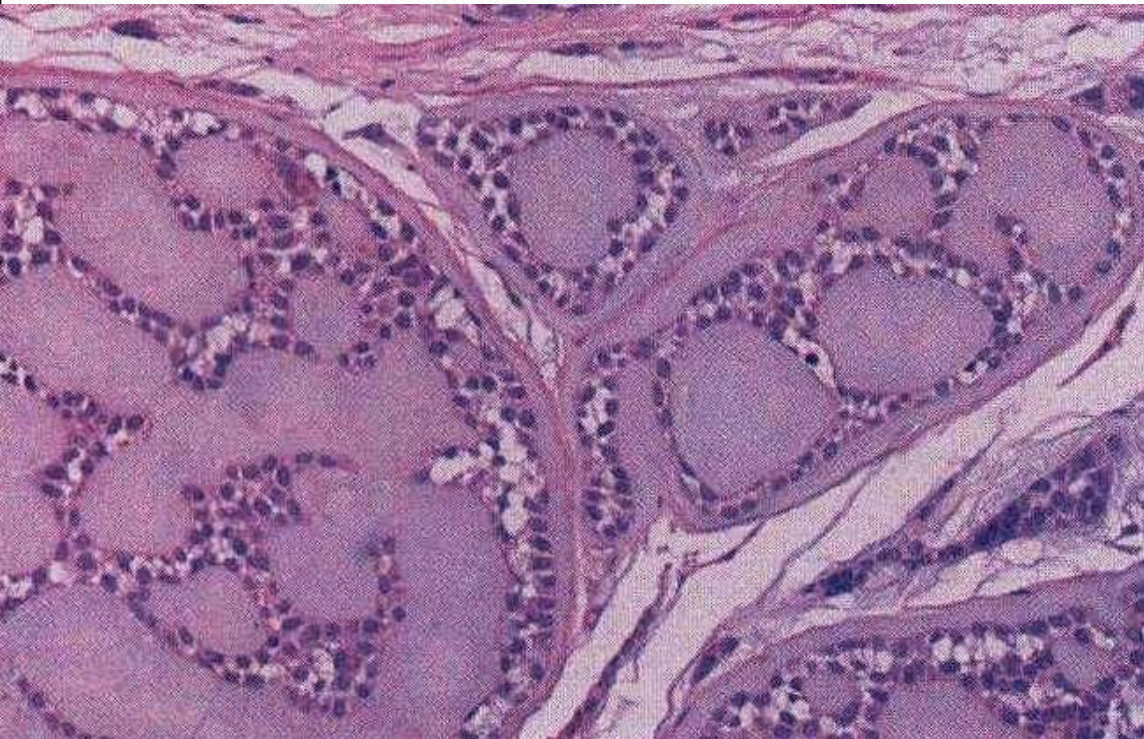
- **The adenoid cystic carcinoma is composed of a mixture of myoepithelial cells and ductal cells that can have a varied arrangement.**
- **Three major patterns are recognized;**
  - **(1) Cribriform**
  - **(2) Tubular**
  - **(3) Solid.**
- **Usually a combination *at these is seen, and the tumor is classified based on the predominant pattern.***

## **Cribriform pattern:**

- **The cribriform pattern is the most classic and best recognized appearance, characterized by islands of basaloid epithelial cells that contain multiple cylindrical, cyst like spaces resembling Swiss cheese or honeycomb pattern.**



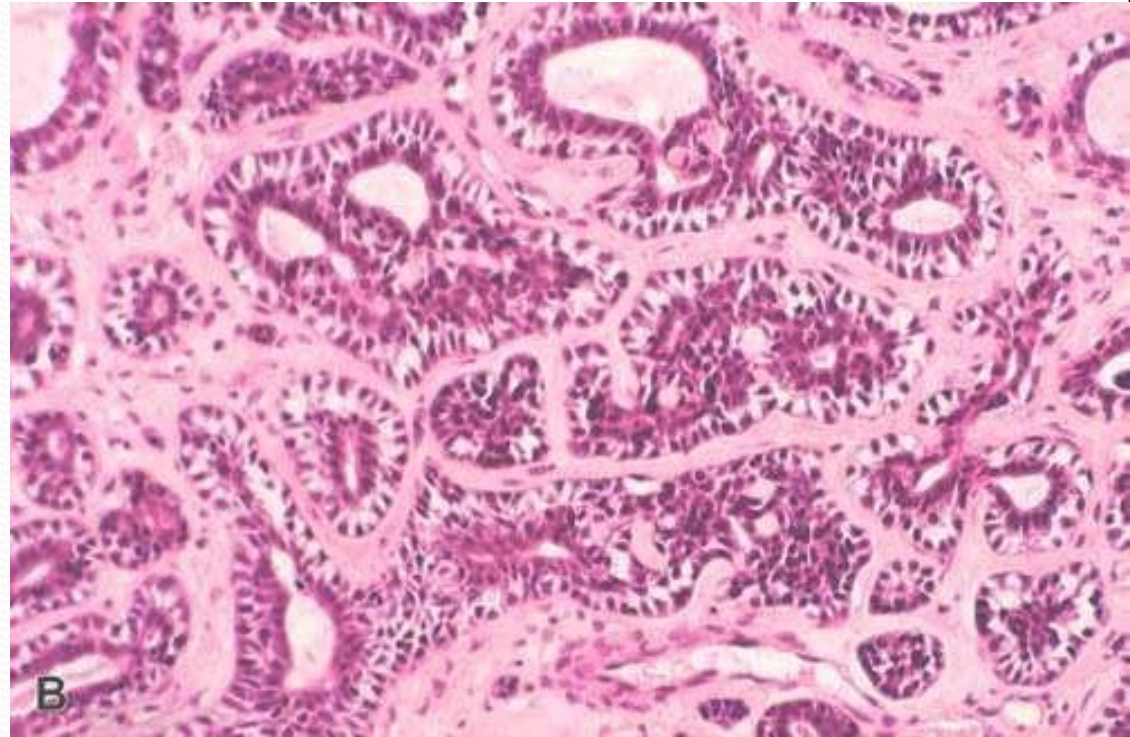
- **These spaces often contain a mildly basophilic mucoid material a hyalinized eosinophilic product , or a combined mucoid hyalinized appearance.**
- **Sometimes the hyalinized material also surrounds these cribriform islands.**



**Adenoid cystic carcinoma.  
The tumor cells are  
surrounded by hyalinized  
material**

## **Tubular pattern:**

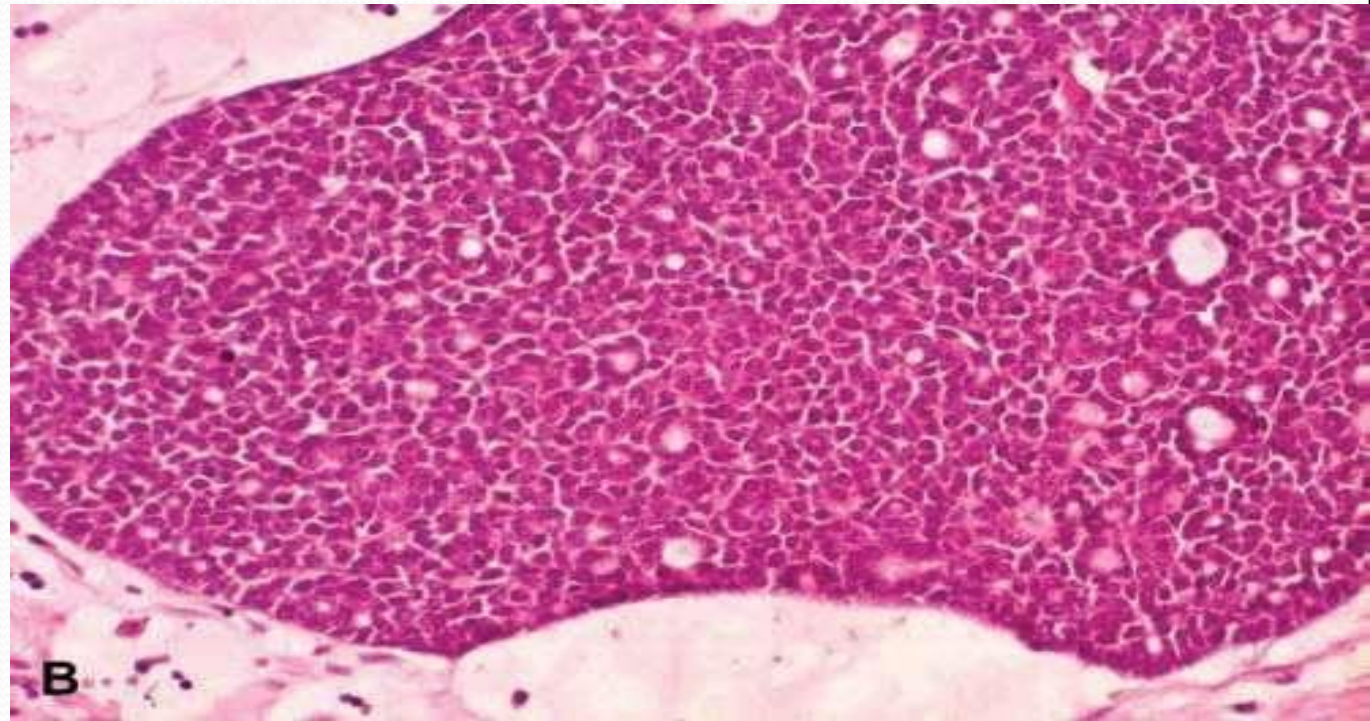
- **Tubular structure that are lined by stratified cuboidal epithelium.**
- **Longitudinal section- ductal structures are viewed as ducts or tubules.**
- **Lumina contains mucinous substance- PAS positive**
- **Cribriform pattern may exist with tubular pattern.**



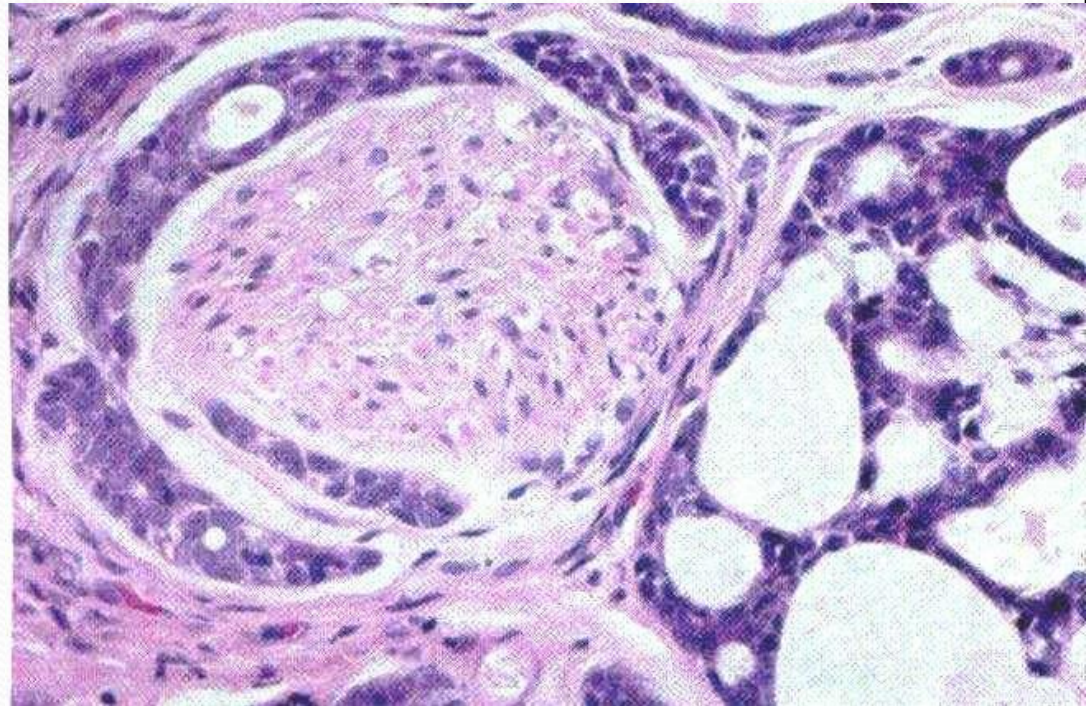


## **Solid pattern:**

- **Solid groups of cuboidal cells with little tendency towards ducts or cyst formation.**
- **Arranged in nests or sheets of varying size and shape.**
- **Areas of necrosis seen**
- **Cellular pleomorphism, mitosis observed.**

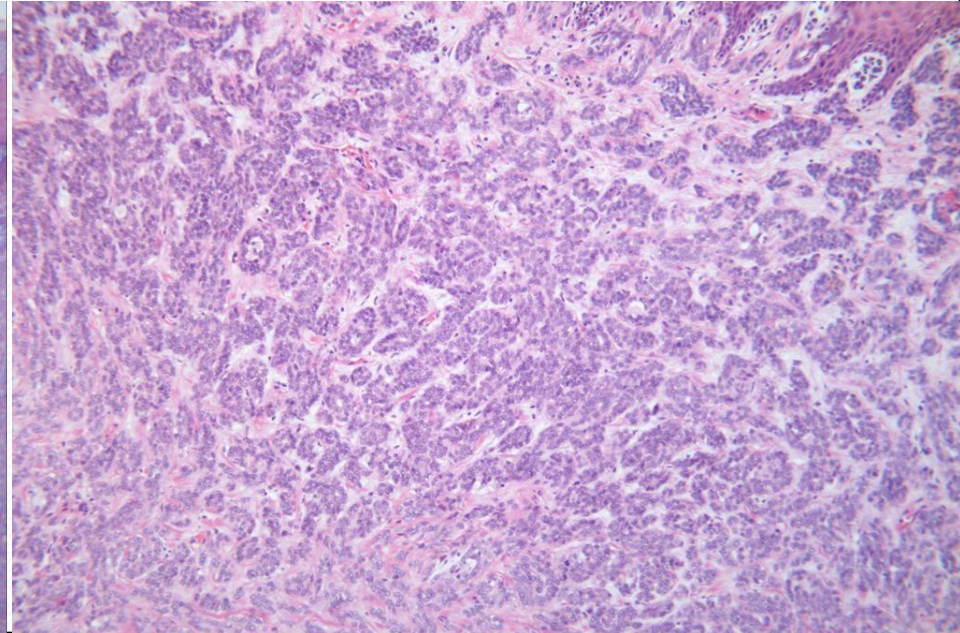
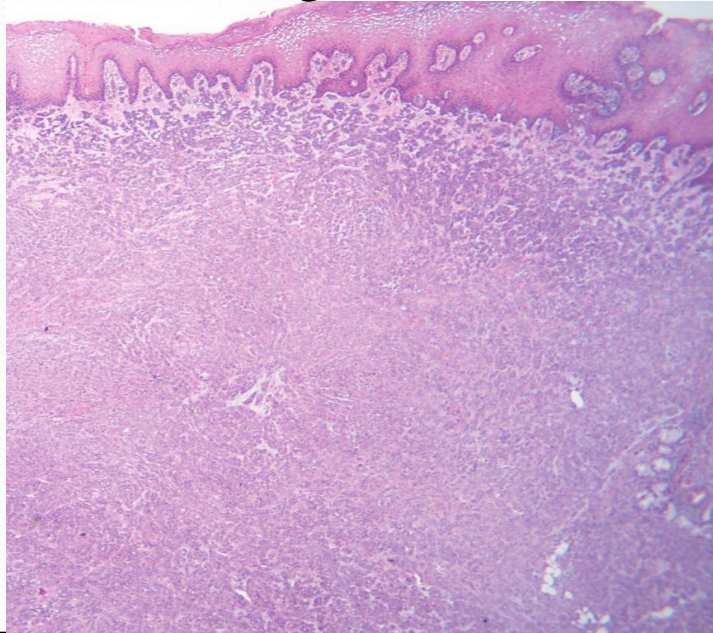


**Adenoid cystic carcinoma.  
Perineural invasion.**



# Pleomorph adenocarcinoma

- Variable cytoarchitectural pattern, infiltrative growth, low metastatic potential
- It develops from the terminal ducts
- The second malignant neoplasm of S.G. achieving 26%
- 19-94 years, average age 59
- 60% of tumors develop in the palate
- Unencapsulated circumscribed mass, yellowish-brown of variable dimensions (average 2.1 cm.)



# Polymorphic adenocarcinoma - perineural invasion

Variable pattern - lobular, microcystic, cribriform, trabecular, solid.

