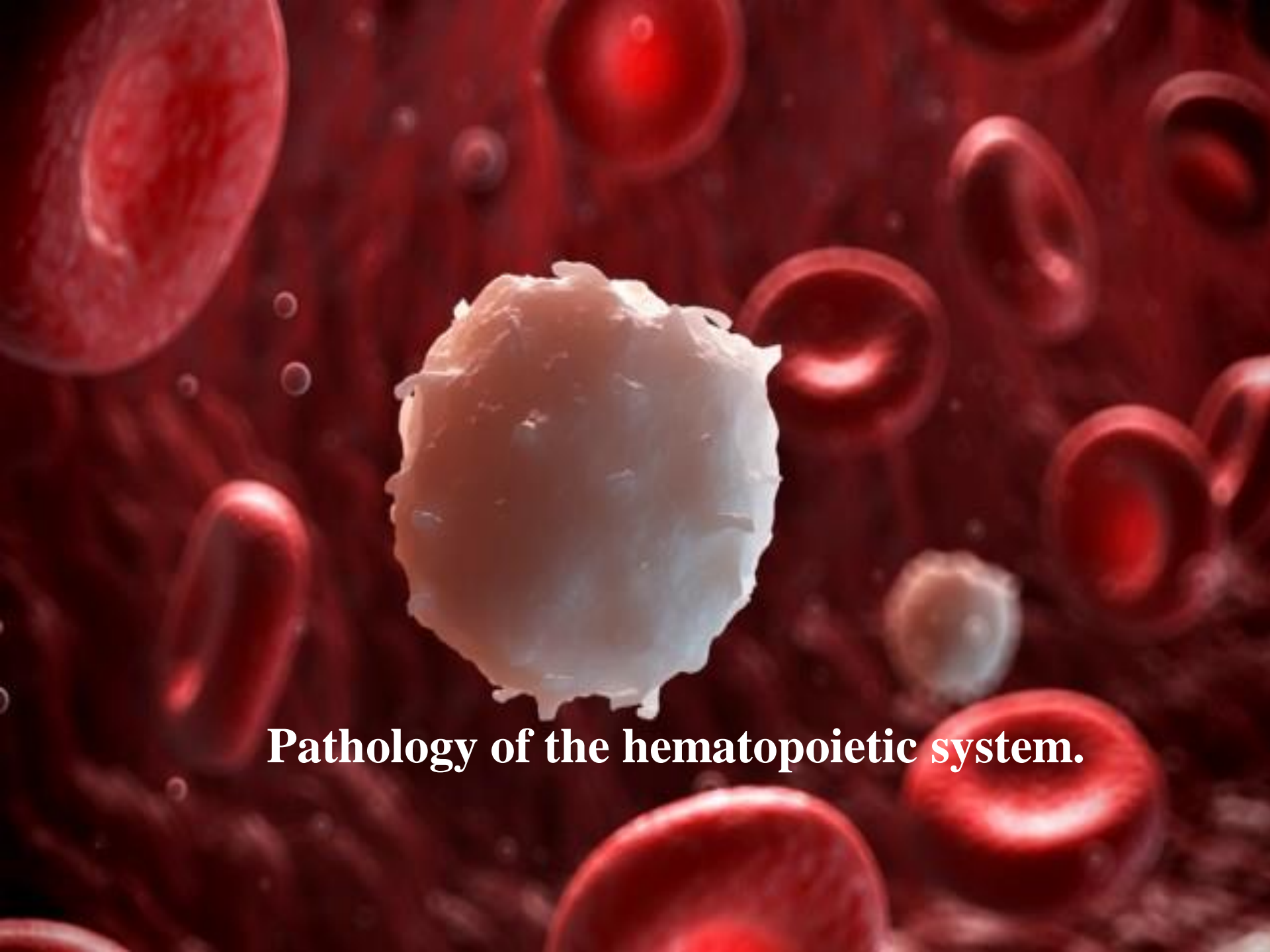



Pathology of the hematopoietic system.

Pathology of the hematopoietic system.

I. Microspecimens:

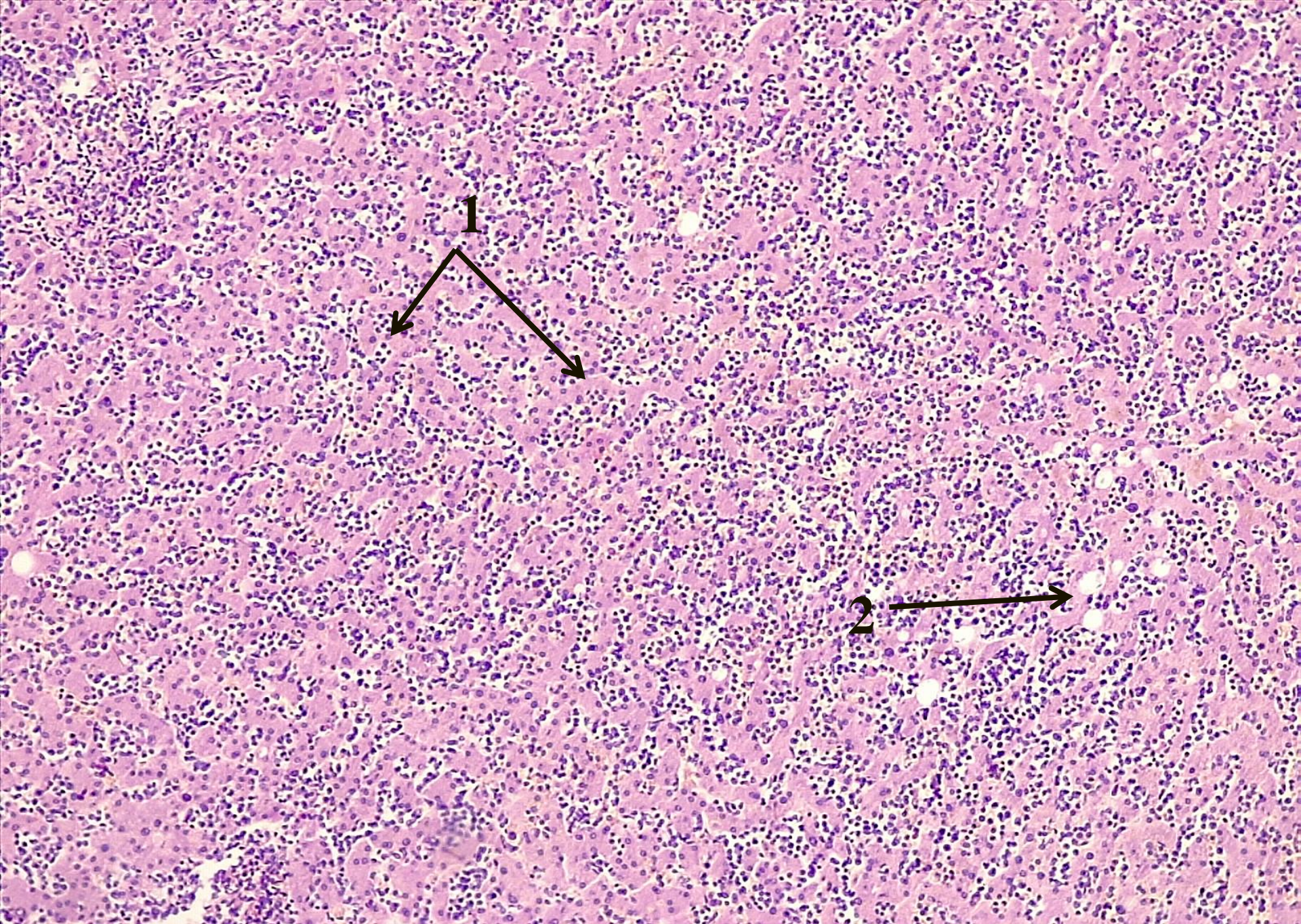
№ 56. Liver in CML (chronic myeloid leukemia). (*H-E stain*).

Indications:

1. Proliferation of tumor cells of myeloid origin along intralobular sinusoidal capillaries.
2. Hepatic cords.

The hepatic parenchyma reveals the diffuse infiltration of the sinusoidal capillaries with leukemic cells from the myeloid series, predominantly myelocytes and metamyelocytes, in the liver cells dystrophic changes, steatosis.

Chronic myeloid leukemia represents ~ 20% of the total number of leukemias in adults, the peak being in the age period 30-40 years. The main morphological substrate consists of excessive hematopoiesis of the granulocyte series, which can reach up to 100,000 leukocytes / μ l in the peripheral blood. Circulating cells are mature neutrophilic leukocytes, metamyelocytes and myelocytes. The bone marrow is hypercellular, replaced by proliferating myeloid cells, the cellularity of the bone marrow reaches 100%. In 90-95% of cases it is associated with the Ph chromosome (PhPhiladelphia), which occurs through the reciprocal translocation between chromosomes 9 and 22 (BCR-ABL fusion gene). Chronic myeloid leukemia evolves in 3 stages: stable, accelerated and blast crisis. The stable phase has a slow evolution, in patients there is anemia, weight loss, bleeding. The spleen is enlarged in size, it can be massive splenomegaly, on the cut section resembles the bone marrow due to excessive extramedullary neoplastic hematopoiesis, circulatory disorders with infarctions and pain in the left rim appear. The liver is also enlarged, sometimes considerably, due to the diffuse infiltration of sinusoids with leukemic cells. It can be generalized lymphadenopathy. The stable phase within a few years passes into the accelerated phase with the progression of anemia and thrombocytopenia and subsequently in terminal blast crisis with increasing myeloblast content in the spinal cord and peripheral blood; clinical-morphological picture similar to acute myeloid leukemia.



№ 56. Liver in CML (chronic myeloid leukemia). (H-E stain).

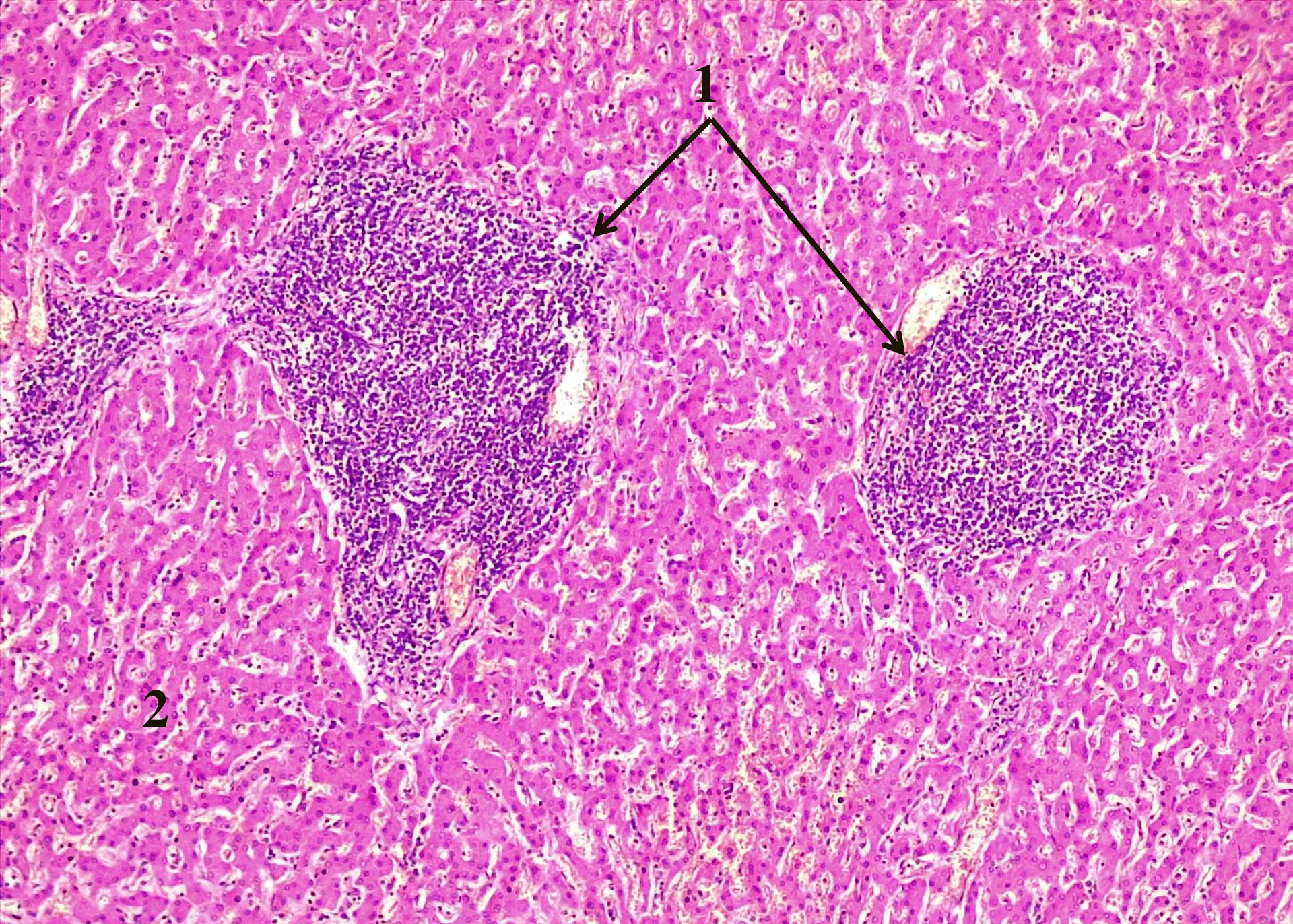
№ 57. Liver in CLL (chronic lymphoid leukemia). (H-E stain).

Indications:

1. Foci of proliferation of tumor cells of lymphoid origin along portal tracts (triads).
2. Hepatic lobule.

With the naked eye in the microspecimen the motley appearance of the section is observed, the microscopic examination reveals multiple focal cell agglomerations, consisting of small lymphocytes, with round nucleus, intensely colored basophilic, with little cytoplasm, located along the interlobular fibroconjunctival septa, in some places in the region of triads, hepatocytes with dystrophic changes, steatosis; leukemic infiltration does not extend into the sinusoidal capillaries.

Chronic lymphocytic leukemia (CLL) is the most common form of leukemia in adults and is identical to small lymphocytic lymphoma (SLL). In LCC, leukemic cells predominate in the peripheral blood, and in SLL - in lymphoid tissues. These lymphoid neoplasms can pass into each other. Most of them are of B-lymphocyte origin. Absolute lymphocytosis of up to 200,000 cells / μ is detected in peripheral blood in CLL, with small mature lymphocytes constituting more than 90% of leukocytes. Morphological lesions: 1) in the bone marrow there is a diffuse proliferation of small lymphocytes, which replace the normal hematopoietic tissue, causing anemia, neutropenia, thrombocytopenia; 2) generalized lymphadenopathy; 3) splenomegaly, sometimes massive, with proliferation of small lymphocytes in the white pulp; 4) hepatomegaly, which can be also massive. In patients with CLL, there are autoimmune reactions with autoantibodies against erythrocytes and platelets, bleeding, distorted immune response and increased susceptibility to infections.



№ 57. Liver in CLL (chronic lymphoid leukemia). (H-E stain).

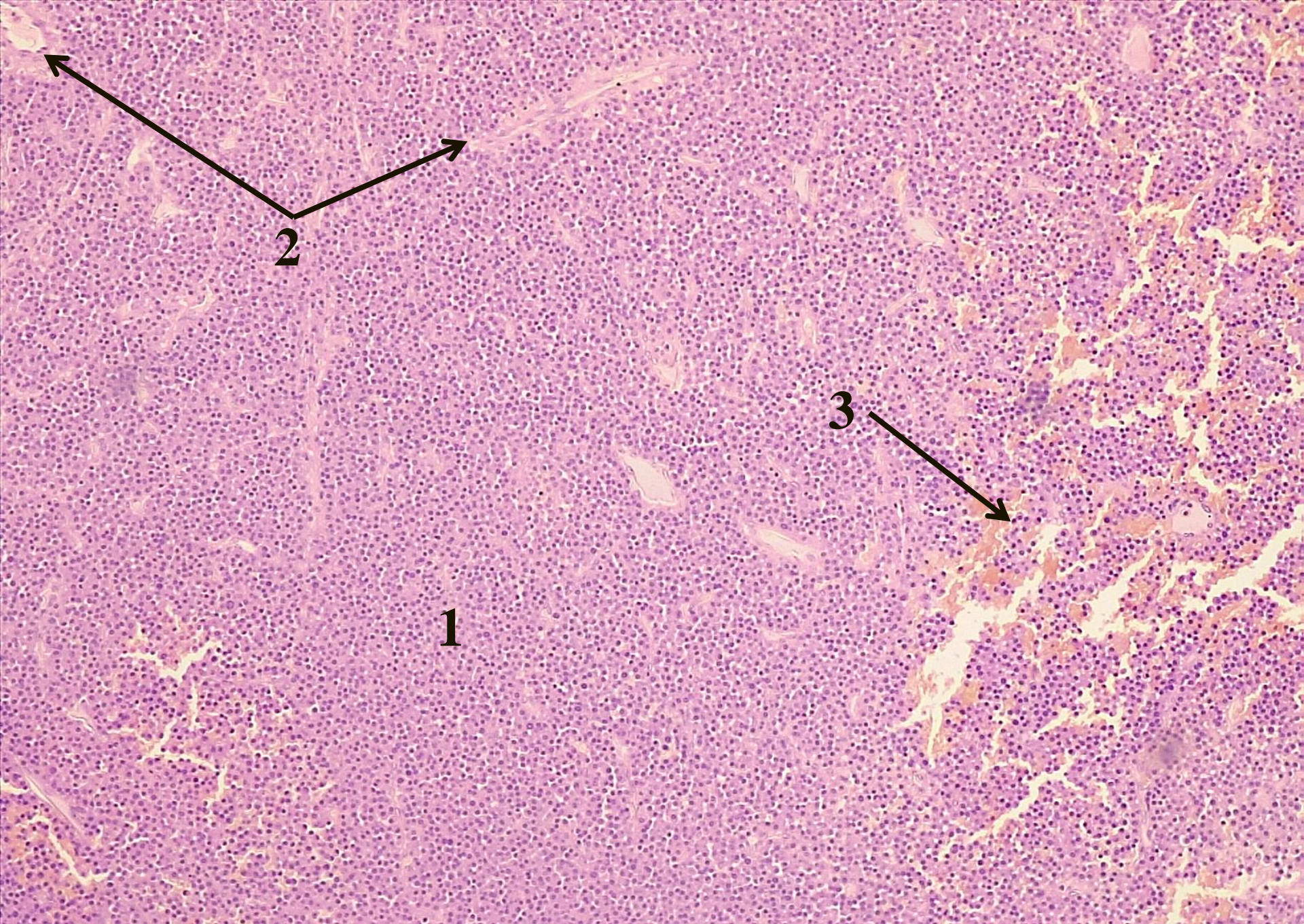
№ 145. Plasmocytoma. (H-E stain).

Indications:

1. Polymorphic tumoral cells of plasmocytic origin.
2. Tumoral stroma with blood vessels.
3. Hemorrhagic foci.

The biopsy was taken from a solitary tumoral node from the region of the skull vault. Microscopically there is a cell mass, composed predominantly of tumoral plasma cells, most of them similar to normal plasma cells, with eccentric nucleus, hyperchrome, chromatin arranged "in wheel spokes", rich cytoplasm, basophilic, with perinuclear halo, absent nucleoli, larger plasmoblasts are observed, the nucleus with a well-defined nucleoli, the tumor stroma is poor, there are foci of plasmorrhagia and hemorrhage.

Solitary plasmacytoma (localized) and multiple myeloma are the main diseases in the group of plasma cell neoplasms, the morphological substrate of which is the excessive, neoplastic proliferation of plasma cells. The lesions begin in 95% of cases in the medullary cavity of the bones and gradually erode the spongy bone tissue, and later the compact one, causing pathological fractures. In solitary plasmacytoma, a single bone is affected, and in multiple myeloma the lesions are multifocal, involving bones with active hematopoiesis: spine, ribs, skull, pelvic bones and a. Solitary plasmacytoma is an early stage of multiple myeloma, progressing within 5-10 years from monoosal to polyosal lesions. The affected bones take on a "moth-eaten" appearance, with defects having a diameter of 1-4 cm. The cellularity of the bone marrow is increased, over 30% being the plasma cells. Tumor cells secrete an immunoglobulin, usually IgG (monoclonal secretion) or light chains of immunoglobulins, which are excreted in the urine - the Bence-Jonck protein. Very important is myelomatous nephropathy, which is manifested by deposits of protein cylinders in the distal tubules and collecting ducts, necrosis of the epithelium of the twisted tubules, metastatic calcinosis, bacterial pyelonephritis, AL amyloidosis. In the terminal stage, the multiple plasmacytoma / myeloma acquires a leukemic appearance. Complications: bone fractures, anemia. Causes of death: renal failure, infectious complications.



№ 145. Plasmocytoma. (H-E stain).

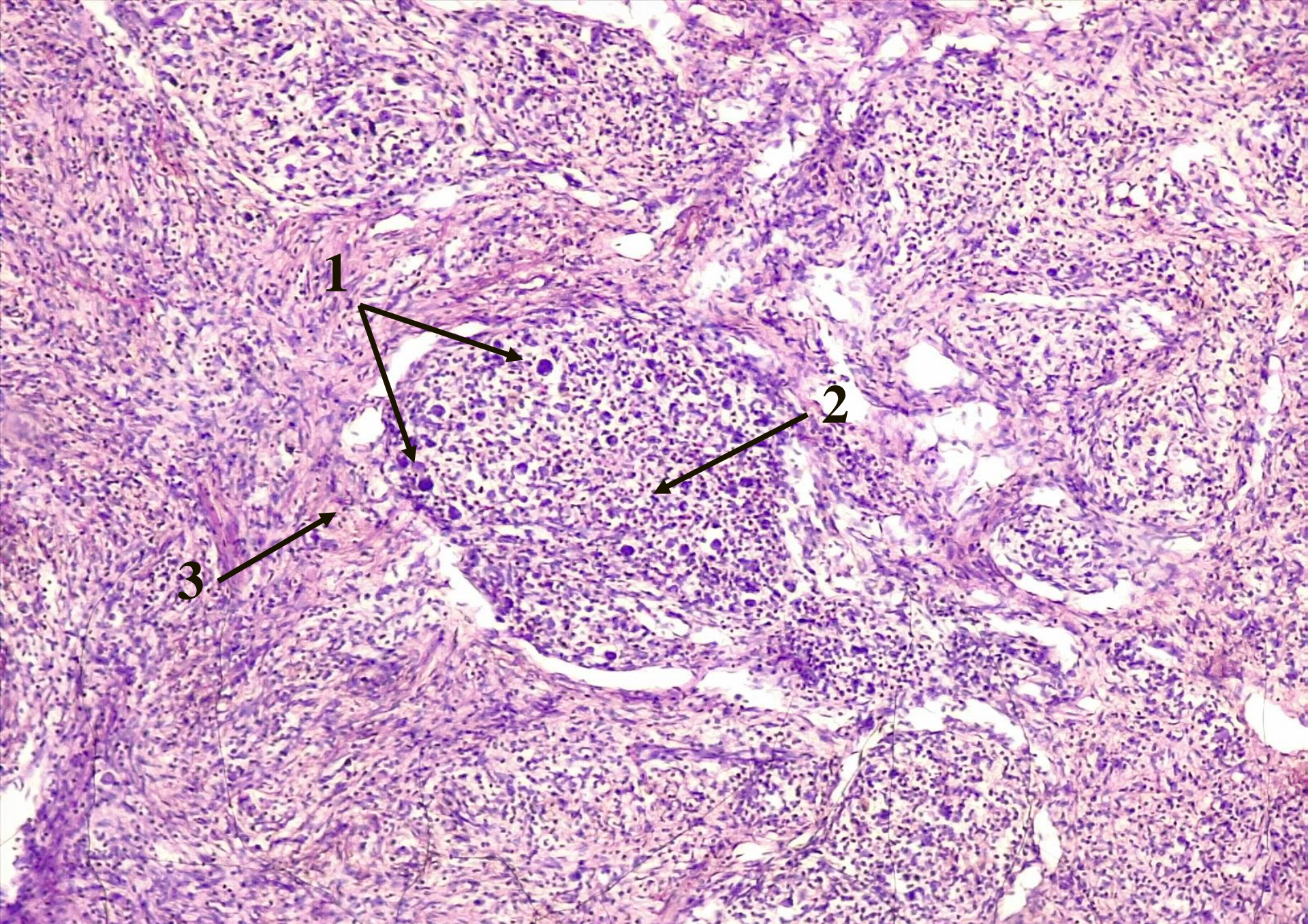
№ 58. Lymph node in Hodgkin's disease (*nodular sclerosis type*). (*H-E stain*).

Indications:

1. Giant polynuclear Reed-Sternberg cells.
2. Lymphocytes.
3. Bundles of newly formed connective tissue.

The microspecimen reveals tumor nodules, consisting of different cellular elements: 1) giant Reed-Sternberg cells, up to 45 μ in diameter, binucleated, with 2 nuclei arranged symmetrically as in a mirror, with prominent nucleoli with a clear perinucleolar halo "owl eyes", 2) large mononuclear Hodgkin cells, 3) lacunar cells (mononuclear cells, with multilobate nucleus, multiple nucleoli and abundant, pale cytoplasm), 4) non-tumoral inflammatory infiltrate with lymphocytes, histiocytes, eosinophils, neutrophils and plasmocytes in various proportions; tumor nodules are separated by collagen bundles of different thickness.

LH is a neoplasm that develops from B lymphocytes in germinal centers. It constitutes on average ~ 30% of the total number of lymphomas. There are 4 classic histological forms (subtypes) of LH: 1) with nodular sclerosis, 2) with mixed cellularity, 3) with lymphocyte predominance and 4) with lymphocyte depletion. The most common are the first 2 - with nodular sclerosis ~ 65-75% and with mixed cellularity ~ 25%. The morphological substrate consists in the proliferation of pathognomonic tumor cells - Reed-Sternberg (RS) cells and their derivatives: lacunar cells, which are a particular form of RS cells and Hodgkin cells, which are the precursors of RS cells. These tumor cells represent only 1-5% of the total cell mass, the other cellular elements are of reactive, inflammatory origin. Immunohistochemical studies have demonstrated with certainty the B lymphocyte origin of RS cells. Although the number of specific tumor cells is so small, the definite diagnosis of LH is established only on the basis of the identification of RS cells or their variants in the biopsy or necropsy material.



№ 58. Lymph node in Hodgkin's disease (*nodular sclerosis type*). (H-E stain).

II. Macrospecimens:

№ 145. Bone marrow in leukemia.

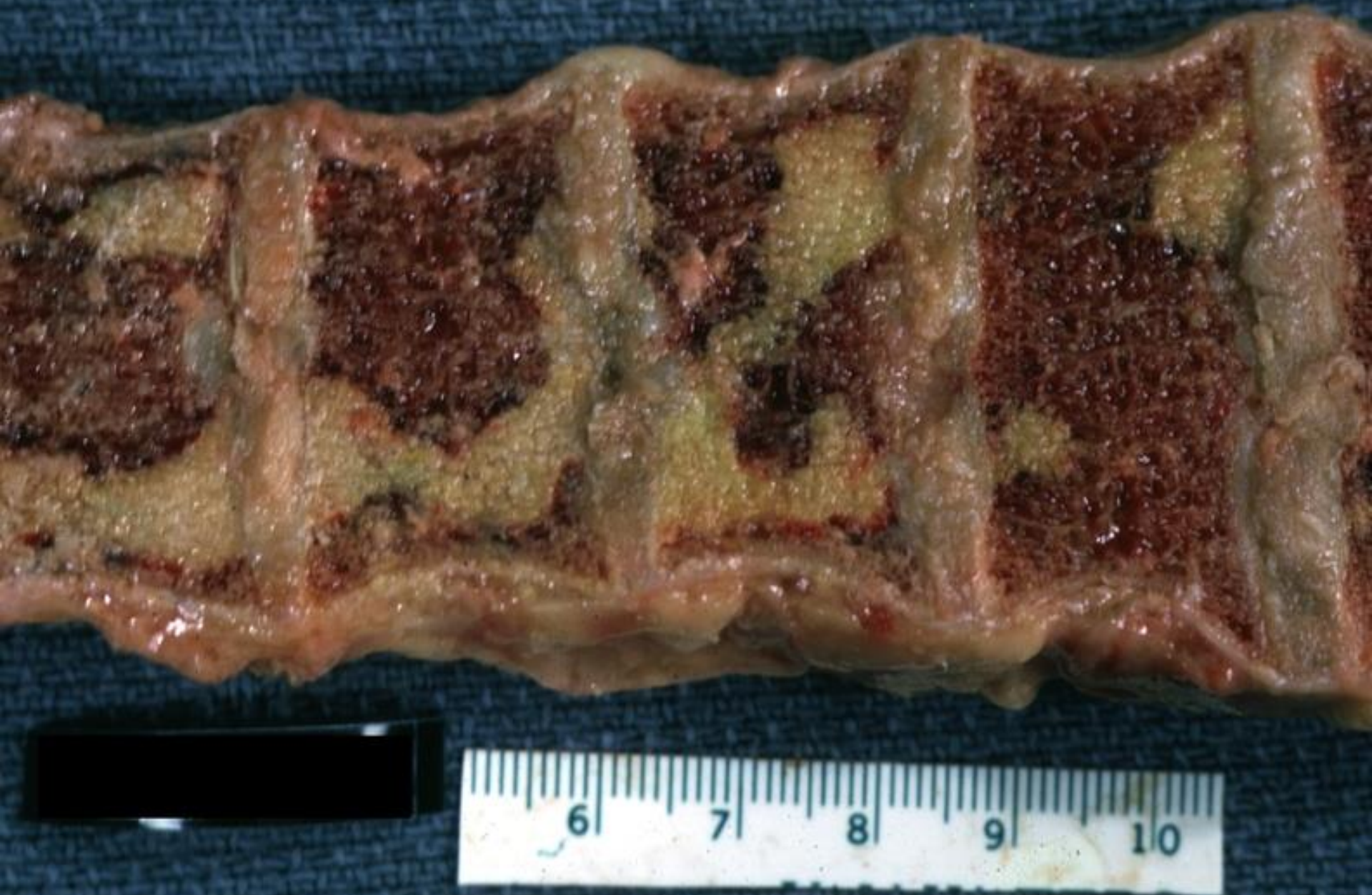Longitudinal section of the femoral bone, the osteomedullary tissue is homogeneous, juicy, the division into red and yellow marrow is absent, the adipose tissue in the diaphysis region is replaced by active hematopoietic tissue, the color is gray-yellow, has a purulent appearance ("pious bone marrow").

In leukosis the bone marrow is affected primarily, namely in the marrow the tumor process begins, and the peripheral blood and other organs are involved secondarily. The neoplastic proliferation of a cell series takes place in the spinal cord, which gradually replaces the other components of the hematopoietic tissue, and from the spinal cord leukemic cells enter the blood and infiltrate other organs, primarily the organs / tissues of the lymphoid system, but also the central parenchymal organs. , skin, etc. Microscopically in the marrow is revealed the increase of cellularity, which can reach the level of 100%, the norm being 50% hematopoietic tissue / 50% adipose tissue. These changes in the hematopoietic marrow are observed in both acute leukosis and chronic leukosis in their accelerated phase and blastic crises.

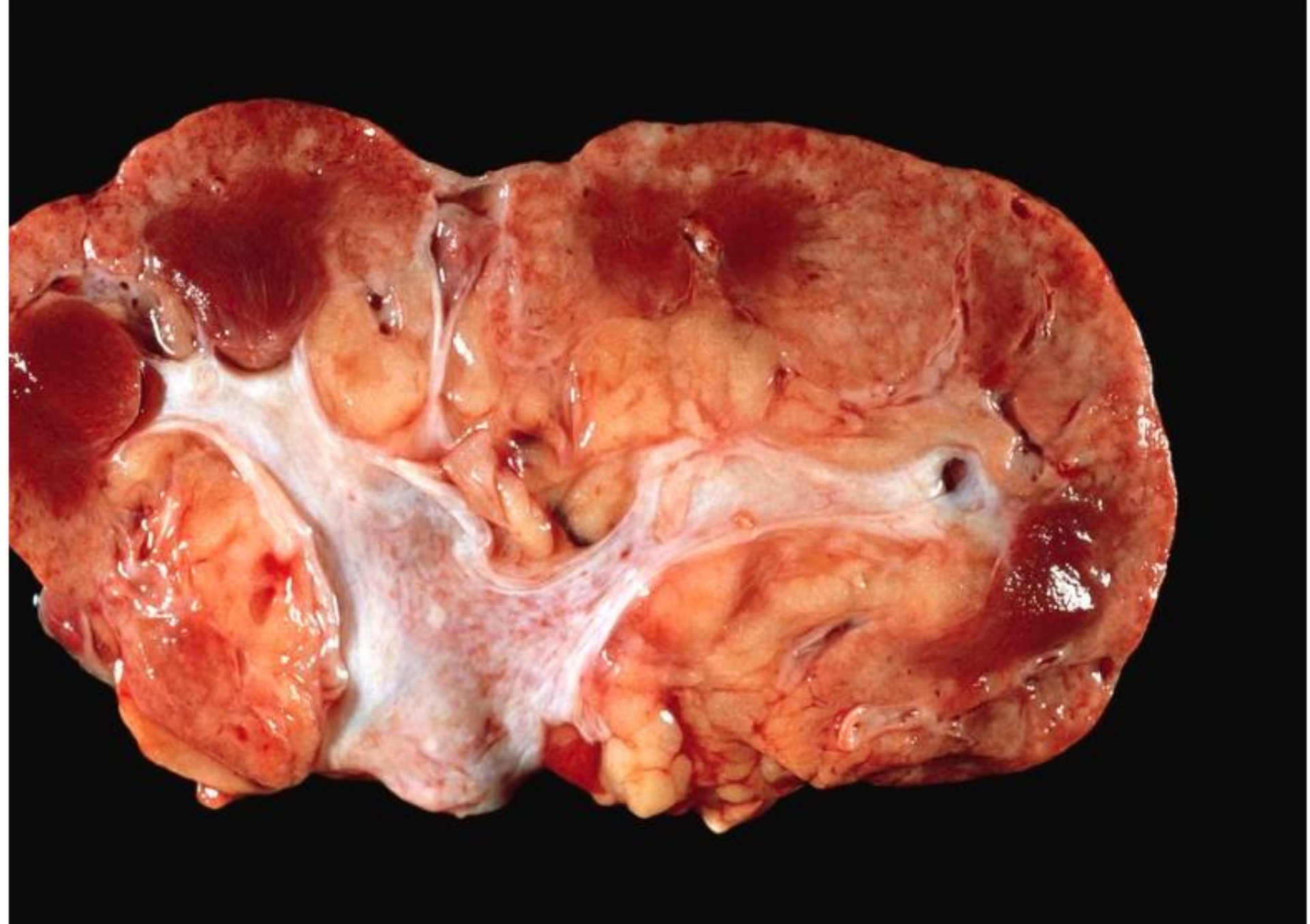№ 84. Kidney in leukemia.

The kidney is enlarged in size, the capsule is relaxed, the consistency is dense, on the cut section the borders between the layers are absent, have a whitish-gray color, with punctiform hemorrhages. Kidney damage can occur in any form of leukosis and is caused by infiltration of the organ with neoplastic elements from the spinal cord, which is initially located perivascular, and later leukemic infiltrates may become more or less extensive.

Due to this fact and circulatory disorders caused by leukemic infiltration of the vascular walls and increased blood viscosity, dystrophic changes of the renal parenchyma occur, there may be foci of necrosis and hemorrhage.



№ 145. Bone marrow in leukemia.



№ 84. Kidney in leukemia.

№ 142. Spleen in CML (chronic myeloid leukemia).

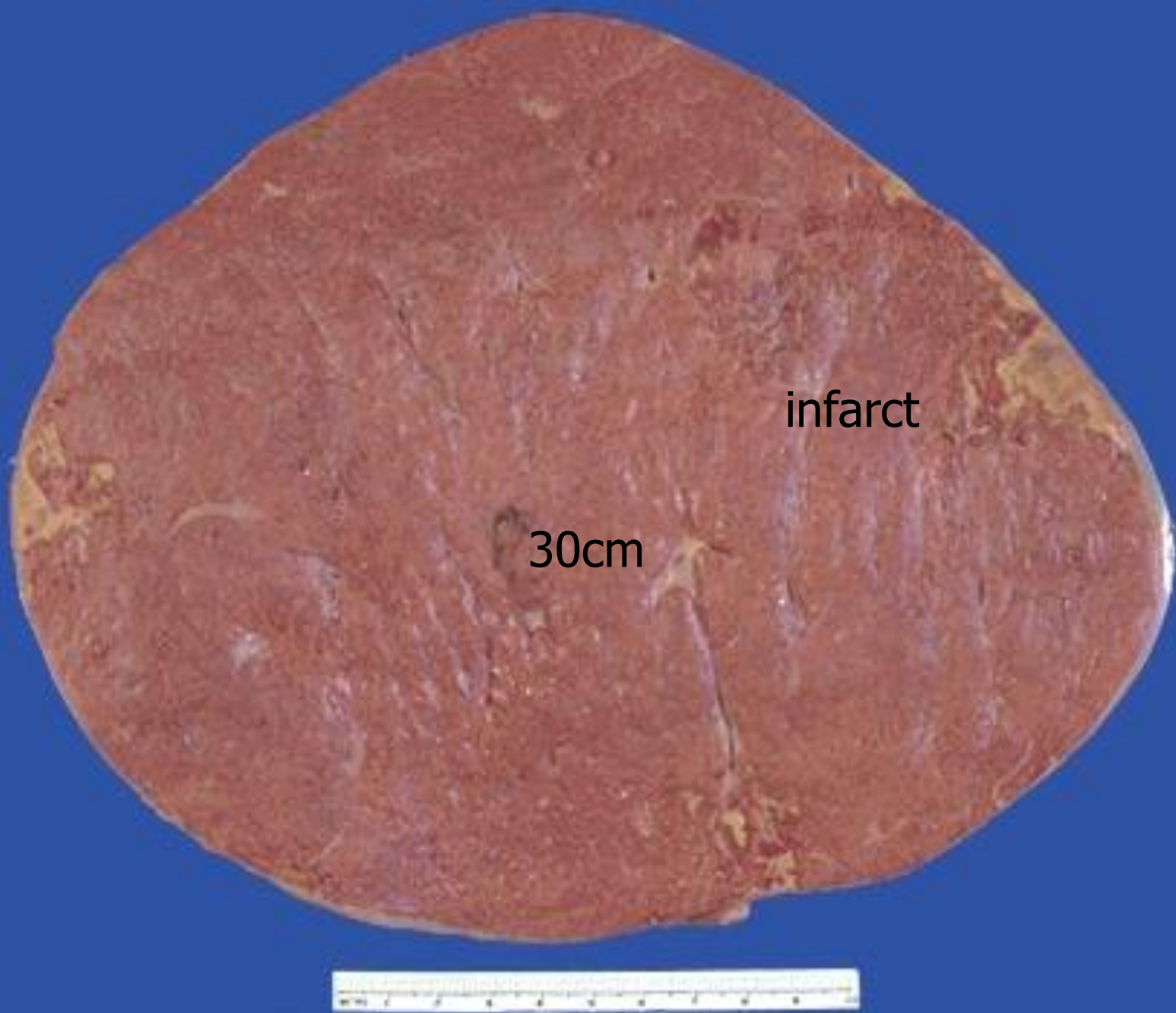
The spleen is considerably enlarged in size, sometimes 20-30 times, the mass reaching a few kg (norm ~ 180 gr), per section reddish-gray color, homogeneous, dense consistency, there may be foci of ischemic infarction and hemorrhage.

Massive splenomegaly, which is revealed in chronic myeloid leukosis is caused by intense leukemic infiltration, diffuse with cells from the myeloid series, predominantly with myelocytes and metamyelocytes; Outbreaks of infarction are caused by increased blood viscosity, which can sometimes lead to leukemic thrombi. Fibrin deposits (perisplenitis), cracks may be deposited on the spleen capsule, it is possible to rupture the capsule with lethal intraperitoneal hemorrhage.

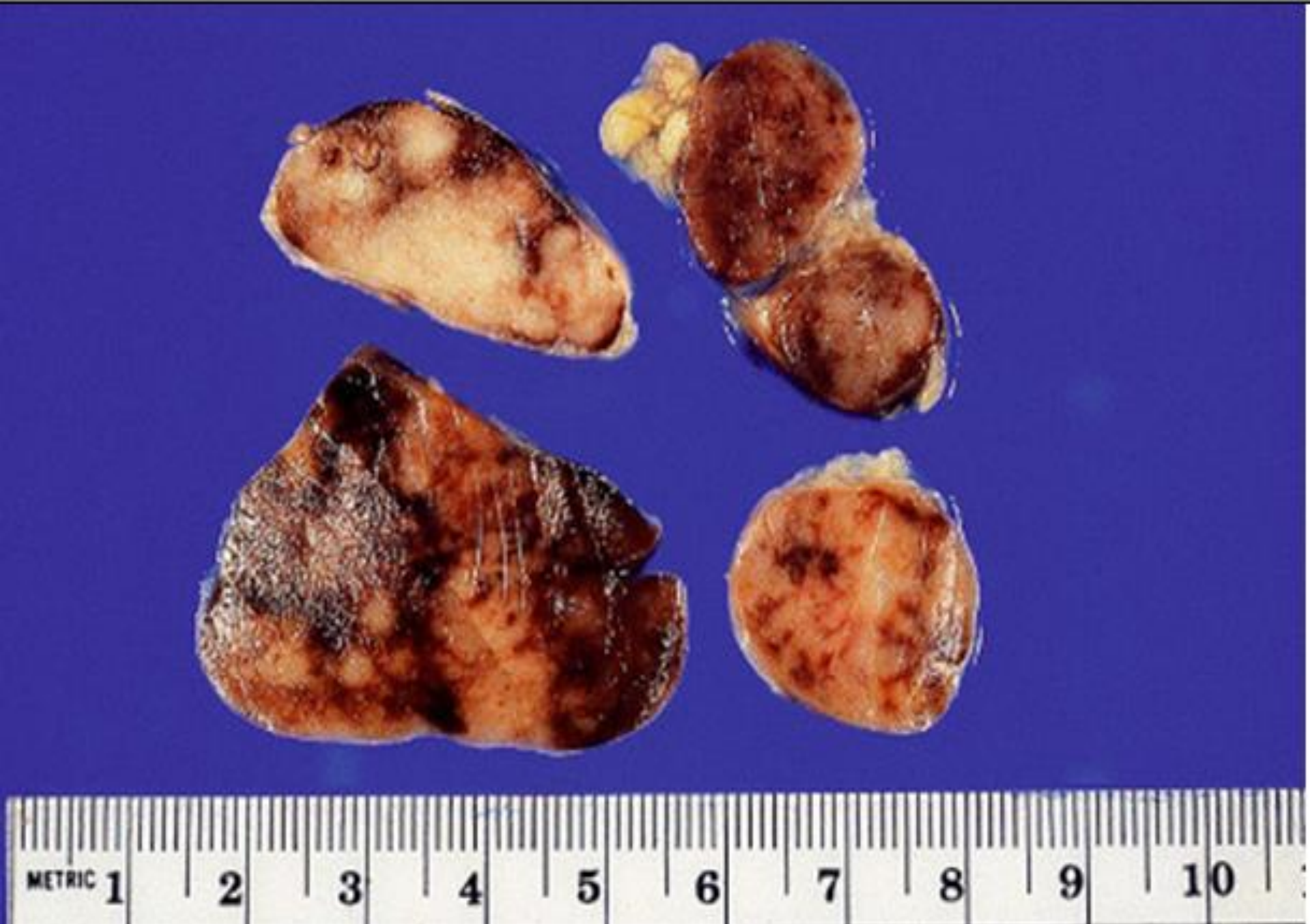
№ 143. Mesenterial lymph node in CLL (chronic lymphoid leukemia).

The lymph nodes are uniformly enlarged in size, dense-elastic consistency, whitish color, form tumor conglomerates, which compress the adjacent organs.

Generalized lymphadenopathy is the predominant clinical-morphological sign of chronic lymphoid leukosis. The lymph nodes are symmetrically enlarged in size, microscopically reveals diffuse infiltration with small mature, uniform lymphocytes, without atypia; foci of proliferation are also observed with larger, mitotically active lymphocytes, without precise limits. 80% of chronic lymphocytic leukosis comes from B-lymphocytes. Although the number of neoplastic lymphocytes is considerably increased, they are immunologically inactive, leading to hypogamaglobulinemia, decreased humoral immunity with infectious complications, and autoimmune reactions, primarily hemolytic anemias and autoimmune thrombocytopenias.



№ 142. Spleen in CML (chronic myeloid leukemia).



№ 143. Mesenterial lymph node in CLL (chronic lymphoid leukemia).

№ 146. Lymph nodes in Hodgkin's disease.

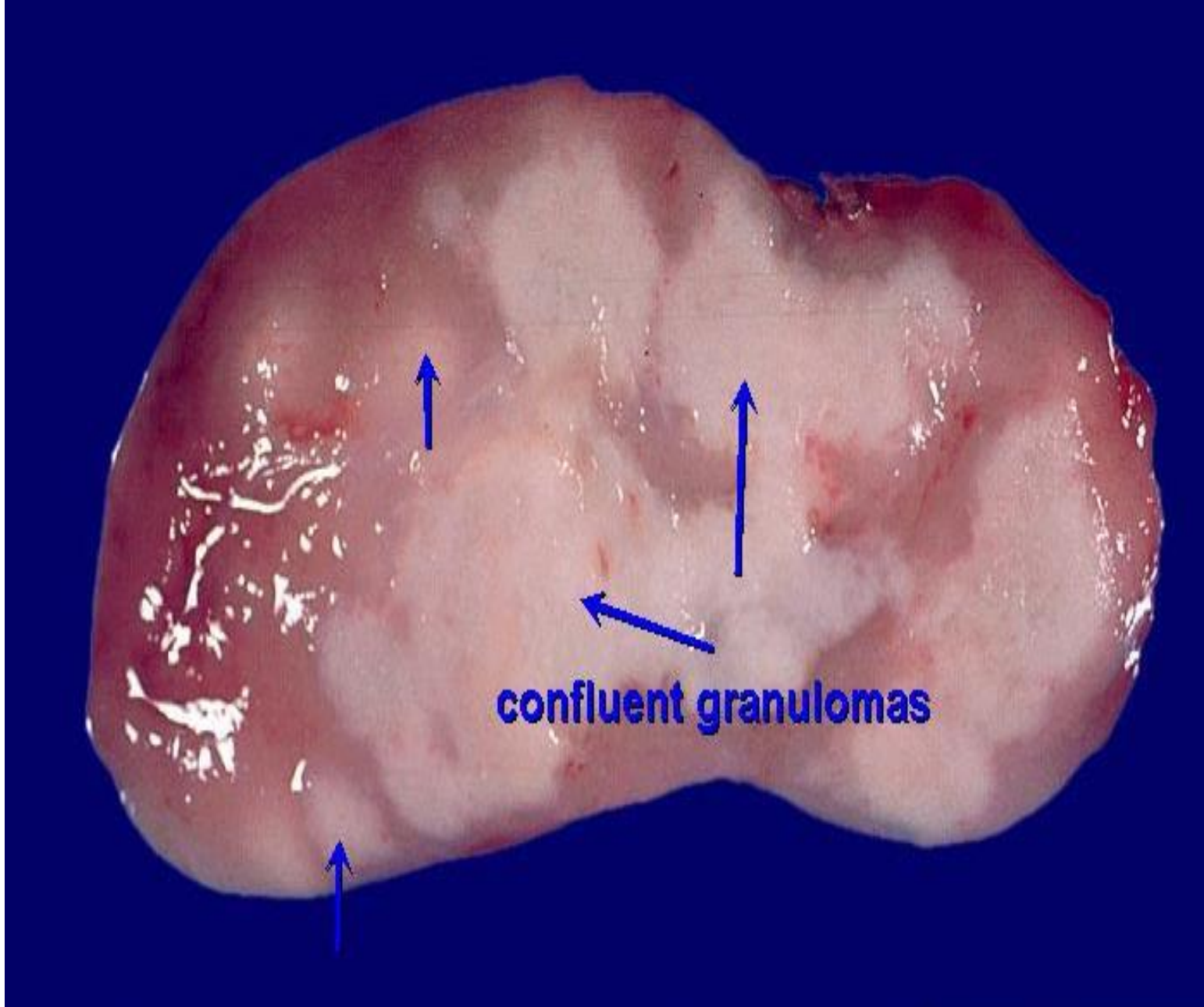
The lymph nodes are unevenly enlarged in size, of dense consistency, light-whitish color, adhere to each other due to infiltration of perinodular connective tissue, on a motley-looking section, white-yellow foci of necrosis and fibrosis.

Hodgkin's lymphoma begins in a single lymph node or in a group of lymph nodes, usually cervical, supraclavicular, or axillary. Subsequently, the tumor process progresses, gradually involving other groups of lymph nodes on the same side of the diaphragm, on both sides of the diaphragm or extralymph (extranodal) tissues / organs. At first the lymph nodes are separated, and later they become adherent, forming tumor conglomerates, which compress the adjacent tissues / organs.

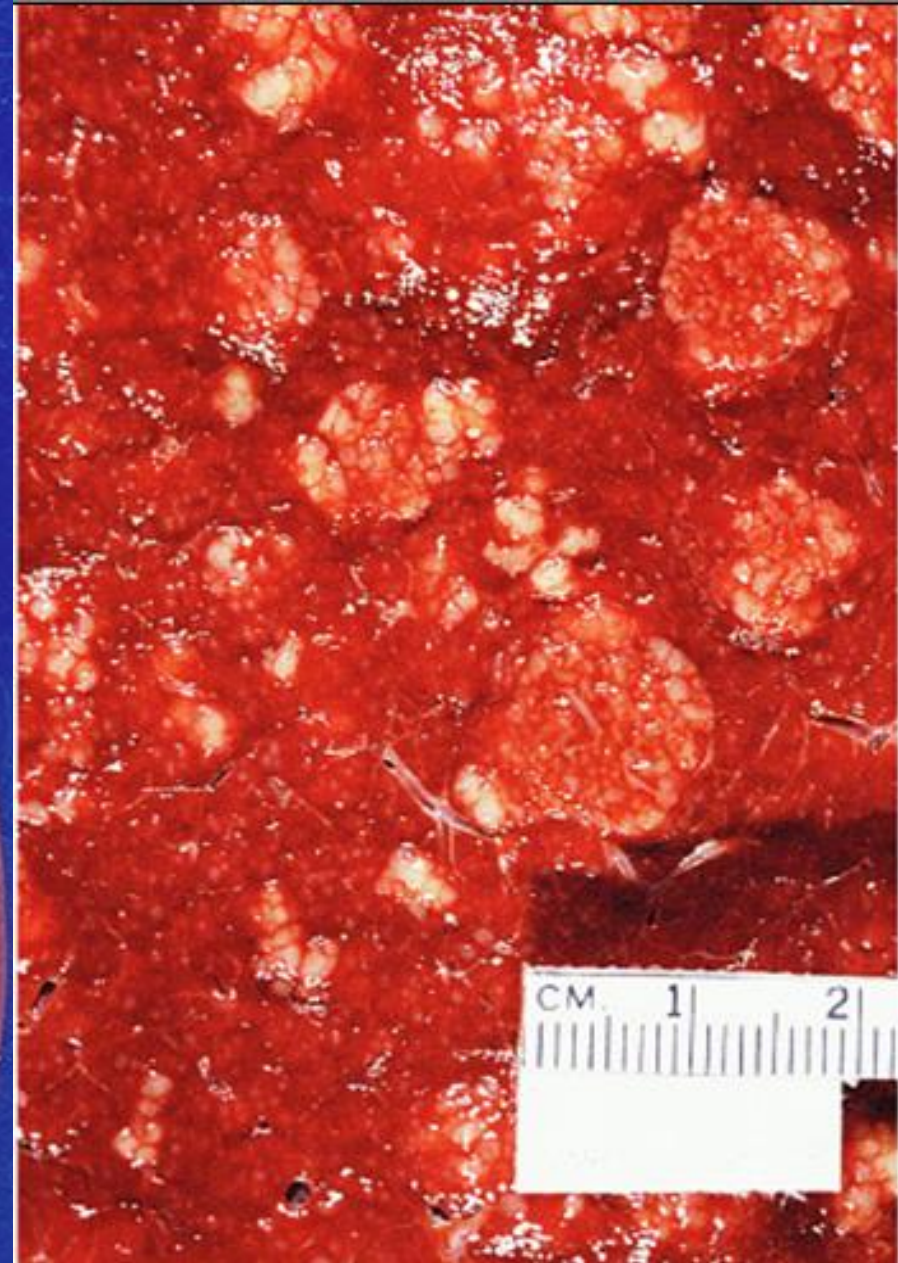
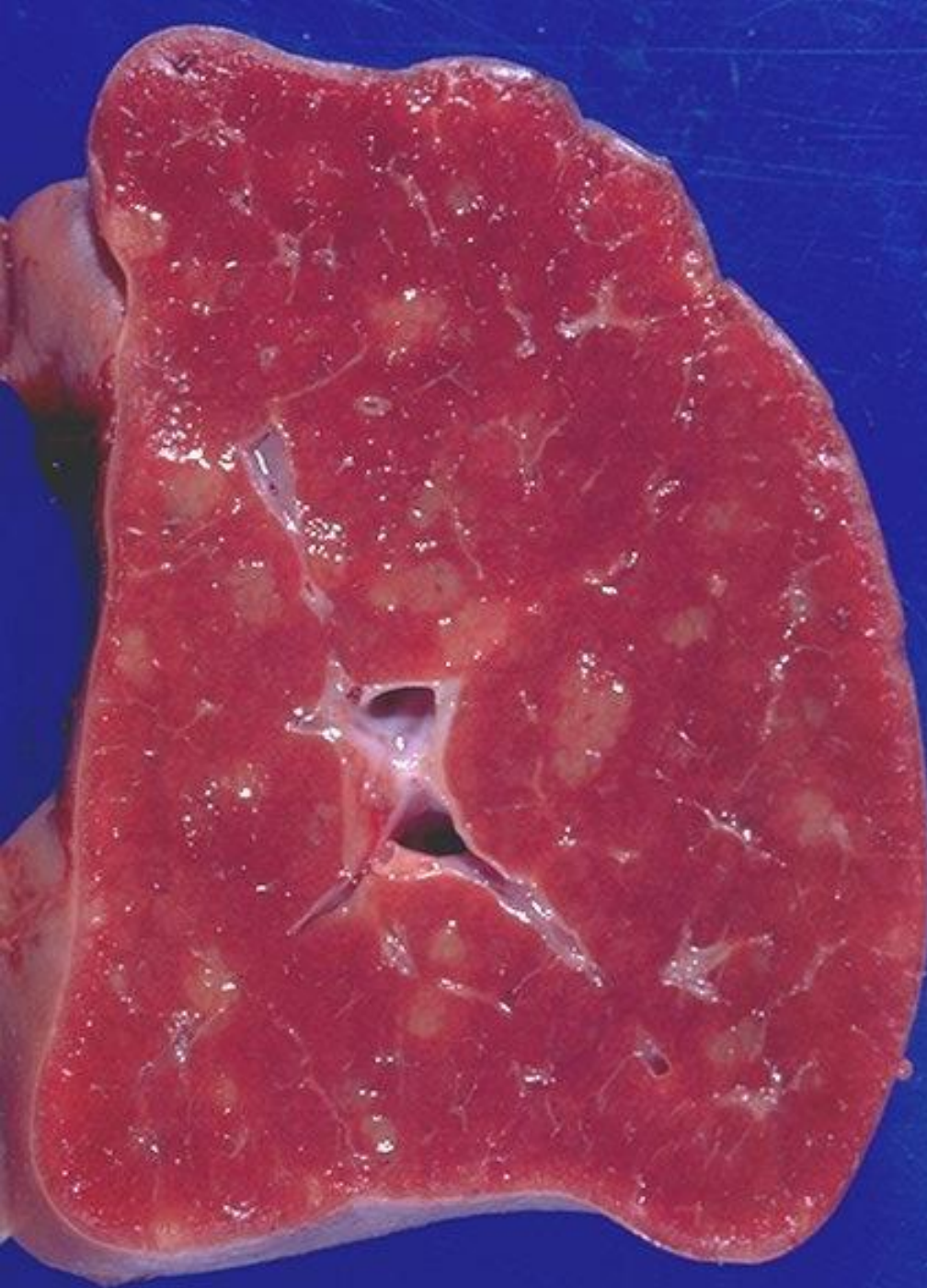№ 147. Spleen in Hodgkin's disease.

The spleen is enlarged in size 3-5 times, the mass reaching up to 1 kg, dense consistency, on a motley-looking section due to the alternation of white-yellowish proliferative foci and necrosis with whitish sclerosis foci on the background of the red pulp, which gives the splenic tissue an appearance similar to porphyry granite ('porphyry spleen') [the motley appearance is poorly pronounced due to the action of formalin].

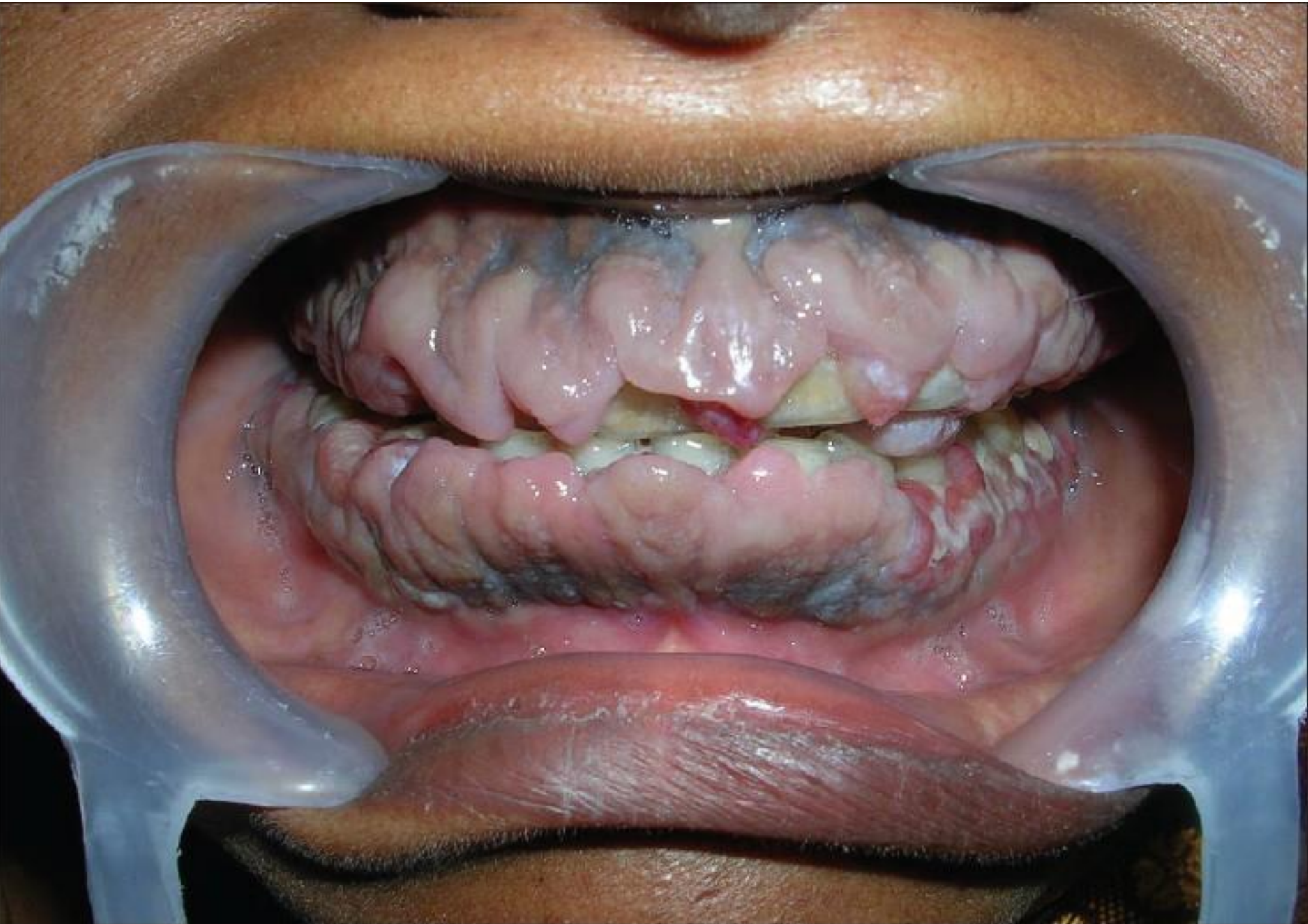Splenomegaly in Hodgkin's lymphoma is an expression of tumor progression, in the first stage being affected lymph nodes, and later other extranodal organs, primarily the spleen. Spleen damage is observed in about half of patients, being a process of metastasis from the primary focus of the lymph nodes. Histologically, tumor nodules consisting of a mixture of Reed-Sternberg cells and reactive cells (eosinophils, plasma cells, neutrophilic leukocytes, macrophages), foci of necrosis, sometimes caseous, and fibrosis are revealed.



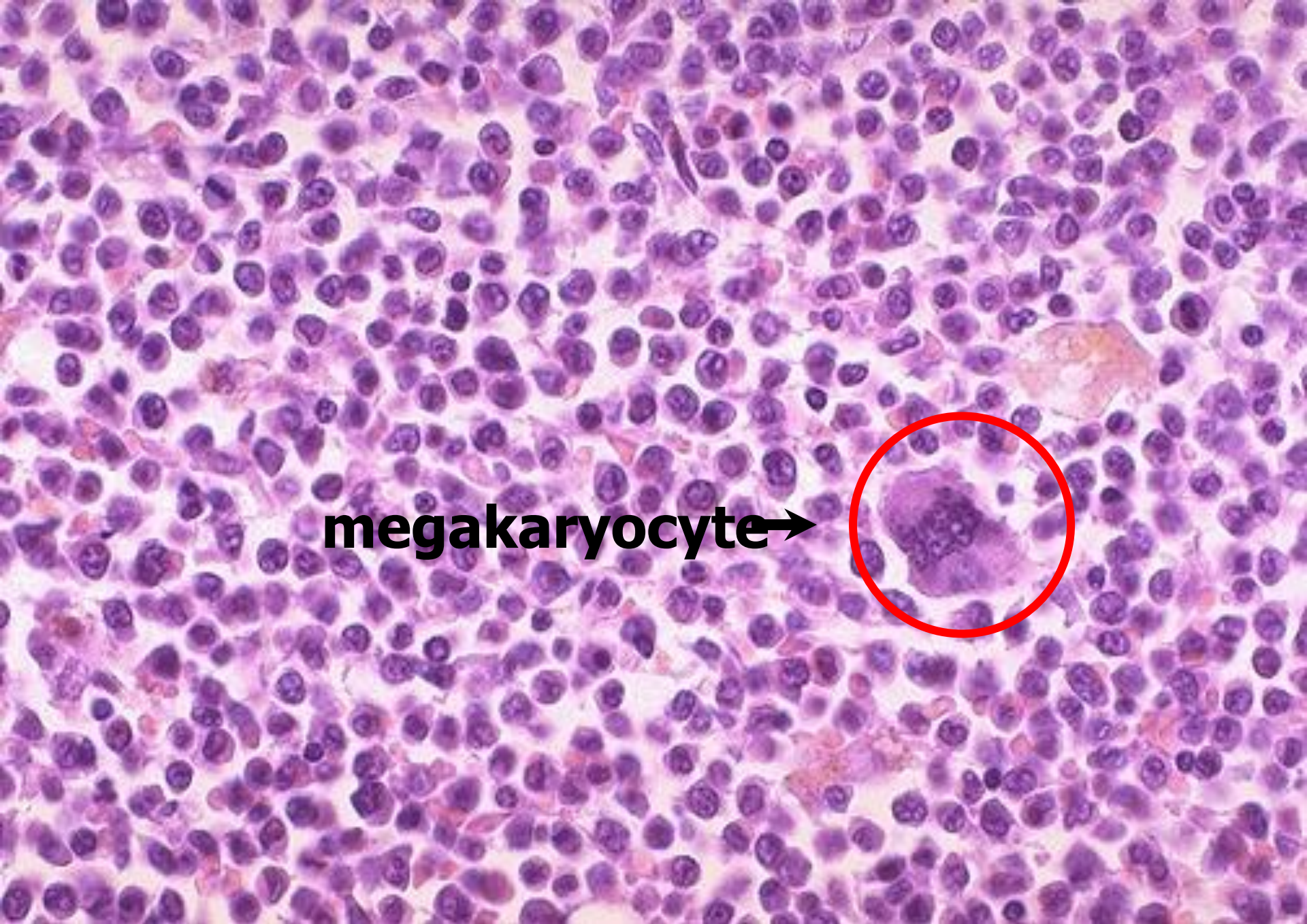
№ 146. Lymph nodes in Hodgkin's disease.



№ 147. Spleen in Hodgkin's disease.

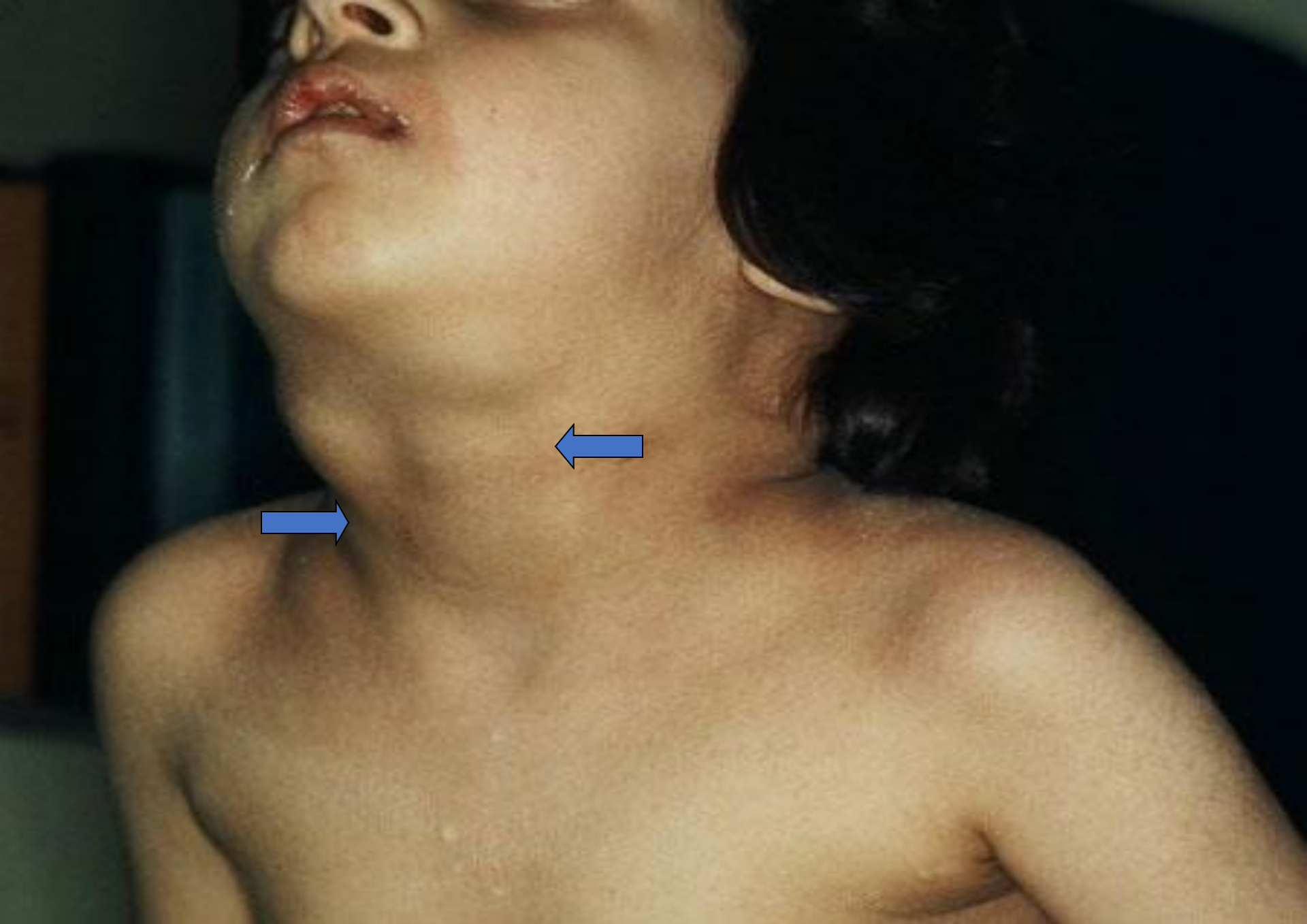


AML - with gingival manifestations.

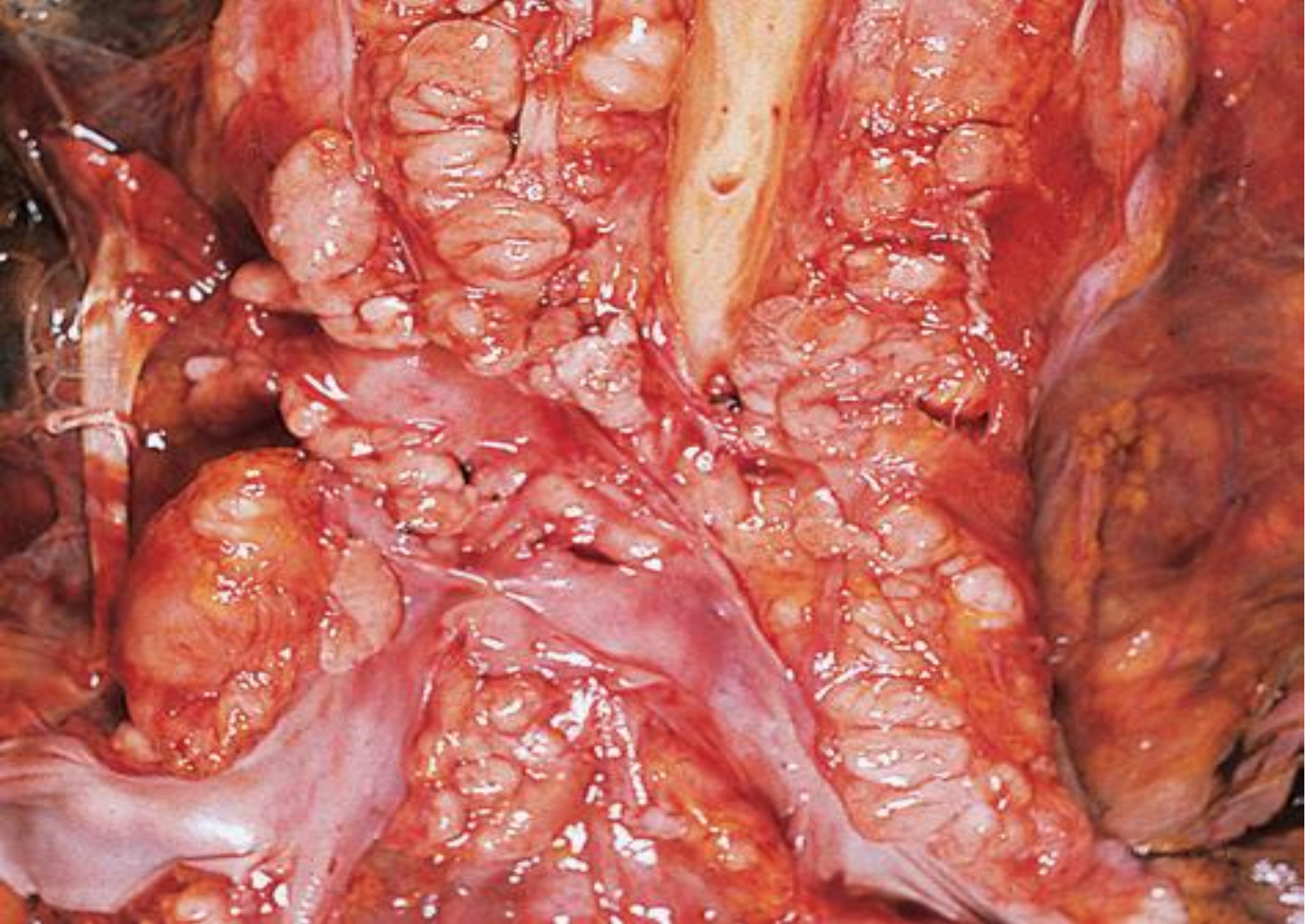


megakaryocyte →

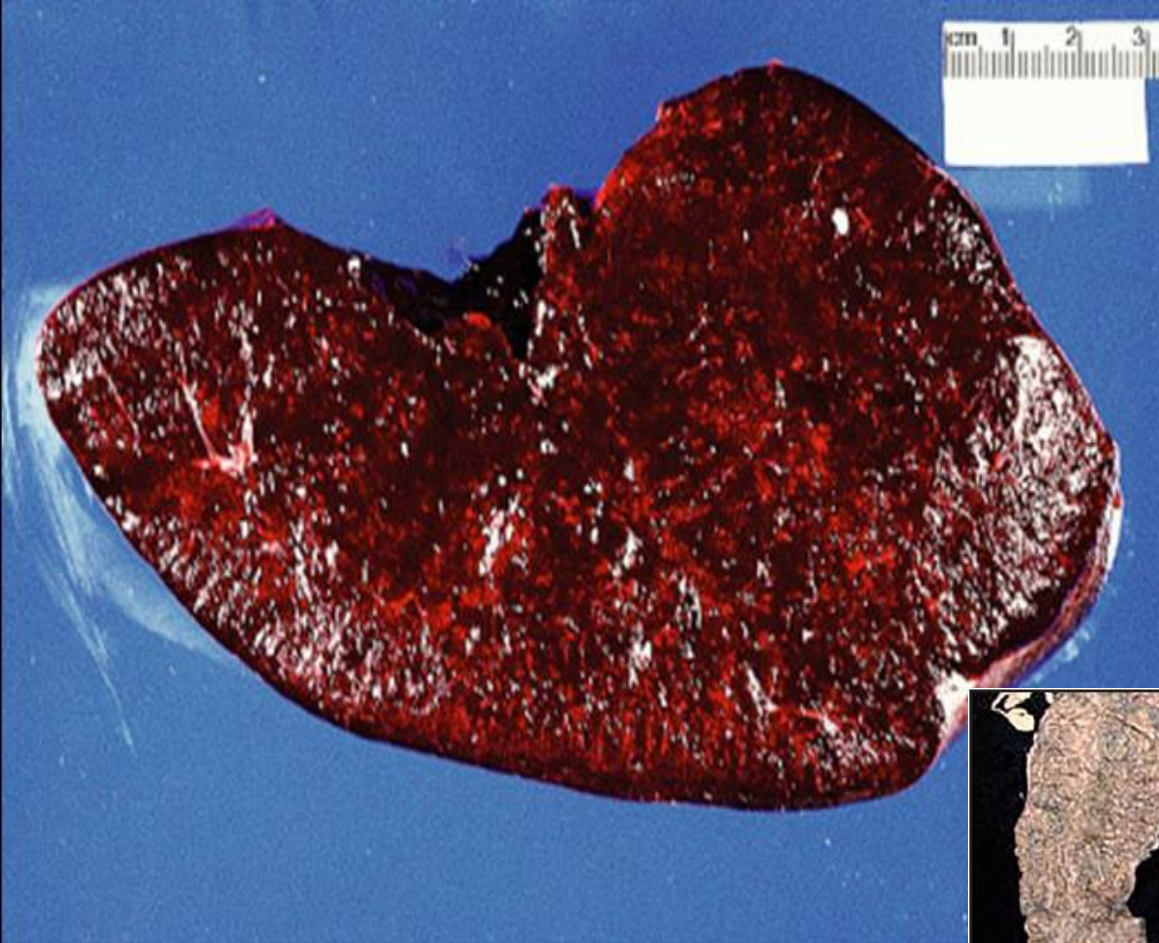
Bone marrow in AML (overloaded with blast cells).



ALL - cervical lymphadenopathy.

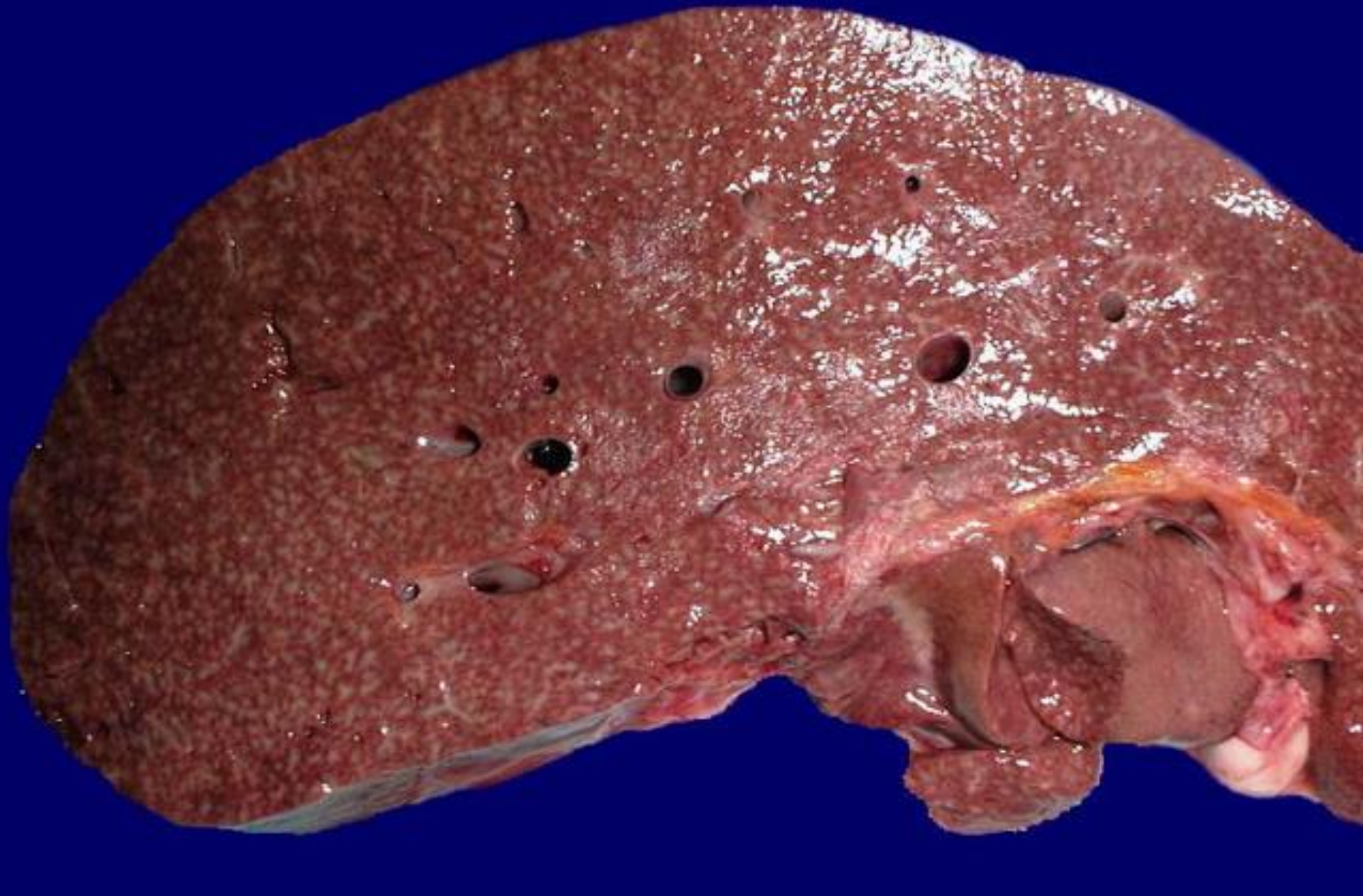

CLL - hyperplasia of periaortic lymph nodes.

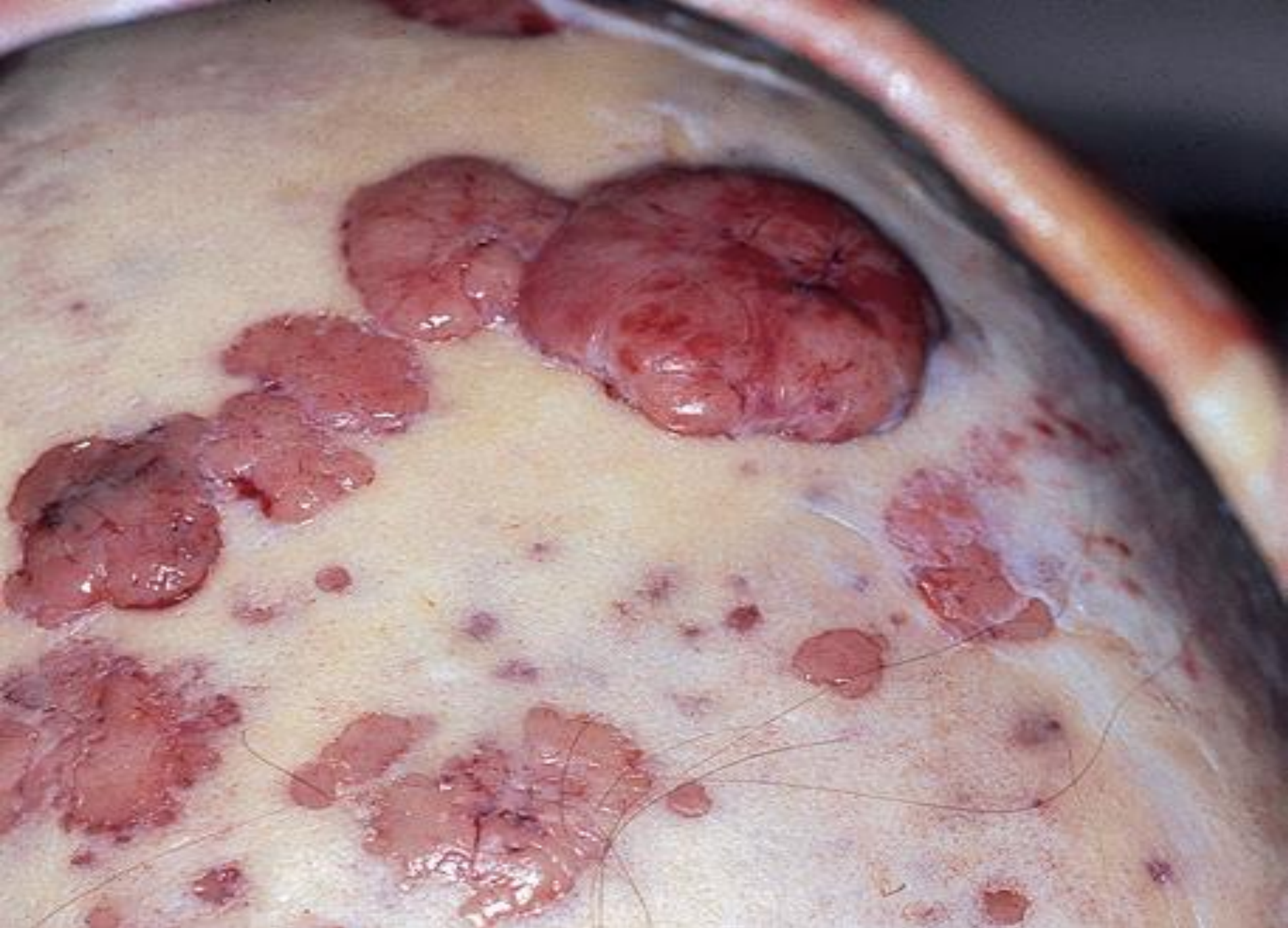

Hyperplasia of the spleen and intestinal lymph follicles in CLL.

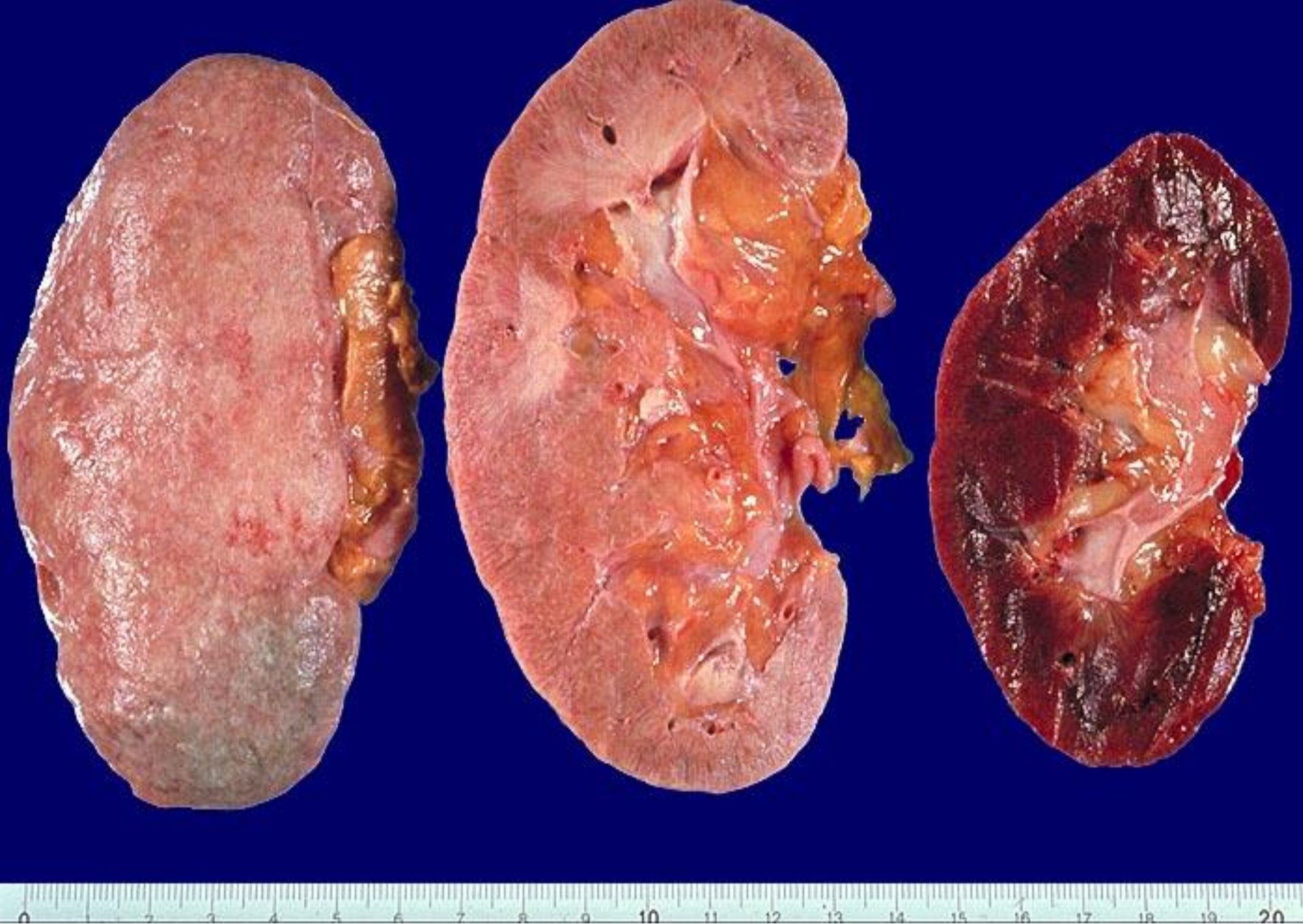



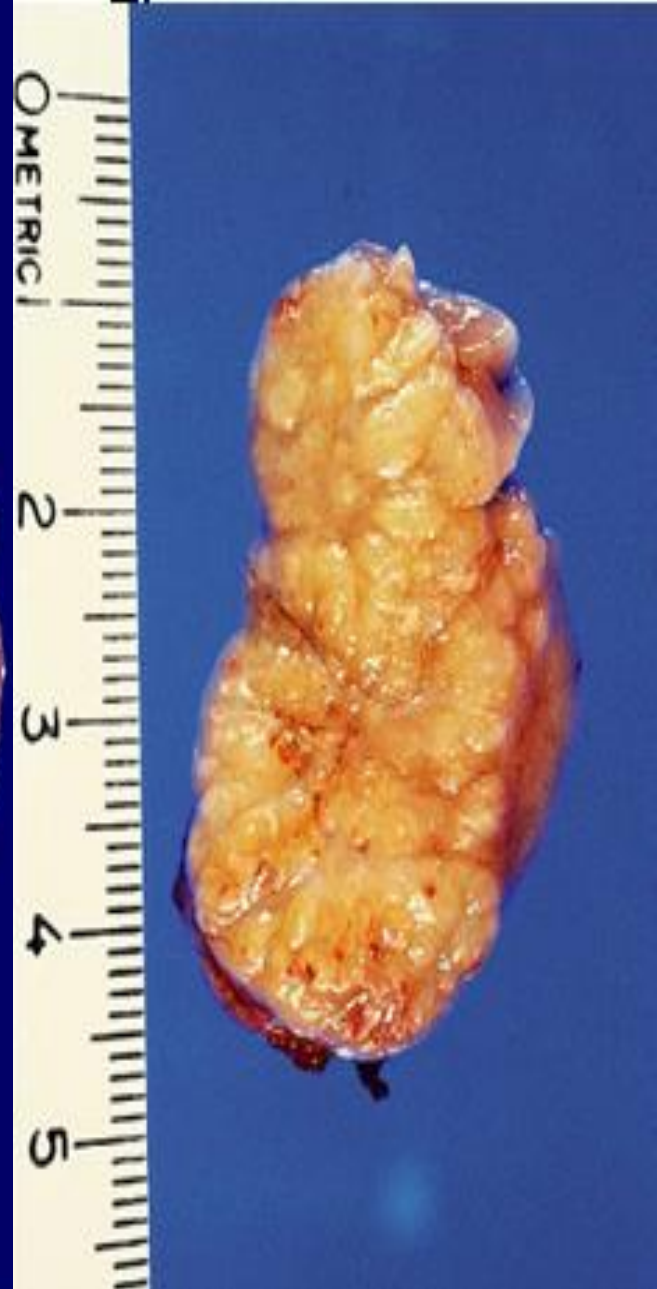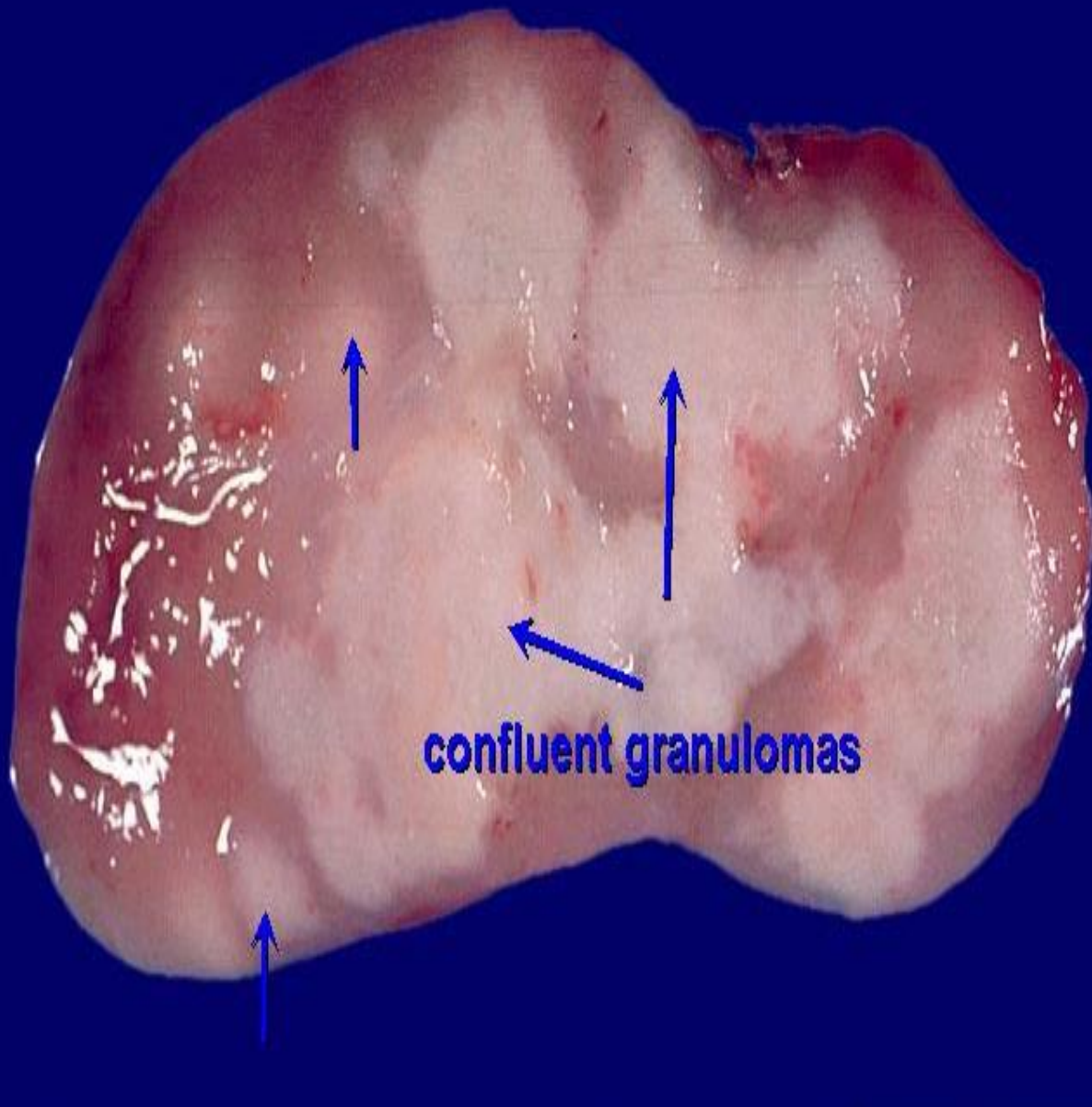
Liver in CLL



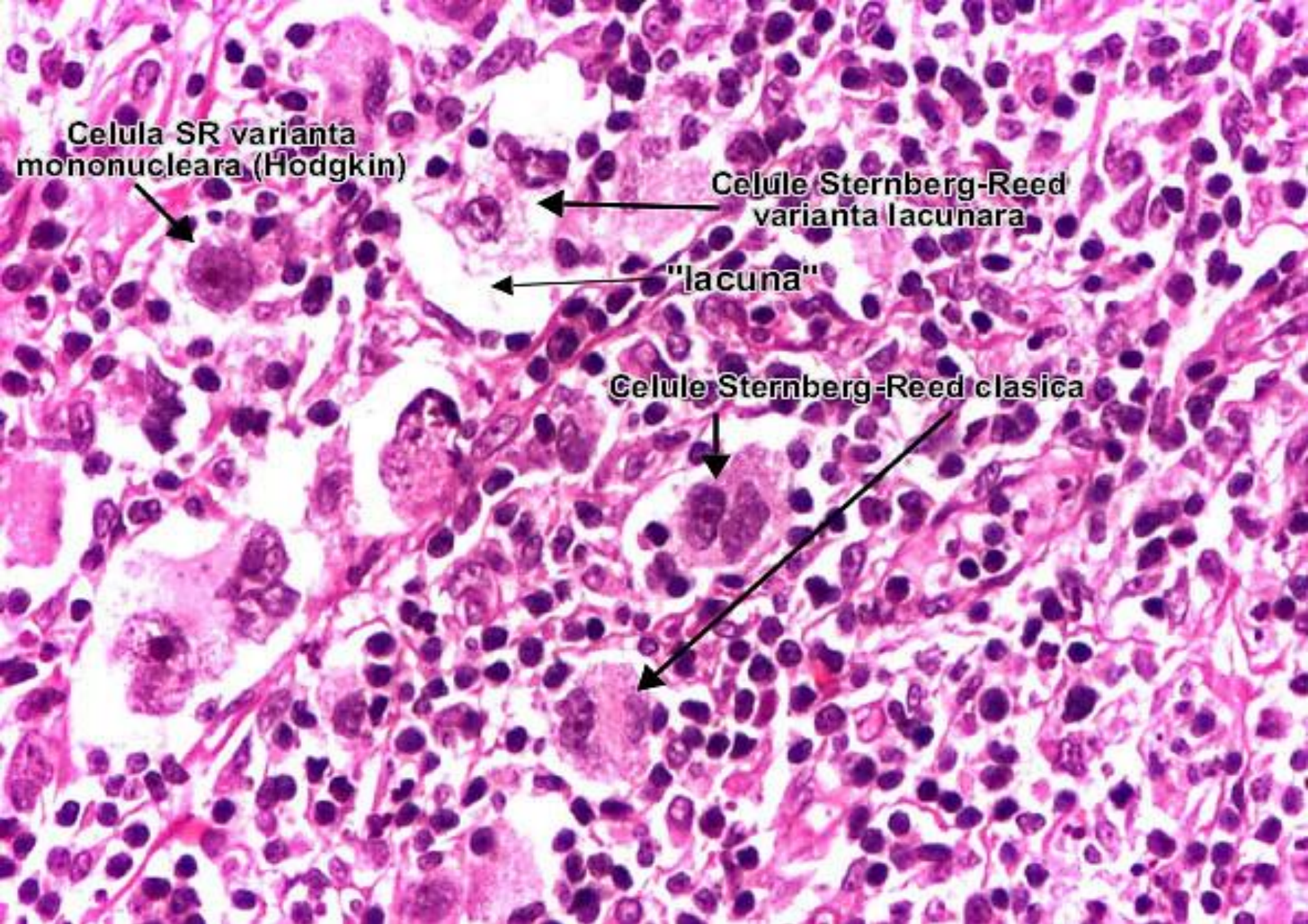
Multiple myeloma.



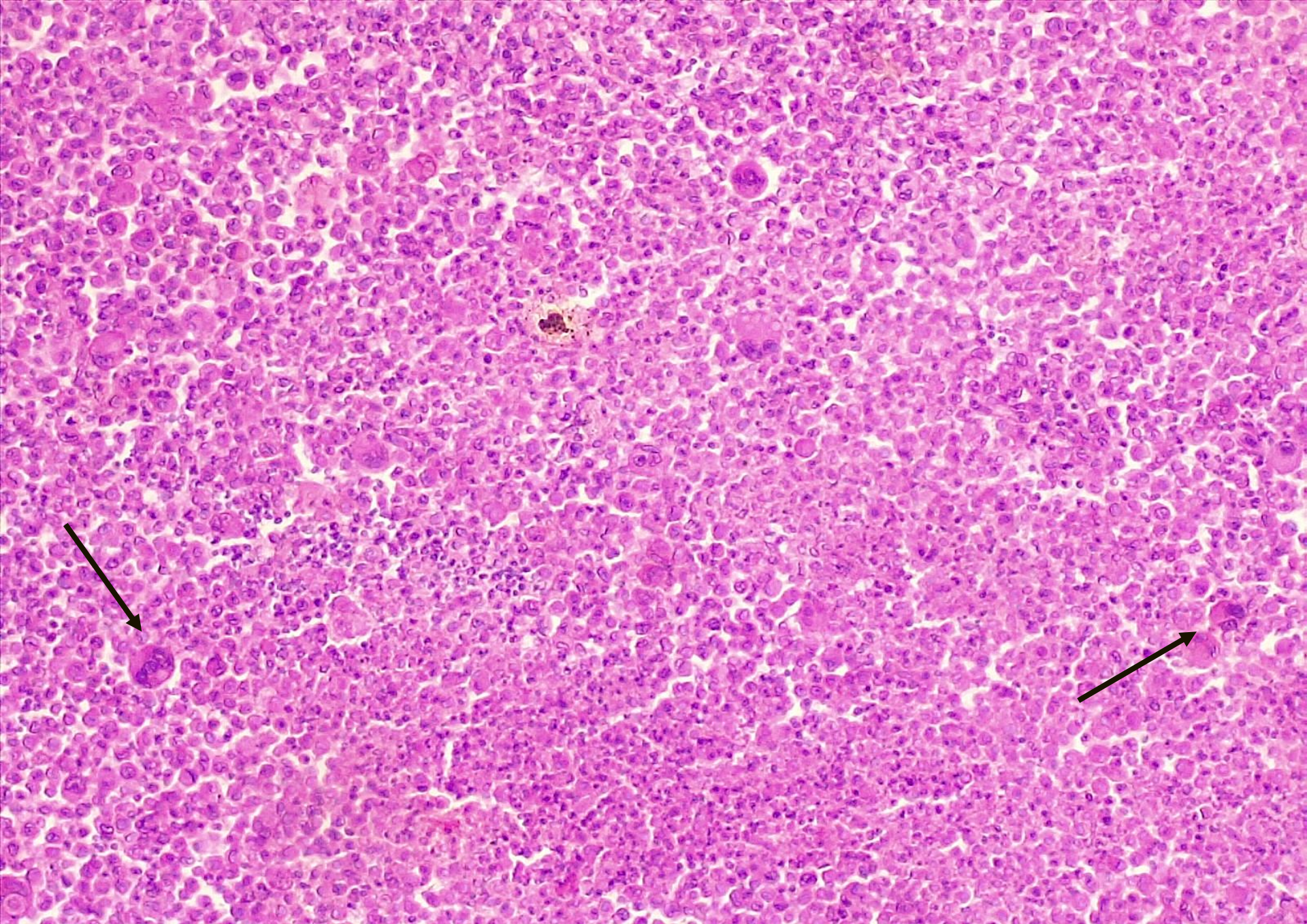
Myeloma kidney and normal kidneys.



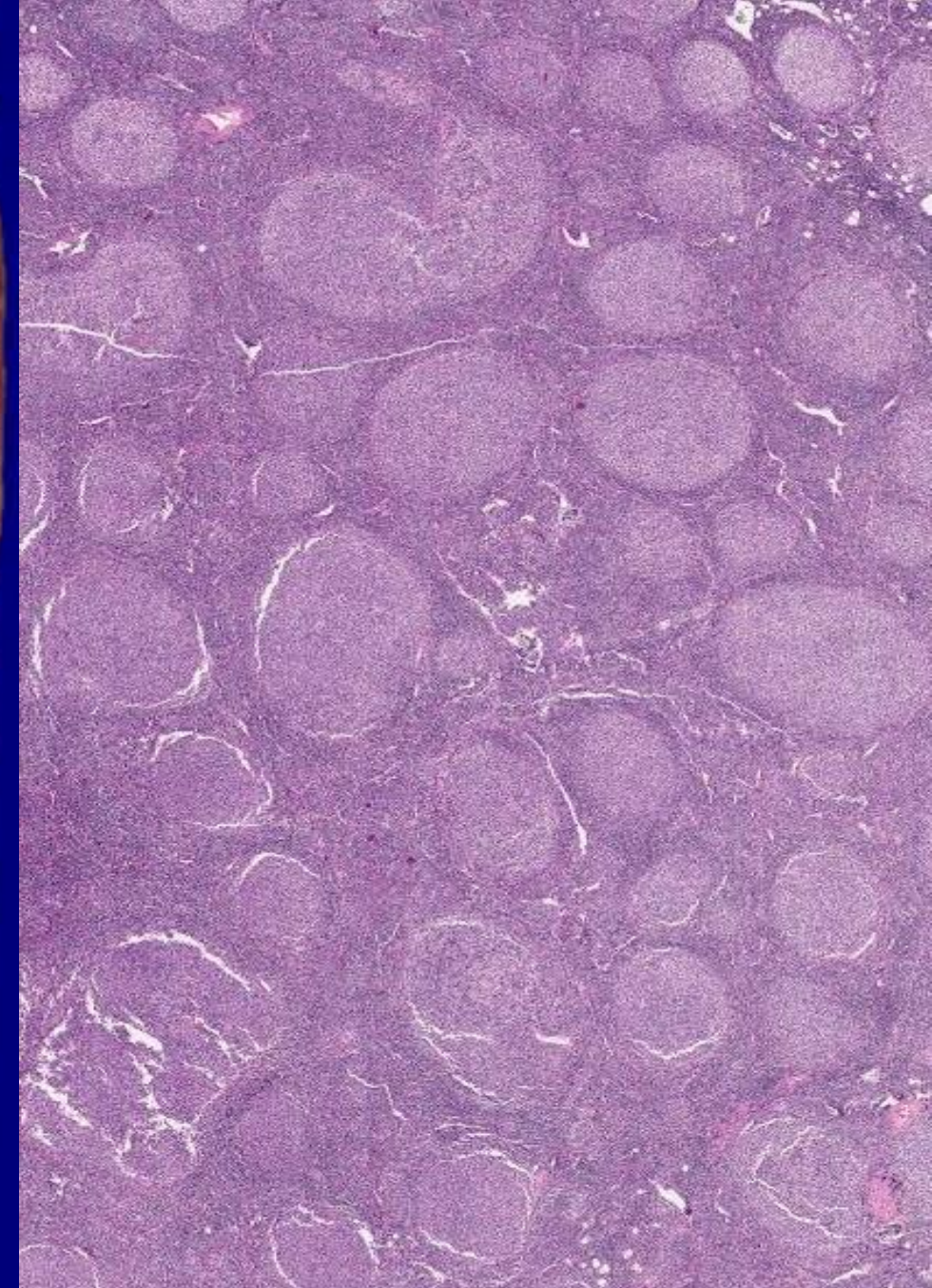
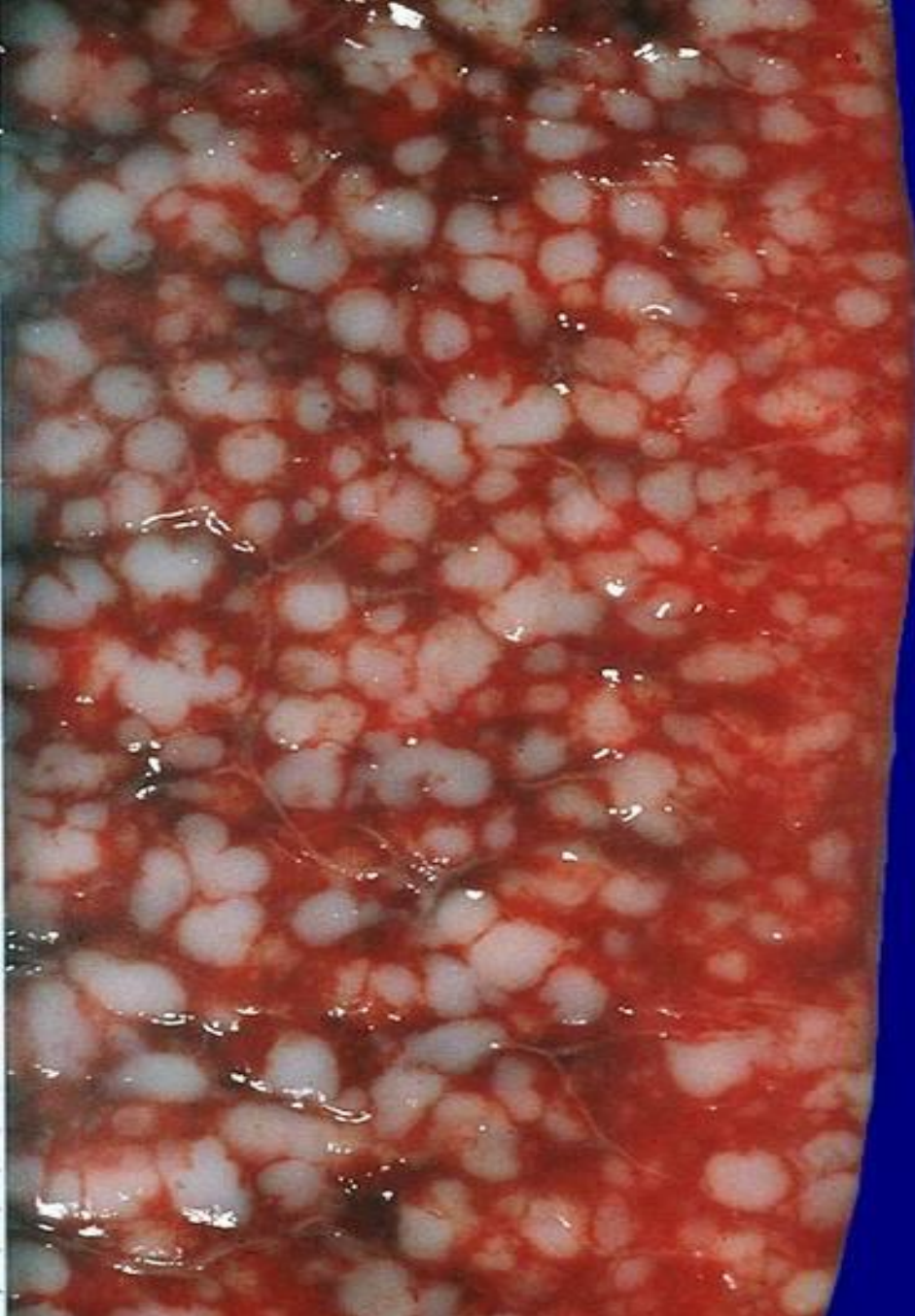
Lymph node in Hodgkin's lymphoma.
(nodular surface).



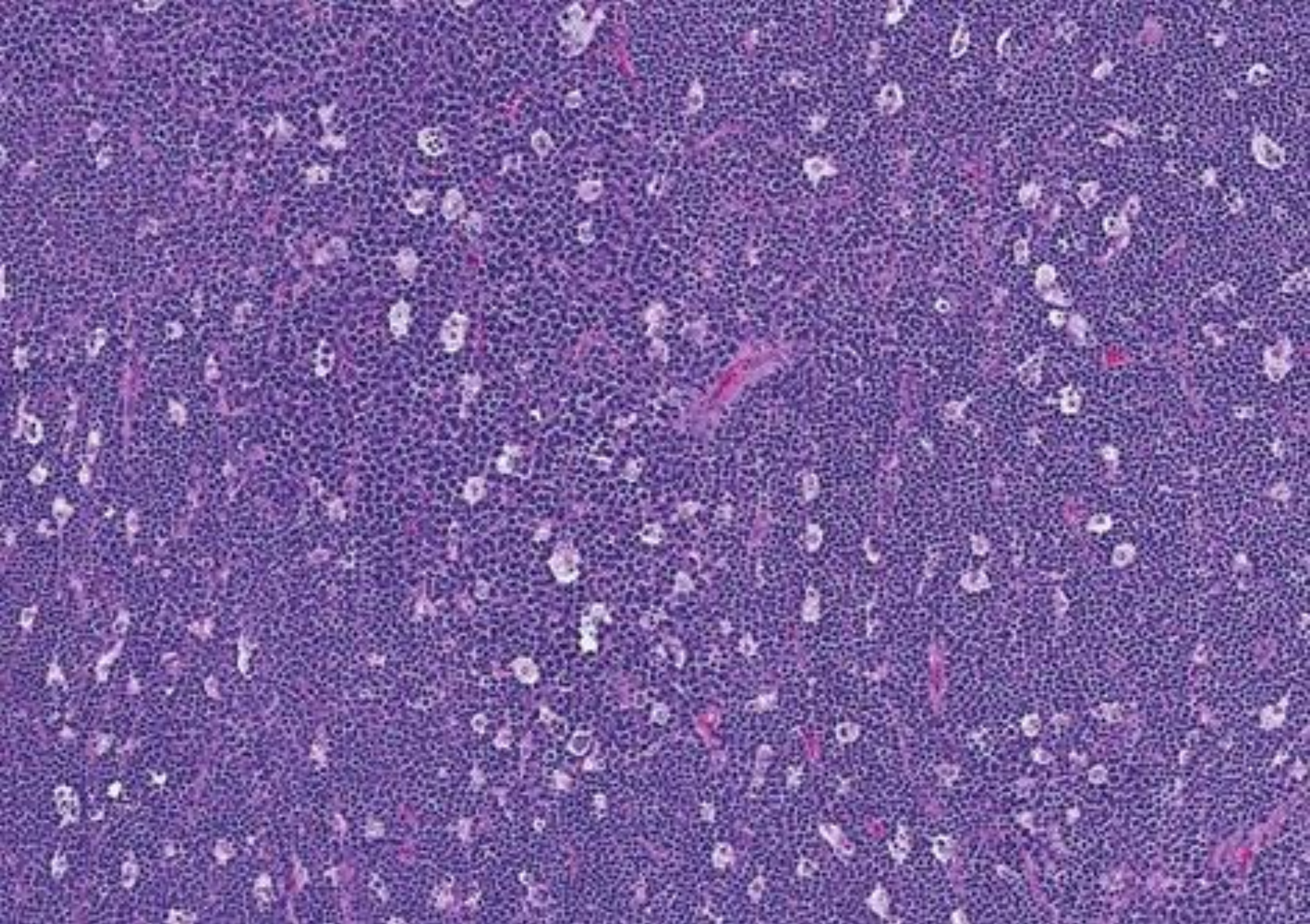
Reed - Sternberg cell.



Lymph node in Hodgkin's disease (mixed-cellularity type). (*H-E stain*).



Follicular lymphoma.

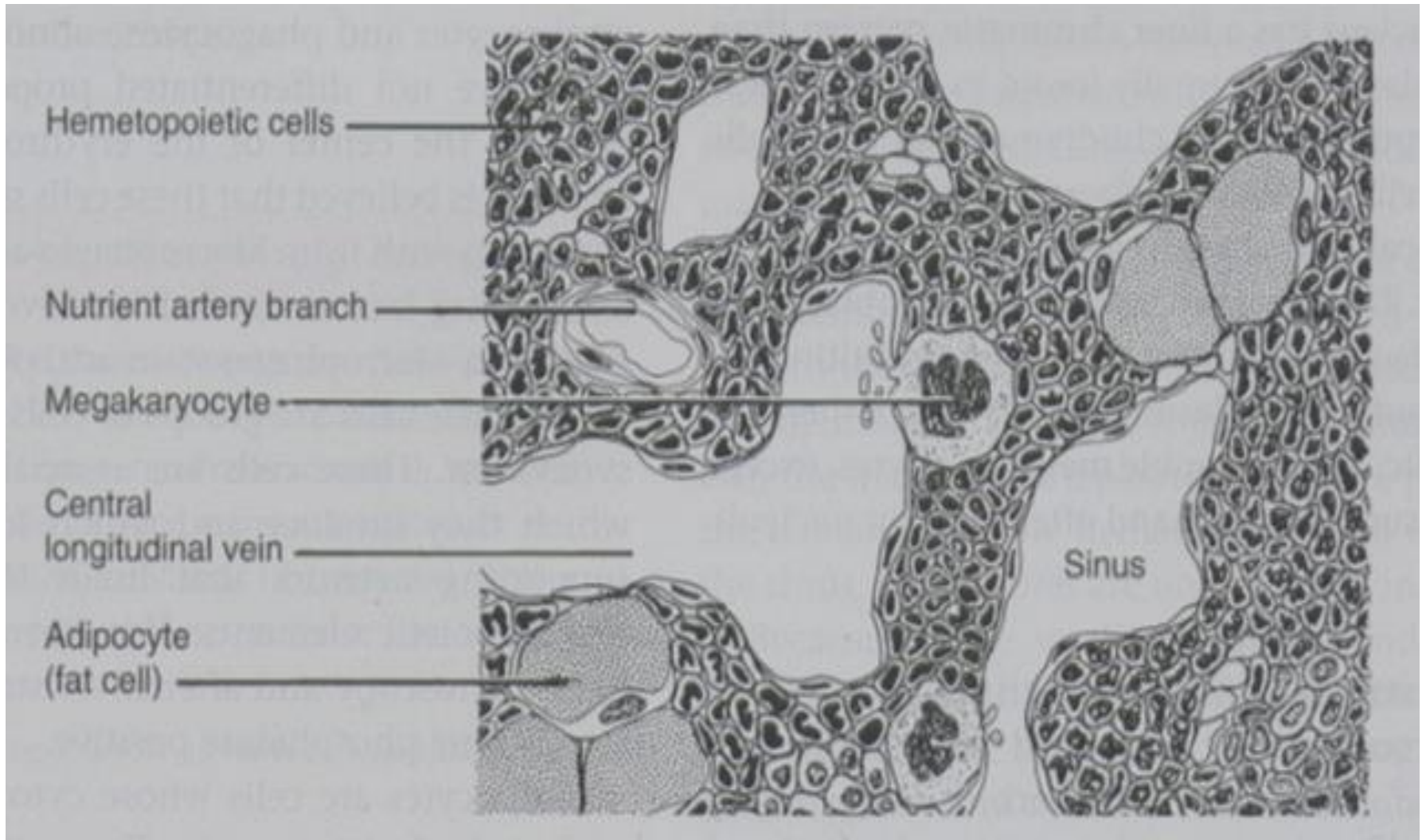


Burkitt's lymphoma (*starry sky appearance*).

A microscopic view of blood cells, showing a large orange-red cell on the left and a cluster of purple and pink cells on the right. The background is black.

BLOOD AND LYMPHATIC DISORDERS

STRUCTURE OF BONE MARROW



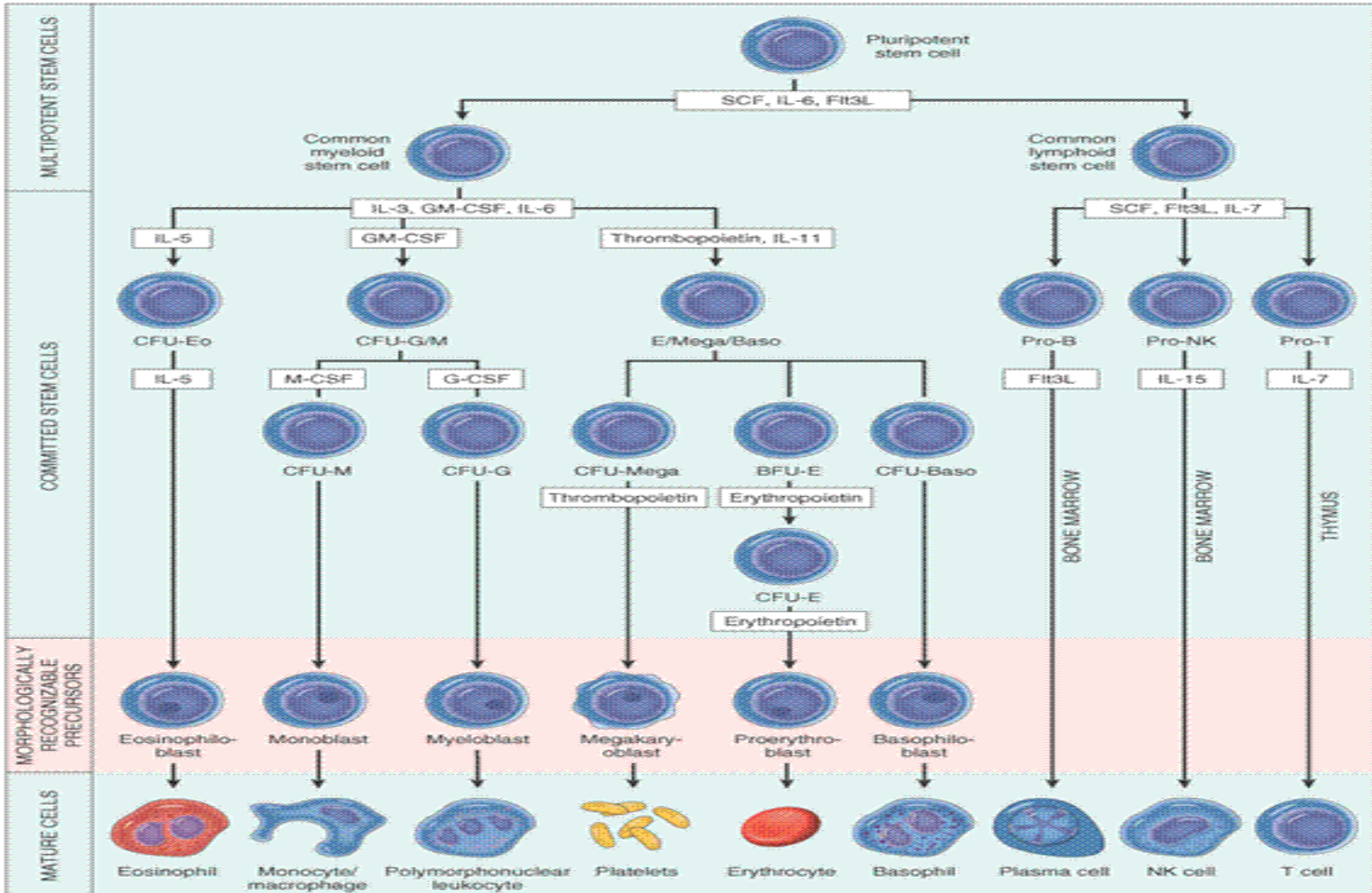
WHERE is MARROW?

- **Yolk Sac: very early embryo**
- **Liver, Spleen: NEWBORN**
- **BONE**
 - **CHILDHOOD: AXIAL SKELETON & APPENDICULAR SKELETON BOTH HAVE RED (active) MARROW**
 - **ADULT: AXIAL SKELETON RED MARROW, APPENDICULAR SKELETON YELLOW MARROW**

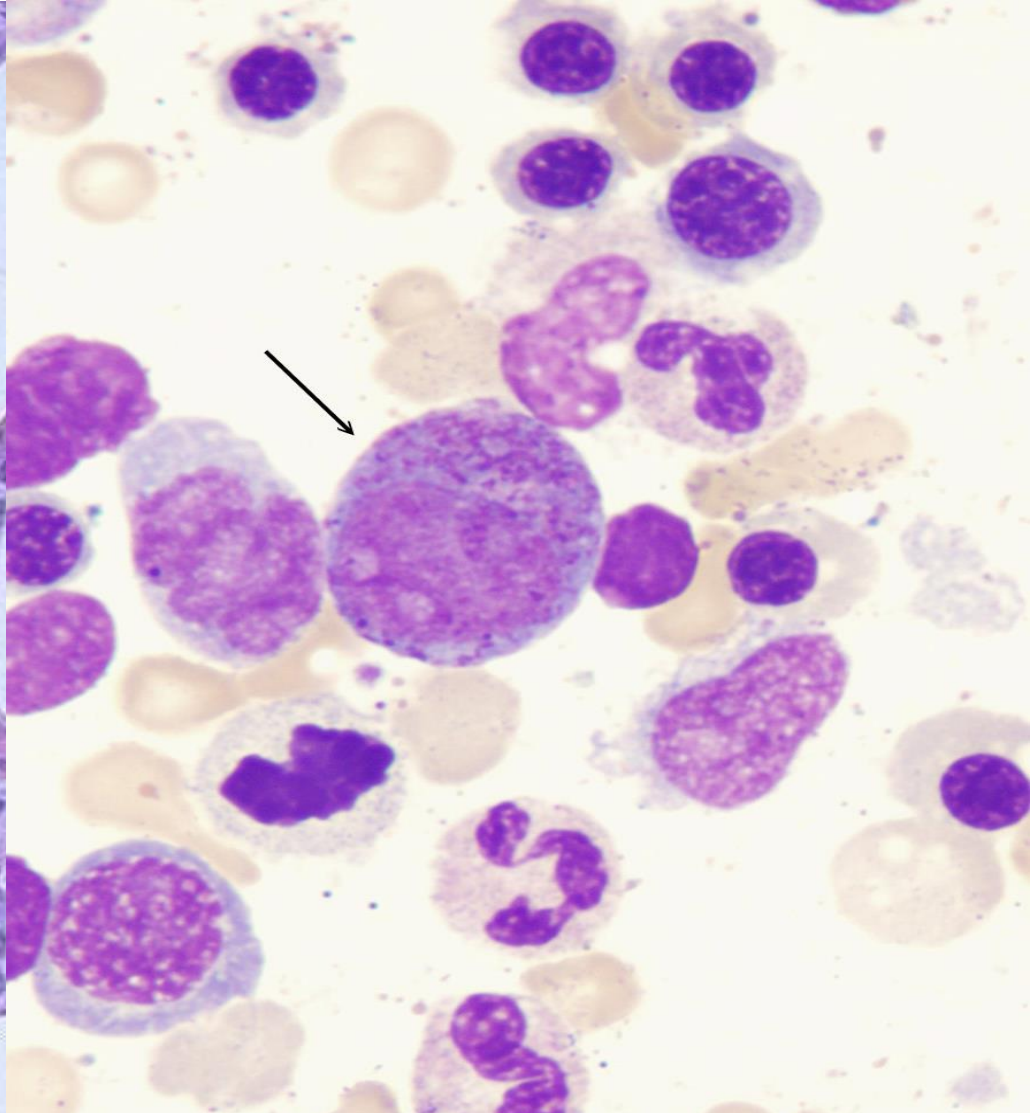
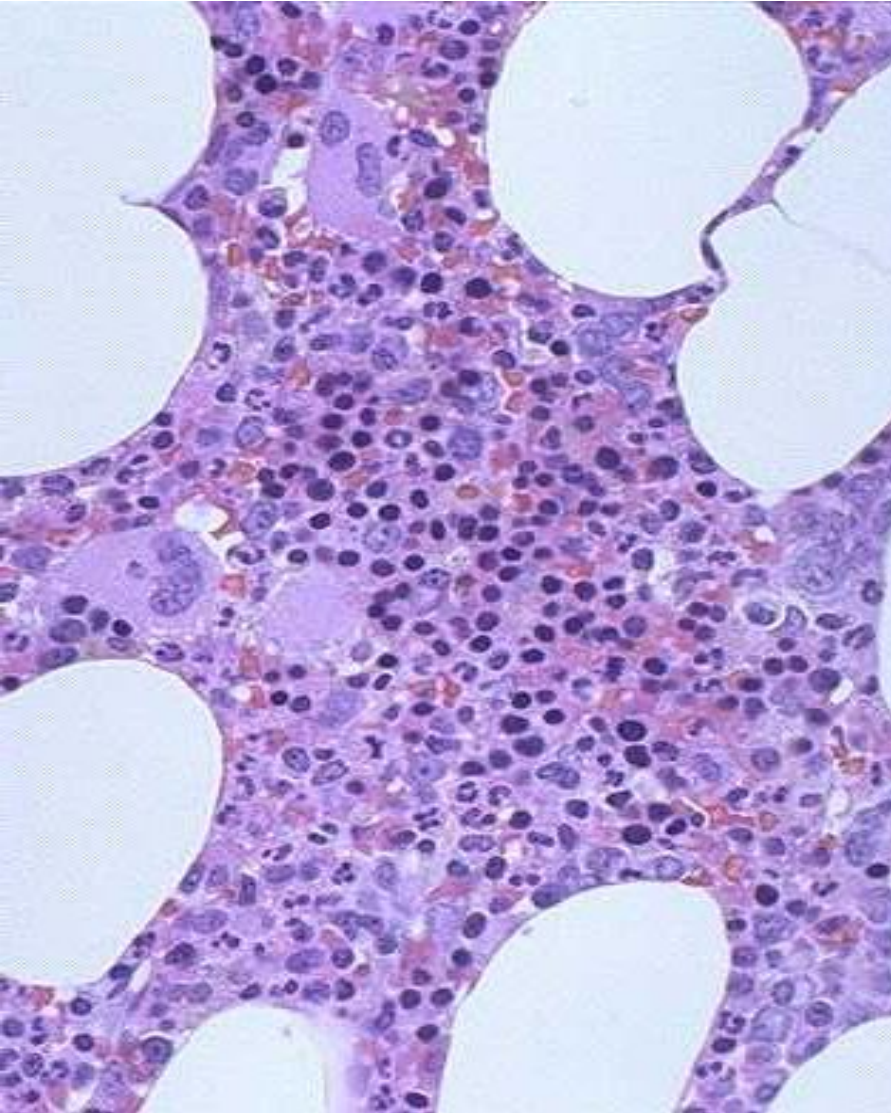
MARROW FEATURES

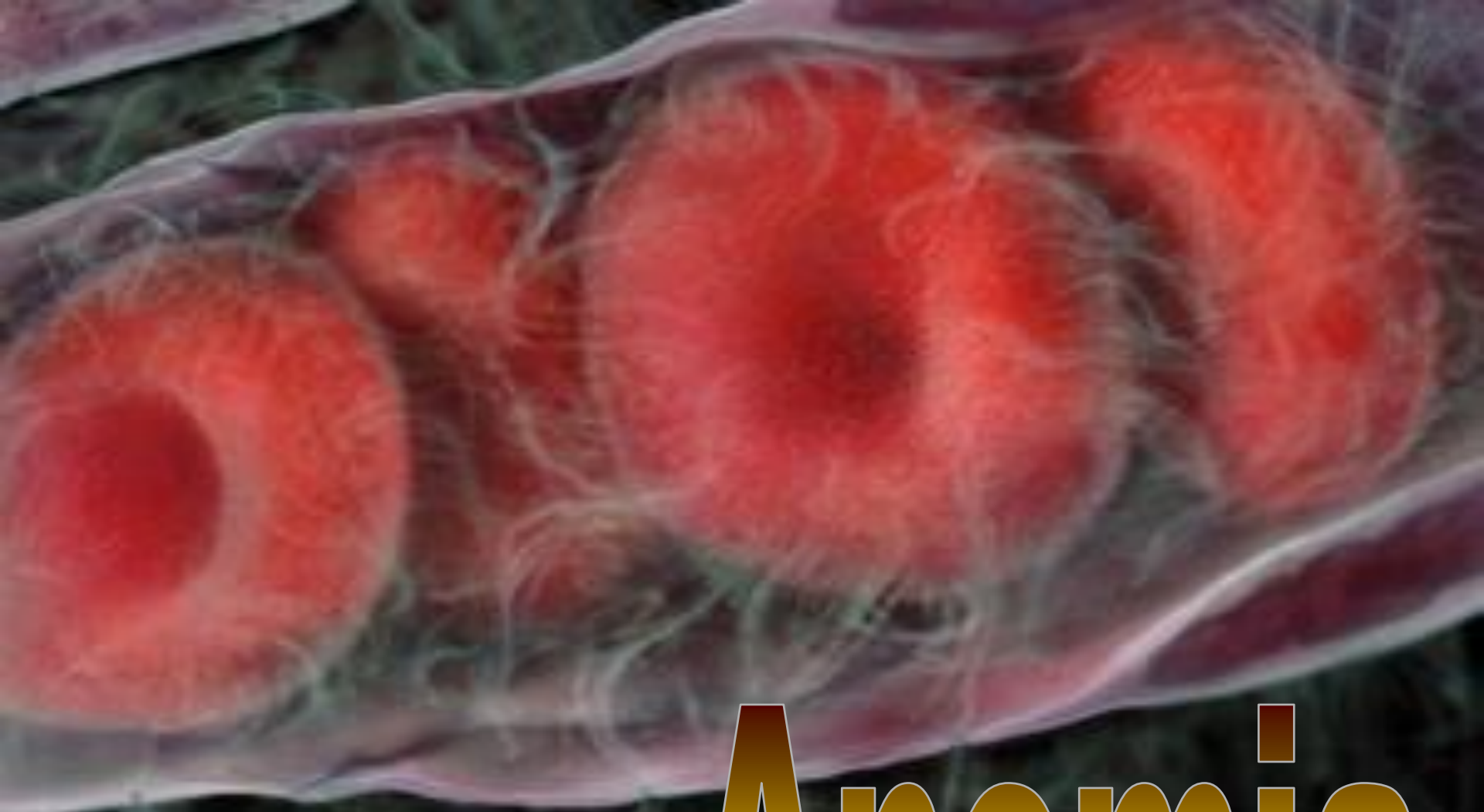
- **CELLULARITY**
- **MEGAKARYOCYTES**
- **M:E RATIO**
- **MYELOID MATURATION**
- **ERYTHROID MATURATION**
- **LYMPHS, PLASMA CELLS**
- **STORAGE IRON, i.e., HEMOSIDERIN**
- **“FOREIGN CELLS”**

MARROW "DIFFERENTIATION"



BONE MARROW



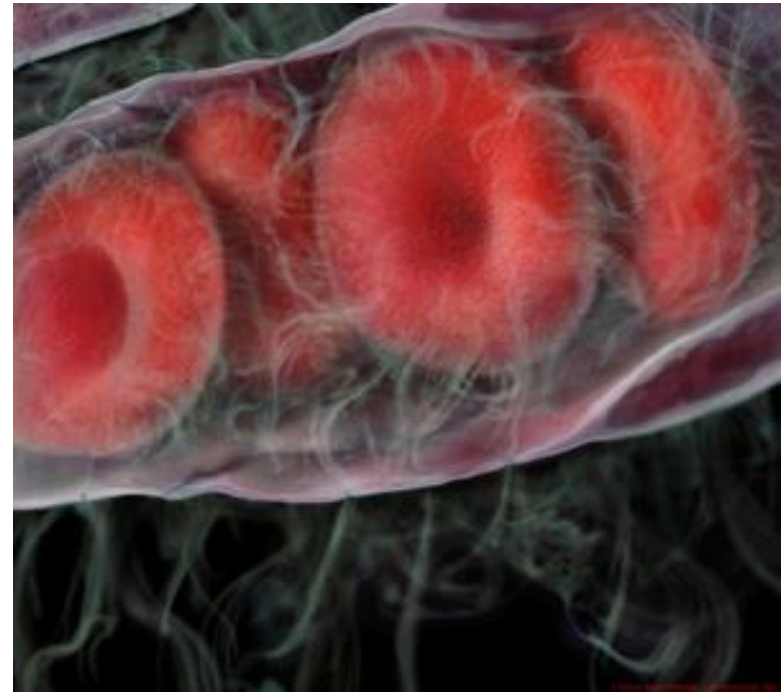


Anemia

ANEMIAS

A good definition would be a decrease in **OXYGEN CARRYING CAPACITY**, rather than just a decrease in red blood cells, because you need to have enough blood cells **THAT FUNCTION**, and not just enough blood cells.

- **BLOOD LOSS**
 1. **acute**
 2. **chronic**
- **IN-creased destruction (HEMOLYTIC)**
- **DE-creased production**



Features of ALL anemias

- **Pallor, where?**
- **Tiredness**
- **Weakness**
- **Dyspnea, why?**
- **Palpitations**
- **Heart Failure (high output), why?**

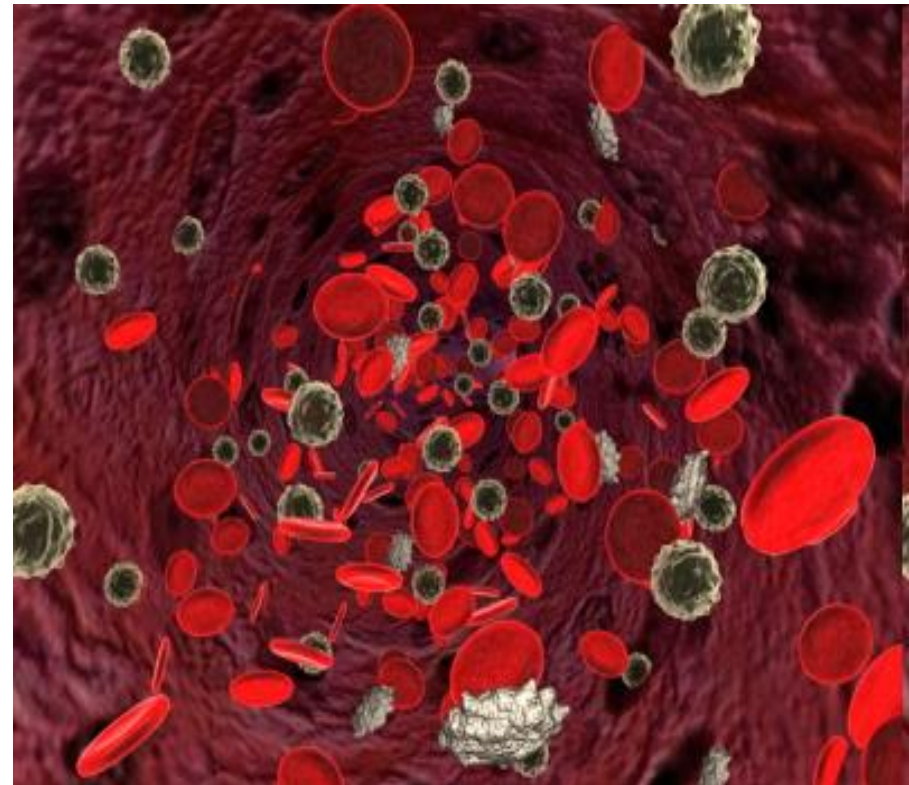
Blood Loss

Acute: trauma

Chronic: lesions of gastrointestinal tract, gynecologic disturbances. The features of chronic blood loss anemia are the same as iron deficiency anemia, and is defined as a situation in which the production cannot keep up with the loss

HEMOLYTIC

- **HEREDITARY**
 - **MEMBRANE disorders: e.g., spherocytosis**
 - **ENZYME disorders: e.g., G6PD deficiency**
 - **HGB disorders (hemoglobinopathies)**
- **ACQUIRED**
 - **MEMBRANE disorders (PNH)**
 - **ANTIBODY MEDIATED, transfusion**
 - **or autoantibodies**
 - **MECHANICAL TRAUMA**
 - **INFECTIONS**
 - **DRUGS, TOXINS**
 - **HYPERSPLENISM**



IMPAIRED PRODUCTION

- **Disturbance of proliferation and differentiation of stem cells: aplastic anemias, pure RBC aplasia, renal failure**
- **Disturbance of proliferation and maturation of erythroblasts**
- **Defective DNA synthesis: (Megaloblastic)**
- **Defective heme synthesis: (Fe)**
- **Deficient globin synthesis: (Thalasseмии)**

MODIFIERS

- **MCV, microcytosis, macrocytosis**
- **MCH**
- **MCHC, hypochromic**
- **RDW, anisocytosis**

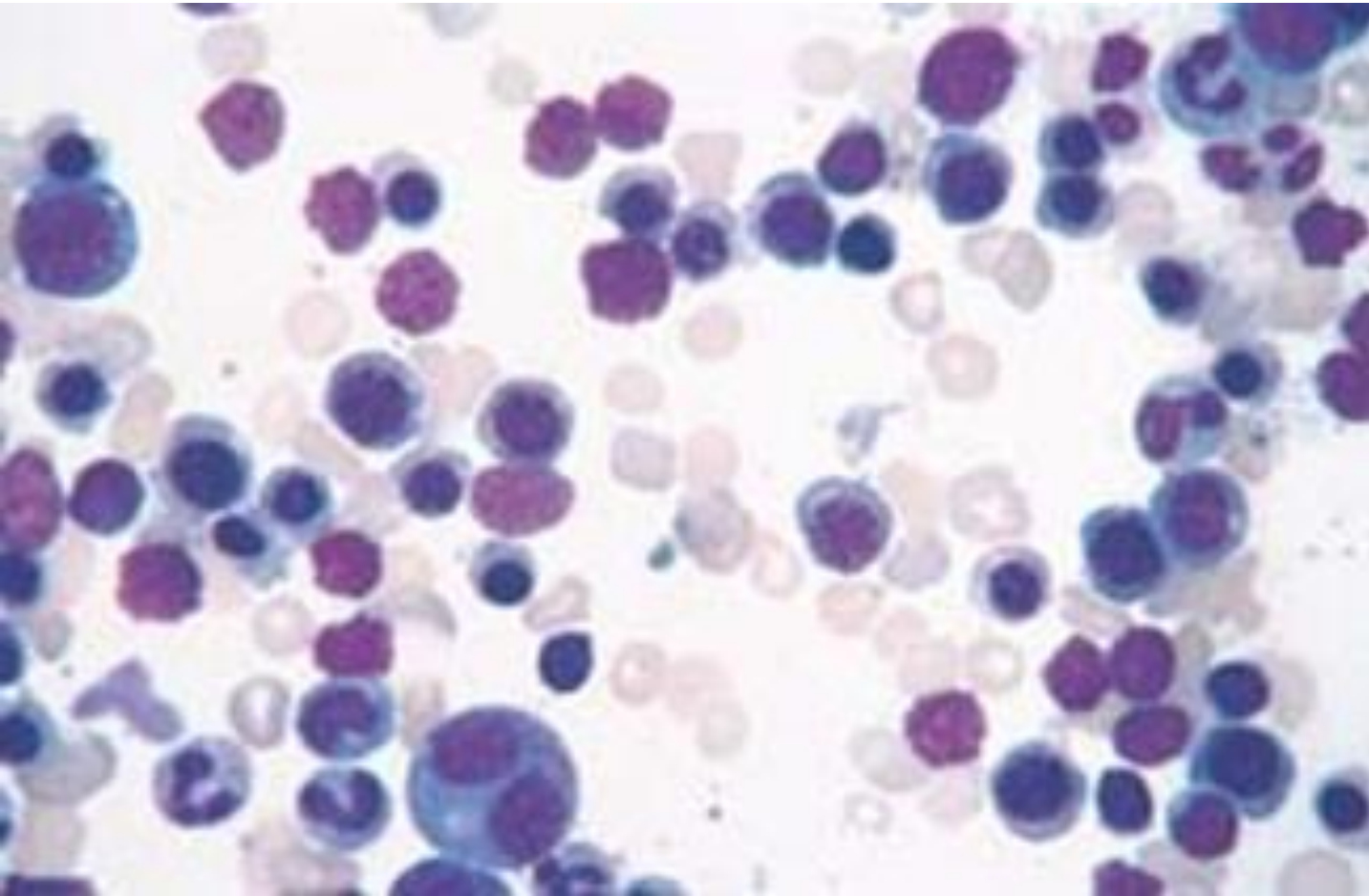
HEMOLYTIC ANEMIAS

- **Life span LESS than 120 days**
- **Marrow hyperplasia (M:E), EPO+**
- **Increased catabolic products, e.g., bilirubin, serum HGB, hemosiderin**

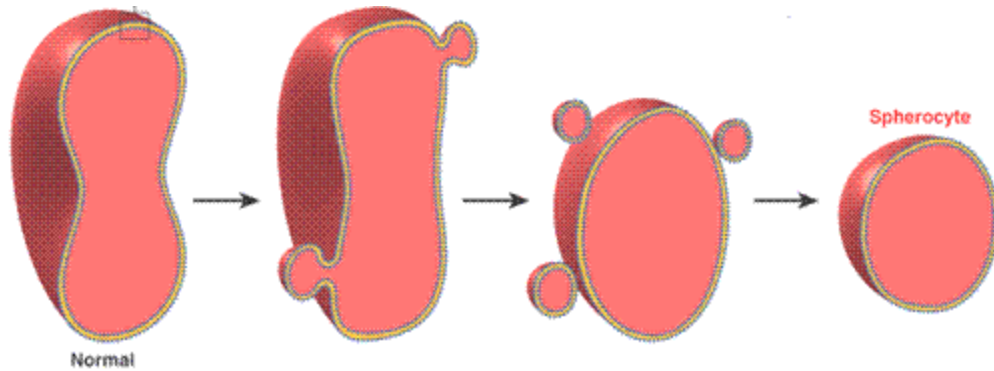
HEMOLYSIS

- **INTRA-vascular (vessels)**
- **EXTRA-vascular (spleen)**

M:E Ratio normally 3:1



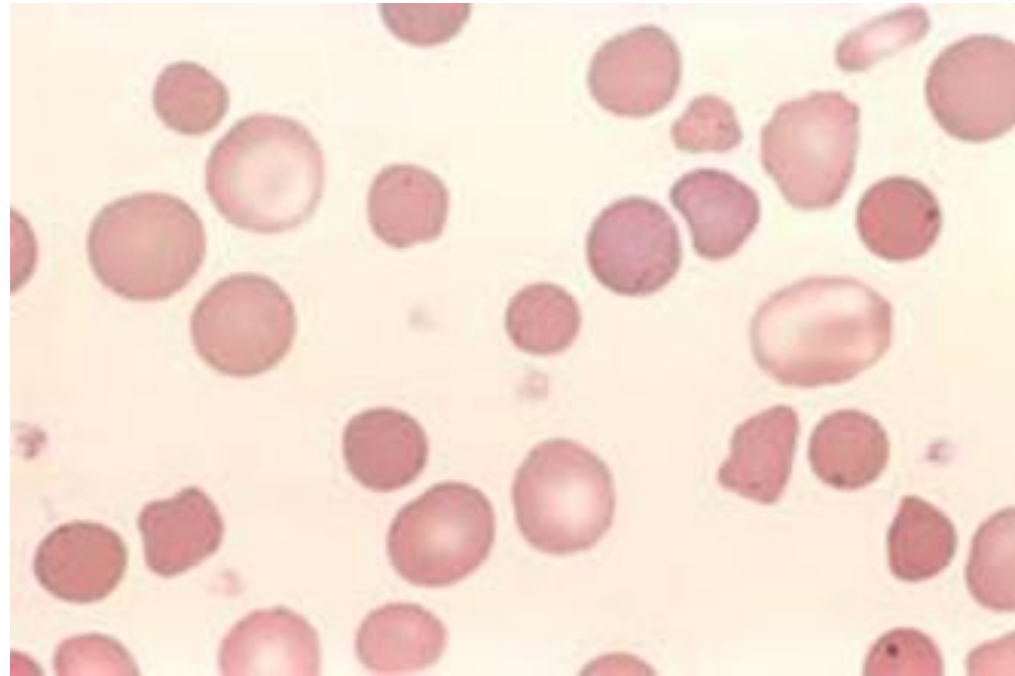
HEREDITARY SPHEROCYTOSIS



Genetic defects affecting ankyrin, spectrin, usually autosomal dominant

Children, adults

Anemia, hemolysis, jaundice, splenomegaly, gallstones (what kind?)

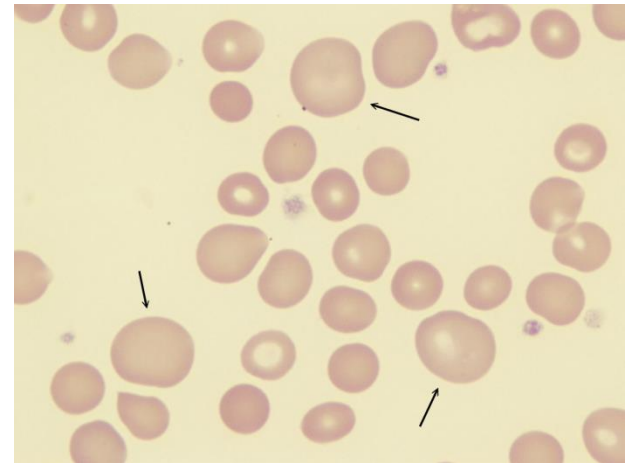
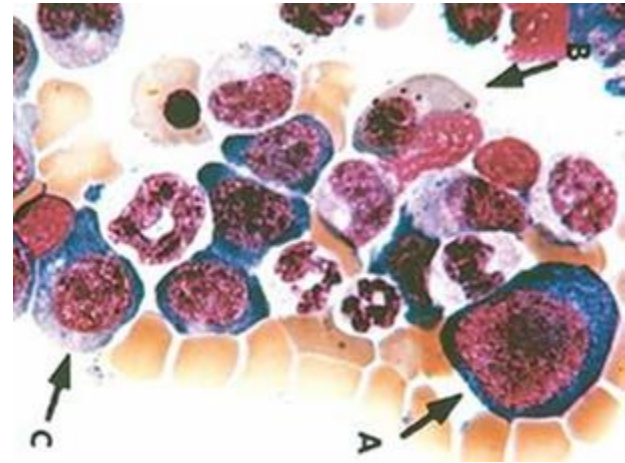


NON-Hemolytic Anemias: i.e., DE-creased Production

- “Megaloblastic” Anemias
- B12 Deficiency (Pernicious Anemia)
- Folate Deficiency
- Iron Deficiency
- Anemia of Chronic Disease
- Aplastic Anemia
- “Pure” Red Cell Aplasia
- OTHER forms of Marrow Failure

MEGALOBLASTIC ANEMIAS

- Differentiating megaloblasts (marrow) from macrocytes (peripheral smear, $MCV > 94$)
- Impaired DNA synthesis
- For all practical purposes, also called the anemias of B12 and FOLATE deficiency



etiology

Decreased intake

Inadequate diet, vegetarianism

Impaired absorption

Intrinsic factor deficiency

Pernicious anemia

Gastrectomy

Malabsorption states

Diffuse intestinal disease, e.g., lymphoma, systemic sclerosis

Ileal resection, ileitis

Competitive parasitic uptake

Fish tapeworm infestation

Bacterial overgrowth in blind loops and diverticula of bowel

Increased requirement

Pregnancy, hyperthyroidism, disseminated cancer

Vit-B12 Physiology

- **Oral ingestion**
- **Combines with INTRINSIC FACTOR in the gastric mucosa**
- **Absorbed in the terminal ileum**
- **DEFECTS at ANY of these sites can produce a MEGALOBLASTIC anemia**

Please remember that ALL megaloblastic anemias are also MACROCYTIC (MCV>94 or MCV~100), and that not only are the RBC's BIG, but so are the neutrophils, and neutrophilic precursors in the bone marrow too, and even more so, HYPERSEGMENTED!!!

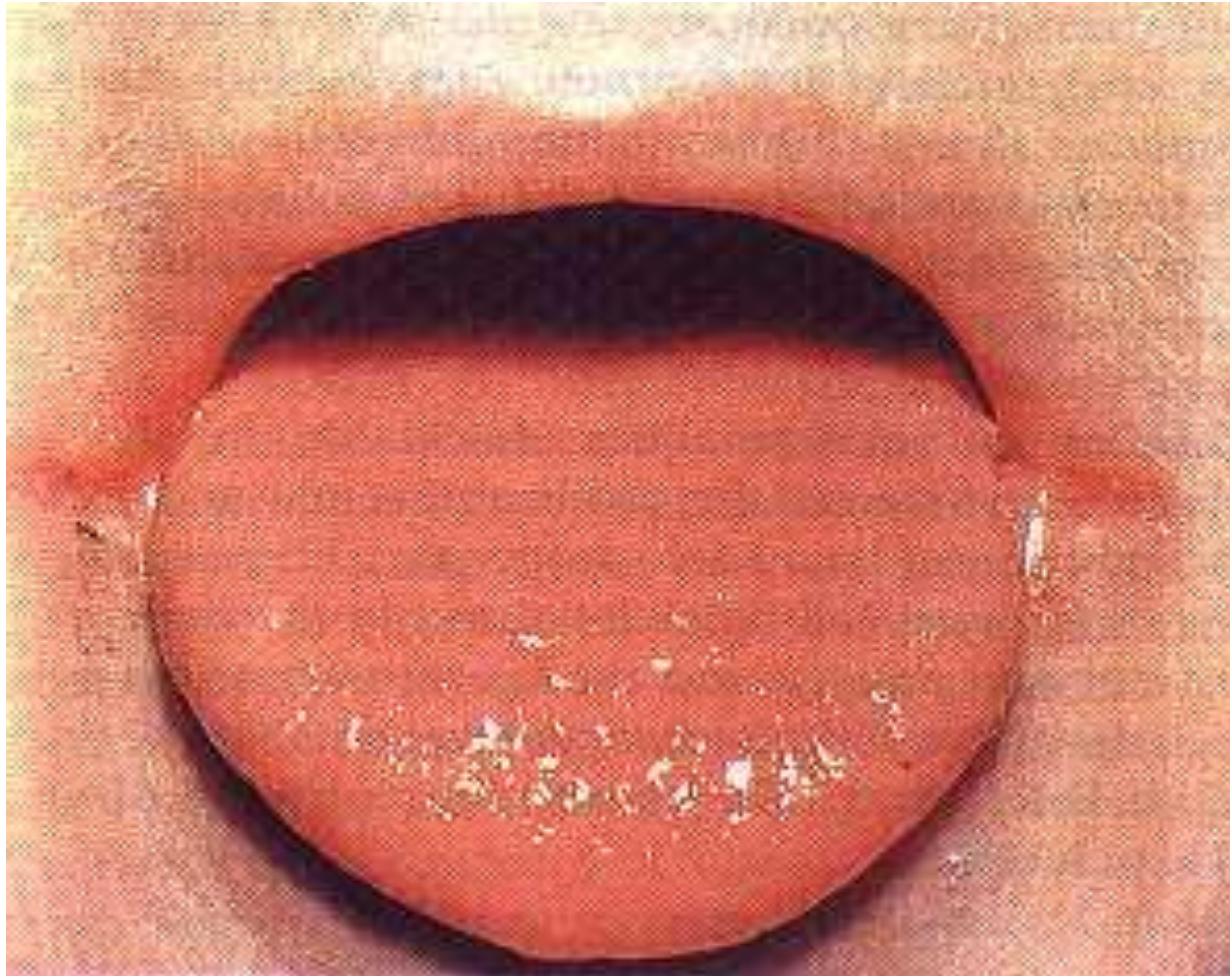
FOLATE DEFICIENCY MEGALOBLASTIC ANEMIAS

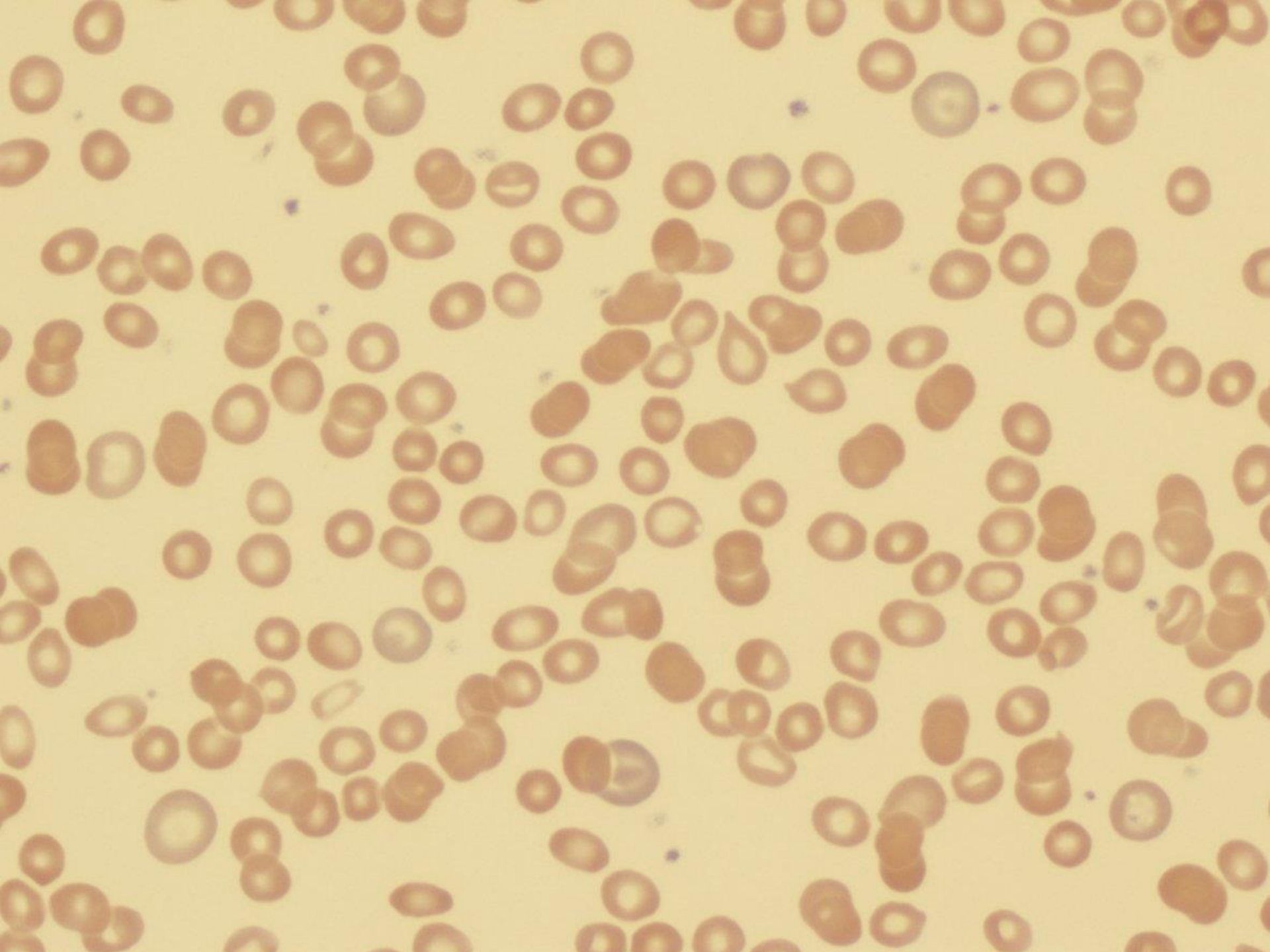
- **Decreased Intake:** diet, etoh-ism, infancy
- **Impaired Absorption:** intestinal disease
- **DRUGS:** anticonvulsants, BCPs, CHEMO
- **Increased Loss:** Hemodialysis
- **Increased Requirement:** Pregnancy, infancy
- **Impaired Usage**

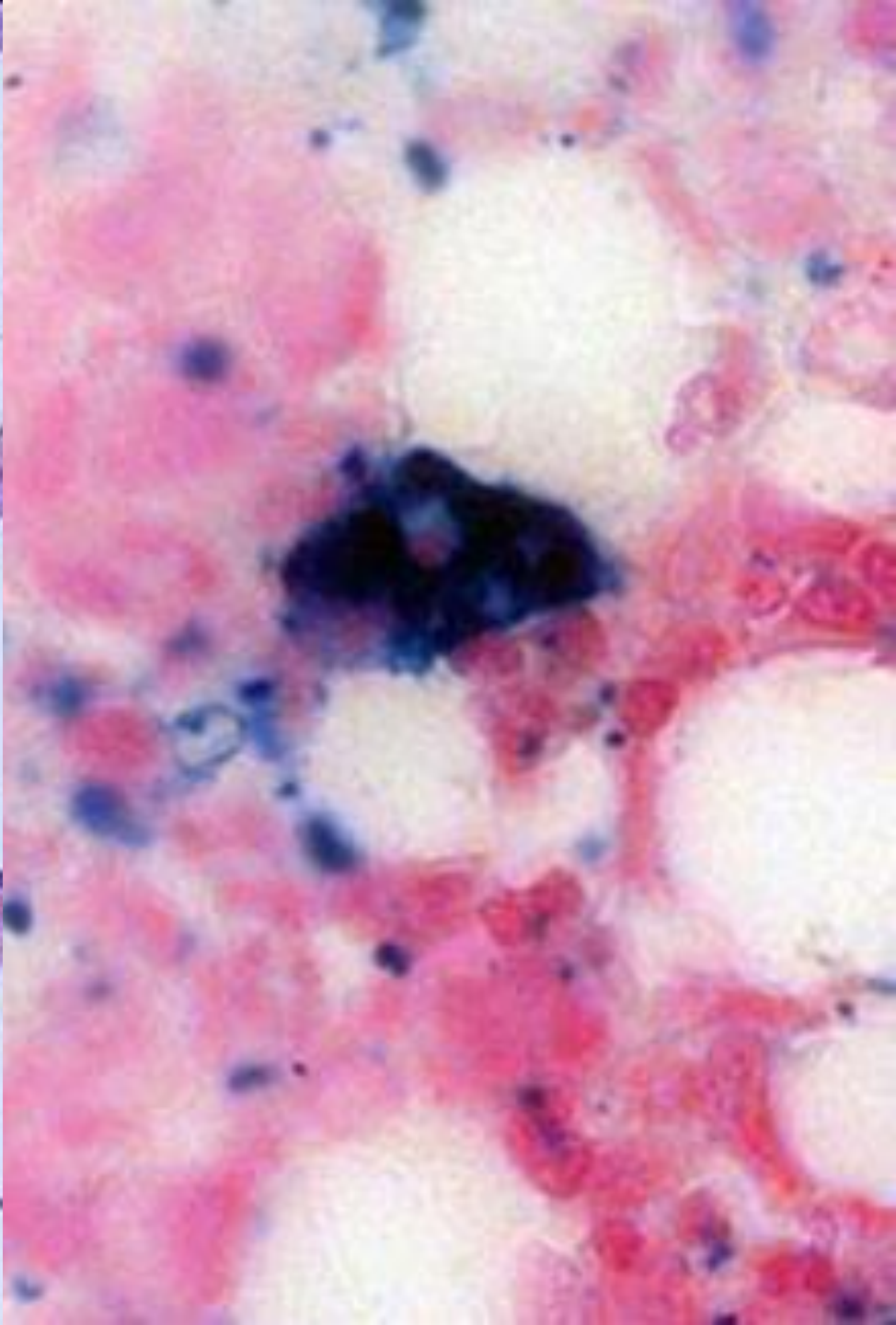
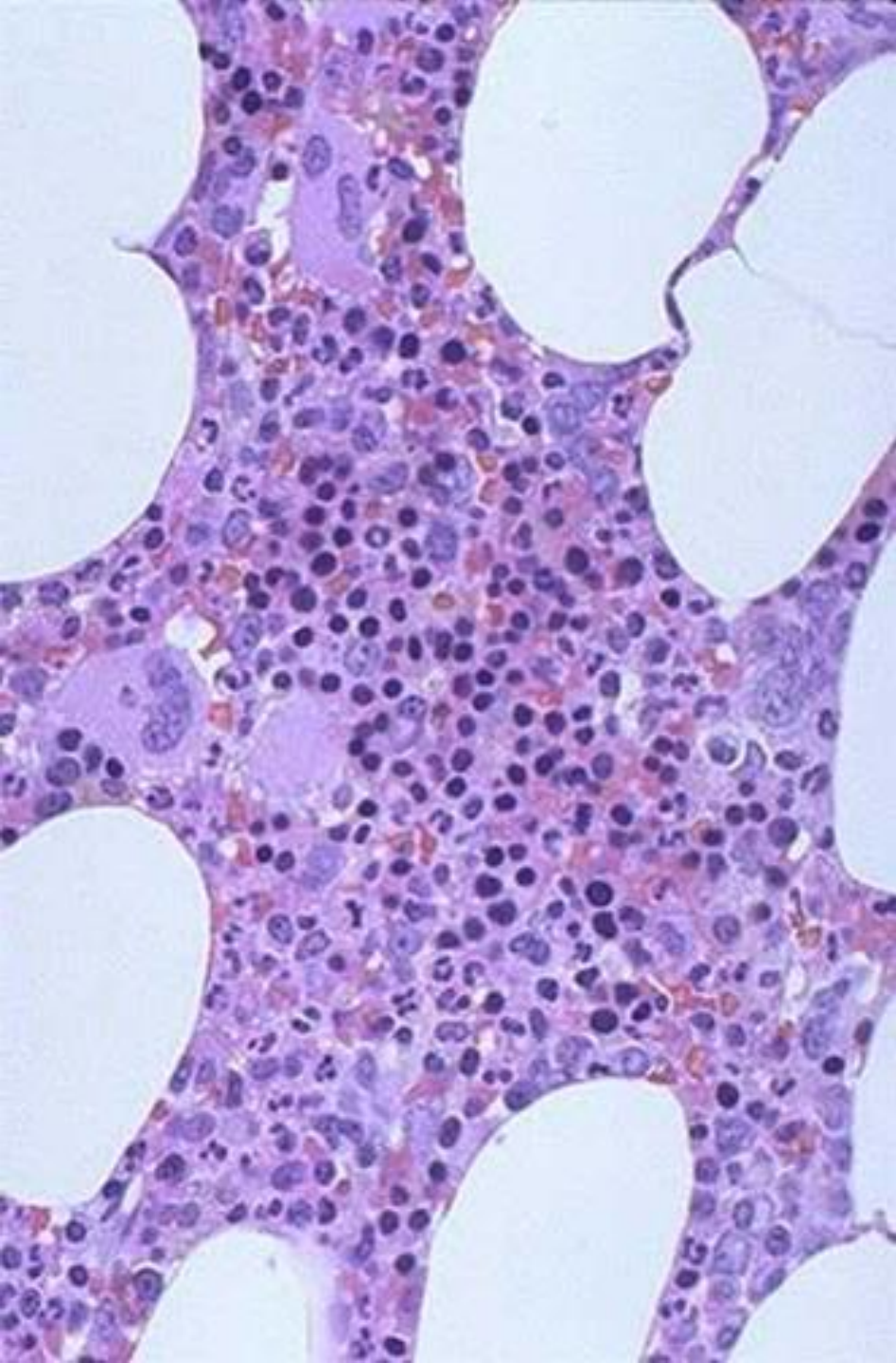
Clinical Fe-Defic-Anemia

- **Adult men: GI Blood Loss**
- **PRE menopausal women: menorrhagia**
- **POST menopausal women: GI Blood Loss**

Clinical Fe-Defic-Anemia







Anemia of Chronic Disease*

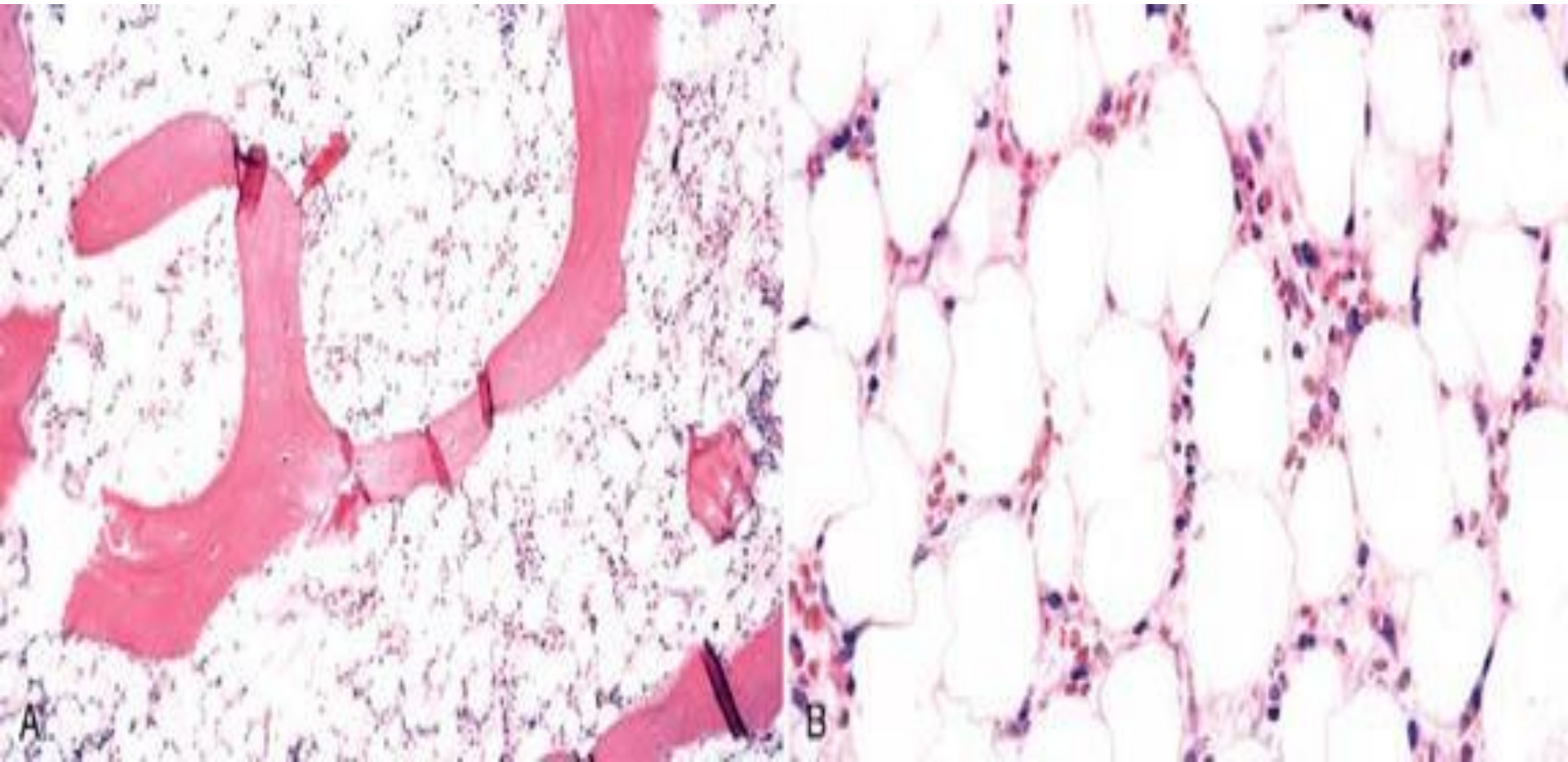
- **CHRONIC INFECTIONS**
- **CHRONIC IMMUNE DISORDERS**
- **NEOPLASMS**
- **LIVER, KIDNEY failure**

* Please remember these patients may very very much look like iron deficiency anemia, BUT, they have **ABUNDANT STAINABLE HEMOSIDERIN** in the marrow!

APLASTIC ANEMIAS

- **ALMOST ALWAYS** involve platelet and WBC suppression as well
- Some are idiopathic, but **MOST** are related to drugs, radiation
- **FANCONI's ANEMIA** is the only one that is inherited, and **NOT** acquired
- Act at **STEM CELL** level, except for "pure" red cell aplasia

APLASTIC ANEMIAS

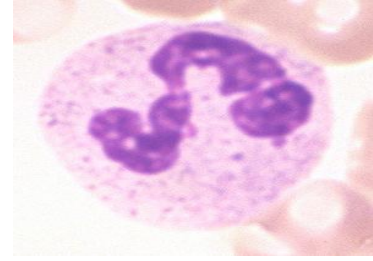
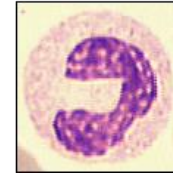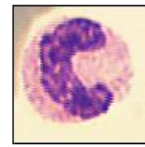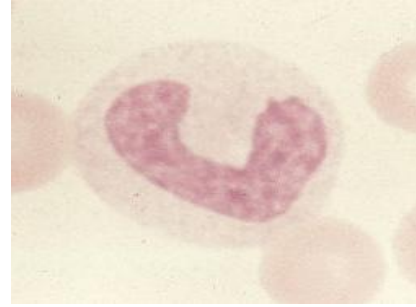
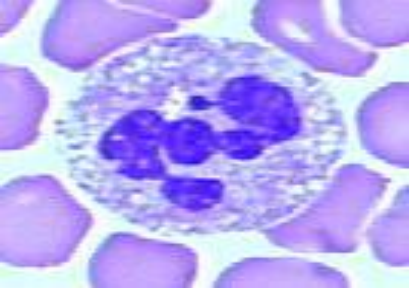


APLASTIC ANEMIAS

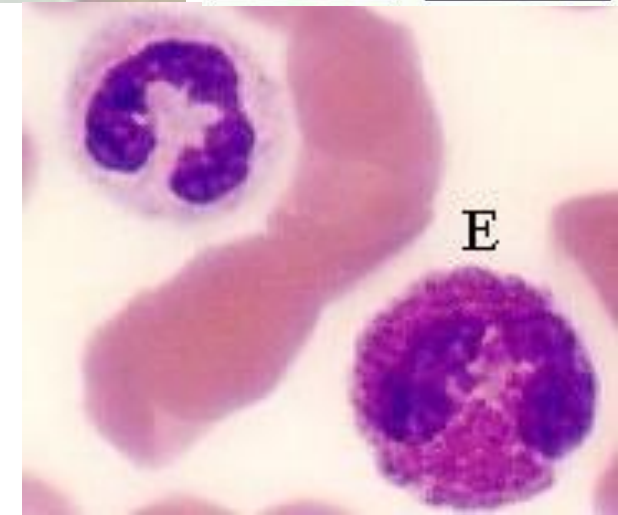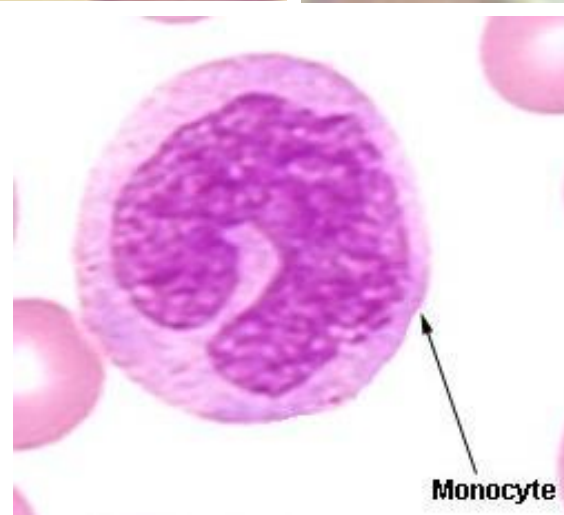
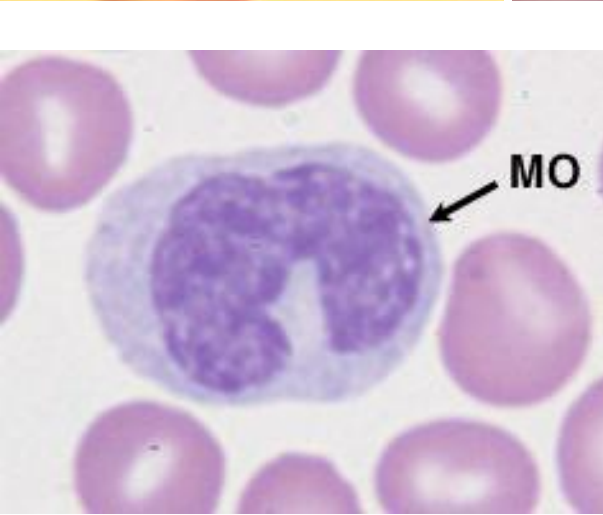
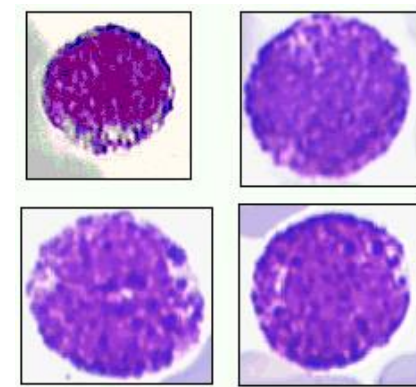
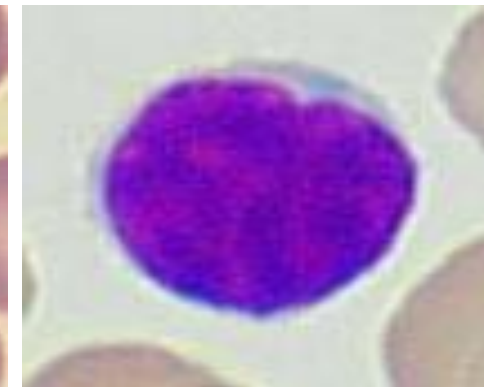
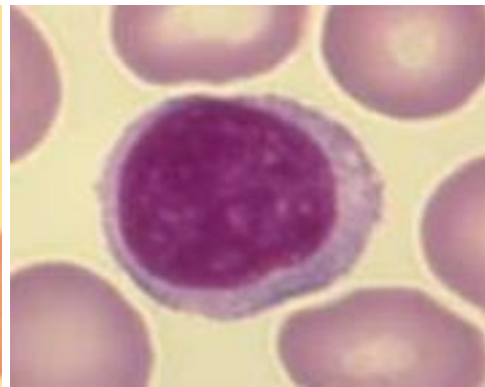
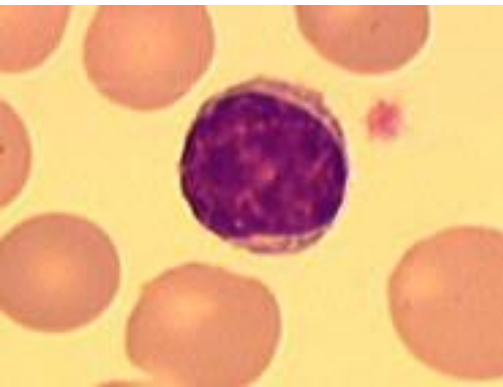
- CHLORAMPHENICOL
- OTHER ANTIBIOTICS
- CHEMO
- INSECTICIDES
- VIRUSES
 - EBV
 - HEPATITIS

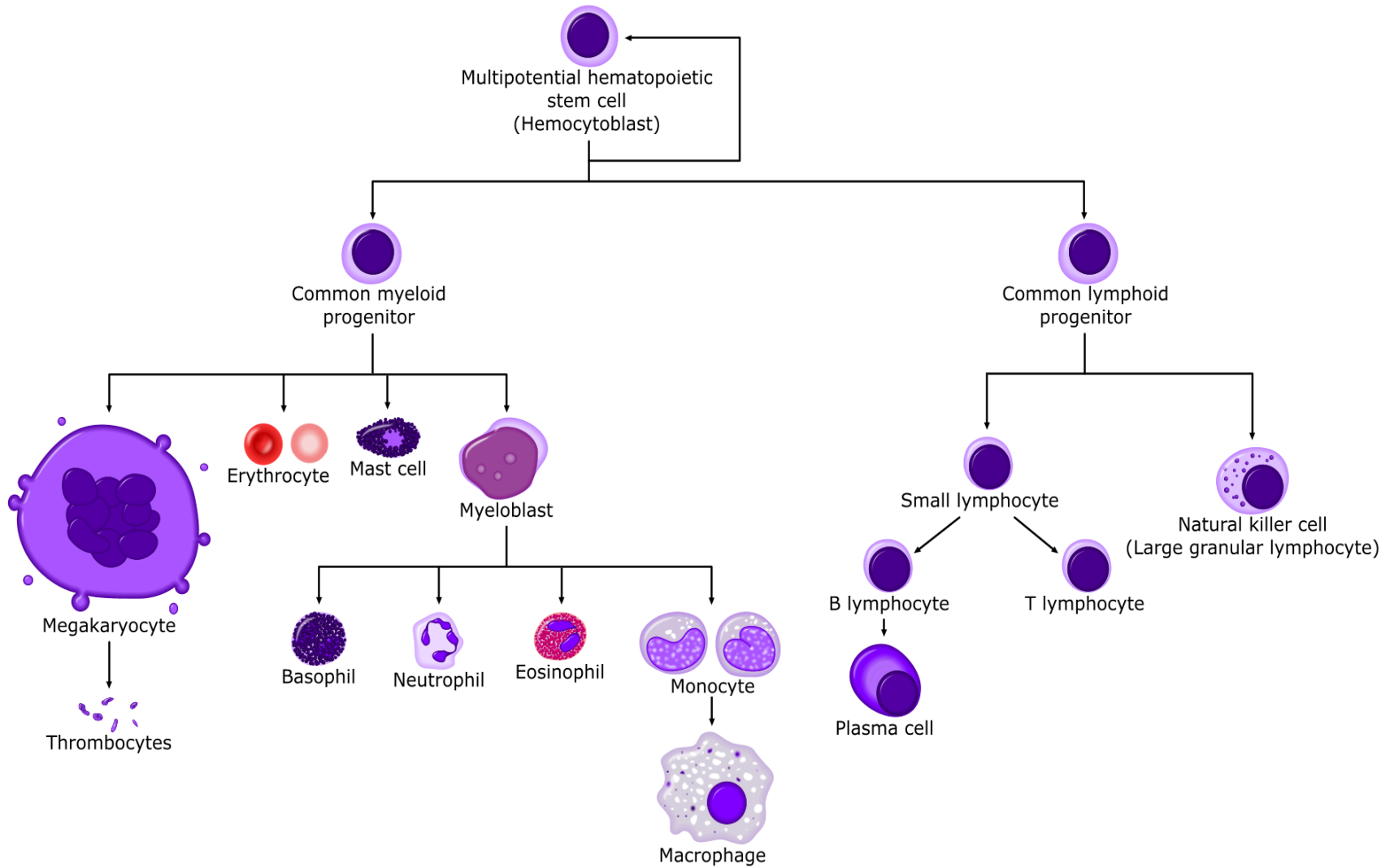
MYELOPHTHISIC ANEMIAS

- **Are anemias caused by metastatic tumor cells replacing the bone marrow extensively**



DISEASES OF WHITE CELLS AND LYMPHOID TISSUE

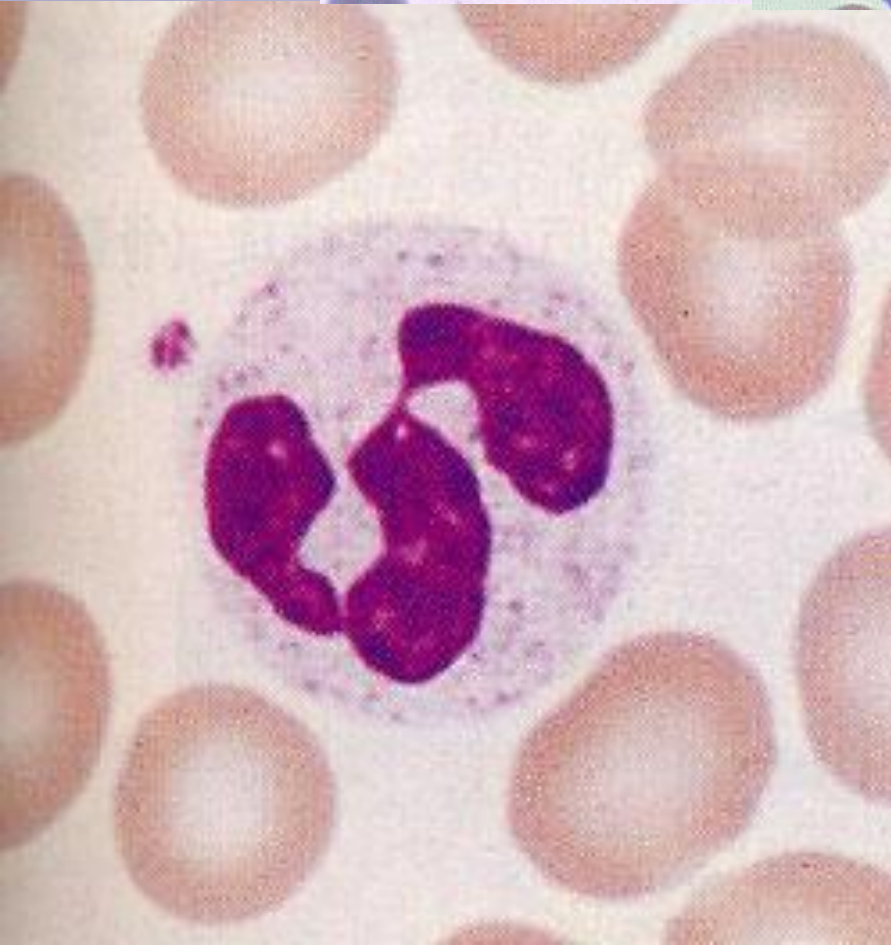
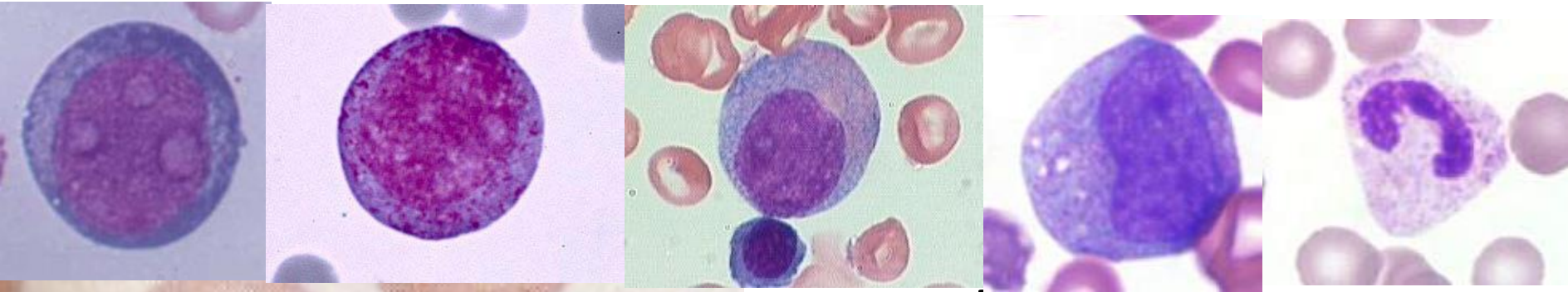




Myeloid

Lymphoid

NEUTROPHIL



Neutrophil

**Polymorphonuclear
Leukocyte, PMN, PML**

“Leukocyte”

**Granulocyte, Neutrophilic
granulocyte**

“Poly-”

Polymorph

LEUKO-penia/NEUTRO-penia
Neutropenia/Agranulocytosis

- **INADEQUATE PRODUCTION**
- **INCREASED DESTRUCTION**

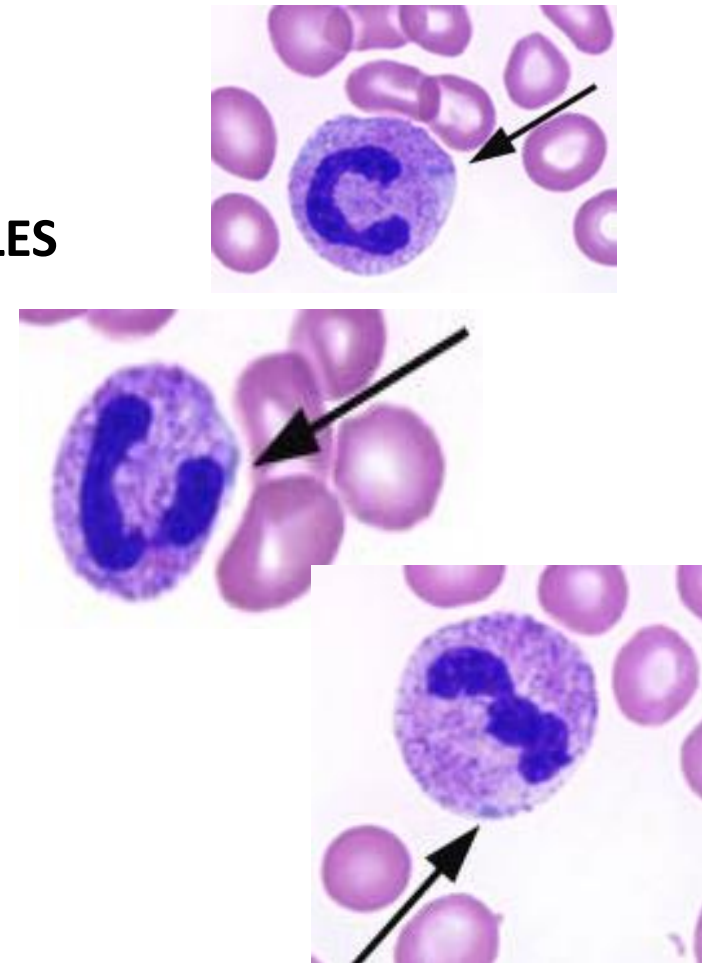
- **500-1000/mm³ is the DANGER zone!**

Leukocytosis/Neutrophilia

- Marrow and splenic pool size
- Rate of release between pool and circulation
- Marginating pool
- Rate of WBCs (neutrophils/monocytes) leaving the vascular compartment
- NON-vascular pools FIFTY times larger than the vascular pools
- TNF/IL-1/cytokines stimulate T-cells to produce CSF, the WBC equivalent of EPO

NEUTROPHIL INCREASES (e.g., “NEUTROPHILIA”)

- BACTERIA
- TISSUE NECROSIS, e.g., MI
- DÖHLE BODIES (e.r. remnants) and TOXIC GRANULES are often seen with NEUTROPHILIA
- Accompanied by a “LEFT” shift



LEUKEMIAS

- **MALIGNANT PROLIFERATIONS of WHITE BLOOD CELLS**
- **In the case of neutrophilic precursors, the primary process is marrow and peripheral blood, but can involve any organ or tissue which receives blood**
- **In the case of lymphocytes, there is an intimate concurrence with malignant lymphomas**

LEUKEMIAS

These are composed of two major groups: myeloid (granulocytic) and lymphoid.

Causes: The cause is unknown but some predisposing factors have been recognized:

1. Myelodysplastic syndromes precede the onset of leukemia
2. Genetic factors may play a role, chromosomal syndromes (Downs, etc.) are associated with increased risk of leukemias.
3. Ionizing radiation; there is increased incidence in those exposed to radiation for treatment or otherwise.
4. Alkylating agents used in chemotherapy are associated with increased risk
5. Viruses: Human T-cell lymphocytic virus-1 (HTLV-1) is an RNA oncogenic virus that causes T-cell leukemias
6. Endogenous oncogenes play a role and are associated with chromosomal breaks, translocations or deletions. The Philadelphia chromosome (translocation of fragments of chromosomes 9 & 22) is associated with the formation of an oncogene (a proto-oncogene on #22 separates from its expression control) and are associated with the development of CML (also ALL & AML to a lesser extent).

Leukemias vs. Lymphomas

- **All leukemias of lymphocytes have lymphoma counterparts**
- **Primary lymphomas can have “leukemic” phases, including multiple myelomas**
- **Any myeloid leukemia can infiltrate a lymph node, or any other site, but if/when it does it is NOT called a lymphoma, but simply a myeloid infiltrate INTO a lymph node**
- **ALL lymphomas are malignant proliferations of lymphocytes**
- **ALL leukemias involve bone marrow changes**

LYMPHOMAS

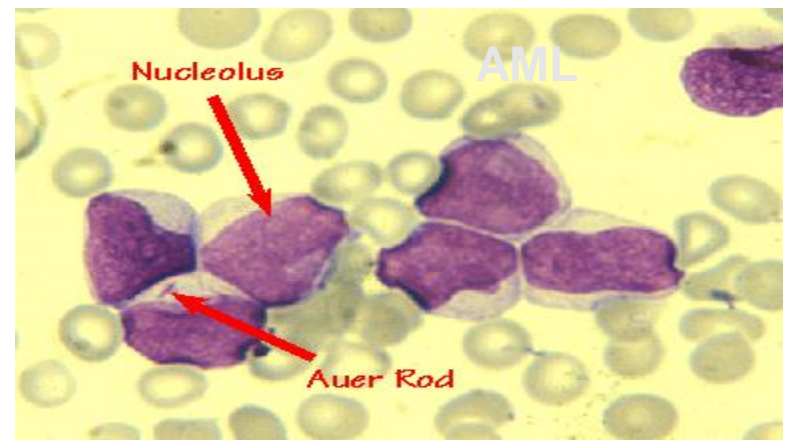
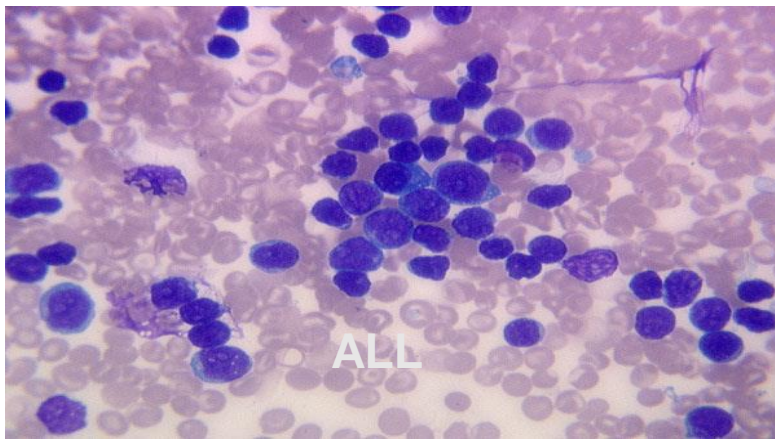
- **NODAL or EXTRANODAL**
- **T or B**
- **SMALL or LARGE CELLS**
- **FOLLICULAR or DIFFUSE**
- **Hodgkins or NON-Hodgkins**
- **“F.A.B. classification” is currently popular this week (French**A**merican**B**ritish), for the NON-Hodgkins lymphomas**

LEUKEMIAS

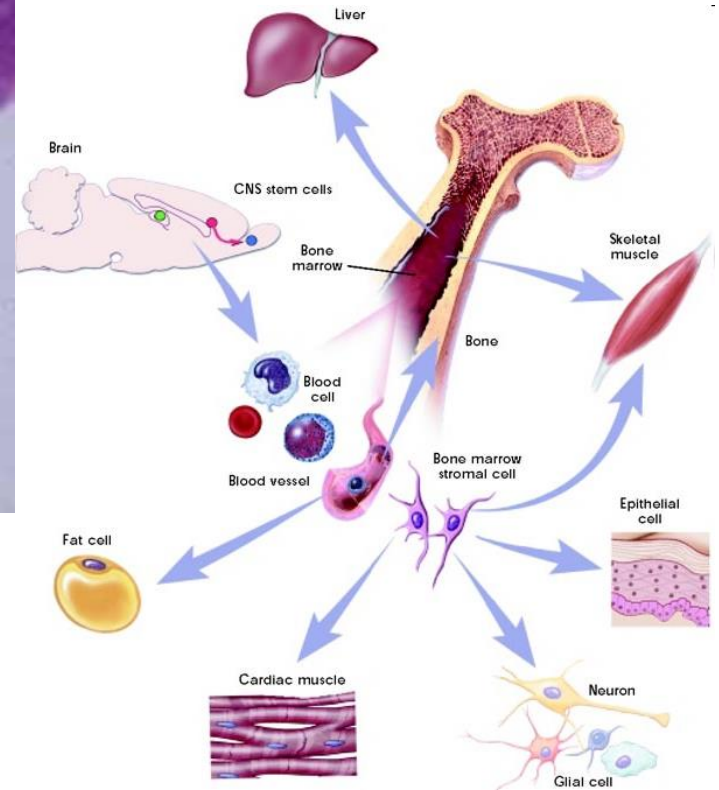
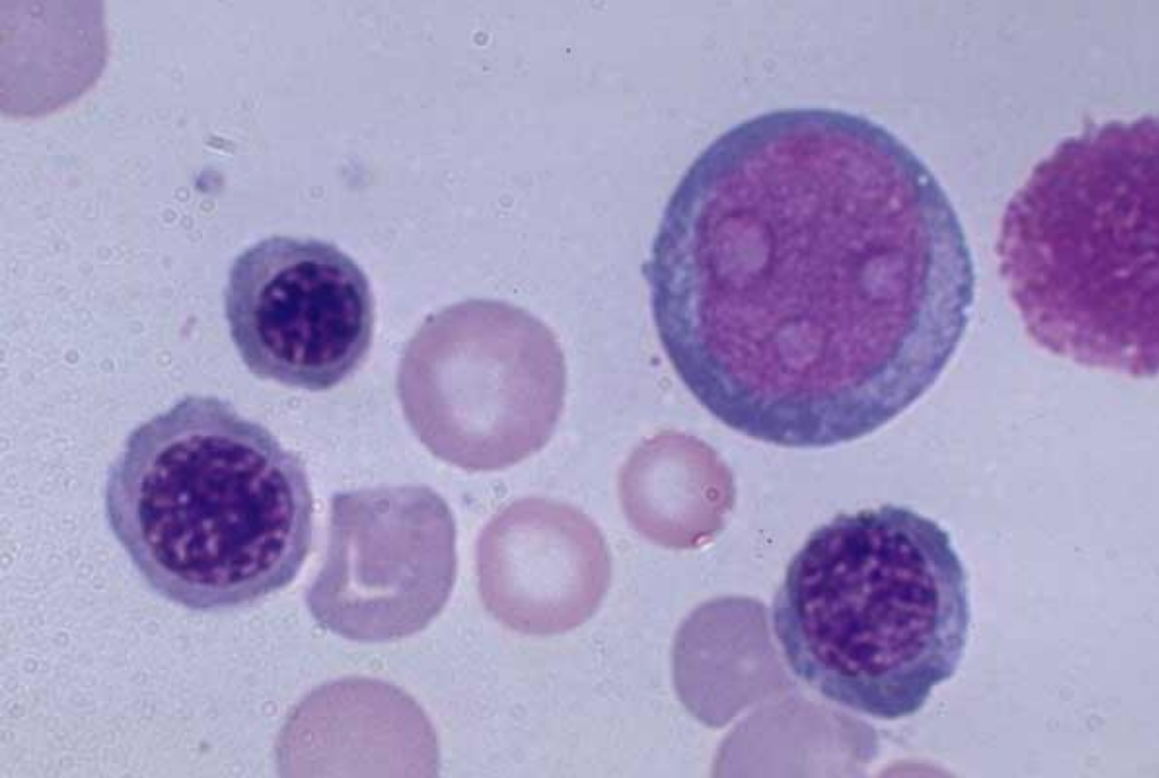
- Acute or Chronic
- Myeloid or Lymphocytic
- Childhood or Adult
- All involve marrow
- All ACUTE leukemias suppress normal hematopoiesis, i.e., have anemia, thrombocytopenia
- Most have chromosomal aberrations
- Some can respond DRASTICALLY to chemo, most notably ALL in children, even be cured!!!!

Types of Leukemias

1. Acute Lymphoblastic leukemia (ALL) ~30% of all leukemias, the most common among children under 5 years old a second peak occurs after age 60. The marrow contains more than 30% lymphoblasts. The prognosis is inversely proportional to age, responds remarkably well to chemotherapy & marrow transplant, 85% long term survival in 1-10 year olds, ~50% in adults.
2. Acute myelogenous leukemia (AML) ~80% of acute leukemias in adults. Marrow has >20% myeloblasts. Overall prognosis is poor with relapse after chemotherapy and most do not survive more than 5 years after diagnosis. Two forms; acute denovo AML(better prognosis ~70% 5 year (especially acute promyelocytic~90% 5 year) or as an end-stage of CML and myelofibrosis (poorer prognosis~15% 5 year).



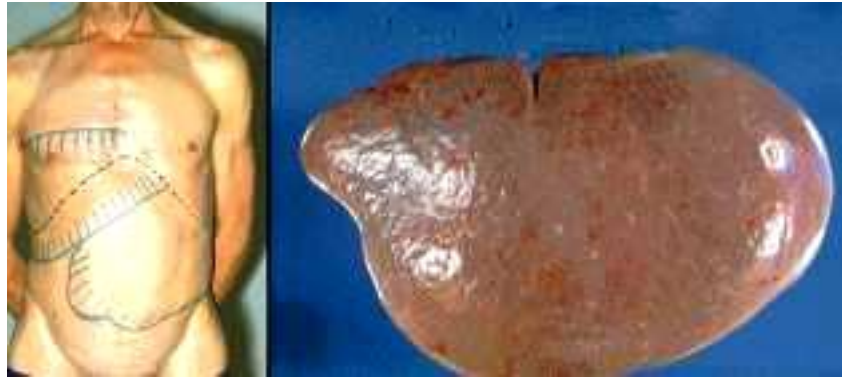BLAST



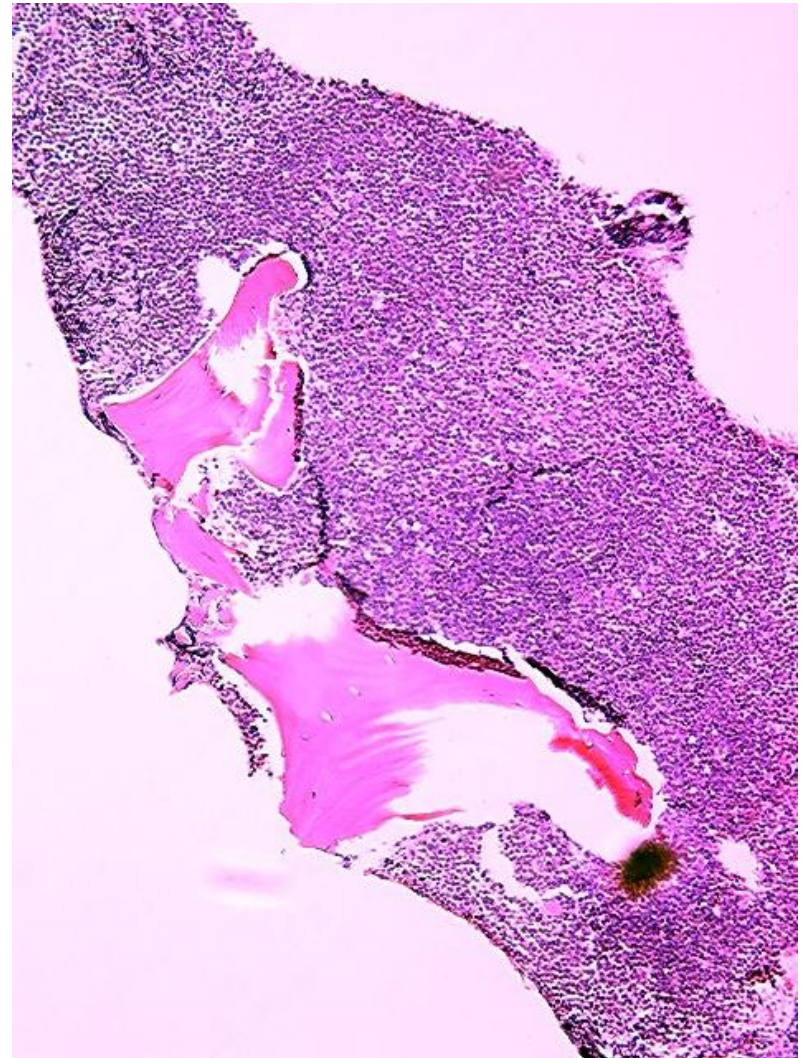
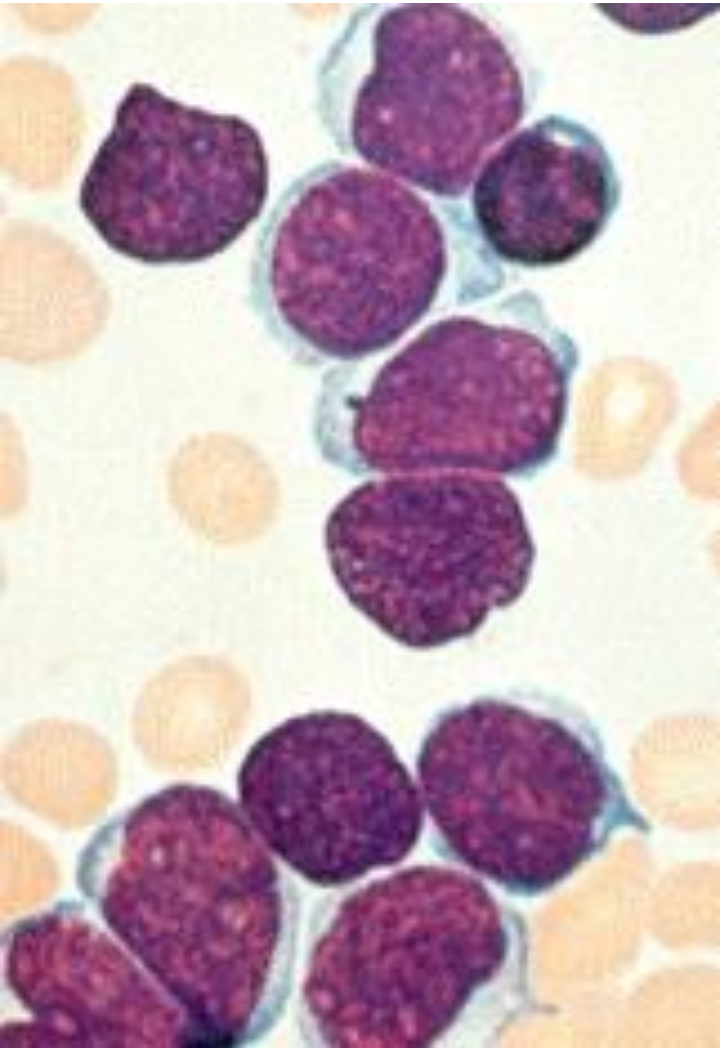
Types of Leukemias

3. **Chronic lymphocytic leukemia (CLL)** Peak incidence is in elderly males >60 years old. Bone marrow has >40% lymphoid cells, peripheral blood has >150,000. Neoplastic cells resemble B-lymphocytes and infiltrate marrow, spleen, liver & nodes. CLL has an indolent course over 7-10 years, it responds poorly to chemotherapy. It is closely related to small cell lymphoma and lymphadenopathy is common.
4. **Chronic myelogenous leukemias (CML)** Peak incidence is 35-50 years old. Symptoms are related to loss of normal marrow functioning; anemia, bleeding & infection. Associated with the presence of the Philadelphia chromosome. Peripheral WBC counts in the 20-50,000 range with large component of “more mature” myeloid precursors. Prominent splenomegaly, greater than hepatomegaly or adenopathy. Frequently terminates in a “blast” crisis with peripheral WBCs of >100,000 with immature myeloid cells. Prognosis is poor despite chemotherapy.

ORGANOMEGALY



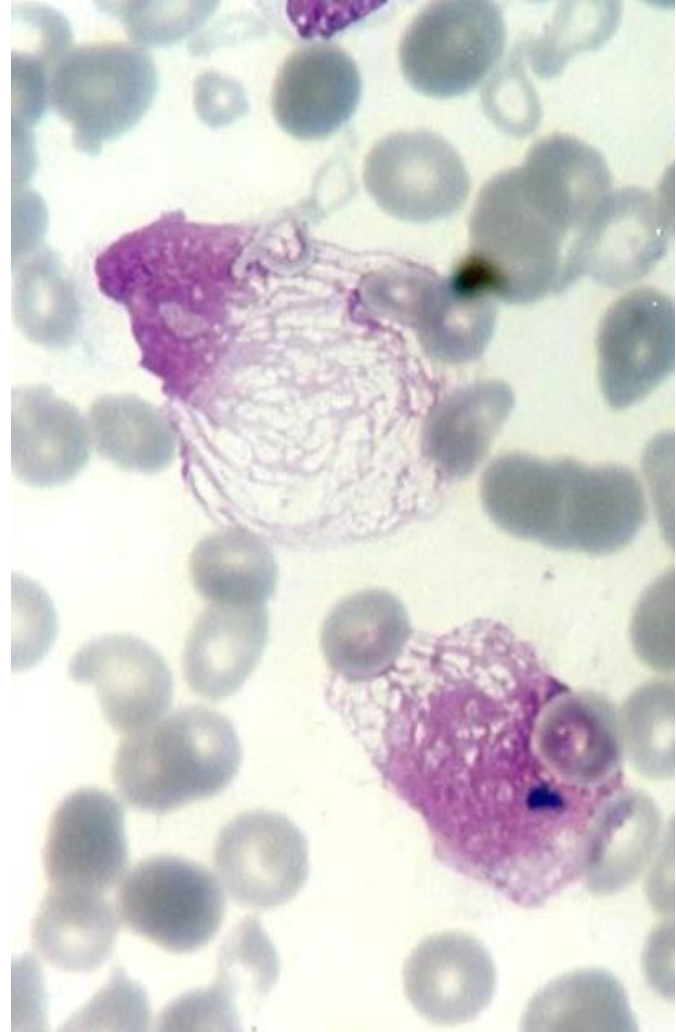
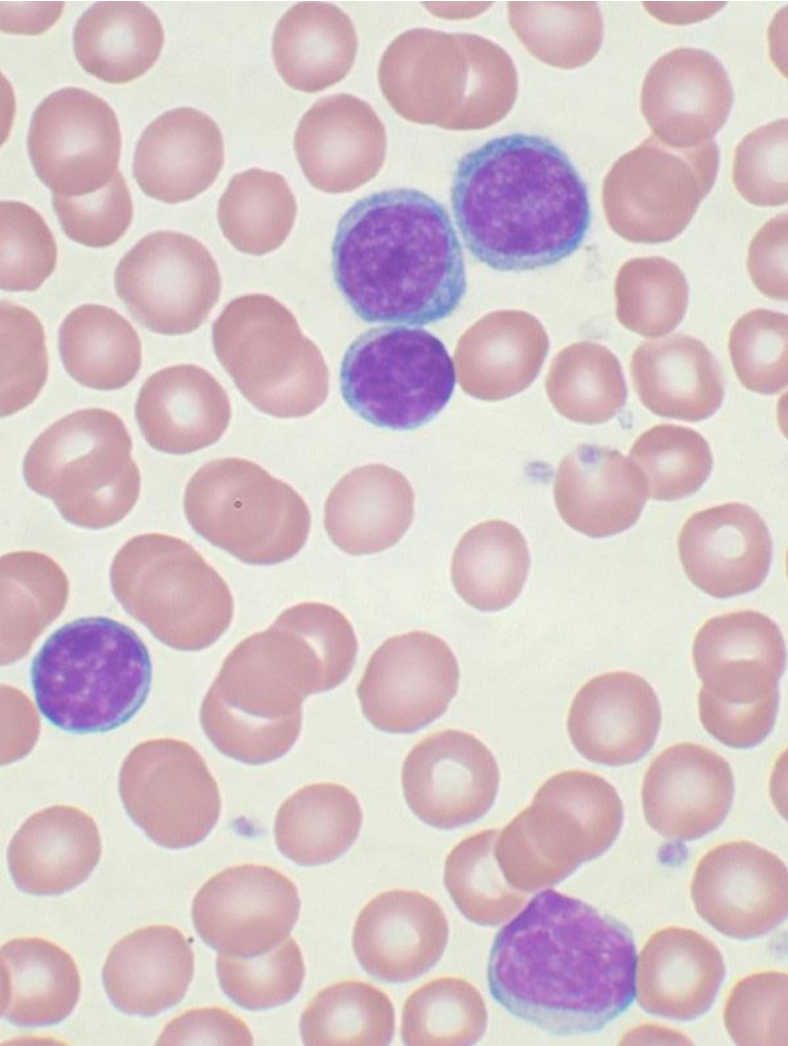
A.L.L.



C.L.L.

- **Unexplained sustained (months) lymph count of $> 4000/\text{mm}^3$ is CLL, usually picked up on CBC**
- **M>F**
- **Lymphs look normal and are NOT blasts**
- **No need for marrow exam for dx, but progressive involvement of marrow, nodes, and other organs is the usual biologic behavior**
- **Liver can be involved portally or sinusoidally**
- **Translocations RARE, but trisomies and deletions common**

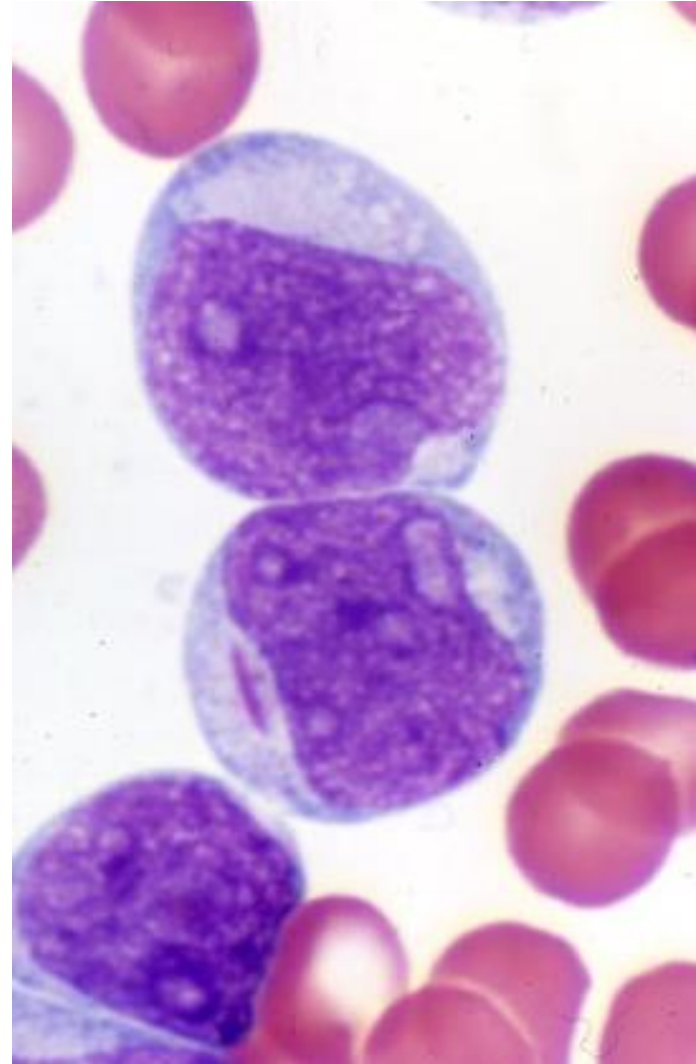
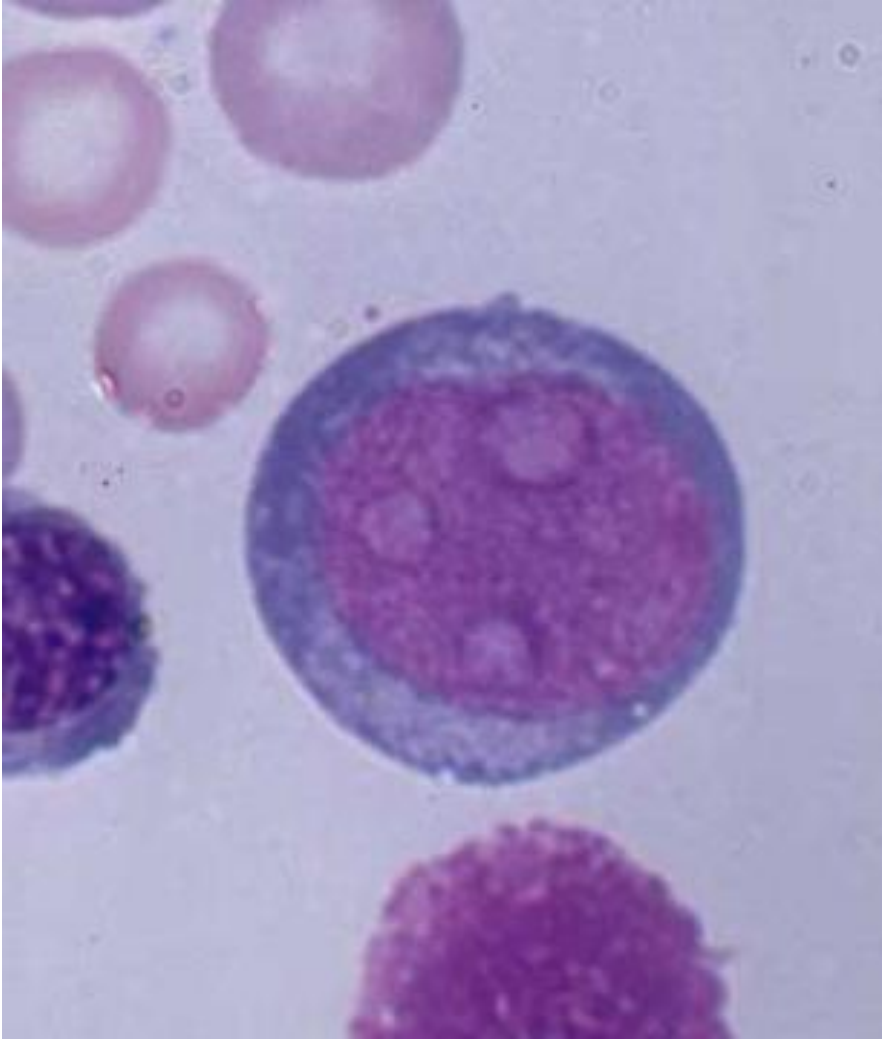
C.L.L.



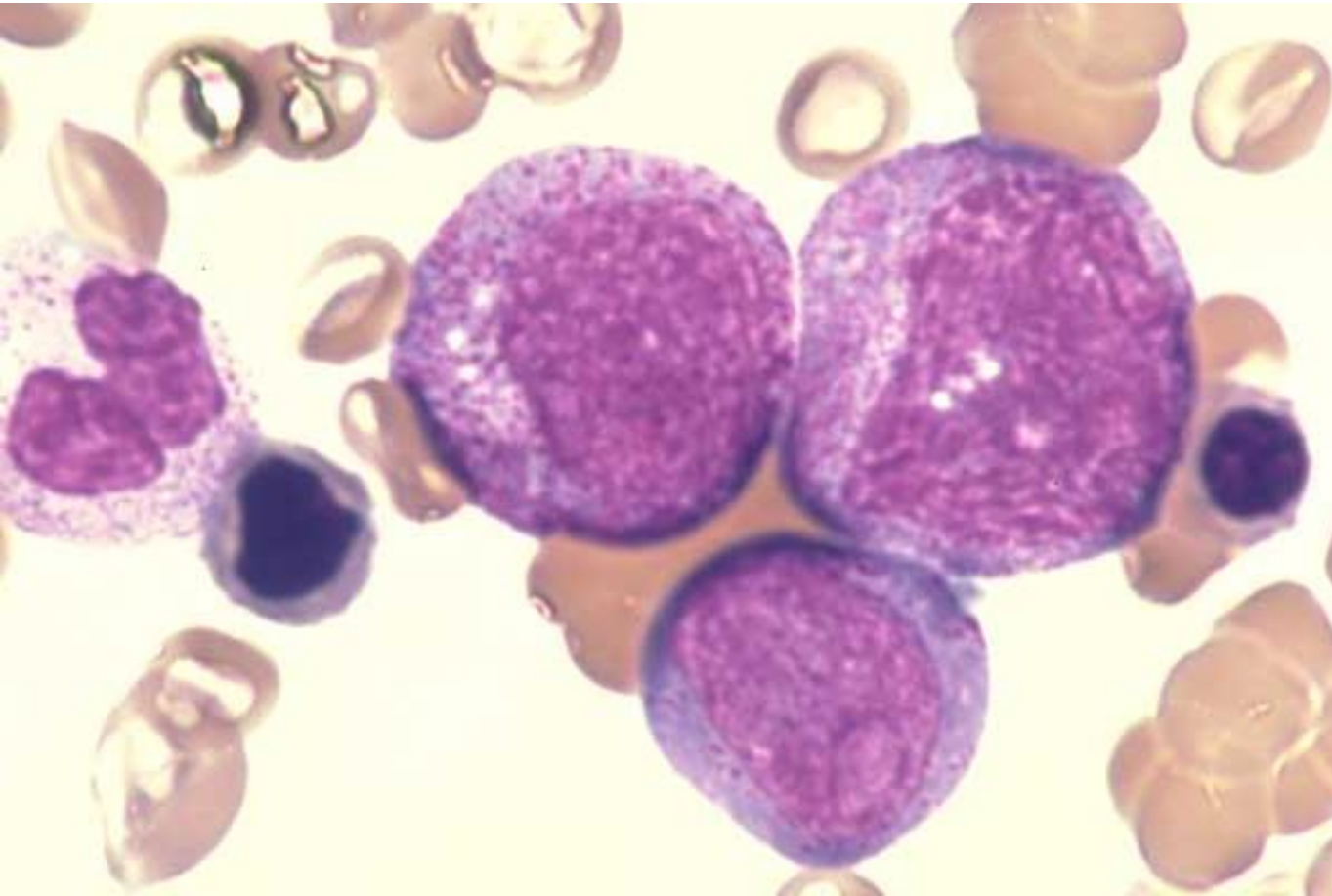
A.M.L.

- GENETIC ABERRATIONS INHIBIT DIFFERENTIATION
- Many have various TRANSLOCATIONS
- F.A.B. classifies them as M0 → M7
- MORE than 20% of BLASTS are needed in the marrow for a diagnosis of acute leukemia!!! (i.e., ANY kind of BLAST)
- NORMALLY, a marrow should have only about 1-2 % blasts

M0 → M2



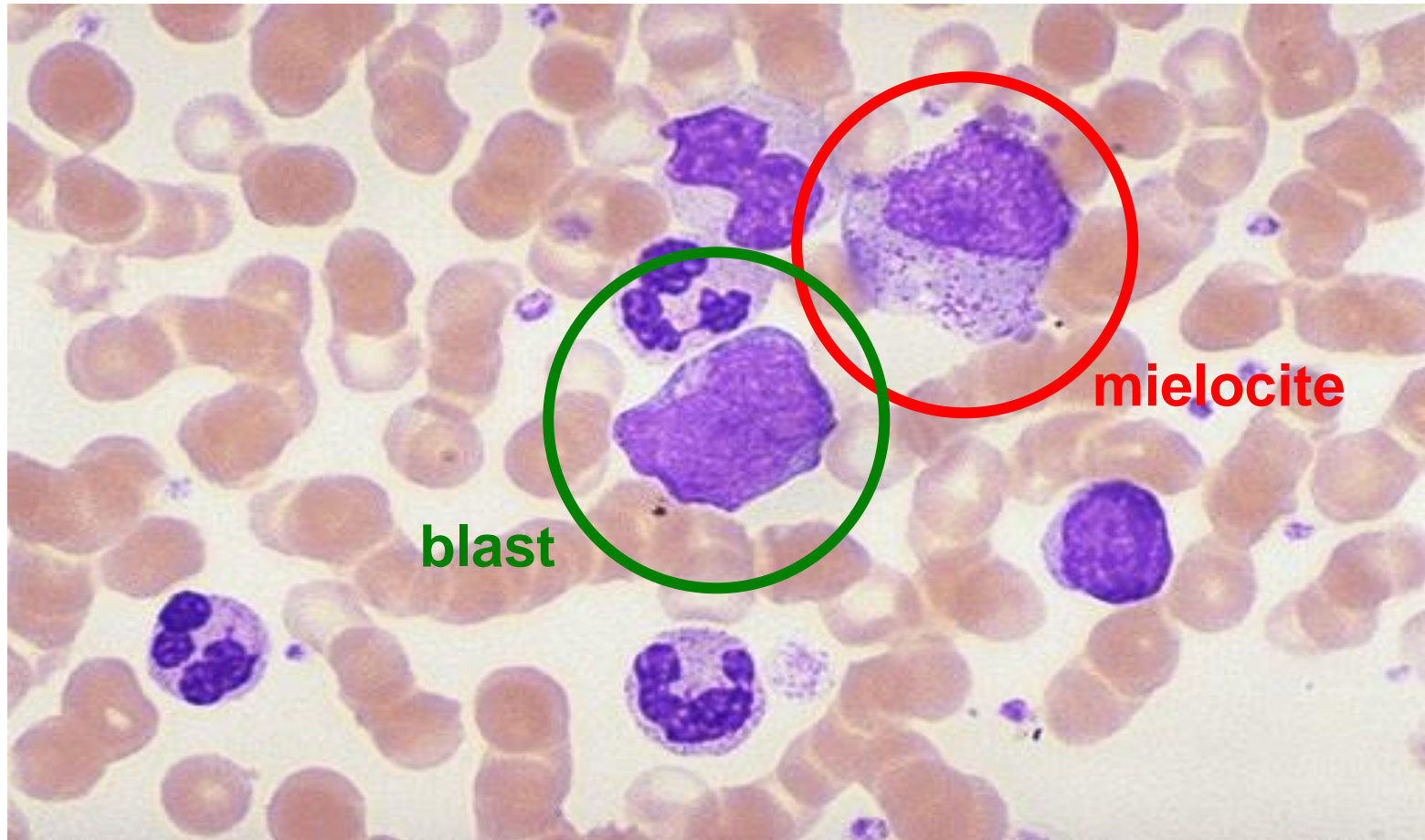
M3




A.M.L.

- Anemia
- Thrombocytopenia (bleeding)
 - Petechiae
 - Ecchymoses
- Fever
- Fatigue
- Lymphadenopathy
- 60% respond, BUT only 20 % are free of remission after 5 years, WORSE than A.L.L.

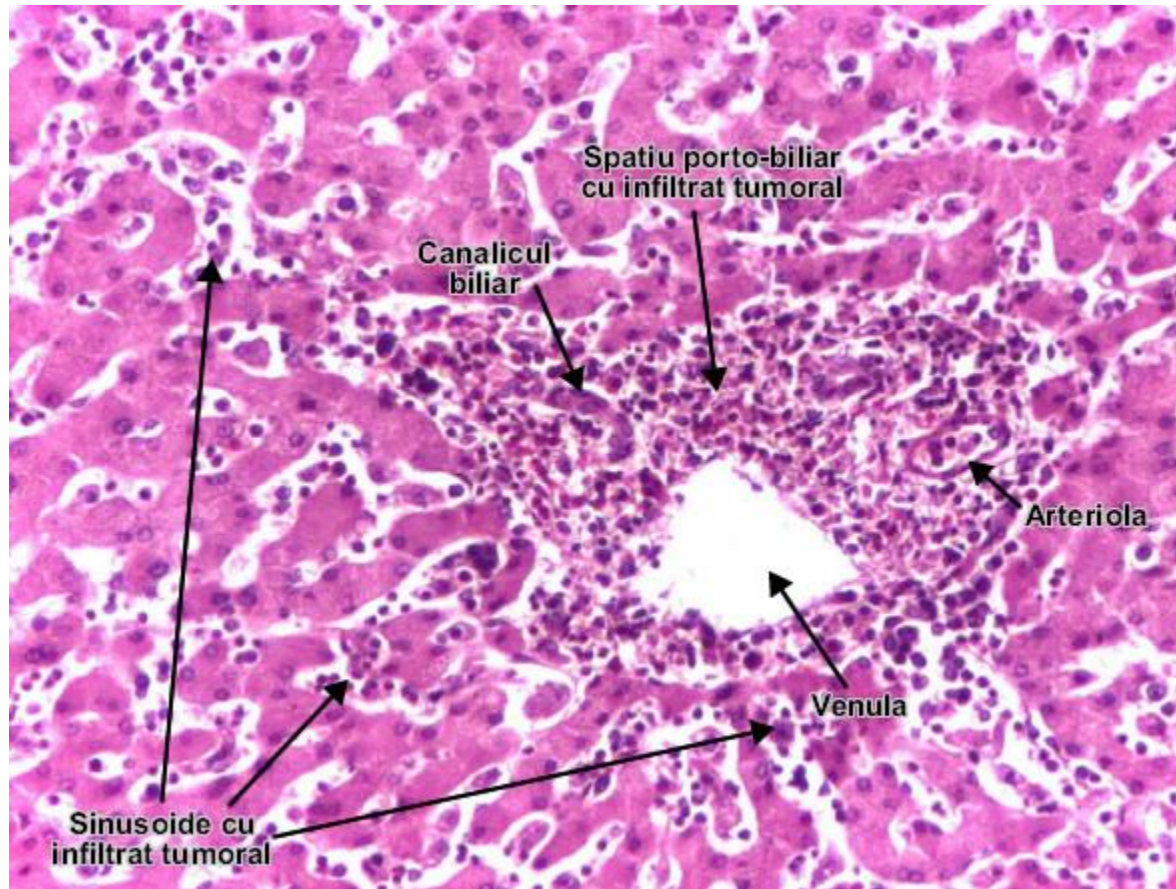
CML high-power



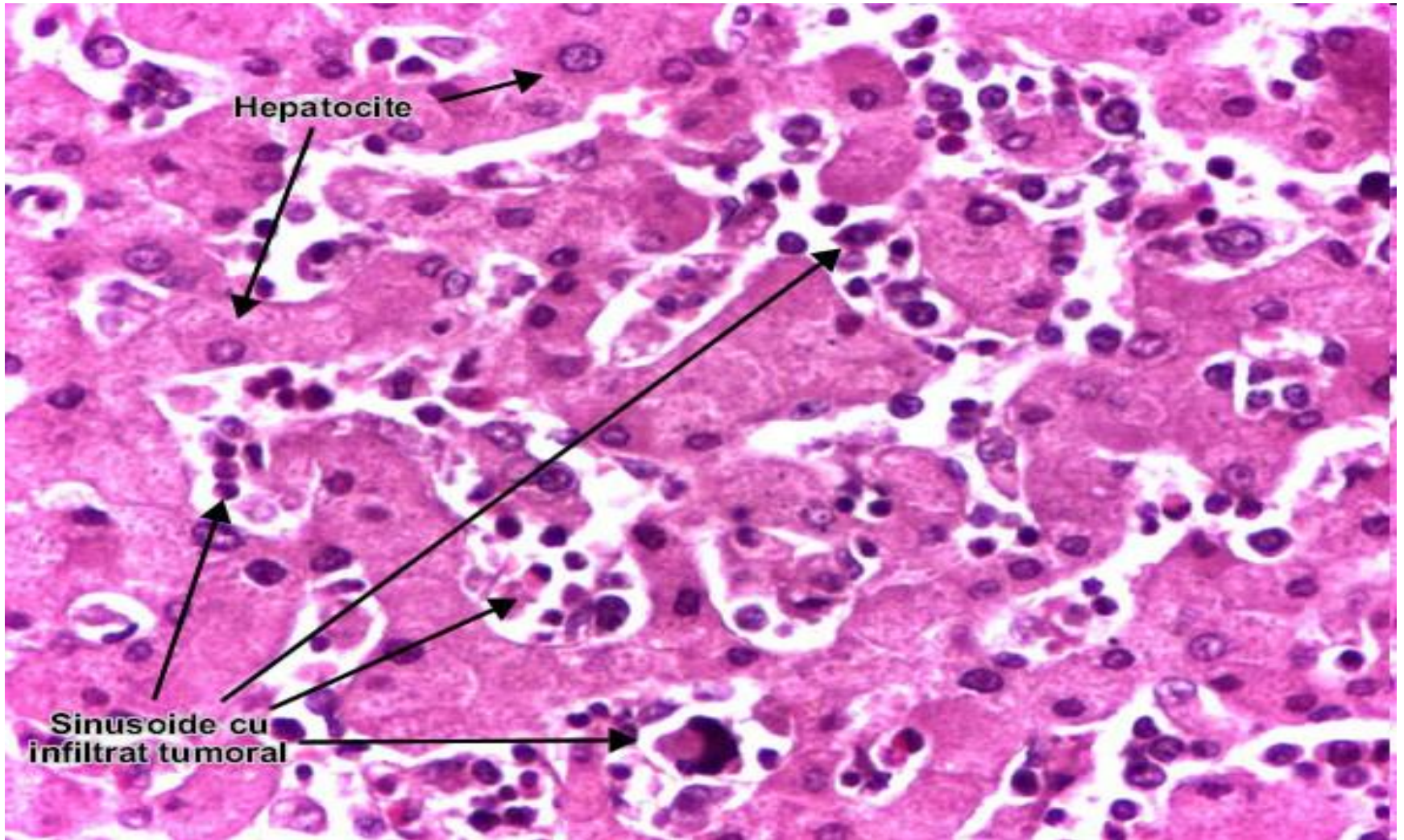
Massive splenomegaly in CML



CLL



CML



PLASMA CELL DISORDERS

Main types

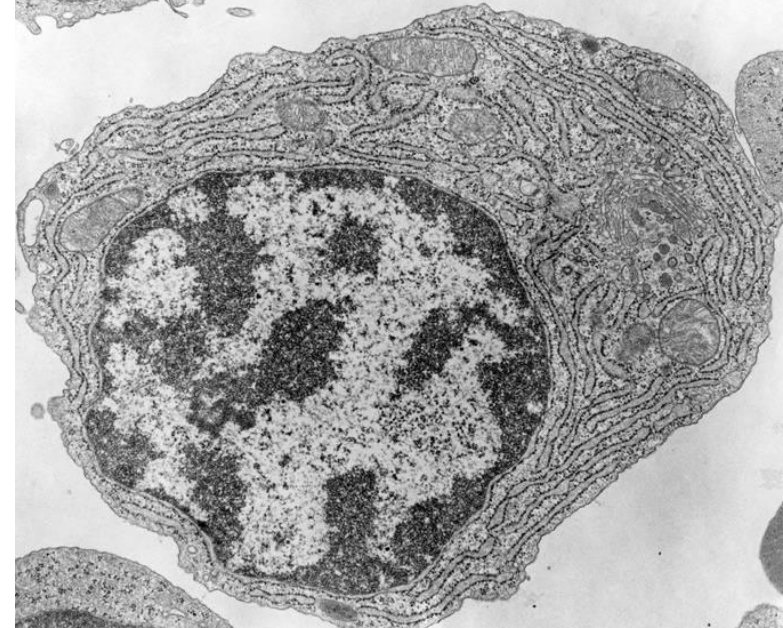
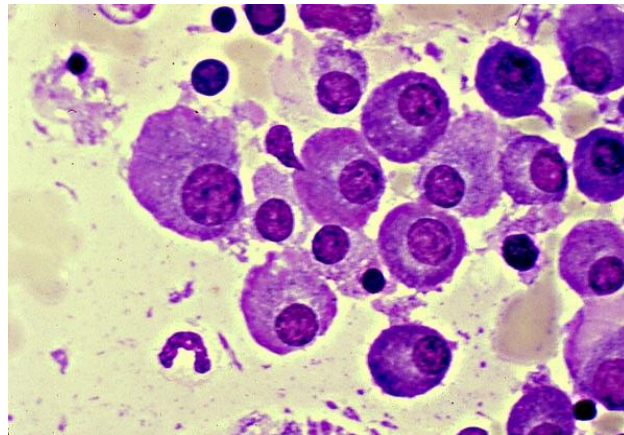
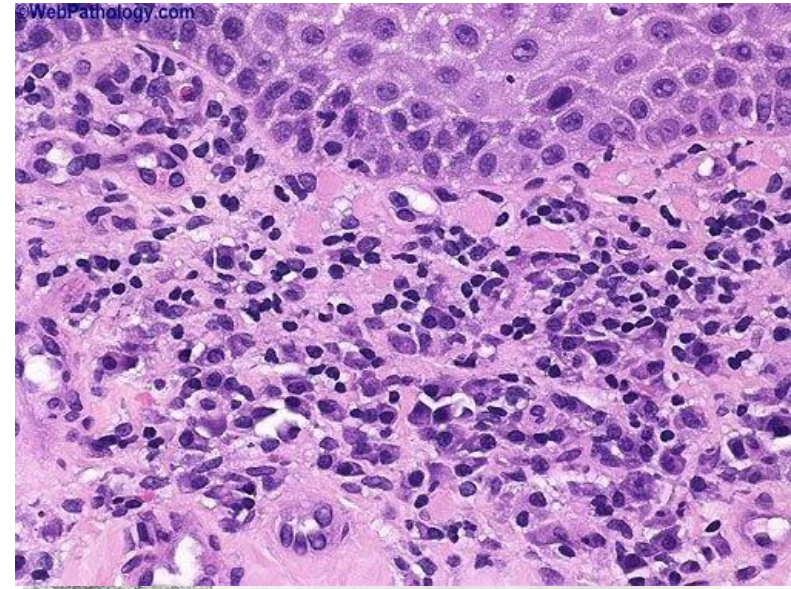
- **Multiple myeloma**
- **Waldenstrom macroglobulinemia:** A malignancy of plasmacytoid lymphocytes that secrete IgM resulting in a hyperviscosity syndrome with renal, retinal and cerebral ischemia as a result of microvascular occlusion. Infiltration of plasmacytoid cells in the marrow, spleen and nodes.
- **Monoclonal gammopathy of unknown significance:** often diagnosed in asymptomatic elderly patients. It is present in ~1% of patients over 60 years old and 3% of patients over 70. There is a 1% risk of developing multiple myeloma. The vast majority suffer no ill effects.

Clinical features

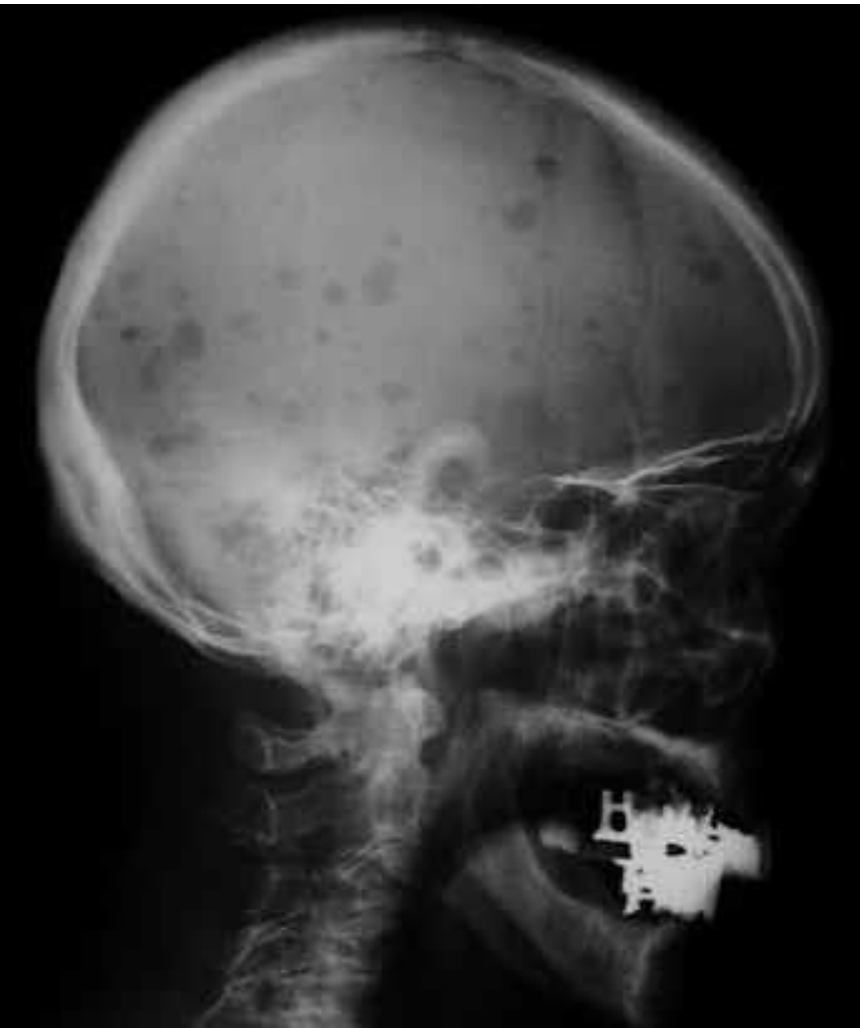- Tend to occur in those >45 years old.
- Neoplastic plasma cells produce a monoclonal immunoglobulin component that can be identified by serum electrophoresis
- Deposition of light chain immunoglobulin may form amyloid deposits in the kidneys, vessels and other organs.

PLASMA CELL classic features

- **OVAL** cytoplasm, **ROUND** nucleus off to side
- **Cartwheel/Clockface** chromatin
- **Prominent Golgi** or “Hoff”

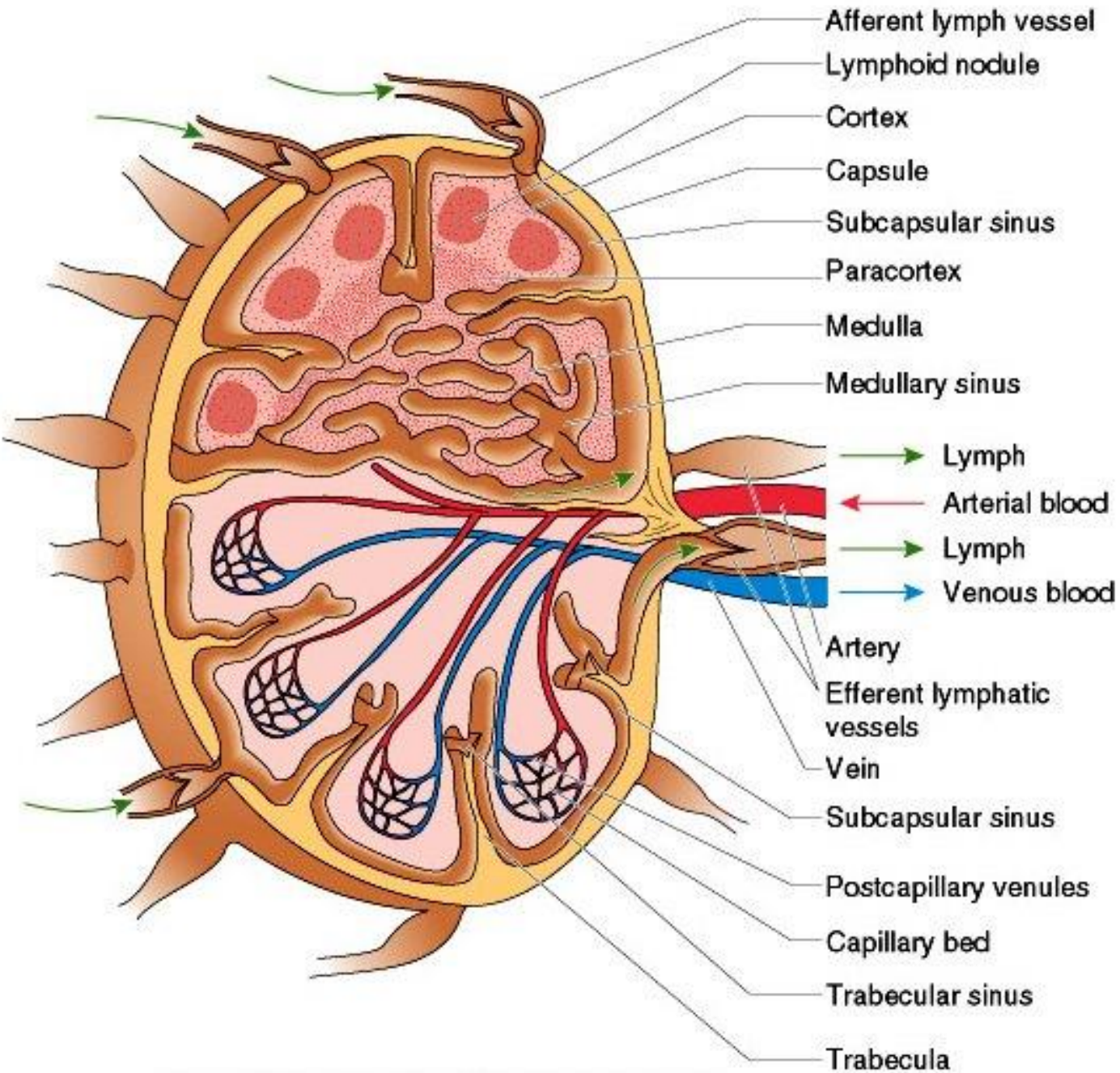


Multiple Myeloma: Skull X-ray

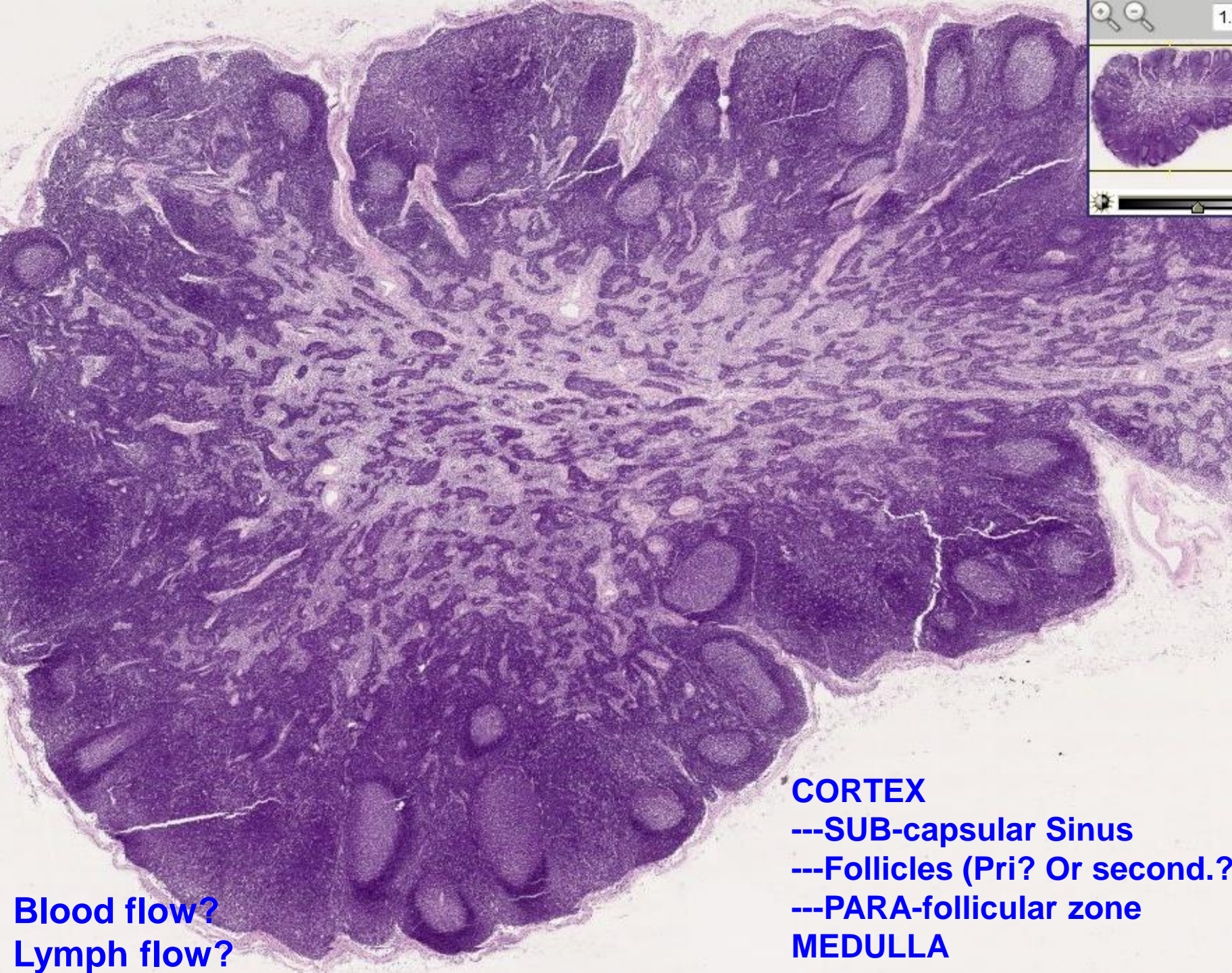


LYMPH NODES

- **Normal Structure, Function**
- **Benign enlargement/Benign disease**
 - Acute
 - Chronic (follicular vs. “sinus histiocytosis”)
- **Lymphomas/Malignant Lymphomas**
 - Adjectives of various classifications
 - Features
 - STAGING
- **Metastatic disease TO lymph nodes**



- Afferent lymph vessel
- Lymphoid nodule
- Cortex
- Capsule
- Subcapsular sinus
- Paracortex
- Medulla
- Medullary sinus
- Lymph
- ← Arterial blood
- Lymph
- Venous blood
- Artery
- Efferent lymphatic vessels
- Vein
- Subcapsular sinus
- Postcapillary venules
- Capillary bed
- Trabecular sinus
- Trabecula



Blood flow?
Lymph flow?

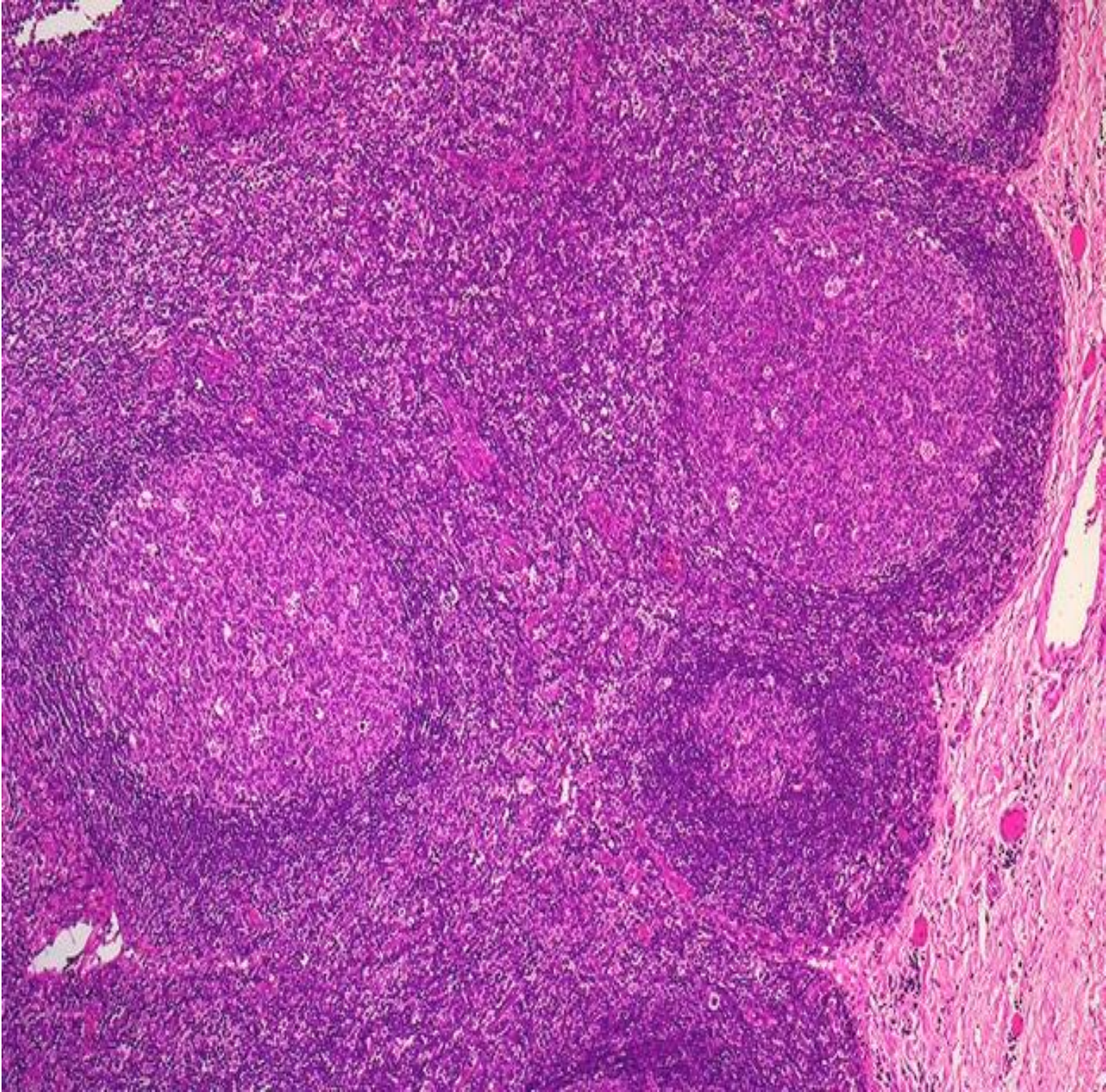
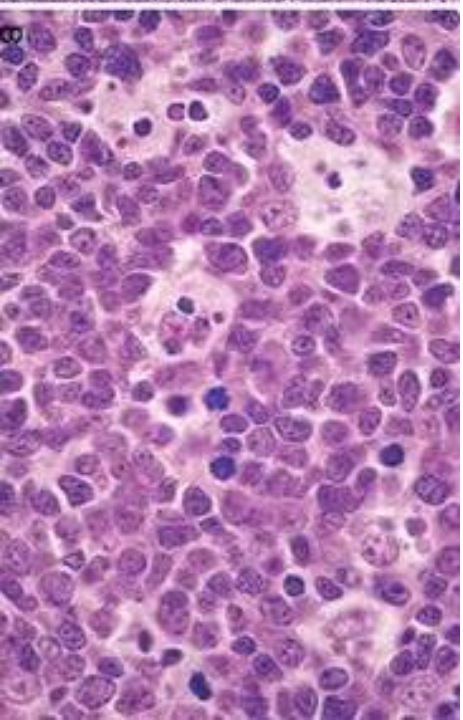
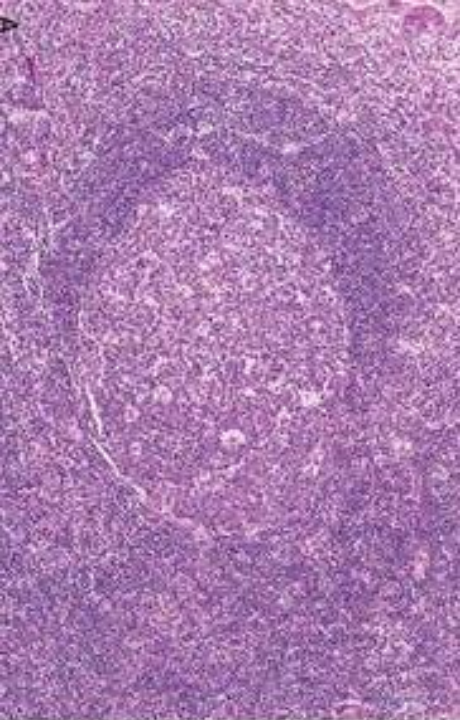
CORTEX
---SUB-capsular Sinus
---Follicles (Pri? Or second?)
---PARA-follicular zone
MEDULLA

Definition of TERMS

- **Lymphadenopathy**
- **Lymphadenitis**
- **What to do if a lymph node is enlarged?**
- **Diffuse/Follicular**
- **T/B/NK, Small/Large, Cleaved/Non-cleaved**
- **Precursor/Peripheral**
- **HD/Non-HD**

BENIGN ENLARGEMENT

- Also called **LYMPHADENITIS**, and **HYPERPLASIA**
- Can be **ACUTE** (tender), or **CHRONIC** (non-tender)
- Usually **SUBSIDE** in, say, less than 6 weeks
- **FOLLICULAR HYPERPLASIA** is enlargement of the cortical secondary follicles and increase in number of the cortical secondary follicles
- **SINUS HISTIOCYTOSIS** is prominence in medullary sinuses (also called “reticular” hyperplasia)

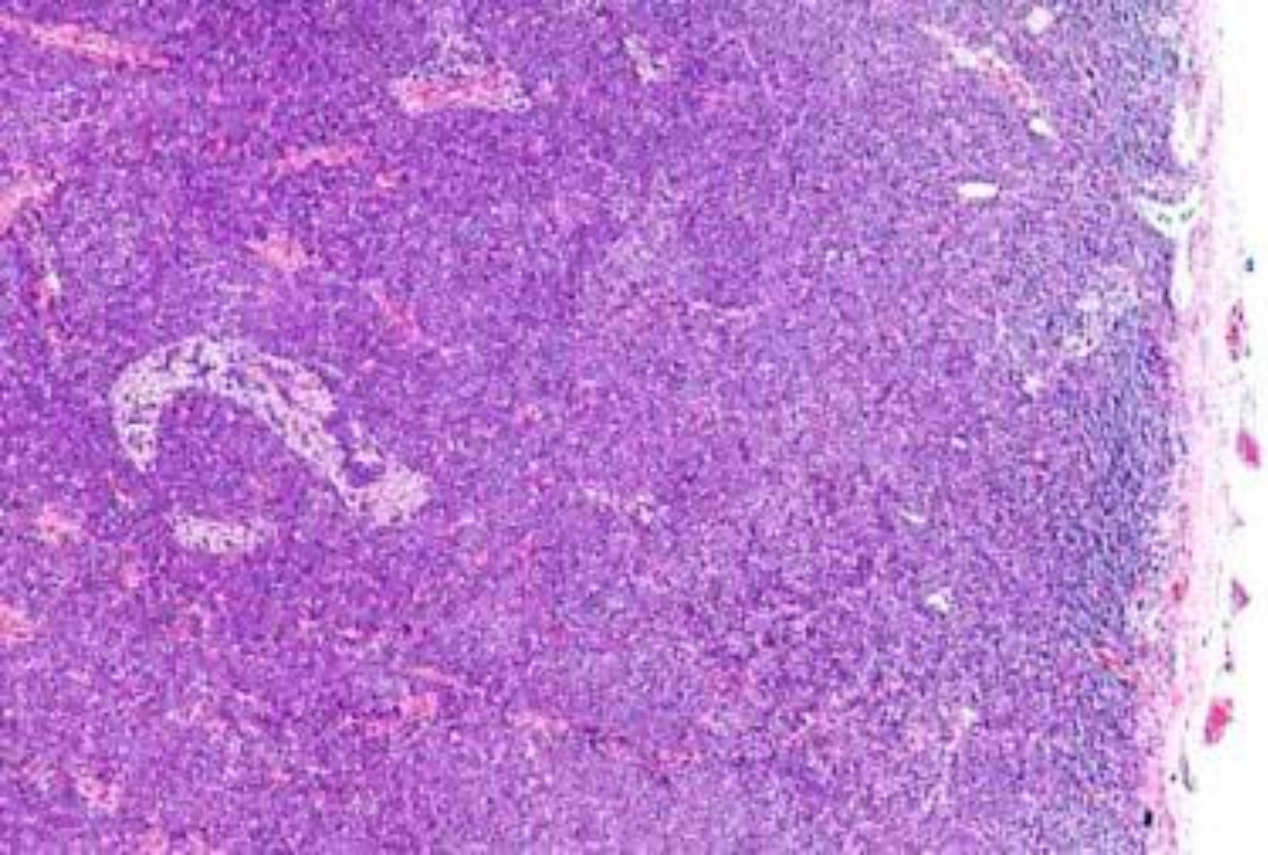


(MALIGNANT) LYMPHOMAS

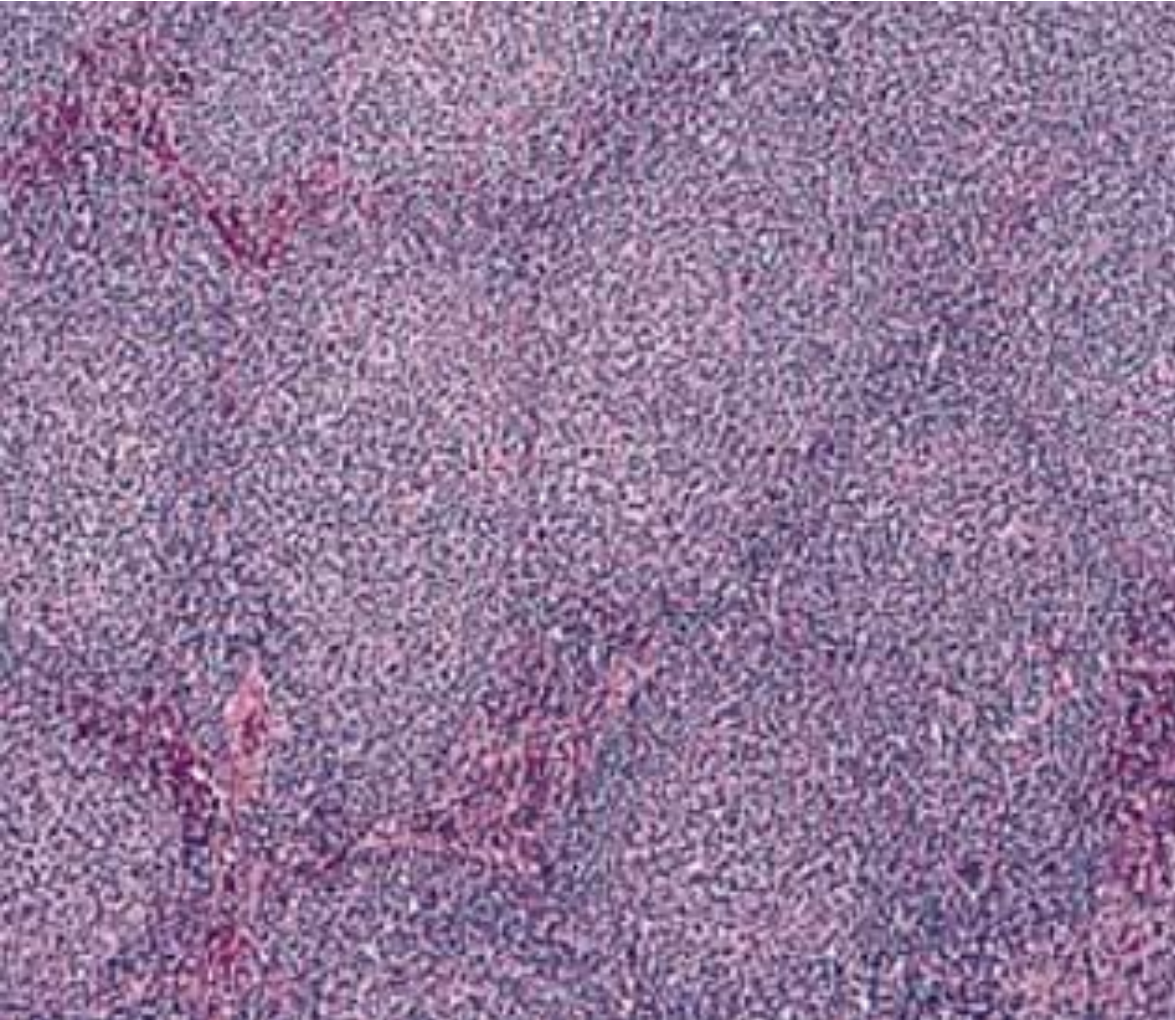
- **Terms in historic classifications:**

- Diffuse/Follicular, Small/Large, Cleaved/Non-cleaved
- Hodgkins /NON-Hodgkins
- Lukes, Rappaport, etc.
- Working Formulation, WHO, NIH, FAB, Intl., etc.
- B
- T
- PRECURSOR (less mature looking)
- PERIPHERAL (more mature looking)

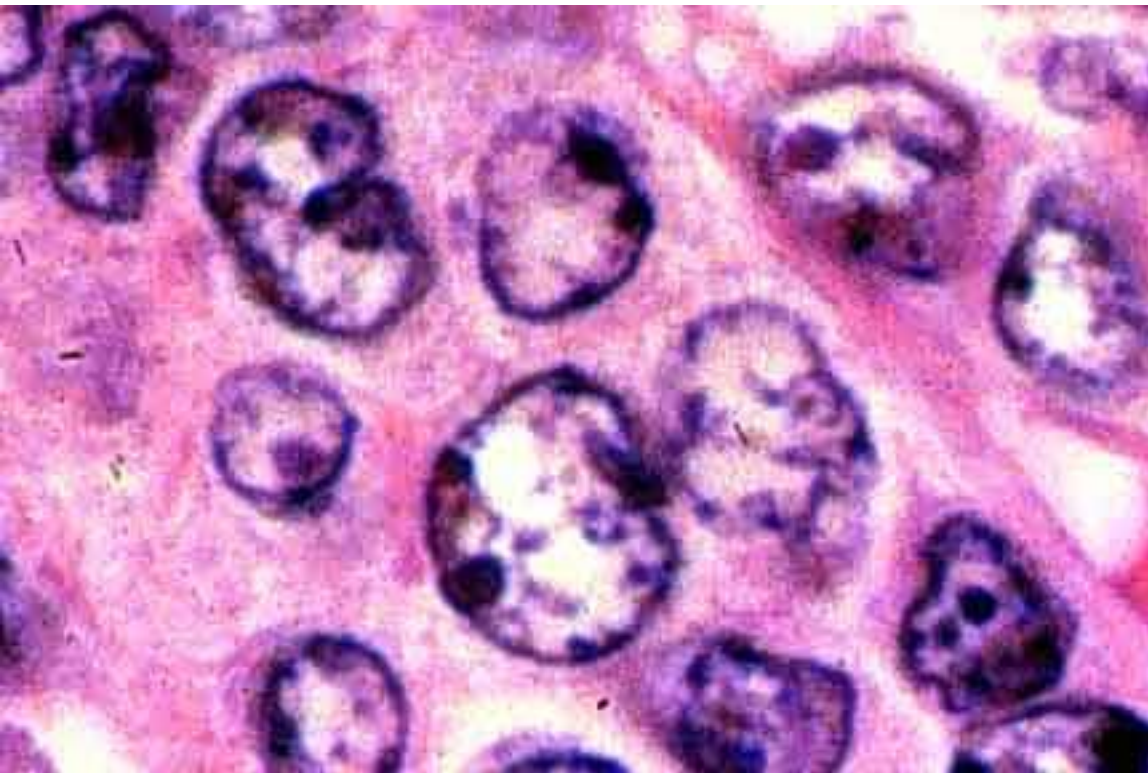
DIFFUSE LYMPHOMA



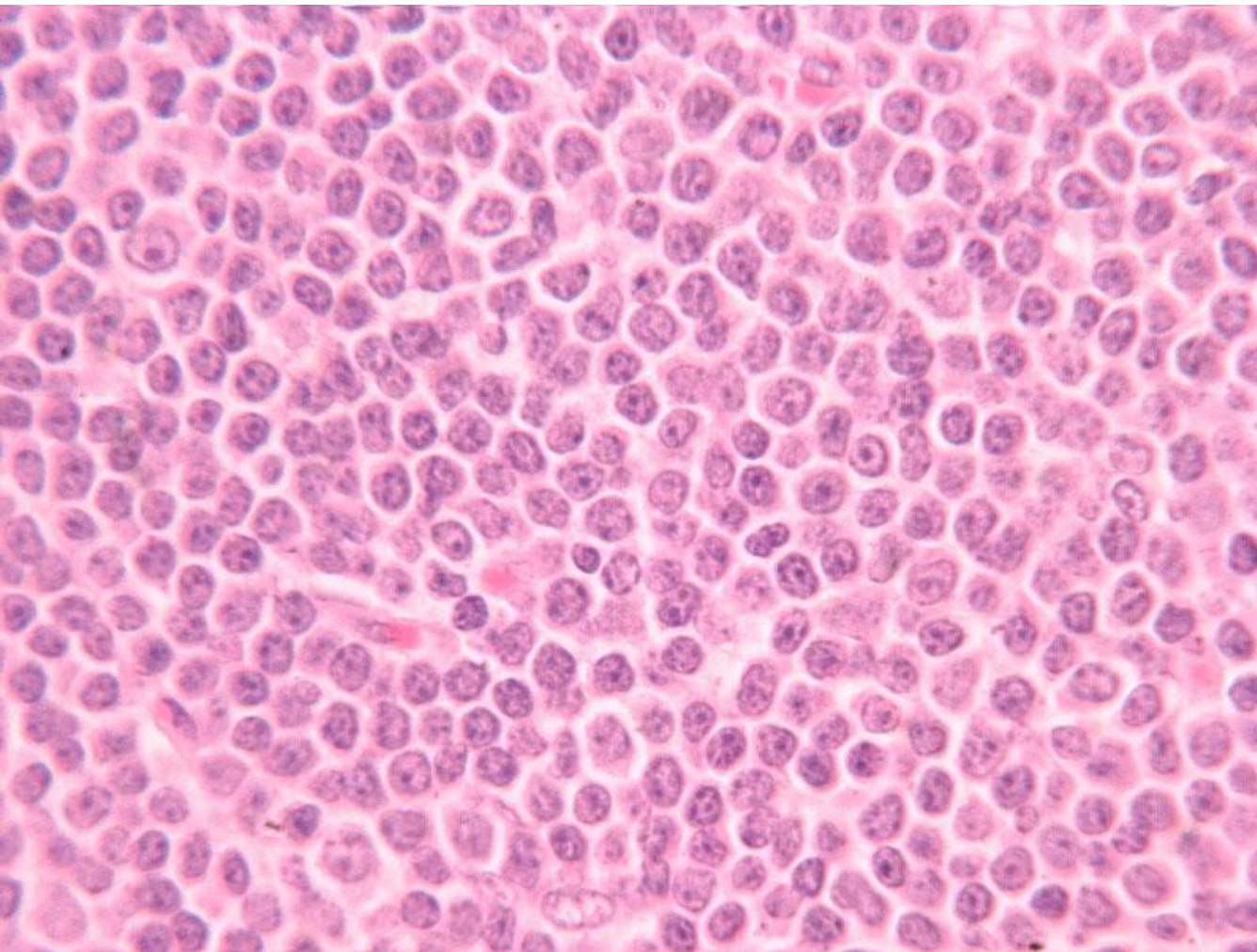
FOLLICULAR LYMPHOMA



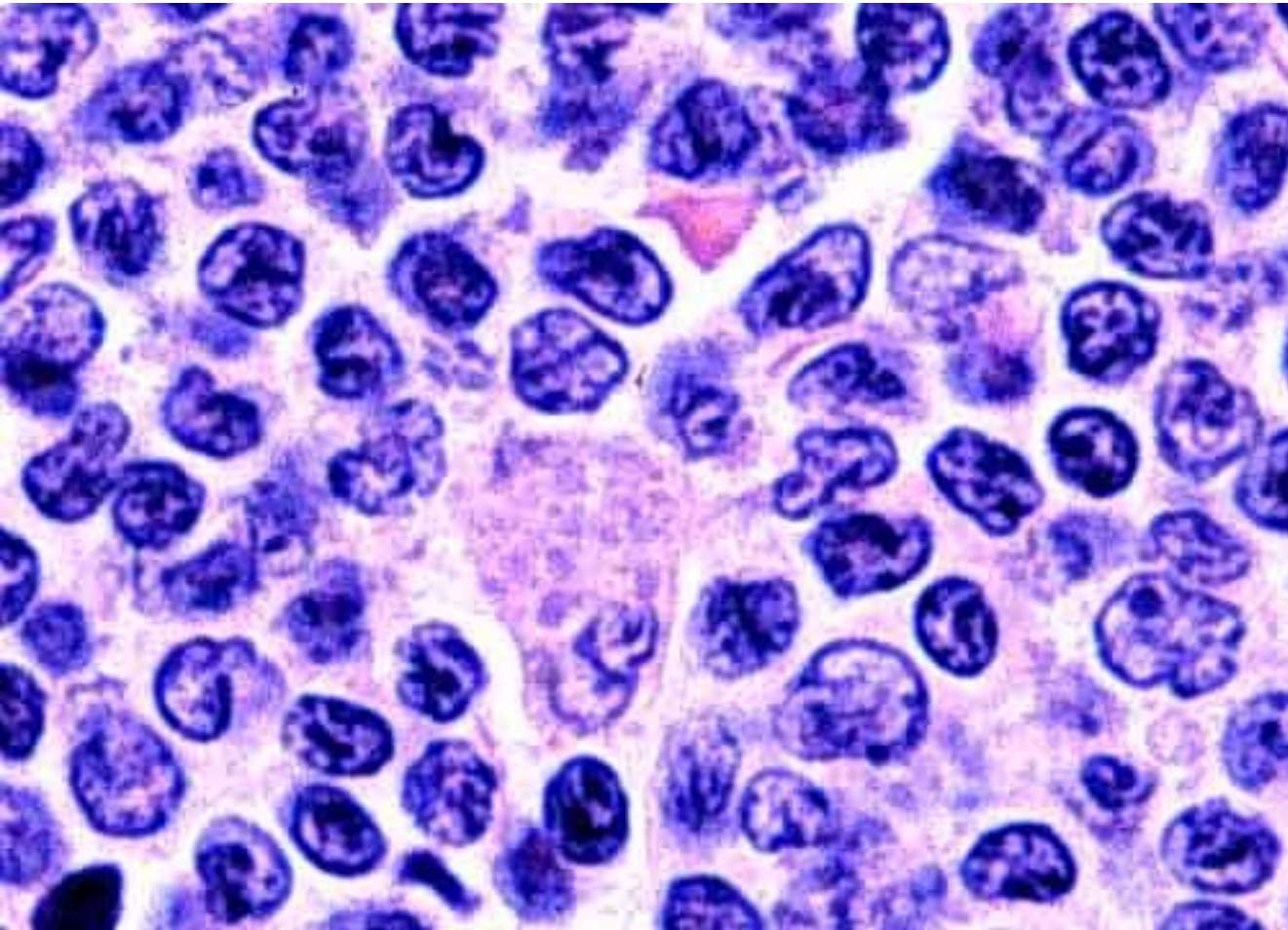
LARGE CELL LYMPHOMA



SMALL CELL LYMPHOMA



“CLEAVED” CELL LYMPHOMA



FEATURES of LYMPHOMAS

- The Antigen receptor genes re-arrangement **PRECEDES** malignant transformation, so the cells are **MONOCLONAL**, **NOT** the usual **POLYCLONAL**
- **85% B-cell, 15% T-Cell**
- The tumor cells congregate wherever T and B cell congregate normally however
- **DISRUPTED** or “**EFFACED**” normal architecture, obliterated subcapsular sinus
- **HD/Non-HD staging CRUCIALLY IMPORTANT**, esp. HD. Why? HD grows more “linearly”

LATEST CLASSIFICATION

- **NON-HODGKIN**

- **PRECURSOR B**

- **PERIPHERAL B**

- **PRECURSOR T**

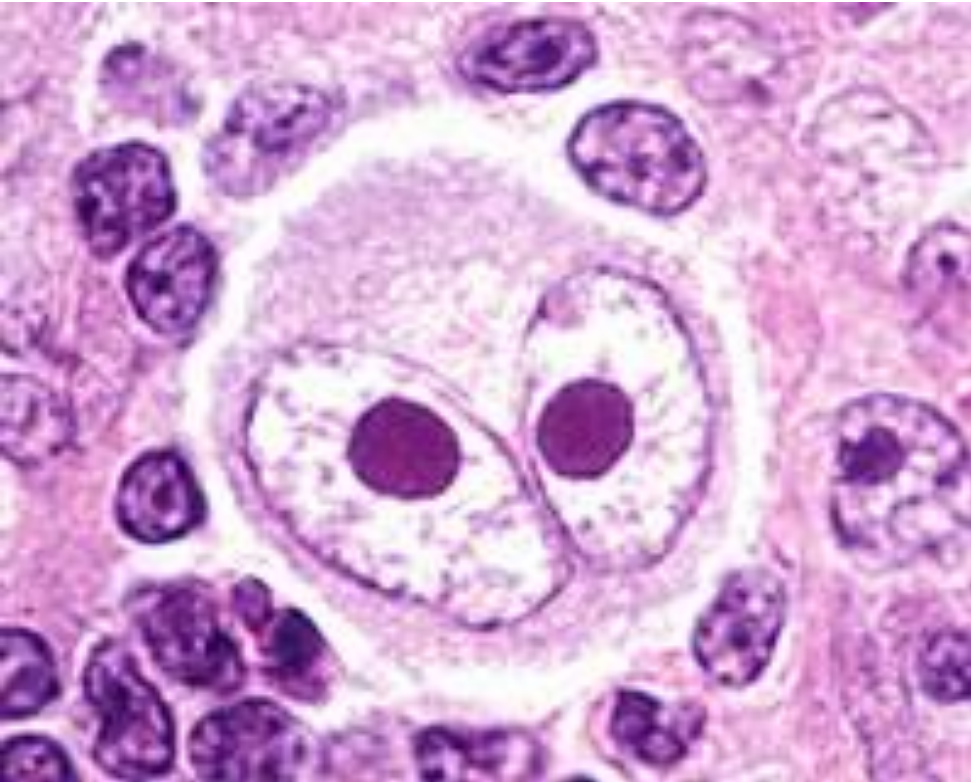
- **PERIPHERAL T**

- **HODGKIN'S DISEASE (i.e., HODGKINS LYMPHOMA)**

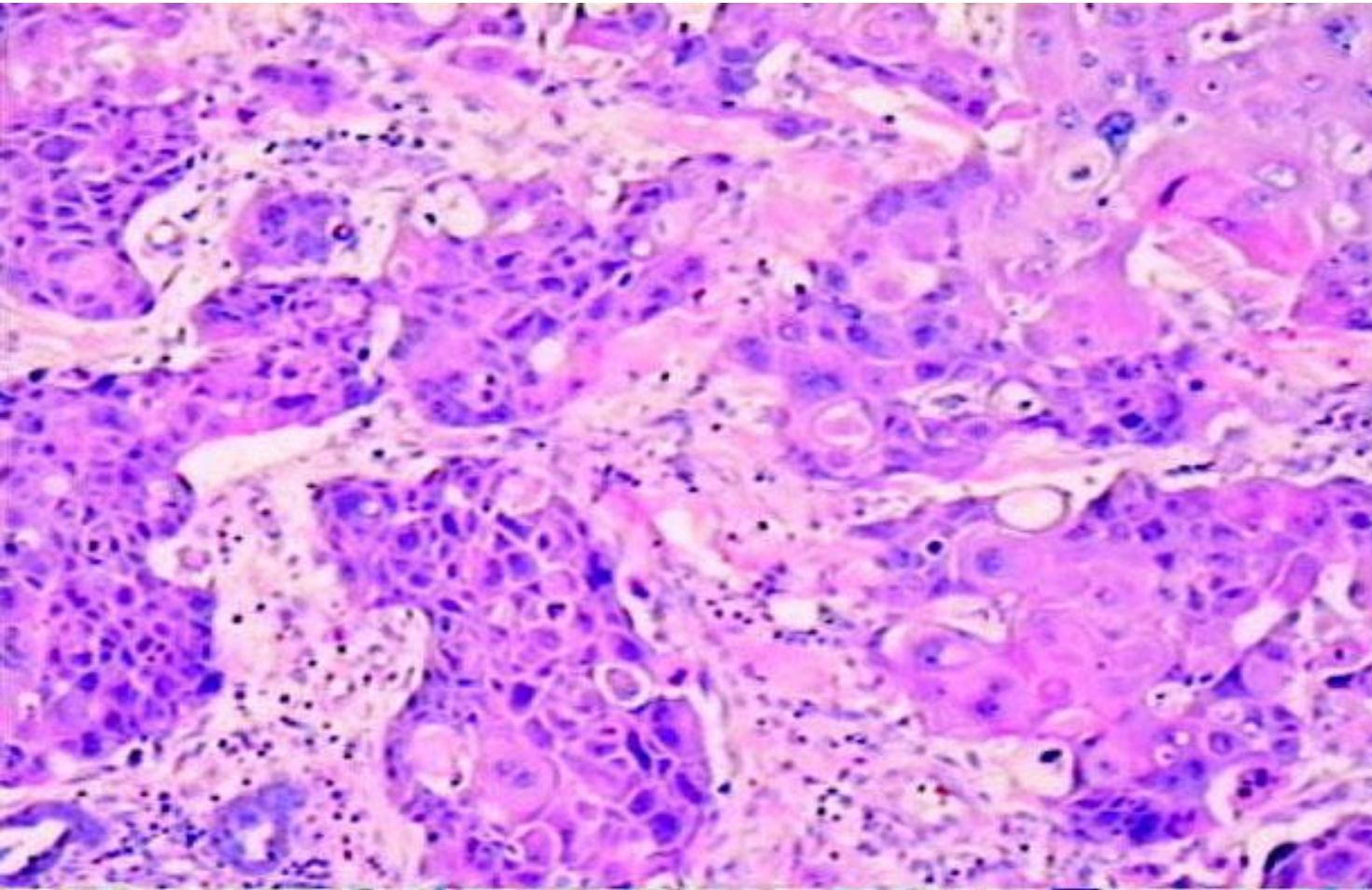
HODGKINS DISEASE

- **NEED R-S (Reed-Sternberg, or Sternberg-Reed) cells for correct diagnosis**
 - **NODULAR SCLEROSIS** (Young Women), the R-S cells may be called “LACUNAR” cells
 - **MIXED CELLULARITY**
 - Lymphocyte RICH
 - Lymphocyte POOR
 - Lymphocyte PREDOMONANCE

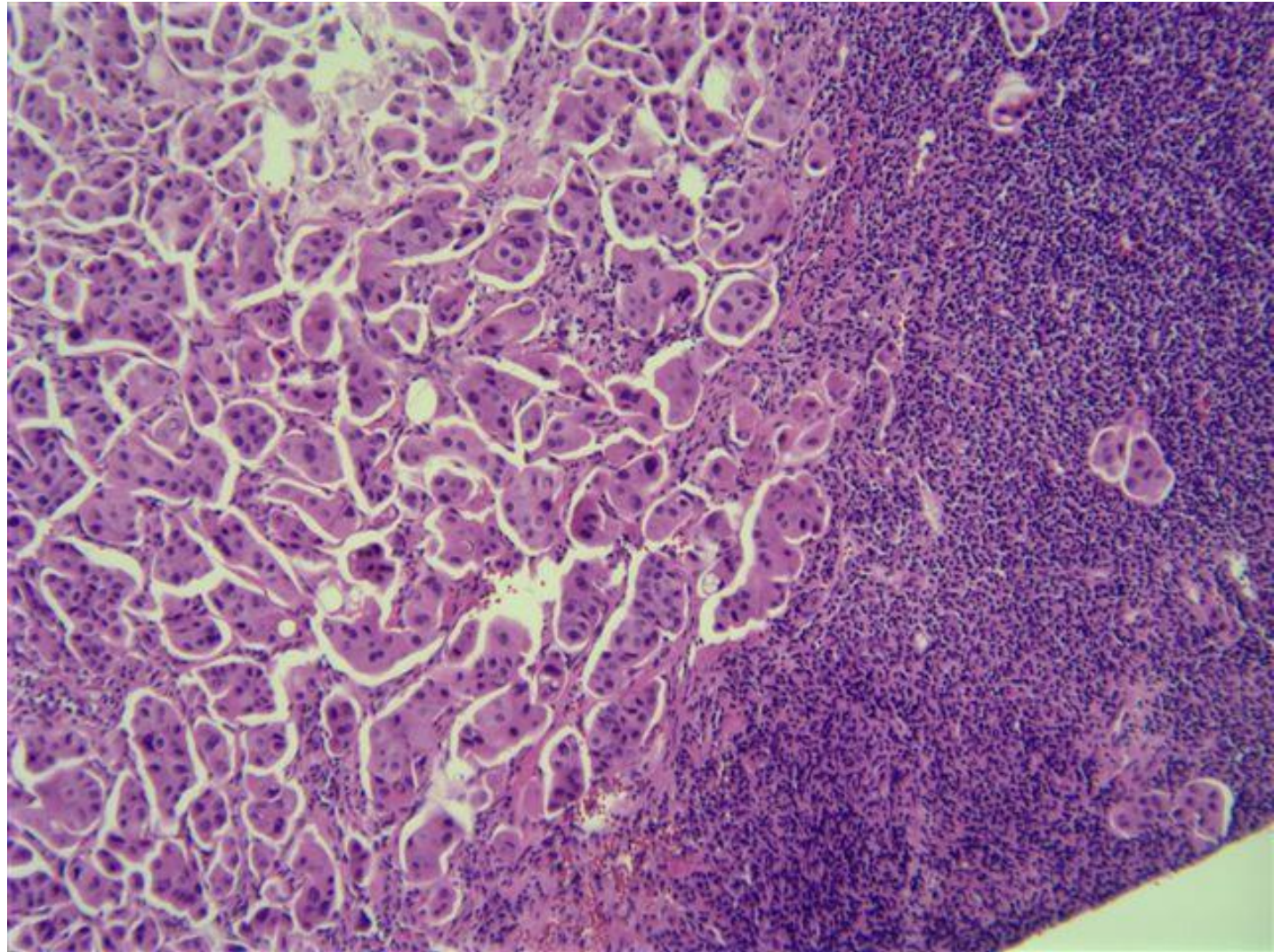
STERNBERG-REED CELL



METASTATIC SQUAMOUS CELL CARCINOMA

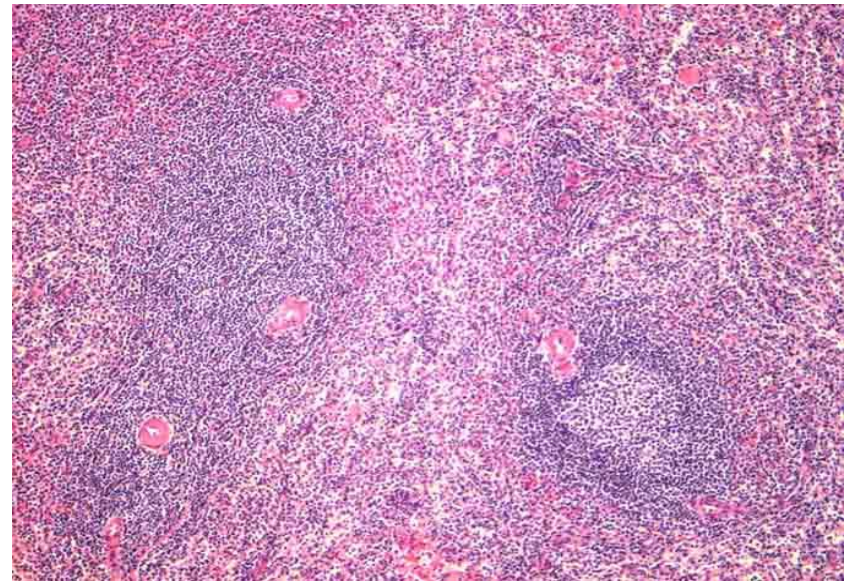
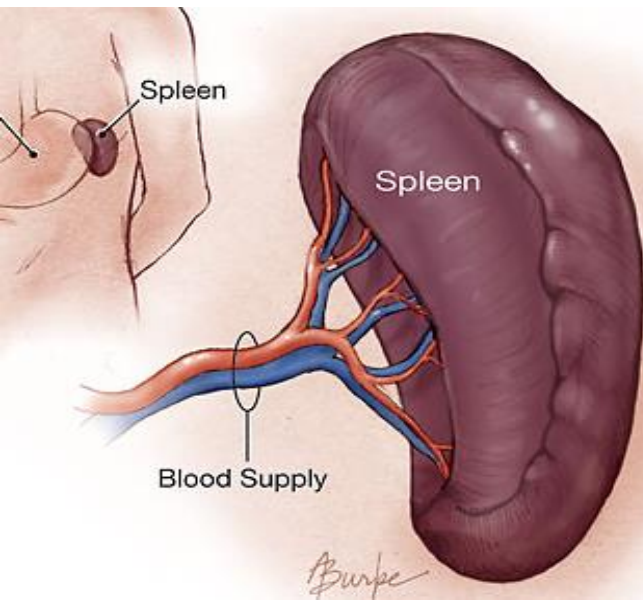


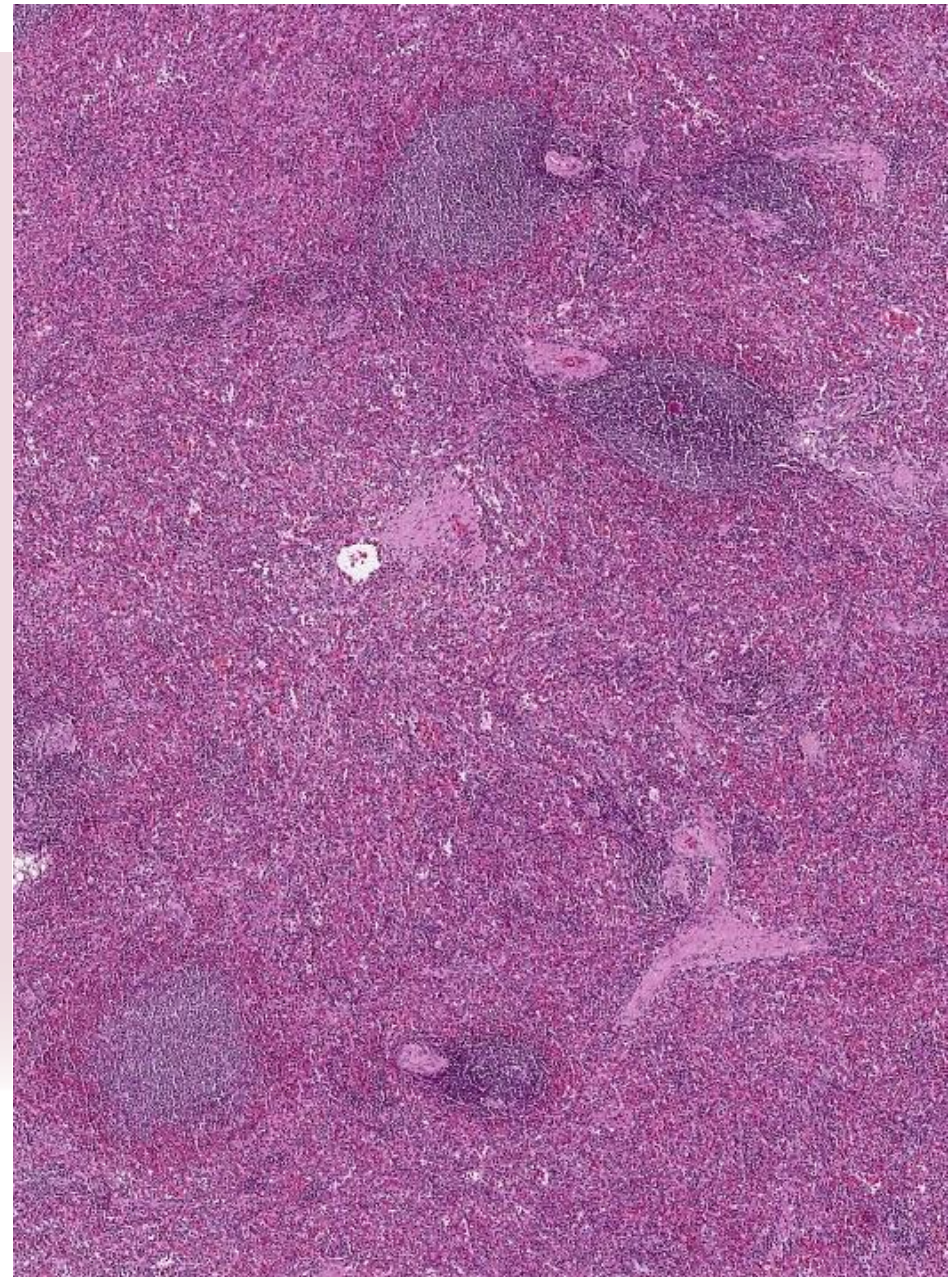
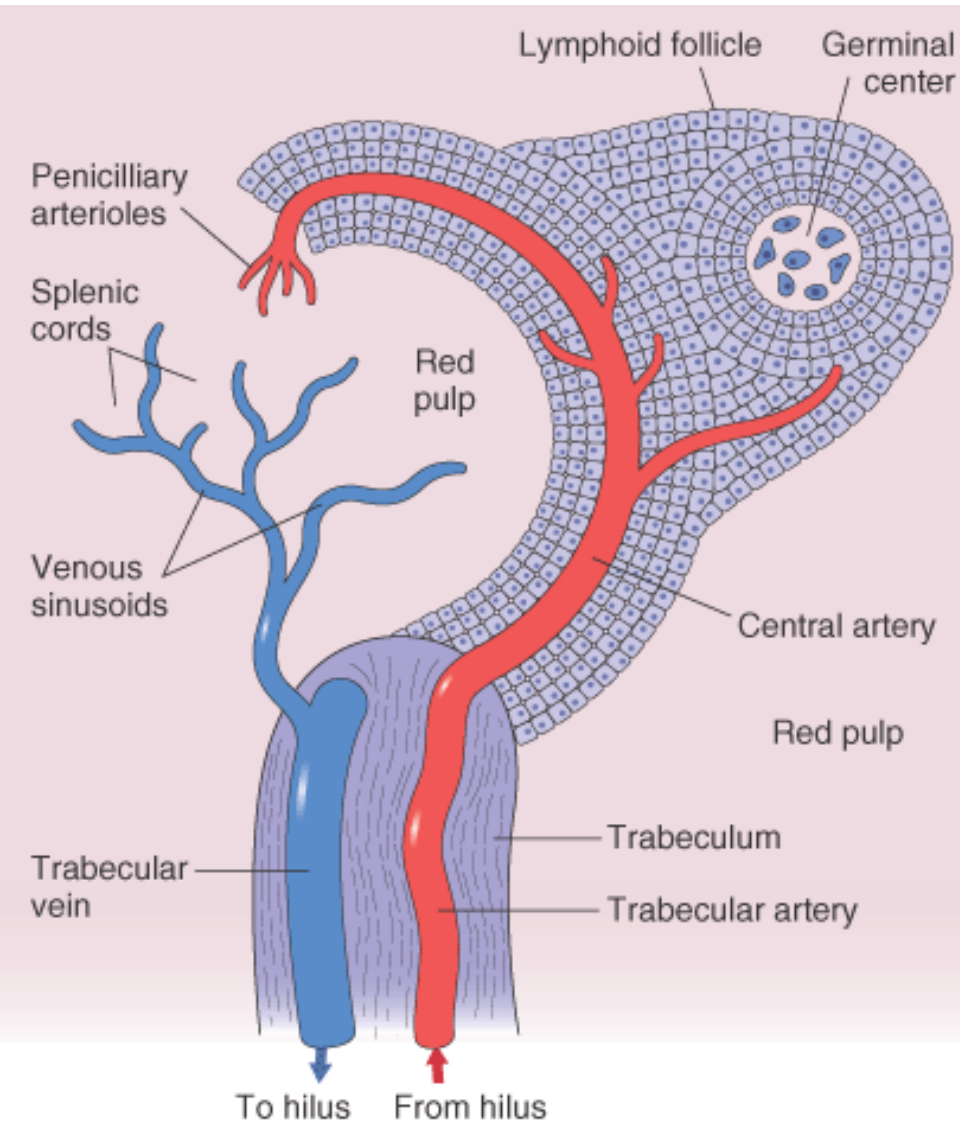
METASTATIC ADENOCARCINOMA



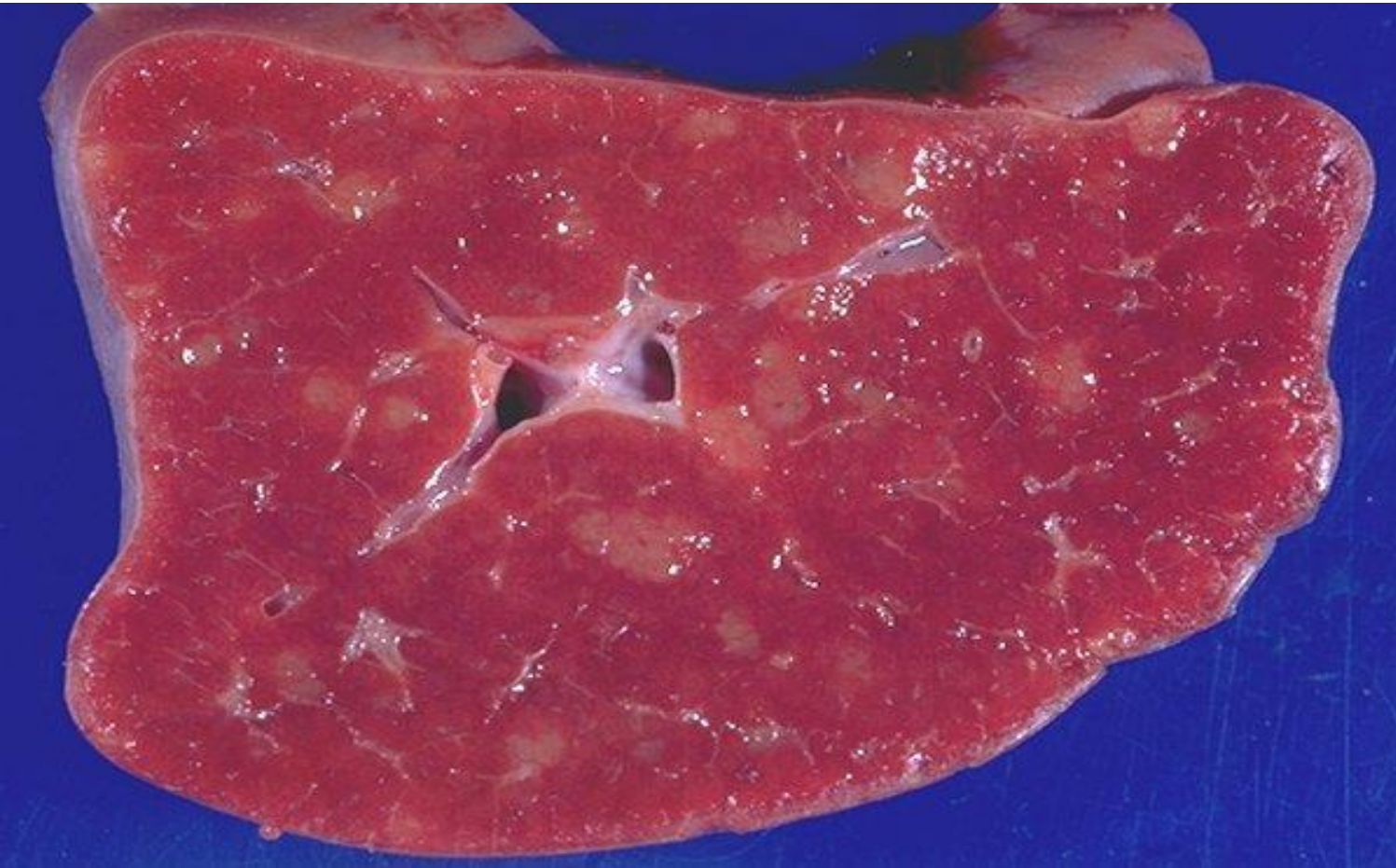SPLEEN

- 150 grams POST-LUQ (just like kidney, 1/10 of liver)
- Bordered by diaphragm, kidney, pancreas, splenic flexure, stomach
- SMOOTH & GLISTENING capsule
- 50% RED pulp, 50% WHITE pulp

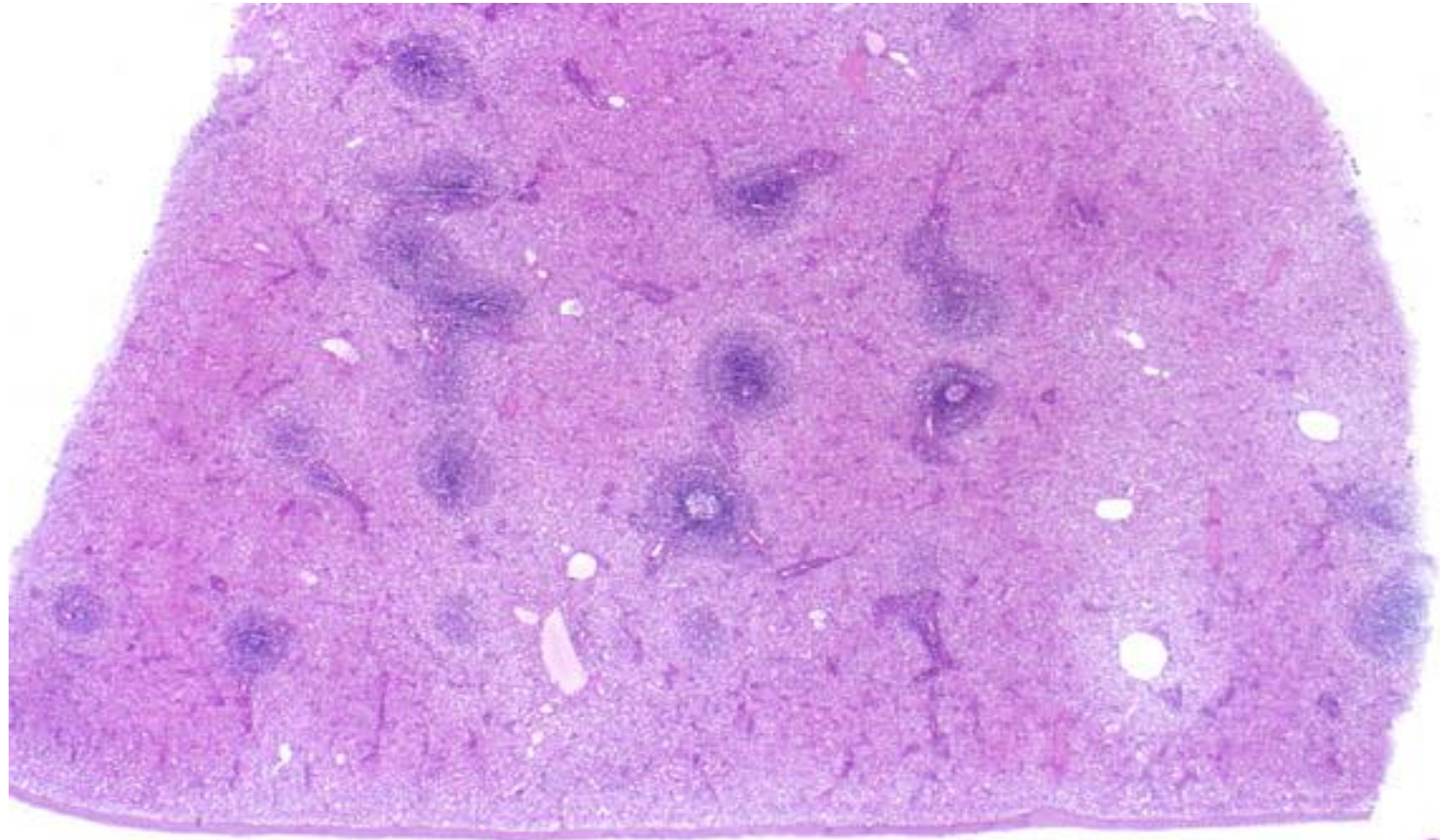




ABNORMAL SPLEEN



ABNORMAL SPLEEN



SPLENIC FUNCTION

- **REMOVE OLD BLOOD CELLS**
- **MAJOR SECONDARY ORGAN of the IMMUNE SYSTEM**
- **HEMATOPOIESIS**
- **SEQUESTER (POOL) BLOOD CELLS**
- **15% of body's PHAGOCYTIC activity is in the spleen (liver has >80)**

SPLENOMEGALY

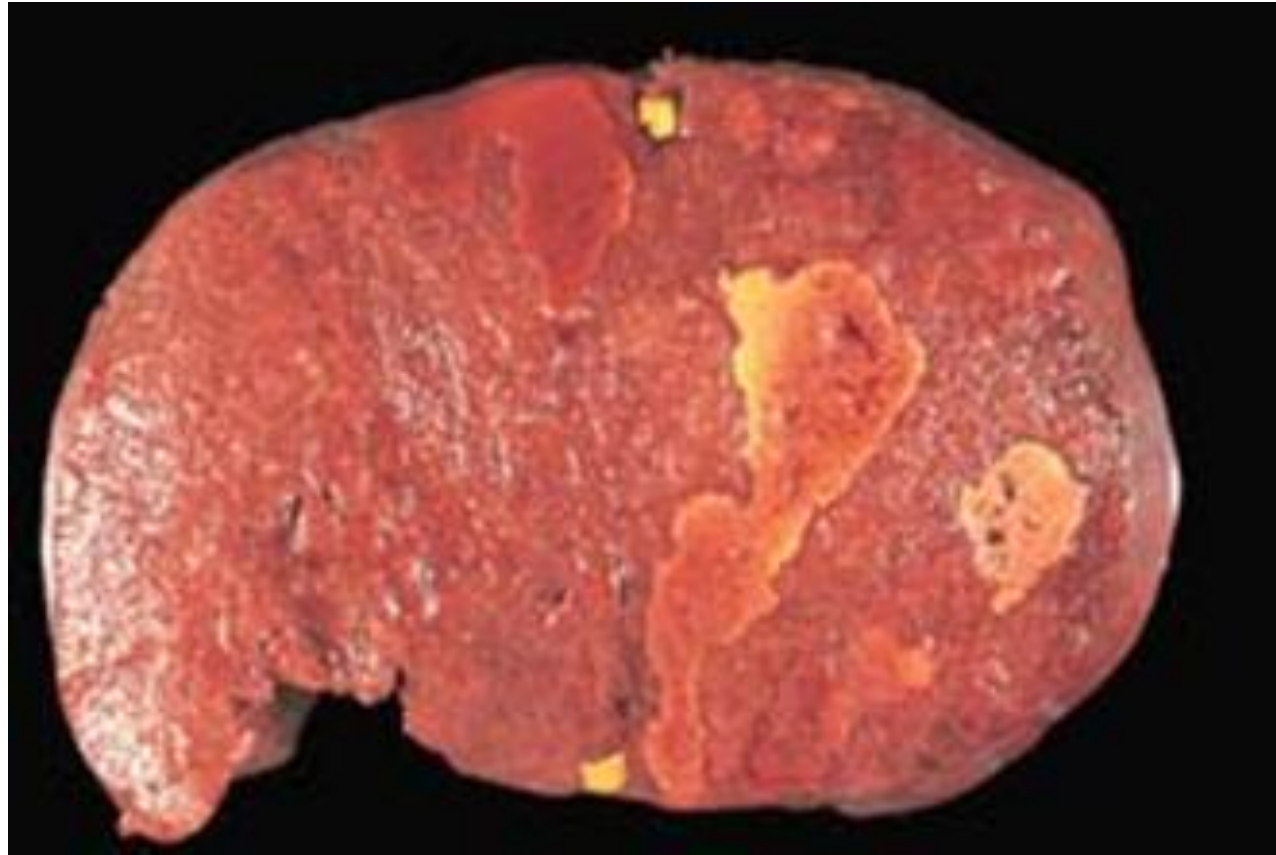
- **CONGESTIVE vs INFILTRATIVE**
- **HYPERSPLENISM**
 - **Anemia**
 - **Leukopenia**
 - **Thrombocytopenia**
- **DECISION for SPLENECTOMY**

SPLENOMEGALY

- **INFECTIONS:** TB, Mono, Malaria, Fungus
- **PORTAL HTN:** CHF, CIRRHOSIS, PV Thromb.
- **LYMPHOHEMATOGENOUS:** Leuk, Lymph
- **IMMUNE:** RA, SLE
- **STORAGE:** Gaucher, Niemann-Pick
- **MISC:** Amyloid, mets (melanoma, lymphoma, Germ cell tumors of testis)

LONG STANDING CONGESTION breeds FIBROSIS

INFARCT

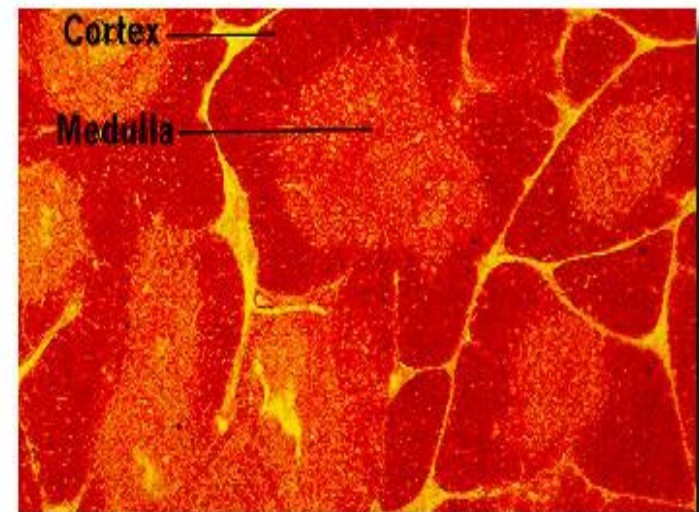


PRIMARY TUMORS (RARE)

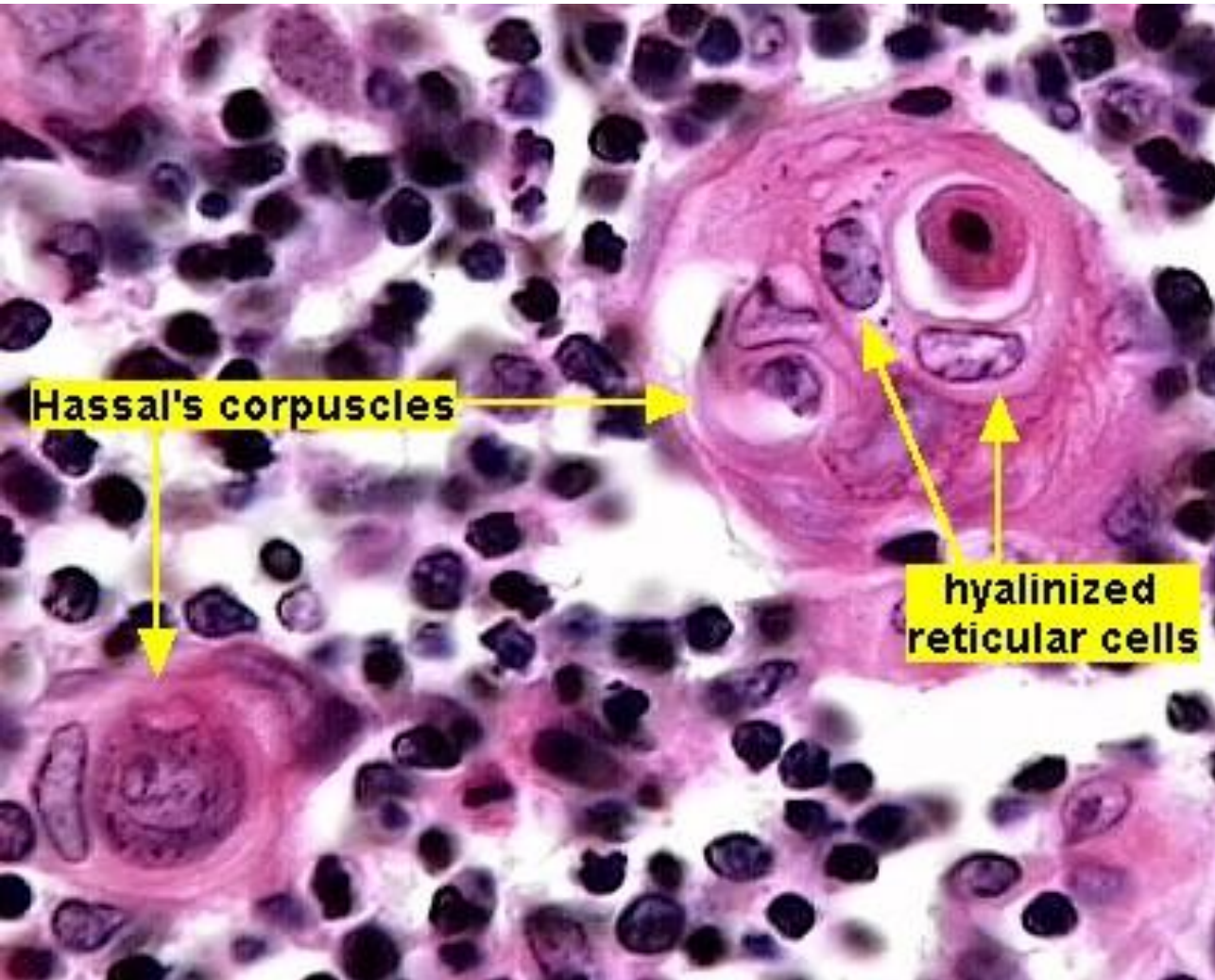
- **HEMANGIOMA**
- **LYMPHANGIOMA**
- fibroma
- osteoma
- chondroma

THYMUS

- **Mother of all T-Cells**
- **Massive in newborns, virtually absent in the elderly, bilobed**
- **Under manubrium**
- **1) Thymocytes**
- **2) Epithelial Ret. Cells**
- **3) Hassal's Corpuscles**



HASSAL'S CORPUSCLES



DISEASES

- **HYPOPLASIA/APLASIA**

- DiGeorge Syndrome

- **CYSTS** (incidental)

- **THYMOMAS**