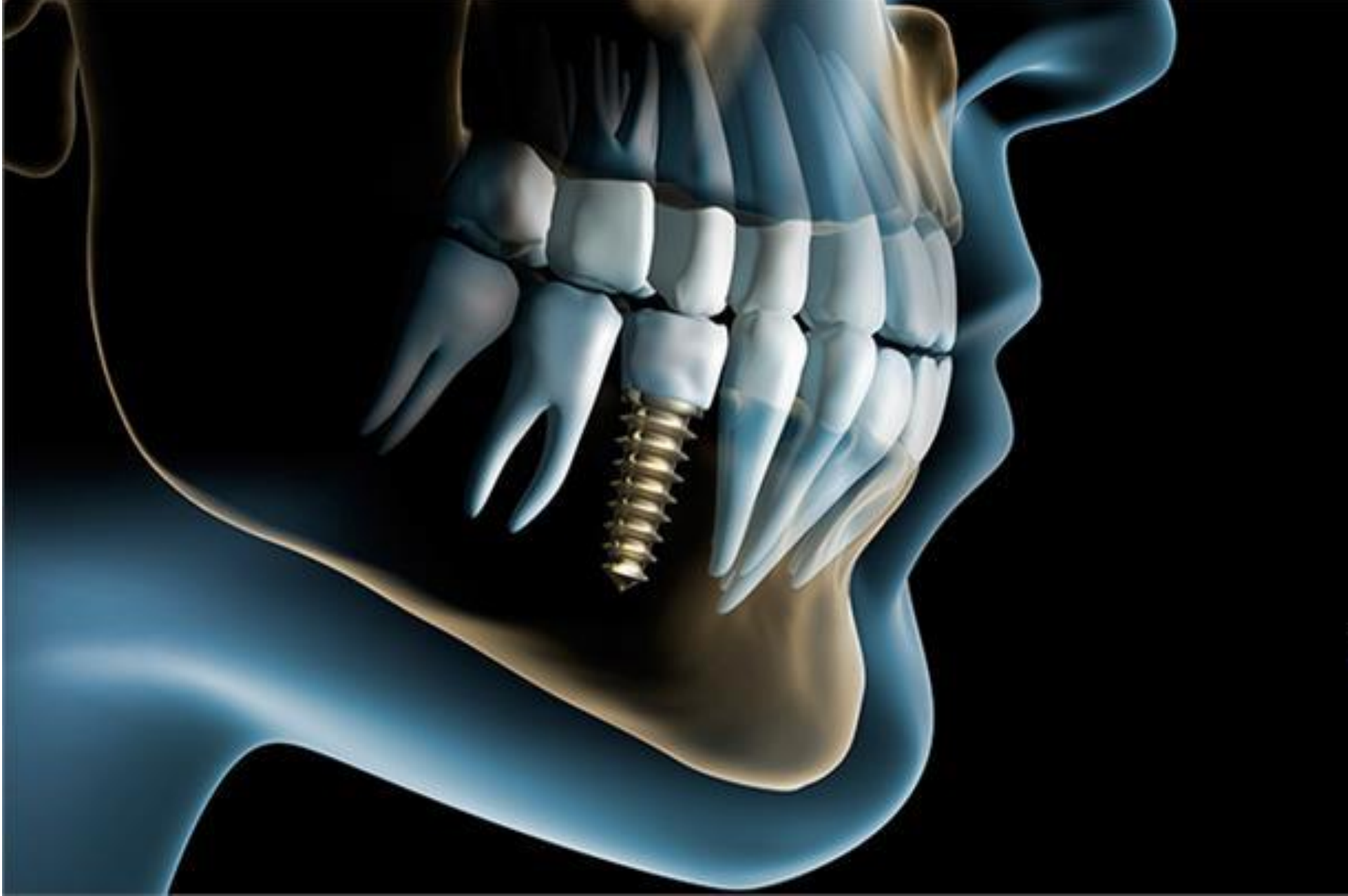



Odontogenic tumors

Odontogenic tumors

Microspecimens:

№ 195. Follicular ameloblastoma (*H-E stain*).

Indications:

1. Odontogenic epithelium (cords of epithelial cell).
2. Fibrous connective tissue.

Microscopically, it consists of epithelial proliferation in the form of beaches or round or oval islands, surrounded by a conjunctival stroma. On the outskirts of beaches and nests, the cells are arranged in a palisade. Tumor cells are cubic or cylindrical, with oval nuclei and reduced cytoplasm. Towards the center of the beaches, the cells have a star shape, anastomosing in a network, whose meshes are filled with a mucoid mass. The surrounding stroma has areas of hyalinization and can sometimes contain a large number of blood vessels.

A series of microscopic variants are described: follicular (beaches of epithelial cells, surrounded by conjunctival stroma, inside beaches with microcysts lined by a unistratified, plexiform epithelium (columnar tumor cells, arranged in anastomous cords and separated by a stroma) more rarely, acantomatous, fusiform, granular, basal cell.

Macroscopically, the tumor has a nodular appearance, on the section it is solid or cystic, white-gray, with hard areas alternating with gelatinous areas. More rarely, the tumor appears as a single cyst, bounded at the periphery by compact bone tissue. The tumor is unencapsulated, therefore developed intraosseously, causes the expansion of the cortex and sometimes its erosion, with the infiltration of perimaxillary tissues.

№ OP6. Ameloblastic fibroma (H-E stain).

Indications:

1. Epithelial proliferations.
2. Fibroblast-rich tumor stroma

Microscopically, the epithelial component consists of branched and anastomosing cords that make loops of various sizes. They are usually bilayered, consisting of columnar cells with a morphology similar to the internal adamantine layer of the enamel organ. The epithelial proliferations are located in a myxoid stroma, densely cellular, rich in fibroblasts with stellar morphology and long and thin cytoplasmic extensions, creating an appearance reminiscent of the ectomesenchyma of the dental papilla.

Macroscopically, it is in the form of a mass, well delimited, usually encapsulated, with dimensions varying between 1-8cm. in diameter, translucent. Their appearance can vary from white to brown (in the case of pigmented lesions). Consistency is increased.

Ameloblastic fibroid is a rare benign odontogenic neoplasm, it develops from the odontogenic epithelium of the enamel organ and the mesenchymal cells of the dental papilla, being a true mixed odontogenic tumor. It is most commonly located in the mandible, especially in the posterior segment.

№ OP 37. Complex odontoma (*H-E stain*).

Indications:

1. Dentine, enamel and cementum arranged disorderly.
 - a. dentine
 - b. enamel
 - c. cementum

Microscopically, the outermost part consists of a rich cellular tissue that forms inwards the dental hard tissues, peripherally individualizes a capsule of connective tissue with bands or islands of odontogenic epithelium. Central is a mass of tubular primary dentin, which surrounds hollow, circular or oval structures, made of decalcified mature enamel.

Macroscopically, it is a large, amorphous, encapsulated mass of high consistency, generally less than 3 cm in diameter, but which can reach up to 6 c, with a yellowish-brown coloration, calcified appearance and irregular, porous surface. , often associated with an unbroken tooth.

It has the most common mixed odontogenic tumor. It is a benign tumor that develops in children in May frequently in the jaw, from the abnormal proliferation of epithelial and conjunctive dentoforming elements. There are two types of odontoma: complex and compound. The complex odontoma develops in the mandible, in the region of the premolars and molars and is made up of masses of dentin, enamel, cement, arranged disorderly, in varying proportions, in a connective tissue. The compound odontoma is located mainly in the upper jaw, in the incisor-canine region and consists of adult dental structures, organized in the form of small, rudimentary teeth or dental fragments, separated by connective tissue. The number of teeth varies from 3-4 to several hundred. Odontomas have a slow evolution, but can produce by their deformation the deformation of the jaws and the disorganization of the dentition, with the appearance of dental inclusions.

№ OP 7. Cemento-ossifying fibroma (*H-E stain*).

Indications:

1. Hypercellular stroma consisting of fibroblasts.
2. Bone structures.

Microscopically, it consists of a fibrous tissue, with variable cellularity, containing mineralized material, either similar to cement, usually arranged in the form of round masses, or in the form of trabeculae of osteoid or bone tissue.

Macroscopically, the tumor is well demarcated at the periphery, sometimes even encapsulated. It is a rare benign tumor, which occurs more frequently in the third and fourth decades of life, especially in females. The most common location is in the mandible, in the area of the premolars and molars. As it grows, the tumor is associated with enlarged mandible and facial asymmetry and less often pain and paresthesia. Being a well-defined tumor, it can be completely excised, so the prognosis is very good and recurrences occur very rarely.

№ OP 46. Odontogenic myxoma (*H-E stain*).

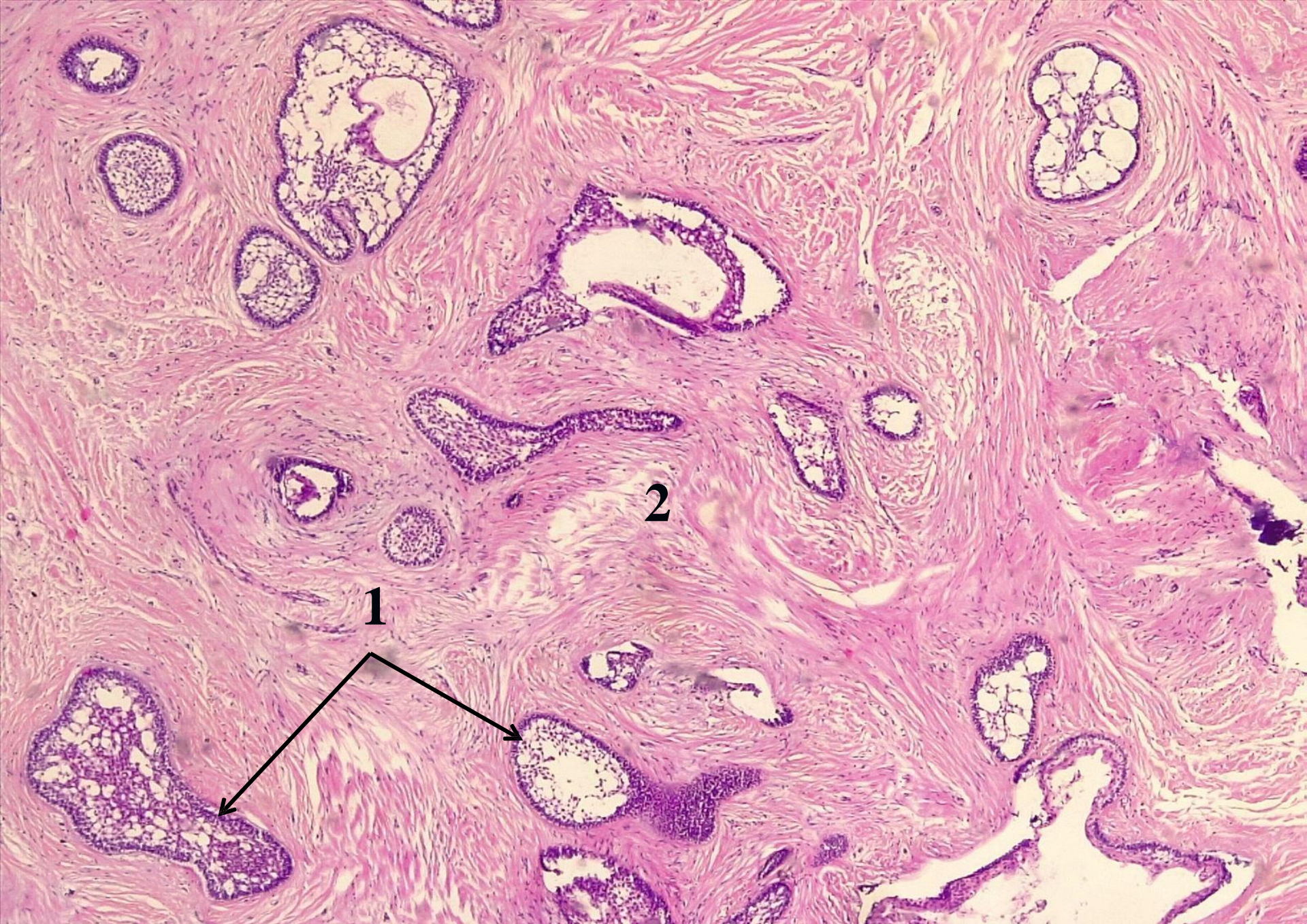
Indications:

1. Stellate cells with cytoplasmic extensions.
2. Nests of odontogenic epithelium.
3. Myxoid tumor stroma.

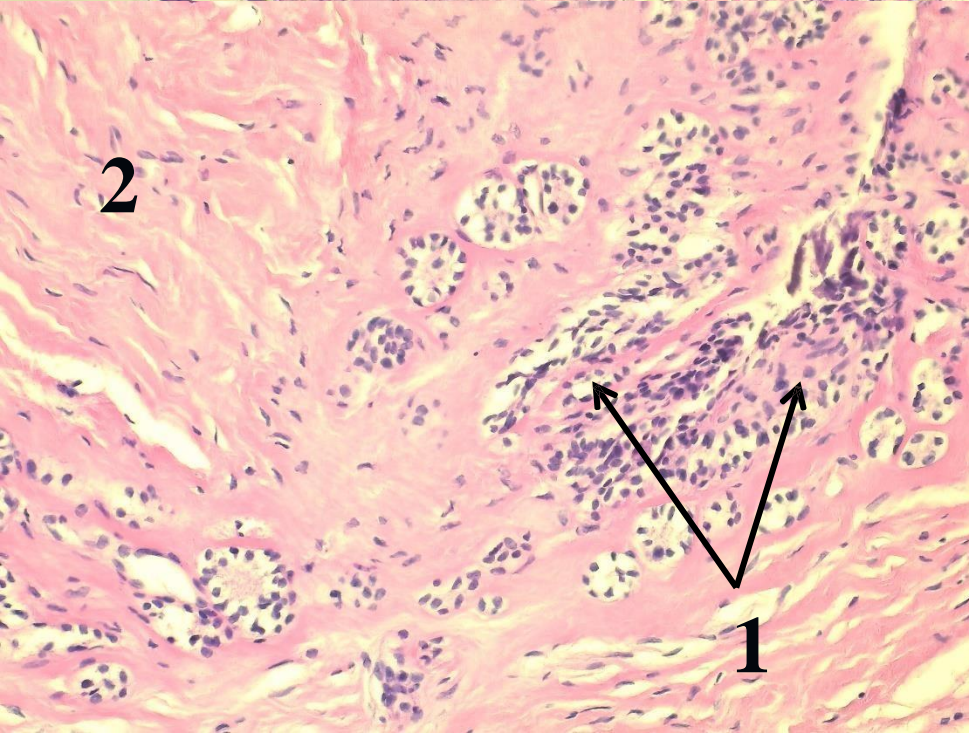
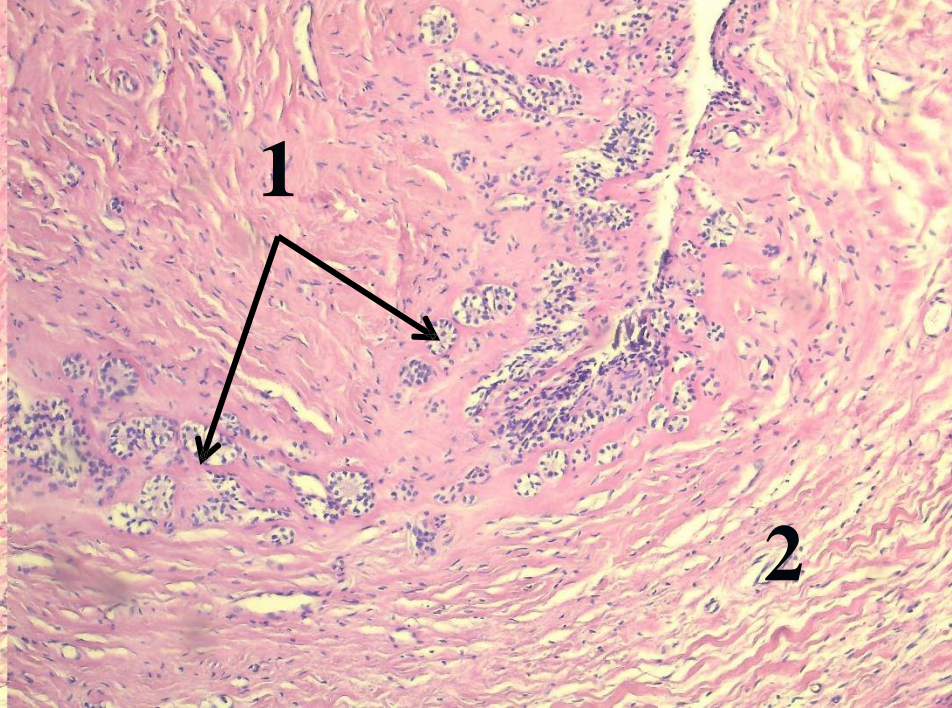
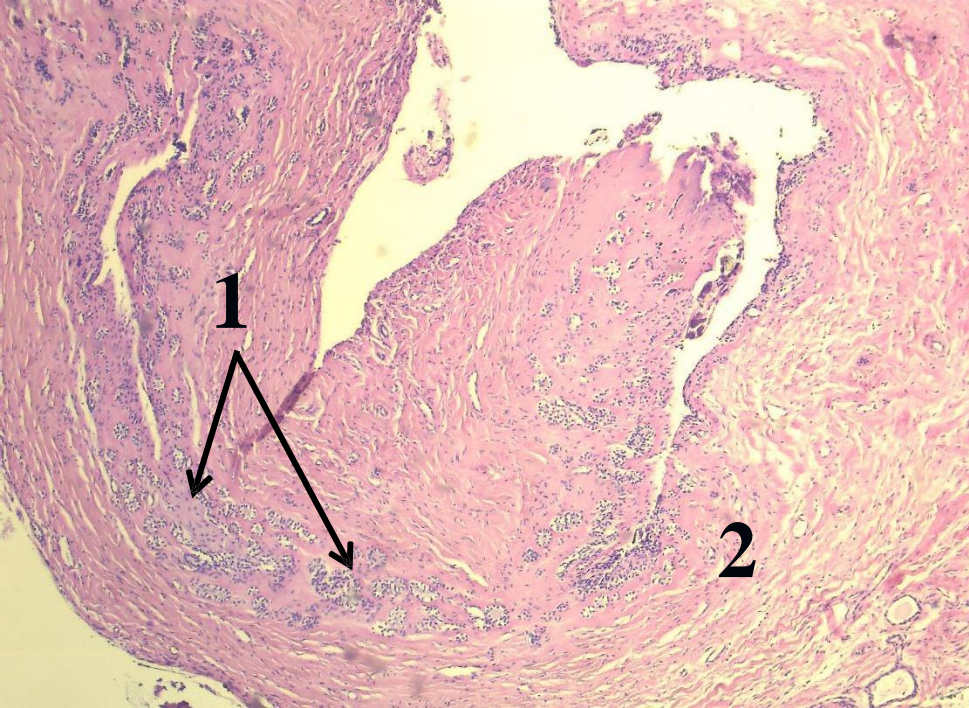
Microscopically, it is characterized by the presence of stellate, fusiform and round cells, with a central nucleus and with slightly eosinophilic, anastamotic cytoplasmic extensions. They are arranged evenly and loosely in an abundant myxoid or mucoid stroma, and contain only a few thin collagen fibers. Nests of odontogenic epithelium can also be highlighted.

Macroscopically, it appears in the form of whitish gray masses, with a typical mucinous, translucent appearance and consistency that can vary from gelatinous to firm, depending on the amount of collagen present.

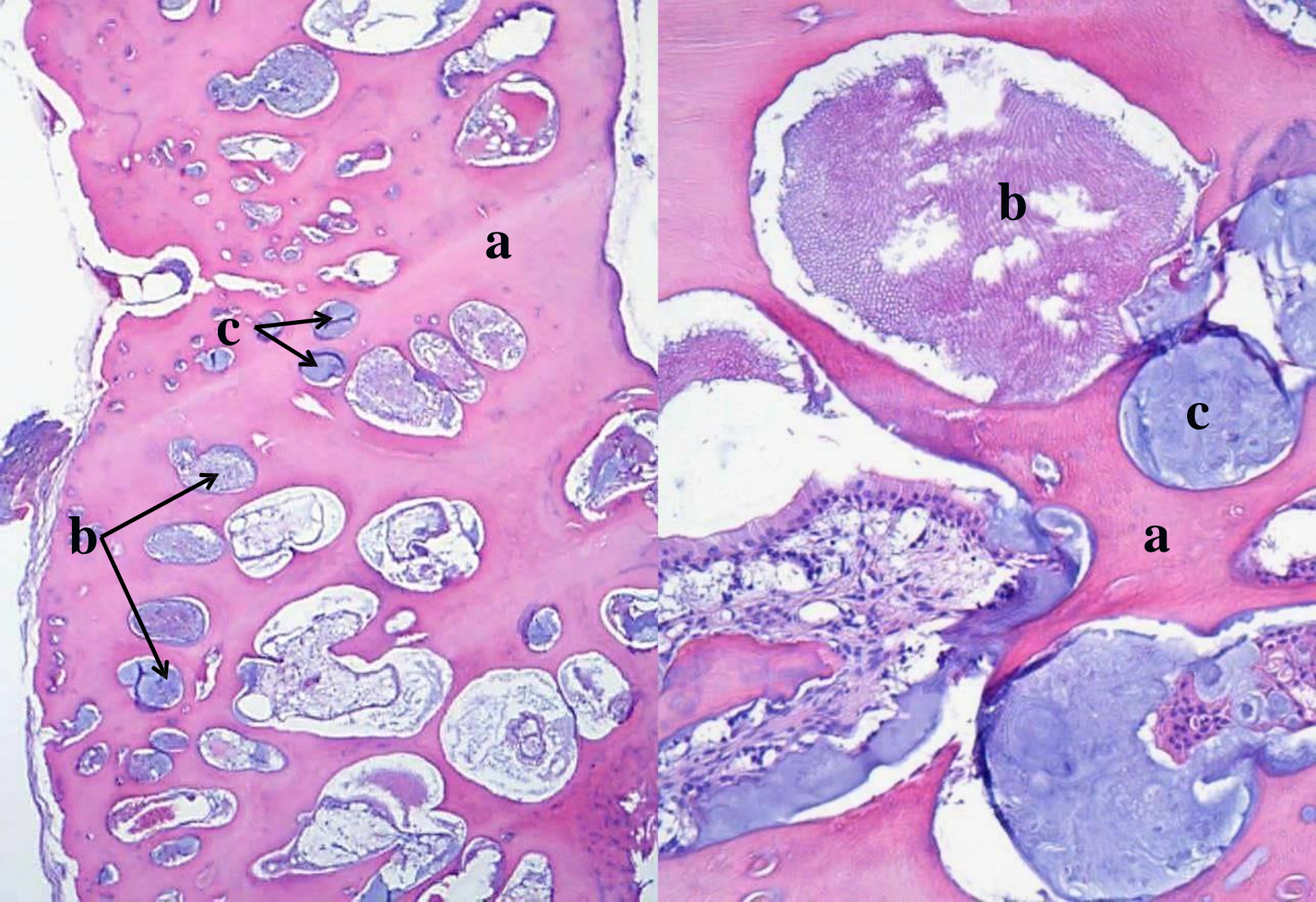
It is a rare tumor, developed from the cellular elements of the dental papilla or of mesenchymal origin. It is a central tumor, with infiltrative character, which deforms and erodes the bone. It usually affects the mandible, most often its molar region. It is asymptomatic if it is small, but the large ones cause painful expansion of the jaws, with the possible perforation of the bone cortex. Myxoma recurs frequently.



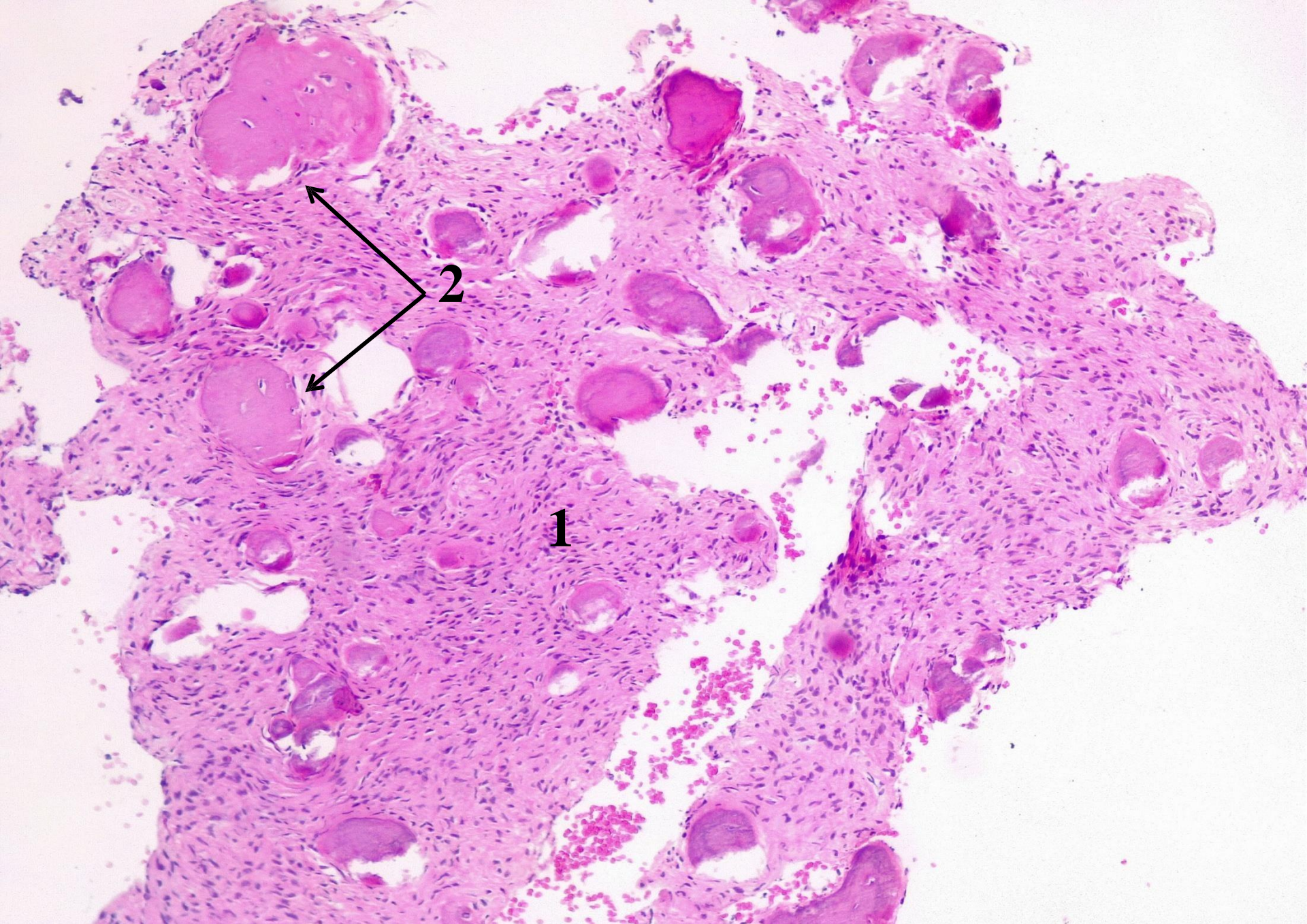
№ 195. Follicular ameloblastoma (*H-E stain*).



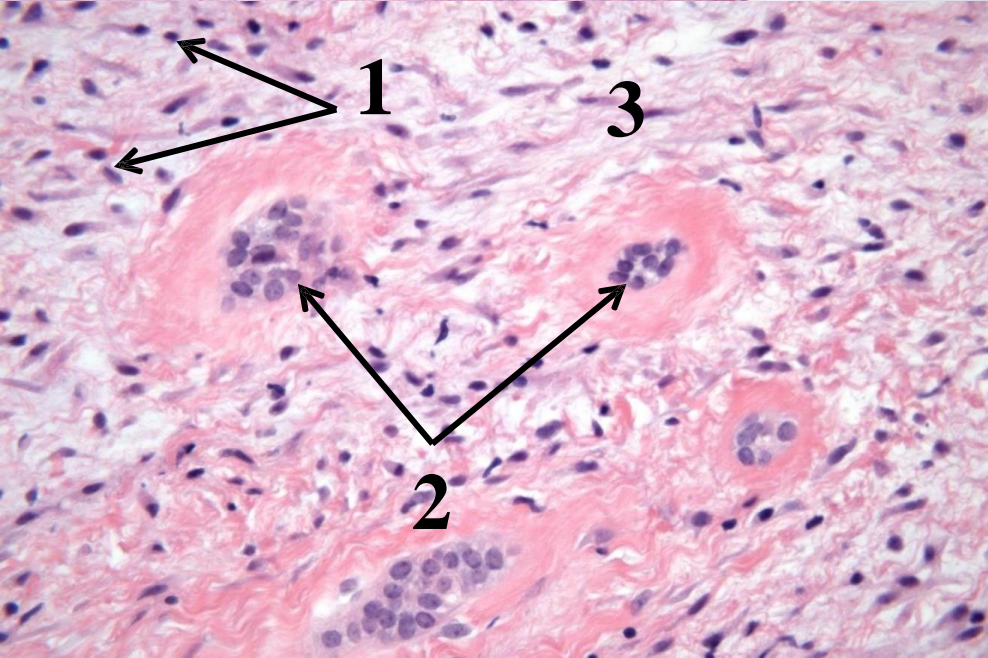
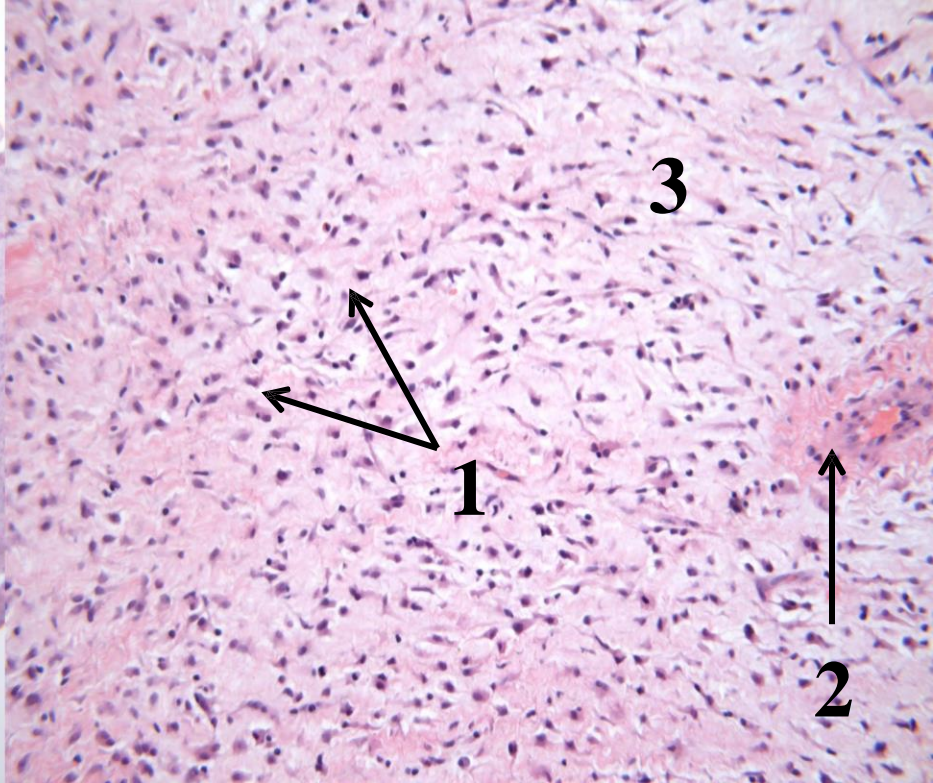
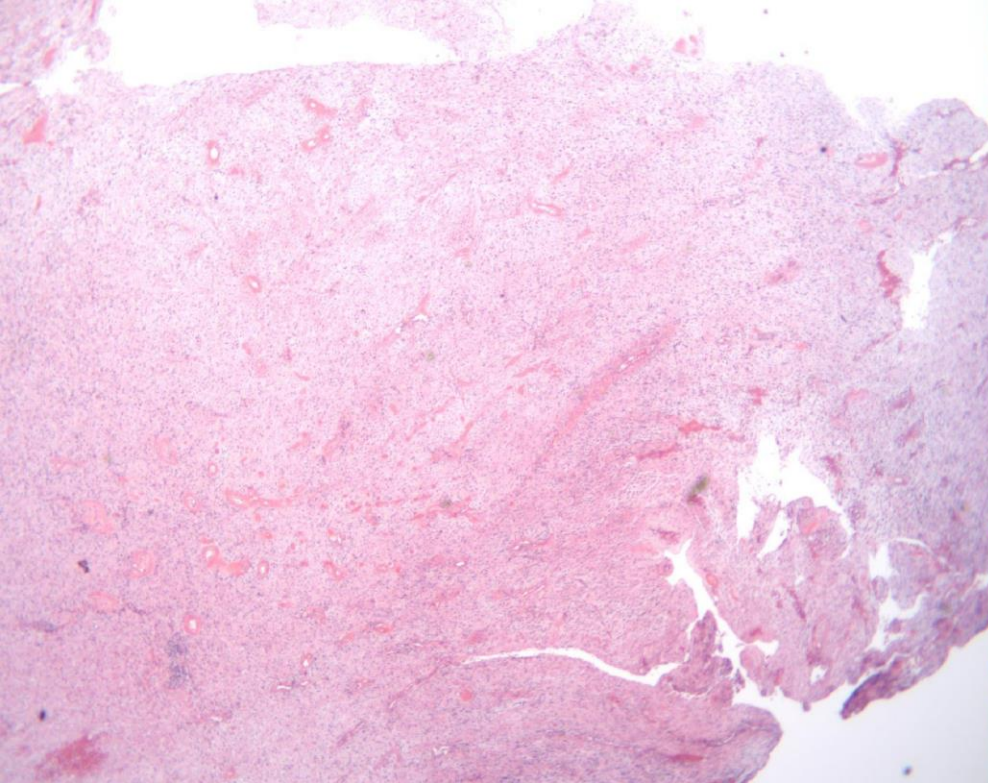
№ OP6. Ameloblastic fibroma (H-E stain).



№ OP 37. Complex odontoma (*H-E stain*).



№ OP 7. Cemento-ossifying fibroma (H-E stain).



№ OP 46. Odontogenic myxoma (*H-E stain*).

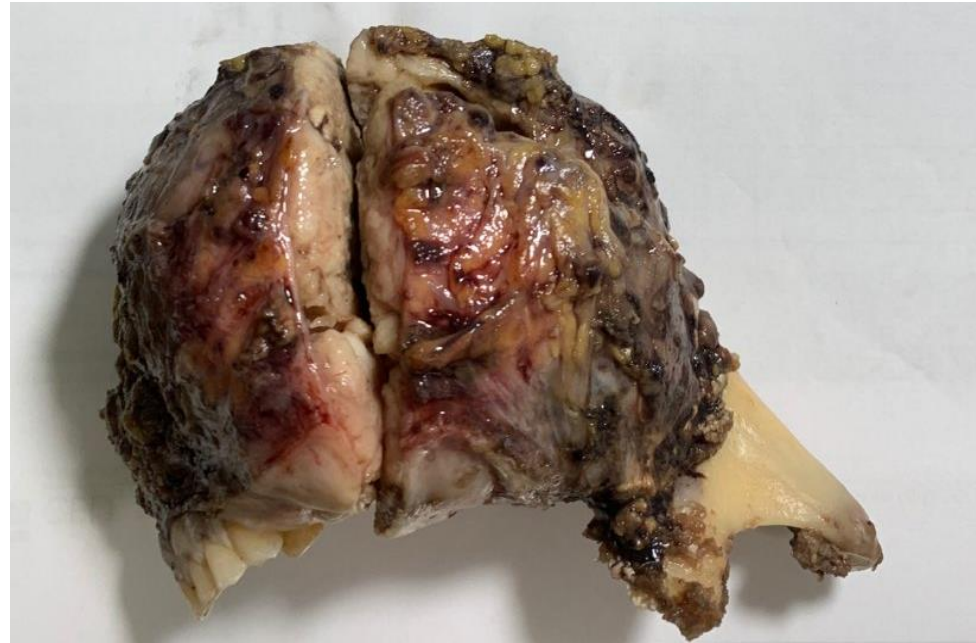Benign epithelial odontogenic tumors

Conventional ameloblastoma

- Uniquistic type ameloblastoma
- Extraosseous / peripheral type ameloblastoma
- Metastasant ameloblastoma
- Squamous odontogenic tumor
- Calcified epithelial odontogenic tumor
- Adenomatoid odontogenic tumor

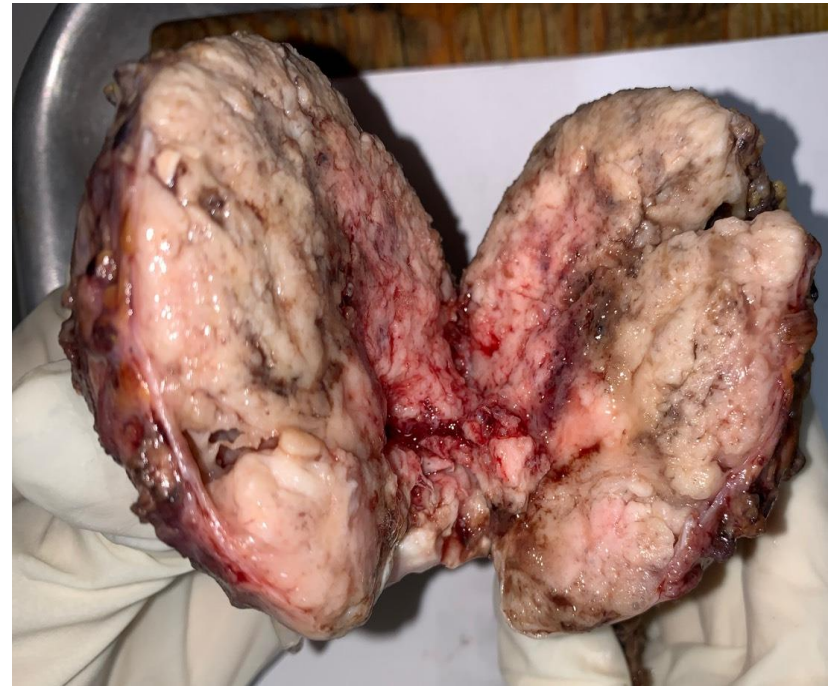Ameloblastoma

- Adults, the molar area of the horizontal branch
- Local invasive
- Single or multilocular
- X-ray: "soap bubbles", may resemble odontogenic myxoma

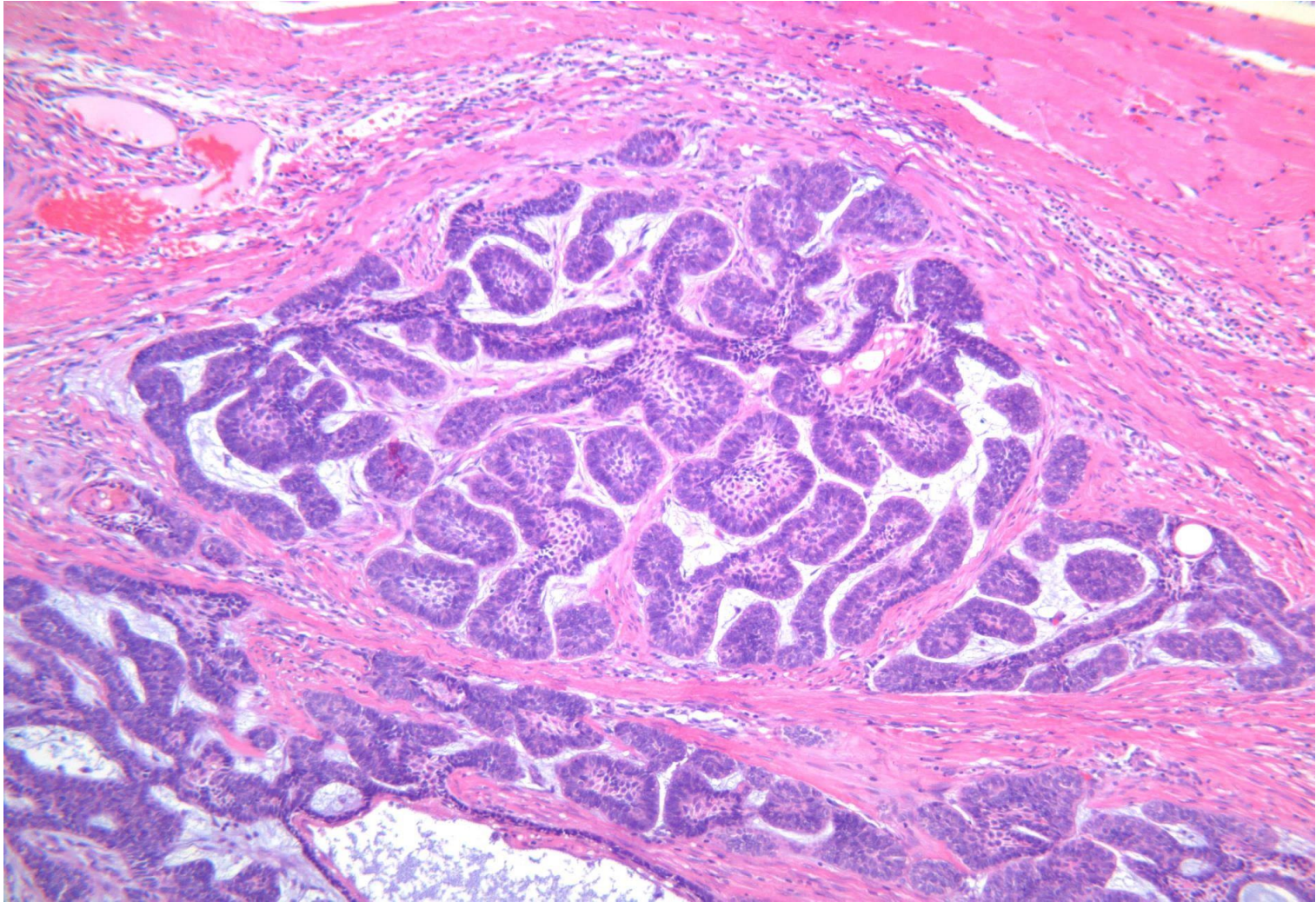


Ameloblastoma

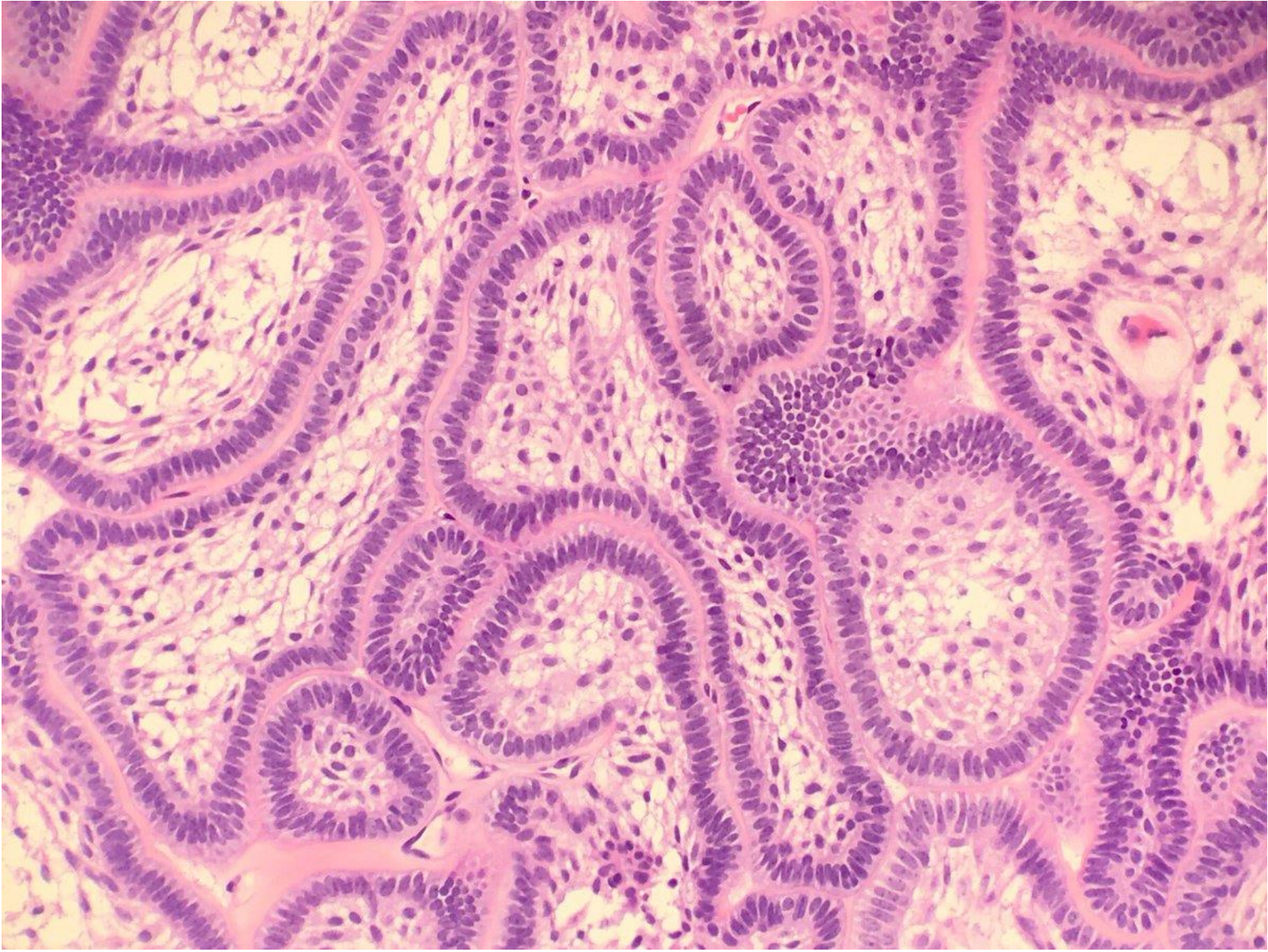
- The follicular histopathological type is the most common type
 - the tumor tissue resembles the enamel organ, being composed of islands and trabeculae of odontogenic epithelium in a fibrous stroma.



Ameloblastoma, follicular type

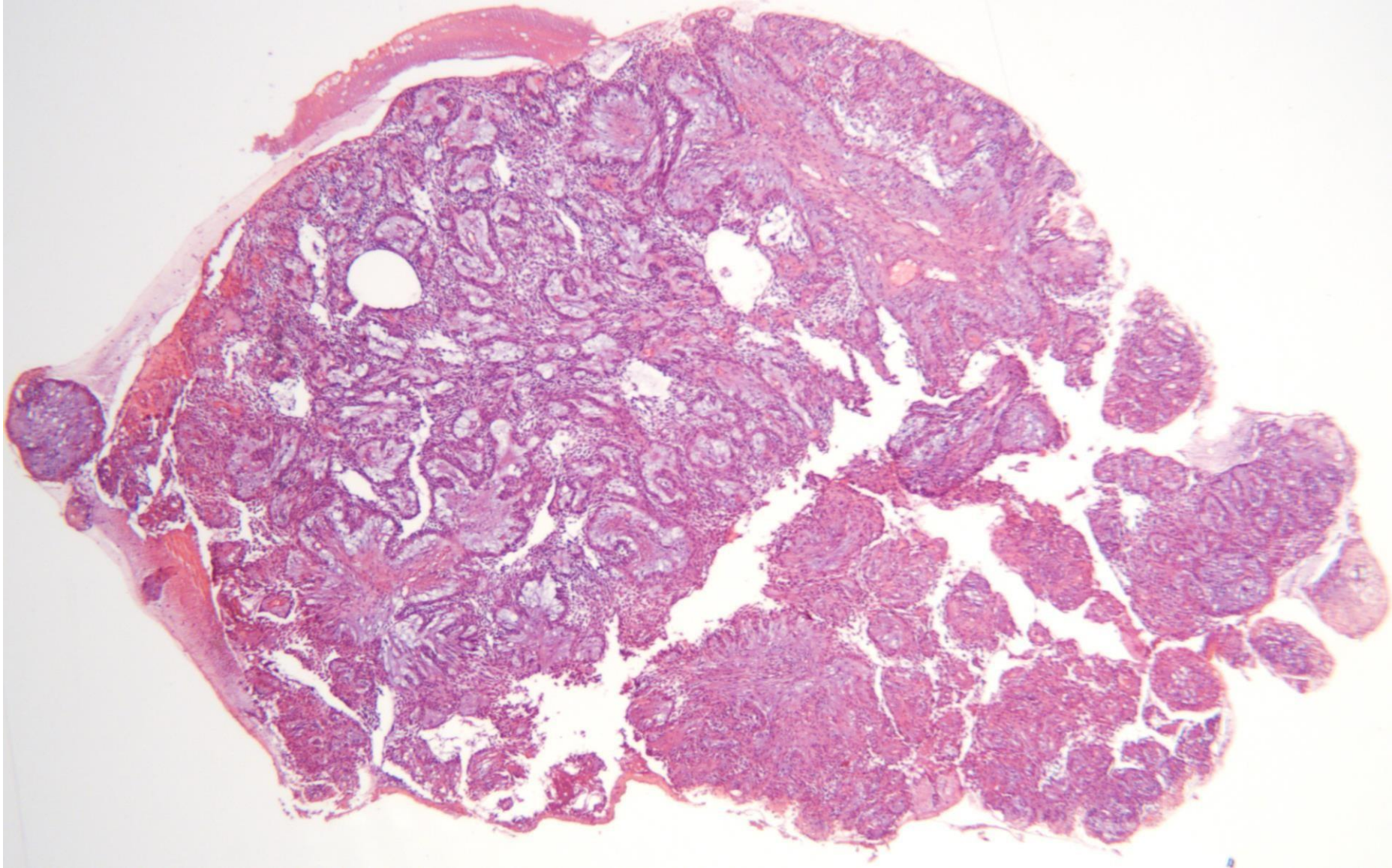


- neoplastic islands with a polygonal or angular cell core arranged similarly to the star lattice
- surrounded by a single palisade row of tall ameloblast-like columnar cells
- with nuclei arranged at the pole opposite the basement membrane (reverse polarity)



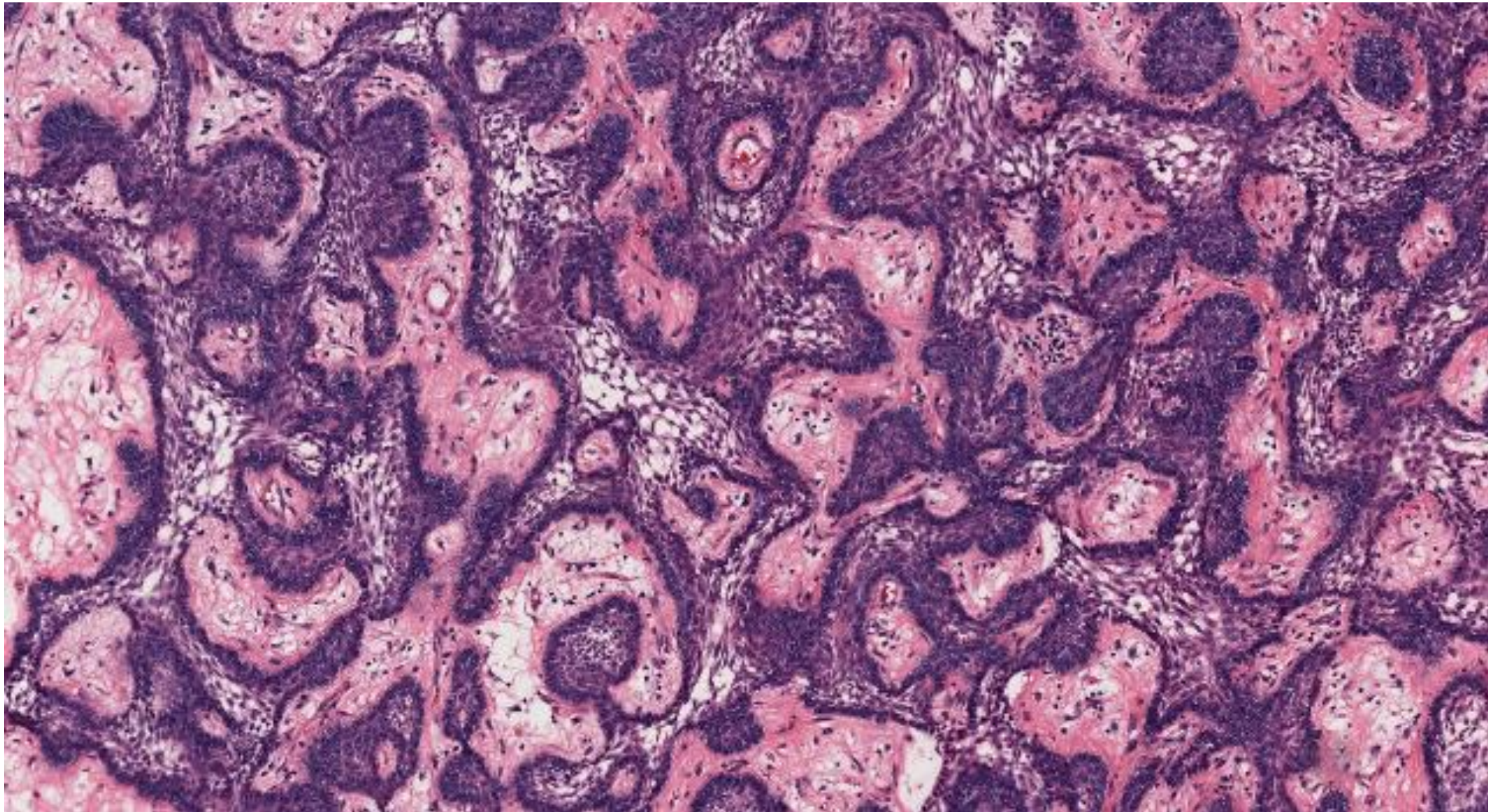
- neoplastic islands with a polygonal or angular cell core arranged similarly to the star lattice
- surrounded by a single palisade row of tall ameloblast-like columnar cells
- with nuclei arranged at the pole opposite the basement membrane (reverse polarity)

Ameloblastoma – plexiform type

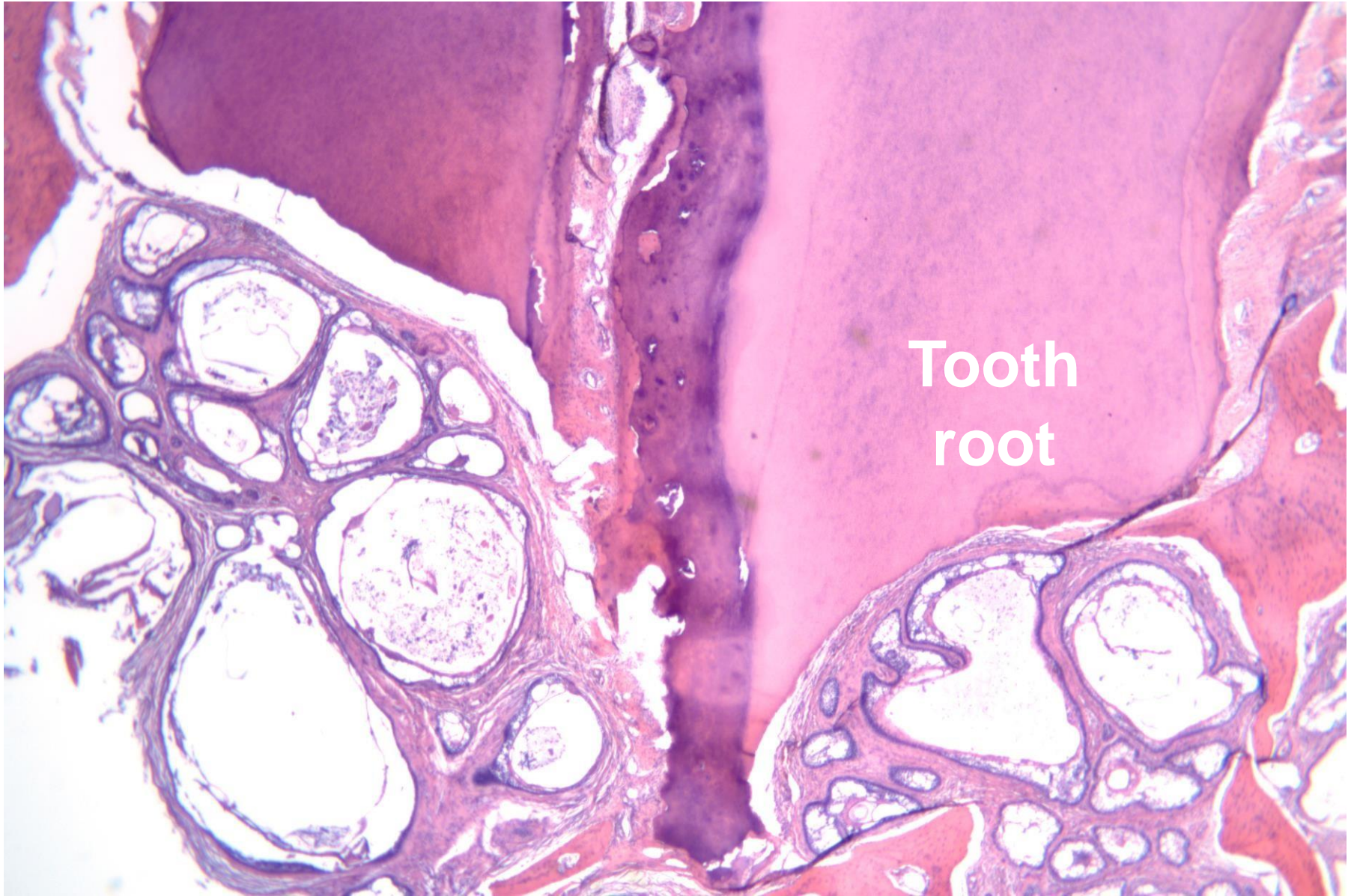

- basal tumor cells, columnar cells less differentiated than follicular ameloblast-like cells
- arranged in cords, fine anastomosed trabeculae

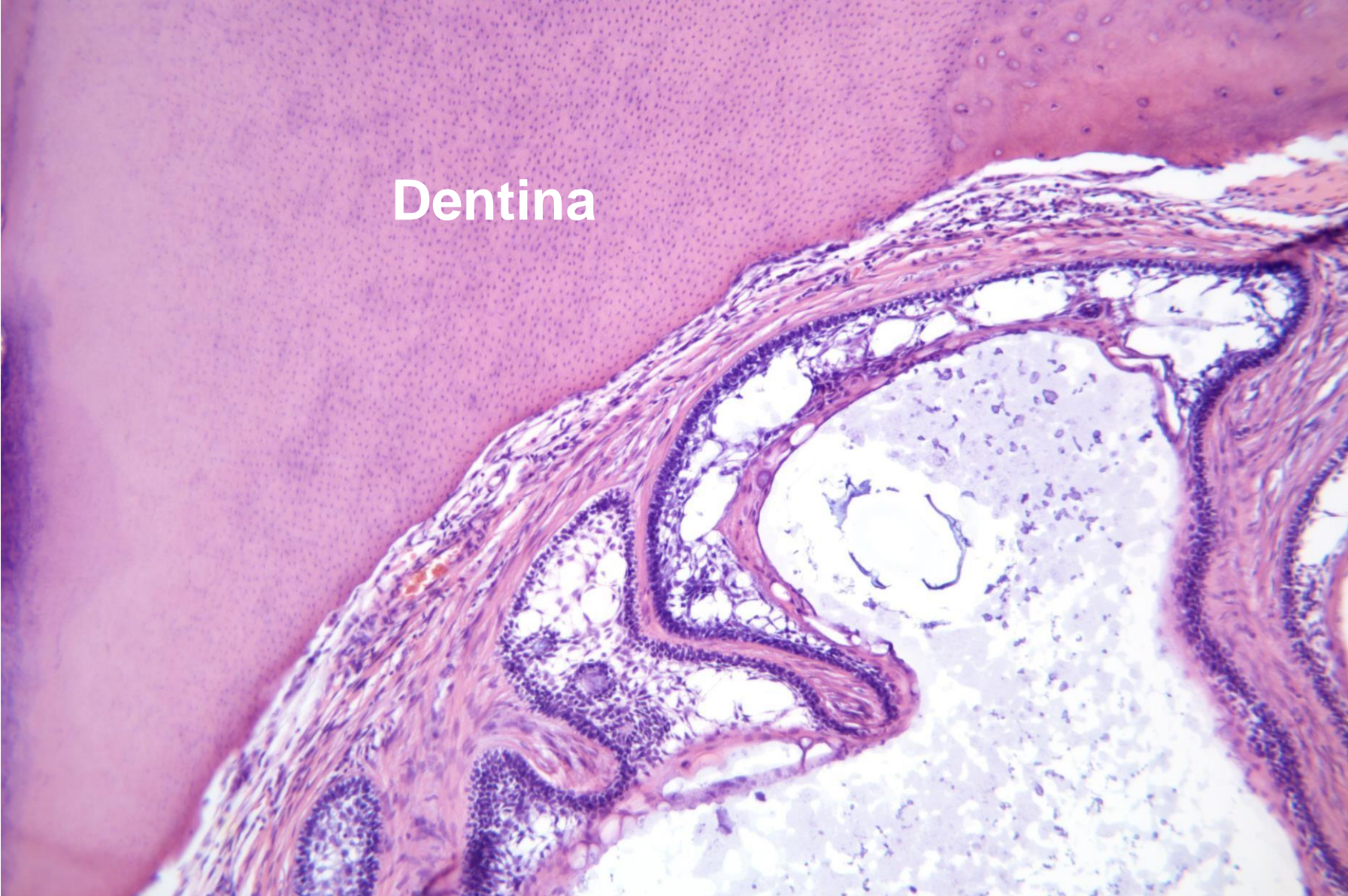
Ameloblastoma – plexiform type

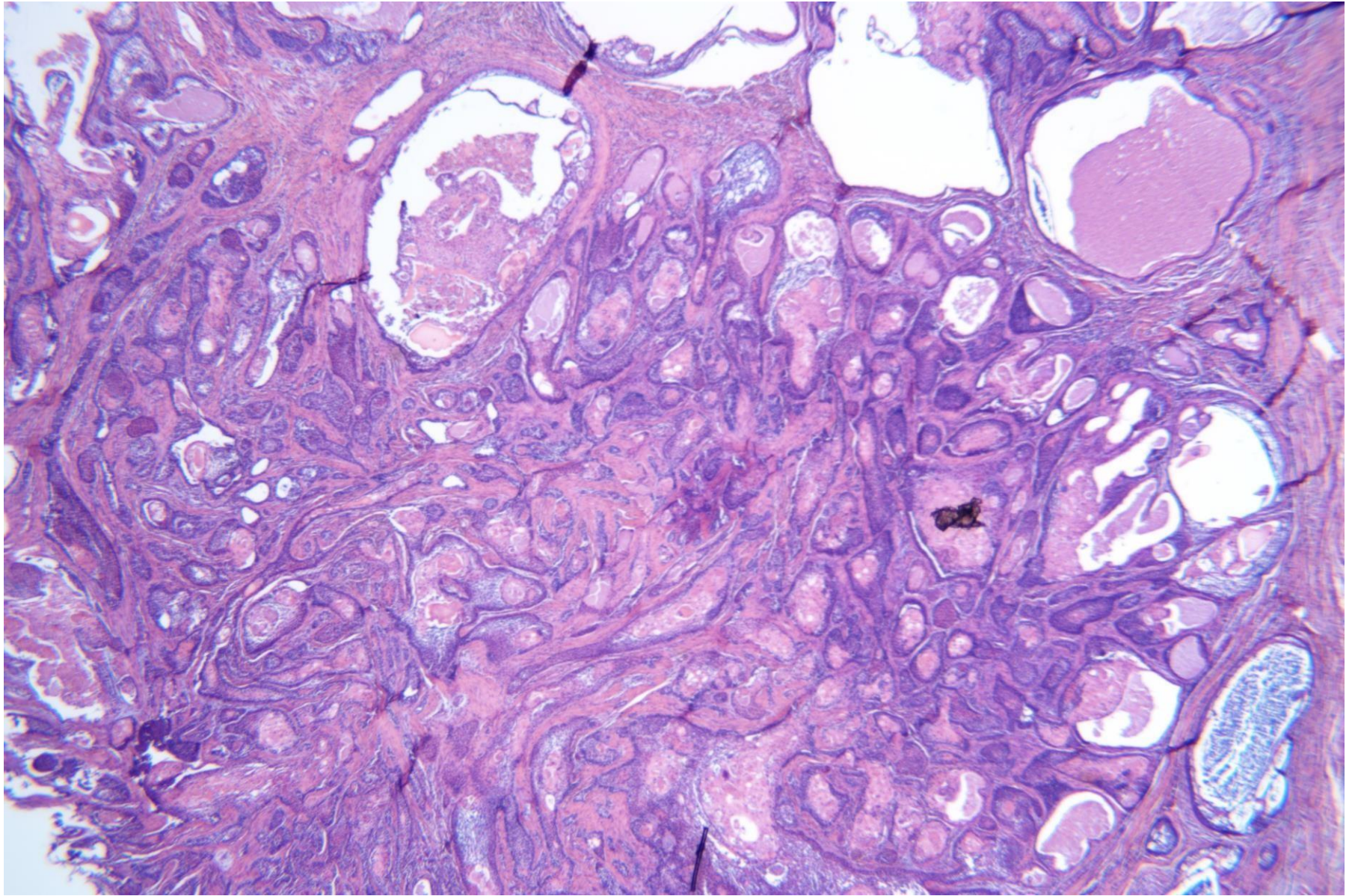


Resorption of the tooth root in ameloblastoma

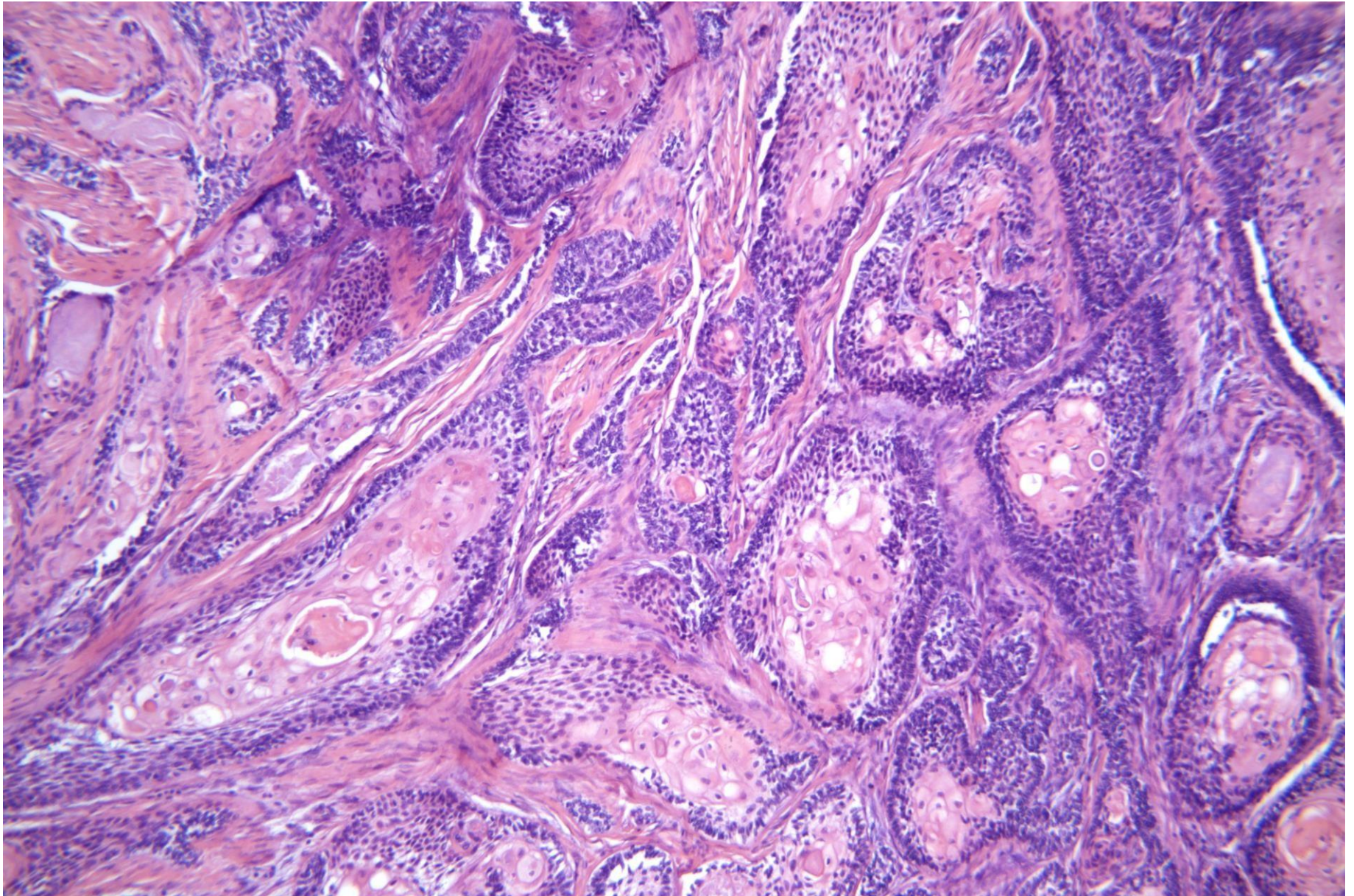


Dentina

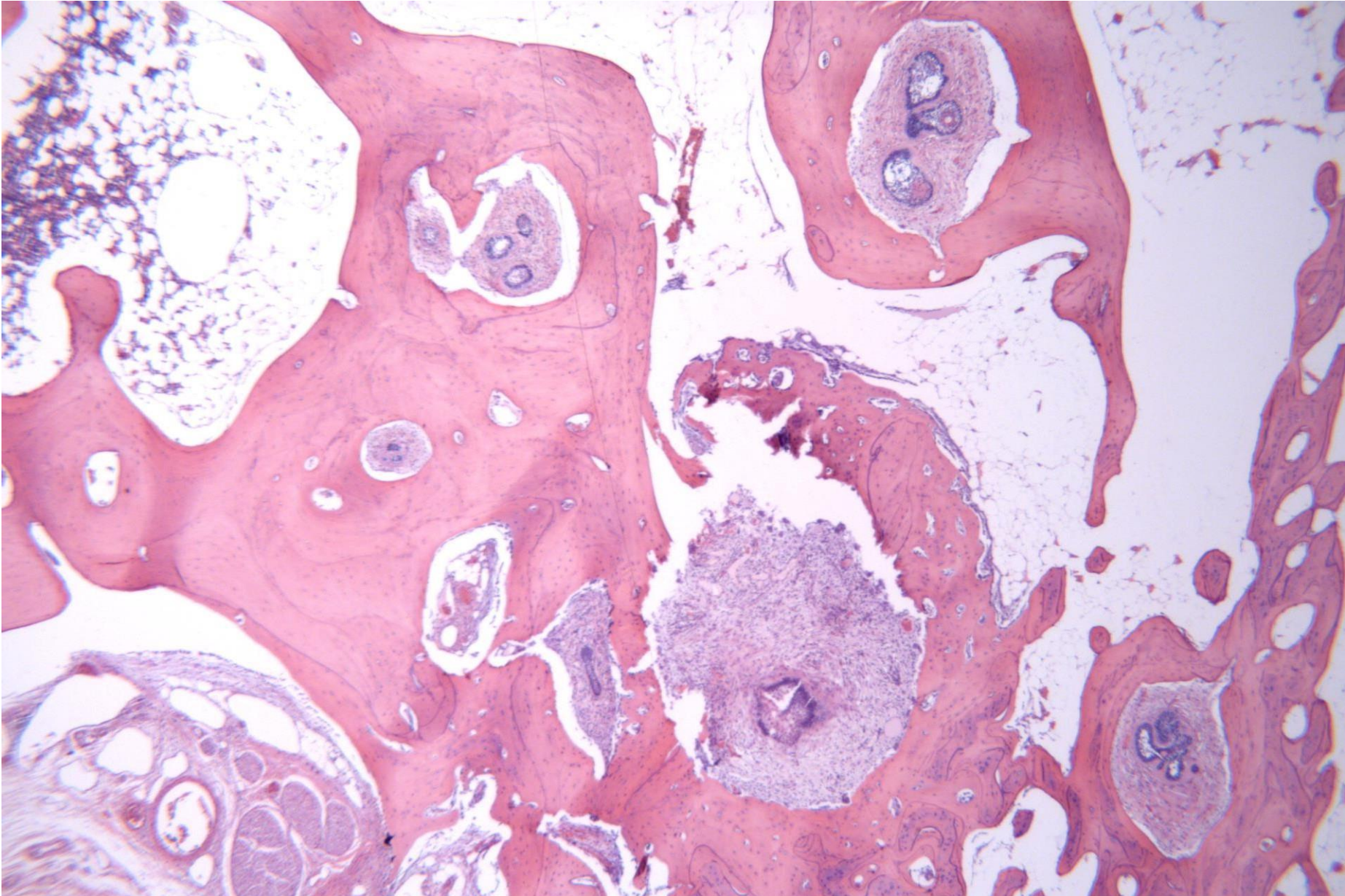


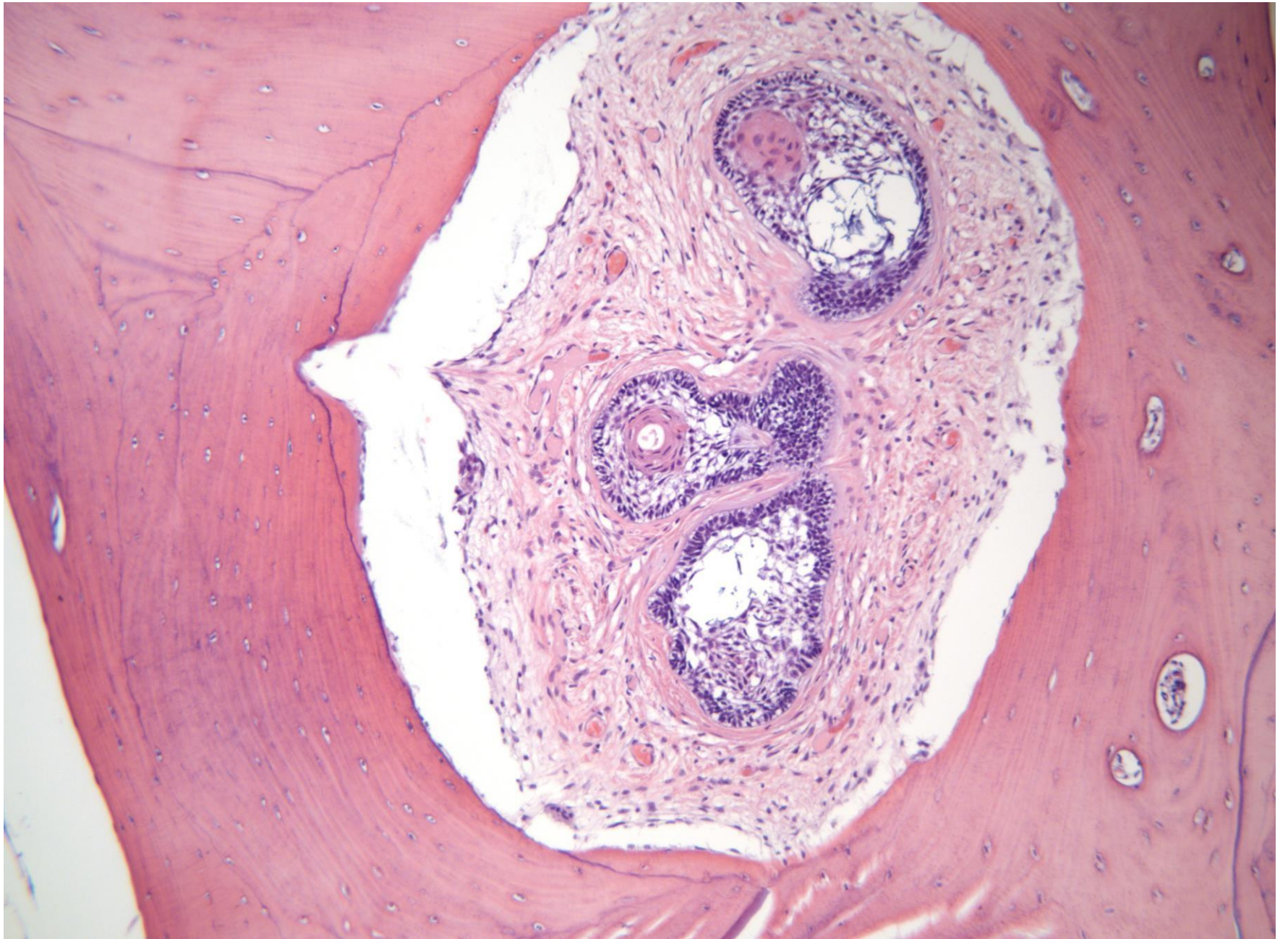


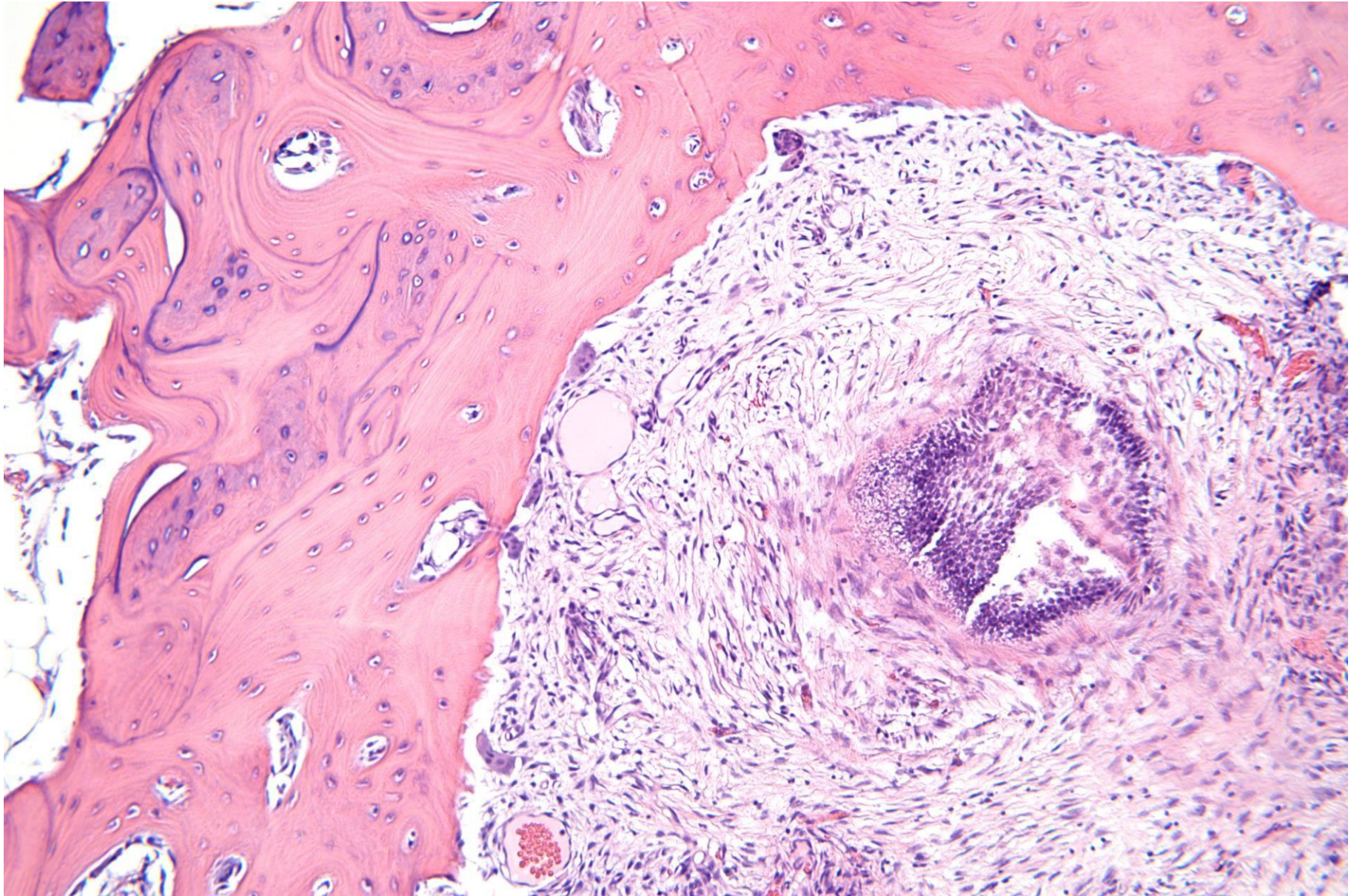
Ameloblastoma – acantomatous tipe



Ameloblastoma – bone invasion





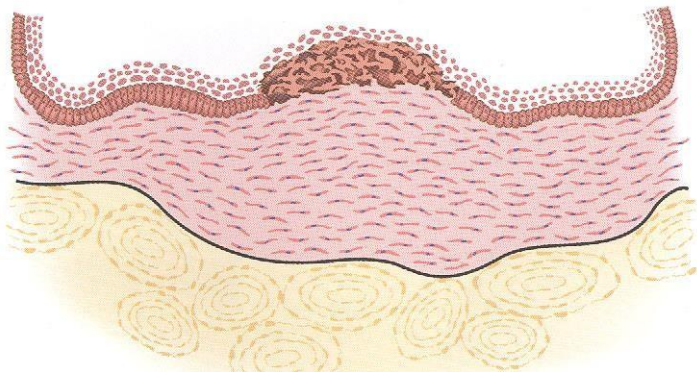


Conventional ameloblastoma

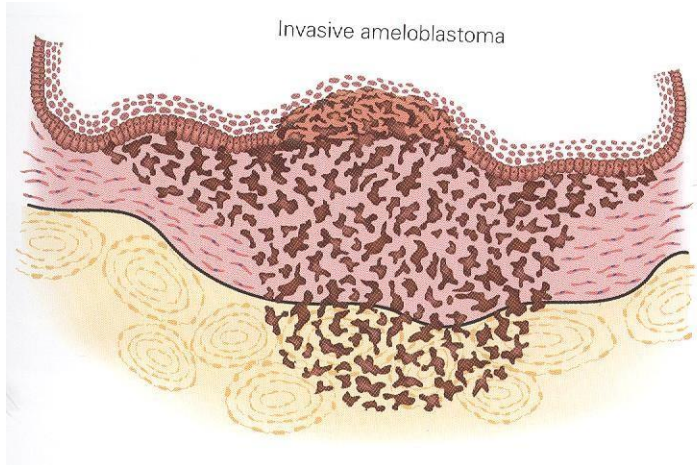
- The treatment of election - radical surgery with wide excision of the tumor, having as a safety margin of at least 1.5 cm in the surrounding normal bone
- For large tumors - resections of the maxillary bones, followed by bone graft
- Radiation therapy can only reduce tumor size - in inoperable cases (posterior reg.)

Ameloblastomas developed in the cyst wall

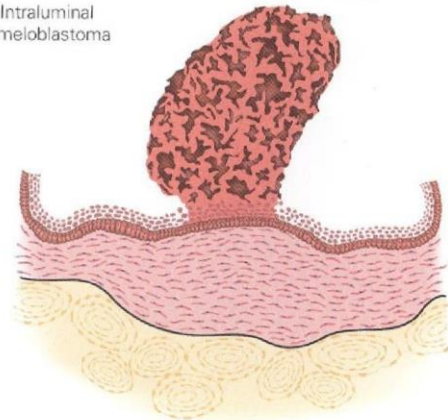
Mural ameloblastoma



Invasive ameloblastoma

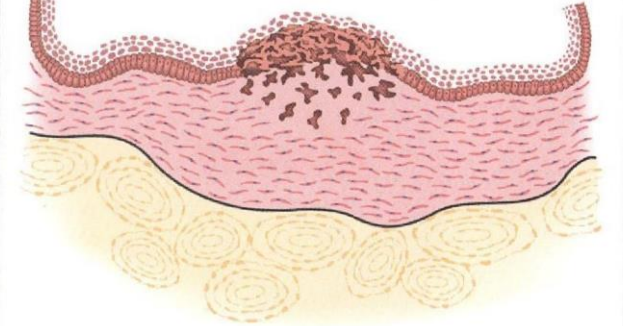


Intraluminal ameloblastoma



Figs 14-4a and 14-4b Intraluminal ameloblastoma in situ arising from

Intramural ameloblastoma



Figs 14-5a and 14-5b Intramural microinvasive ameloblastoma arising from the inner lining of the cyst.

Transmural ameloblastoma

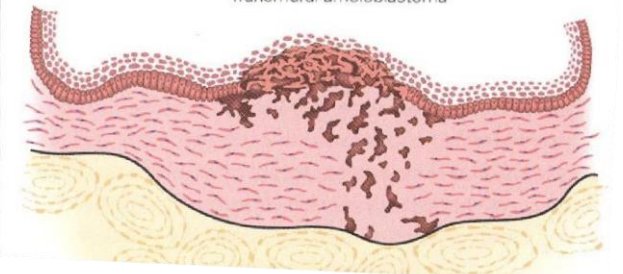

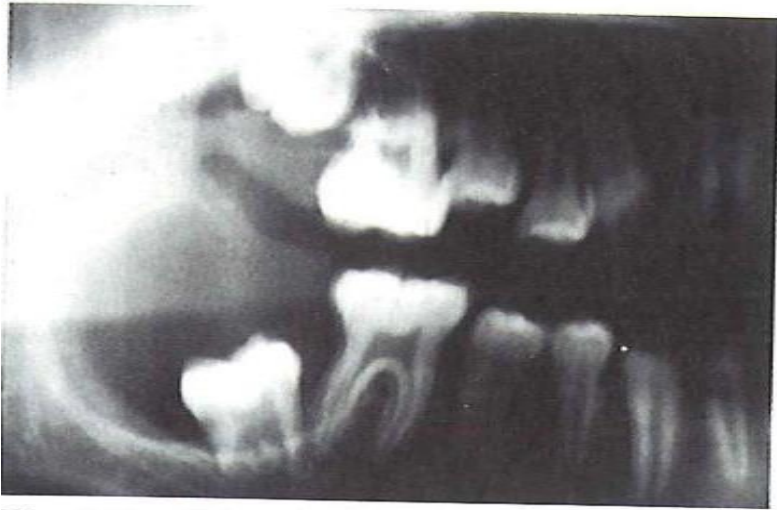


Fig. 6.21 Unicyclic ameloblastoma. Panoramic radiograph mimicking dentigerous (follicular) cyst with impacted second mandibular molar.


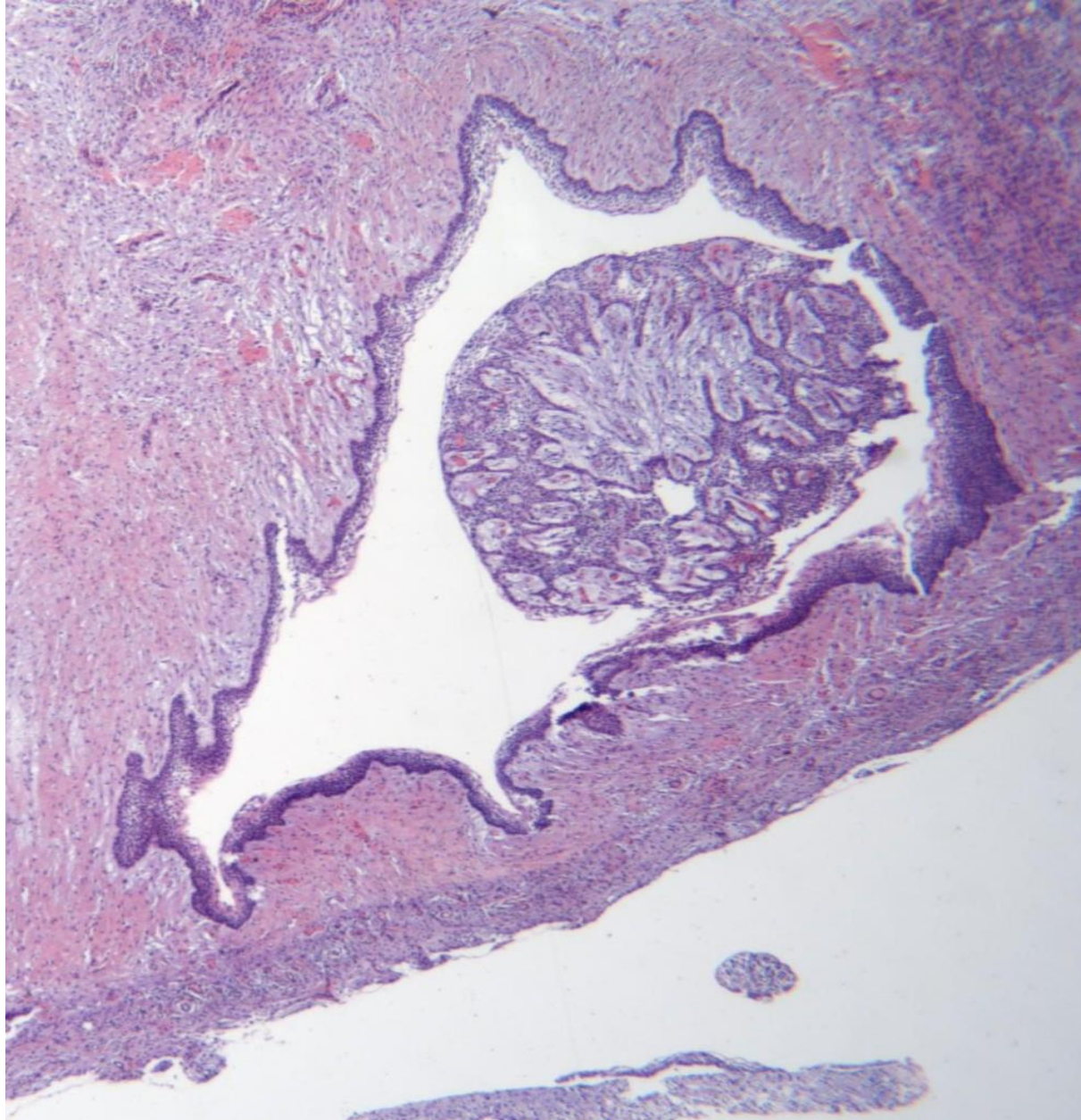
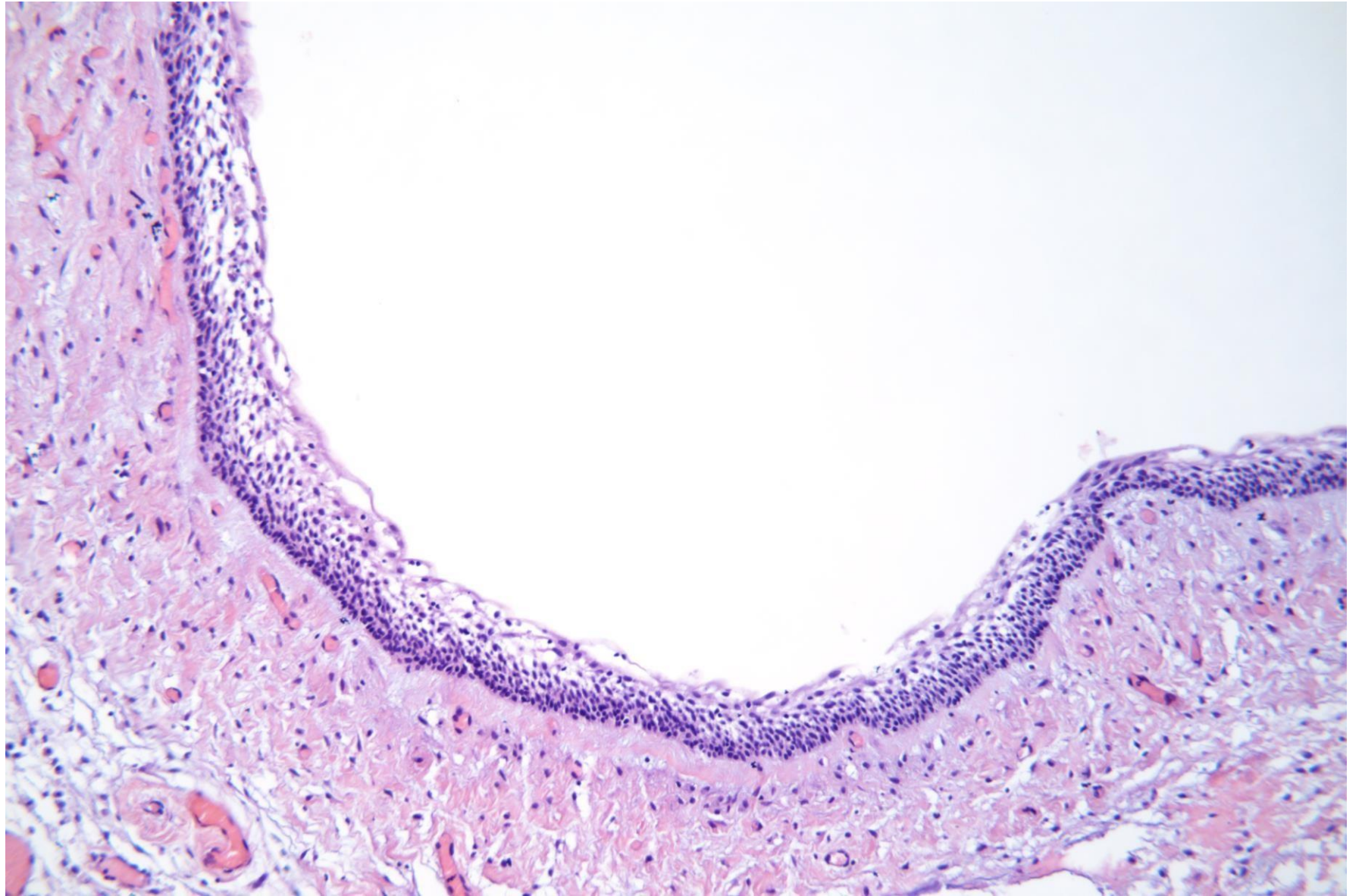
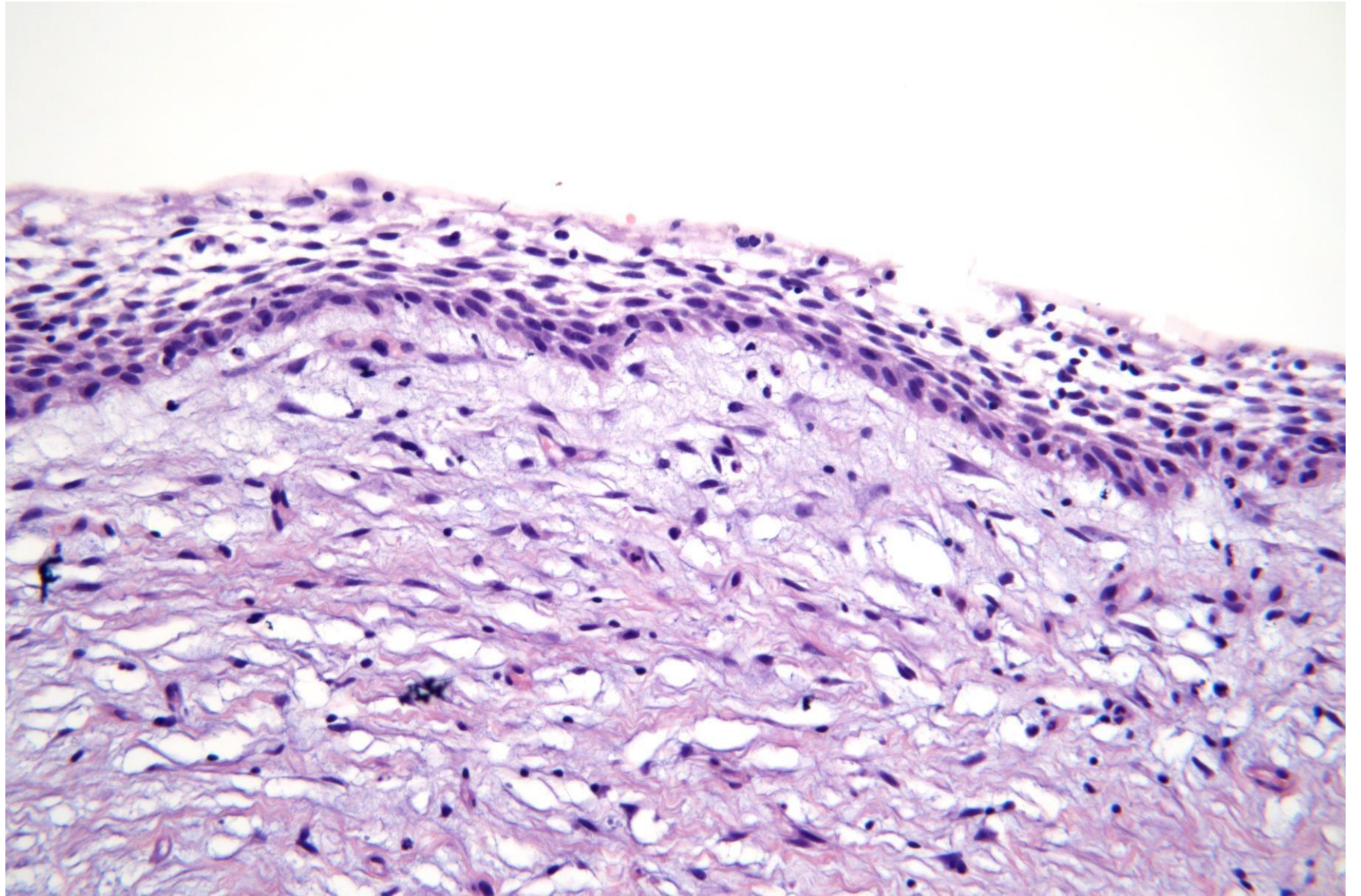


Fig. 6.22 Schematic view of histological variants of unicyclic ameloblastoma: luminal (ameloblastomatous cyst epithelium), intraluminal (protruding into cyst cavity) and mural (left and right, invading cyst wall).

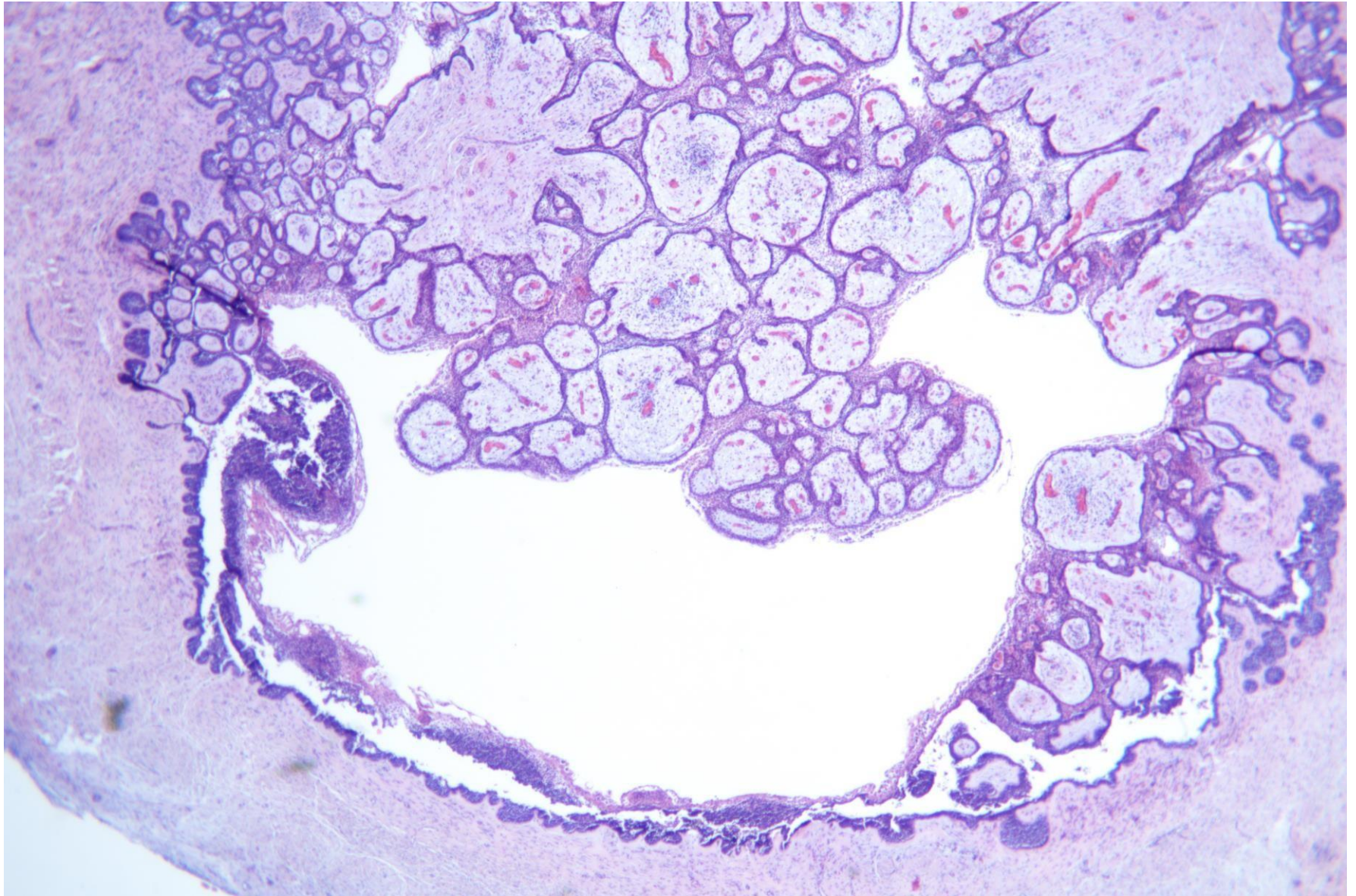
Cystic ameloblastoma







Cystic ameloblastoma



Cystic ameloblastoma

- Luminal and intraluminal variants therapeutic attitude-enucleation with radiological follow-up
- Mural variant - local resection

Peripheral ameloblastoma

- The extraosseous variant of conventional ameloblastoma
- It develops in the gums
- Possibly from the suprapariosteal remains of the dental lamina
- Histologically similar to conventional ameloblastoma

Peripheral ameloblastoma

- DD - gingival extension of an intraosseous ameloblastoma
- Non-invasive behavior
- Local excision
- Low recurrence rate

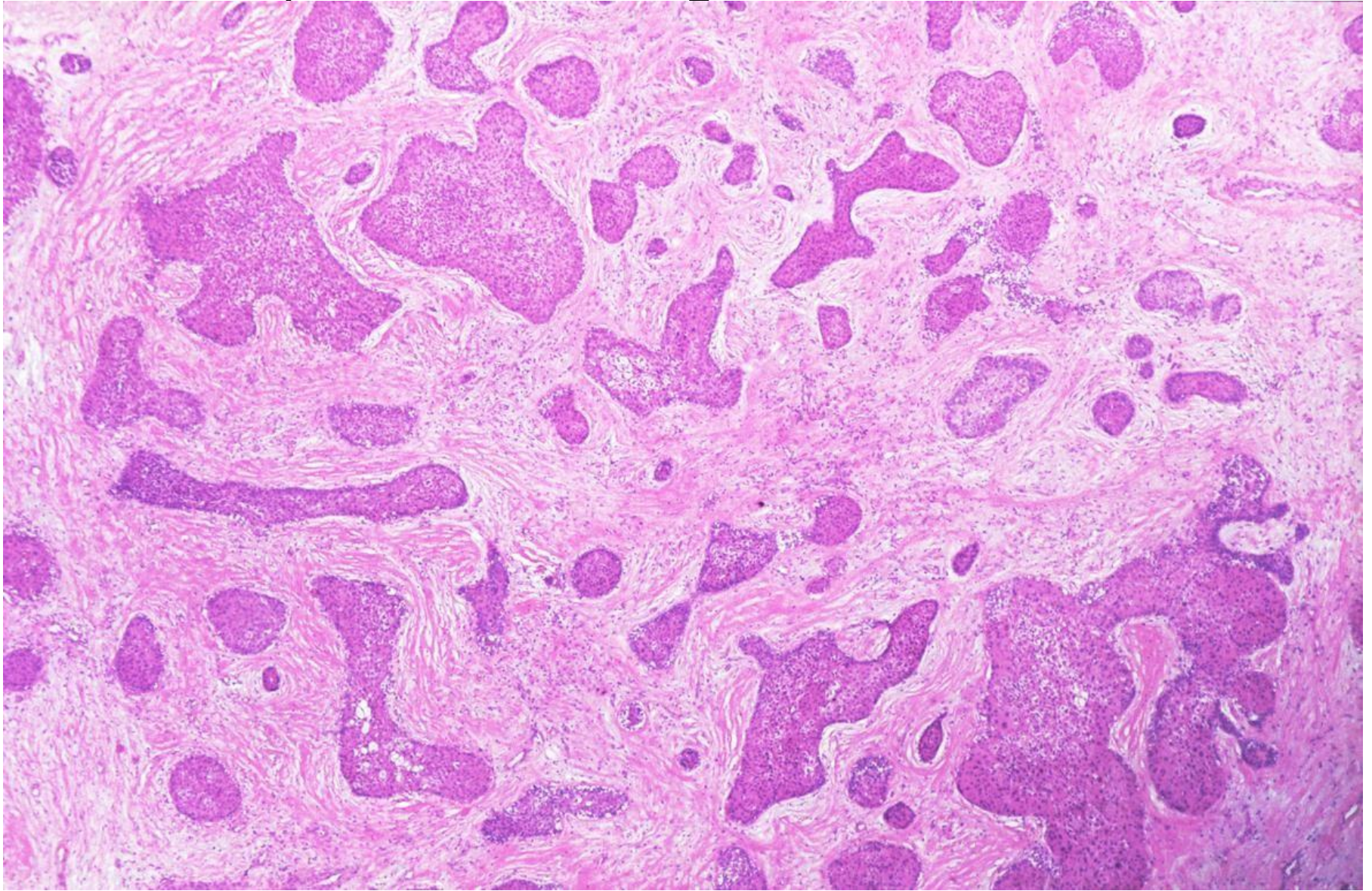
Metastasant ameloblastoma

- Metastases despite benign histological appearance
- Metastatic cells have slowed growth rate with clinical manifestations secondary to late metastasis
- MT in the Lungs (88%), NL reg., Vertebral bodies, liver.

Squamous odontogenic tumor

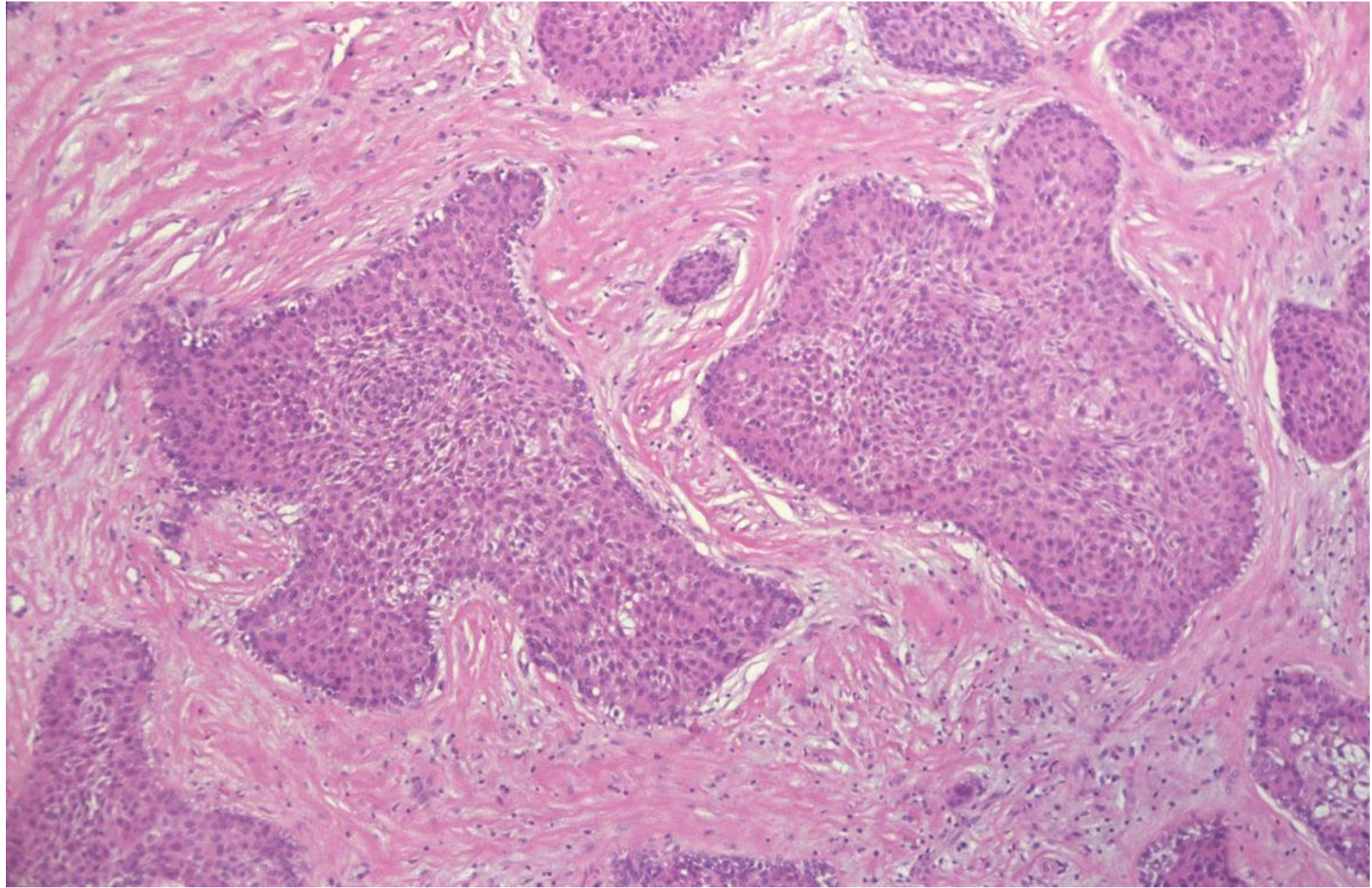
- Most likely neoplasm of the dental lamina
- Grown ups
- Well demarcated
- Frequently associated with tooth root

Squamous odontogenic tumor



- islands of squamous epithelium
- stroma represented by fibrous, hypocellular and poorly vascularized tissue.

Squamous odontogenic tumor



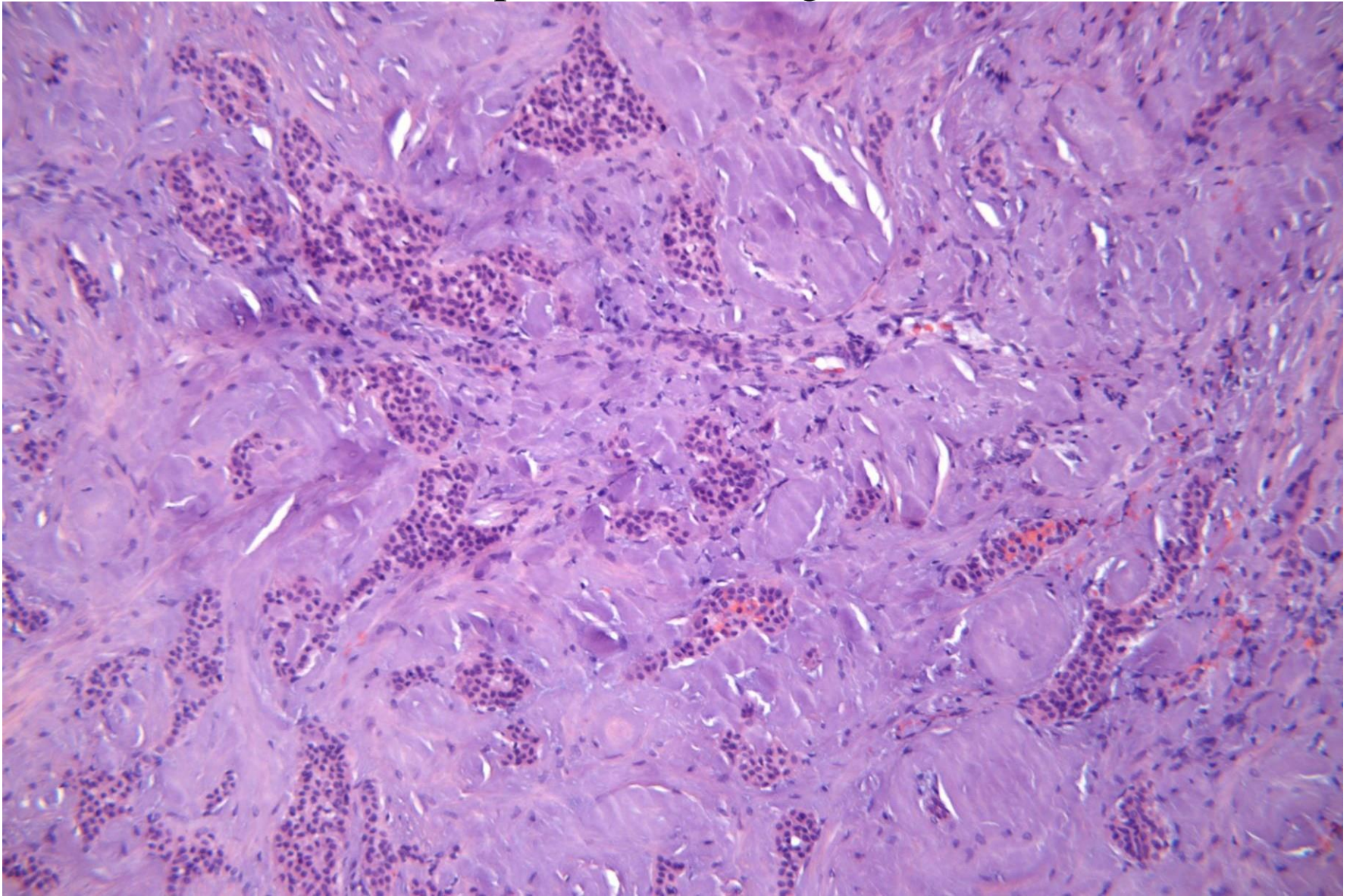
Squamous odontogenic tumor

- Treatment - removal of the lesion associated with the extraction of the tooth concerned.
- Benign behavior
- 25% of asymptomatic patients

Calcified epithelial odontogenic tumor (Pindborg)

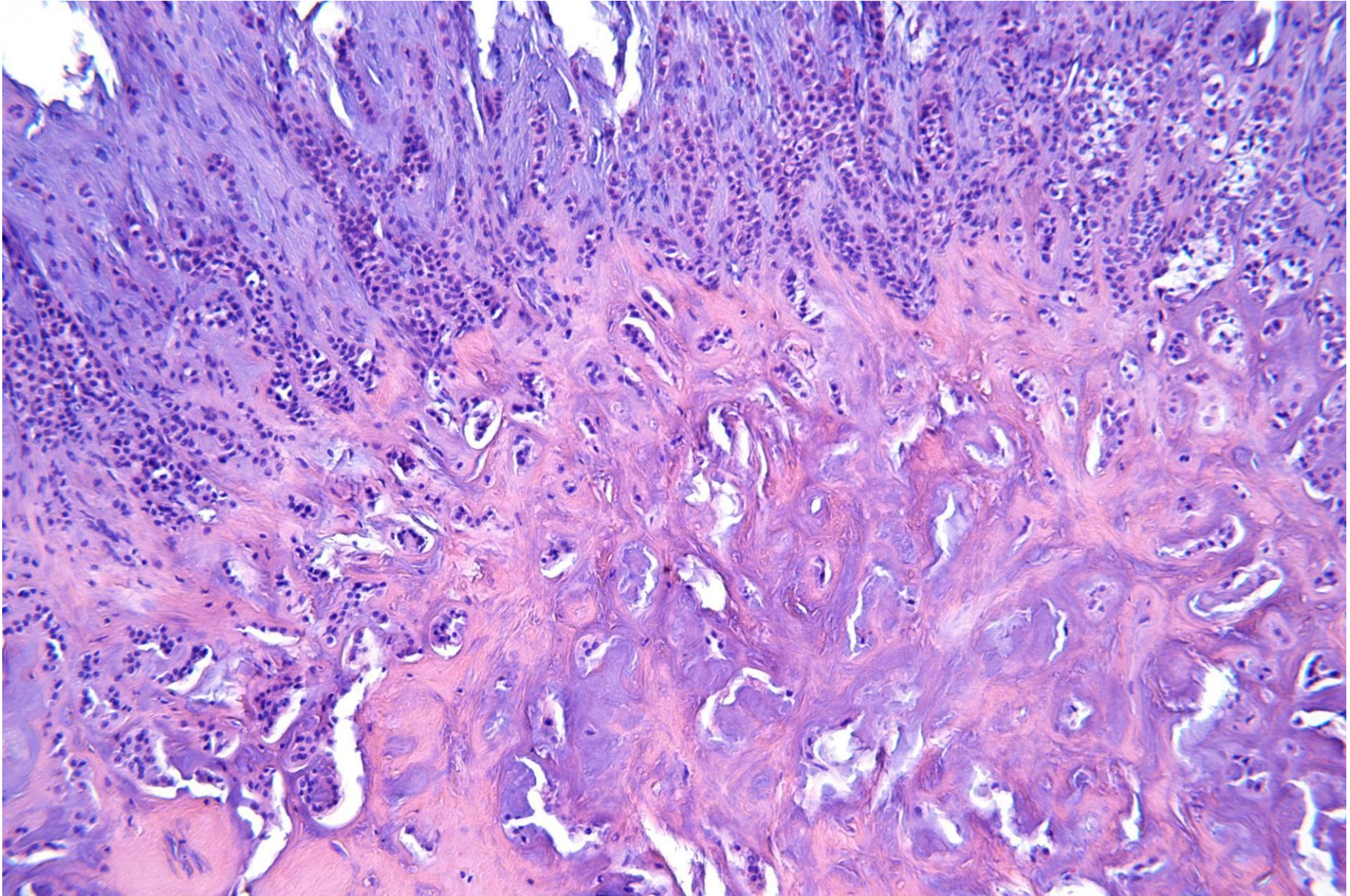
- It expands
- Invade locally
- Adamantine epithelium of an unbroken tooth
- 50% are related to the affected tooth
- Well demarcated, can be diffused
- Uni- or multilocular
- Develop radio-opaque foci with variable density
- recur

Calcified epithelial odontogenic tumor



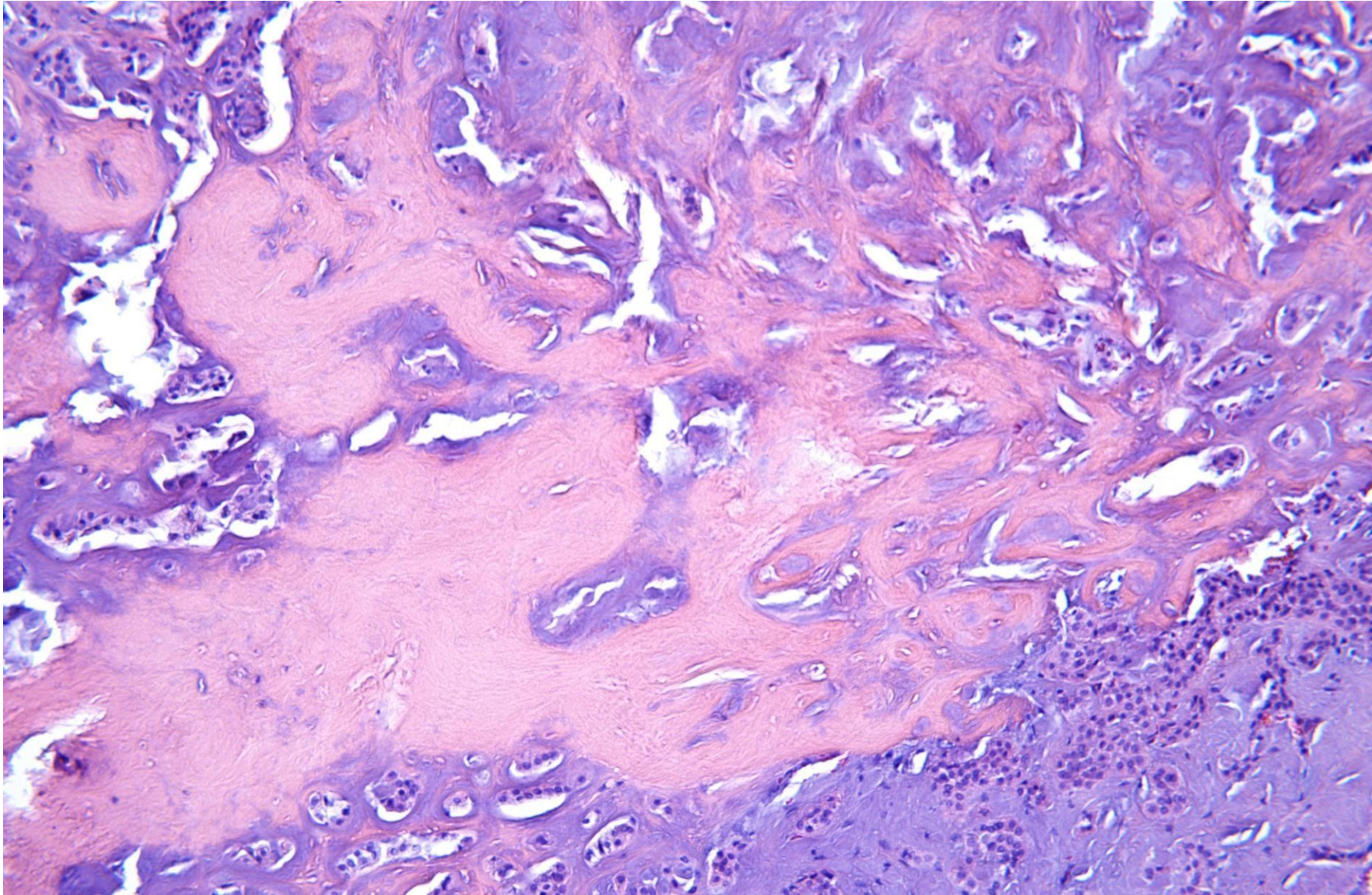
- islands formed by epithelial cells arranged in a fibrous stroma

Calcified epithelial odontogenic tumor



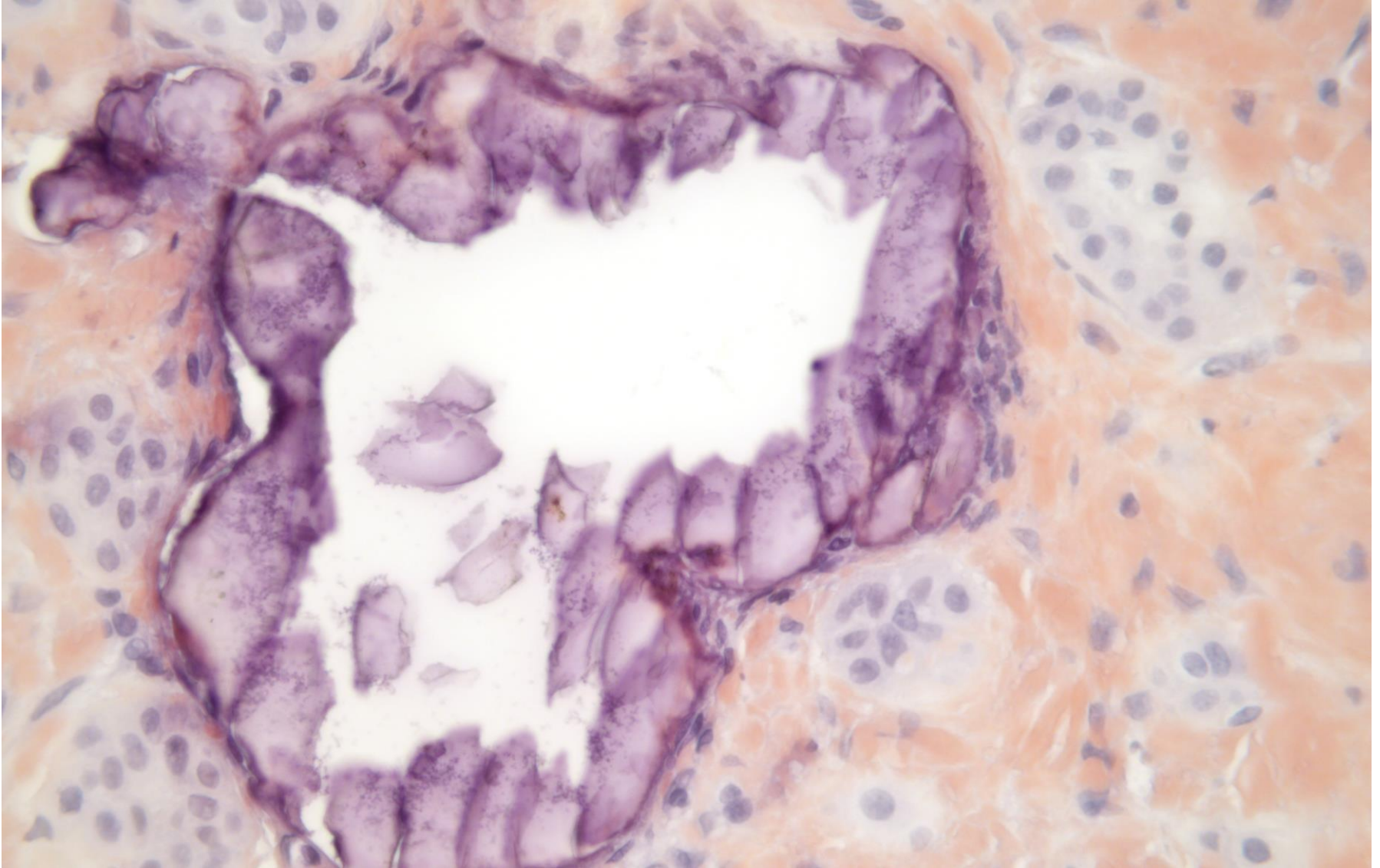
- the presence of a hyaline, homogeneous, often calcified eosinophilic material arranged in or around epithelial proliferations

Calcified epithelial odontogenic tumor



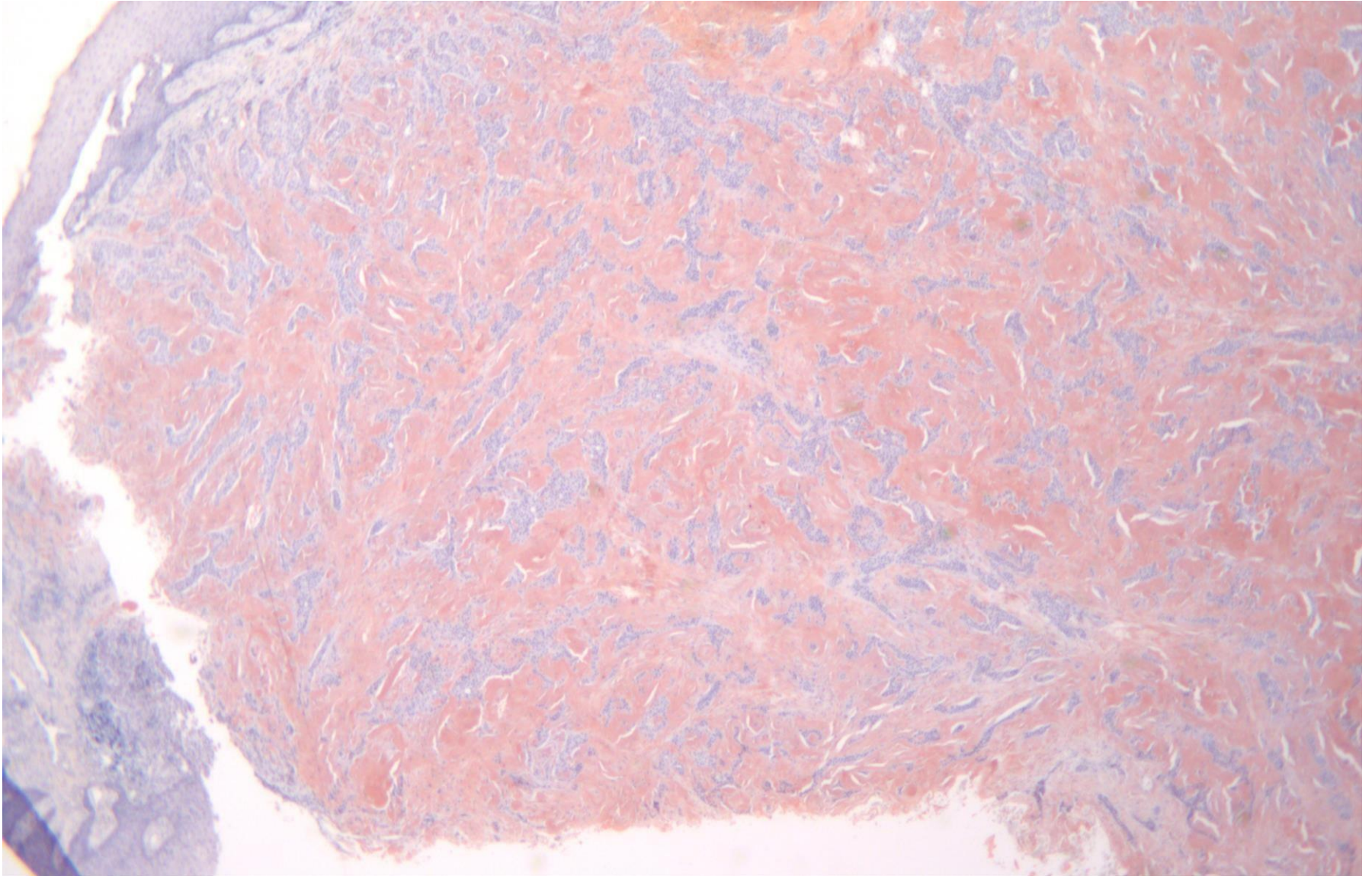
- special stains show reactivity similar to that of amyloid

Calcified epithelial odontogenic tumor – calcification+amyloid



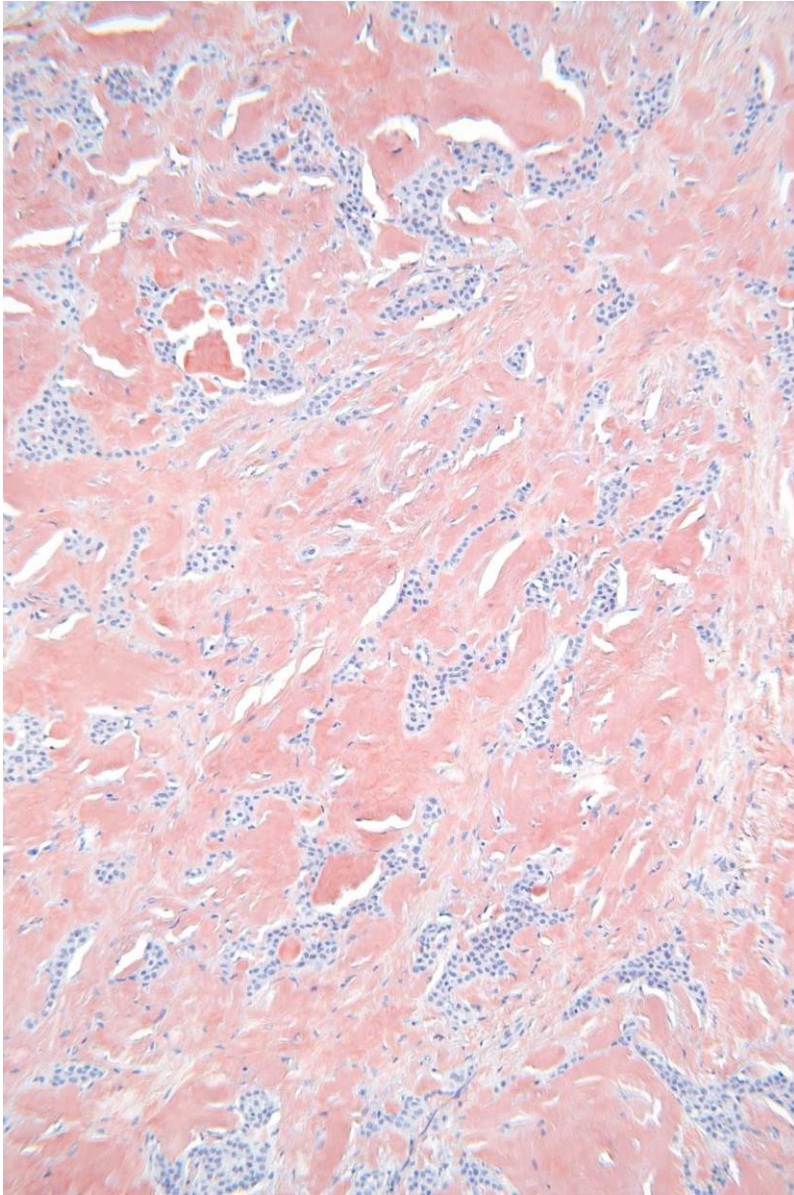


- the exact nature of this material is not known (degradation of epithelial comp.) or is produced by active secretion

Congo Red – amyloid

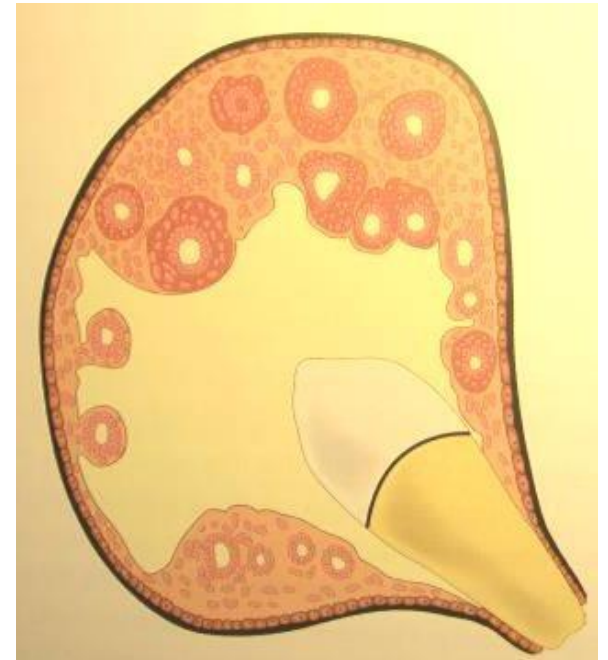


Amyloid – polarized microscopy

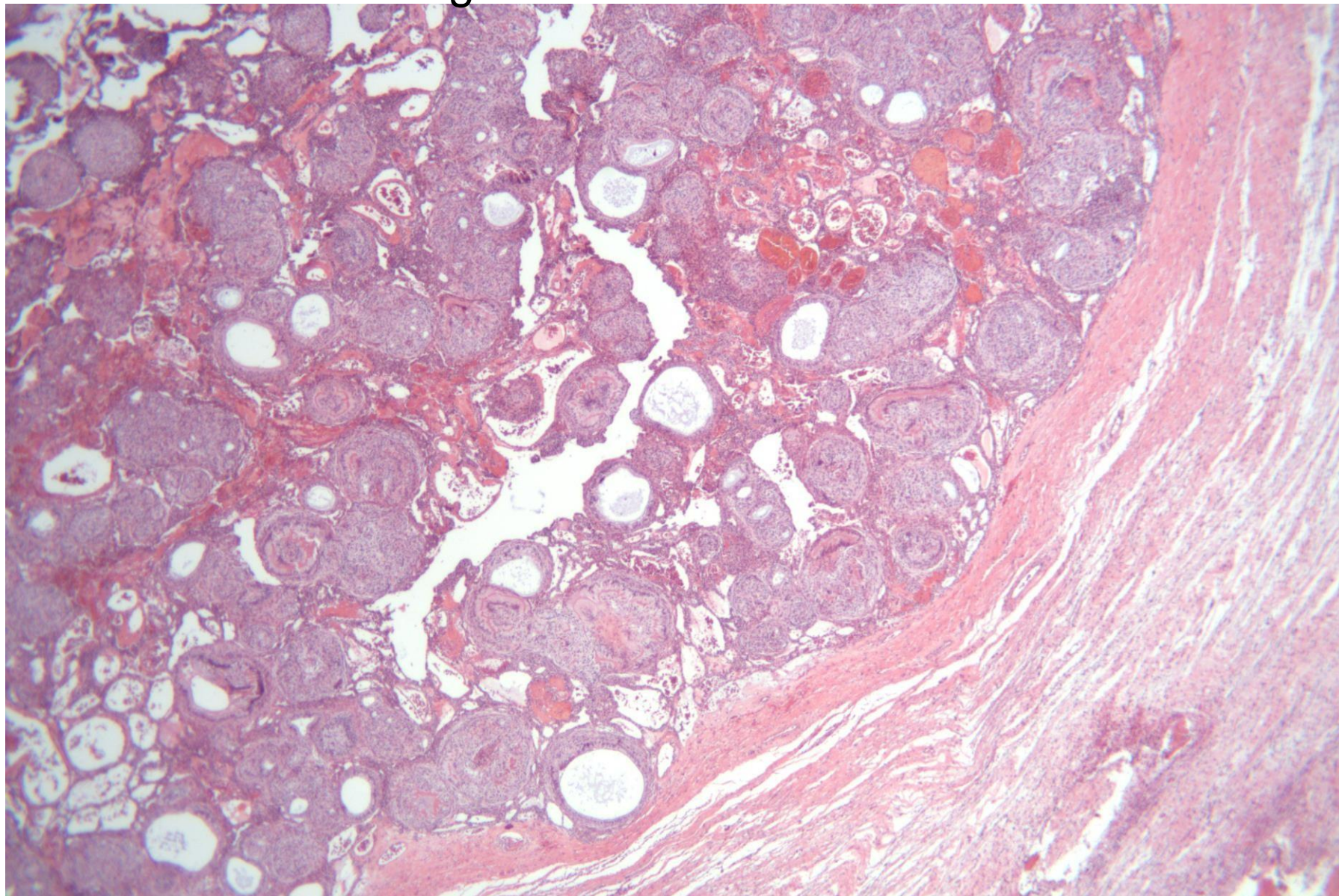


Adenomatoid odontogenic tumor

- Adolescents
- Maxilla, anterior
- He often surrounds a canine
- It can prevent the eruption
- Slow growth

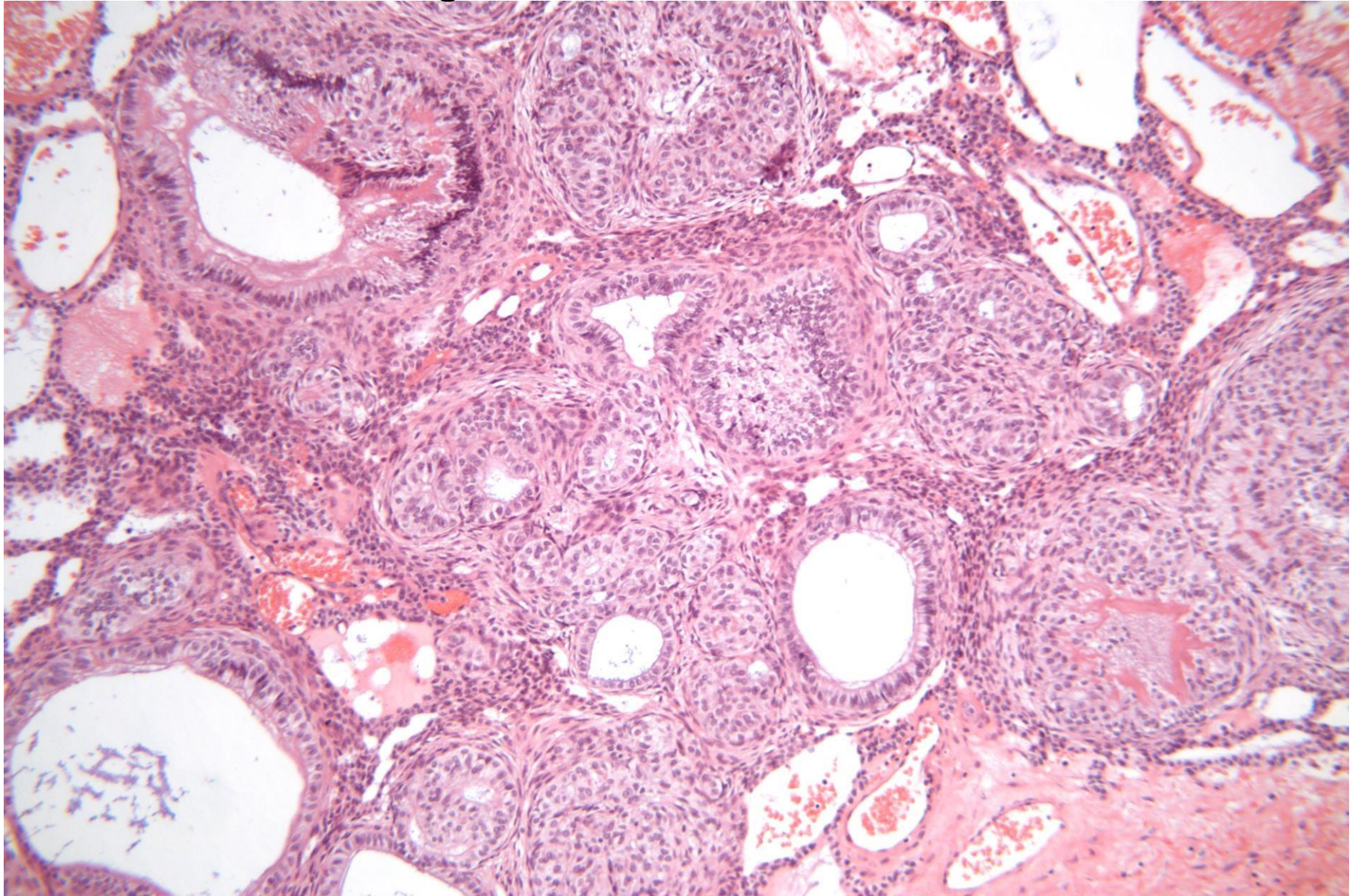


Adenomatoid odontogenic tumor

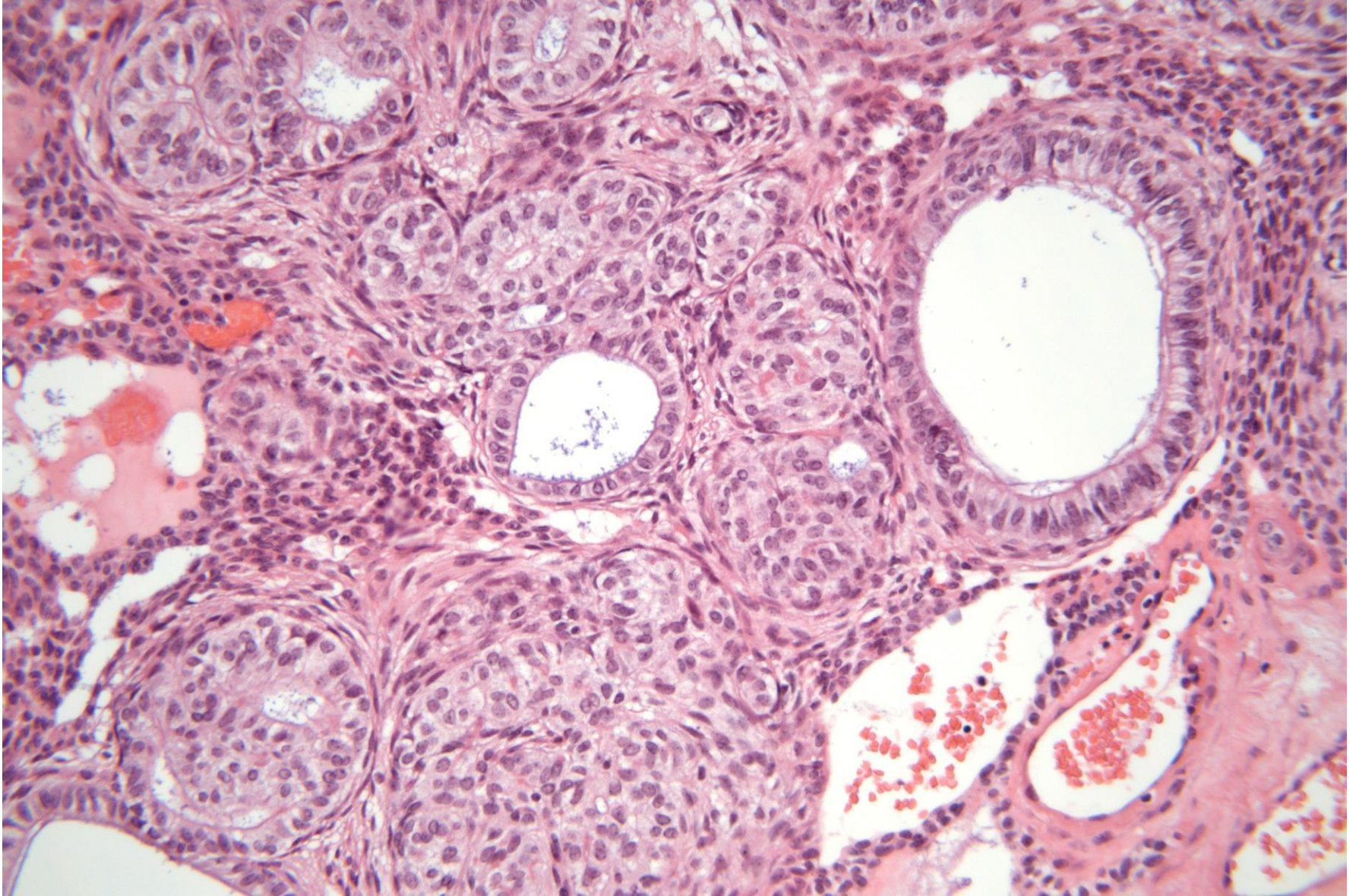


solid nodular masses of odontogenic epithelial cells forming nests arranged in a reduced conjunctival stroma

Adenomatoid odontogenic tumor



- tubular pattern similar to ducts inside solid areas, their lumen is free or contains eosinophilic material or cellular debris



- ductal-like structures are delimited by a single row of columnar epithelial cells, they represent pseudolumens created by the secretion of columnar cells.

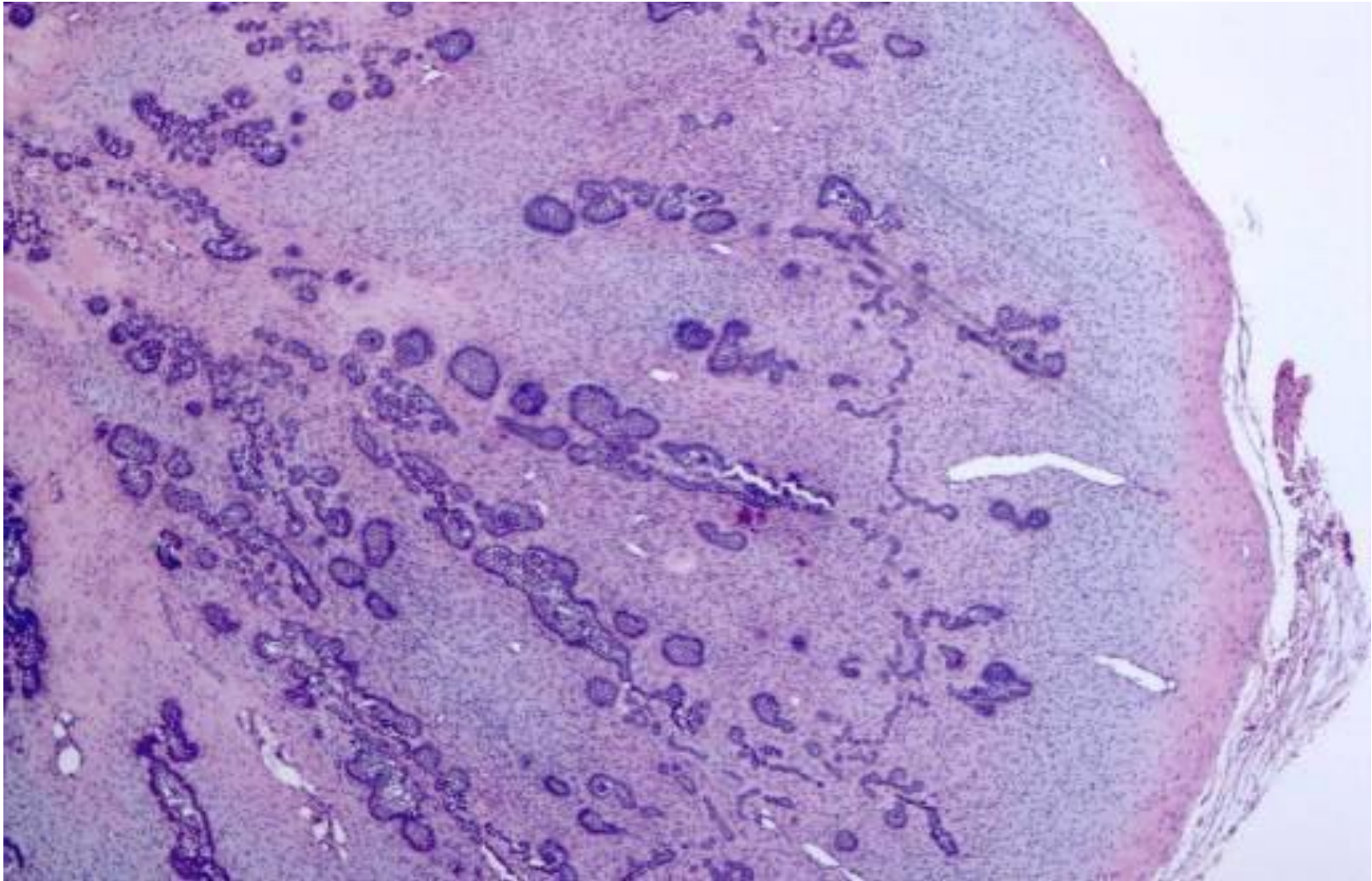
Ameloblastic fibroma

- Children and adolescents
- Molar region, mandible
- Well circumscribed
- Uni- or multilocular
- Relaps
- Has malignant potential (FSA)

Fibrom Ameloblastic

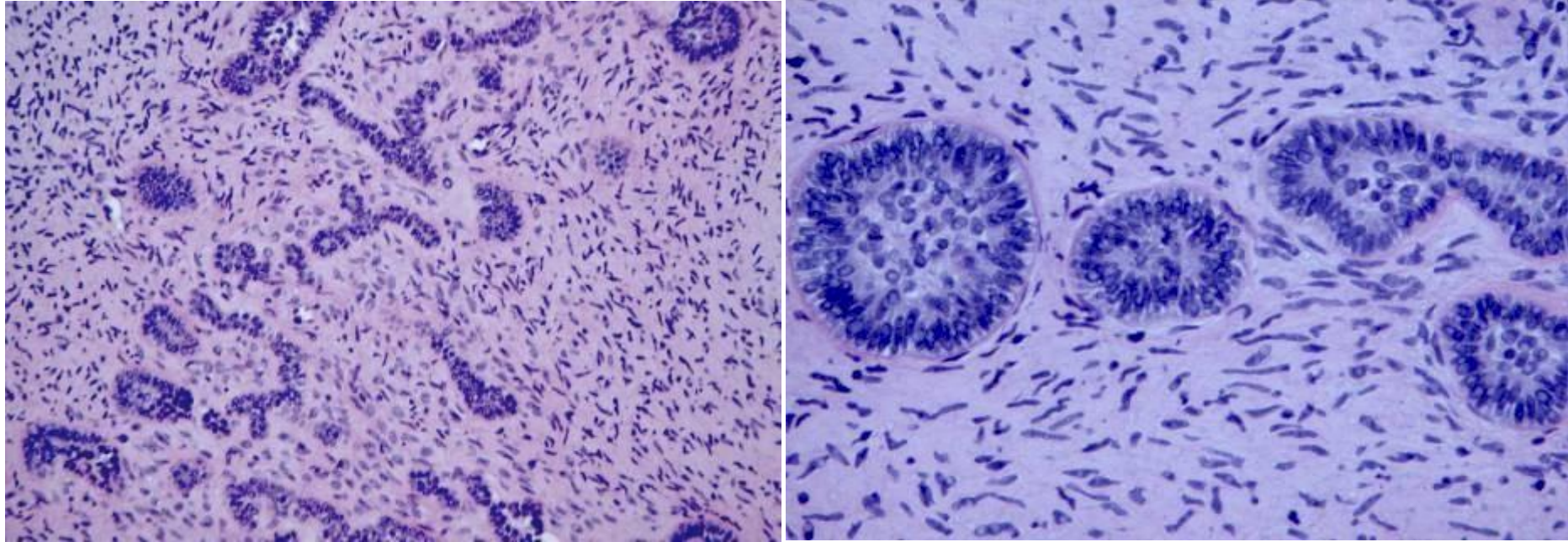
- Mezenchim odontogen asemănător papilei dentare
- Celule epiteliale asemănătoare laminei dentare și organul smalțului
- Nu sunt prezente structuri dure dentare.

Ameloblastic fibroma



- CE - branched and anastomosed cords that make loops

Ameloblastic fibroma



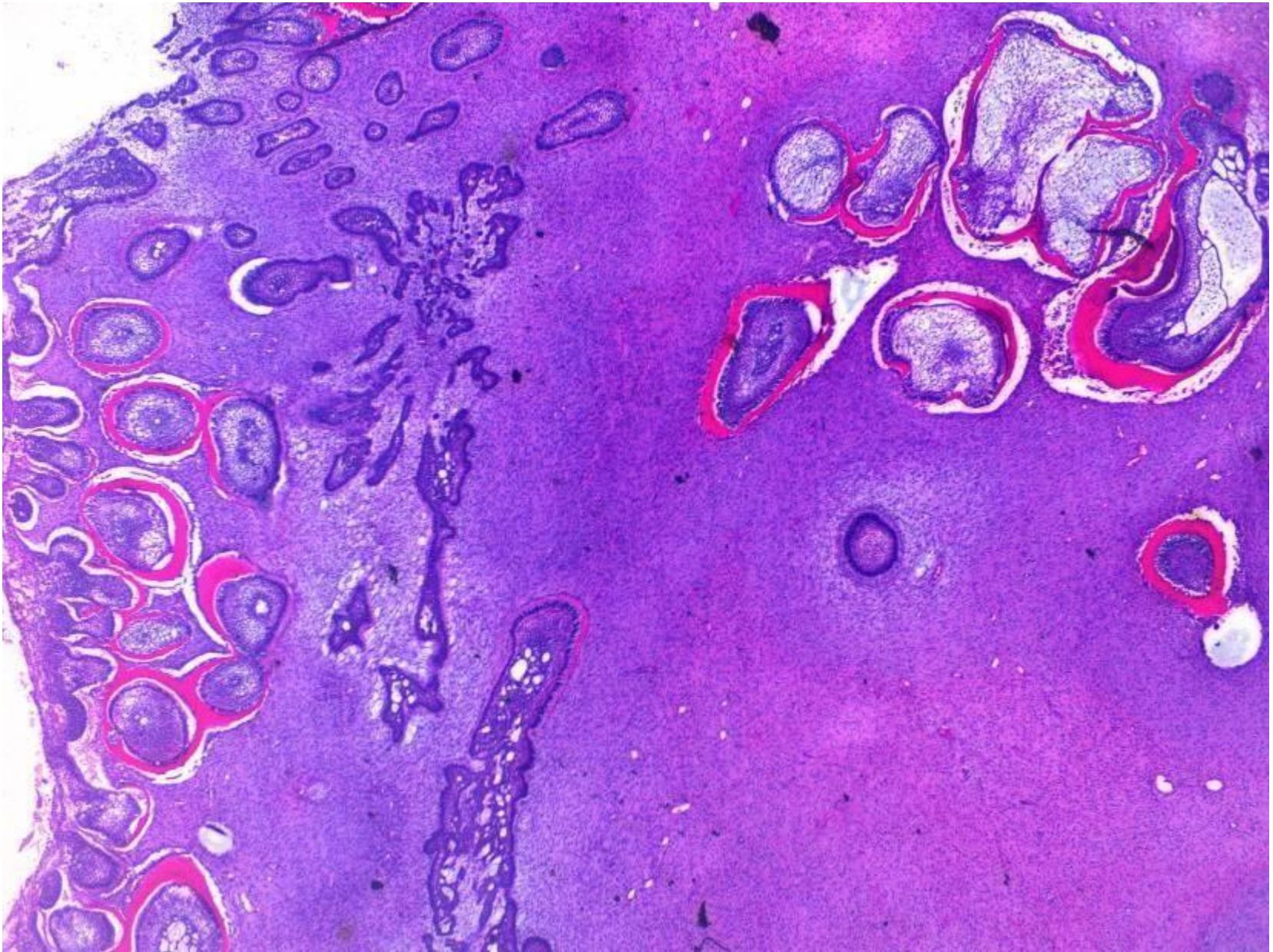
- EC - bilayered columnar cells with a morphology similar to the internal adamantine layer of enamel organ
- CM- densely cellular myxoid stroma, rich in fibroblasts with stellate morphology
- long and thin cytoplasmic extensions look similar to the ectomesenchyme dental papilla

(Ameloblastic Fibro-odontoma)

Now considered the early stage of the complex odontoma

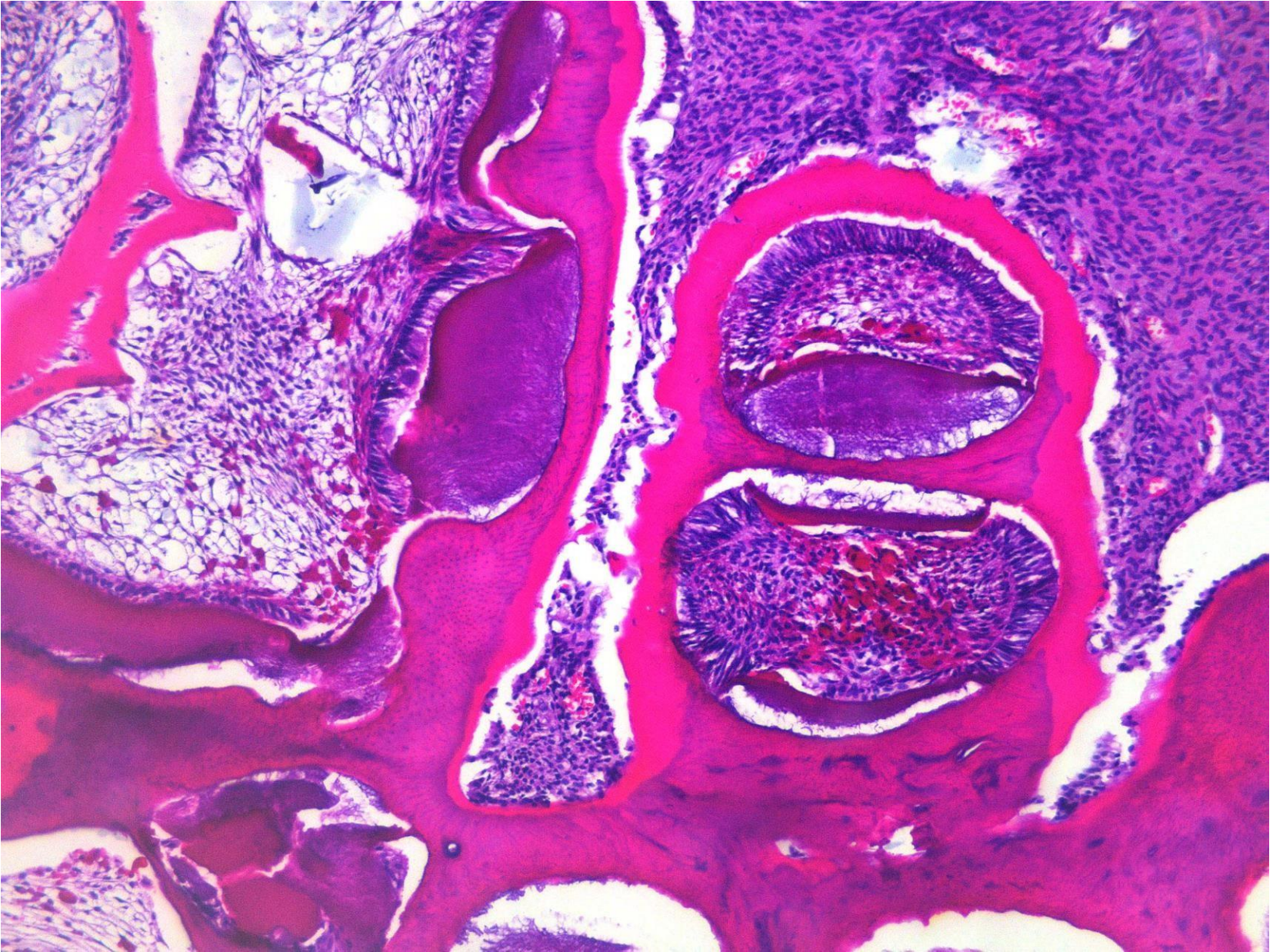
- It resembles ameloblastic fibroid, but has additional - dentin and enamel
- Frequently children (8 - 12 years)
- Often discovered due to an affected tooth
- Non-aggressive tumor
- Low recurrence rate

Ameloblastic fibro-odontoma



- Soft component similar to that of FA
- Hard component - hard dental structures

Ameloblastic fibro-odontoma

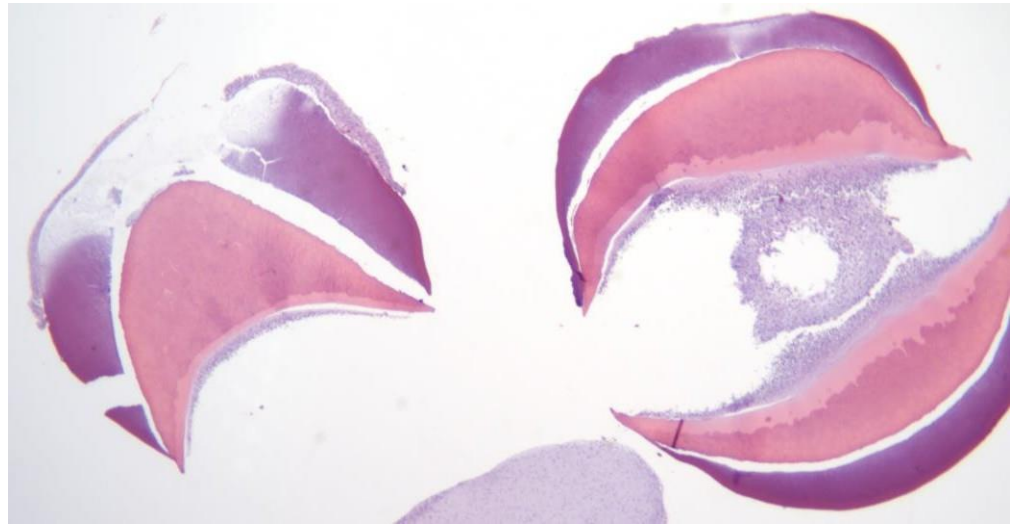
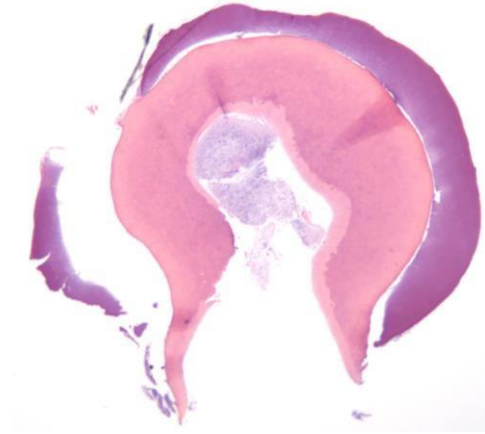
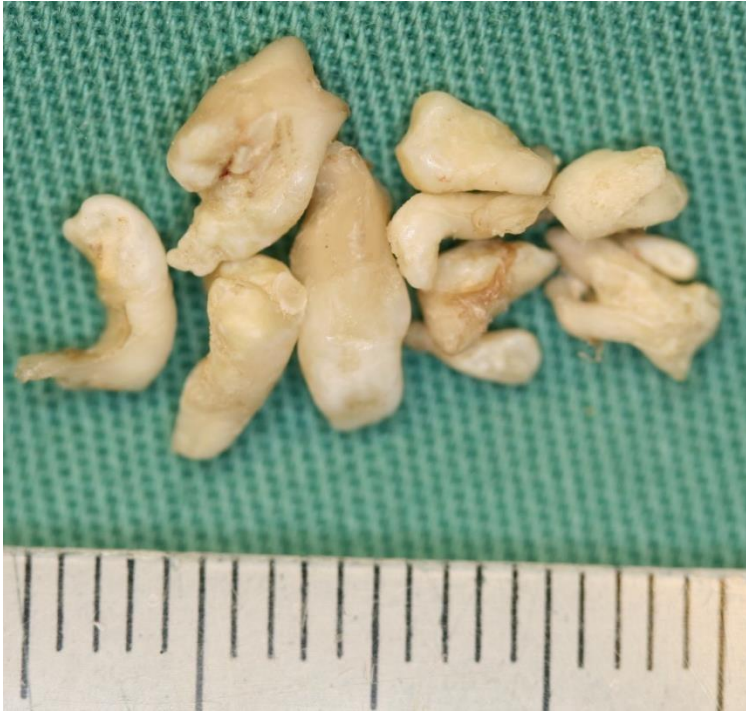

- The arrangement of hard structures reproduces the appearance of a complex odontoma

Odontoma

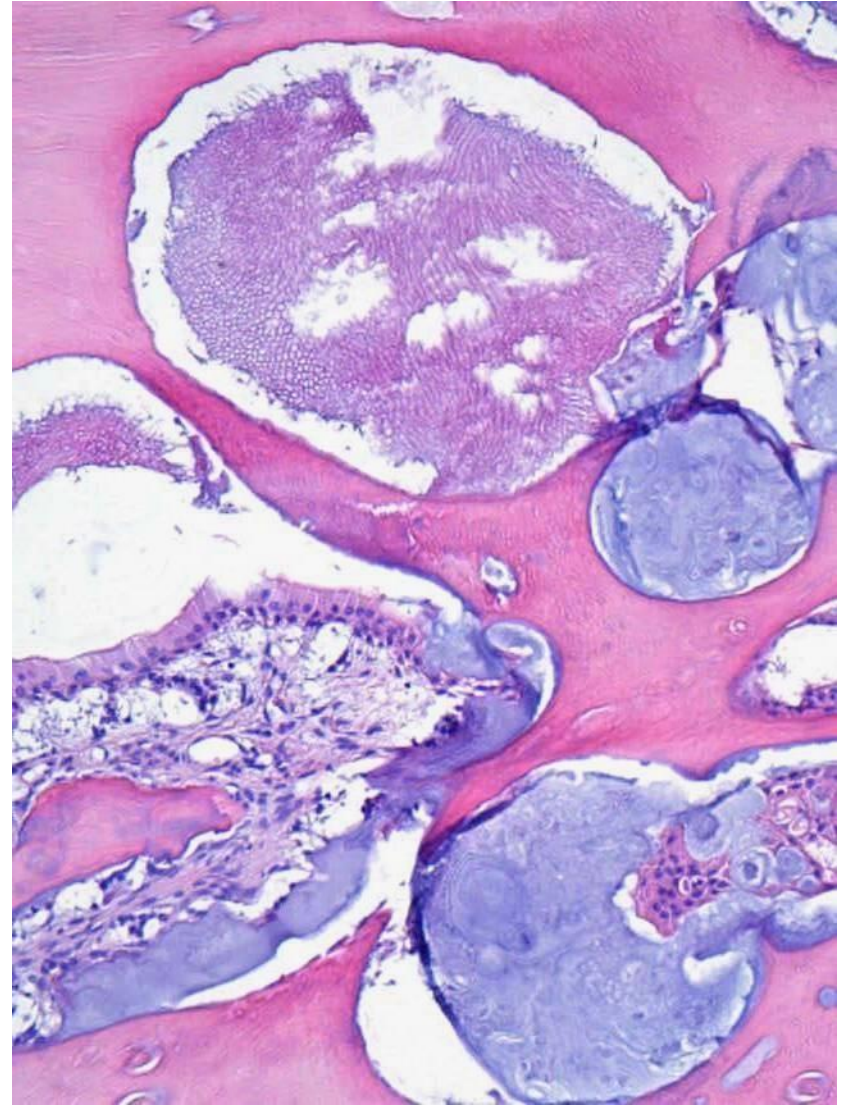
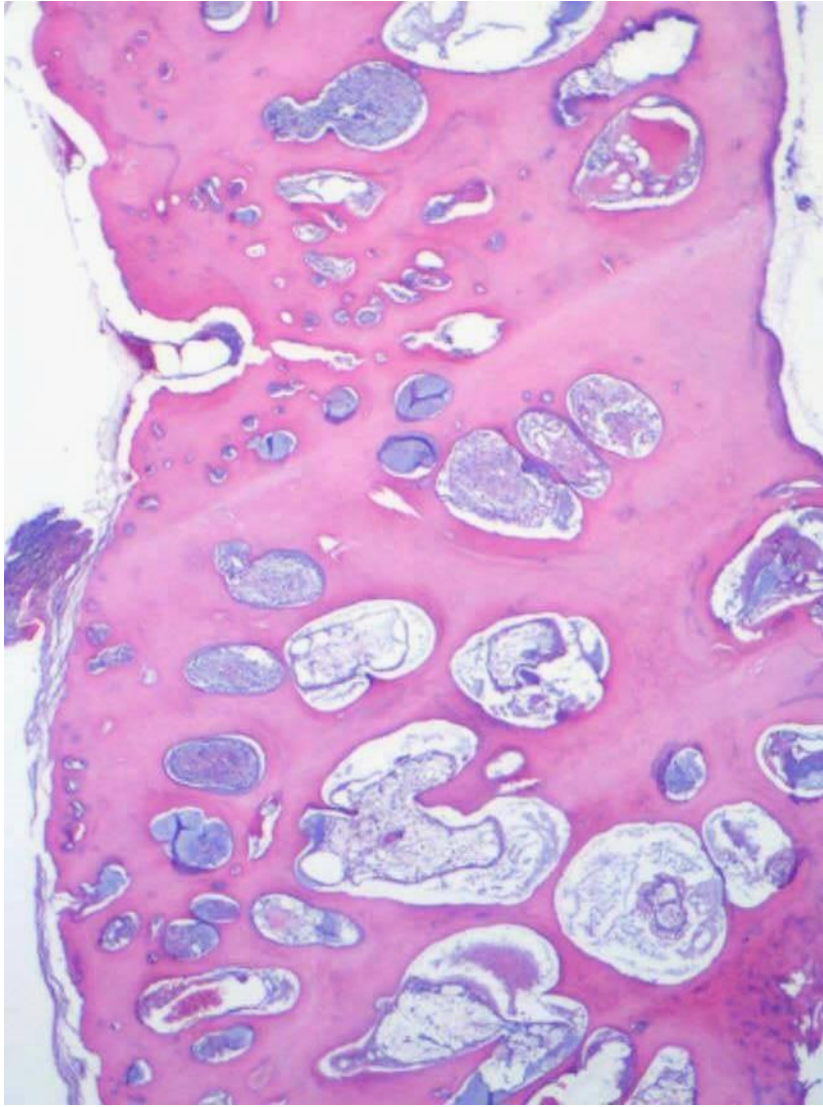
- Children and adolescents
- Compound: anterior maxilla
- Complex: posterior mandible
- Soft tissue capsule inside the cortical bone
- Hamartoma?

Compound Odontoma



- Dental buds placed in a loose connective tissue

Complex odontoma

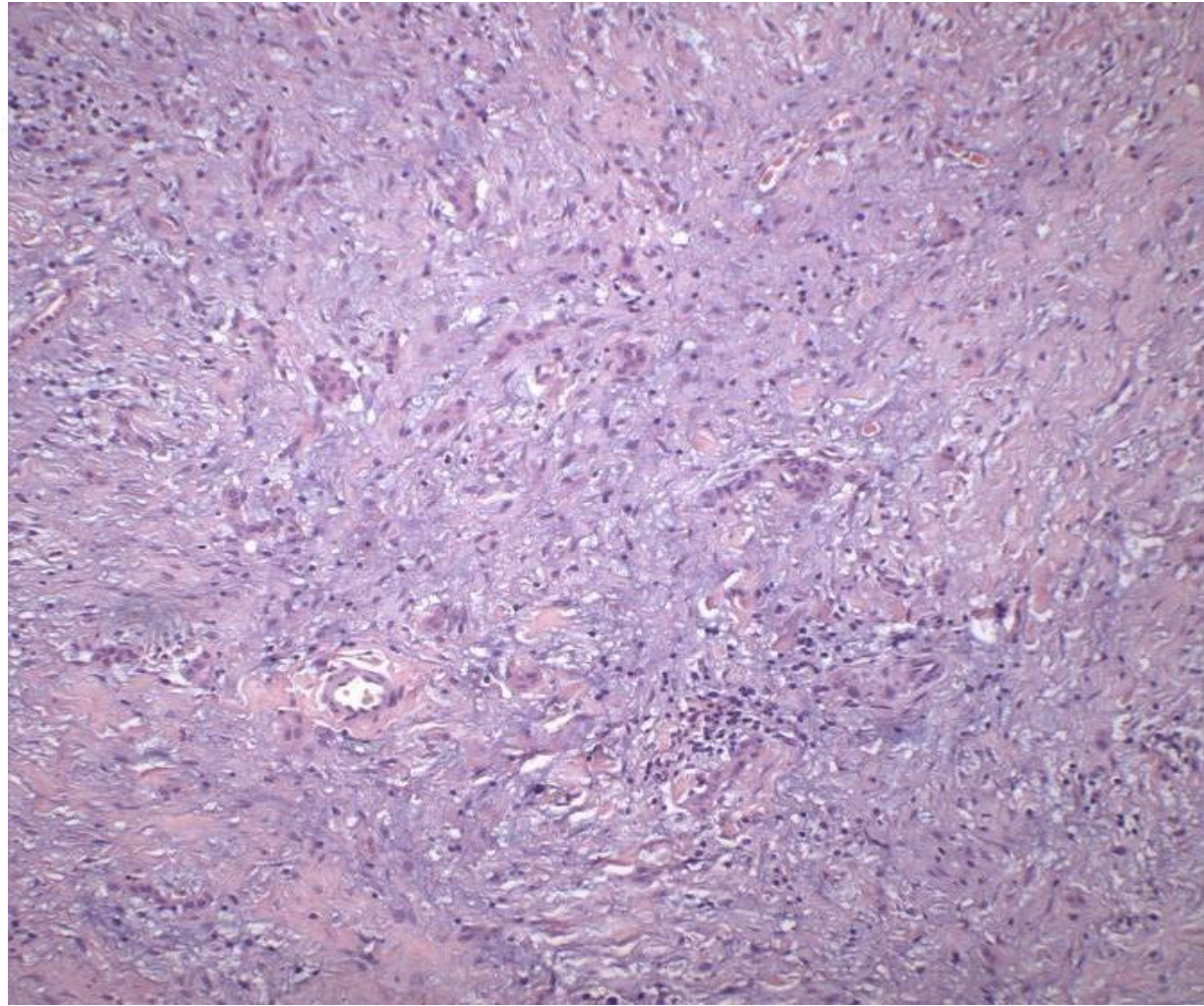
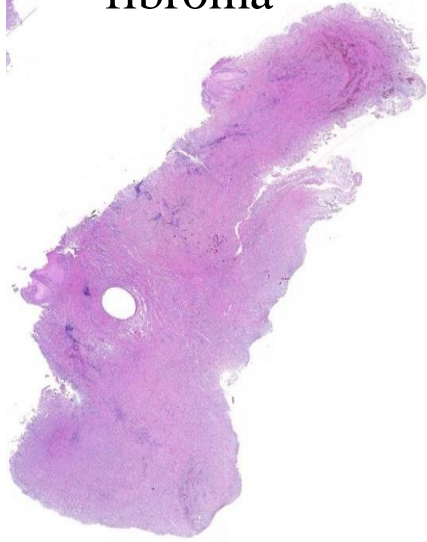

- Never perform the histoarchitecture of a normal tooth
- walls of dystrophic or tubular dentin covered with enamel.

Odontogenic fibroma

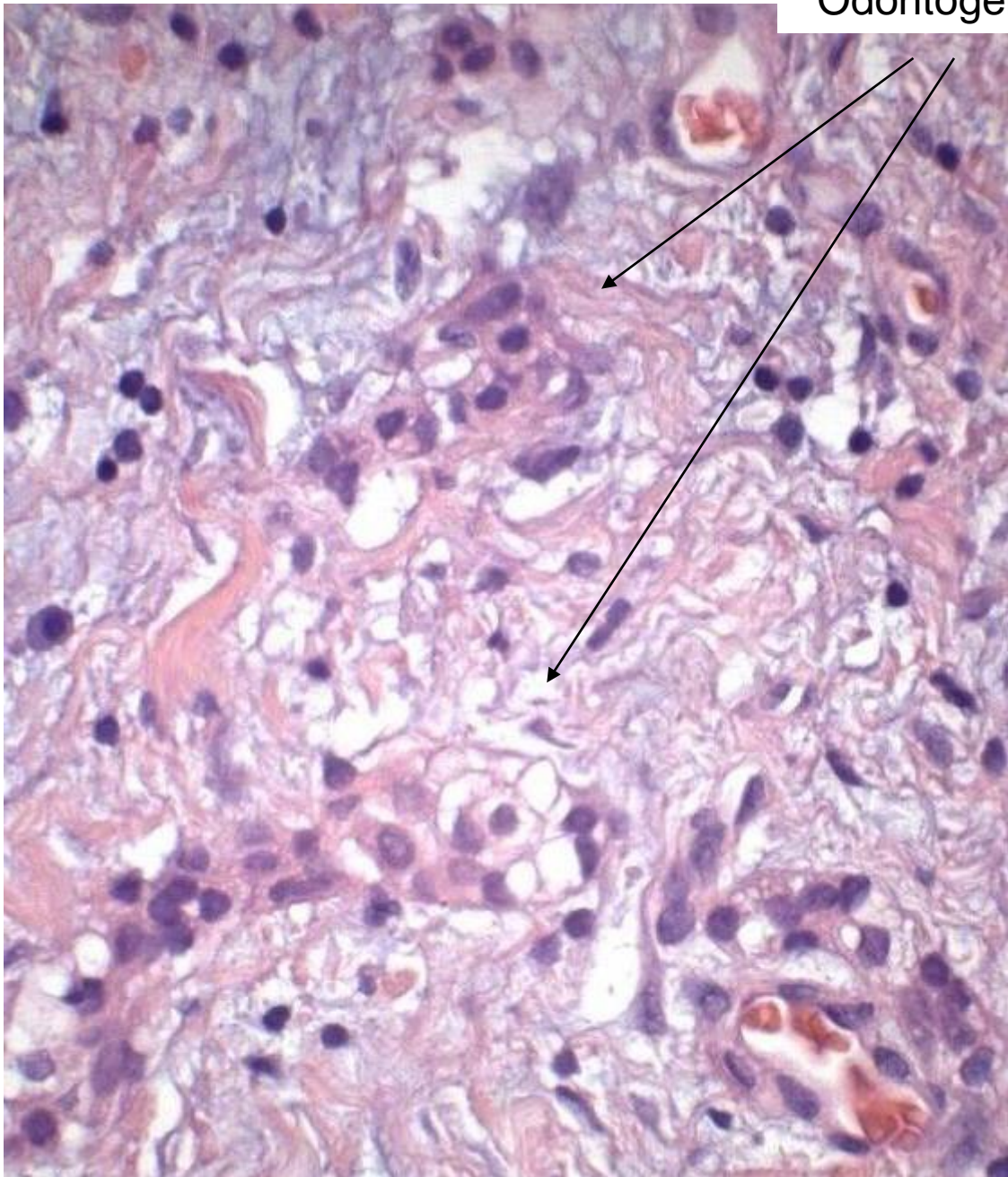
- rare
- Consisting of inactive odontogenic epithelium arranged in a mature fibrous stroma
- It can be intra- or extraosseous
- Periodontal ligament - rich epithelial variant
- Dental follicle - poor epithelial variant
- It rarely recurs

Odontogenic fibroma

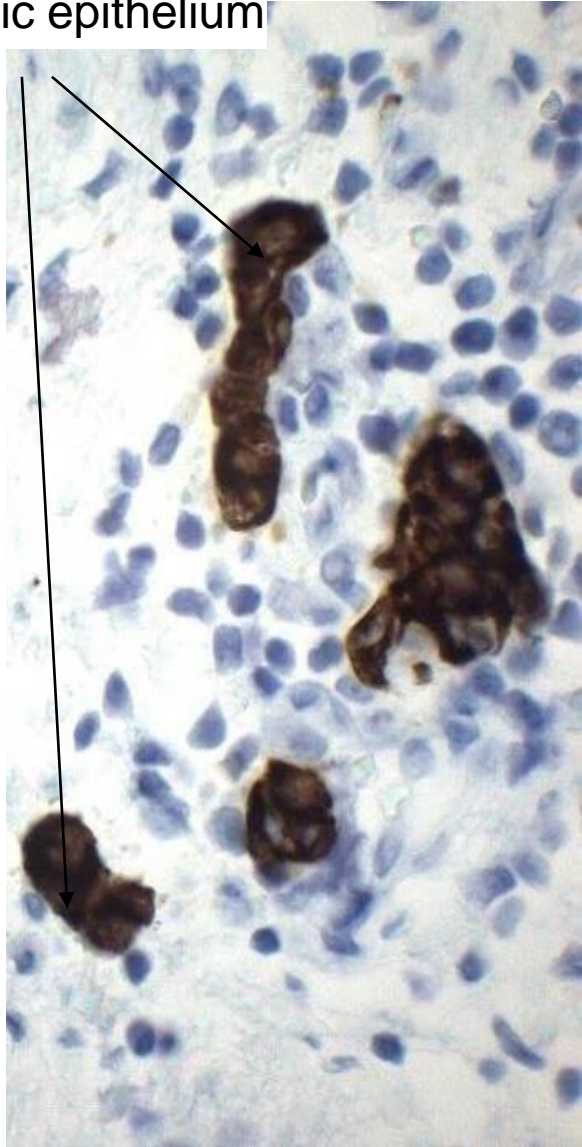


- Poor epithelial variant - non-infiltrative connective tissue similar to dental follicle, inactive islands of odontogenic epithelium
- Weaving. conj. with stellate fibroblasts, and a considerable amount of fundamental substance which creates the appearance of a mixoid background

Odontogenic fibroma



Odontogenic epithelium



Cytokeratin staining

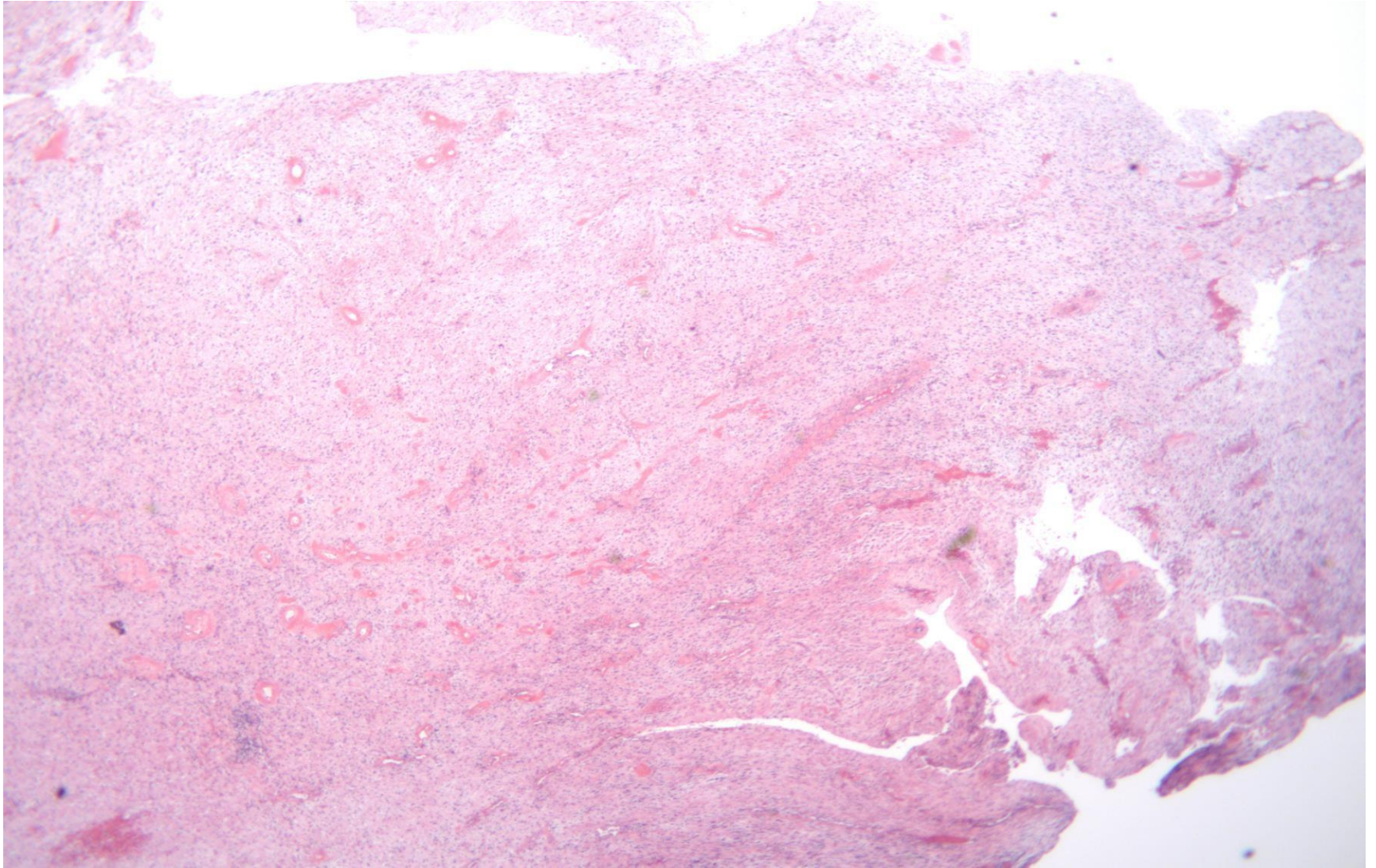
Odontogenic mixoma

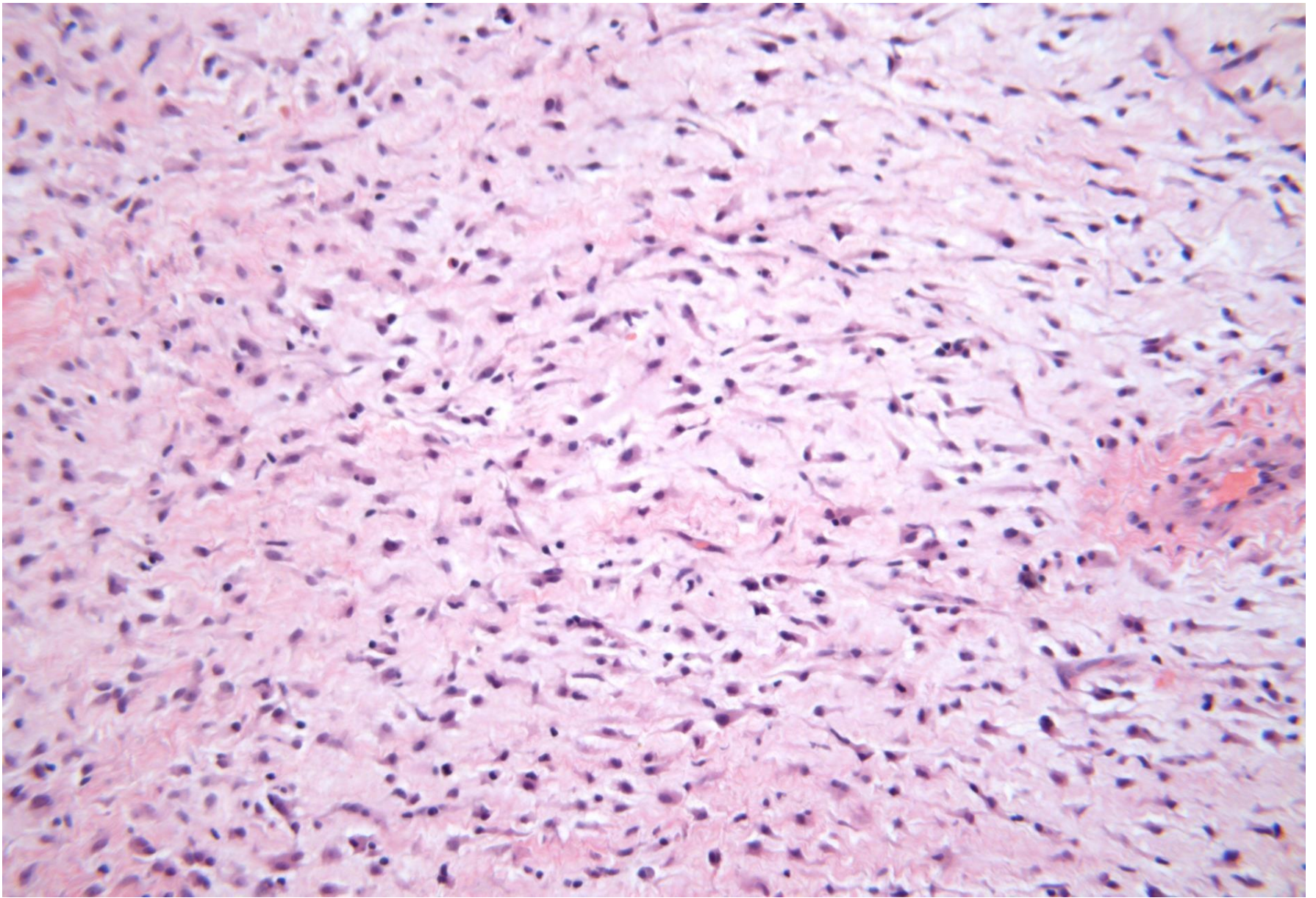
- Young adults, 3-20% of odontogenic tumor
- Premolar-molar area
- Three times more often in the mandible
- Well demarcated, like the cyst when small
- Multilocular for honeycomb magnification

Odontogenic mixoma

- It moves and can resorb the tooth
- It develops from modified fibroblasts that produce an excessive amount of GAG that inhibits glycogen polymerization
- Invades the medullary spaces of the maxillary bones
- Recurrences after excision are common

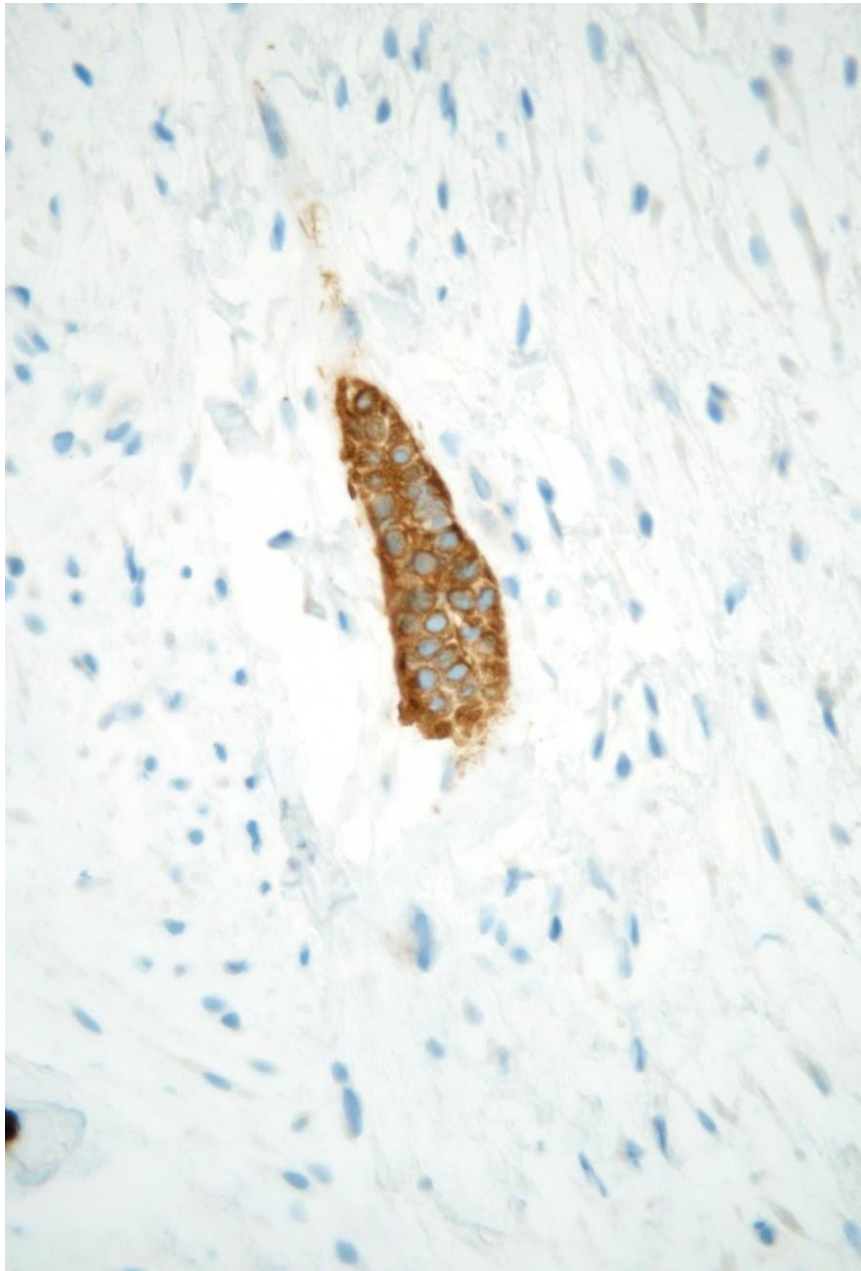
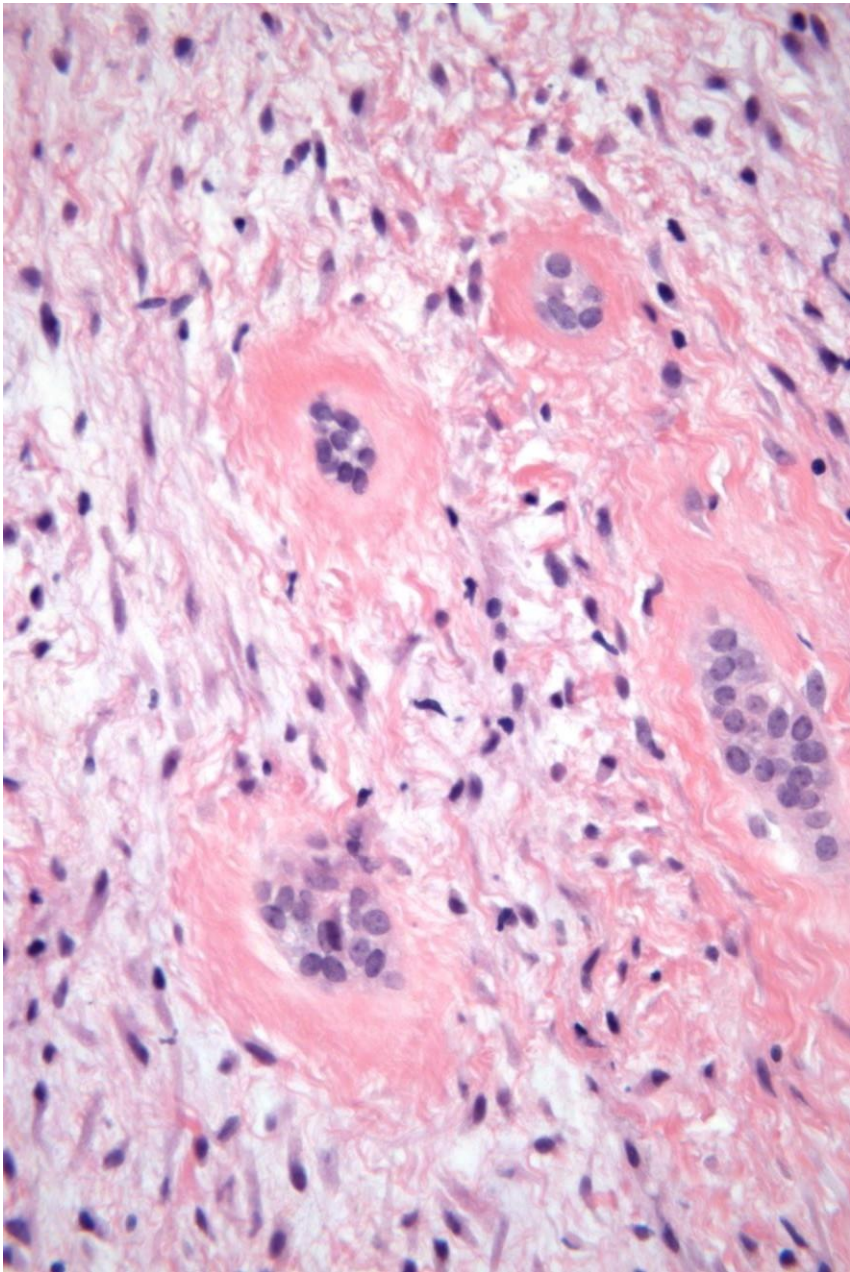
Odontogenic mixoma





- stellate cells with a central nucleus and eosinophilic cytoplasmic extensions
- myxoid stroma containing unique collagen fibers

Odontogenic epithelium, confirmed by staining with cytokeratin

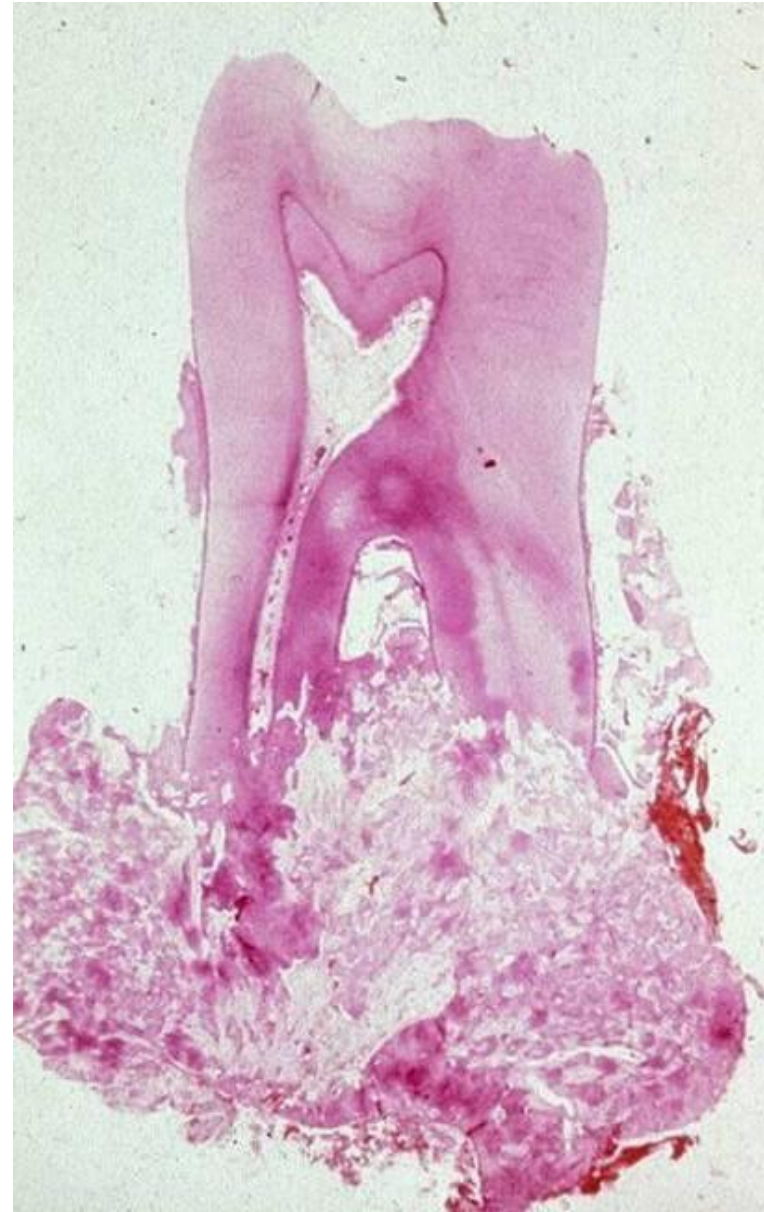
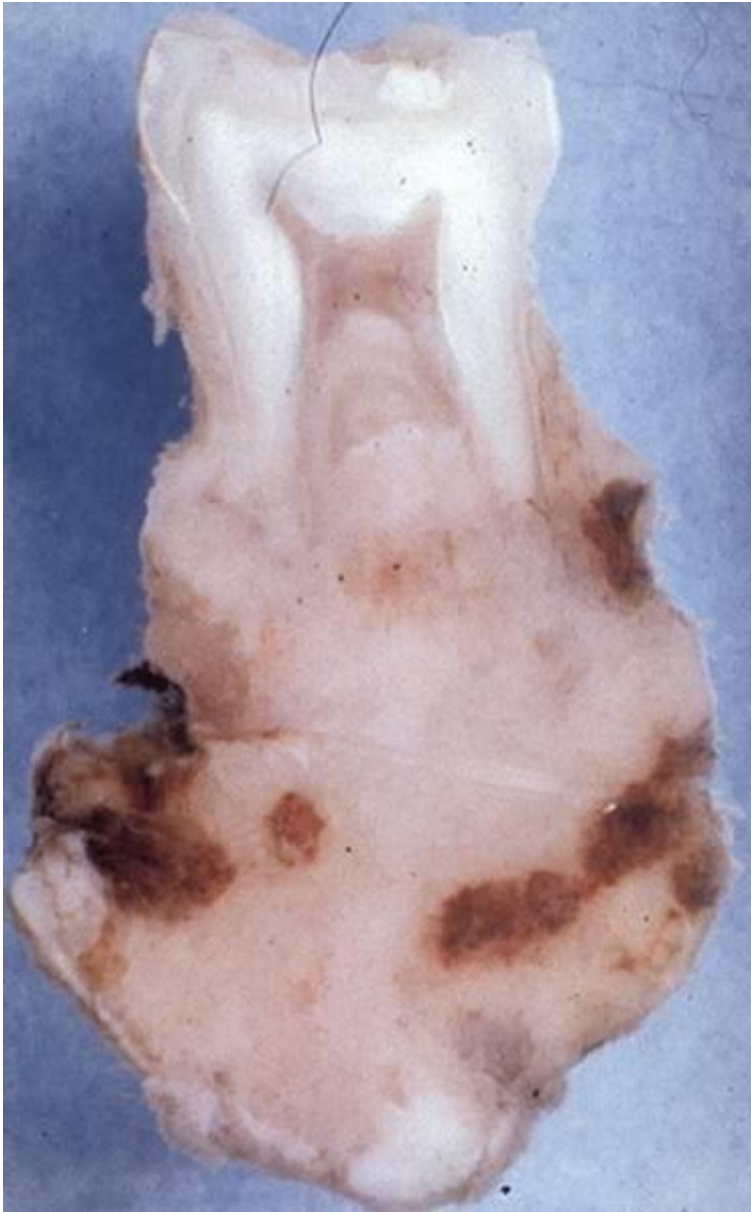
- odontogenic epithelial nests

Cementoblastoma

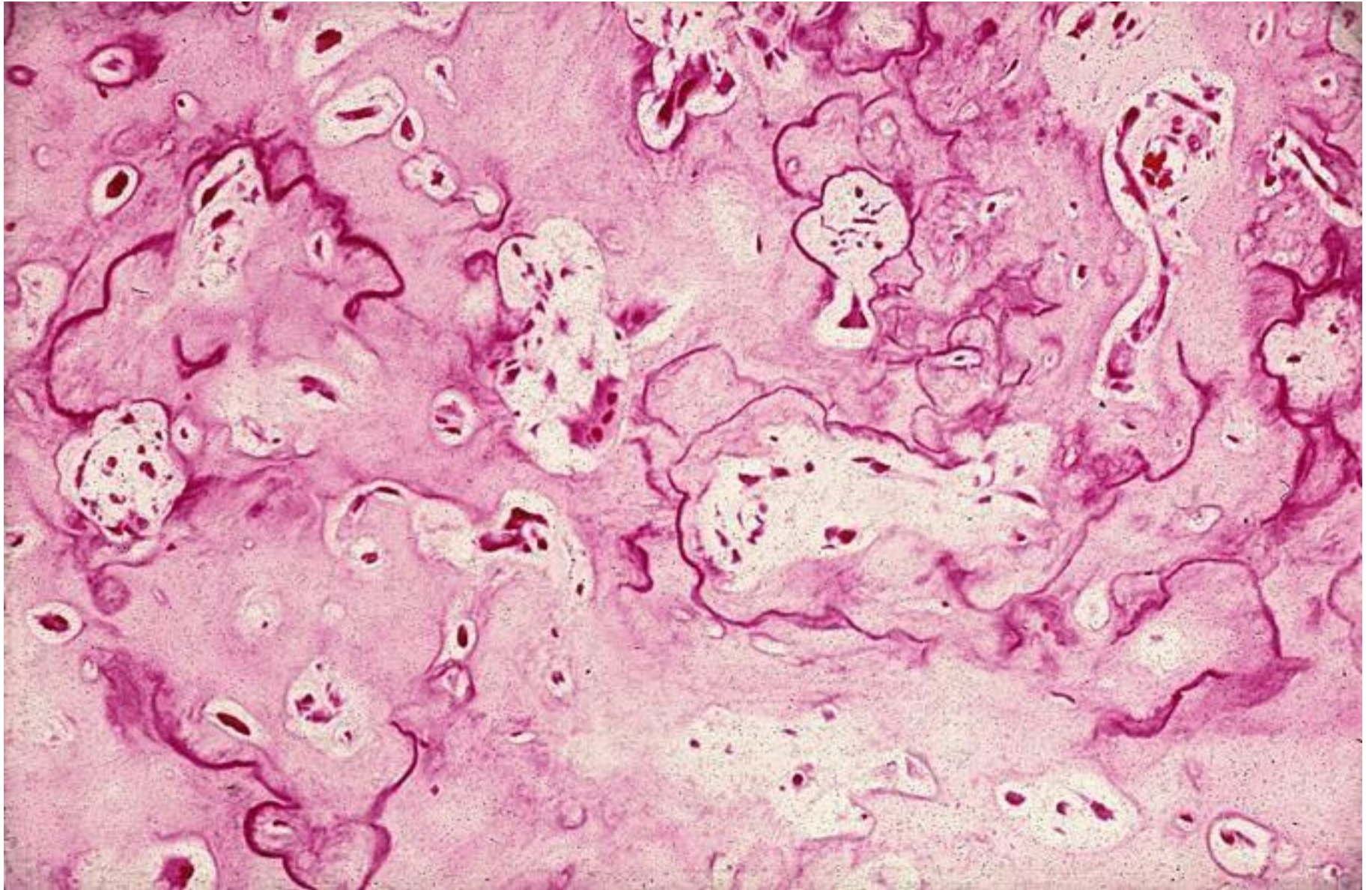
- Young adults, relatively rare
- Radiopac with radiolucent demarcation
- Mandible
- The root of the premolar or first molar
- It absorbs the tooth and the bone
- Diffuse pain may be associated
- Rare recurrence

Benign cementoblastoma



- the tumor mass fuses with the root of the tooth, producing a resorption of it

Benign cementoblastoma

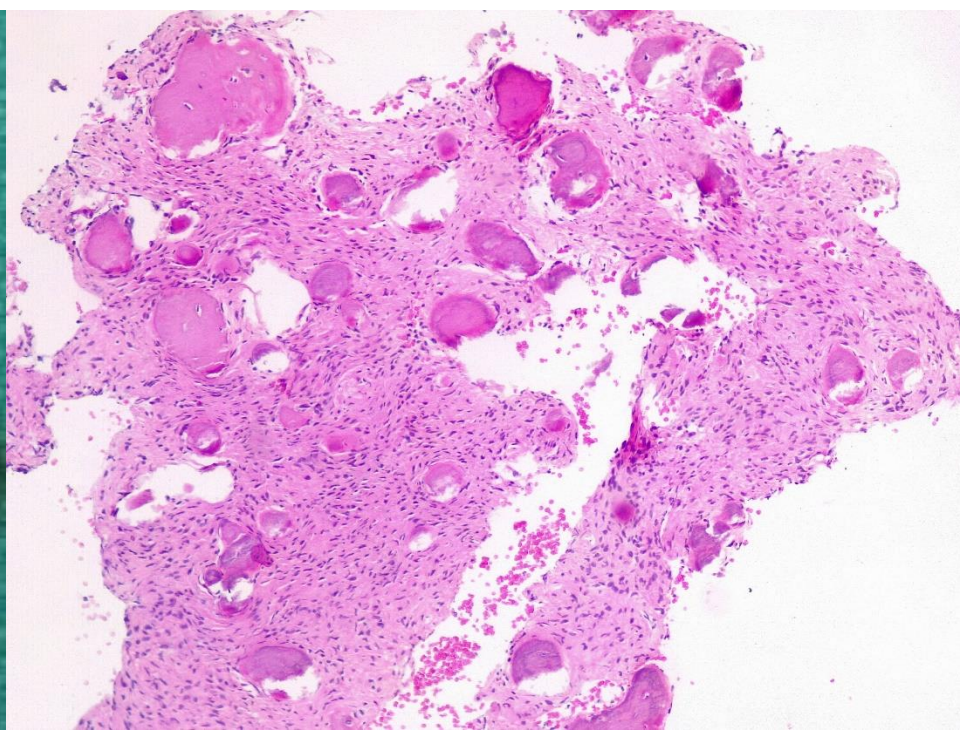
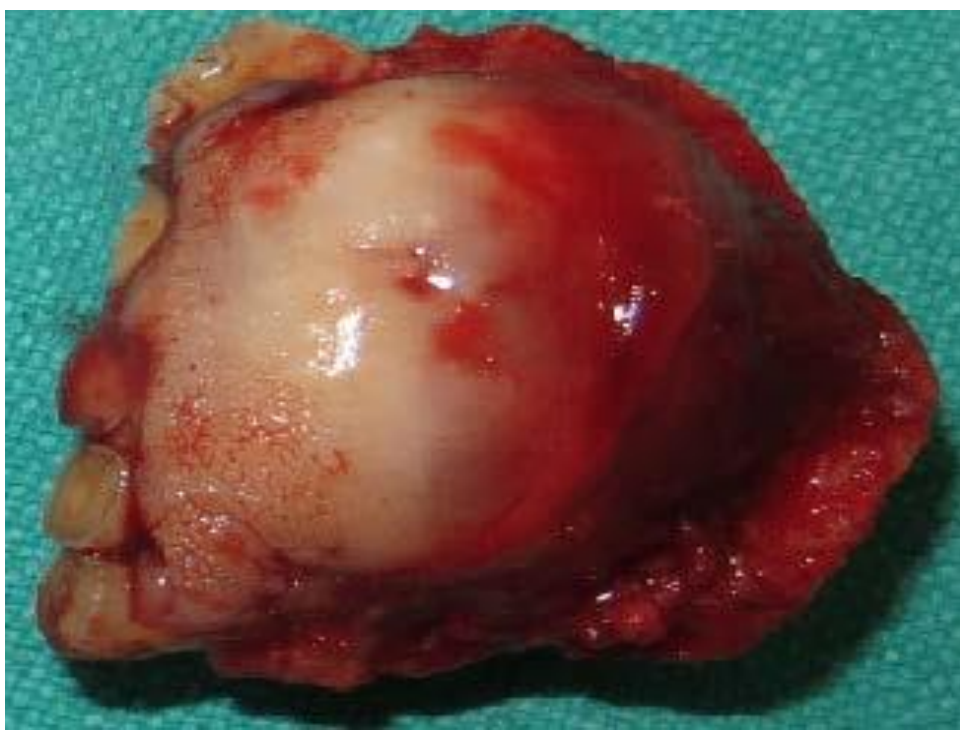

- dense masses of cement-like material arranged in a fibrous stroma

Cemento-ossifying fibroma

- Made of fibrous fabric and mineralized material similar to cement
- Rare recurrences
- Mandible
- Well demarcated with smooth contour hard consistency
- Different stages of osteoid and cement deposition

Cemento-ossifying fibroma



- Irregular calcified proliferations in a stroma of hypercellular connective tissue
- Basophilic colored immature cement
- Eosinophilic colored osteoid