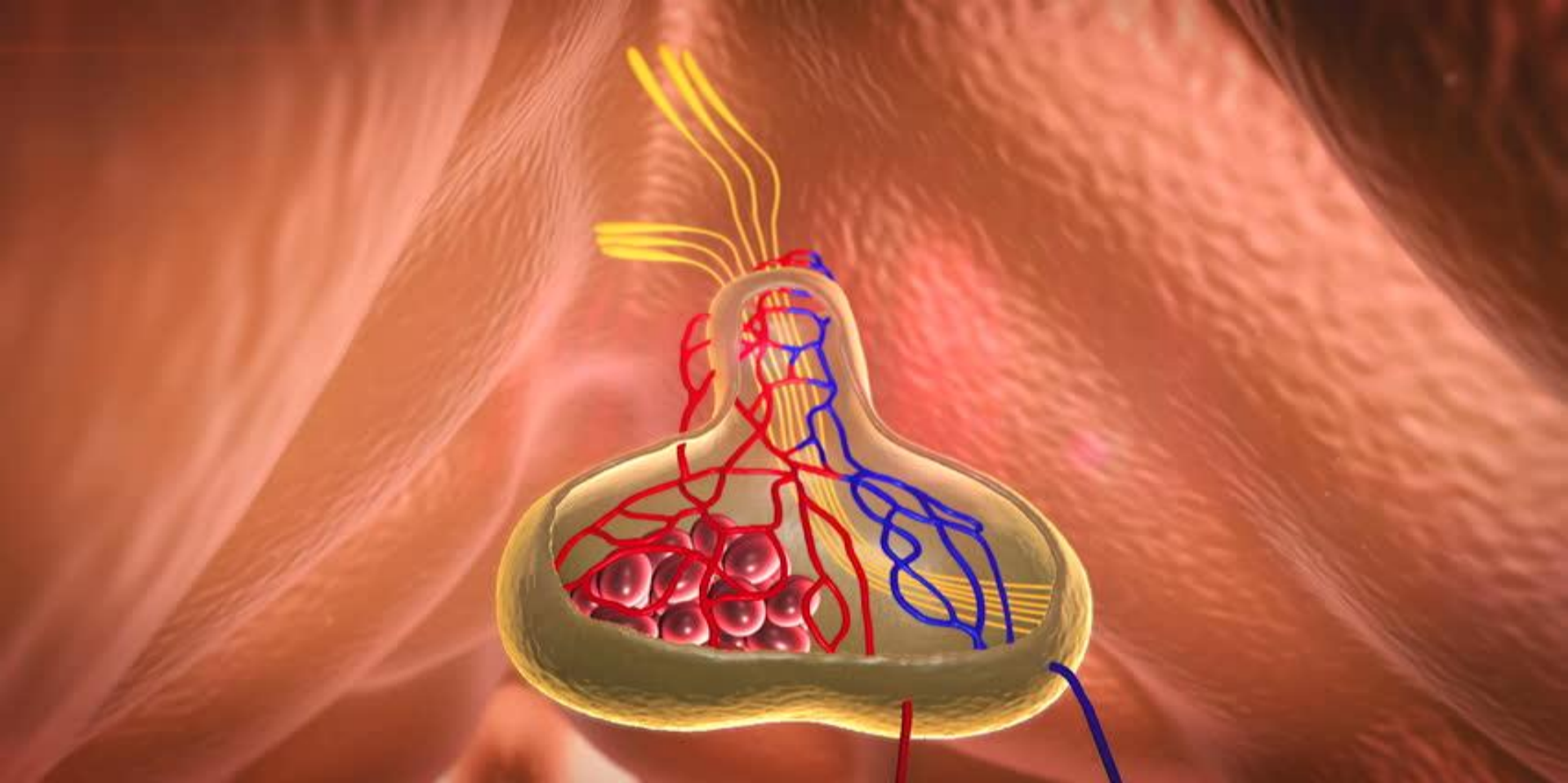

**Endocrine glands pathology.**

## Endocrine glands pathology.

### *I. Microspecimens:*

**№ 132. Colloid goiter.** (*H.E. stain*).

#### **Indications:**

1. Follicles are dilated and increased in size .
2. Masses of colloid in the lumen of the follicles.

Most thyroid follicles are enlarged in size, dilated, cysts-like, the epithelium is flattened, colloid is intensely stained.

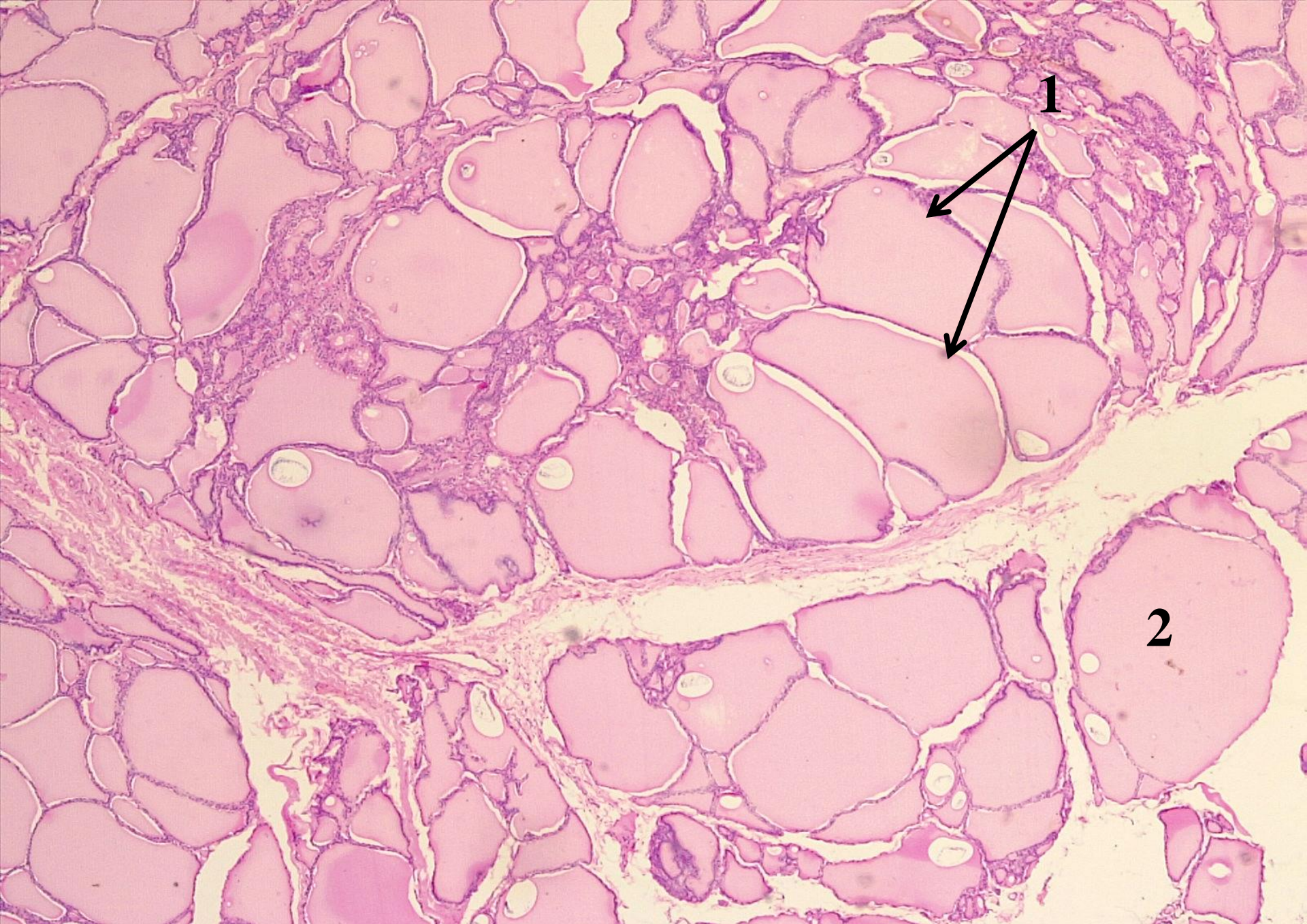
**№ 115. Toxic diffuse goiter (Grave's disease).** (*H.E. stain*).

#### **Indications:**

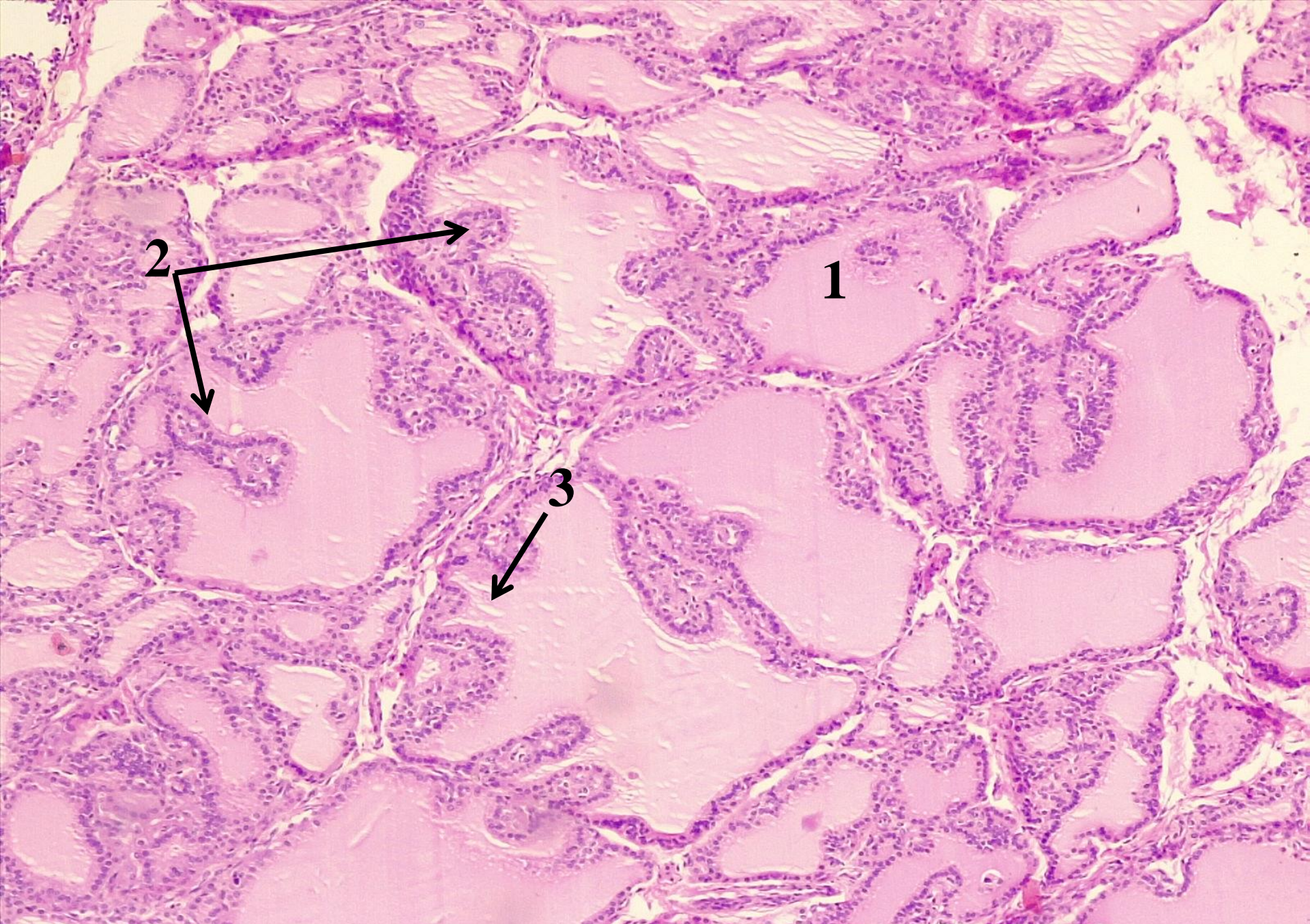
1. Distorted follicle.
2. Proliferation of follicular epithelium with formation of papillary structures.
3. Weakly stained colloid with vacuolization.
4. Lymphocytic infiltration of the stroma.

The follicles are deformed with branched papillary projections, which fill the lumen of some follicles, the epithelium is high, cylindrical, the colloid is weakly colored (pale pink) and vacuolized. In the interfollicular stroma, lymphocyte infiltration is determined, in some areas lymphoid follicles with germinal centers.

*Thyrotoxicosis is clinically manifested by tachycardia, cardiac arrhythmias, nervousness, irritability, excessive sweating, exophthalmia, diarrhea and weight loss.*



**№ 132. Colloid goiter. (H.E. stain).**



**№ 115. Toxic diffuse goiter (Grave's disease). (H.E. stain).**

**№ 210. Corticotroph (basophilic) adenoma of hypophysis.** (*H.E. stain*).

**Indications:**

1. Tumoral cells with basophilic cytoplasm.
2. Hemorrhages in the tumor stroma.

Section from a tumor nodule, consisting of groups of monomorphous cells with basophilic colored cytoplasm, well contoured nuclei, in stroma multiple hemorrhagic foci are observed.

*Corticotroph pituitary adenoma is clinically manifested by ACTH hypersecretion and ACTH-dependent Cushing's syndrome. Tumors can exert local tumor compression with neurological signs and symptoms (mass effect).*

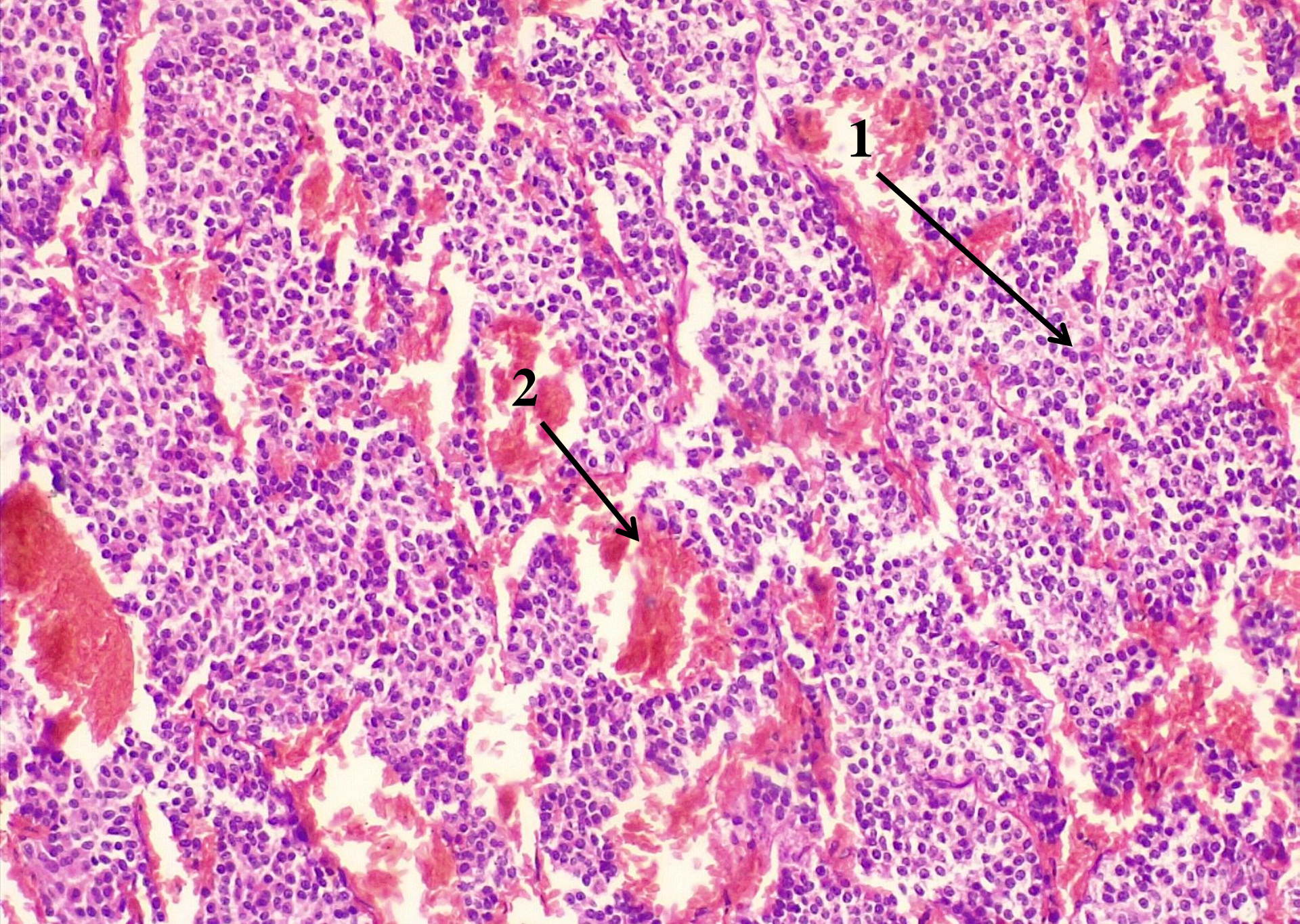
**№ 14. Pheochromocytoma.** (*H.E. stain*).

**Indications:**

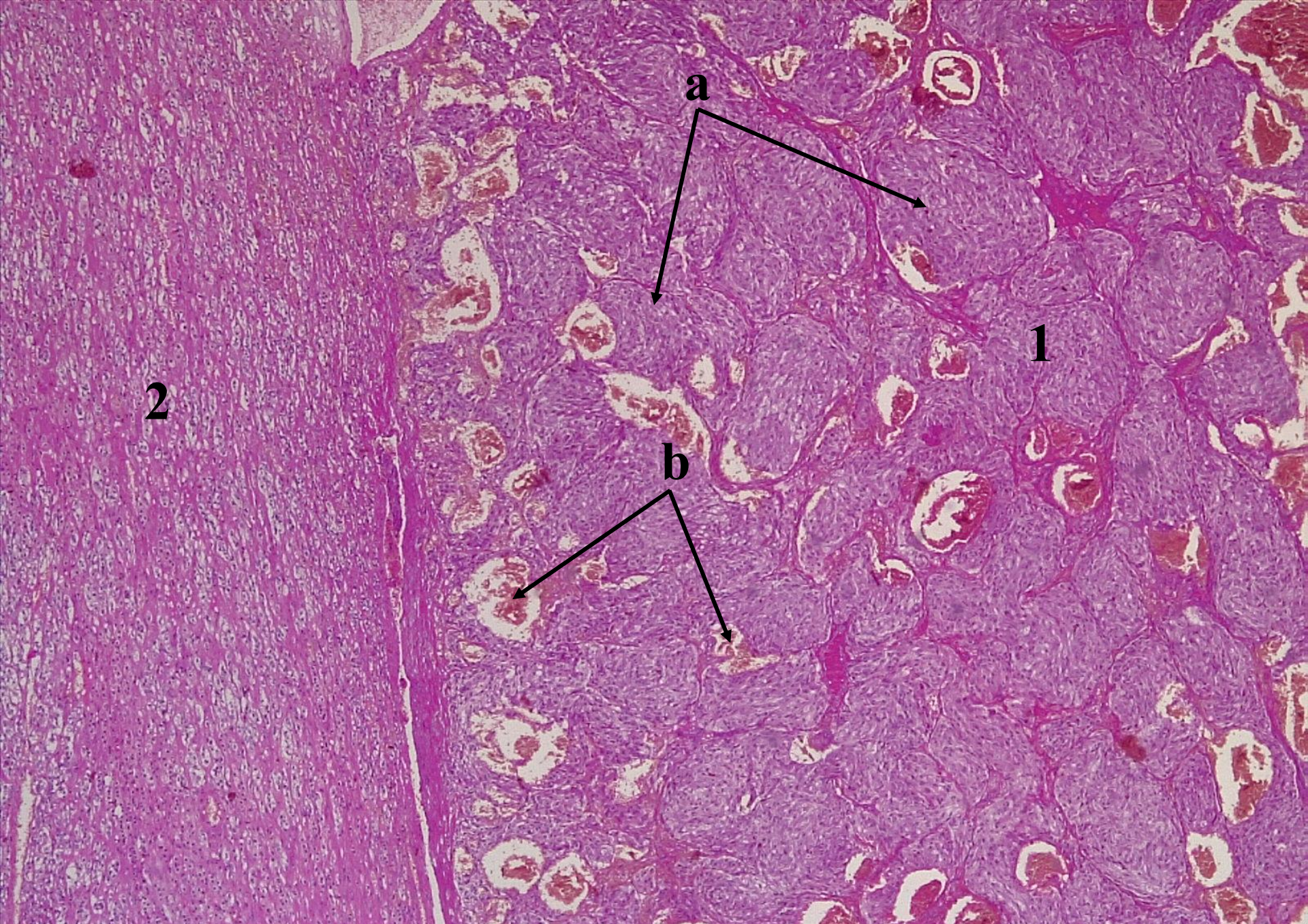
1. Tumor nodule:
  - a. nests of tumor cells;
  - b. rich vascular network.
2. Adrenal cortex.

Section from a well-delimited tumor nodule, consisting of nests / islands of polymorphic cells with clear cytoplasm, separated by thin bundles of connective tissue with multiple dilated, hyperemic blood vessels, the adjacent cortical tissue is intact.

*Pheochromocytoma secretes large amounts of catecholamines (adrenaline and noradrenaline) and is clinically manifested by secondary hypertensive syndrome.*



**№ 210. Corticotroph (basophilic) adenoma of hypophysis. (H.E. stain).**



**№ 14. Pheochromocytoma. (H.E. stain).**

**№ 224. Diabetic nodular glomerulosclerosis. (H.E. stain).**

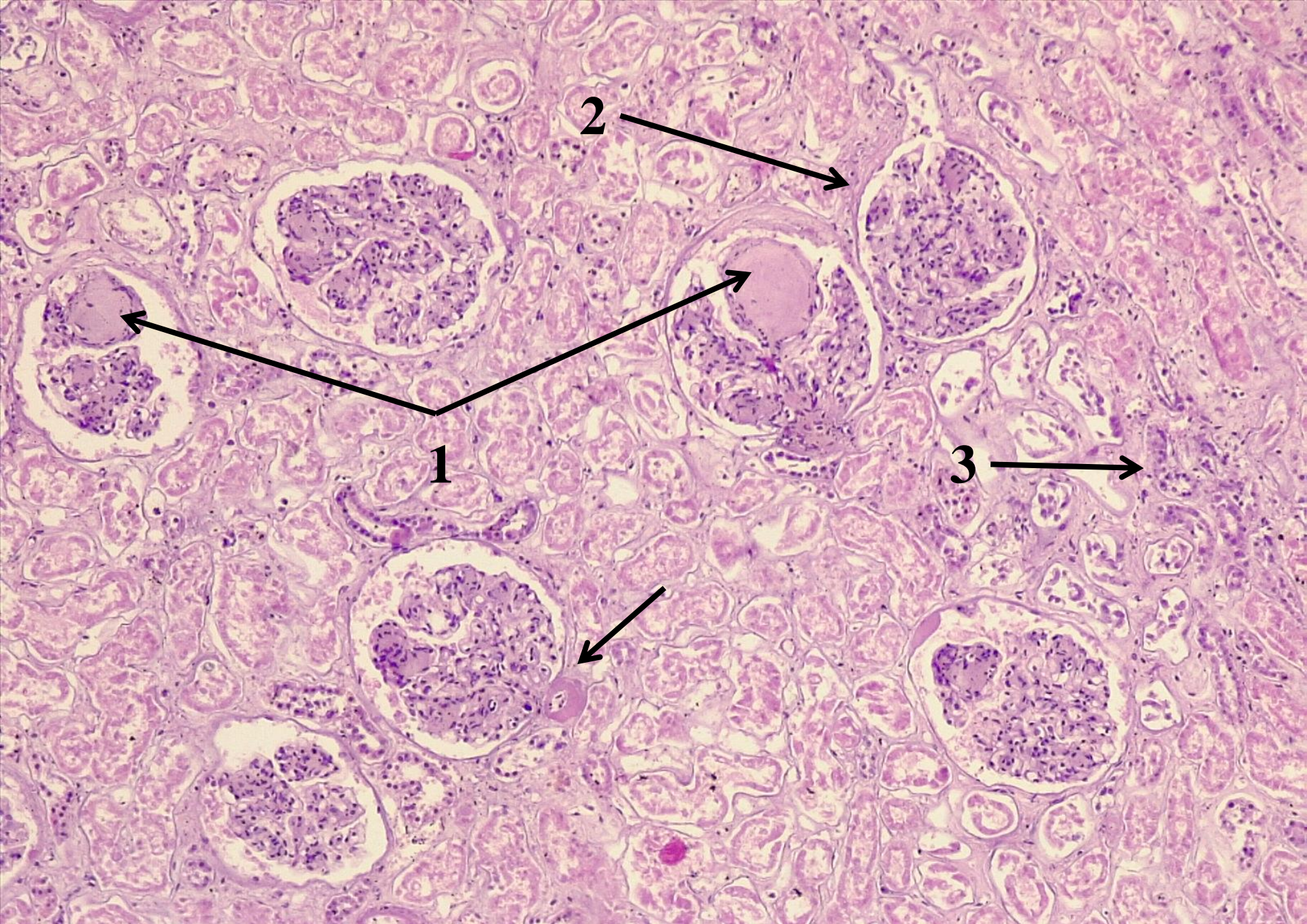
**Indications:**

1. Foci of sclerosis and hyalinosis of renal glomerulus.
2. Unchanged glomerulus.
3. Convoluted tubes.

In the cortical kidney tissue there are glomeruli with foci of sclerosis and hyalinosis of homogeneous eosinophilic color, the walls of the arterioles are thickened, hyalinized (diabetic microangiopathy), the cytoplasm of the nephrocytes of convoluted tubules has a granular appearance, pale nuclei (protein degeneration), in the lumen of some tubules eosinophilic protein masses are observed, the straight tubules are unchanged.

*Diabetic nodular glomerulosclerosis is the morphological substrate of Kimmelstiell-Wilson syndrome, which is clinically manifested by pronounced proteinuria, edema and hypertension.*





**№ 224. Diabetic nodular glomerulosclerosis. (H.E. stain).**

## ***II. Macrospecimens:***

### **№ 132. Colloid goiter.**

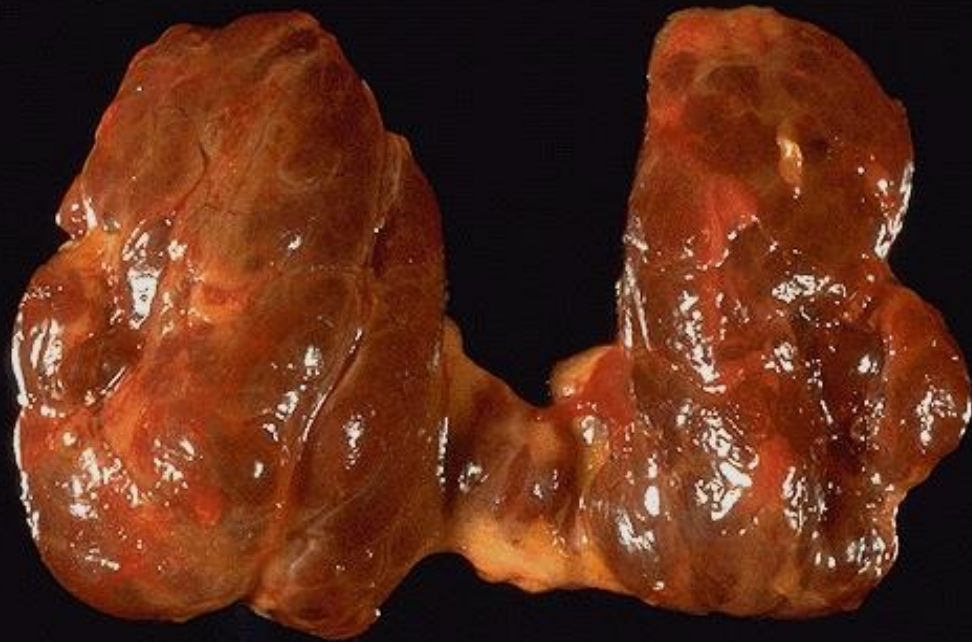The thyroid gland is enlarged in size, on section nodules with microcystic structure are observed, with rich gelatinous colloid content of brown color.

*The main cause of colloid goiter is iodine deficiency in diet. The clinical effects are manifested by the compression of the adjacent cervical organs, which can cause airway obstruction, dysphagia, compression of the large vessels of the neck and upper portion of the thorax (superior vena cava syndrome).*

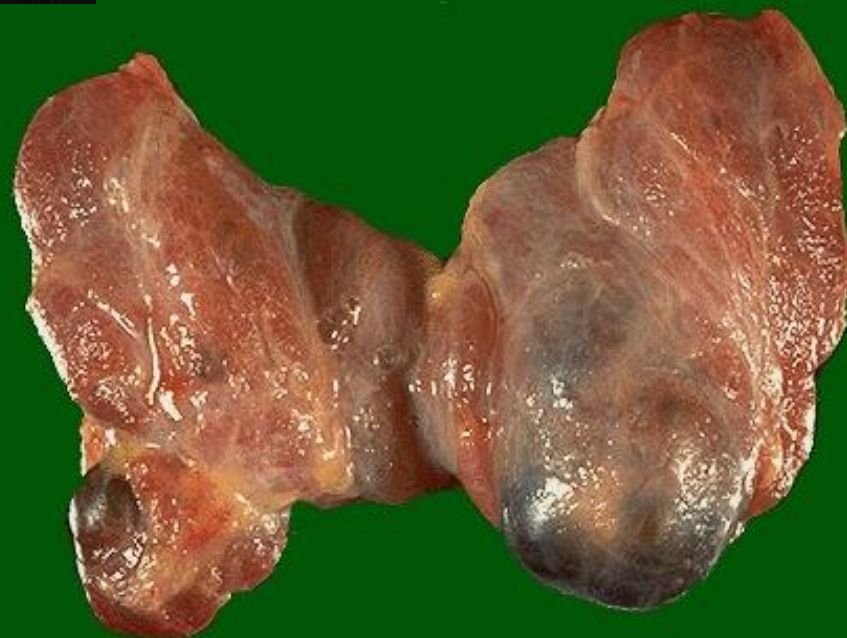### **№ 133. Adrenocortical adenoma.**

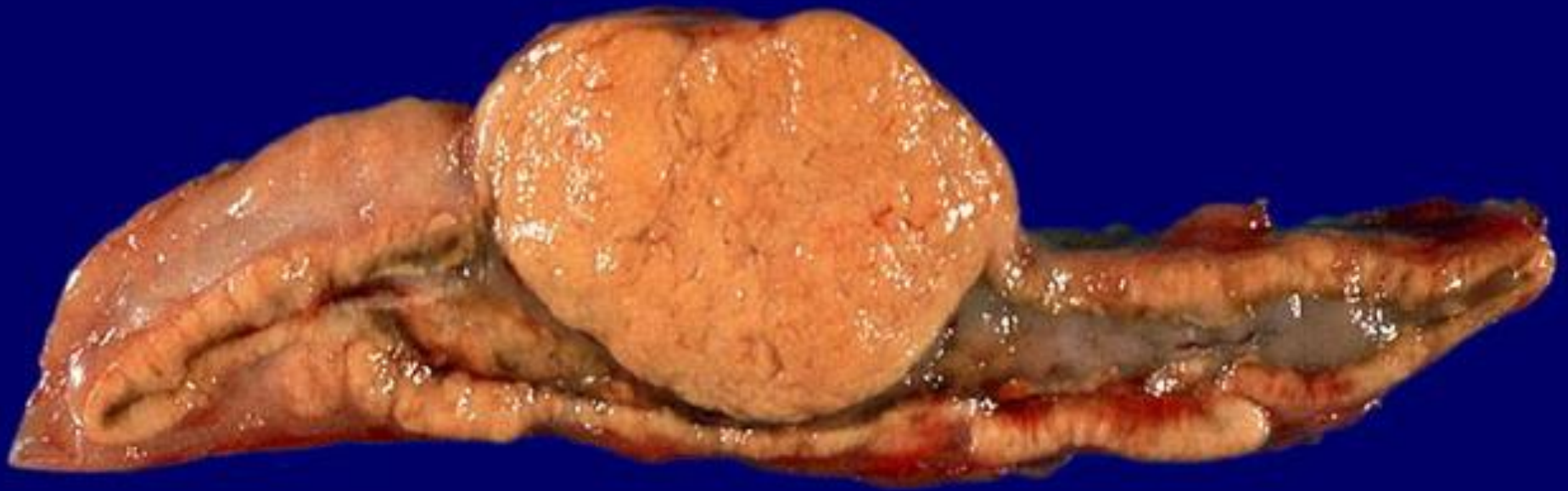In adrenal on section, there is a round or oval tumor node, of 1-2-3 cm in diameter, well delimited, yellow, located in the cortical layer.

*Adrenocortical adenomas may be functional or non-functional. In most cases are accidentally detect at autopsy, which is why they are called "adrenal incidentaloma". The functional profile cannot be determined by the macroscopic or microscopic aspect. Hormonal active adenomas are clinically manifested by glucocorticoid hypersecretion (adrenal Cushing's syndrome, ACTH-independent) or aldosterone (Conn's syndrome - primary hyperaldosteronism).*

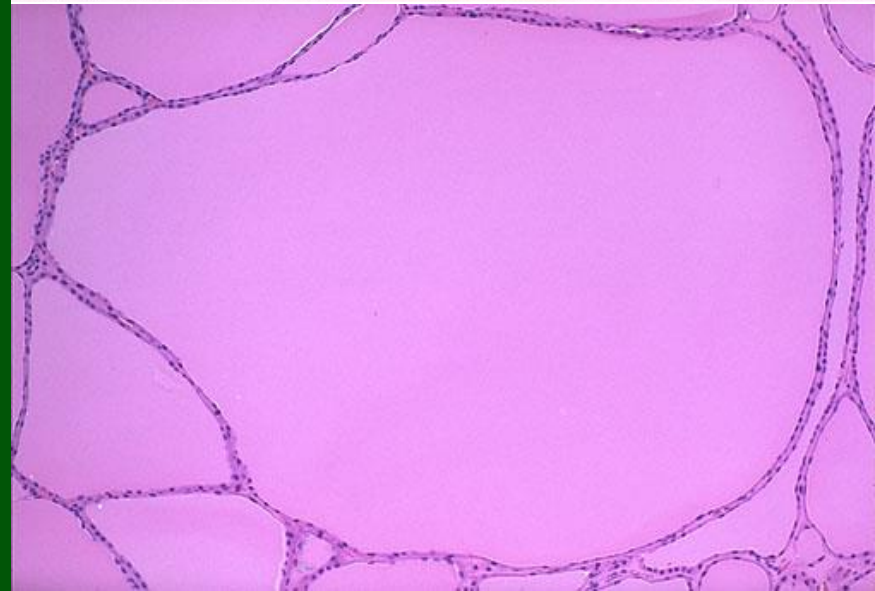
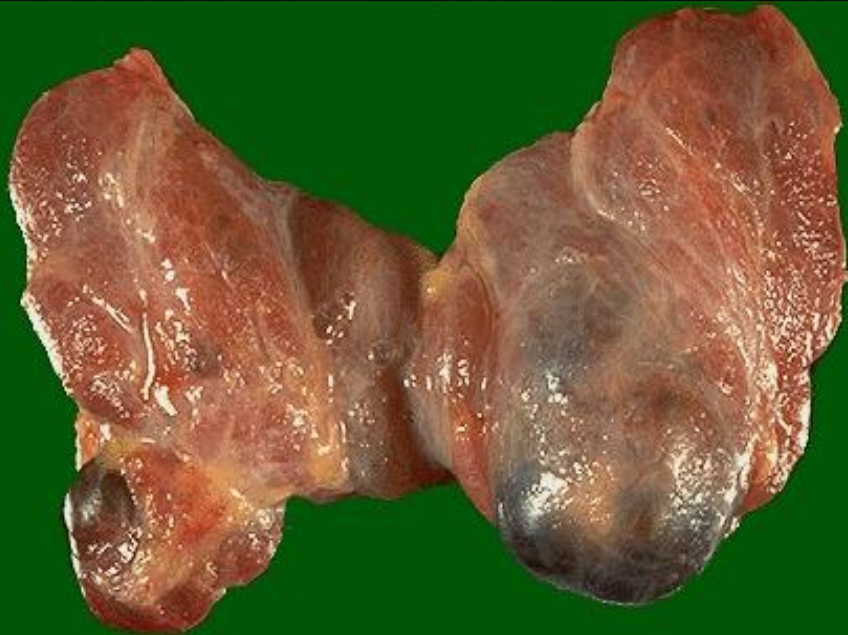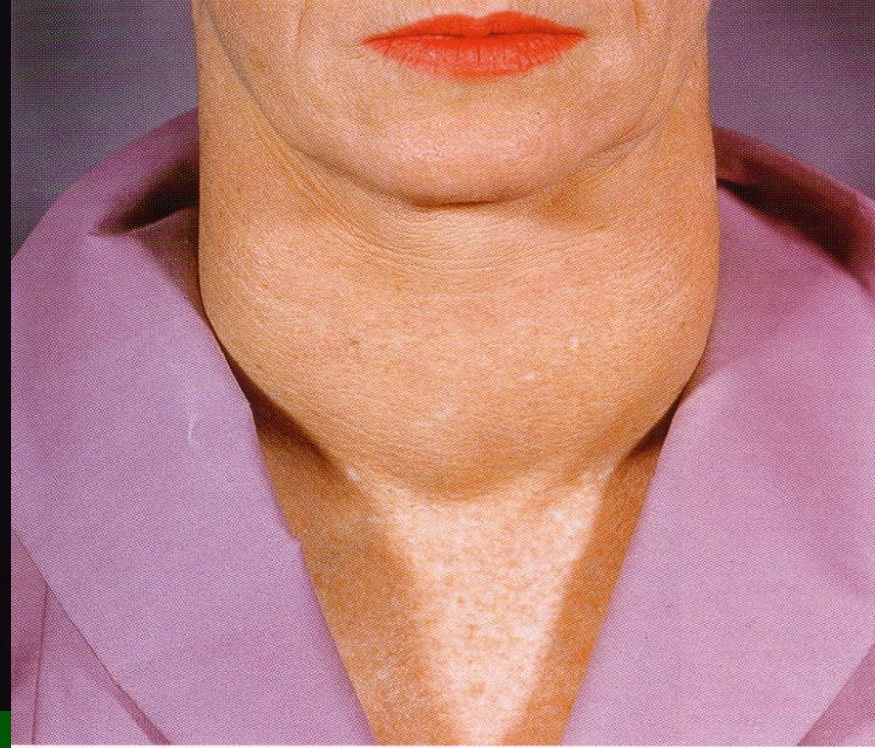

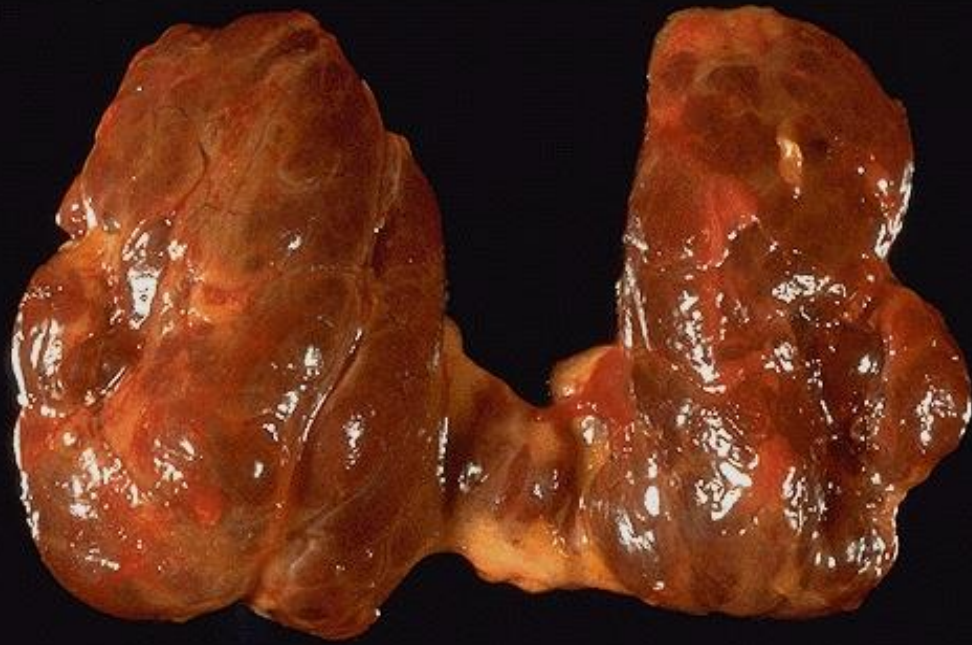
**№ 132. Colloid goiter.**

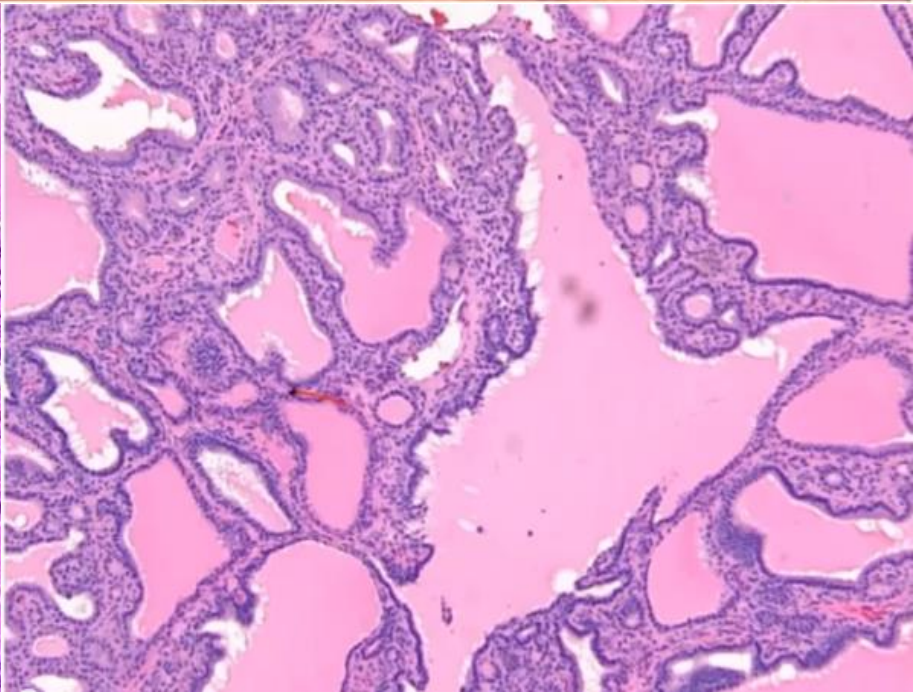
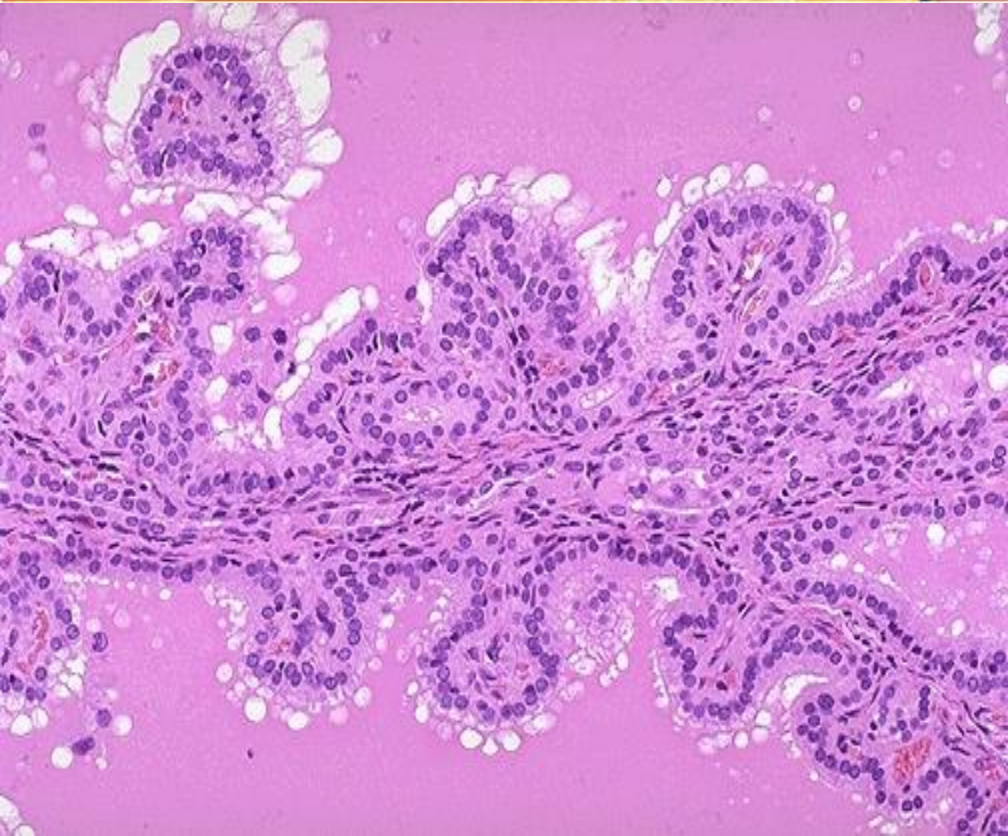
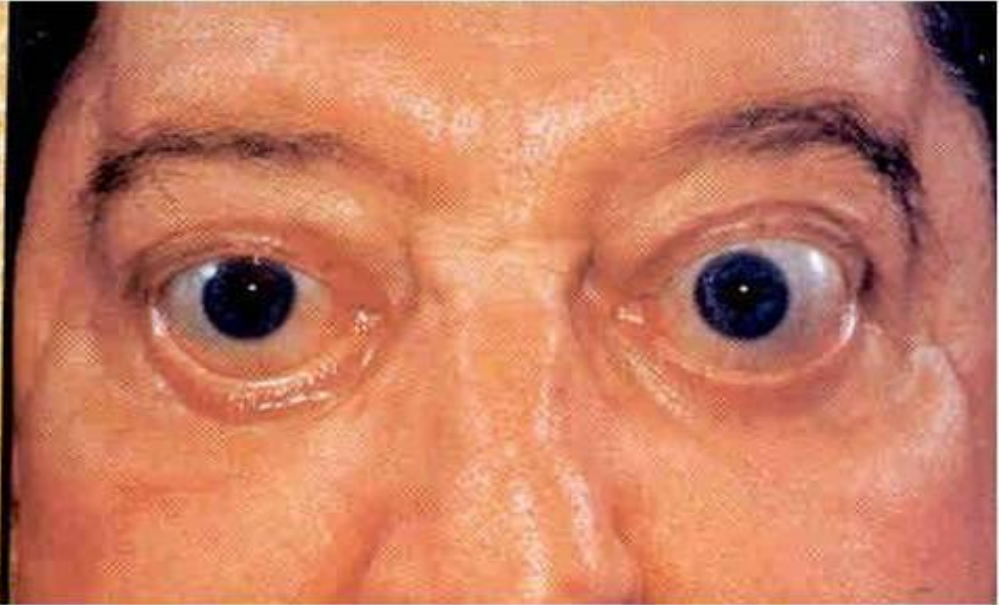
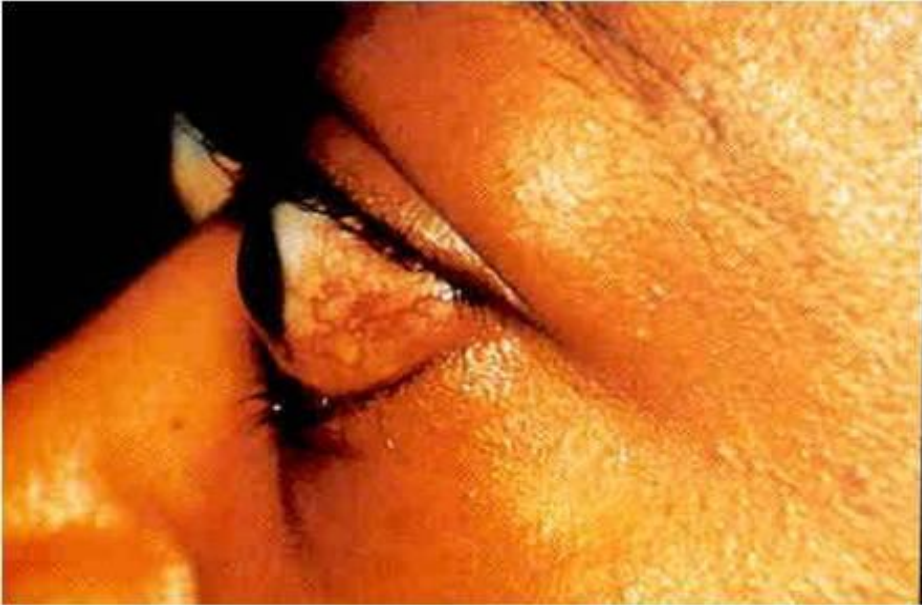


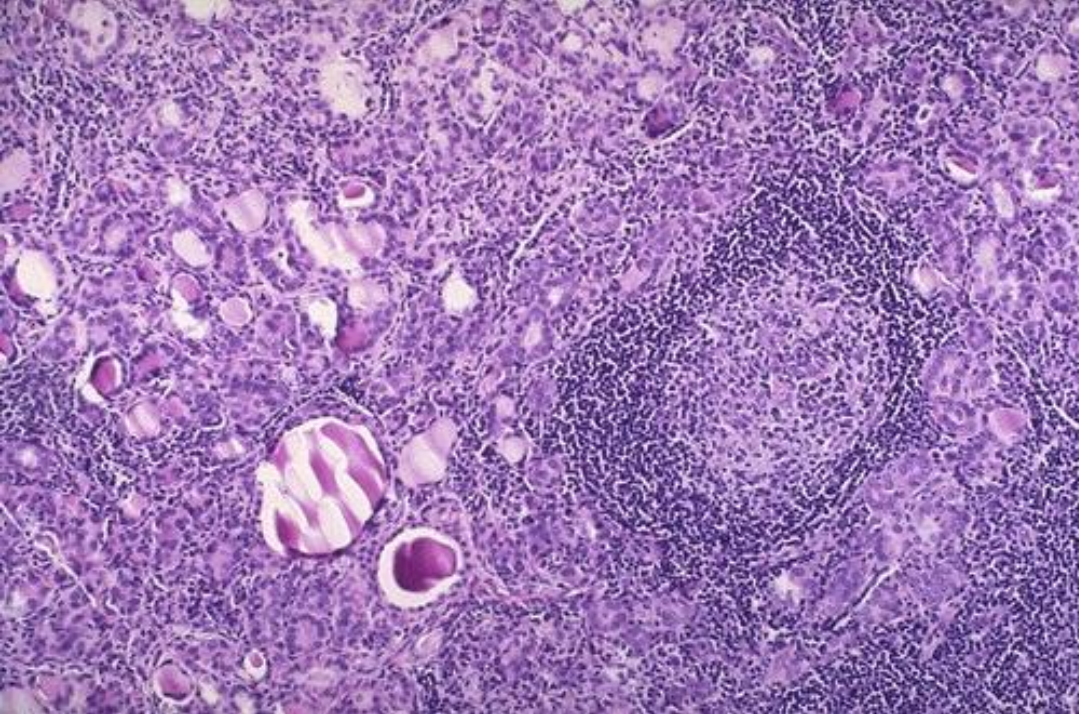
**№ 133. Adrenocortical adenoma.**



**Colloid goiter.**

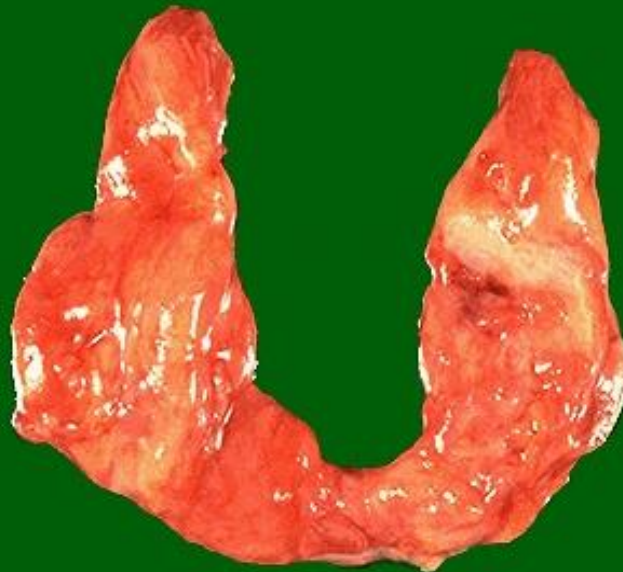

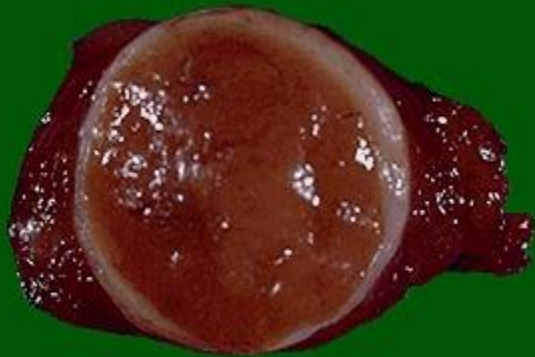
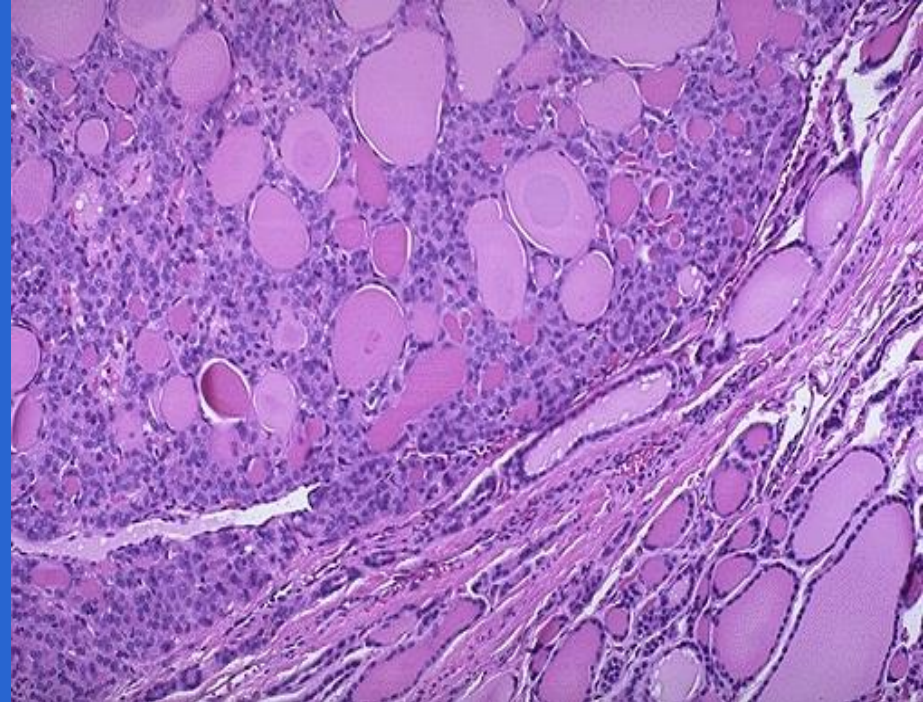

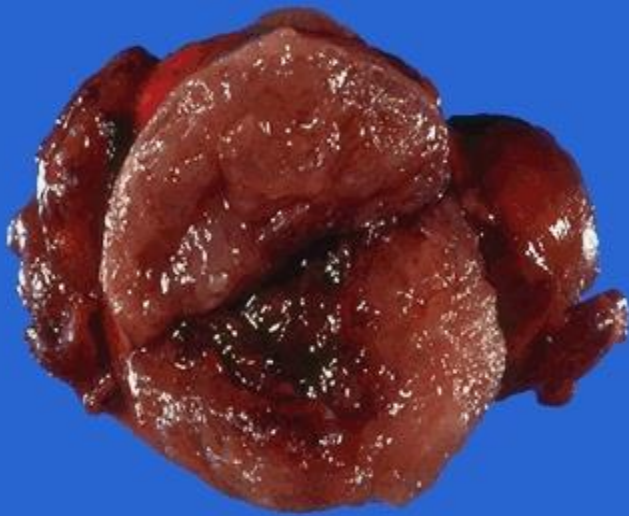
**Toxic diffuse goiter.**



**Hashimoto thyroiditis.**

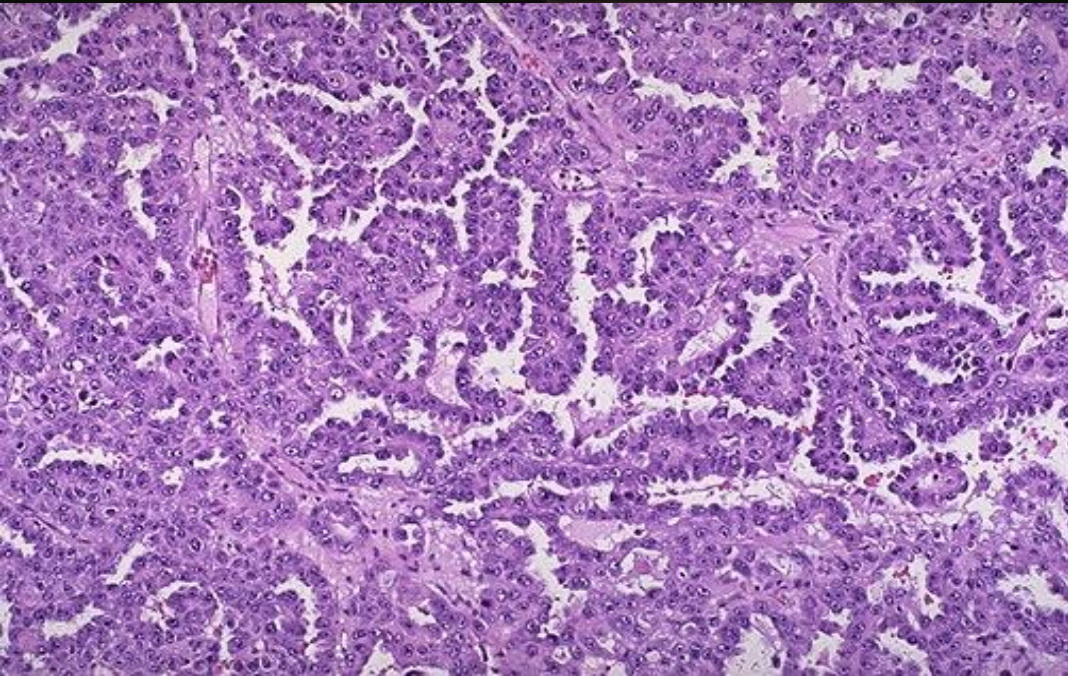
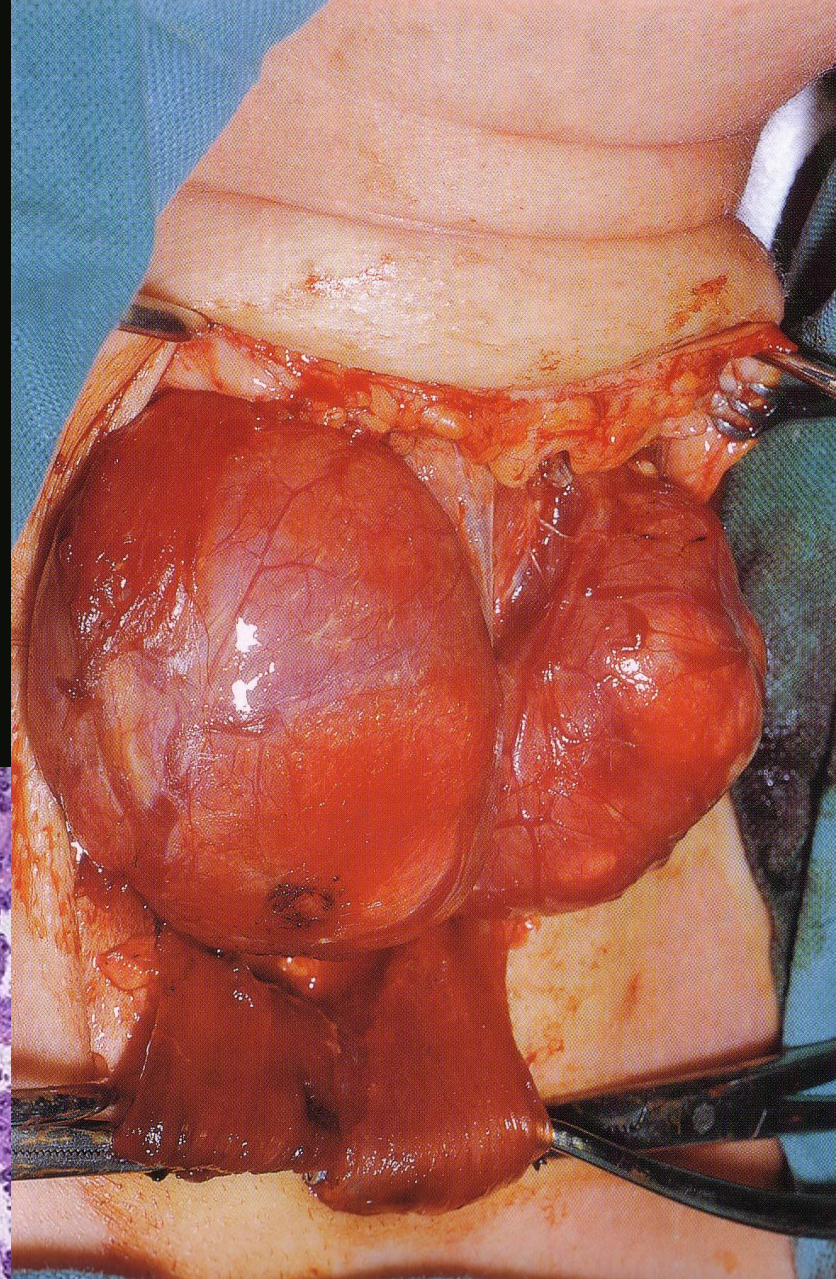
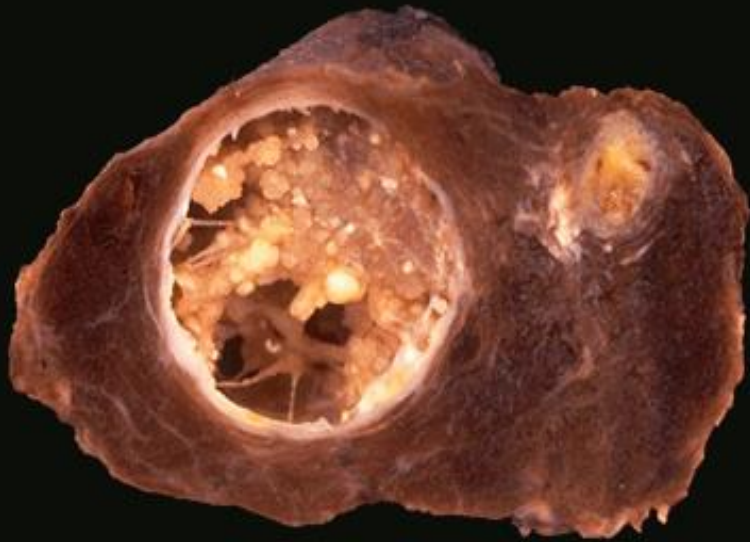**macro - thyroid gland  
atrophy.**





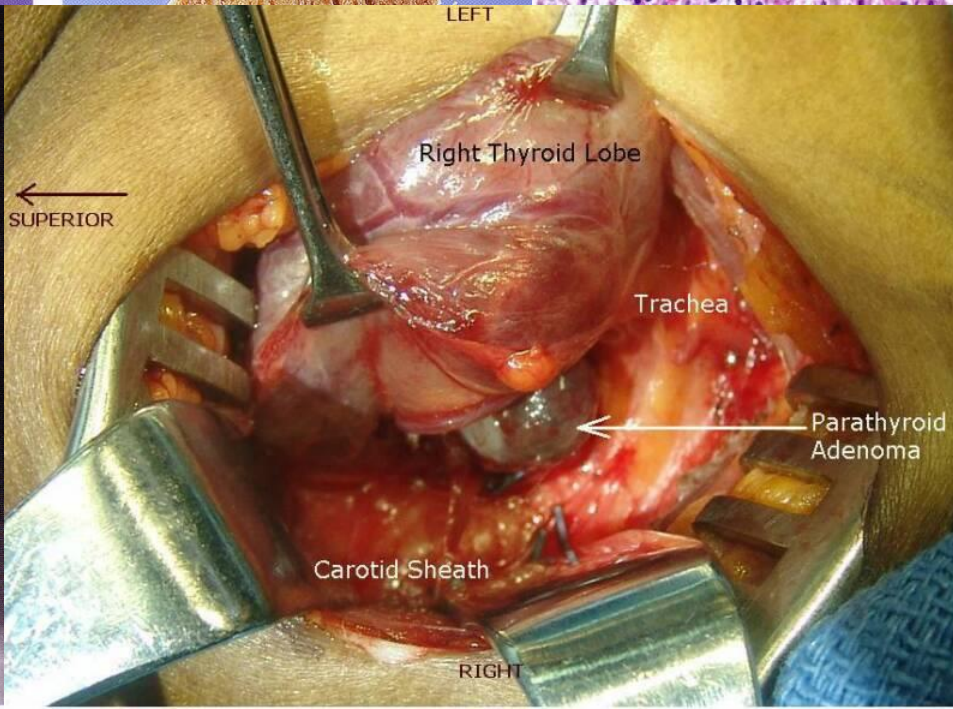
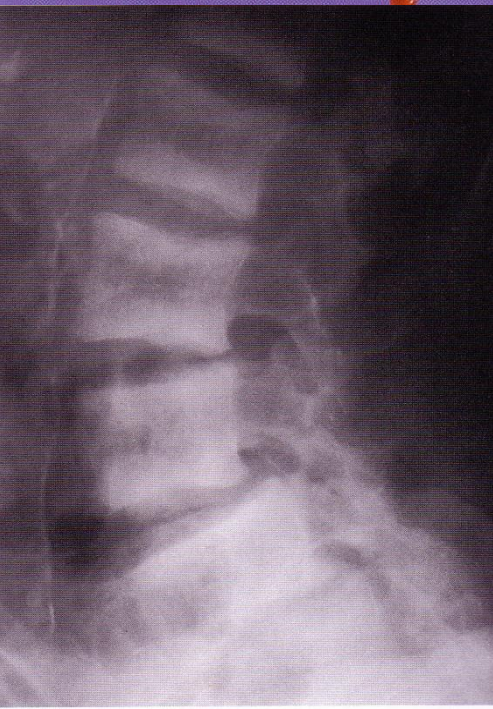
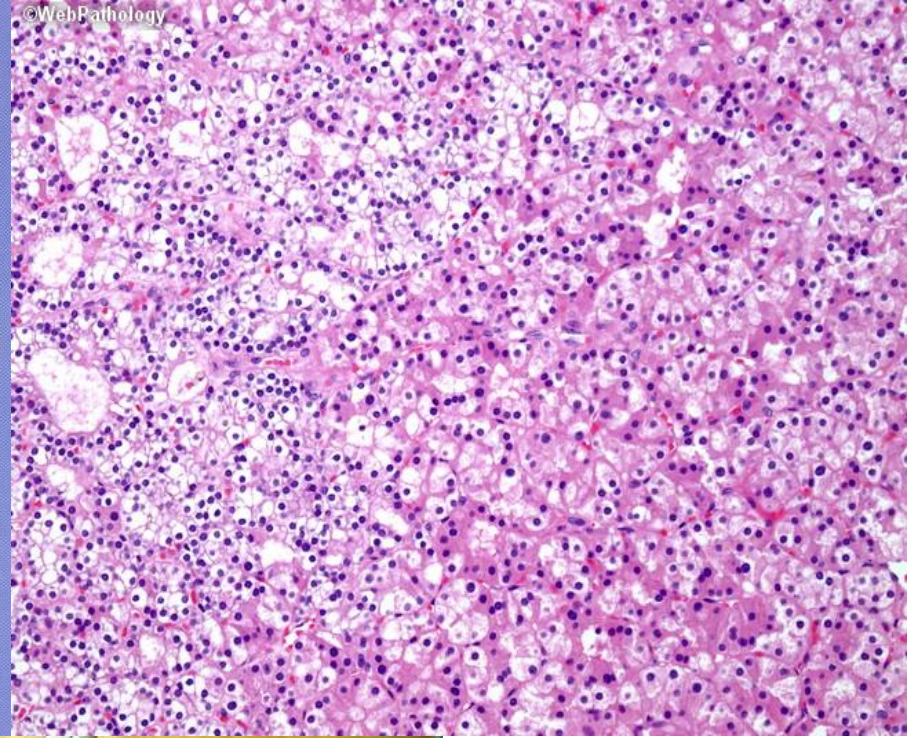
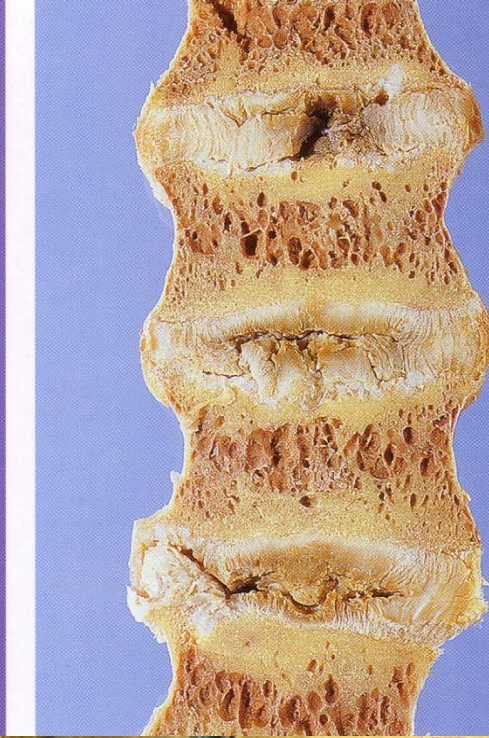
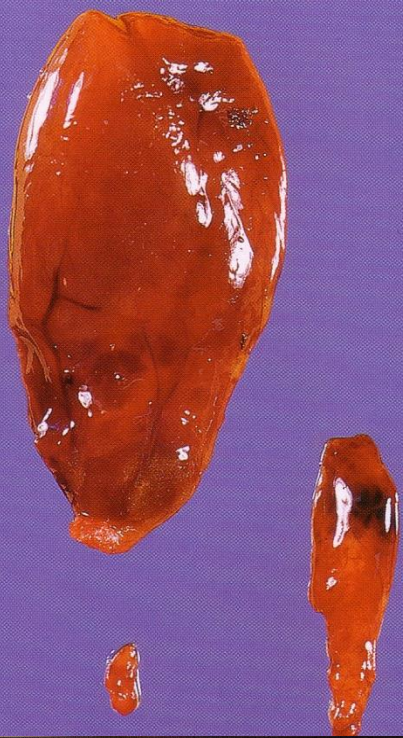**Follicular thyroid adenoma.**





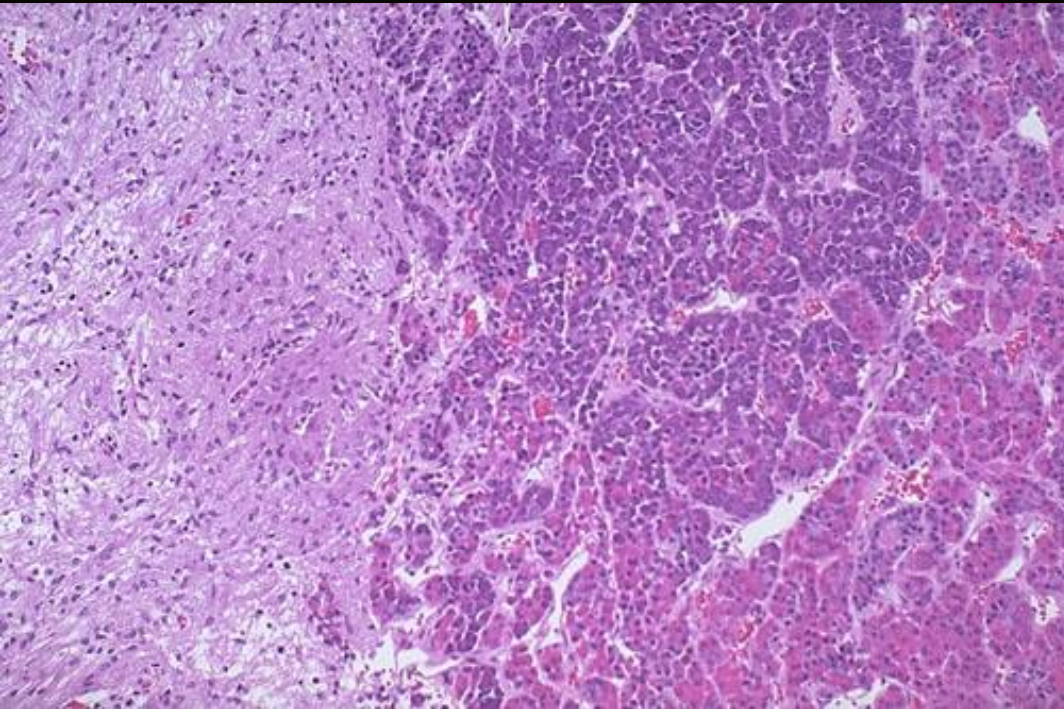
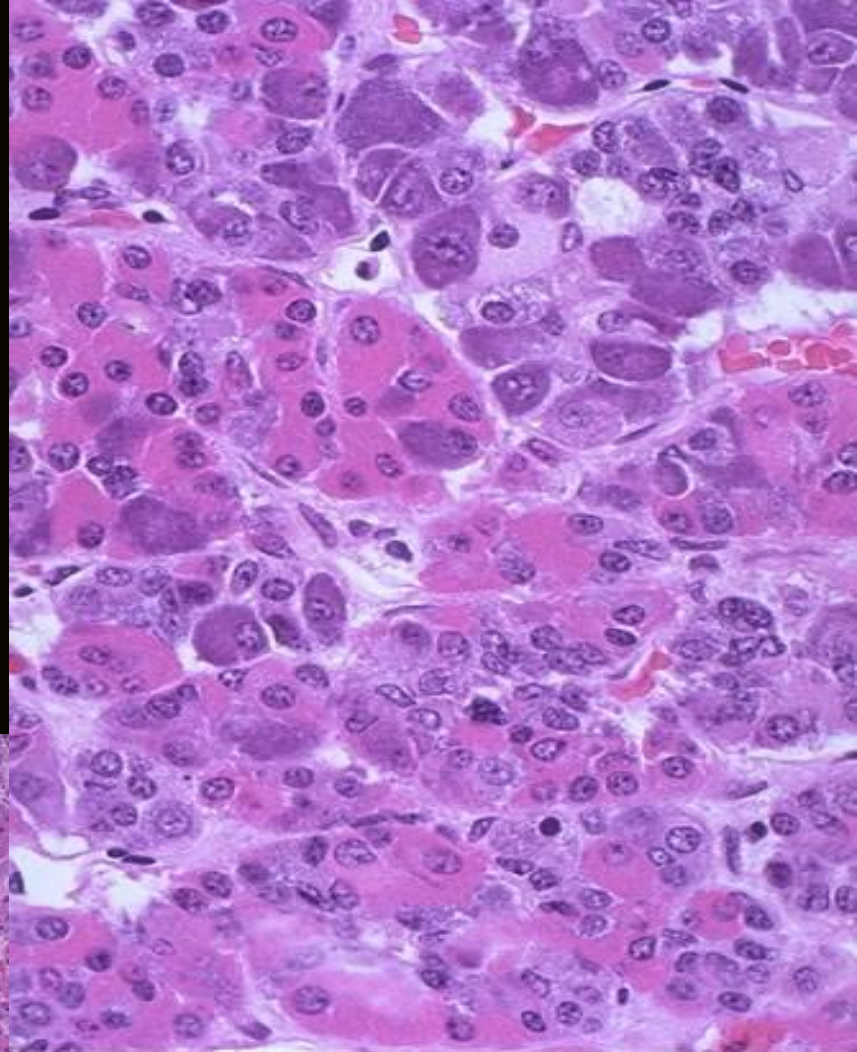
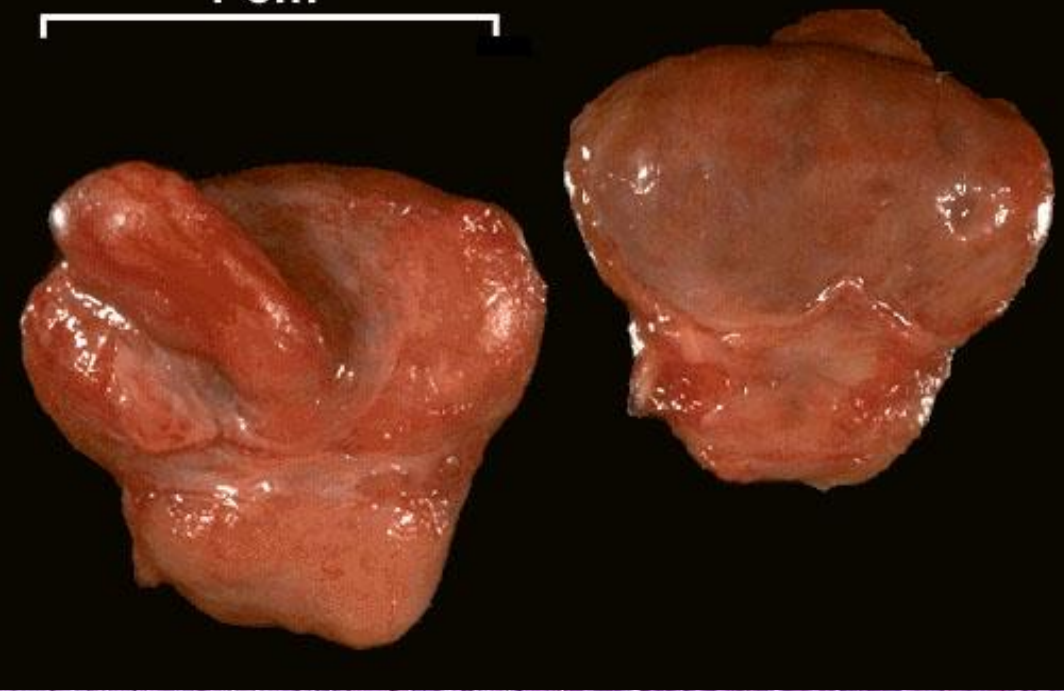
**Thyroid carcinoma**

⇐⇐ papillary and medullary ↑



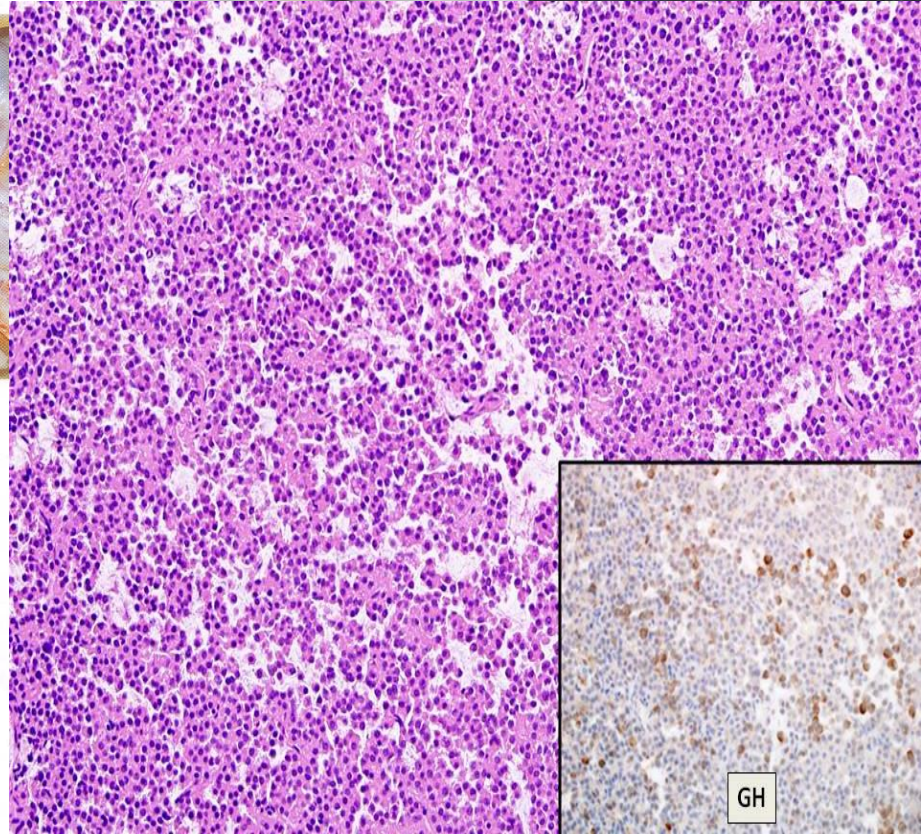
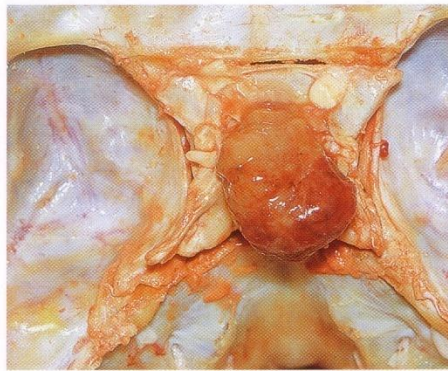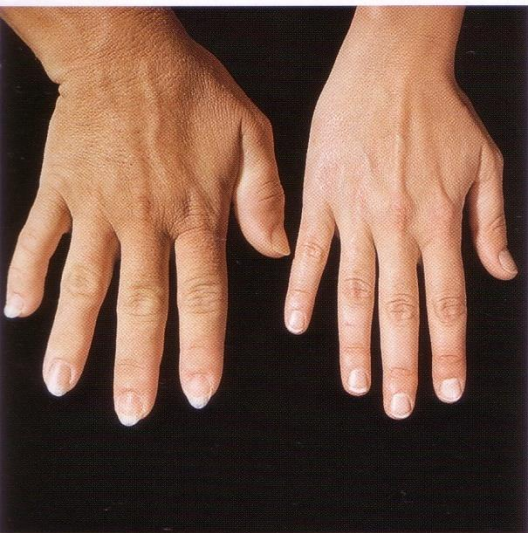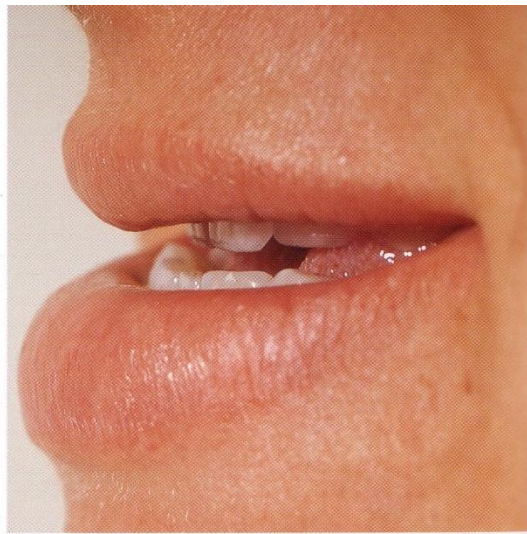
**Parathyroid  
osteodystrophy,  
*parathyroid adenoma.***

1 cm

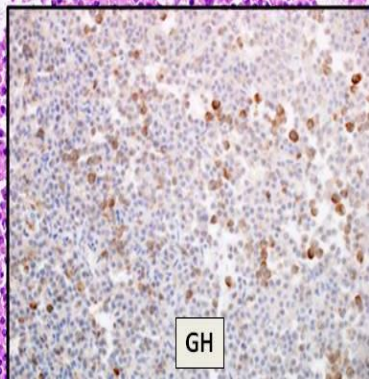


## Hypophysis,

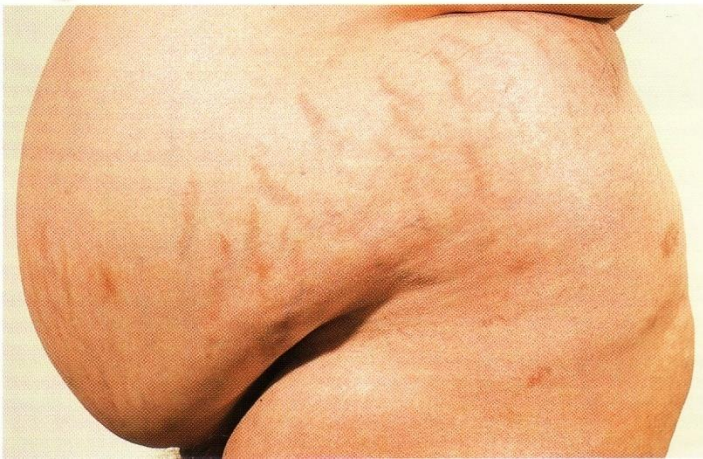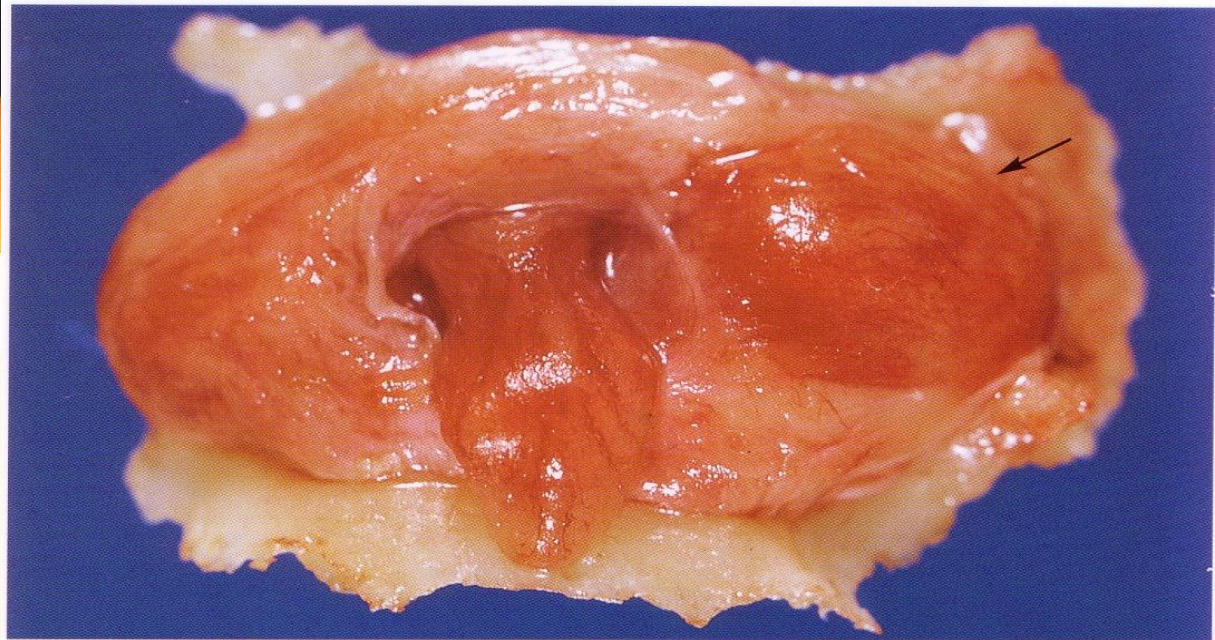
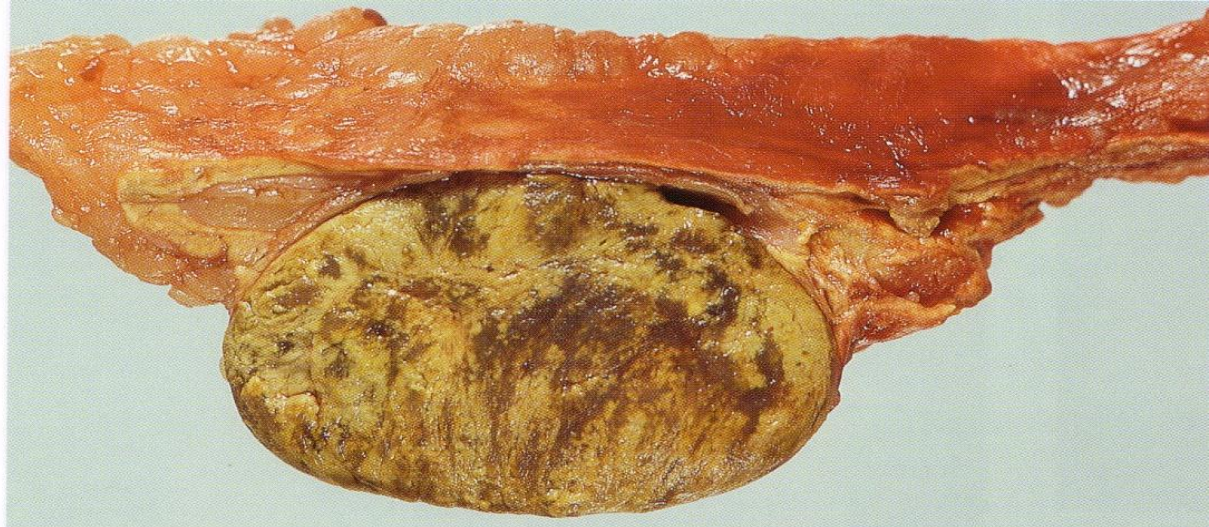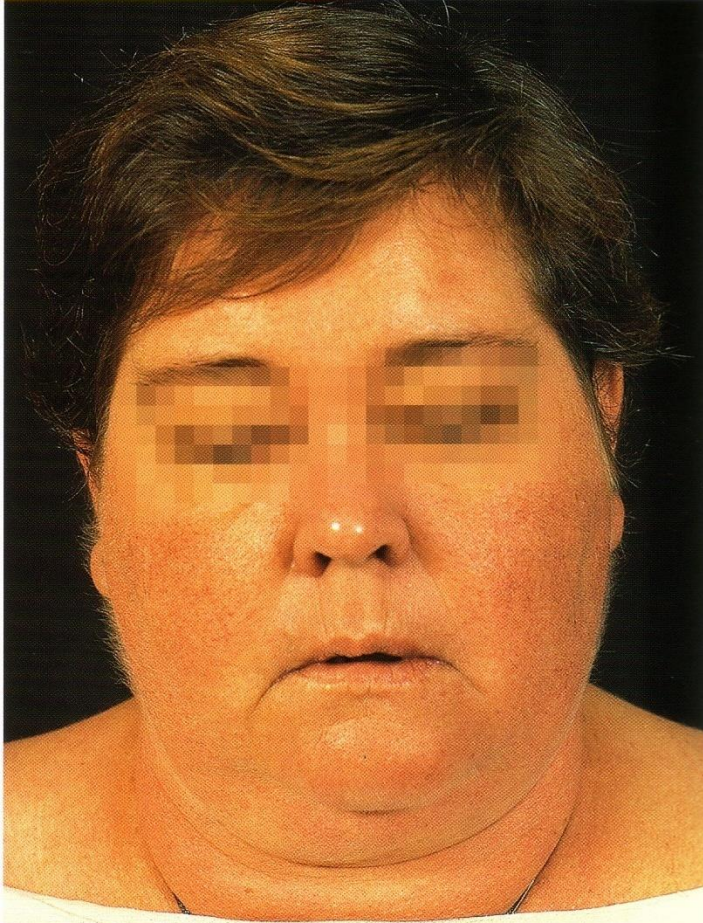⇐ *micro: left - neurohypophysis, right - adenohypophysis, basophilic and acidophilic cells*



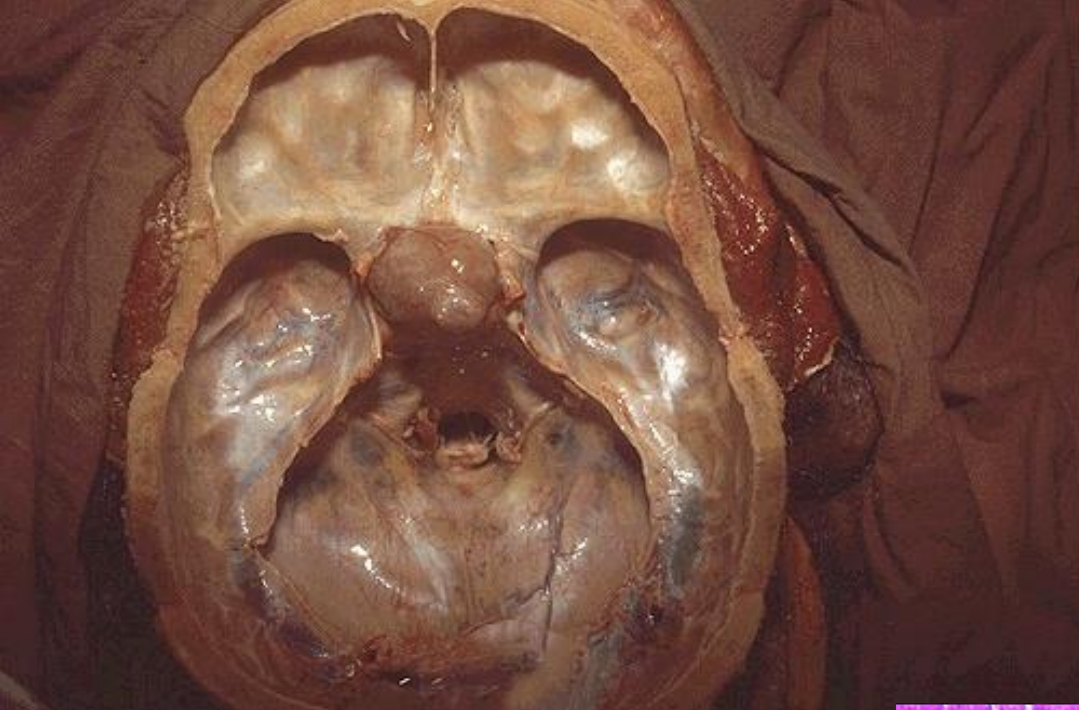**Gigantism  
(eosinophilic pituitary  
adenoma)**



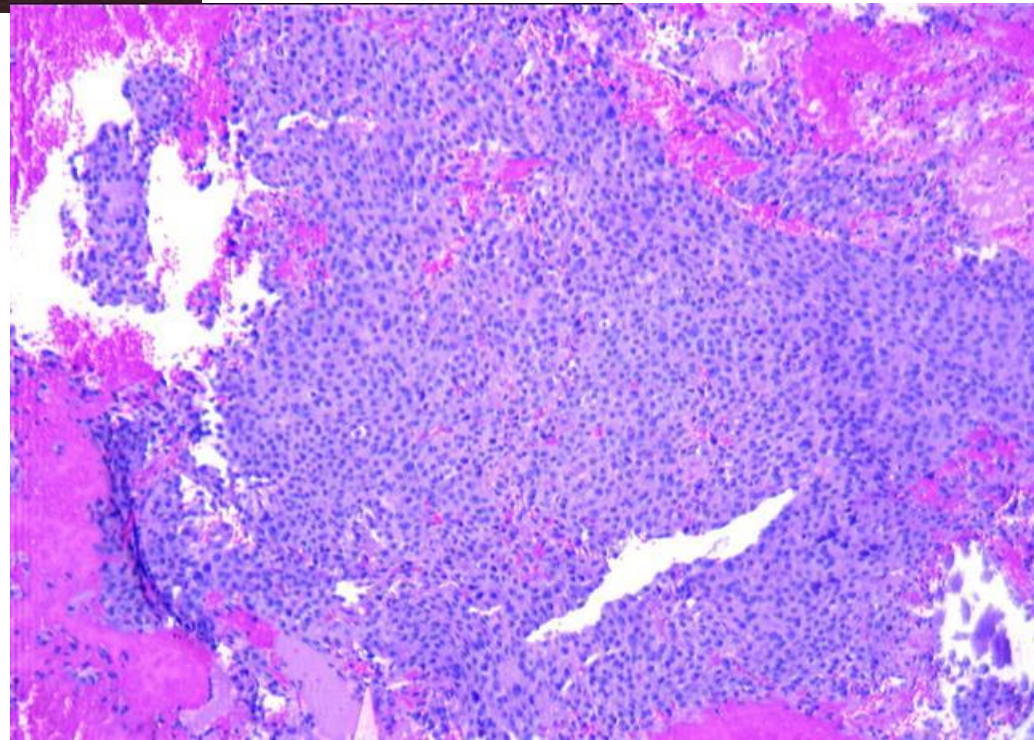
GH

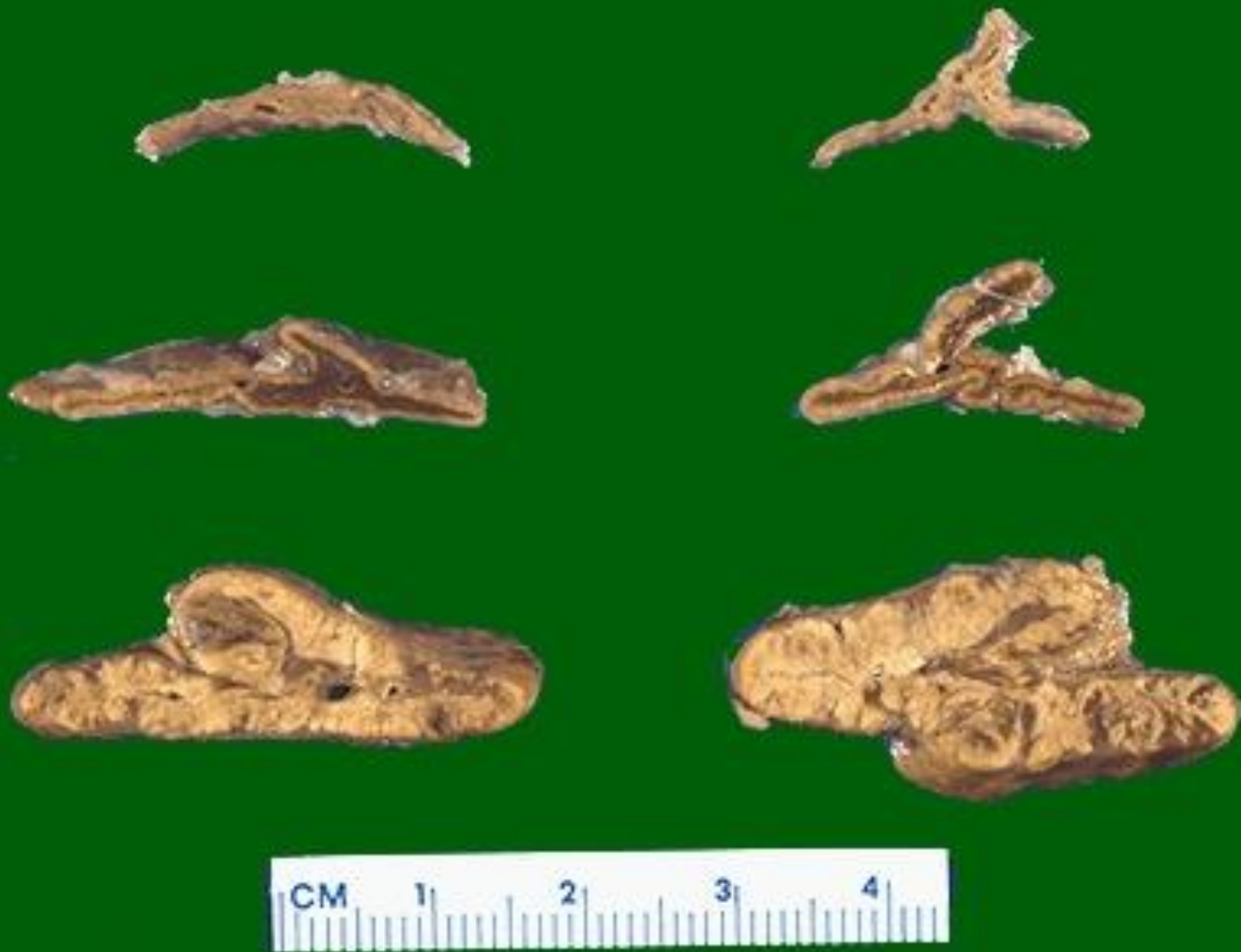

**Cushing's syndrome**  
*(adrenal adenoma and pituitary basophilic adenoma).*

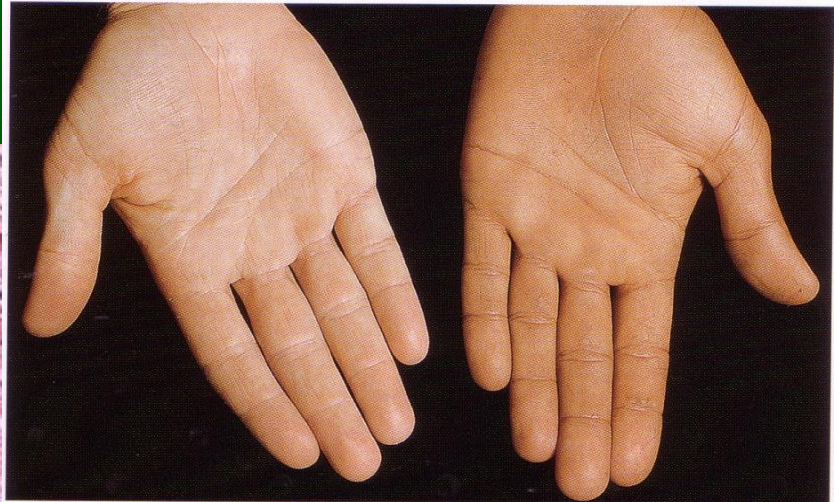
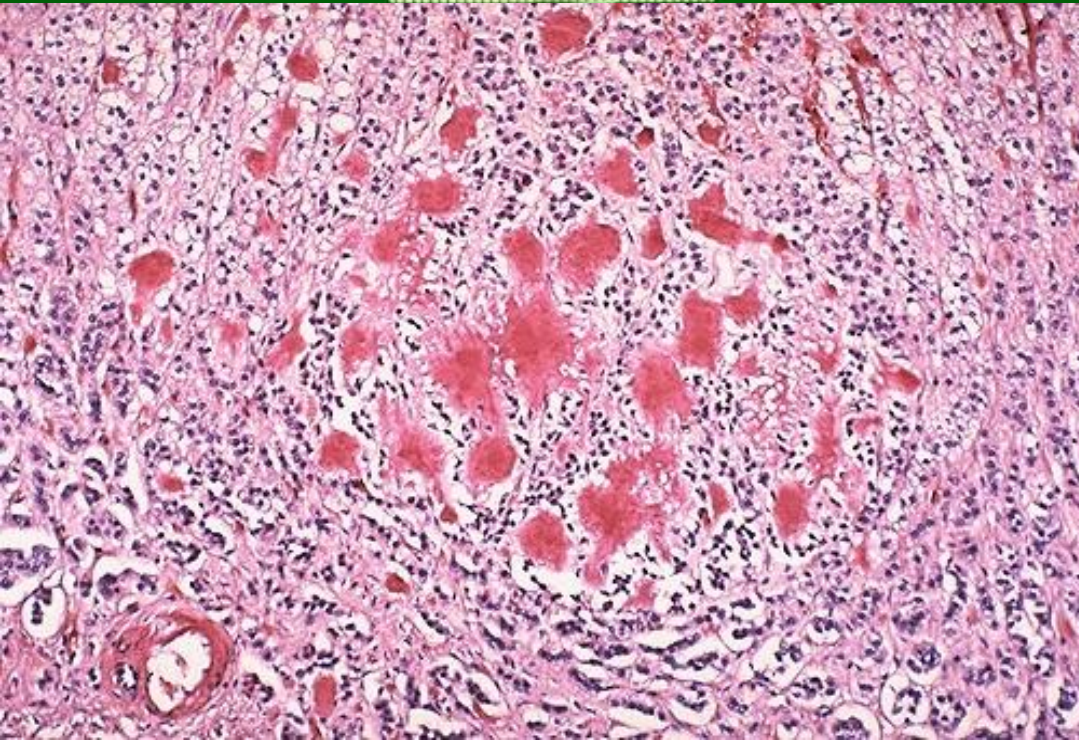
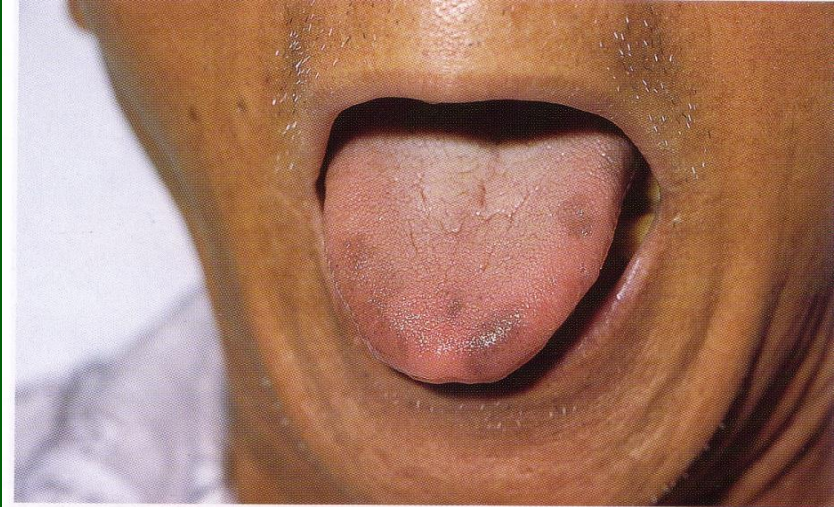
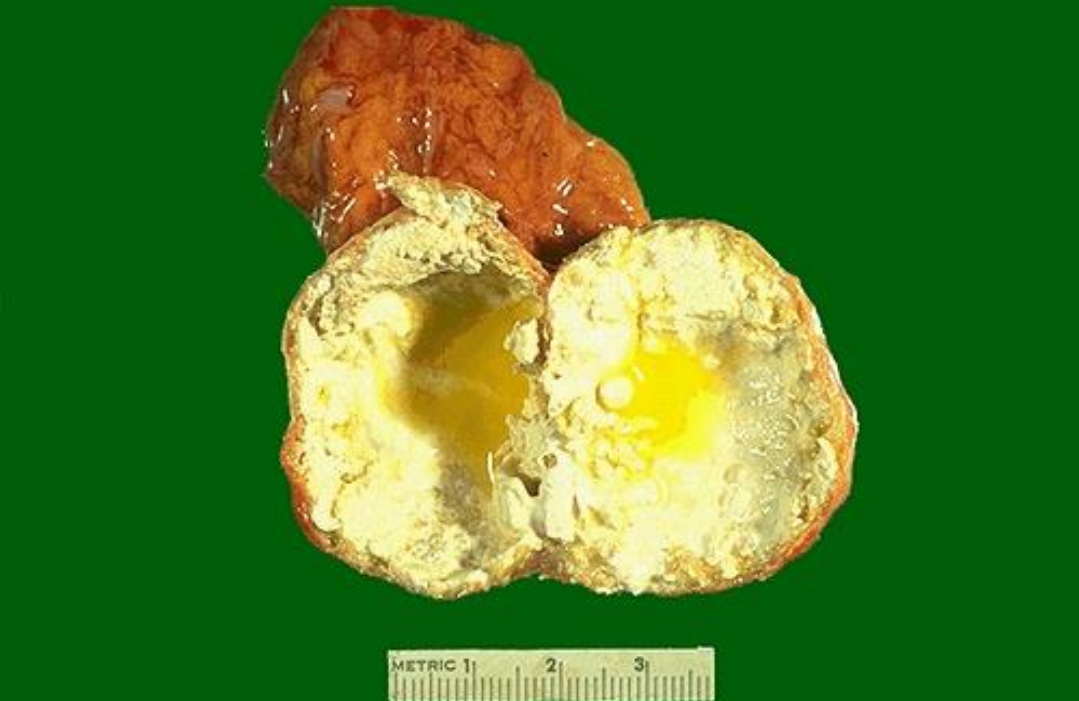

**Basophilic pituitary  
adenoma.**



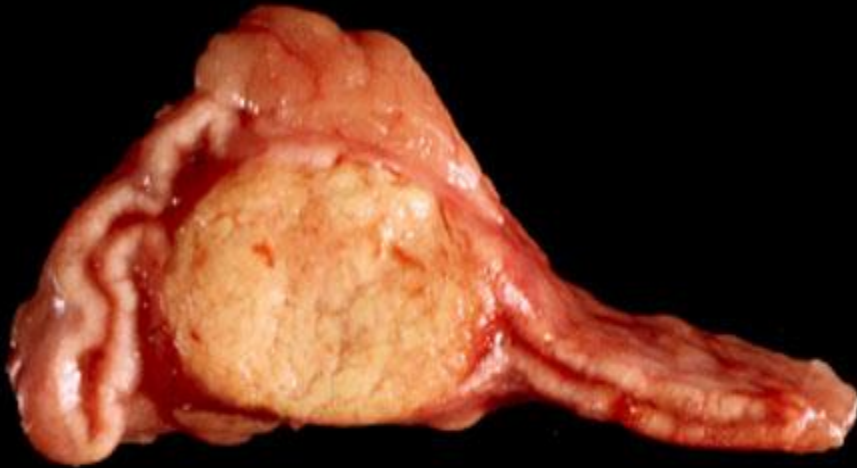
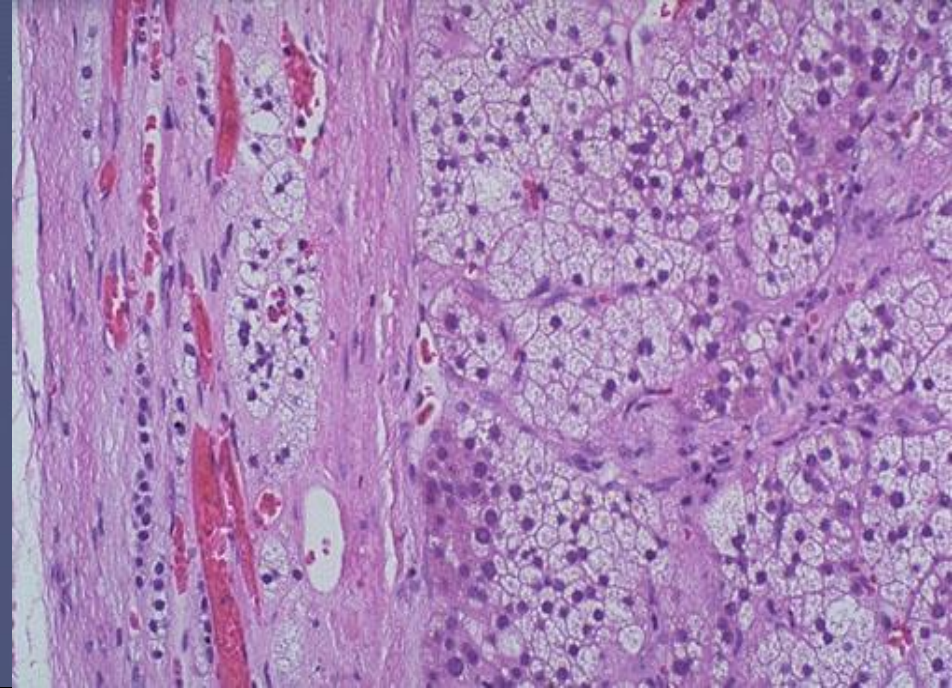
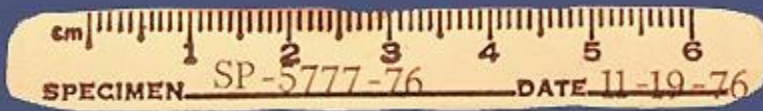
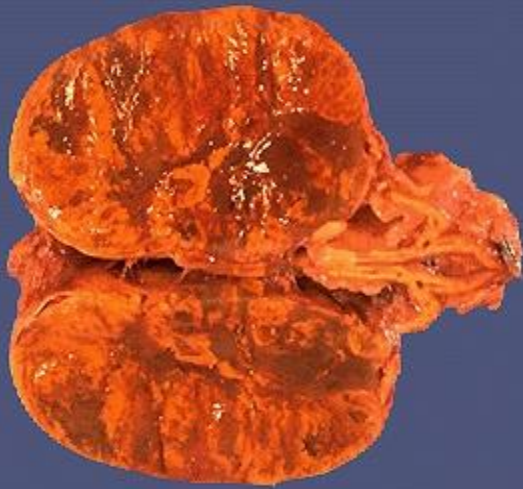
- Adrenal atrophy in Addison's disease.
- Normal adrenal glands.
- Adrenal adenoma in Cushing's syndrome.



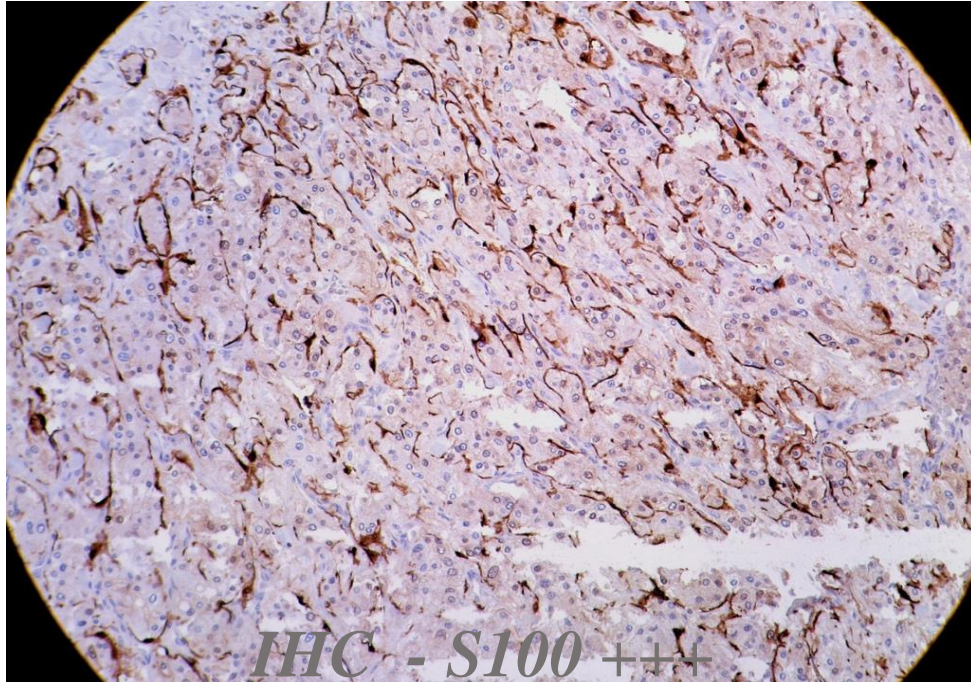
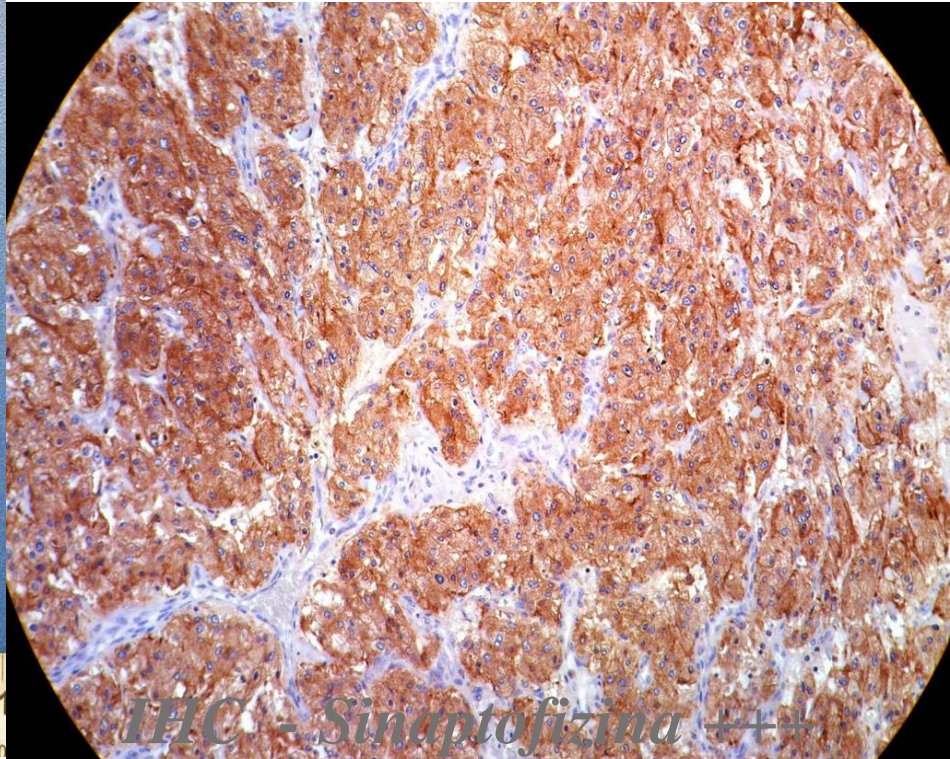
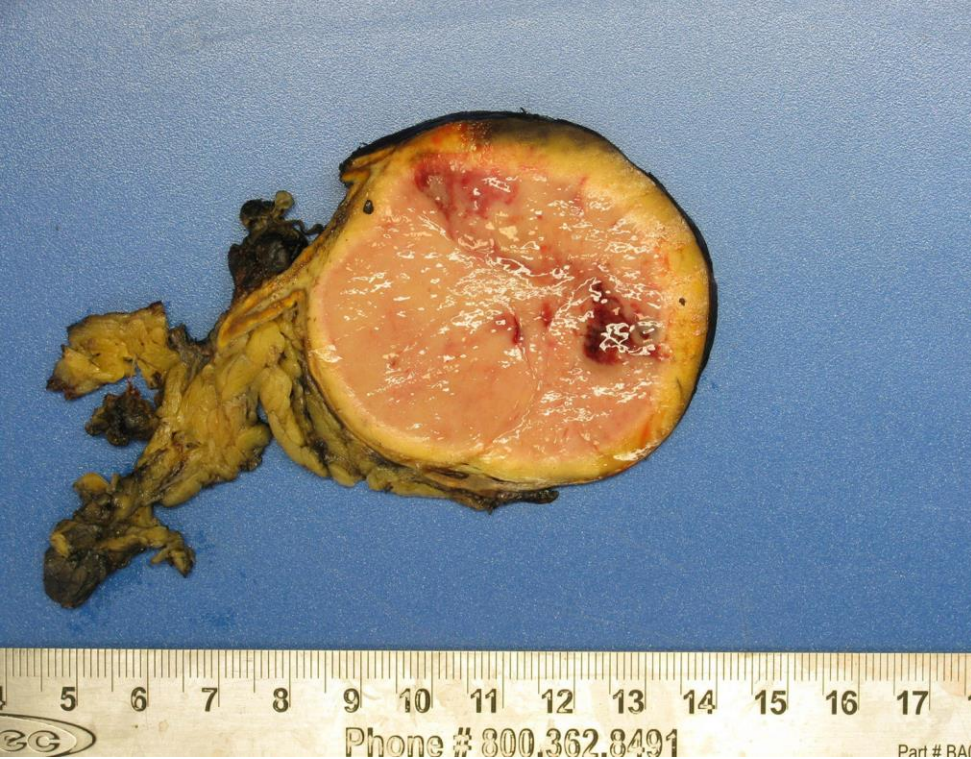**Tuberculosis (caseous necrosis) and amyloidosis (Congo red stain.) of the adrenal glands. Clinically – Addison's disease.**



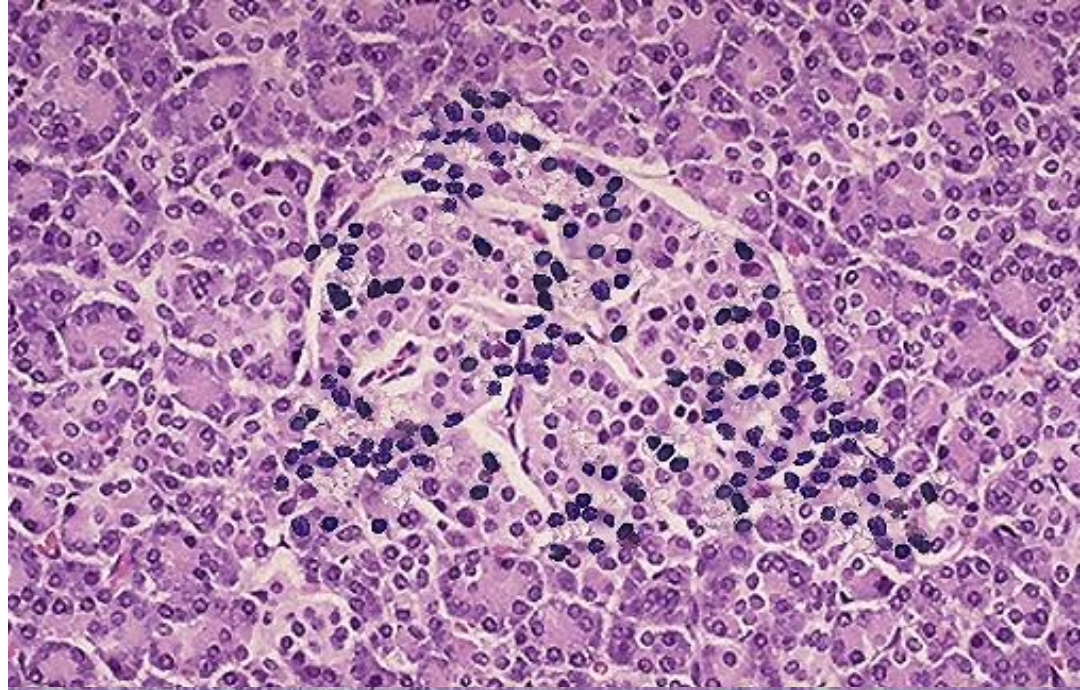
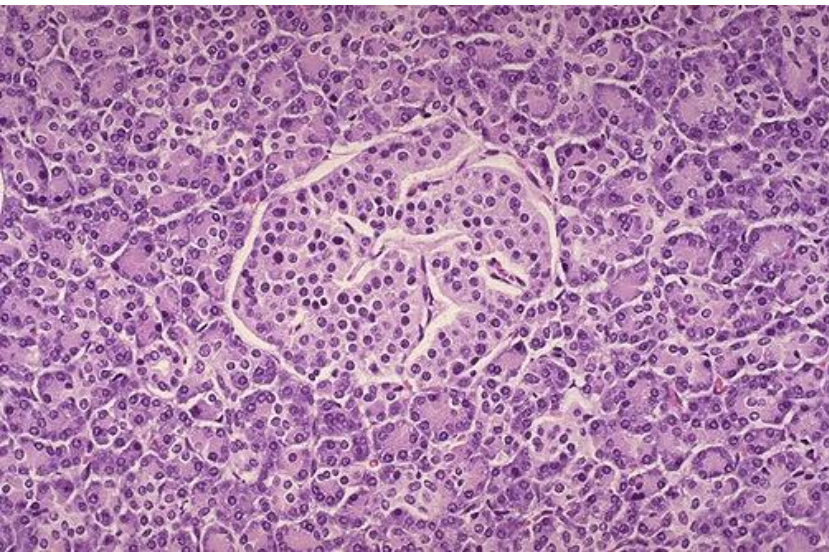


## Adrenal adenoma

*(Cushing's syndrome,  
Conn syndrome).*



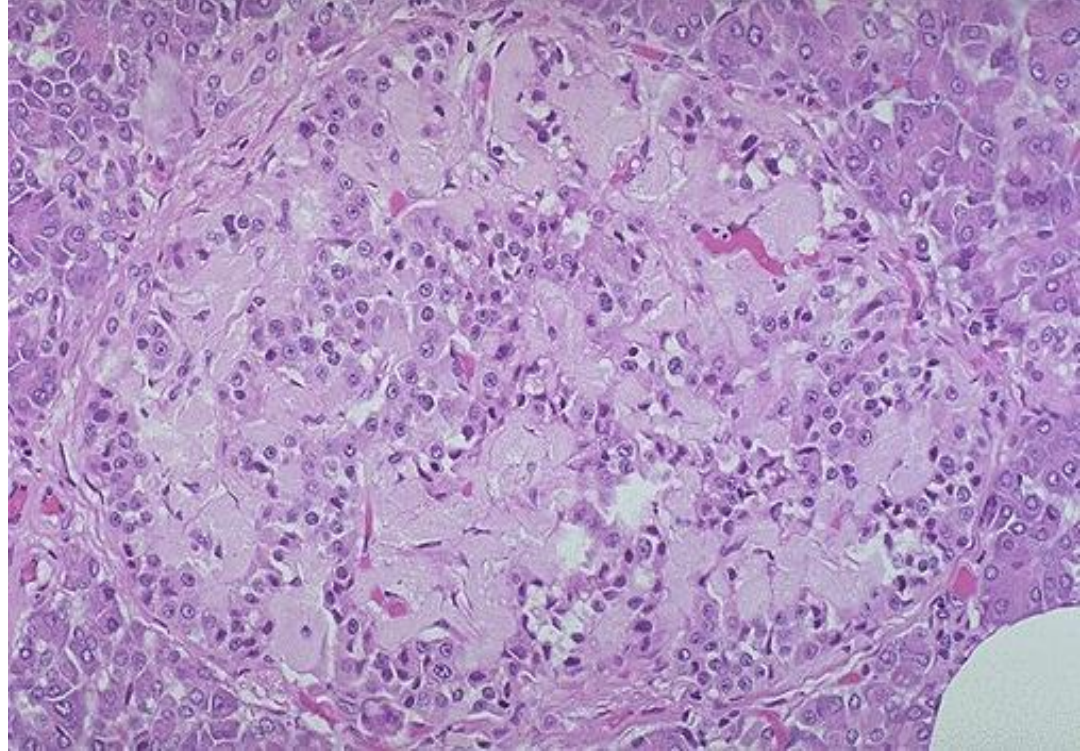
**Pheochromocytoma.**

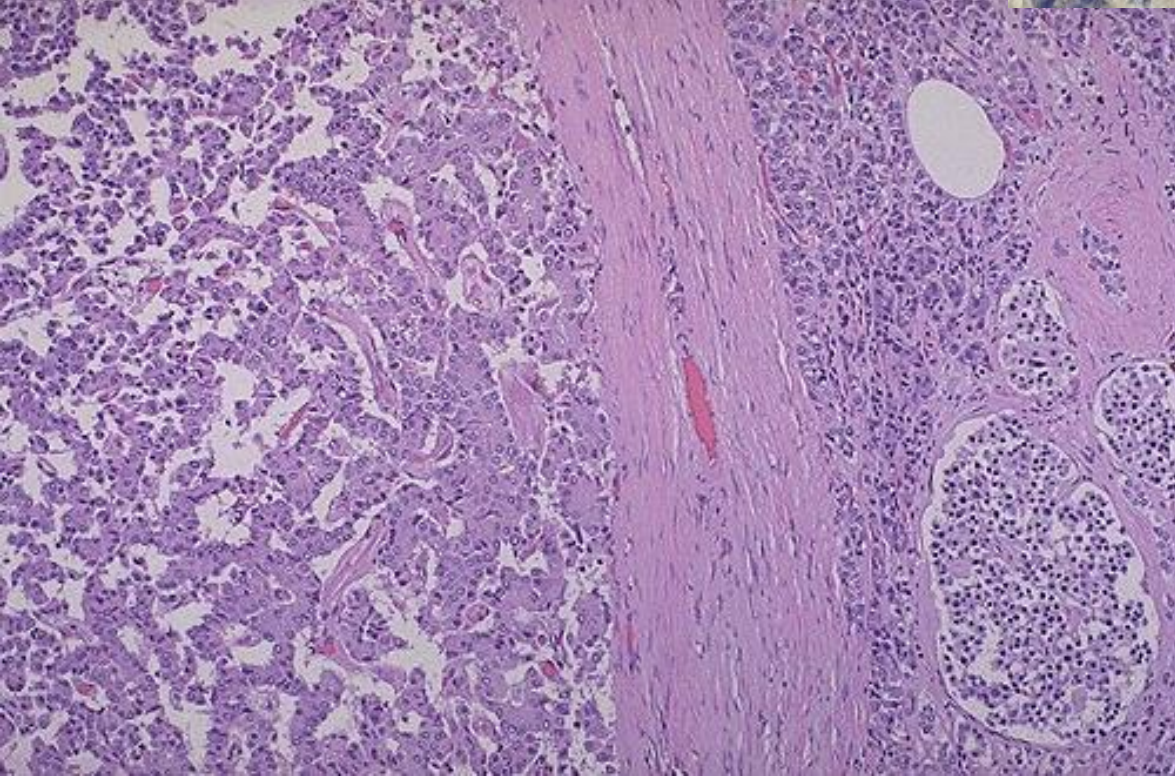
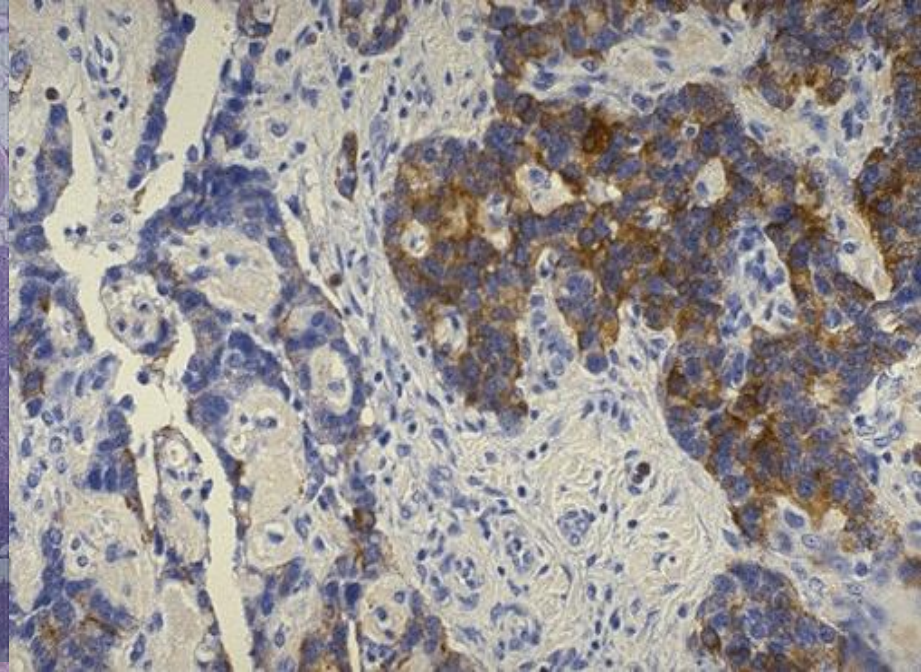
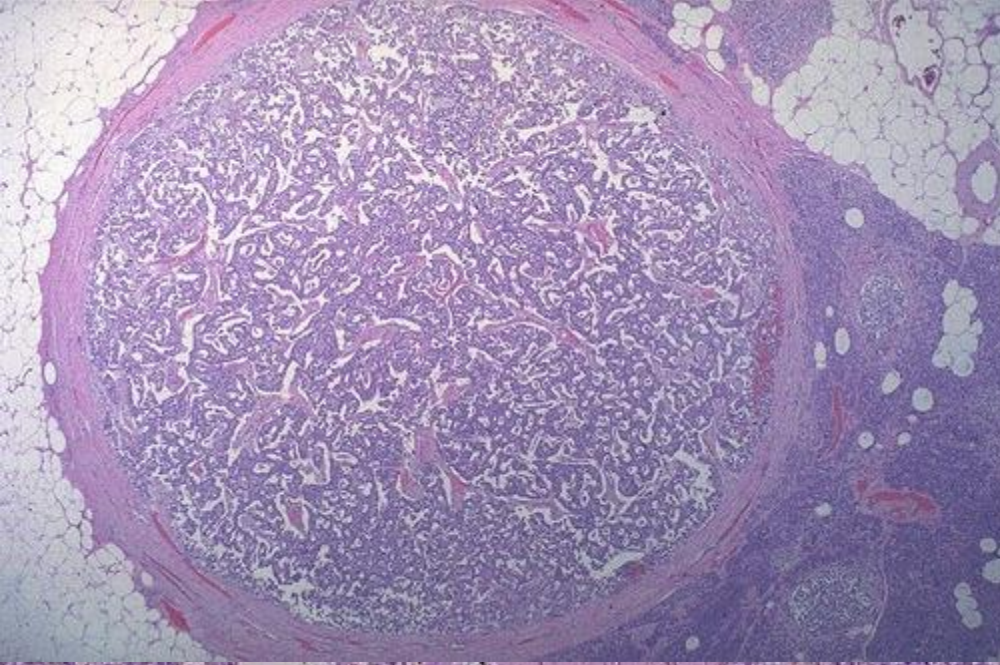


**↑ Normal Langerhans islets;**

**Autoimmune, type I  
diabetes; →**

**Pancreatic islet amyloidosis,  
type II diabetes →→**

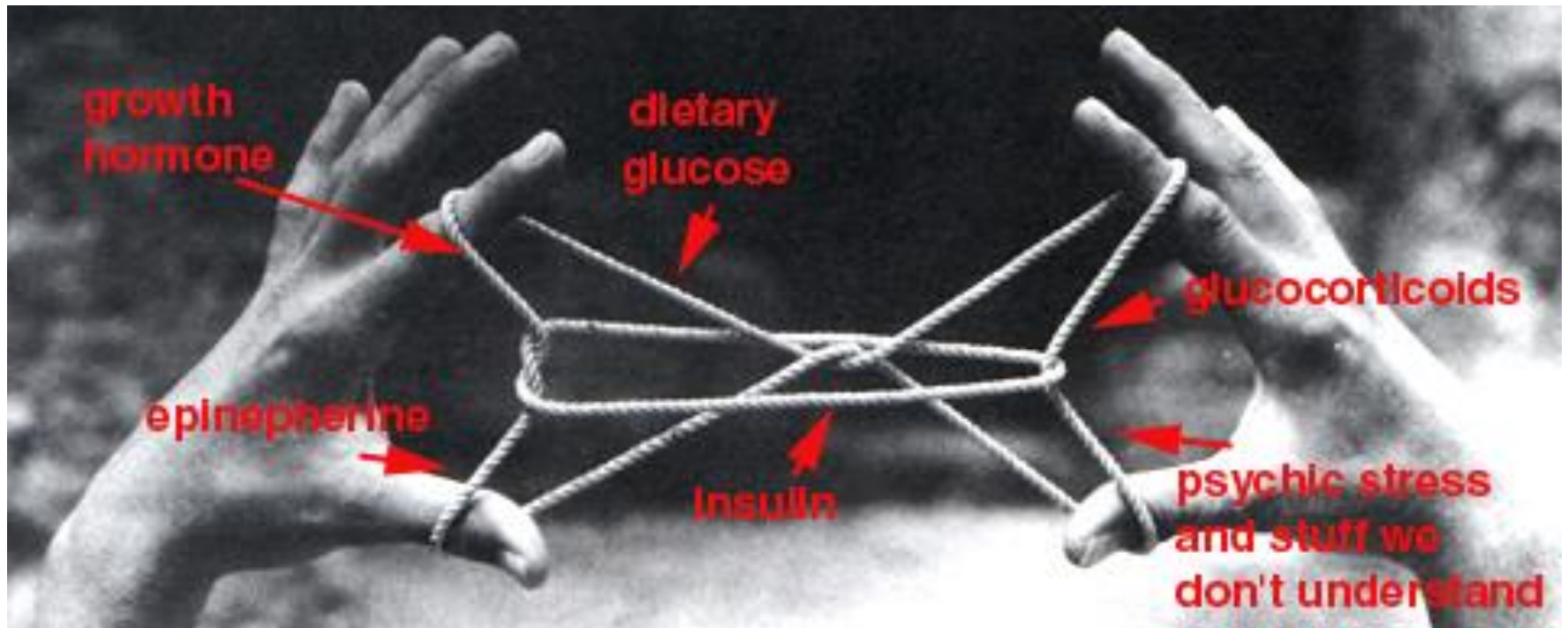




**Pancreatic insulinoma,**  
*sus dreapta – reacție*  
*top right - immunohistochemical*  
*reaction to insulin ( $\beta$  insulinoma)*

# Endocrine Pathology

- All parts of the endocrine system interconnect.



# Endocrine Pathology

- The role of the endocrine system is difficult to overestimate. It includes a group of special organs, the mass of which in the aggregate is only 0.1% of the total body weight.
- These organs produce only 0.5 - 0.6 g per day. biologically active substances \ hormones \ that affect all vital processes in the body.

# ALGORITHM

- **PITUITARY**
  - ANTERIOR
  - POSTERIOR
- **THYROID**
- **PARATHYROID**
- **PANCREAS (endo.)**
- **ADRENAL**
  - CORTEX
  - MEDULLA
- **NON-NEOPLASTIC**
  - HYPER-function
  - HYPO-function
- **NEOPLASTIC**
  - FUNCTIONAL
  - NON-FUNCTIONAL
  - Functional endocrine malignancies are RARE.

- Pituitary
  - Essential control functions over endocrine system
  - Adenohypophysis (75%)
  - Neurohypophysis (25%)
- Adrenal Medulla
  - chromaffin cells & sympathetic nerves
  - catecholamines
- Adrenal Cortex
  - 3 histological zones
  - Mineralcorticoids; glucocorticoids; sex steroids
- Thyroid
  - Thyroxine ( $T_4$ ) & tri-iodothyronine ( $T_3$ )
  - Calcitonin
- Parathyroid
  - Parathyroid hormone (PTH) → calcium homeostasis
- Endocrine Pancreas
  - Islets of Langerhans → insulin & glucagon



# Pituitary

- Also called hypophysis; small pea-sized gland located in brain.
- The hypothalamus in the brain sends signals to cause the pituitary to release or inhibit many hormones such as growth, thyroid stimulation, pregnancy, etc.
- Basically the pituitary hormones tell other glands what to do.

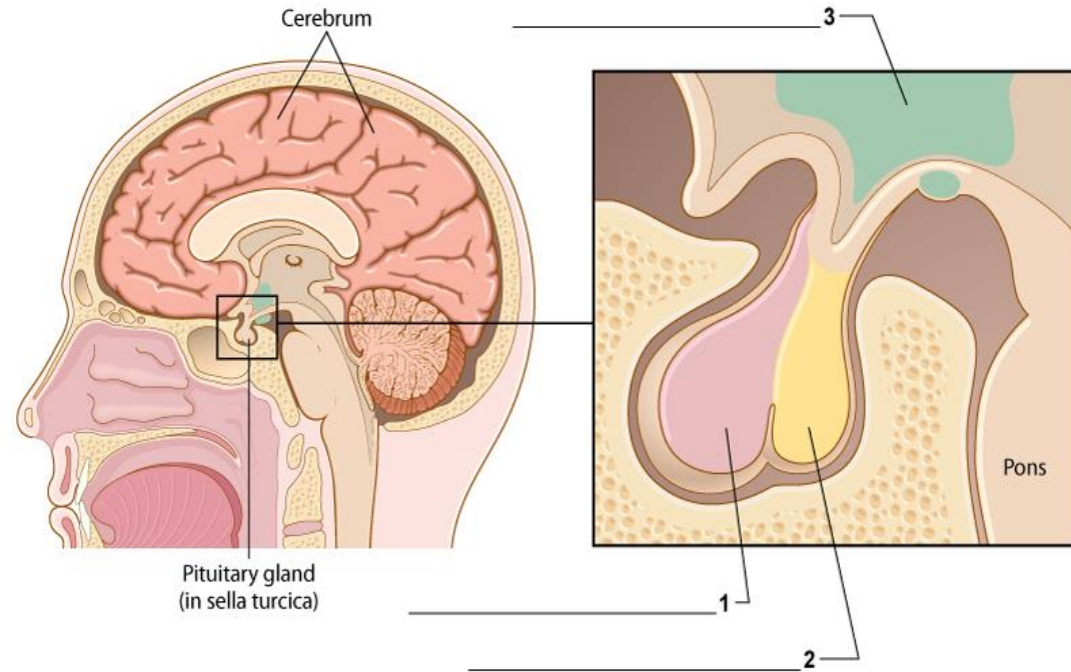
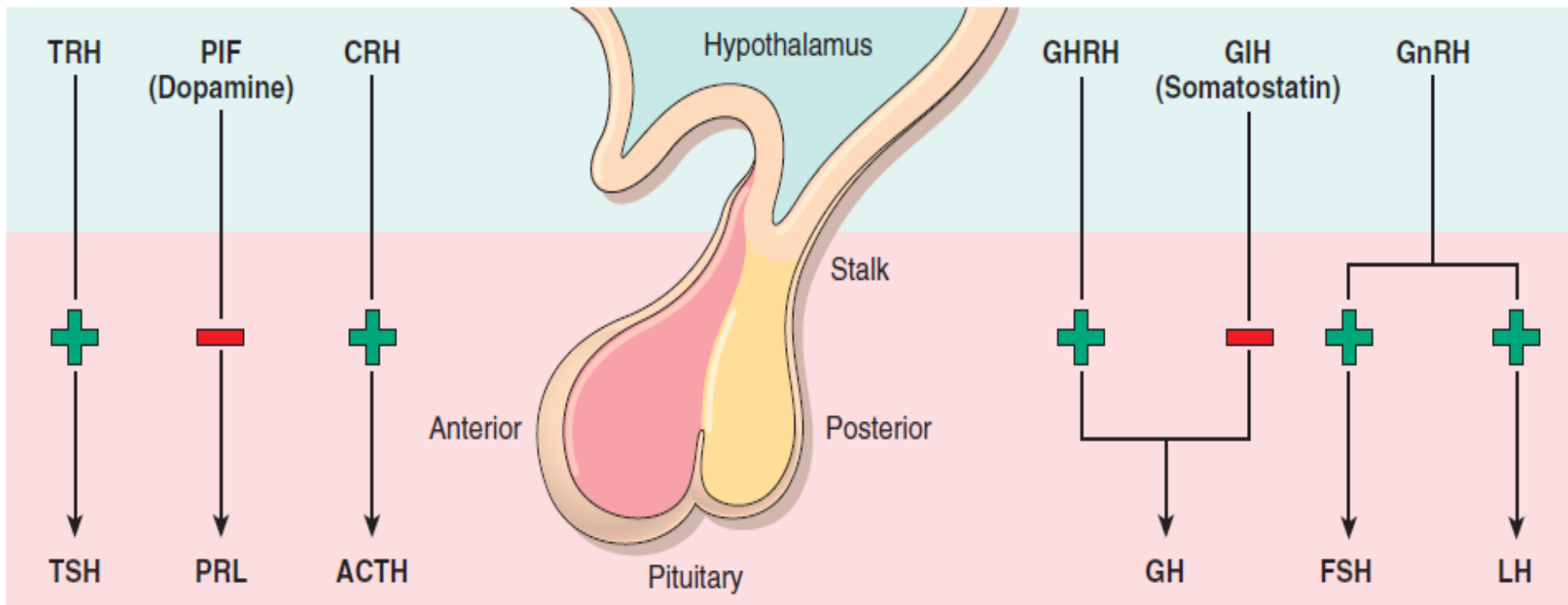


Fig. 18-10. The pituitary gland.

Copyright © 2007, 2004 by Saunders, an imprint of Elsevier Inc. All rights reserved.



The adenohypophysis (anterior pituitary) releases six hormones: adrenocorticotrophic hormone (ACTH), or corticotropin; folliclestimulating hormone (FSH); growth hormone (GH), or somatotropin; luteinizing hormone (LH); prolactin (PRL); and thyroid-stimulating hormone(TSH), or thyrotropin.

These hormones are in turn under the control of various stimulatory and inhibitory hypothalamic releasing factors. The *stimulatory* releasing factors are corticotropin-releasing hormone (CRH), growth hormone–releasing hormone (GHRH), gonadotropin-releasing hormone (GnRH), and thyrotropin-releasing hormone (TRH). The *inhibitory* hypothalamic factors are growth hormone inhibitory hormone (GIH), or somatostatin, and prolactin inhibitory factor (PIF), which is the same as dopamine.

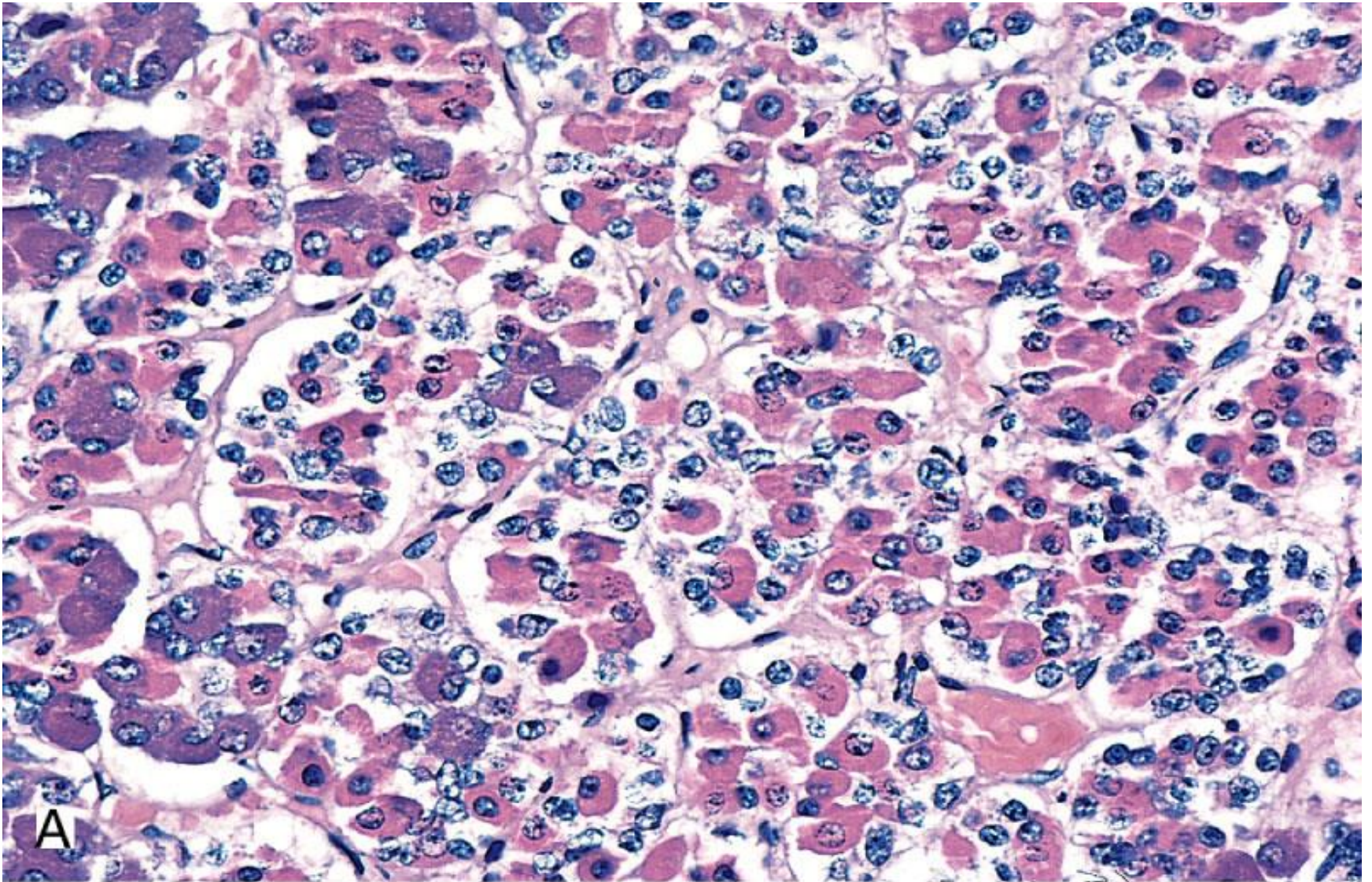


Fig. 24-2. A, Photomicrograph of normal pituitary. The gland is populated by several distinct cell populations containing a variety of stimulating (trophic) hormones.

Elsevier items and derived items 2005 by Elsevier Inc.

# Pituitary

The following clinical manifestations are characteristic of pituitary diseases:

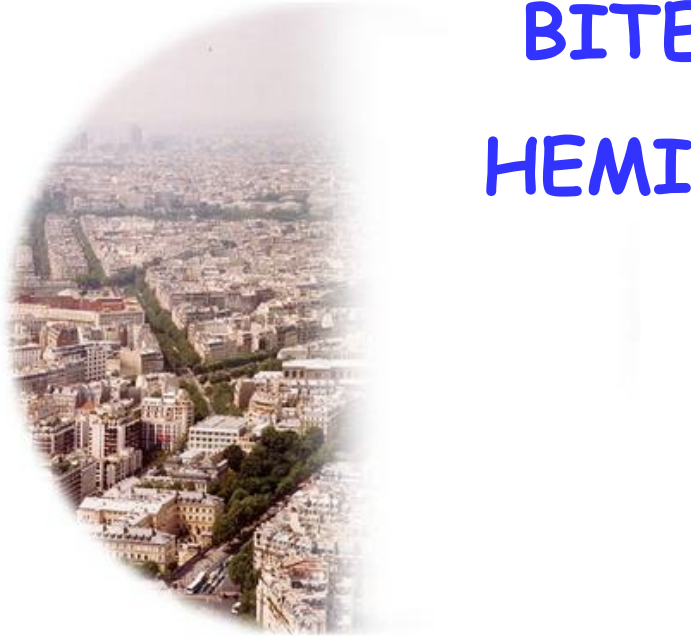- Hyperpituitarism. It is observed with excessive secretion of tropic hormones. The causes may be pituitary adenoma, hyperplasia and carcinoma of the anterior pituitary gland, hormone production by tumors located outside the pituitary gland, and some lesions of the hypothalamus.

# Pituitary

Hypopituitarism. It is observed with a deficiency of tropic hormones. This can be caused by a variety of destructive processes, including ischemic damage, surgery, radiation exposure, inflammation, and non-functioning pituitary adenoma.

# Pituitary

Mass effect (effect of volume formations). The earliest changes due to the mass effect are the x-ray changes of the Turkish saddle, including its expansion, bone erosion and rupture of the diaphragm of the Turkish saddle. Since the optic nerves and the optic cross (chiasm) are located in the immediate vicinity of the Turkish saddle, the extensive growth of pituitary tumors often leads to compression of the fibers in the area of the visual intersection. This causes visual field disturbances, usually defects in the lateral (temporal) visual fields (bilateral temporal hemianopsia).



# BITEMPORAL HEMIANOPSIA

# Hyperpituitarism

The most common cause of hyperpituitarism is pituitary adenoma. Pituitary adenomas are classified according to the hormone or hormones produced by tumor cells.

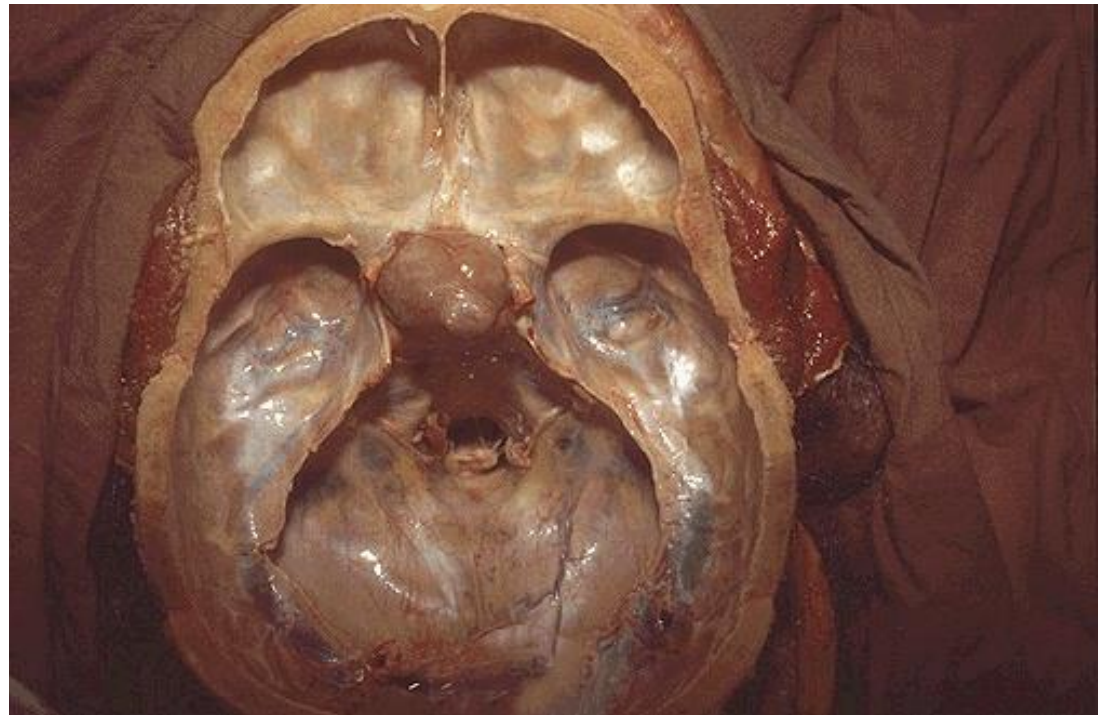
## Classification of pituitary adenomas

Pituitary Cell Type	Hormone	Tumor Type	Associated Syndrome*
Corticotroph	ACTH and other POMC-derived peptides	Densely granulated Sparsely granulated	Cushing syndrome Nelson syndrome
Somatotroph	GH	Densely granulated Sparsely granulated	Gigantism (children) Acromegaly (adults)
Lactotroph	Prolactin	Densely granulated Sparsely granulated	Galactorrhea and amenorrhea (in females) Sexual dysfunction, infertility
Mammomatotroph	Prolactin, GH	Mammomatotroph	Combined features of GH and prolactin excess
Thyrotroph	TSH	Thyrotroph	Hyperthyroidism
Gonadotroph	FSH, LH	Gonadotroph, "null cell," oncocytic adenomas	Hypogonadism, mass effects and hypopituitarism



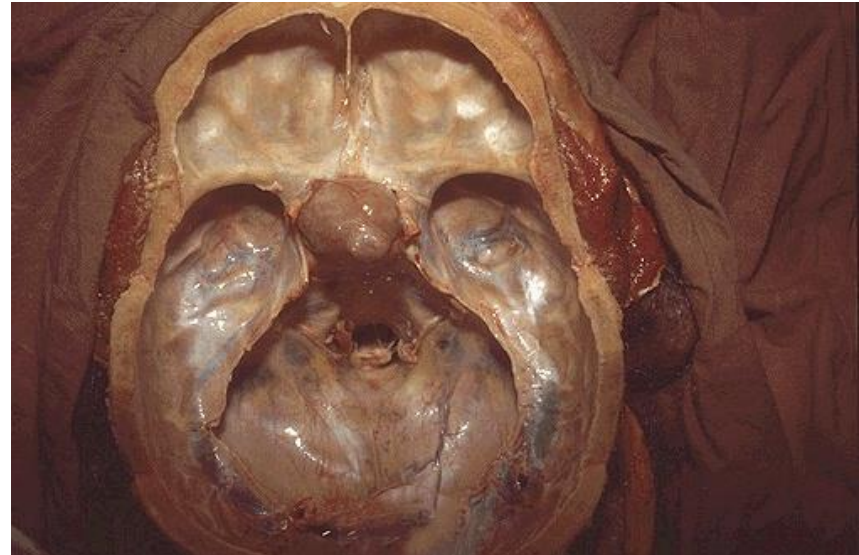
# Hyperpituitarism

Morphology. A typical pituitary adenoma is a soft, well-defined formation located in the Turkish saddle. Large formations usually spread upward through the diaphragm of the Turkish saddle to the suprasellar region, where the visual cross and adjacent structures, such as cranial nerves.

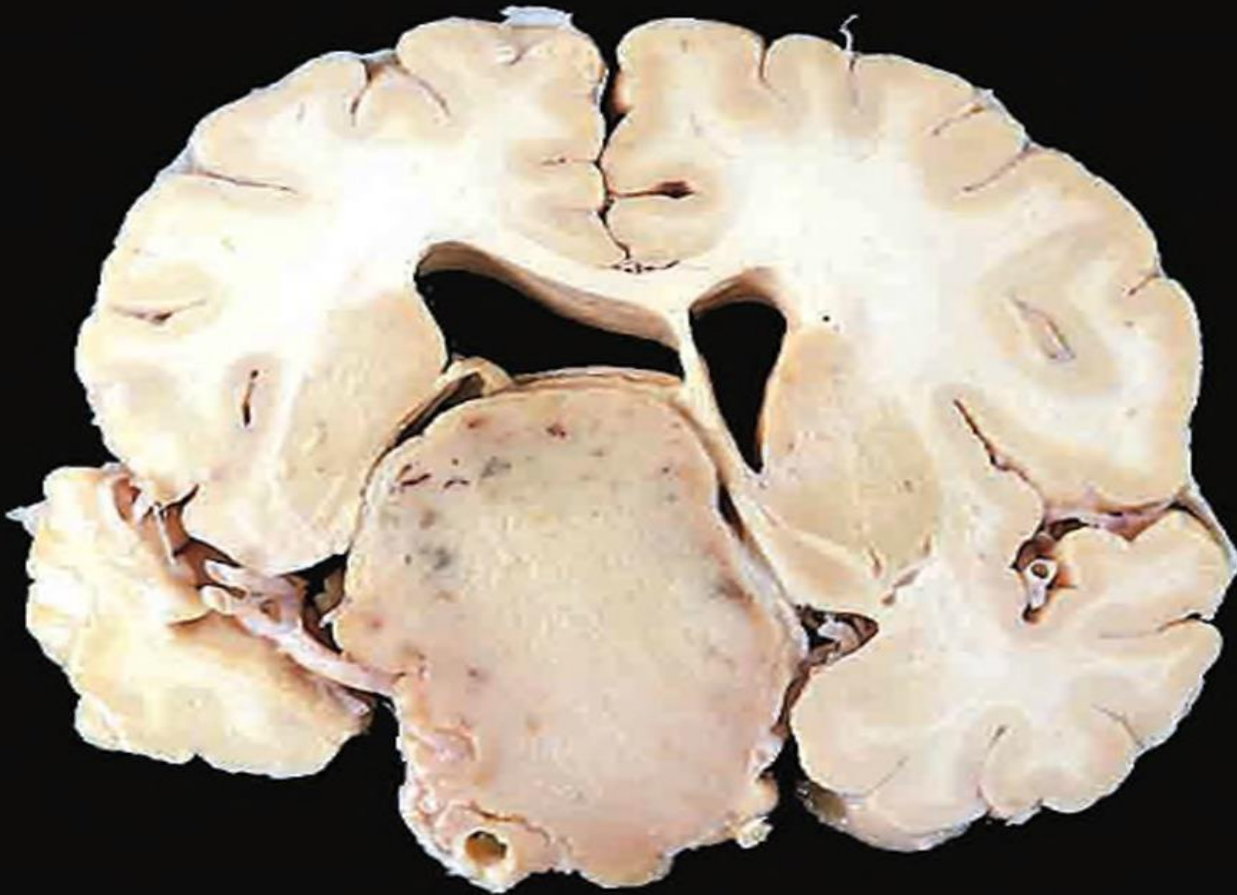


# Hyperpituitarism

In = 30% of observations with a macroscopic examination of adenomas, it is clear that they do not have a capsule and infiltrate adjacent tissues: cavernous and wedge-shaped sinuses, dura mater and sometimes the brain. Such formations are referred to by the term "invasive adenoma". Unsurprisingly, macroadenomas are more often invasive than small tumors. Also, in large tumors, hemorrhages and necrosis zones are more often observed.

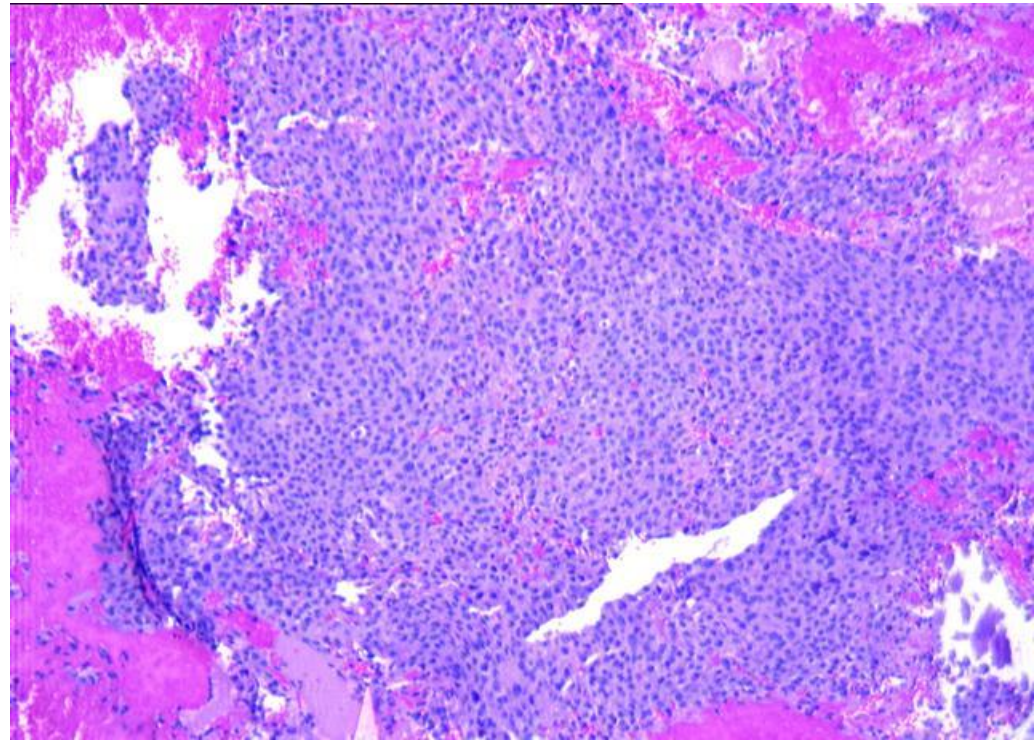


Pituitary adenoma. A large non-functioning adenoma extends far beyond the Turkish saddle and deforms the adjacent structures of the brain. Non-functioning adenomas at the time of diagnosis are usually larger than functioning adenomas.



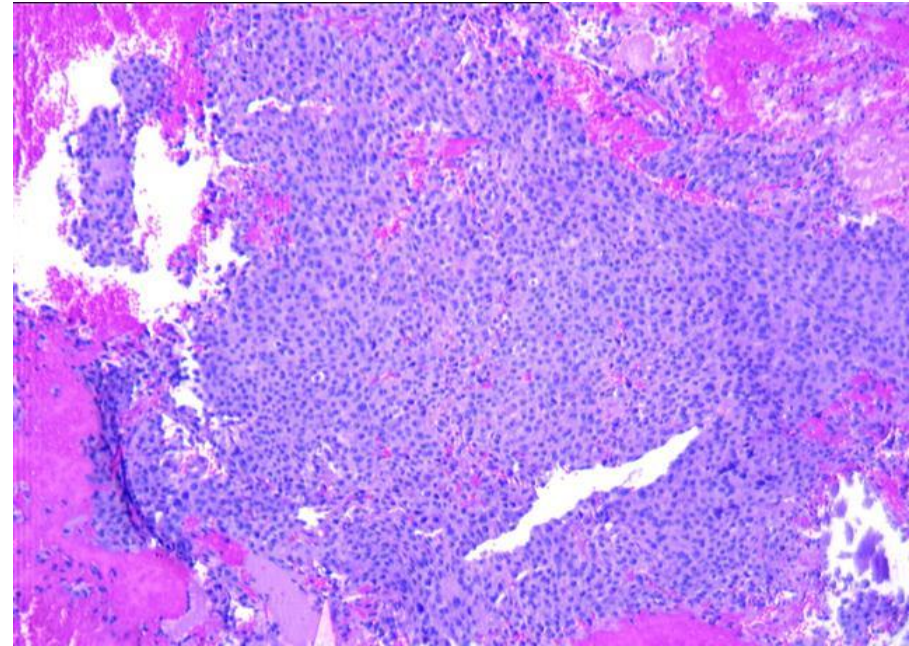
# Hyperpituitarism

In histological examination, typical pituitary adenomas consist of relatively homogeneous polygonal cells located in the form of layers or cords. The poorly expressed connective tissue surrounding these cells, or reticulin, determines the soft, gelatinous consistency of many such formations.

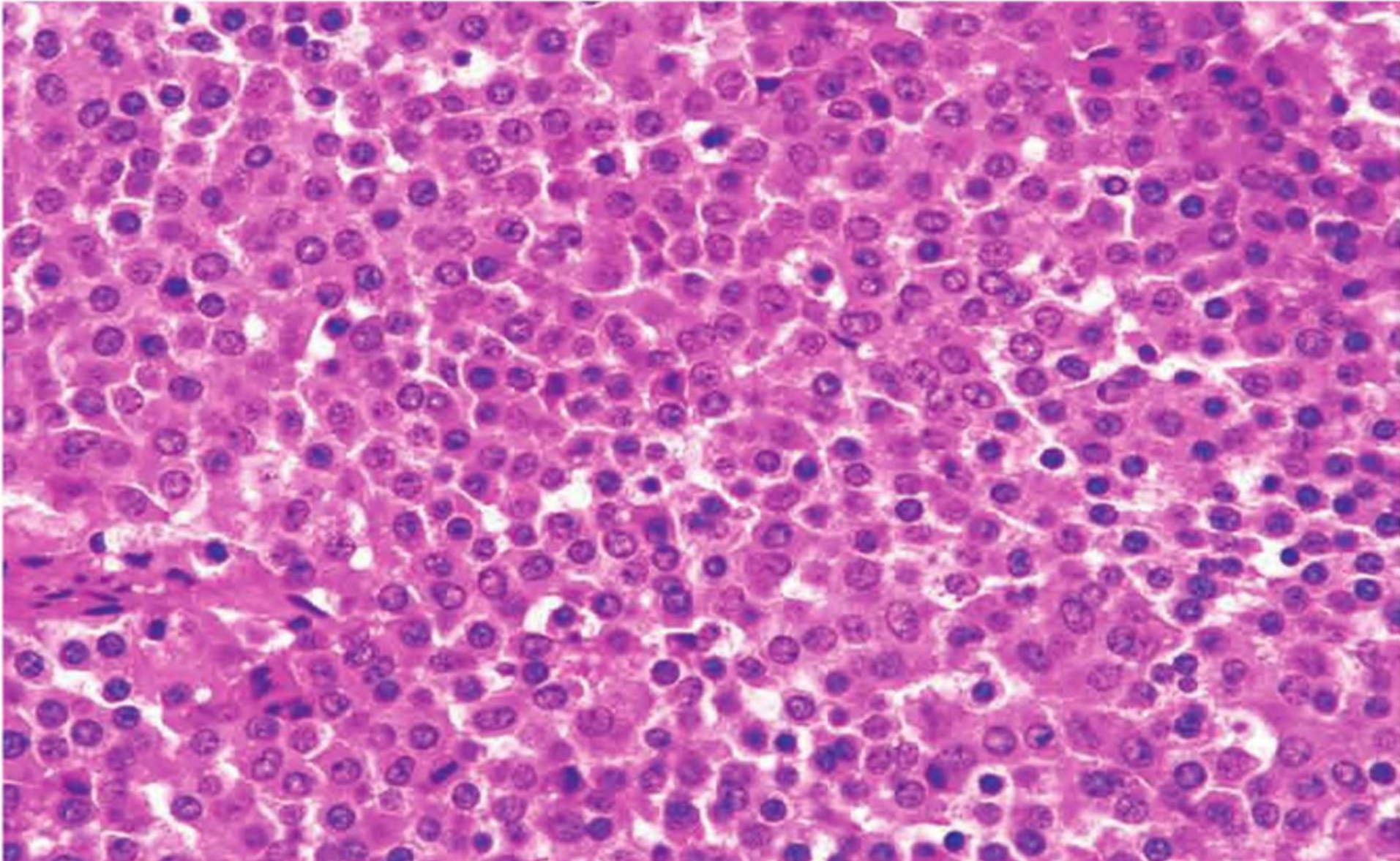


# Hyperpituitarism

Mitotic activity of tumor cells is usually low, the cytoplasm may be acidophilic, basophilic or chromophobic depending on the type and amount of secretion in the cells, but usually it is the same in all tumor cells. Such monomorphism of cells and the absence of a pronounced reticulin network distinguish pituitary adenomas from the normal parenchyma of the anterior pituitary gland.



Pituitary adenoma. The accumulation of monomorphic cells contrasts sharply with the heterogeneous cells of the normal anterior pituitary gland. Reticulin network is absent.

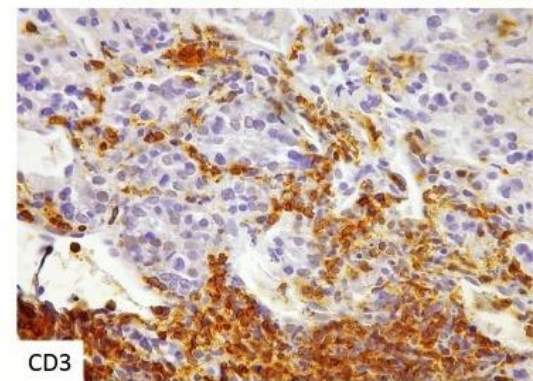
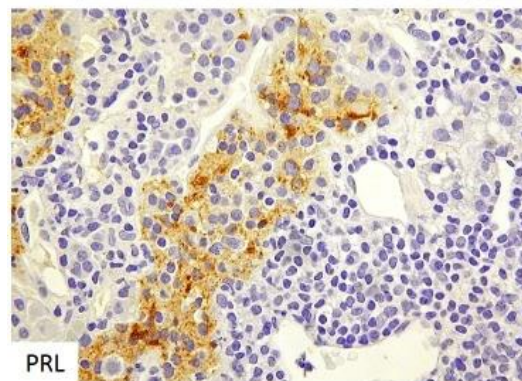
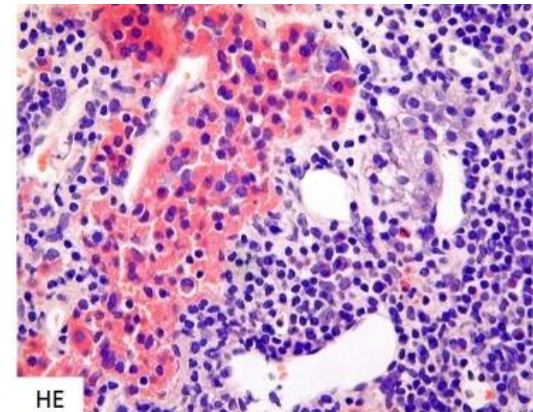
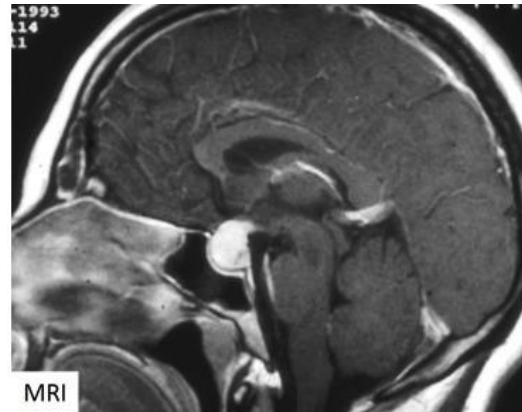


## Lactotrophic pituitary adenomas

Lactotropic adenomas (prolactinomas) are the most common type of hyperfunctional pituitary adenomas, accounting for ~ 30% of all clinically significant pituitary adenomas. These formations can be microadenomas or large common tumors, accompanied by pronounced signs of mass effect.

# Lactotrophic pituitary adenomas

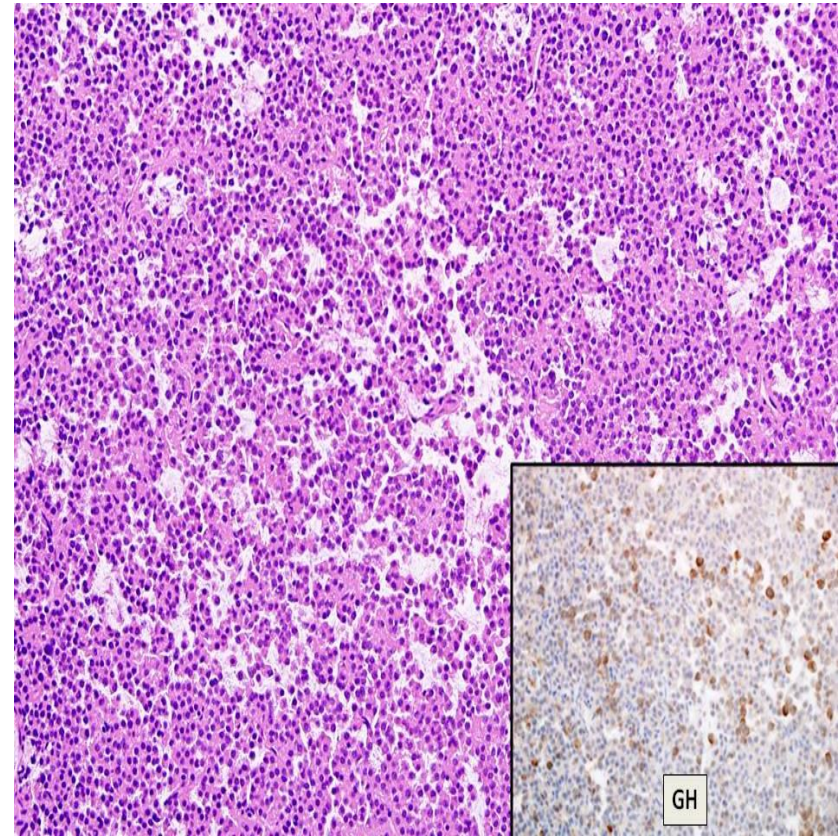
Prolactinemia (increased serum prolactin concentration) causes amenorrhea, galactorrhea, decreased libido and infertility. Lactotrophic adenomas are diagnosed, as a rule, in women aged 20-40 years, since menstrual dysfunction occurs in hyperprolactinemia.





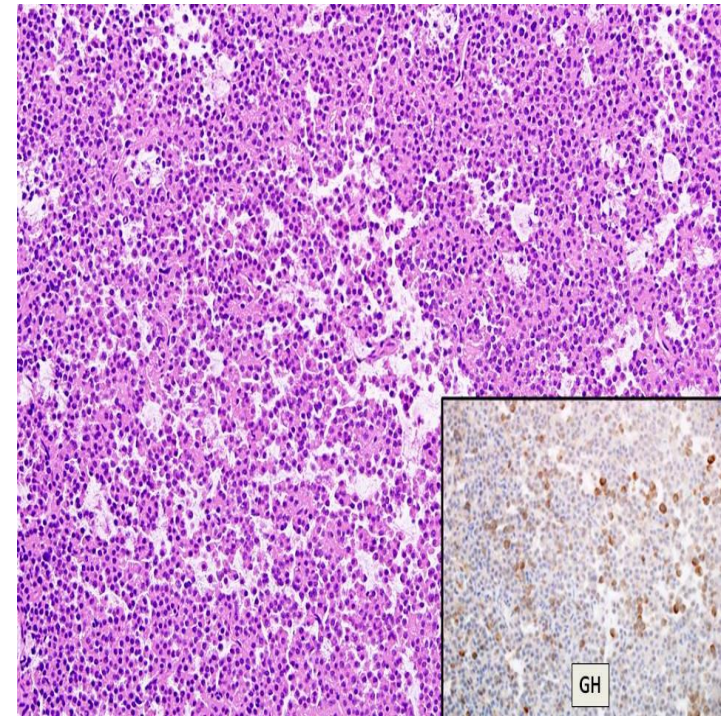
# Somatotrophic pituitary adenomas

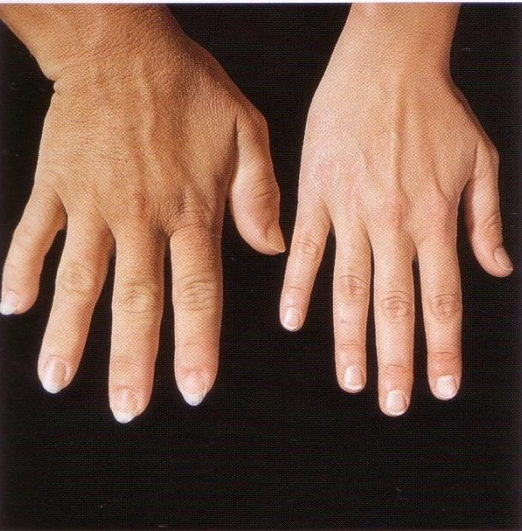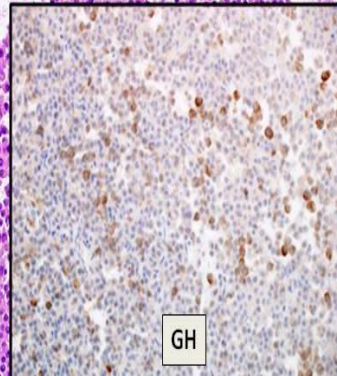
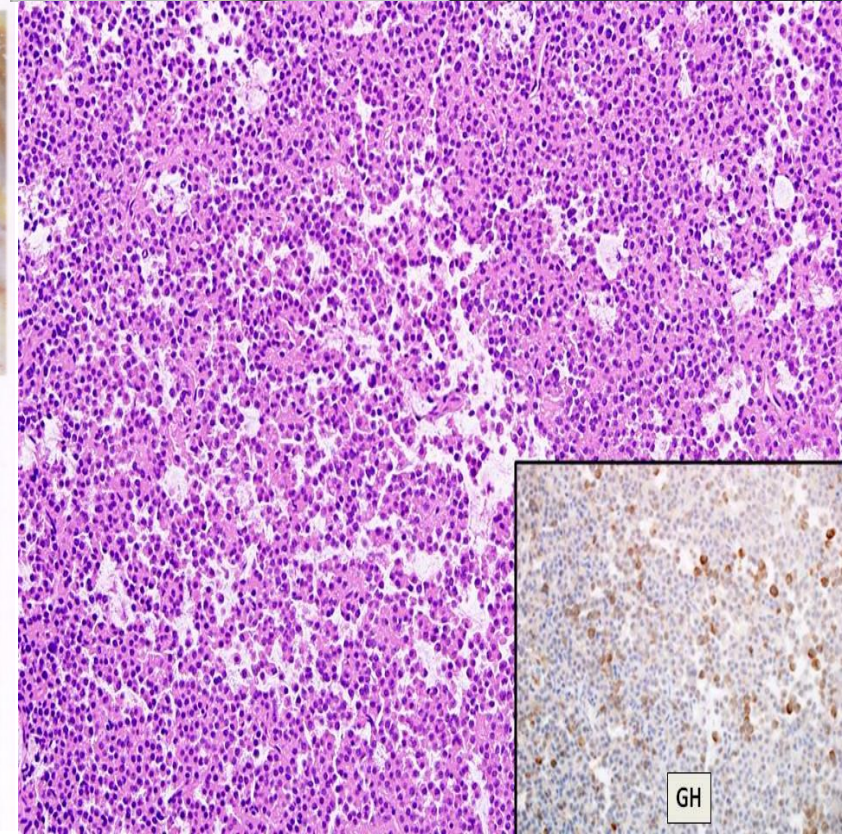
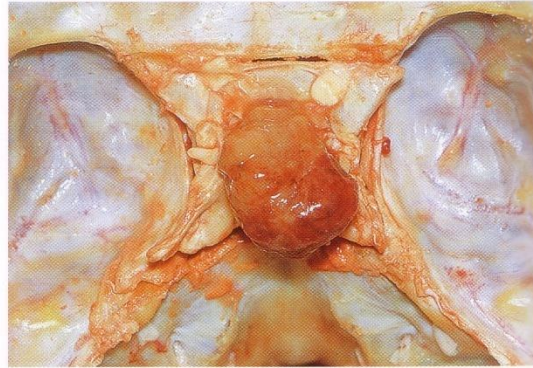
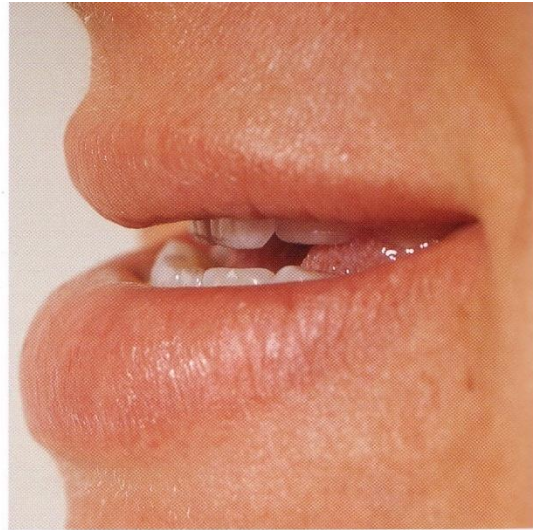
GH-producing tumors are the second most common type of functioning pituitary adenoma. Somatotrophic adenomas can reach very large sizes at the time of diagnosis, since increased secretion of GH and the associated symptoms may be negligible.



## Somatotrophic pituitary adenomas

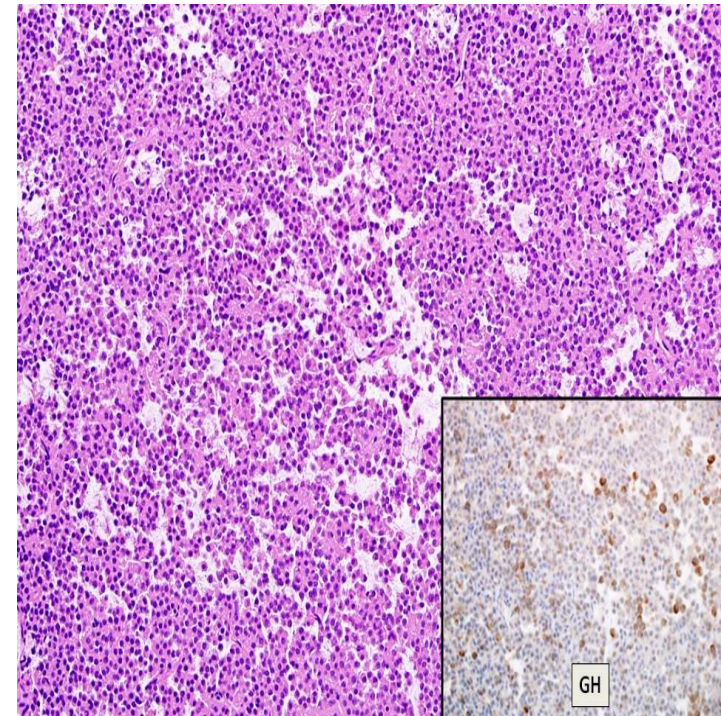
If growth hormone adenoma develops in a child up to the closing of growth zones in the epiphysis of long bones, high levels of GH (and IGF-1) lead to gigantism. Gigantism is characterized by a general increase in body size and disproportionately long limbs. If the GH level rises after the closure of growth zones, acromegaly develops.





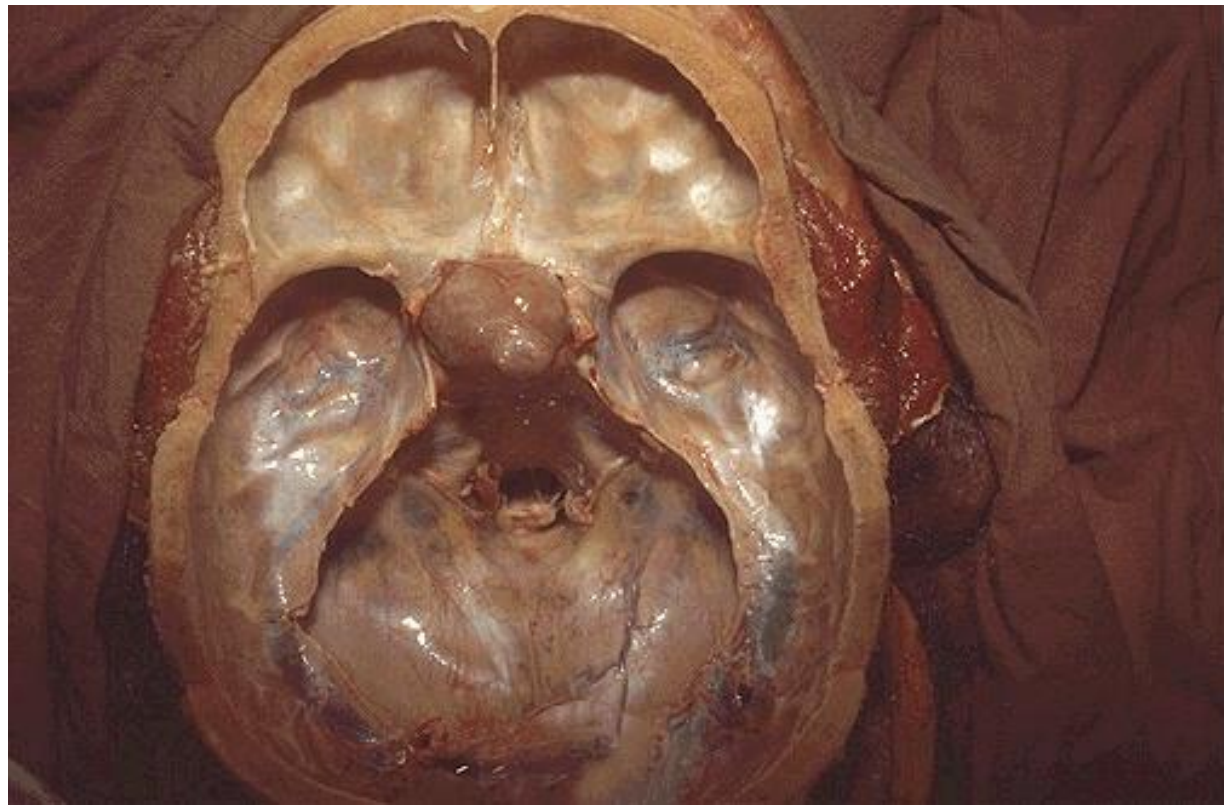
# Corticotrophic pituitary adenomas

If growth hormone adenoma develops in a child up to the closing of growth zones in the epiphysis of long bones, high levels of GH (and IGF-1) lead to gigantism. Gigantism is characterized by a general increase in body size and disproportionately long limbs. If the GH level rises after the closure of growth zones, acromegaly develops.



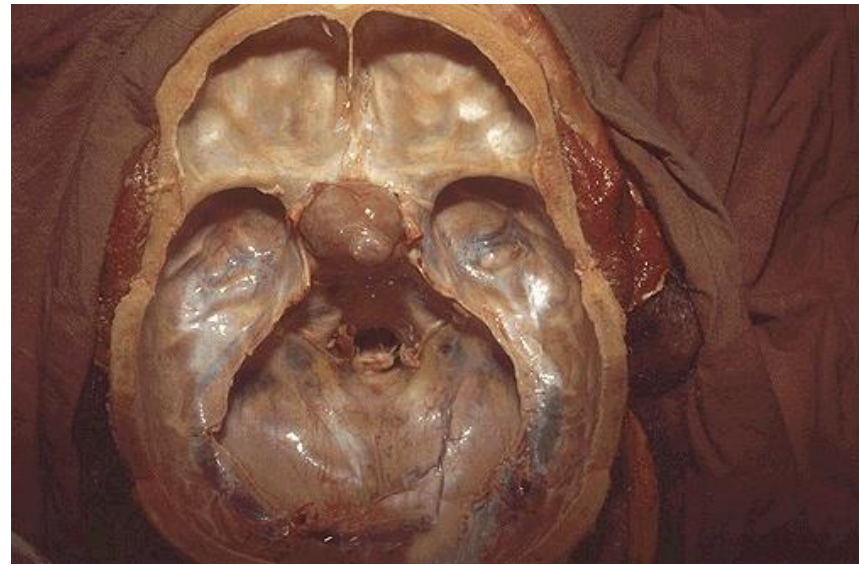
## Corticotrophic pituitary adenomas

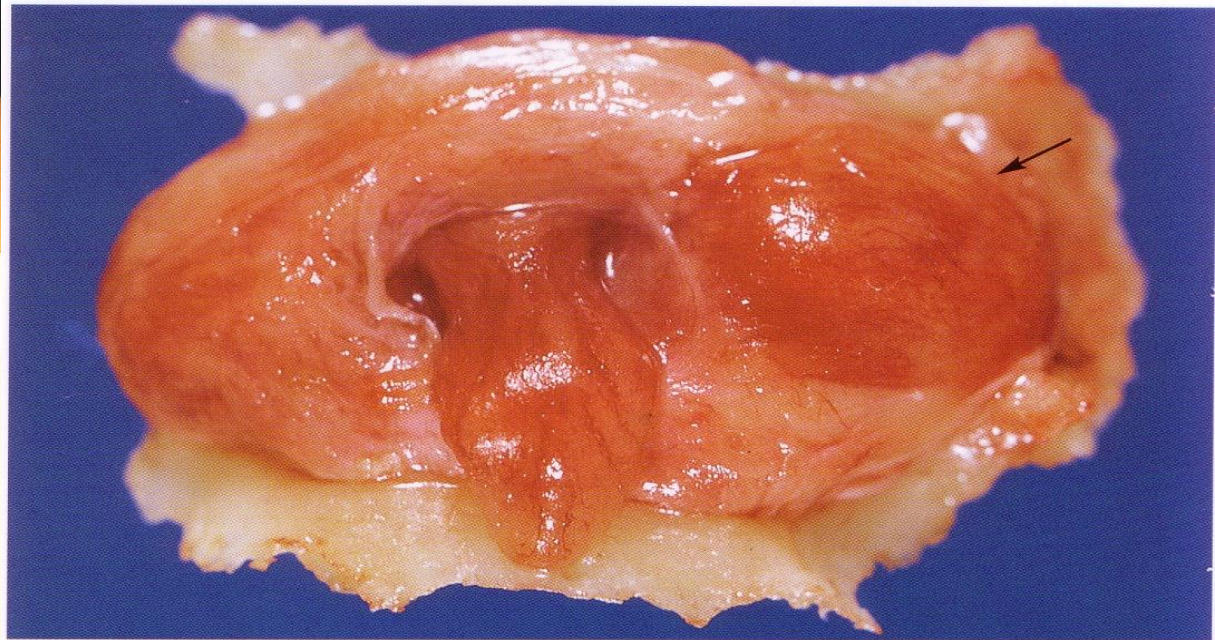
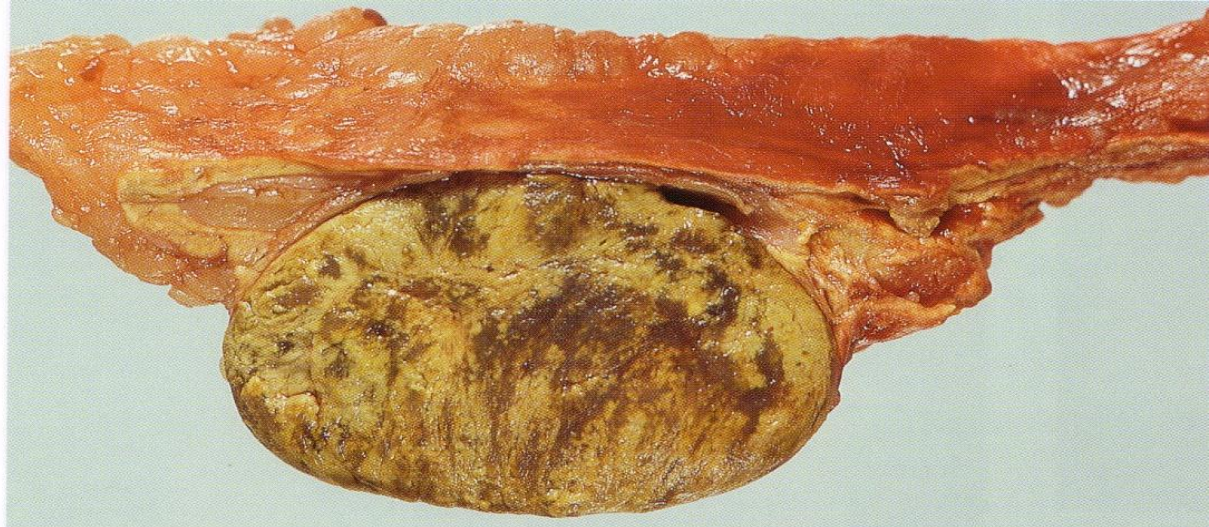
At the time of diagnosis, corticotrophic adenomas are usually microadenomas. These tumors are most often basophilic, severely granular and occasionally chromophobic.



## Corticotrophic pituitary adenomas

Excessive production of ACTH by a corticotrophic adenoma leads to hypersecretion of the adrenal cortisol and the development of Cushing's disease. In patients after surgical removal of the adrenal glands in order to treat Cushing's syndrome, large pituitary adenomas with a destructive growth type can form. This condition, called Nelson's syndrome, develops most often due to the lack of inhibitory effects of corticosteroids on corticotrophic microadenomas.

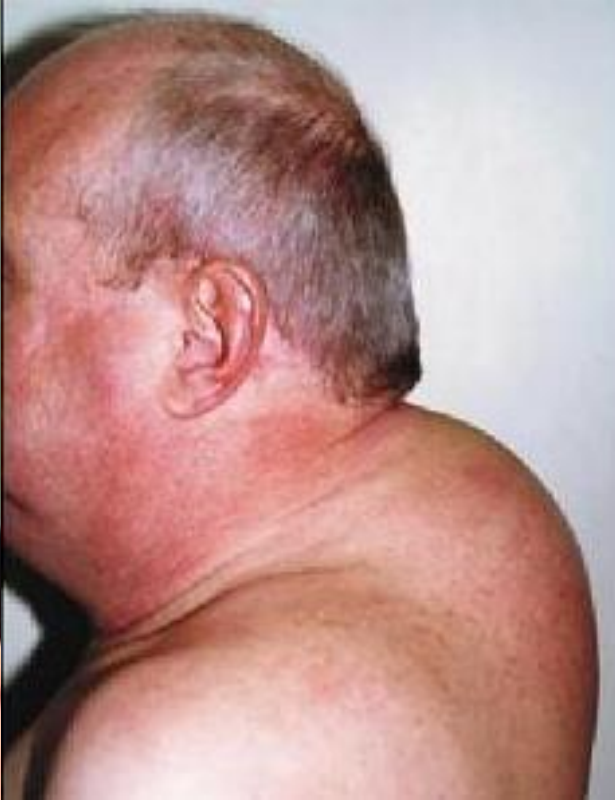



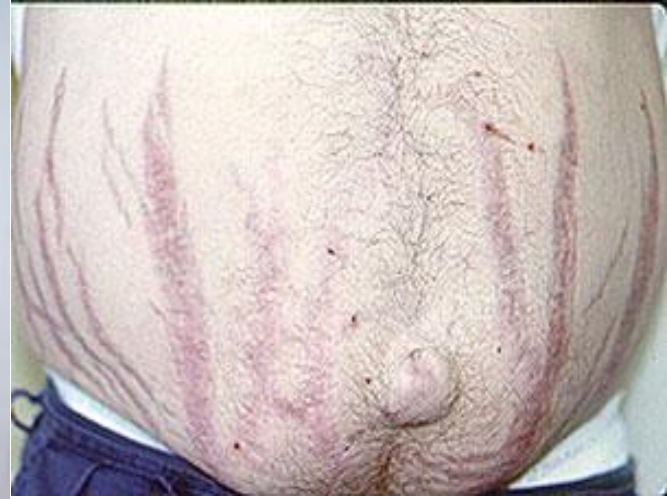**Cushing's Syndrome  
(adrenal adenoma and pituitary basophilic adenoma).**



**MOON  
FACIES**



**BUFFALO  
HUMP**



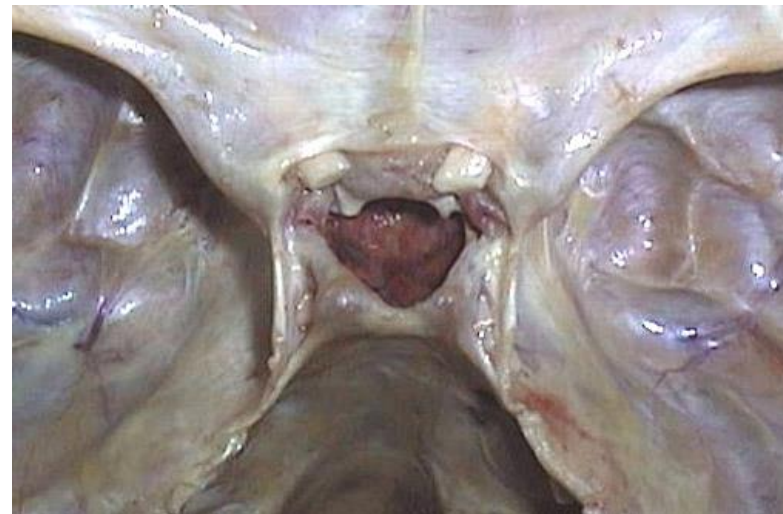**STRIAE**



# Hypopituitarism

Hypopituitarism is the result of pathology of the hypothalamus or pituitary gland. Hypofunction of the anterior pituitary gland is observed when ~ 25% of its parenchyma remains.

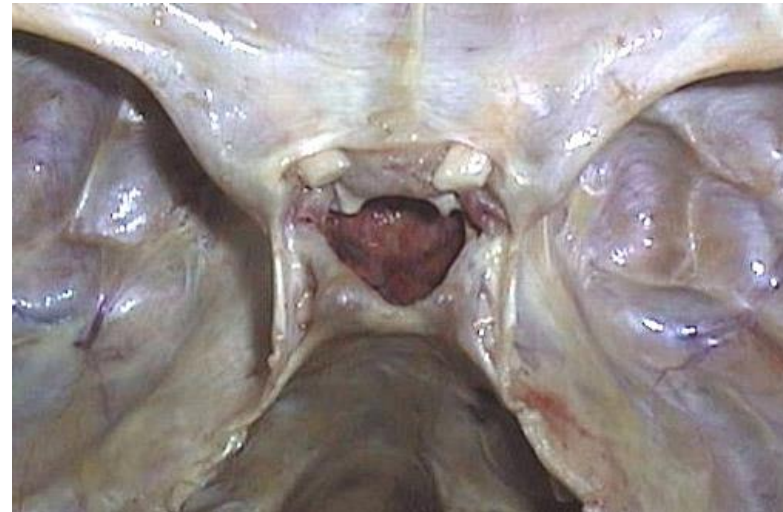***Tumors and other volume formations.*** Hypopituitarism can cause pituitary adenomas, other benign tumors in the Turkish saddle, primary and metastatic malignancies, as well as cysts. Any volume formation in the region of the Turkish saddle can cause damage to the pituitary gland due to compression of its cells.



# Hypopituitarism

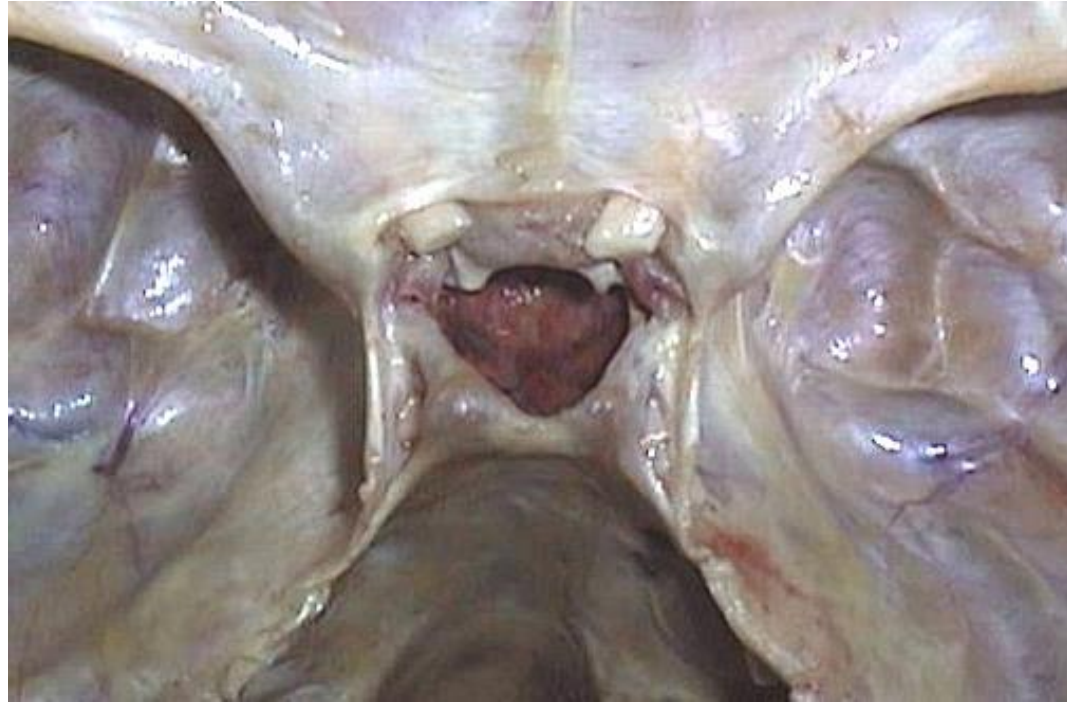**Traumatic brain damage and subarachnoid hemorrhage.** This is one of the common causes of pituitary hypofunction.

**Surgery on the pituitary gland or exposure to radiation.** During surgical excision of the pituitary adenoma, unaffected pituitary tissue may be accidentally removed or damaged. Irradiation of the pituitary zone to prevent re-growth of the tumor after surgical excision can also lead to organ damage.



# Hypopituitarism

**Pituitary apoplexy.** This is a frequent sudden hemorrhage in the pituitary adenoma. Classic clinical picture: sudden excruciating headache, diplopia due to compression of the oculomotor nerves and hypopituitarism. In severe cases, pituitary apoplexy can cause cardiovascular collapse, loss of consciousness, and even sudden death. Thus, pituitary apoplexy is a condition in which emergency neurosurgical intervention is necessary.

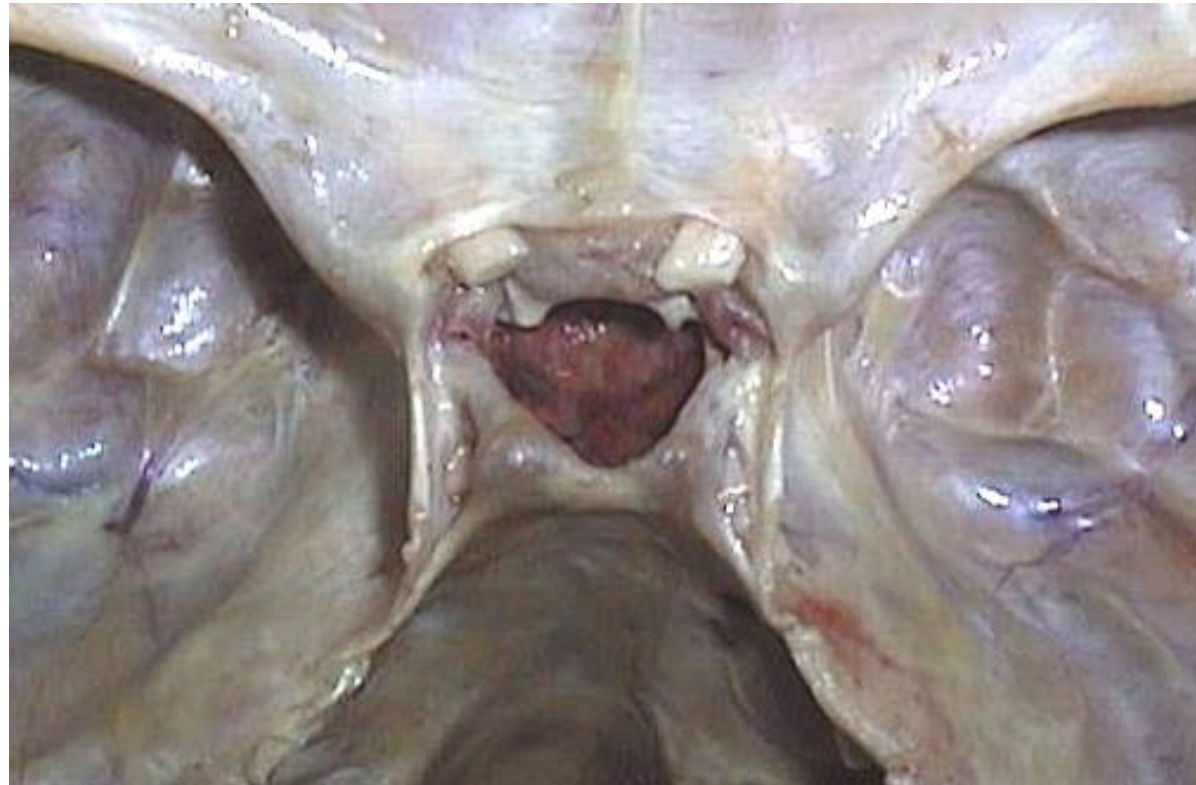

# Hypopituitarism

Ischemic necrosis of the pituitary gland and Sheehan's syndrome (postpartum necrosis of the anterior pituitary gland) is the most common form of clinically significant ischemic necrosis of the anterior pituitary gland. During pregnancy, the volume of the anterior pituitary gland increases by ~ 2 times. Such a physiological enlargement of the gland is not accompanied by an increase in its blood supply from the venous system with low blood pressure. Thus, during pregnancy, relative hypoxia of the pituitary gland is observed. A sharp decrease in the volume of circulating blood, caused, for example, by uterine bleeding or shock, can lead to infarction of the anterior pituitary gland.

## Pituitary Syndromes

The posterior pituitary gland, which receives blood from arteries, is much less susceptible to ischemic damage, so it is usually not damaged. Pituitary necrosis is also observed in disseminated intravascular coagulation and (much less frequently) in sickle cell anemia, increased intracranial pressure, trauma, as well as in shock of any origin.



# Thyroid

Secretes thyroxine (tetraiodothyronine) (T4) and triiodothyronine (T3).

These are hormones synthesized from iodine from the bloodstream; necessary to maintain metabolism by helping cells take in oxygen.

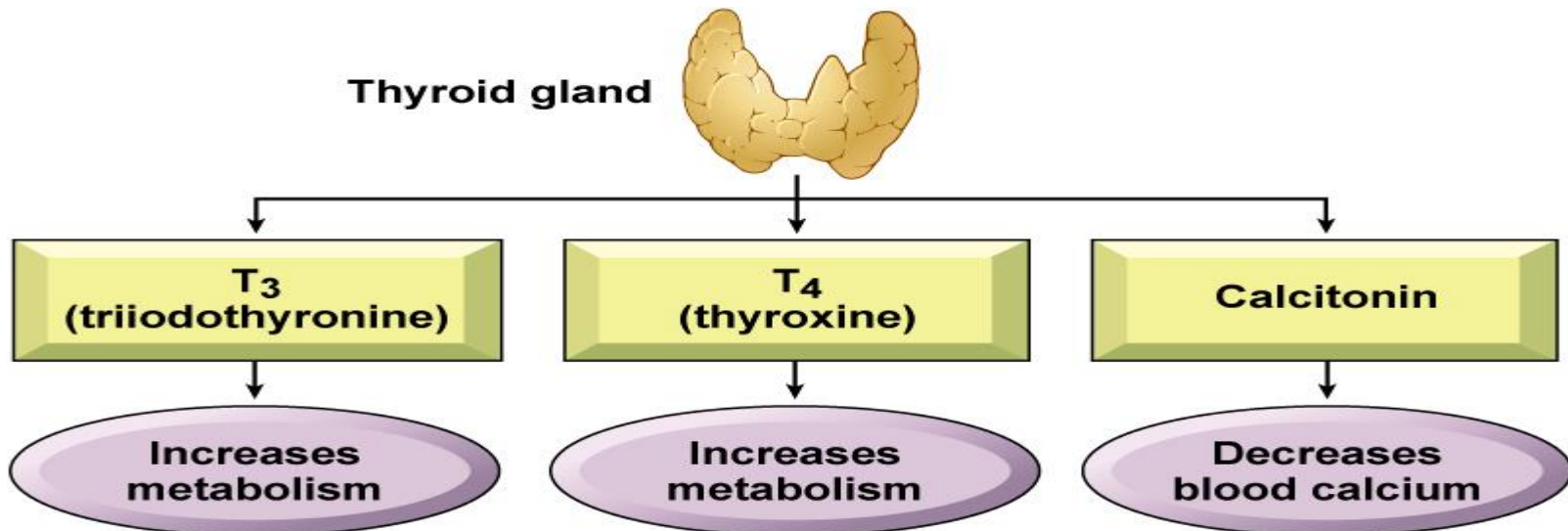
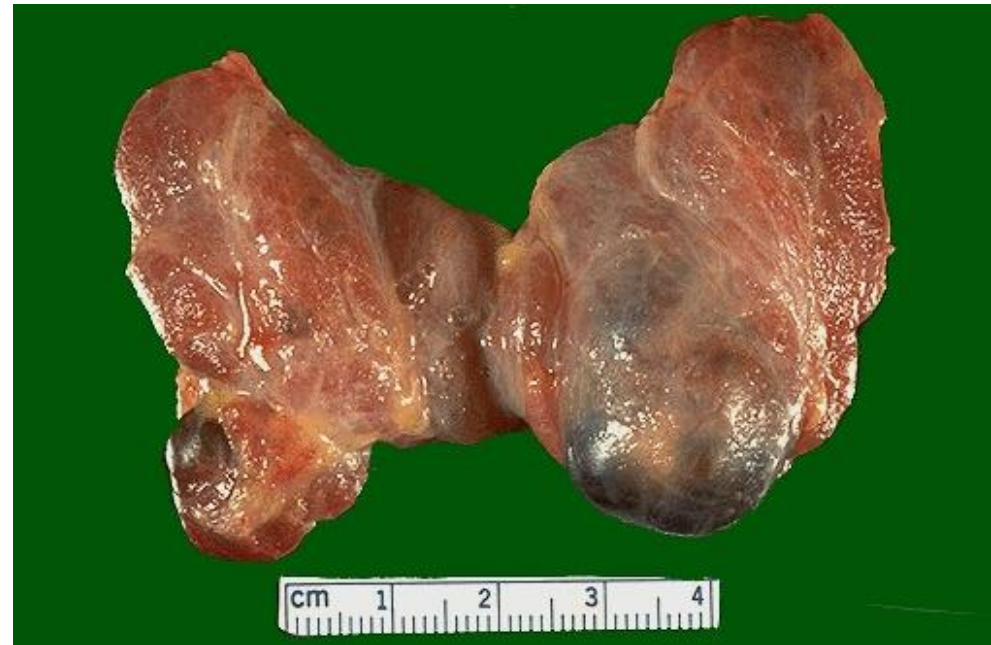

Fig. 18-3. The thyroid gland: its hormones and actions.

# Diseases of the Thyroid Gland

- Congenital diseases
- Inflammation
- Functional abnormality
- Diffuse and Multinodular goiters
- Neoplasia



# Overview

- **Benign Pathology**

- Grave's Disease
- Hashimoto's Thyroiditis
- Multi-nodular goiter
- Follicular Adenoma

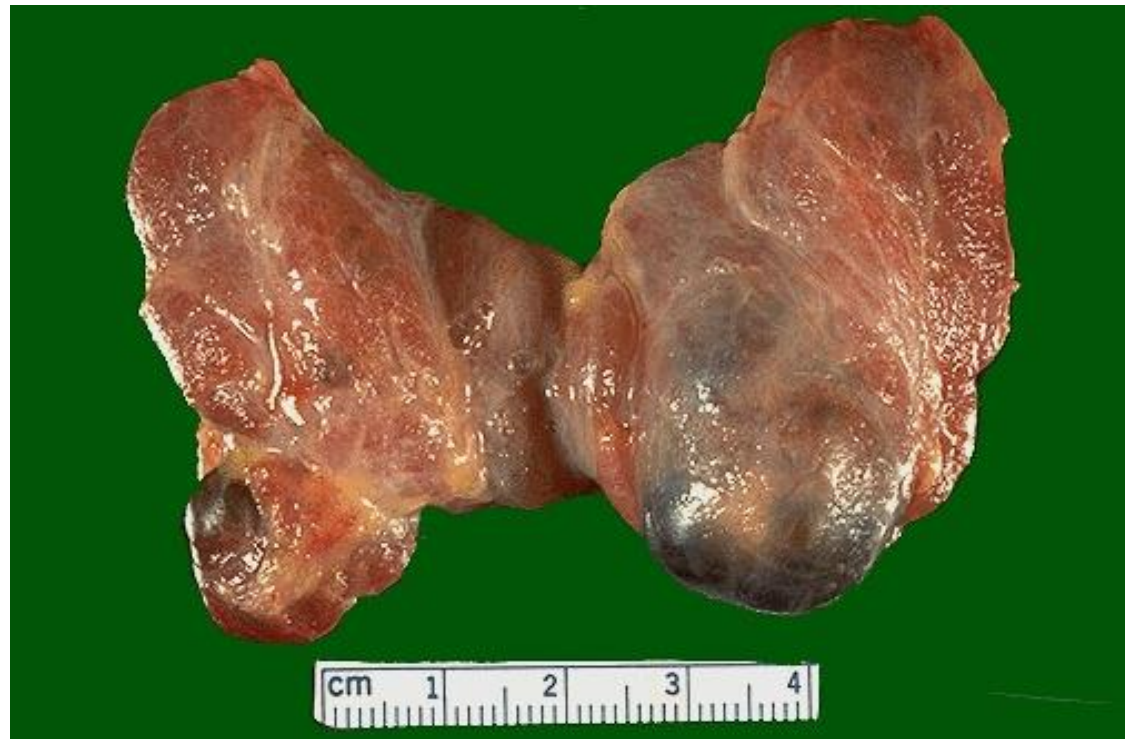- **Malignant Pathology**

- Papillary Carcinoma
- Follicular Carcinoma
- Medullary Carcinoma
- Anaplastic Carcinoma



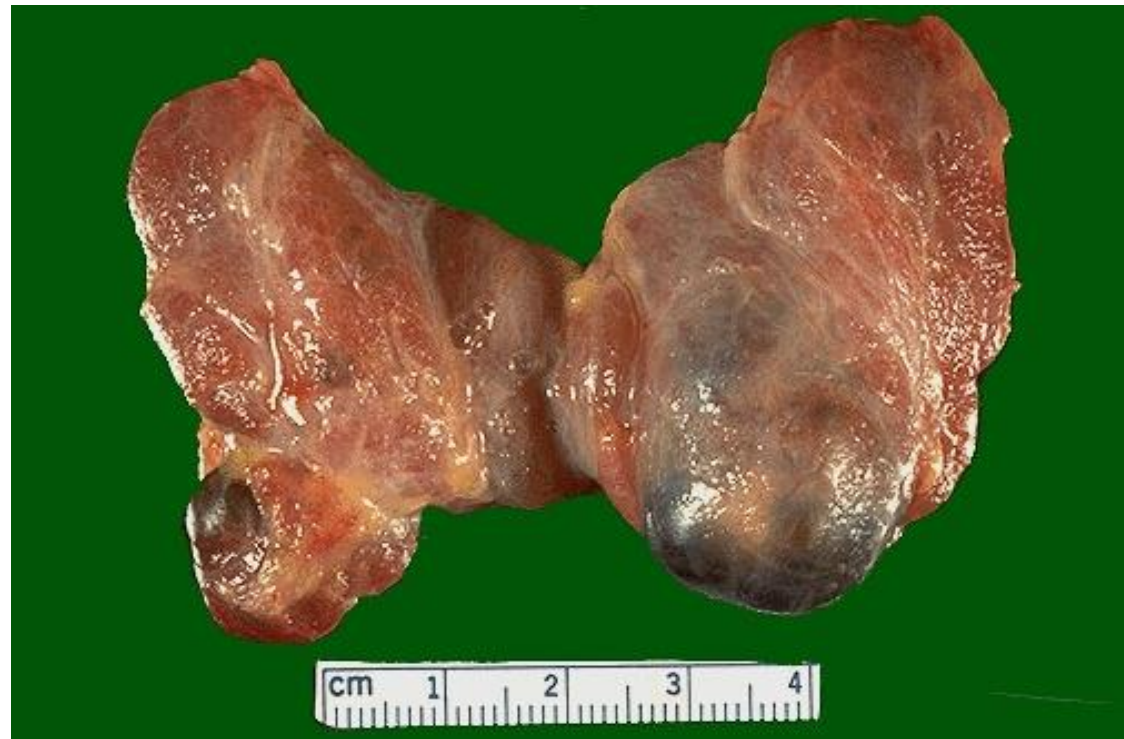# Diseases of the Thyroid Gland

Thyroid diseases include conditions accompanied by excessive secretion of thyroid hormones (hyperthyroidism), thyroid hormone deficiency (hypothyroidism), as well as a mass effect.



# Hyperthyroidism

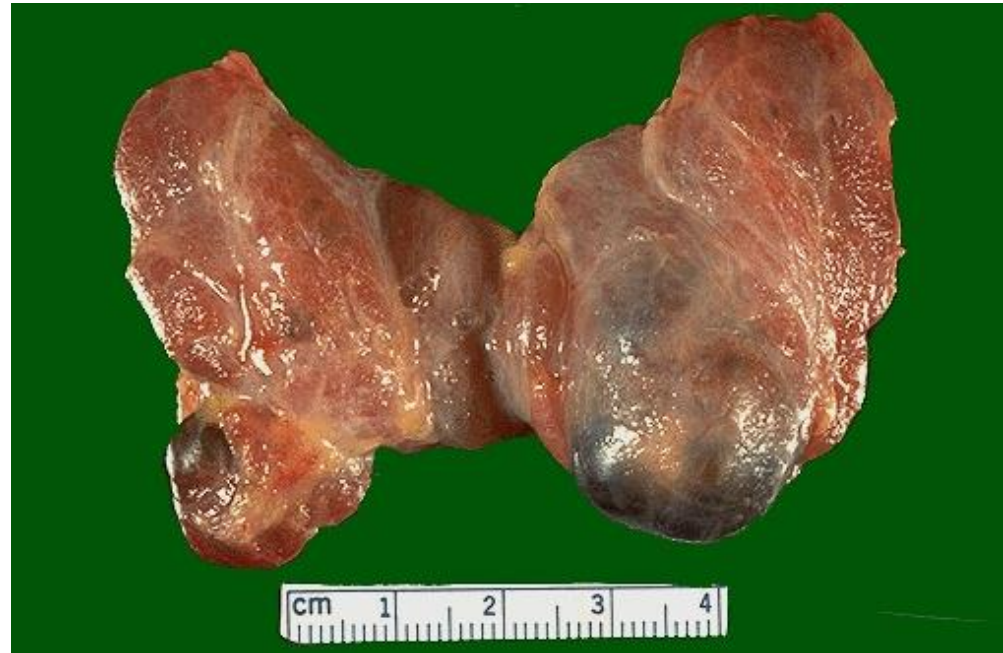An increased metabolism caused by high levels of free T3 and T4 circulating in the blood is called thyrotoxicosis. This condition is most often associated with thyroid hyperfunction (hyperthyroidism).



# Hyperthyroidism

The 3 most common causes of thyrotoxicosis:

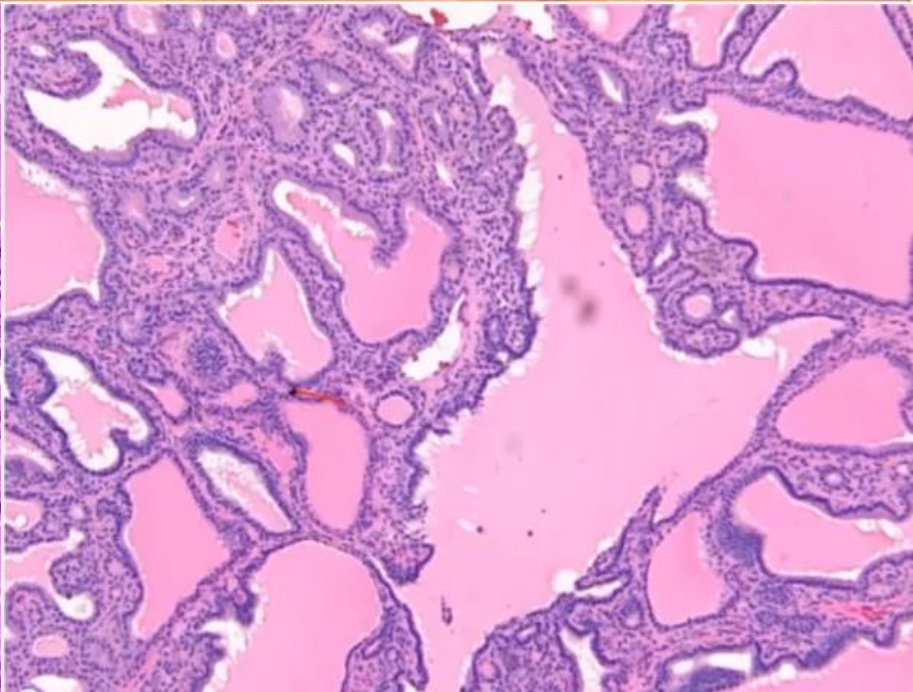
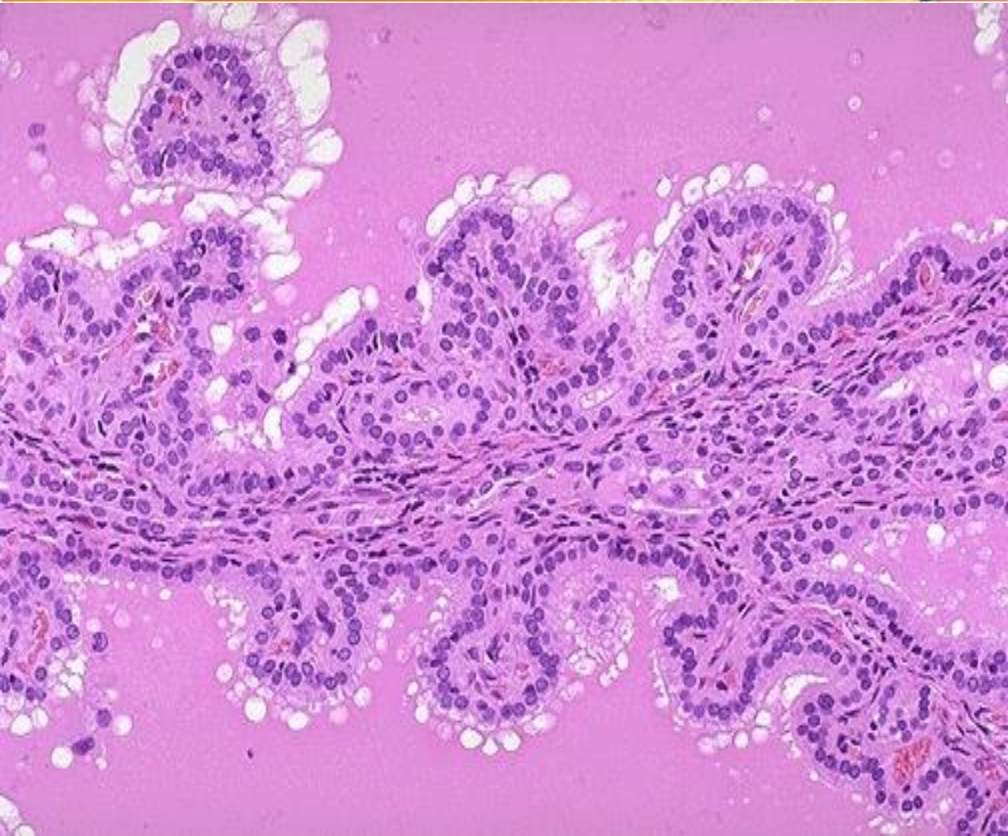
- diffuse thyroid hyperplasia associated with Graves disease (85% of cases);
- hyperfunctional multinodular goiter;
- hyperfunctional thyroid adenoma.



# Graves disease

The most common cause of endogenous hyperthyroidism is characterized by a triad of symptoms:

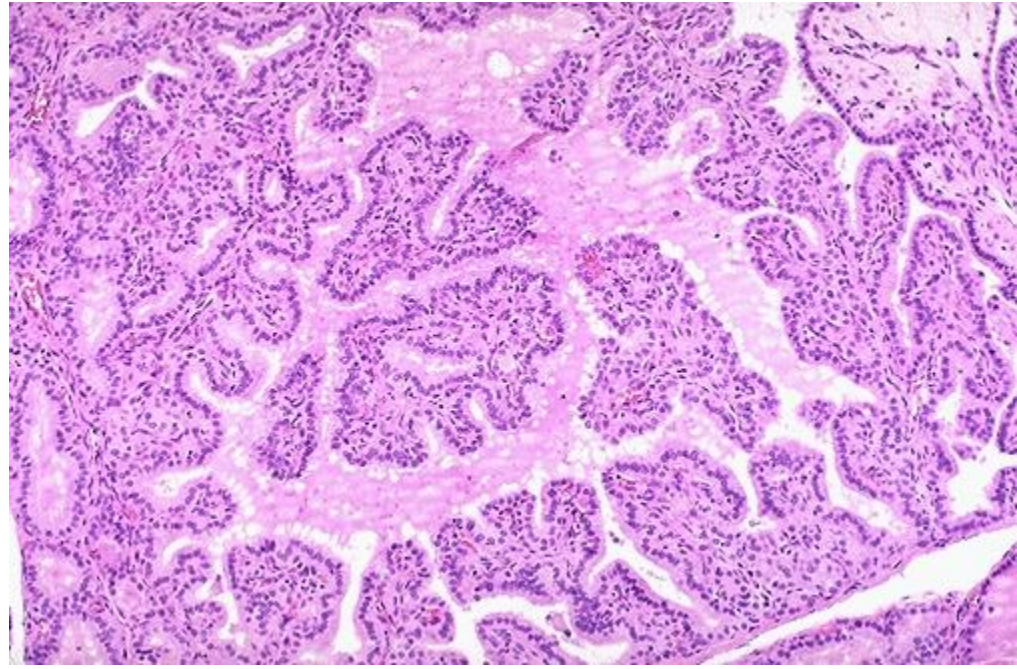
- hyperthyroidism due to diffuse hyperfunctional enlargement of the thyroid gland;
- infiltrative ophthalmopathy with the development of exophthalmos;
- focal infiltrative dermatopathy, which is sometimes called pretibial myxedema and is observed in a small number of patients.



# Graves disease

Graves' disease is characterized by impaired tolerance to thyroid autoantigens, primarily to the TSH receptor.

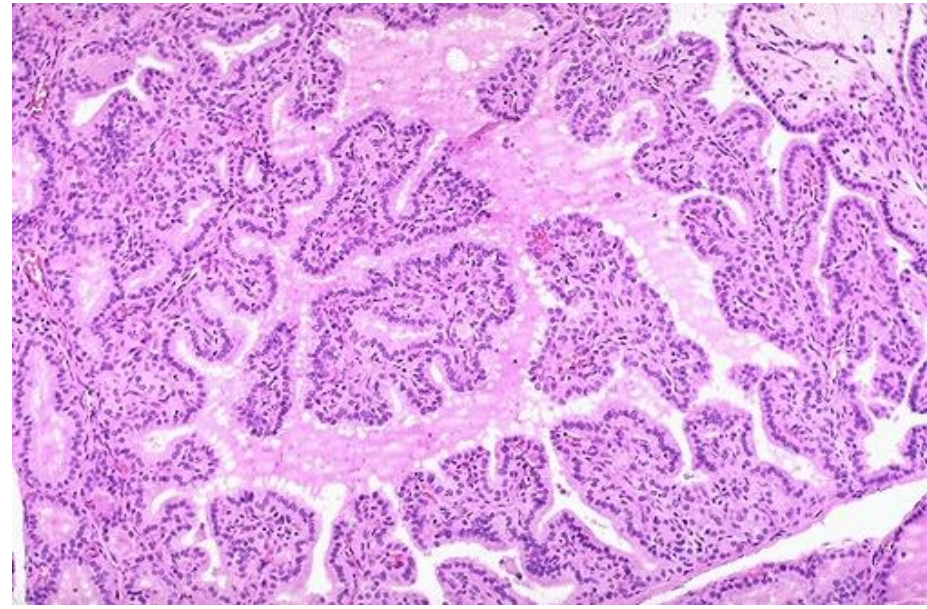
- thyroid stimulating immunoglobulin. These class G antibodies bind to the TSH receptor and mimic its effects.
- immunoglobulin, stimulating the growth of the thyroid gland. This Ig, also acting on the TSH receptor, stimulates thyroid growth.



# Graves disease

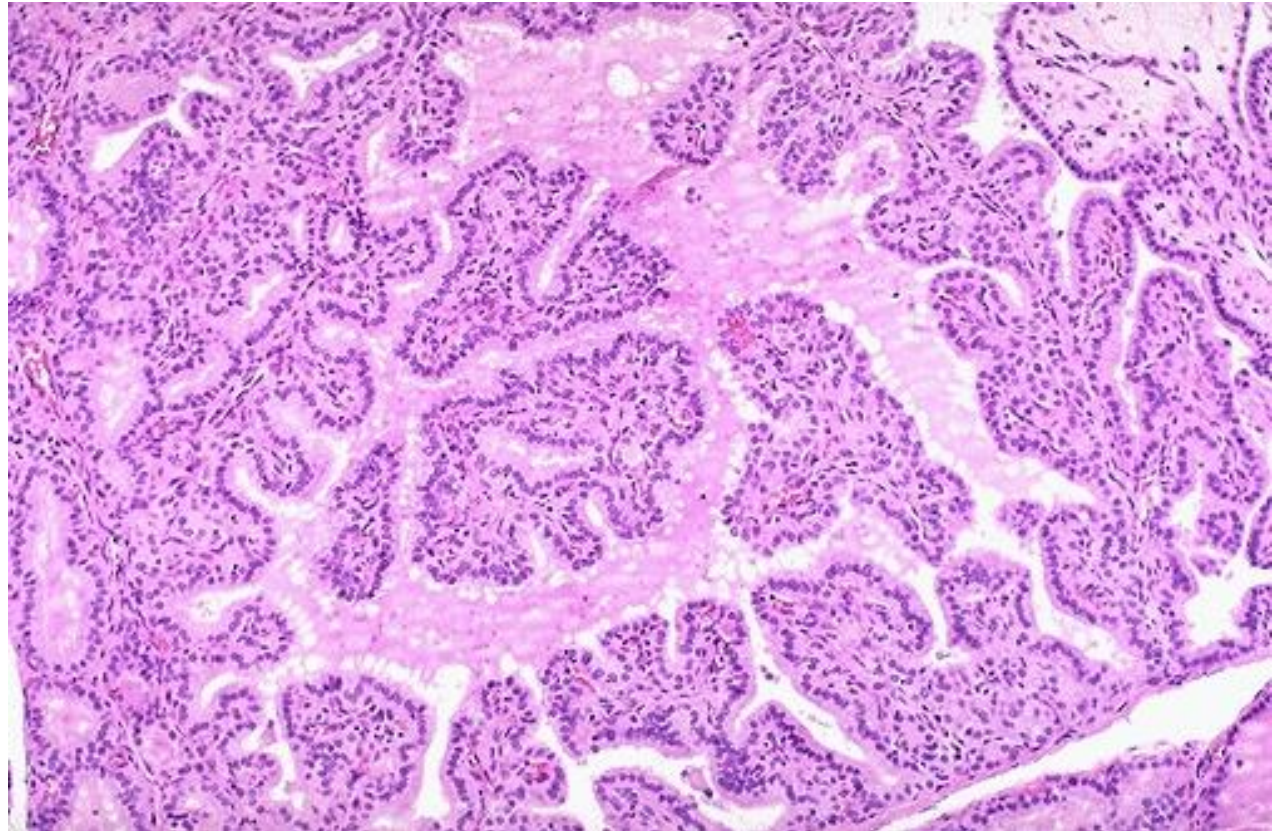
The thyroid gland is usually symmetrically enlarged due to diffuse hypertrophy and hyperplasia of the follicular epithelium. Often, the mass of the gland exceeds 80 g.

during histological examination, follicular cells are tall and located closer than usual. Such a close arrangement of cells often leads to the formation of small papillae that protrude into the lumen of the follicle and push out the colloid, and sometimes fill the lumen of the follicle. The colloid in the lumen of the follicles is pale.



# Graves disease

In these papillae there is no fibrovascular stalk, unlike papillae with papillary carcinoma. In interstitium, lymphoid infiltrates are determined, containing mainly T-lymphocytes, a few B-lymphocytes and mature plasma cells; germinative centers are often observed.





# Graves disease, manifestations:

## 1\ Heart.

myocardial cell dystrophy and hypertrophy

serous myocarditis

lymphostasis, lymphoid infiltration

Thyrotoxic heart.

## 2\ Liver: serous hepatitis.

3\ Exophthalmos. The reason is mucoid edema of retrobulbar fiber, squeezing of the eyeball. With malignant exophthalmos, a sharp tension of the nerves and blood vessels of the eyeball bundle and its necrosis occur. The severity of exophthalmos does not coincide with the strength of thyrotoxicosis.

# Graves disease, manifestations:

A form of exacerbation of pathology is thyrotoxic crises. Manifestations of thyrotoxic crises:

simultaneous release of a large amount of thyroxine

encephalopathy with hallucinations and delusions

tachycardia \ up to 200 beats per minute \

chills, temperature, dystrophy and necrosis of organs, especially the heart

death of heart failure.

# Hypothyroidism

## Primary hypothyroidism

- Impaired development of the thyroid gland (mutations PAX8, FOXE1, TSHR)
- Thyroid hormone resistance (THRB mutations)
  - Postablative hypothyroidism (surgical excision, radioiodine therapy or radiation)
- Autoimmune hypothyroidism (Hashimoto's thyroiditis)
- Iodine deficiency
- Medicines (lithium, iodides, p-aminosalicylic acid)
- Congenital metabolic disorder of thyroid glands (dysmorphogenetic goiter)

## Secondary hypothyroidism

- Pituitary insufficiency
- Hypothalamic insufficiency

# Hypothyroidism

Cretinism is a manifestation of hypothyroidism, which develops in infancy or early childhood. The term "cretin" comes from the French word chretien, meaning "Christian" or "like Christ." Sick people were called by this word because they considered them incapable of sinning because of mental retardation.

Cretinism develops as a result of impaired development of the skeletal system and central nervous system, which is manifested by short stature, large facial features, protruding tongue, umbilical hernia, and severe congenital dementia

# Hypothyroidism

The term "myxedema" refers to hypothyroidism in older children and in adults.

The clinical signs of myxedema are - decrease in physical and mental activity.

The initial symptoms - general weakness, apathy in the early stages of the disease resemble depression.

Speech and intellectual activity slow down. Patients with myxedema are lethargic, cannot tolerate cold, and are often overweight.

A decrease in the activity of the sympathetic nervous system leads to constipation and a decrease in sweating.

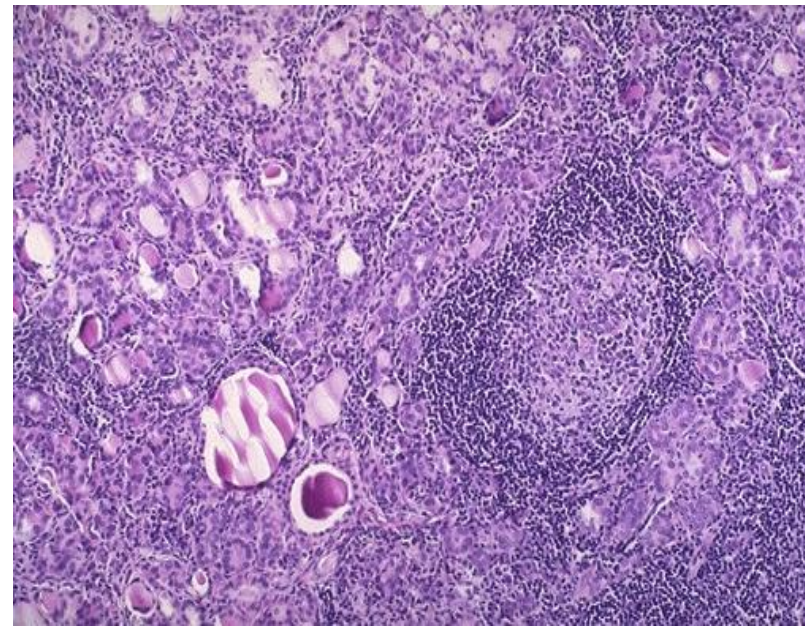
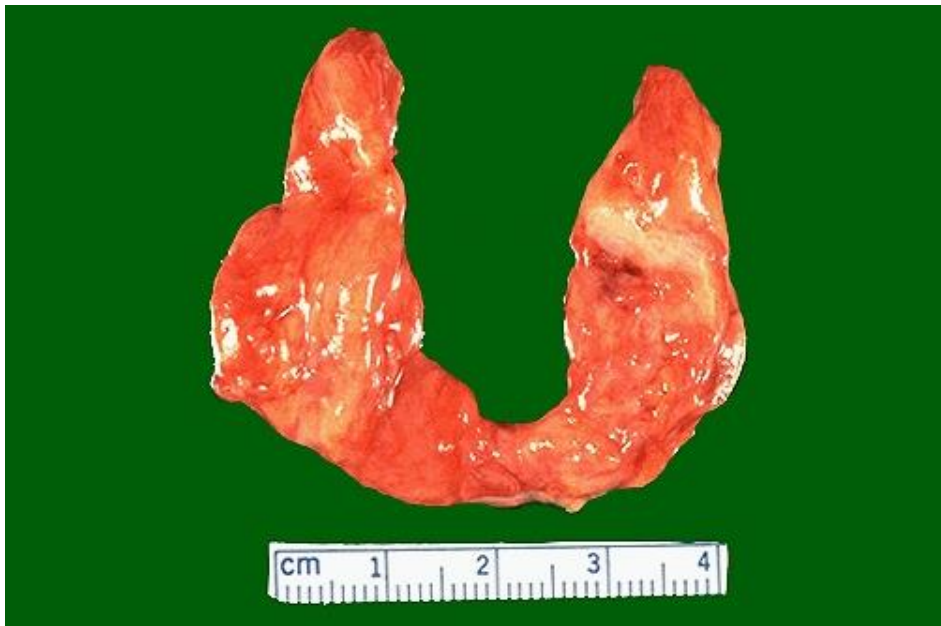# Thyroiditis

1. Hashimoto's thyroiditis;
2. subacute granulomatous thyroiditis;
3. subacute lymphocytic thyroiditis.

Hashimoto's thyroiditis occurs as a result of impaired tolerance to thyroid autoantigens.

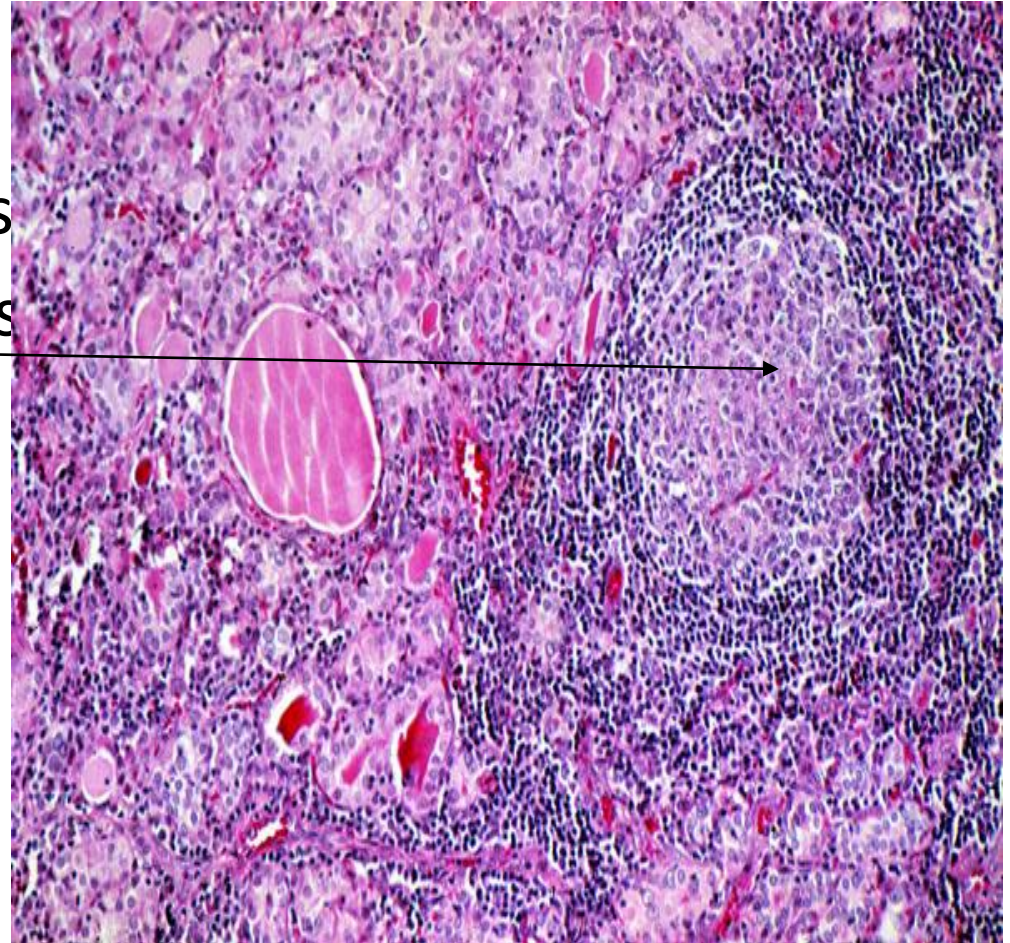
Most patients with this thyroiditis have circulating autoantibodies to thyroglobulin and thyroid peroxidase in the blood

A decrease in the activity of the sympathetic nervous system leads to constipation and a decrease in sweating.



# Hashimoto's Thyroiditis

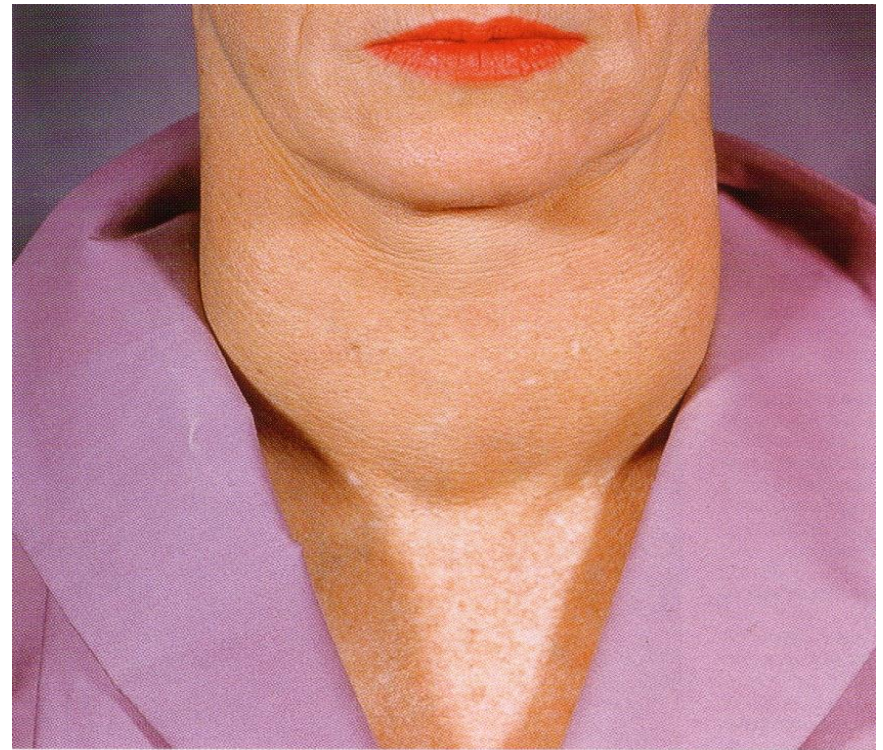
- Lymphocytic infiltrate in the thyroid, with lymphoid follicle formation and fibrosis
- Presence of oncocytes always has oncocytic metaplasia



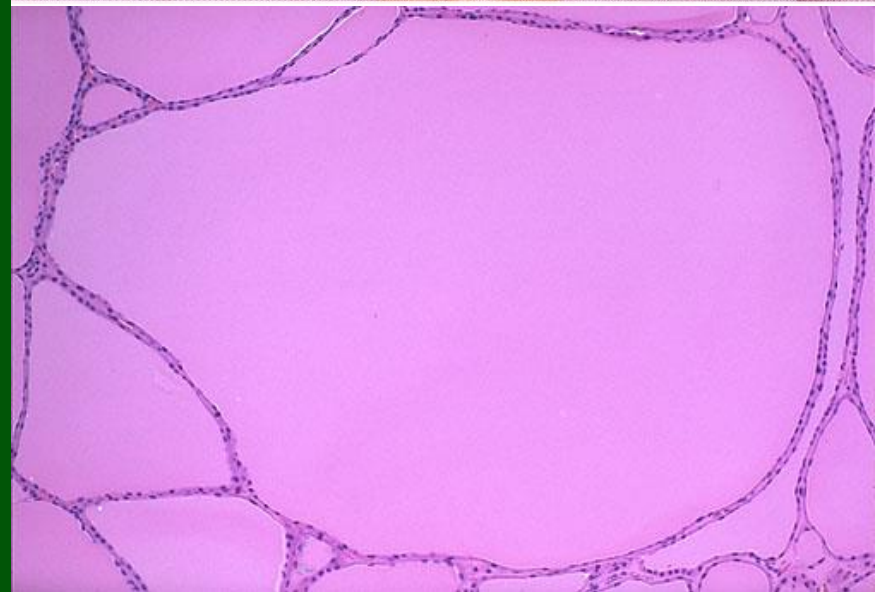
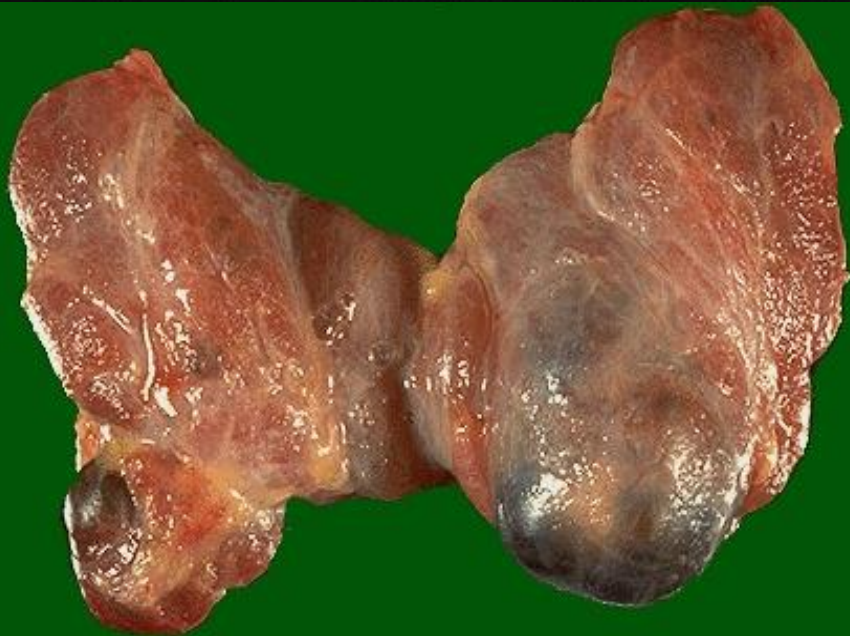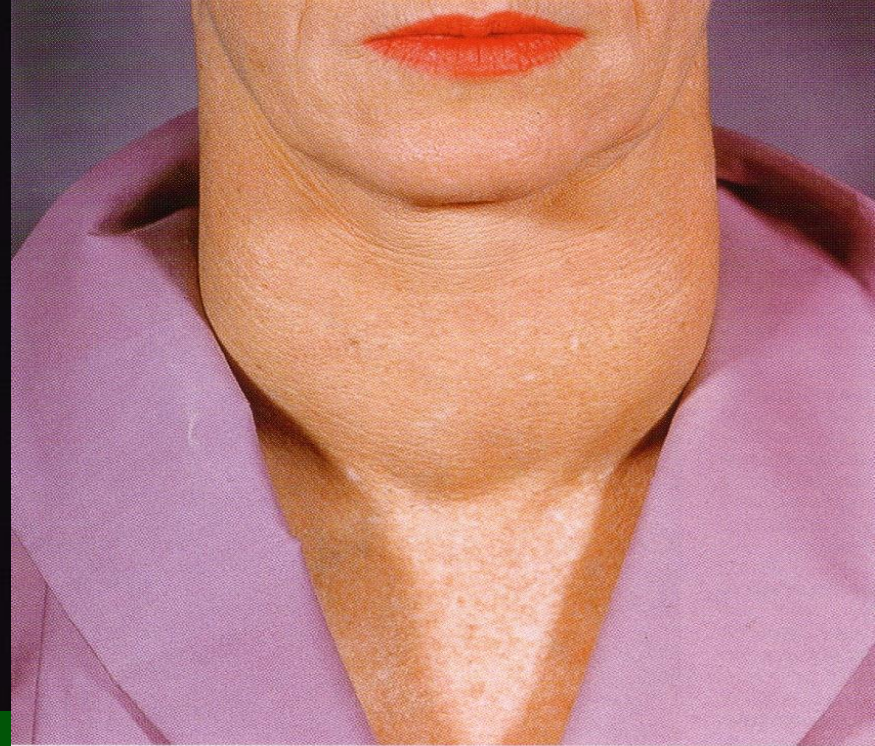
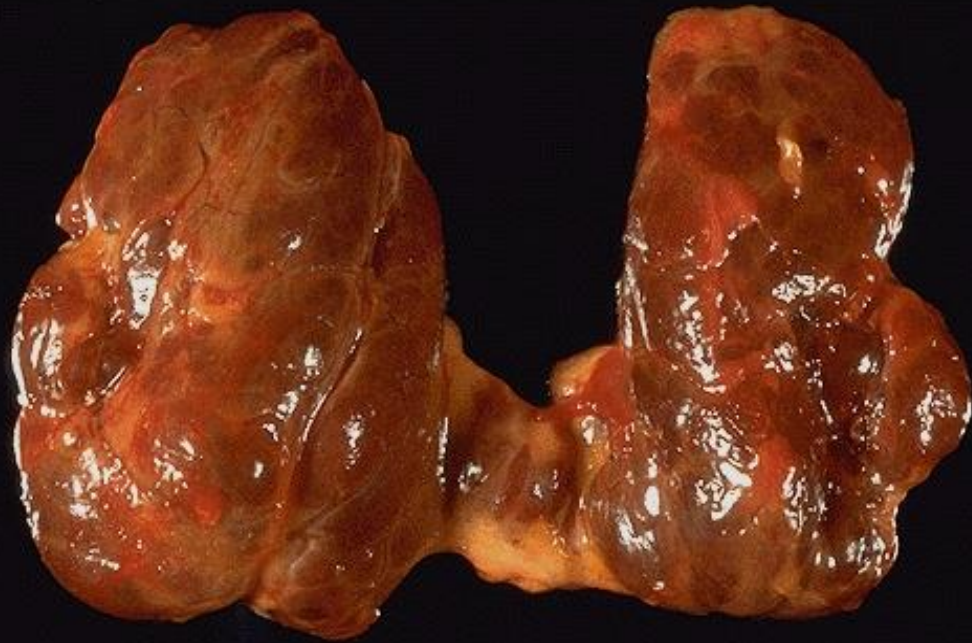# Goiter

- Endemic goiter
  - Caused by dietary deficiency of iodine
- Sporadic goiter is less common than endemic, significantly prevails among women, and the peak incidence occurs during puberty or young age

- Both hypo and hyperthyroidism can have goiter as a symptom
- Goiter is a swelling of the neck due to hypertrophy of the thyroid gland







**Colloid goiter.**

# Simple Goitre

(Enlargement of the thyroid gland without hyperthyroidism)

- Parenchymatous goitre
  - Hyperplasia of thyroid epithelium with loss of stored colloid
  - Less active areas appear later → compresses by hyperplastic areas
- Multinodular goitre
  - Tracts of fibrosis separating hyperplastic & less active areas
  - Multiple nodules may be palpated
  - 1 large nodule → suspicion of neoplasia
- Colloid
  - No epithelial hyperplasia
  - Follicles accumulate large volumes of colloid → coalesce → colloid-filled cysts
  - Areas of haemorrhage, fibrosis & dystrophic calcification
  - May be diffuse or multinodular
  - Rapid enlargement d.t. haemorrhage → tracheal compression; stridor

# Follicular Adenoma

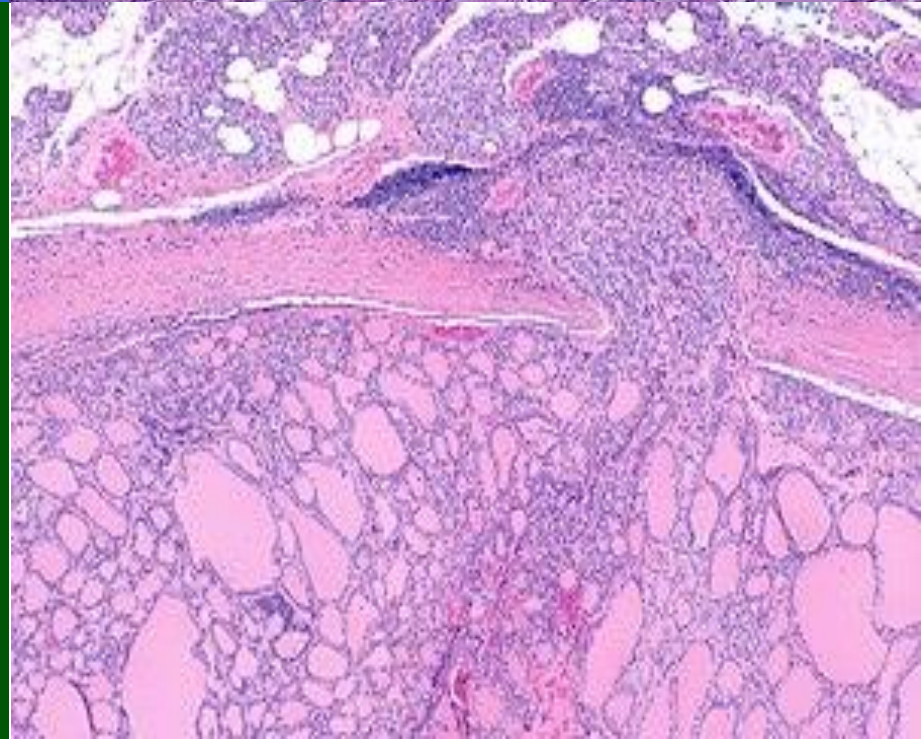
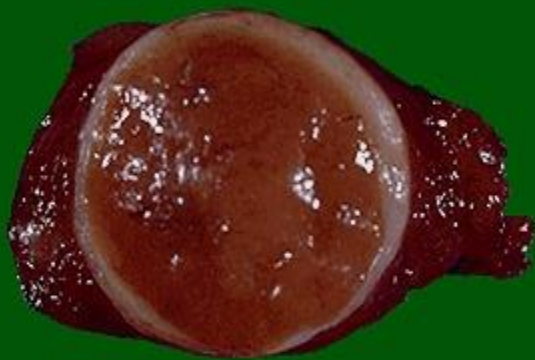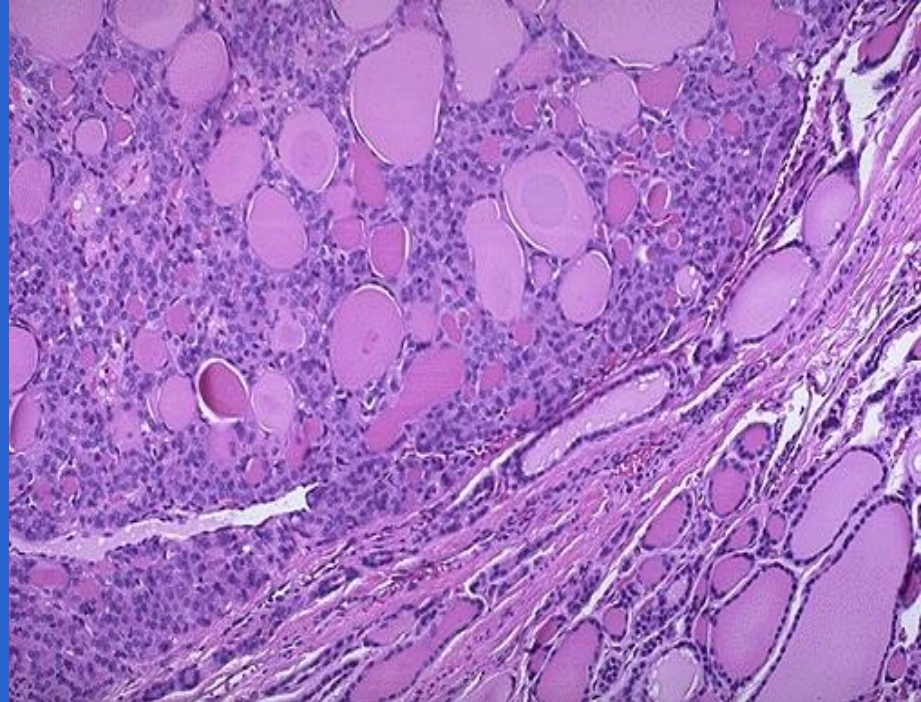

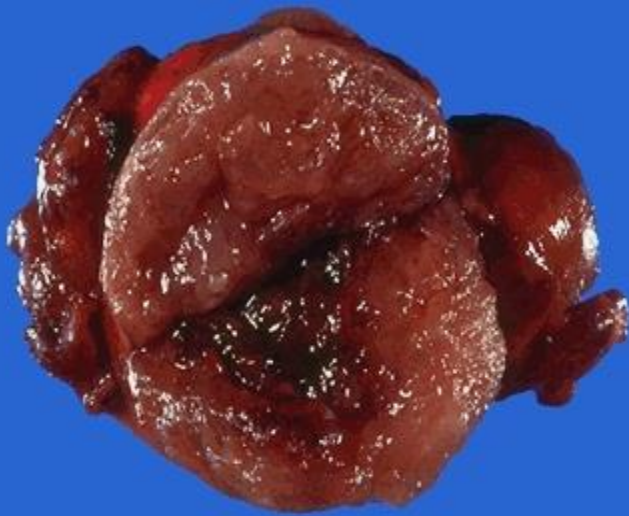
## *Microscopic*

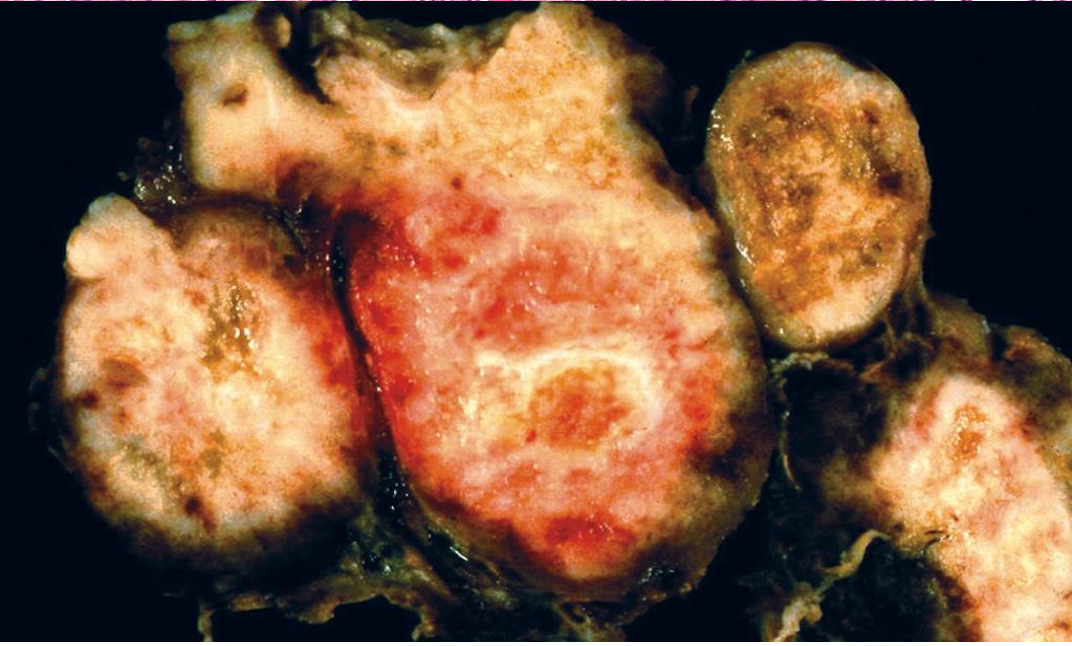
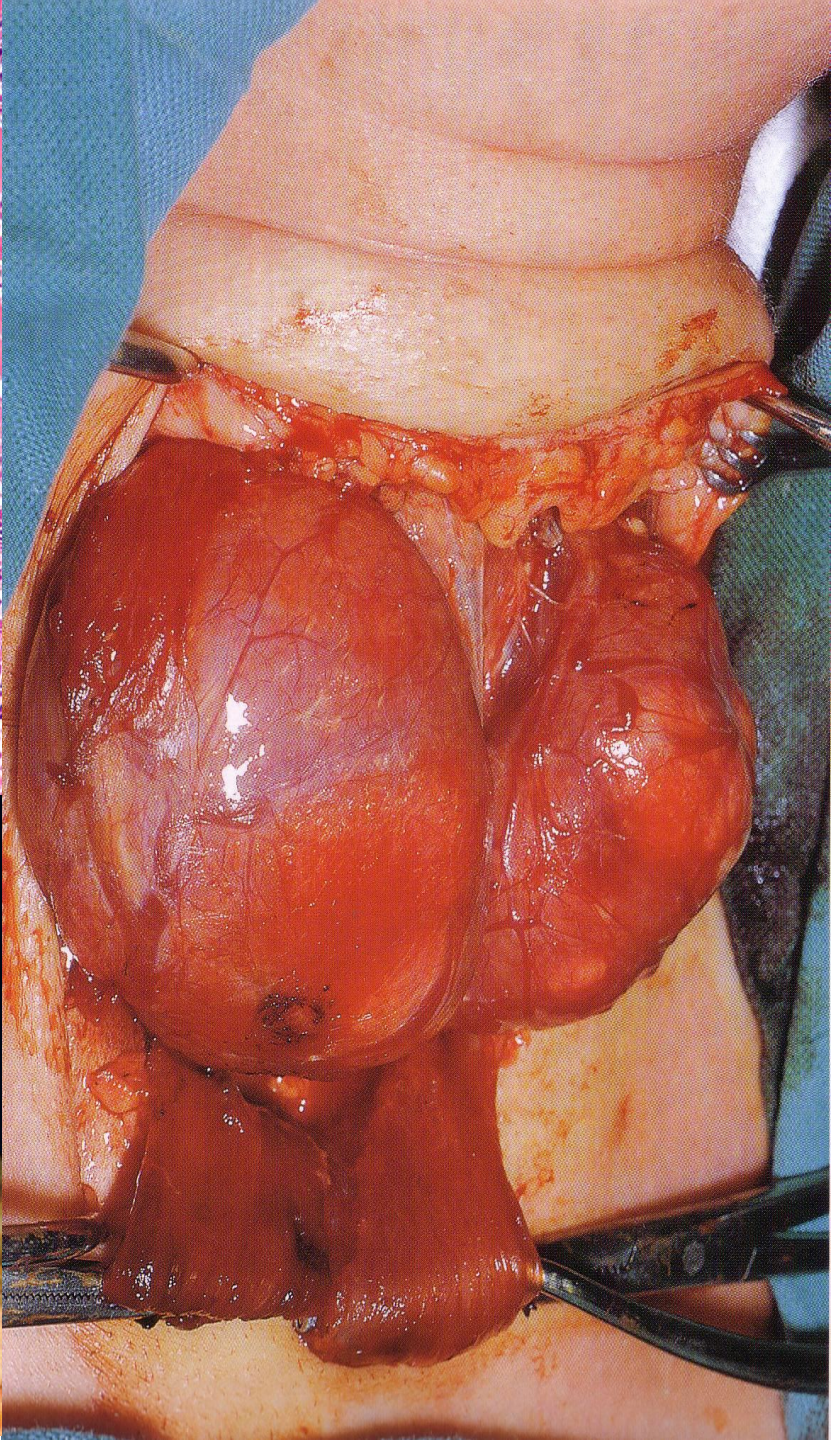
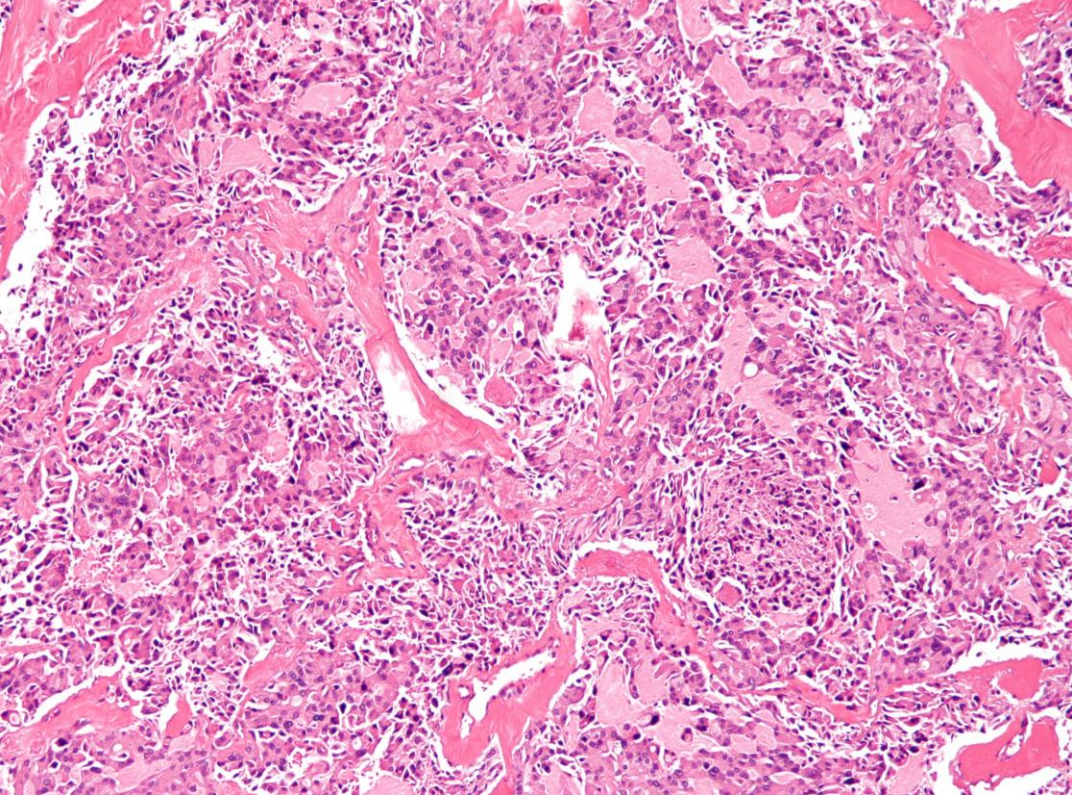
- Microscopically, the constituent cells often form uniform-appearing follicles that contain colloid
- The follicular growth pattern within the **adenoma** is usually quite distinct from the adjacent non-neoplastic thyroid
  - distinguishing feature b/w **adenomas** and **MNG-** nodular and uninvolved thyroid parenchyma may have similar growth patterns

# Follicular Adenoma

## *Microscopic*

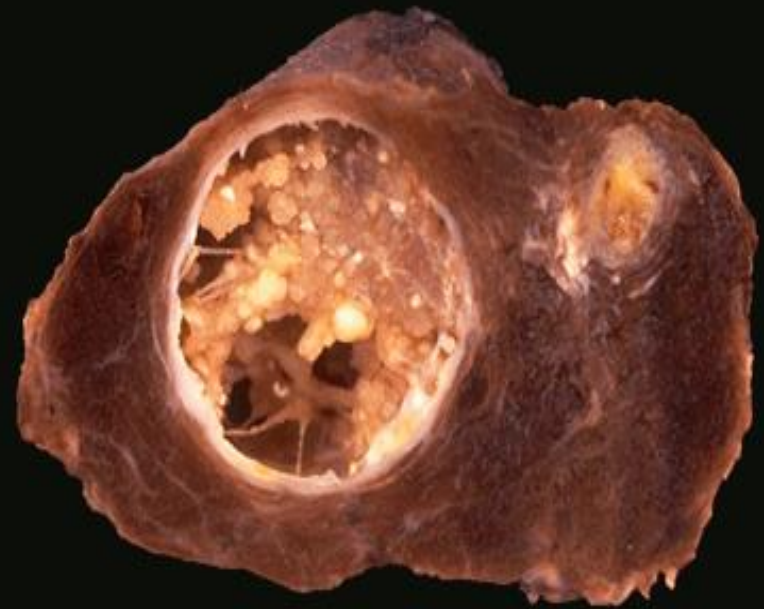
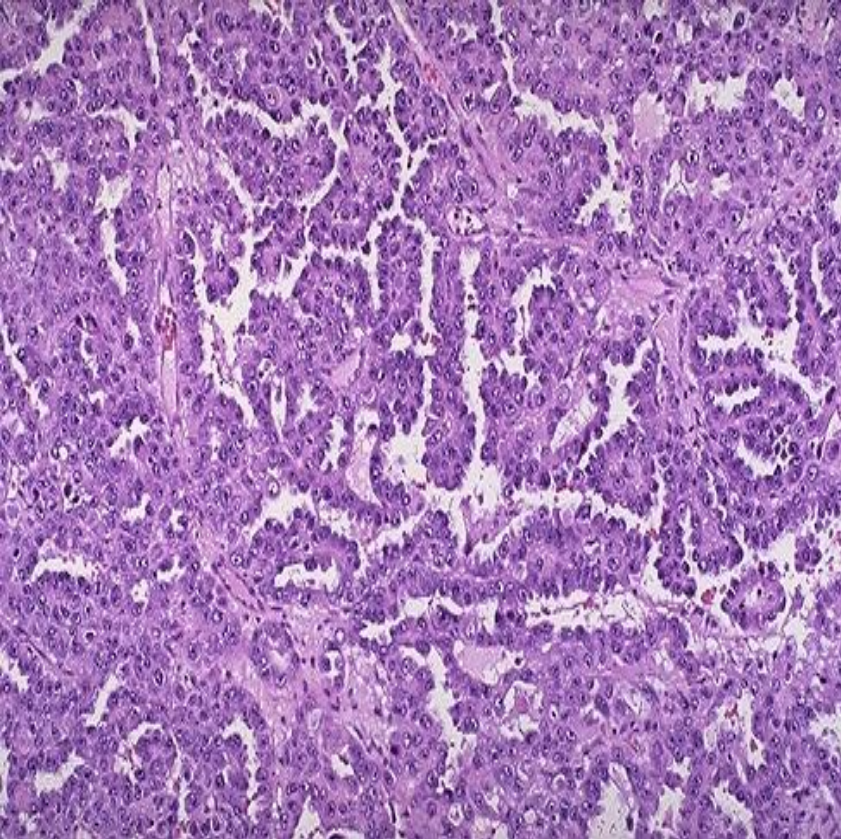
- Mitotic figures are rare
- papillary change is not a typical feature of **adenomas** and, if extensive, should raise the suspicion of an encapsulated papillary carcinoma
- Occasionally, the neoplastic cells acquire brightly eosinophilic granular cytoplasm (oxyphil or Hürthle cell change)



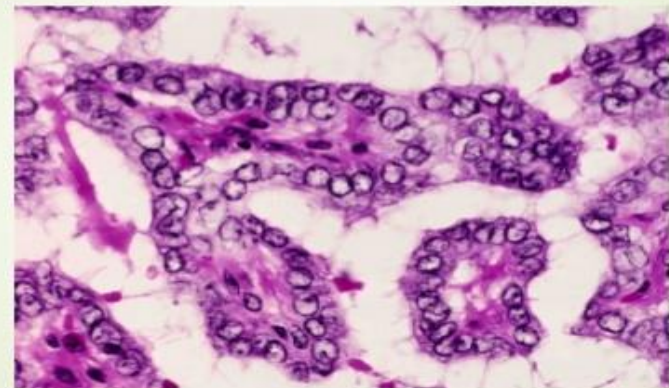


# Papillary Thyroid Carcinoma

- can contain branching papillae having a fibrovascular stalk covered by a single to multiple layers of cuboidal epithelial cells
- **NUCLEI** of papillary carcinoma cells contain finely dispersed chromatin, which imparts an **optically clear** or **empty** appearance, giving rise to the designation **ground glass** or **Orphan Annie eye** nuclei
- invaginations of the cytoplasm may in cross-sections give the appearance of intranuclear inclusions ("pseudo-inclusions") or **intranuclear grooves**



Orphan Annie eye appearance





# Parathyroid

- Hypoparathyroid
  - surgical excision during thyroid surgery
  - fatal tetany 3-4 days
- Hyperparathyroid = excess PTH secretion
  - tumor in gland
  - causes soft, fragile and deformed bones
  - ↑ blood  $\text{Ca}^{2+}$
  - renal calculi

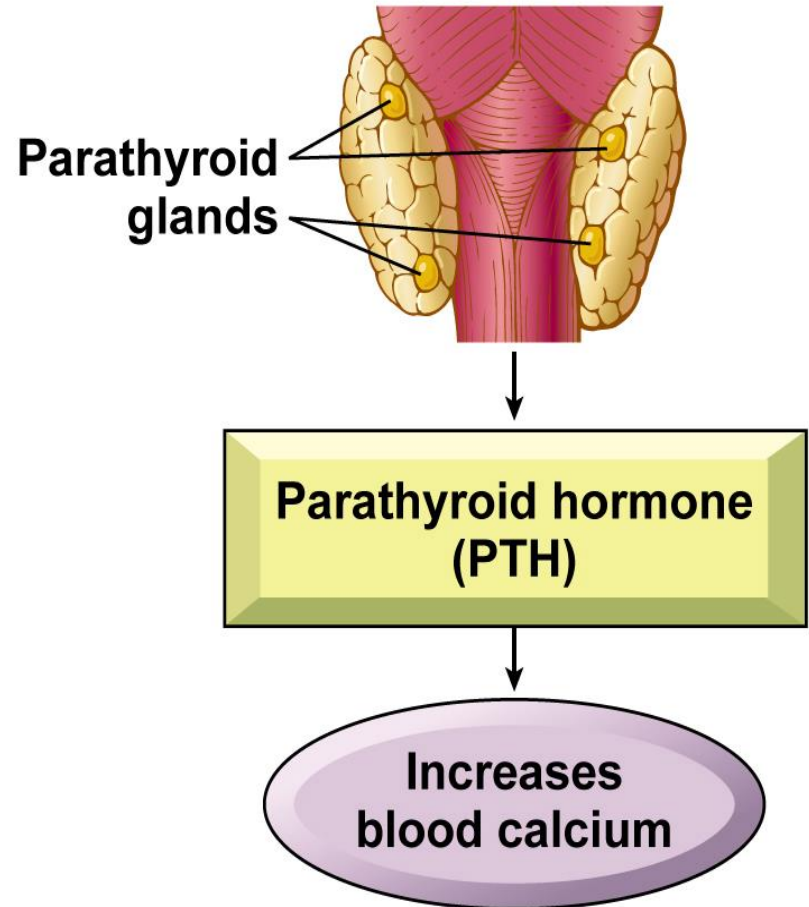
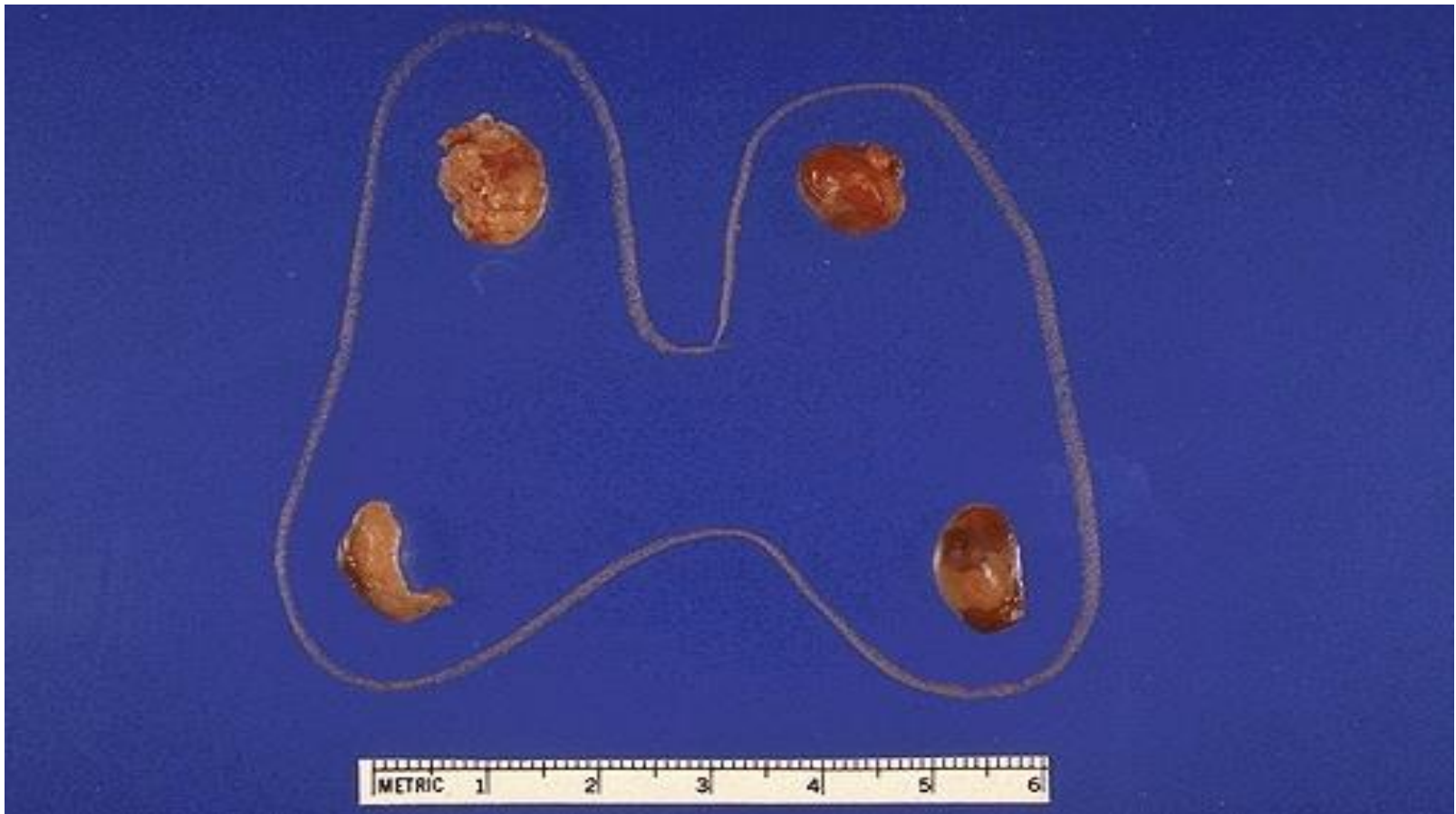

Fig. 18-5. The parathyroid glands: their hormone and action.

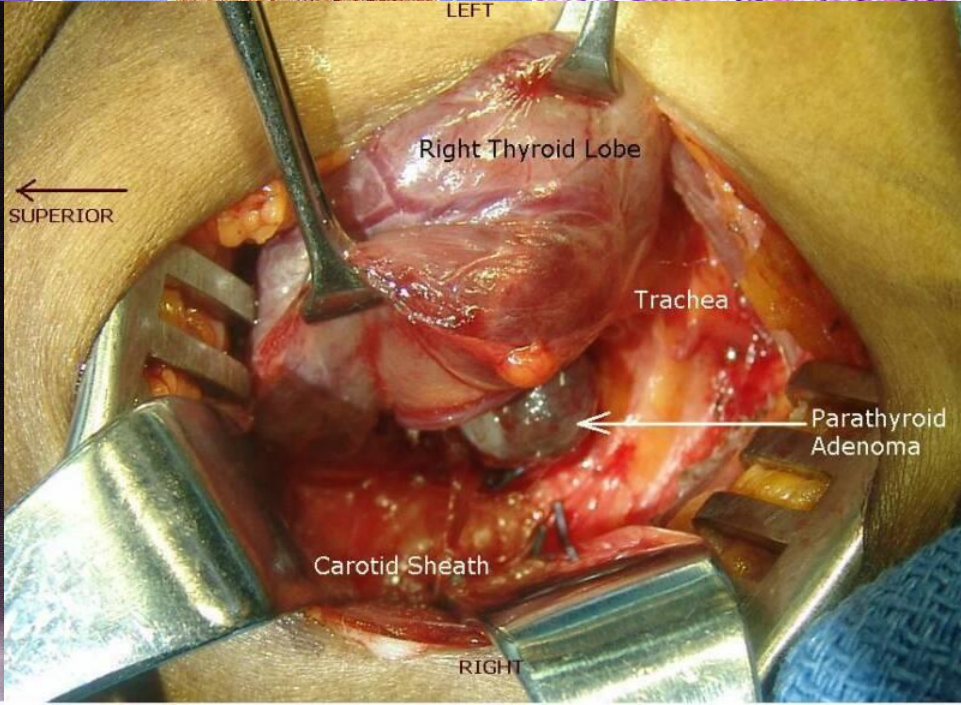
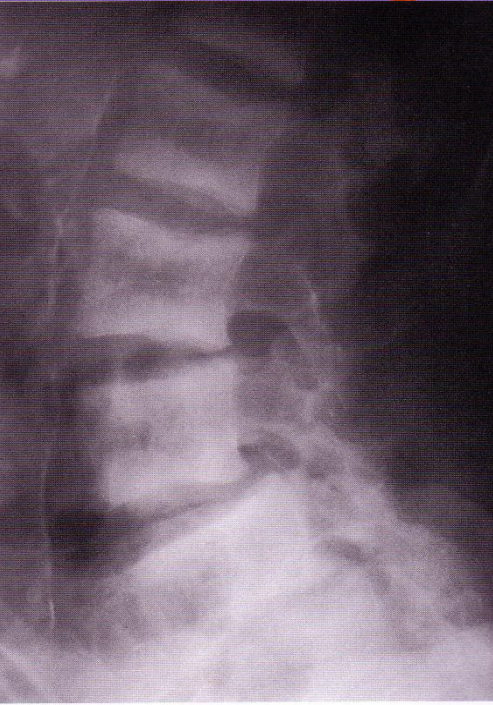
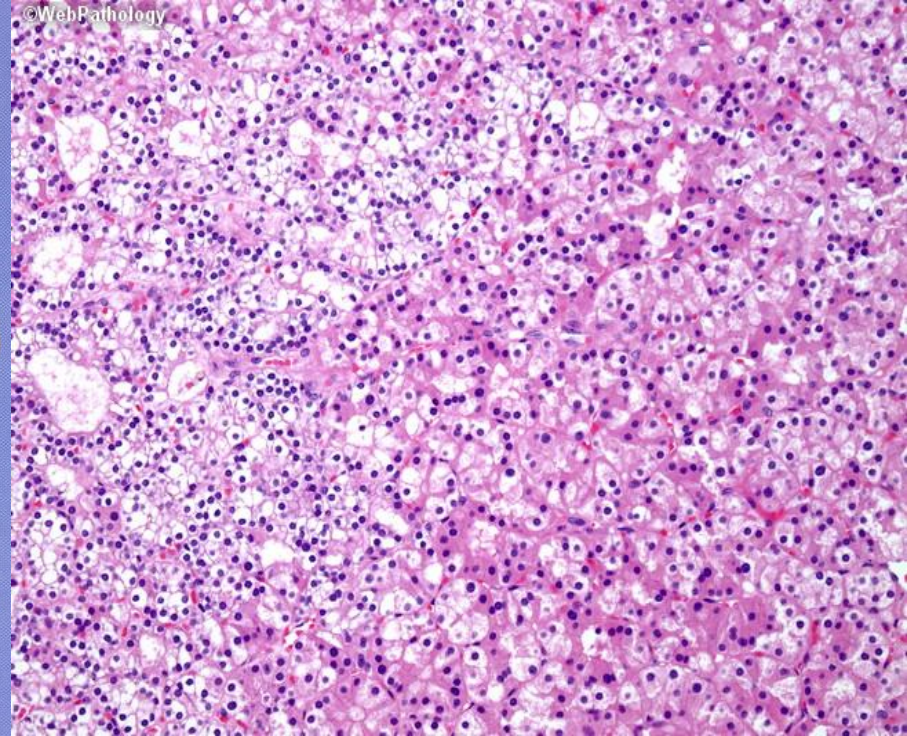
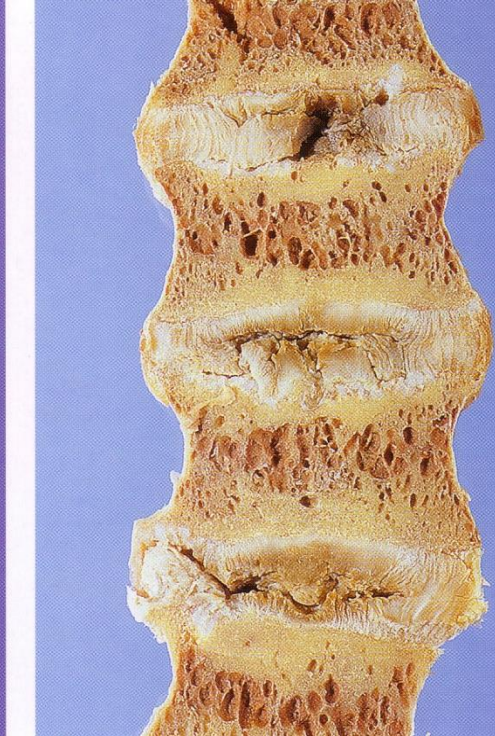
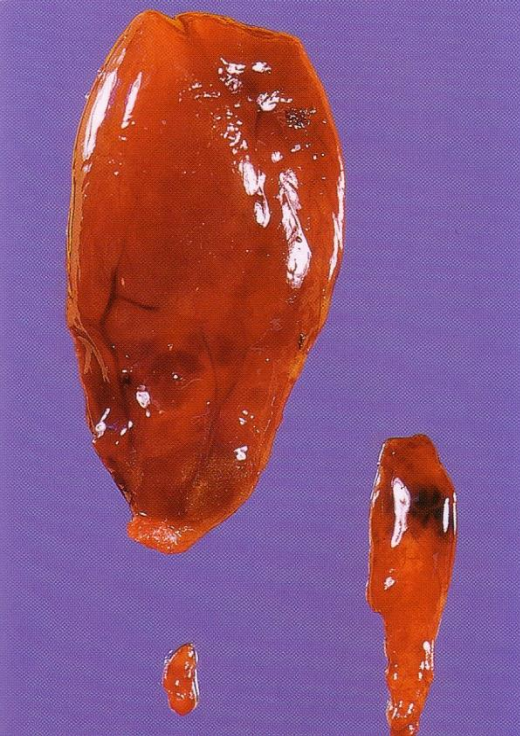Copyright © 2007, 2004 by Saunders, an imprint of Elsevier Inc. All rights reserved.



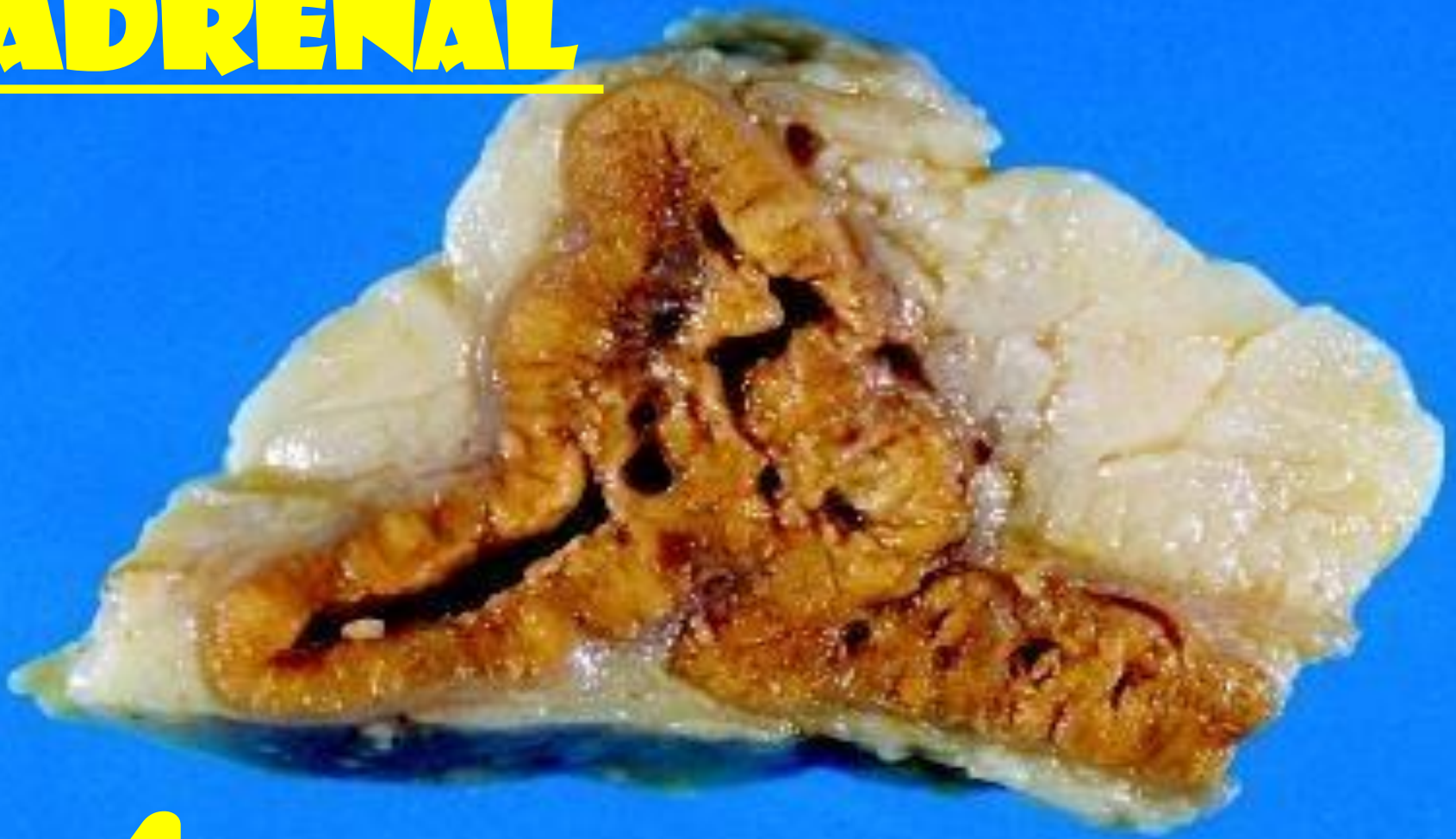**Parathyroid hyperplasia** is shown here.

Three and one-half glands have been removed (only half the gland at the lower left is present).

**Parathyroid hyperplasia** is the **second most common form of primary hyperparathyroidism**, with parathyroid carcinoma the least common form.



**ADRENAL**



**4 g.**

# Adrenal :

- Two small glands on top of each kidney. Composed of two parts; an inner (medulla) and outer (cortex) portion.
- **Cortex:** secretes corticosteroids (complex chemicals made from cholesterol)
  - ✓ **Cortisol** to regulate glucose, fat and protein metabolism
  - ✓ **Aldosterone** to regulate electrolytes or salts
  - ✓ **Androgens** and **Estrogens** to regulate male and female sex characteristics
- **Medulla:** secretes catecholamines (chemicals made from amino acids).
  - ✓ **Epinephrine** to increase heart rate and BP, dilate bronchial tubes, release glucose and glycogen for more energy - "flight or fight"
  - ✓ **Norepinephrine** constricts blood vessels to raise BP)

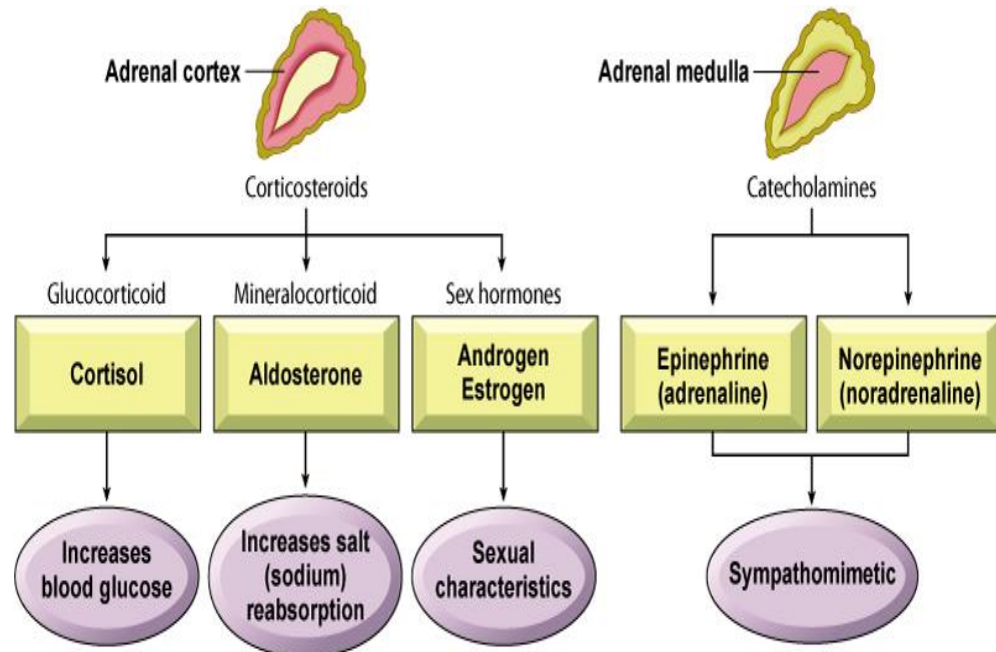


Fig. 18-7. The adrenal cortex and adrenal medulla: their hormones and actions.

Copyright © 2007, 2004 by Saunders, an imprint of Elsevier Inc. All rights reserved.

# Conditions Affecting Adrenal Cortex

## Adrenocortical Hyperfunction

- Cushing's syndrome
  - Increased glucocorticoid levels
- Hyperaldosterone
  - Excessive water retention → Ht
- Adrenogenital syndromes
  - Excess androgens (testosterone) in peripheral tissue
    - Dehydroepiandrosterone
    - Androstentendione

## Adrenocortical Insufficiency

- Acute Adrenocortical Insufficiency
- Chronic Adrenocortical Insufficiency (Addison's)

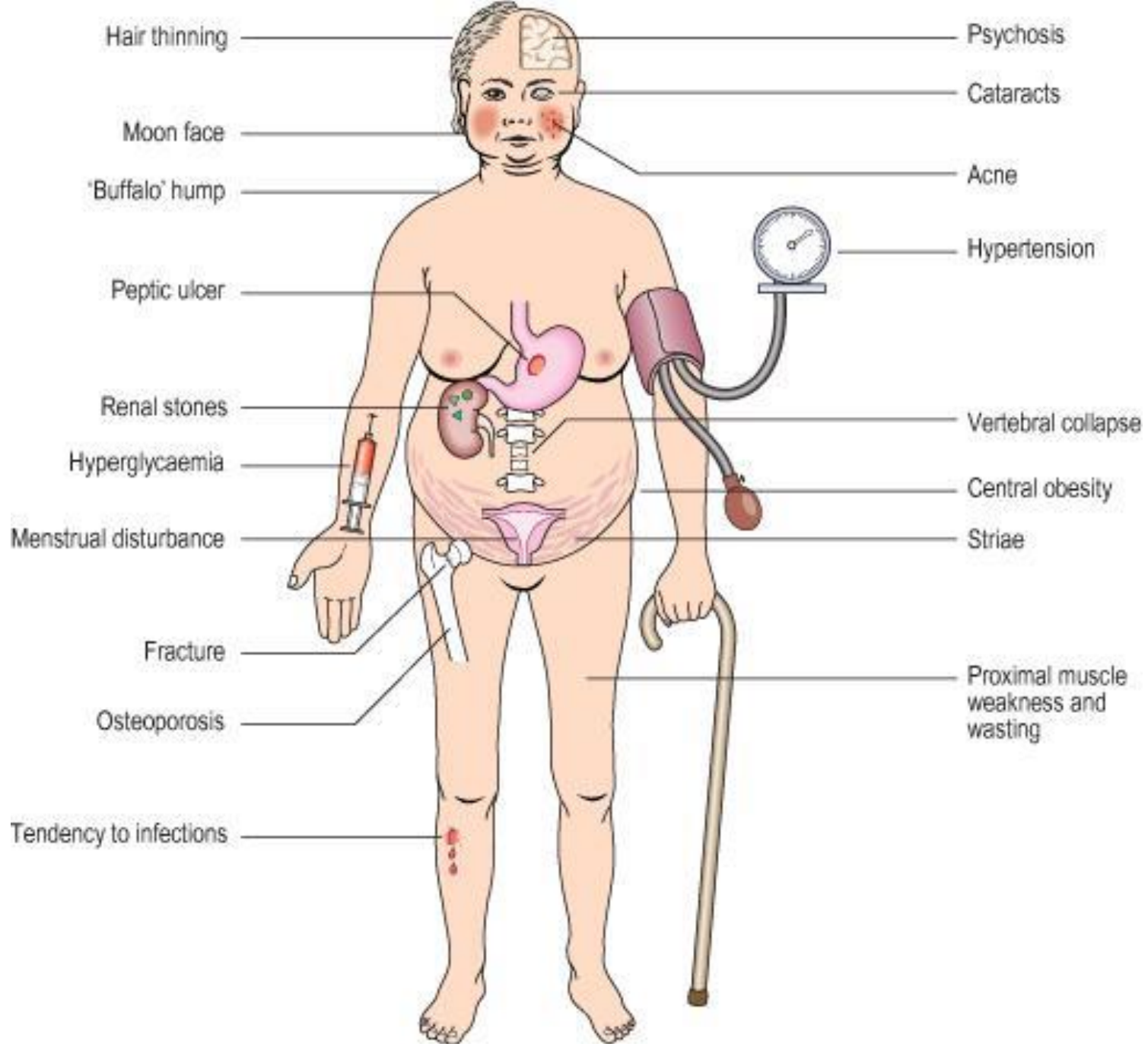
# Cushing's Syndrome

## Hypercortisolism

- Constellation of bodily responses to excess glucocorticoids
- Most common in adult woman
- May occur with excess androgen production → virilization

## Aetiology & Pathogenesis

- Exogenous glucocorticoids
  - Bilateral atrophy of adrenal cortex
  - Due to suppression of endogenous ACTH
- Endogenous glucocorticoids
  - Bilateral adrenal hyperplasia
  - Adrenal cortices thickened & yellow
  - Histologically → cortex depleted of lipids (secretions discharged)
  - May show nodularity
- Pituitary
  - Crooke hyaline change
    - Homogenous basophil material
    - replaces normal granular cytoplasm of cells
  - ACTH secreting adenoma or hyperplasia (Cushing's dx)





# Acute Adrenocortical Insufficiency

## Aetiology & pathogenesis

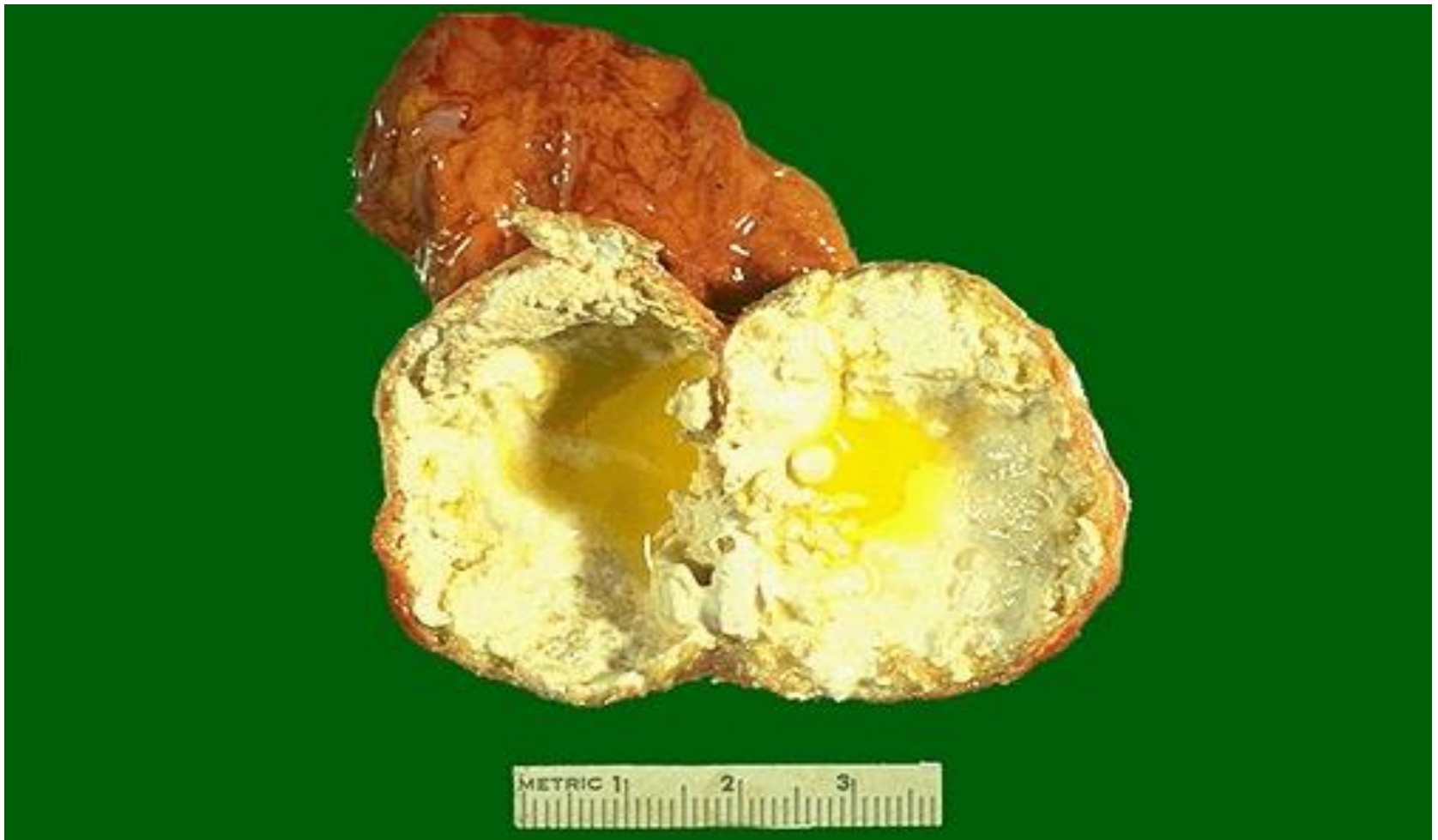- Sepsis → Waterhouse-Friderichsen syndrome
  - Neisseria meningitidis (classic)
  - Pseudomonas; pneumococci; H. influenzae (others)
  - Unclear pathogenesis → endotoxin induced vascular injury (massive haemorrhage) with associated DIC
- Sudden withdrawal of long term corticosteroid treatment
  - Inability of atrophic adrenals to produce glucocorticoids
- Stress with underlying chronic adrenal insufficiency
  - Acute adrenal crises on limited physiological reserves

# Chronic Adrenocortical Insufficiency

## “Addison’s Disease”

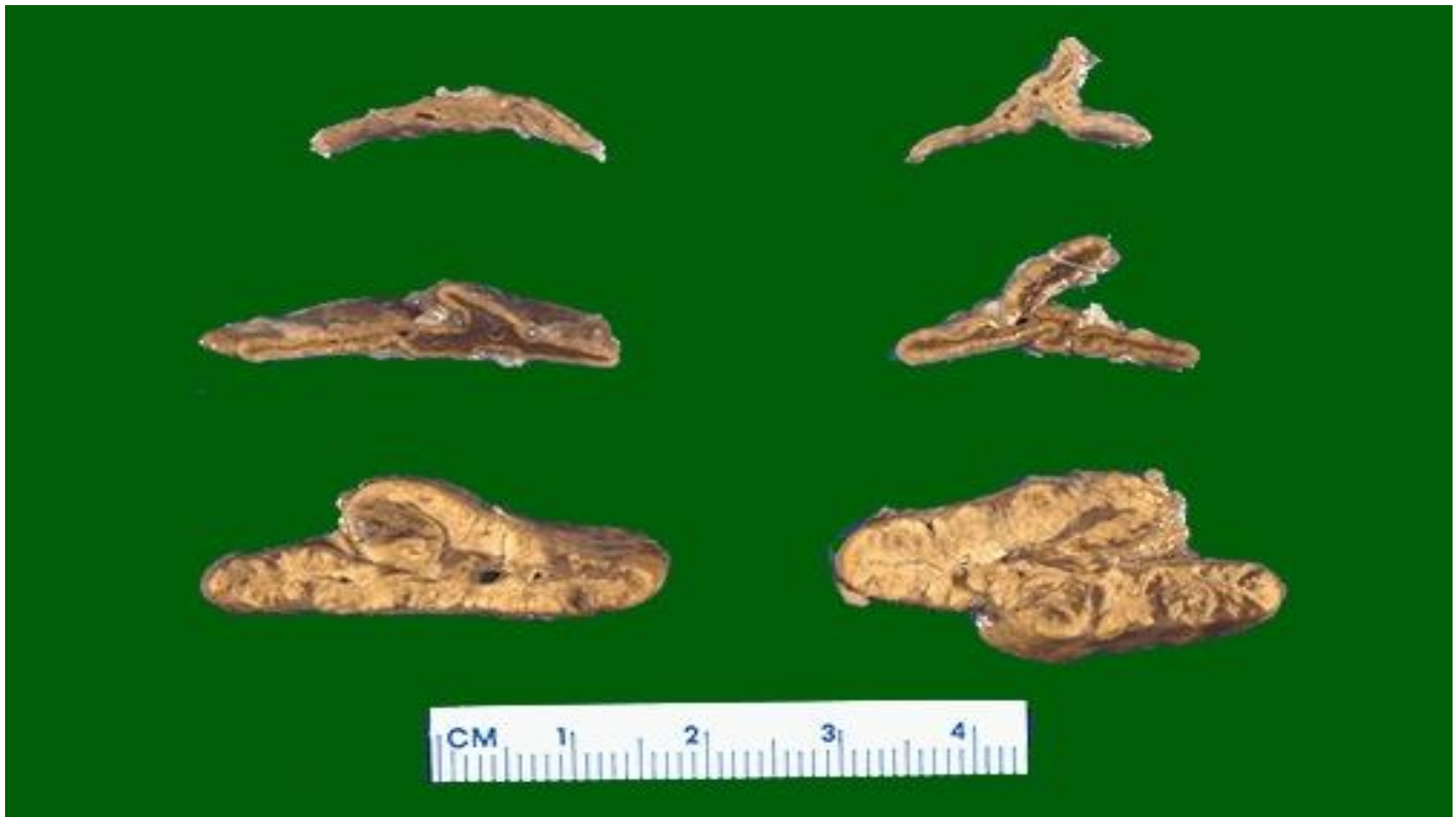### Aetiology & pathogenesis

- Primary → Addison’s disease
- Secondary causes
  - Tuberculosis → caseous necrosis of adrenal cortex
  - Autoimmune adrenalitis
    - Ass with e.g. pernicious anaemia; thyroiditis; IDDM
  - AIDS
  - Metastatic disease
  - Systemic amyloidosis
  - Fungal infections
  - Haemochromatosis
  - Sarcoidosis



This is a **caseating granuloma of tuberculosis in the adrenal gland**. Tuberculosis used to be the most common cause of chronic adrenal insufficiency.

Now, idiopathic (presumably autoimmune) Addison's disease is much more often the cause for chronic adrenal insufficiency. 99

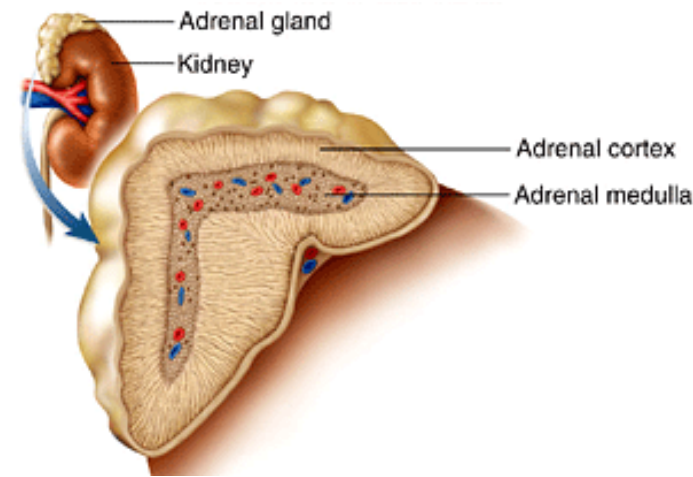


The pair of adrenals in the center are normal. Those at the top come from a patient with adrenal atrophy (with either Addison's disease or long-term corticosteroid therapy). The adrenals at the bottom represent bilateral cortical hyperplasia. This could be due to a pituitary adenoma secreting ACTH (Cushing's disease), or Cushing's syndrome from ectopic ACTH production, or idiopathic adrenal hyperplasia.

# Adrenal Medulla

## Pheochromocytoma

Neoplasm of chromaffin cells (paraganglioma)



### • Epidemiology

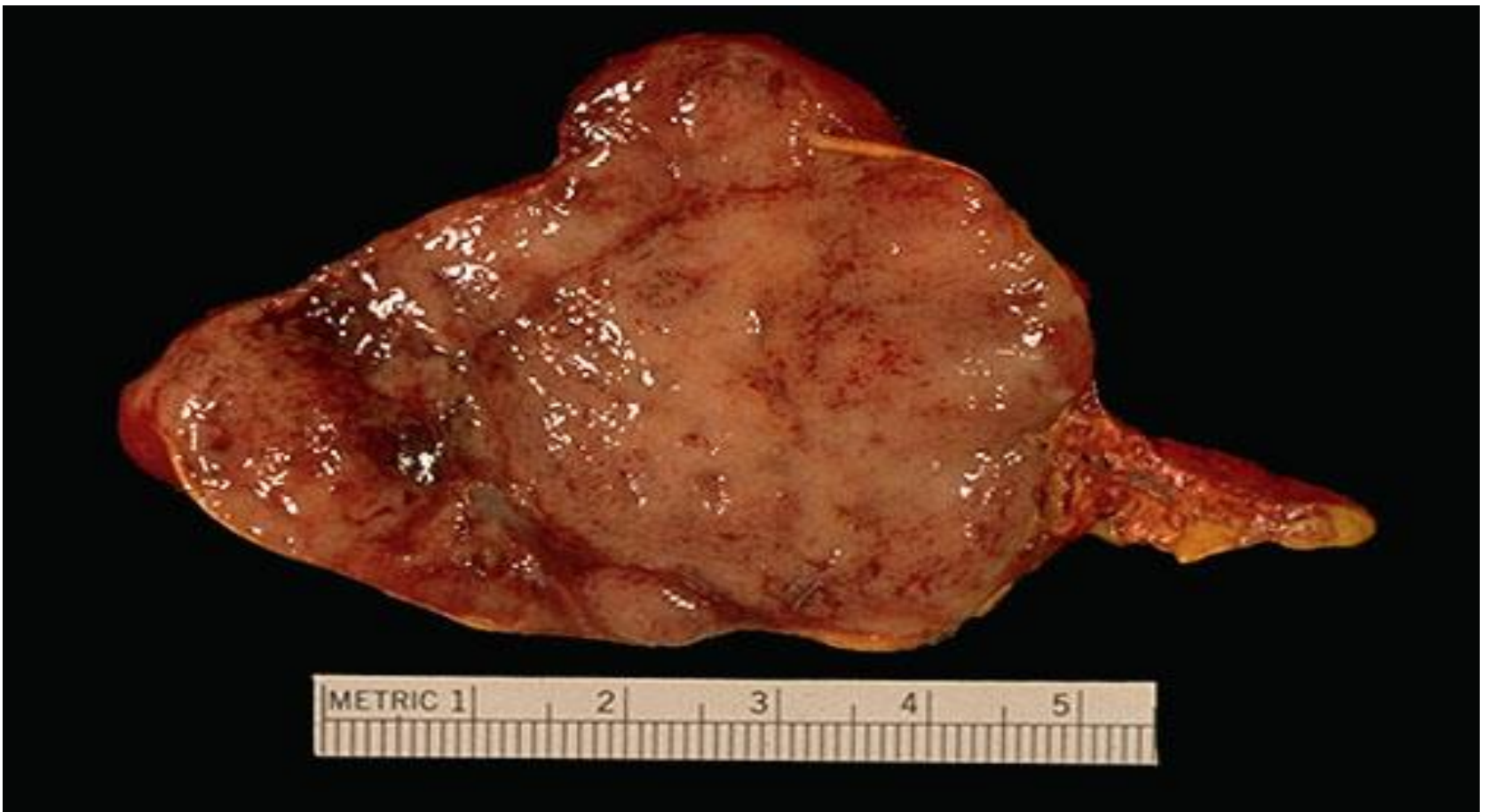- Mostly sporadic; 10% familial
- Can become malignant

### • Morphology

- Small circumscribed lesion or large & haemorrhagic
- Usually unilateral; s/t bilateral
- May have capsular or vascular invasion

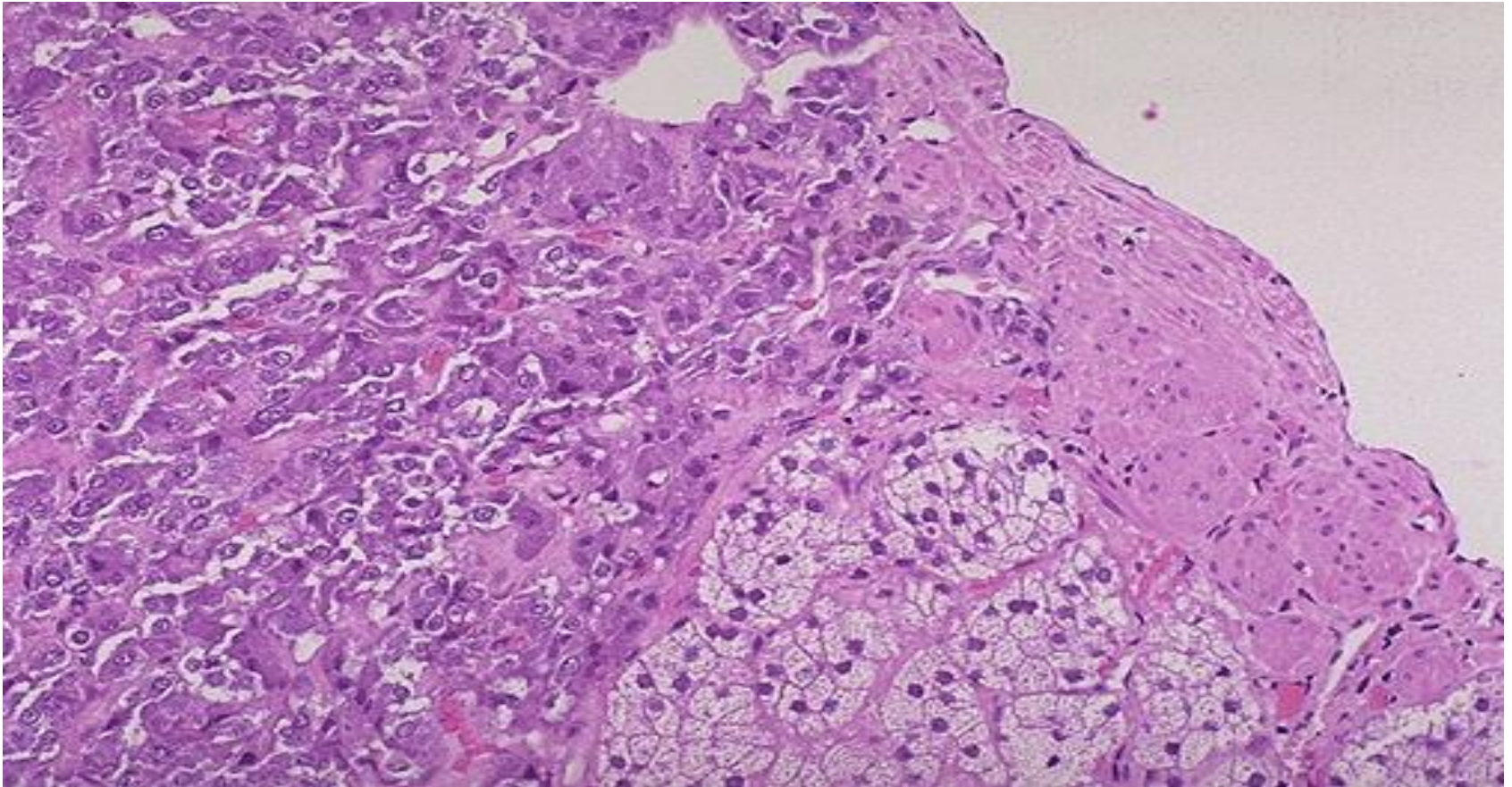
### • Clinical

- Secondary hypertension
  - Paroxysmal episodes of Ht
  - Chronic sustained Ht → risk → CHF; MI; renal damage; sudden death
- Tachycardia; palpitations
- Headaches; sweating; tremor
- Sense of apprehension



This large **adrenal neoplasm** has been sectioned in half.  
Note the grey-tan color of the tumor compared to the yellow cortex stretched around it and a small remnant of remaining adrenal at the lower right.

This patient had **episodic hypertension**.  
This is a tumor arising in the **adrenal medulla--a pheochromocytoma**.



There is some residual adrenal cortical tissue at the lower center right, with the darker cells of **pheochromocytoma** seen above and to the left.

# Endocrine Pancreas Diabetes Mellitus

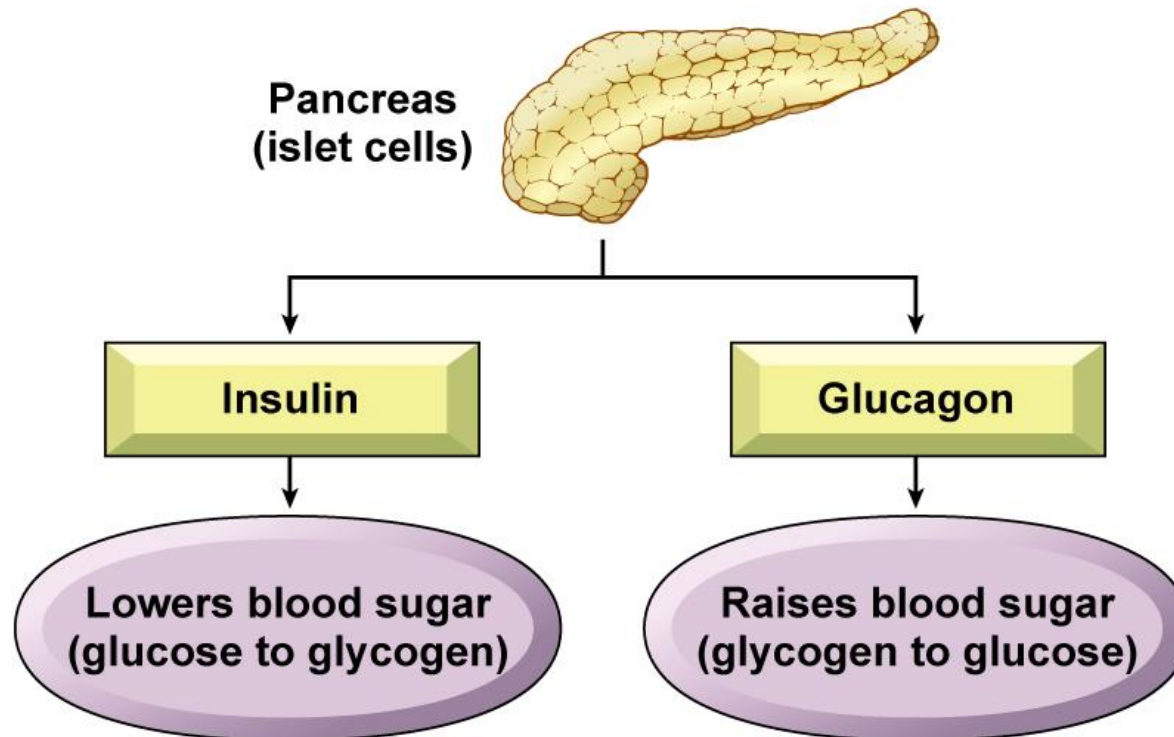


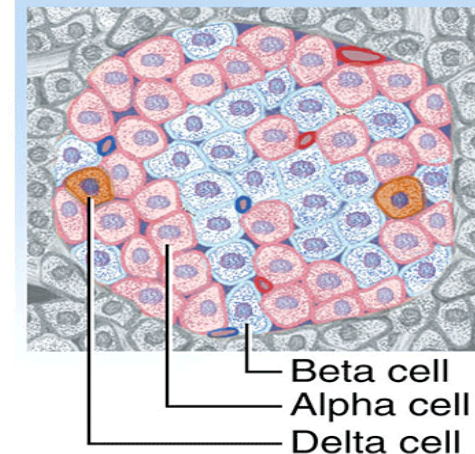
Fig. 18-9. The pancreas (islets of Langerhans): its hormones and actions. Insulin is the only hormone that lowers blood sugar levels.

Copyright © 2007, 2004 by Saunders, an imprint of Elsevier Inc. All rights reserved.



# Cells of islets of Langerhans

- $\alpha$  (alpha cells)  $\rightarrow$  Glucagon
  - Promotes breakdown of glycogen (liver)
  - Promotes gluconeogenesis from proteins
- $\beta$  (beta cells)  $\rightarrow$  Insulin
  - Promotes glucose entry into cells
  - Promotes glycogen synthesis (inhibits breakdown)
  - Promotes lipogenesis from glucose (inhibits lipolysis)
  - Promotes protein synthesis with GH
  - Synthesis & release stimulated by increased serum glucose
- $\delta$  (delta cells)  $\rightarrow$  somatostatin
  - Inhibits insulin & glucagon secretion
- PP (polypeptide cells)  $\rightarrow$  pancreatic polypeptide
  - Function in humans unknown



# Diabetes Mellitus

- Chronic disorder of fat & protein metabolism
- Abnormal metabolic state in which there is glucose intolerance due to inadequate insulin action
- Diagnosis based on clinical demonstration of glucose intolerance
- Signs and symptoms of hyposecretion of insulin
  - polyuria, polydipsia, polyphagia
  - hyperglycemia, glycosuria, ketonuria
  - osmotic diuresis
    - blood glucose levels rise above transport maximum of kidney tubules, glucose remains in urine (ketones also present)
    - increased osmolarity draws water into urine

# Classification

## Insulin Dependant Diabetes Mellitus

- Presents in childhood
- Typical catabolic effects
- Prone to develop ketoacidosis
- Lymphocytic infiltration of islets →  $\beta$ -cells destruction
- Aetiology
  - Autoimmunity
  - Genetic factors (HLA)
  - Viral infection (trigger?)

## Non-Insulin Dependant Diabetes Mellitus

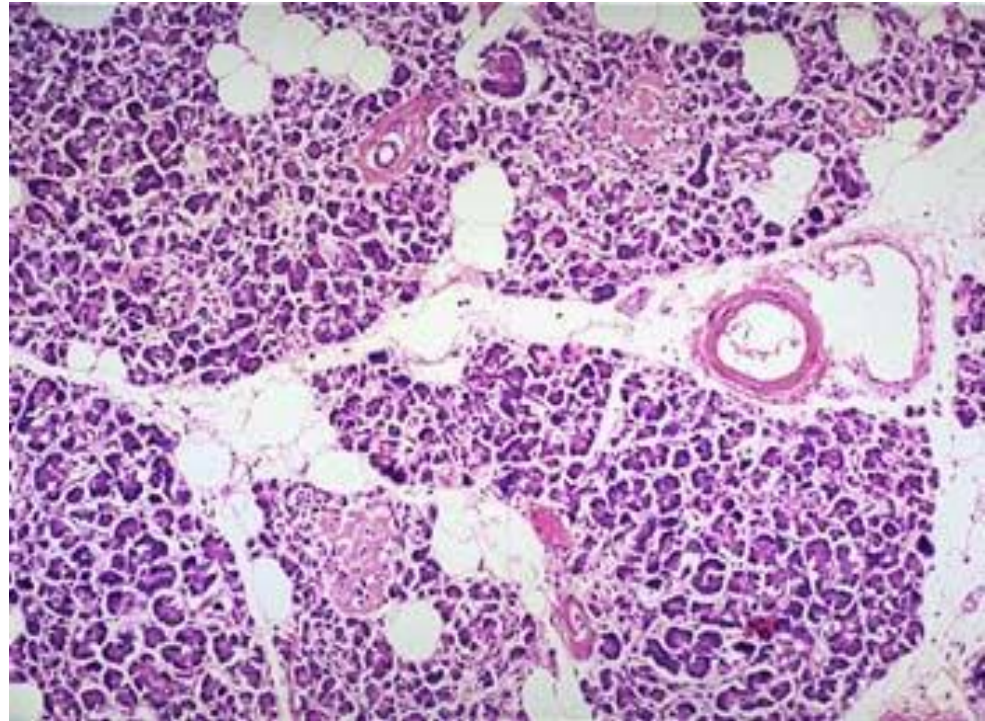
- Presents in adulthood
- Common in obese patients
- Not prone to ketoacidosis
- May develop a non-ketotic coma → hyperosmolarity of the plasma
- Insulin secretion normal or increased → reduction in number of cell surface receptors
- Aetiology
  - Genetic factors

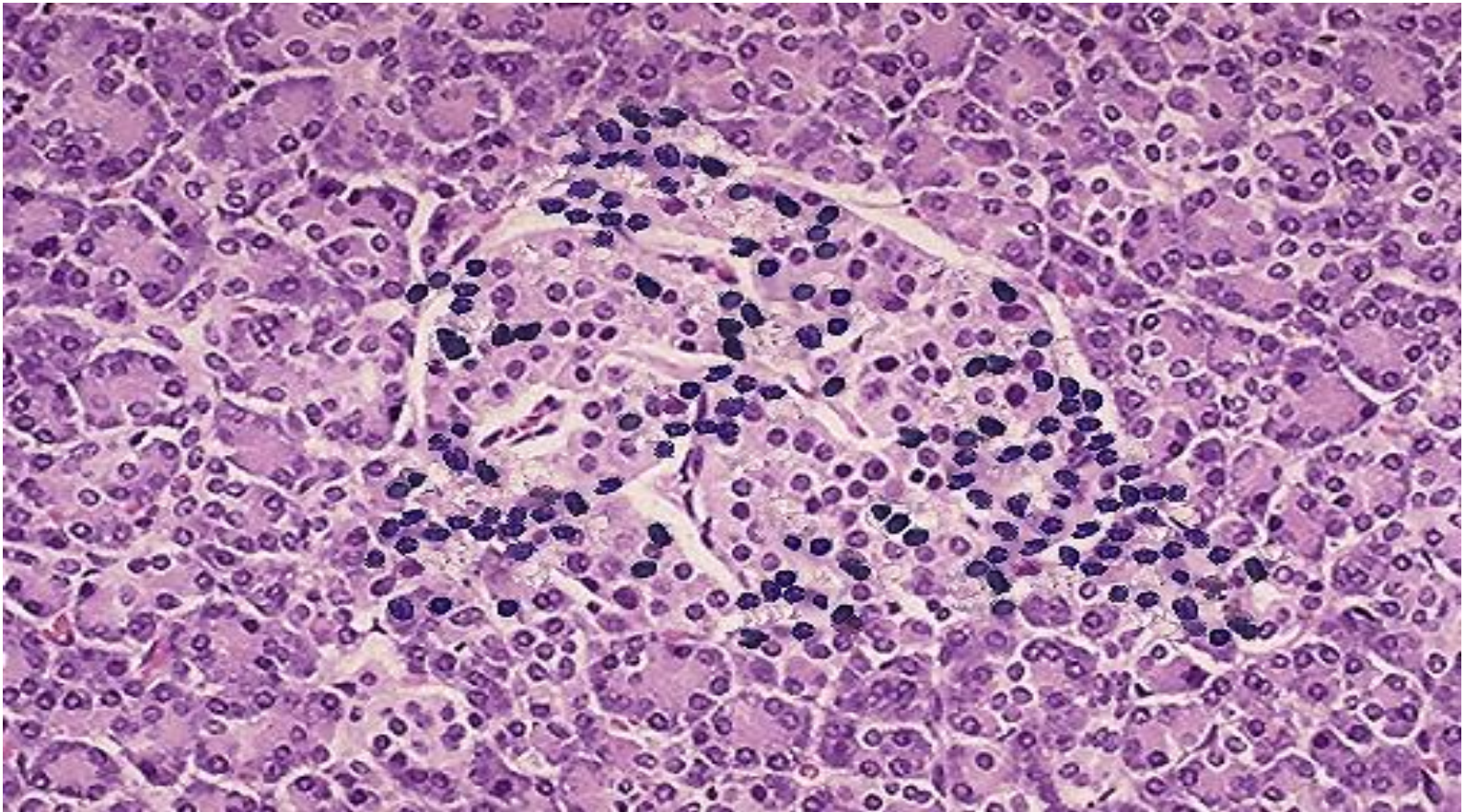
# Types of Diabetes Mellitus

- Type I (IDDM) - 10% of cases
  - autoimmune destruction of  $\beta$  cells, diagnosed  $\sim$  12
  - treat with diet, exercise, monitoring of blood glucose and insulin injections
- Type II (NIDDM) - 90%
  - insulin resistance
    - failure of target cells to respond to insulin
  - risk factors: heredity, age (40+) and obesity
  - treat with weight loss, diet and exercise
  - oral medications improve insulin secretion or target cell sensitivity

## Secondary Diabetes

- Chronic pancreatitis
- Hormonal tumours
- Corticosteroid drugs
- Haemochromatosis
- Genetic disorders
- Surgical

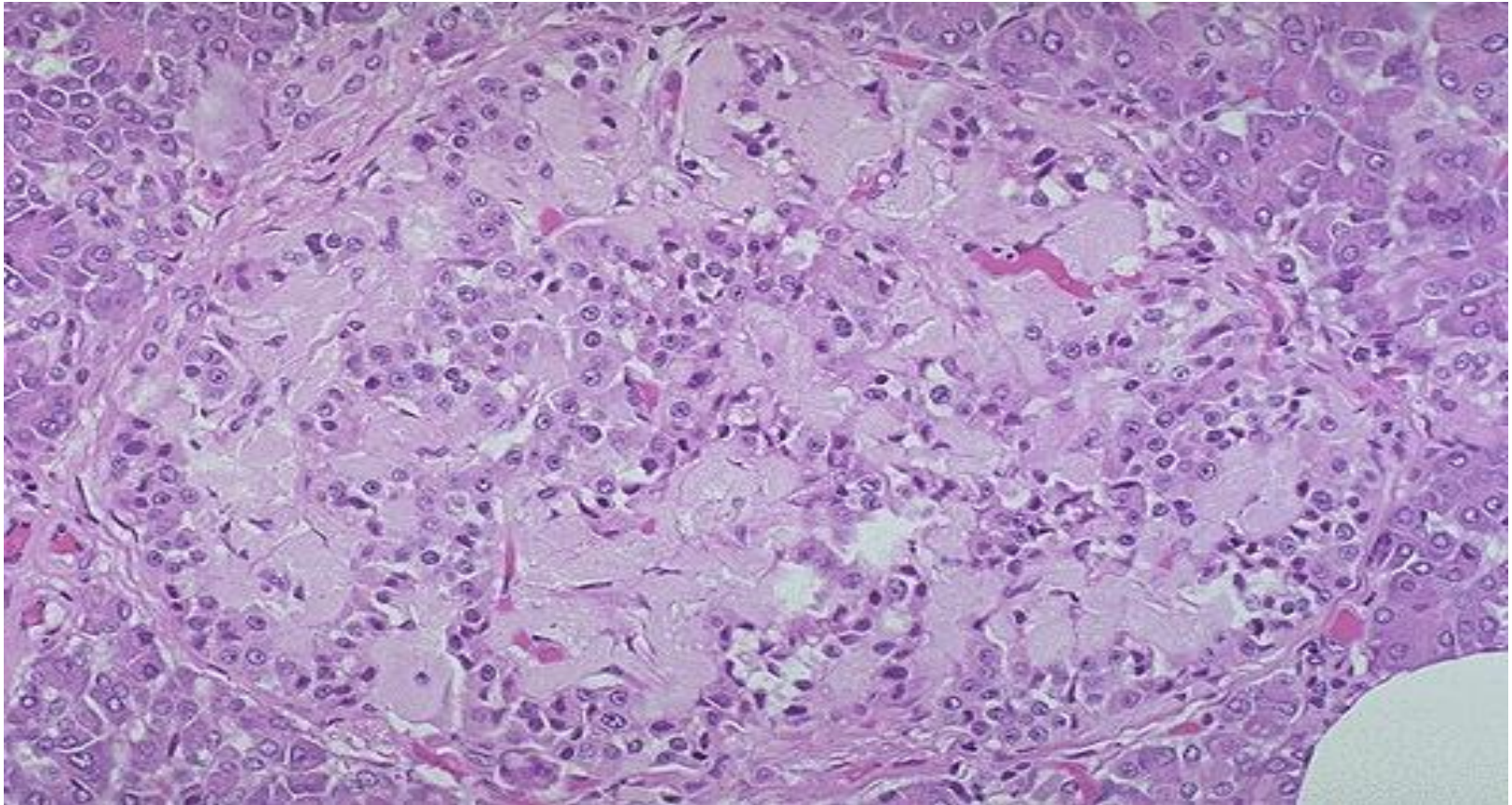




This is an **insulinitis** of an islet of Langerhans in a patient who will eventually develop type I diabetes mellitus.

The presence of the lymphocytic infiltrates in this edematous islet suggests an autoimmune mechanism for this process.

The destruction of the islets leads to an absolute lack of insulin that characterizes type I diabetes mellitus.



This islet of Langerhans demonstrates pink hyalinization (with deposition of amyloid) in many of the islet cells. This change is common in the islets of patients with **type II diabetes mellitus**.

# Complications

## Large Blood Vessels

- Accelerated ATH → MI; cerebrovascular dx; ischaemic limbs

## Small blood vessels

- Endothelial cells & basal lamina damage
- Retinopathy → blindness
- Nephropathy
- Gangrene of extremities

## Peripheral Nervous System

- Neuropathy

## Neutrophils

- Susceptibility to infections

## Pregnancy

- Pre-eclampsia toxemia; large babies; neonatal hypoglycaemia