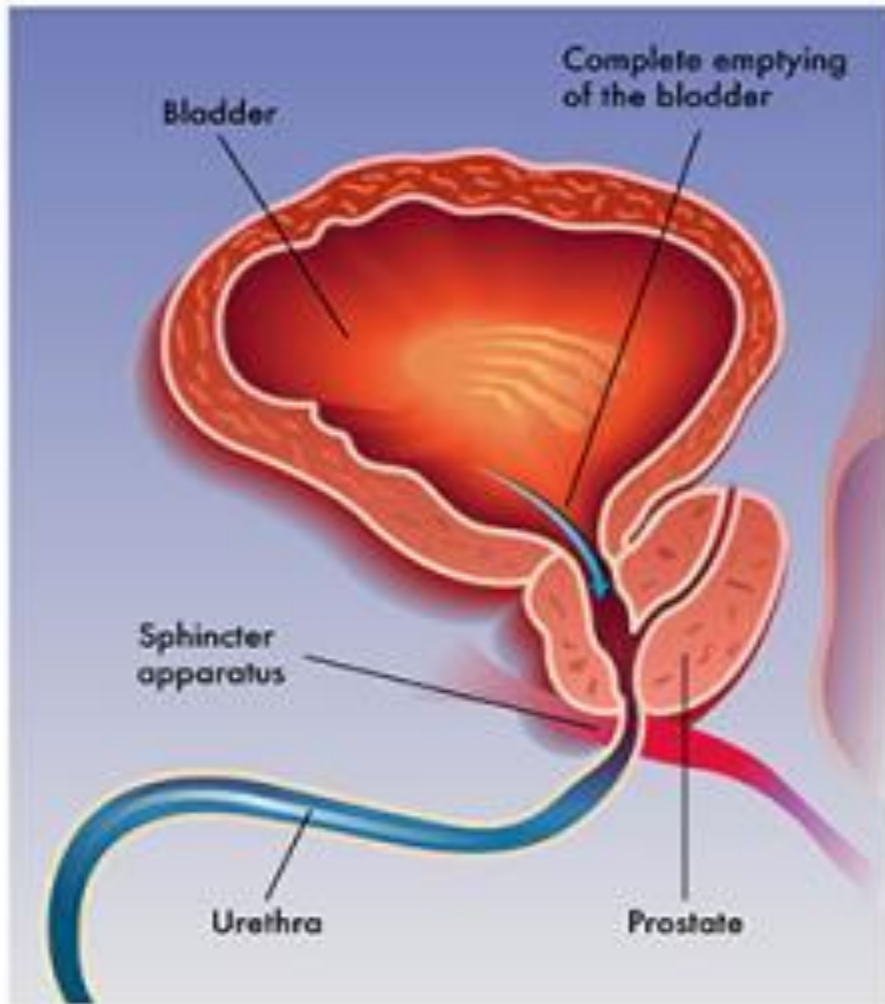
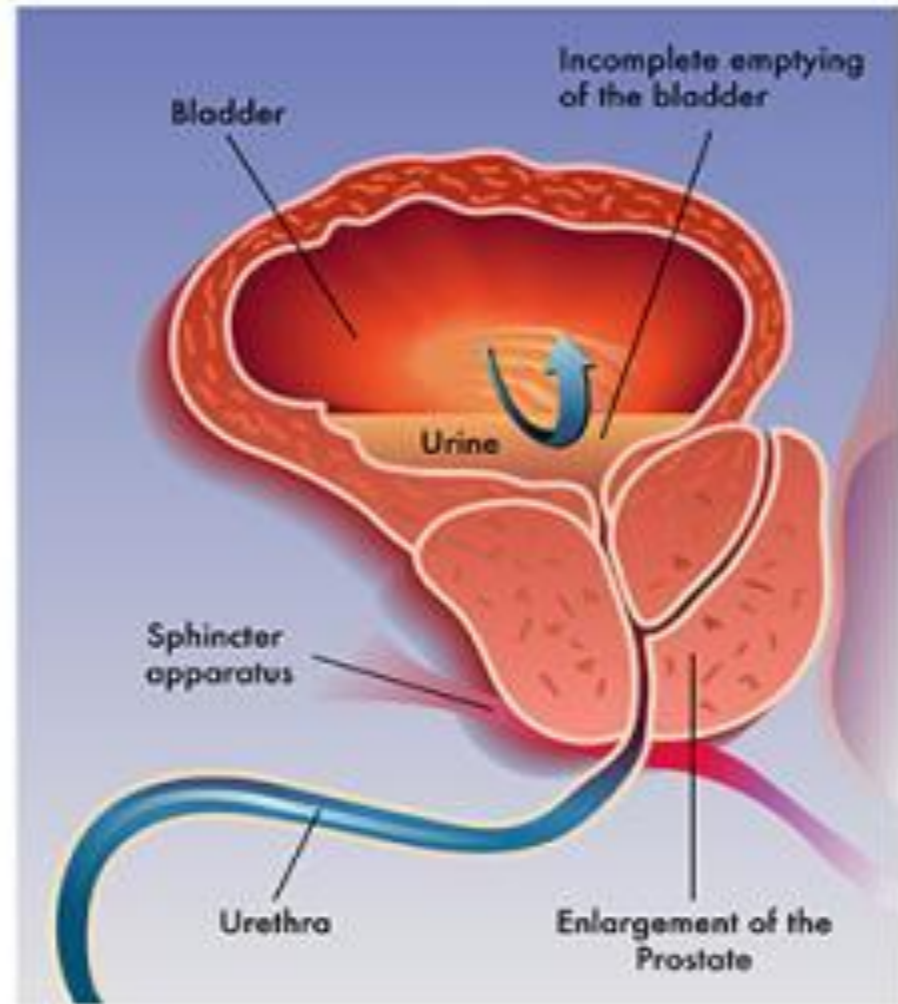


Normal Prostate



Prostatic Hypertrophy



Patologia sistemului genital masculin, infecțiile sexual transmisibile.

Болезни мужских половых органов. Инфекции, передающиеся половым путем.

Pathology of the male genital system, sexually transmitted infections.

Tema: Patologia sistemului genital masculin, infecțiile sexual transmisibile.

I. Micropreparate :

№ 226. Ginecomastia. (colorație H-E). Indicații:

1. Ducturi glandulare dilatate cu proliferarea epiteliului.
2. Fascicule de țesut fibroconjunctiv.
3. Țesut adipos.

№ 227. Adenocarcinom de prostată pe fond de hiperplazie glandulară. (colorație H-E). Indicații:

1. Focarul de țesut canceros cu proliferarea unor structuri glandulare atipice.
2. Țesutul prostatic adiacent cu semne de hiperplazie:
 - a. glande dilatate chistic de formă neregulată;
 - b. țesut fibro-muscular.

№ 214. Seminom testicular. (colorație H-E). Indicații:

1. Celule tumorale de formă poligonală cu citoplasma clară.
2. Infiltrate limfoide în fasciculele fibroconjunctive.

№ 33. Mezaortită sifilitică. (colorație H-E). Indicații:

1. Infiltrate limfo-plasmocitare în jurul *vasa vasorum* în adventiția și media peretelui aortei.
2. Focare de distrucție a fibrelor elastice.
3. Focare de calcinoză.

II. Macropreparate :

№ 90. Hiperplazia nodulară a prostatei cu hipertrofia peretelui vezicii urinare.

№ 15. Aneurism sifilitic al aortei.

Тема : Болезни мужских половых органов. Инфекции, передающиеся половым путем.

I. Микропрепараты:

№ 226. Гинекомастия. (окраска Г-Э). Обозначения:

1. Расширенные железистые протоки с пролиферацией эпителия.
2. Прослойки соединительной ткани между протоками.
3. Жировая ткань.

№ 227. Аденокарцинома предстательной железы на фоне железистой гиперплазии. (окраска Г-Э).

Обозначения:

1. Очаговое разрастание атипичных раковых железистых структур.
2. Прилежащая ткань простаты с признаками гиперплазии:
 - а. кистозно расширенные железы неправильной формы;
 - б. фиброзно-мышечная ткань.

№ 214. Тестикулярная семинома. (окраска Г-Э). Обозначения:

1. Опухолевые клетки полигональной формы со светлой цитоплазмой.
2. Лимфоидные инфильтраты в прослойках фиброзной ткани между тяжами опухолевых клеток.

№ 33. Сифилитический мезаортит. (окраска Г-Э). Обозначения:

1. Лимфоидно-плазмоцитарная инфильтрация по ходу *vasa vasorum* в адвентиции и медики стенки аорты.
2. Очаги деструкции (разрыва) эластических волокон.
3. Очаговые отложения солей кальция.

II. Макропрепараты:

№ 90. Узловатая гиперплазия предстательной железы с гипертрофией стенки мочевого пузыря.

№ 15. Сифилитическая аневризма аорты.

Pathology of the male genital system, sexually transmitted infections.

I. Microspecimens:

№ 226. Gynecomastia. (H.E. stain). Indications:

1. Dilated glandular ducts with proliferation of the epithelium;
2. Fibrous tissue bundles;
3. Adipose tissue.

№ 227. Prostatic adenocarcinoma on benign prostatic hyperplasia background. (H.E. stain). Indications:

1. Focus of cancerous tissue with proliferation of atypical glandular structures;
2. Adjacent prostate tissue with signs of hyperplasia;
 - a. cystically dilated glands of irregular shape;
 - b. fibro-muscular tissue.

№ 214. Testicular seminoma. (H.E. stain). Indications:

1. Tumoral cells with clear cytoplasm and polygonal shape.
2. Lymphoid infiltrates into connective tissue bundles.

№ 33. Syphilitic mesaortitis. (H.E. stain). Indications:

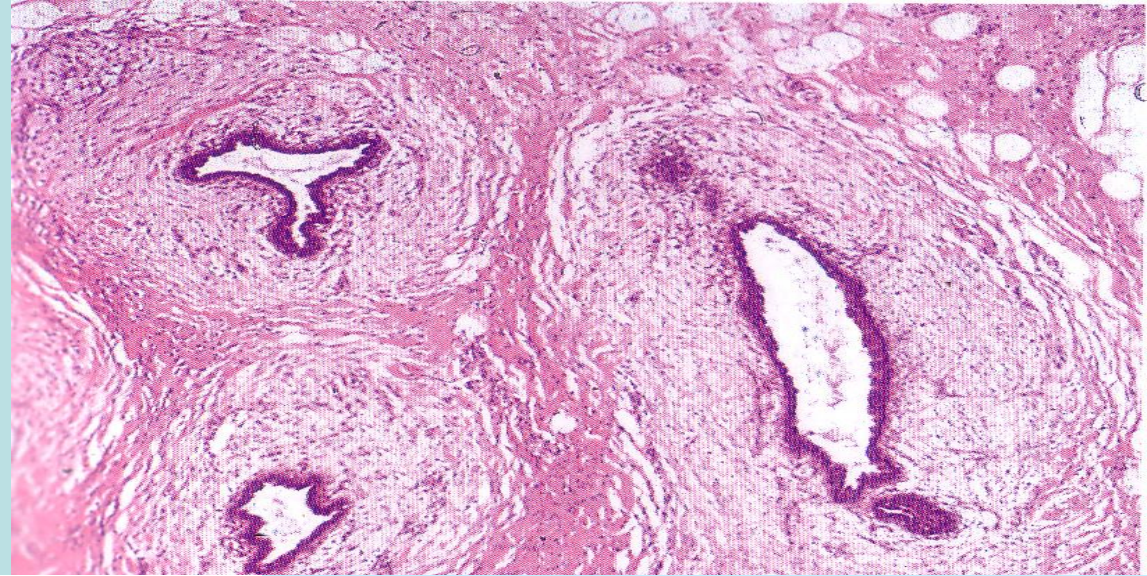
1. Lymphoplasmacytic infiltration around vasa vasorum, in adventitia and in media of aortic wall ;
2. Foci of destruction of elastic fibers;
3. Foci of calcinosis.

II. Macrospecimens:

№ 90. Glandular prostatic hyperplasia with urinary bladder wall hypertrophy.

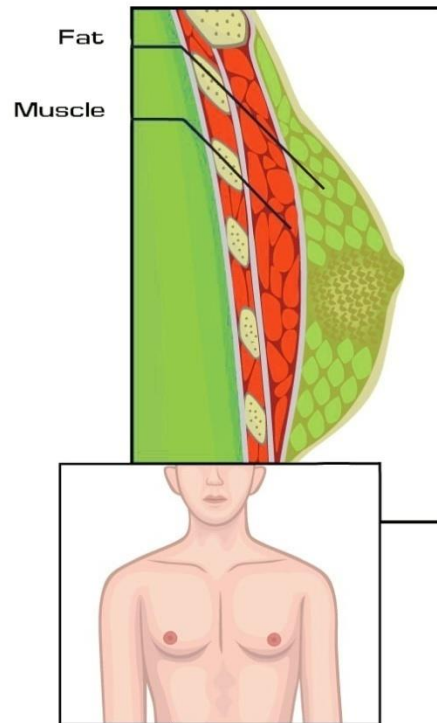
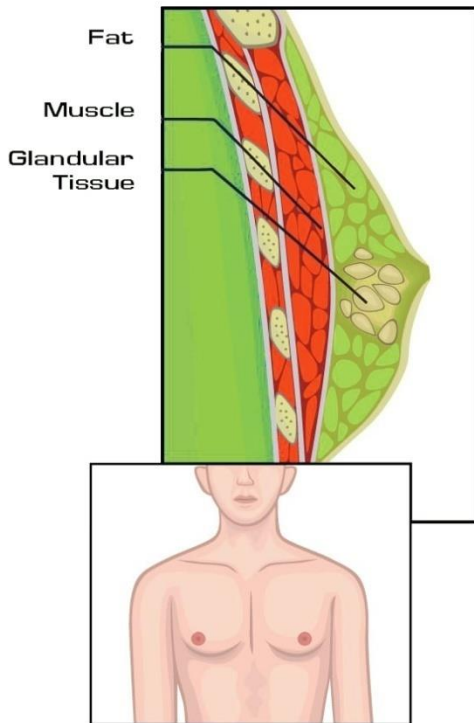
№ 15. Aortic aneurysm in syphilis.

Ginecomastie

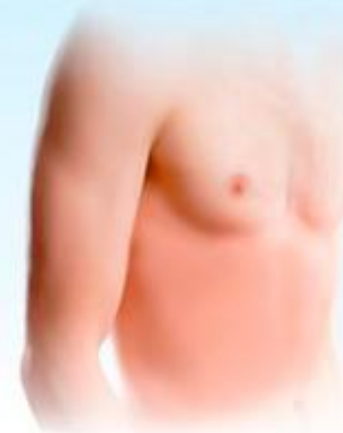

Gynecomastia

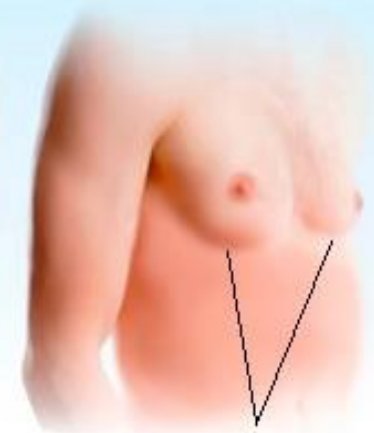Pseudogynecomastia



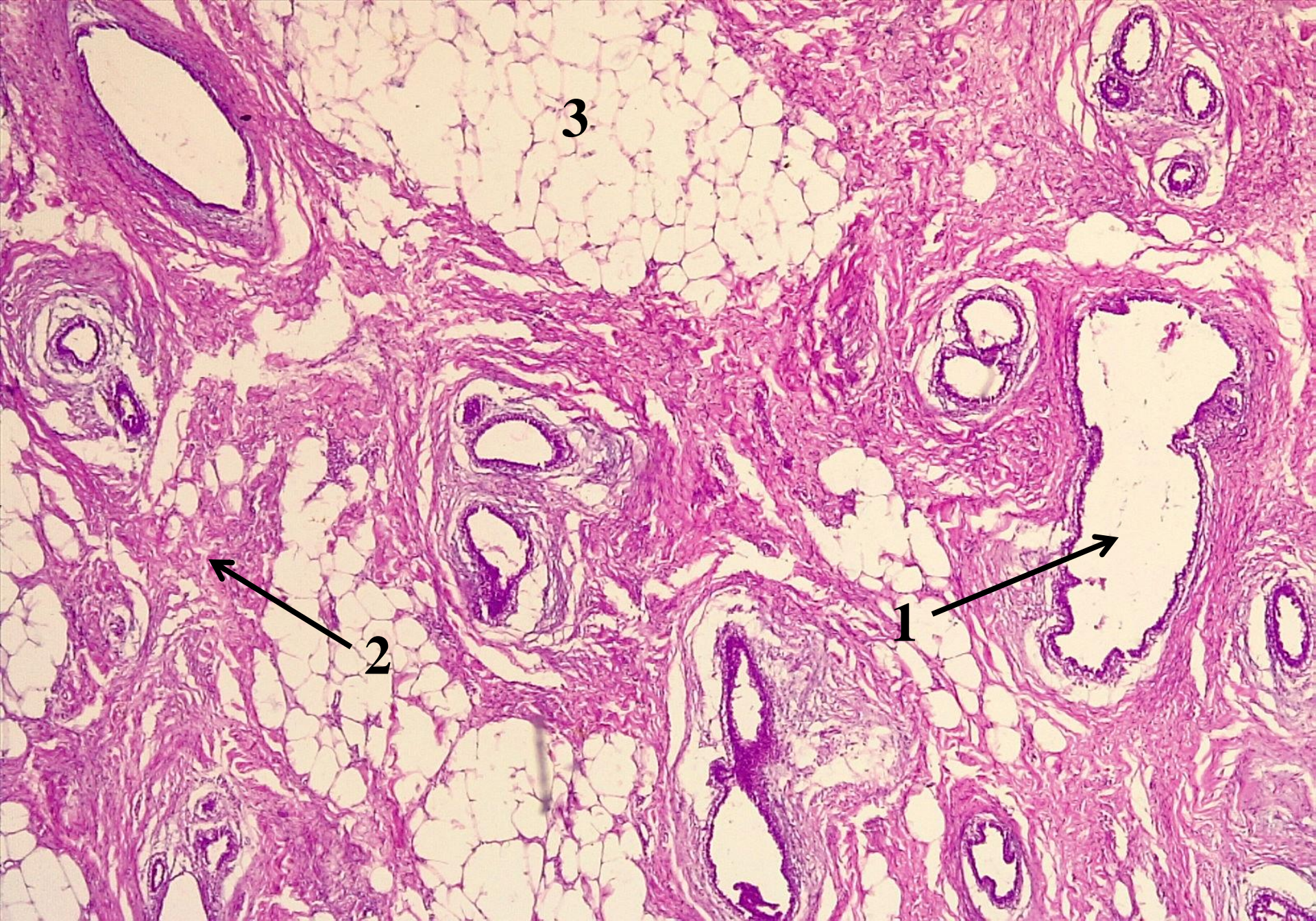
Gynecomastia



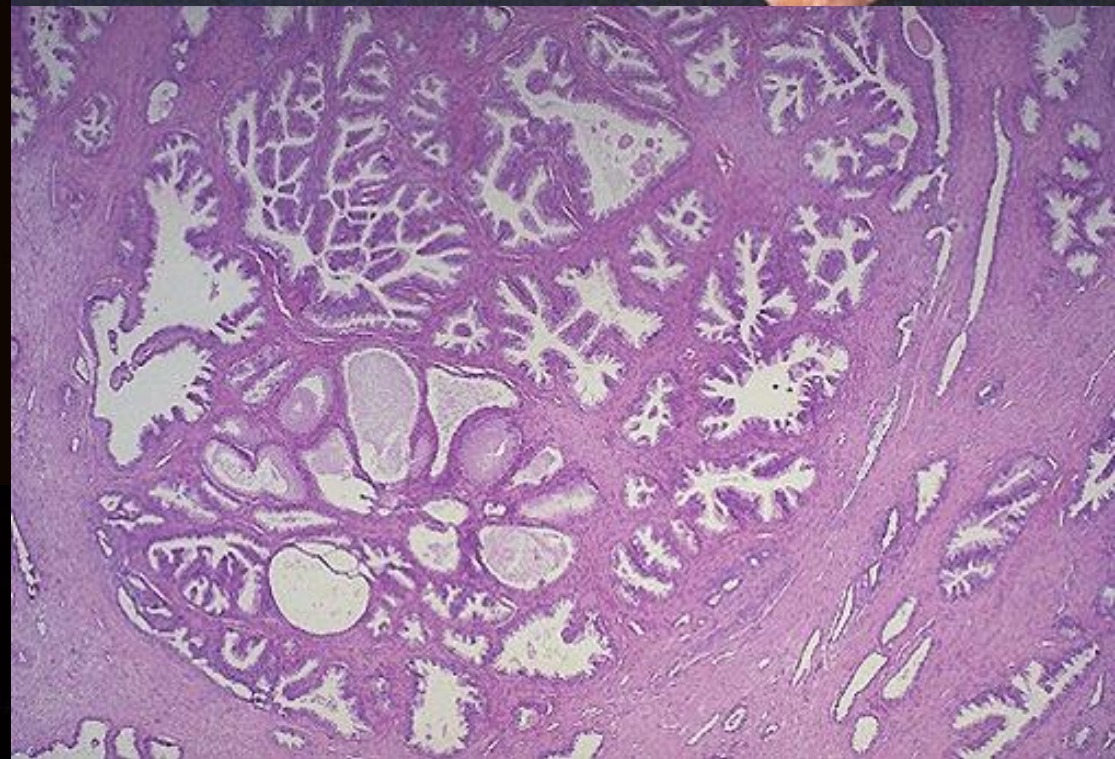
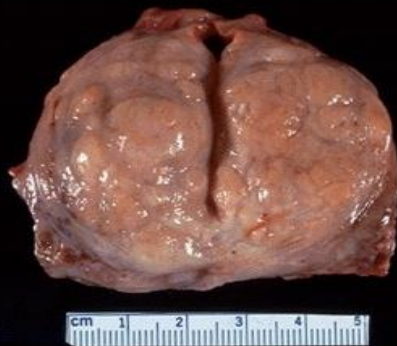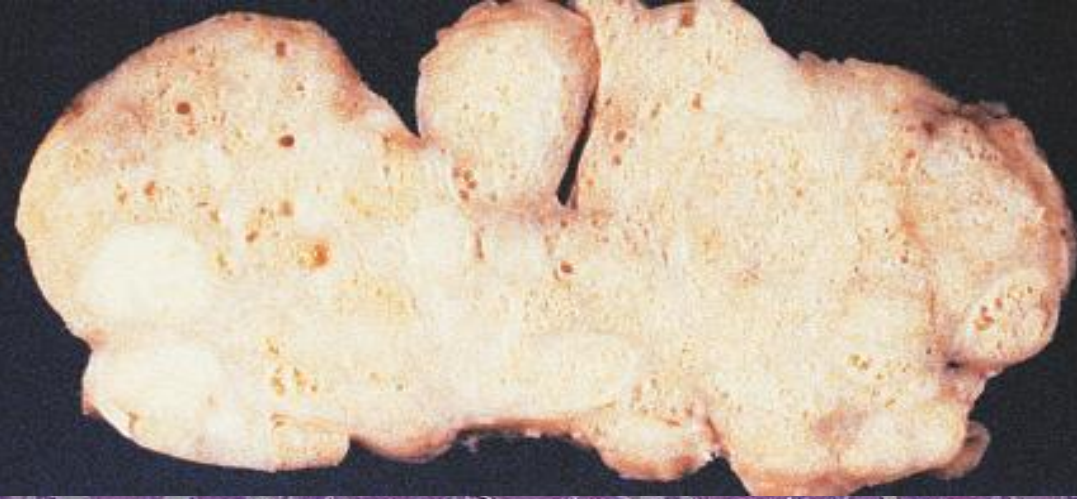
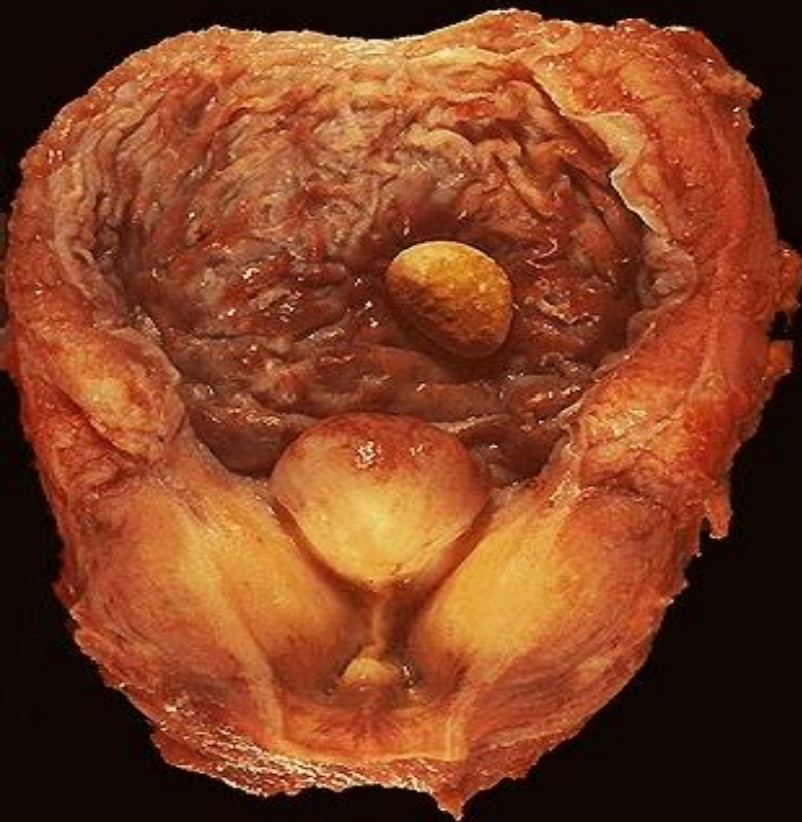Normal male breast



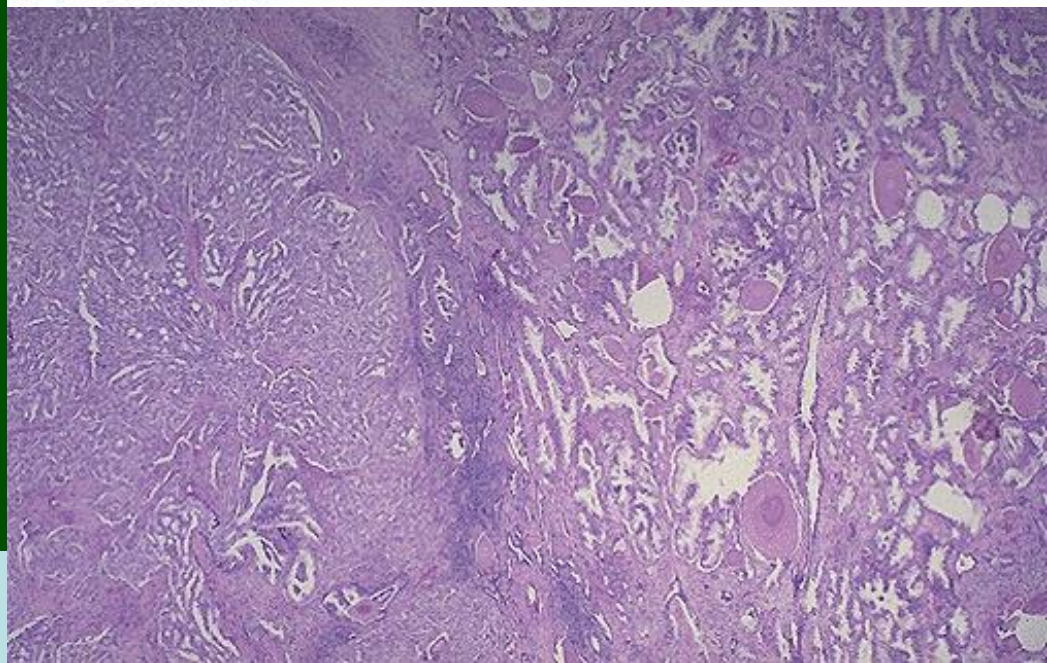
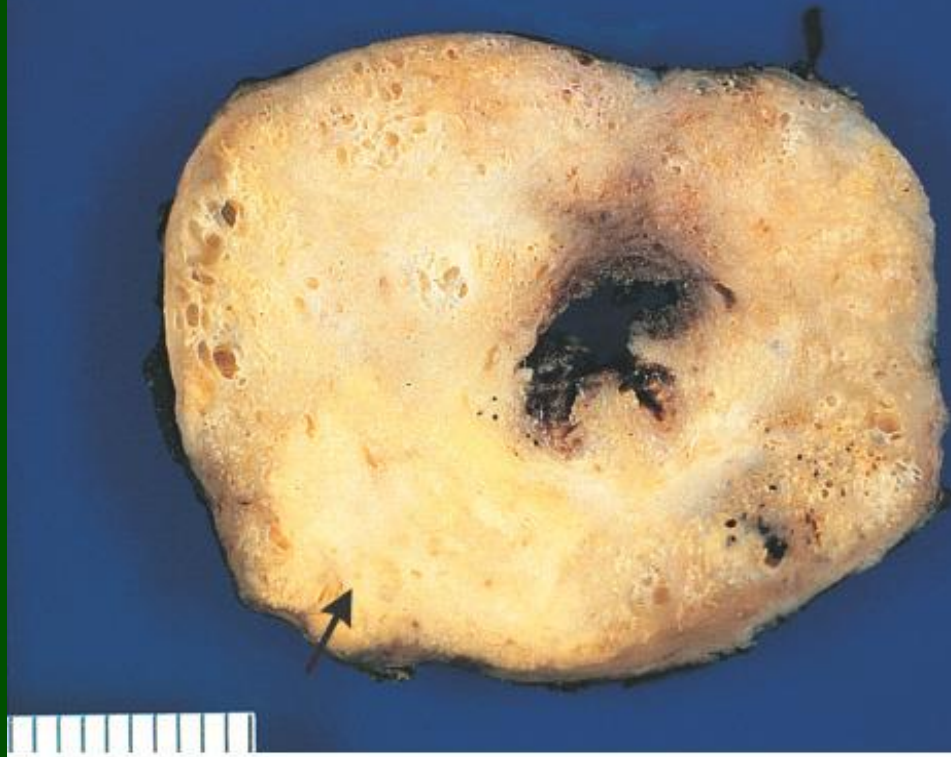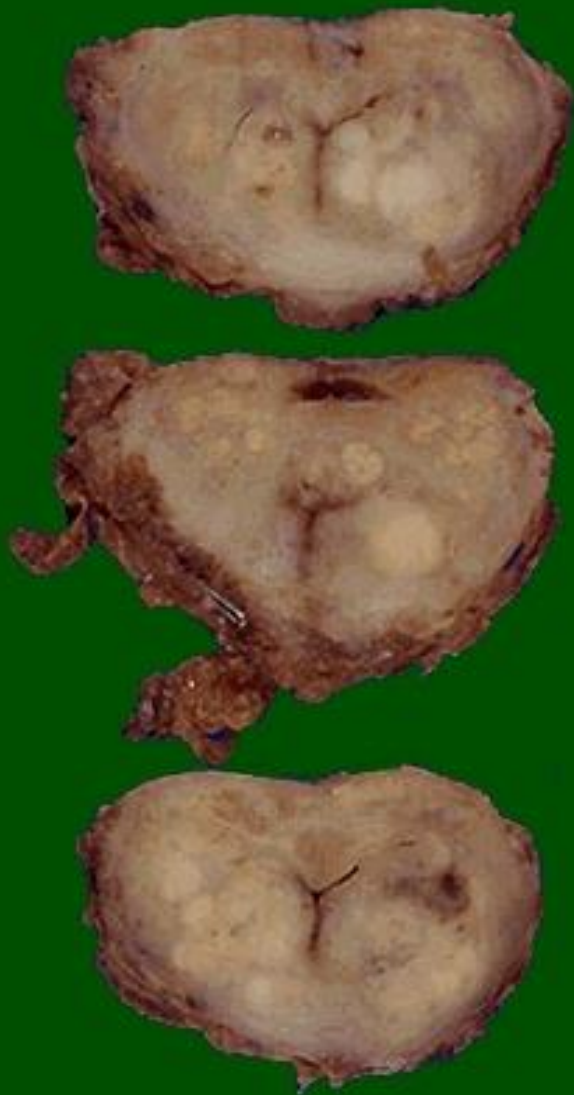
Bilateral enlargement of male mammary glands



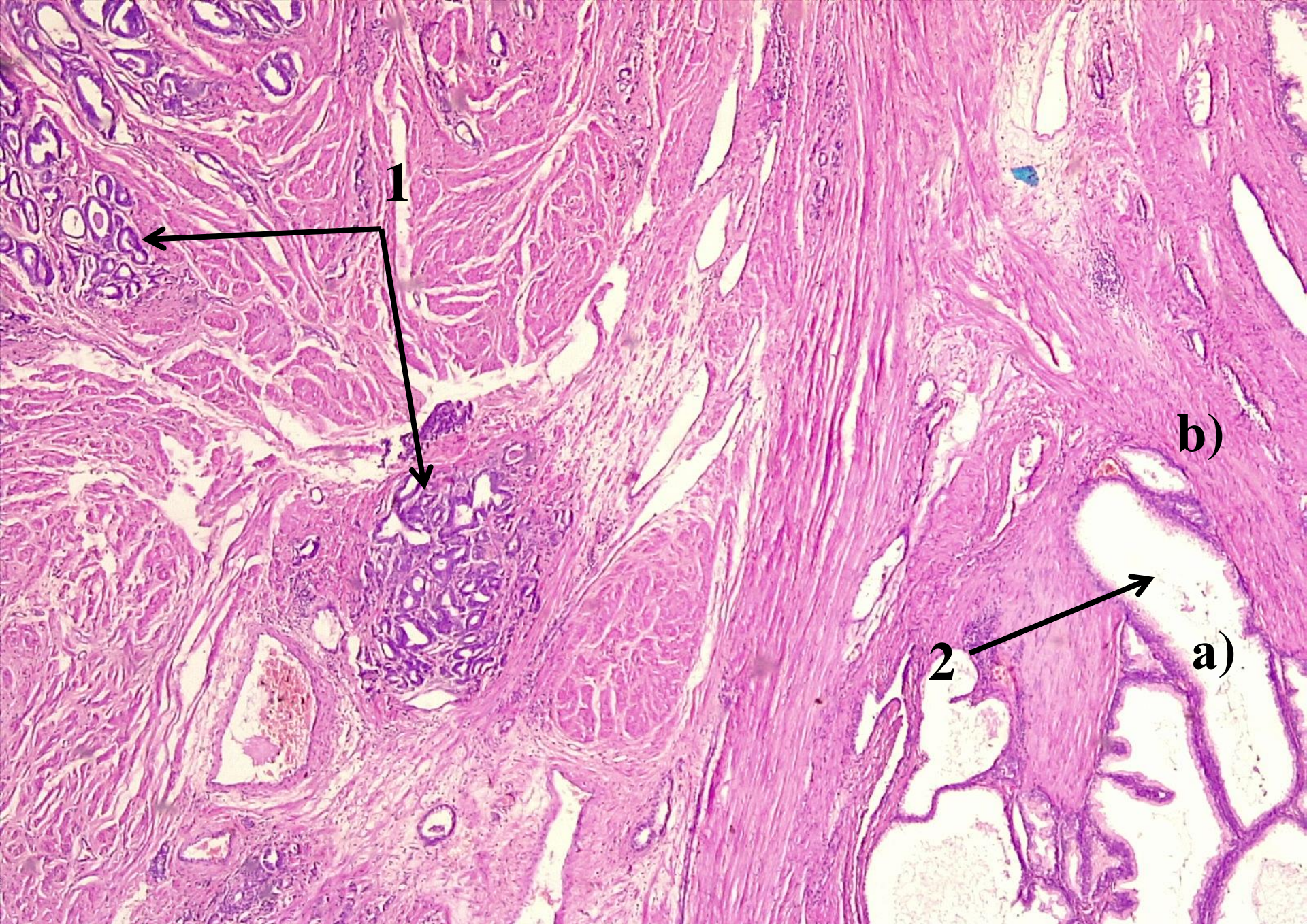
№ 226. Ginecomastie. (colorație H-E).



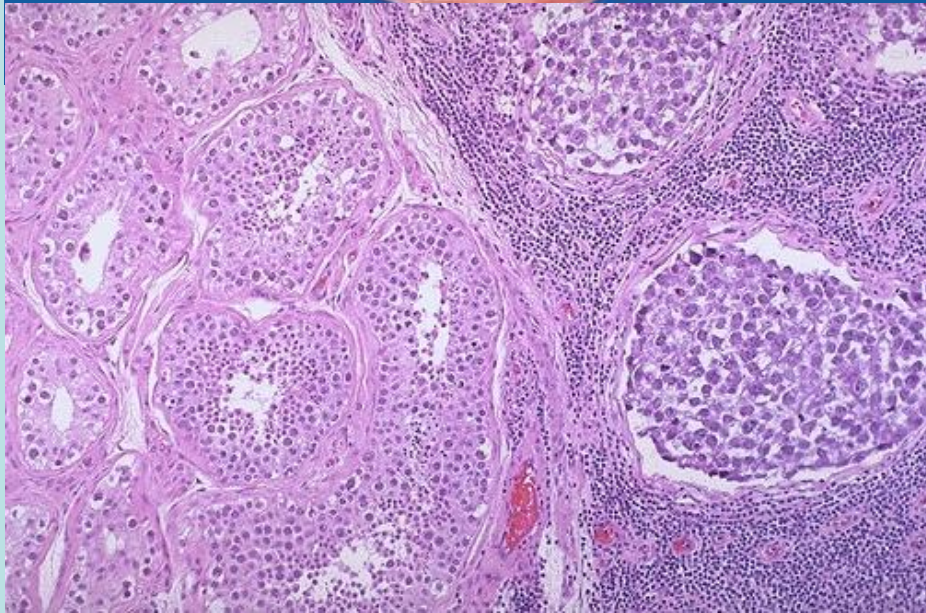
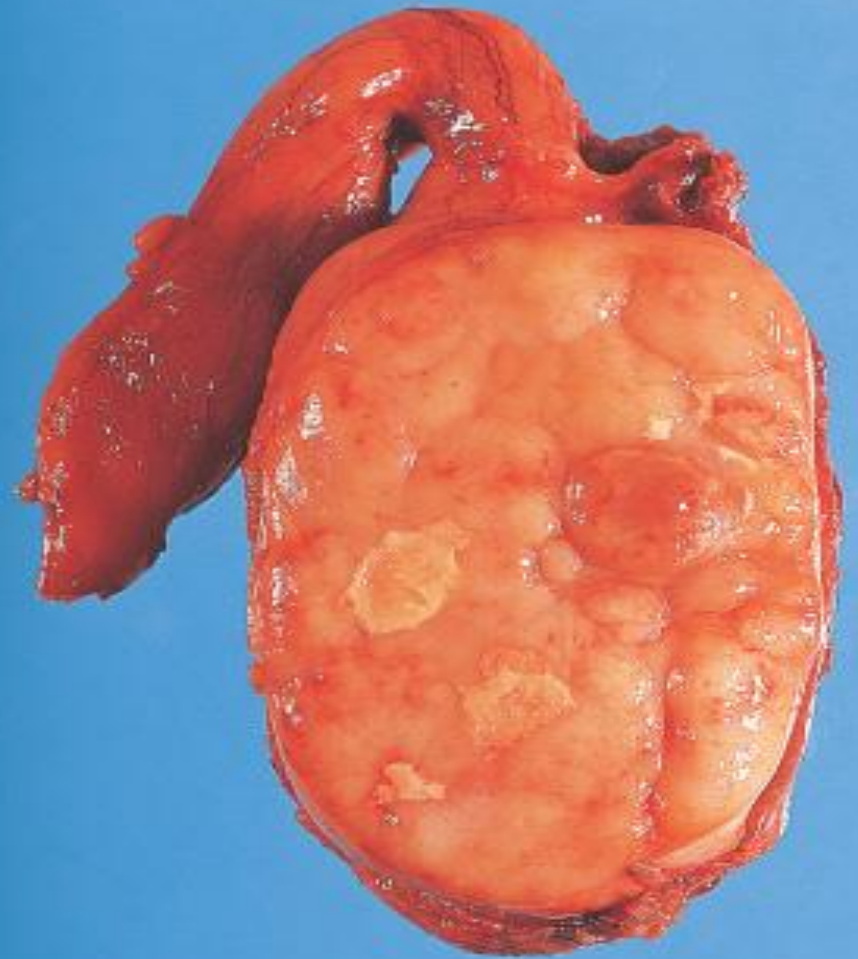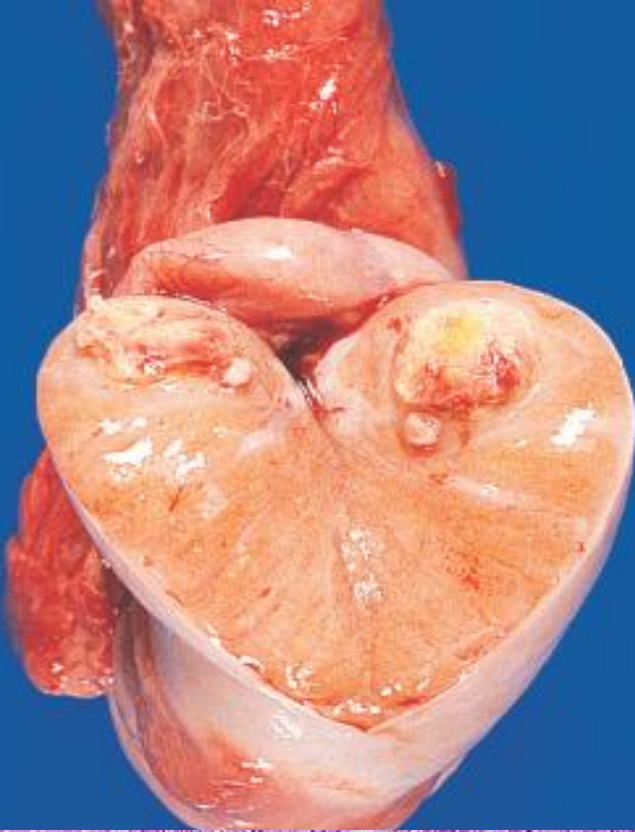
Hiperplazie nodulară a prostatei.



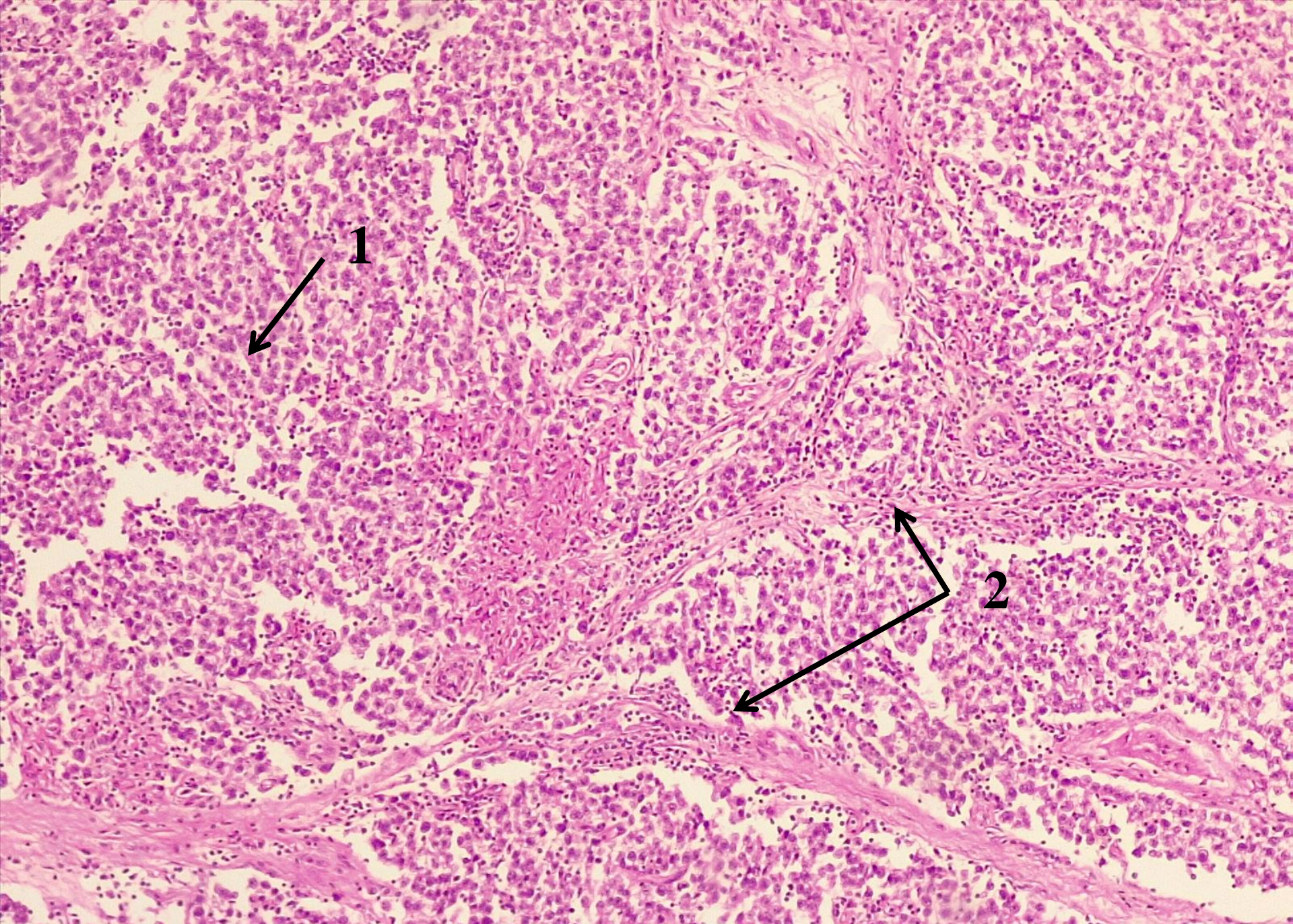
Adenocarcinom de prostată pe fond de hiperplazie glandulară.



№ 227. Adenocarcinom de prostată pe fond de hiperplazie glandulară. (colorație H-E).

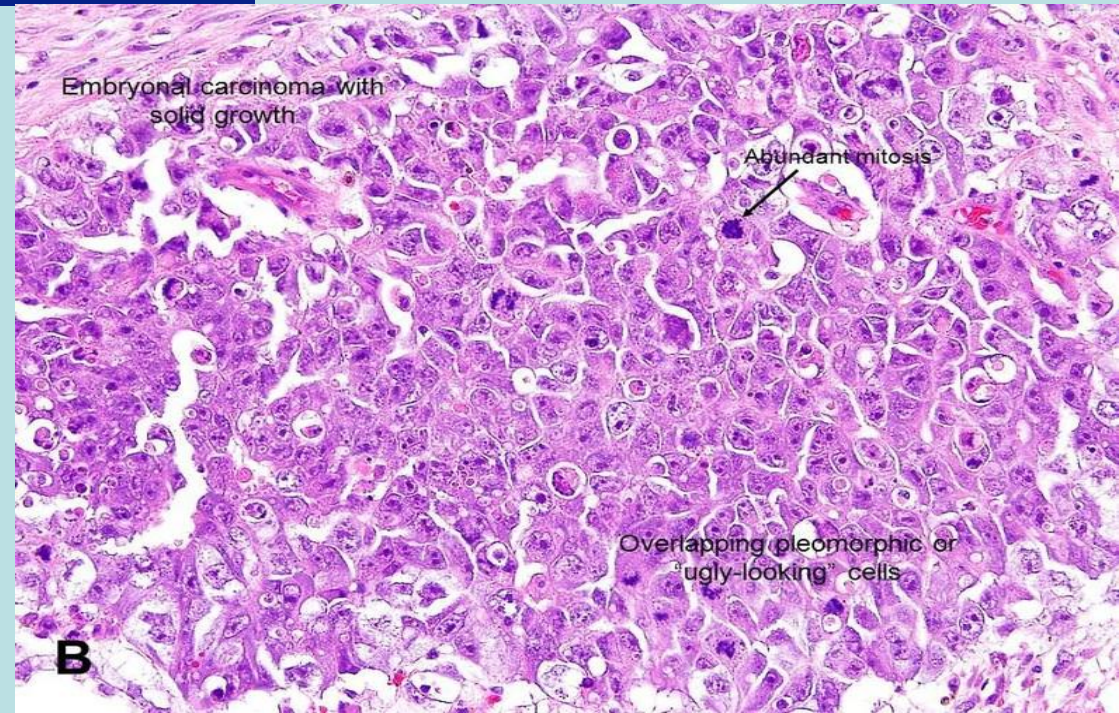
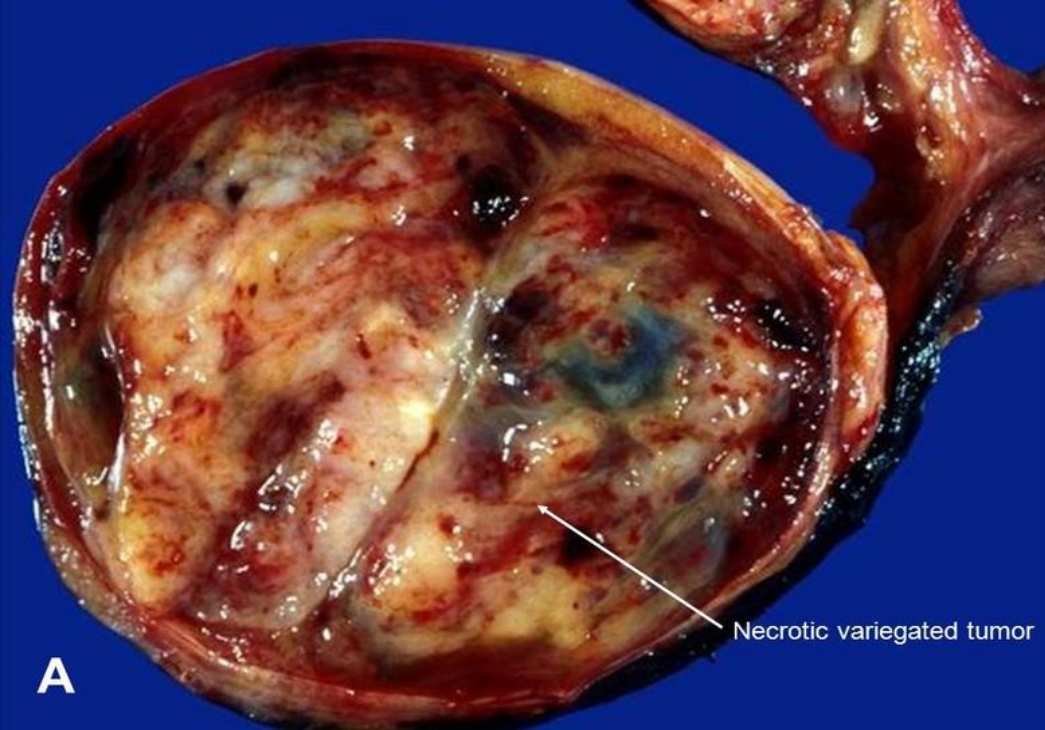

**Seminom
testicular.**


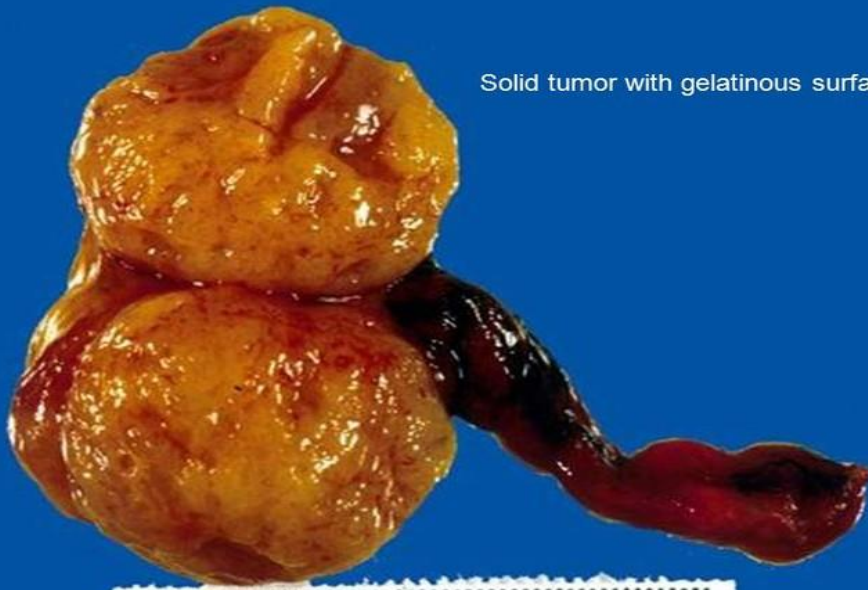


№ 214. Seminom testicular. (colorație H-E).

Carcinom testicular embrional. (pattern solid).

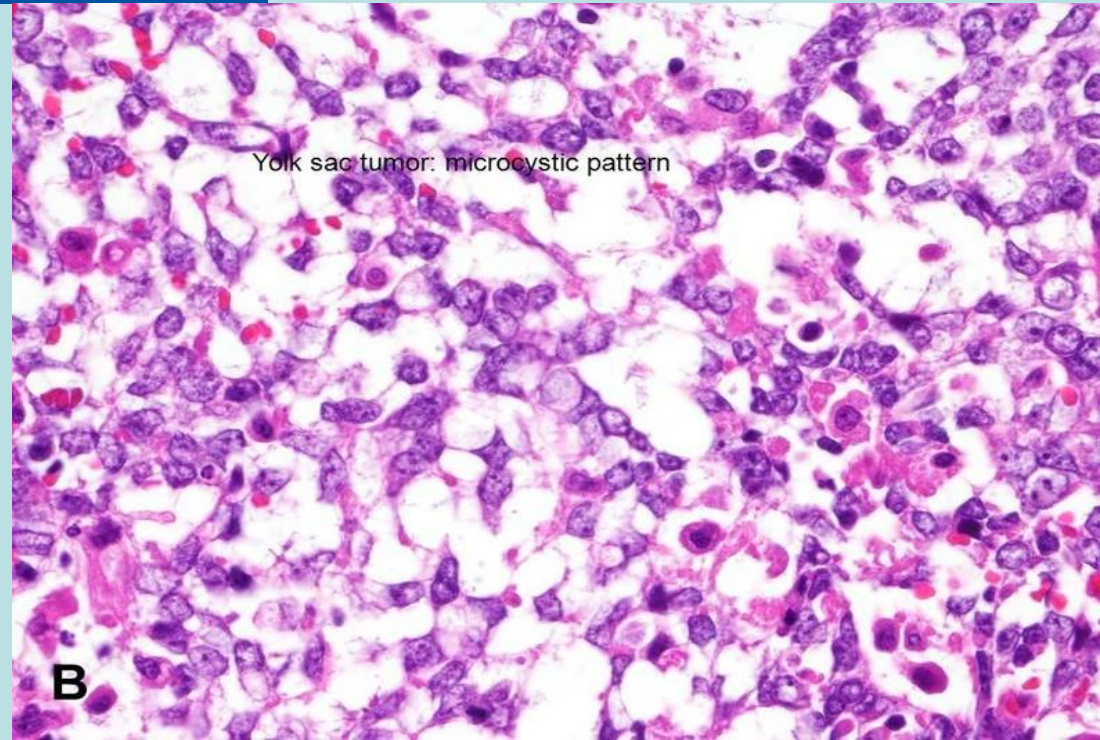


Solid tumor with gelatinous surface

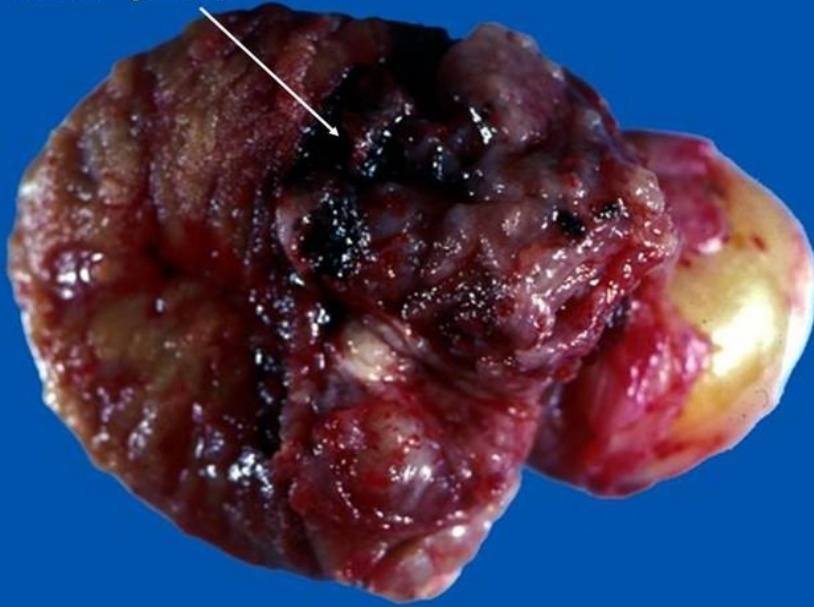

**Tumora de sac Yolc
(sac vitelin) testiculară.
(pattern microchistic).**

Yolk sac tumor: microcystic pattern



Hemorrhagic tumor

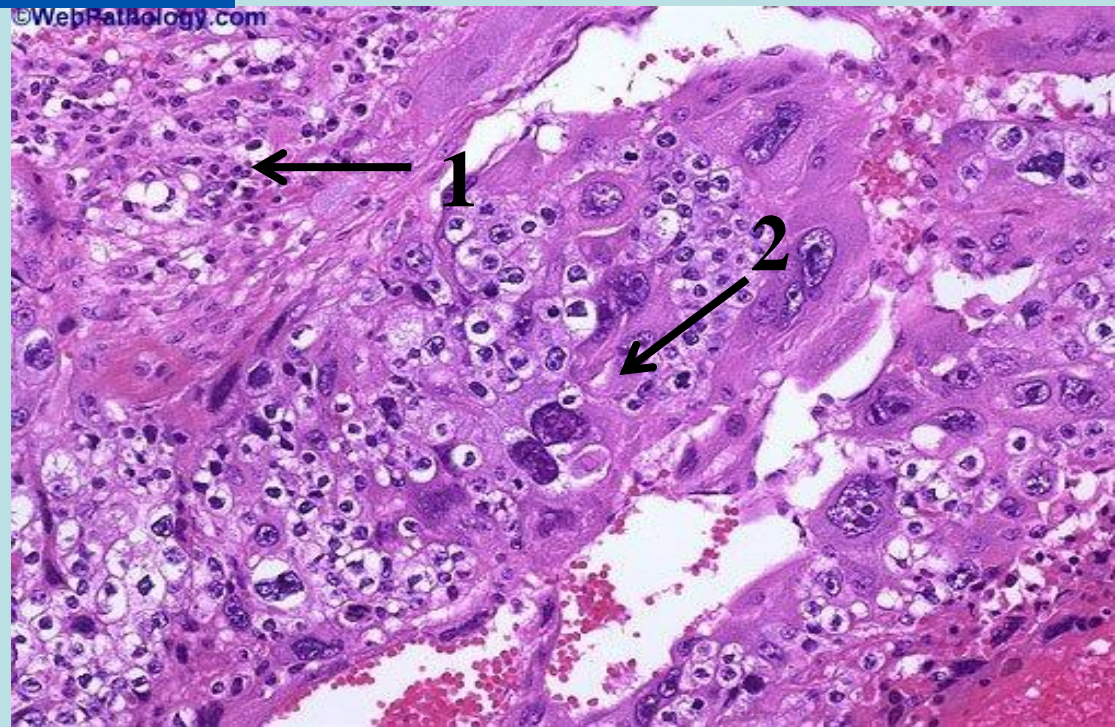


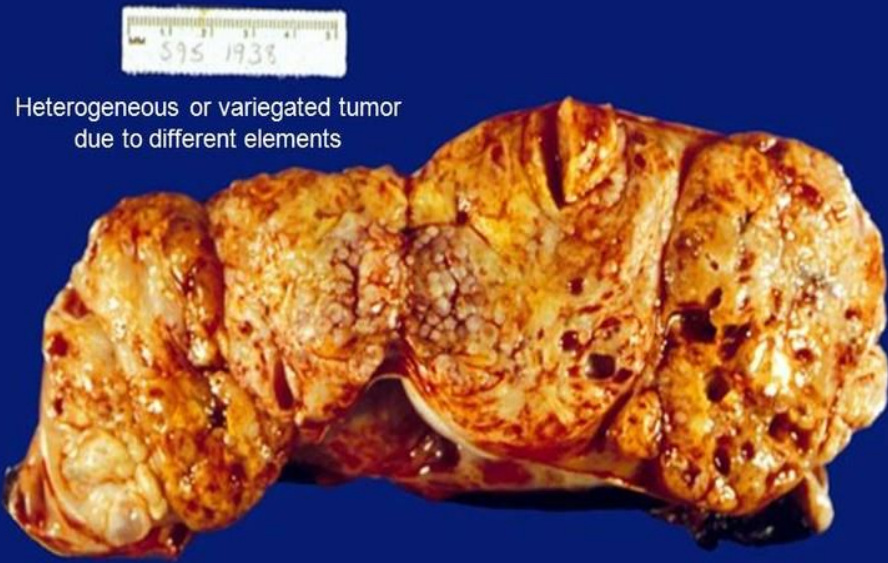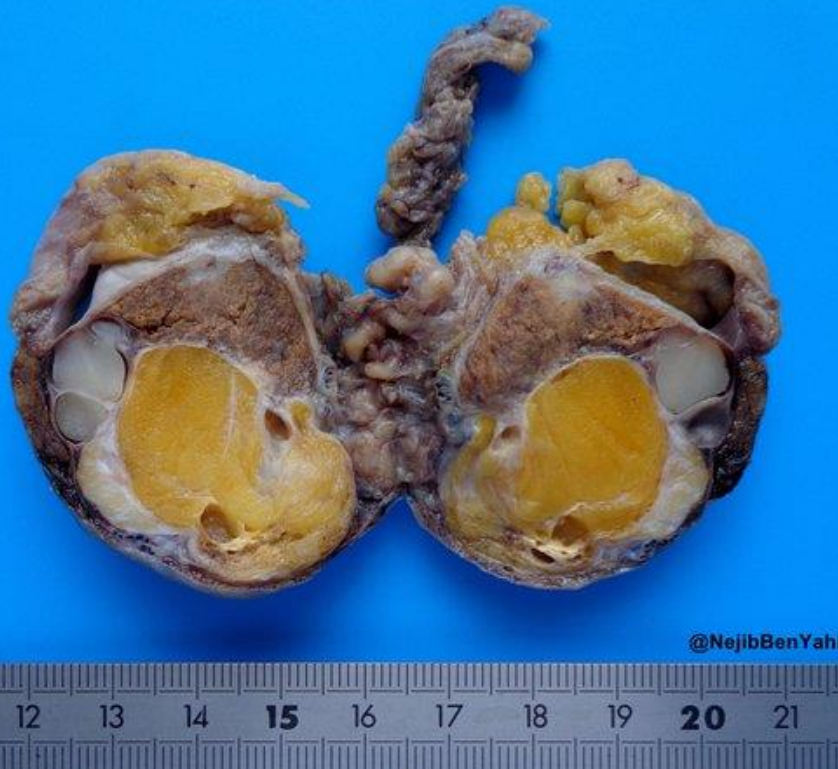A

Coriocarcinom testicular.

1. Citotrofoblast.
2. Sincitiotrofoblast.

©WebPathology.com



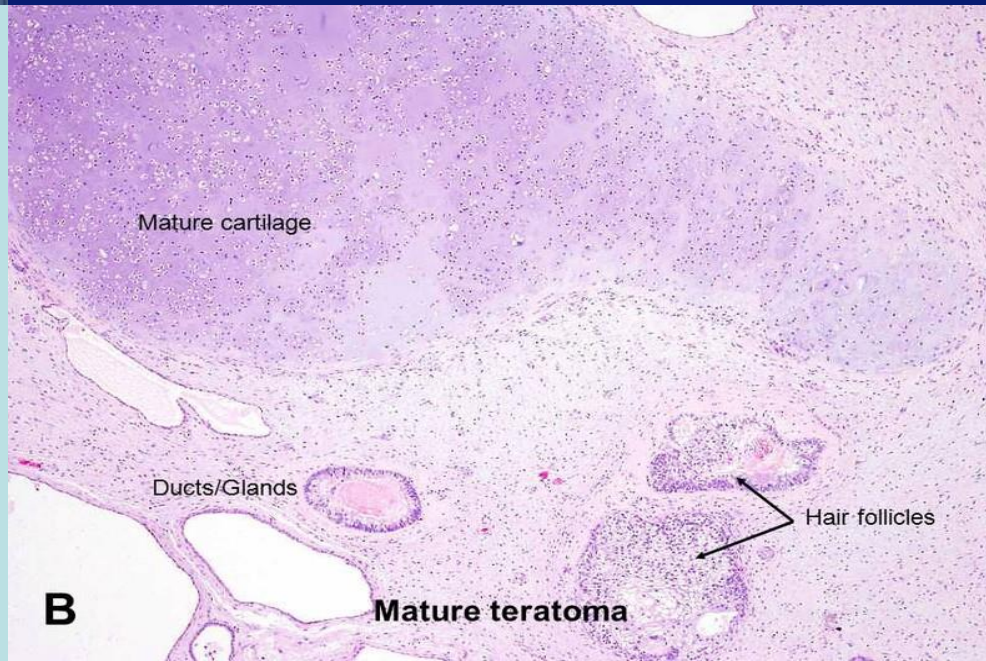


Heterogeneous or variegated tumor due to different elements

A

Mature teratoma

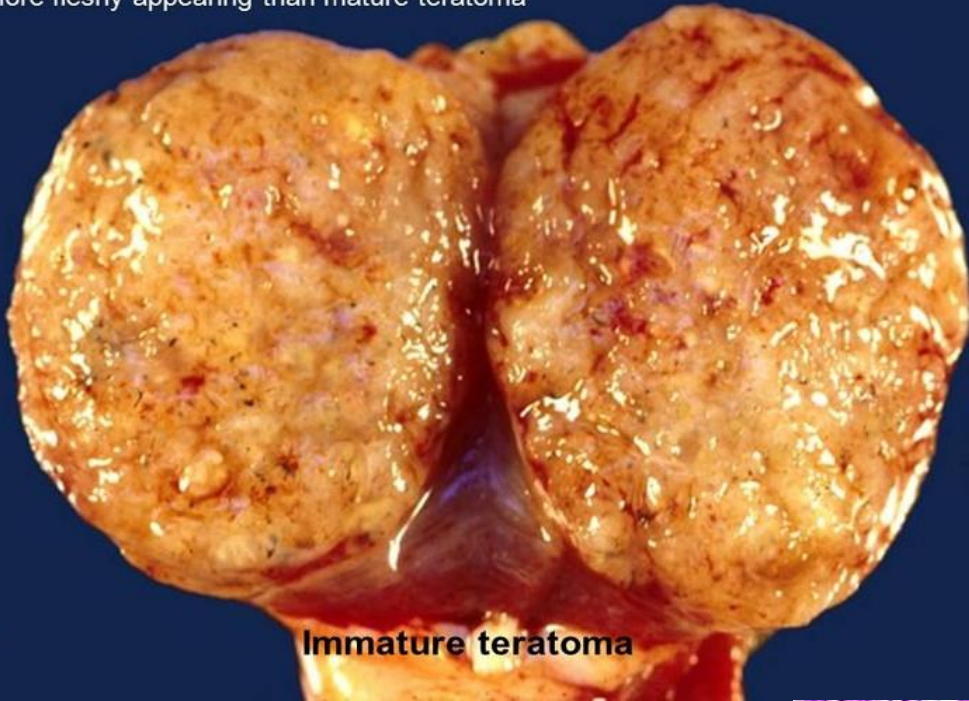
Teratom testicular matur.



B

Mature teratoma

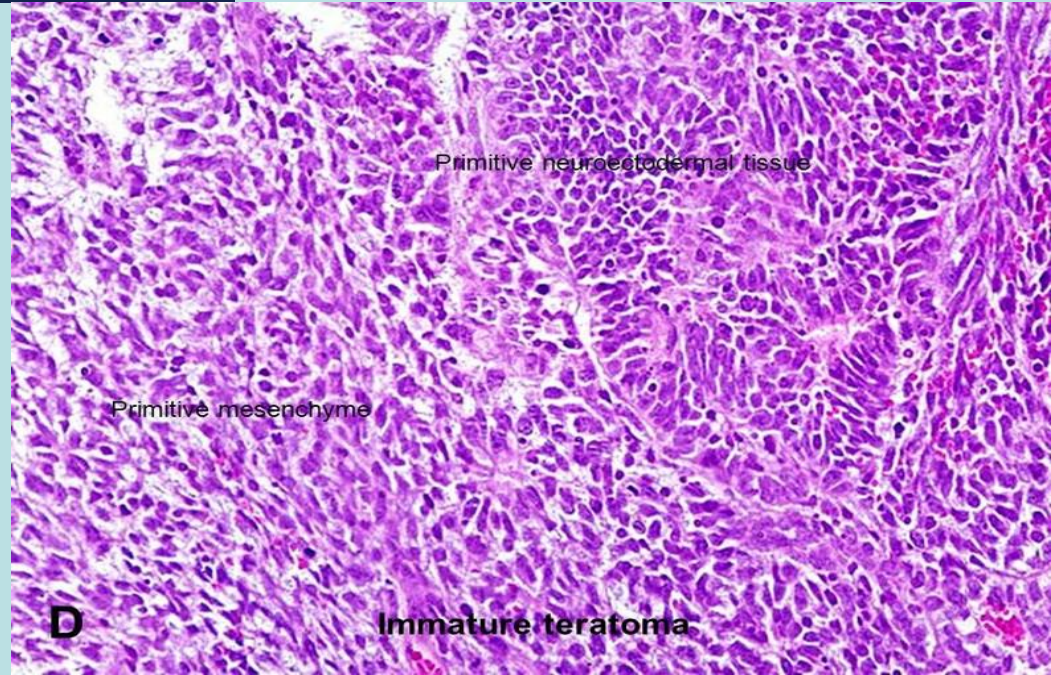
More fleshy appearing than mature teratoma



C

Immature teratoma

Teratom testicular imatur.



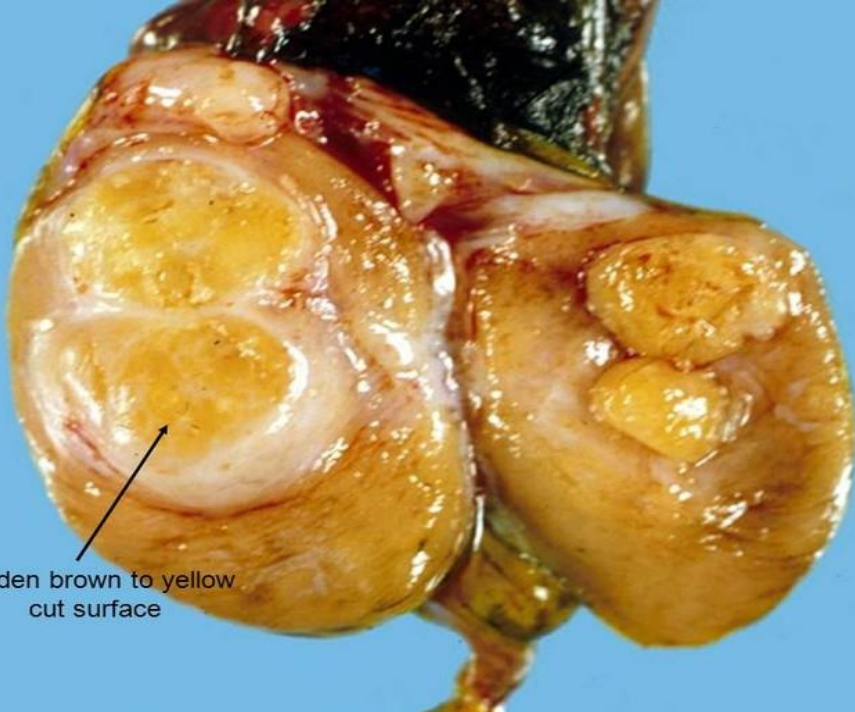Primitive neuroectodermal tissue

Primitive mesenchyme

D

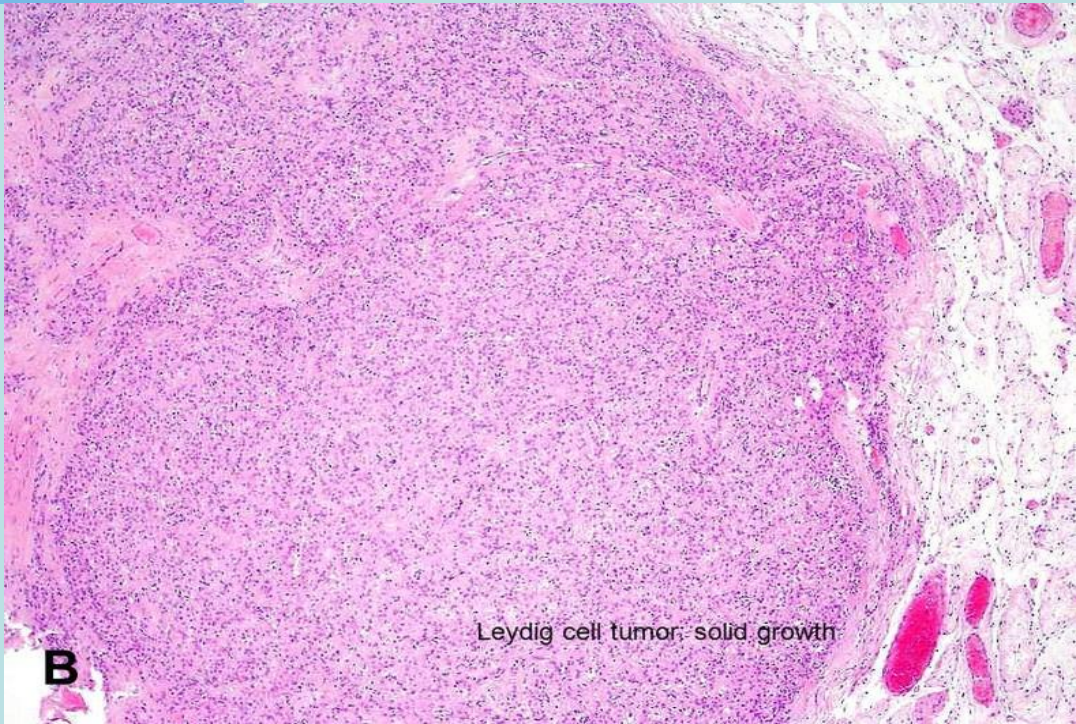
Immature teratoma

Leidigom testicular. (pattern-solid).



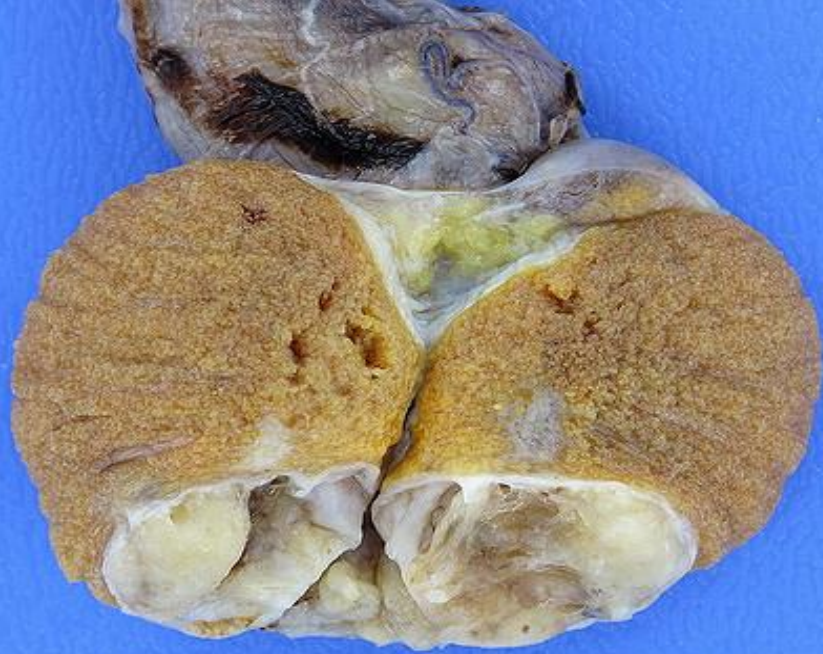Golden brown to yellow
cut surface

A

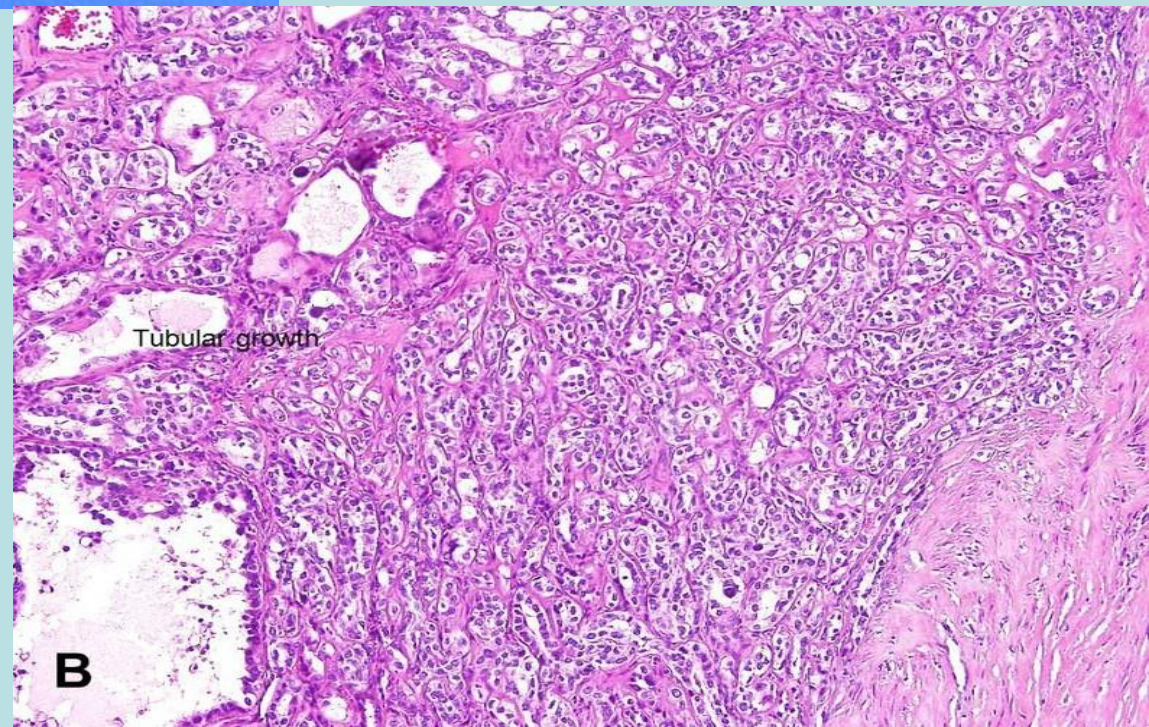


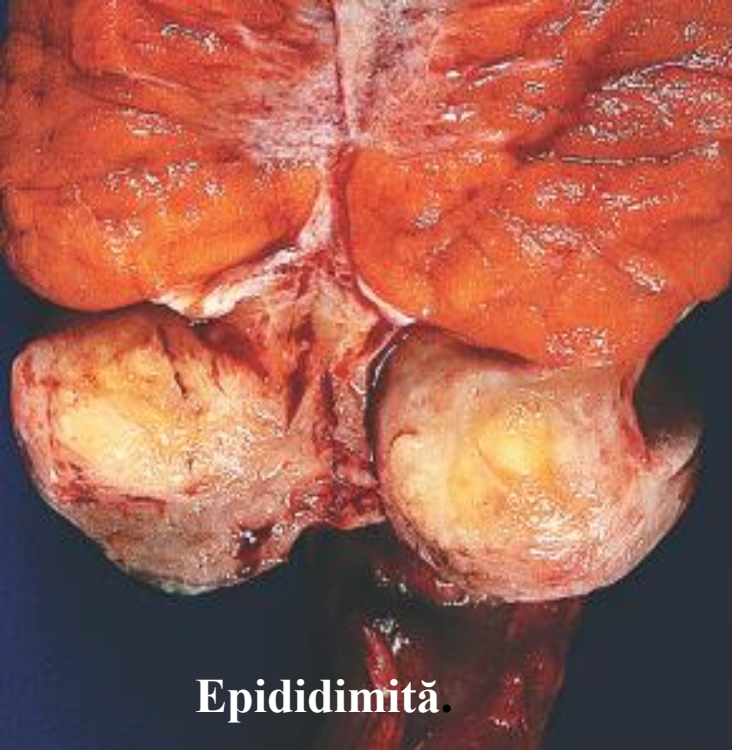
Leydig cell tumor: solid growth

B

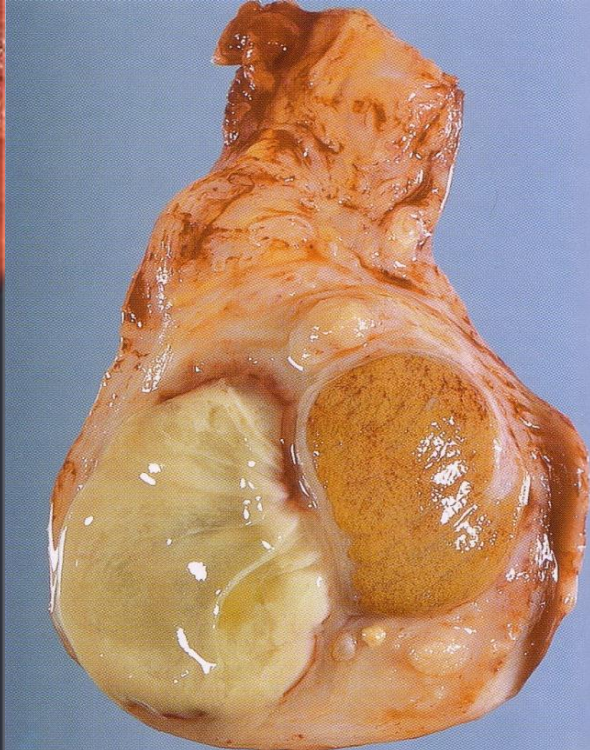


**Tumoră testiculară cu celule
Sertoli.
(pattern tubular).**

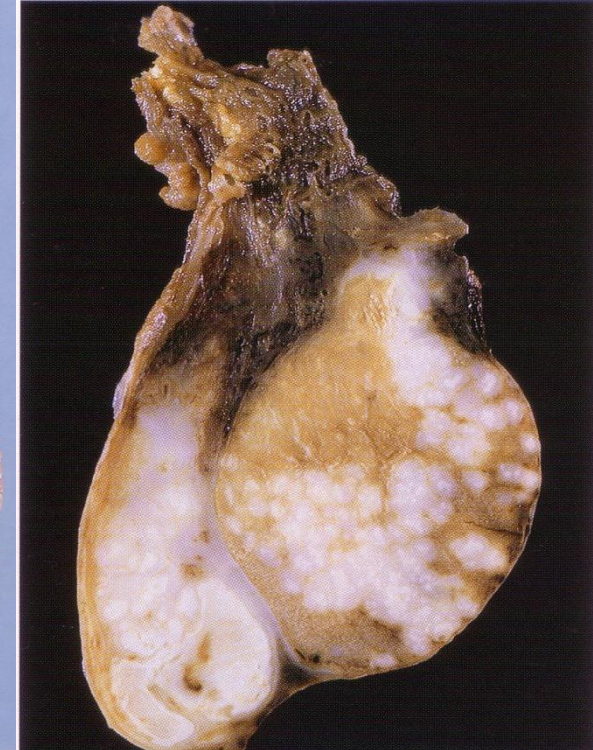




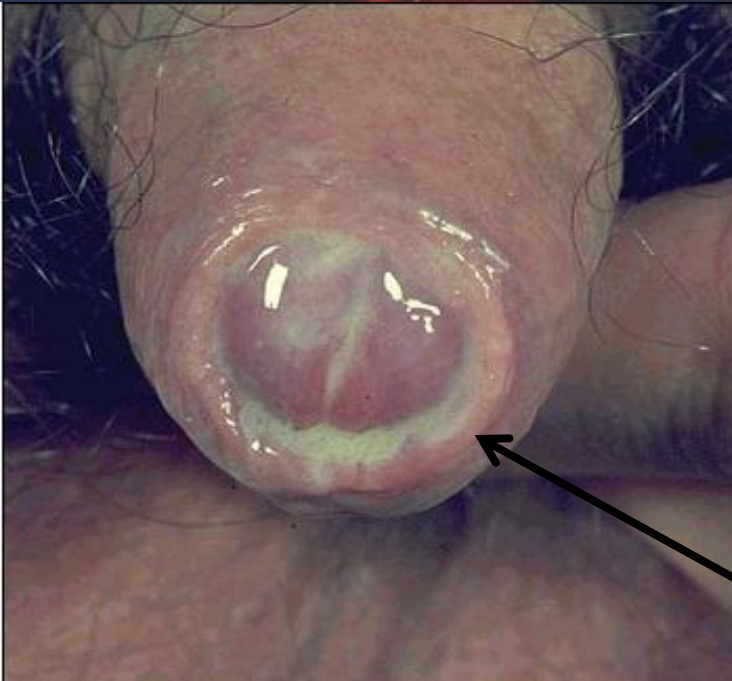
Epididimită.



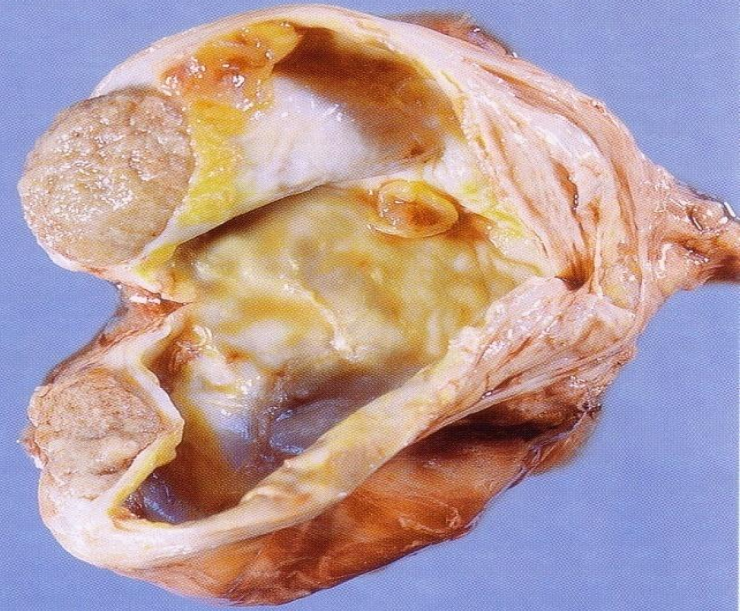
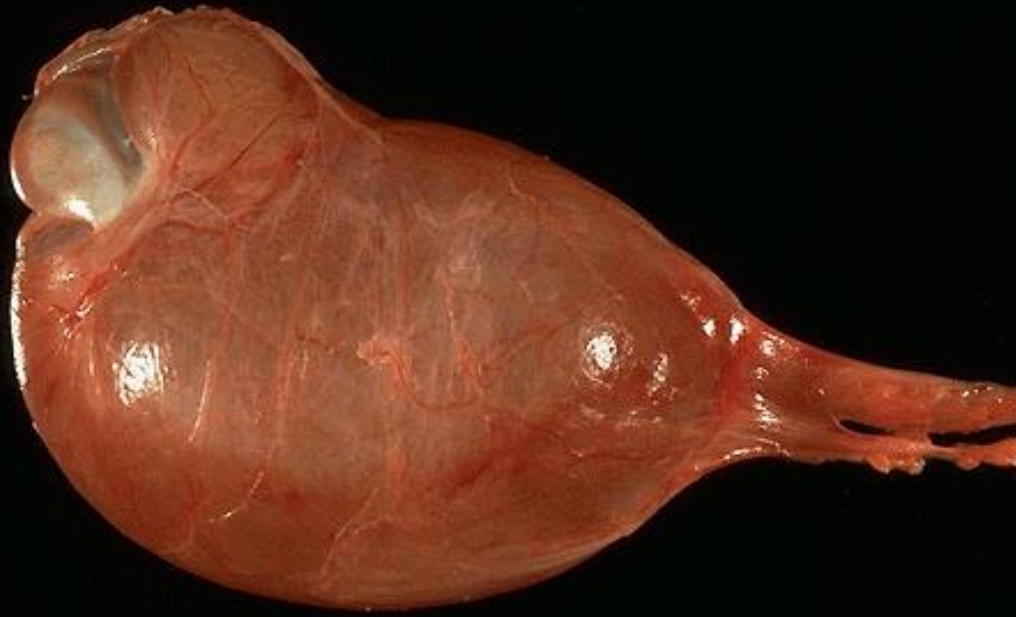
Abces epididimar.



**Orhoepididimită.
tuberculoasă.**

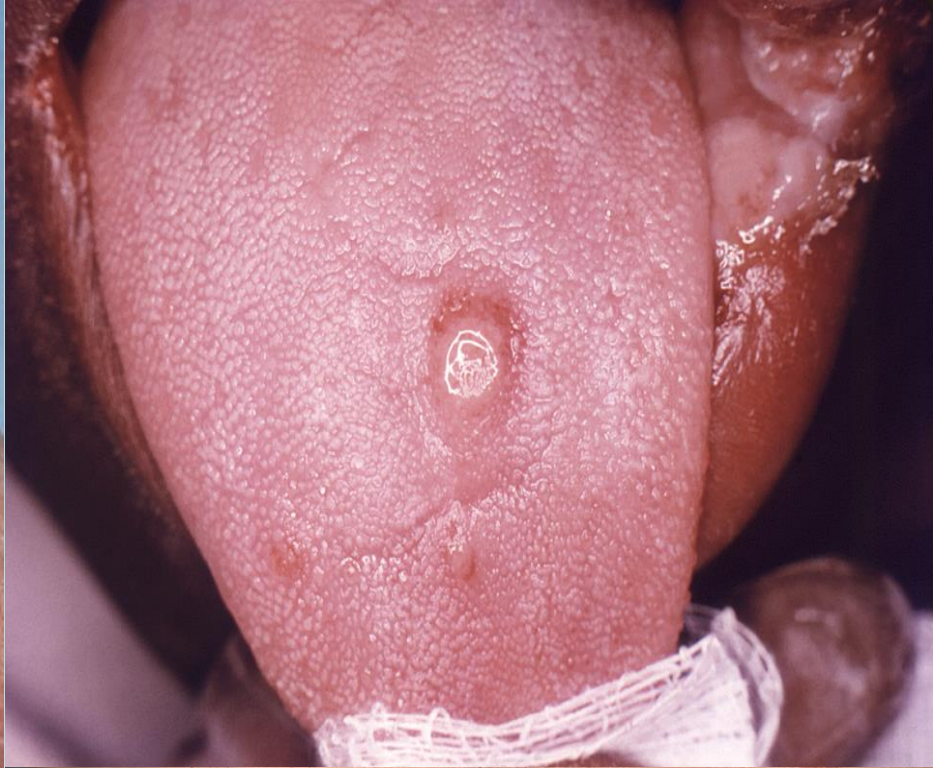
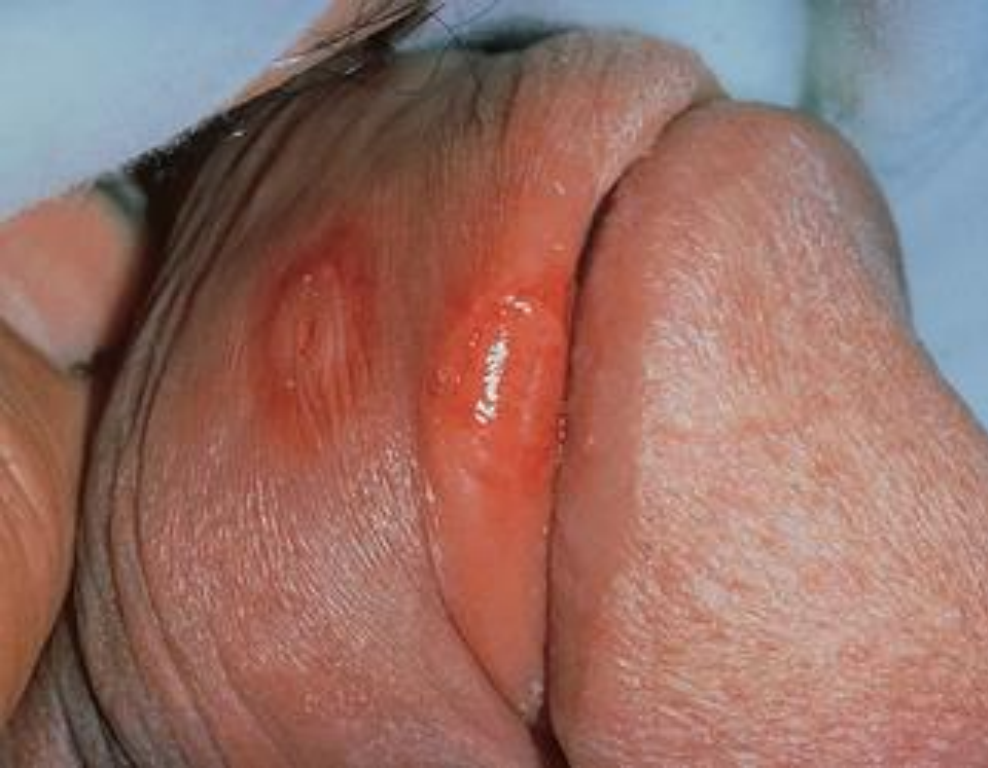
Uretrită purulentă (*gonoree*).

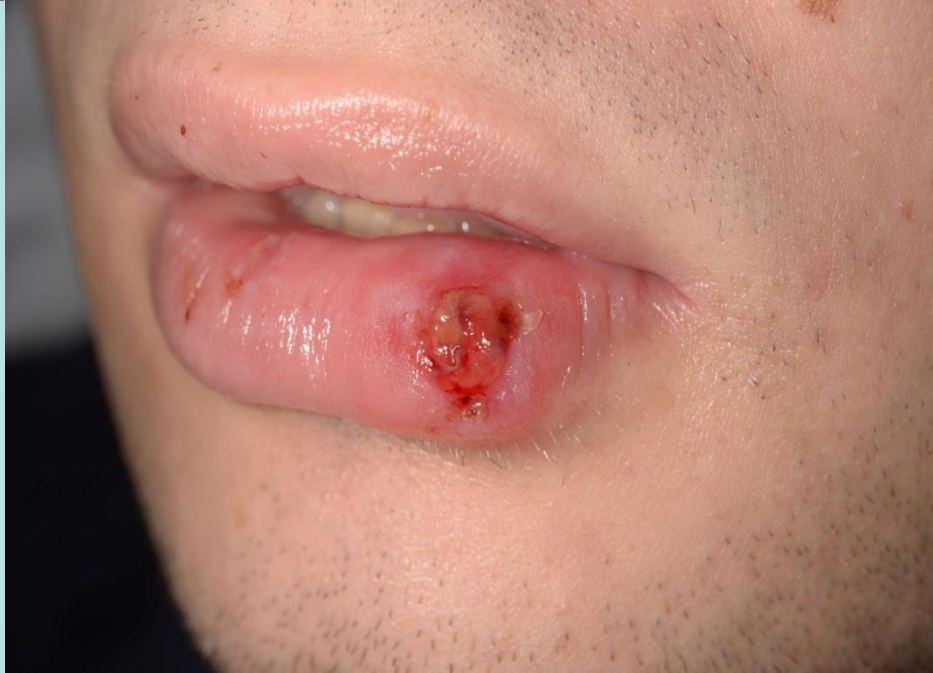

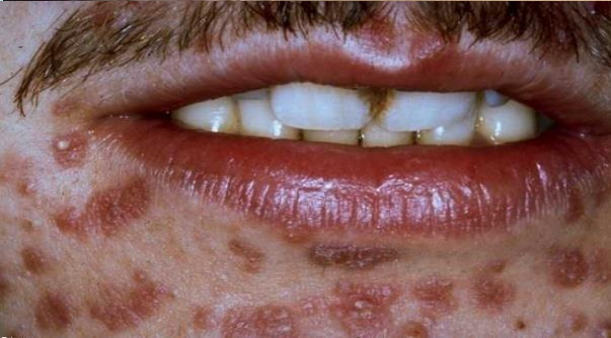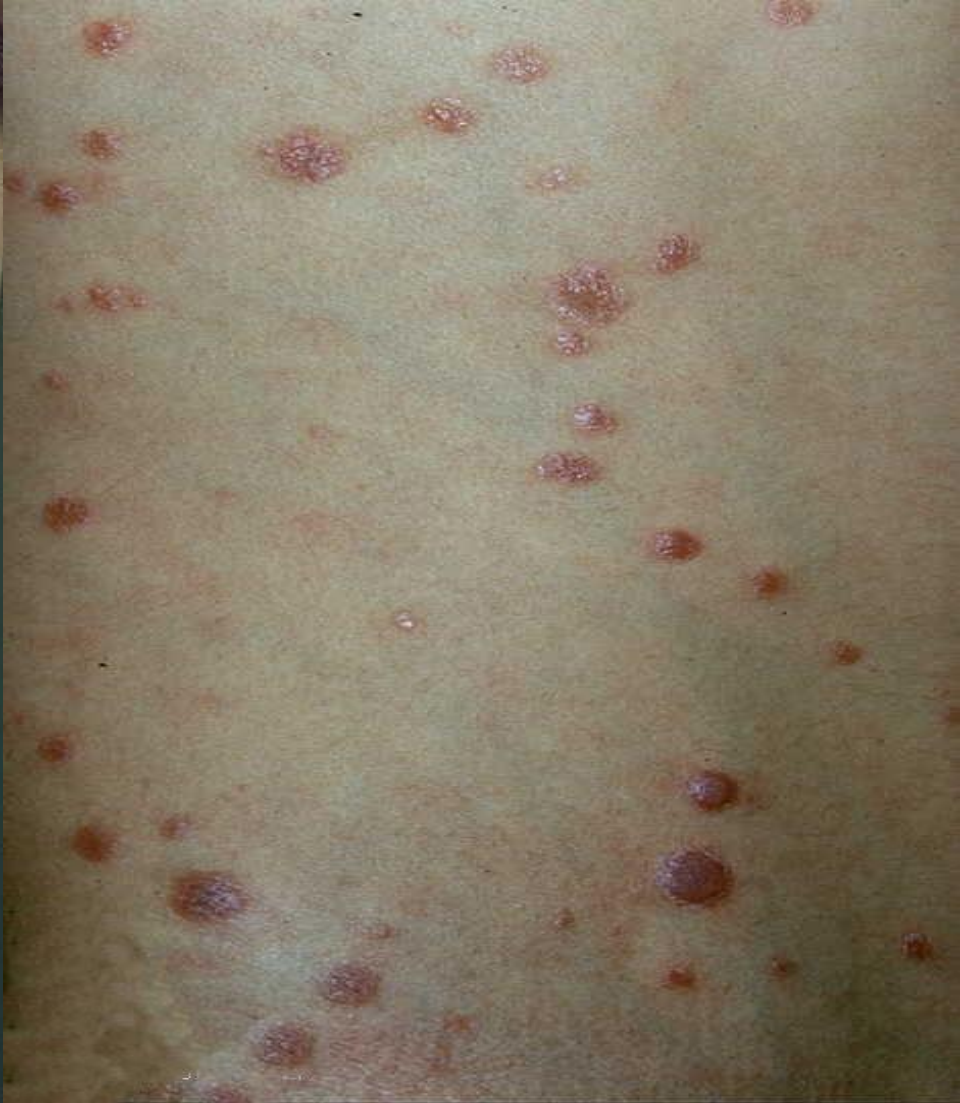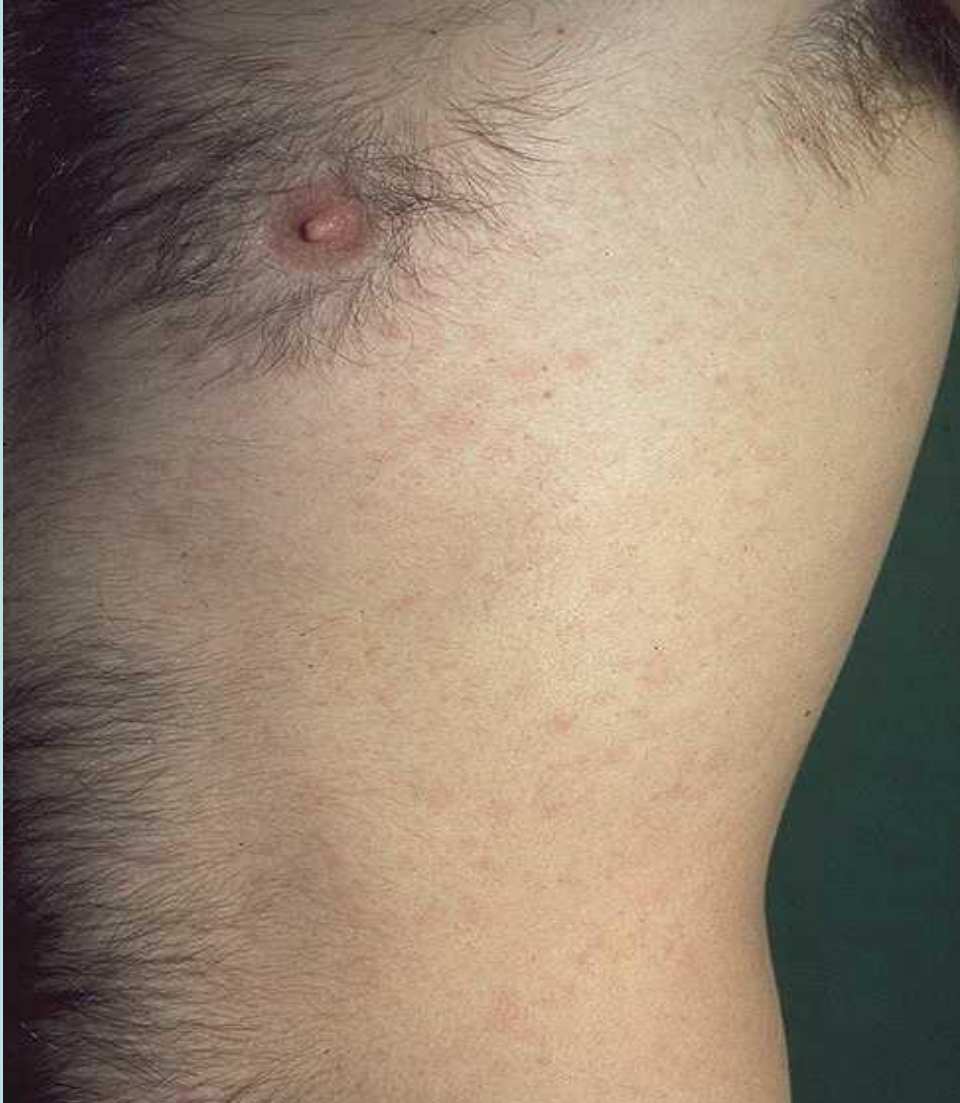Hidrocel ↑↑

← Chist epididimar

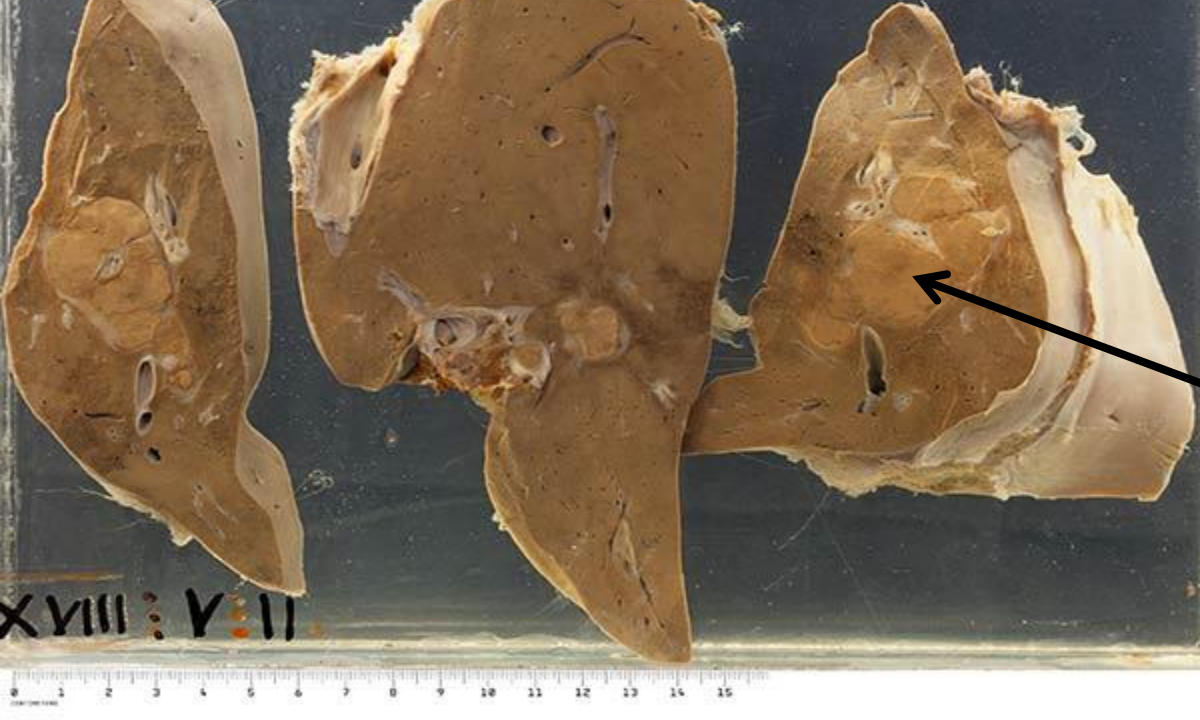

Sifilis primar, şancru dur.

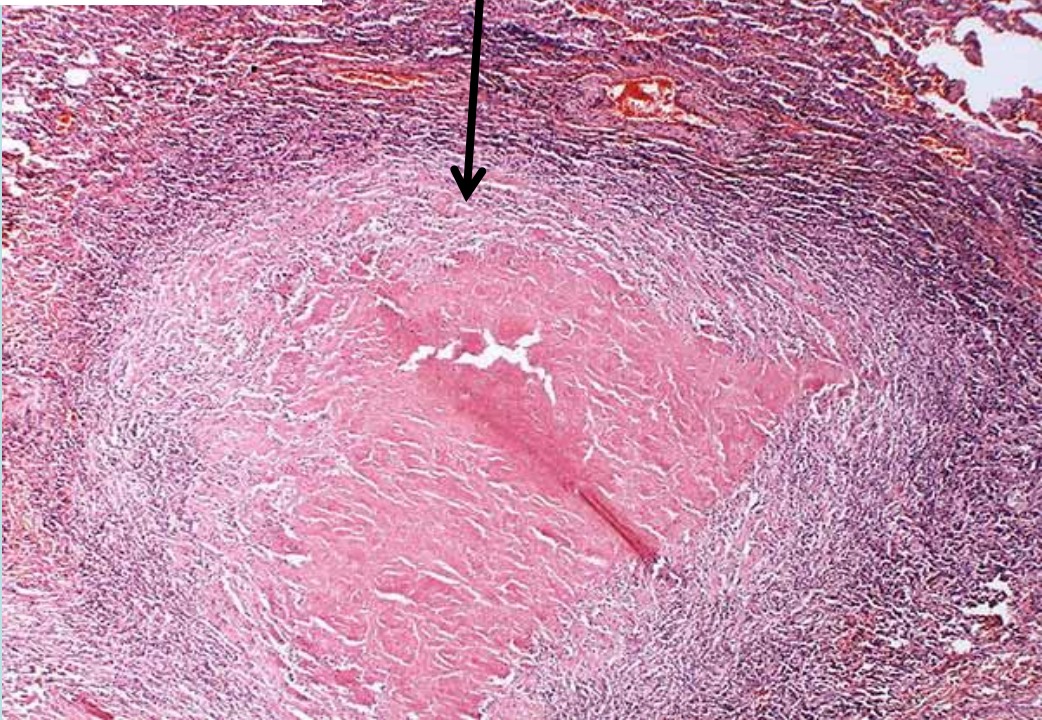




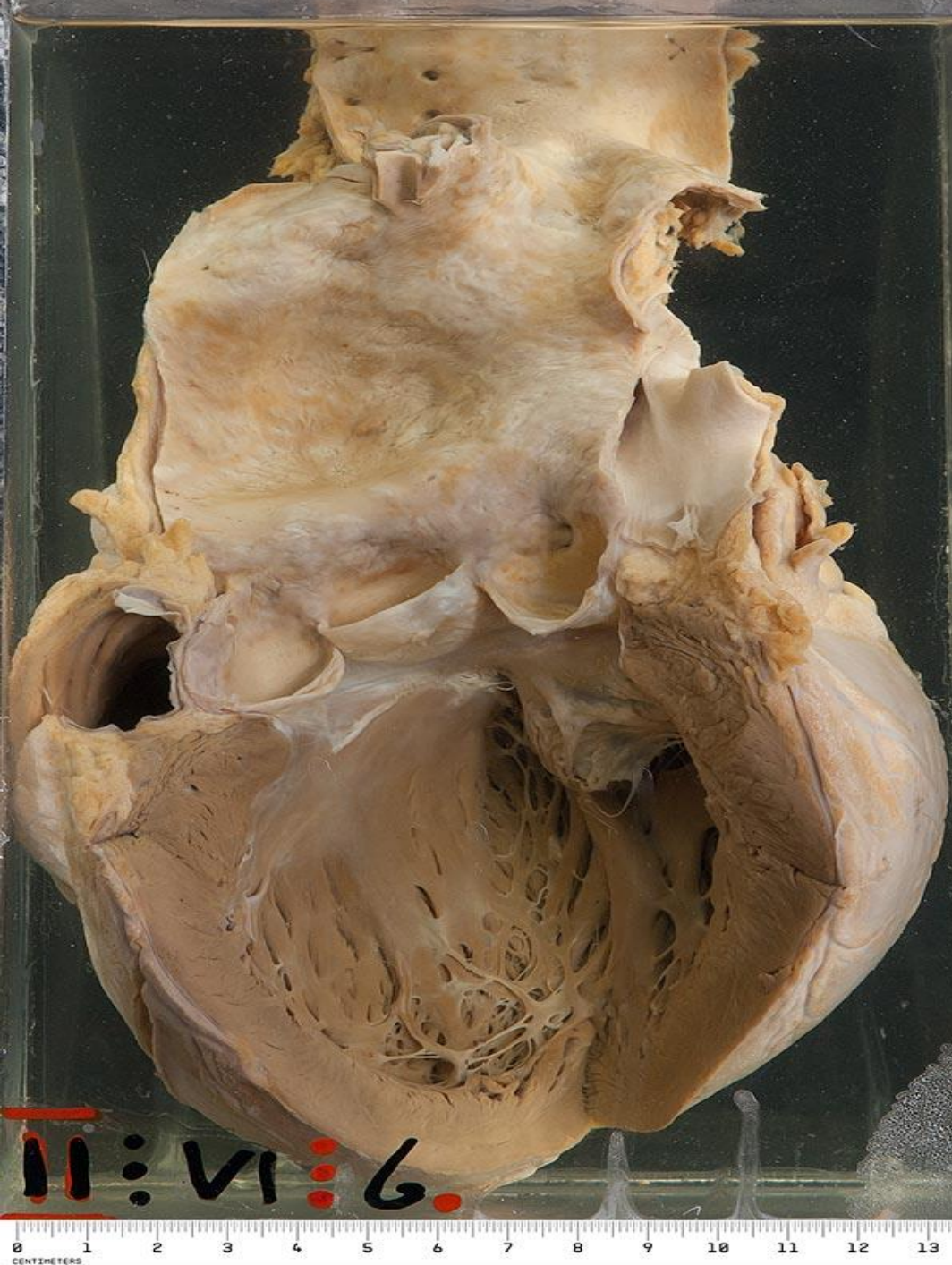
Sifilis secundar, *sifilide*.



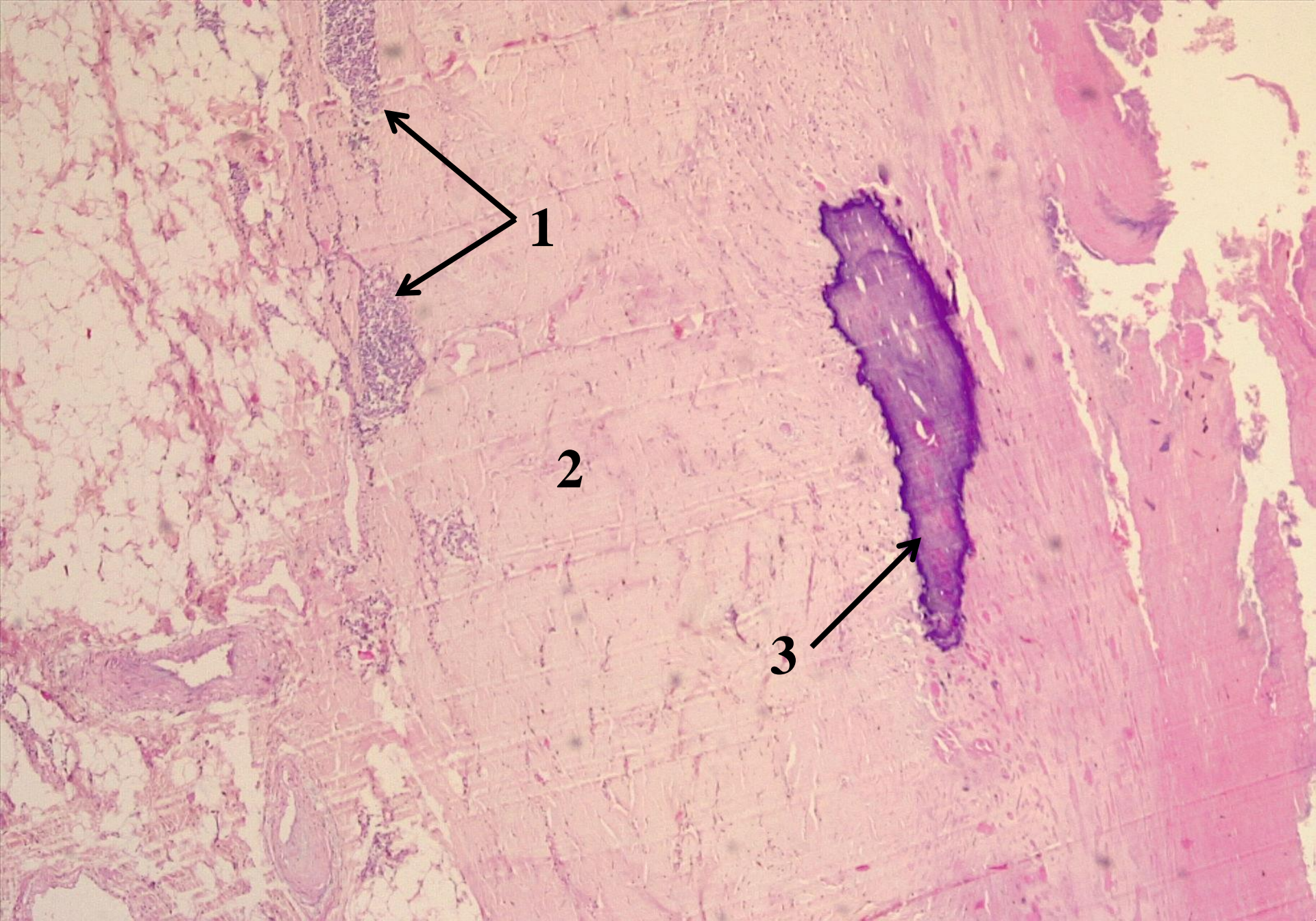
Goma sifilitică.



Ficat.



Aortită sifilitică.



№ 33. Mezaortită sifilitică. (colorație H-E).