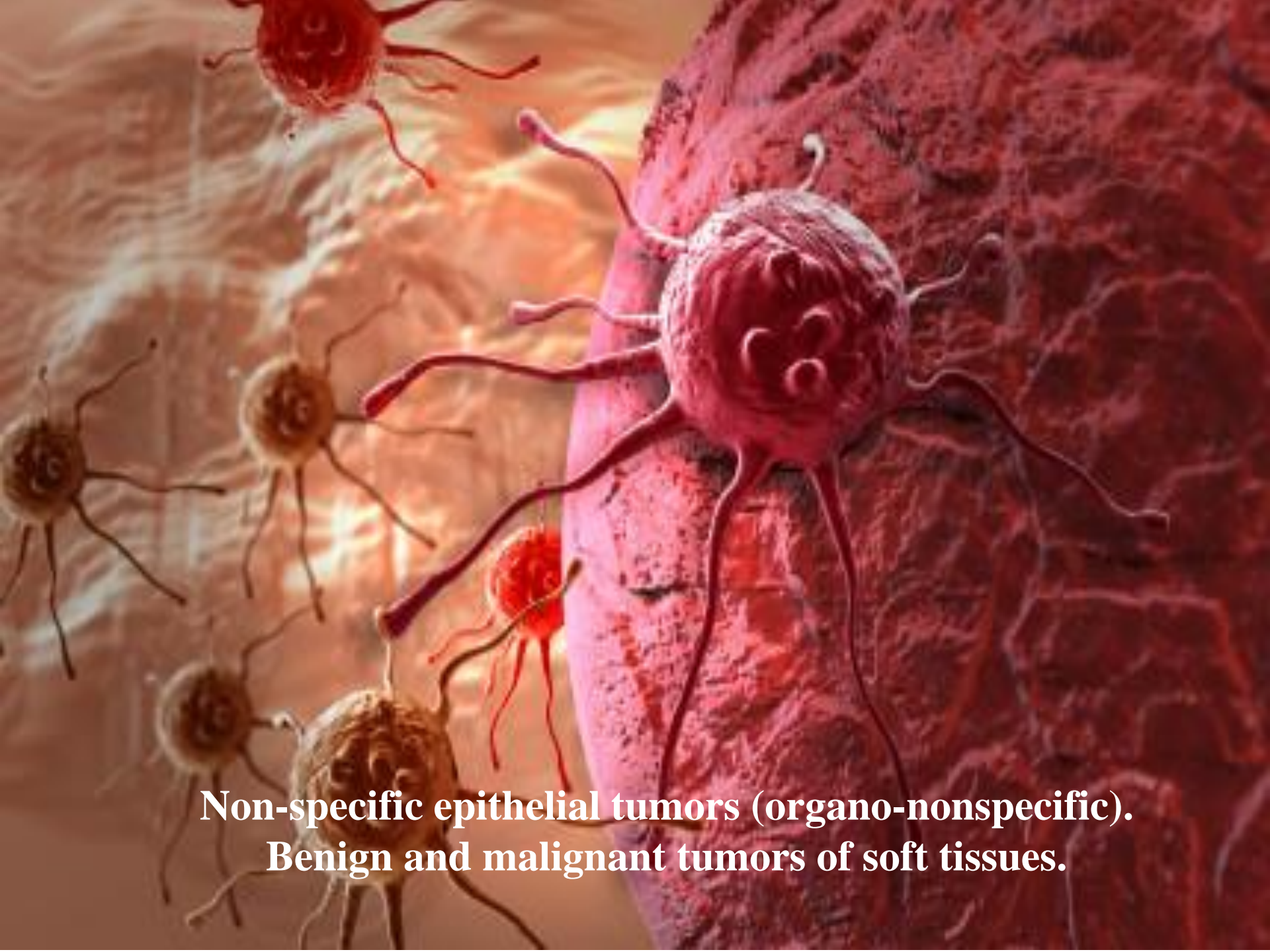



**Non-specific epithelial tumors (organo-nonspecific).  
Benign and malignant tumors of soft tissues.**

***I. Microspecimens:***

**№ 46. Papilloma of skin. (H-E stain).**

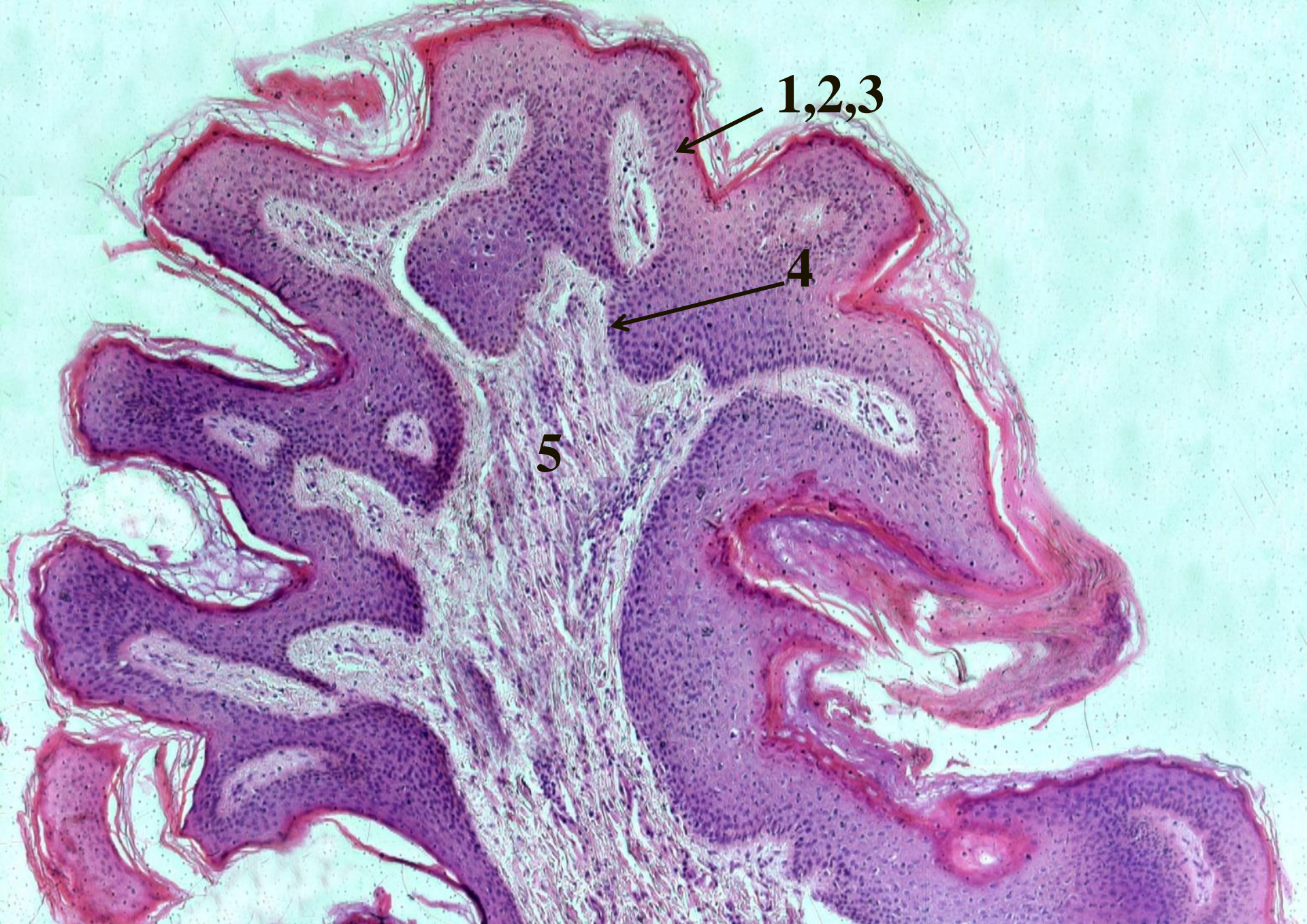
**Indications:**

1. Stratified squamous epithelium uniformly thickened.
2. Epithelial proliferations, which penetrate the underlying connective tissue (acanthosis).
3. Epidermal hyperkeratosis.
4. Intact basement membrane.
5. Connective tissue stroma.

Microspecimen has a section from a tumoral node with a diameter varying from a few mm to 1-2 cm, removed from the surface of the skin. On microscopic examination, multiple papillary proliferations of the squamous cell epithelium are observed, which is irregular thickened, the proliferated stratum spinosum (malpighian layer) forms elongations of the epidermal ridges, which penetrate the underlying fibroconnective tissue (acanthosis), the stratum corneum is also thickened, excess of keratin (hyperkeratosis), the basement membrane is well defined, intact; subepithelial fibroconnective tissue (tumor stroma) is well vascularized, contains a weakly pronounced lymphoid infiltrate.

*The papilloma develops from the multilayered squamous epithelium (squamous cell) and of the transitional type (urothelial). It is found on the skin and on the mucous membranes covered with the respective epithelia: the oral cavity, pharynx, larynx, esophagus, urinary tract, cervix, it is also observed in the excretory ducts of the exocrine glands, the mammary gland. Macroscopically, there is a spherical tumor formation, with is of rough surface (reminiscent of raspberry fruit), dense in consistency, can be wide implanted, sessile or pedunculate, dimensions can be up to a few cm. Histological lesions consist of excessive, irregular proliferation of the squamous cell epithelium, which protrudes on the surface of the skin or mucous membranes; at the same time the subepithelial fibroconnective tissue stroma proliferates. These changes reflect tissue atypia in the papilloma. Epithelial cells have a normal structure, are well differentiated, the integrity of the basement membrane are preserved, cell complexity and polarity, which is characteristic for benign tumors. The clinical manifestations and the evolution depend on the location, it can be complicated with exulcerations and secondary inflammation. Papillomas can be single or multiple (papillomatosis). Sometimes they recur after removal (especially the papilloma of the vocal chords and urinary bladder). In cases of prolonged mechanical excitation, the papilloma may become malignant (squamous cell carcinoma occurs). Papillomas of the excretory ducts, larynx and urinary tract are assessed as potentially precancerous lesions.*





**№ 46. Papilloma of skin. (H-E stain).**

## **№ 102. Keratinizing squamous cell carcinoma. (H-E stain).**

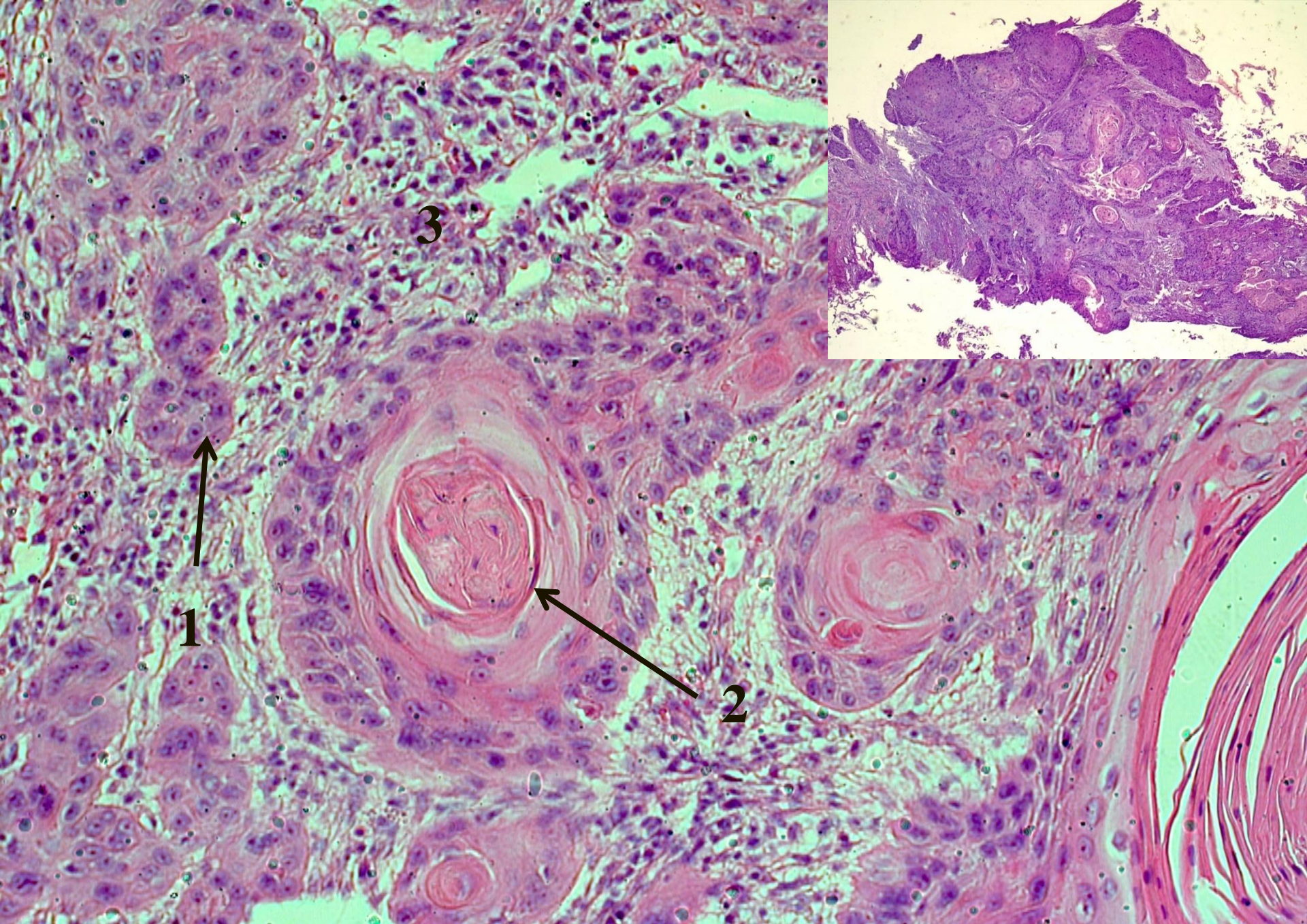
### **Indications:**

1. Clusters of cancer cells which infiltrating the subepithelial layer.
2. "Keratin pearls".
3. Tumor stroma.

The tumor consists of atypical, polymorphic squamous cell cords, the basement membrane is altered, cancerous proliferations deeply infiltrate the subepithelial tissue, forming nests, agglomerations of neoplastic cells, in the center of which accumulate masses of keratin, forming so-called "keratin pearls"- the characteristic sign of squamous cell carcinoma (epidermoid) with keratinization; in the stroma there is moderate lymphoid infiltration, edema, hemorrhage.

*Squamous cell carcinoma carcinoma is found on the skin and mucous membranes covered with multilayered squamous epithelium or on the mucous membranes covered with glandular epithelium, which previously suffered a squamous metaplasia. The type of growth can be exophytic and endophytic. Histologically it has 2 variants: keratinized and non-keratinized. Dystrophic, necrotic, circulatory lesions, secondary inflammation, ulcerations usually occur in the tumor, which largely determine the evolution and clinical manifestations. Invasive growth in adjacent tissues and organs depends on the location of the tumor and may play an important role in clinical evolution. It gives more frequent lymphatic metastases, the first metastases being located in the regional lymph nodes.*





**№ 102. Keratinizing squamous cell carcinoma. (H-E stain).**



## **№ 48. Adenocarcinoma of the colon. (H-E stain).**

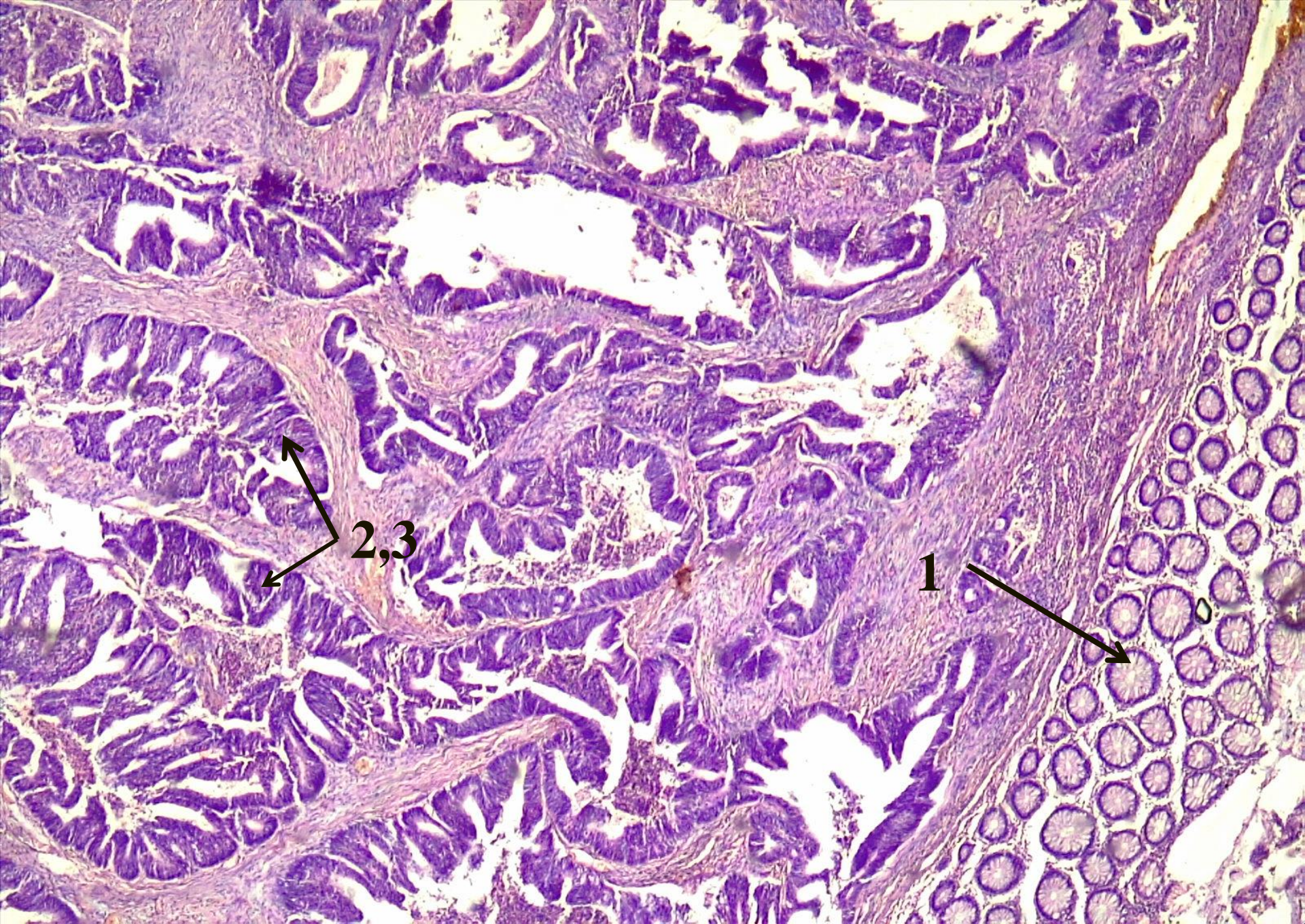
### **Indications:**

1. Normal intestinal mucosal epithelium.
2. Atypical glandular structures, which penetrate the intestinal wall thickness.
3. The polymorphic atypical cells.

In section of the colon - are areas of normal mucosa and areas with atypical polymorphic glandular structures, of various shapes and sizes, which diffuse infiltrate the colonic wall, extending even below the normal mucosa. Polymorphic cancer cells, differ significantly from the normal epithelium, in some places arranged in several rows with intensely basophilic nuclei, mitotic figures, in the lumen of the glands- mucus, tissue debris, leukocytes can be seen. The basement membrane is absent; stroma is with edema, hemorrhage, inflammatory lymphohistiocytic infiltrate.

*Adenocarcinoma or glandular carcinoma develops from the prismatic, cylindrical and cubic epithelia of the mucous membranes and glandular organs. It is located more frequently in the stomach, colon, uterus, lungs, bile ducts, pancreas, prostate, mammary gland, etc. Histological variants: tubular, papillary, acinous. Depending on the degree of differentiation, adenocarcinoma can be highly differentiated, moderately differentiated and with low differentiation. In poorly differentiated tumors the ability to form glands decreases considerably and on microscopic examination it is difficult to detect glandular structures (undifferentiated adenocarcinoma). It is often preceded by dysplasia of the glandular epithelium. It metastasizes primarily by lymphogenous route in satellite (regional) lymph nodes, but as the tumor progresses, hematogenous metastases also occur.*





**№ 48.** Adenocarcinoma of the colon. (*H-E stain*).



**№ 52. Metastasis of adenocarcinoma into liver. (H-E stain).**

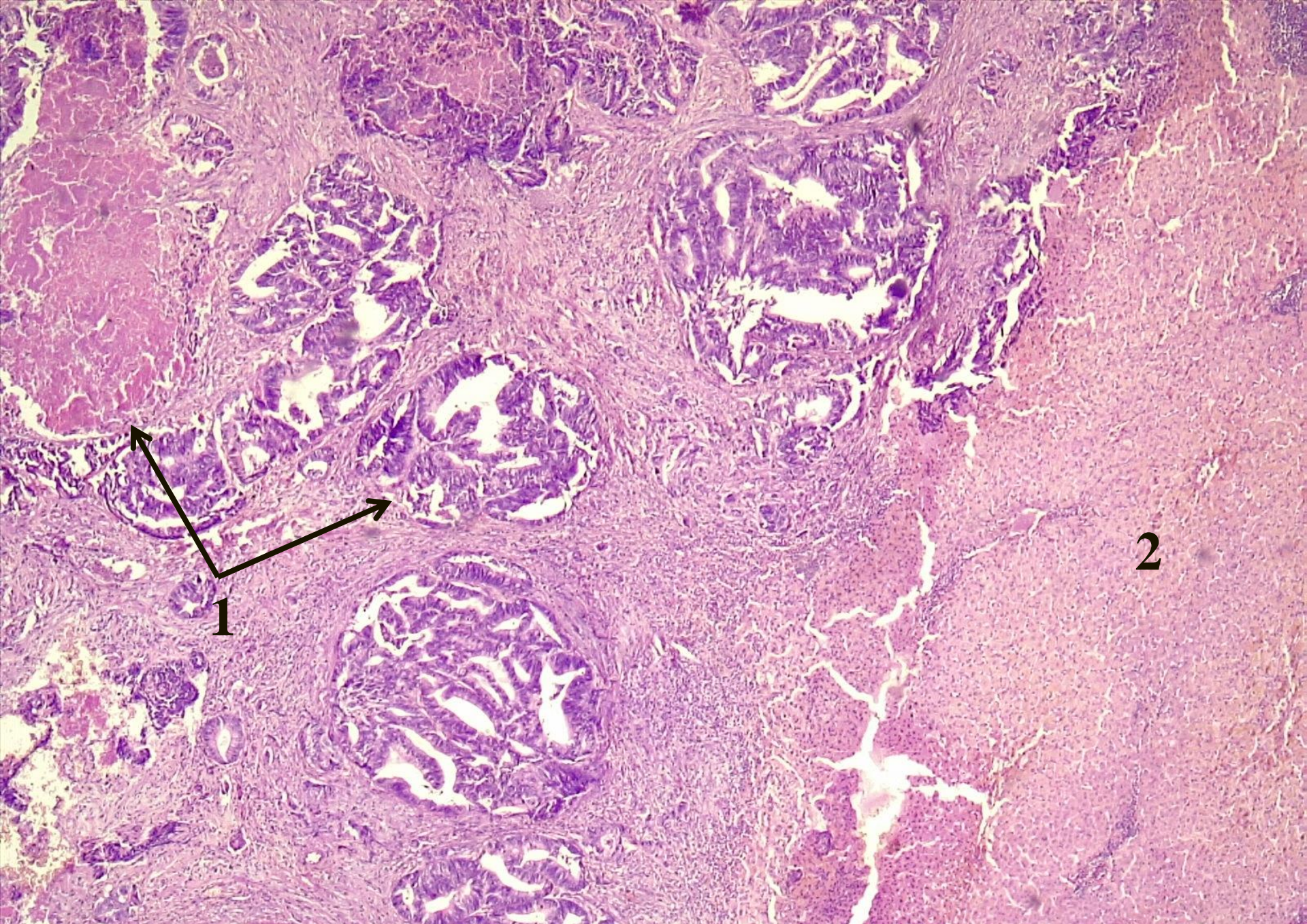
**Indications:**

1. Metastatic tumoral nodule (atypical glandular structures).
2. Adjacent liver parenchyma.

In most cases the metastatic nodule is visible to the naked eye, the microscopic examination in the liver reveals a nodule, consisting of atypical, polymorphic glandular structures, cancer cells are equally atypical, polymorphic, with intensely basophilic nuclei, there are foci of necrosis, hemorrhage and leukocyte infiltration; in the adjacent liver parenchyma are dystrophic changes, hepatocyte steatosis, chronic inflammation.

*Liver carcinoma metastases develop hematogenously by the blood through the portal vein, the primary tumor being located in any intra-abdominal organ, usually they are multiple. In dynamics, the cancerous cells from the liver reach the right heart, lungs, left heart, aorta and its branches through the inferior vena cava. Hematogenous metastases in the liver may also be from other intra-abdominal malignancies, eg, sarcomas, melanomas, choriocarcinomas, but also from malignancies with primary extra-abdominal localization.*





**№ 52. Metastasis of adenocarcinoma into liver. (H-E stain).**



**№ 42. Cavernous hemangioma of liver. (H-E stain).**

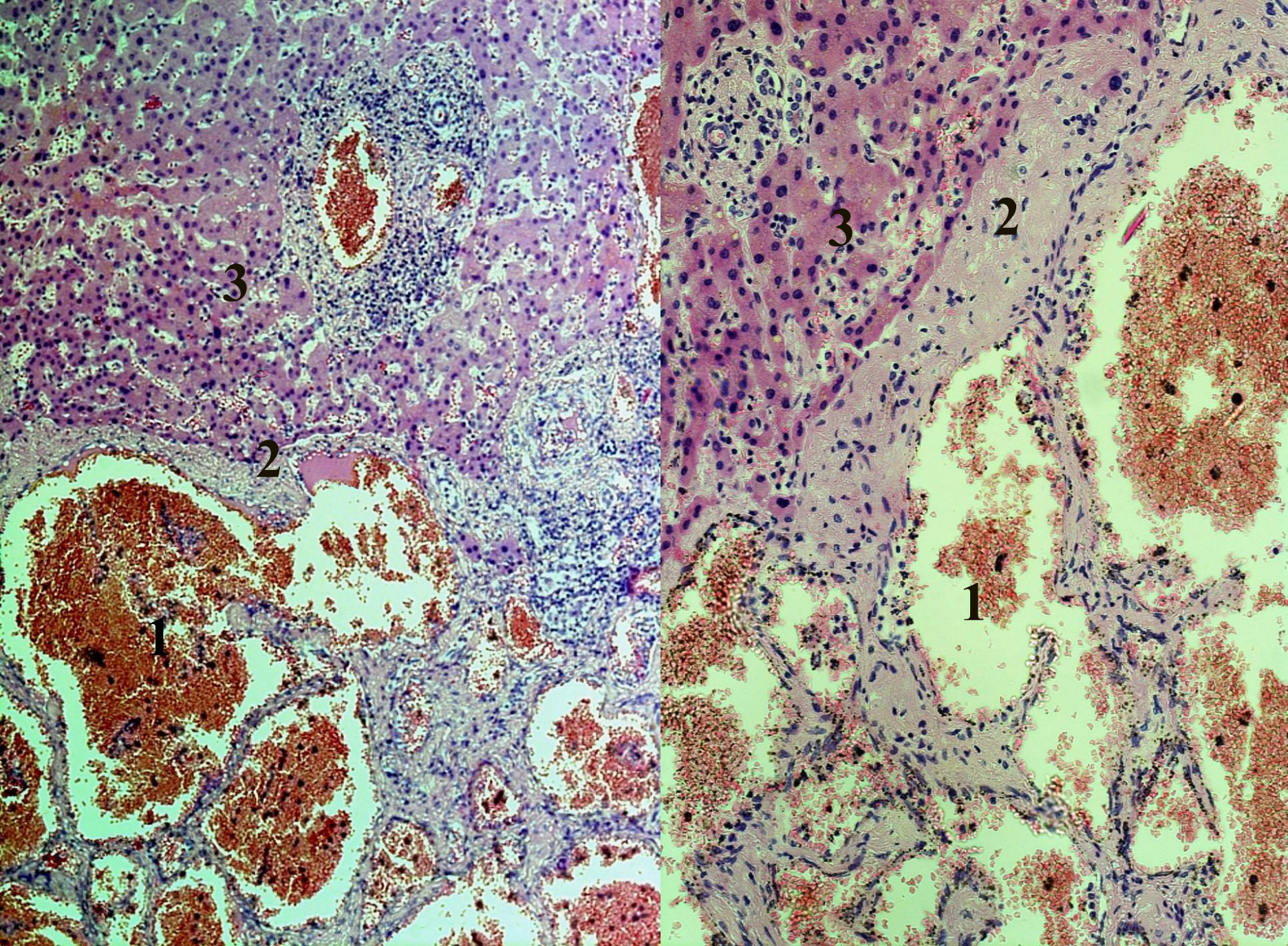
**Indications:**

1. Cavernous cavities filled with blood.
2. Fibroconnective capsule of the tumor.
3. Adjacent hepatic parenchyma.

The tumoral node in the microspecimen, is visible to the naked eye, on microscopic examination the tumor has large, dilated vascular cavities (caverns), of different sizes, intercommunicating, filled with blood, lined with endothelial cells, with thin walls, formed of fibrous connective tissue, is well delimited by adjacent liver tissue with dystrophic changes, steatosis.

*Macroscopically, the tumor node can have variable shapes and sizes, is well delimited by the adjacent tissue, has a dark red color, soft consistency, spongy structure. Cavernous hemangioma of the liver is a benign tumor of vascular origin, usually located subcapsularly. Beside liver, it is found in the skin, spongy bones, skeletal muscles, etc. In most cases, hepatic hemangioma develops clinically asymptotically and is detected accidentally. Rarely, hemangioma ruptures with hemorrhage in the peritoneal cavity. In many cases, the tumoral node fibroses and then calcifies.*





**№ 42. Cavernous hemangioma of liver. (H-E stain).**



## ***II. Macrospecimens:***

### **№ 39. Central lung carcinoma.**

In the main bronchus is a tumor node, size ~ 4-5 cm, which grows exophyte, stenosing the lumen, with rough surface, dense consistency, white-yellow color, tumor tissue infiltrates the adjacent peribronchial lung parenchyma.

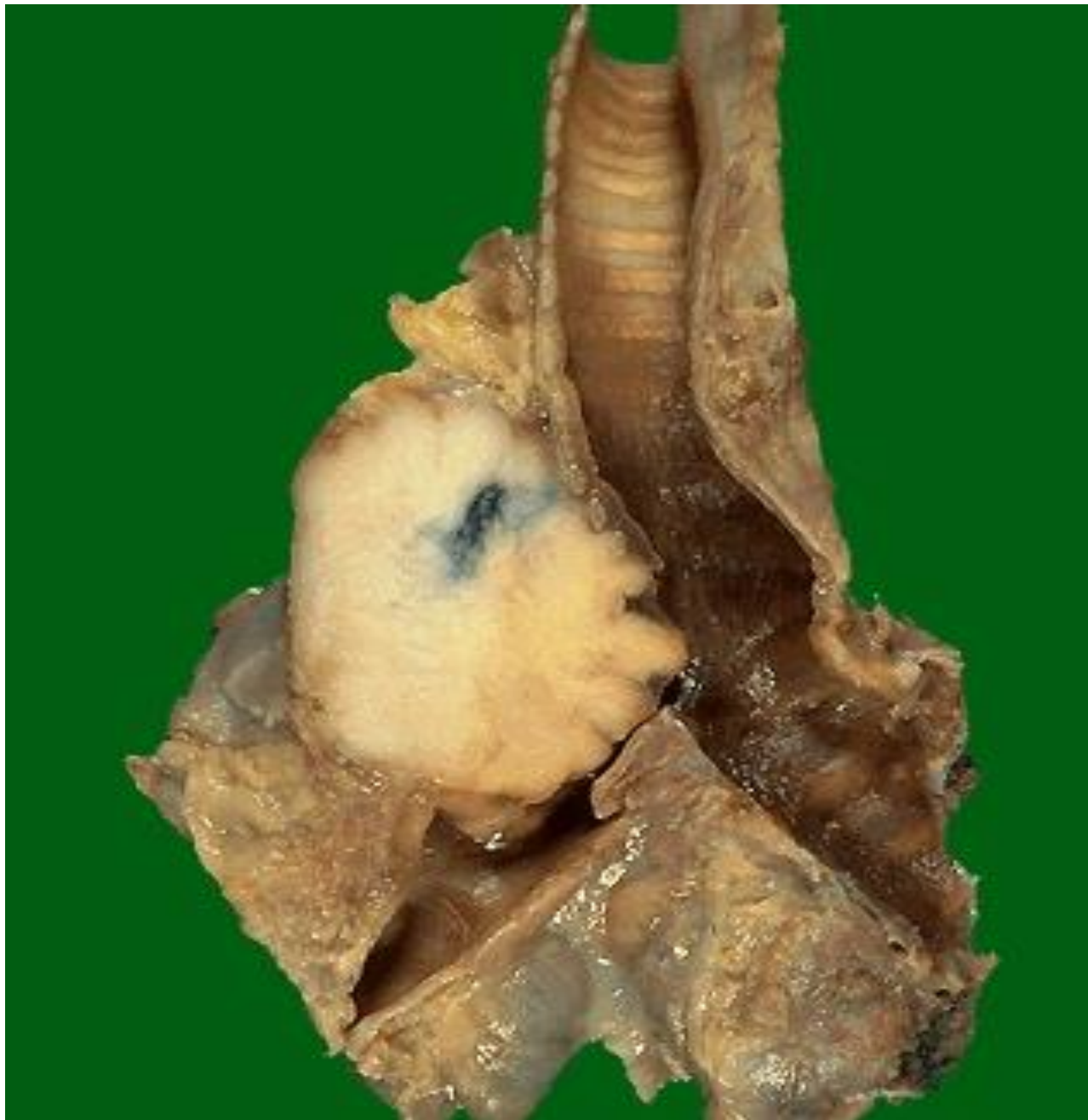*It develops from the epithelium of the main bronchi and their branches, more often on the right. Frequently complicated with atelectasis by obturation, hemorrhage, abscess, fibrino-hemorrhagic or purulent pleurisy. Infiltrative growth can occur in peribronchial lung tissue, contralateral bronchi, pleura, pericardium, and myocardium. Lymphogenic metastases occur in the mediastinal, cervical, supraclavicular, para-aortal lymph nodes, hematogenous metastases - in various organs, more commonly in the liver, adrenal glands, bones, pancreas, brain, etc. It usually occurs on the background of chronic bronchitis, especially in smokers bronchitis, bronchiectasis, chronic abscess, pneumoconiosis. The most common histological form is keratinizing or non-keratinizing squamous cell carcinoma preceded by squamous metaplasia of the respiratory epithelium.*

### **№ 41. Carcinoma of larynx.**

In the laryngeal cavity there is a tumoral node, which grows exophyte, protruding on the surface of the mucosa, dense consistency, white-gray color, having in the center an area of necrosis and exulceration.

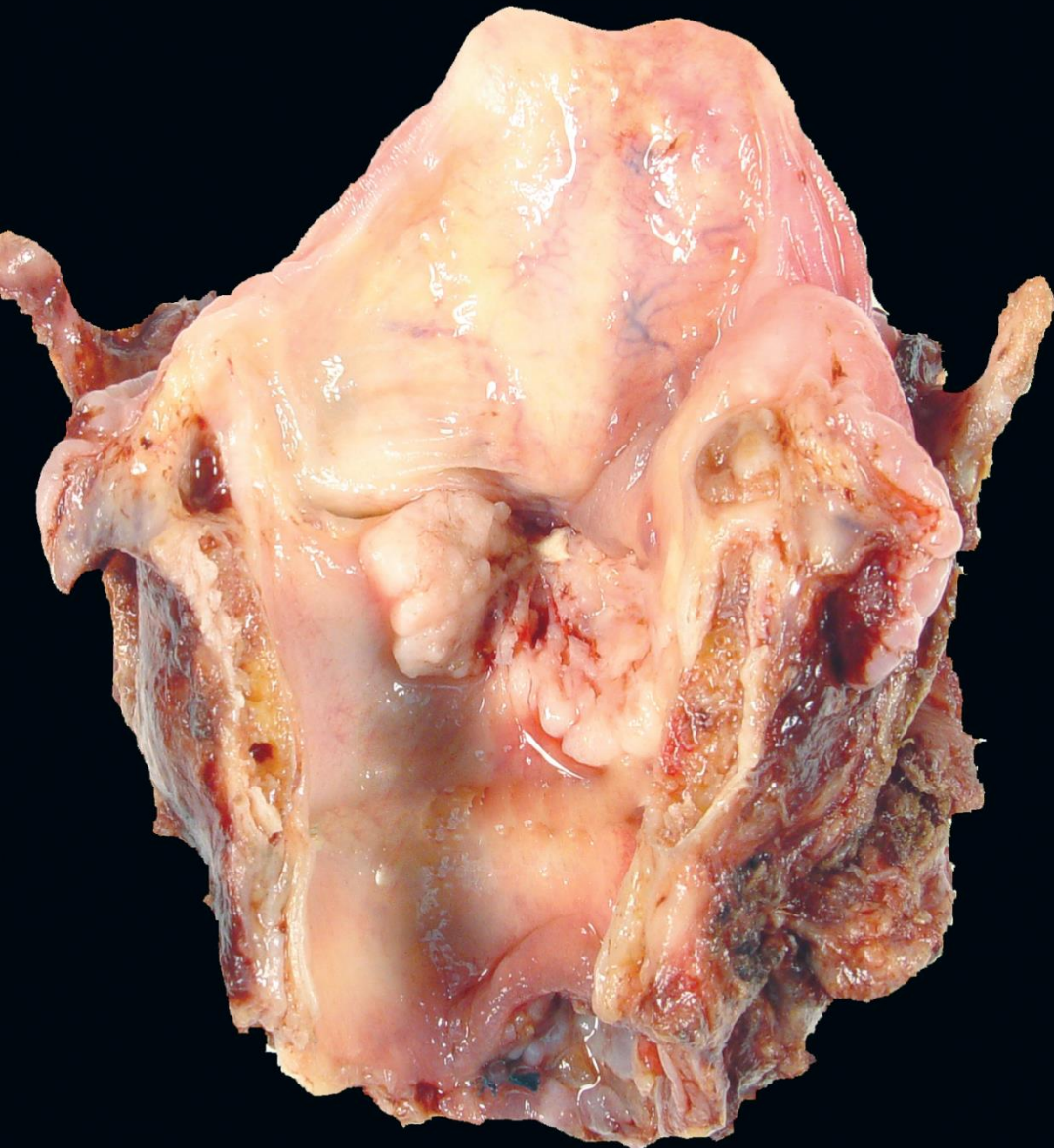*It can be complicated by mechanical asphyxia, hemorrhage, secondary inflammation, infections, metastases, especially in regional lymph nodes. In most cases it develops at the level of the vocal chords. The most common histological form - in 99% of cases - is squamous cell carcinoma with / or without keratinization. It occurs frequently on the background of chronic inflammation, leukoplakia and dysplasia of the laryngeal mucosa, etc. Complications: infiltration of vital and adjacent organs - trachea, carotid artery, intercurrent infections, pneumonia by aspiration, disseminated metastases, cachexia.*





**№ 39. Central lung carcinoma.**





**№ 41. Carcinoma of larynx.**



## **№ 60. Carcinoma of stomach.**

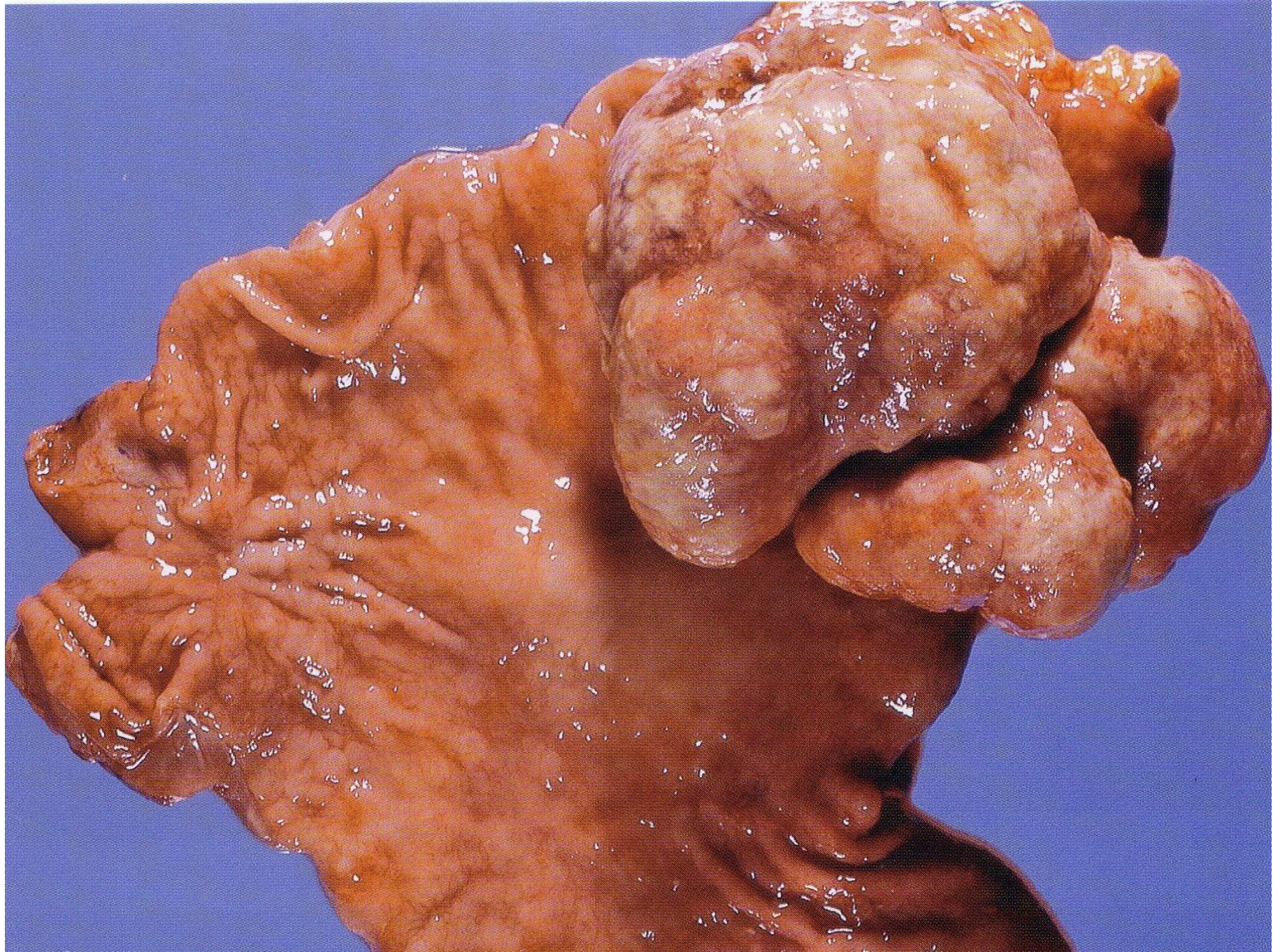In the stomach it is a voluminous tumor with exophytic growth, irregular surface, hemorrhagic foci, dense-elastic consistency, white-gray color, fungal appearance. It is located more frequently in the region of the small curvature and the pyloric canal.

*Gastric carcinoma is most often preceded by precancerous conditions such as chronic atrophic gastritis with intestinal metaplasia of the epithelium, epithelial dysplasia, adenomatous polyps, Helicobacter pylori infection. The most common location is in the region of small curvature, pylorus, pyloric antrum. The most common histological variant is adenocarcinoma with different degrees of differentiation. Gastric carcinoma can spread continuously through the esophagus, peritoneum (peritoneal carcinomatosis), large omentum, pancreas, liver, transverse colon, and by implantation - in mono- or bilateral ovaries - Krukenberg tumor. Locally it can be complicated by hemorrhage, perforation, inflammation of the gastric wall (phlegmon). It gives metastasis primarily in the regional lymph nodes of the small curvature, cardia, and suprapancreatic lymph nodes. A pathognomonic sign is metastasis to the left supraclavicular lymph nodes - the Virchow or Troisier sign. Hematogenous metastases occur first in the liver, later - in the lungs, brain, bones, kidneys.*

## **№ 74. Metastasis of carcinoma into liver.**

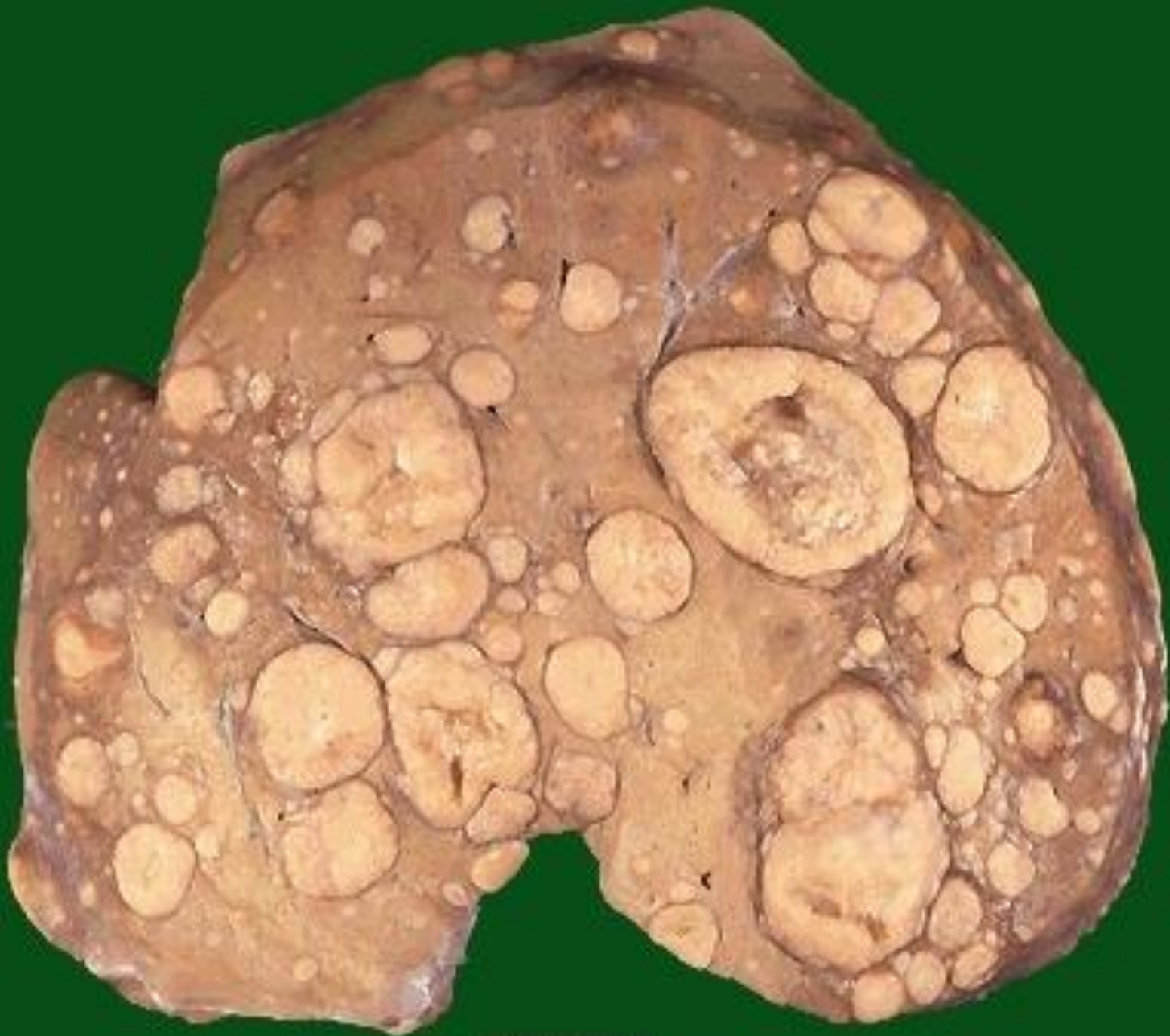The liver is enlarged in size, on the section and under the capsule there are multiple tumoral nodules with a diameter from 0.5-1 to 4-5 cm, round or oval, well delimited, whitish color, distributed relatively irregular on the surface of the organ, hepatic parenchyma between nodules with signs of steatosis (microspecimen no. 52)





**№ 60. Carcinoma of stomach.**





**№ 74. Metastasis of carcinoma into liver.**



## **№ 42. Metastasis of carcinoma into into lungs.**

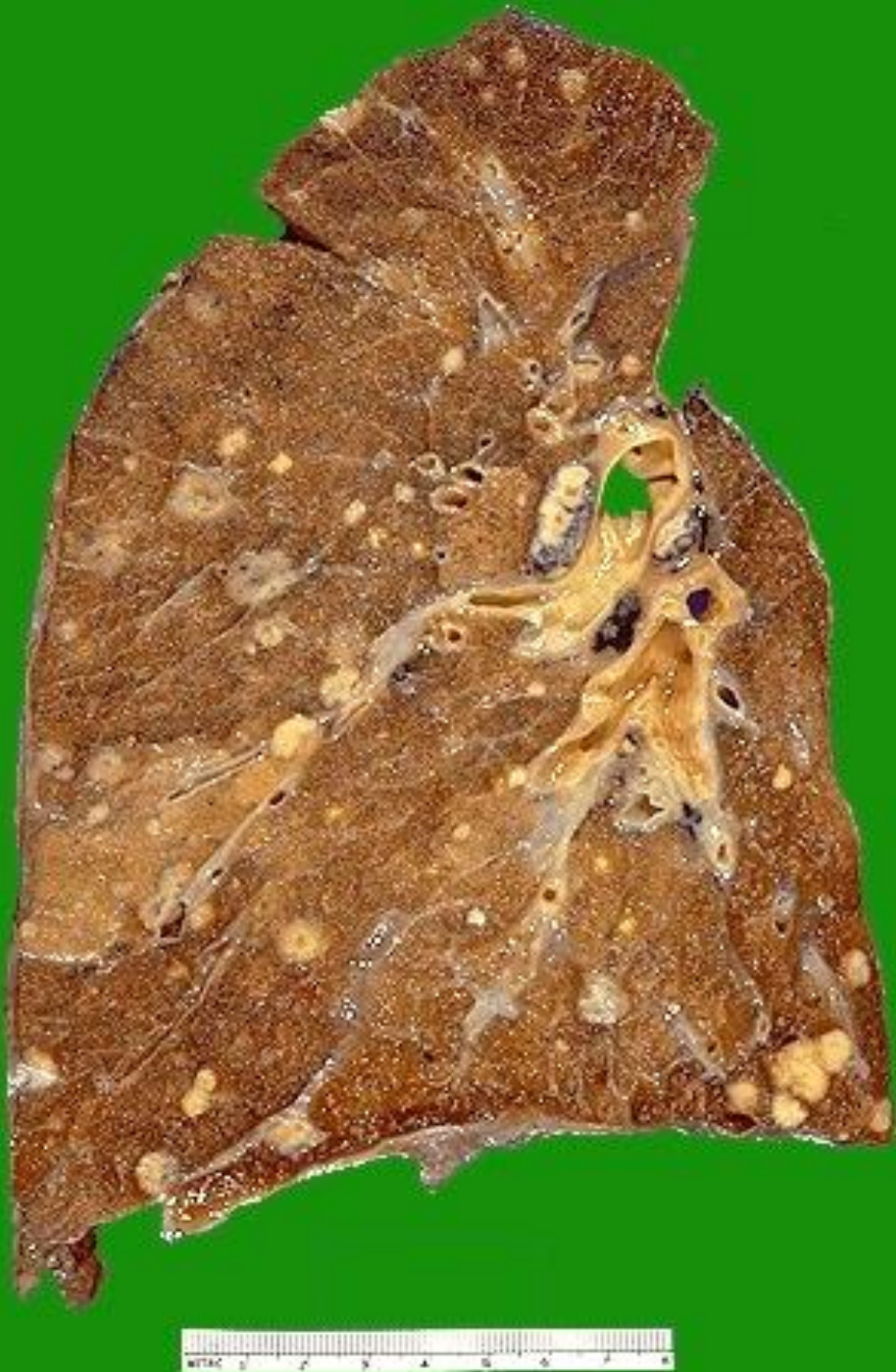In the lung, under the visceral pleura and on the cut section, are observed multiple white-gray tumoral nodules, round or oval in shape, with a diameter of up to 3-5 cm, well delimited by the adjacent tissue.

*Lung metastases are more common than primary lung tumors. The preferred location is in the peripheral areas of the lungs. More commonly in the lungs there are metastases of carcinoma of the colon, mammary gland, thyroid, kidneys, pancreas.*

## **№ 59. Carcinoma of esophagus.**

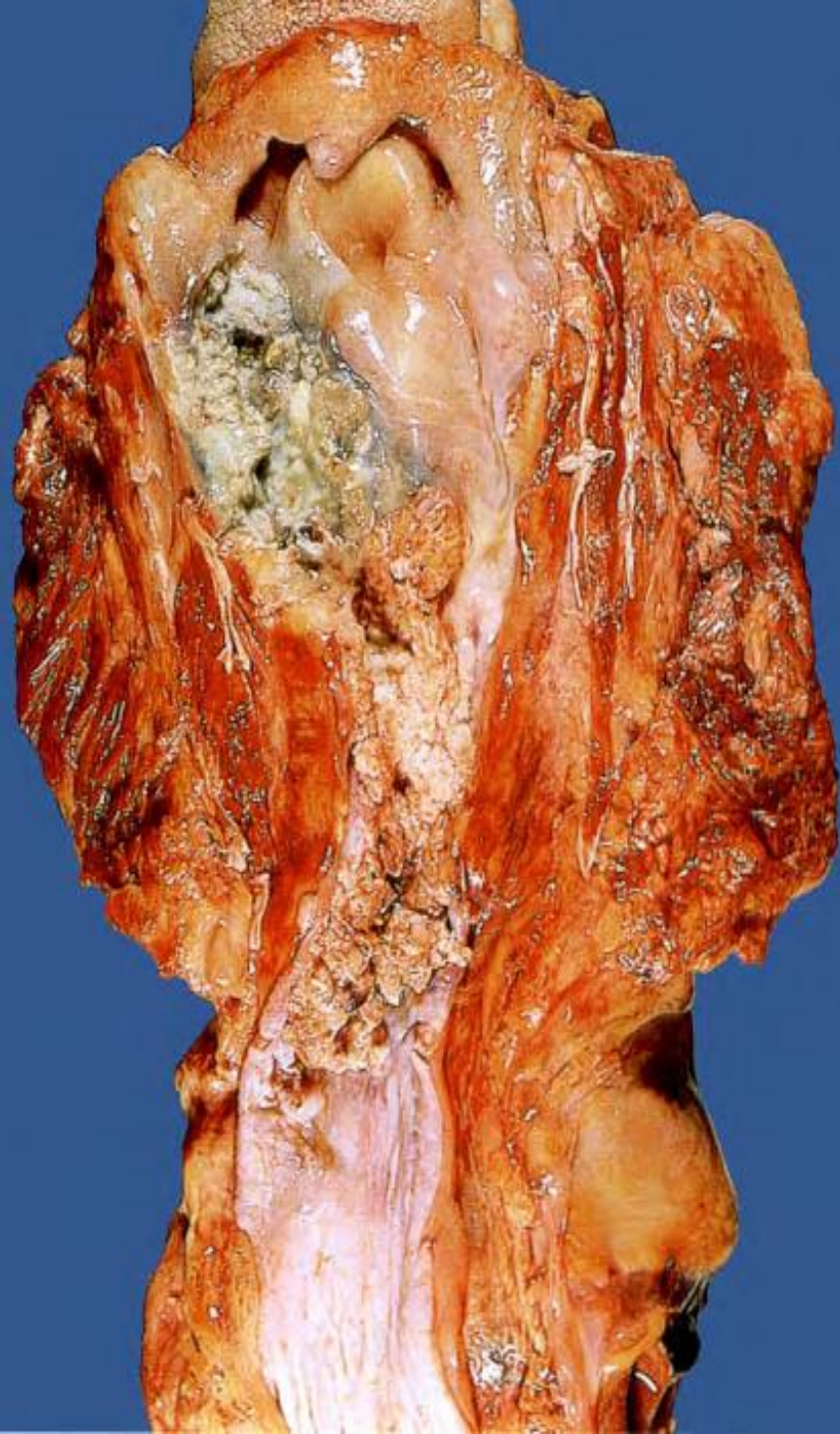The esophagus is sectioned longitudinally, in the middle third is revealed a tumoral node, which grows circularly, protruding and stenosing the lumen, with an irregular, ulcerated surface, covered with necrotic masses.

*Most esophageal carcinomas are located in the middle third. Histologically the most common form - 90% of the total number is keratinized or non-keratinized squamous cell carcinomas. Complications: infiltration into the stomach, hypopharynx, trachea with the formation of esophageal-tracheal fistula, larynx, mediastinum, lungs, pleura, aorta. Lymphogenic metastases - in the cervical, para-esophageal, tracheobronchial, subdiaphragmatic nodules. Hematogenous metastases are rare.*

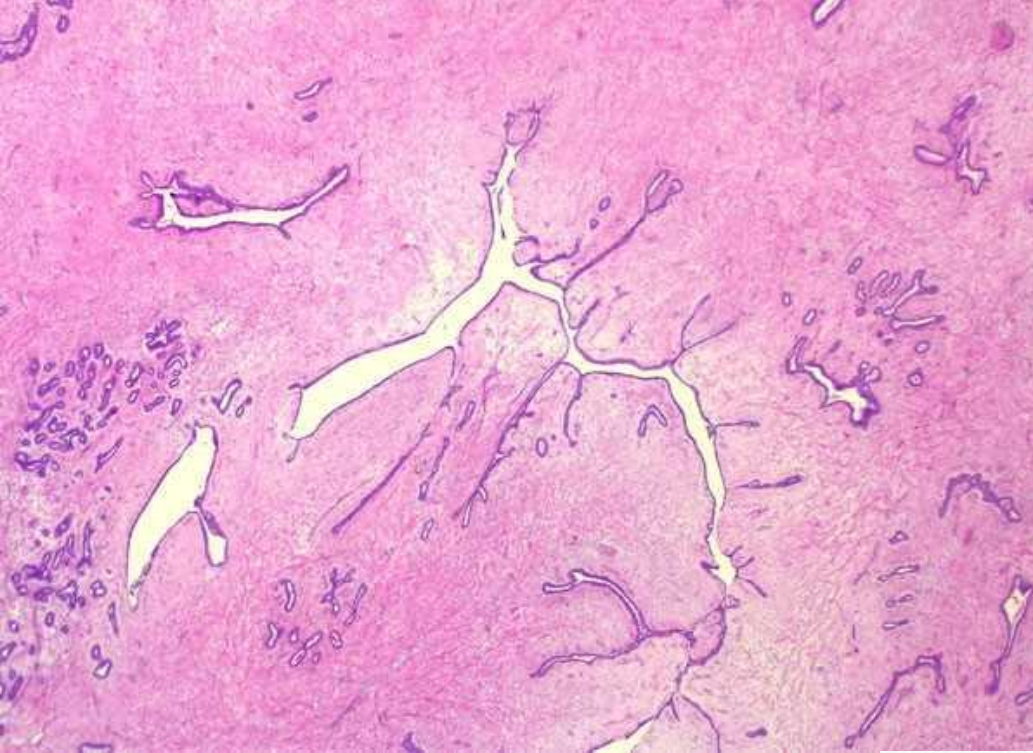


**№ 42. Metastasis of carcinoma into into lungs.**



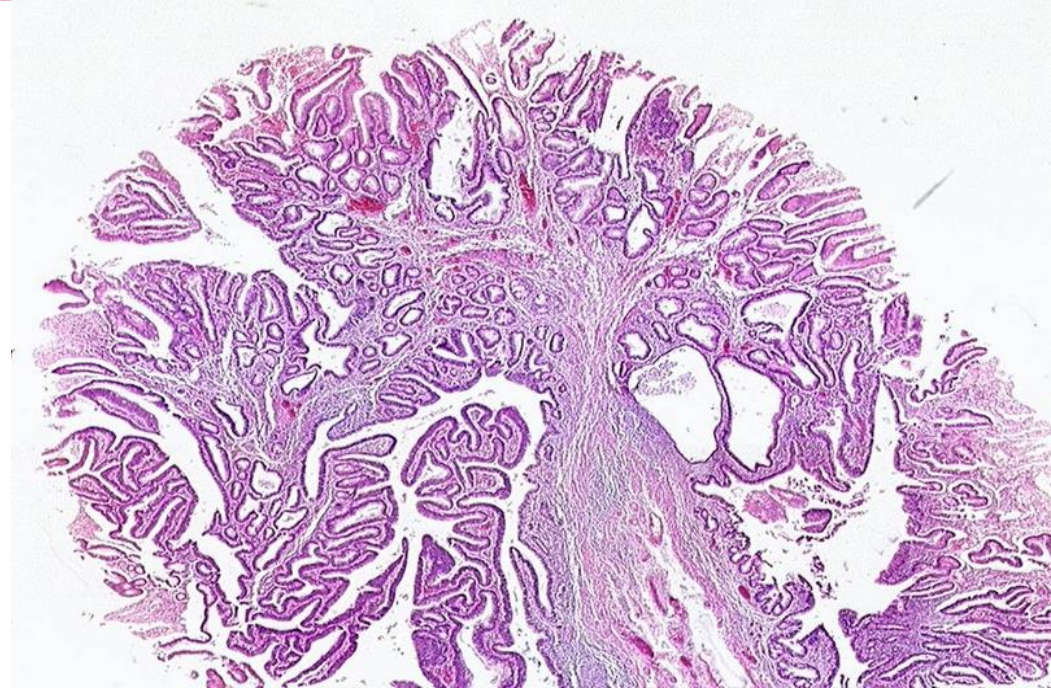


**№ 59. Carcinoma of esophagus.**



**Tissue atypia in tubulo-villous adenoma of the colon. (*H-E stain*).**

**Tissue atypia in fibroadenoma of the mammary gland. (*H-E stain*).**

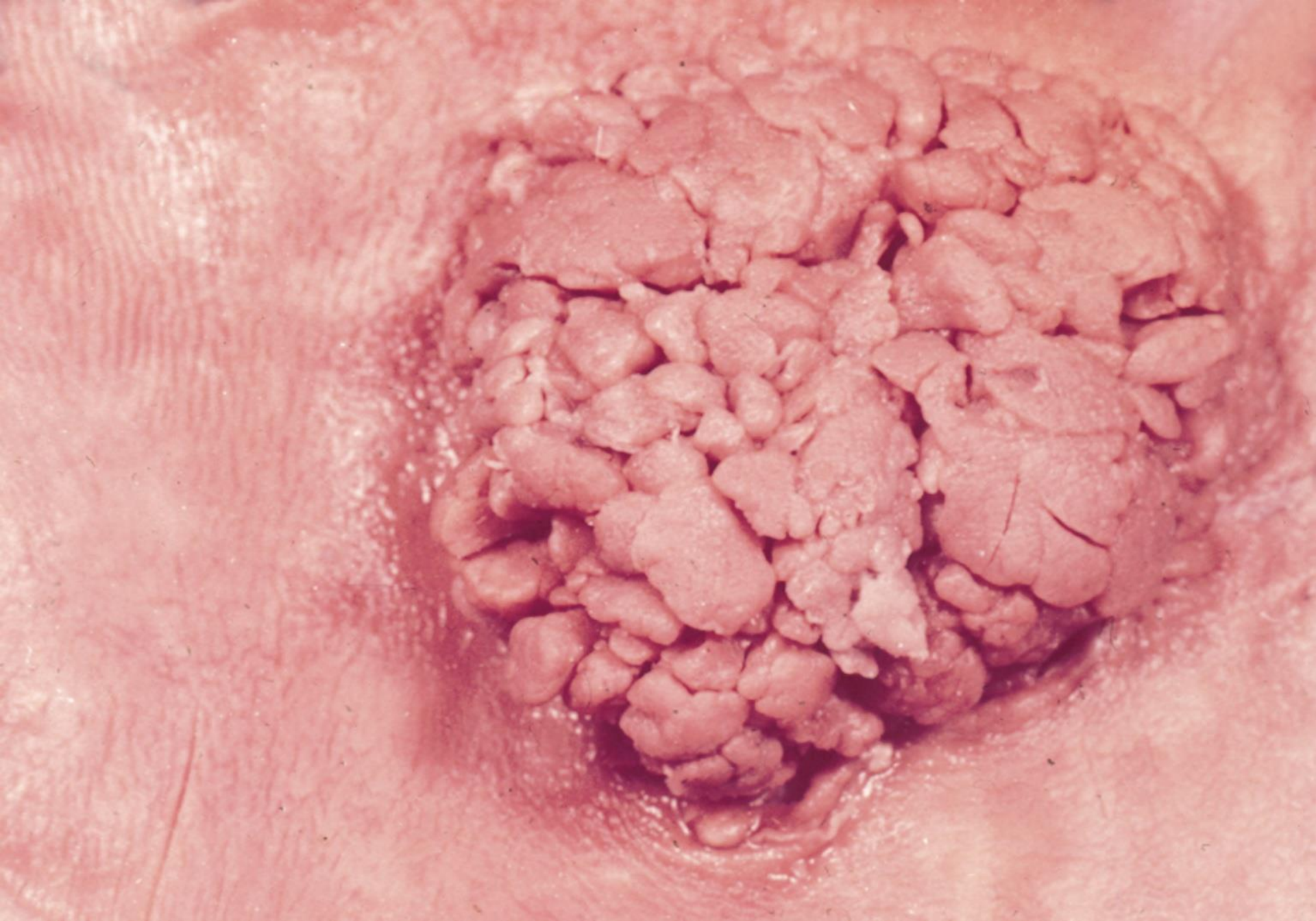





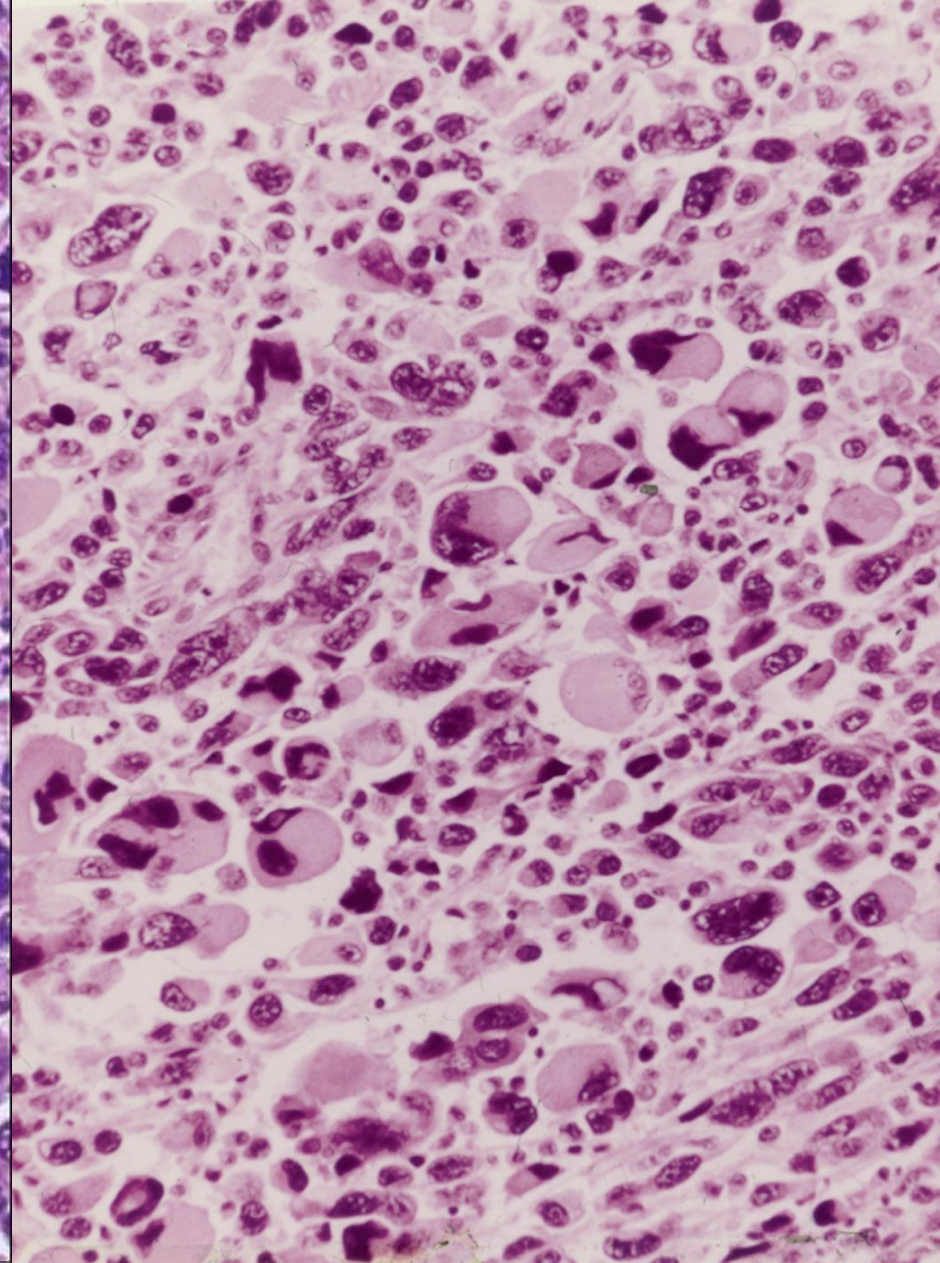
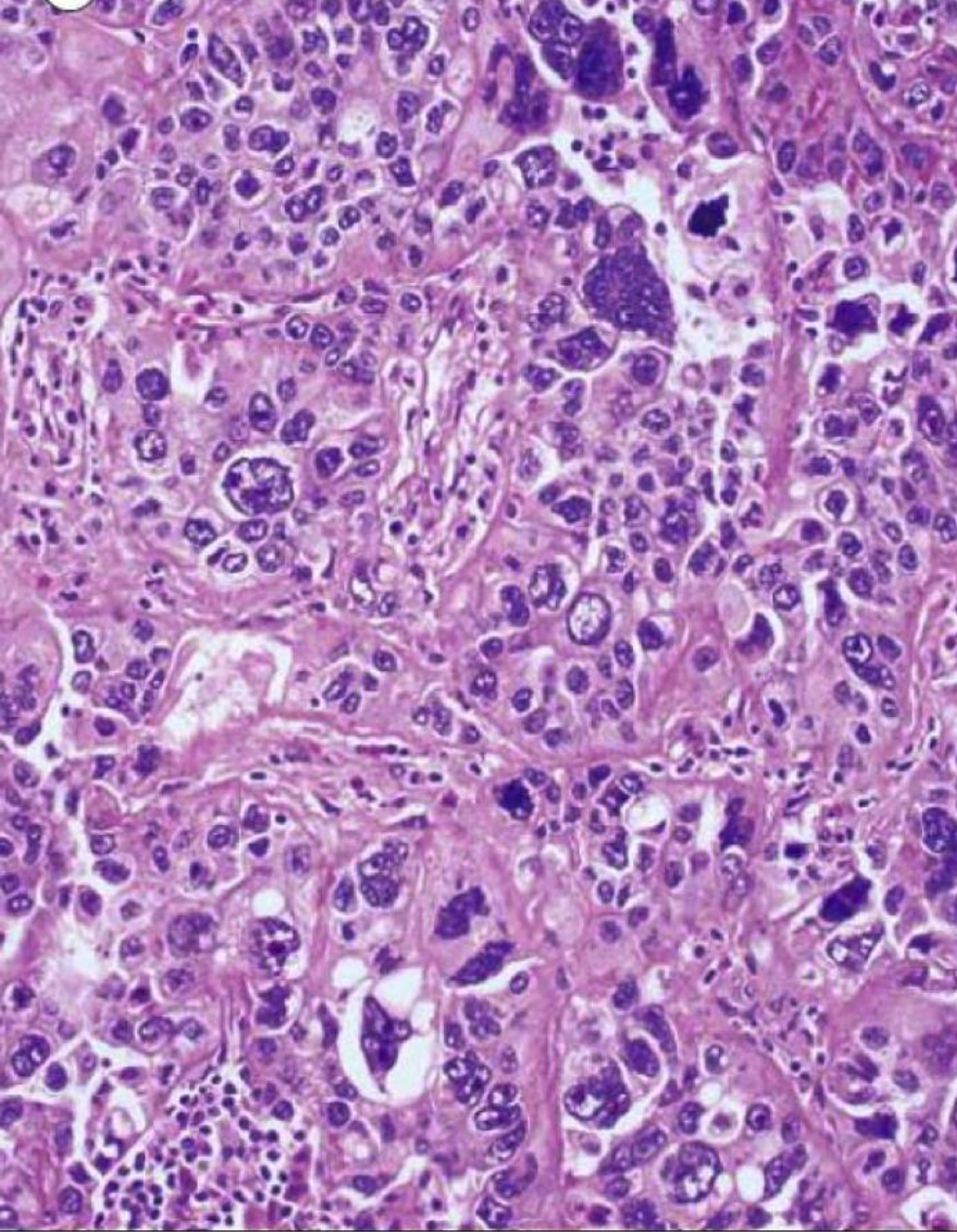
**Familial adenomatous polyposis.**





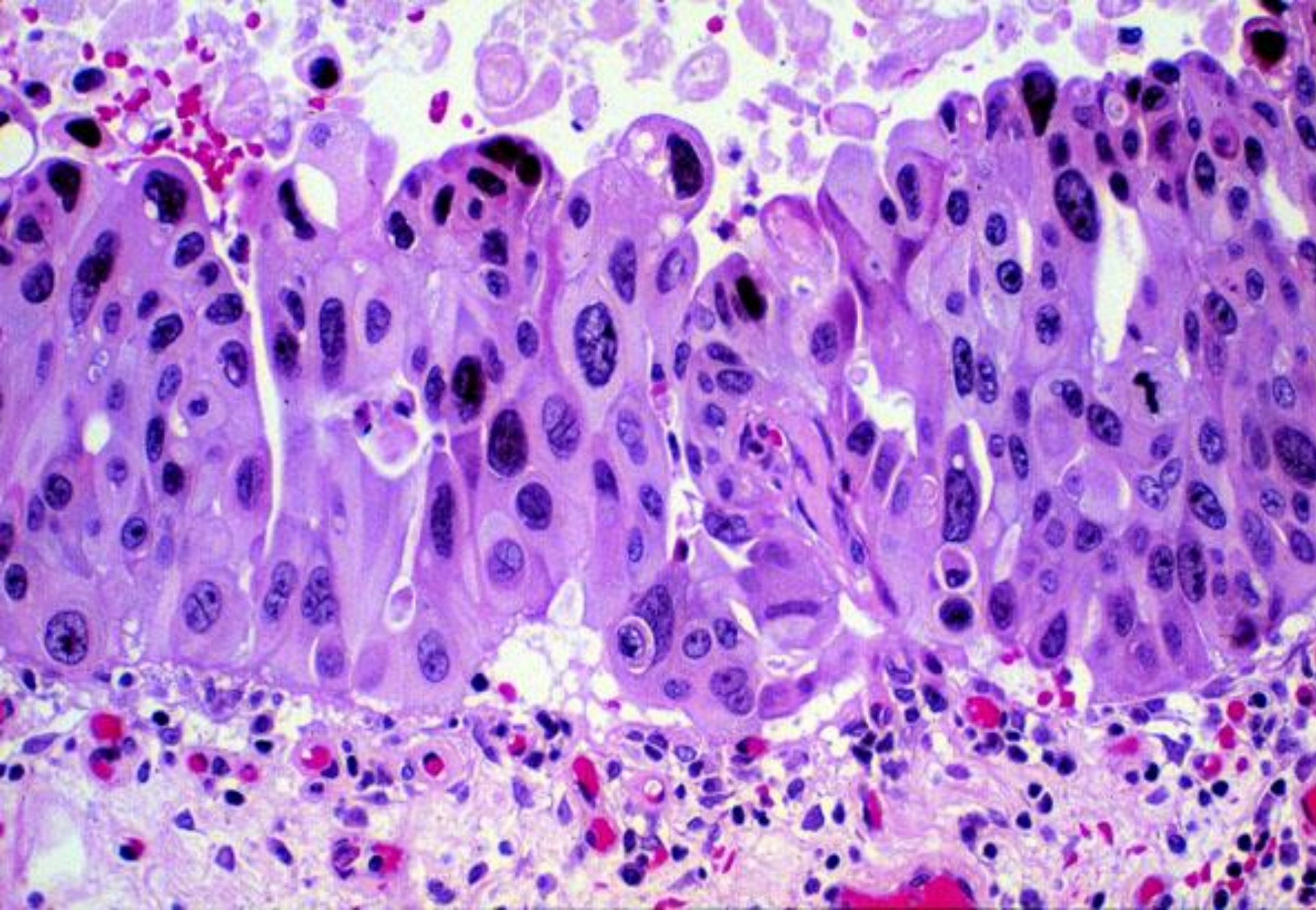
**Skin papilloma.**





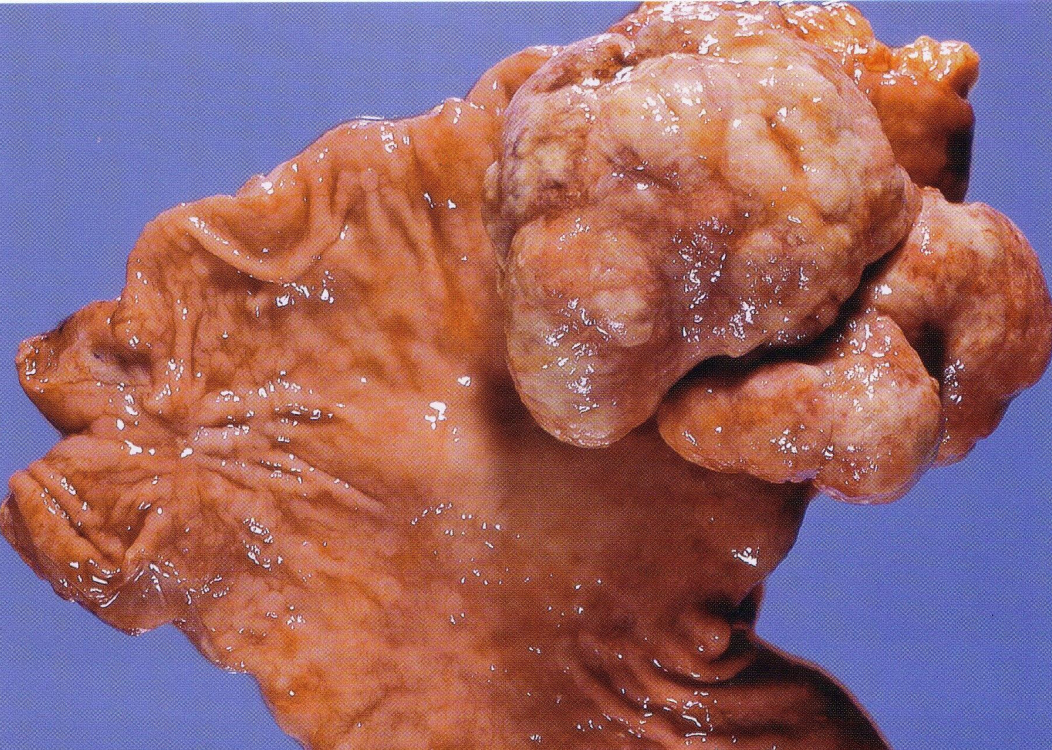**Cellular atypia in malignant tumors (undifferentiated carcinoma and rhabdomyosarcoma).**





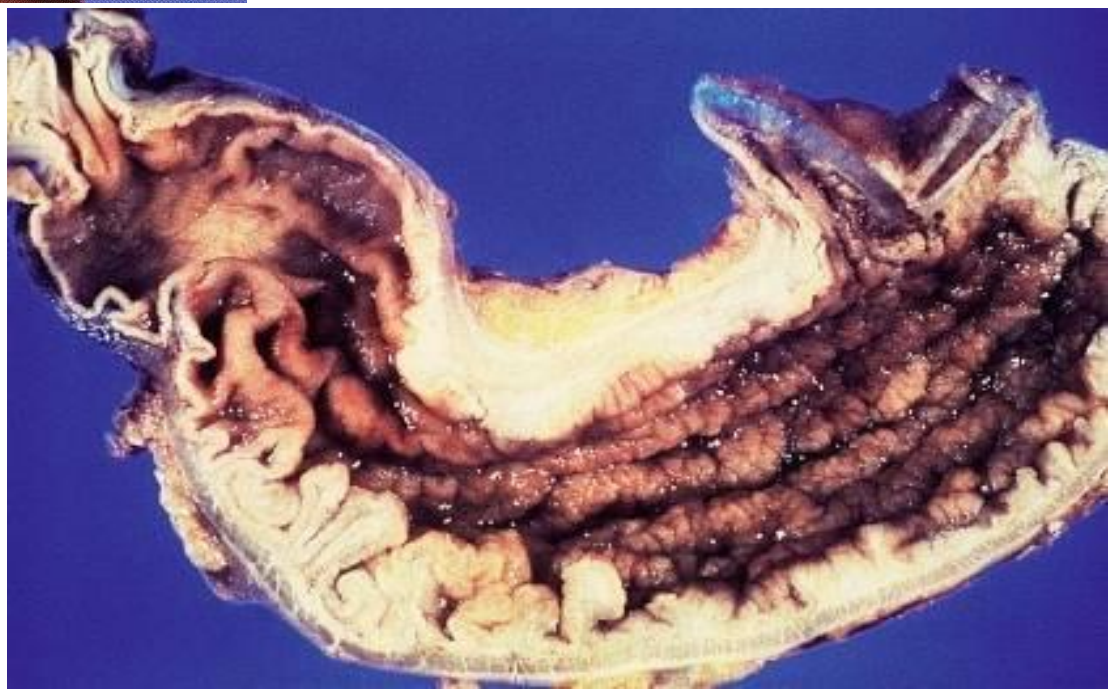***Carcinoma in situ. (H-E stain).***



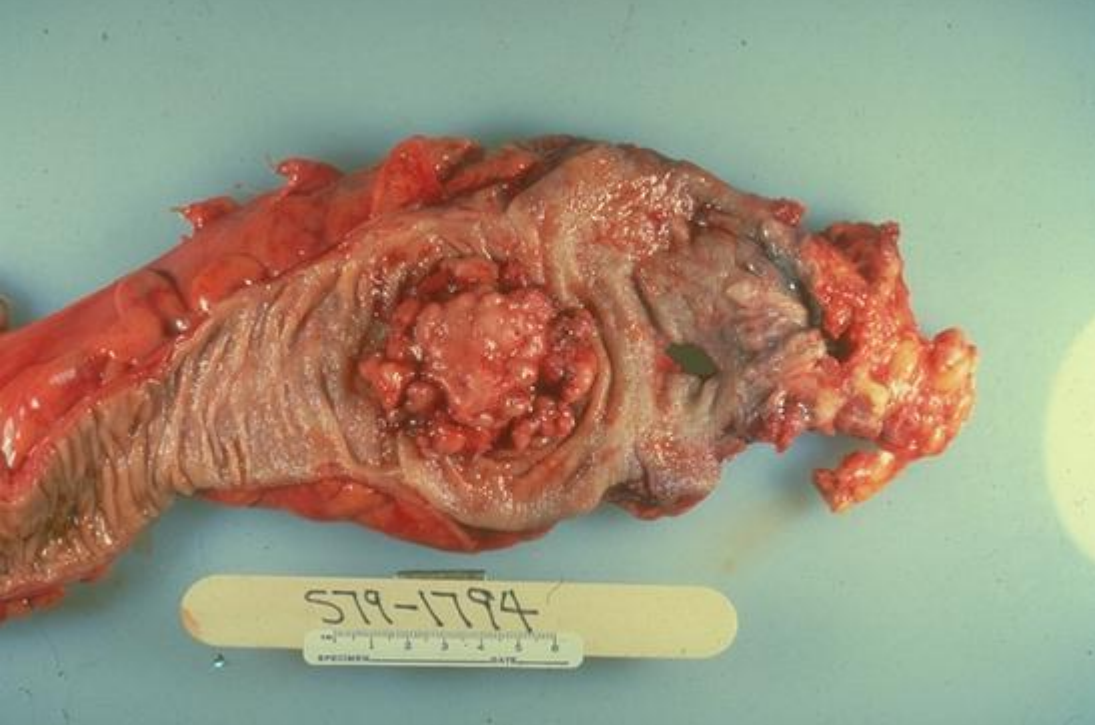


**Infiltrative gastric carcinoma.**

**Polypoid gastric carcinoma**

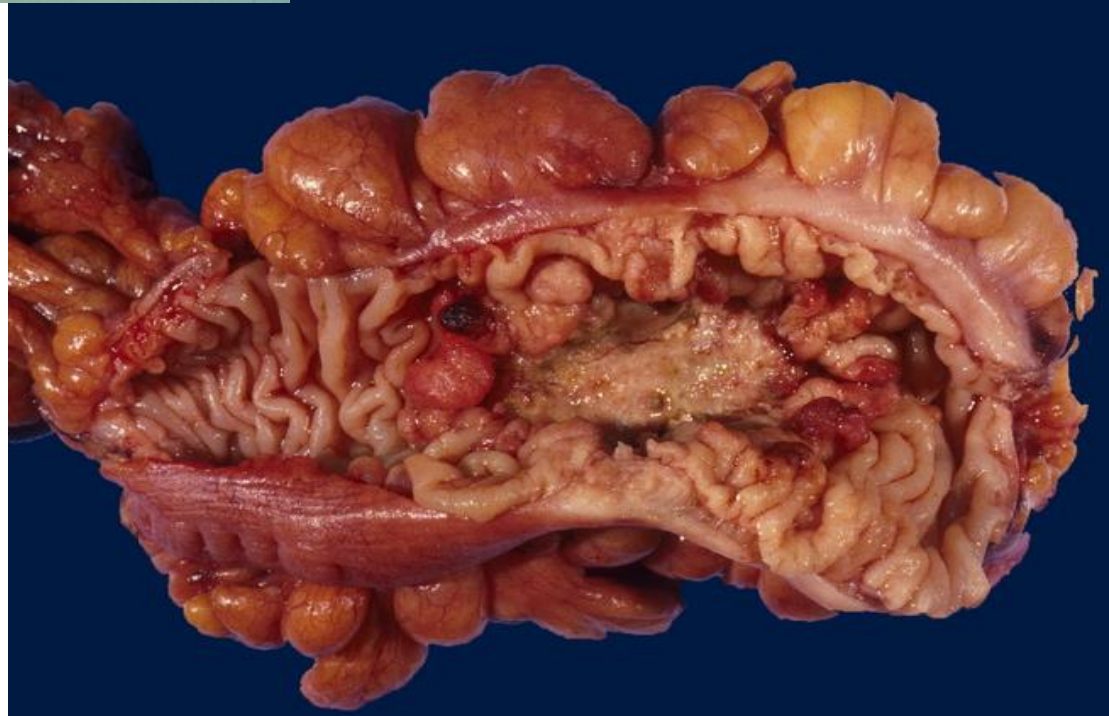



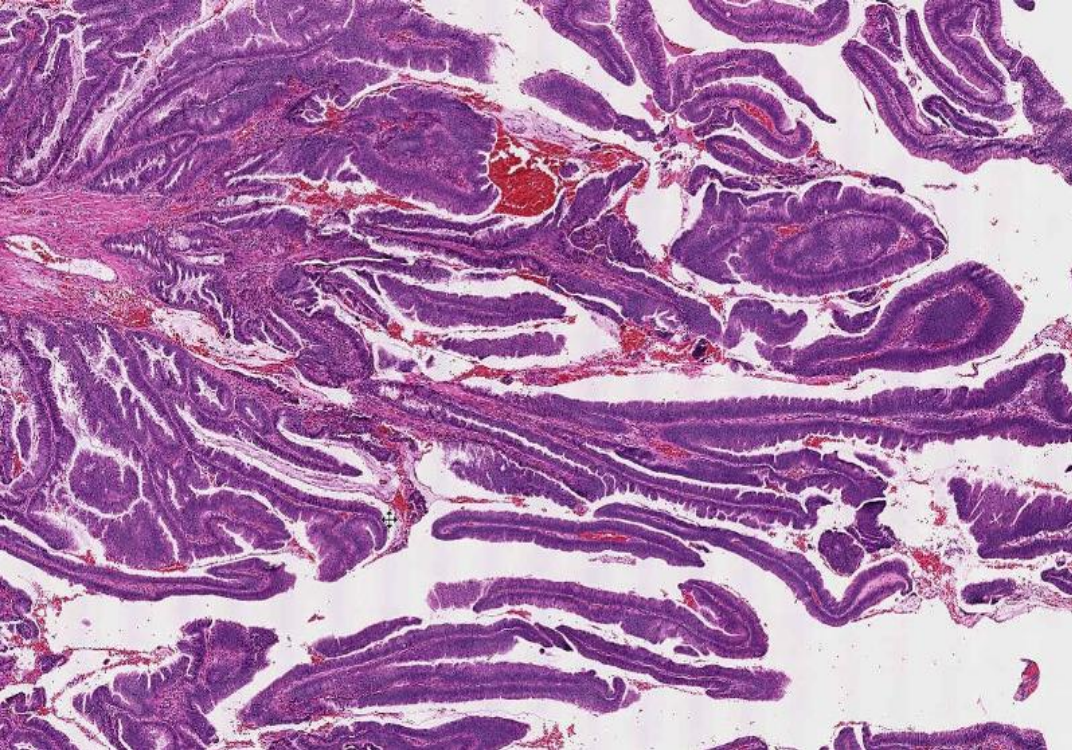


**Infiltrative colon carcinoma.**

**Colon carcinoma  
(exophytic lesion).**

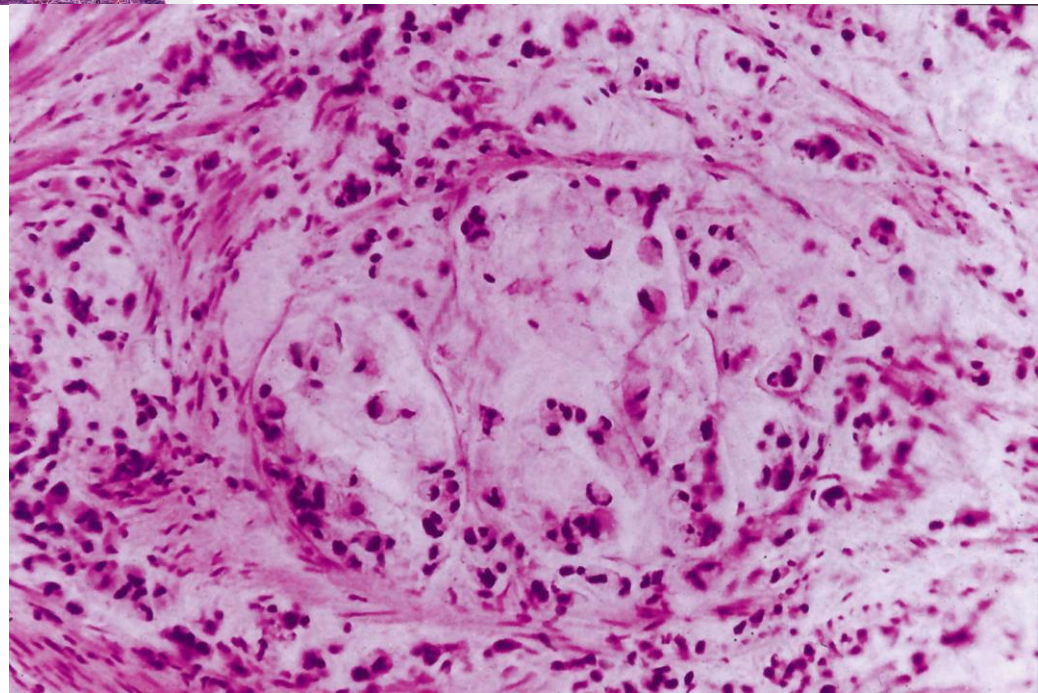




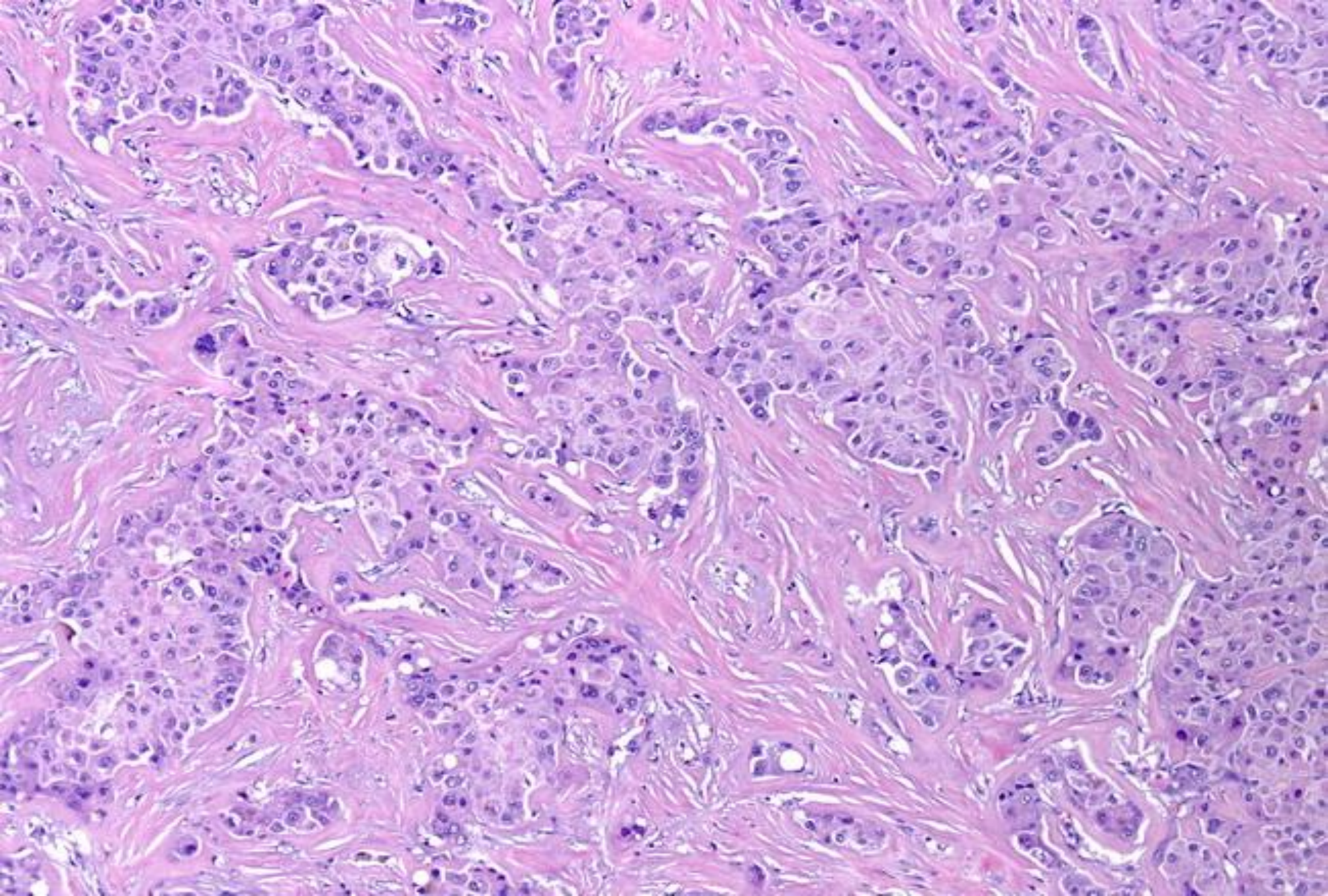


**Mucinous carcinoma.**  
*(H-E stain).*

**Papillary glandular carcinoma.**  
*(H-E stain).*

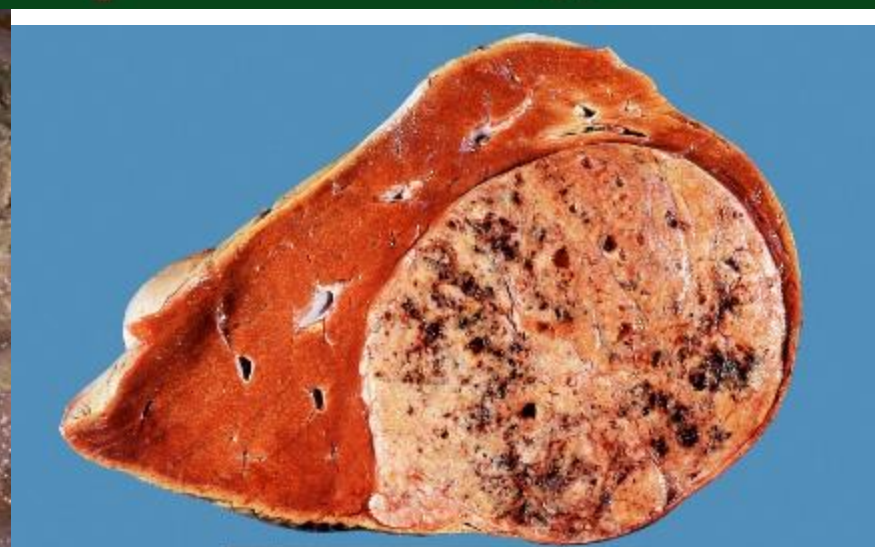
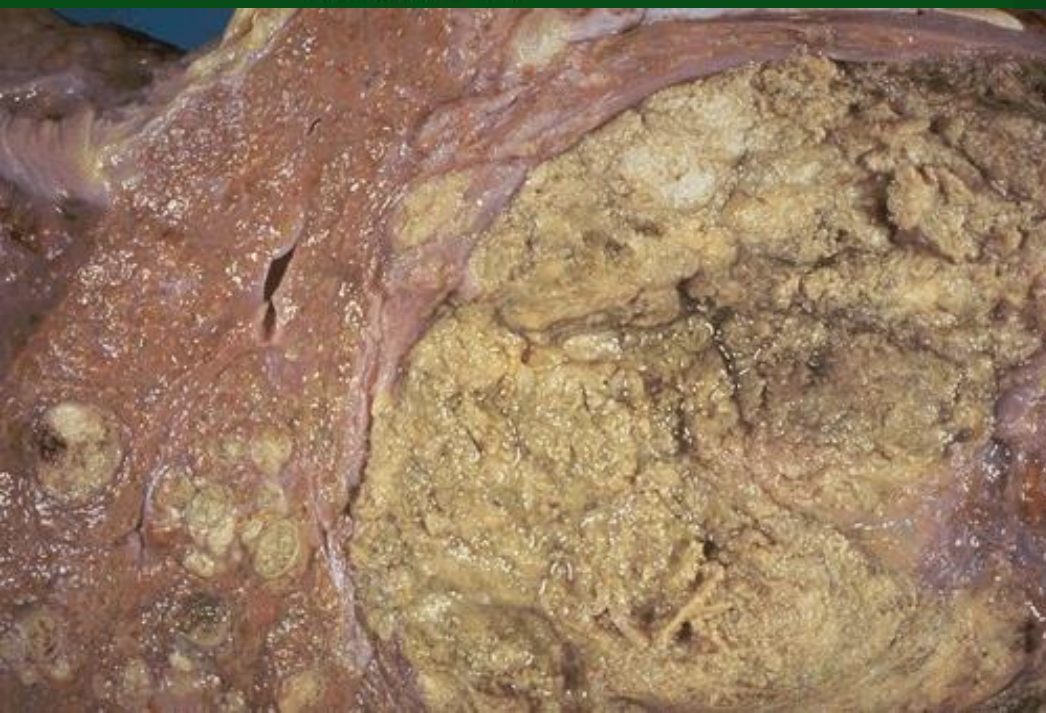
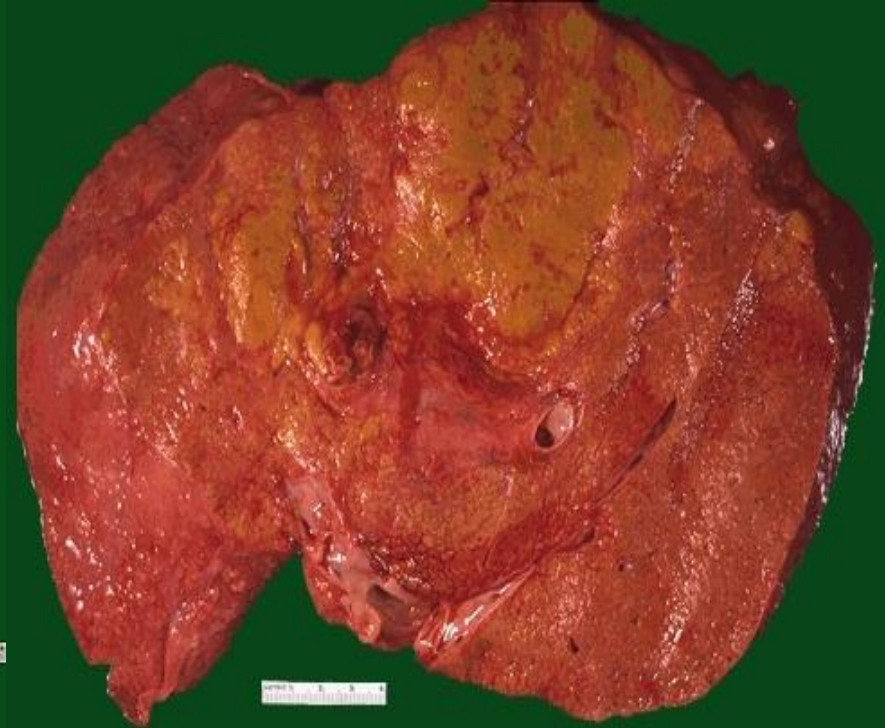






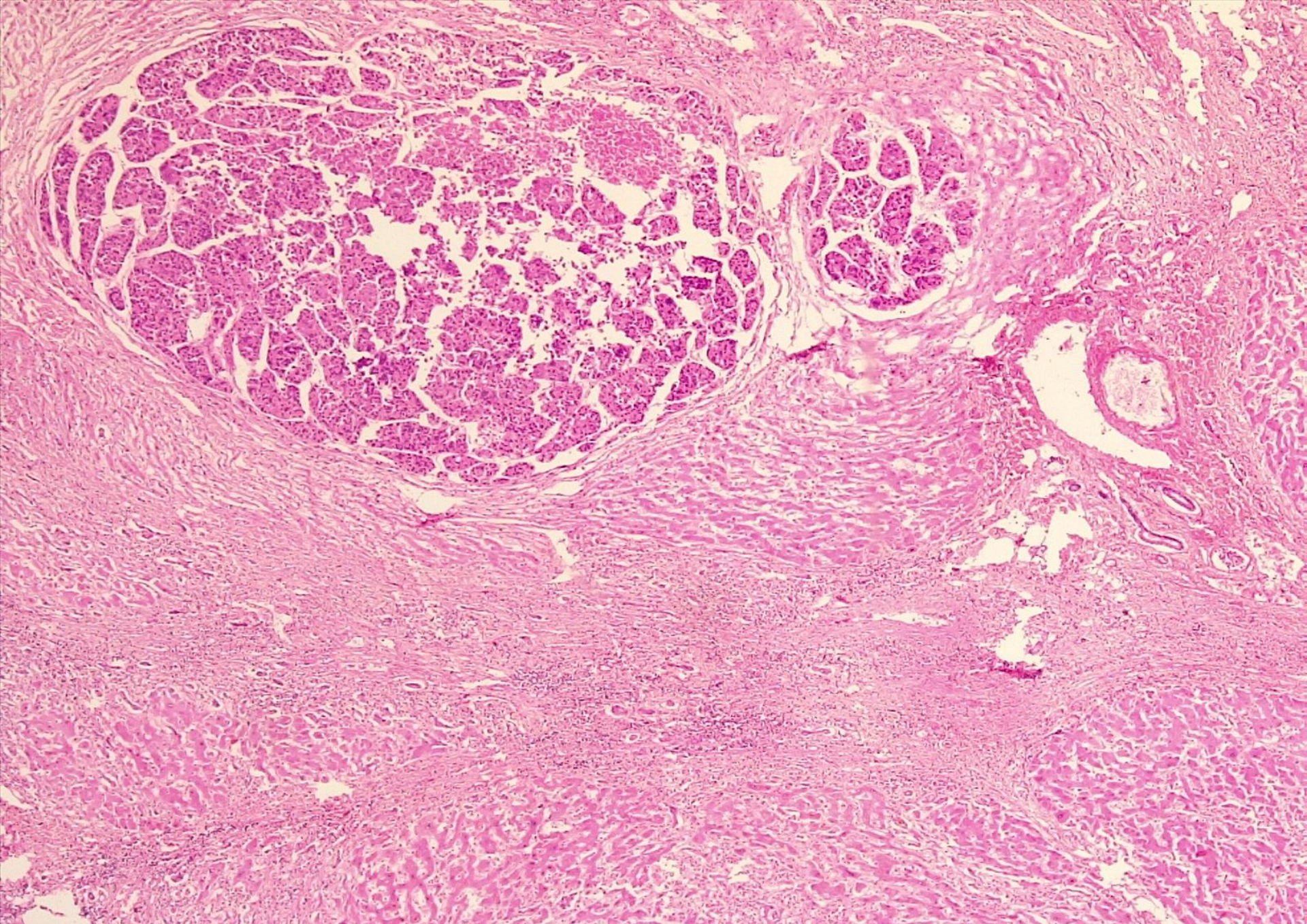
**Scirrhous (fibrous) carcinoma. (*H-E stain*).**  
**(*Hepatocellular carcinoma with scirrhous pattern*).**





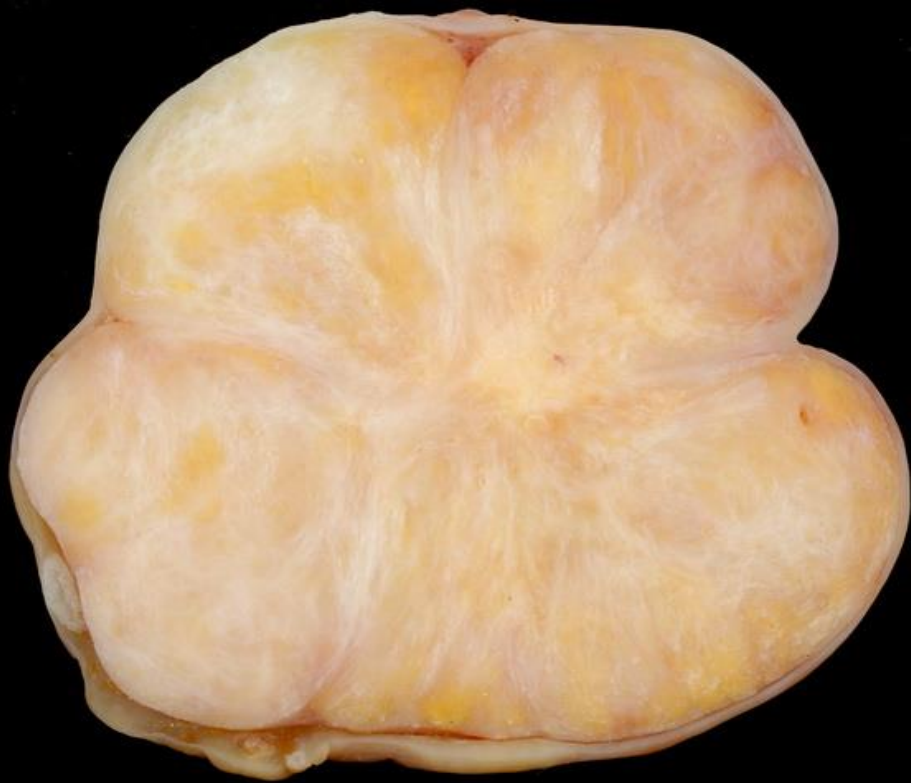**Hepatic carcinoma.**



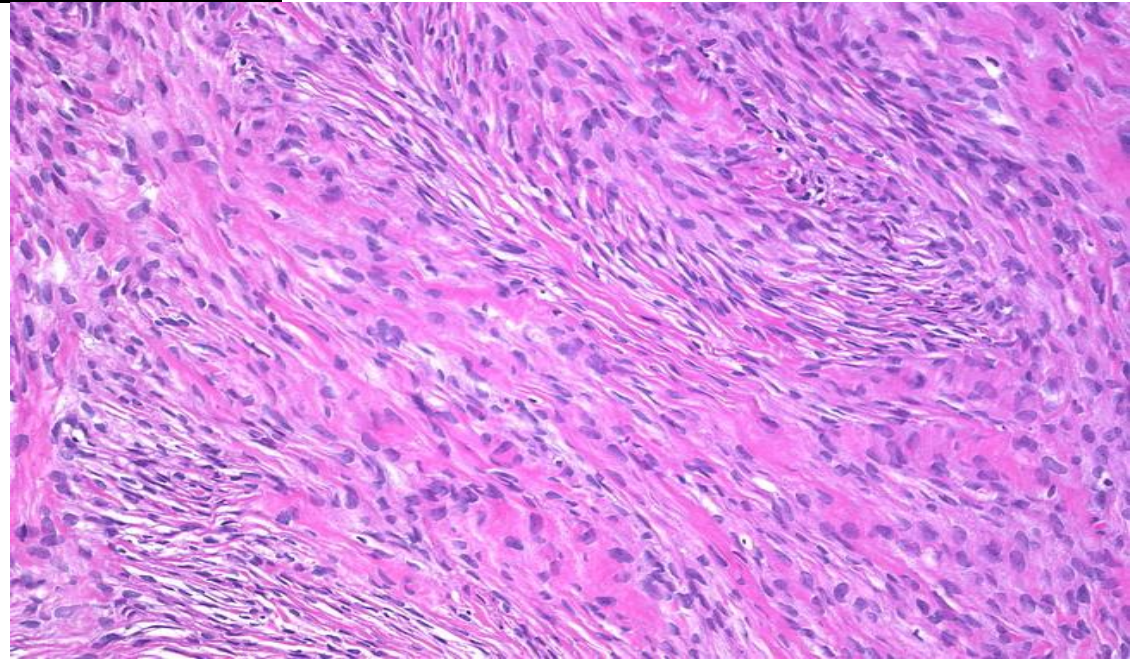


**Cellular atypia in hepatocellular carcinoma. (*H-E stain*).**

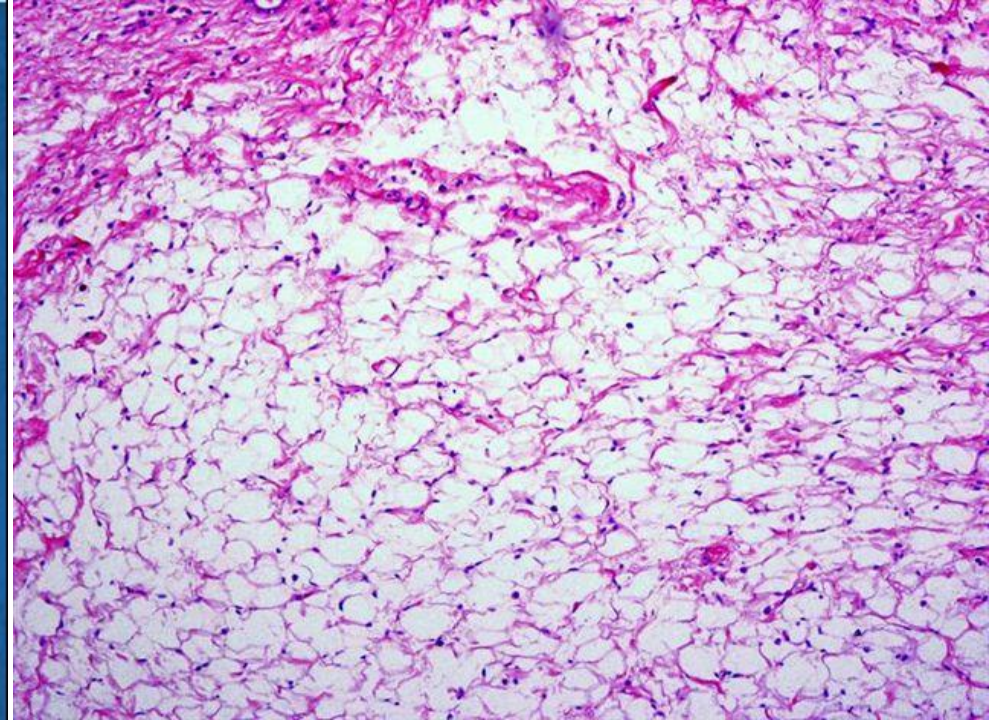
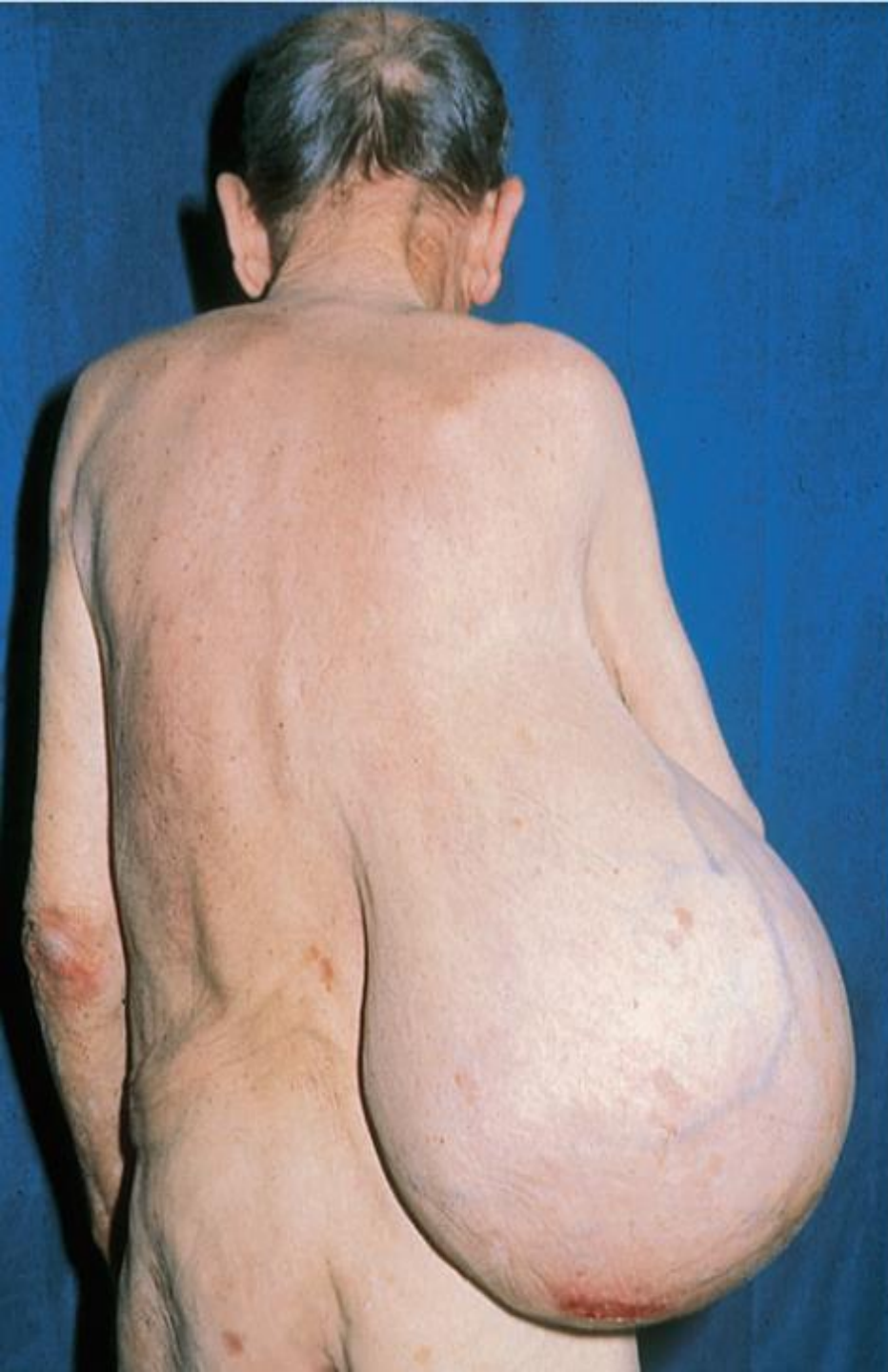



**Fibroma.**

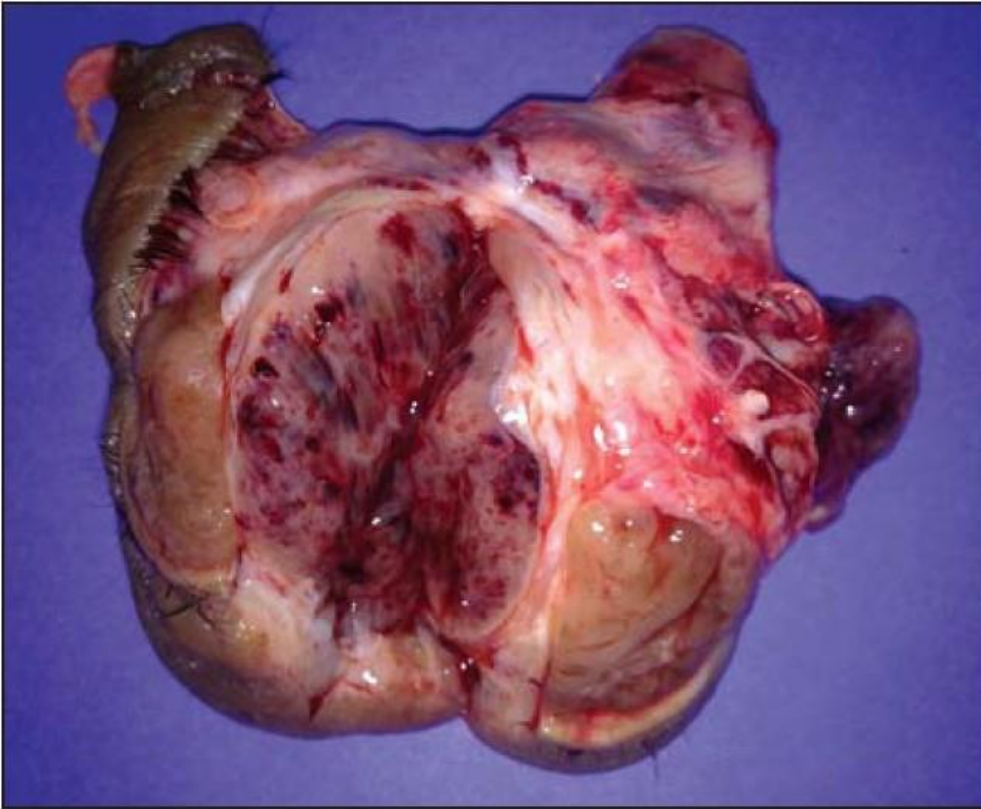




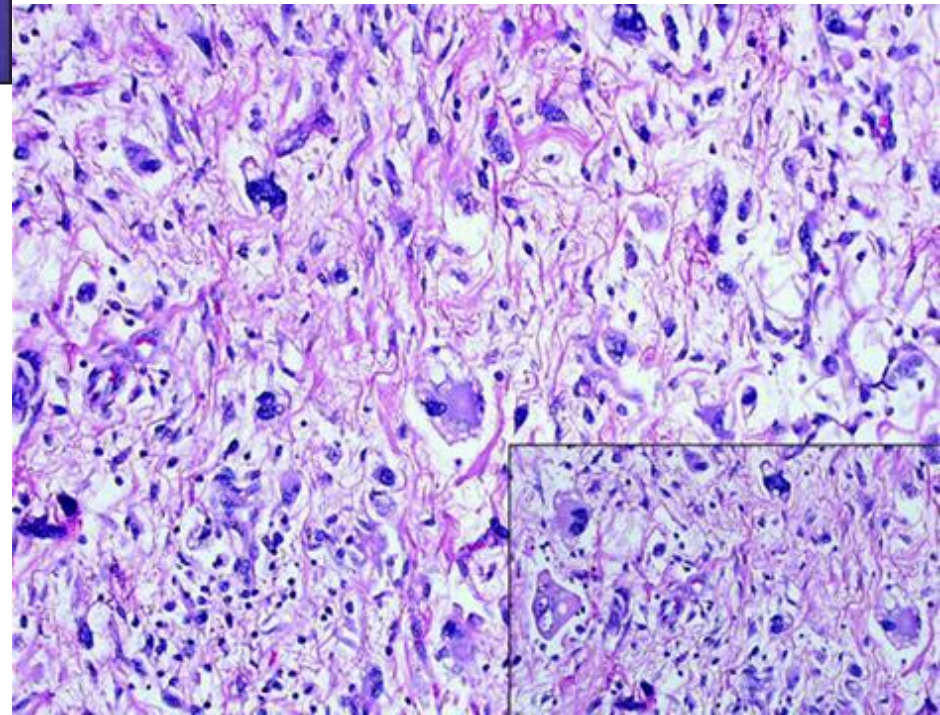


**Lipoma.**

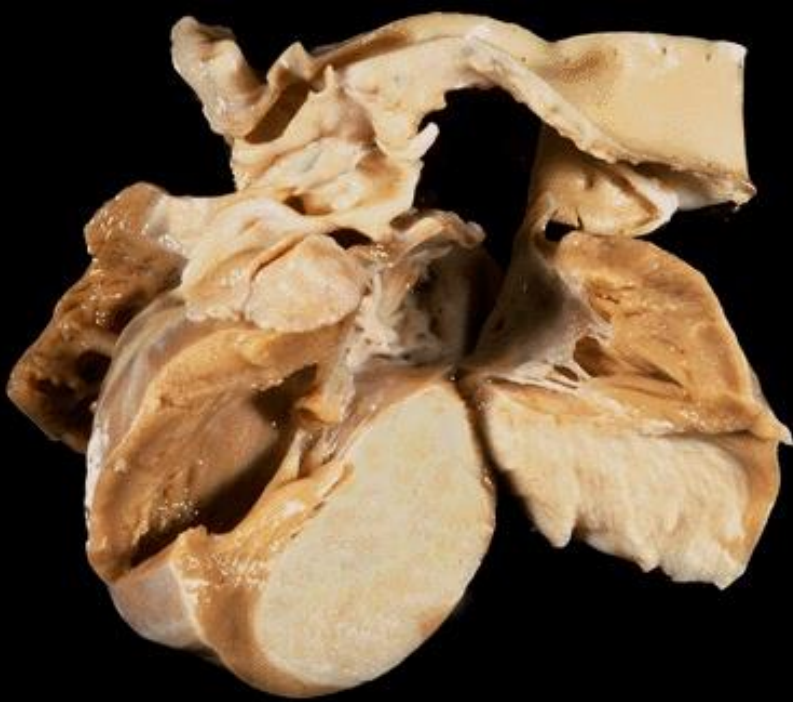



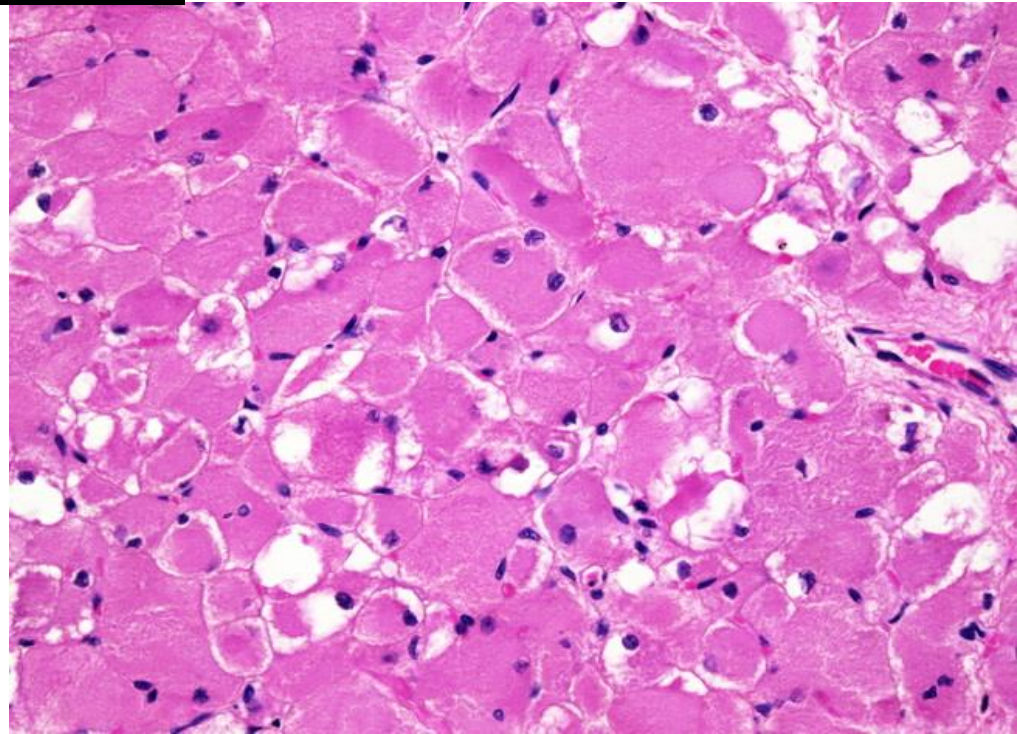
**Liposarcoma.**



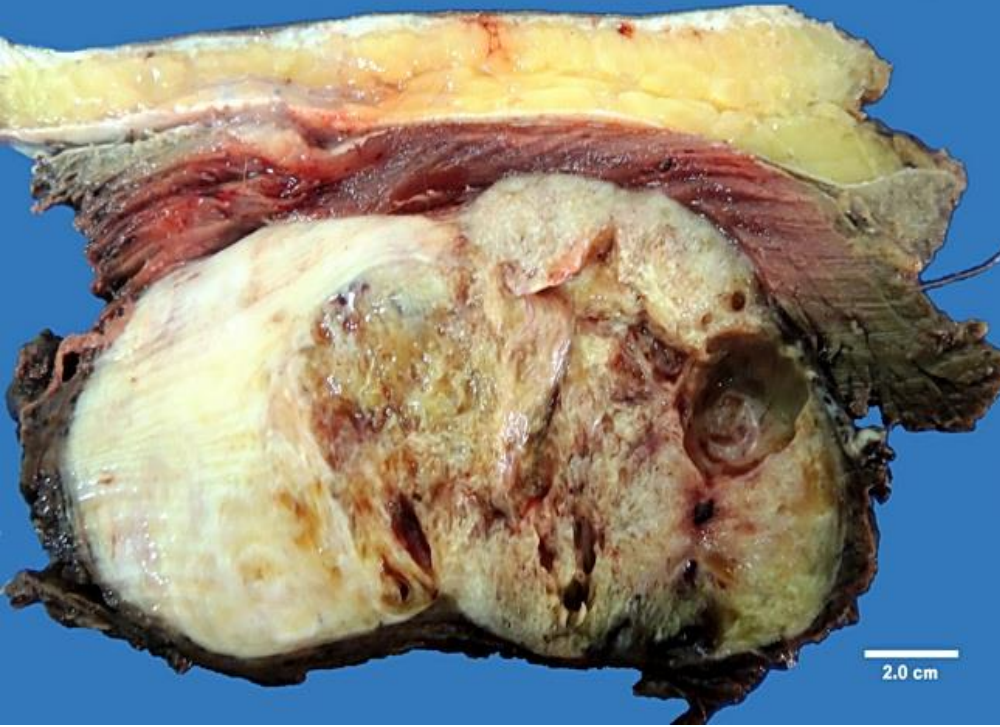




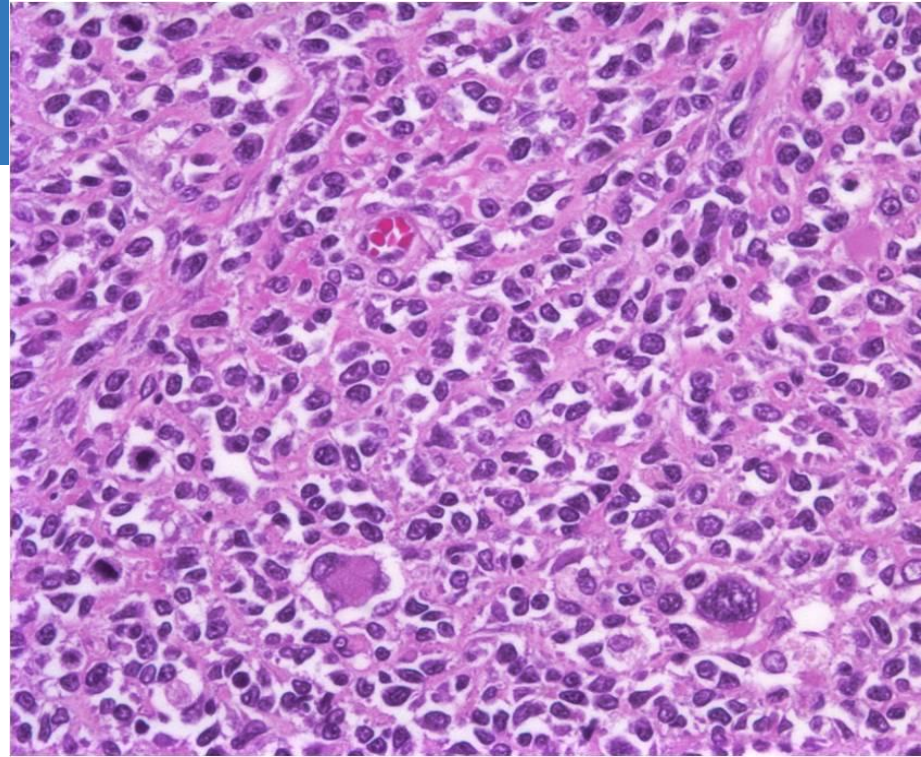
**Cardiac rhabdomyoma.**



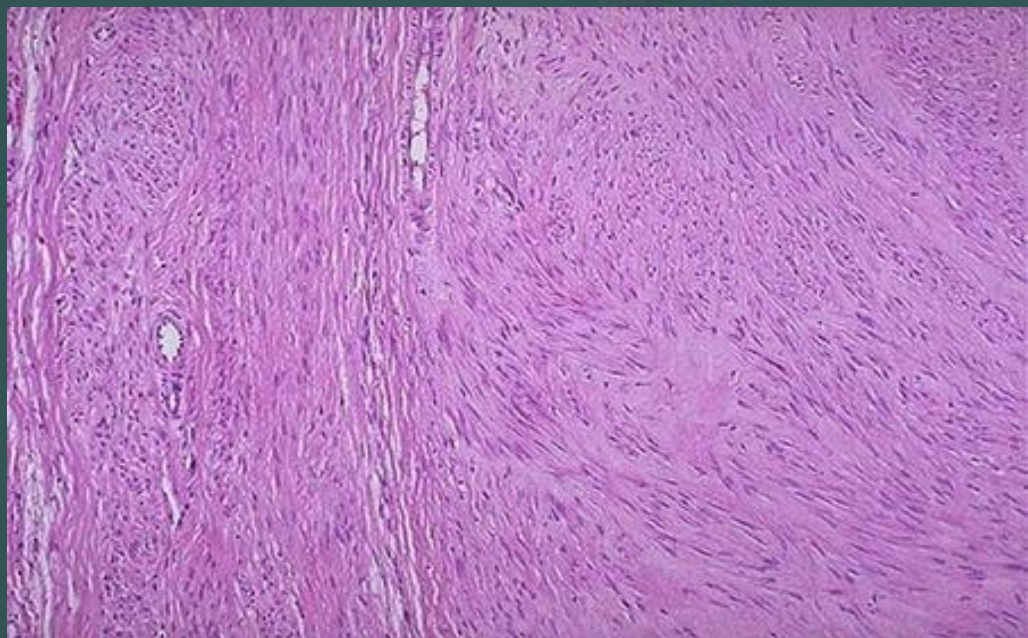
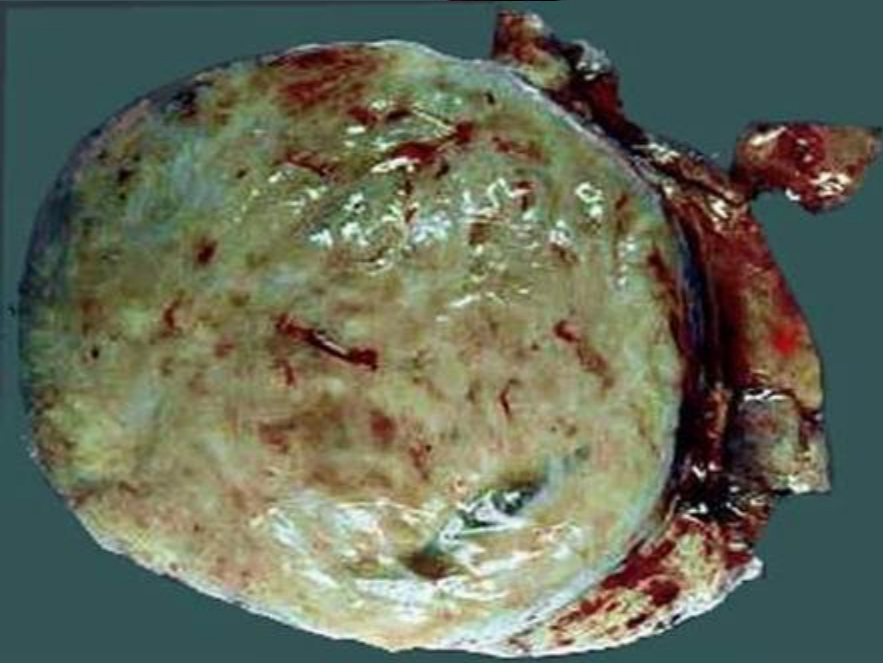
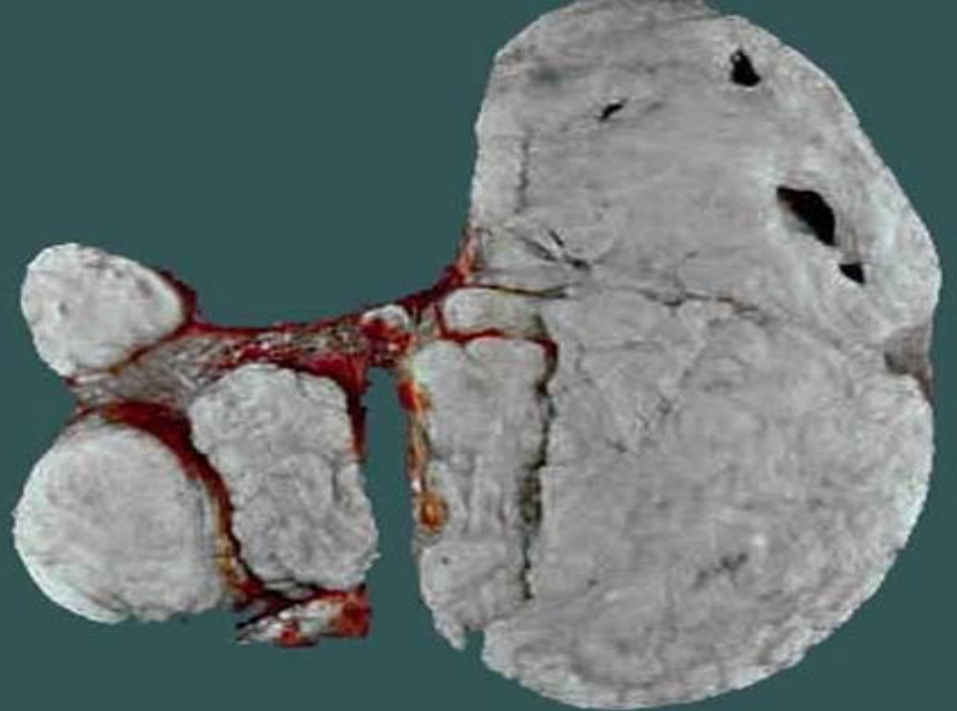
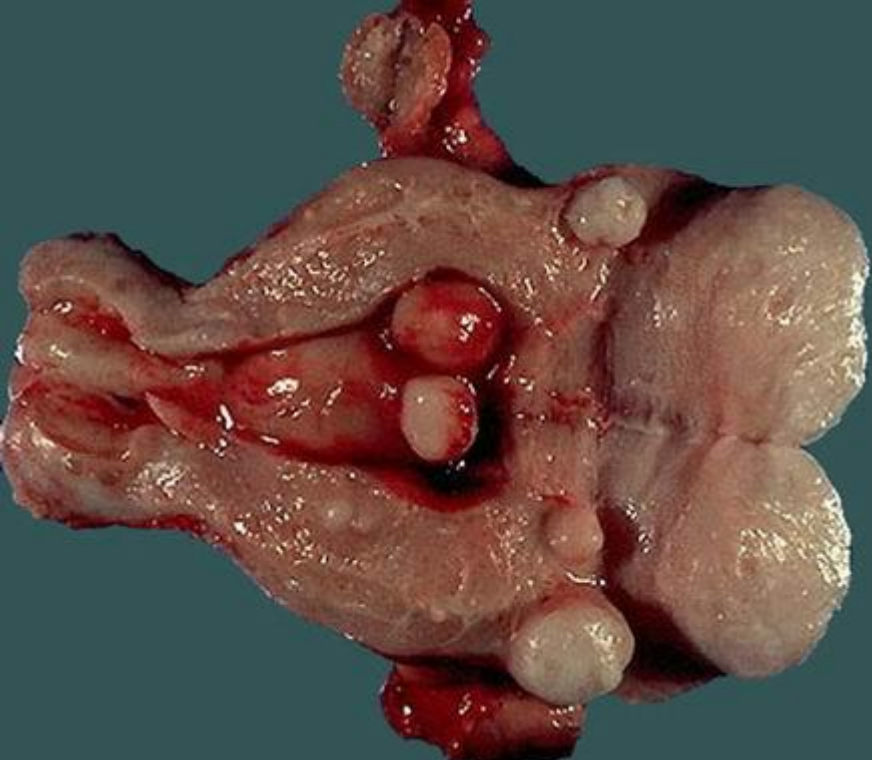



**Rhabdomyosarcoma at the level  
thigh.**

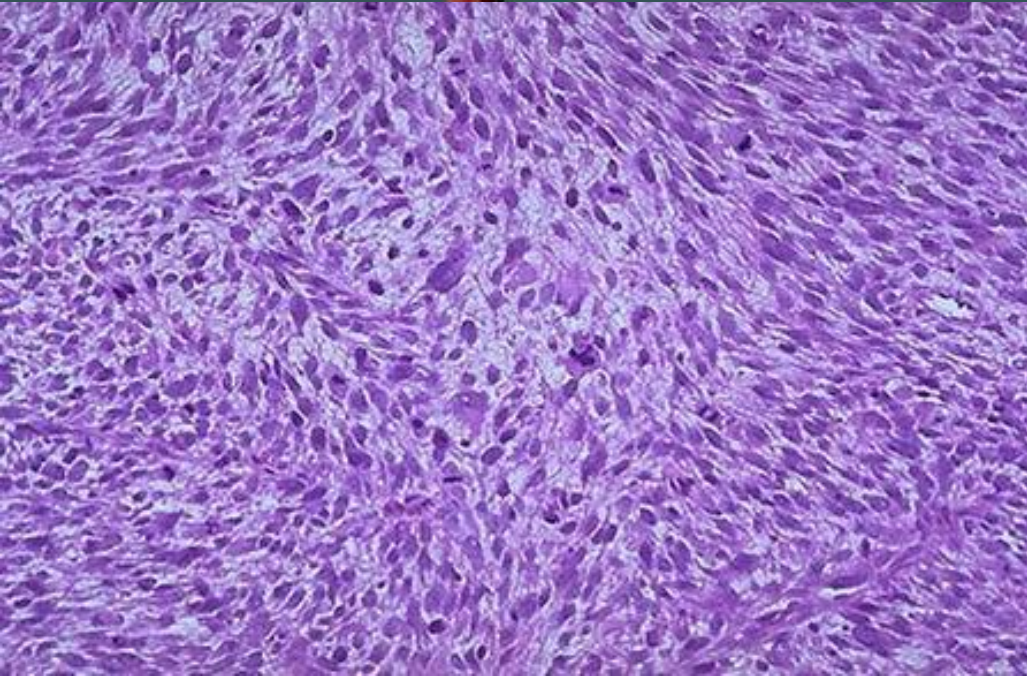
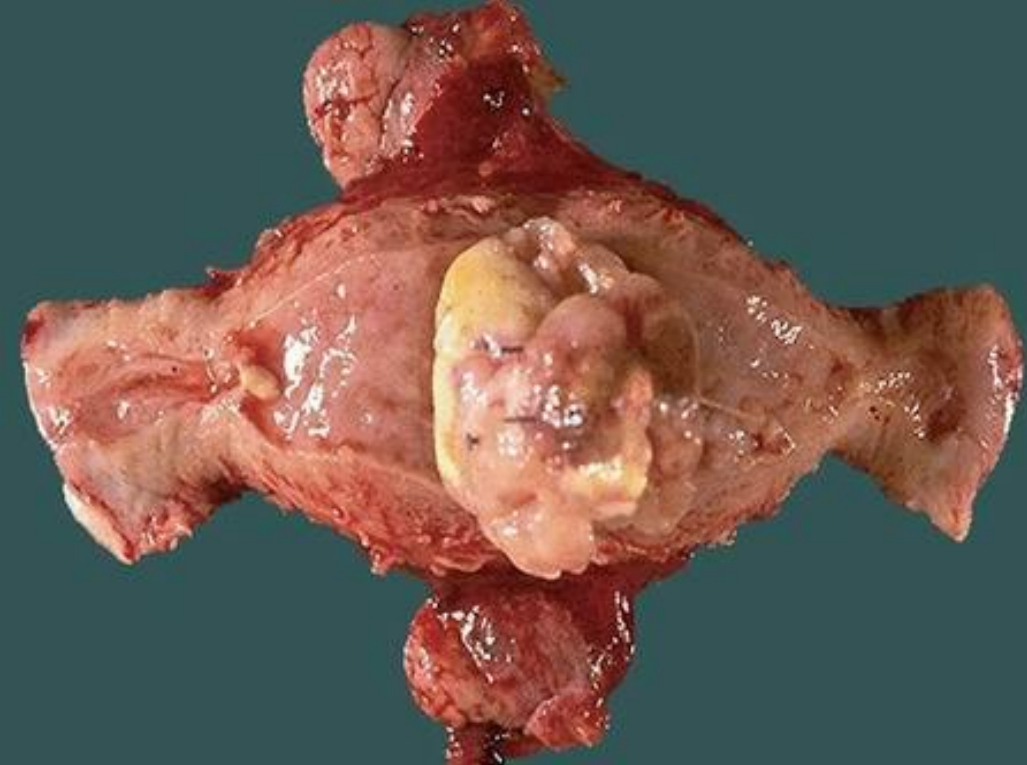






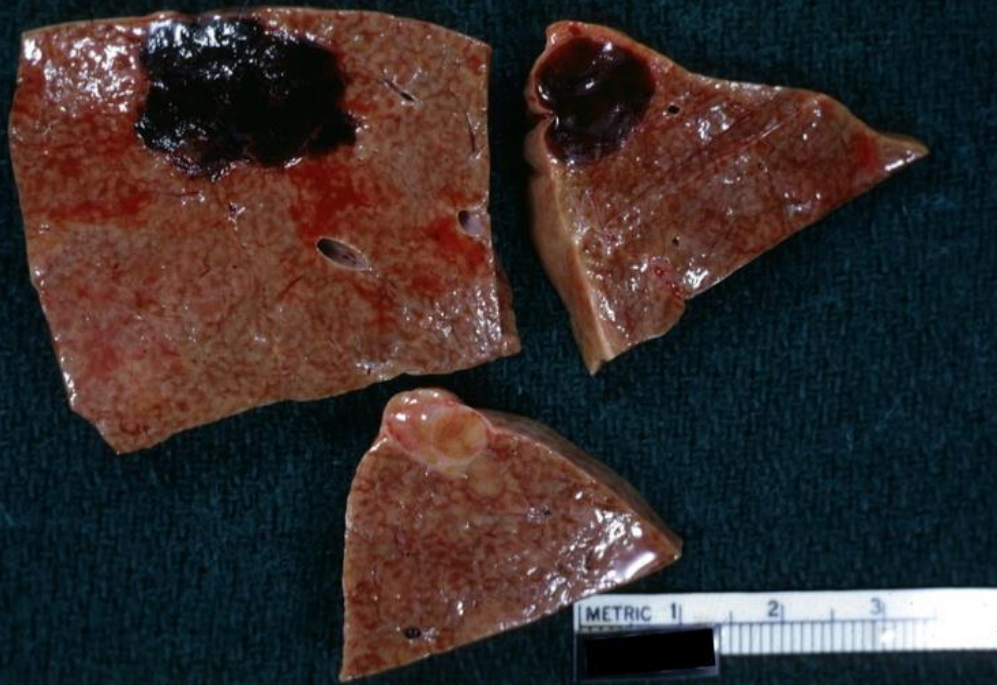**Uterine leiomyoma.**



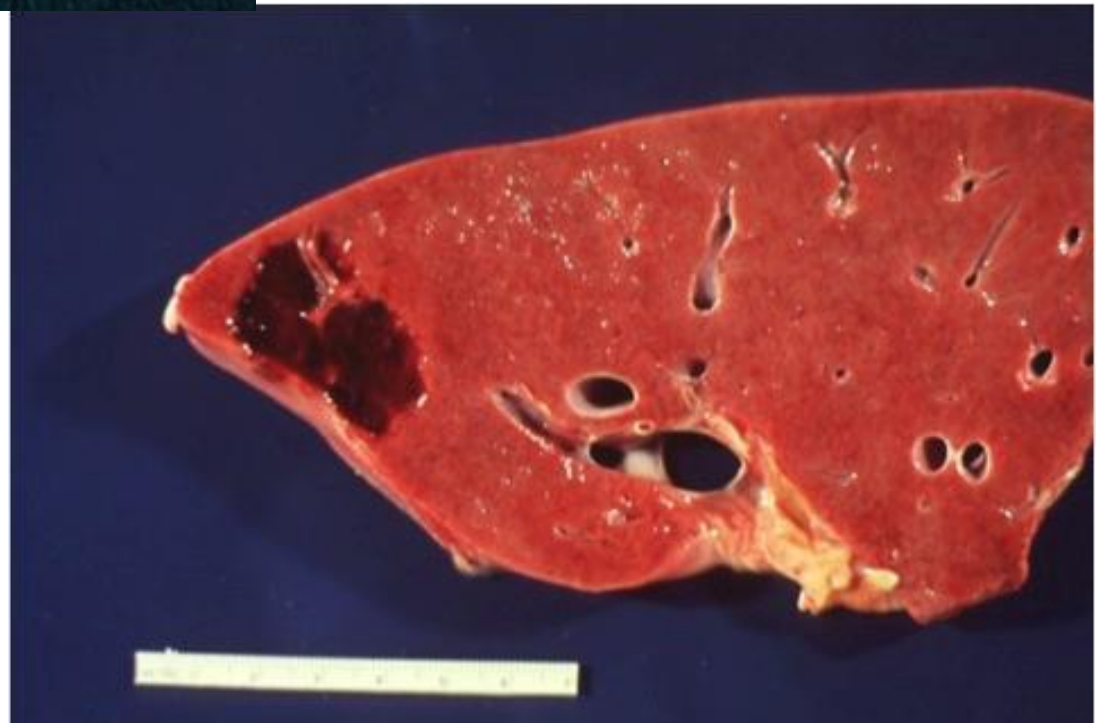

**Leiomyosarcoma.**

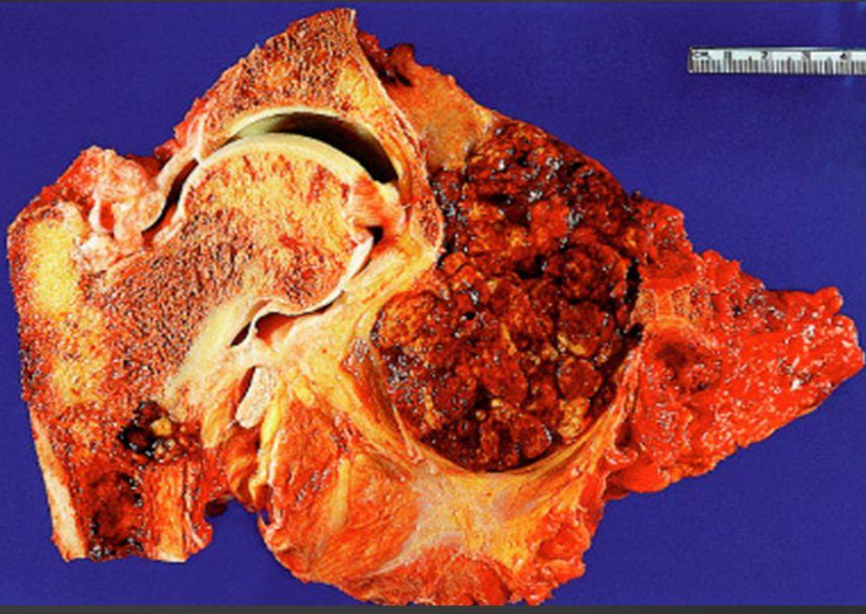



**Hepatic cavernous hemangioma.**

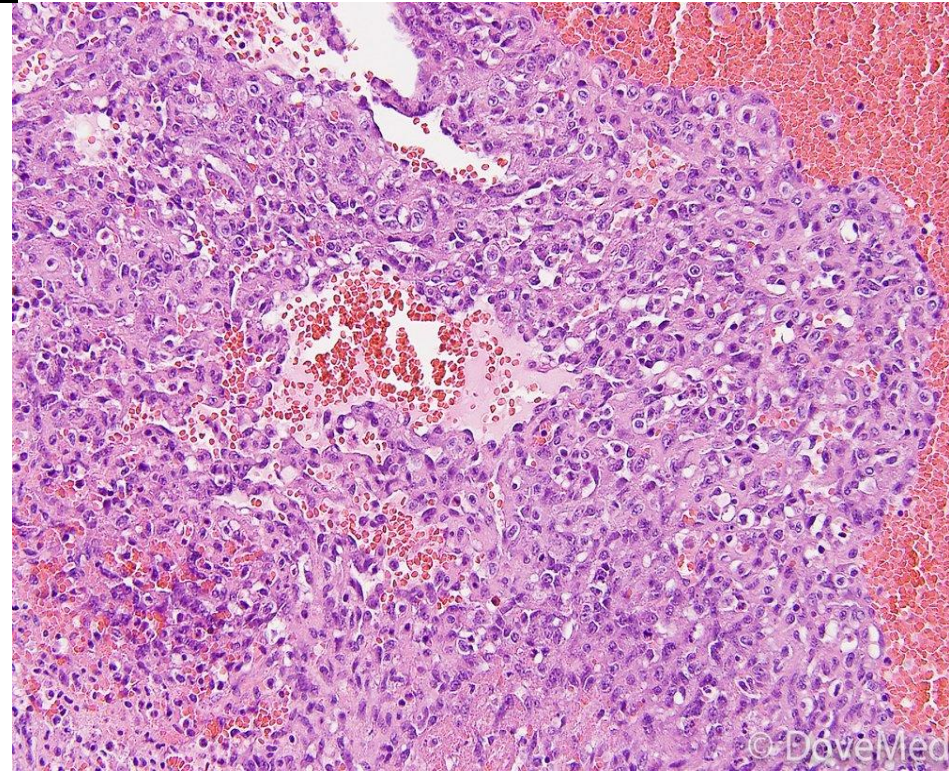






Gross : Hemorrhagic appearance of angiosarcoma of lip

## Angiosarcoma.





# Definition

- ▶ **Tissue neoformation** constituted by cell proliferation with three characteristics:
  - **persistent** growth
  - **unlimited growth**
  - high degree of biological **autonomy**
- ▶ The proliferating cells **can come from any tissue.**
  - the tumor will always have **tissue structure** and not the organ and may have different degrees of resemblance to the normal tissue of origin.
- ▶ Synonyms - **neoplasm** or **neoplasm** (neo = new, plasien = to form - newly formed "tissue mass").



Factors that can cause tumor development are called - carcinogens.

It is considered that 80% - 90% of human cancers result from the action of environmental factors through their mutagenic action.

Theories of carcinogenesis:

- T.C. Chemical
- T.C. Physicists
- T.C. viral



T.C. Chemicals - chemicals substances wit carcinogenic effect

- Polycyclic aromatic hydrocarbons (cigarette smoke - lung cancer)
- Azo dyes (aniline) in the rubber industry – carcinoma of urinary bladder
- Amines and aromatic amides (naphthylamine) - Metals (Co, Ni, Pb)
- Substances produced from plants and fungi (aspergillus flavus, aflatoxin B1 - liver Cr.)
- Immunodepressants (Cyclophosphomide)
- Asbestos - Lung Cr., pleural mesothelioma
- Arsenic - Skin Cr
- Hormones - estrogen
- Breast, endometrial CR.



In chemical carcinogenesis, the following are important:

- The dose and duration of the action of the chemical.
- The path of penetration into the body -
- The physico-chemical nature of the substances.



R.T. Physical: - ultraviolet rays - CR of skin or malignant melanomas located on the exposed parts of the sun  
- electromagnetic radiation - pulmonary CR in the mines from the mines with radioactive deposits  
- leukemias following the atomic explosion H. and N., CR of the thyroid gland (Chernobyl), treatment with radioactive isotopes.  
They induce mutations through the action on DNA



R.T. Viruses: Viruses that contain DNA

- HPV - cervical cancer - Epstein-Barr associated with Burkitt lymphoma, nasopharyngeal CR, B-cell lymphoma, Hodgkin lymphoma,

- Hepatitis B viruses, C.

Viruses containing RNA

- human T-cell lymphoma virus

# **Name of tumors**

- multiple names
- In general, tumors are referred to with the suffix “oma” - lipoma, myoma.
- Some tumors are called by the name of the organ where they developed, the name also indicating the cells from which they derive - hepatoma, meningioma.
- Some tumors are named after the authors who described them - Wilms tumor, Grawitz



# Classification of tumors

\* Biological evolution criterion:

- **benign tumors** - do not invade locally and do not give distant metastases

- **malignant tumors** - invade locally and give distant metastases

\* For differentiation:

- macroscopic aspects

- cytological and histological characters

- degree of influence of the organism

**SINGLE POSSIBILITY OF DIFFERENTIATION -  
PATHOLOGICAL DIAGNOSIS !!!!**

## Effects on the body

### Benign tumors

- changes induced by compression
- hormonal activity
- do not recur after complete surgical resection or even if recurrences do not destroy local tissues and are the consequence of incomplete excision.
- do not invade locally and do not give distant metastases (the risk of a tumor diagnosed as benign on morphopathological criteria to generate distant metastases is below 1 case in 50 000 tumors)
- examples - benign fibrous histiocytoma, chronic villonodular tenosynovitis



## Malignant tumors

- invades locally
- distant metastases (the risk of metastasis in sarcomas varies between 20 and 100%, depending on the tumor type)

## ■ Difficulties:

- Tumors that cannot be classified as benign or malignant until they give metastases: ex - pheochromocytoma
- ambiguous situations in which a tumor meets both malignancy and benignity criteria: "tumor with intermediate malignancy" or tumor with potential malignant borderline".



## Tumors with locally aggressive intermediate malignancy

- relapses locally after resection
- behaves aggressively against local tissues (they are infiltrative and cause local destruction)
- prototype - desmoid fibromatosis

# Tumors with intermediate malignancy with reduced risk of metastasis

- locally aggressive
- risk of distant metastasis in less than 2% of cases
- prototype - angiomatoid fibrous histiocyoma



# *Macroscopic characters of **benign tumors**:*

- very common and ubiquitous
- they have a tissue mass appearance in the development territory
- they do not invade the surrounding tissues
- well delimited, sometimes encapsulated (easy to remove).

■ Macroscopic aspects:

**polyp** - benign tumor developed from the surface epithelia (skin, mucous membranes)

- vegetation with wide implantation base (sessile tumor)

- attached to the surface through a pedicle through which the blood vessels (pedicle tumor) penetrate.

**Node** - benign tumor developed in different tissues and organs - appearance of spherical nodule, compact, with distinct boundaries or capsule

**Cyst**- some deep tumors



- Dimensions: small (from a few mm to a few cm - slow growth rate); some benign tumors can reach important dimensions - of the order of tens of cm - papillary cystadenoma of the ovary, neurofibroma
- Number: usually single but can be multiple, developed simultaneously or in succession (colorectal polyps)

## *Microscopic characters*

Tumor tissue, both benign and malignant, is composed of two components: the **tumor parenchyma** (made up of tumor cells) **tumor stroma** (made up of connective tissue with blood vessels).



## *Microscopic characters of **benign tumors***

\* Benign tumors reproduce the structure of the origin tissue - multilayered epithelium, glandular epithelium, muscle tissue, adipose tissue, hyaline cartilage etc.

\* Benign tumor cells

- they are differentiated

- have cytological characteristics similar to normal cells

- they retain the function of normal cells

(mucus secretion, horny maturation capacity, hormone secretion, etc.).

- Rare and typical mitosis.

- \* The tumor stroma consists of connective tissue, blood vessels and nerve trunks.
- \* Balance between tumor cell proliferation and stroma → no necrosis occurs



## *Evolutionary characters of **benign tumors***

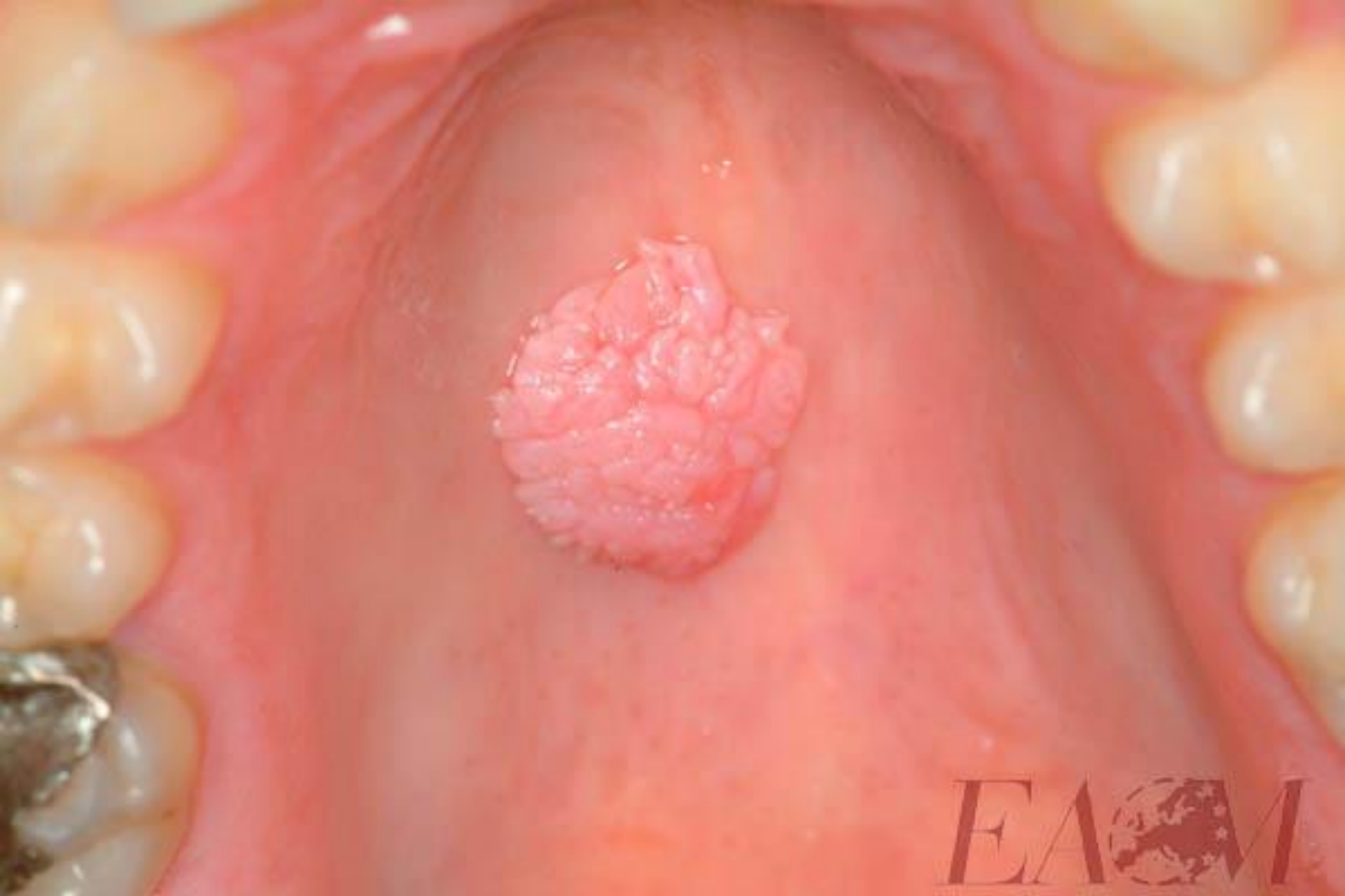- they evolve locally
- they don't invade surrounding tissues
- they don't give metastases
- they don't recur after complete surgical removal.
- does not influence the general state of the body.

### **Exceptions:**

Voluminous benign tumors cause local compression

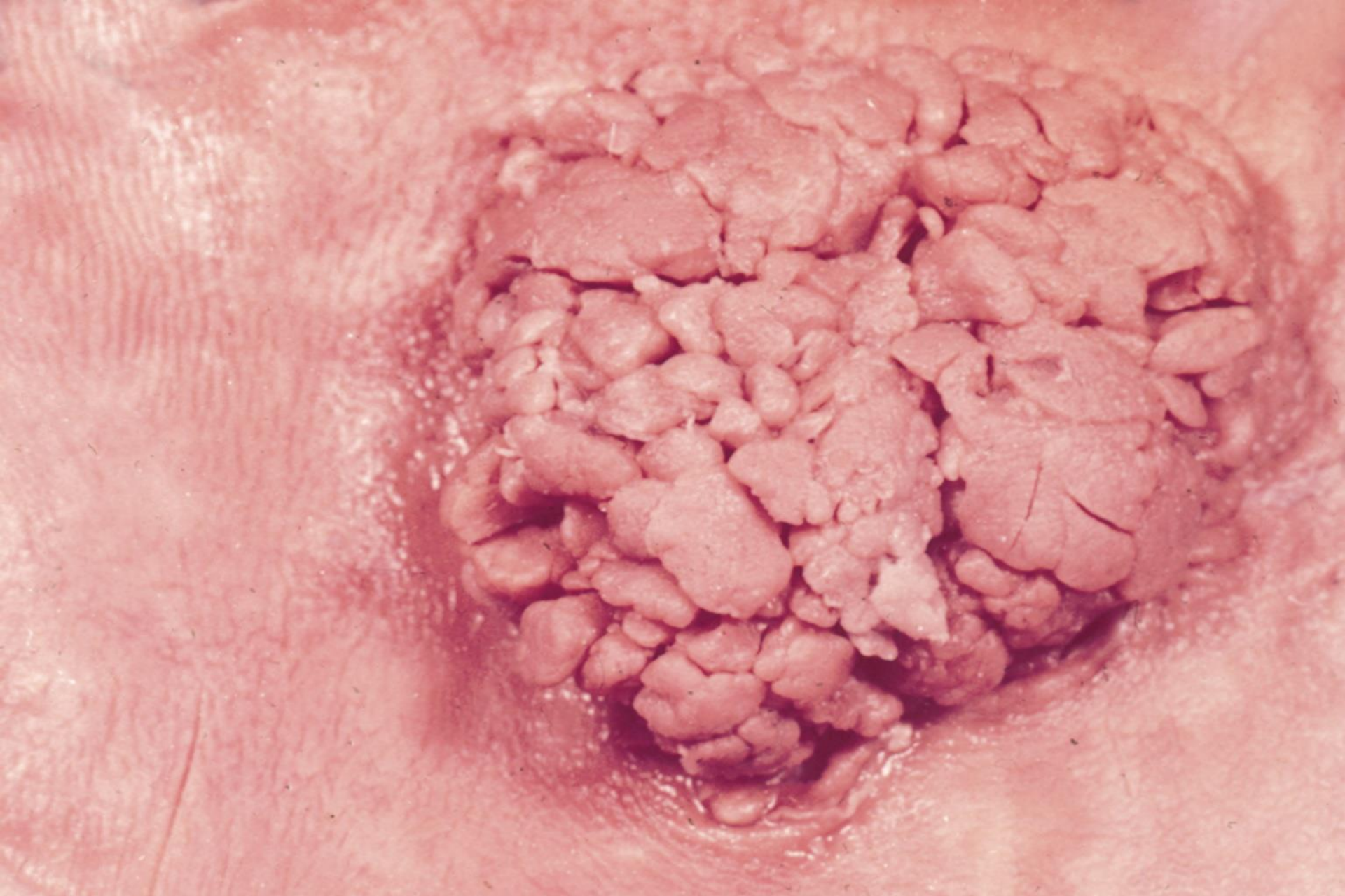- a large tumor of the uterine muscles that compresses the pelvic organs and determines urinary stasis
- the benign tumor of the meninges compresses the cerebral cortex

Benign tumors of the endocrine glands may have specific hormonal activity, which causes endocrine dysfunction.



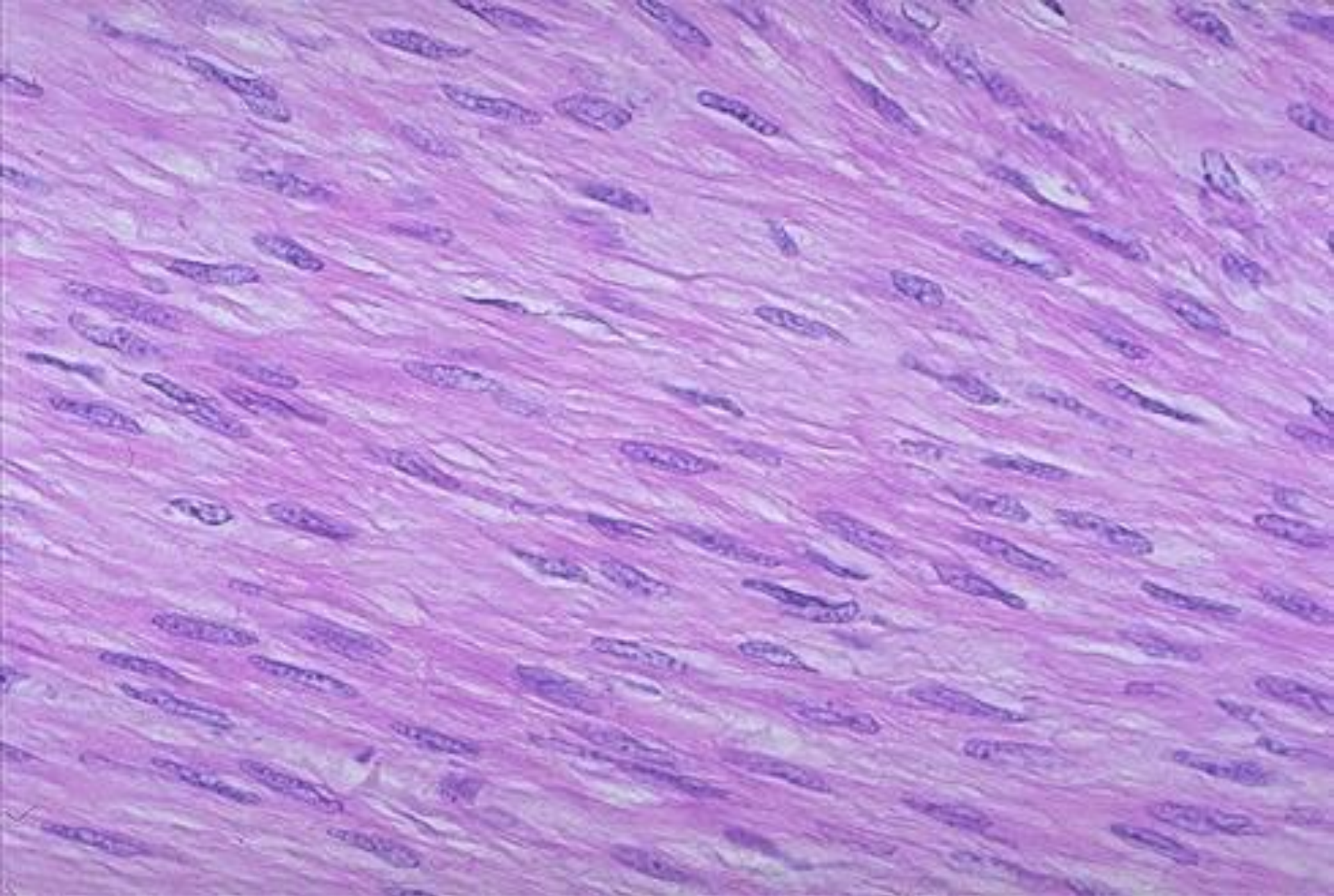
Papiloma of oral cavity





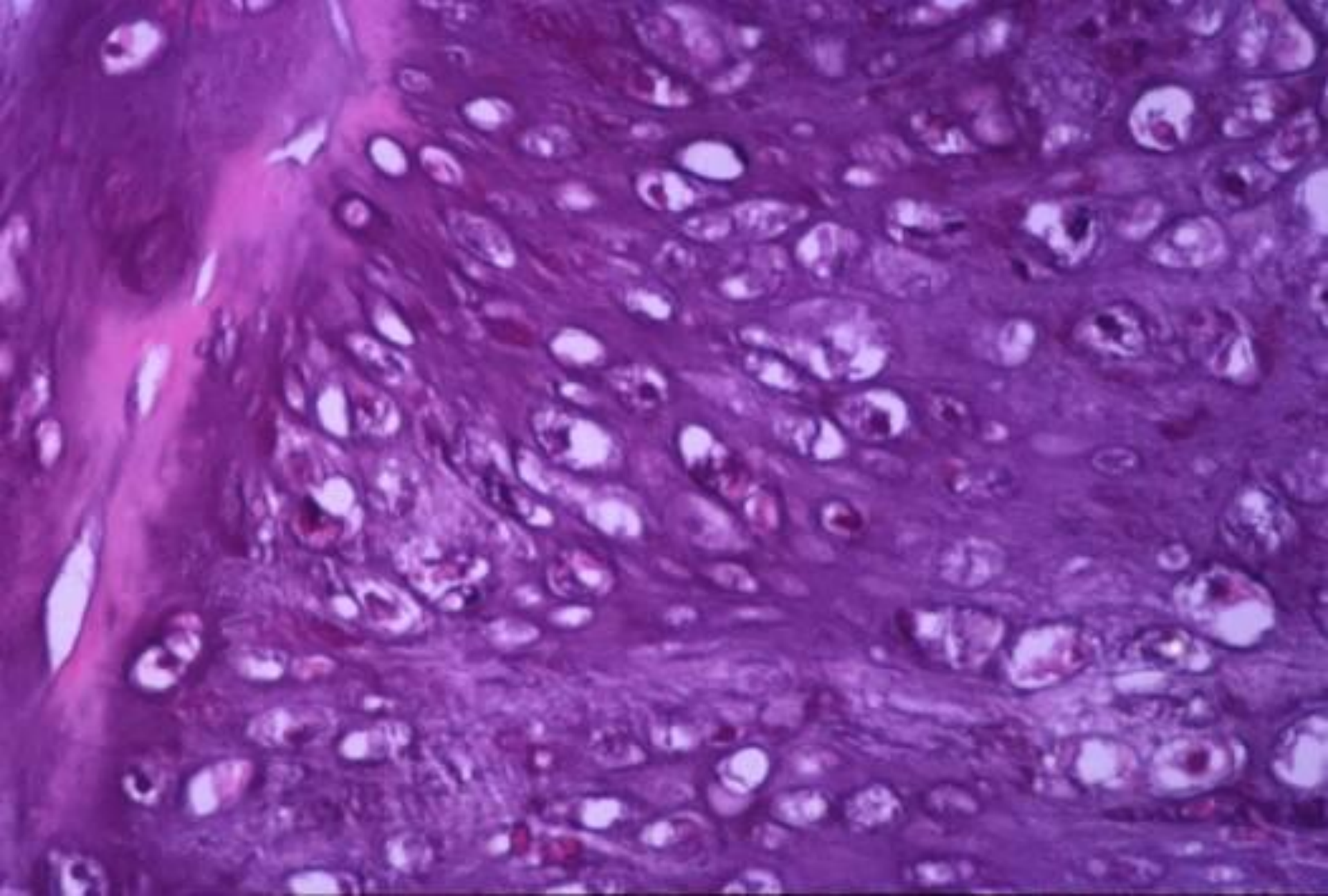
Papilom of thw skin





Leiomyoma





Chondroma

## *Macroscopic characters of malignant tumors*

- tissue mass without distinct boundaries
- local invasive character
- Possible: distinct malignant tumors macroscopically but without capsule (cancer with false encapsulation) - areas of necrosis in the tumor mass.
  - \* In tumors externalized to the surface of the skin or mucous membranes the area of necrosis is eliminated, resulting in ulcerations.
  - \* In deep tumors, central liquefaction leads to the formation of cavities, mimicking a cavern - possibly, if the tumor invades a conduit - for example a bronchial branch - the liquefied necrotic content can be eliminated resulting in a cavity (cavitation phenomenon).
- large size - fast growth rate.
- the color and consistency depend on the histopathological type.



## *Microscopic characters of malignant tumors*

Tumor parenchyma: Cancer cells are different from normal ones through a whole set of changes in cell character, nucleus, cytoplasm and nuclear membrane = cytological malignancy criteria:

- Anomalies of shape and size
- Nuclear anomalies
- Cytoplasmic abnormalities
- Cellular membrane abnormalities
- The arrangement of the tumor cells is different from the normal one:
  - architectural changes

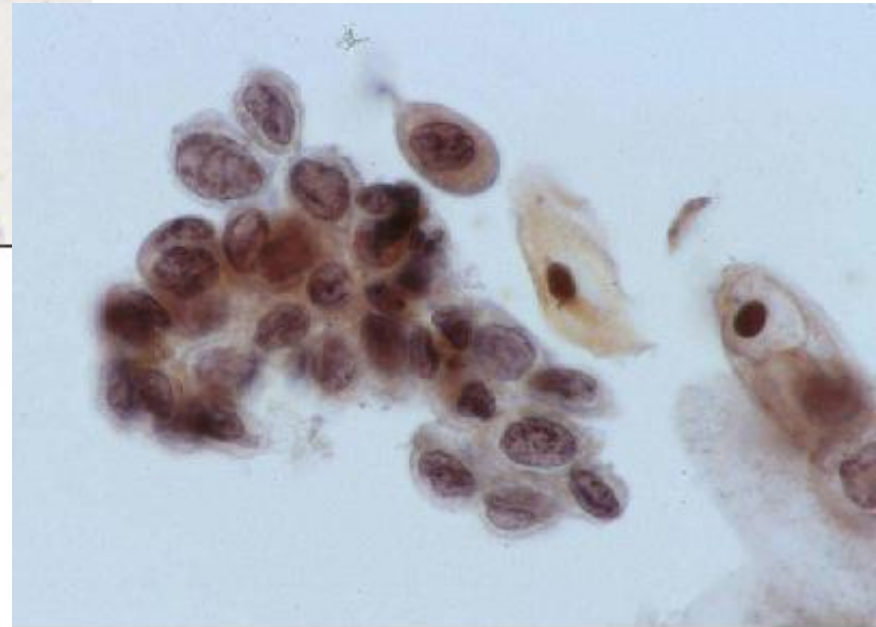
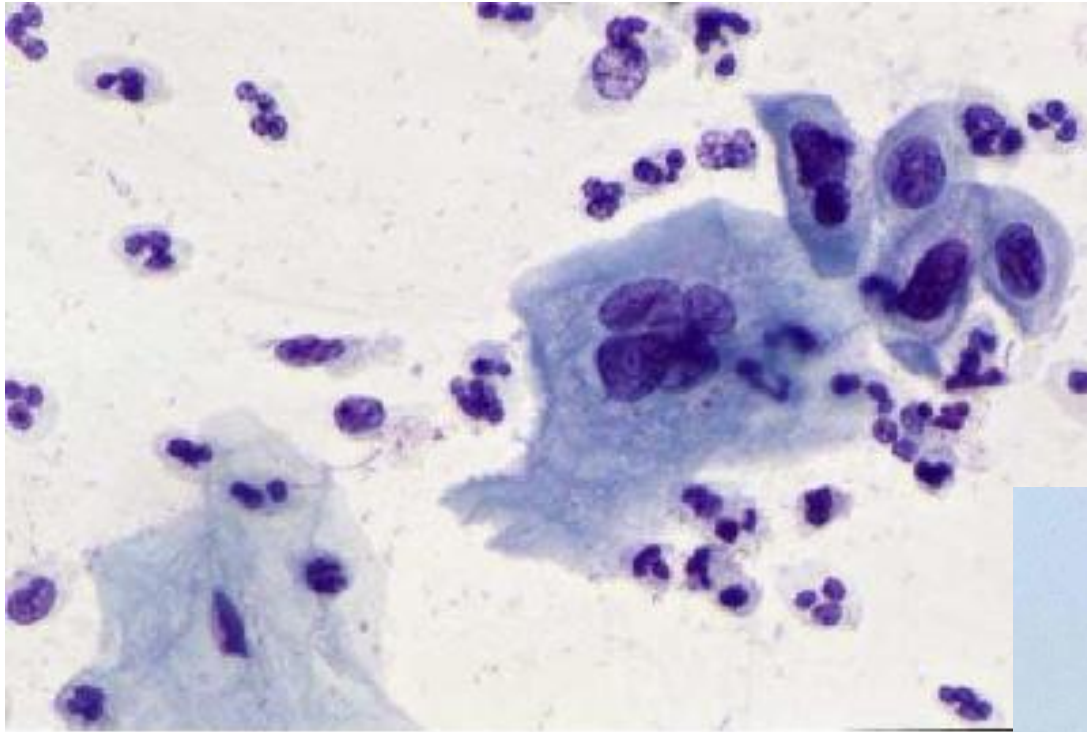
# **Cytological criteria for malignancy**

## ***Form and size abnormalities:***

The appearance of cancer cells varies from small, uniform, to large, round, oval or elongated cells, sometimes monstrous (cellular pleomorphism).



Pleomorphism: variation in size and shape



## ■ **Abnormalities of the cell membrane**

The membrane of the cancer cell shows changes in the chemical composition, changes that influence the behavior of the cancer cell against the normal cell, both in vivo and in vitro. In the membrane the glycoprotein and glycolipid fractions are reduced (these changes being due to the blocking of synthesis).



## ■ Cytoplasmic abnormalities

In cancer cells the cytoplasm is reduced quantitatively (a situation that contributes to the increase of the nucleo-cytoplasmic ratio. The cytoplasm of the malignant cells is more basophilic than normal due to the presence in the cytoplasm of numerous ribosomes (containing RNA - so nucleic acid that stains with hem). In the cytoplasm, accumulations of glycogen, lipids, monoclonal immunoglobulins, mucus - depending on the type of cell of origin - mucus retention determines the peripheral displacement of the nucleus, giving the cell the appearance of a "ring with seals".

■ **Nuclear anomalies** most suggestive for malignancy - anisocarrria (carios = nucleus, isos = identical, an = no) - dimensional inequalities; they will always be larger than the cells of origin, in some cases leading to the inversion of the nucleo-cytoplasmic ratio in favor of the nucleus.

- Hyperchromatosis - color more intense than normal - high affinity to the basic dyes

- nuclear pleomorphism - the shape of the nuclei is variable

- there may be multinucleated tumor cells

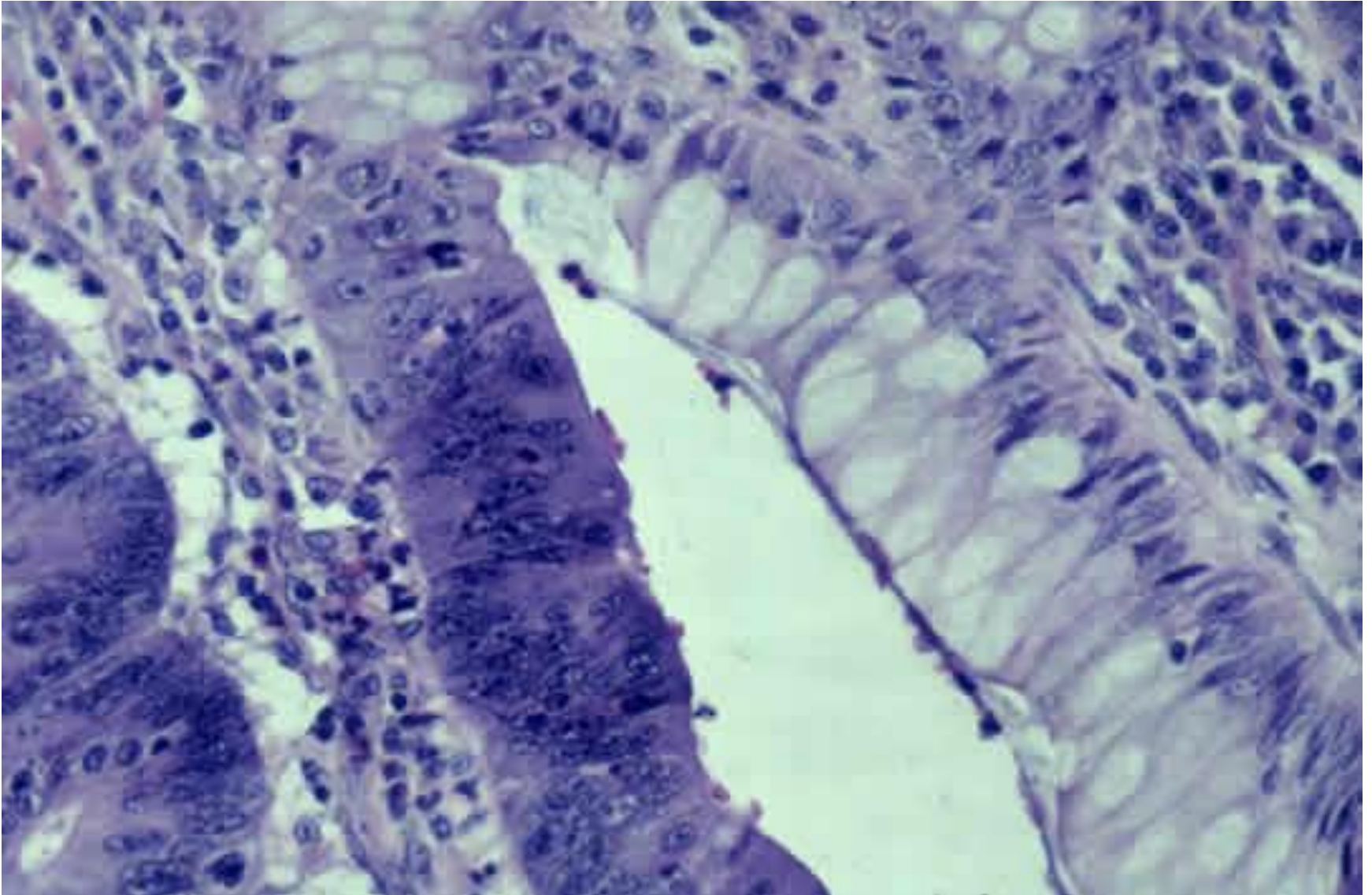
- The nucleoli of cancer cells, due to their very active cellular metabolism, are hypertrophied, vesicular, multiple, sometimes with anomalies - pseudovesicular, fibrillary or granular inclusions.

- The mitotic index is higher than in normal cells: Typical bipolar mitosis  
Atypical mitosis.

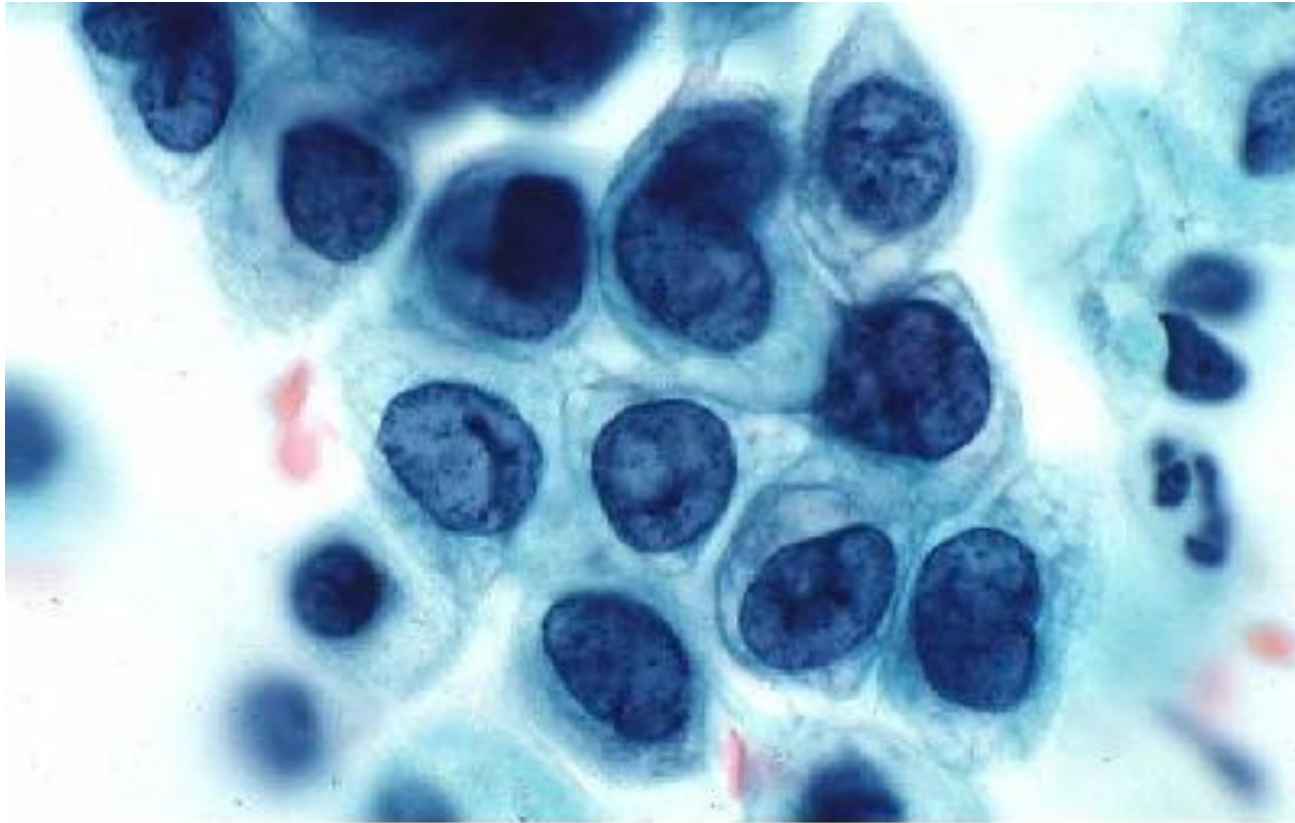
**NOTE:** the presence of typical mitosis, even in large numbers, can be detected in normal tissues (for example, hematogenous bone marrow) or in hyperplastic processes; the presence of atypical mitosis is reported only in malignancies.



## Loss of polarity

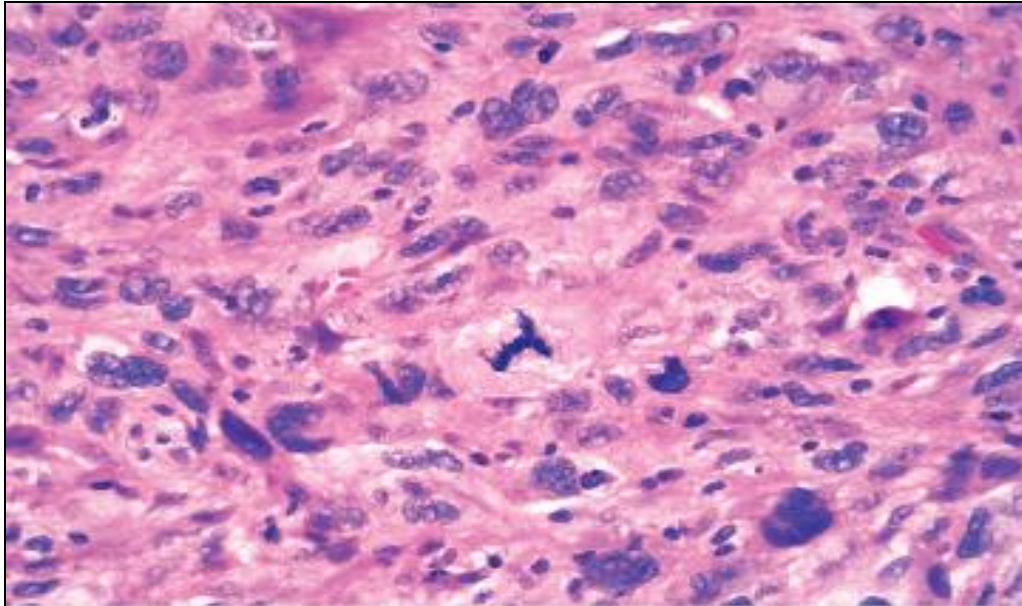


**Abnormal nuclear morphology: hyperchromatic (abundant DNA), increased N:C ratio (normal 1:4-1:6)**

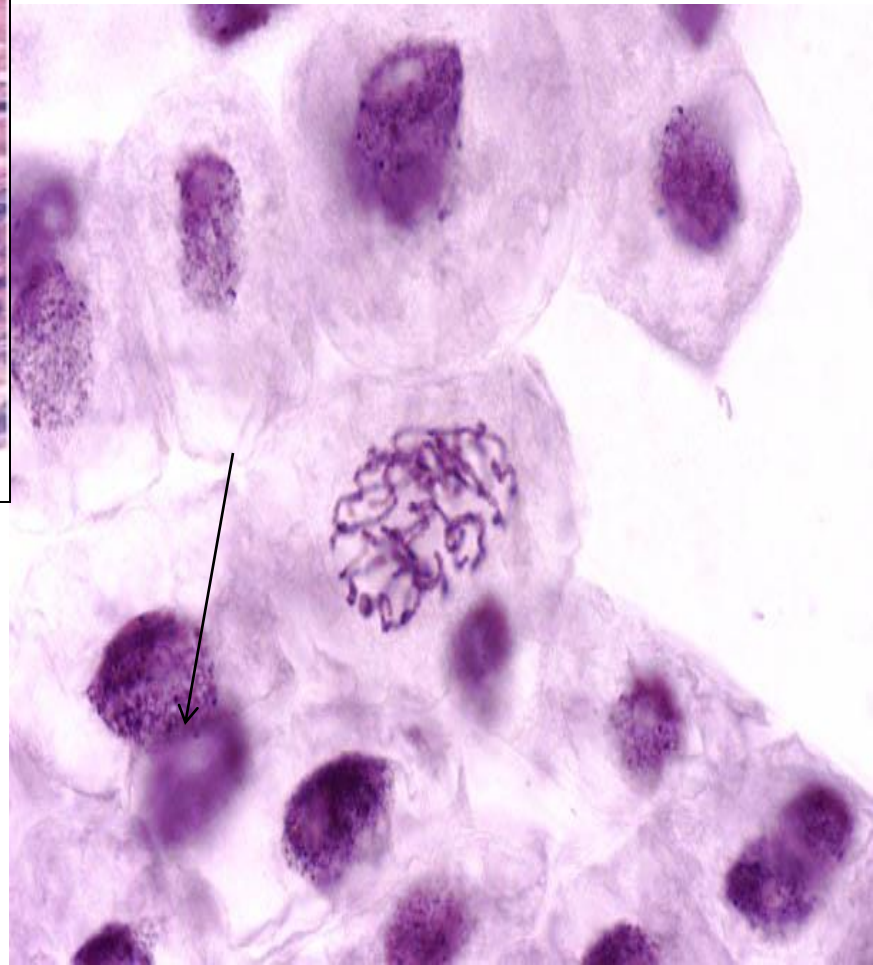




## Mitosis: multiple, bizarre



© Elsevier 2005



# **Malignant tumor stroma**

- is formed as a result of the interaction between cancer cells and normal tissues of the host organism.
- consists of common connective tissue, consisting of blood and lymphatic vessels
- The vascularization of the tumor is provided by the connective stroma which is connected to the arteriovenous pedicle of the tumor tissue. Tumor vessels consist exclusively of capillary networks and arteriovenous venous anastomoses that favor circulatory shunts.



- **Tumor angiogenesis** is precocious and conditions the proliferation of cancer cells. It is stimulated by angiogenic factors secreted by cancer cells.
  - In malignant tumors the stroma is insufficient compared to the degree of proliferation → necrosis
  - The treatment may target angiogenic factors - the conjunctival stroma varies quantitatively
    - \* well developed in tumors of epithelial nature and lower in those of conjunctive nature
    - \* reduced stroma - the consistency of the tissue is reduced and areas of necrosis and haemorrhages that are explained by the fragility of the capillary vessels in the composition of the tumor or vascular obstruction with consecutive ischemic necrosis occur frequently.
    - \* abundant fibrous conjunctival stroma - desmoplasia → hard, woody consistency (squirrel cancer).

■ **Microscopically**, the conjunctival stroma presents variable aspects.

- In most cases it is accompanied by inflammatory reactions to cancer cells (stromal reaction); infiltrates may be neutrophils, lymphocytes, plasmocytes, macrophages.

- Sometimes eosinophilic infiltrate (eosinophilic stroma) predominates.

- In the stroma, a granulomatous inflammatory reaction of the tuberculoid type can sometimes be highlighted.

The stroma can be reshaped by the type found in the common connective tissue: hyalinization, elastogenesis, amyloid accumulation, calcifications.



## Differentiation and anaplasia

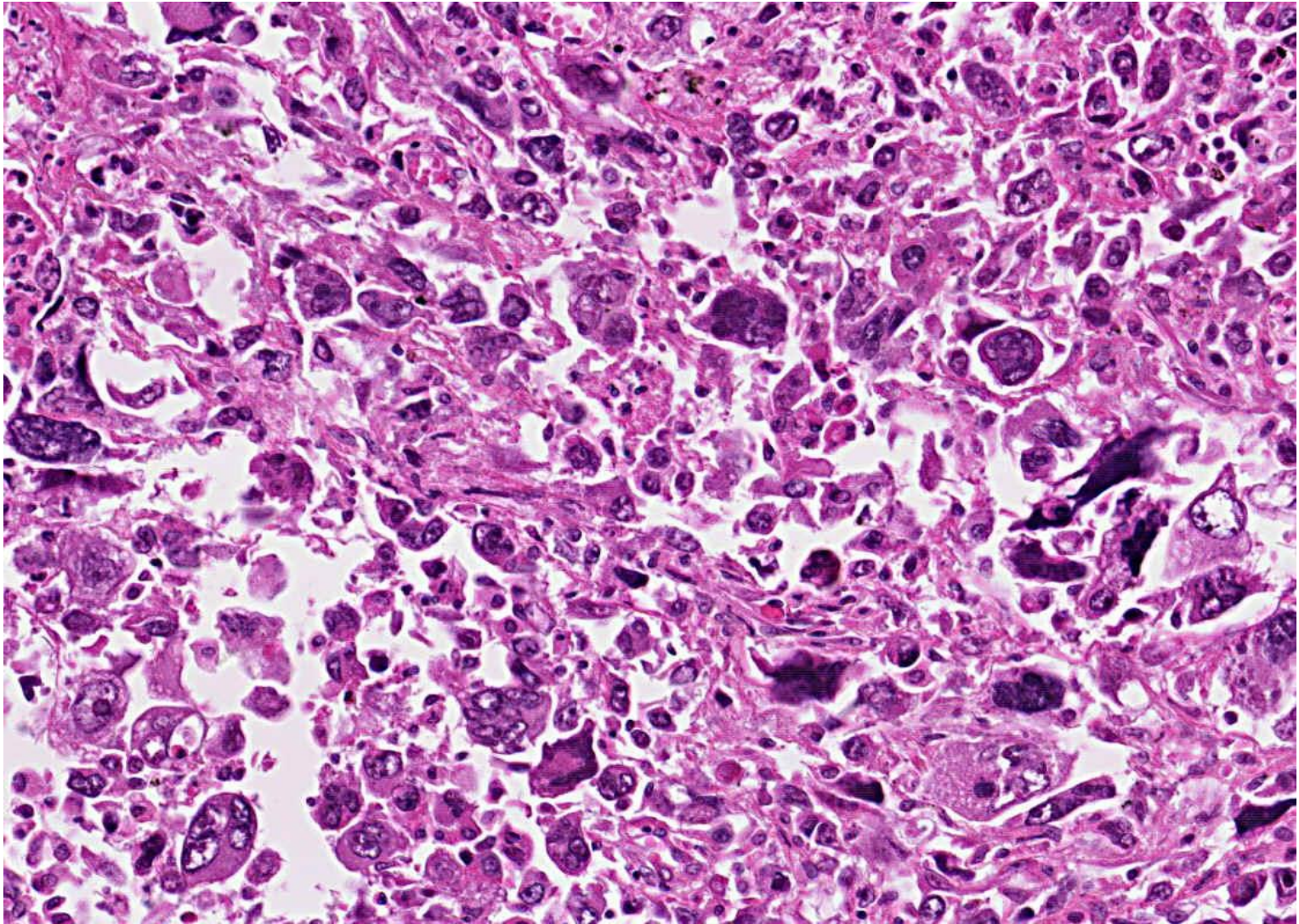
- Differentiation is appreciated by comparing the resemblance with the origin tissue (cancer is differentiated when the histological characters resemble the origin tissue and undifferentiated when it loses any resemblance to the origin tissue).
- The assessment of the degree of microscopic differentiation of the cancer has value for diagnosis (in the assessment of prognosis and evolution).
- Differentiated cancer - the histological diagnostic criteria concern the organization of the tumor tissue (architecture - in tubular, cordal structures, etc.) and the functional characters (presence of mucus secretion, immunoglobulins, horny differentiation, etc.).

Tumor architecture and cytologic characters suggest the origin of tumor proliferation.

- Undifferentiated cancer - tumor tissue has a compact architecture - thick beaches and trabeculae. Cancer cells are immature, sometimes embryonic in nature, with no evidence to suggest the source cell. The origin of the tumor is difficult to determine by optical microscopy and requires immunohistochemical examinations (to determine the presence of certain antigens - for example cytokeratins in carcinomas, melanocyte antigen HMB 45 in malignant melanomas etc.).
  - Anaplasia (lack of differentiation) is considered to be the basic feature of malignant transformation.



# Anaplasia



- **Anaplasia** must be separated by differentiation - cancers originate in stem cells (present in all specialized tissues) - transformed stem cells that proliferate by differentiating more (differentiated cancers) or less or even (non-differentiated cancers). Differentiation involves cell regression from a mature cell to a less mature one.
  - Anaplasia is inversely proportional to the differentiation - the more a tumor is differentiated, the lower the anaplasia degreeThe degree of anaplasia is noted with G and varies from 1 to 4



## Local invasion

- the ability of cancer cells to progressively penetrate and replace normal peritumoral tissues.
- it is accompanied by the simultaneous development of the stroma, an element necessary for the growth of the tumor tissue.
- it is favored by the
  - \* increased rate of cancer cell multiplication.
  - \* ability to mobilize cancer cells
  - \* secretion of enzymes with cytosolic and histolytic action by cancer cells.
- it is made through the interstitial spaces, preformed cavities, along the nerve trunks, of the small blood and lymphatic vessels.
- They resist the invasion of hard tissues (bone tissue, cartilaginous tissue) and large arteries (they are more resistant than large veins due to the large amount of elastic tissue and the presence in the arterial walls of some tumor protease inhibitors).

## *Malignant Tumor Dissemination*

- Leads to Metastasis Formation
- Metastases are secondary tumors, an effect of disseminating cancer cells away from the primary tumor.
- The occurrence of metastases transforms localized cancer into a systemic disease, metastases being more frequently the cause of death than the primary tumor.
- Pathways of metastasis:
  - lymphatic
  - hematogenous
  - mixed (lympho-hematogenous)
  - transcelomic
  - natural pipes



# *Effects of malignant tumors on the body*

## *Direct complications*

- Bleeding - common in surface cancers. They can be abundant and repeated in vegetative cancer. They can be massive in ulcerated cancer (stomach, cervix).

- **compression**, for example - mechanical jaundice by compression of the bile ducts (pancreatic head cancer), atrophy of the cortico-adrenal by compression by a retroperitoneal tumor

- **Obstructions and stenoses** in the cancers of the organs of the cavity - esophageal cancer (dysphagia), colon cancer (subocclusion, occlusion)

- **Cancerous cachexia** - metabolic factors and polypeptide substances with inhibitory action of normal cellular metabolism.

## ■ Indirect complications

- paraneoplastic syndromes: secretion of ectopic hormones
- haematological repercussions: leukocyte abnormalities (leukopenia, leukemoid leukocytosis, eosinophilia - over 10%), venous thrombosis
- infections associated with malignant tumors
- fever: non-tumoral resorption



## General characteristic of tumors

Criterion	Benign tumors	Malignant tumors	Tumors with locally destructive growth
Growth rate	Slow	Rapid	Slow
Degree of differentiation of tumor cells	Mature, differentiated cells	Immature, undifferentiated cells	Mature, differentiated cells
Atypism	Tissular	Tissue, cellular (ultrastructural, biochemical, histochemical, antigenic)	Tissular
Growth character towards adjacent tissues	Expansive	Infiltrative (invasive)	Infiltrative
Tumor boundaries	Clear, precise (encapsulated)	Blurred, unclear	Blurred, unclear
Metastasis	No metastasis	Metastasis	No metastasis
Recurrence	No relapse	Relapse	Relapse
Clinical, morphological evolution	Can turn malignant	Cannot turn benign	Can turn malignant

## TNM coding

- The therapy and prognosis of malignancies depend on the location and degree of tumor extension.
- In order to establish the degree of tumor extension, it was necessary to develop standardization systems with practical utility.
- The TNM system is the most widely used in the clinic.

It responds to two major objectives. In the individual case of the cancer patient it allows the evaluation of the tumor extension by clinical and paraclinical methods - TMN establishes groups of homogeneous cases for the evolutionary assessment under the action of the treatment.

- In the TNM system are considered - the local extension of the T tumor (depending on the affected organ, the criteria of appreciation differ - dimensions - breast cancer, invasion in the thickness of the wall of the tubular organs - gastric, colonic, urinary bladder, invasion in different segments of of the uterus - cervical cancer etc.)
  - presence of lymphoganglionic metastases - N
  - presence of distant metastases (other than lymphoganglionic) - M



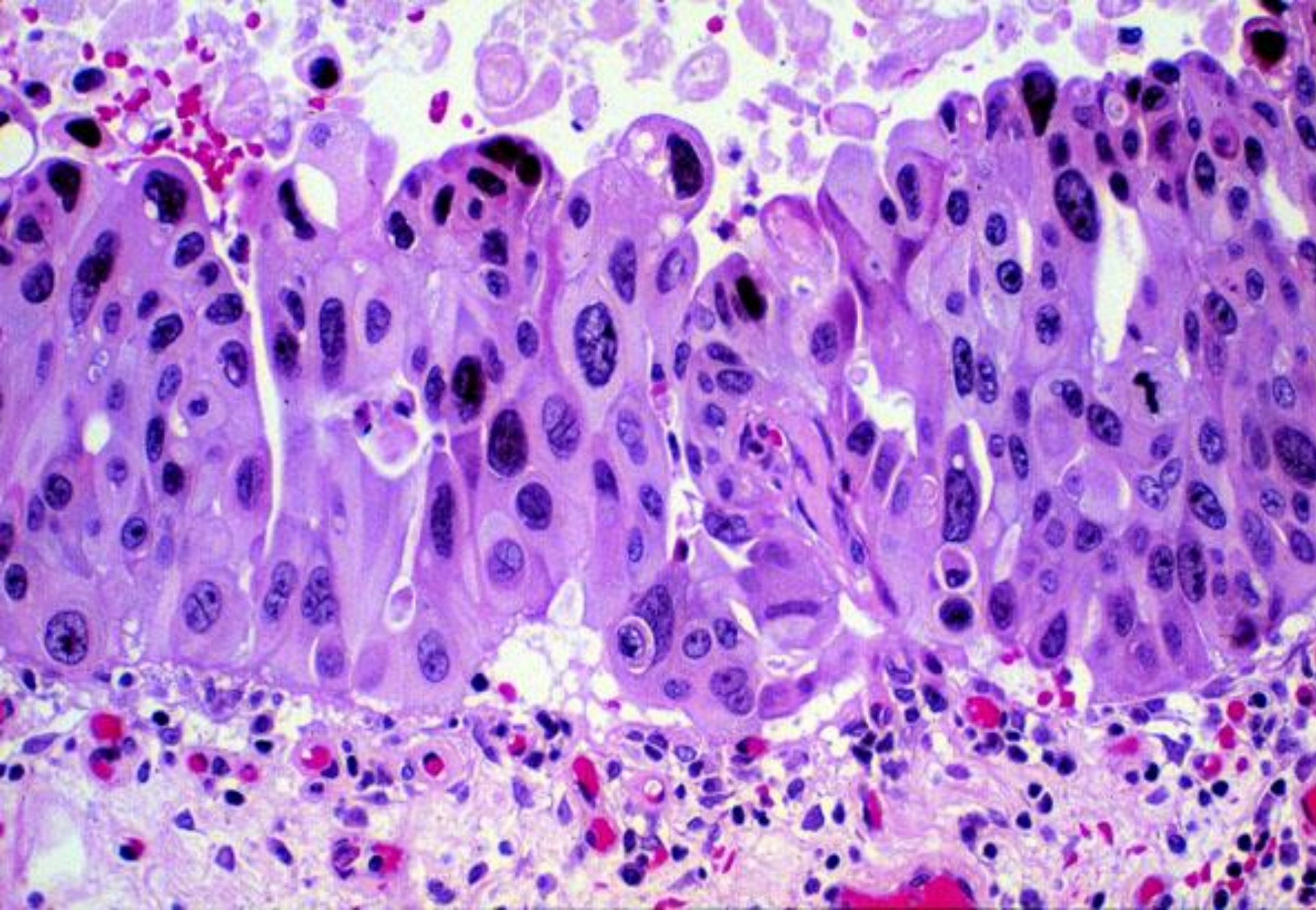
■ To these 3 letters add numbers and / or additional letters that define a certain type of extension.

For the primary tumor (T):  
the coding varies from T1 to T4; the criteria of appreciation differ depending on the body affected. T0 encoding is used when the primary tumor could not be detected, Tx when the tumor is present but Tis cannot be classified for in situ carcinoma.

- For the regional lymphoganglions  
N0 means the absence of metastases,  
N1 - N3 indicates the presence of metastases  
(depending on the number and location of the  
affected lymph nodes).  
Nx - the condition of the lymph nodes cannot  
be appreciated due to the anatomical position.  
For distant metastases  
M0 = absence of metastases, M1 or  
sometimes M2 their presence, Mx =  
metastases impossible to appreciate.

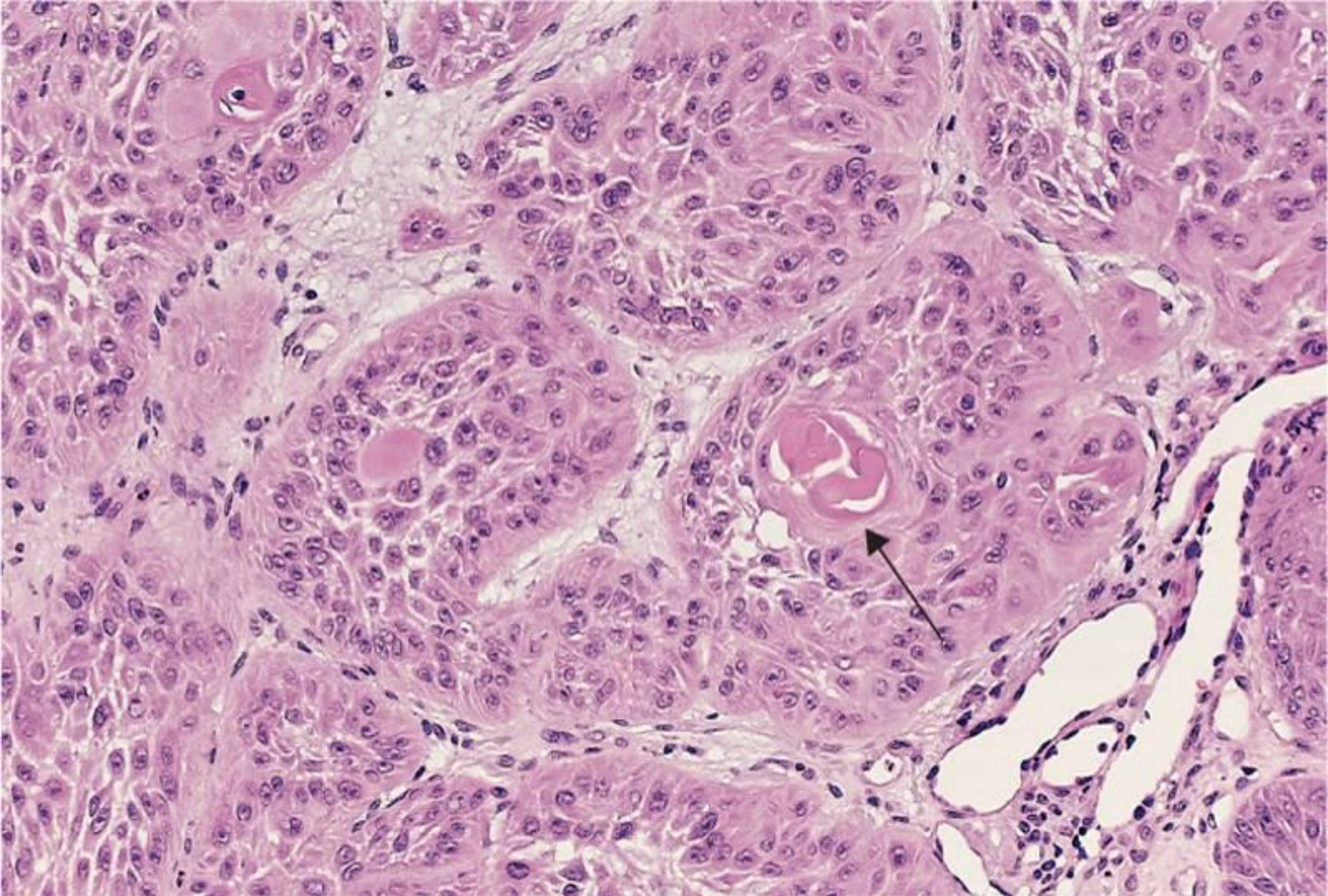
Depending on the TNM grades, each patient is individually included in a "stage" category numbered from I to IV. For example, for any T1N0M0 organ represents stage I, whereas any T1N0M1 represents stage IV.





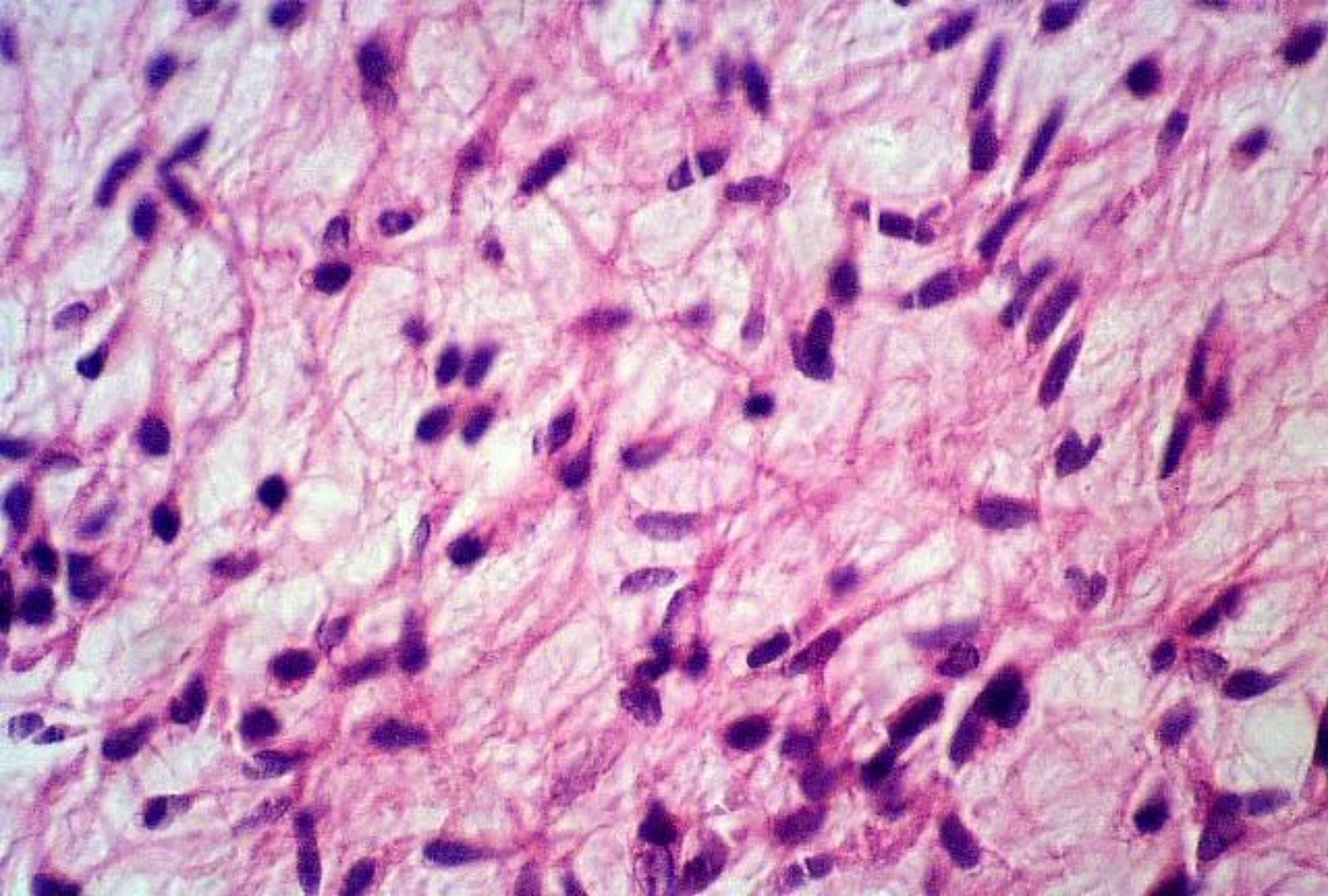
Carcinoma *in situ*. (H-E).





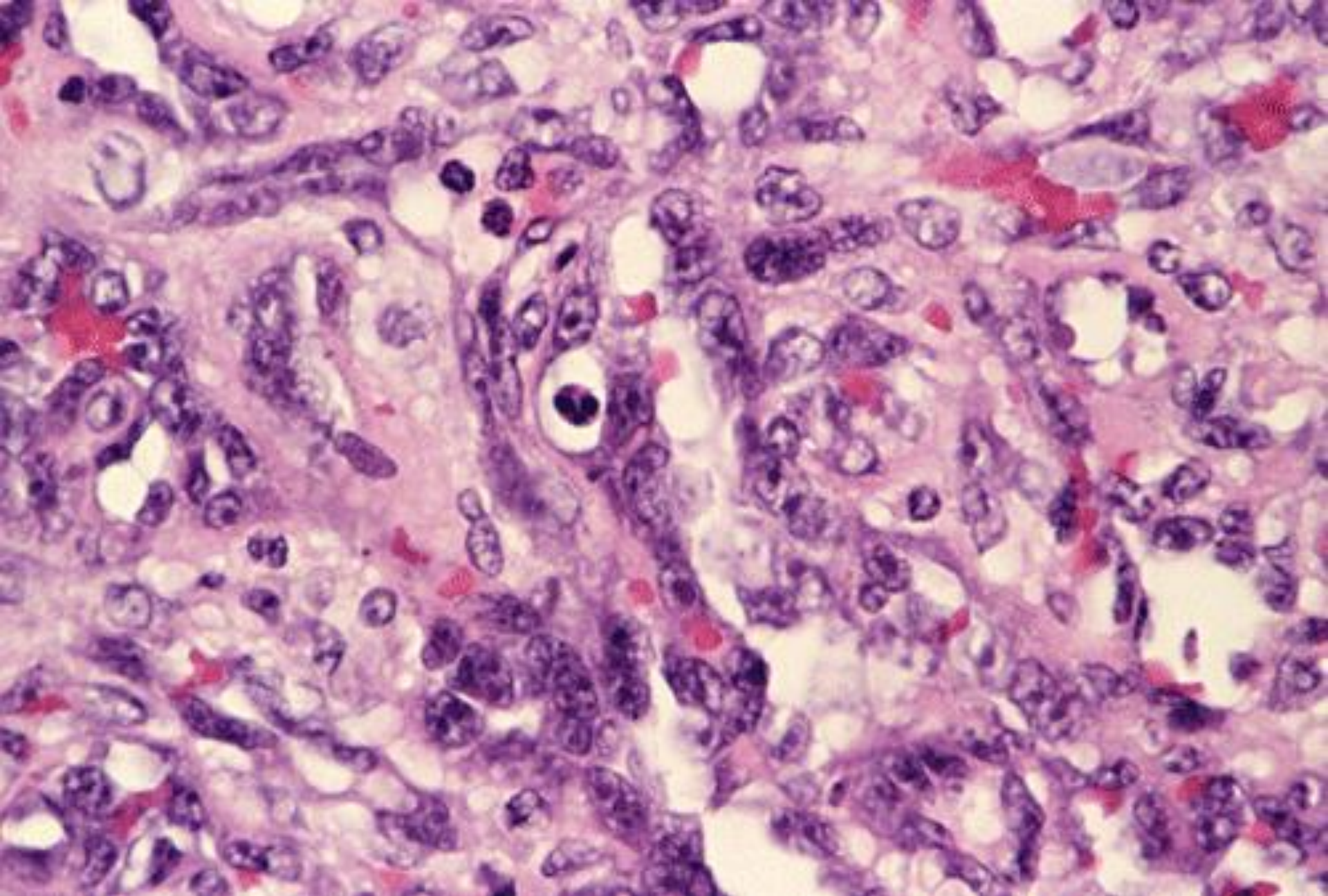
Keratinized squamous cell carcinoma





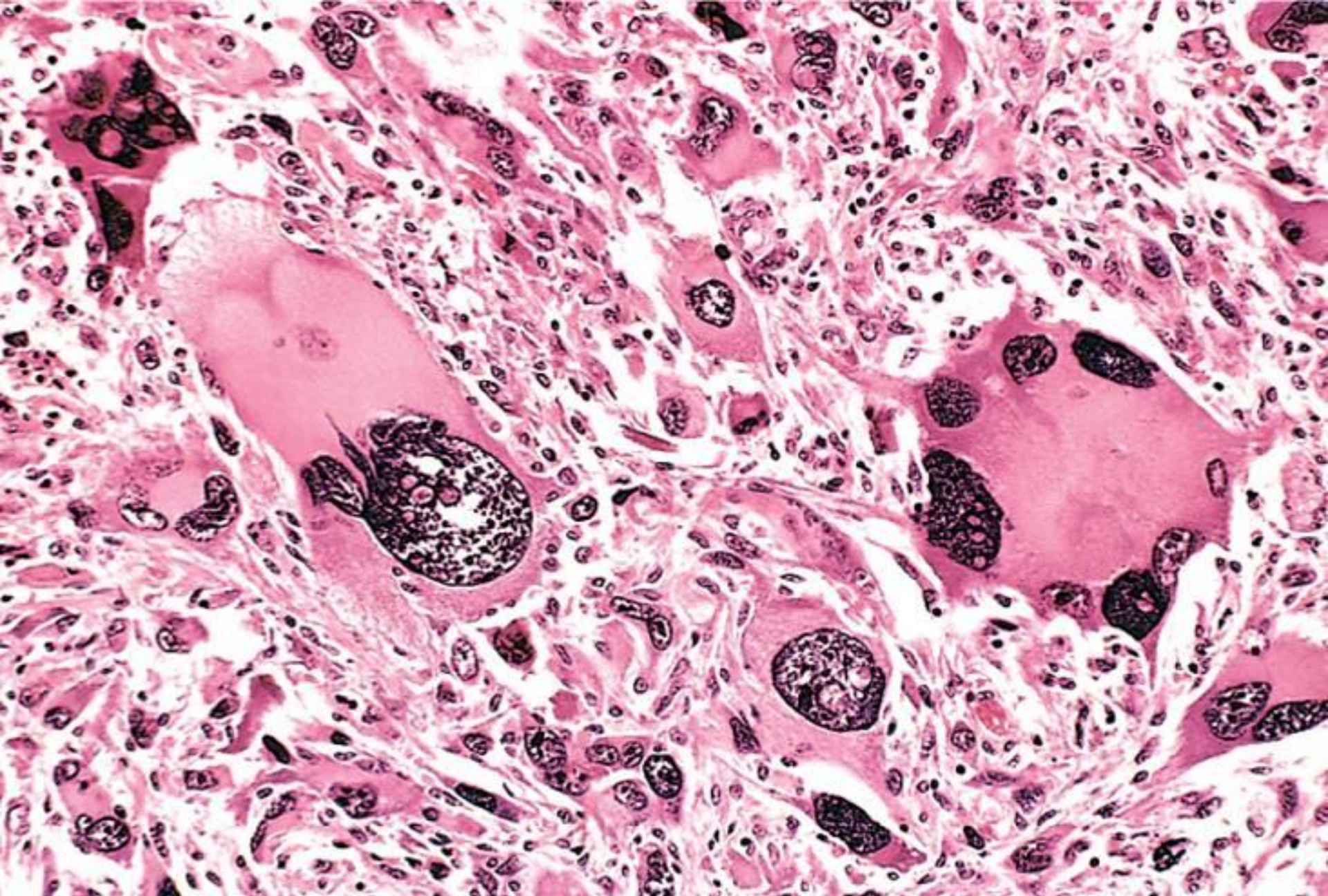
Chondrosarcoma





Angiosarcoma





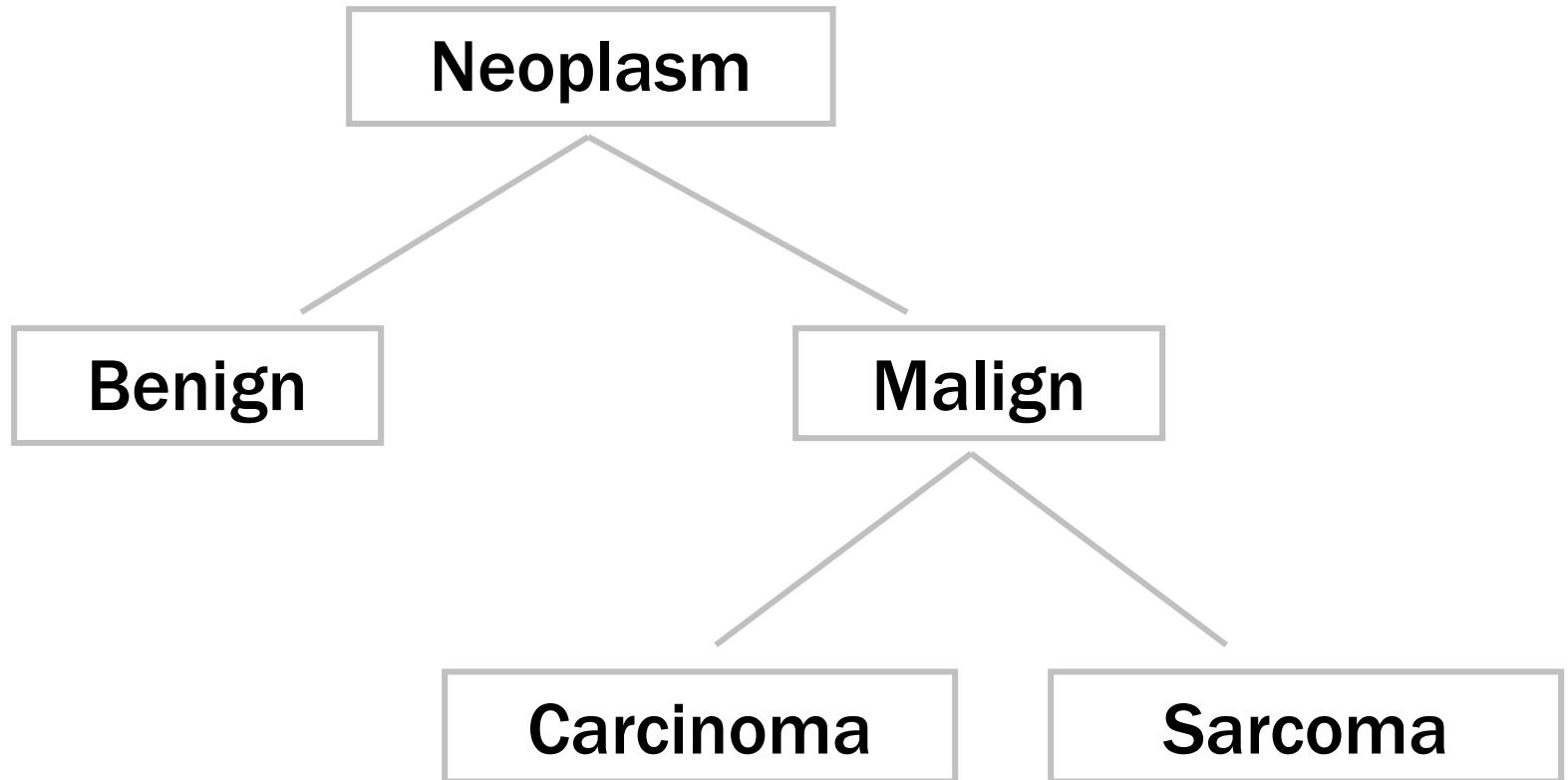
Rabdmiosarcoma



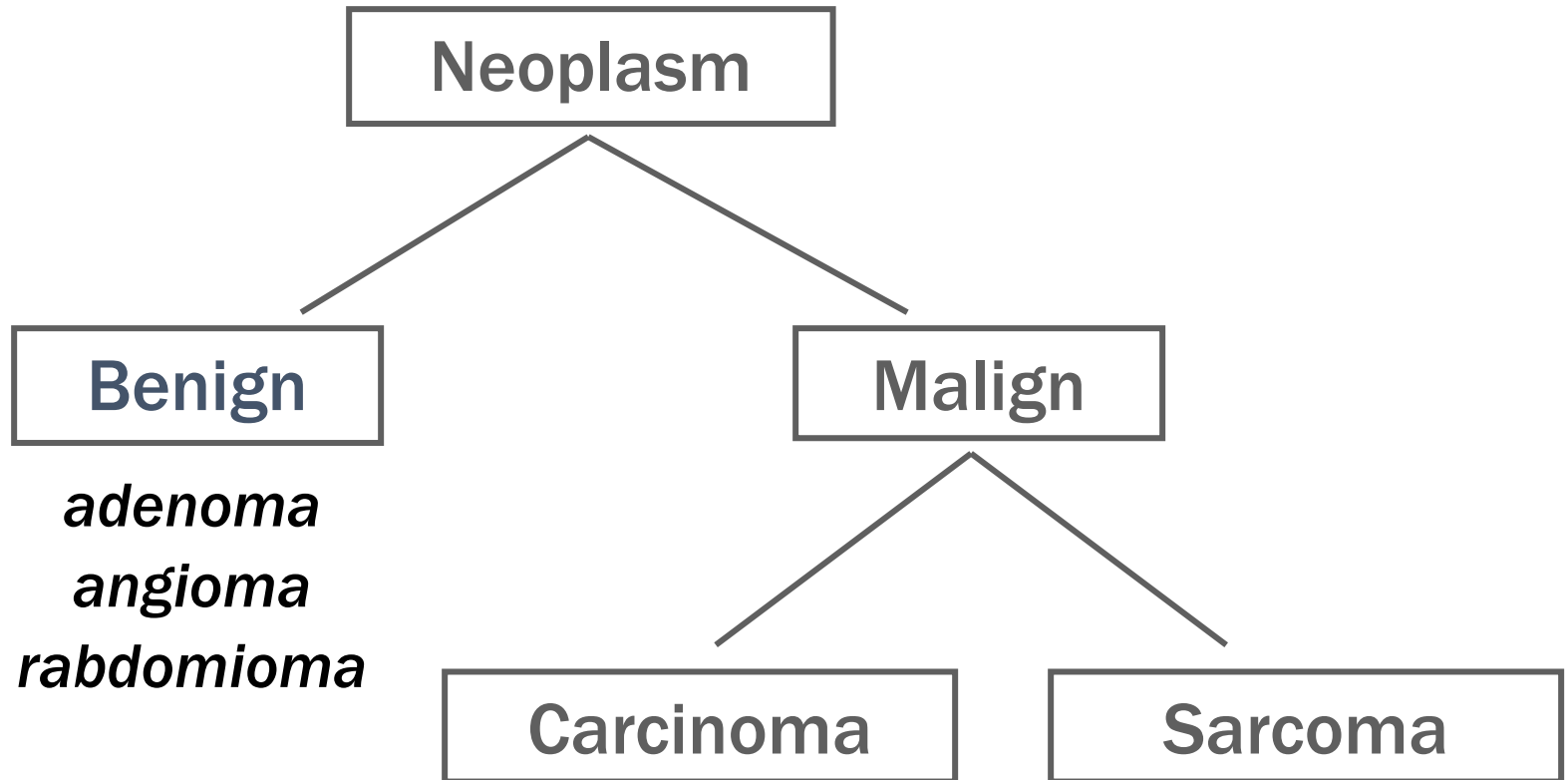




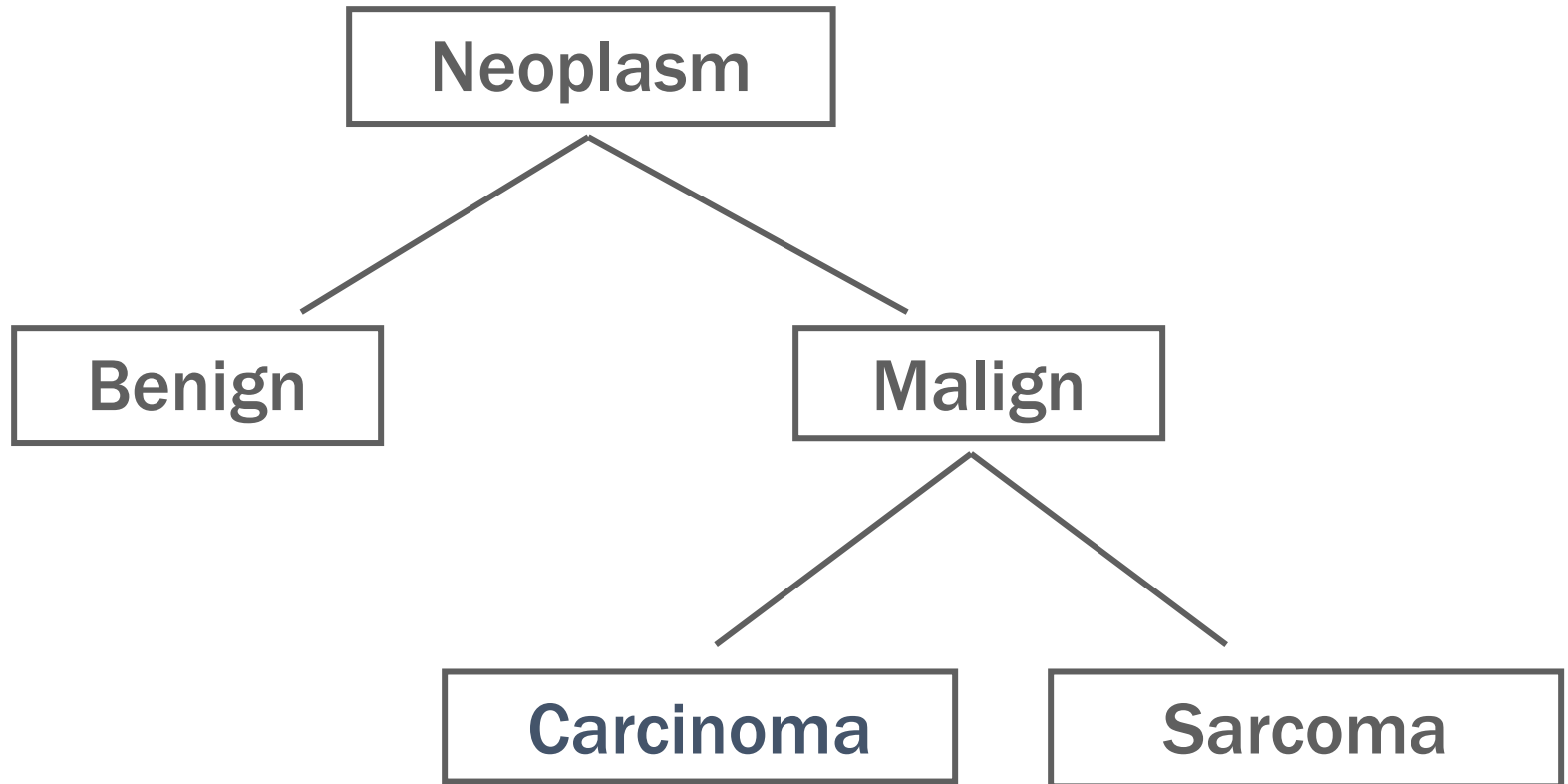
# Nomenclature



# Nomenclature



# Nomenclature

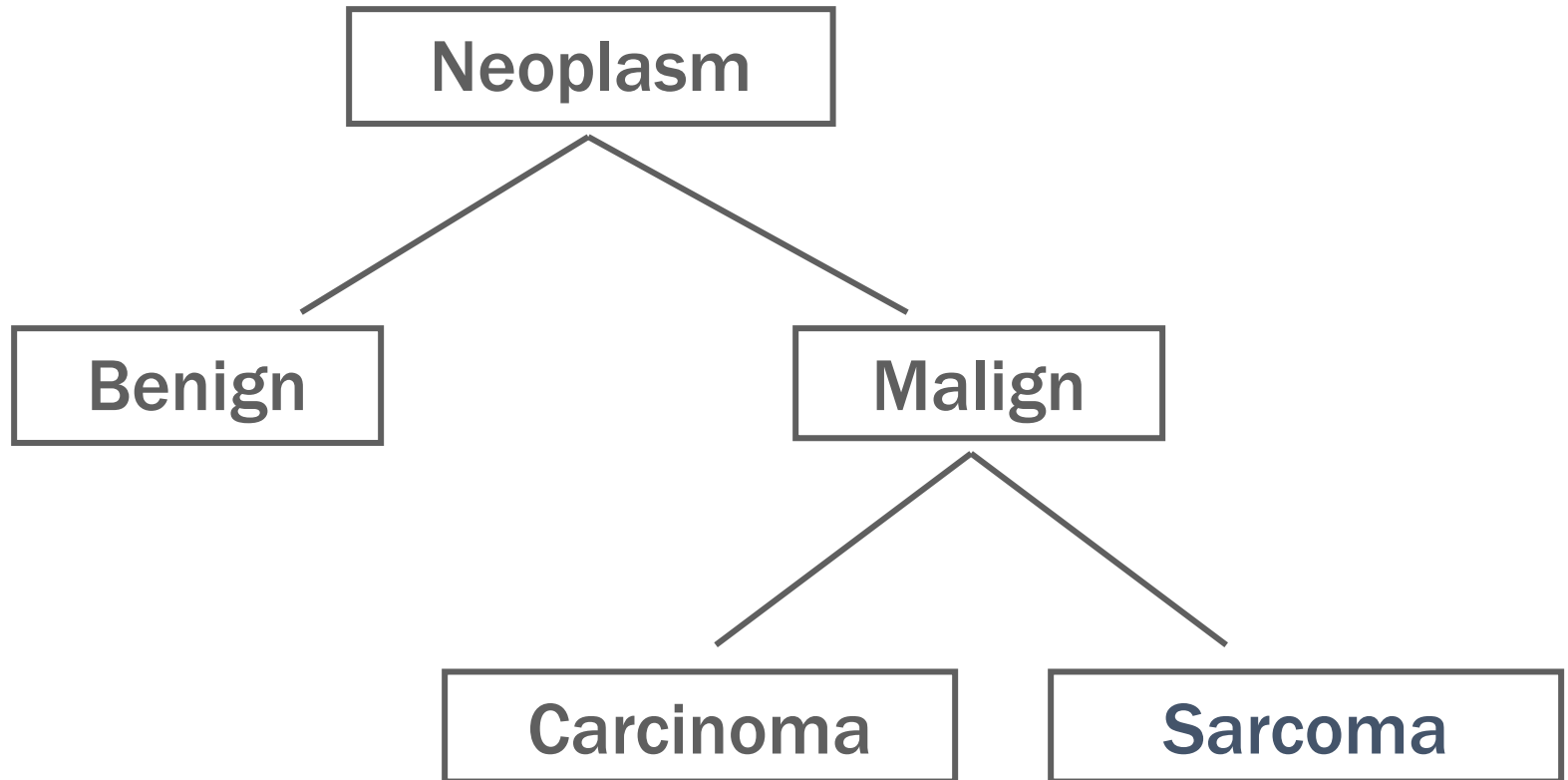


*squamous cell carcinoma*

*adenocarcinoma*



# Nomenclature



*angiosarcoma*  
*rabdomiosarcoma*

## Classification of mesenchymal tumors

Tissue of origin	Benign tumors	Malignant tumors
Connective tissue	Fibroma (soft, hard) Dermatofibroma (histiocytoma) Elastofibroma Fibromatosis (desmoid tumor)	Fibrosarcoma Malignant histiocytoma
Adipose tissue	Lipoma Hibernoma	Liposarcoma Malignant hibernoma
Muscular tissue	Leiomyoma Rhabdomyoma	Leiomyosarcoma Rhabdomyosarcoma
Blood vessels	Hemangioma (capillary, venous, cavernous, arterial) Hemangiopericytoma Glomangioma	Hemangiosarcoma (malignant hemangioendothelioma or hemangiopericytoma)
Lymphatic vessels	Lymphangioma	Lymphangiosarcoma
Bone tissue	Osteoma (compact, spongy) Osteoid osteoma (benign osteoblastoma)	Osteosarcoma (osteoblastic or osteolytic)
Cartilaginous tissue	Chondroma (ecchondroma, enchondroma) Benign chondroblastoma	Chondrosarcoma
Mesothelial tissue	Benign mesothelioma	Malignant mesothelioma
Synovial membranes	Benign synovioma	Synovial sarcoma (malignant synovioma)

# Paraneoplastic syndromes

Syndrom	Mecanism	Example
<b>Cushing Sindrome</b>	Substances of the type ACTH	Small cell lung carcinoma
<b>Hypercalcemie</b>	Parathormone-like substances	Lung (squamous cell) carcinoma
<b>Hyponatremia</b>	Abnormal secretion of ADH	Small cell lung carcinoma
<b>Policitemie</b>	Substances of the erythropoietin type	<a href="#"><u>Nephrocellular carcinoma</u></a>
<b>Trousseau Sindrome</b>	Hypercoagulability status	Various carcinomas
<b>Hipoglycemie</b>	Insulin-like substances	Various carcinomas
<b>Carcinoid Sindrom</b>	Acid 5-hidroxi-indoleacetic (5-HIAA)	Metastatic malignant carcinoid tumors



# **What are the fatal complications of malignancies (the causes of death)**

- **PNEUMONIA**
- **CACHEXY**
- **RENAL INSUFFICIENCY**
- **BLEEDING**
- **SEVERE ANEMIA, THROMBOCYTOPENIA**
- **INFECTIONS**
- **HIPERGUABILITATE**
- **CID SYNDROME**