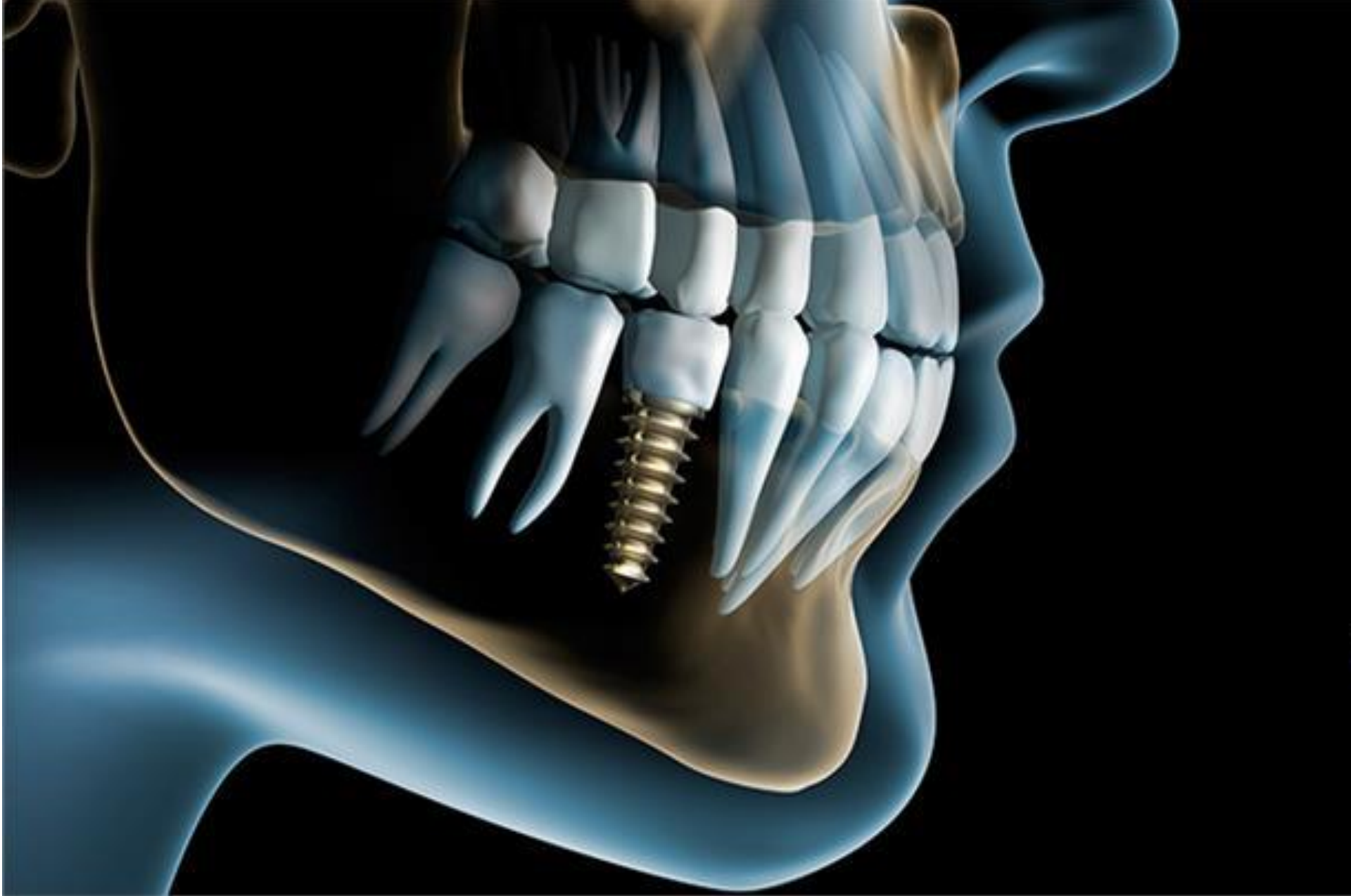



**Tumors, general notions. Epithelial and mesenchymal, benign and malignant tumors of the soft tissues of the oral cavity.**

# **Tumors, general notions. Epithelial and mesenchymal, benign and malignant tumors of the soft tissues of the oral cavity.**

## ***I. Microspecimens:***

### **№ OP43. Squamous cell papilloma of the oral mucosa. (*H-E stain*).**

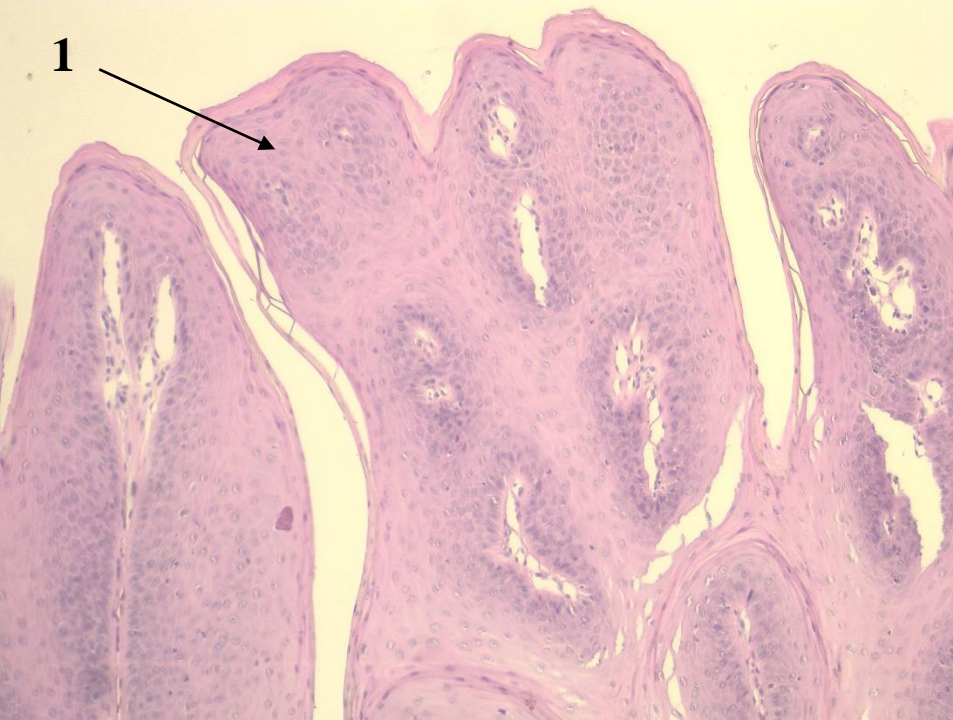
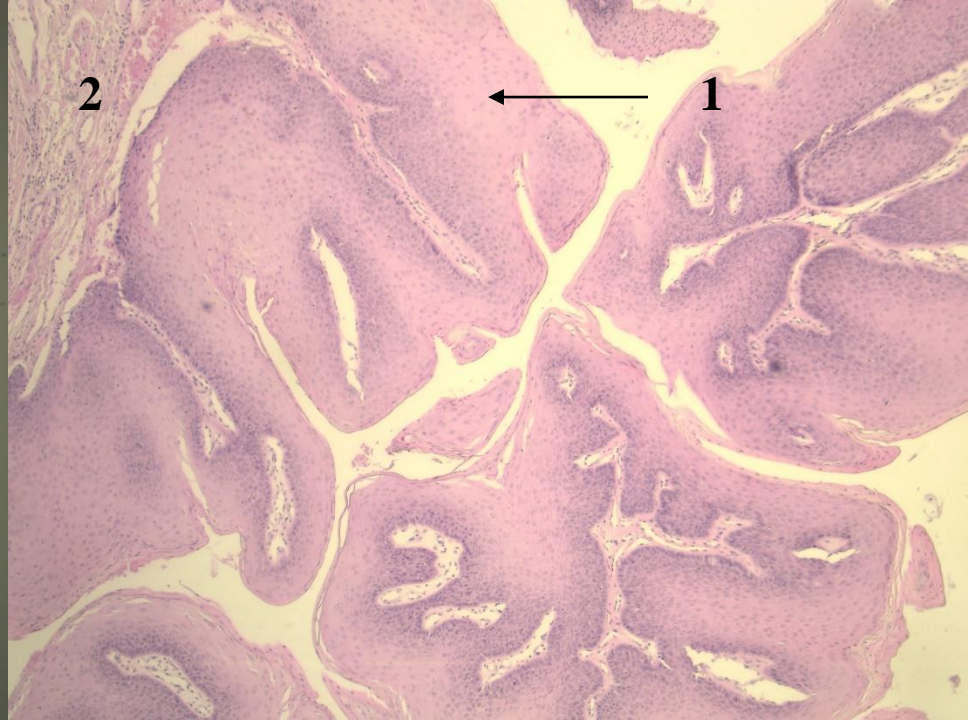
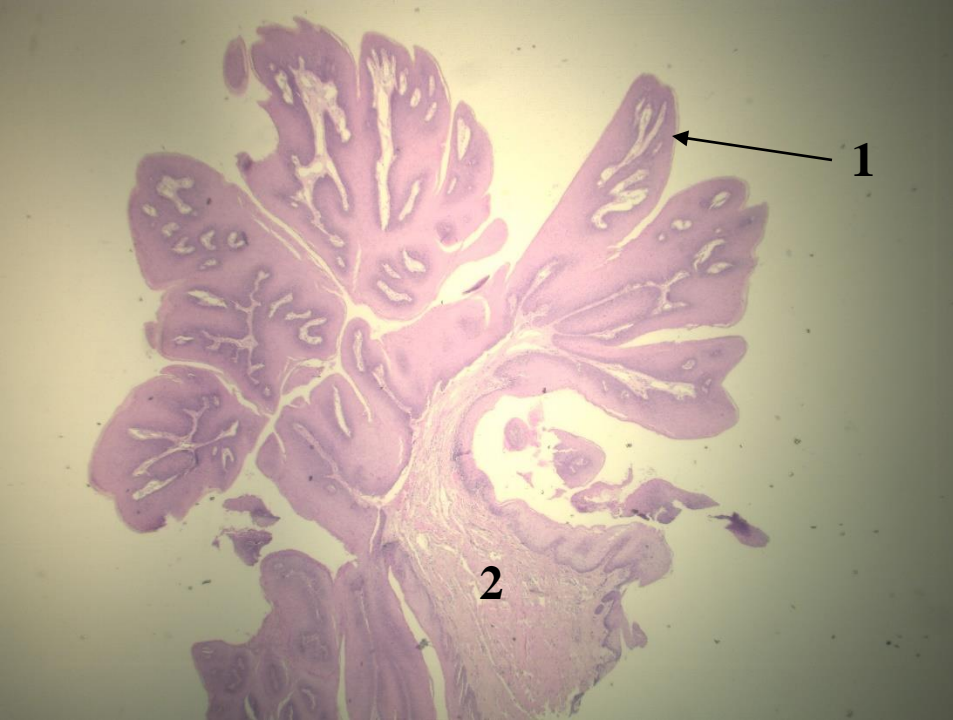
#### **Indications:**

1. Thickened superficial epithelium with acanthosis, hyperkeratosis and parakeratosis.
2. Stroma, represented by well-vascularized connective tissue.

Microscopically, the lesion has a papillary appearance, being made up of fibrovascular cores, covered with thickened epithelium, presenting acanthosis (thickening of the spinous layer), hyperkeratosis (thickening of the stratum corneum), parakeratosis (persistence of the nuclei in the superficial layers). There are no signs of dysplasia.

Macroscopically, it has a cauliflower appearance, is sessile or pedunculate of white-gray color with dimensions of a few mm. up to 3 cm.

*Squamous cell papilloma of the oral mucosa is a benign, exophytic tumor that occurs more frequently in males, especially in decades 4,5 and 6 of life, due to HPV infection, especially type 6 and 11. It is located more frequently on the tongue, lips, palate, oral mucosa, tonsils and uvula. It is usually a solitary tumor, asymptomatic from a clinical point of view. Papillomatosis of the oral cavity occurs more frequently in children and is associated with papillomas of the larynx and pharynx. Papillomas grow to puberty and have a tendency to local recurrence. In adults, papillomatosis is favored by the presence of dental root remnants and poor oral hygiene. Multiple papillomatosis of the oral cavity may be associated with focal dermal hypoplasia or epithelial hyperplasia in Heck syndrome. Oral papillomatosis is also associated with facial skin tumors, as well as gastrointestinal, CNS, musculoskeletal and thyroid abnormalities in Cowden syndrome, a disease with autosomal dominant inheritance.*



**№ OP43. Squamous cell papilloma of the oral mucosa. (H-E stain).**

**№ OP17. Lipoma of the oral cavity. (H-E stain).**

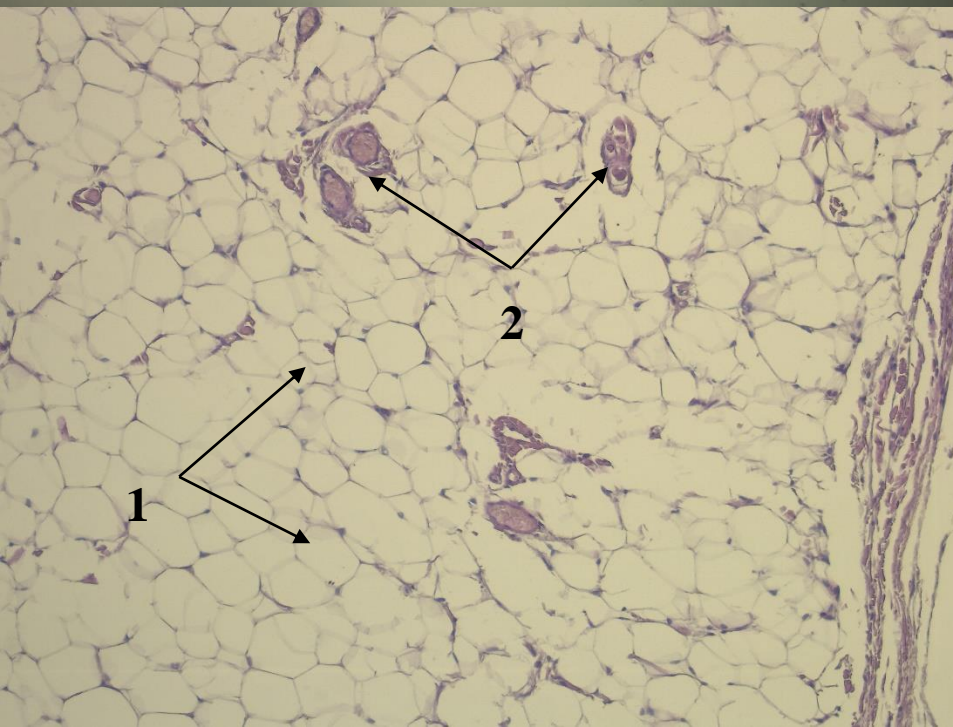
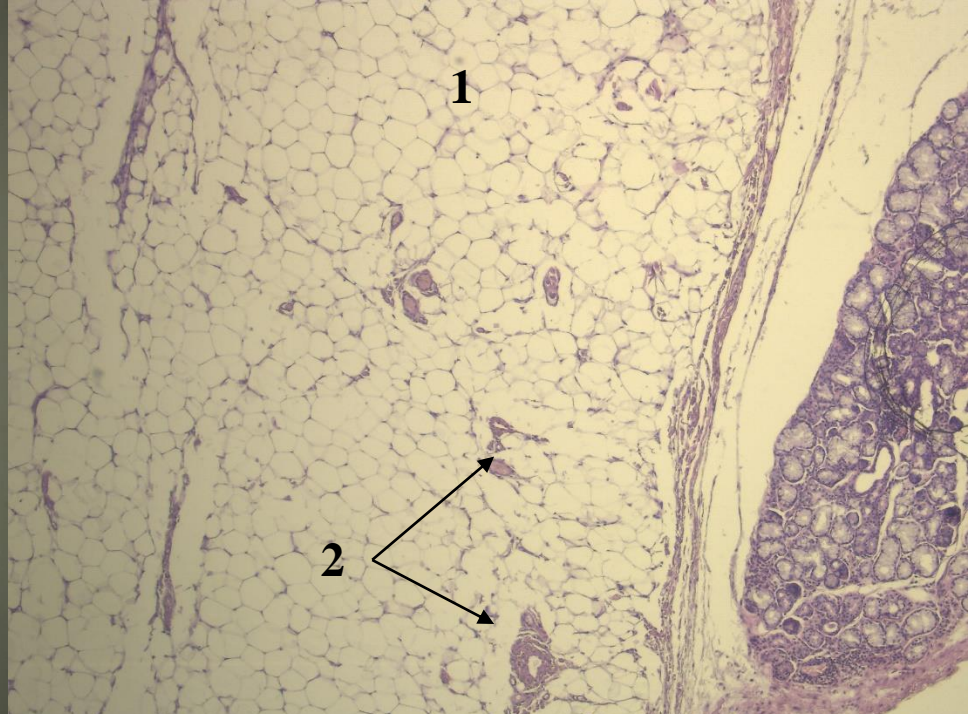
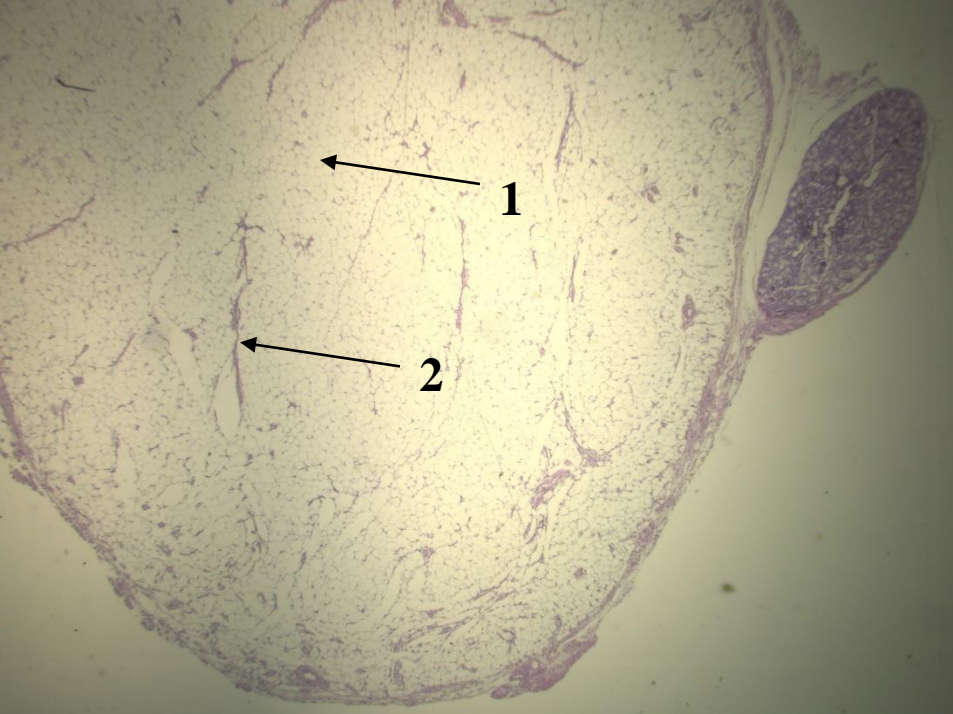
**Indications:**

1. Mature adipocytes.
2. Connective tissue septa with blood vessels.

Microscopically, it consists of mature fat cells, among which are seen connective tissue septa with blood vessels. No lipoblasts are observed. Sometimes foci of necrosis, hemorrhage, infarct, calcification, cystic degeneration, without prognostic significance, may occur in the tumor. There are following microscopic variants: myxolipoma, fibrolipoma, pleomorphic lipoma, spindle-cell lipoma, angiolipoma, angiomyolipoma, chondrolipoma, osteolipoma.

Macroscopically, *it has a nodular appearance, well delimited, sessile or pedunculate, with a smooth surface, of elastic consistency and yellow color, obviously through the transparency of the overlying mucosa, painless. It grows slowly and can have very variable dimensions, the diameter sometimes reaching up to 4-5 centimeters. At the periphery it is surrounded by a fine capsule.*

*Lipoma is rarely found in the oral cavity and can be located on the tongue or lip, sometimes on the floor of the mouth. It occurs more frequently in the 5th and 6th decades of life, especially in obese and in female gender. Symmetrical enlargement of the neck due to overgrowth of adipose tissue at this level is called benign symmetrical lipomatosis or Madelung's disease.*



**№ OP17. Lipoma of the oral cavity.**  
*(H-E stain).*

**No OP18. Granular cell tumor of the tongue. (H-E stain).**

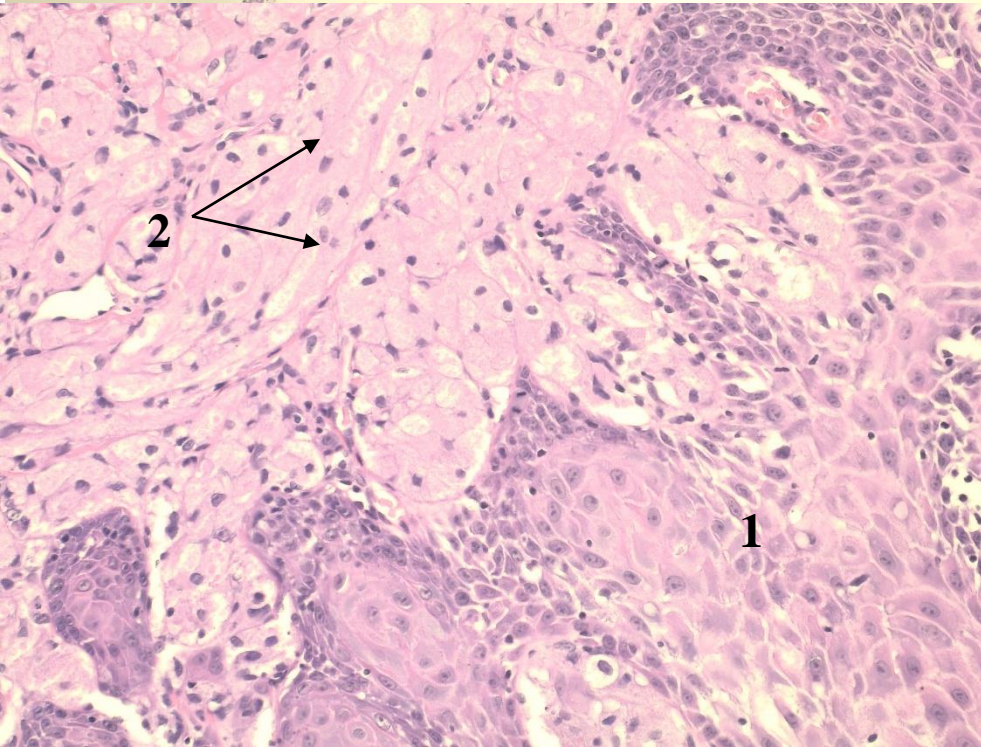
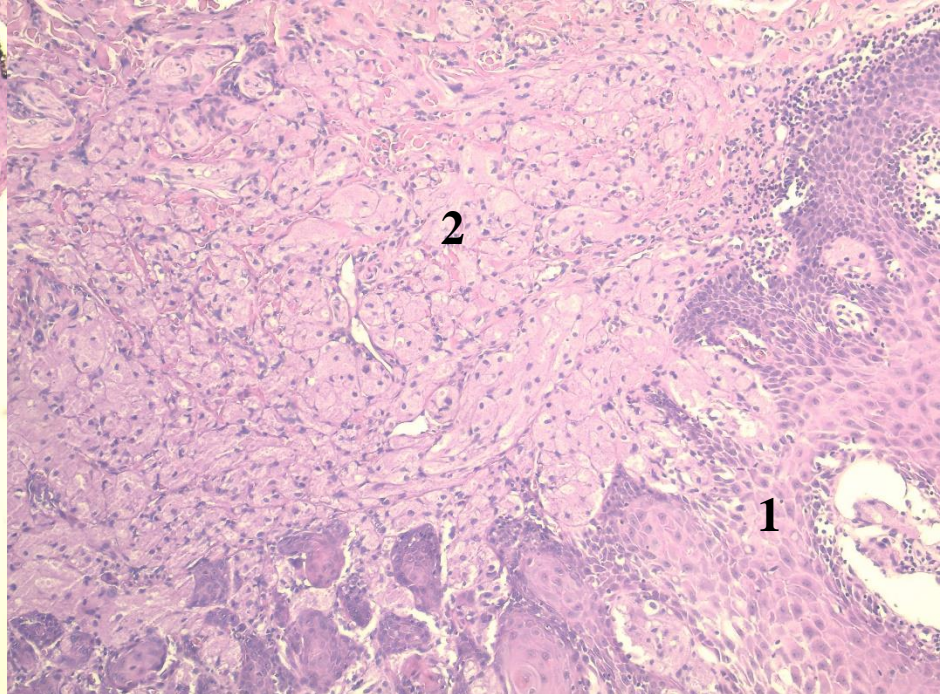
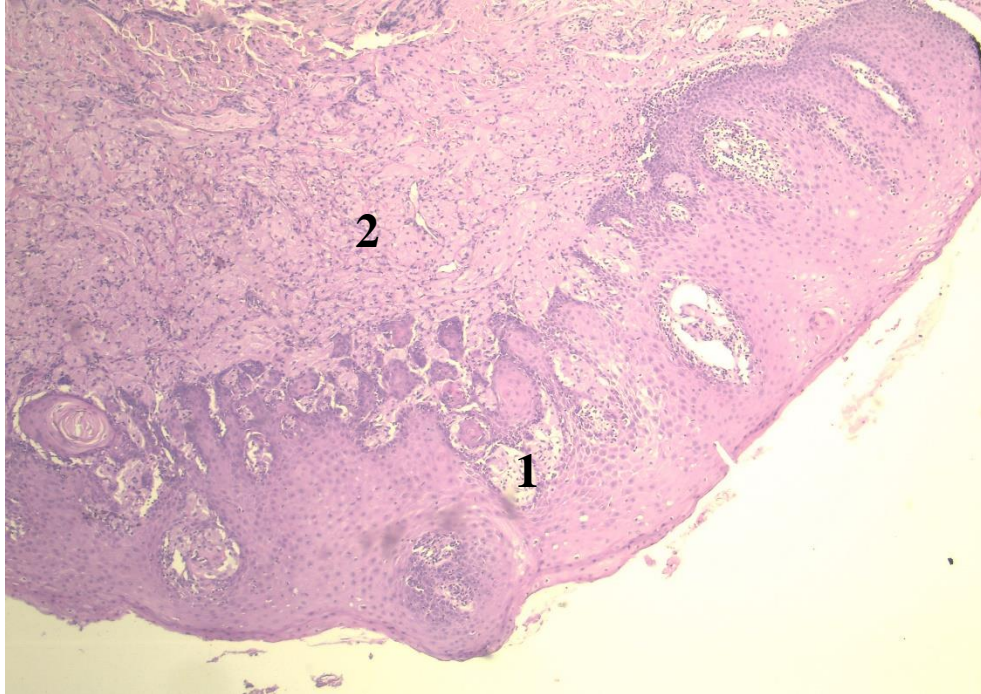
**Indications:**

1. Superficial epithelium.
2. Cells with eosinophilic, finely granular cytoplasm.

Microscopically, the tumor is composed of large, polygonal cells with eosinophilic, finely granular cytoplasm and small, hyperchromic nuclei.

Macroscopically, *it is a well-defined, sessile, pink node with a diameter of 2 centimeters that protrudes subepithelially.*

*Granular cell tumor it is very rare, most often located on the tongue, usually on dorsal side. It occurs more frequently in adults and females. Electron microscopy and immunohistochemical studies indicate the nervous origin (Schwann cells) and not the muscle origin of the lesion. The overlying epithelium may have pseudocarcinomatous hyperplasia, which should not be confused, especially on biopsy with a carcinoma.*



**№ OP18. Granular cell tumor of the tongue. (H-E stain).**

**№ OP18. Hemangioma of the oral cavity. (*H-E stain*).**

**Indications:**

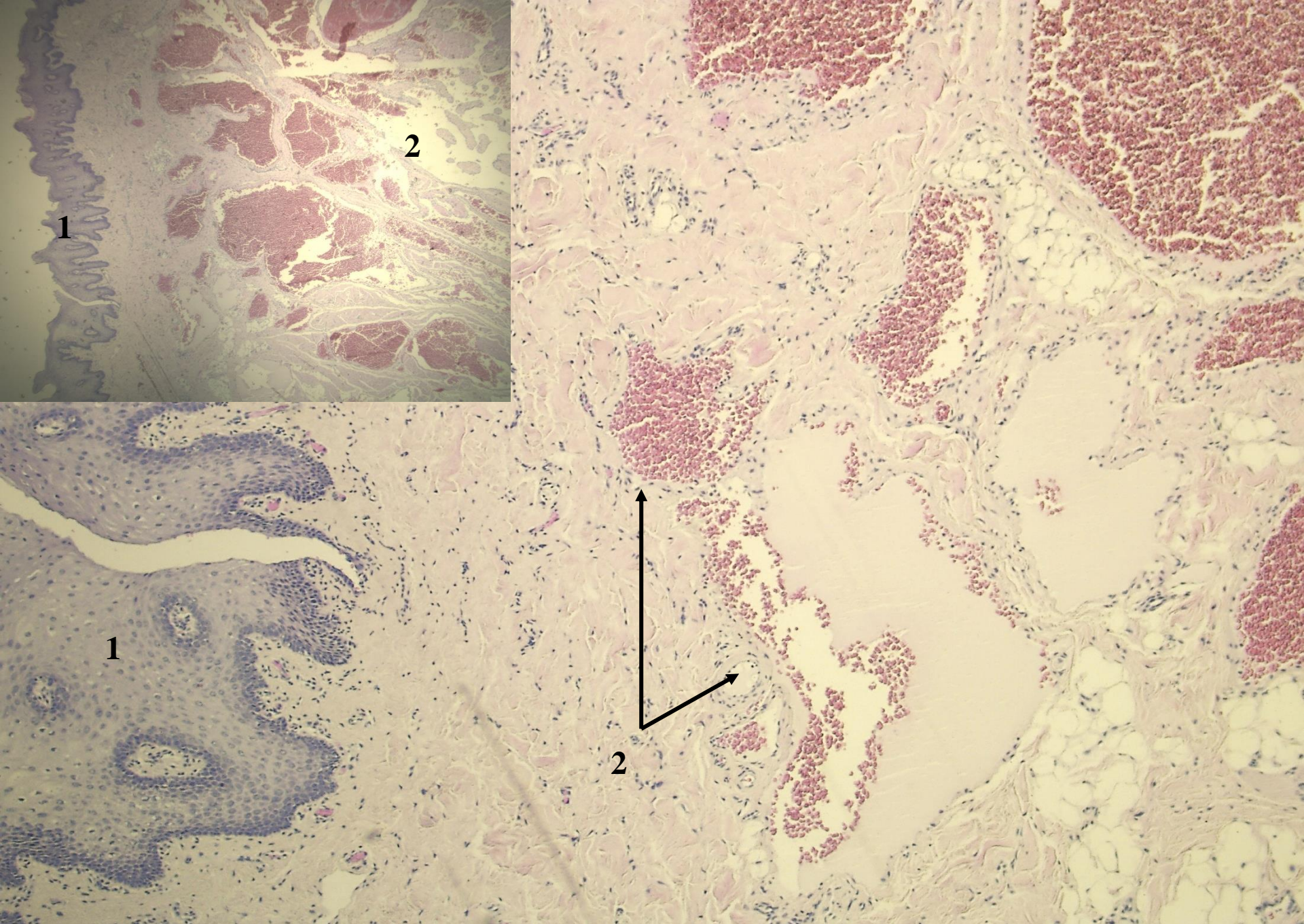
1. Superficial epithelium.
2. Cystic dilated vascular spaces of cavernous appearance.

Microscopically, it consists of a proliferation of endothelial cells, which delimit vascular spaces, sometimes with indistinct lumen. As the lesion matures, the endothelial cells flatten and the vascular spaces become more obvious. When the lesion regresses the vascular spaces appear cystic dilated of cavernous appearance. Unlike hemangioma, vascular malformations are present from birth, but persist throughout life and are not associated with endothelial proliferation.

Macroscopically, *appears as a flat or prominent, purple-colored lesion that is associated with macrocheilia and macroglossia. It is well defined, and has a soft consistency. It can sometimes ulcerate, causing bleeding.*

*Hemangioma of oral cavity is a benign tumor made up of blood vessels, which is located more frequently in the lower lip and tongue. It is a congenital lesion, it grows rapidly after birth, but has a tendency to spontaneous involution.*





**№ OP18. Hemangioma of the oral cavity. (H-E stain).**

## **No OP16. Well-differentiated squamous cell carcinoma. (H-E stain).**

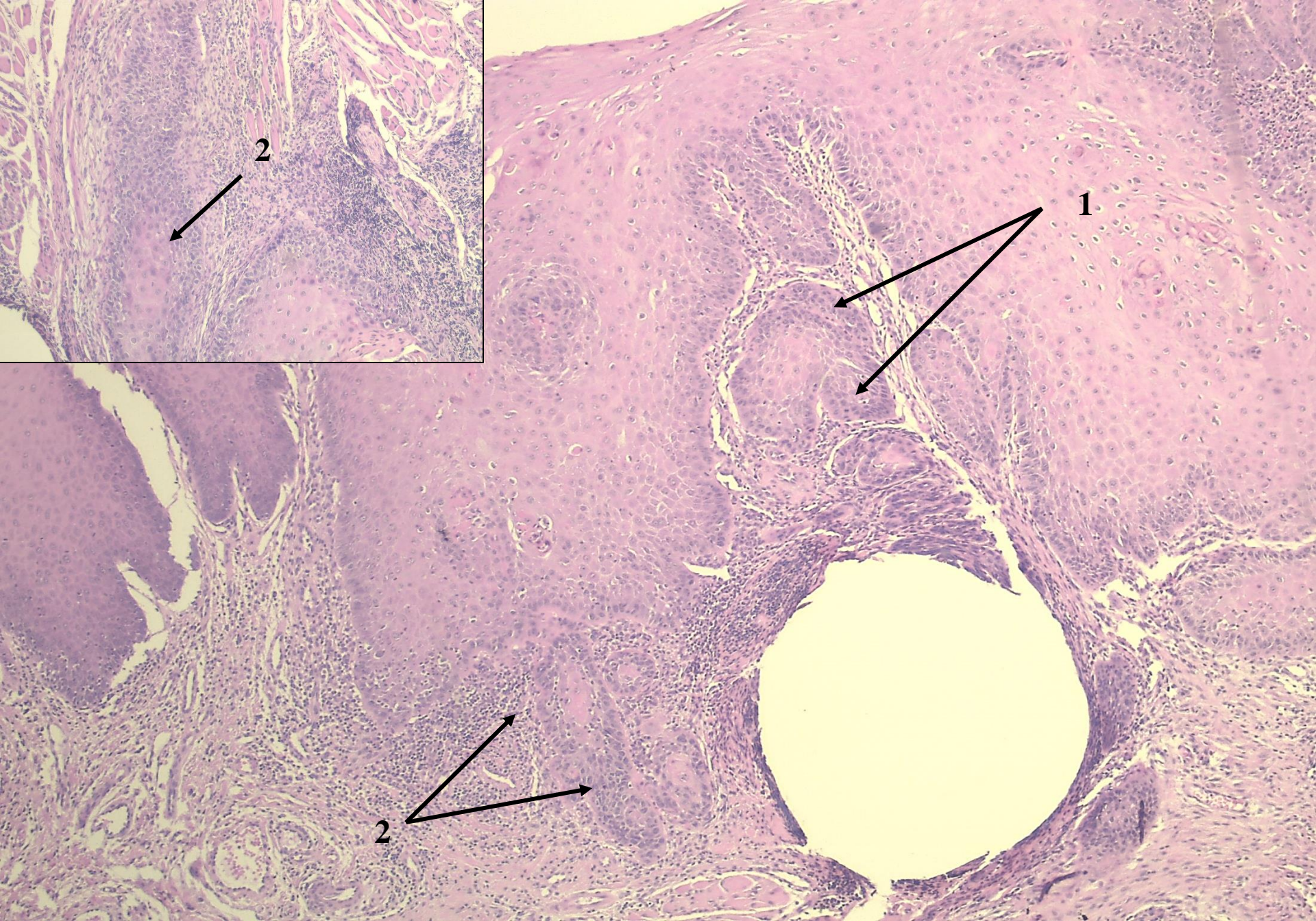
### **Indications:**

1. Superficial epithelium with signs of dysplasia
2. Tumor cells that infiltrate lamina propria.

Microscopically, the tumor is characterized by a proliferation of tumor cells arranged in cords, which infiltrate the lamina propria, overlying epithelium shows signs of dysplasia. Tumor cells have abundant eosinophilic cytoplasm, hyperchromic nuclei, and mitotic figures. At the level of tumor cords, keratin pearls can be highlighted in the form of round, eosinophilic, concentric corpuscles. The stroma around the tumor cells shows an inflammatory infiltrate with areas of necrosis. Microscopic grading is based on the differentiation of tumor cells and the production of keratin.

Macroscopically, *it can be exophytic (cauliflower appearance), endophytic (infiltrative or ulcerative), leukoplastic (white area), erythroplastic (red area) and erythroleukoplastic (white area with red foci).*

*It is the most common malignant tumor of the oral cavity. It represents 5-8% of all malignant tumors. The etiology of squamous cell carcinoma is multifactorial. The most important extrinsic predisposing factors are smoking and alcohol, oncogenic viruses (HSV), sun exposure (for lip carcinoma). Intrinsic factors include systemic conditions such as malnutrition and iron deficiency anemia. Among the precancerous lesions, the role of leukoplakia is known. The tumor is more common in the lips, tongue, mouth, gums, palate. Metastases develop by lymph in the ipsilateral cervical lymph nodes, sometimes bilaterally, in advanced stages hematogenous metastases develop in the lungs, liver, bones. The prognosis of squamous cell carcinoma of the oral cavity is reserved, being influenced by a number of factors, the most important of which are: the clinical stage (according to the TNM classification) and the microscopic degree of the tumor. The three parameters that are assessed in this clinical staging are: the size of the primary tumor in centimeters (T), the number and size of lymph nodes affected by metastases (N), and the presence of distant metastases (M). According to this staging, four stages of oral squamous cell carcinoma are recognized, in stage I the 5-year survival being 85%, while in stage IV only 9%.*



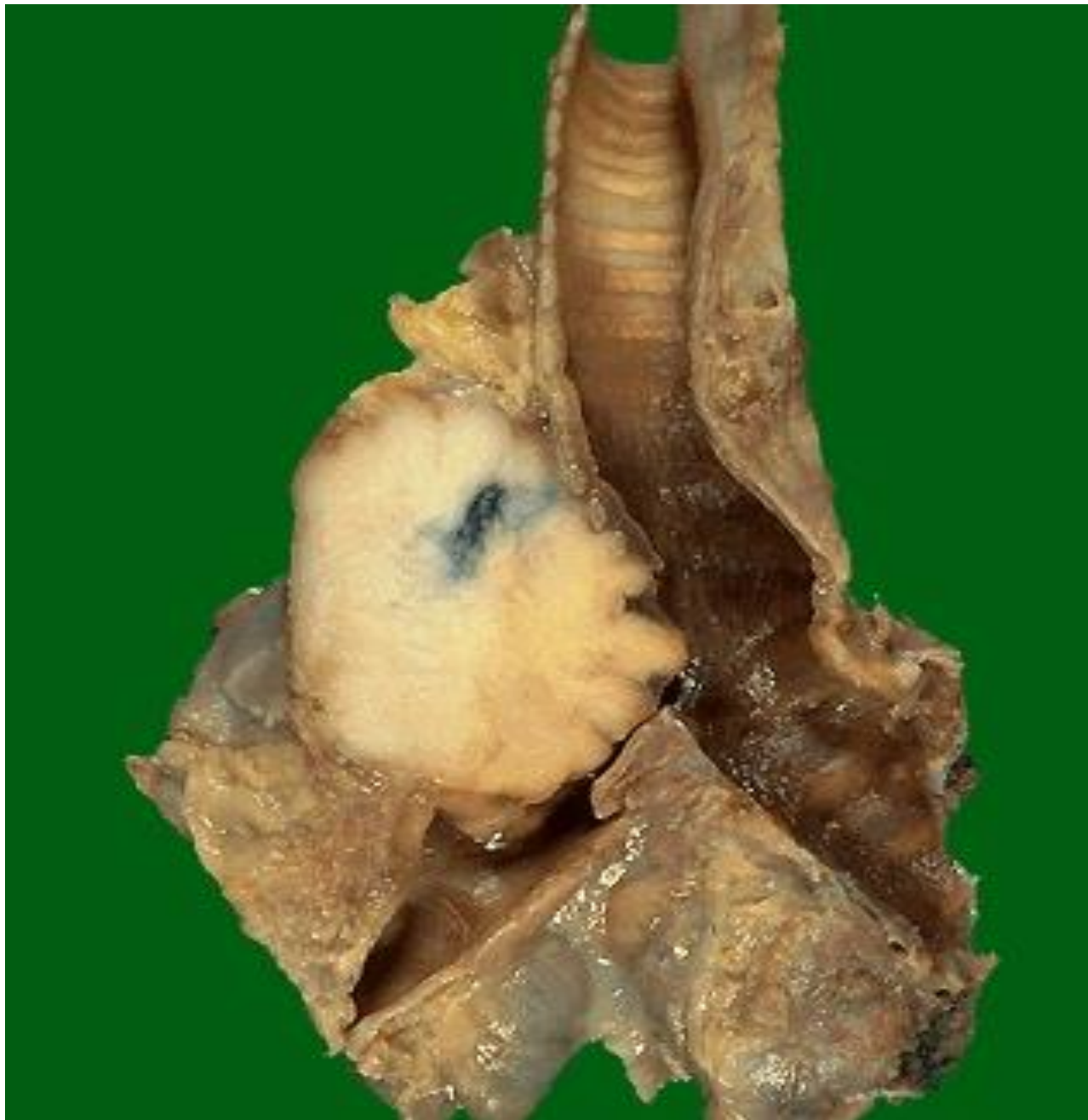**№ OP16. Well-differentiated squamous cell carcinoma. (H-E stain).**

## ***II. Macrospecimens:***

### **№ 39. Central lung carcinoma.**

In the main bronchus is a tumor node, size ~ 4-5 cm, which grows exophyte, stenosing the lumen, with rough surface, dense consistency, white-yellow color, tumor tissue infiltrates the adjacent peribronchial lung parenchyma.

*It develops from the epithelium of the main bronchi and their branches, more often on the right. Frequently complicated with atelectasis by obturation, hemorrhage, abscess, fibrino-hemorrhagic or purulent pleurisy. Infiltrative growth can occur in peribronchial lung tissue, contralateral bronchi, pleura, pericardium, and myocardium. Lymphogenic metastases occur in the mediastinal, cervical, supraclavicular, para-aortal lymph nodes, hematogenous metastases - in various organs, more commonly in the liver, adrenal glands, bones, pancreas, brain, etc. It usually occurs on the background of chronic bronchitis, especially in smokers bronchitis, bronchiectasis, chronic abscess, pneumoconiosis. The most common histological form is keratinizing or non-keratinizing squamous cell carcinoma preceded by squamous metaplasia of the respiratory epithelium.*

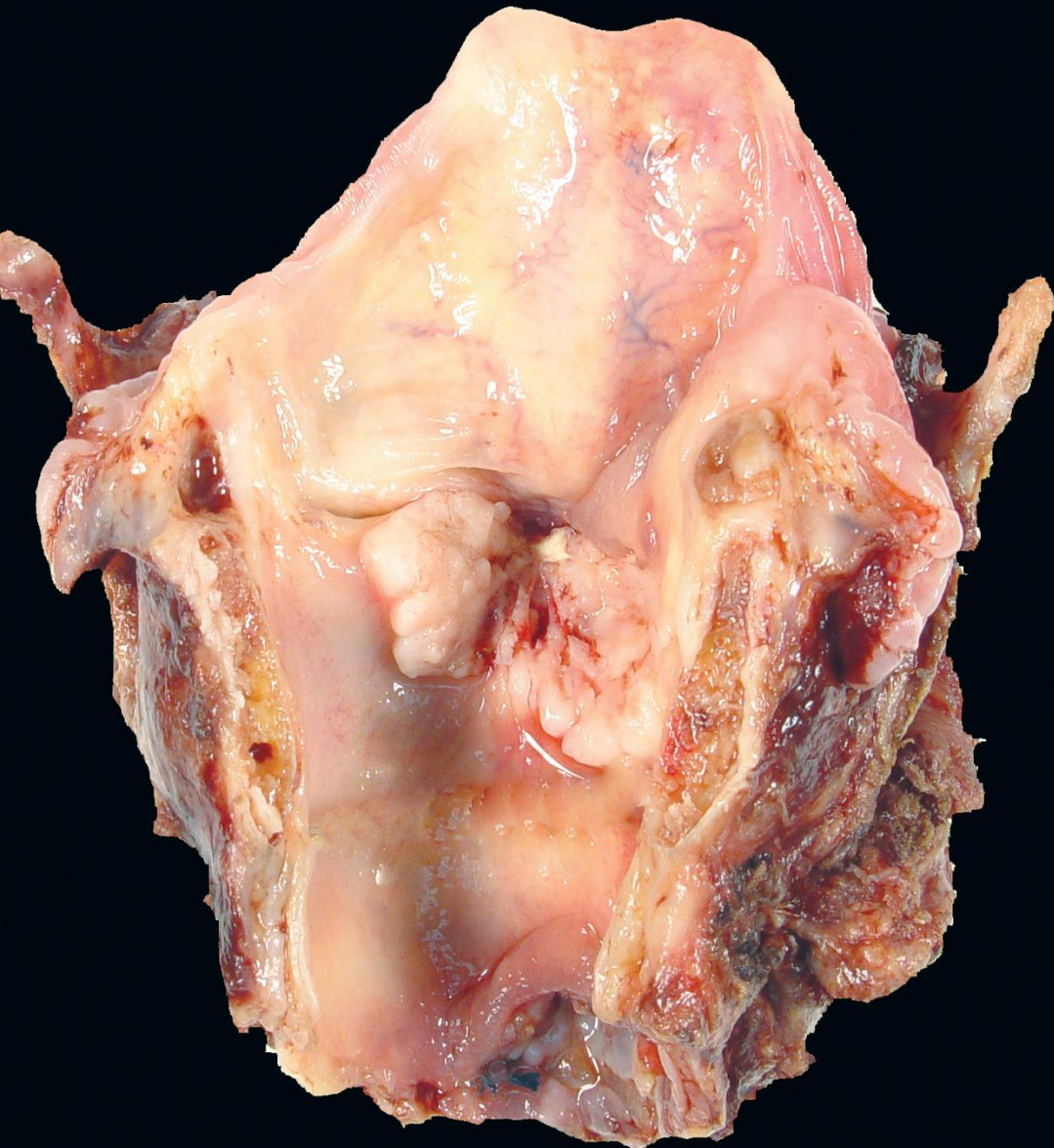

**№ 39. Central lung carcinoma.**

## **№ 41. Carcinoma of larynx.**

In the laryngeal cavity there is a tumoral node, which grows exophyte, protruding on the surface of the mucosa, dense consistency, white-gray color, having in the center an area of necrosis and exulceration.

*It can be complicated by mechanical asphyxia, hemorrhage, secondary inflammation, infections, metastases, especially in regional lymph nodes. In most cases it develops at the level of the vocal chords. The most common histological form - in 99% of cases - is squamous cell carcinoma with / or without keratinization. It occurs frequently on the background of chronic inflammation, leukoplakia and dysplasia of the laryngeal mucosa, etc. Complications: infiltration of vital and adjacent organs - trachea, carotid artery, intercurrent infections, pneumonia by aspiration, disseminated metastases, cachexia.*



**№ 41. Carcinoma of larynx.**

## **№ 60. Carcinoma of stomach.**

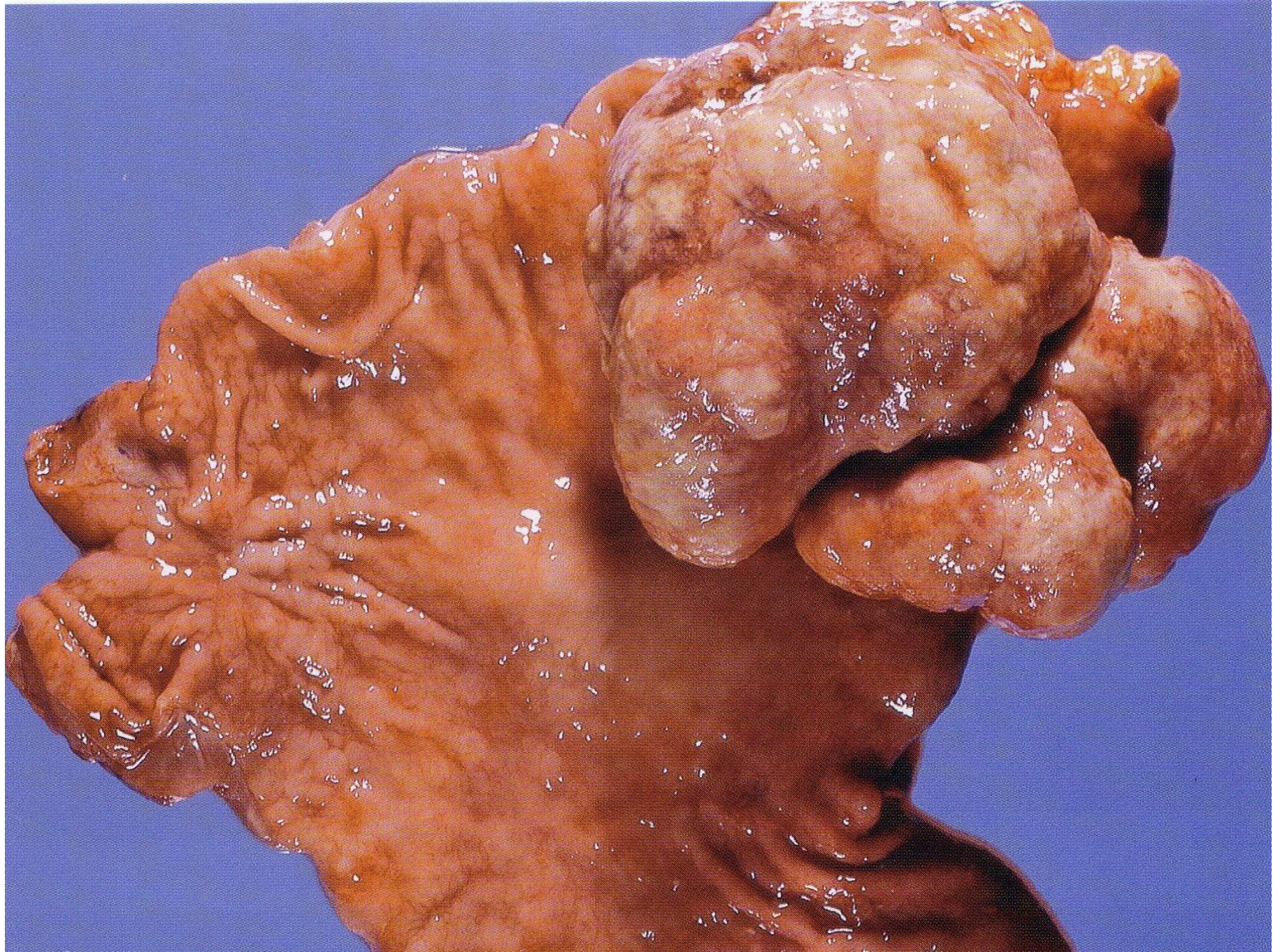In the stomach it is a voluminous tumor with exophytic growth, irregular surface, hemorrhagic foci, dense-elastic consistency, white-gray color, fungal appearance. It is located more frequently in the region of the small curvature and the pyloric canal.

*Gastric carcinoma is most often preceded by precancerous conditions such as chronic atrophic gastritis with intestinal metaplasia of the epithelium, epithelial dysplasia, adenomatous polyps, Helicobacter pylori infection. The most common location is in the region of small curvature, pylorus, pyloric antrum. The most common histological variant is adenocarcinoma with different degrees of differentiation. Gastric carcinoma can spread continuously through the esophagus, peritoneum (peritoneal carcinomatosis), large omentum, pancreas, liver, transverse colon, and by implantation - in mono- or bilateral ovaries - Krukenberg tumor. Locally it can be complicated by hemorrhage, perforation, inflammation of the gastric wall (phlegmon). It gives metastasis primarily in the regional lymph nodes of the small curvature, cardia, and suprapancreatic lymph nodes. A pathognomonic sign is metastasis to the left supraclavicular lymph nodes - the Virchow or Troisier sign. Hematogenous metastases occur first in the liver, later - in the lungs, brain, bones, kidneys.*

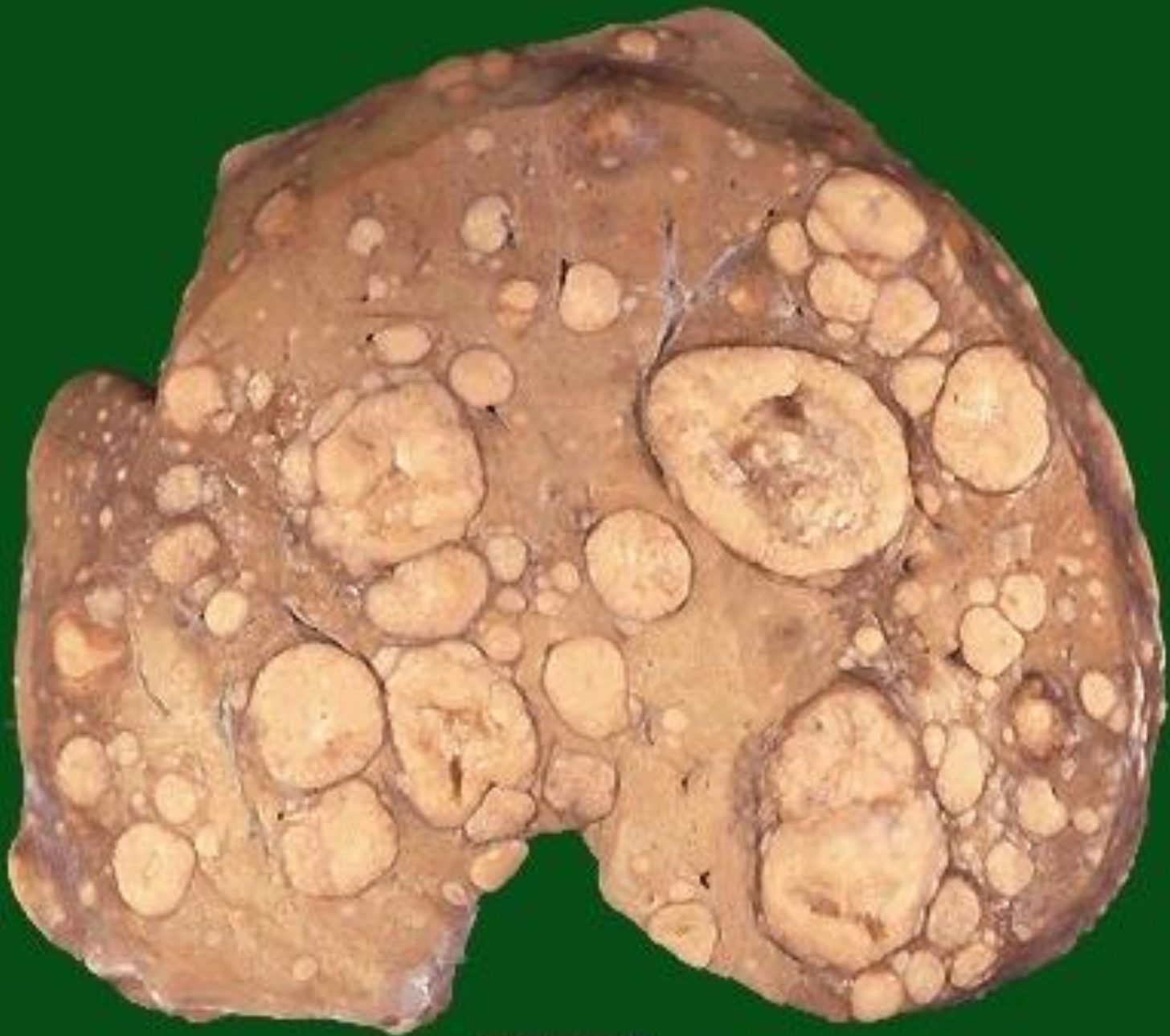## **№ 74. Metastasis of carcinoma into liver.**

The liver is enlarged in size, on the section and under the capsule there are multiple tumoral nodules with a diameter from 0.5-1 to 4-5 cm, round or oval, well delimited, whitish color, distributed relatively irregular on the surface of the organ, hepatic parenchyma between nodules with signs of steatosis (microspecimen no. 52)





**№ 60. Carcinoma of stomach.**



**№ 74. Metastasis of carcinoma into liver.**

## **№ 42. Metastasis of carcinoma into into lungs.**

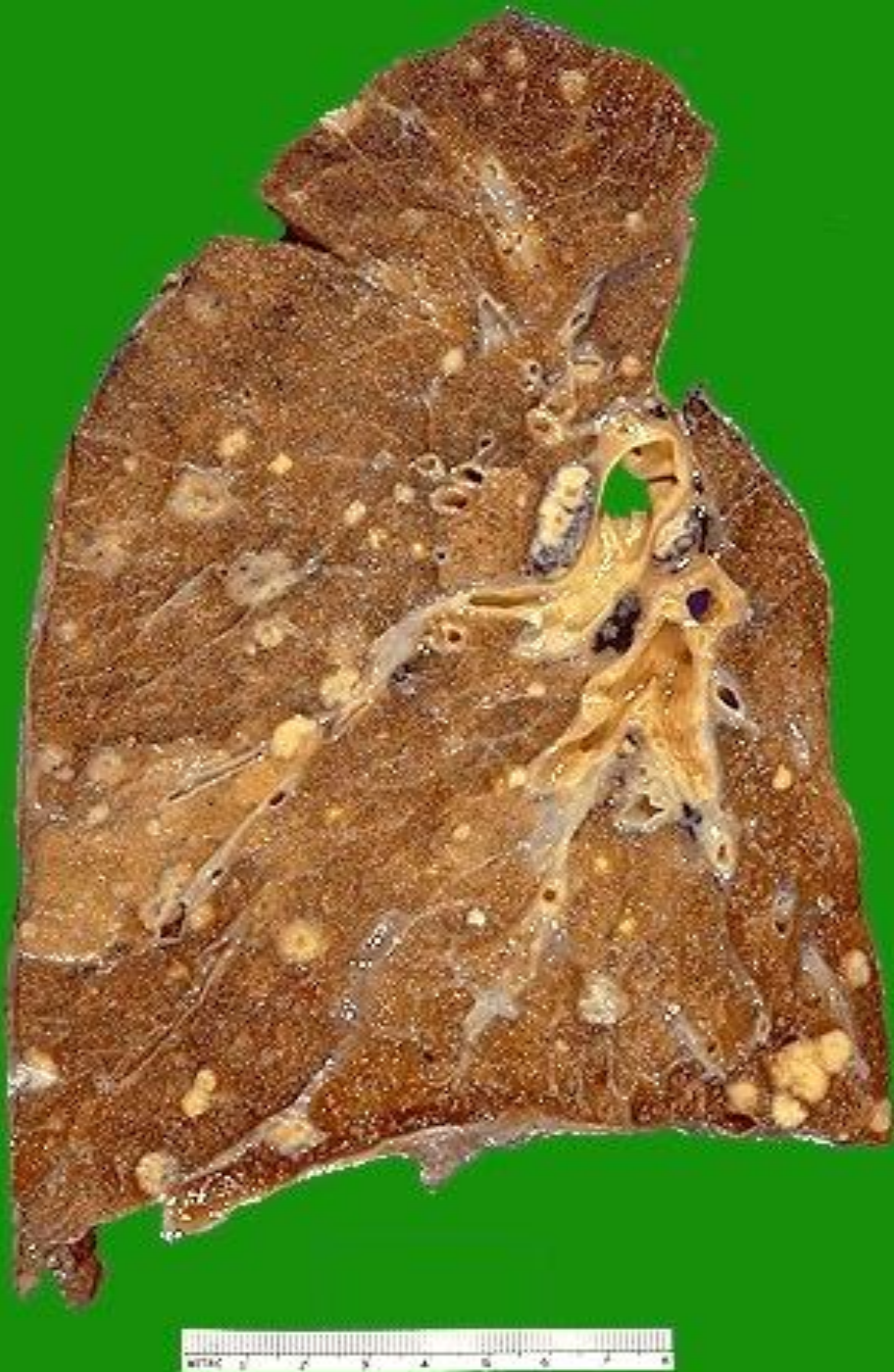
In the lung, under the visceral pleura and on the cut section, are observed multiple white-gray tumoral nodules, round or oval in shape, with a diameter of up to 3-5 cm, well delimited by the adjacent tissue.

*Lung metastases are more common than primary lung tumors. The preferred location is in the peripheral areas of the lungs. More commonly in the lungs there are metastases of carcinoma of the colon, mammary gland, thyroid, kidneys, pancreas.*

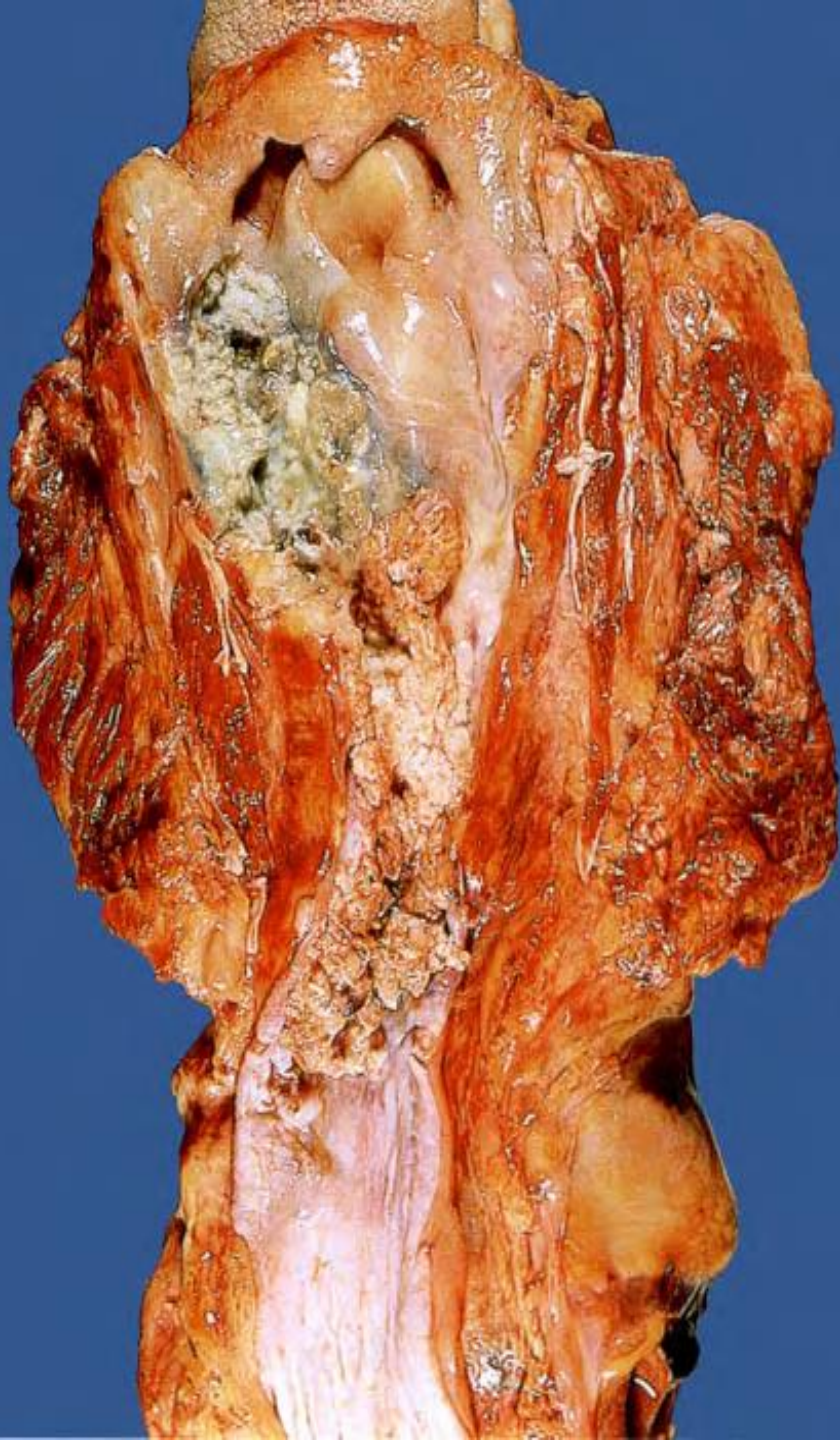## **№ 59. Carcinoma of esophagus.**

The esophagus is sectioned longitudinally, in the middle third is revealed a tumoral node, which grows circularly, protruding and stenosing the lumen, with an irregular, ulcerated surface, covered with necrotic masses.

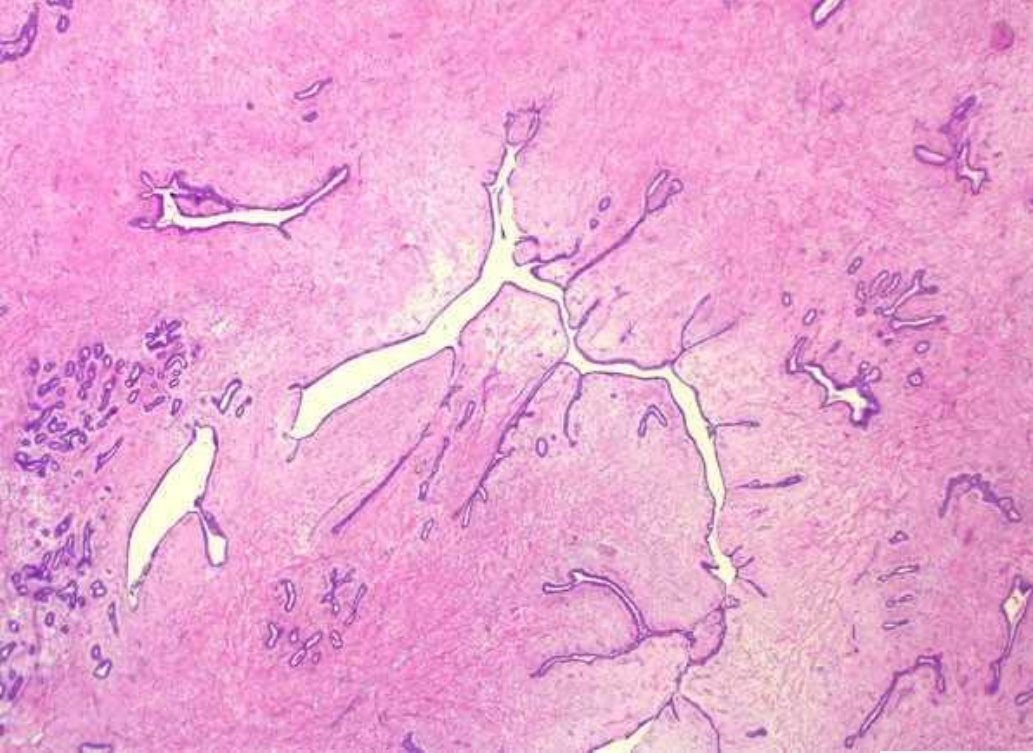
*Most esophageal carcinomas are located in the middle third. Histologically the most common form - 90% of the total number is keratinized or non-keratinized squamous cell carcinomas. Complications: infiltration into the stomach, hypopharynx, trachea with the formation of esophageal-tracheal fistula, larynx, mediastinum, lungs, pleura, aorta. Lymphogenic metastases - in the cervical, para-esophageal, tracheobronchial, subdiaphragmatic nodules. Hematogenous metastases are rare.*



**№ 42. Metastasis of carcinoma into into lungs.**

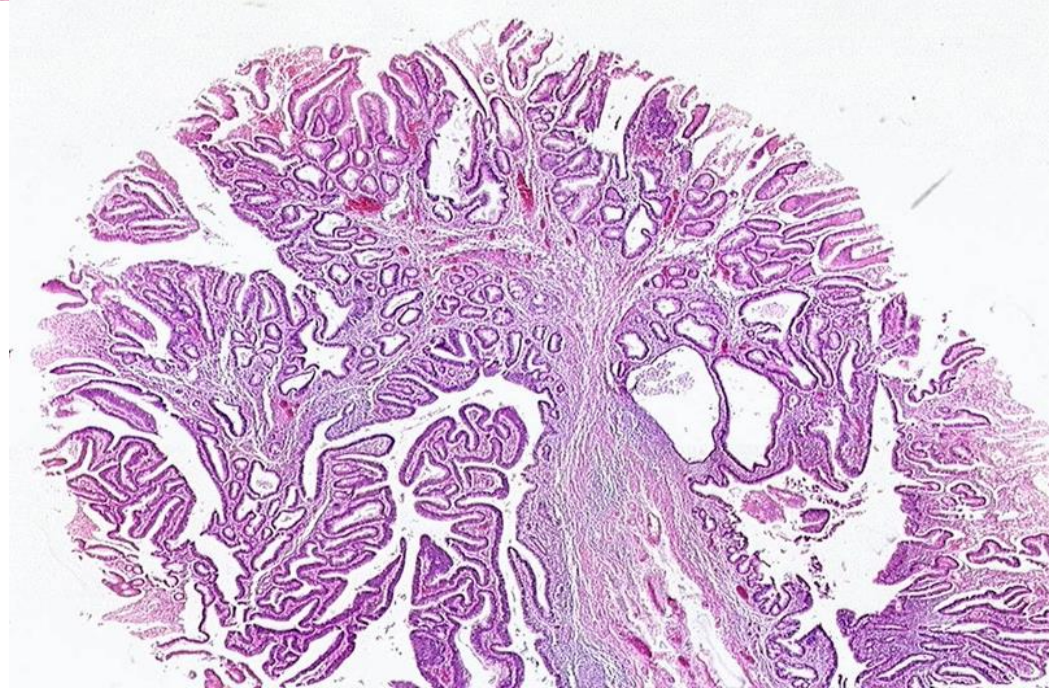


**№ 59. Carcinoma of esophagus.**



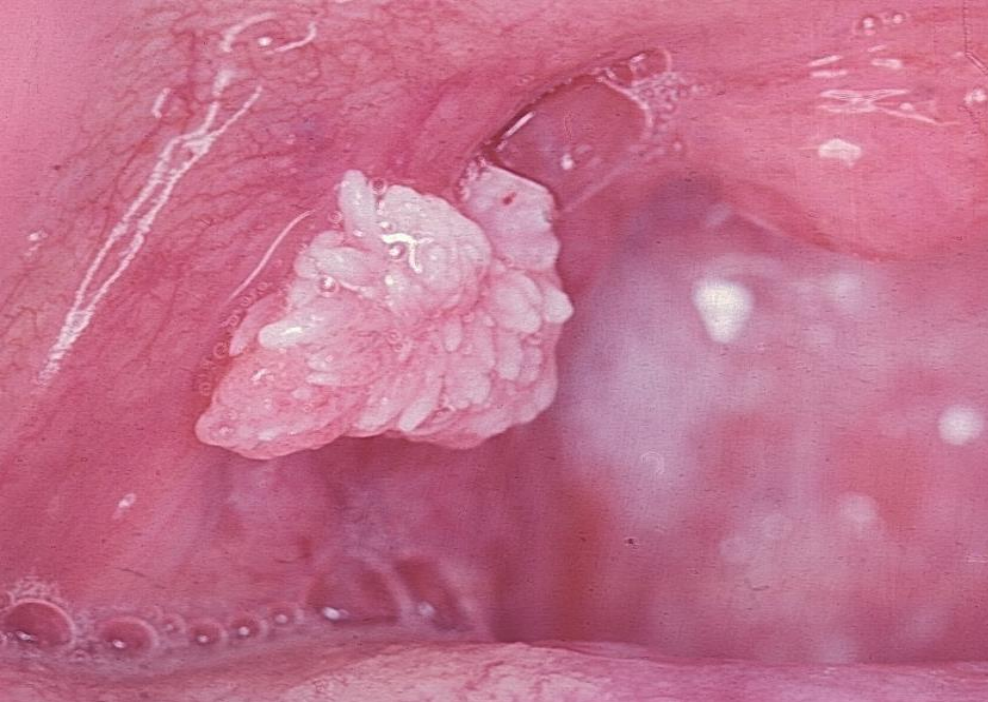
**Tissue atypia in tubulo-villous adenoma of the colon (*H-E stain*).**

**Tissue atypia in mammary gland fibroadenoma (*H-E stain*).**

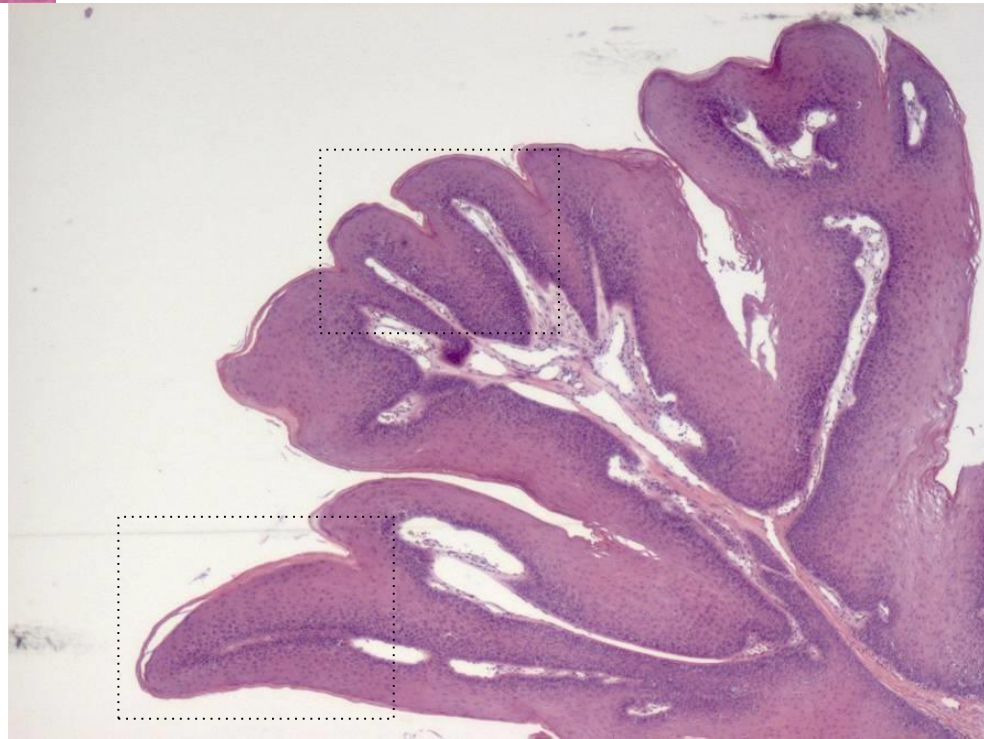




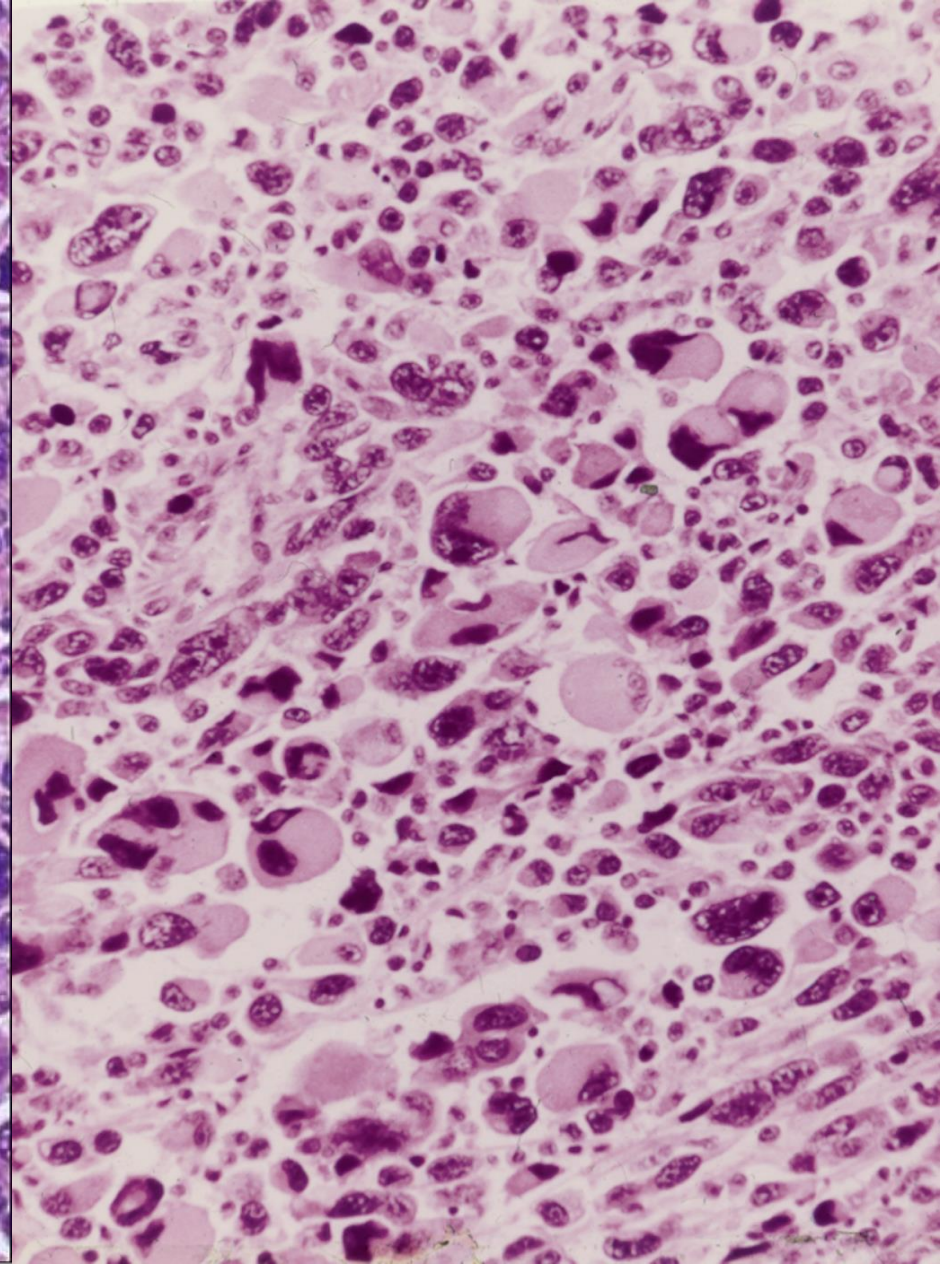
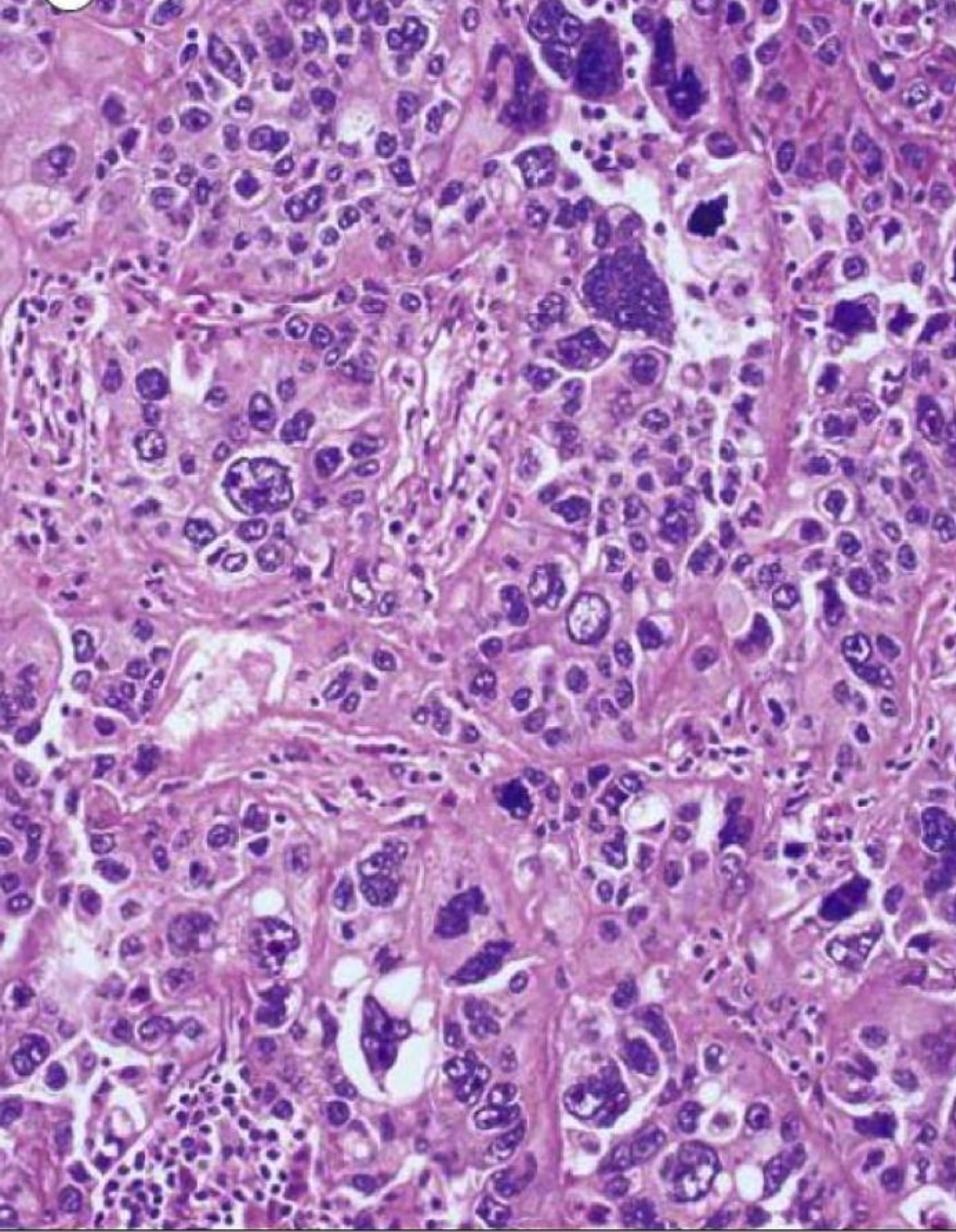
**Familial adenomatous polyposis.**



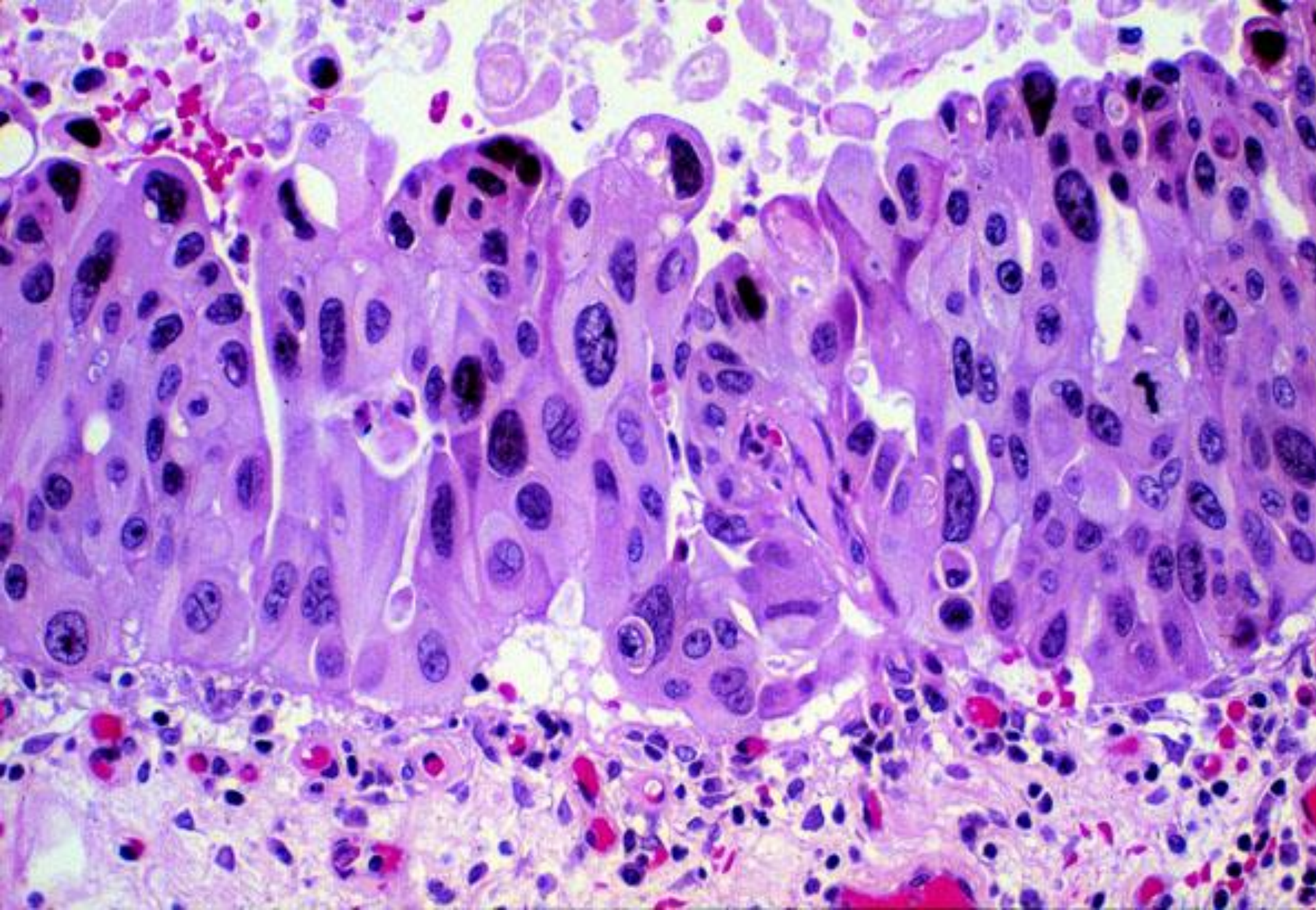
**Oral papilloma.**



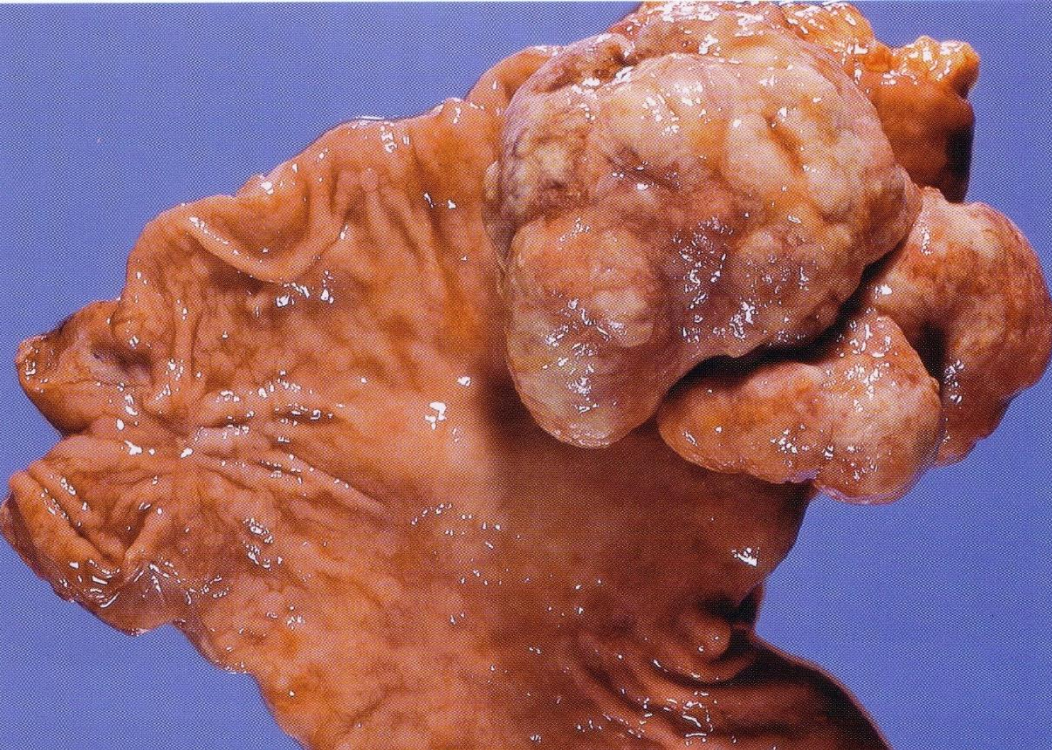



**Cellular atypia in malignant tumors (undifferentiated carcinoma and rhabdomyosarcoma).**

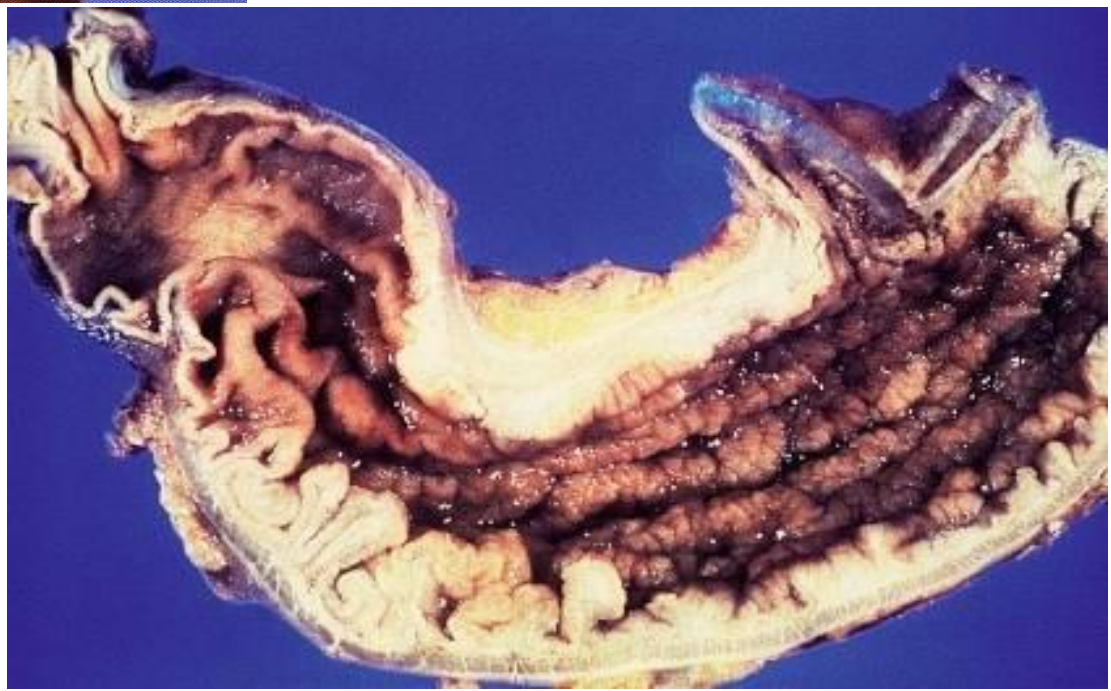

***Carcinoma in situ. (H-E stain).***



**Infiltrative gastric carcinoma.**

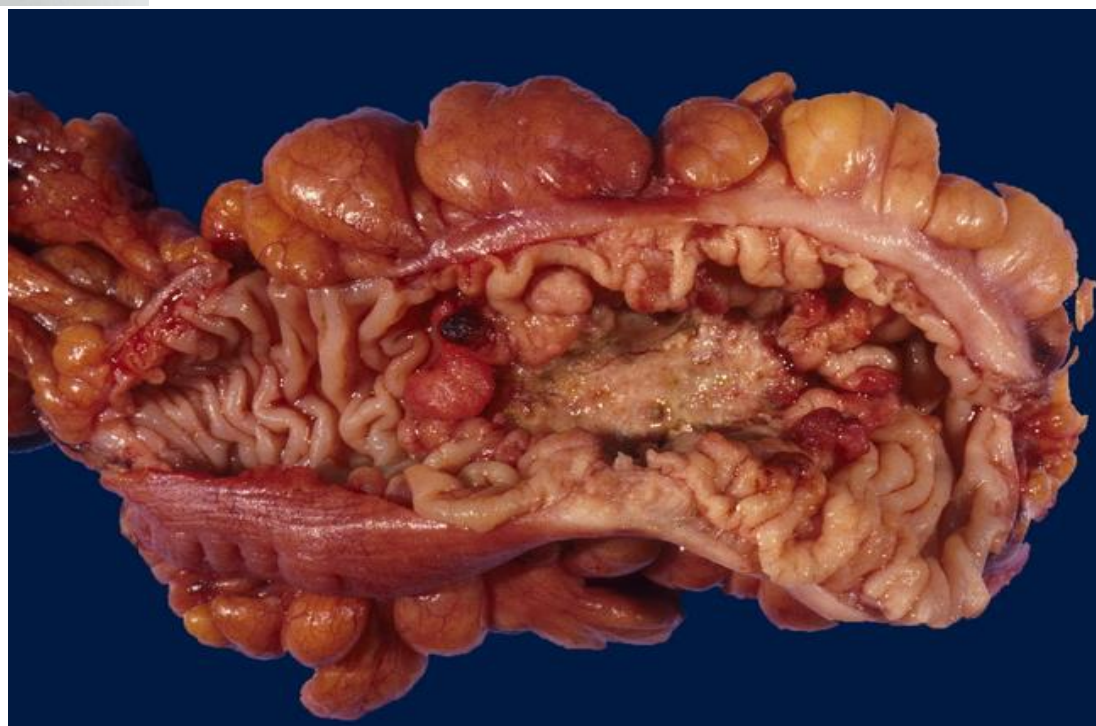**Polypoid gastric carcinoma.**

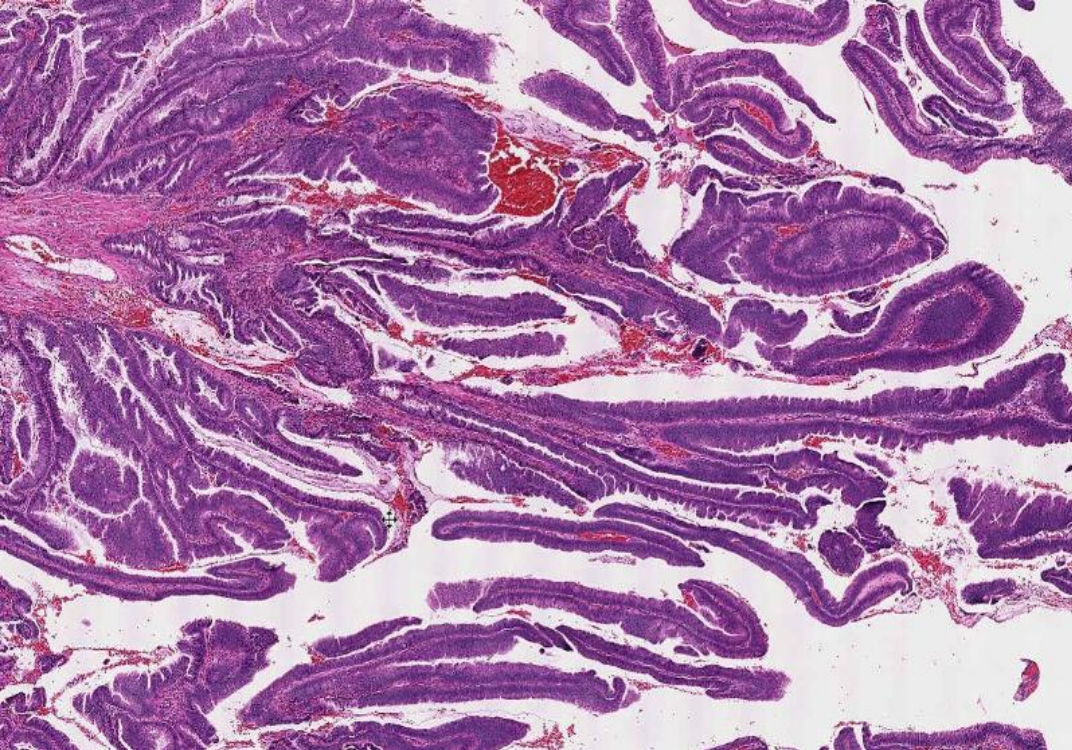




**Infiltrative colon carcinoma.**

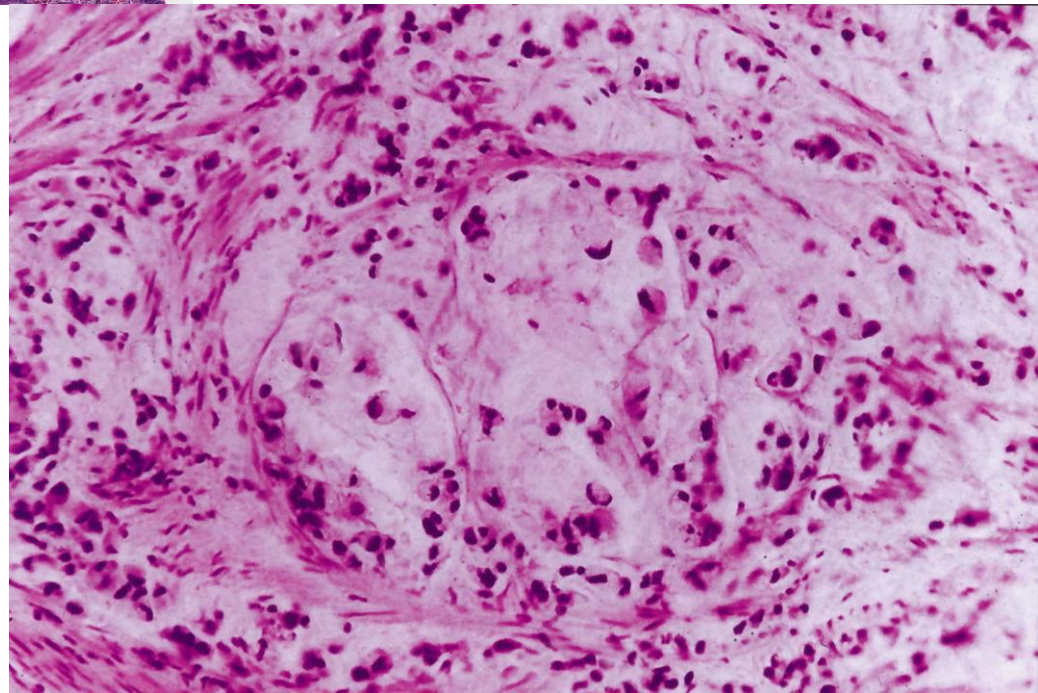
**Colon carcinoma  
(exophytic lesion).**

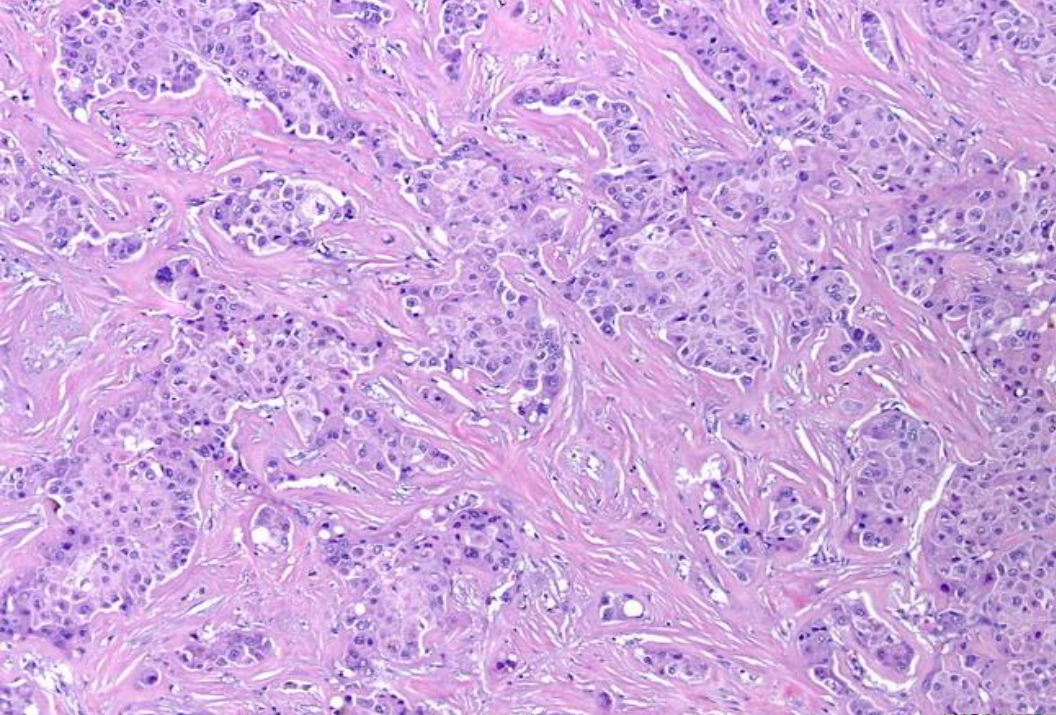




**Mucinous carcinoma.**  
*(H-E stain).*

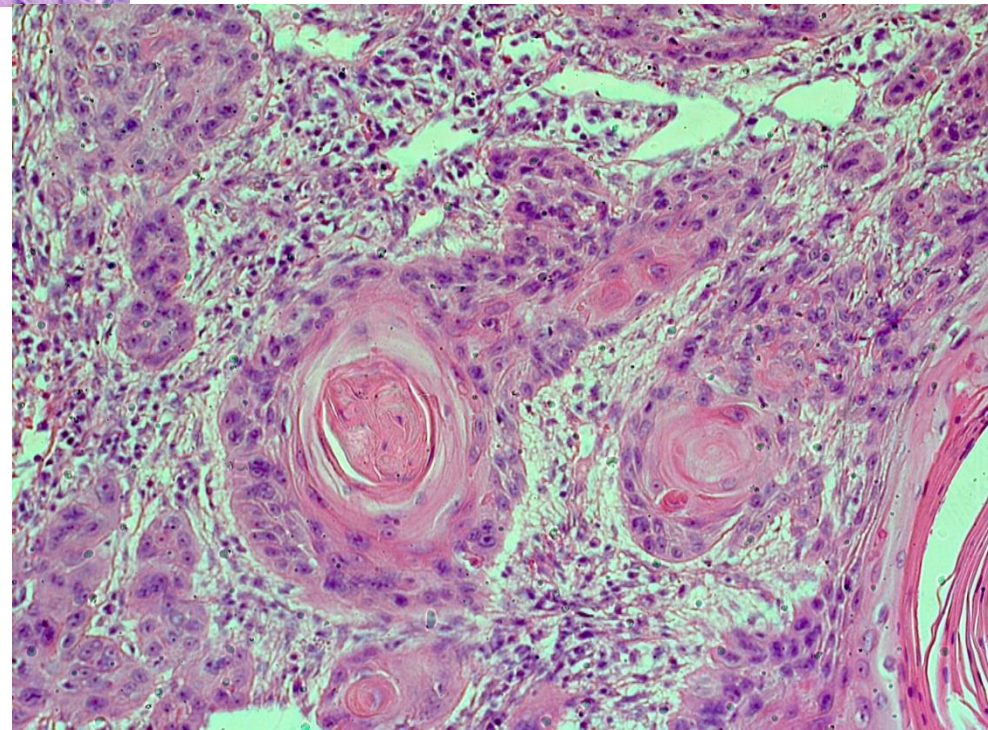
**Papillary glandular carcinoma.**  
*(H-E stain).*

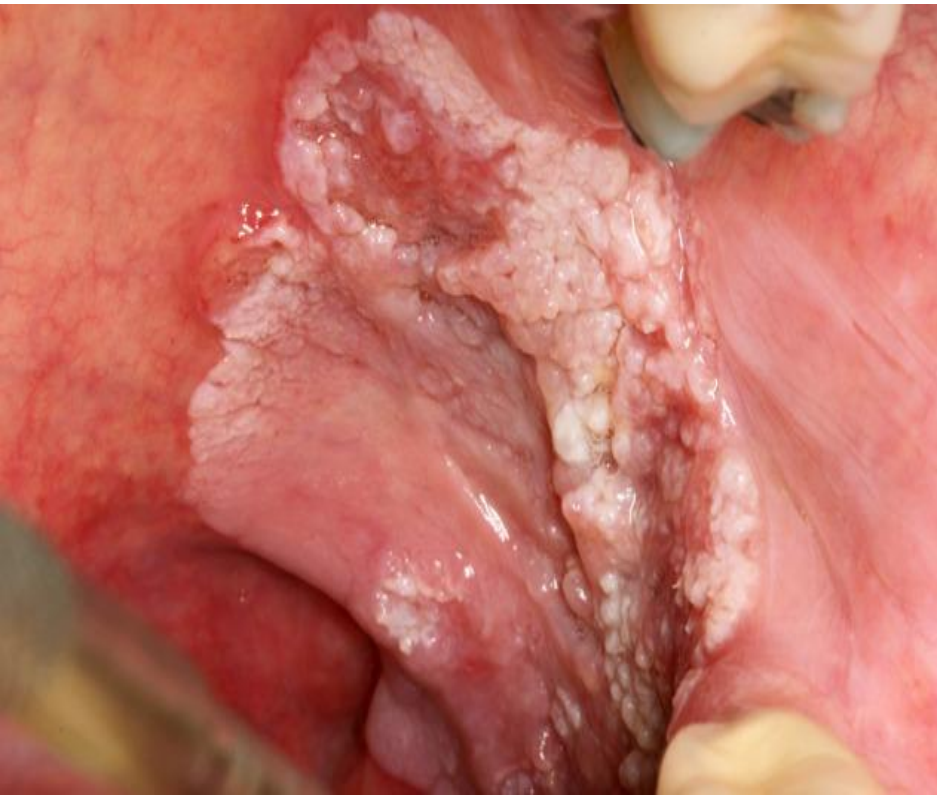



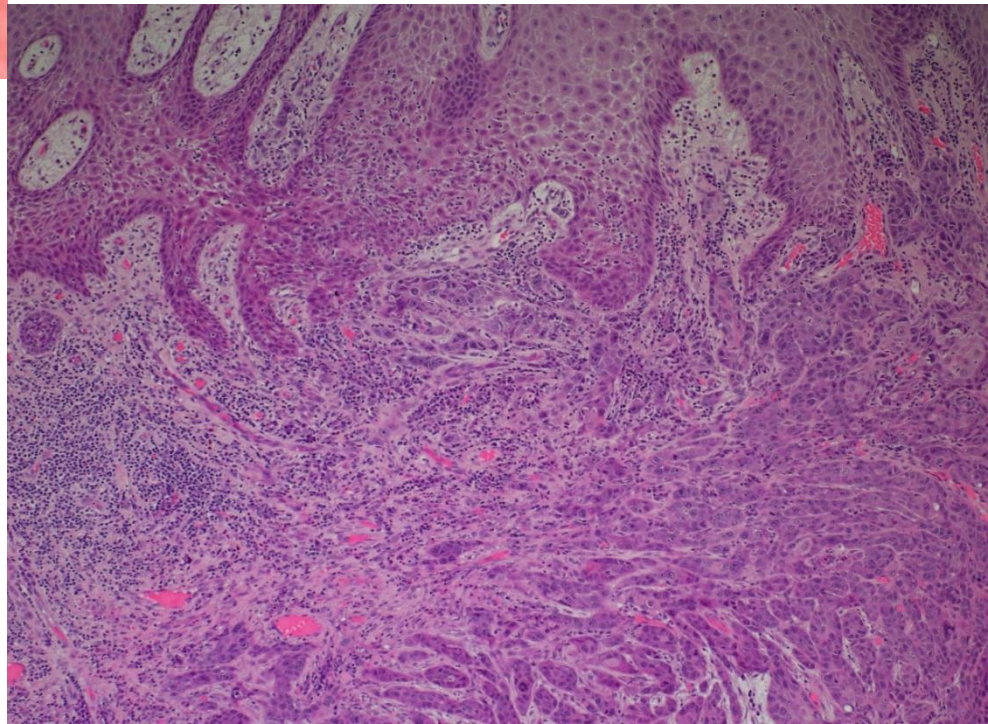
**Keratinizing Squamous Cell  
Carcinoma.**  
*(H-E stain).*

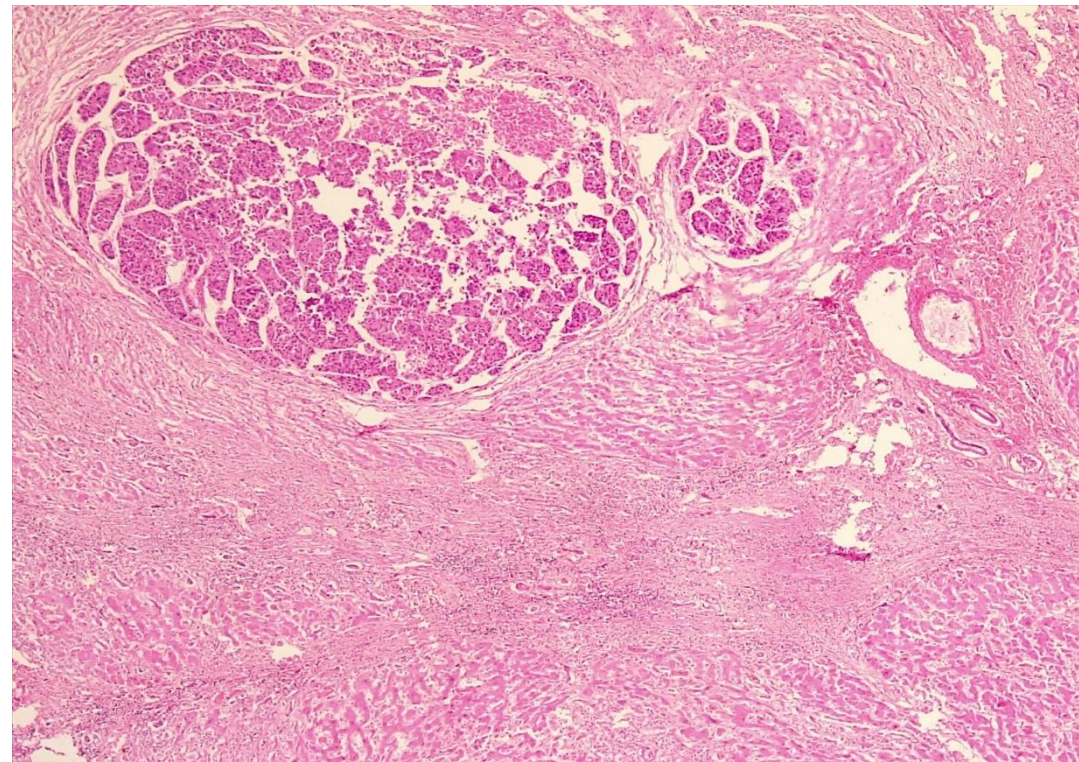
**Scirrhous (fibrous) carcinoma.** *(H-E stain).*  
*(Hepatocellular carcinoma with scirrhous  
pattern ).*





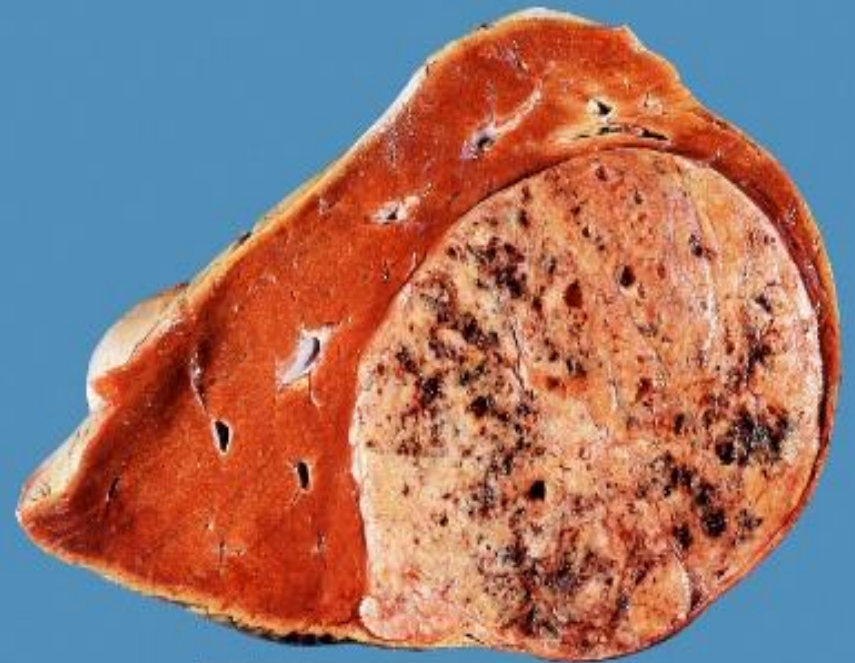
**Oral nonkeratinizing squamous cell carcinoma.**



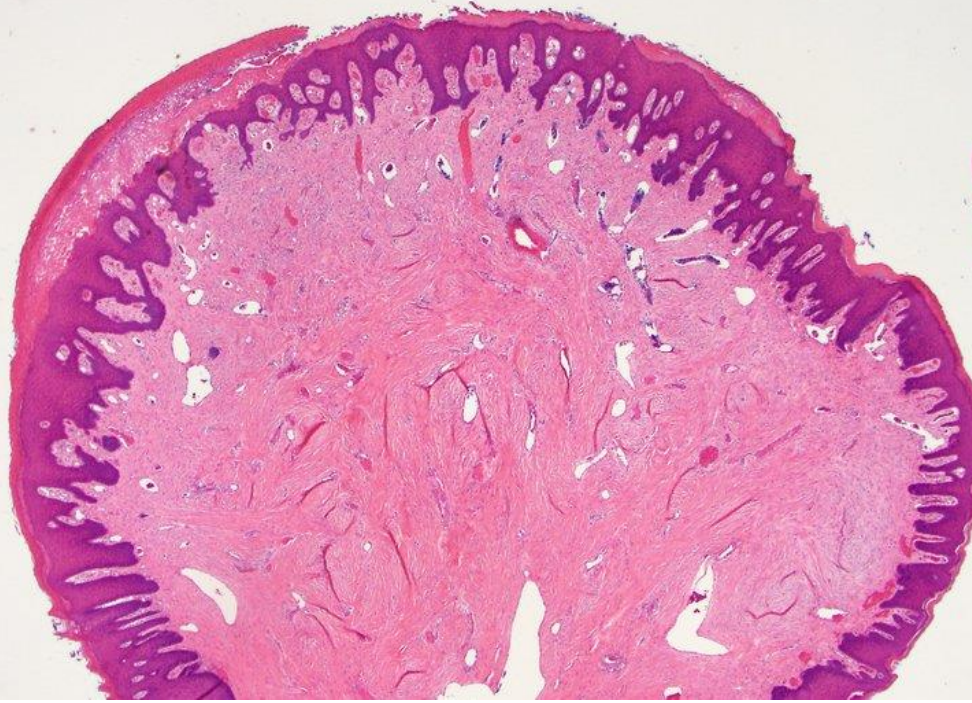


**Nodular hepatic carcinoma.**

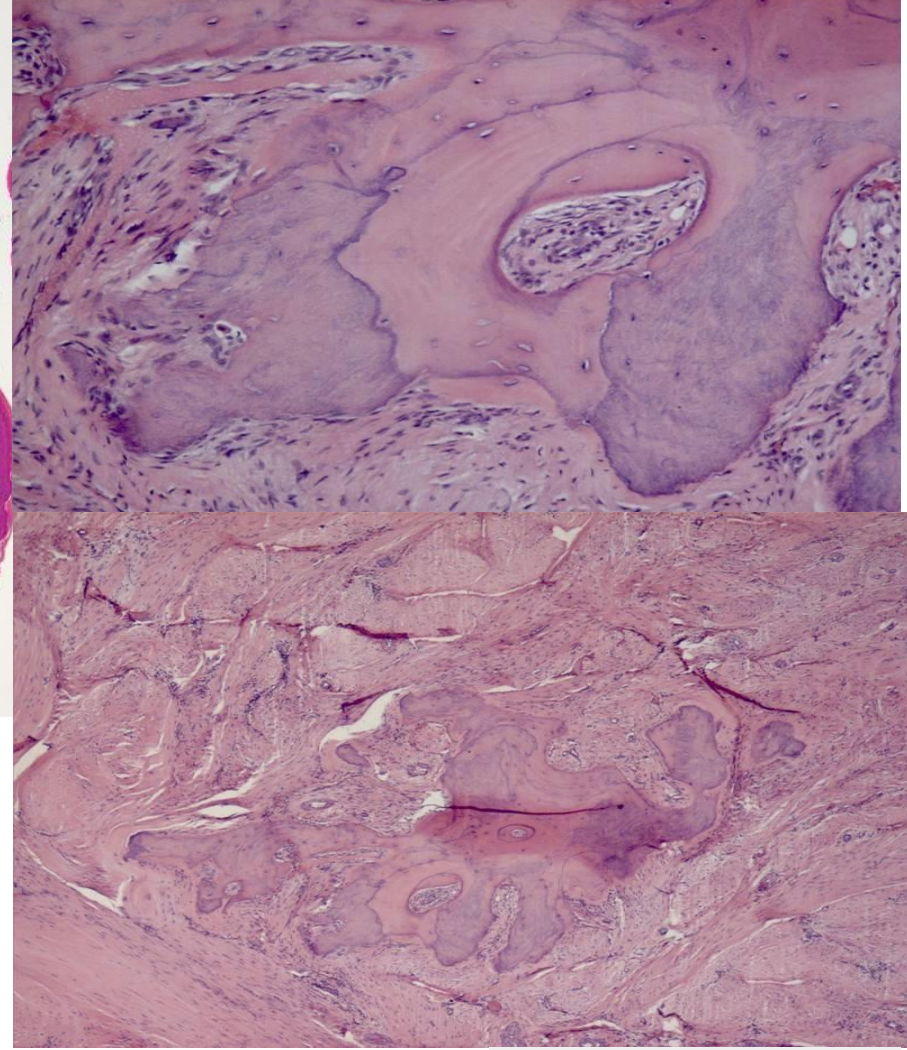
**Cellular atypia in hepatocellular carcinoma.**  
*(H-E stain).*



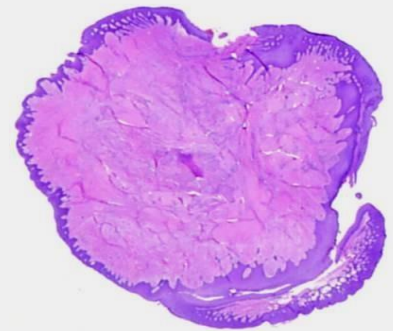


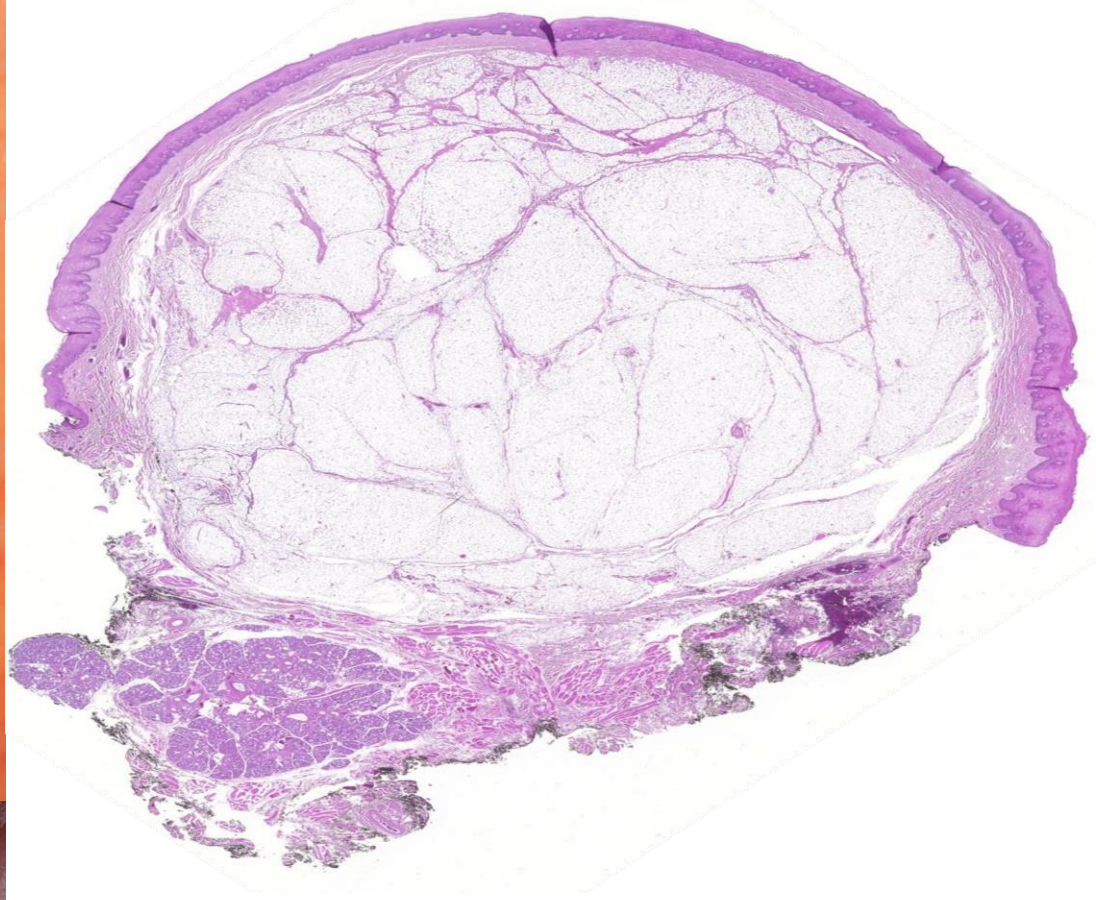
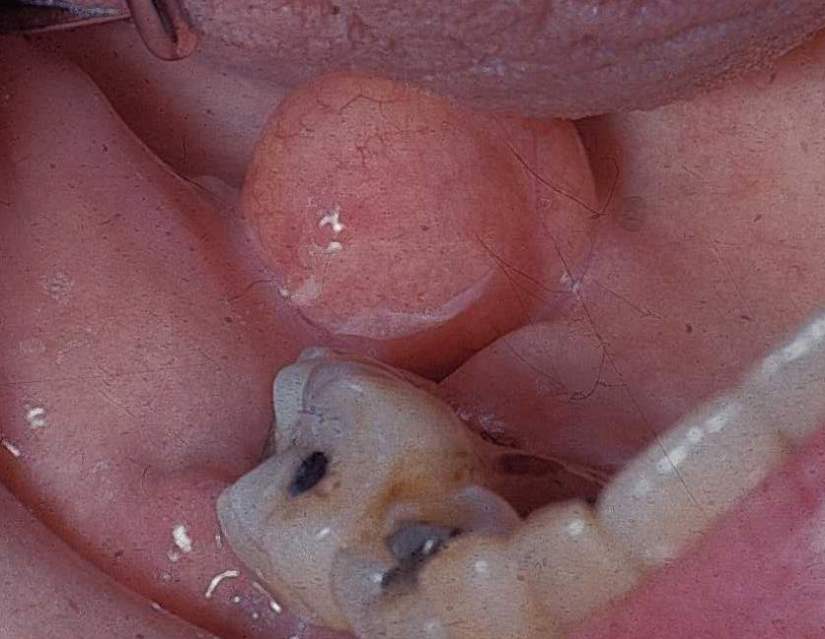
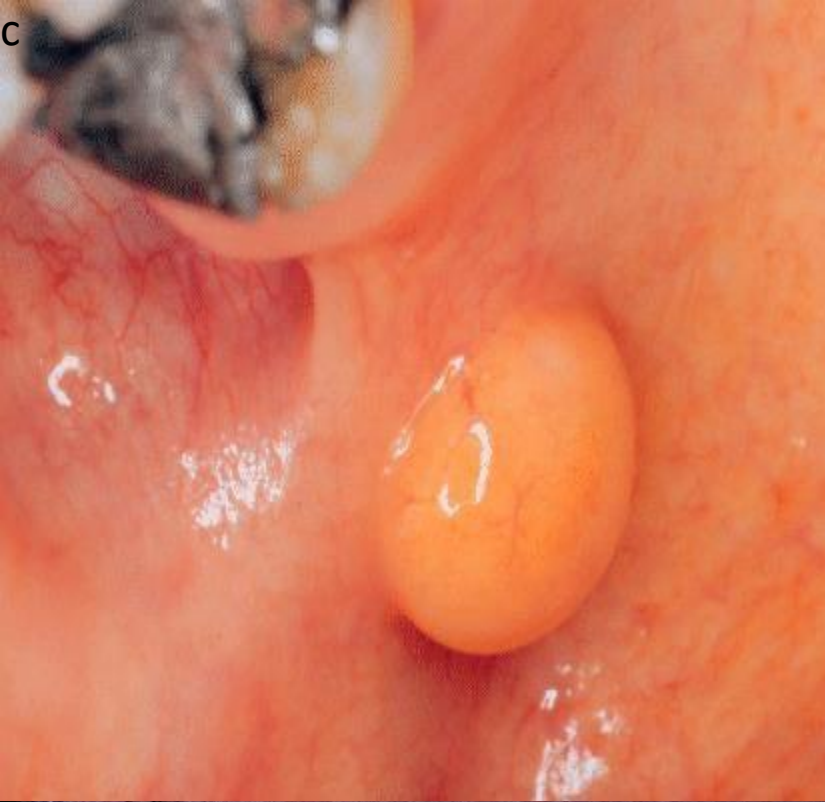
**Oral fibroma.**

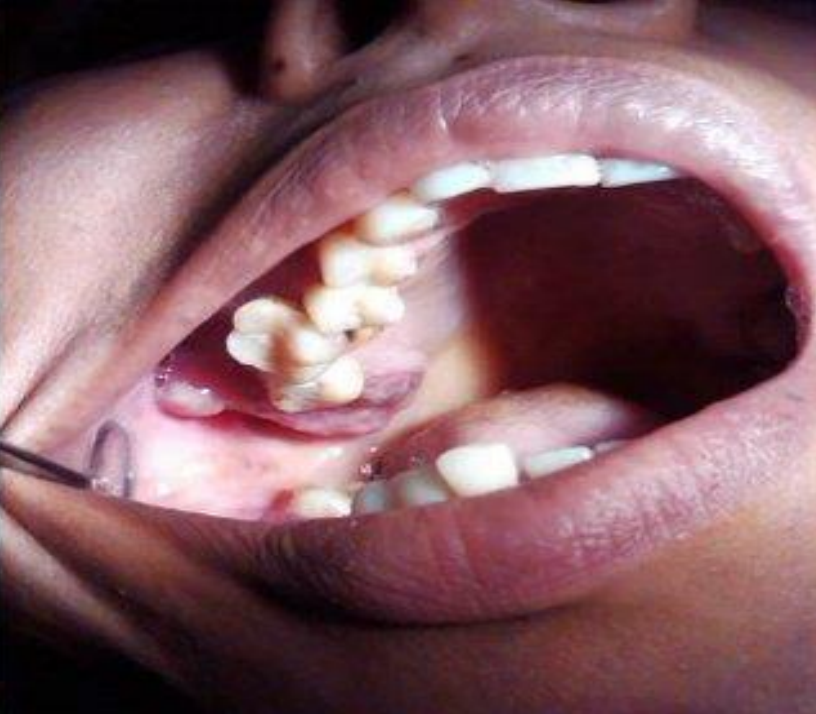

**Oral peripheral ossifying fibroma.**

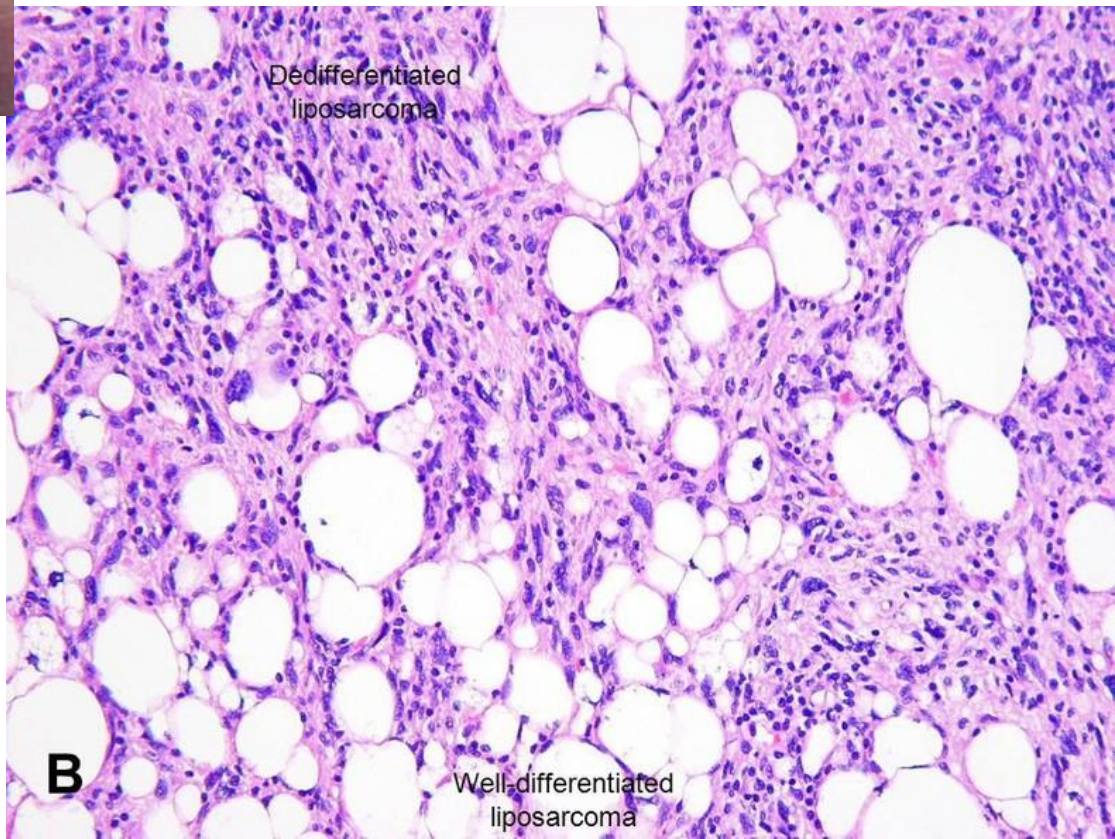


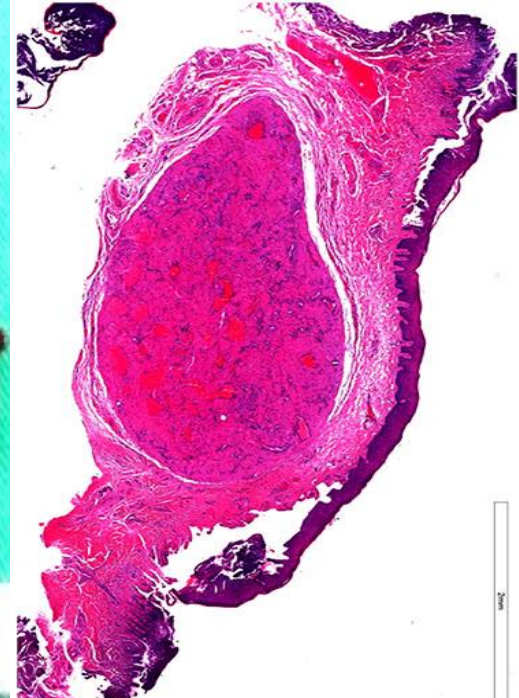
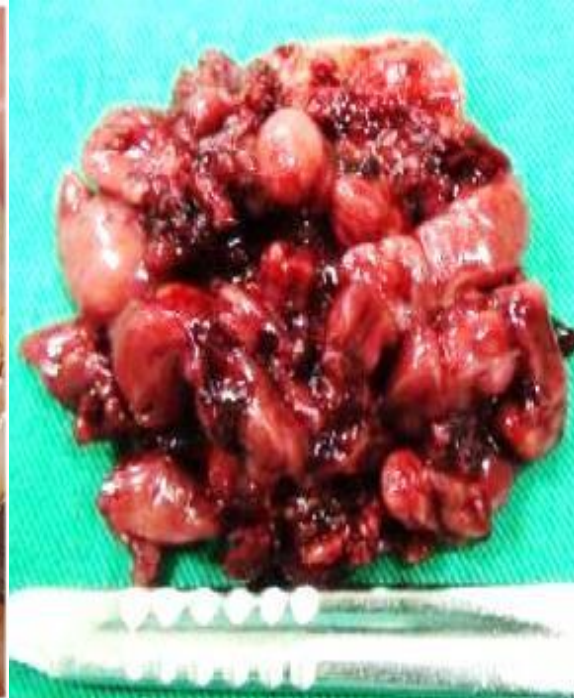
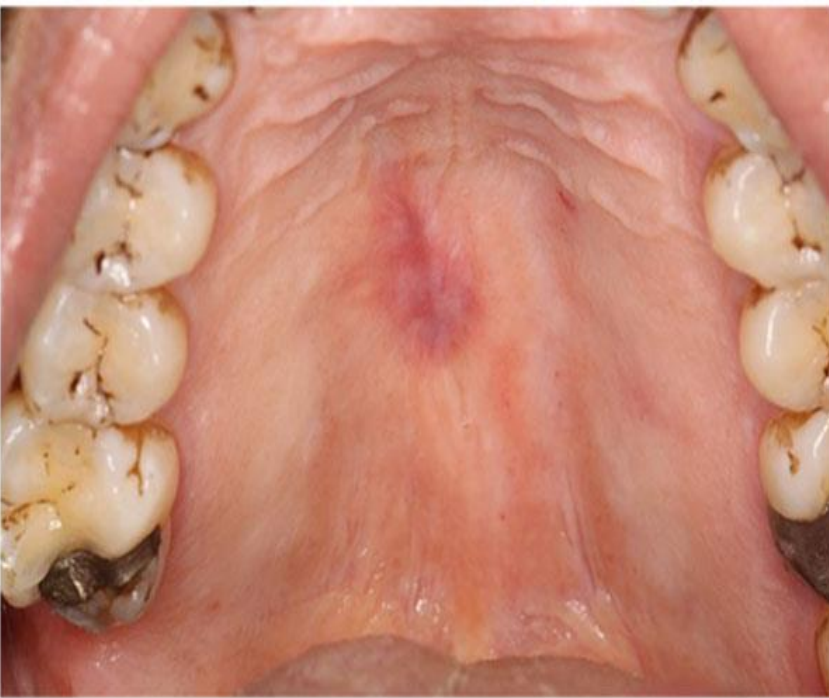
**Oral lipoma.**

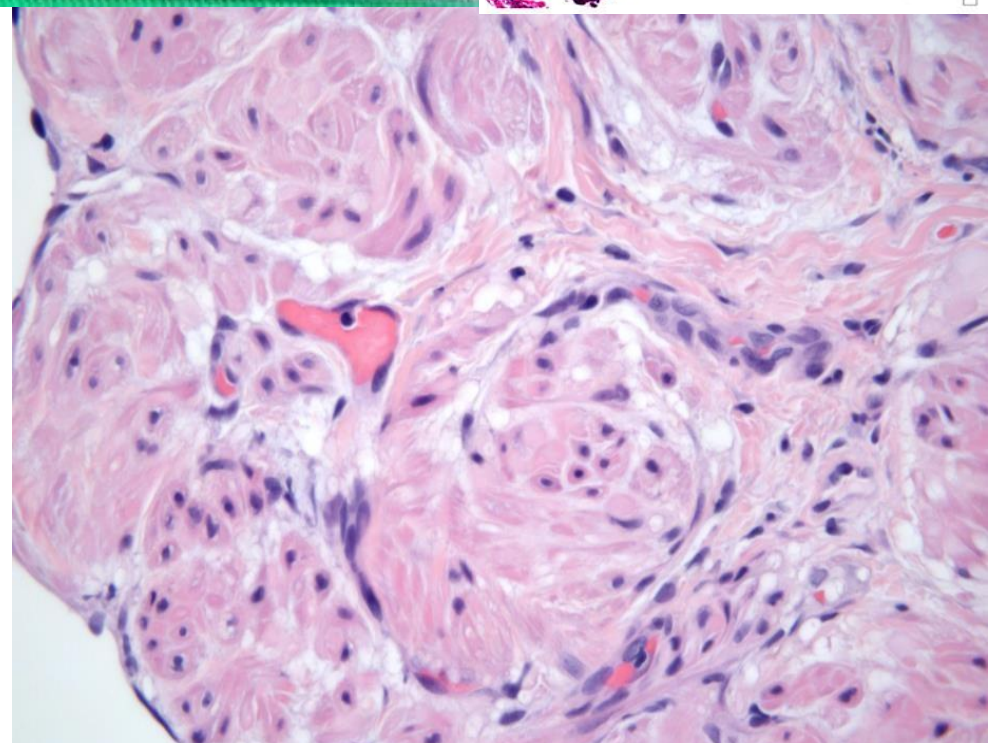


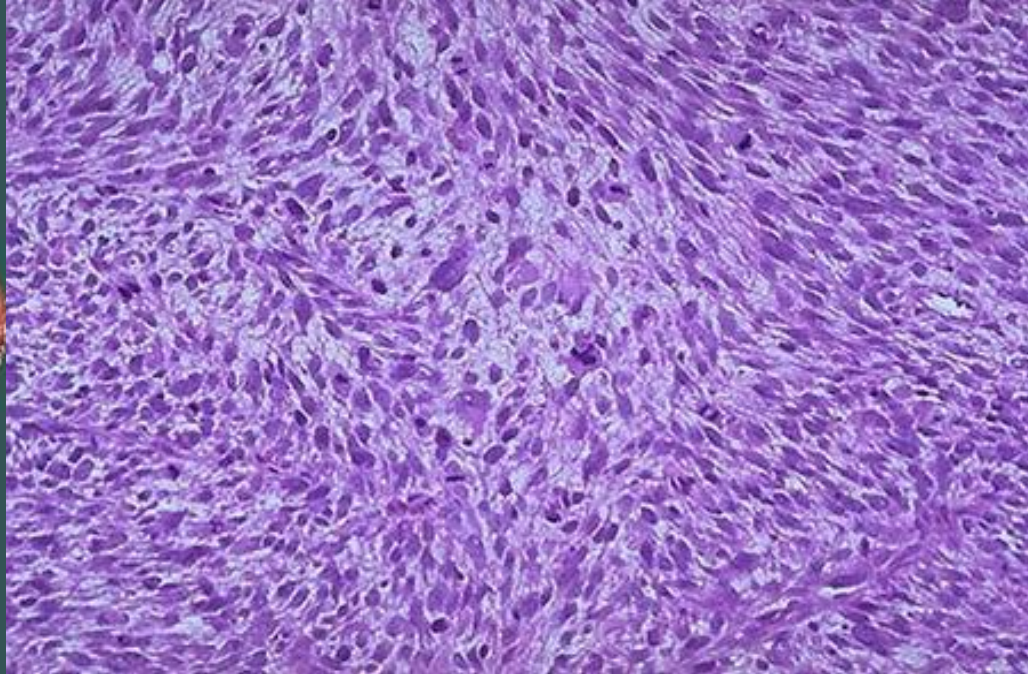
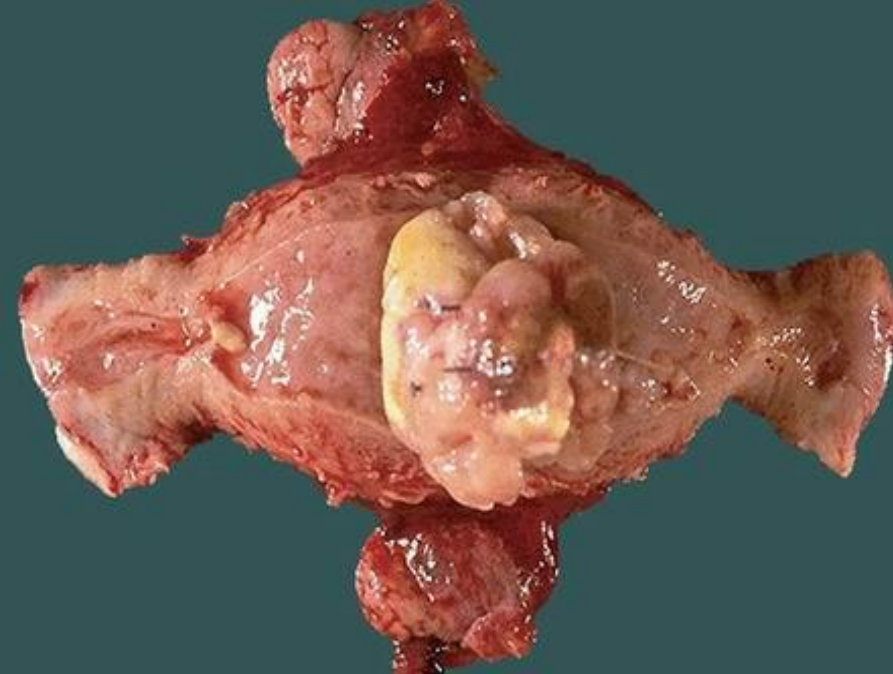
## Oral liposarcoma.





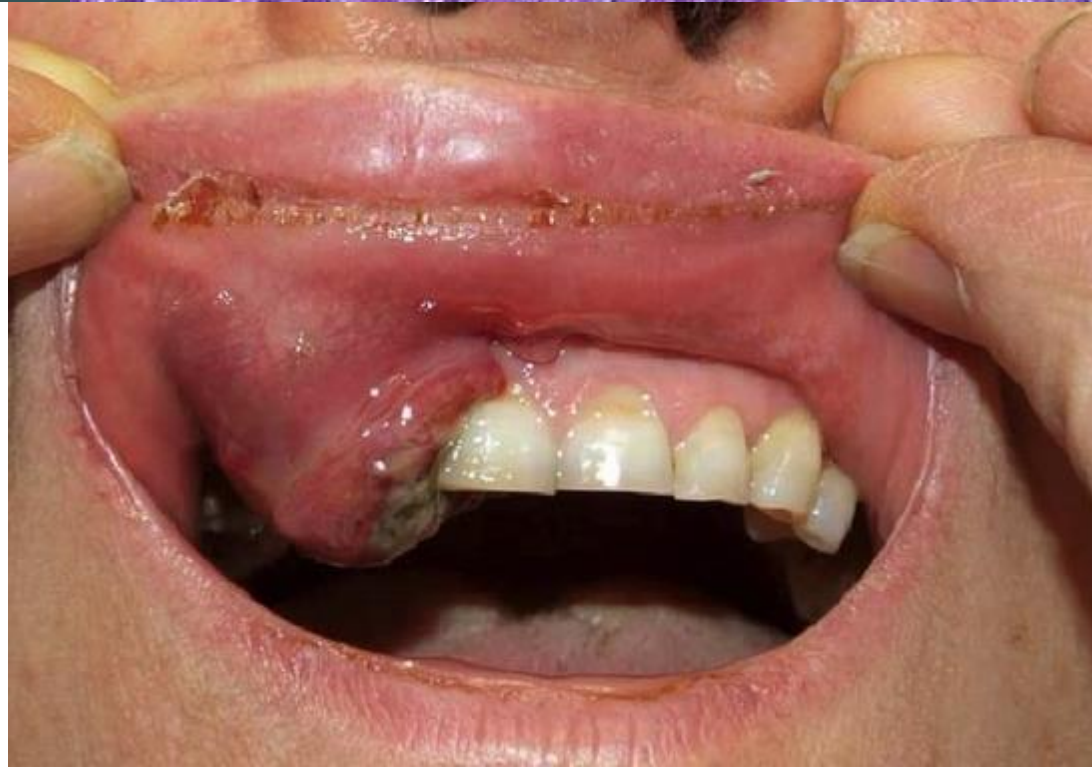**Oral leiomyoma.**

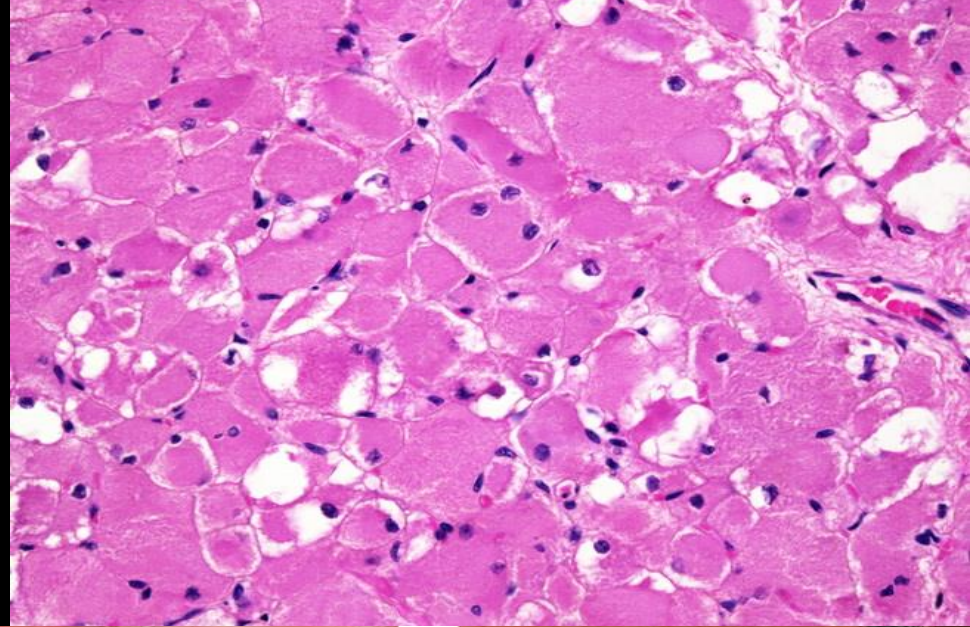




**Uterine leiomyosarcoma.**

**Metastatic uterine leiomyosarcoma in the upper buccal gingiva.**

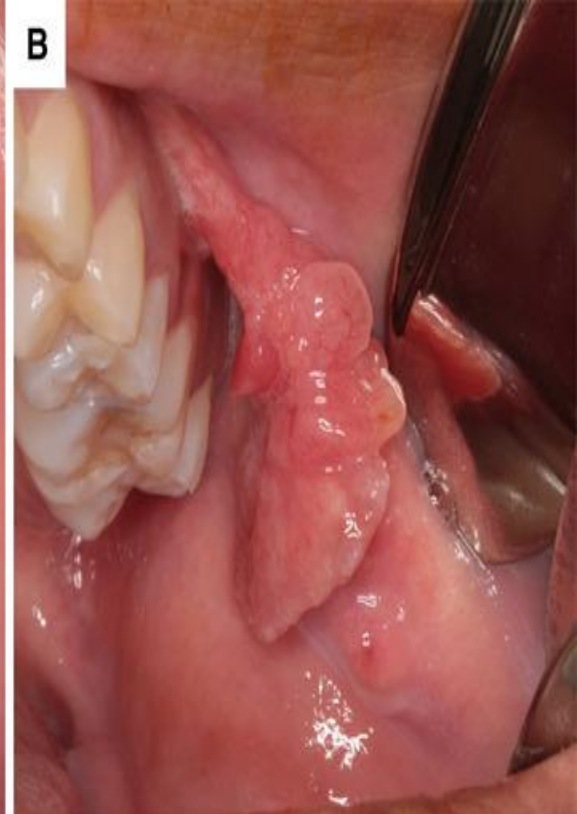
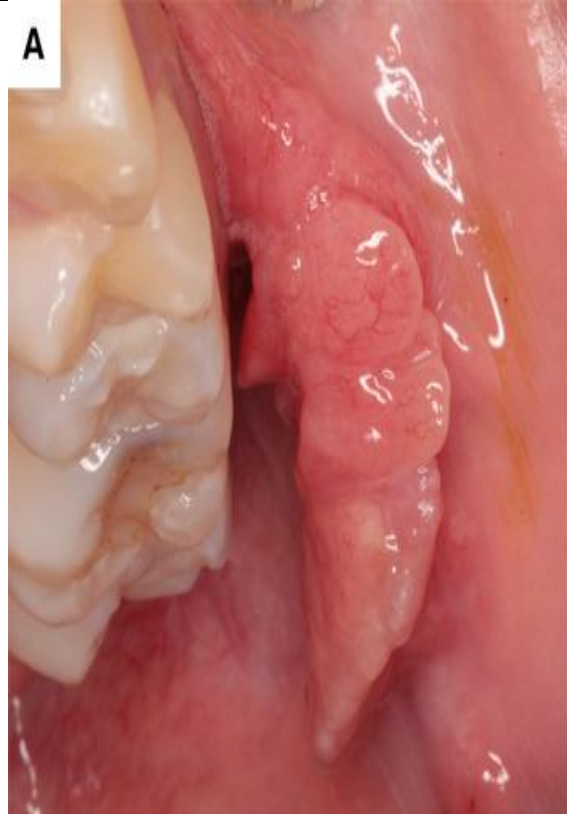


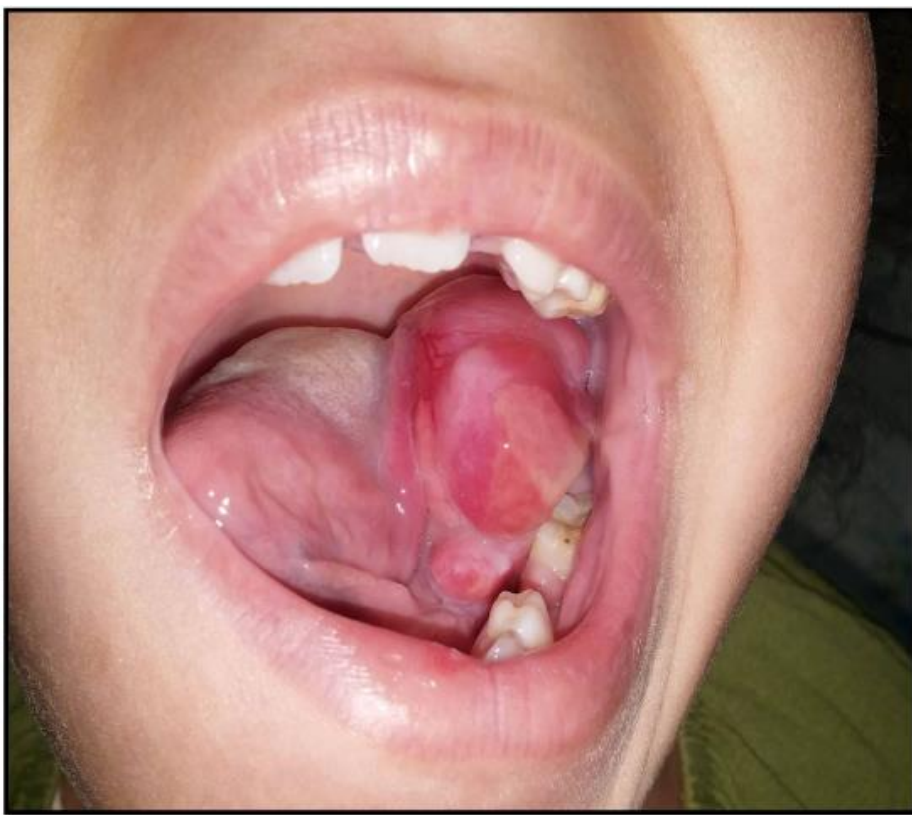
**Cardiac rhabdomyoma.**

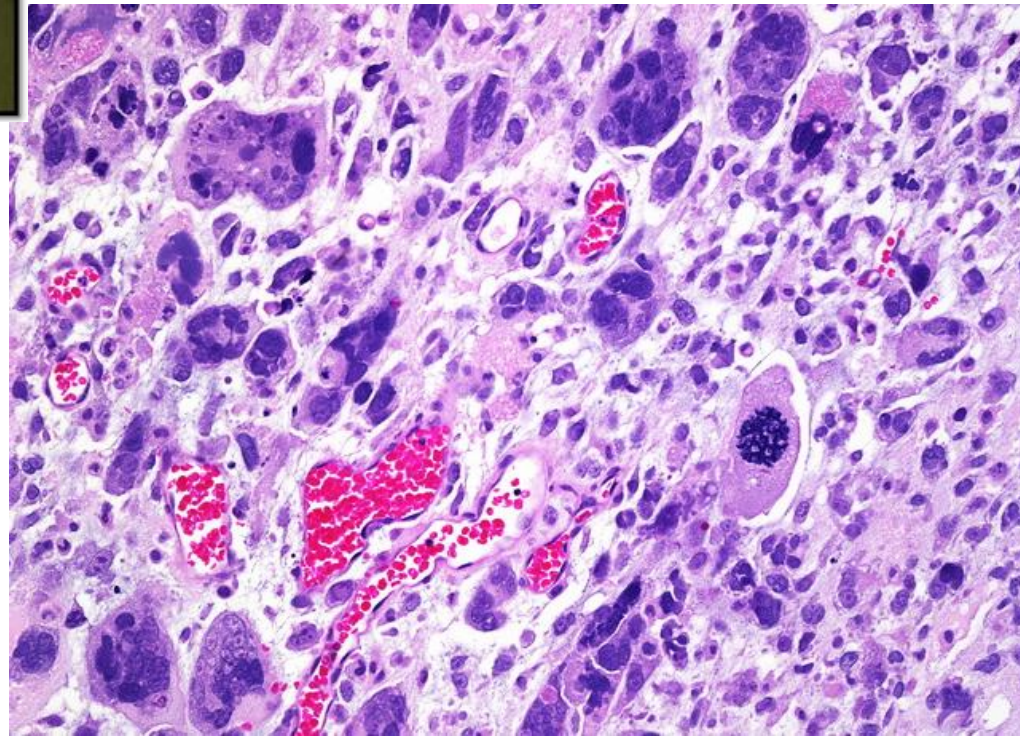


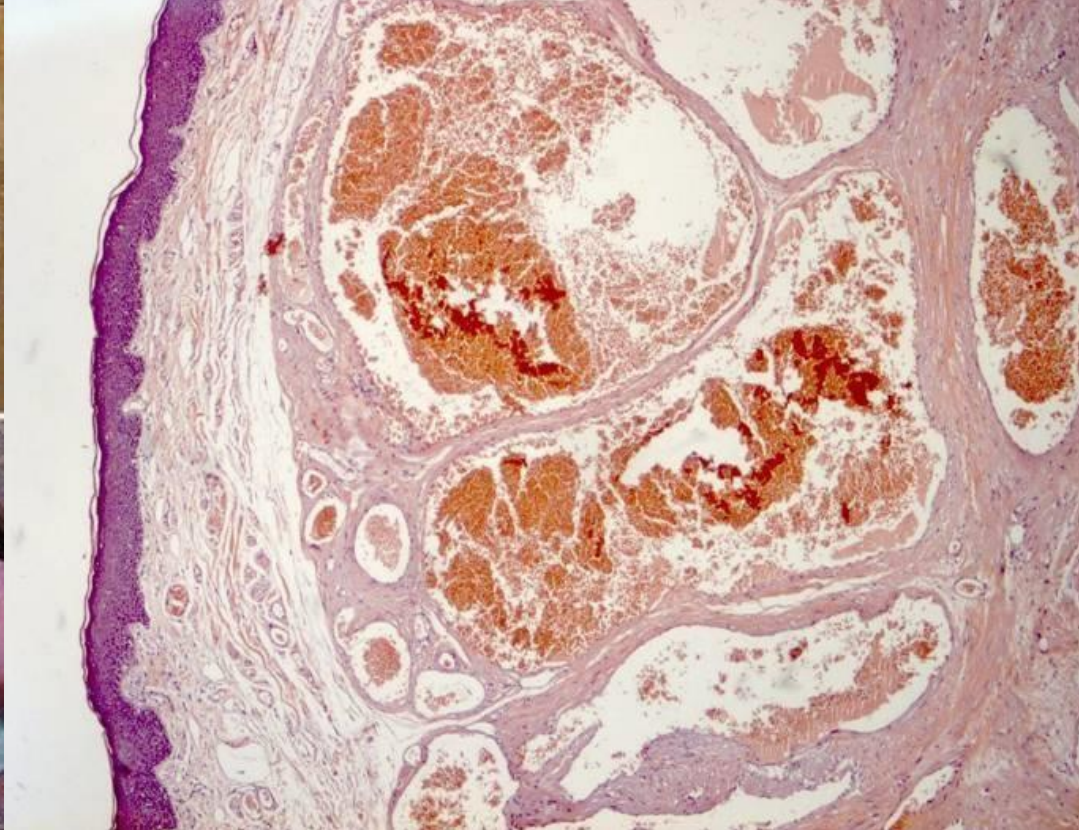
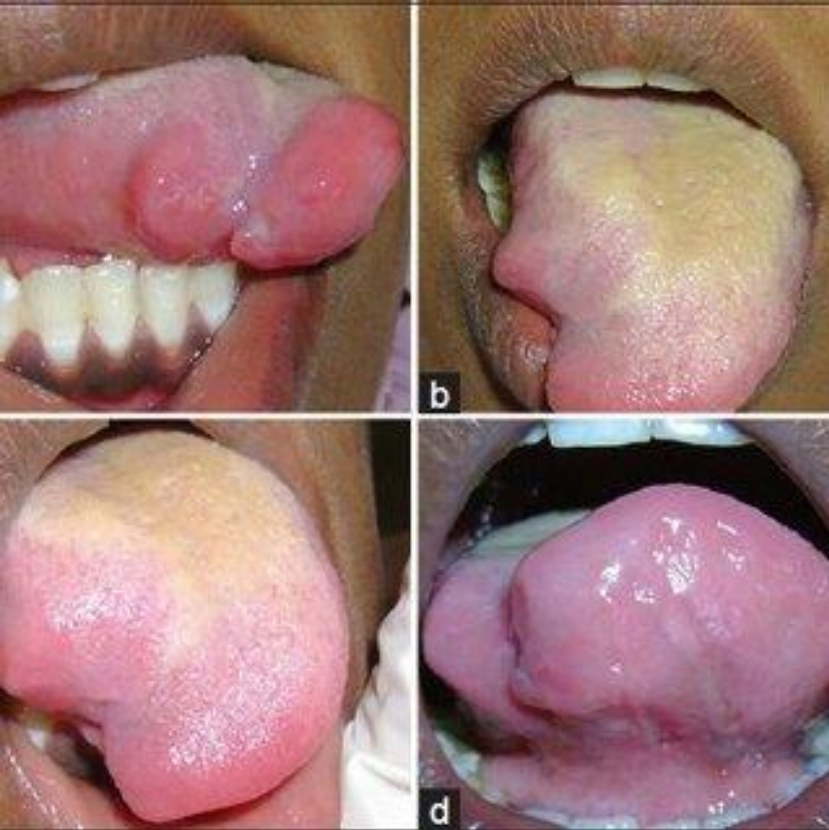**Oral rhabdomyoma.**



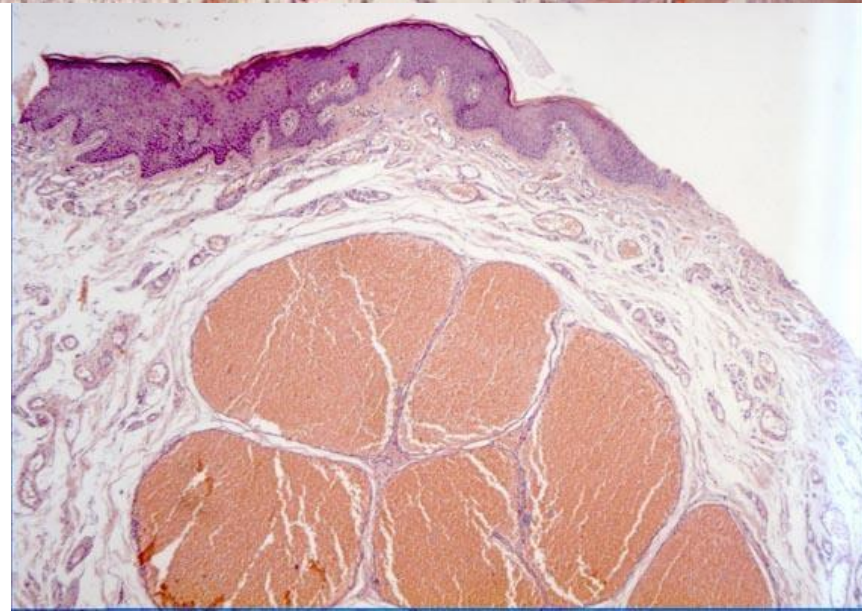


**Oral rhabdomyosarcoma.**





**Oral hemangioma.**





# Definition

- ▶ **Tissue neof ormation** constituted by cell proliferation with three characteristics:
  - **persistent** growth
  - **unlimited growth**
  - high degree of biological **autonomy**
- ▶ The proliferating cells **can come from any tissue**.
  - the tumor will always have **tissue structure** and not the organ and may have different degrees of resemblance to the normal tissue of origin.
- ▶ Synonyms - **neoplasm** or **neoplasm** (neo = new, plasien = to form - newly formed "tissue mass").

Factors that can cause tumor development are called - carcinogens.

It is considered that 80% - 90% of human cancers result from the action of environmental factors through their mutagenic action.

Theories of carcinogenesis:

- T.C. Chemical
- T.C. Physicists
- T.C. viral

T.C. Chemicals - chemicals substances with carcinogenic effect

- Polycyclic aromatic hydrocarbons (cigarette smoke - lung cancer)
- Azo dyes (aniline) in the rubber industry – carcinoma of urinary bladder
- Amines and aromatic amides (naphthylamine) - Metals (Co, Ni, Pb)
- Substances produced from plants and fungi (aspergillus flavus, aflatoxin B1 - liver Cr.)
- Immunodepressants (Cyclophosphamide)
- Asbestos - Lung Cr., pleural mesothelioma
- Arsenic - Skin Cr
- Hormones - estrogen
- Breast, endometrial CR.

In chemical carcinogenesis, the following are important:

- The dose and duration of the action of the chemical.

- The path of penetration into the body -  
The physico-chemical nature of the substances.

R.T. Physical: - ultraviolet rays - CR of skin or malignant melanomas located on the exposed parts of the sun

- electromagnetic radiation - pulmonary CR in the mines from the mines with radioactive deposits

- leukemias following the atomic explosion H. and N., CR of the thyroid gland (Chernobyl), treatment with radioactive isotopes.

They induce mutations through the action on DNA

R.T. Viruses: Viruses that contain DNA

- HPV - cervical cancer - Epstein-Barr associated with Burkitt lymphoma, nasopharyngeal CR, B-cell lymphoma, Hodgkin lymphoma,

- Hepatitis B viruses, C.

Viruses containing RNA

- human T-cell lymphoma virus

## **Name of tumors**

- multiple names
- In general, tumors are referred to with the suffix “oma” - lipoma, myoma.
- Some tumors are called by the name of the organ where they developed, the name also indicating the cells from which they derive - hepatoma, meningioma.
- Some tumors are named after the authors who described them - Wilms tumor, Grawitz

# Classification of tumors

\* Biological evolution criterion:

- **benign tumors** - do not invade locally and do not give distant metastases

- **malignant tumors** - invade locally and give distant metastases

\* For differentiation:

- macroscopic aspects

- cytological and histological characters

- degree of influence of the organism

SINGLE POSSIBILITY OF DIFFERENTIATION -

**PATHOLOGICAL DIAGNOSIS !!!!**



## Effects on the body

### Benign tumors

- changes induced by compression
- hormonal activity
- do not recur after complete surgical resection or even if recurrences do not destroy local tissues and are the consequence of incomplete excision.
- do not invade locally and do not give distant metastases (the risk of a tumor diagnosed as benign on morphopathological criteria to generate distant metastases is below 1 case in 50 000 tumors)
- examples - benign fibrous histiocytoma, chronic villonodular tenosynovitis

## Malignant tumors

- invades locally
- distant metastases (the risk of metastasis in sarcomas varies between 20 and 100%, depending on the tumor type)

## ■ Difficulties:

- Tumors that cannot be classified as benign or malignant until they give metastases: ex - pheochromocytoma
- ambiguous situations in which a tumor meets both malignancy and benignity criteria: "tumor with intermediate malignancy" or tumor with potential malignant borderline".

# **Tumors with locally aggressive intermediate malignancy**

- relapses locally after resection
- behaves aggressively against local tissues (they are infiltrative and cause local destruction)
- prototype - desmoid fibromatosis

# **Tumors with intermediate malignancy with reduced risk of metastasis**

- locally aggressive
- risk of distant metastasis in less than 2%  
of cases
- prototype - angiomatoid fibrous  
histiocyoma

# *Macroscopic characters of **benign tumors**:*

- very common and ubiquitous
- they have a tissue mass appearance in the development territory
- they do not invade the surrounding tissues
- well delimited, sometimes encapsulated (easy to remove).

## ■ Macroscopic aspects:

**polyp** - benign tumor developed from the surface epithelia (skin, mucous membranes)

- vegetation with wide implantation base (sessile tumor)

- attached to the surface through a pedicle through which the blood vessels (pedicle tumor) penetrate.

**Node** - benign tumor developed in different tissues and organs - appearance of spherical nodule, compact, with distinct boundaries or capsule

**Cyst**- some deep tumors

- Dimensions: small (from a few mm to a few cm - slow growth rate); some benign tumors can reach important dimensions - of the order of tens of cm - papillary cystadenoma of the ovary, neurofibroma

- Number: usually single but can be multiple, developed simultaneously or in succession (colo-rectal polyps)



## *Microscopic characters*

Tumor tissue, both benign and malignant, is composed of two components: the **tumor parenchyma** (made up of tumor cells)  
**tumor stroma** (made up of connective tissue with blood vessels).

## *Microscopic characters of **benign tumors***

\* Benign tumors reproduce the structure of the origin tissue - multilayered epithelium, glandular epithelium, muscle tissue, adipose tissue, hyaline cartilage etc.

\* Benign tumor cells

- they are differentiated

- have cytological characteristics similar to normal cells

- they retain the function of normal cells (mucus secretion, horny maturation capacity, hormone secretion, etc.).

- Rare and typical mitosis.

- \* The tumor stroma consists of connective tissue, blood vessels and nerve trunks.
- \* Balance between tumor cell proliferation and stroma → no necrosis occurs

## *Evolutionary characters of **benign tumors***

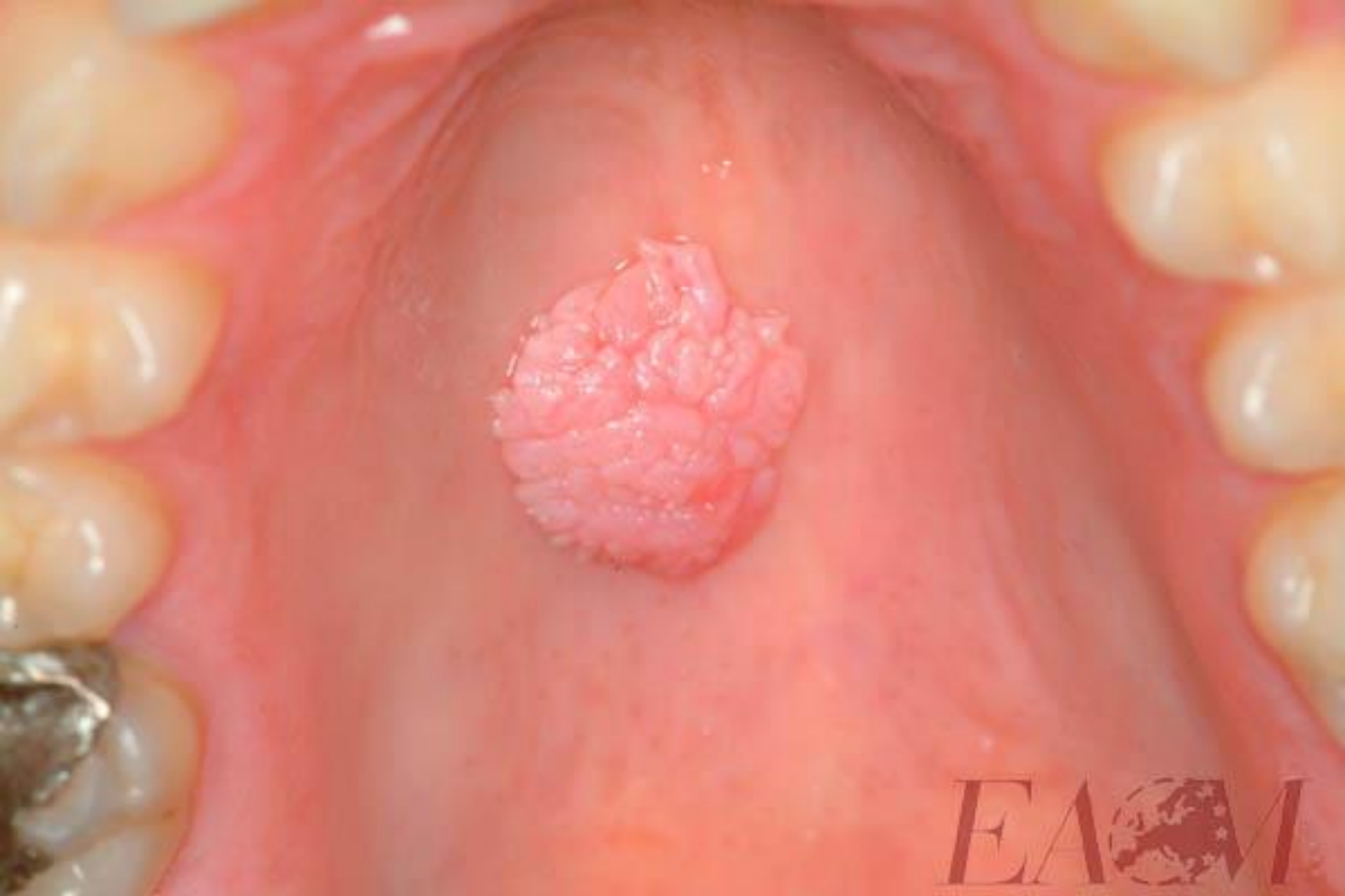- they evolve locally
- they don't invade surrounding tissues
- they don't give metastases
- they don't recur after complete surgical removal.
- does not influence the general state of the body.

### **Exceptions:**

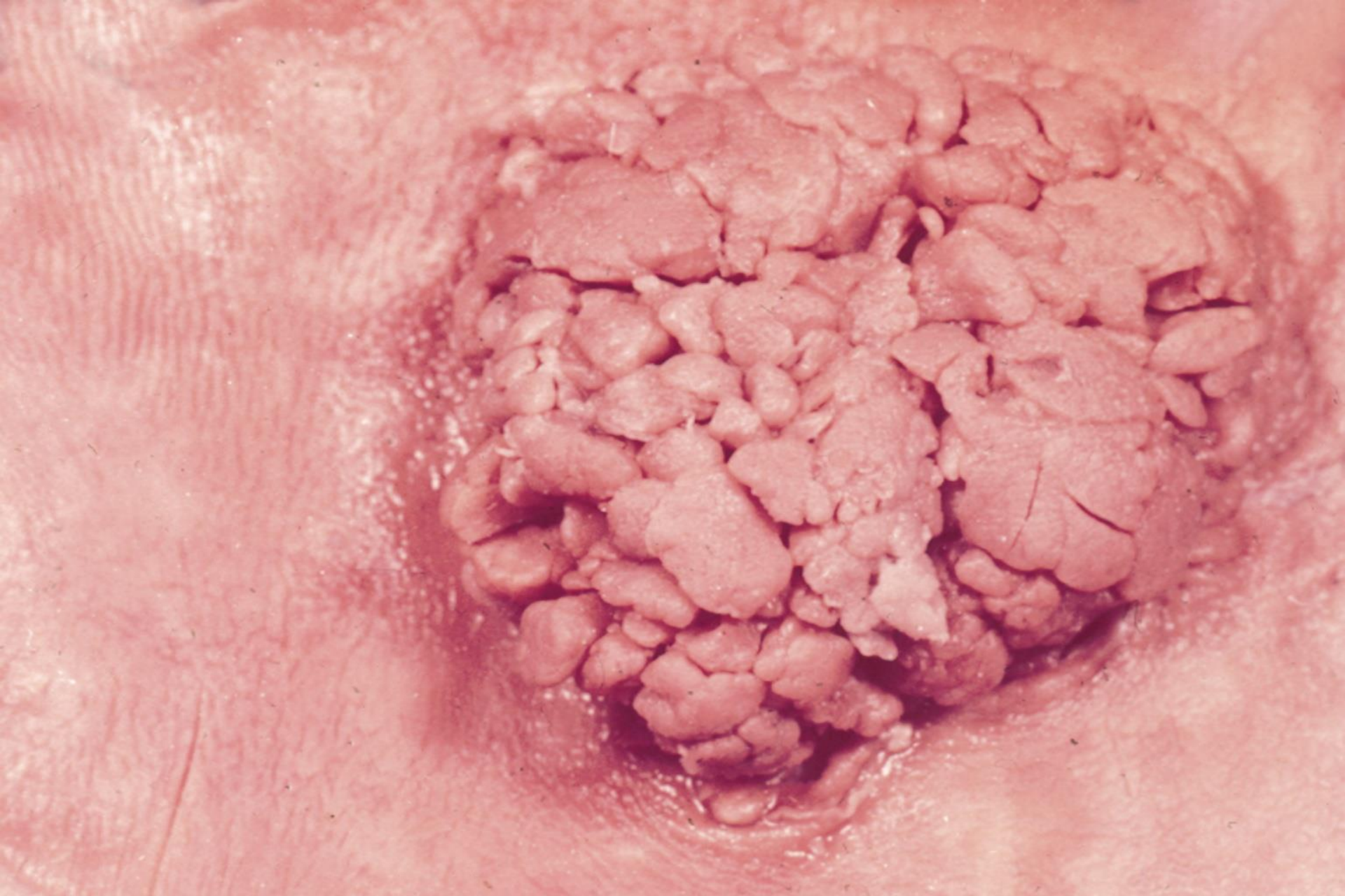Voluminous benign tumors cause local compression

- a large tumor of the uterine muscles that compresses the pelvic organs and determines urinary stasis
- the benign tumor of the meninges compresses the cerebral cortex

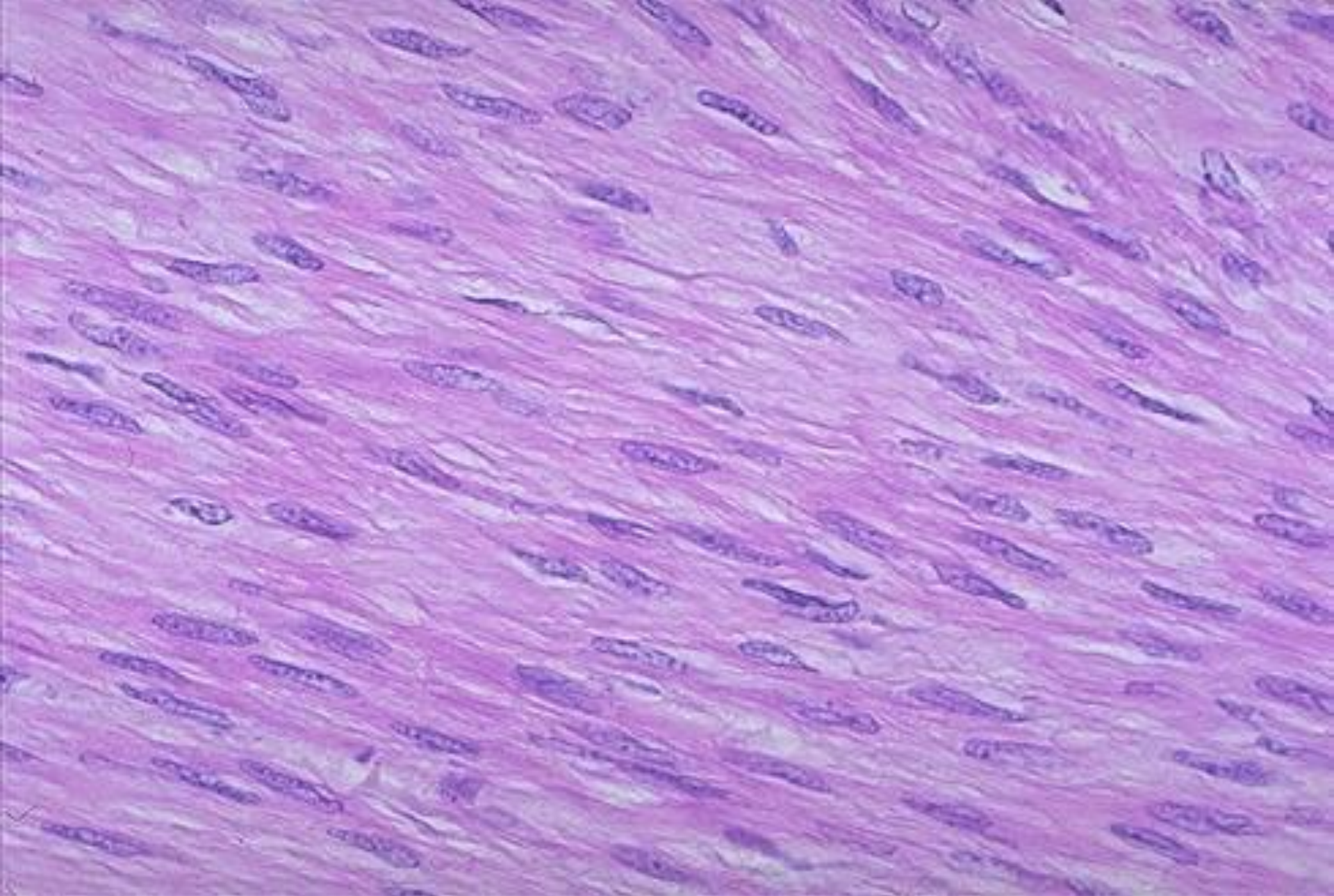
Benign tumors of the endocrine glands may have specific hormonal activity, which causes endocrine dysfunction.



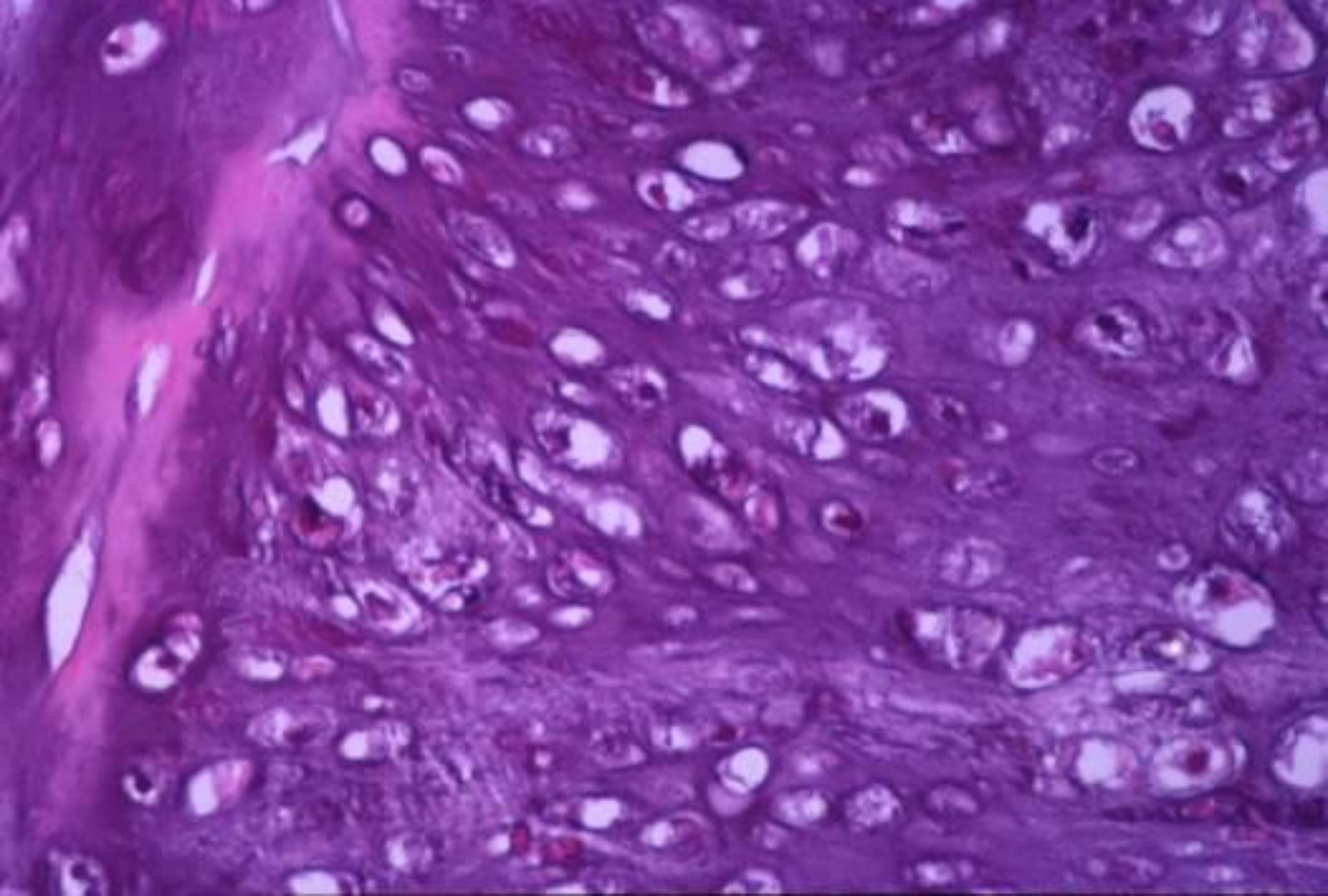
Papiloma of oral cavity



Papilom of thw skin



Leiomyoma



Chondroma



## *Macroscopic characters of malignant tumors*

- tissue mass without distinct boundaries
- local invasive character
- Possible: distinct malignant tumors macroscopically but without capsule (cancer with false encapsulation) - areas of necrosis in the tumor mass.
  - \* In tumors externalized to the surface of the skin or mucous membranes the area of necrosis is eliminated, resulting in ulcerations.
  - \* In deep tumors, central liquefaction leads to the formation of cavities, mimicking a cavern - possibly, if the tumor invades a conduit - for example a bronchial branch - the liquefied necrotic content can be eliminated resulting in a cavity (cavitation phenomenon).
- large size - fast growth rate.
- the color and consistency depend on the histopathological type.

## *Microscopic characters of malignant tumors*

Tumor parenchyma: Cancer cells are different from normal ones through a whole set of changes in cell character, nucleus, cytoplasm and nuclear membrane = cytological malignancy criteria:

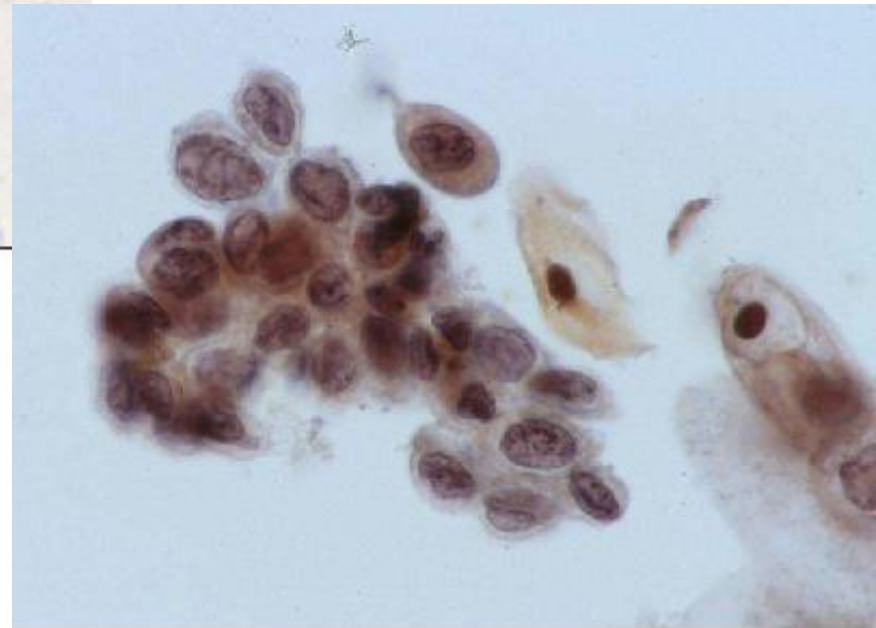
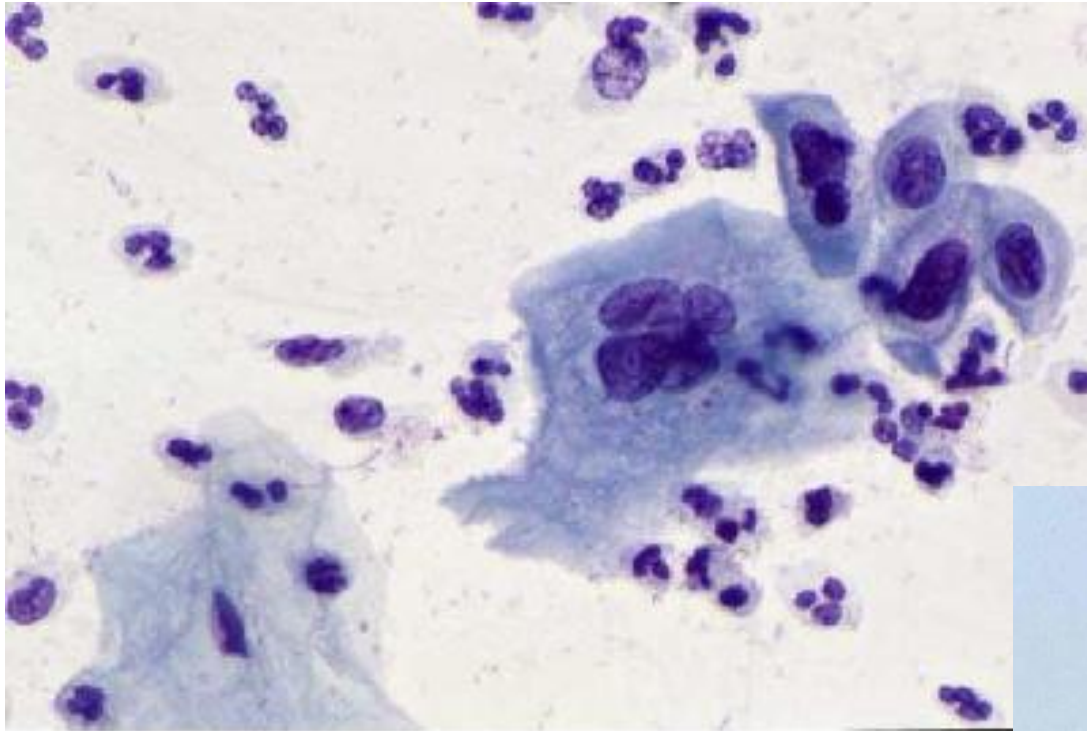
- Anomalies of shape and size
- Nuclear anomalies
- Cytoplasmic abnormalities
- Cellular membrane abnormalities
- The arrangement of the tumor cells is different from the normal one:
  - architectural changes

# **Cytological criteria for malignancy**

## ***Form and size abnormalities:***

The appearance of cancer cells varies from small, uniform, to large, round, oval or elongated cells, sometimes monstrous (cellular pleomorphism).

# Pleomorphism: variation in size and shape



## **Abnormalities of the cell membrane**

The membrane of the cancer cell shows changes in the chemical composition, changes that influence the behavior of the cancer cell against the normal cell, both in vivo and in vitro. In the membrane the glycoprotein and glycolipid fractions are reduced (these changes being due to the blocking of synthesis).

## ■ Cytoplasmic abnormalities

In cancer cells the cytoplasm is reduced quantitatively (a situation that contributes to the increase of the nucleo-cytoplasmic ratio. The cytoplasm of the malignant cells is more basophilic than normal due to the presence in the cytoplasm of numerous ribosomes (containing RNA - so nucleic acid that stains with hem). In the cytoplasm, accumulations of glycogen, lipids, monoclonal immunoglobulins, mucus - depending on the type of cell of origin - mucus retention determines the peripheral displacement of the nucleus, giving the cell the appearance of a "ring with seals".

■ **Nuclear anomalies** most suggestive for malignancy - anisocarrria (carios = nucleus, isos = identical, an = no) - dimensional inequalities; they will always be larger than the cells of origin, in some cases leading to the inversion of the nucleo-cytoplasmic ratio in favor of the nucleus.

- Hyperchromatosis - color more intense than normal - high affinity to the basic dyes

- nuclear pleomorphism - the shape of the nuclei is variable

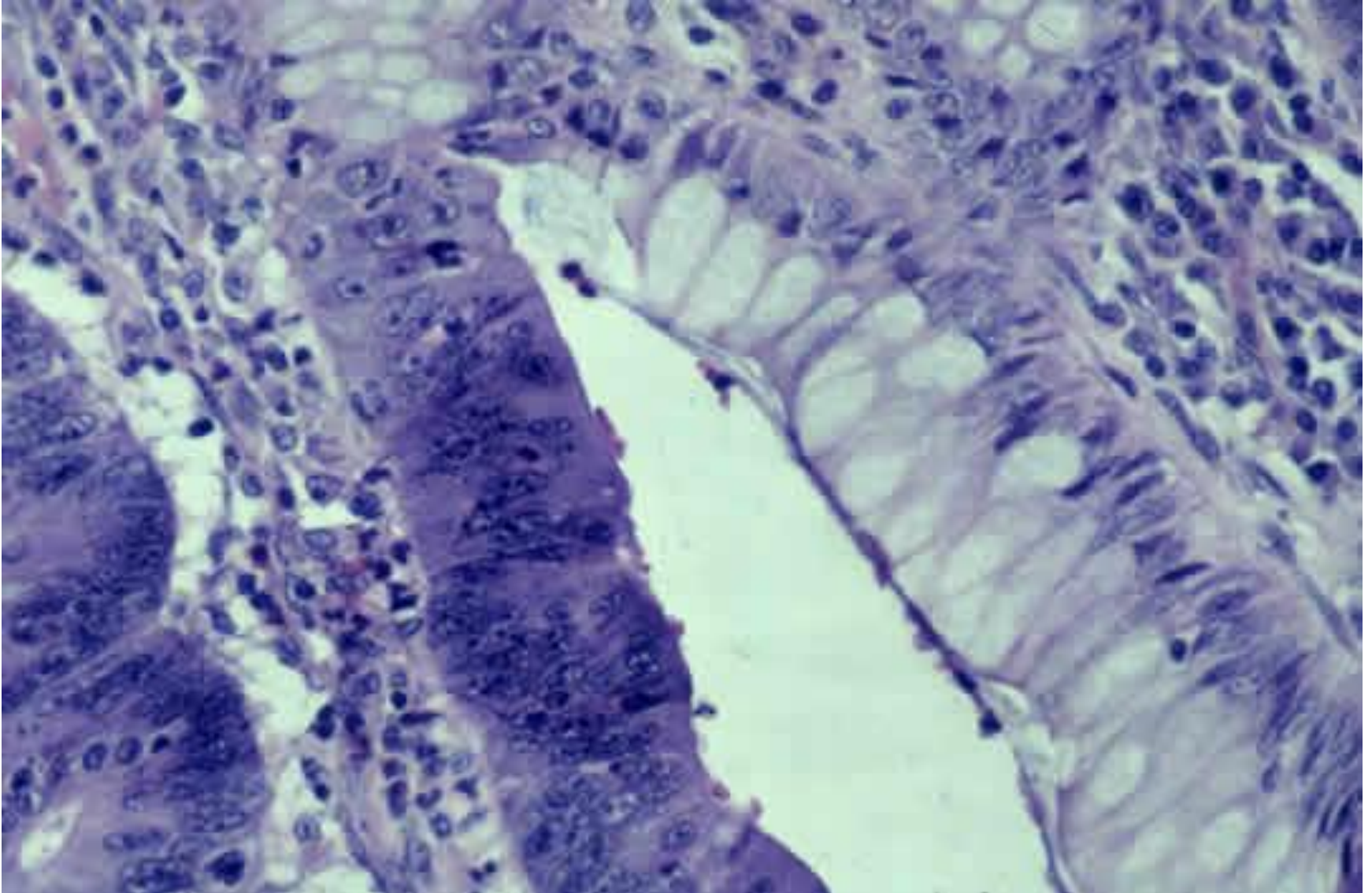
- there may be multinucleated tumor cells

- The nucleoli of cancer cells, due to their very active cellular metabolism, are hypertrophied, vesicular, multiple, sometimes with anomalies - pseudovesicular, fibrillary or granular inclusions.

- The mitotic index is higher than in normal cells: Typical bipolar mitosis  
Atypical mitosis.

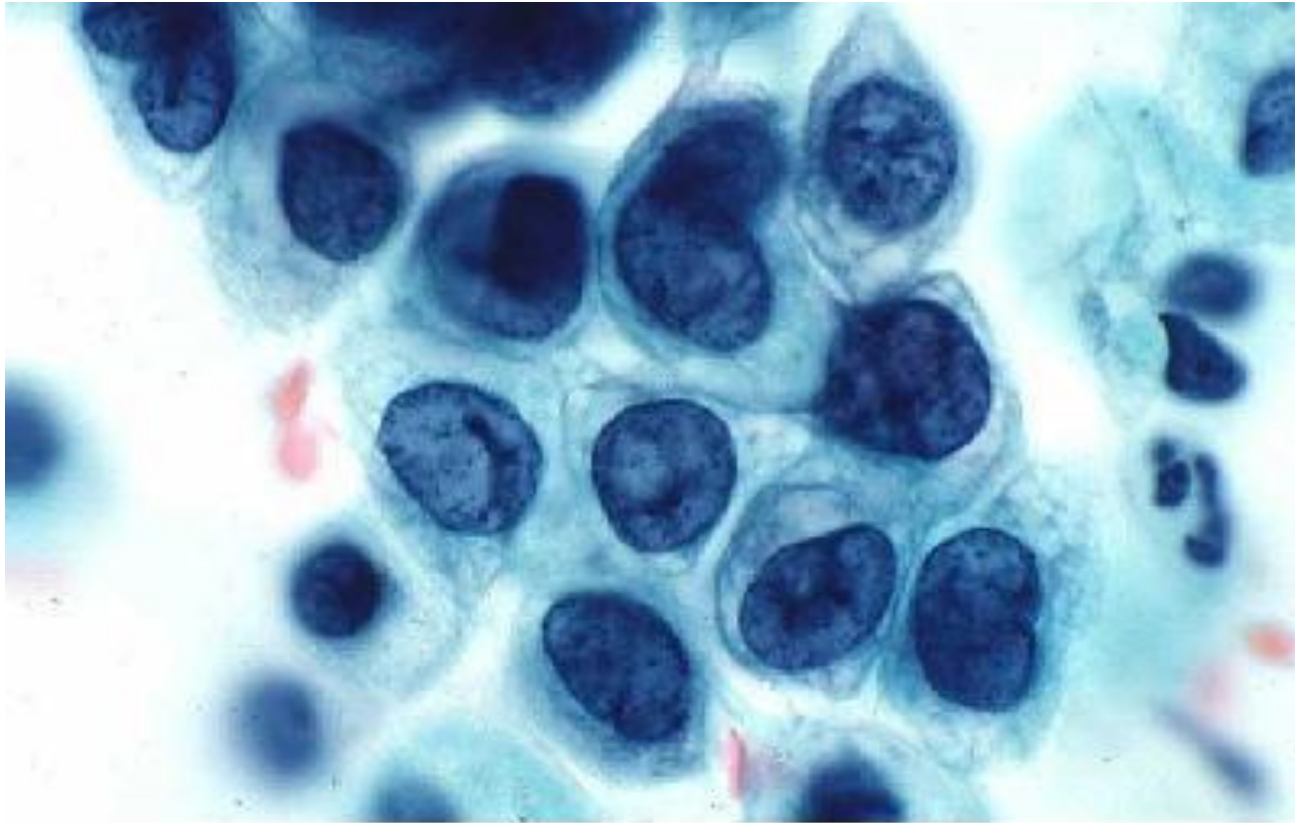
**NOTE:** the presence of typical mitosis, even in large numbers, can be detected in normal tissues (for example, hematogenous bone marrow) or in hyperplastic processes; the presence of atypical mitosis is reported only in malignancies.

# Loss of polarity

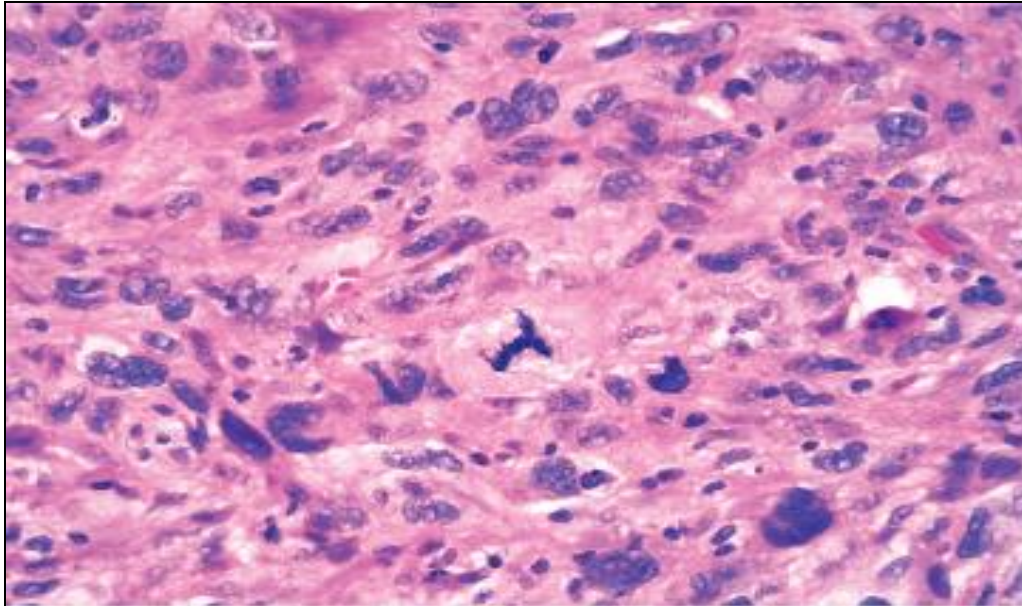




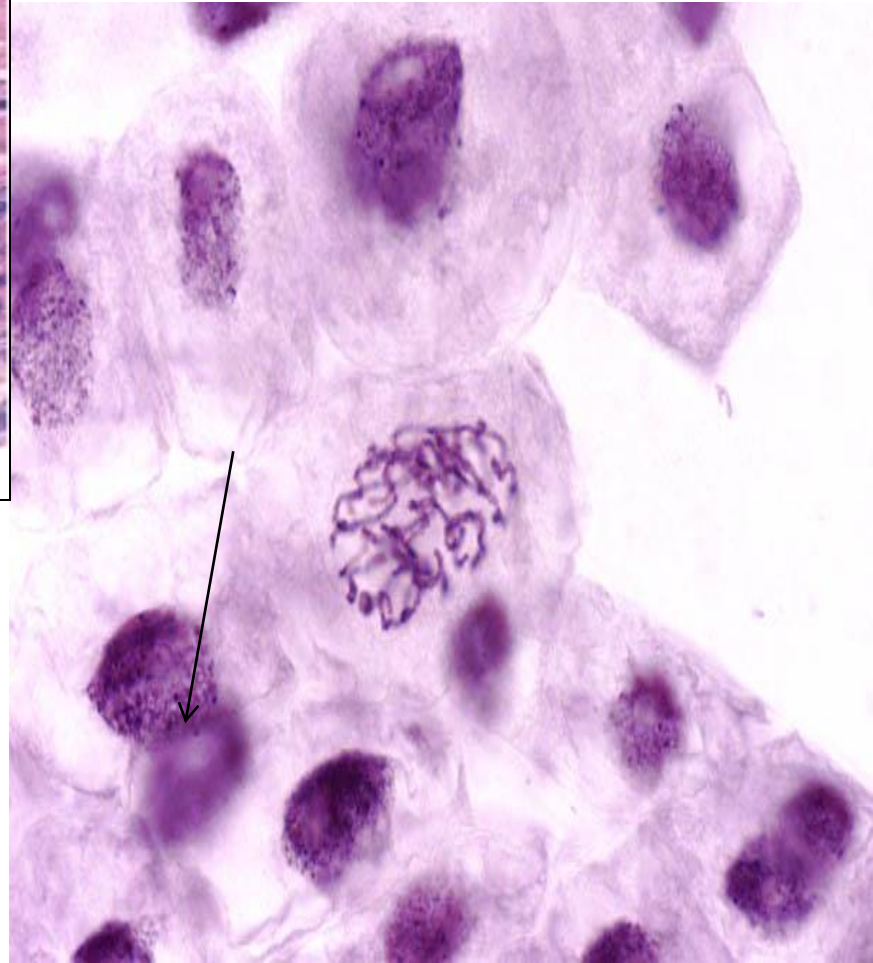
**Abnormal nuclear morphology: hyperchromatic (abundant DNA), increased N:C ratio (normal 1:4-1:6)**



# Mitosis: multiple, bizarre



© Elsevier 2005



# **Malignant tumor stroma**

- is formed as a result of the interaction between cancer cells and normal tissues of the host organism.
- consists of common connective tissue, consisting of blood and lymphatic vessels
- The vascularization of the tumor is provided by the connective stroma which is connected to the arteriovenous pedicle of the tumor tissue. Tumor vessels consist exclusively of capillary networks and arteriovenous venous anastomoses that favor circulatory shunts.

■ **Tumor angiogenesis** is precocious and conditions the proliferation of cancer cells. It is stimulated by angiogenic factors secreted by cancer cells.

- In malignant tumors the stroma is insufficient compared to the degree of proliferation → necrosis

- The treatment may target angiogenic factors - the conjunctival stroma varies quantitatively

\* well developed in tumors of epithelial nature and lower in those of conjunctive nature

\* reduced stroma - the consistency of the tissue is reduced and areas of necrosis and haemorrhages that are explained by the fragility of the capillary vessels in the composition of the tumor or vascular obstruction with consecutive ischemic necrosis occur frequently.

\* abundant fibrous conjunctival stroma - desmoplasia → hard, woody consistency (squirrel cancer).

■ **Microscopically**, the conjunctival stroma presents variable aspects.

- In most cases it is accompanied by inflammatory reactions to cancer cells (stromal reaction); infiltrates may be neutrophils, lymphocytes, plasmocytes, macrophages.

- Sometimes eosinophilic infiltrate (eosinophilic stroma) predominates.

- In the stroma, a granulomatous inflammatory reaction of the tuberculoid type can sometimes be highlighted.

The stroma can be reshaped by the type found in the common connective tissue: hyalinization, elastogenesis, amyloid accumulation, calcifications.

## Differentiation and anaplasia

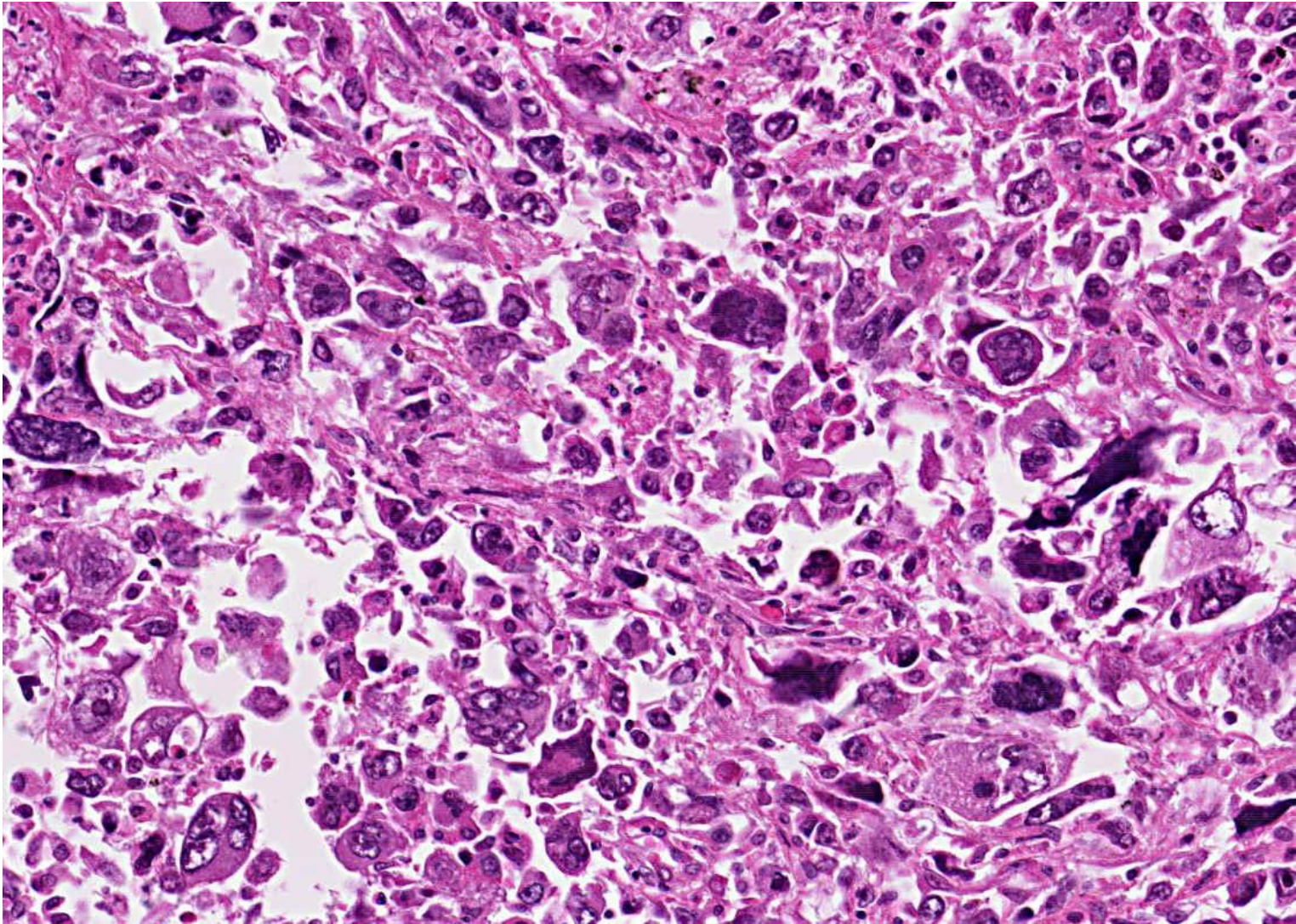
- Differentiation is appreciated by comparing the resemblance with the origin tissue (cancer is differentiated when the histological characters resemble the origin tissue and undifferentiated when it loses any resemblance to the origin tissue).
- The assessment of the degree of microscopic differentiation of the cancer has value for diagnosis (in the assessment of prognosis and evolution).
- Differentiated cancer - the histological diagnostic criteria concern the organization of the tumor tissue (architecture - in tubular, cordal structures, etc.) and the functional characters (presence of mucus secretion, immunoglobulins, horny differentiation, etc.).

Tumor architecture and cytologic characters suggest the origin of tumor proliferation.

■ Undifferentiated cancer - tumor tissue has a compact architecture - thick beaches and trabeculae. Cancer cells are immature, sometimes embryonic in nature, with no evidence to suggest the source cell. The origin of the tumor is difficult to determine by optical microscopy and requires immunohistochemical examinations (to determine the presence of certain antigens - for example cytokeratins in carcinomas, melanocyte antigen HMB 45 in malignant melanomas etc.).

- Anaplasia (lack of differentiation) is considered to be the basic feature of malignant transformation.

# Anaplasia





- **Anaplasia** must be separated by differentiation - cancers originate in stem cells (present in all specialized tissues) - transformed stem cells that proliferate by differentiating more (differentiated cancers) or less or even (non-differentiated cancers). Differentiation involves cell regression from a mature cell to a less mature one.
  - Anaplasia is inversely proportional to the differentiation - the more a tumor is differentiated, the lower the anaplasia degree The degree of anaplasia is noted with G and varies from 1 to 4

## Local invasion

- the ability of cancer cells to progressively penetrate and replace normal peritumoral tissues.
- it is accompanied by the simultaneous development of the stroma, an element necessary for the growth of the tumor tissue.
- it is favored by the
  - \* increased rate of cancer cell multiplication.
  - \* ability to mobilize cancer cells
  - \* secretion of enzymes with cytosolic and histolytic action by cancer cells.
- it is made through the interstitial spaces, preformed cavities, along the nerve trunks, of the small blood and lymphatic vessels.
- They resist the invasion of hard tissues (bone tissue, cartilaginous tissue) and large arteries (they are more resistant than large veins due to the large amount of elastic tissue and the presence in the arterial walls of some tumor protease inhibitors).

## *Malignant Tumor Dissemination*

- Leads to Metastasis Formation
- Metastases are secondary tumors, an effect of disseminating cancer cells away from the primary tumor.
- The occurrence of metastases transforms localized cancer into a systemic disease, metastases being more frequently the cause of death than the primary tumor.
- Pathways of metastasis:
  - lymphatic
  - hematogenous
  - mixed (lympho-hematogenous)
  - transcelomic
  - natural pipes

## *Effects of malignant tumors on the body*

### *Direct complications*

- Bleeding - common in surface cancers. They can be abundant and repeated in vegetative cancer. They can be massive in ulcerated cancer (stomach, cervix).

- **compression**, for example - mechanical jaundice by compression of the bile ducts (pancreatic head cancer), atrophy of the cortico-adrenal by compression by a retroperitoneal tumor

- **Obstructions and stenoses** in the cancers of the organs of the cavity - esophageal cancer (dysphagia), colon cancer (subocclusion, occlusion)

- **Cancerous cachexia** - metabolic factors and polypeptide substances with inhibitory action of normal cellular metabolism.

## ■ Indirect complications

- paraneoplastic syndromes: secretion of ectopic hormones
- haematological repercussions: leukocyte abnormalities (leukopenia, leukemoid leukocytosis, eosinophilia - over 10%), venous thrombosis
- infections associated with malignant tumors
- fever: non-tumoral resorption

## General characteristic of tumors

Criterion	Benign tumors	Malignant tumors	Tumors with locally destructive growth
Growth rate	Slow	Rapid	Slow
Degree of differentiation of tumor cells	Mature, differentiated cells	Immature, undifferentiated cells	Mature, differentiated cells
Atypism	Tissular	Tissue, cellular (ultrastructural, biochemical, histochemical, antigenic)	Tissular
Growth character towards adjacent tissues	Expansive	Infiltrative (invasive)	Infiltrative
Tumor boundaries	Clear, precise (encapsulated)	Blurred, unclear	Blurred, unclear
Metastasis	No metastasis	Metastasis	No metastasis
Recurrence	No relapse	Relapse	Relapse
Clinical, morphological evolution	Can turn malignant	Cannot turn benign	Can turn malignant

## TNM coding

- The therapy and prognosis of malignancies depend on the location and degree of tumor extension.
- In order to establish the degree of tumor extension, it was necessary to develop standardization systems with practical utility.
- The TNM system is the most widely used in the clinic.

It responds to two major objectives. In the individual case of the cancer patient it allows the evaluation of the tumor extension by clinical and paraclinical methods - TMN establishes groups of homogeneous cases for the evolutionary assessment under the action of the treatment.

- In the TNM system are considered - the local extension of the T tumor (depending on the affected organ, the criteria of appreciation differ - dimensions - breast cancer, invasion in the thickness of the wall of the tubular organs - gastric, colonic, urinary bladder, invasion in different segments of of the uterus - cervical cancer etc.)
  - presence of lymphoganglionic metastases - N
  - presence of distant metastases (other than lymphoganglionic) - M

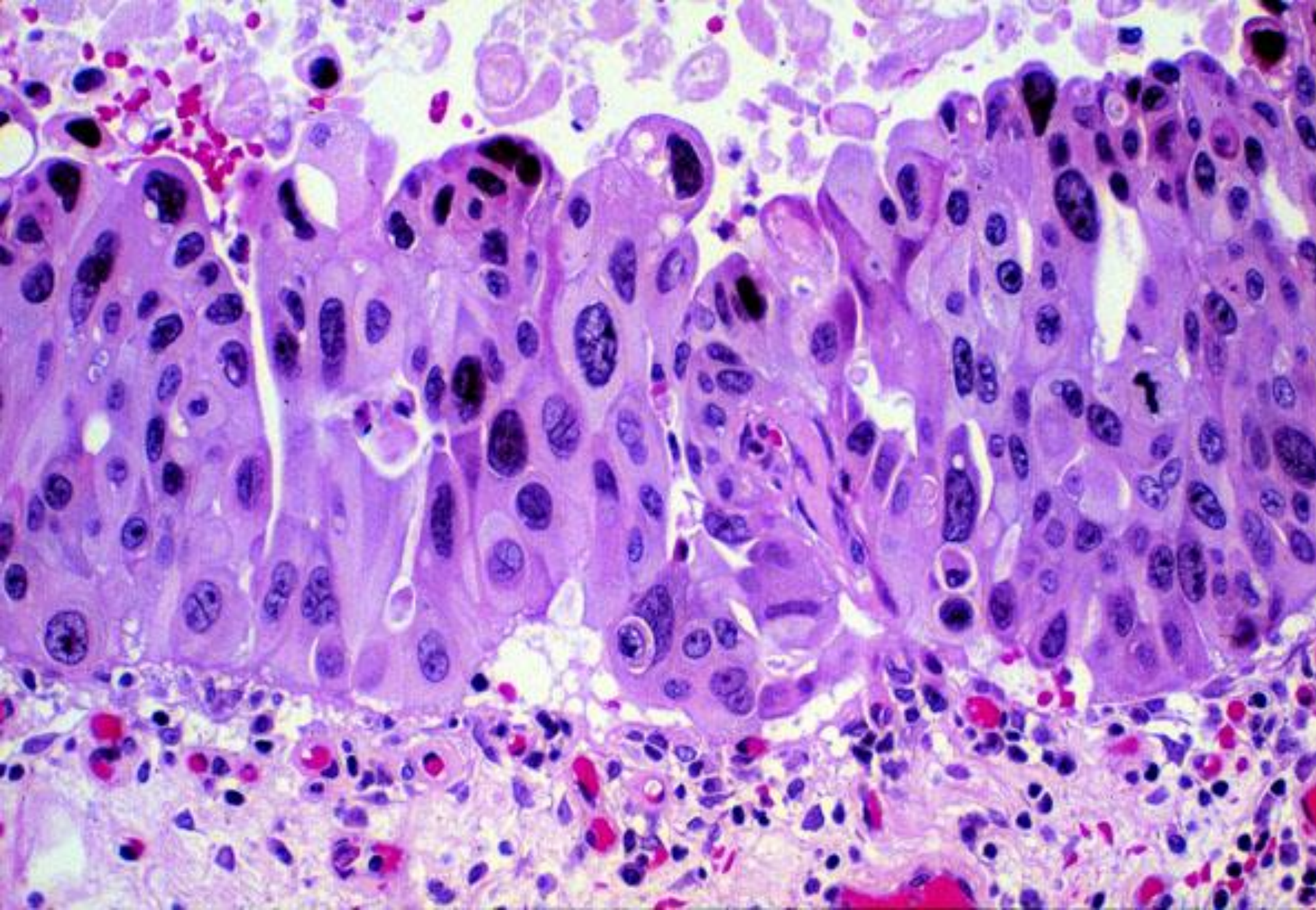


■ To these 3 letters add numbers and / or additional letters that define a certain type of extension.

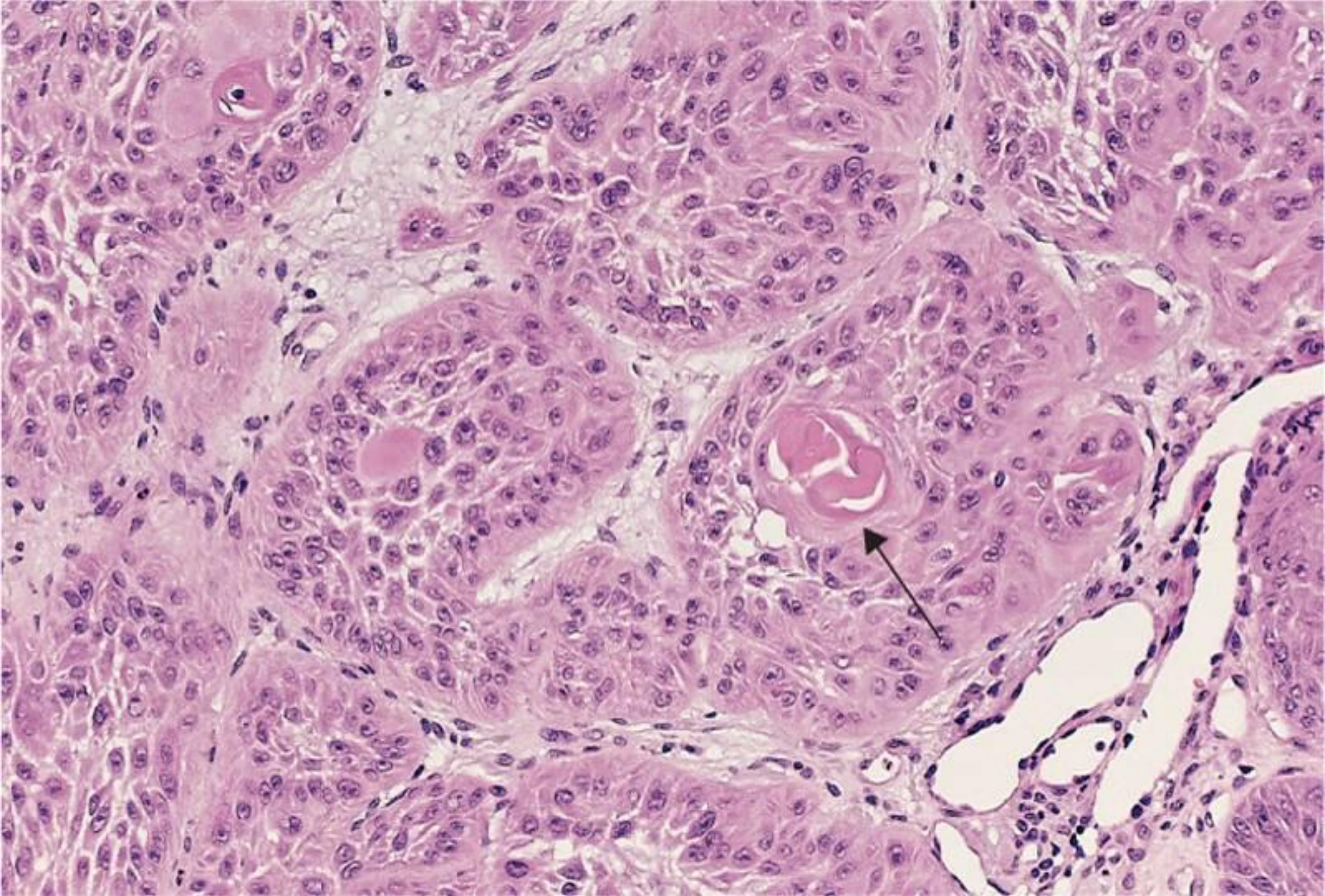
For the primary tumor (T):  
the coding varies from T1 to T4; the criteria of appreciation differ depending on the body affected. T0 encoding is used when the primary tumor could not be detected, Tx when the tumor is present but Tis cannot be classified for in situ carcinoma.

- For the regional lymphoganglions  
N0 means the absence of metastases,  
N1 - N3 indicates the presence of metastases  
(depending on the number and location of the  
affected lymph nodes).  
Nx - the condition of the lymph nodes cannot  
be appreciated due to the anatomical position.  
For distant metastases  
M0 = absence of metastases, M1 or sometimes  
M2 their presence, Mx = metastases  
impossible to appreciate.

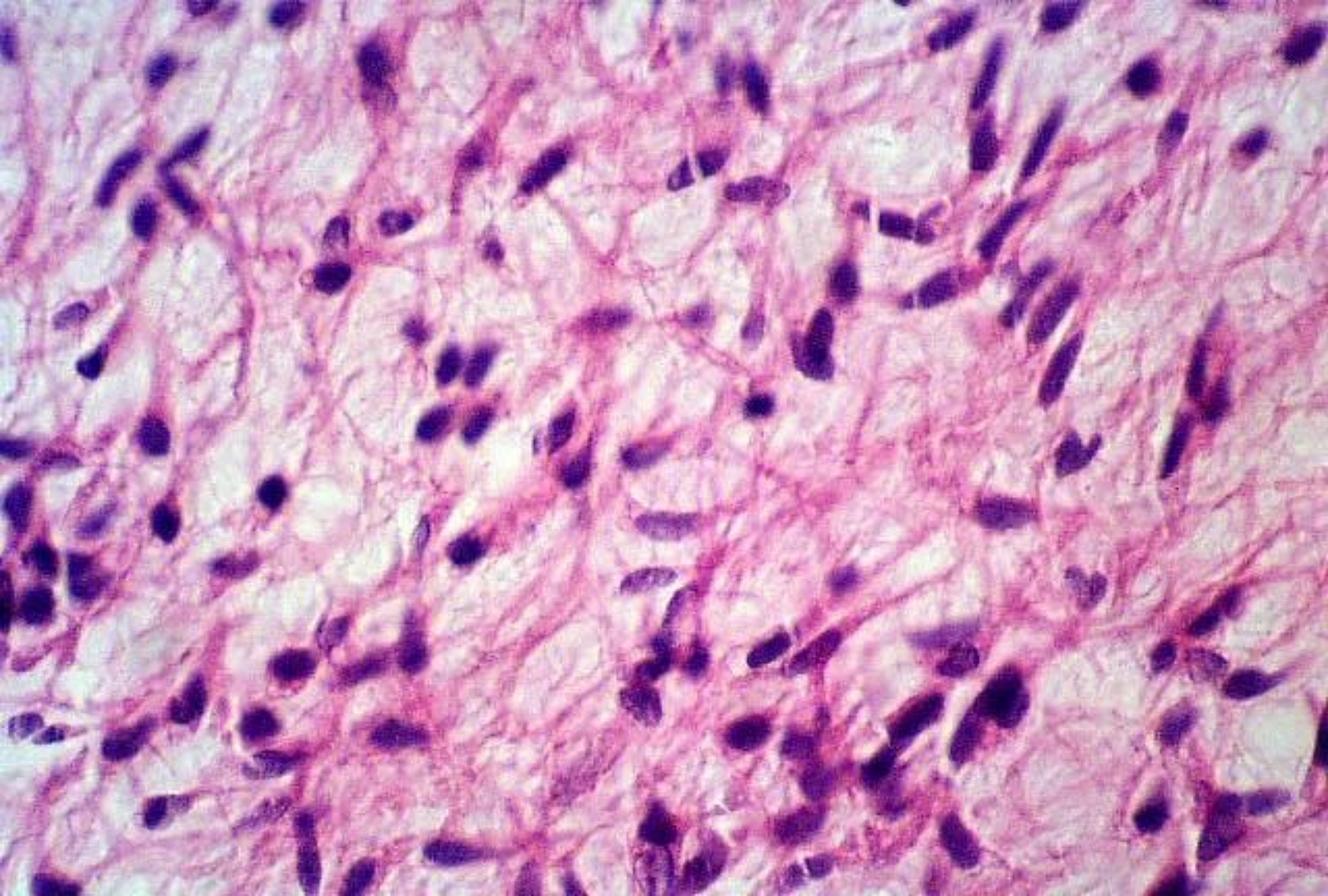
Depending on the TNM grades, each patient is individually included in a "stage" category numbered from I to IV. For example, for any T1N0M0 organ represents stage I, whereas any T1N0M1 represents stage IV.



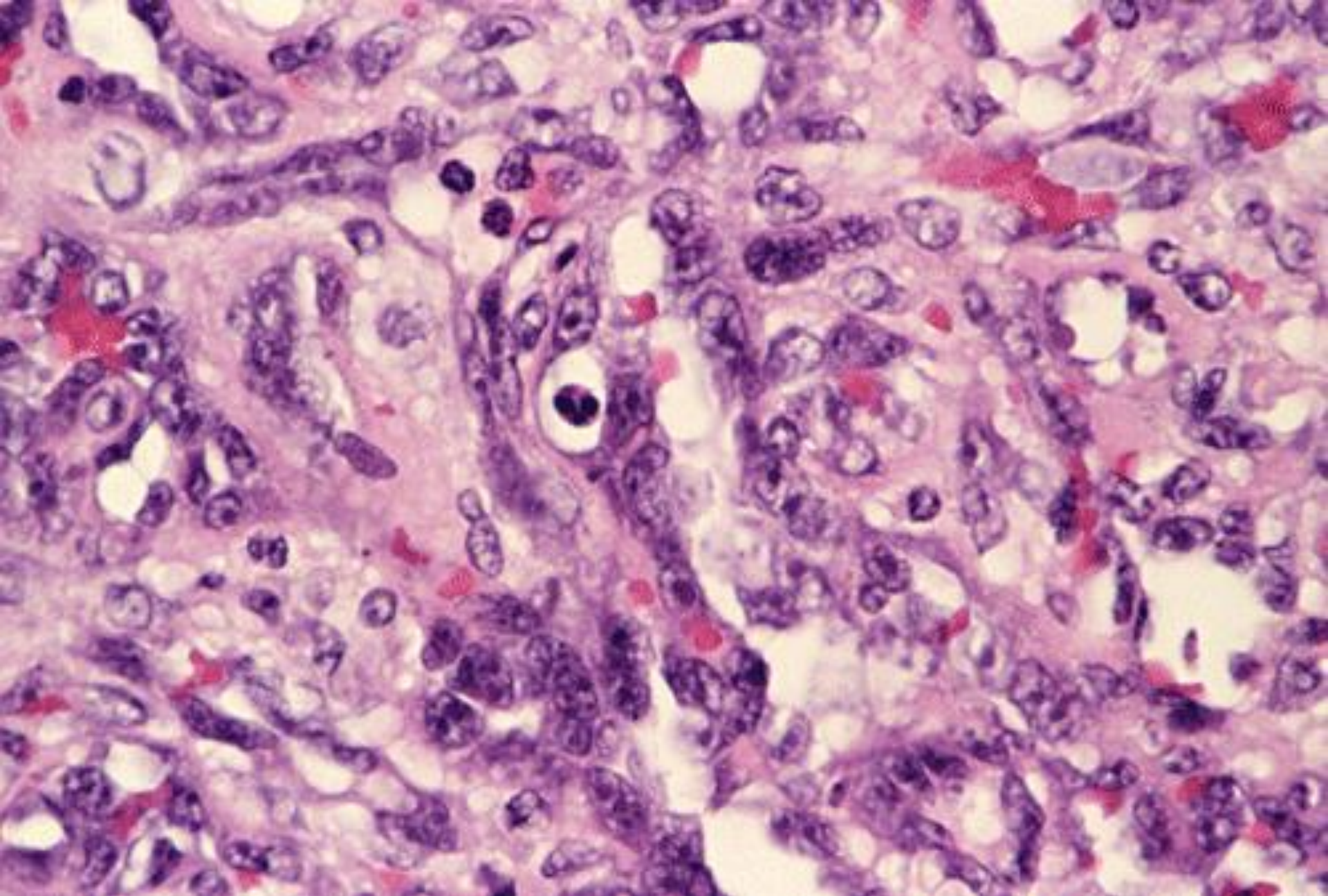
Carcinoma *in situ*. (H-E).



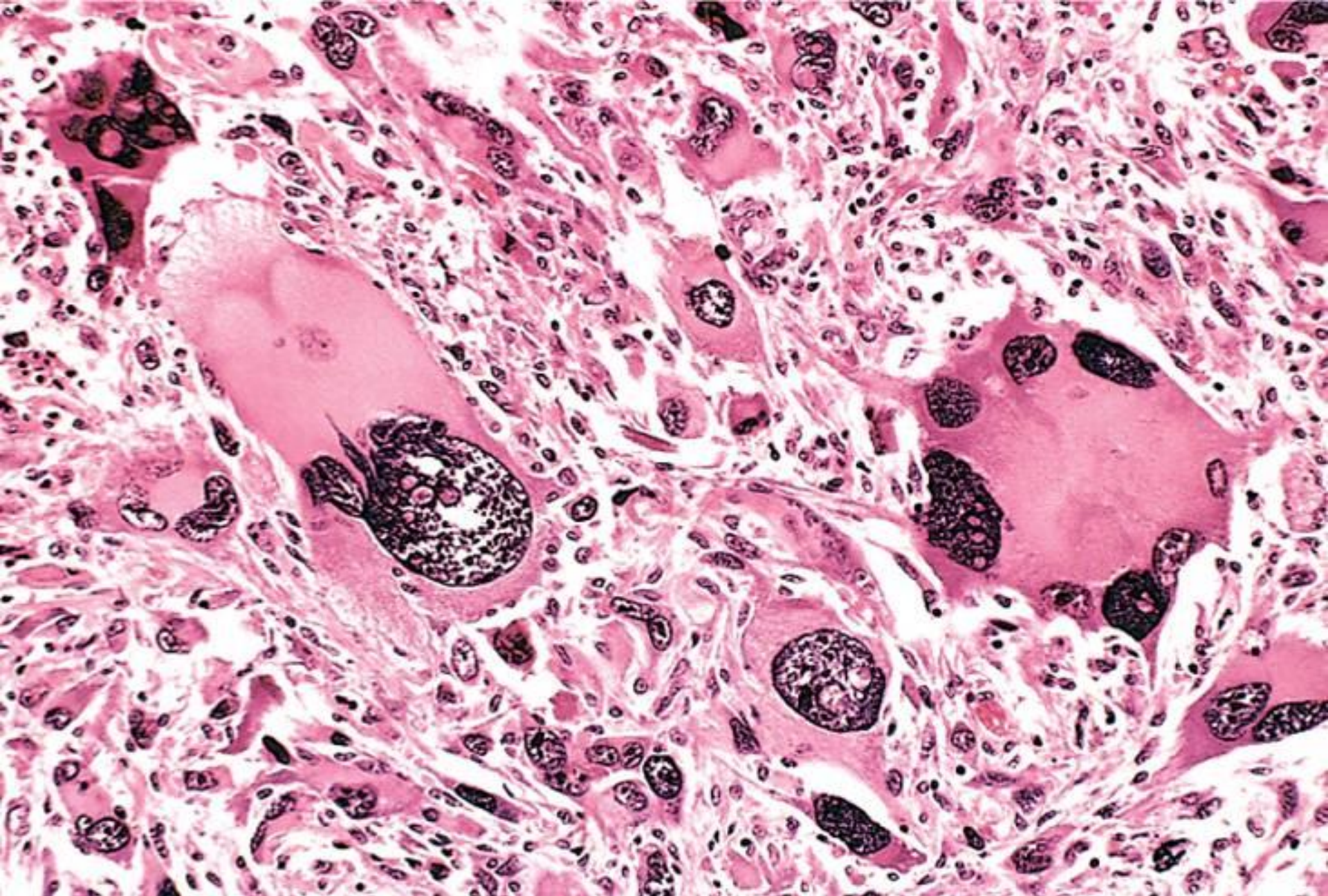
Keratinized squamous cell carcinoma



Chondrosarcoma



Angiosarcoma

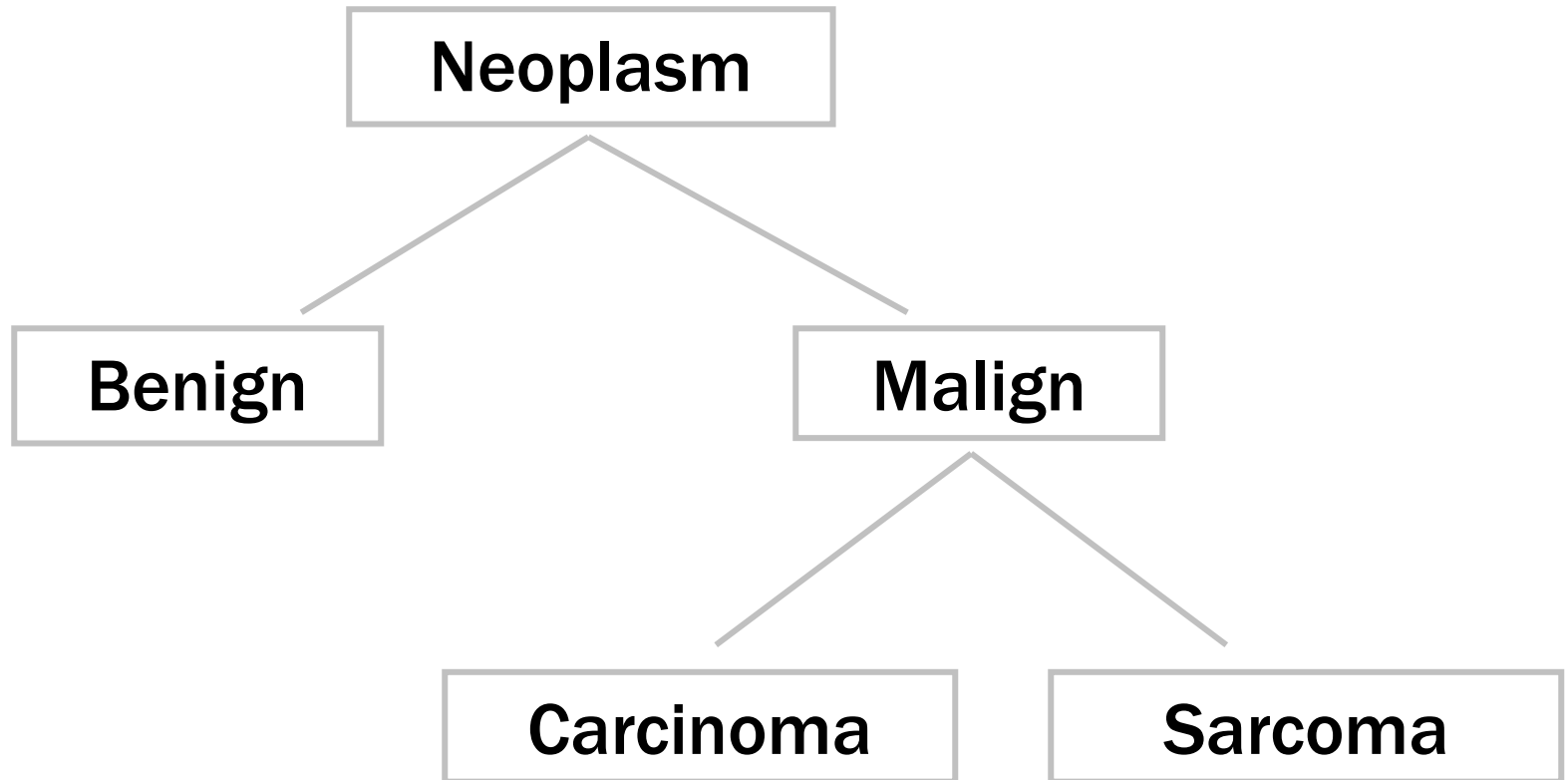


Rabdmiosarcoma

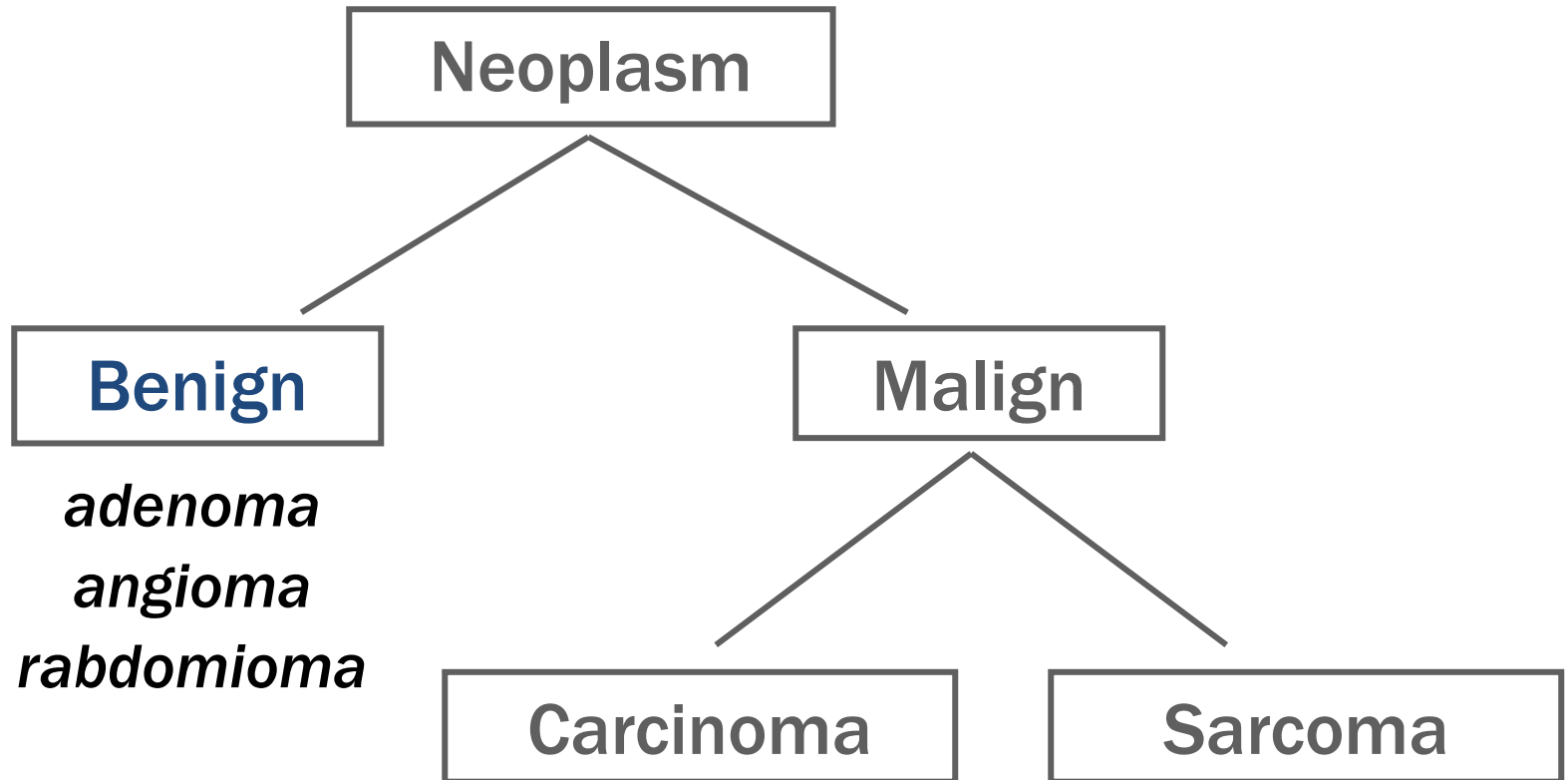




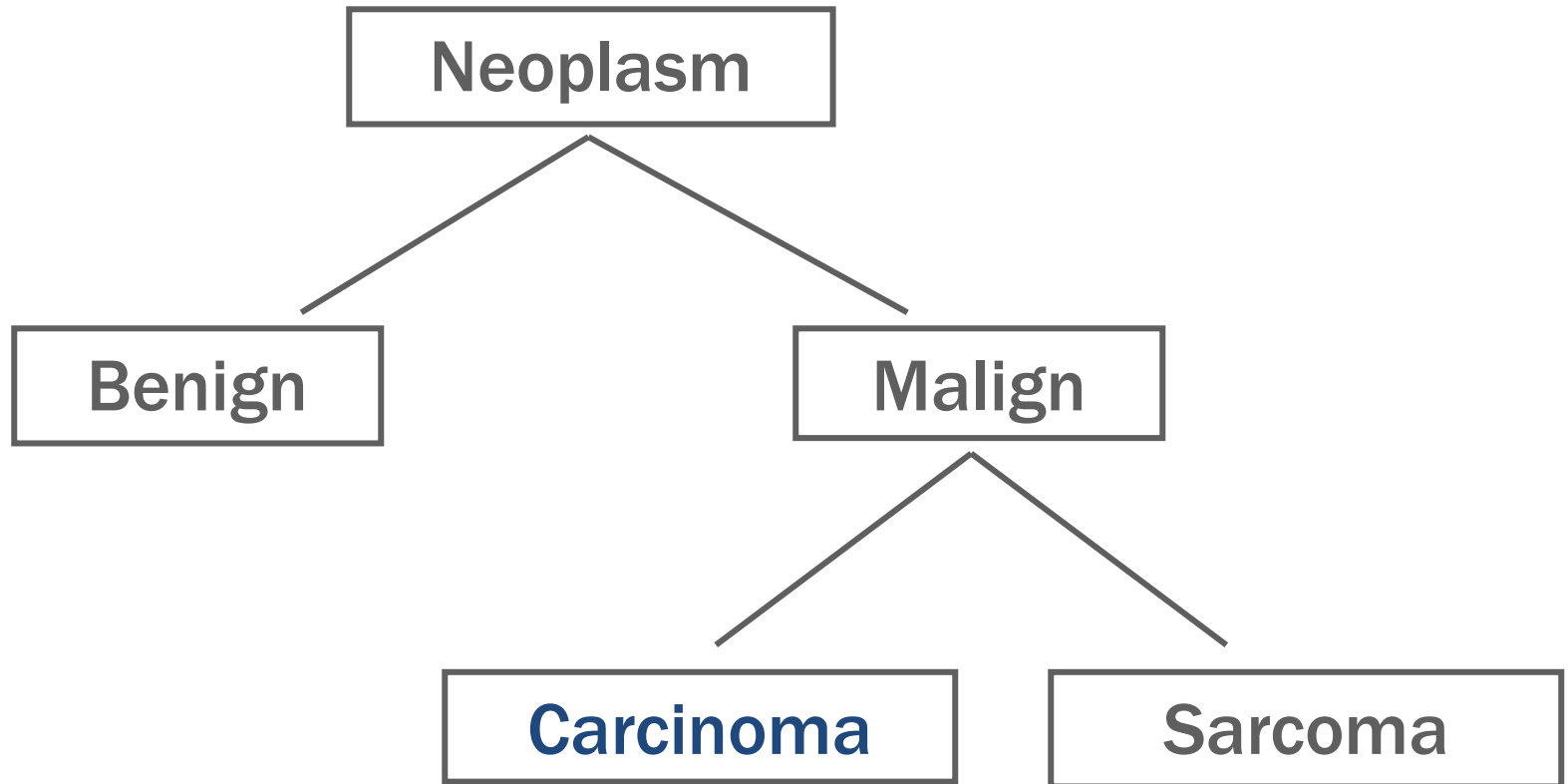
# Nomenclature



# Nomenclature



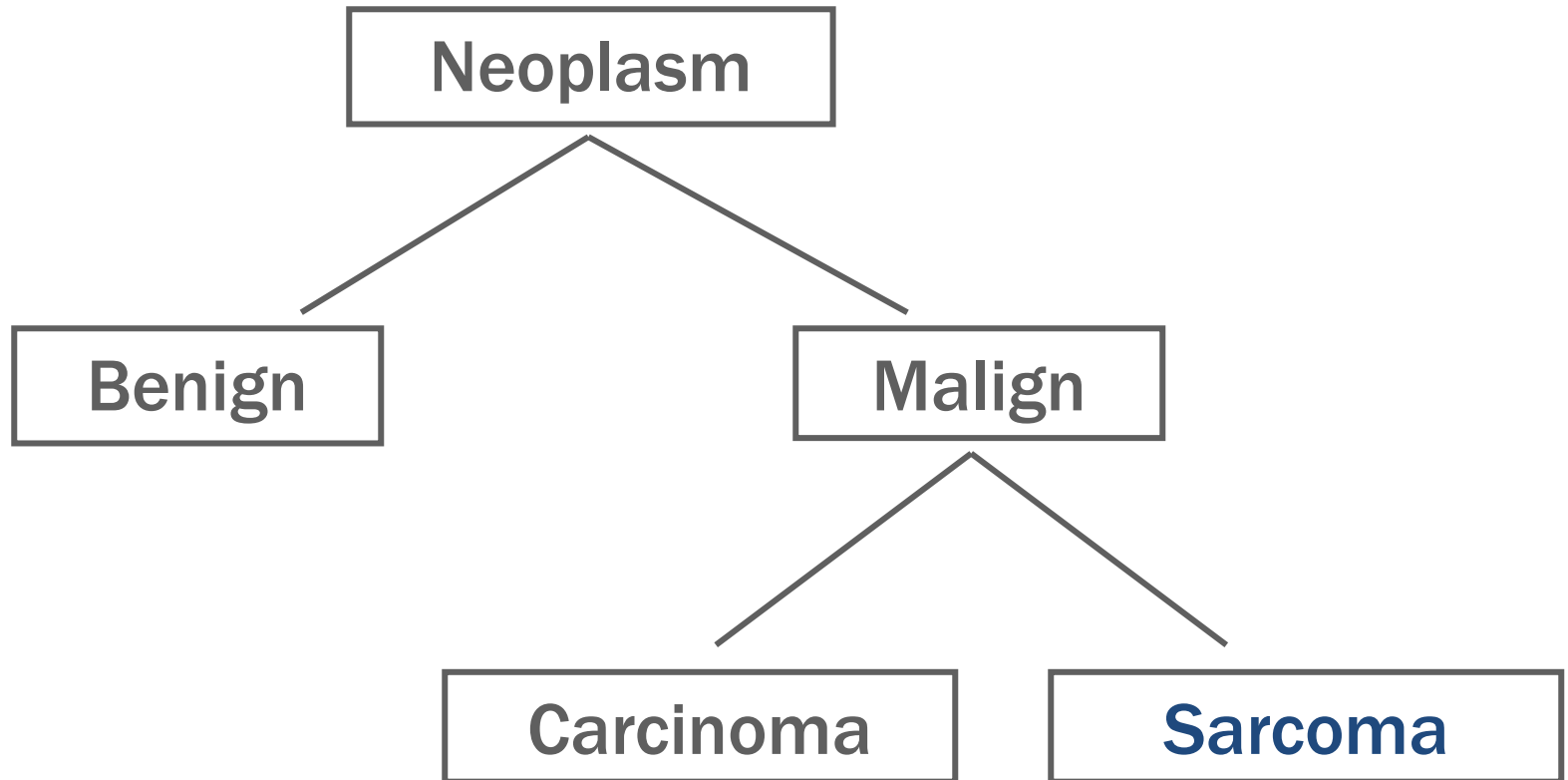
# Nomenclature



*squamous cell carcinoma*

*adenocarcinoma*

# Nomenclature



*angiosarcoma*  
*rabdomiosarcoma*

## Classification of mesenchymal tumors

Tissue of origin	Benign tumors	Malignant tumors
Connective tissue	Fibroma (soft, hard) Dermatofibroma (histiocytoma) Elastofibroma Fibromatosis (desmoid tumor)	Fibrosarcoma Malignant histiocytoma
Adipose tissue	Lipoma Hibernoma	Liposarcoma Malignant hibernoma
Muscular tissue	Leiomyoma Rhabdomyoma	Leiomyosarcoma Rhabdomyosarcoma
Blood vessels	Hemangioma (capillary, venous, cavernous, arterial) Hemangiopericytoma Glomangioma	Hemangiosarcoma (malignant hemangioendothelioma or hemangiopericytoma)
Lymphatic vessels	Lymphangioma	Lymphangiosarcoma
Bone tissue	Osteoma (compact, spongy) Osteoid osteoma (benign osteoblastoma)	Osteosarcoma (osteoblastic or osteolytic)
Cartilaginous tissue	Chondroma (ecchondroma, enchondroma) Benign chondroblastoma	Chondrosarcoma
Mesothelial tissue	Benign mesothelioma	Malignant mesothelioma
Synovial membranes	Benign synovioma	Synovial sarcoma (malignant synovioma)

# Paraneoplastic syndromes

Syndrom	Mecanism	Example
<b>Cushing Syndrome</b>	Substances of the type ACTH	Small cell lung carcinoma
<b>Hypercalcemie</b>	Parathormone-like substances	Lung (squamous cell) carcinoma
<b>Hyponatremia</b>	Abnormal secretion of ADH	Small cell lung carcinoma
<b>Policitemie</b>	Substances of the erythropoietin type	<a href="#"><u>Nephrocellular carcinoma</u></a>
<b>Trousseau Syndrome</b>	Hypercoagulability status	Various carcinomas
<b>Hipoglycemie</b>	Insulin-like substances	Various carcinomas
<b>Carcinoid Syndrome</b>	Acid 5-hydroxy-indoleacetic (5-HIAA)	Metastatic malignant carcinoid tumors

# **What are the fatal complications of malignancies (the causes of death)**

**PNEUMONIA**

**CACHEXY**

**RENAL INSUFFICIENCY**

**BLEEDING**

**SEVERE ANEMIA, THROMBOCYTOPENIA**

**INFECTIONS**

**HIPERGUABILITATE**

**CID SYNDROME**



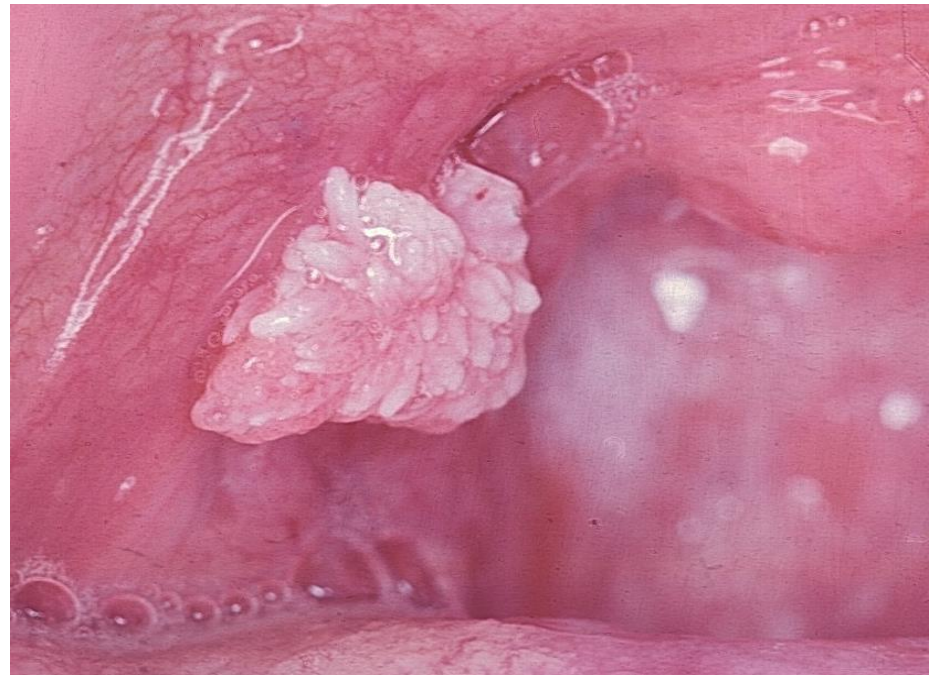
# BENIGN AND MALIGNANT TUMORS OF MORPHOLOGICAL TYPES OF THE ORAL CAVITY

---

- Nomenclature: suffix –oma (benign neoplasm)
- The name according to the tissue from which the neoplasm originates

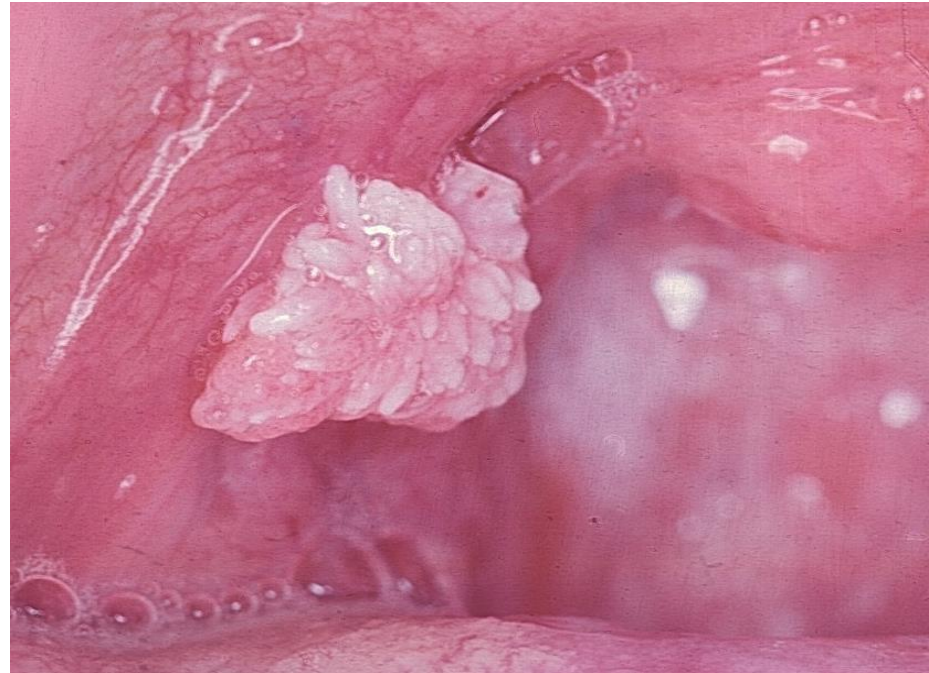
# Papilloma

- Average age 38 years
- Associated in 50% of cases with HPV
- Location: 35% soft, hard and uvula palate, 25% tongue.
- Treatment - excision
- 4% relapses

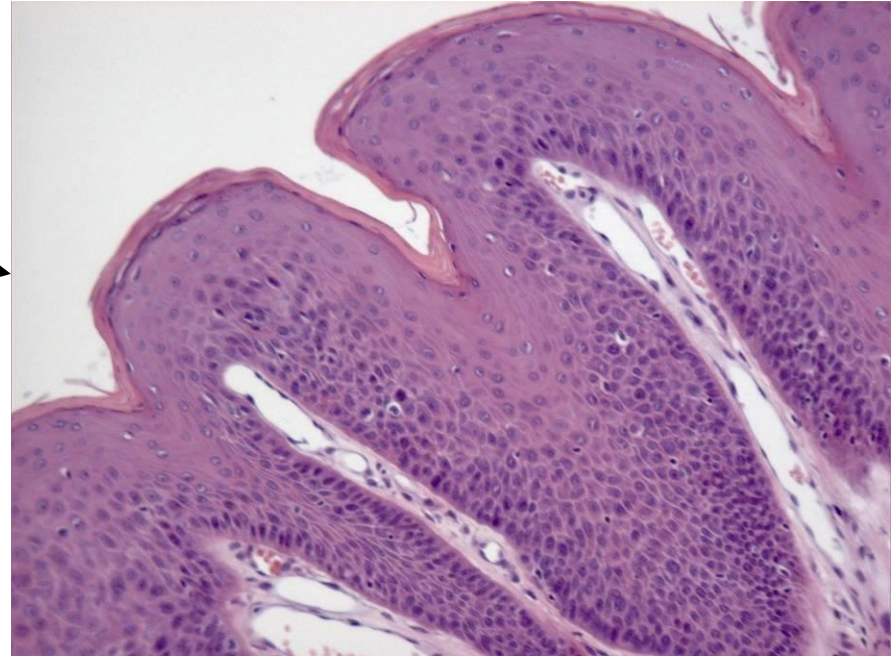
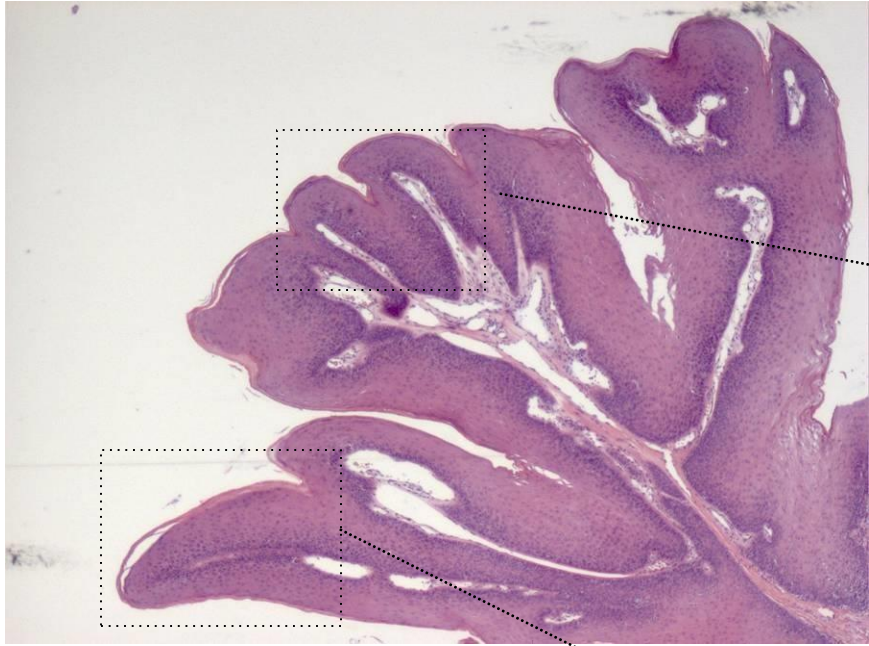


# Papilloma

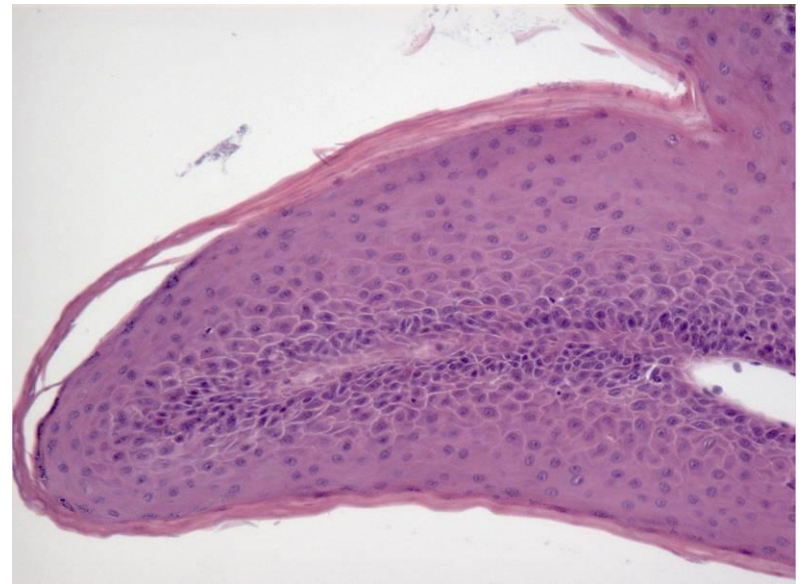
- Macroscopically, it has a conopidiform appearance, is sessile or pedicled, gray-white, a few mm in size. up to 3cm.
- Microscopically, the lesion has a papillary appearance, being made up of fibro-conjunctival axes, covered with thickened epithelium, presenting acanthosis (thickening of the spinal layer), hyperkeratosis (thickening of the horny layer), parakeratosis (persistence of nuclei in the superficial layers). No signs of dysplasia are observed.



# Papilloma

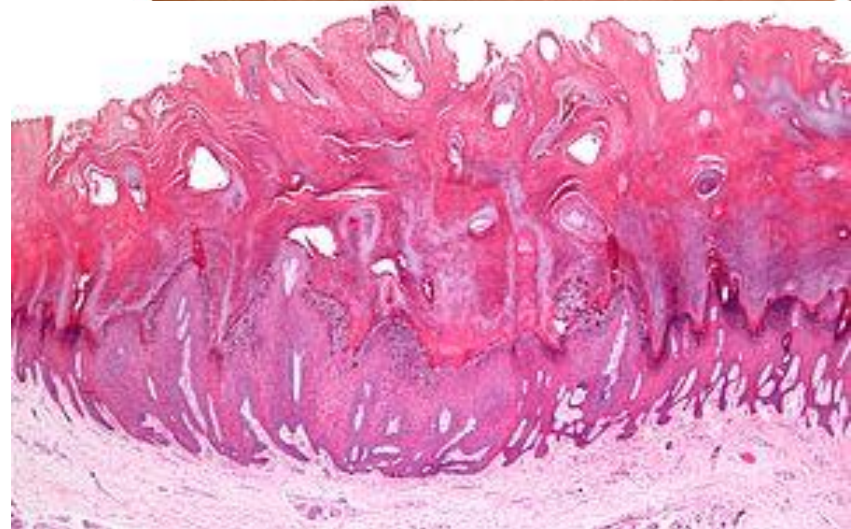
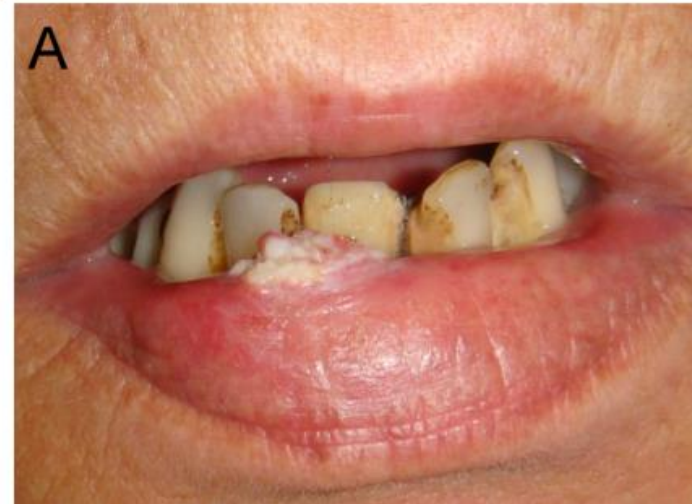

Papillomatous growth pattern,  
stroma represented by well-vascularized connective tissue



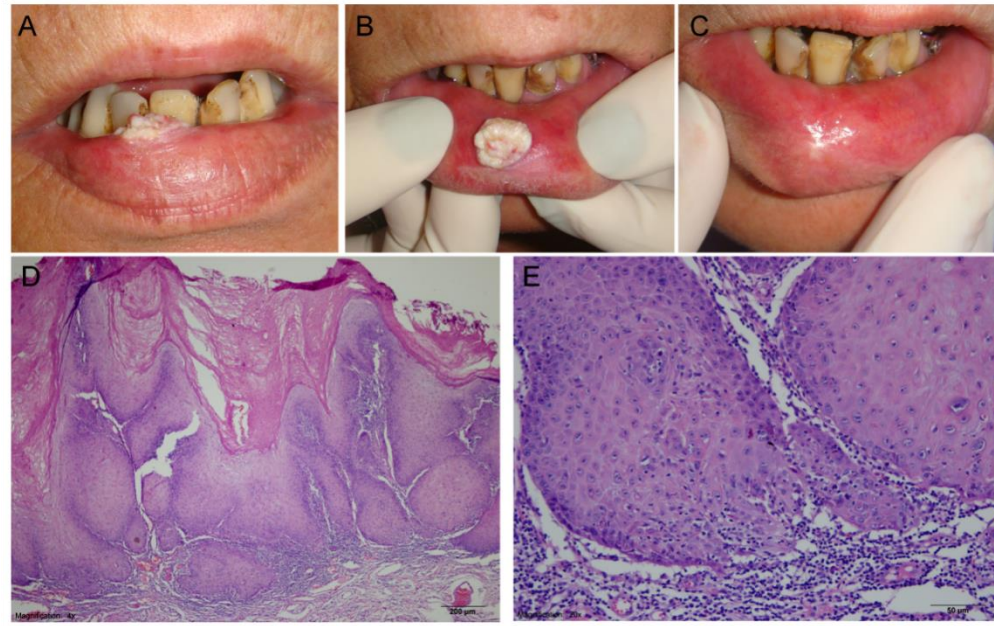
# Veruca vulgaris

- A contagious lesion that can spread to other regions of the mucosa by autoinoculation
- Children and young adults
- Associated with HPV infection (2,4,6,40)
- It develops more frequently at the level of the muco-cutaneous joint of the lips and the tongue



# Veruca vulgaris

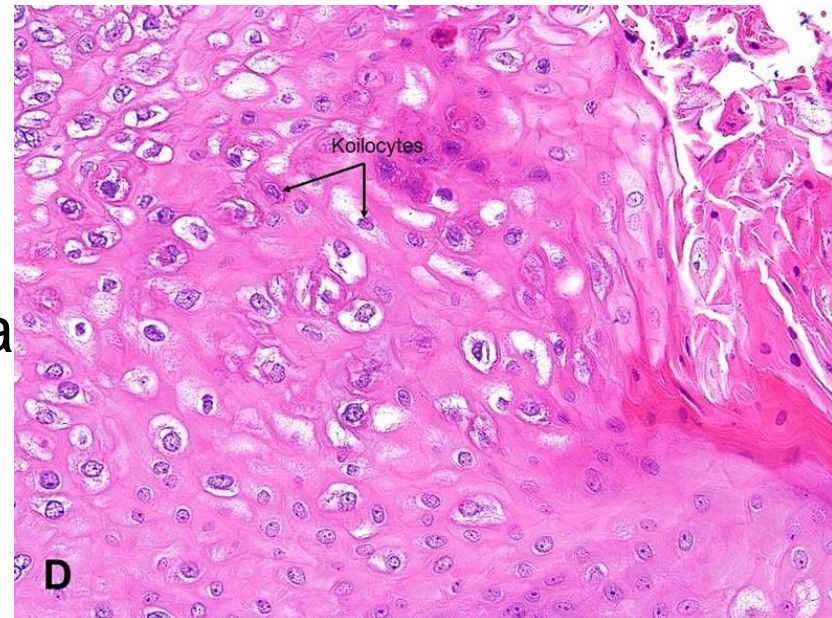
- Macroscopically, it has the appearance of a nodular, painless lesion, with rough surface, well delimited, usually sessile, white in color and a few cm. in diameter.
- Microscopically, it is characterized by papillary hyperplasia of the squamous epithelium, the papillary projections being covered by an epithelium with acanthosis and hyperkeratosis. In the granular layer viral inclusions can be highlighted.



# Acuminate condyloma

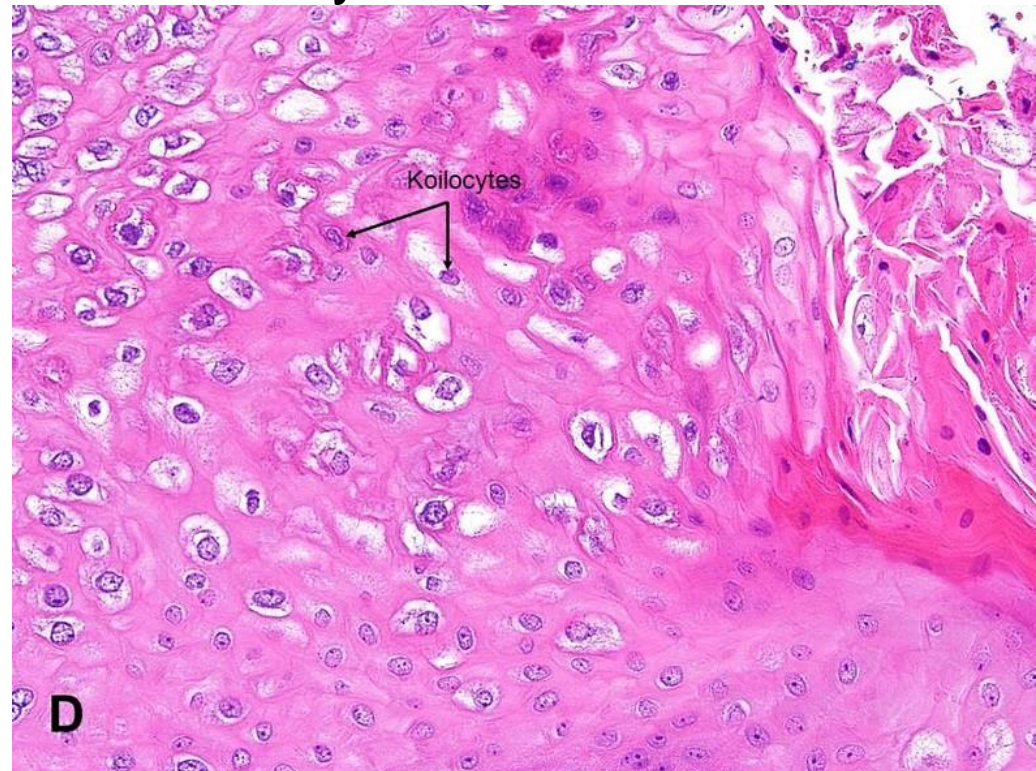
- Associated with HPV infection (2,6,18,28) which is transmitted sexually
- Sometimes the oral lesion develops at the same time as a similar ano-genital lesion
- Adolescents and young adults, frequently associated with HIV

Common location - lip lining, soft bed and frenulum  
glossal



# Acuminate condyloma

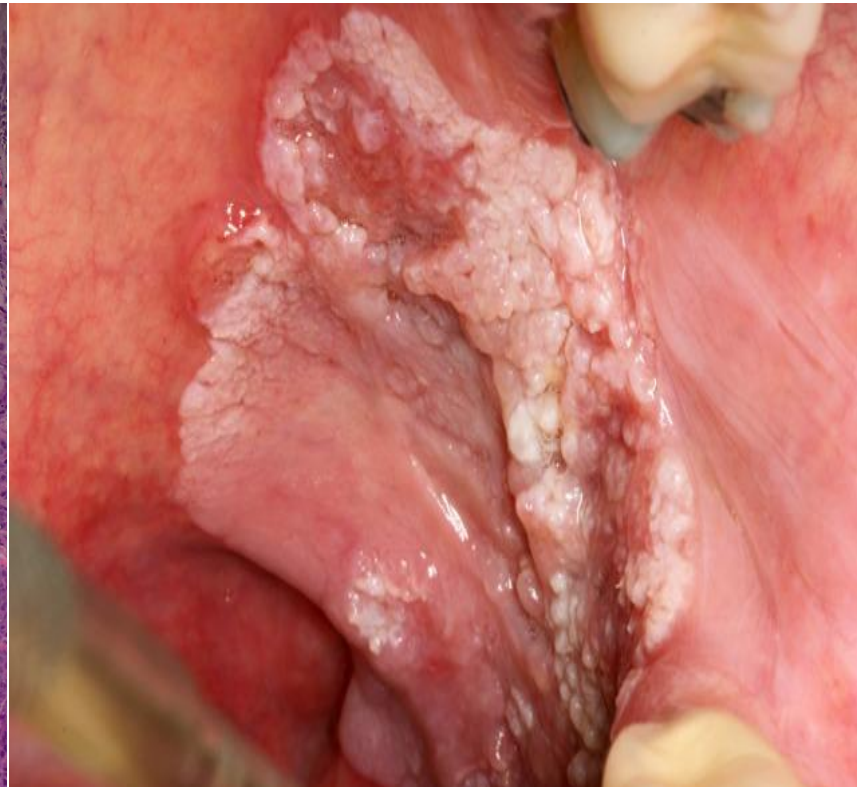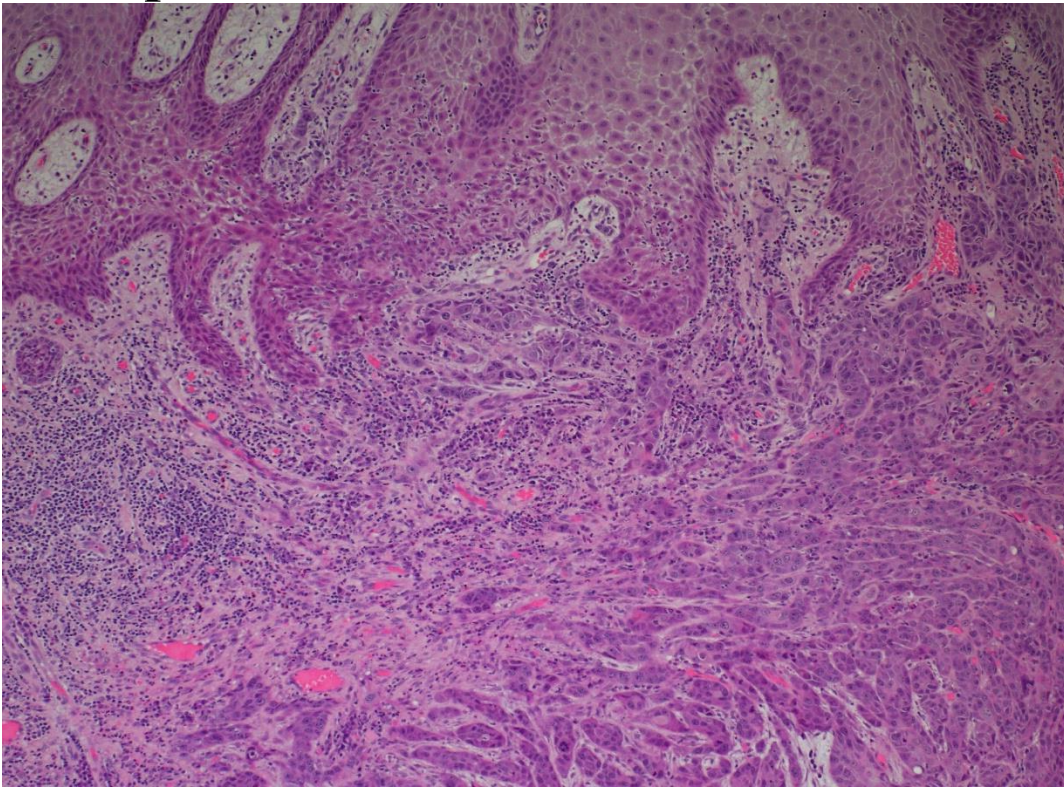
- Macroscopic is a sessile lesion, well delimited, exophytic, pink and diameter 1-1.5 cm.
- Microscopic is papillary, with fibro-conjunctival axes lined with squamous epithelium, acanthosis and hyperkeratosis. In the epithelium, epithelial cells called koilocytes that contain viral particles appear.





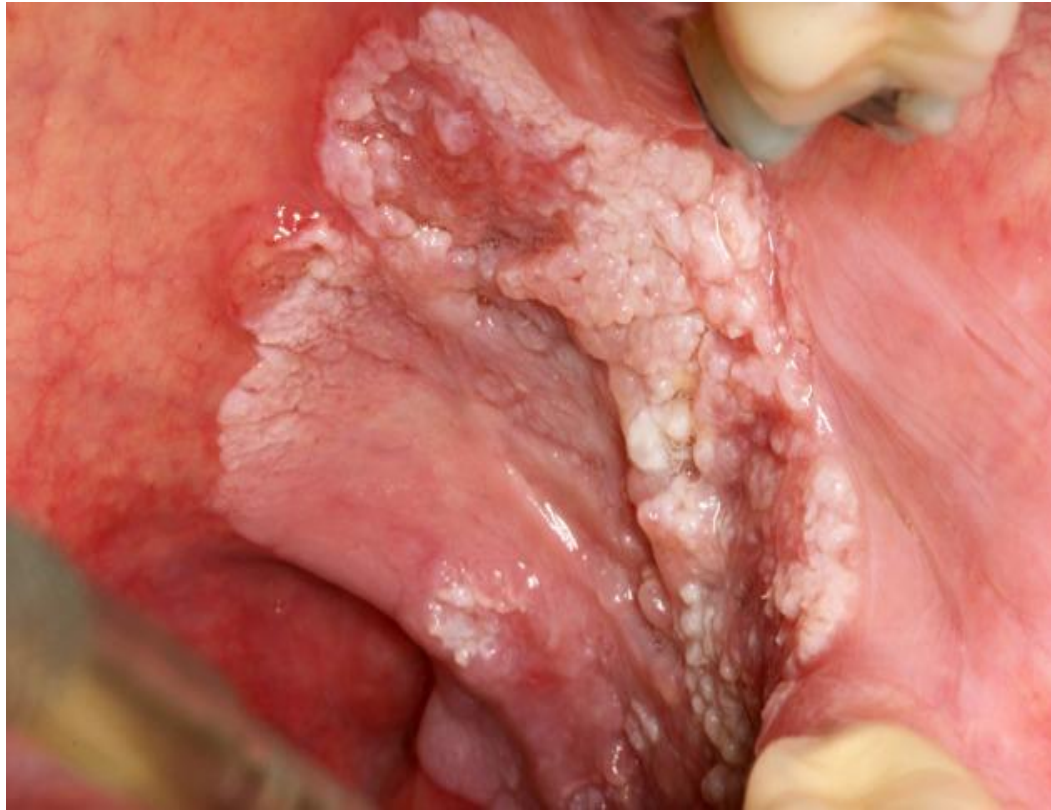# Squamous cell carcinoma

- The most common malignant tumor of the oral cavity
- It represents 5-8% of all malignant tumors
- Multifactorial etiology - extrinsic predisposing factors: smoking and alcohol, oncogenic viruses, sun exposure (lip carcinoma). Intrinsic factors: malnutrition and iron deficiency anemia. Precancerous lesion - leukoplakia.



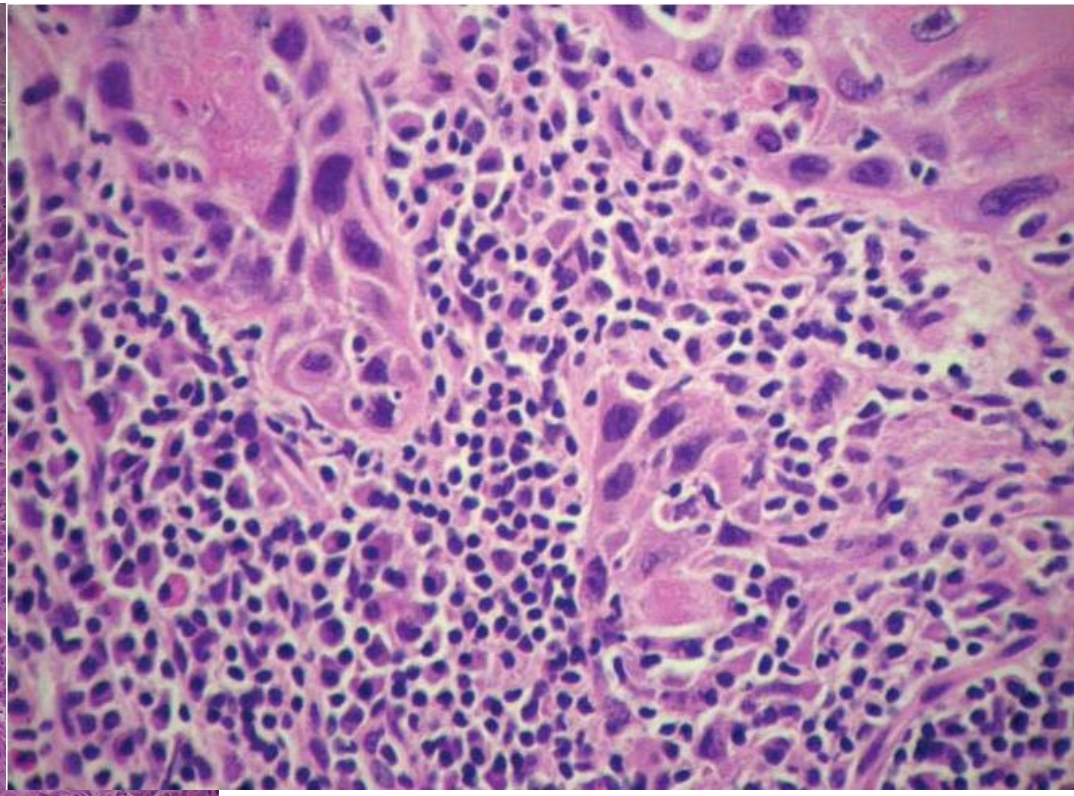
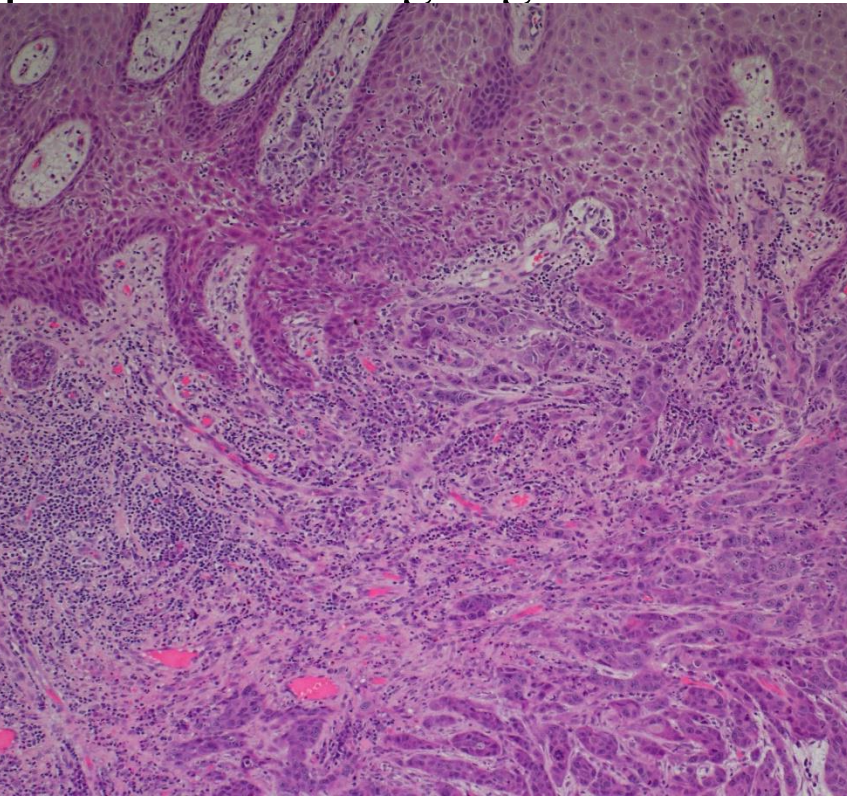
# Squamous cell carcinoma

- Localization: lips, tongue, buccal floor, gum, palate.
- Macroscopically, it can be present in exophytic (conopidiform), endophytic (infiltrative or ulcerative), leukoplastic (white area), erythroplastic (red area) and erythroleucoplastic (white spot with red outbreaks)



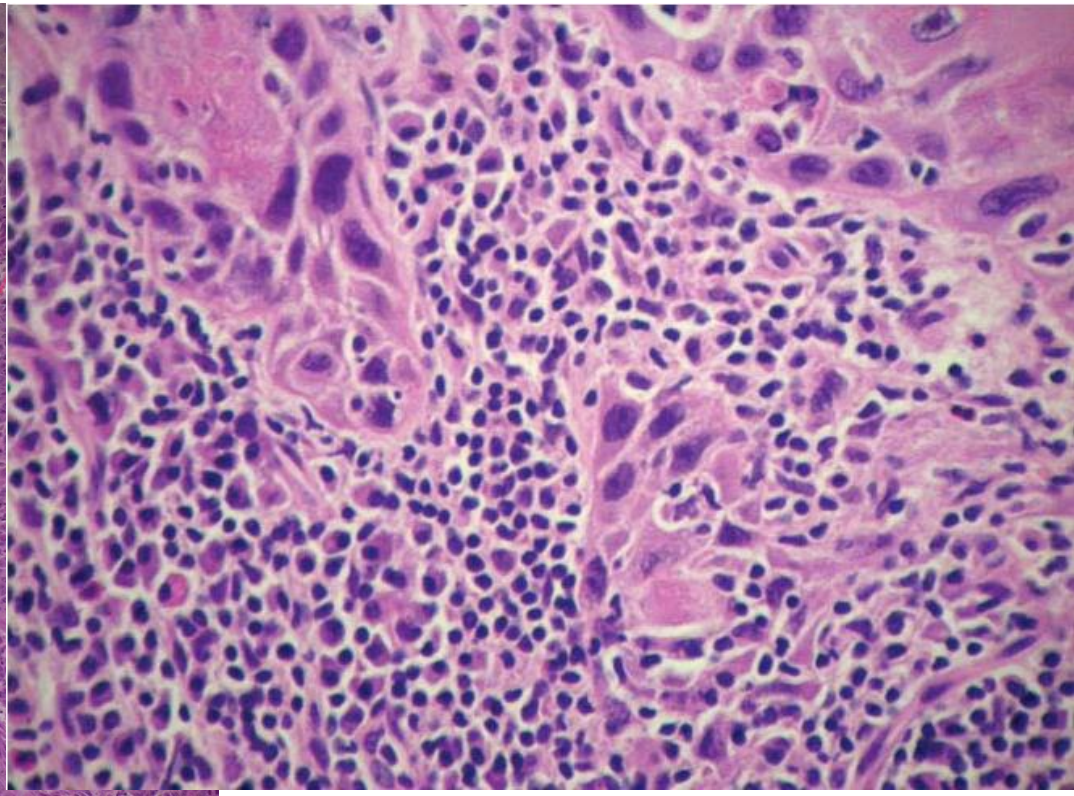
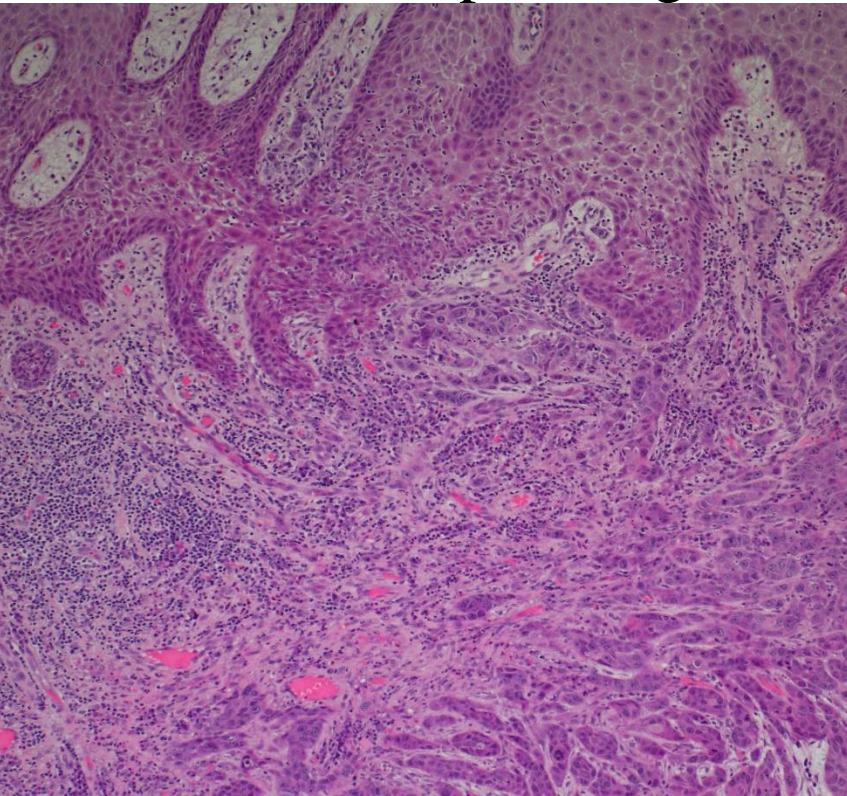
# Squamous cell carcinoma

- Microscopically, proliferation of tumor cells arranged in placards and cords, which infiltrate the lamina propria, overlying, the epithelium shows signs of dysplasia.
- Tumor cells have abundant eosinophilic cytoplasm, hyperchromic nuclei and mitotic figures. At the level of the tumor placards keratin pearls can be highlighted.



# Squamous cell carcinoma

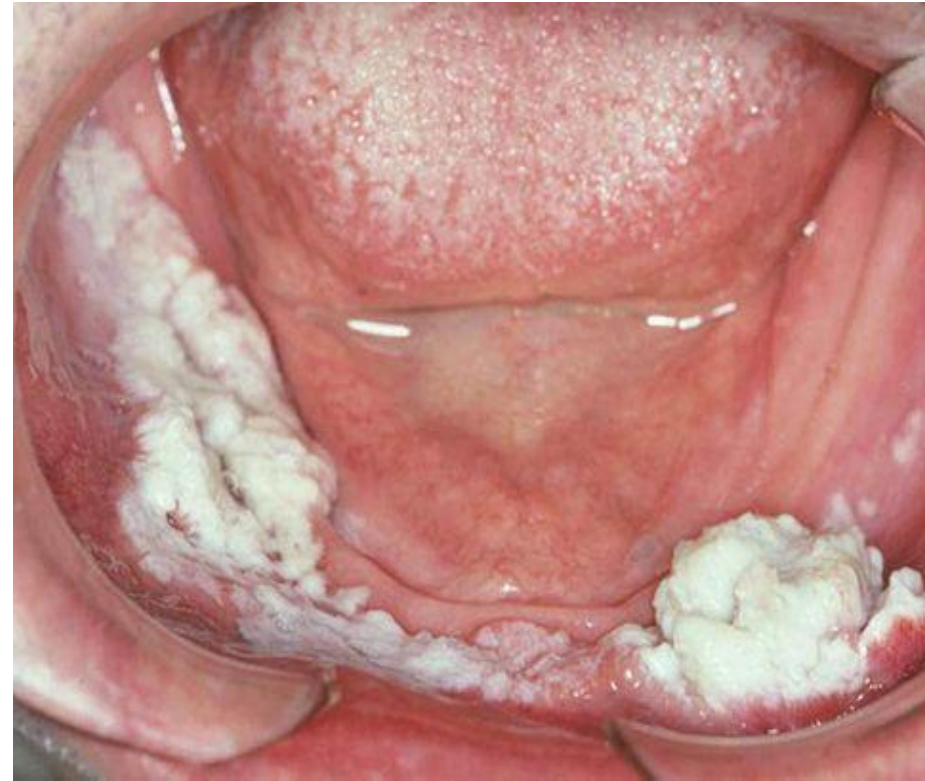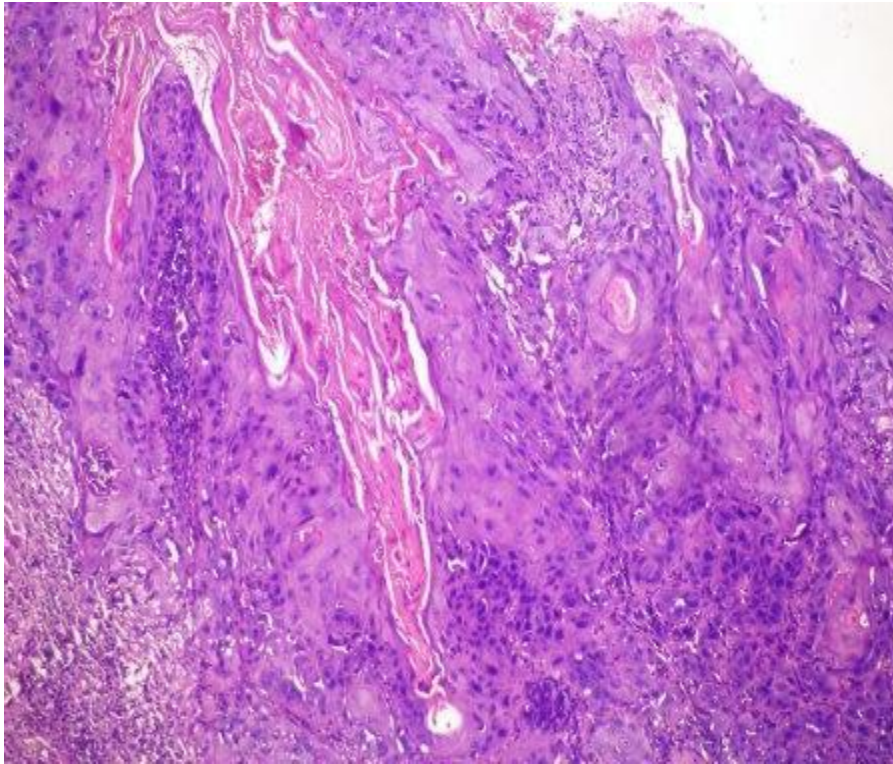
- The stroma around the tumor cells has an inflammatory infiltrate and areas of necrosis.
- The microscopic grading is done according to the differentiation of the tumor cells and the production of keratin
- Metastases develop lymphatically in the ipsilateral cervical lymph nodes, sometimes bilaterally, in advanced stages hematogenous metastases develop in lungs, liver, bones.



# Squamous cell carcinoma

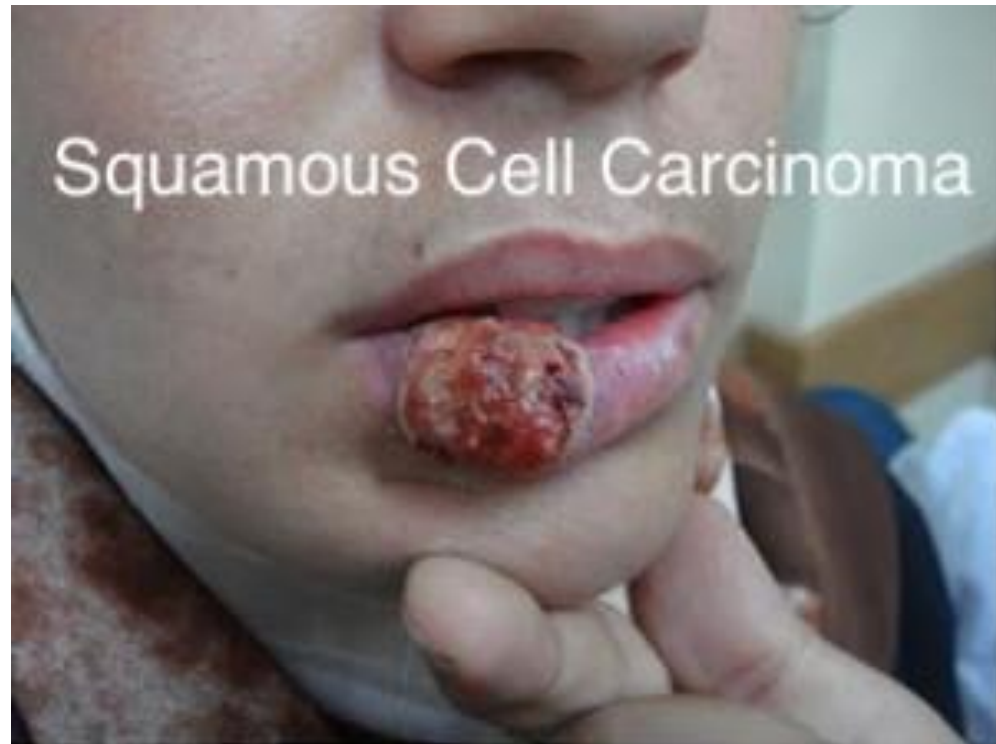The particular variants are:

- worm carcinoma (exophytic lesion associated with acanthosis)
- sarcomatoid carcinoma (proliferation of fusiform, pleomorphic tumor cells)
- carcinoma adenoscuamos (presents with areas of glandular differentiation)
- basaloid carcinoma (basal cell tumor plaques)



# Carcinoma of the lip

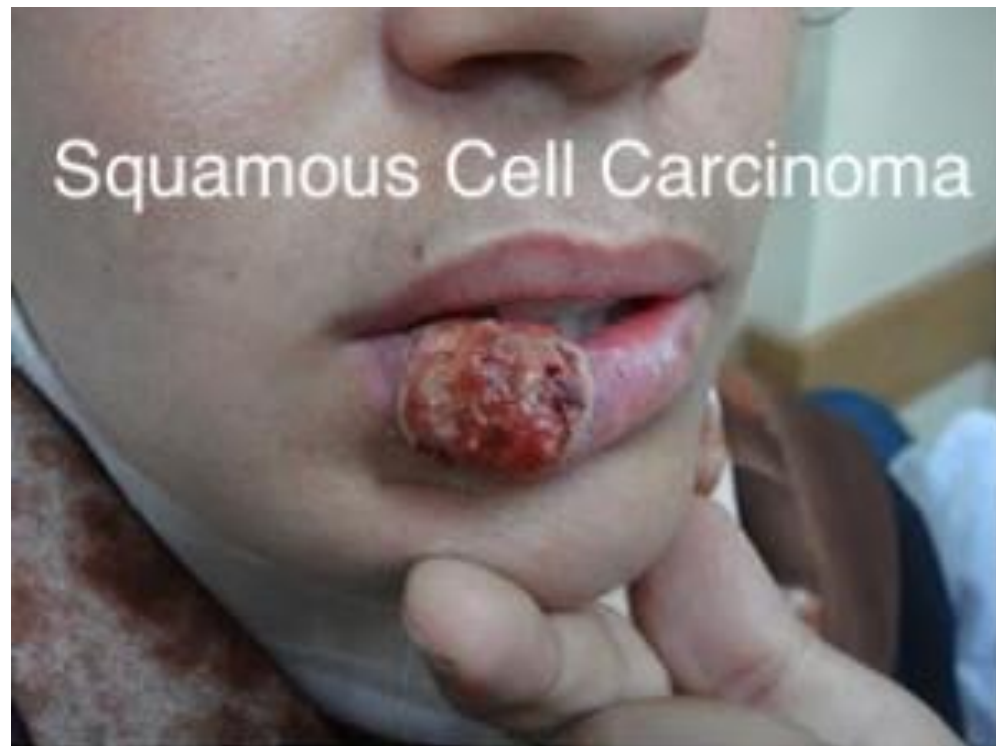- 40% of all oral carcinomas
  - Men, 90% on the lower lip at the junction between the redness of the lip and the cutaneous portion.
- Favorable factors: sun exposure and smoking (pipe smoking)
- Precancerous lesions: leukoplakia and actinic cheilitis.
- Macroscopic has the appearance of an ulcerated or indurated lesion, with local infiltrative character



# Carcinoma of the lip

- The lesion starts in the form of a crack or a small ulceration
- The ulceration is covered with sero-haemorrhagic crusts which then detach, underlying an ulcerative lesion, which extends and whose edges become indurated.

Microscopically, it is usually a well-differentiated, less moderate or less differentiated keratinized squamous cell carcinoma.



# Carcinoma of the lip

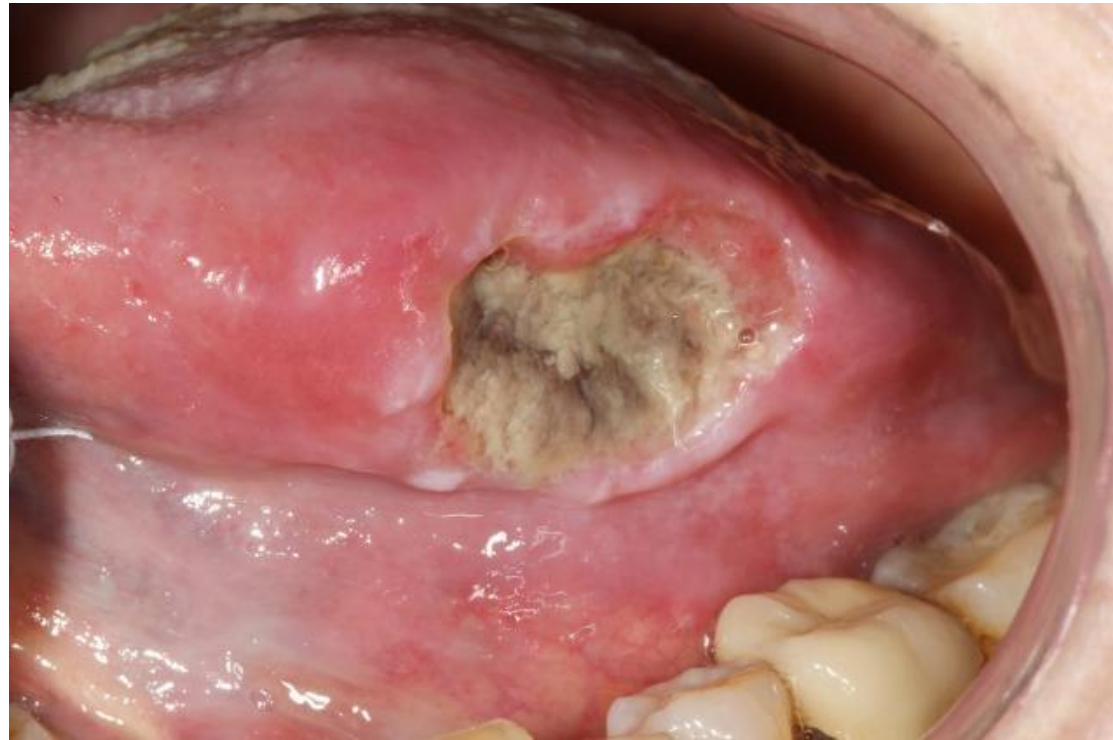- The tumor grows slowly, extending to the cutaneous region of the lip, endobuccal or neighboring regions (vestibular slope, alveolar ridge, buccal commissure)
- It produces metastases more frequently in the submandibular and submentonary lymph nodes





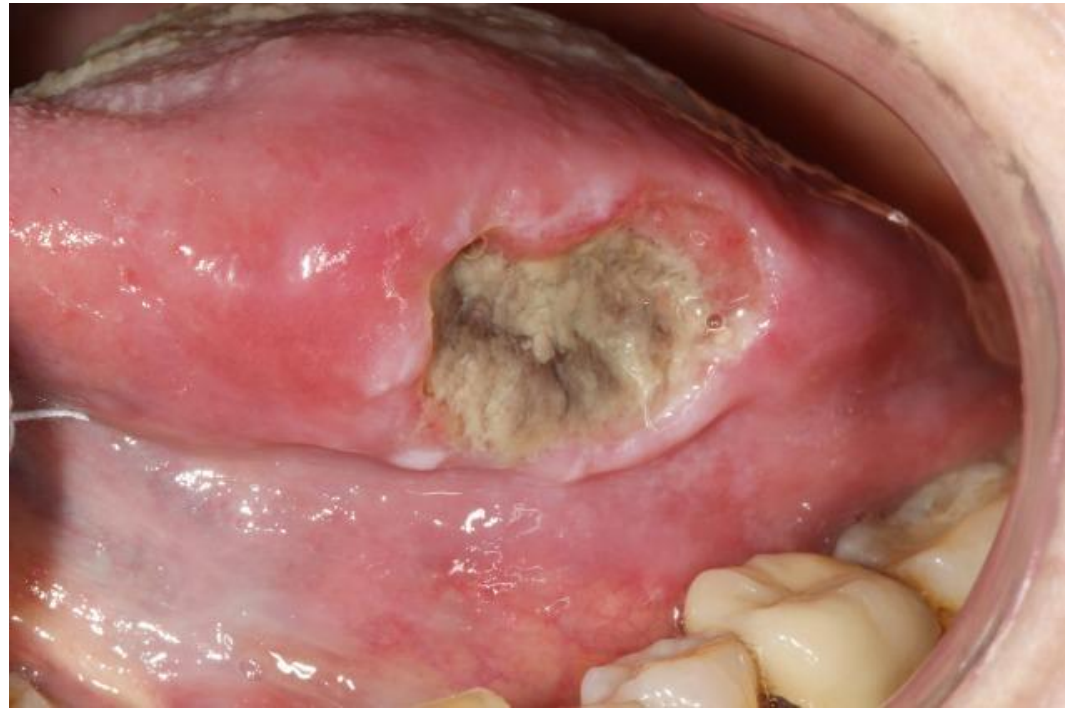# Carcinoma of the lip

- 25% of all oral carcinomas
- Men in decades 5-9 of life
- Location in the posterior 2/3 of the tongue, along the lateral edges
- Favorable factors: alcohol, smoking, ulcers of the tongue produced by tooth decay, root residues, incorrectly adapted prostheses.



# Carcinoma of the lip

- Macroscopically usually appears as an ulcerated exophytic tumor mass with irregular margins
- Microscopically, the carcinoma located in the anterior 2/3 is of the type of a well-differentiated squamous carcinoma, while the carcinoma that appears in the posterior region is undifferentiated.
- Quickly infiltrates the surrounding tissues (buccal floor, epiglottis), leading to tongue fixation, invasion of the tonsils



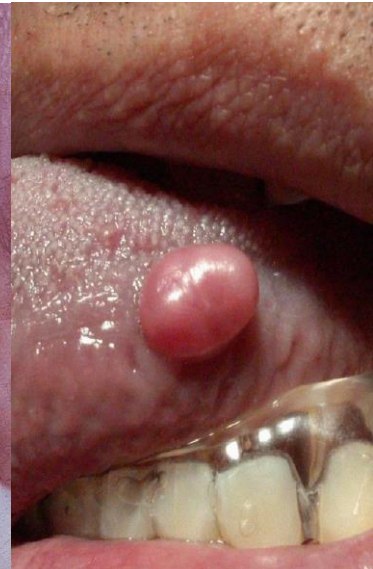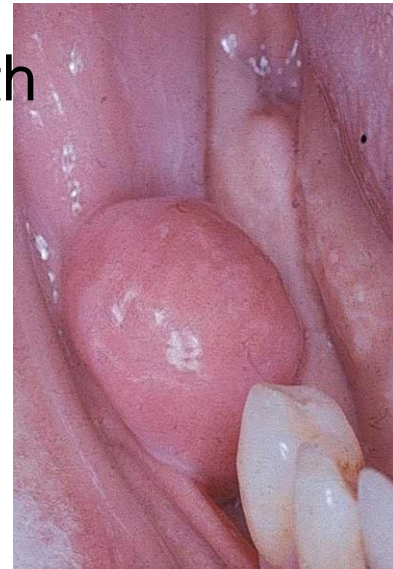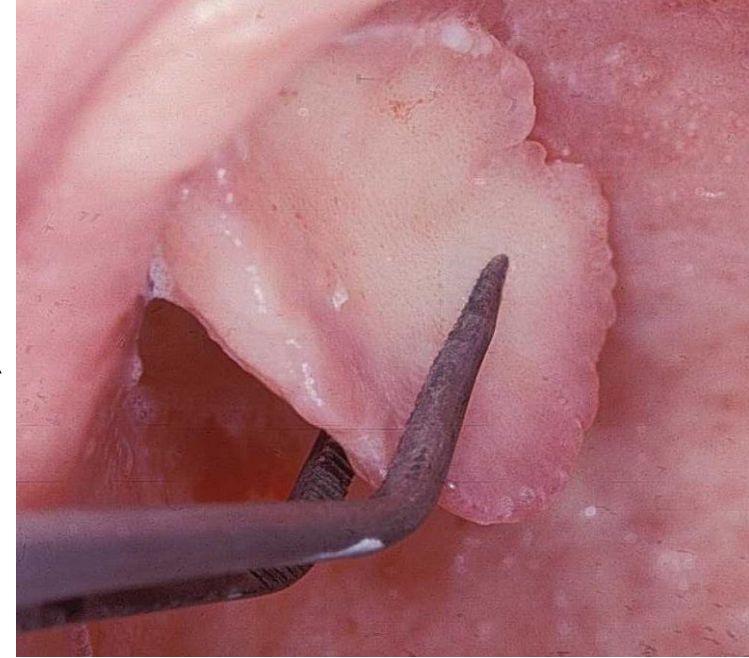
# Carcinoma of the lip

- Lymphatic metastases occur early in the submandibular, deep jugular (upper cervical, carotid, lower cervical) lymph nodes.
- The prognosis is reserved, the more so as the lesion is located later



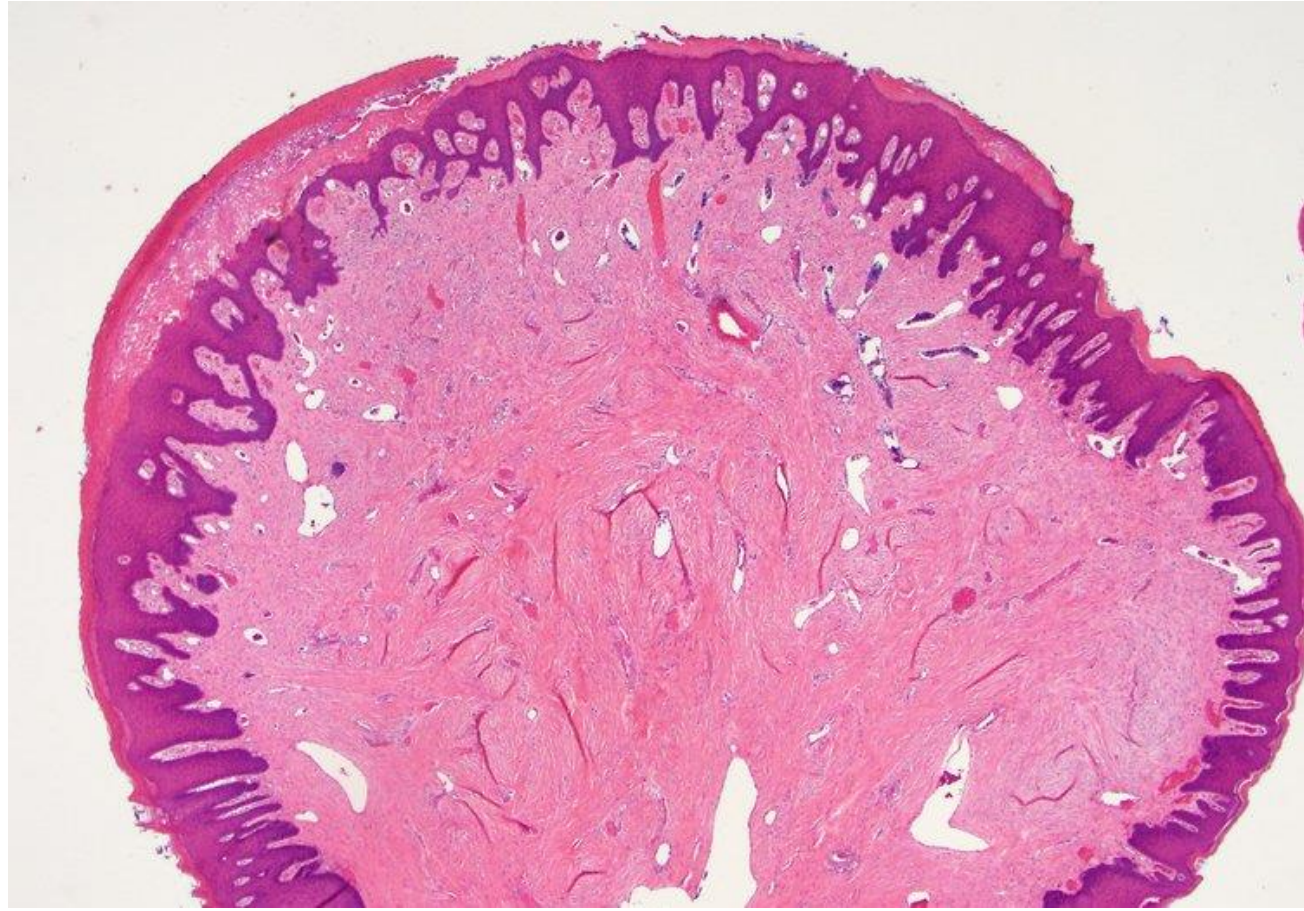
# Fibroma (irritation fibroma)

- The most common tumor of the oral cavity, determined by local irritants
- Localization - jugal mucosa, tongue, palate and buccal floor and appears as a single tumor, rarely multiple, sessile or pedicled.
- The tumor is nodular, well delimited, with a smooth surface and pink color, with a diameter of 1.5 cm.



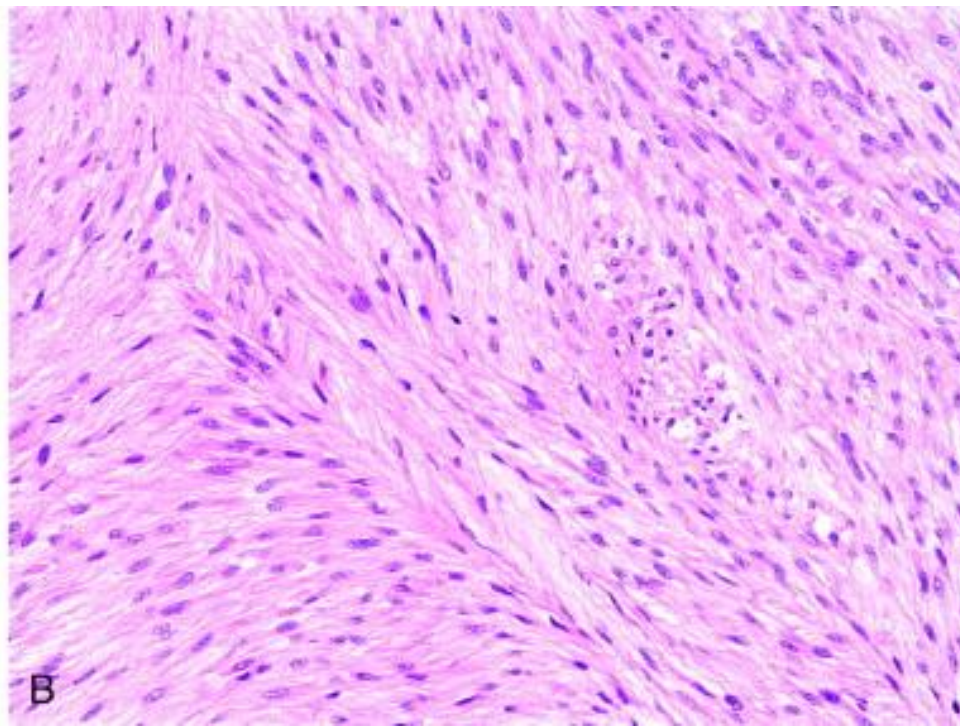
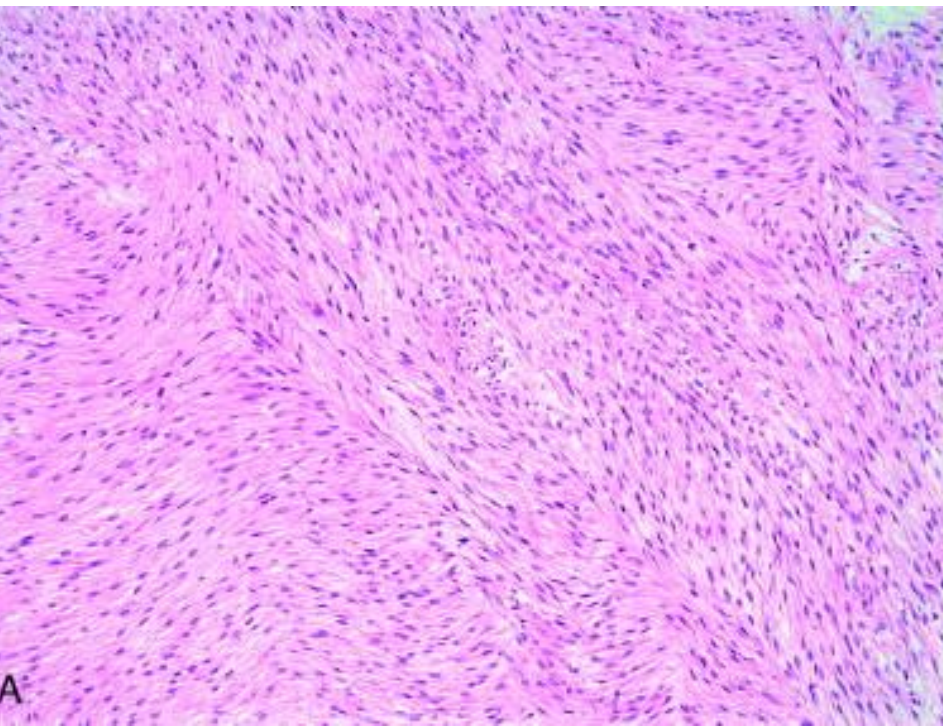
# Fibroma

- Microscopic is made up of connective tissue, composed of fibroblasts arranged in fascicles, without signs of atypia and collagen bands. On the surface the tumor is covered by a squamous keratinized epithelium, and at the periphery it is not encapsulated.



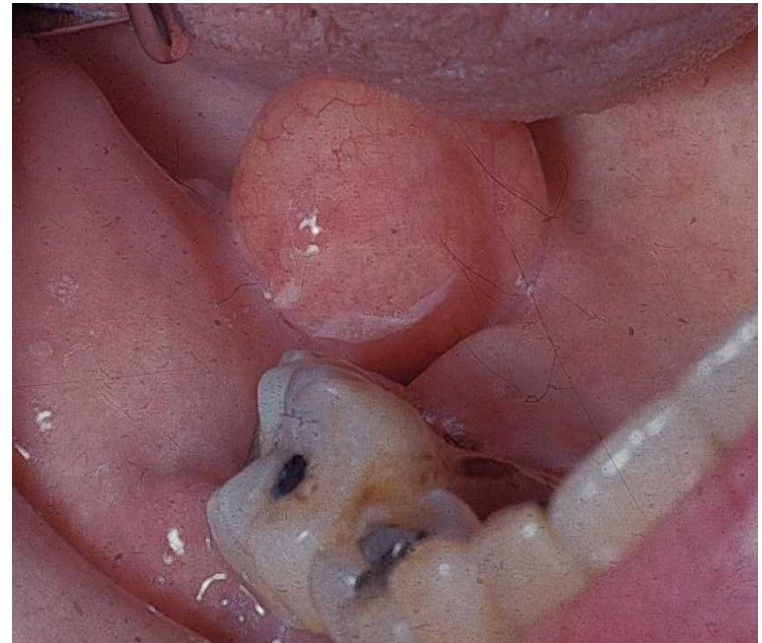
# Fibrosarcoma

- Malignant tumor consisting of a proliferation of atypical fibroblasts.
- Young adults and children
  - Microscopic: bundles of fusiform cells, with nuclear pleomorphism and atypical mitotic figures, that intersect in space, forming sharp angles, looking like a "fish bone"



# Lipoma

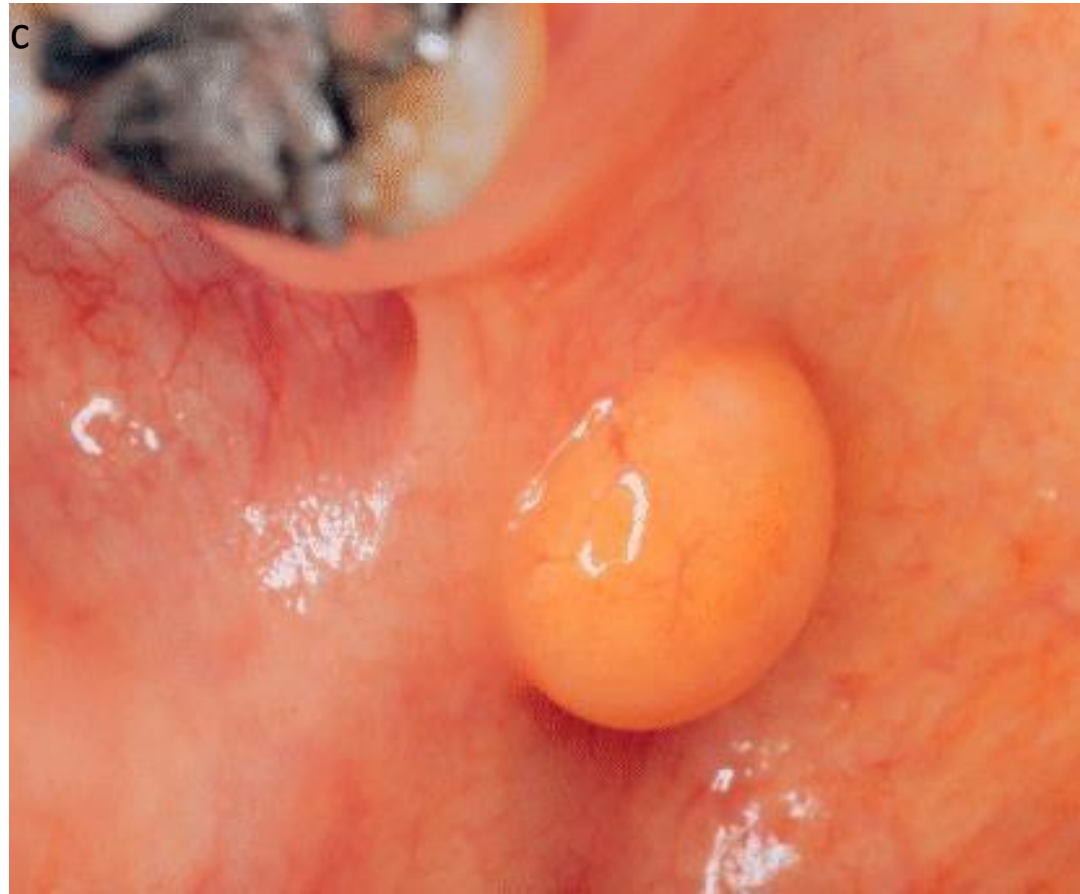- Age 40+, obese and female
- Rarely encountered in the oral cavity
- Localization: 50% of the oral lipomas are in the jugal mucosa. It can be in the tongue or lips.
- asymptomatic until they reach large size and may interfere with speech and chewing
- Treatment - excision
- Don't relapse



# Lipoma

- Macroscopic has nodular appearance, well delimited, sessile or pedicled, with smooth surface, elastic consistency and yellow color

- It grows slowly and can have variable dimensions, sometimes reaching 4-5 cm in diameter.

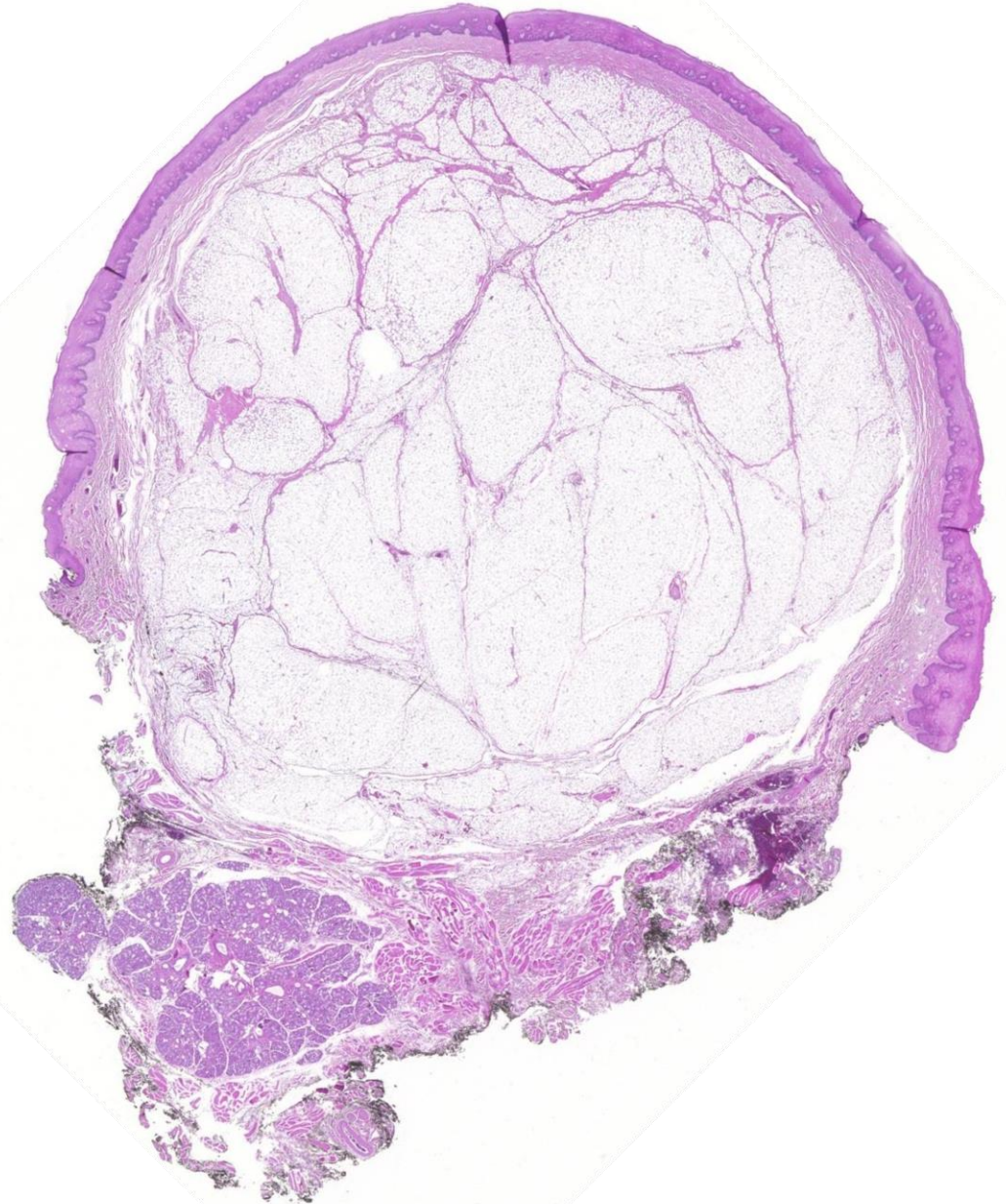




# Lipoma

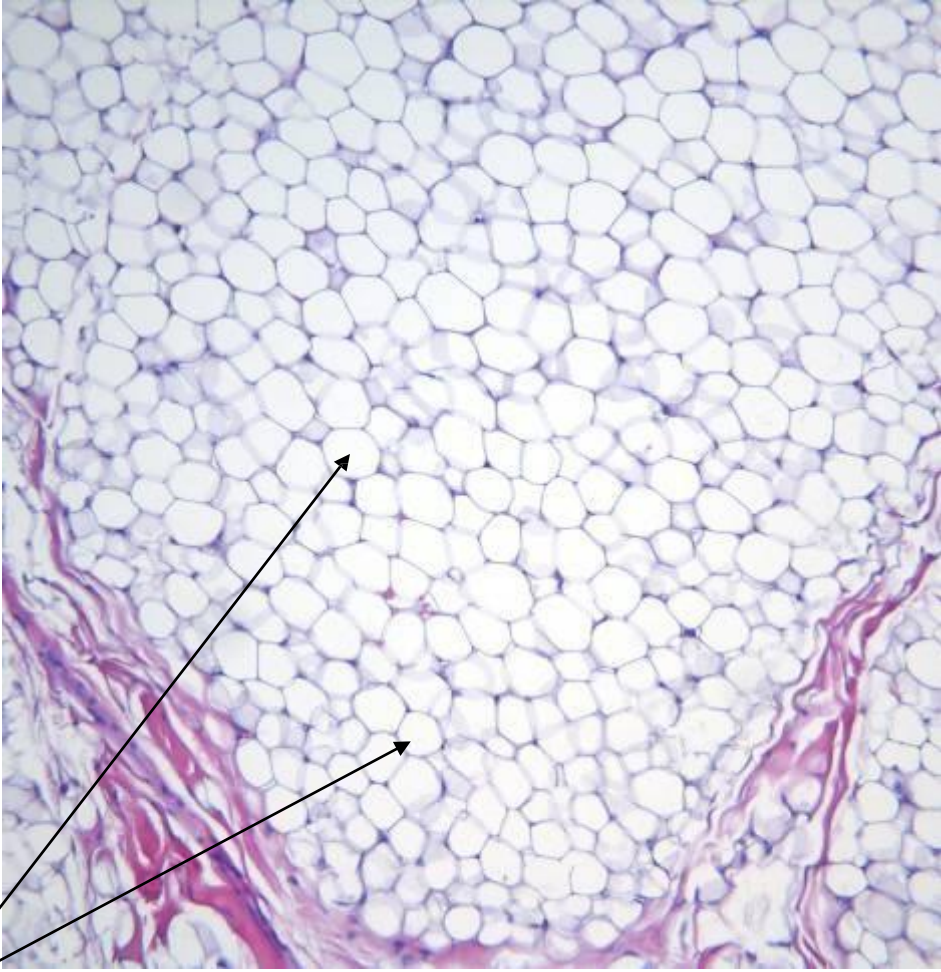
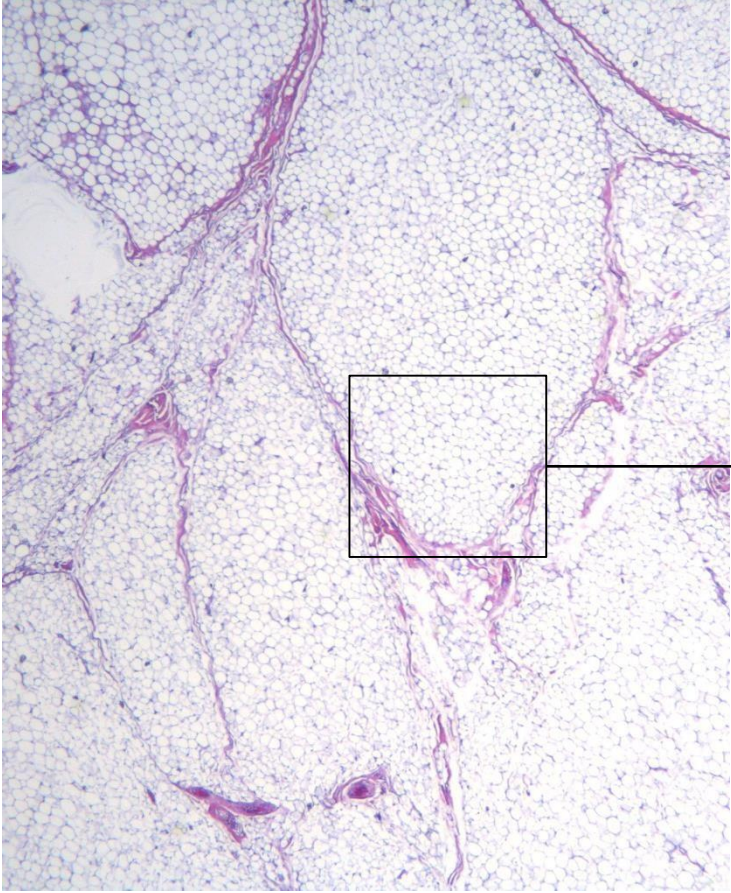
---

Microscopically, it consists of mature adipose cells, including conjunctival septum with blood vessels.



# Lipoma

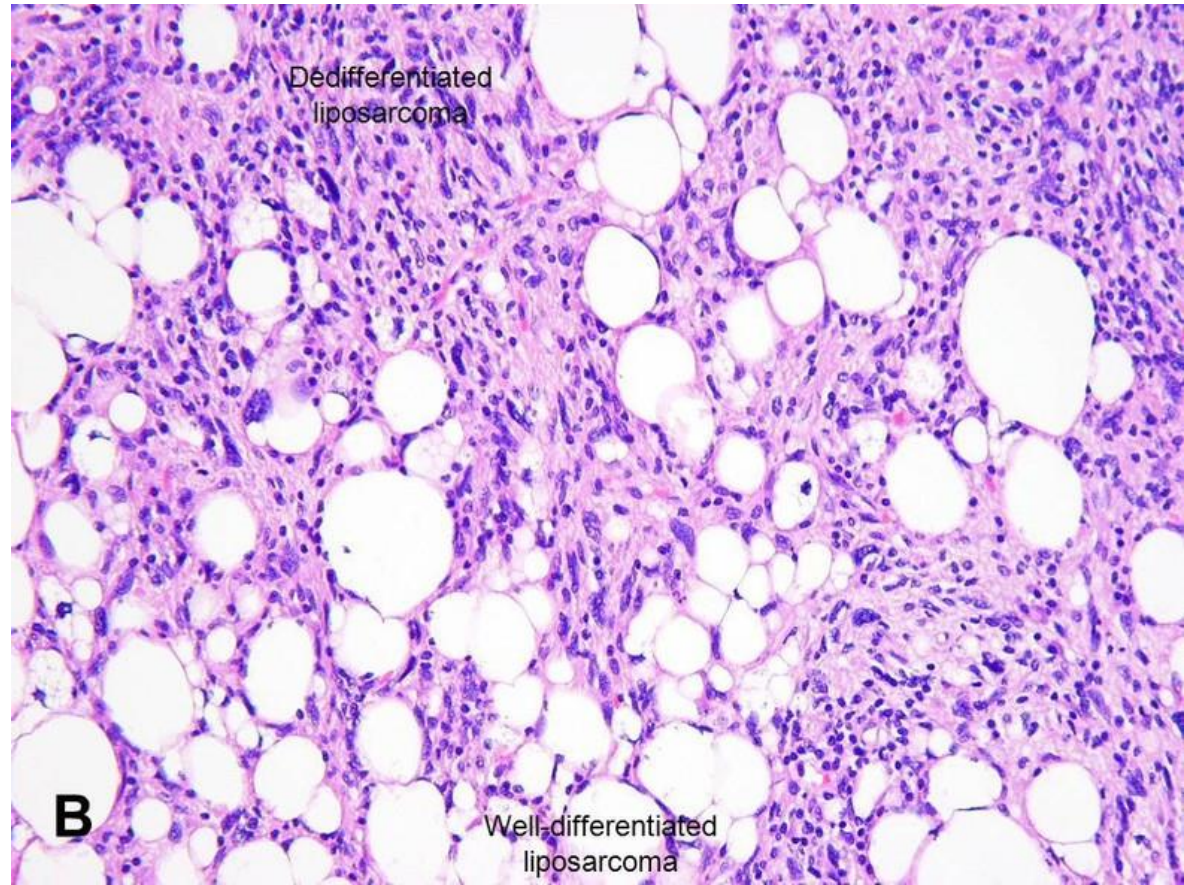
---



Normal adipos cells

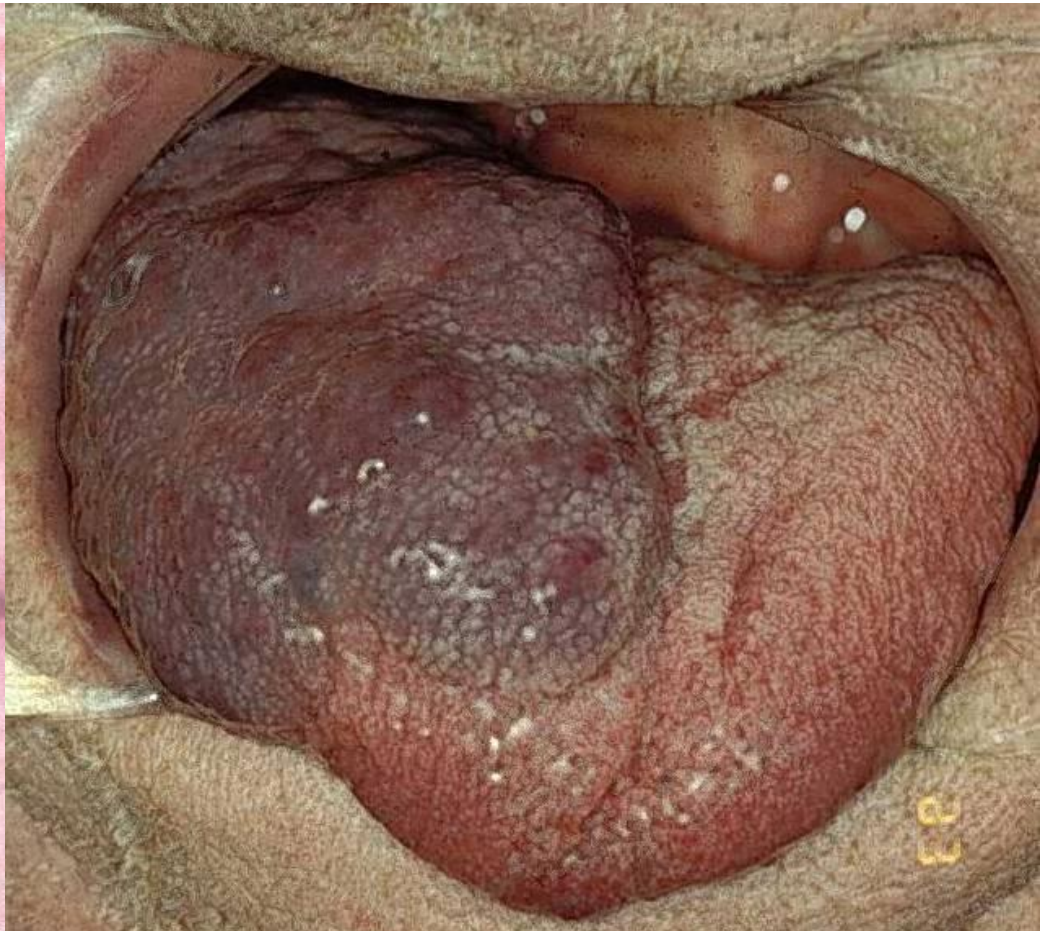
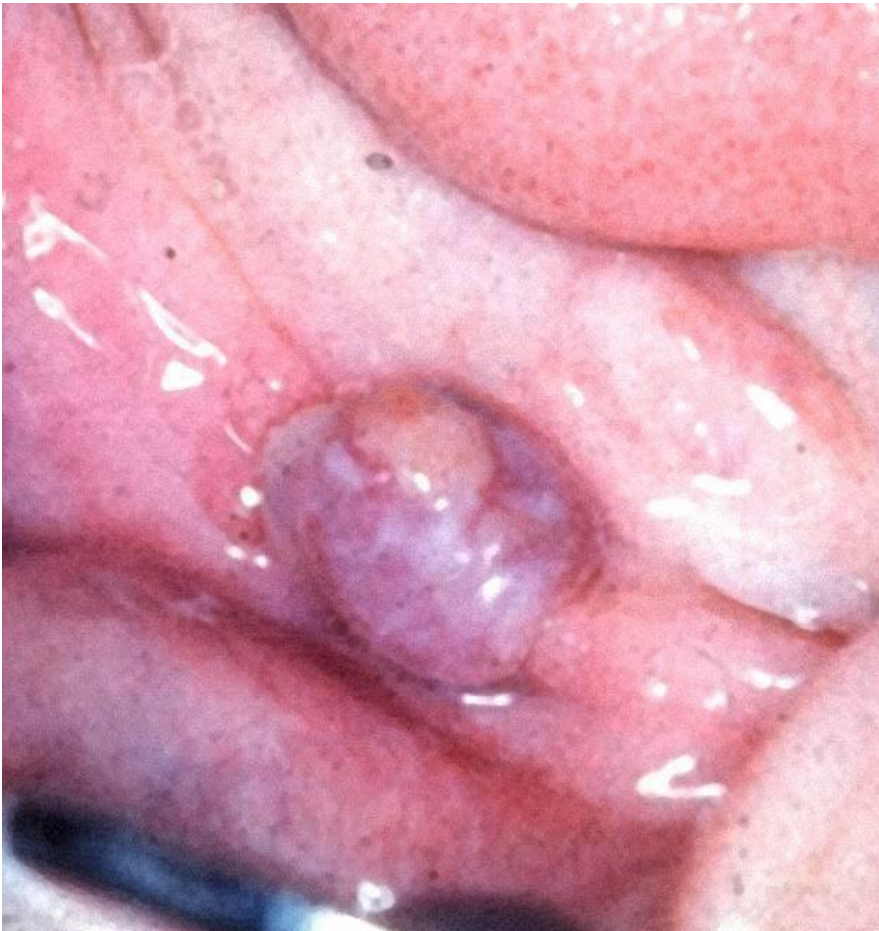# Liposarcoma

- Adults, frequently on the cheek and tongue
- Microscopic, can be presented in the form of a
  - myxoid liposarcoma (lipoblasts, capillaries and myxoid matrix)
  - round cell
  - well differentiated
  - pleomorphic



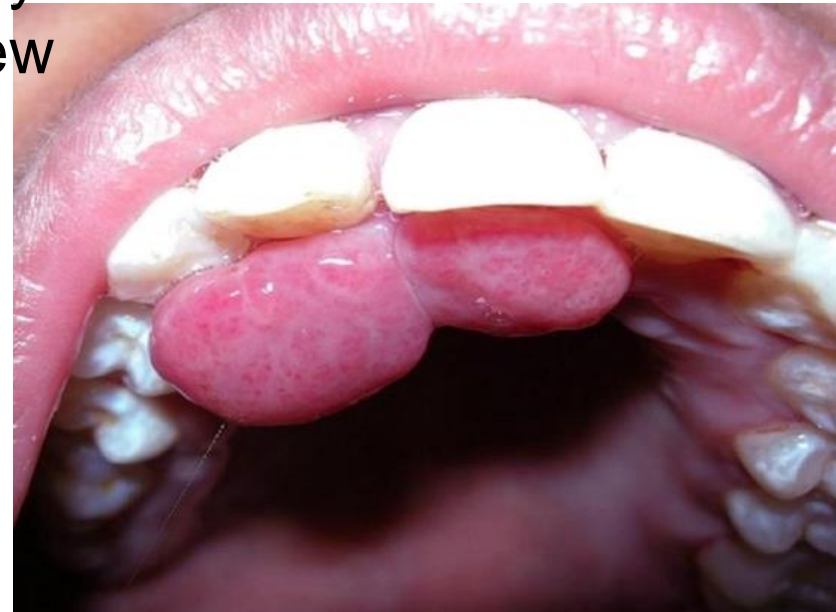# Hemangioma

- Congenital lesion, which grows rapidly after birth, but has a tendency of spontaneous involution

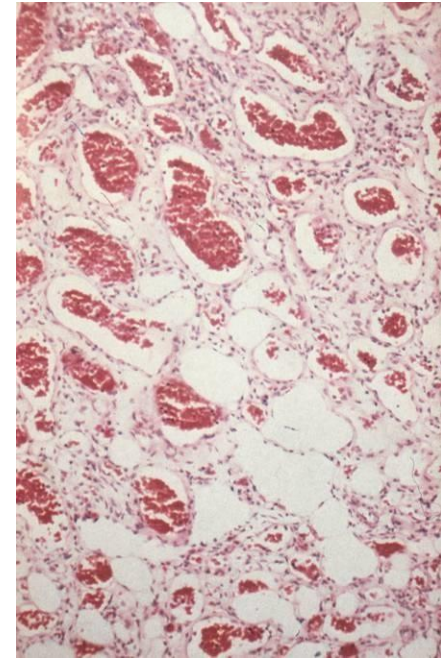
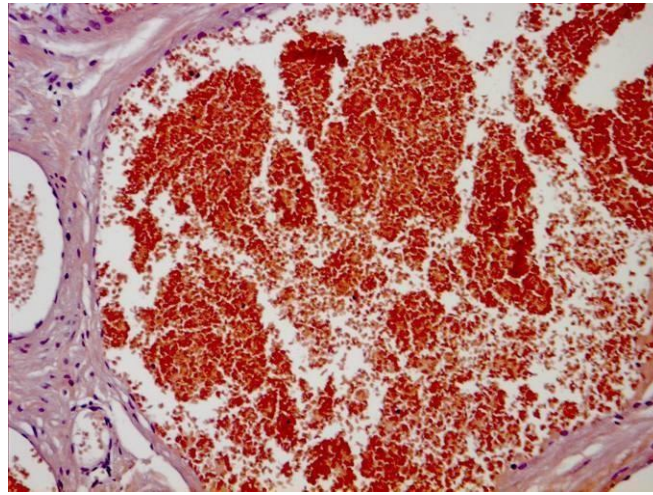
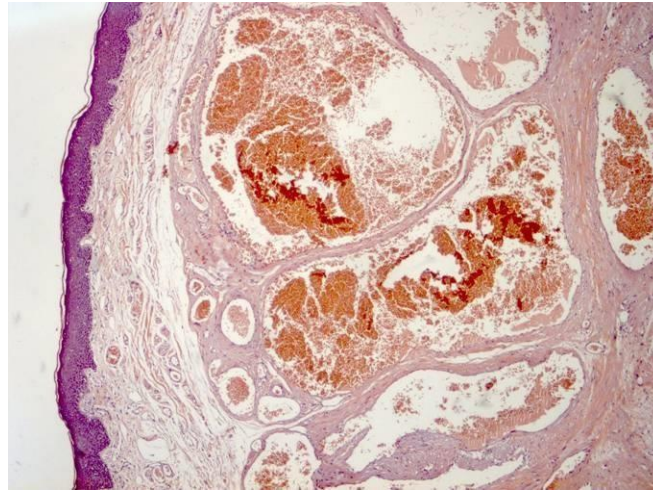
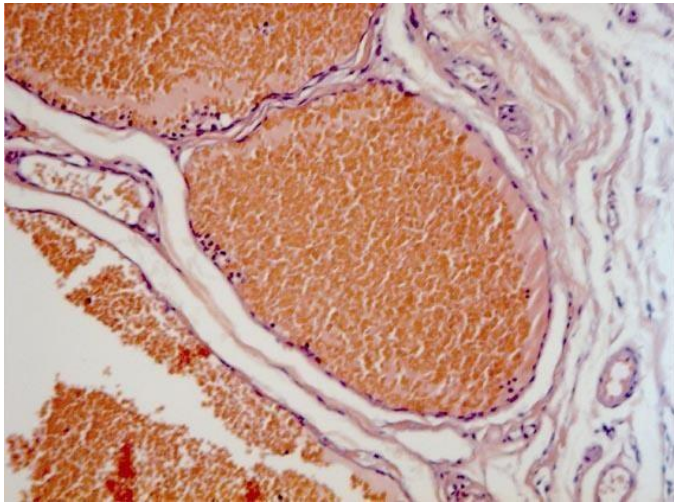
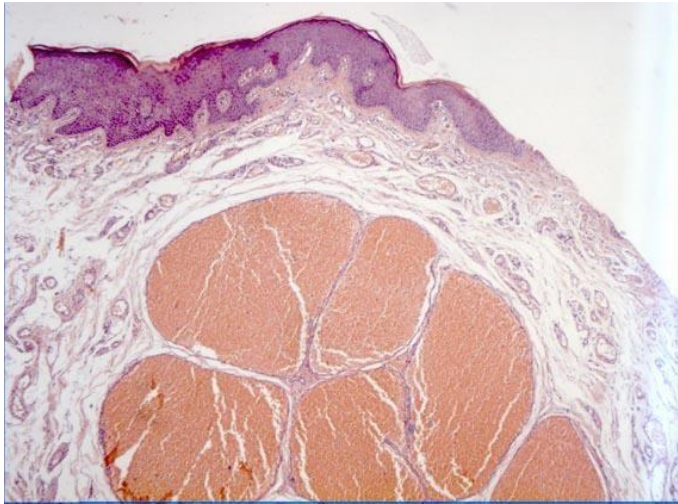


# Hemangioma

- Children and young adults
- Localization: tongue, lips, mucosa (buccal, gingival and palatal), salivary glands.
- appears as a soft mass, smooth or lobed, sessile or pedunculate and may vary in size from a few mm. up to a few cm.
- Treatment - excision
- Don't relapse



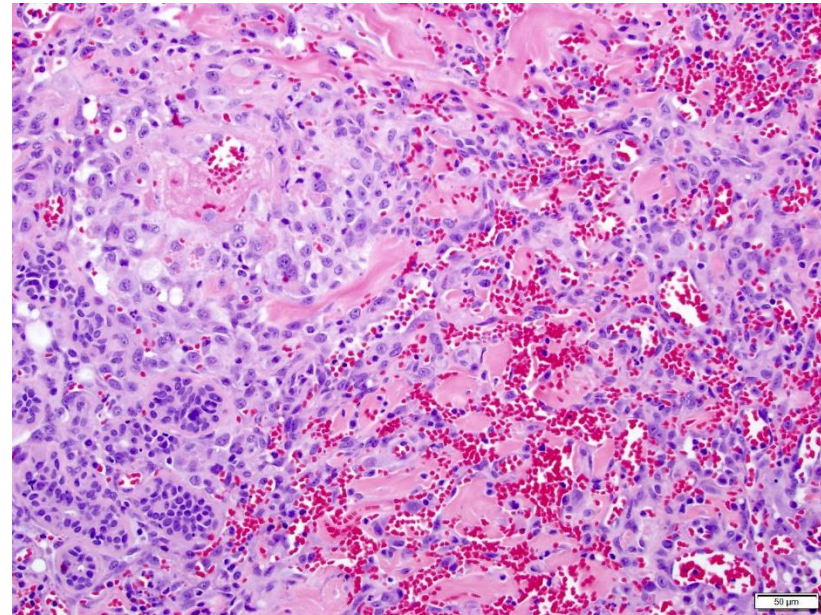
# Hemangioma



Two types: cavernous and capillary (can be combined)

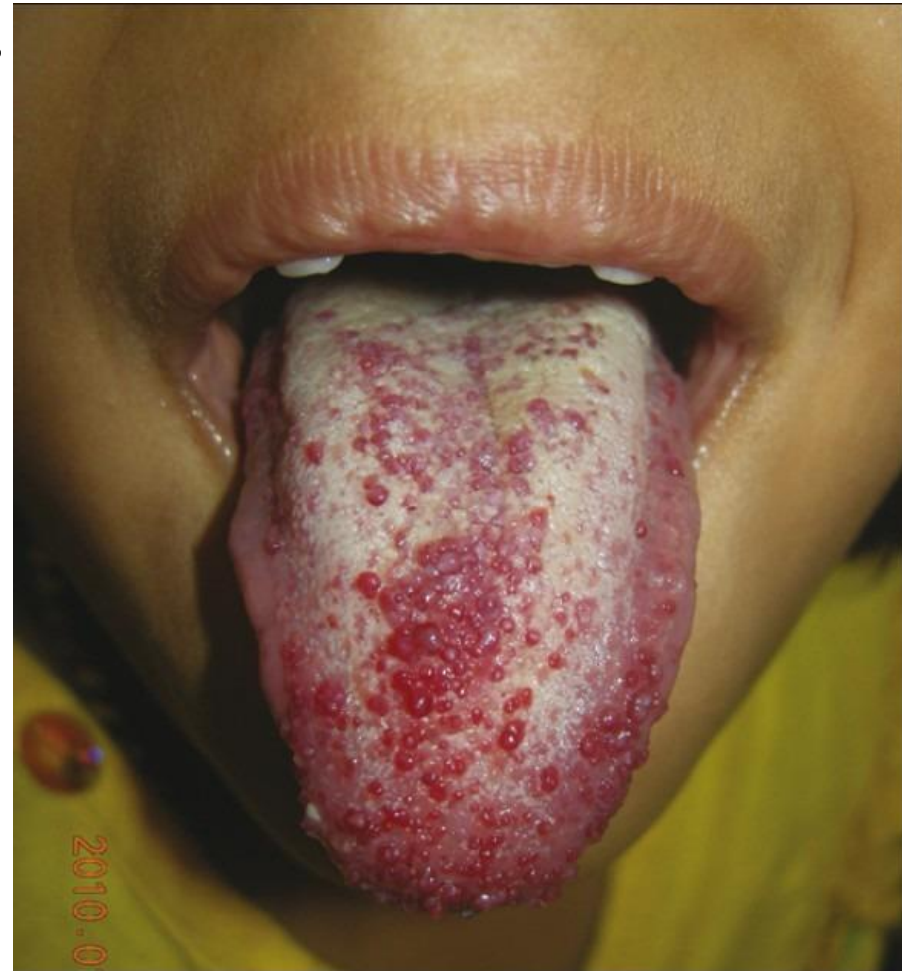# Angiosarcoma

- Purple color especially at the level of the mandible
- Rare, it develops from the vascular endothelium
- Microscopic, proliferation of anastomosed vascular spaces and delimited by atypical endothelial cells



# Lymphangioma

- About half of the lesions are observed at birth and about 90% develop at the age of 2 years
- Location: on the back of the tongue, followed by the palate, mouth and gingival mucosa and lips.





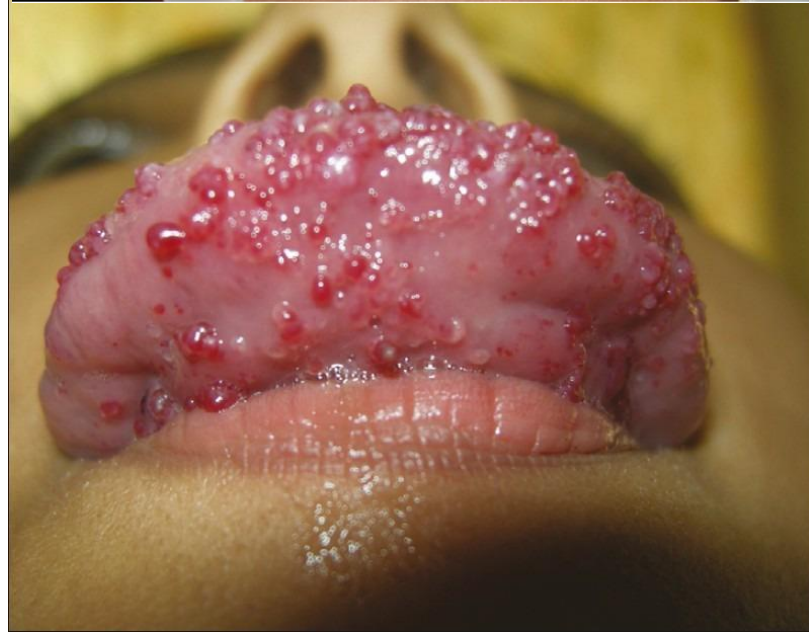
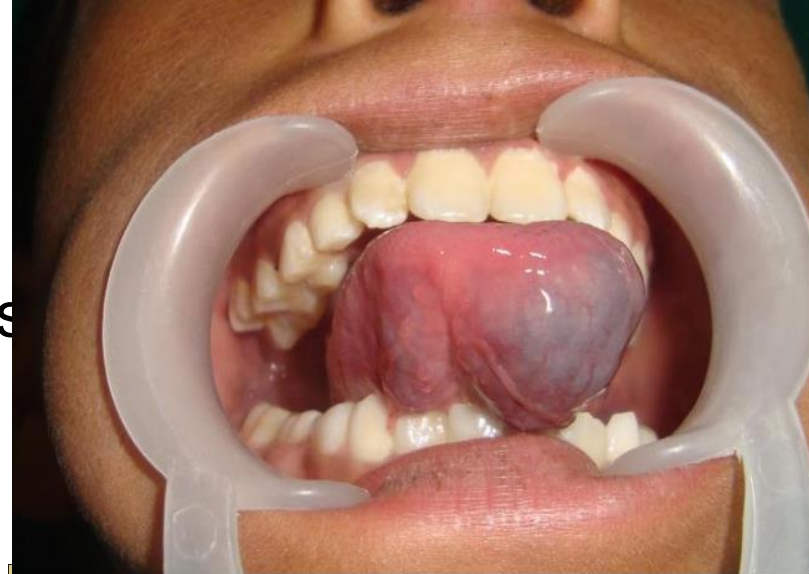# Lymphangioma

Multiple papular lesions of a few mm.,  
Or formation of several cm.

Treatment - excision

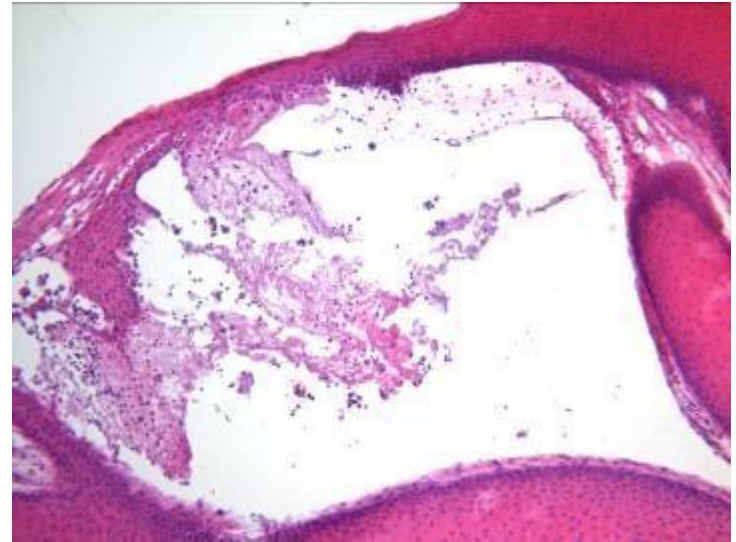
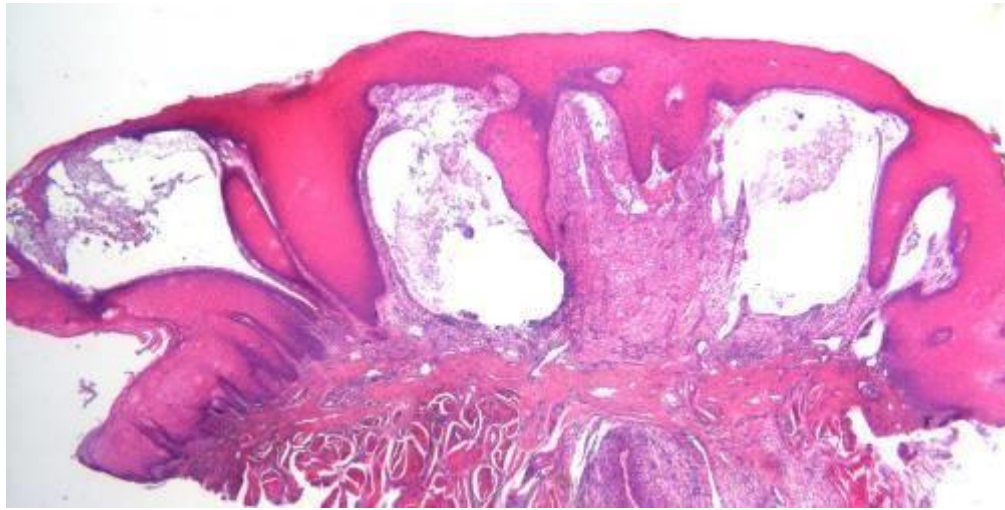
The prognosis is good for most patients  
although large tongue tumors can  
lead to airway obstruction.

Don't relapse

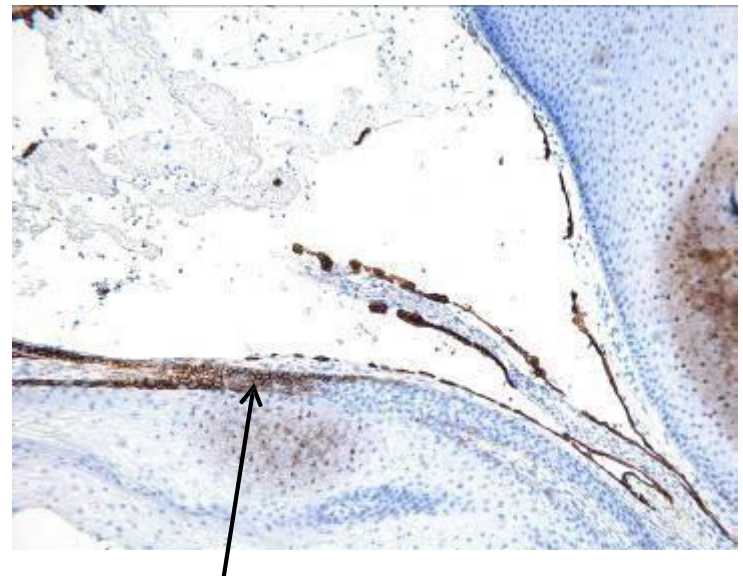
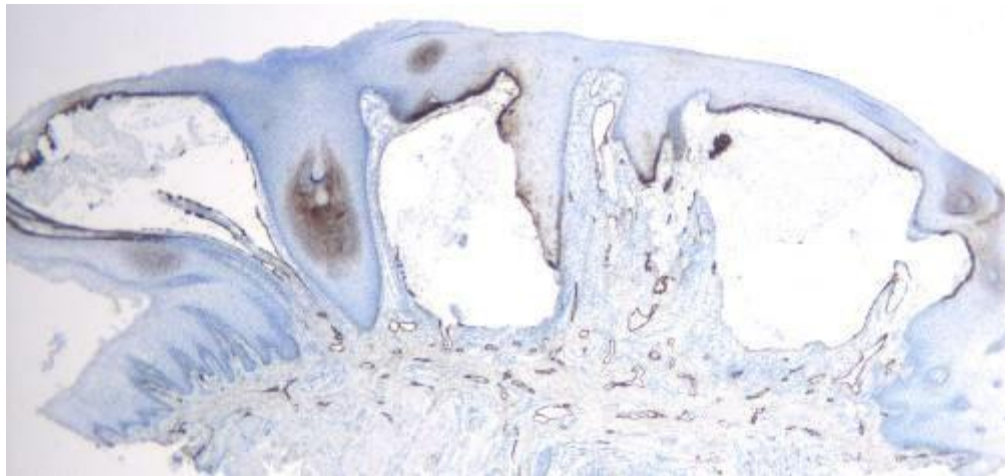


# Lymphangioma

---



Lymphatic vessels (erythrocytes absent)

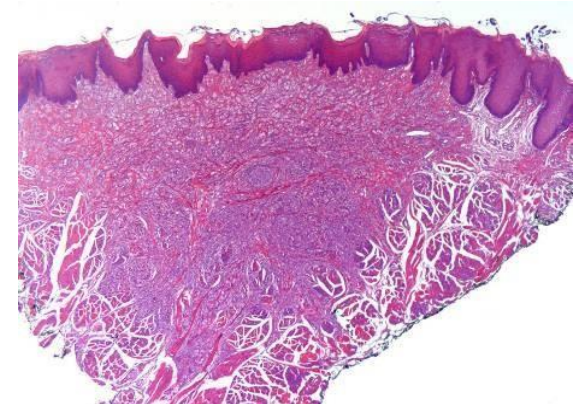


Antibodies against lymphatic vessels

# Granular cell tumor

---

- For a long time considered to be of myoblastic origin ("granular cell myoblastoma")
- Currently, the lesion is thought to come from Schwann cells
- The fourth to sixth decade and is rare in children
- asymptomatic solitary node on the front of the tongue, sometimes having a yellow or pink appearance 2cm in diameter.
- Excision treatment
- Rare recurrence

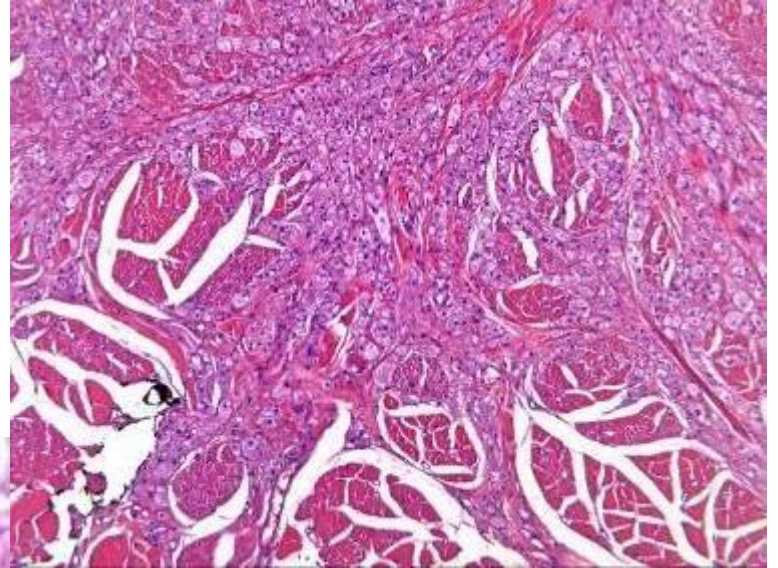


# Granular cell tumor

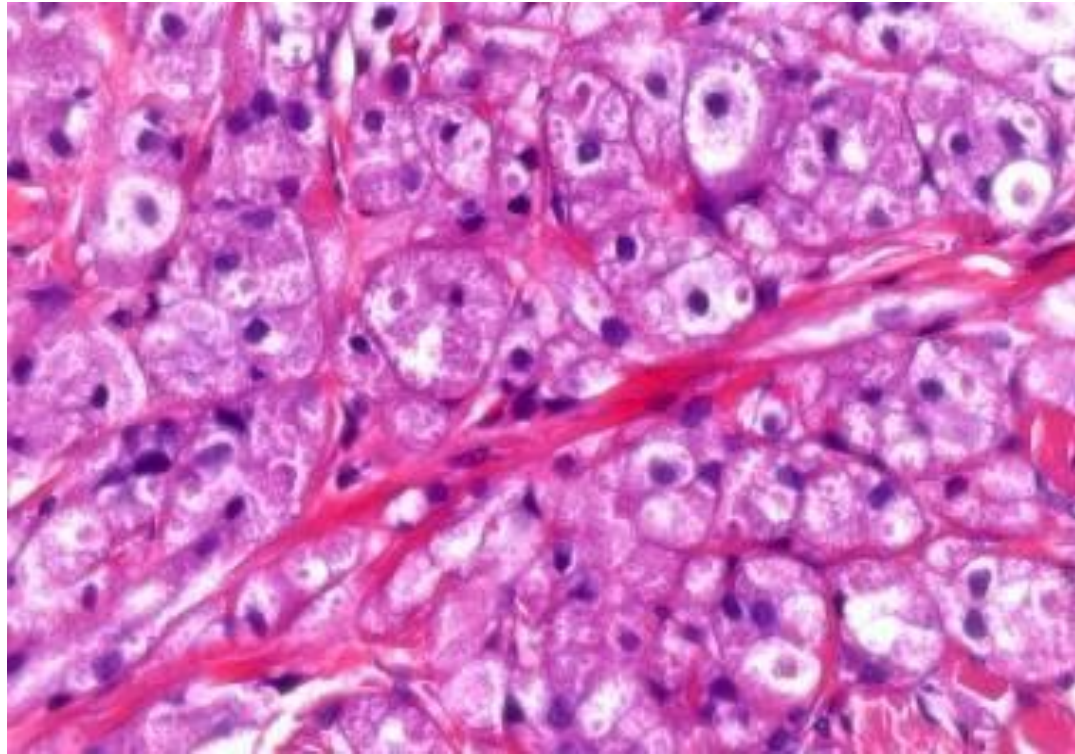
---

Biopsy of the tongue

Large polygonal cells with eosinophilic cytoplasm, fine granular and small hyperchromic nuclei



Nu are capsulă- infiltrează mușchii striați



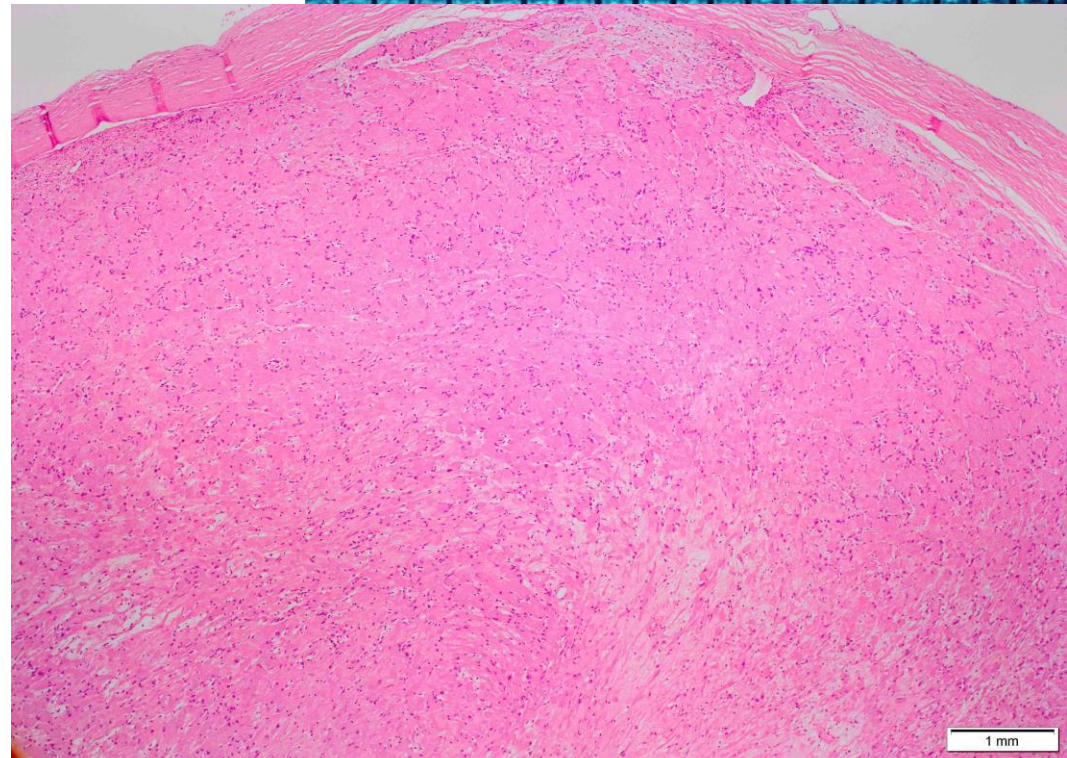
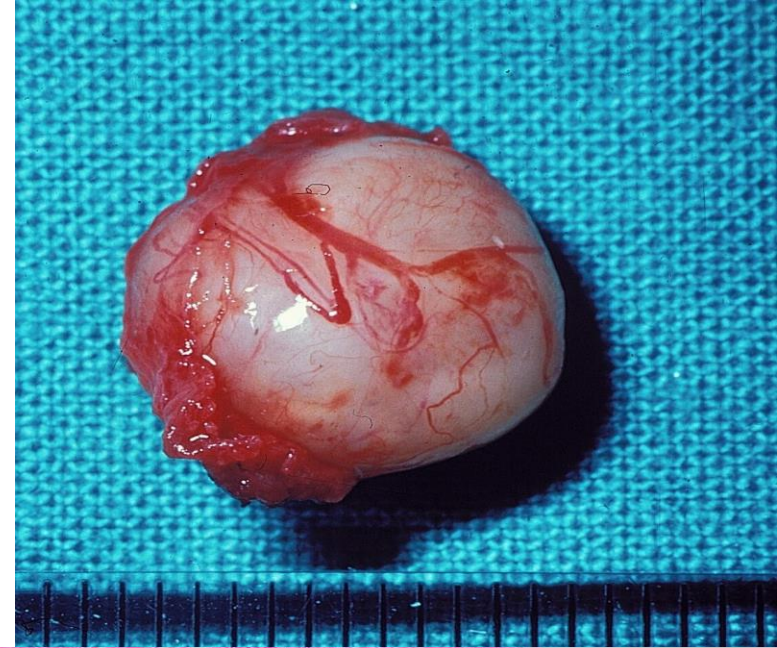
# Schwannoma

20-50 years

Benign tumor of nerve tissue from differentiated Schwann cells

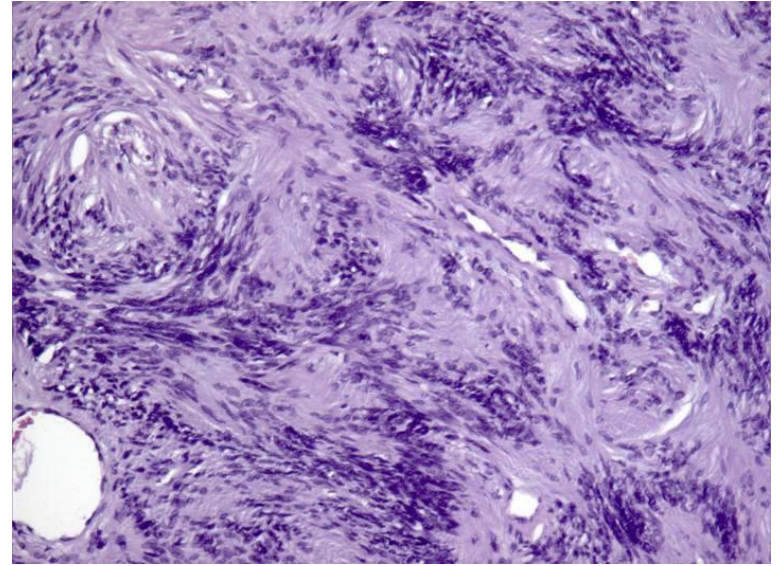
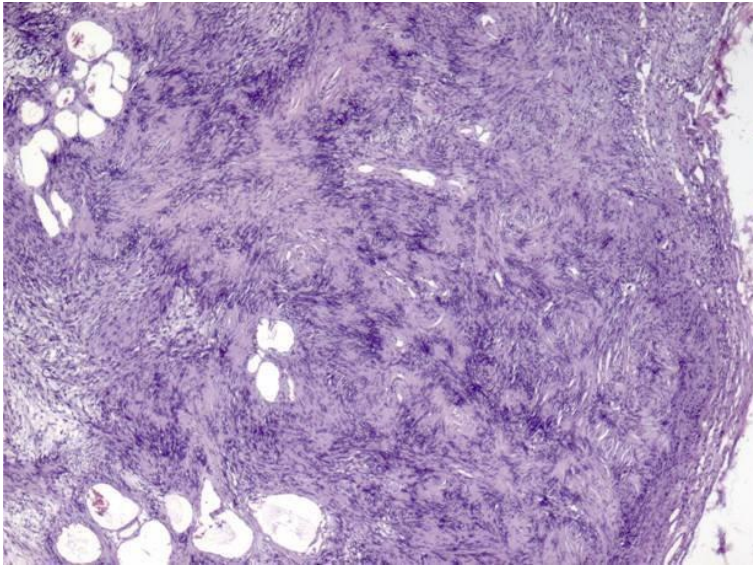
Biphasic: compact hypercellular Antoni A zones (fusiform cells arranged in bundles) and hypocellular Antoni B hypocellular zones

The elevated knot, encapsulated

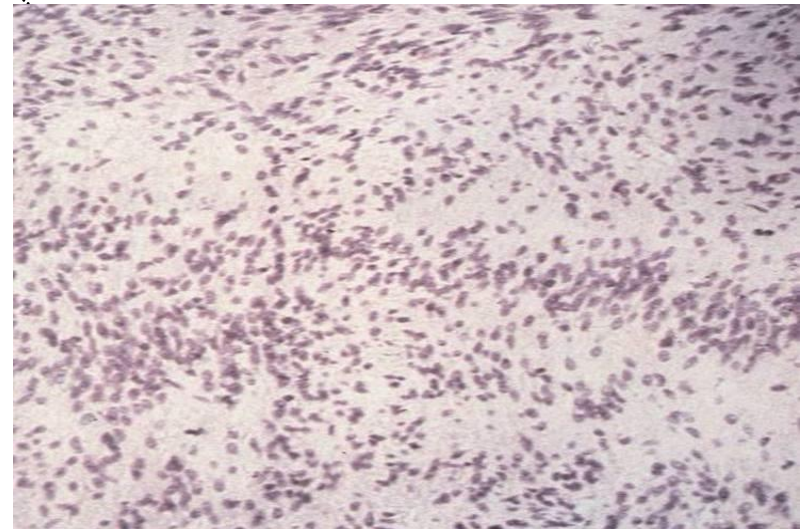
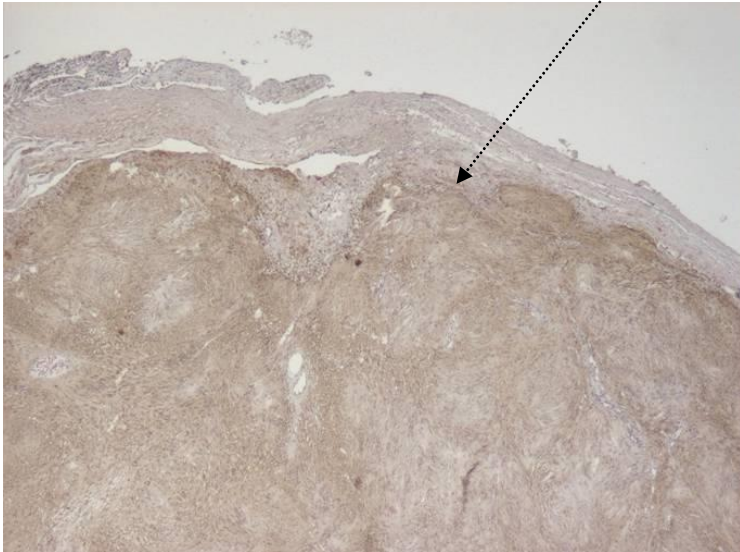


Schwannoma from the right lateral border of tongue (H&E)

# Schwannoma

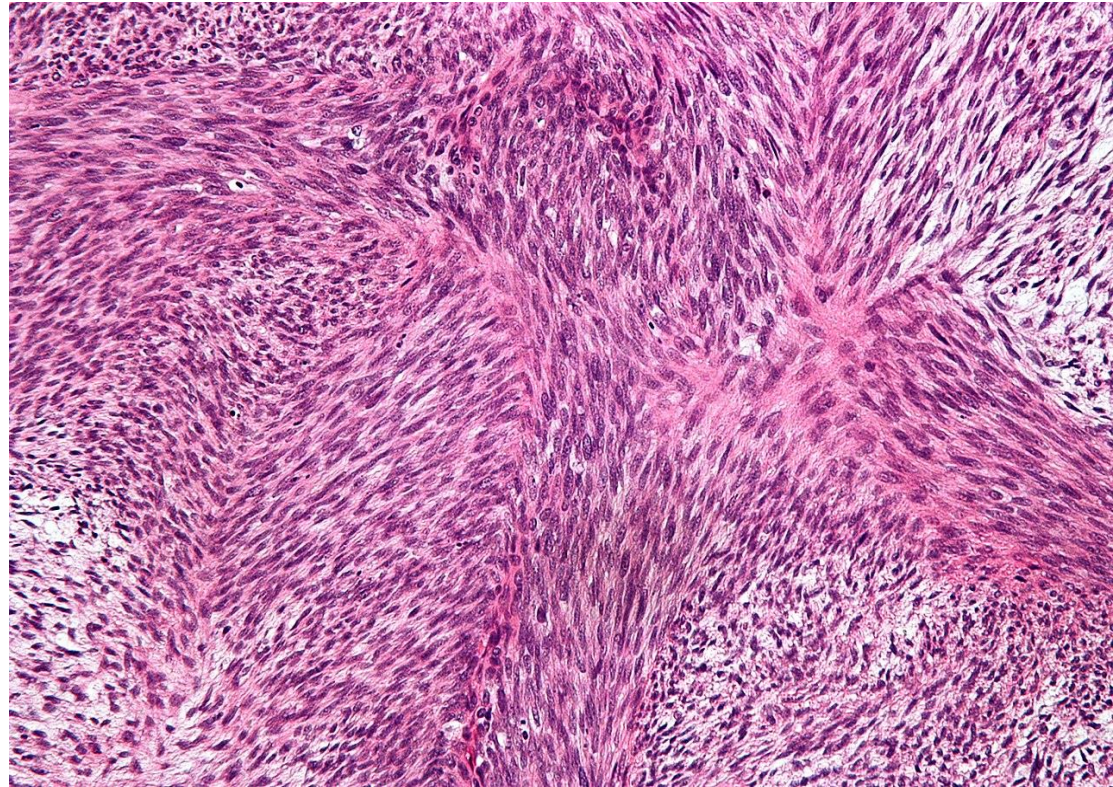


Antibodies against nerve fibers



# Malignant schwannoma

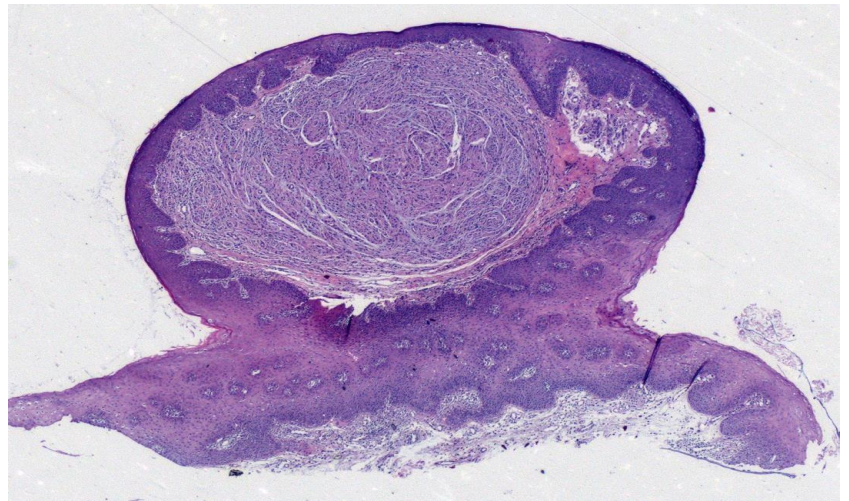
- Young adults, location in the jaw, lips and mouth mucosa
- Microscopic, proliferation of fusiform cells, arranged in fascicles, the cells having corrugated nuclei with obvious atypia



# Neurofibroma

---

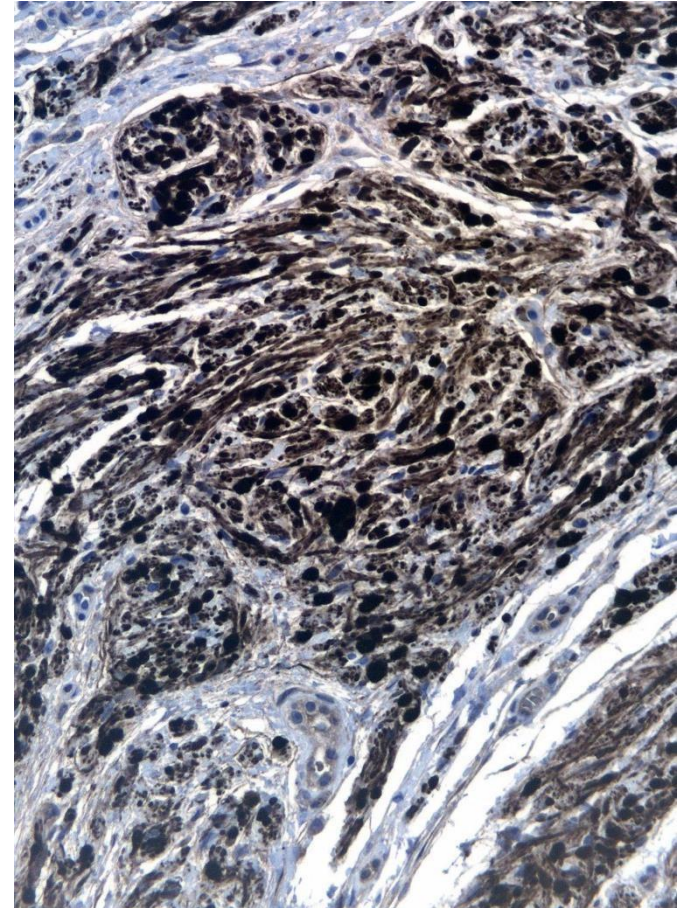
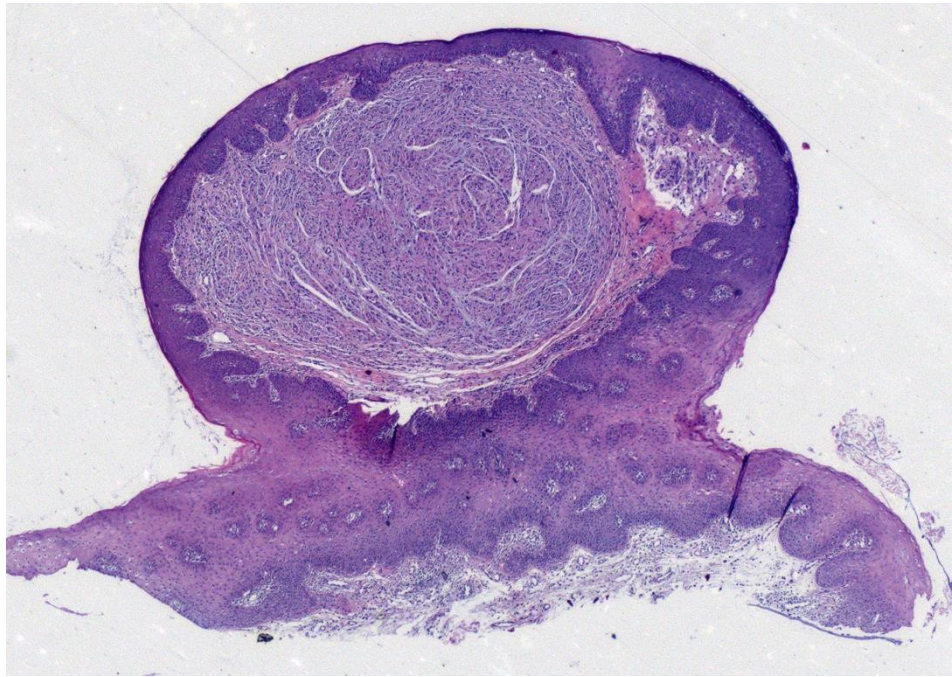
- It occurs in the second or third decade of life
- Benign peripheral nerve tissue tumor
- the neuronal component comprising transformed Schwann cells and a non-neoplastic fibrous component including fibroblasts
- Elevated papule with a whitish, soft, unencapsulated appearance



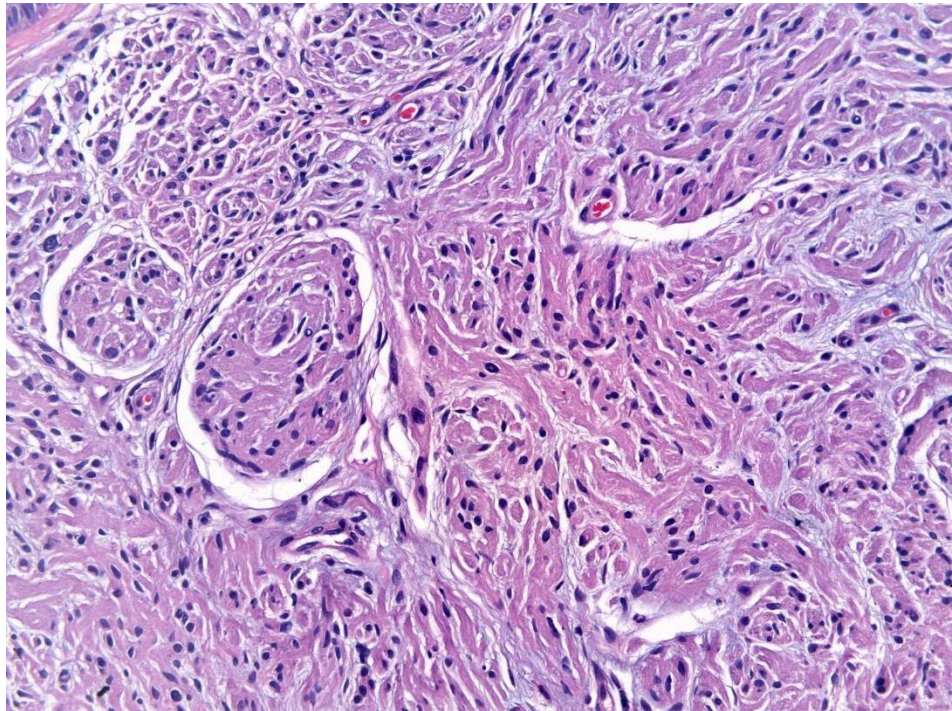


# Neurofibroma

---



S100



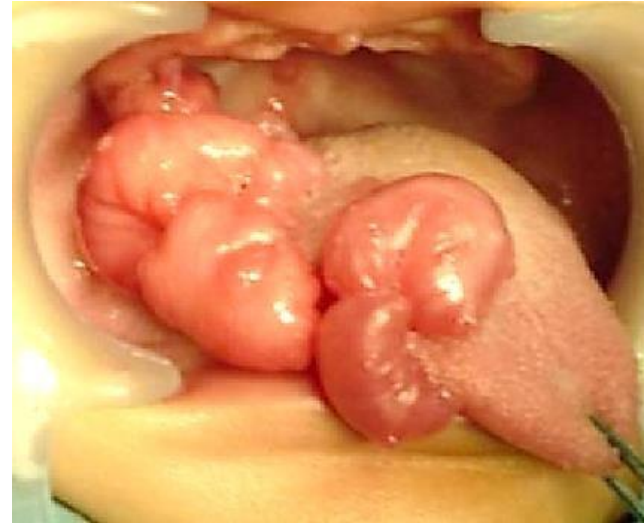Fusiform cells arranged in bundles

# Benign tumors of muscular tissue

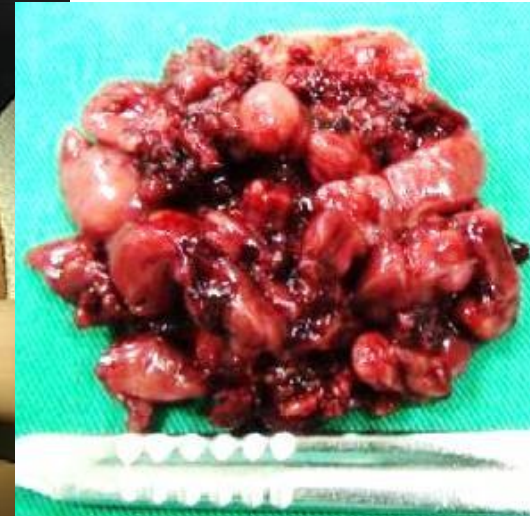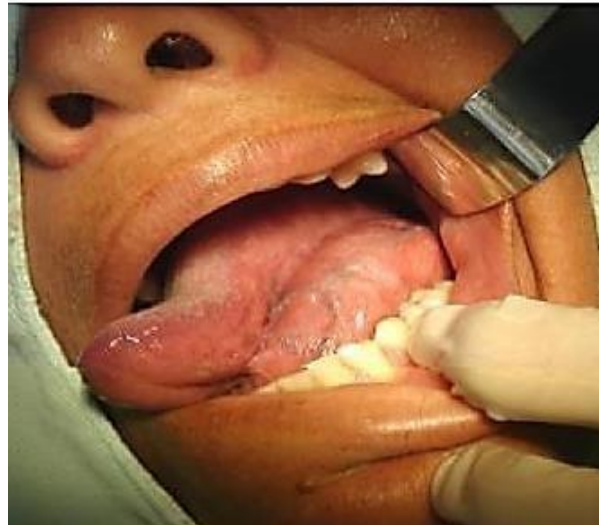- Leiomyoma            benign tumor of smooth muscle tissue
- Rhabdomyoma       benign tumor that derives from striated muscles

# Benign tumors of muscular tissue

Leiomyoma

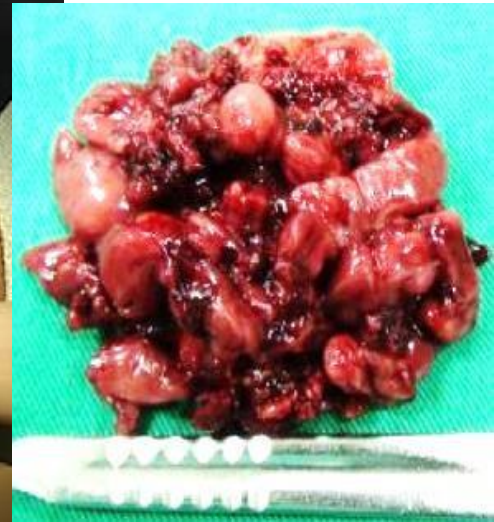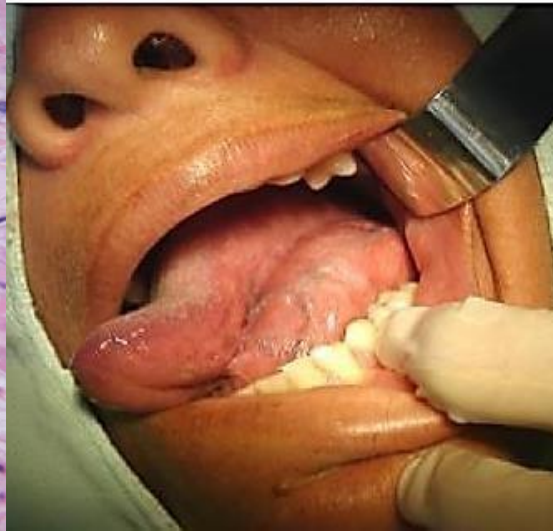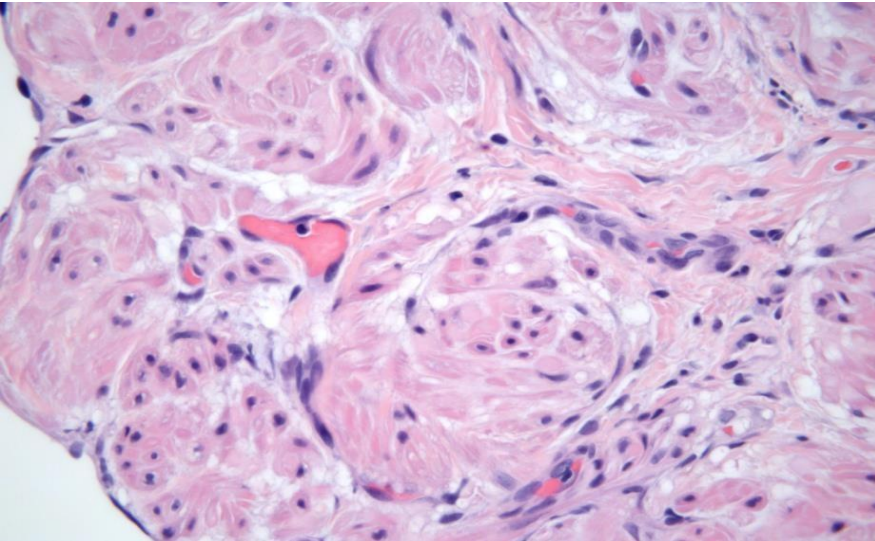


Rhabdomyoma

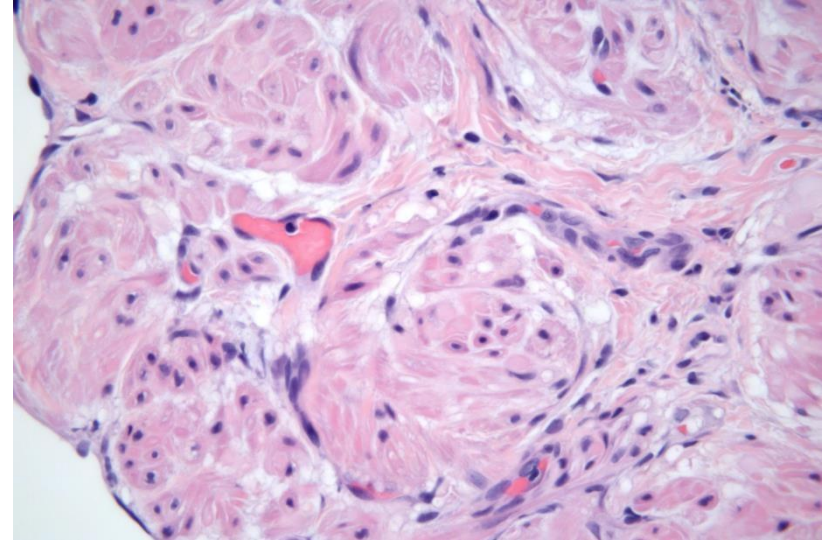
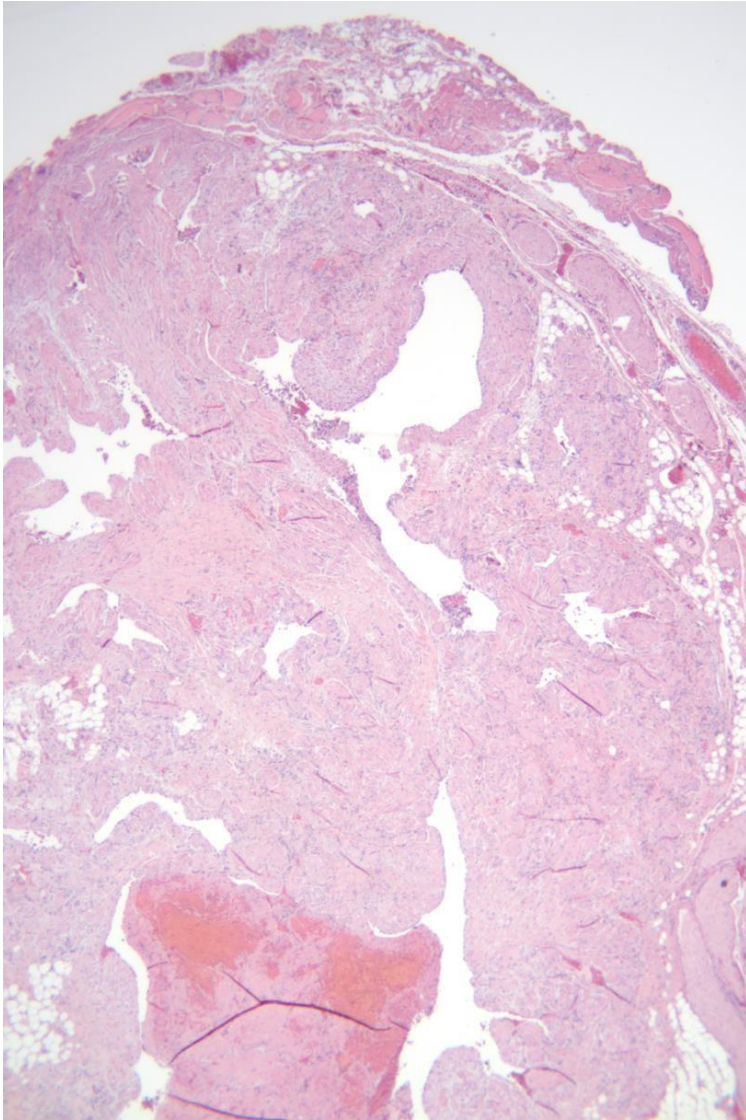


# Leiomyoma

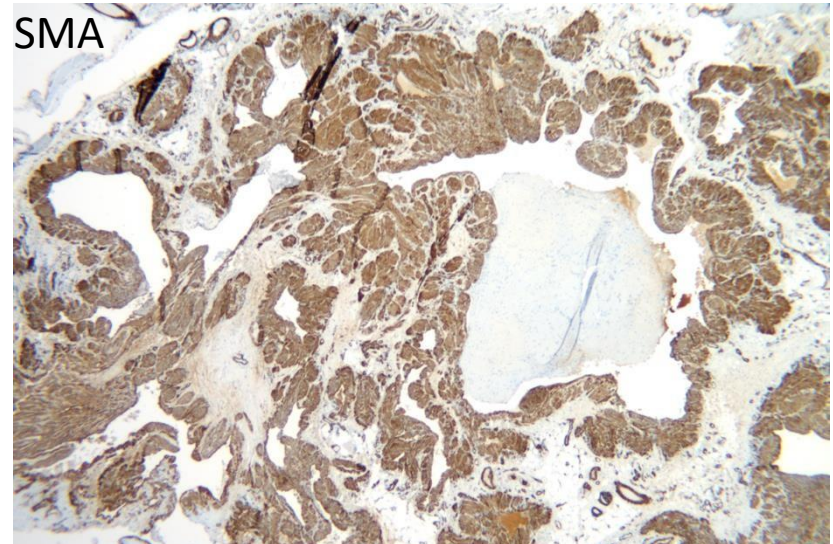
- Appears at any age
- Rare in the oral cavity
- The firm knot located at the level of the lips, tongue and palate
- Microscopic, well delimited, consisting of bundles of smooth muscle fibers, elongated with fusiform nuclei.



A 46-year-old woman with asymptomatic lower lip tumor - present for several months.  
Tentative diagnosis: pleomorphic adenoma? Oral mucocele?



Anticorpi împotriva celulelor musculare netede confirmă diagnosticul de leiomom

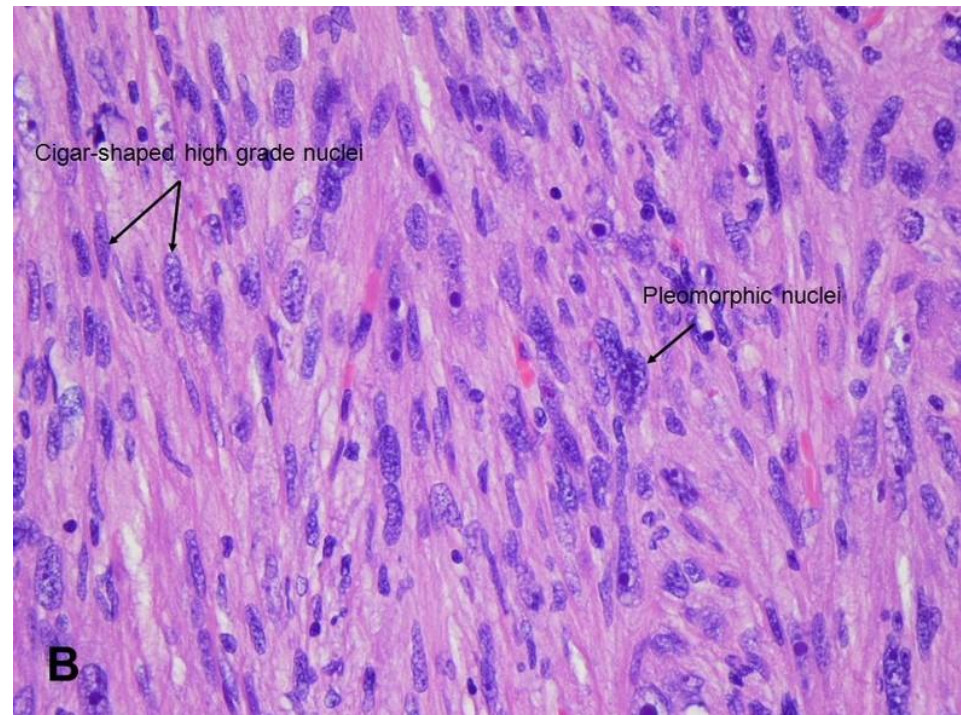


Diagnosis: Leiomyoma

# Leiomyosarcoma

Appears at any age

- Microscopic, proliferation of fusiform cells, with abundant cytoplasm, eosinophils and oval nuclei, arranged in fascicles, with numerous mitotic figures.

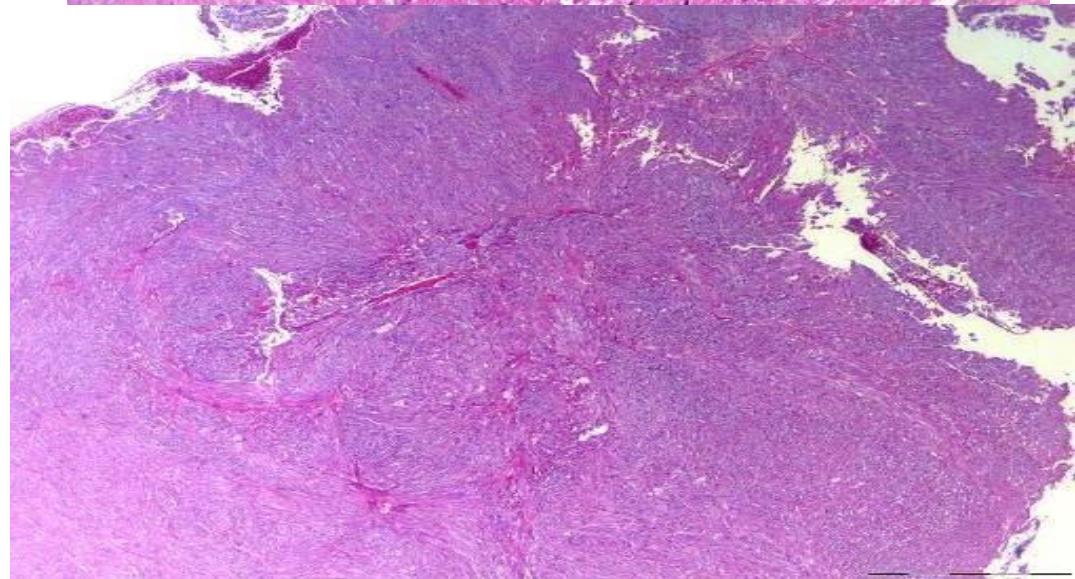
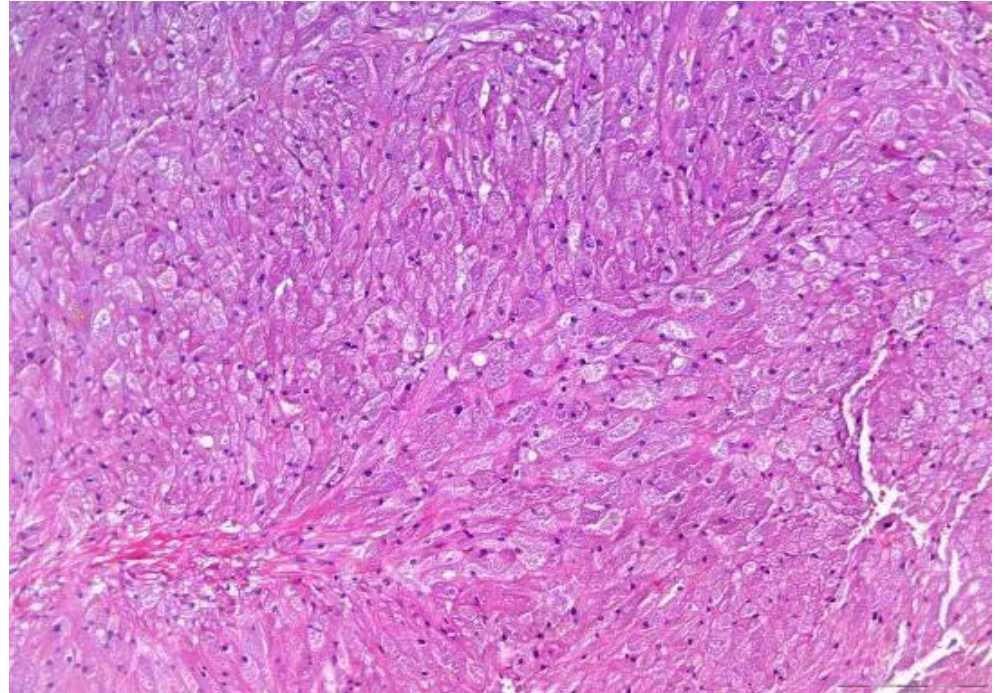


# Rhabdomyoma

Consists of similar cells  
to the striated muscles

Adult men (adult rhabdomyoma)

Location: buccal floor, soft palate and  
tongue base

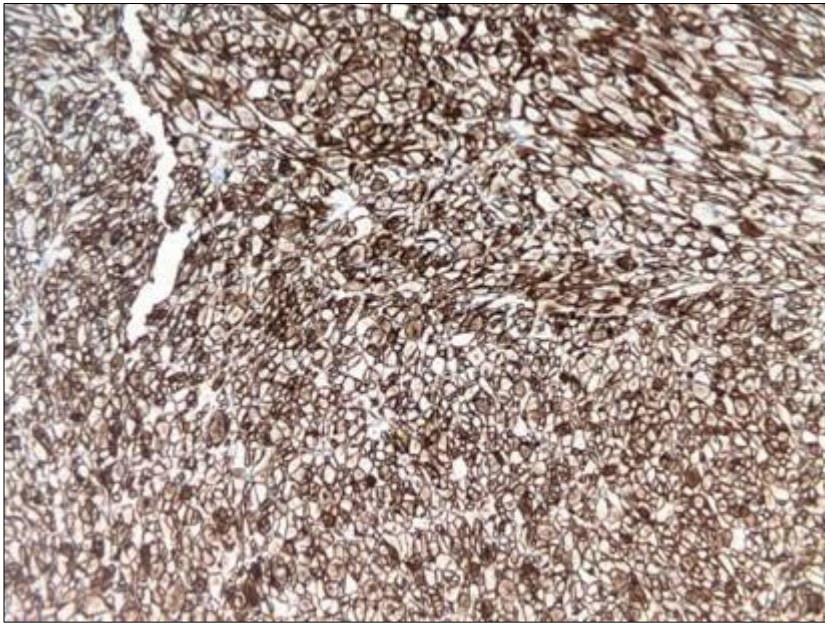


# Rhabdomyoma

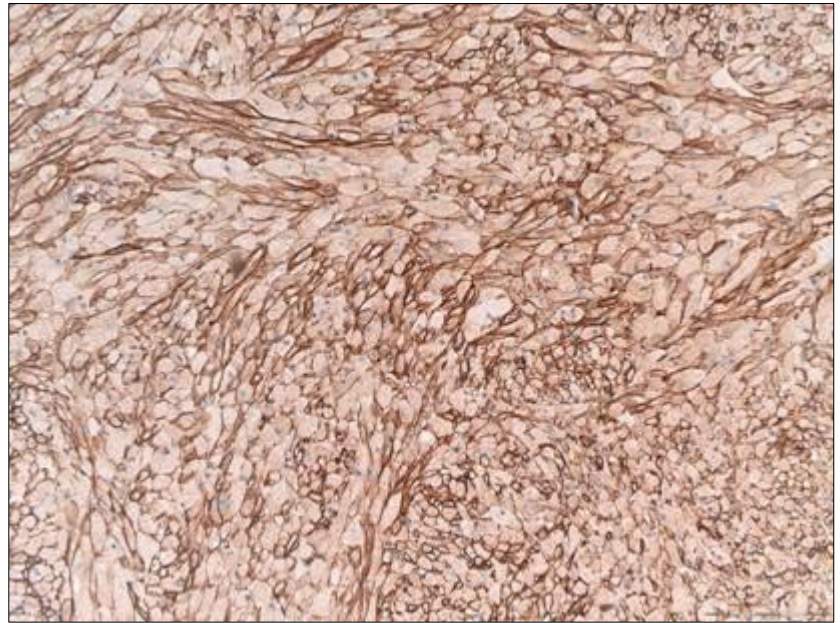
---

Antibodies against striated muscles

Desmin



Actin HHF35 (actină specifică musculară)

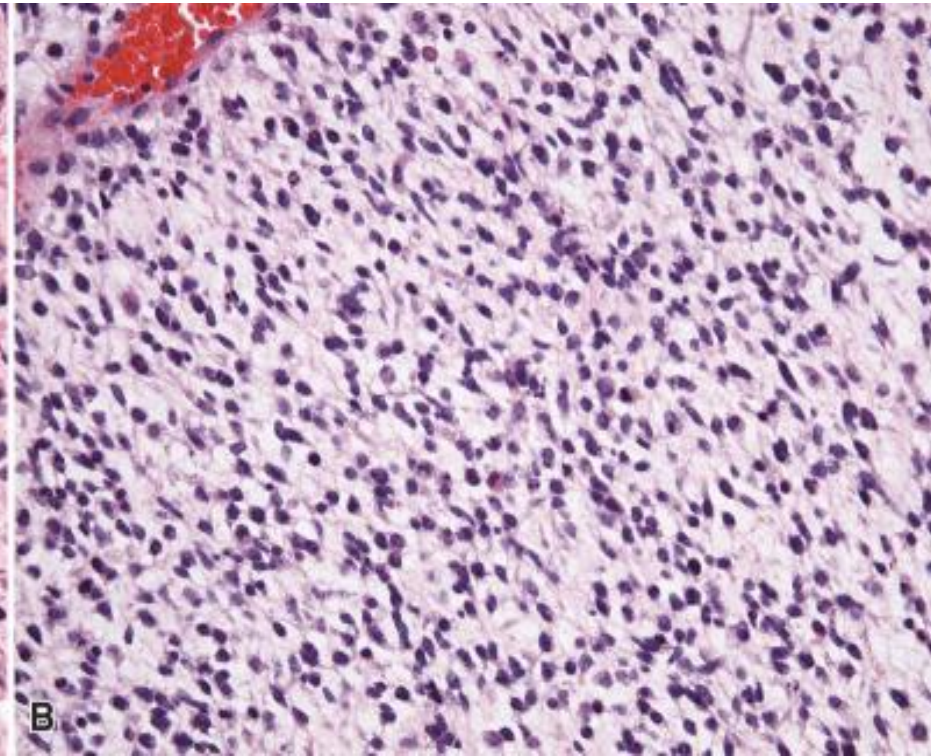
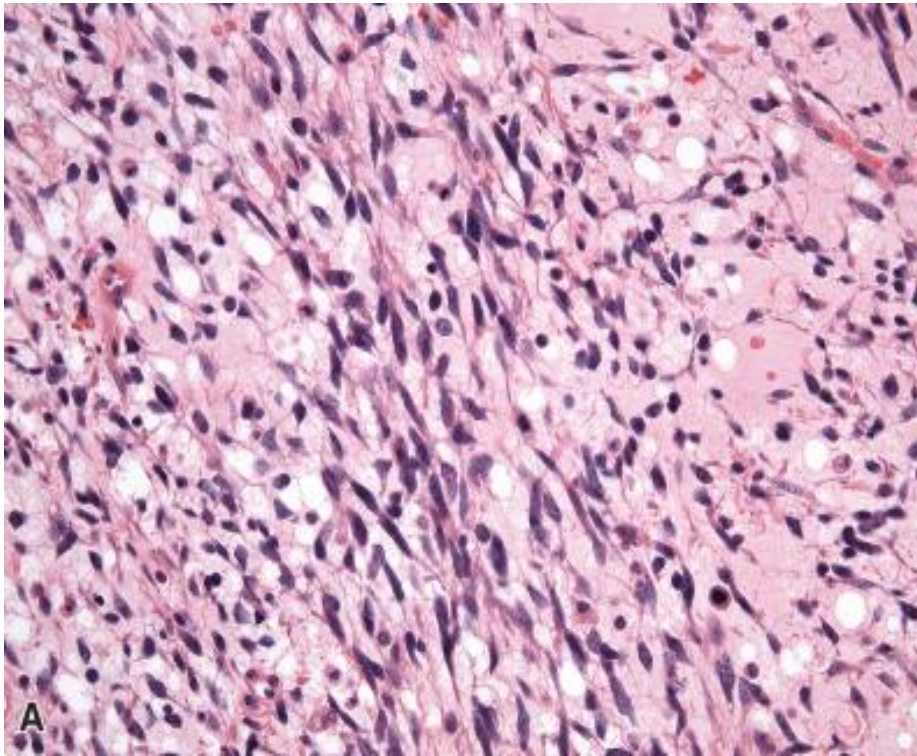




# Rhabdomyosarcoma

- The most common sarcoma in children
- It has three variants:

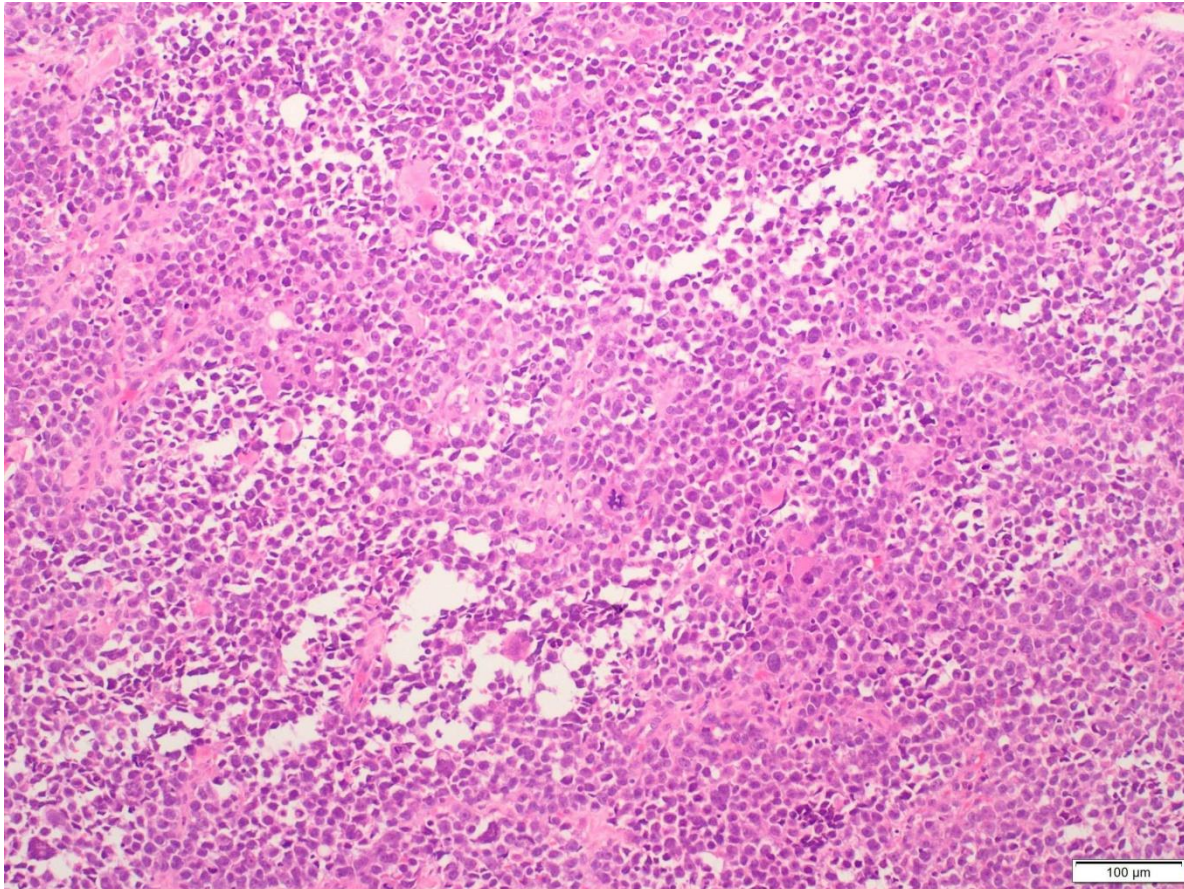
1. Embryonic (hypercellular areas, formed by round or fusiform tumor cells, alternating with hypocellular areas, which are characterized by a myeloid stroma).



# Rhabdomyosarcoma

- It has three variants:

- 2. alveolar (proliferation of non-cohesive, round tumor cells, arranged in alveolar structures, separated by septa of dense fibrous connective tissue).

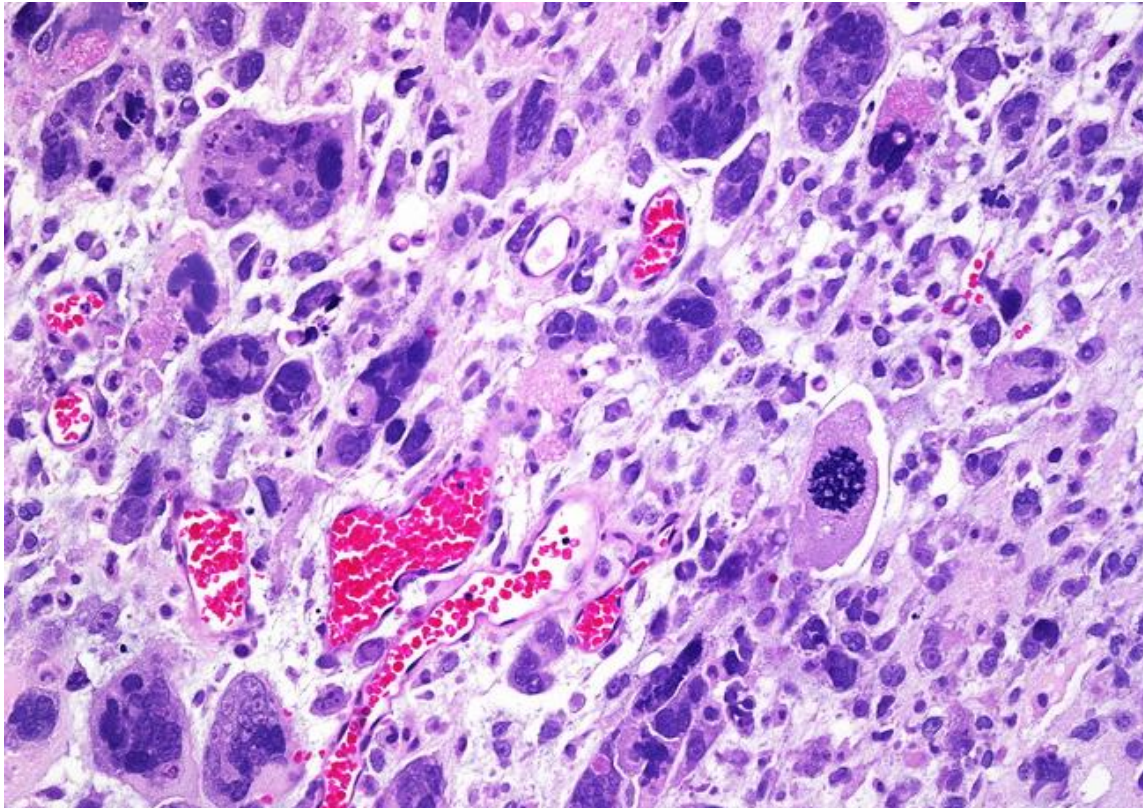


Soft tissue, alveolar rhabdomyosarcoma, classical subtype

# Rhabdomyosarcoma

3. pleomorphic (proliferation of tumor cells, fusiform or large and multinucleated pleomorphic).

- It grows rapidly and infiltrates adjacent tissues.
- The most frequent location is at the palate level



# Myxoma

It is not encapsulated. It consists of free myxomatous stroma, with stellate cells.

