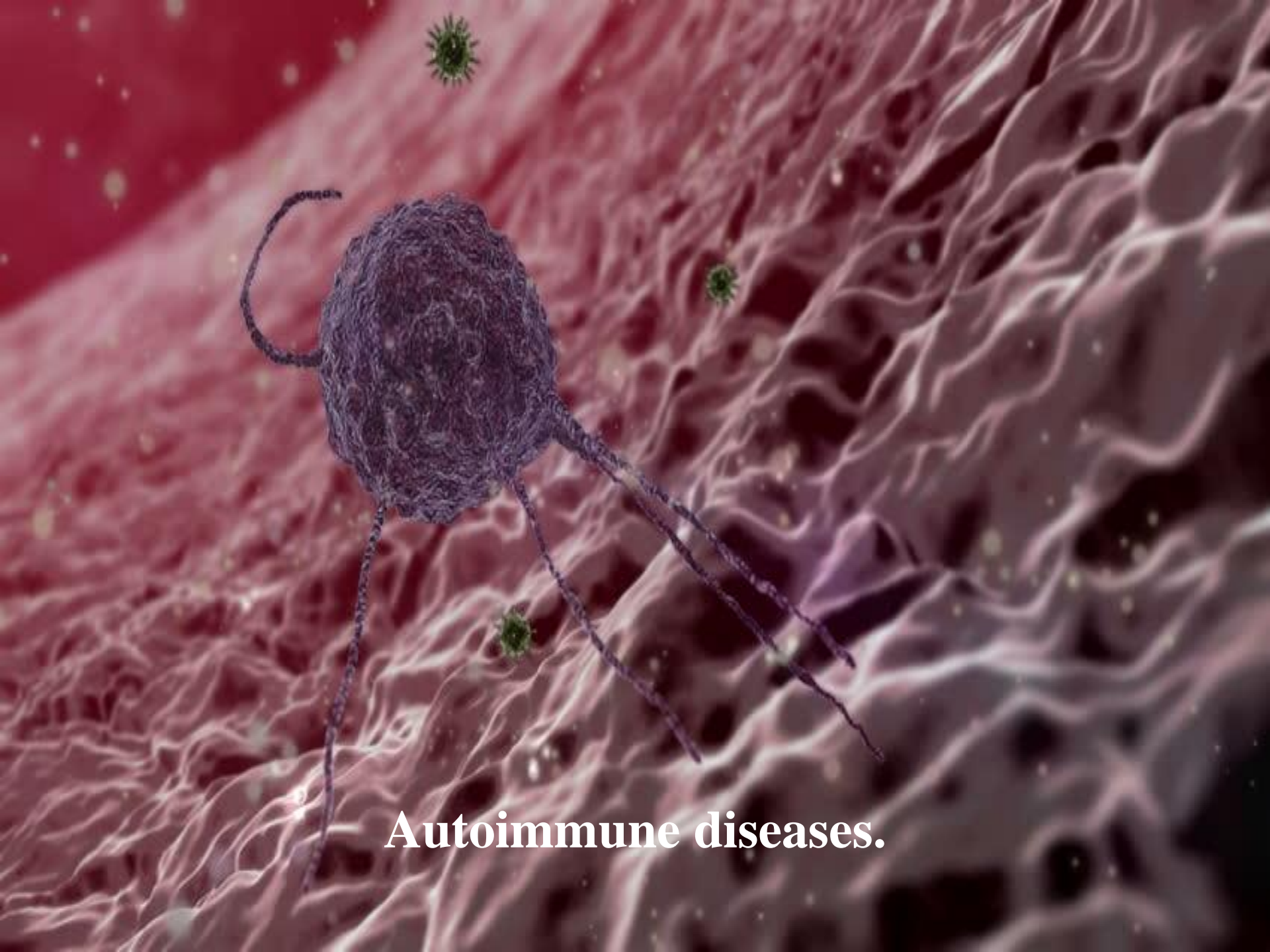



**Autoimmune diseases.**

# Autoimmune diseases.

## *I. Microspecimens:*

### **№ 125. Polyarteritis nodosa. (H-E. stain).**

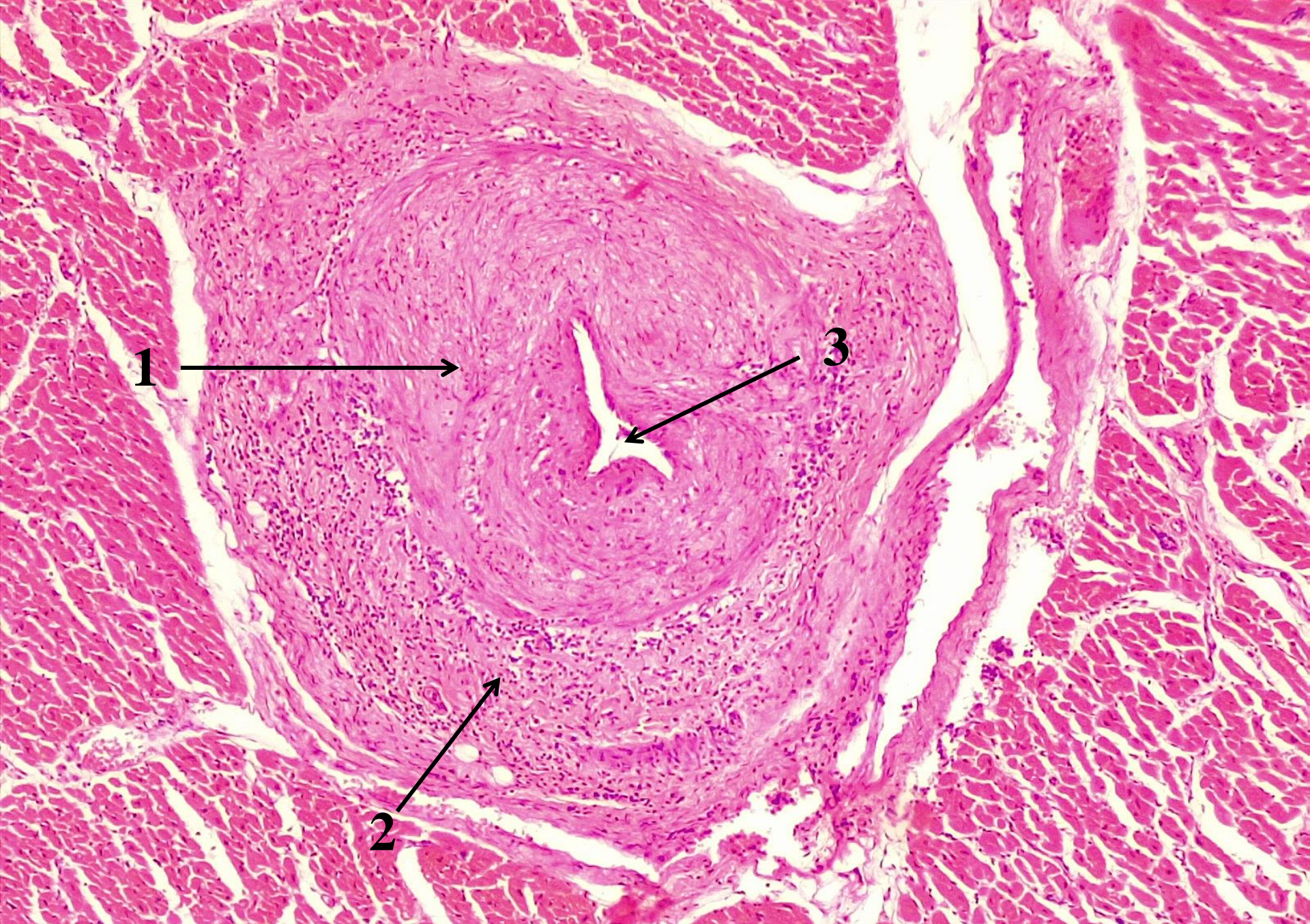
#### **Indications:**

1. Thickened arterial wall.
2. Diffuse lymphocytic and macrophage infiltration located predominantly in adventitia.
3. Narrowed artery lumen.

In the microspecimen, there are branches of the coronary arteries with thickened walls, lumen stenosis. The arterial walls are edematous, infiltrated with lymphocytes, plasmacytes and macrophages. The inflammatory process has a focal, nodular character and is more pronounced in the adventitia. In adjacent cardiomyocytes – granular and hyaline degeneration.

*Nodular polyarteritis is a systemic vasculitis, generalized, affecting the small and medium caliber arteries, being involved more frequently the renal (90-100%), coronary (88-90%), mesenteric (57-60%), cerebral (45%) arteries, and others. Morphologically it is manifested by predominantly exudative changes in the media of the vessels and predominantly proliferative - in adventitia. It can be acute, subacute and chronic. During periods of acute exacerbation there may be fibrinoid necrosis of the walls of the arteries, thrombosis and infarction. It results in nodular sclerosis and non-uniform stenosis of the arteries with chronic ischemia of the respective areas, parenchyma atrophy and sclerosis. It is an immune disease, mediated by circulating immune complexes or formed in situ. In 1/3 of the patients cases, have hepatitis B, and in the arteries there are immune complexes, consisting of the surface antigen of the hepatitis B virus - HBsAg and the anti-HBsAg antibody.*





**№ 125. Polyarteritis nodosa. (H-E. stain).**



## **№ 148 Hashimoto's thyroiditis. (H-E. stain).**

### **Indications:**

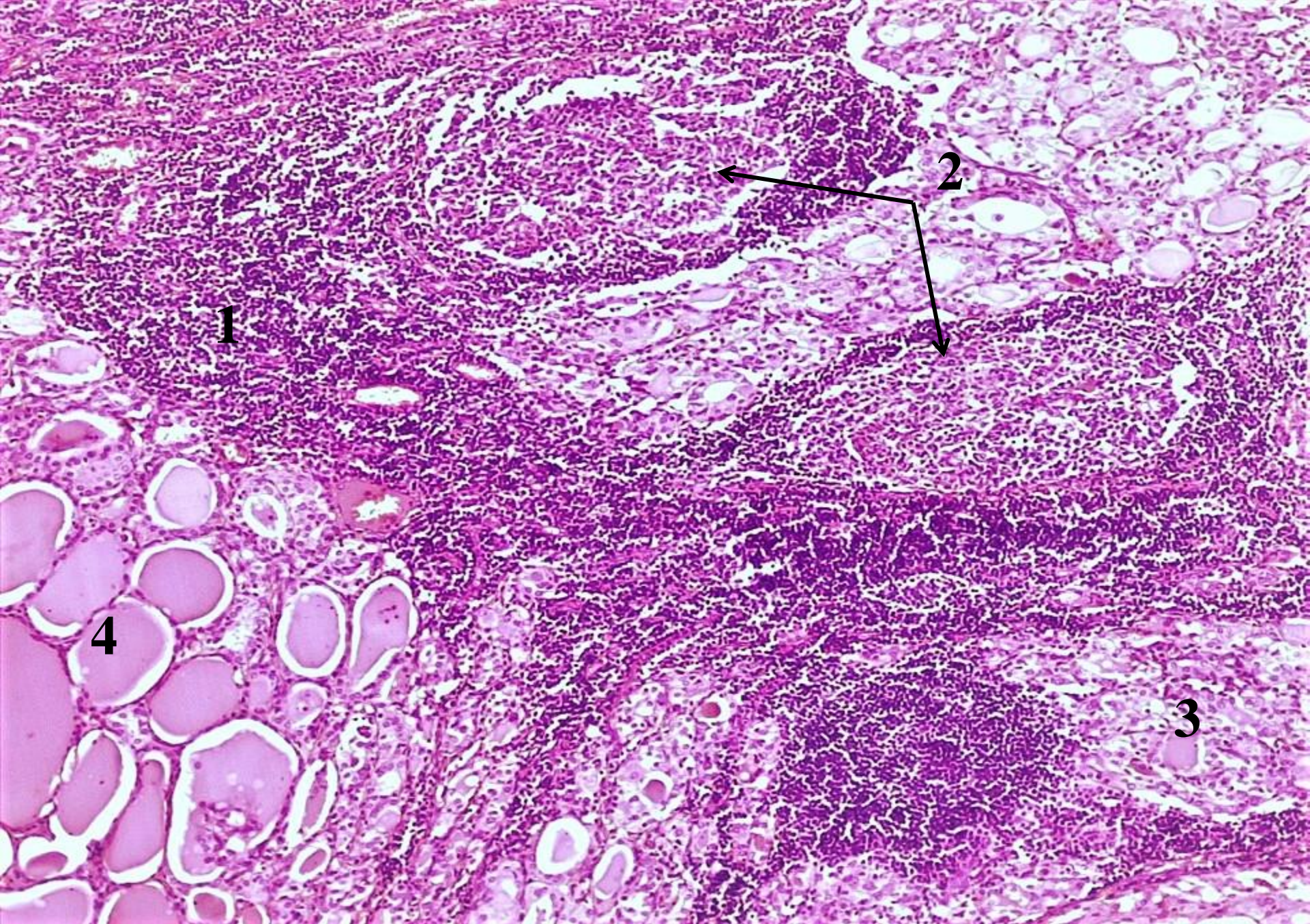
1. Lymphocyte infiltration of the thyroid gland.
2. Lymphatic follicles.
3. Atrophied thyroid follicles with pale colloid.
4. Unchanged thyroid follicles.

In the thyroid gland there is diffuse infiltration of the stroma with lymphocytes and plasmocytes, sometimes with the formation of lymphoid follicles with clear germinal centers. These infiltrates replace the glandular parenchyma, the thyroid follicles are atrophied, contain weakly colored or vacuolized colloid, some of them without lumen, also are present foci of fibrosis. In some follicles the epithelial cells become intensely eosinophilic, with granular cytoplasm, transforming into Hurthle or oncocyte cells, which is a reactive oncocytal metaplasia of the follicular epithelium.

*Macroscopically at the initial stage the thyroid gland is enlarged diffused in size, and over time it progressively atrophies, densifies, the parenchyma being replaced by connective tissue. Clinically, it is manifested by hypothyroidism and develops mixedem. It is found almost exclusively in women between 40 and 50 years of age.*

*Hashimoto's autoimmune thyroiditis or chronic lymphocytic thyroiditis is a true organ-specific autoimmune disease (with organ specificity). It is the first autoimmune disease described by the Japanese physician Hashimoto in 1912. It is the most common cause of hypothyroidism in non-endemic regions, where iodine content is sufficient. The pathogenetic mechanism consists in the disturbance of immunological tolerance to thyroid antigens. In the body appear autoantibodies against thyroglobulin, thyroid peroxidase, anti-TSH (thyroid stimulating hormone) receptors, which react with the autoantigenic components of thyroid follicles, cause autoimmune inflammation, gradual destruction of thyroid cells by apoptosis, replacement of the glandular parenchyma, with lymphoid infiltrate and fibrous connective tissue. The main etiopathogenetic factors are viral infection, radiation and genetic predisposition (certain subtypes of histocompatibility antigens - HLA-DR3 and HLA-DR5).*





**№ 148** Hashimoto's thyroiditis. (*H-E. stain*).



**№ 21. Focal spleen amyloidosis (sago spleen).** (*Congo-red and hematoxylin stain.*)

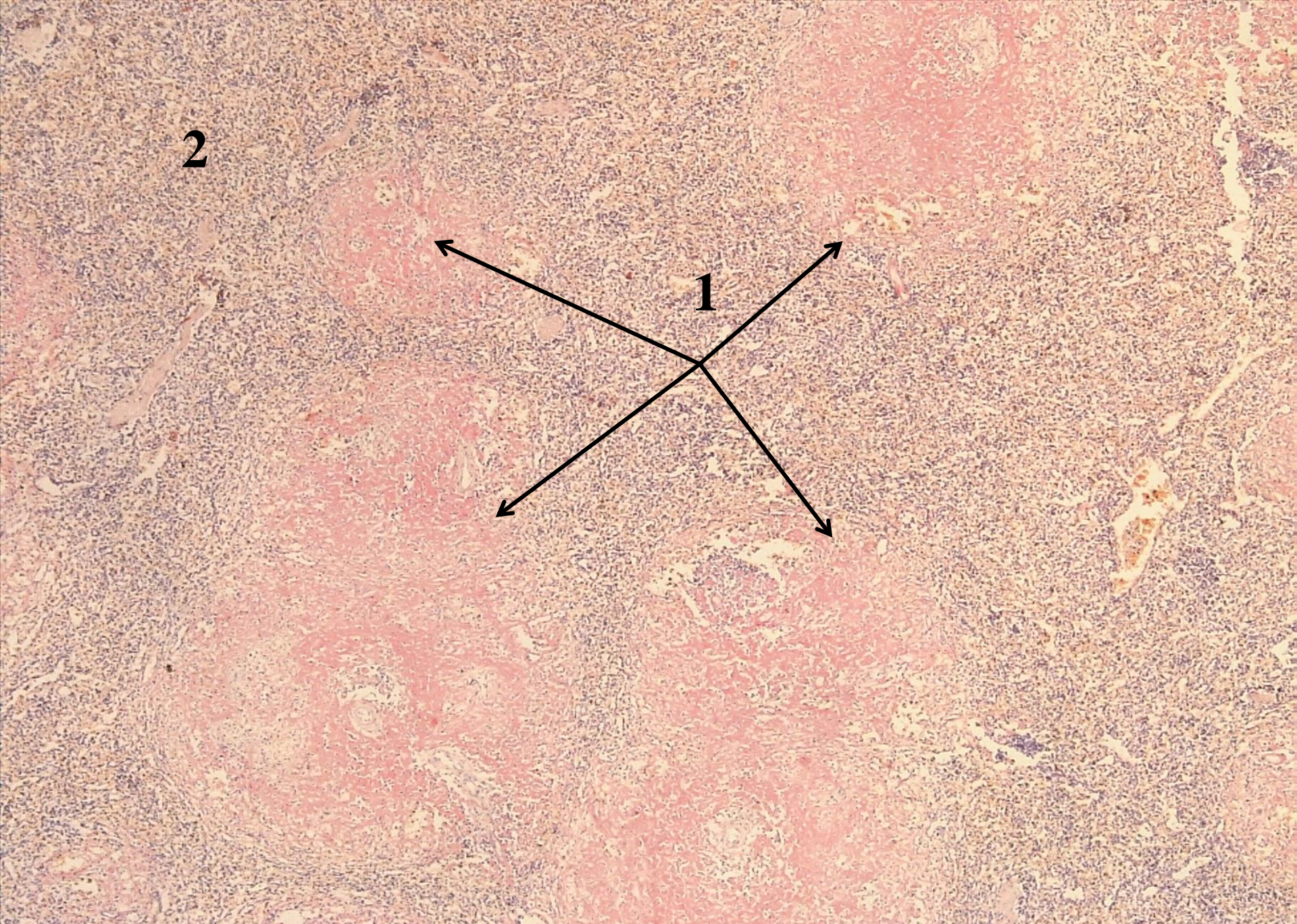
**Indications:**

1. Focal deposits of amyloid in the center of lymphoid follicles.
2. Unchanged red pulp.

In the spleen we can see focal deposits of amyloid, uniformly colored in red with Congo red, located in the center of the lymph follicles; deposition of the amyloid masses begins in the walls of the centrollicular arteries, and then extends throughout the follicle, which gives the macroscopic spleen appearance of a "sago spleen" (amyloid inclusions remember sago grains).

*Spleen amyloidosis is a manifestation of generalized amyloidosis, being most commonly found in secondary, reactive amyloidosis (biochemical variant -AA). It is found in tuberculosis, bronchiectasis, chronic osteomyelitis, rheumatoid arthritis, systemic lupus erythematosus. In this form of amyloidosis besides the spleen, other organs of the abdominal cavity are affected, e.g., the kidneys, liver, adrenals, intestine. In some cases in the spleen, the amyloid deposits may be diffuse, spreading all over the red pulp, and macroscopically it becomes greasy. The consequences of spleen amyloidosis may be progressive in amyloid deposits and irreversible atrophy of an organ parenchyma with functional impairment.*





**No 21. Focal spleen amyloidosis (*sago spleen*). (Congo-red and hematoxylin stain.).**



## № 19. Renal amyloidosis. (Congo-red and hematoxylin stain.)

### Indications:

1. Amyloid deposits:
  - a. in glomerular capillaries;
  - b. in the artery wall;
  - c. on the basement membrane of the renal tubules.
2. Protein cylinders in tubule lumen.

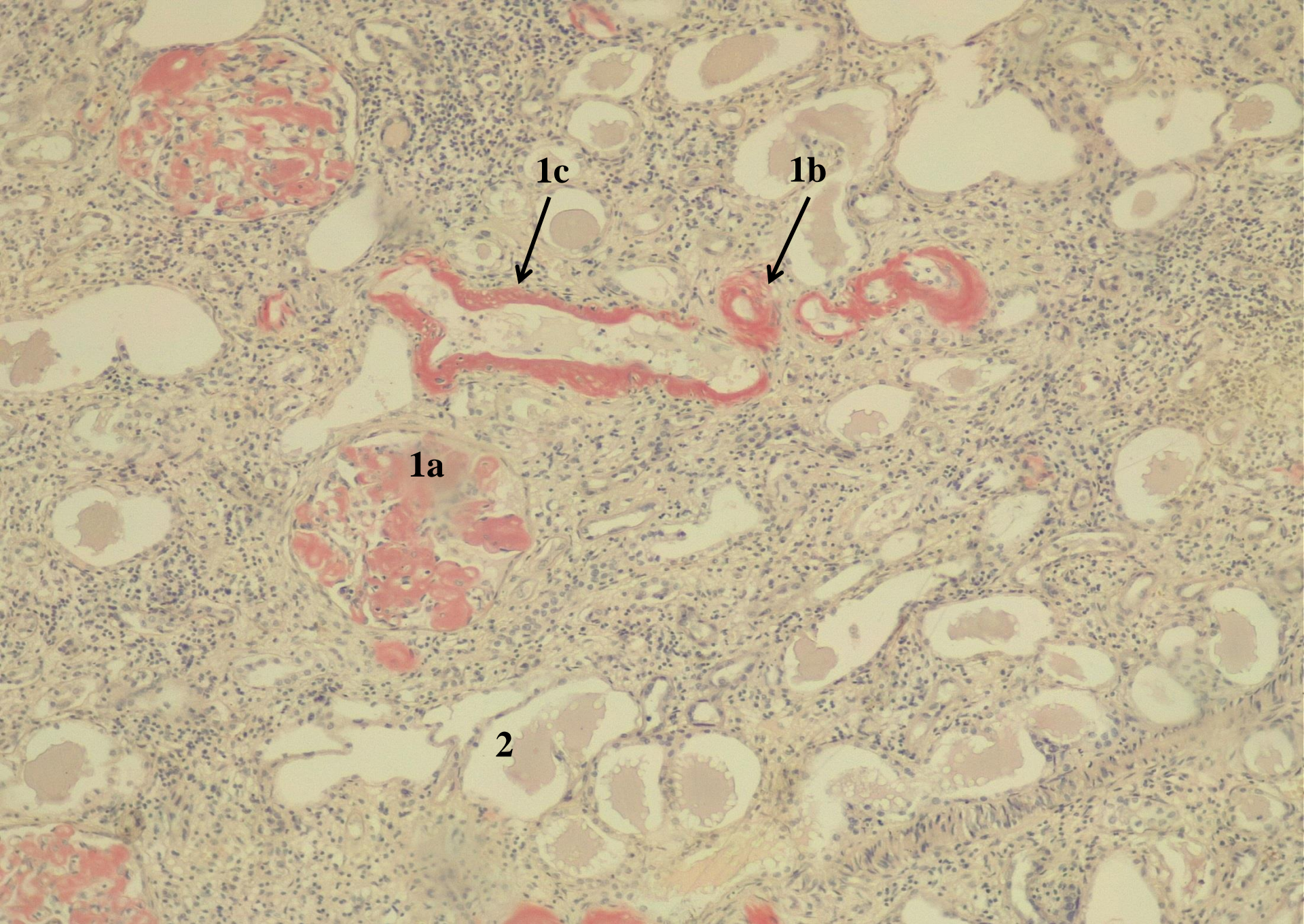
*In the kidneys it is observed the selective deposition of a homogeneous mass, colored in red, in the glomerular capillaries, under the endothelium, as well as in the walls of the arterioles and small arteries, in tubes containing the basement membrane, under the epithelium and on the path of the reticulum fibers of the stroma. In the epithelial cells of the tubes they contain granular dystrophy, in the lumen of some tubes - hyaline cylinders.*

Kidney amyloidosis is a manifestation of generalized amyloidosis. *The macroscopic picture—macrospecimen № 82. Regardless of the organ, the amyloid deposits are detected histologically in: a) the walls of the blood and lymphatic vessels (in the intima or adventitia), b) in the glandular structures (tubes, collecting ducts) and c) in the stroma, along the reticular fibers and collagenic (perireticular and pericolagenic amyloidosis).*

*The main methods of identification of the amyloid substance in the histological slides are Congo red (it is colored in red) and polarizing microscopy (it is colored in yellow-green). Macroscopically the amyloid can be identified with the help of the specific Virchow reaction: amyloid deposits are colored with iodine (Lugol solution) in red-brown, which turns after treating the section with a 10% solution of sulfuric acid from blue-violet to dark green.*

*Amyloidosis is an irreversible process, in the kidneys progressively evolving towards complete replacement of glomeruli and pyramids with amyloid masses, and subsequently diffuse proliferation of connective tissue and amyloid shrunken of the kidneys with the development of renal failure and azotemic uremia.*





**No 19. Renal amyloidosis. (Congo-red and hematoxylin stain.)**



## *II. Macrospecimens:*

### **№ 82. Renal amyloidosis.**

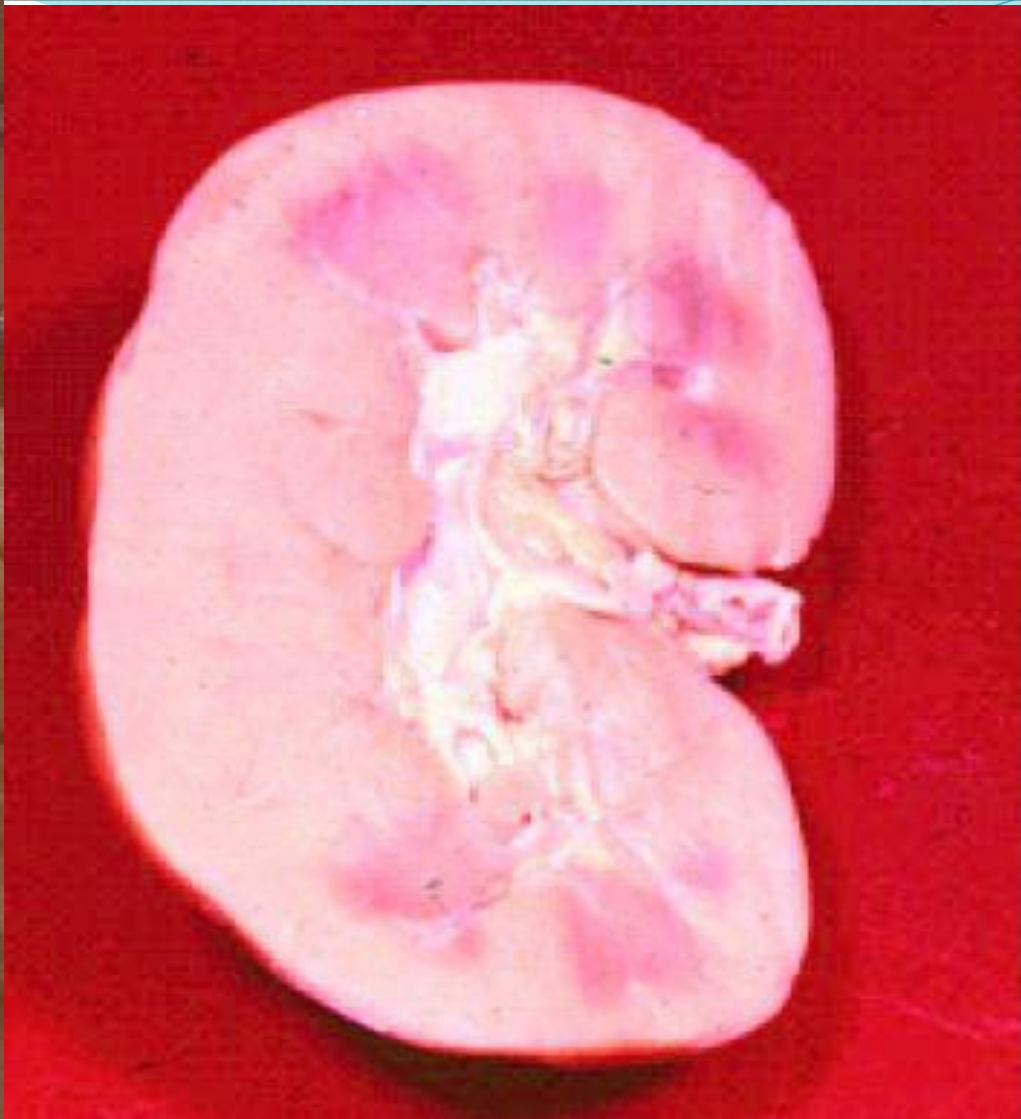The kidney is enlarged in size of dense consistency, gray yellowish color and lardy or waxy appearance, the surface is slightly wavy, on section layers are poorly delimited - "big white amyloidic kidney".

*Renal amyloidosis (amyloid nephropathy) is found in both primary amyloidosis, e.g., multiple myeloma (AL amyloidosis) and secondary amyloidosis, eg, purulent osteomyelitis, tuberculosis, bronchiectasis, rheumatoid arthritis (AA amyloidosis).*

*Clinically manifested by nephrotic syndrome: massive proteinuria (more than 3.5 g in 24 hours, hypoalbuminemia, generalized edema, hyperlipidemia and lipiduria, azotemia, hypertension (in 50% of cases).*

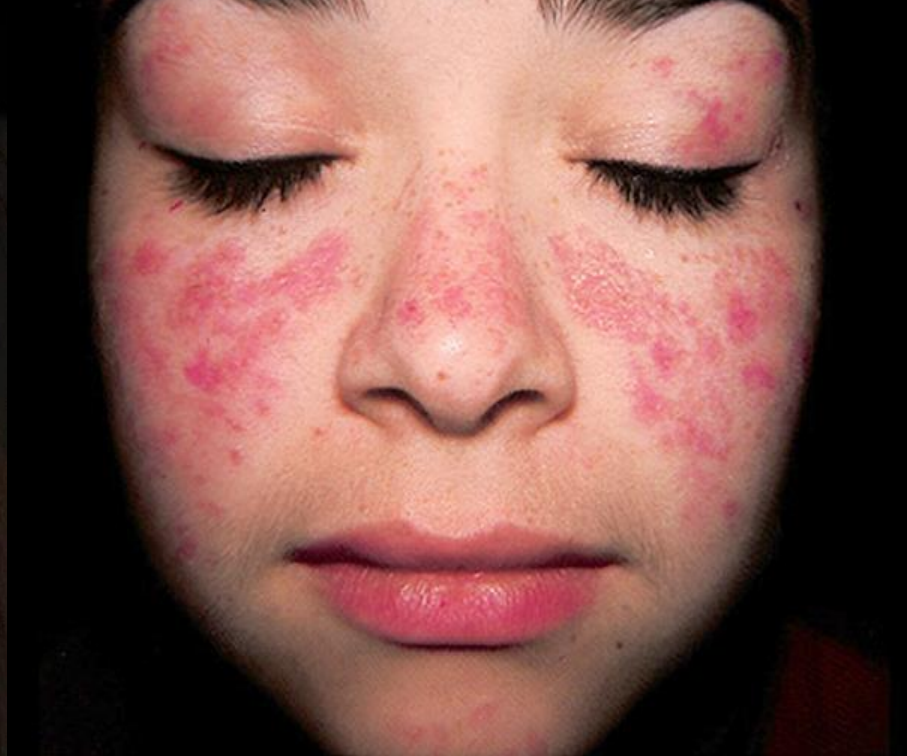*Complications: renal failure, association of infections due to decreased immunity, cardiovascular insufficiency, predisposition to thrombosis of vessels due to loss with urine of immunoglobulins and anticoagulant system proteins.*





**№ 82. Renal amyloidosis.**

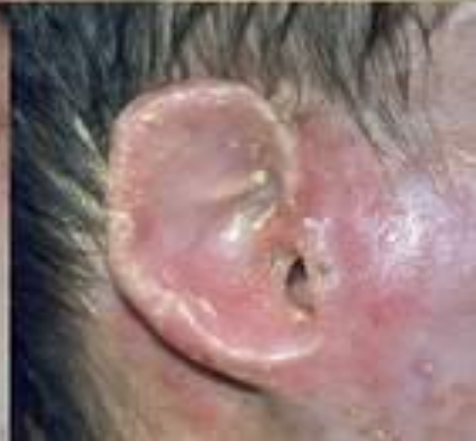
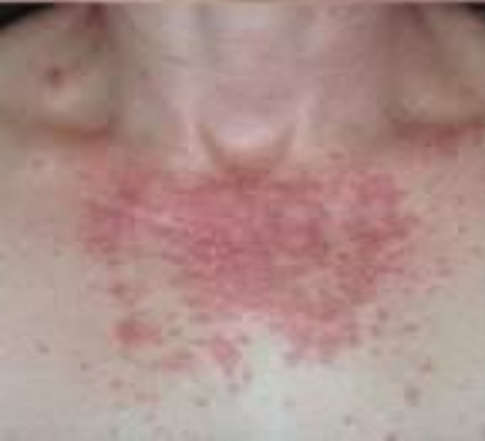
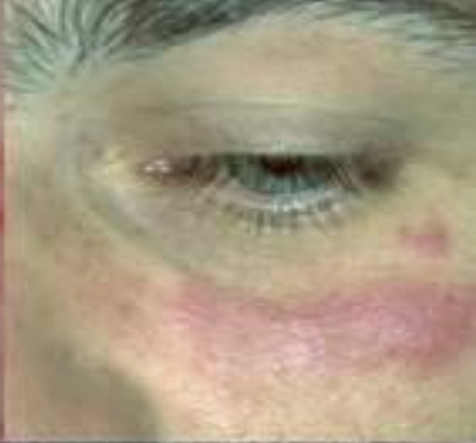
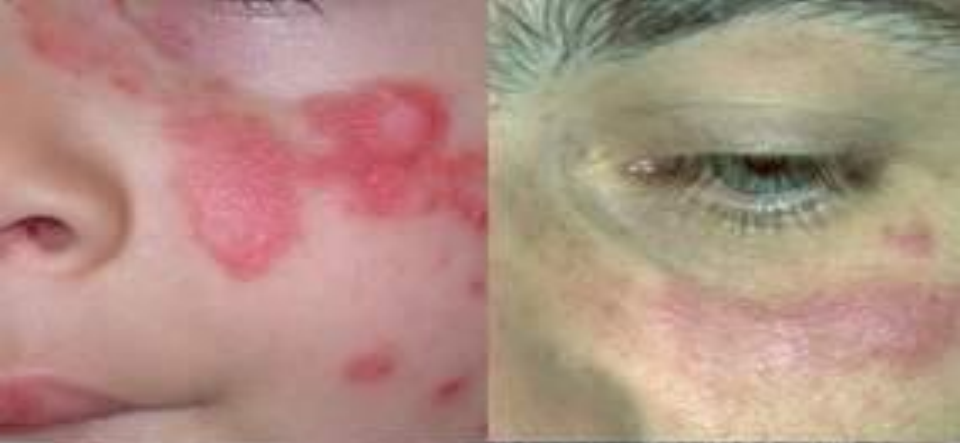
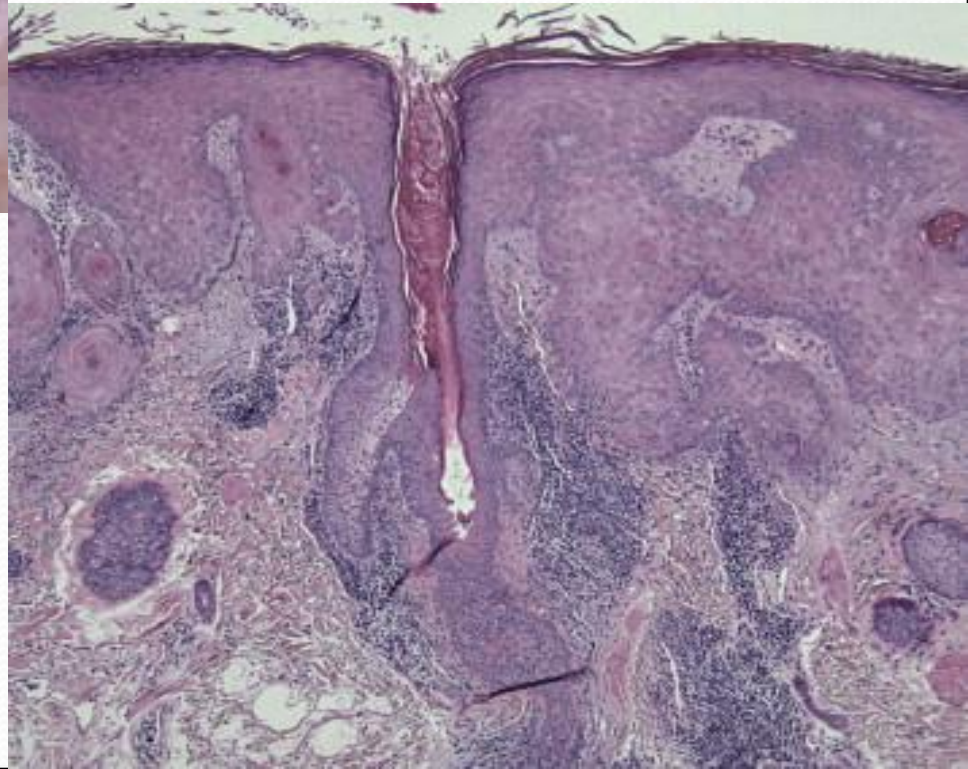
**Systemic lupus erythematosus**  
*("butterfly rash")*



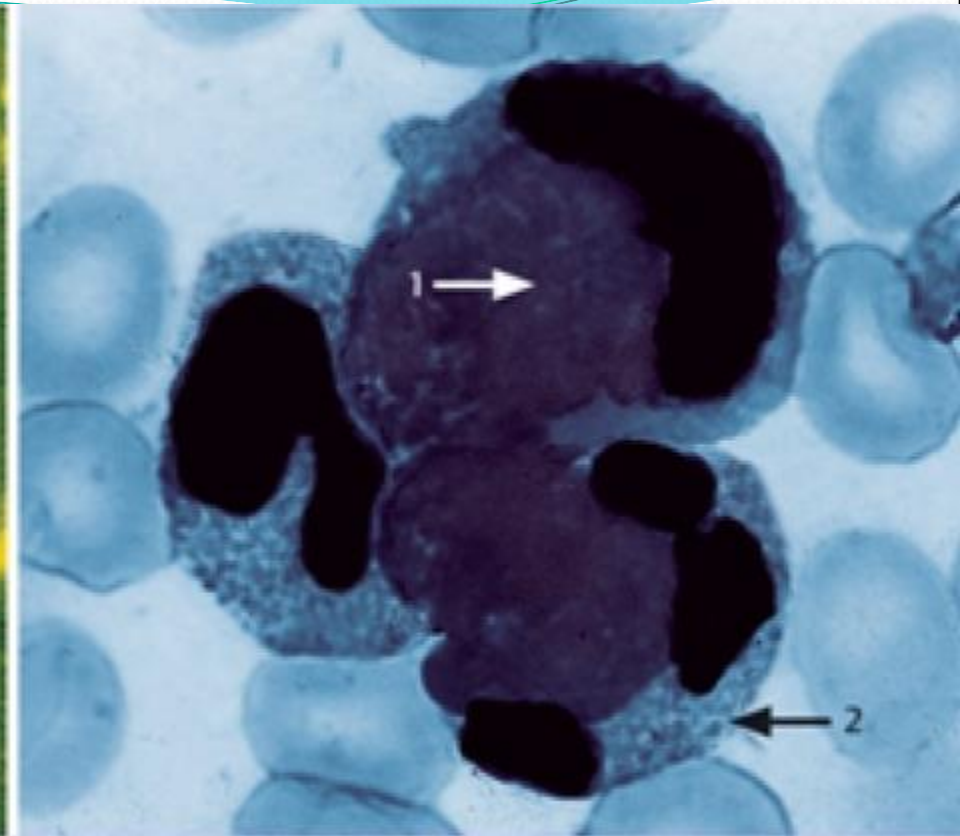
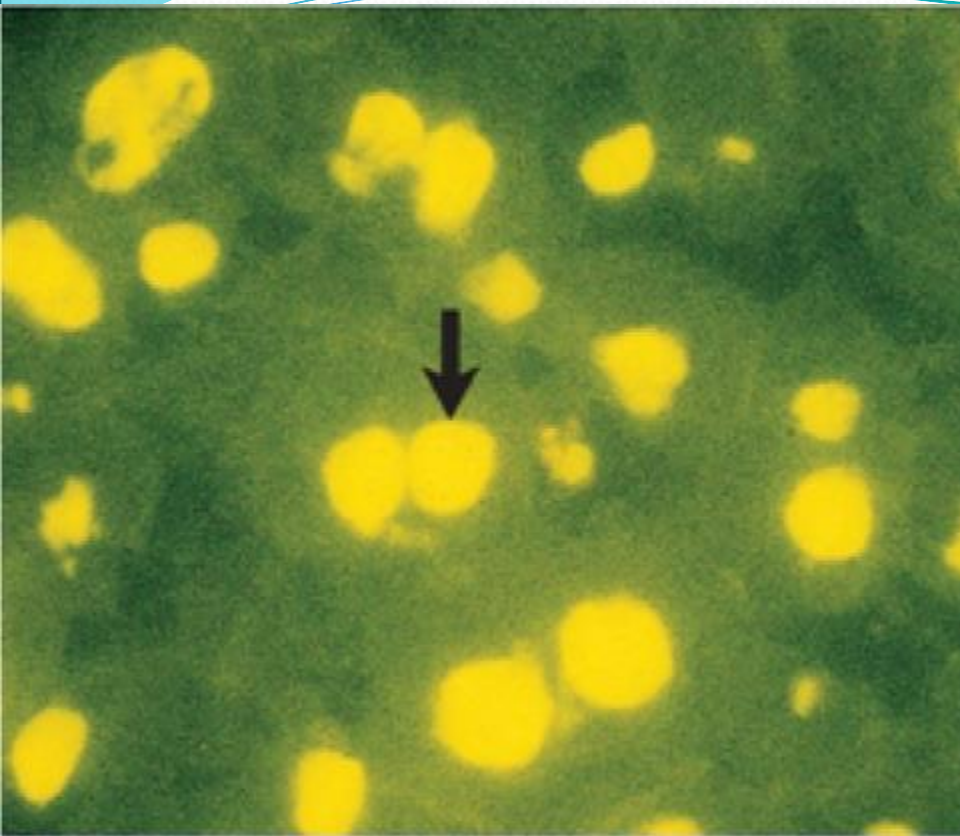




## **Discoid lupus erythematosus**

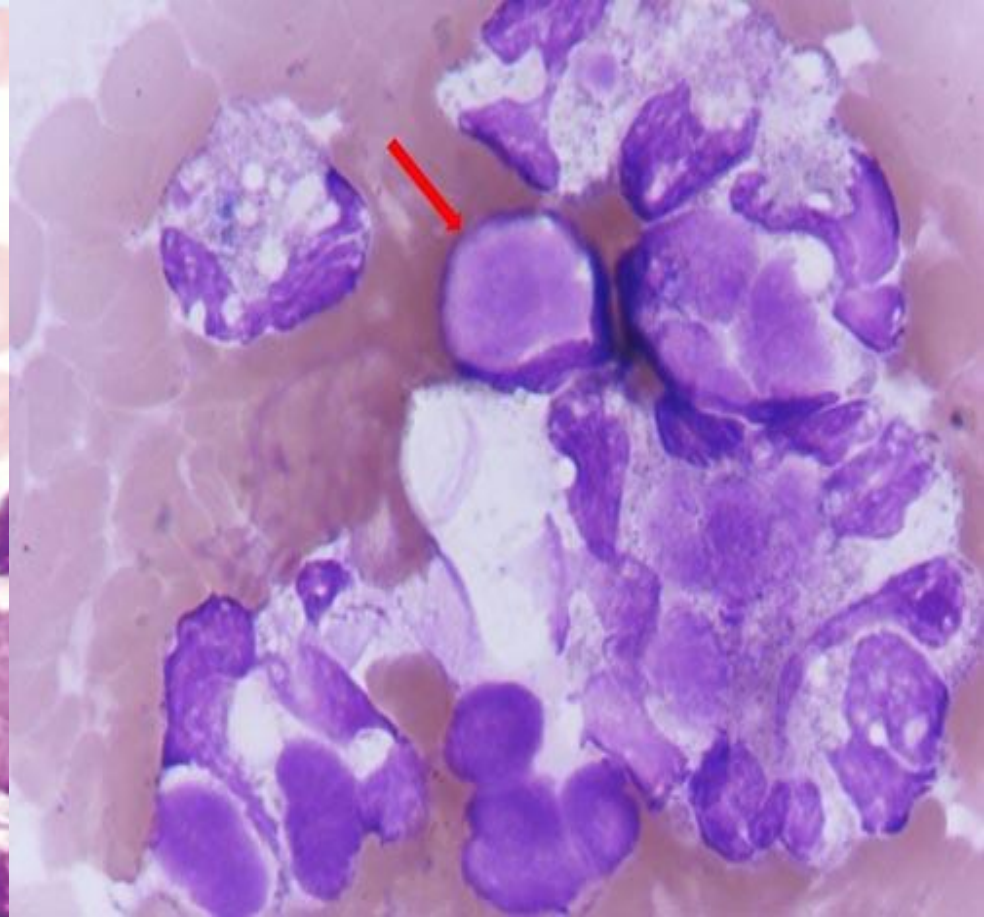
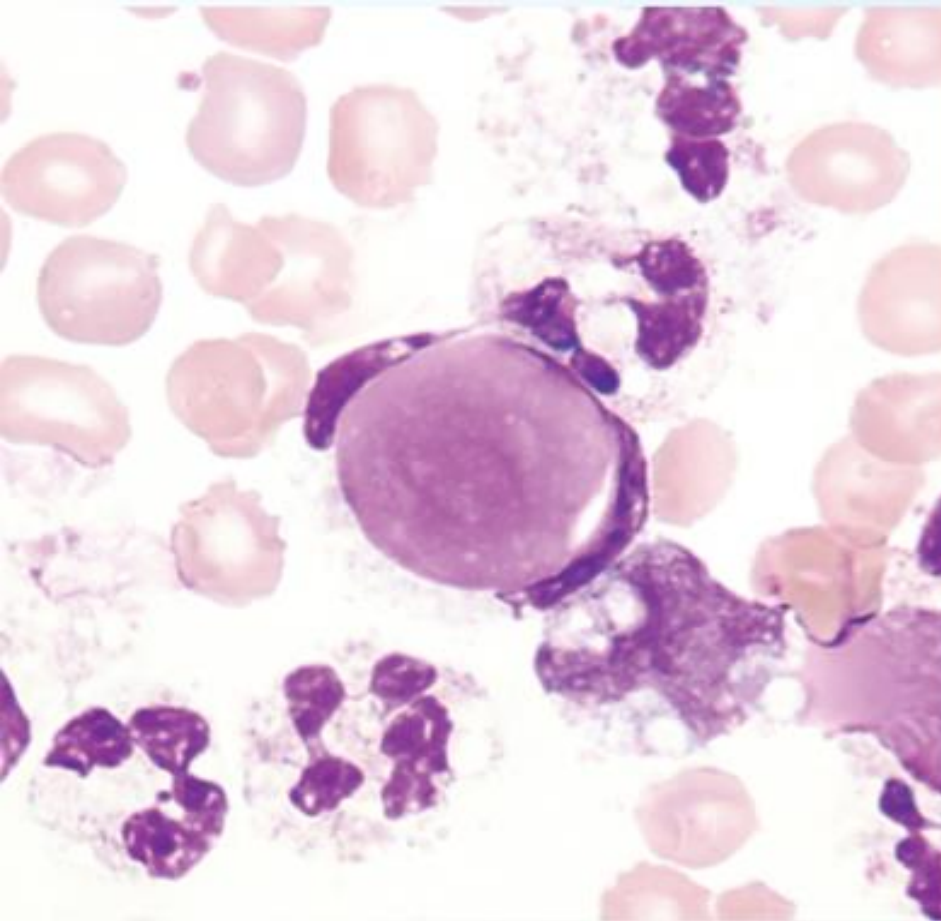






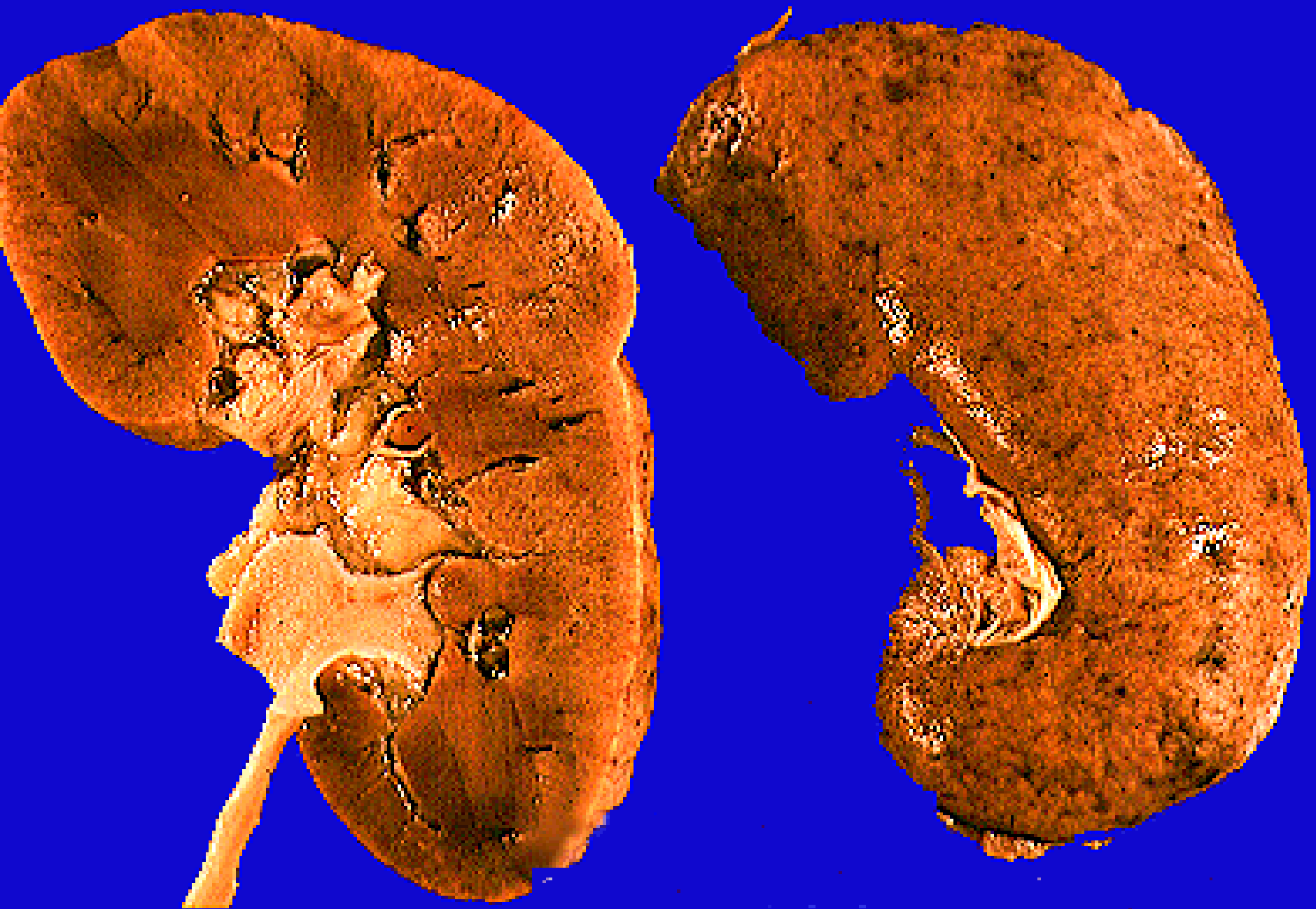**Antinuclear autoantibodies and  
hematoxylin bodies.**





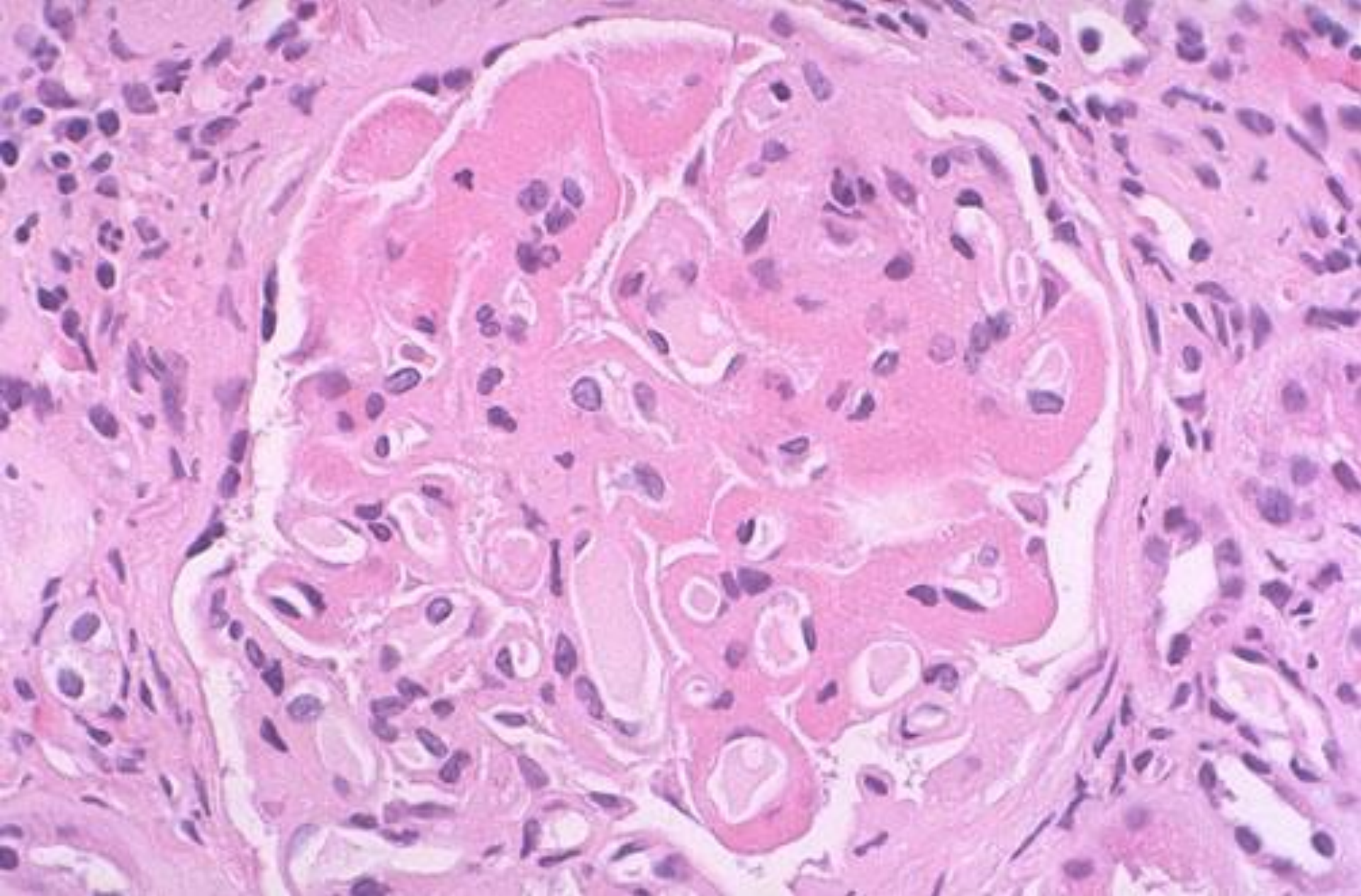
**Lupus erythematosus (LE) cell**  
*(neutrophil leukocyte, which phagocytosed a denatured nucleus).*





**Lupus glomerulonephritis.**

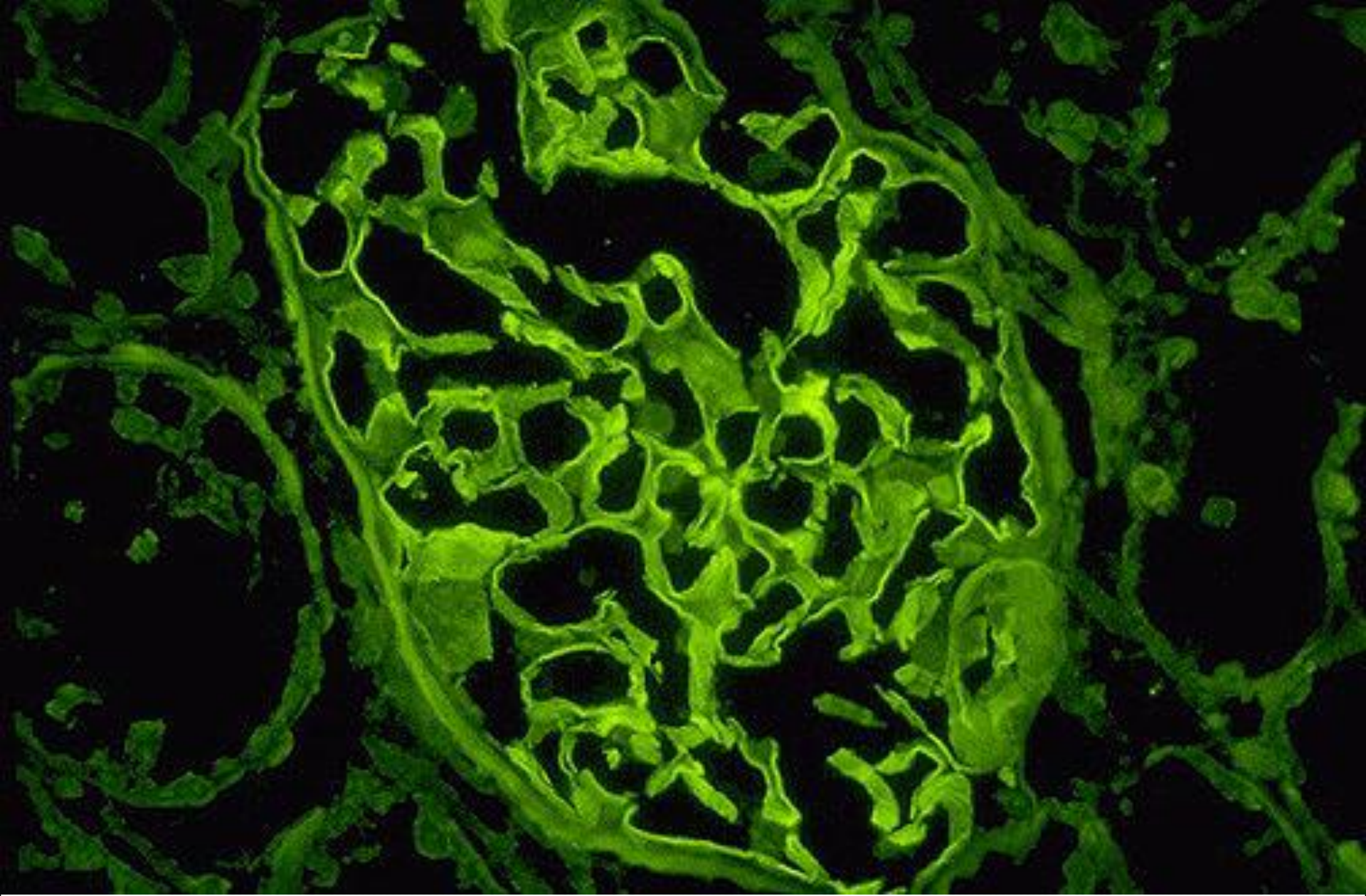




**Lupus glomerulonephritis.**

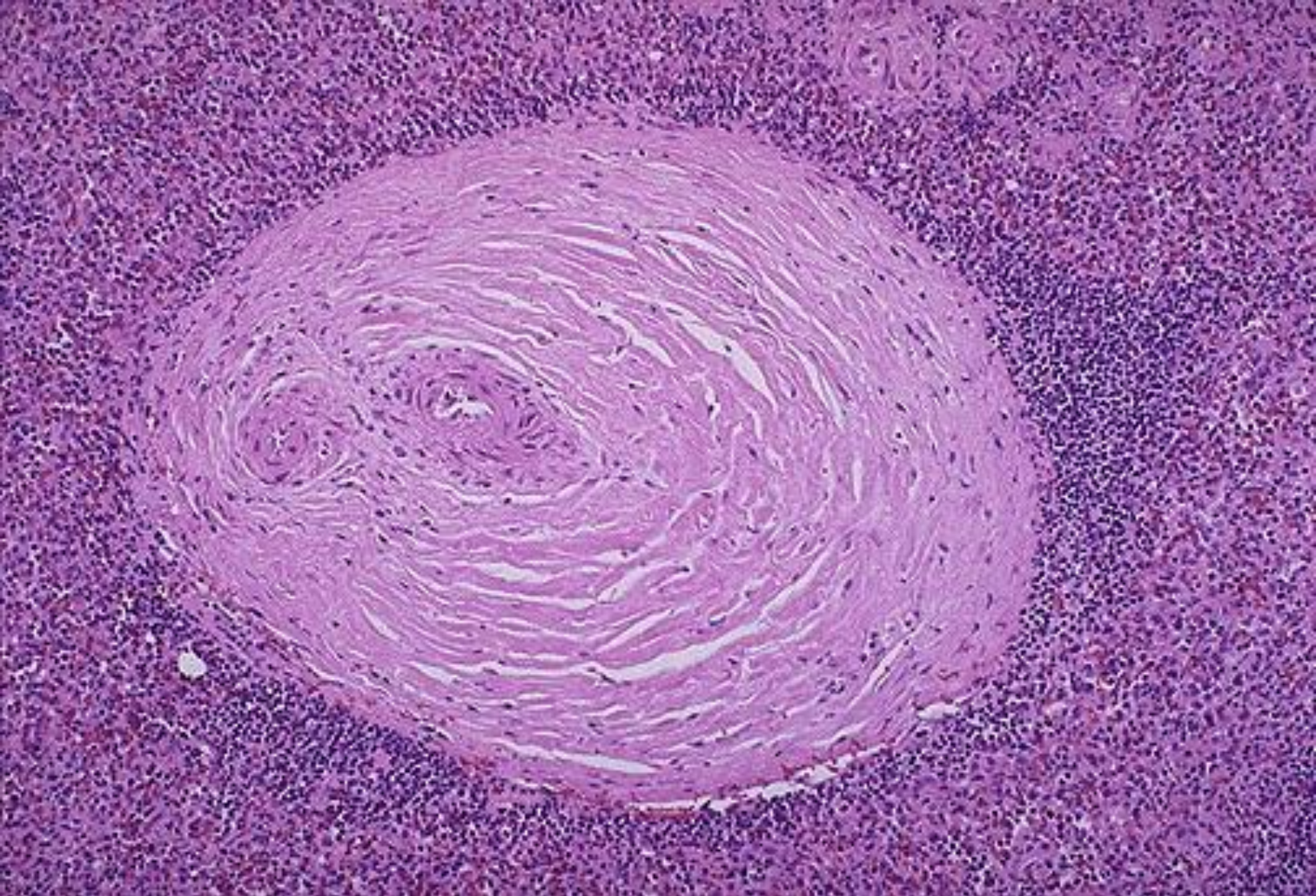
*(glomerular capillaries with wire loop appearance).*





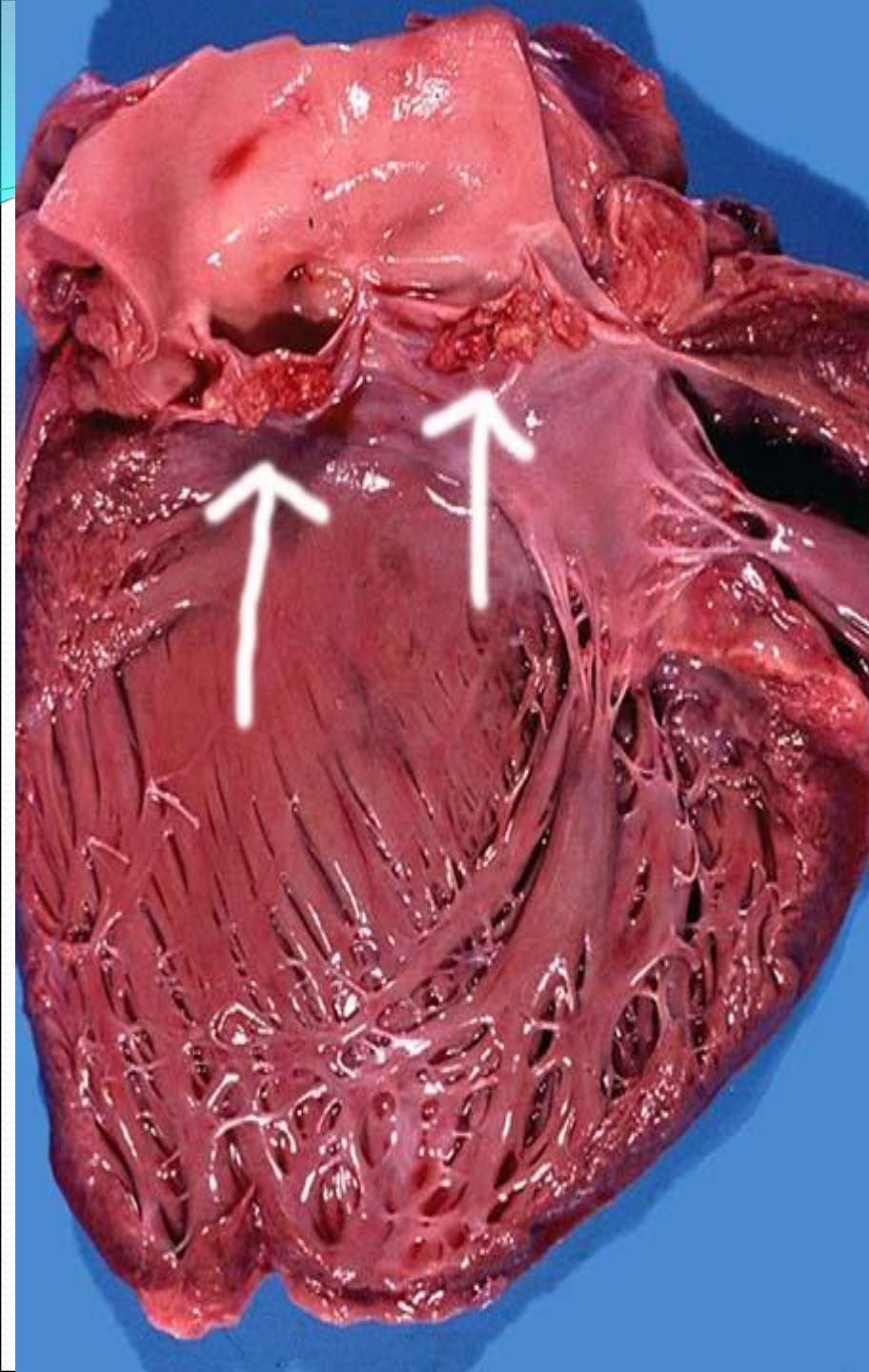
**Lupus glomerulonephritis, fluorescent microscopy with antibodies against IgG  
(*linear aspect of the deposits of immune complexes*).**



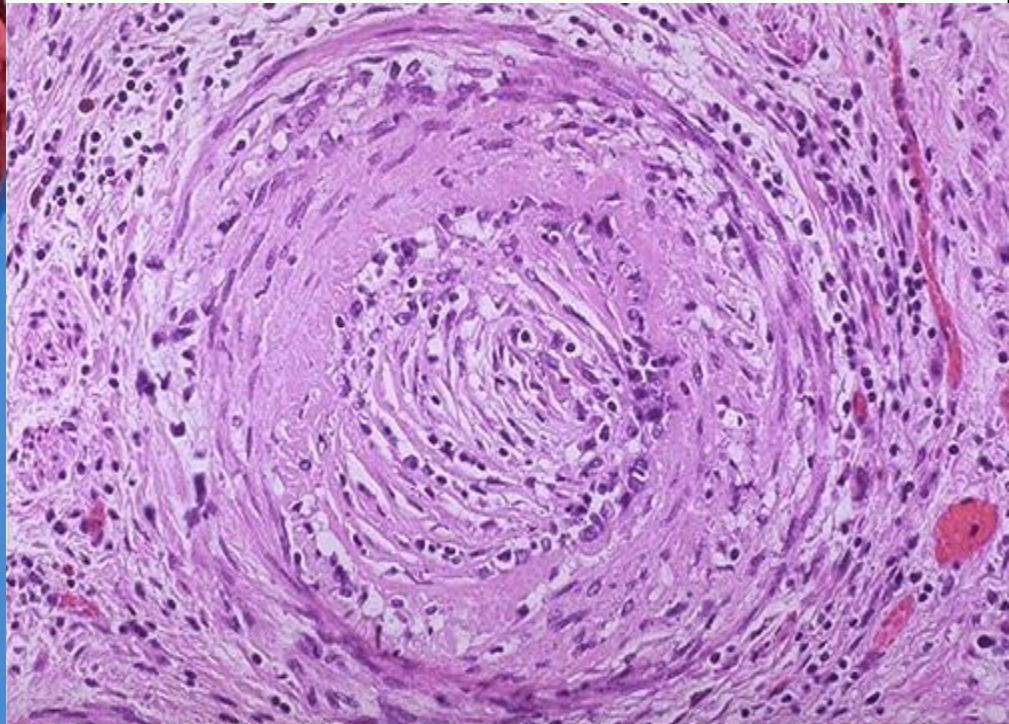


**Periarterial sclerosis “onion-skin lesion” in spleen in SLE.**

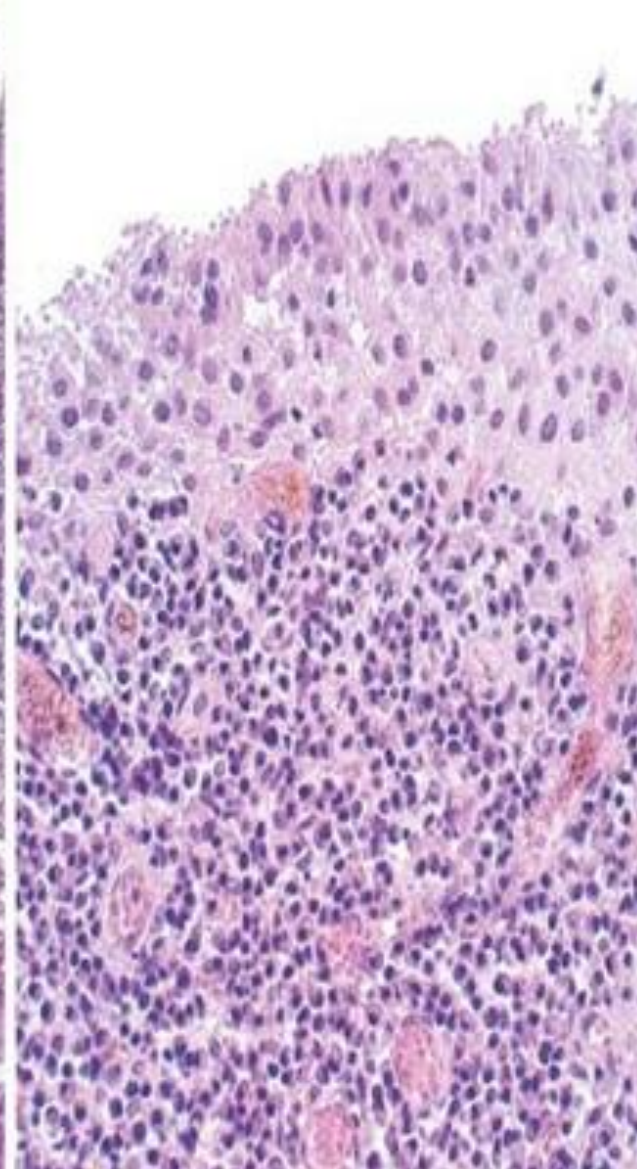
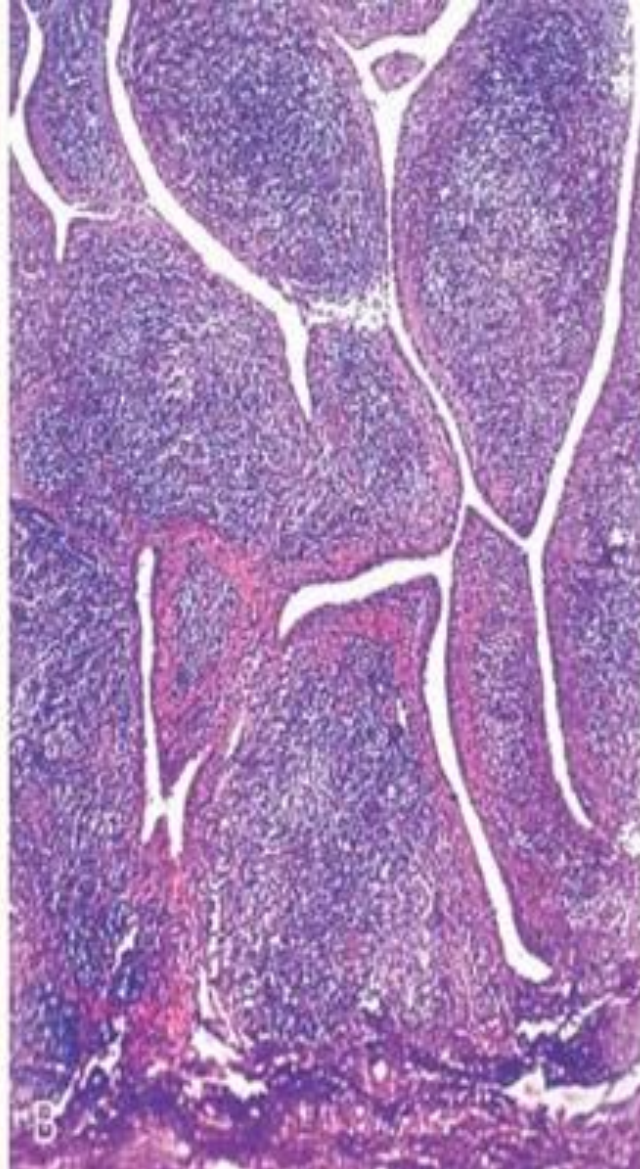
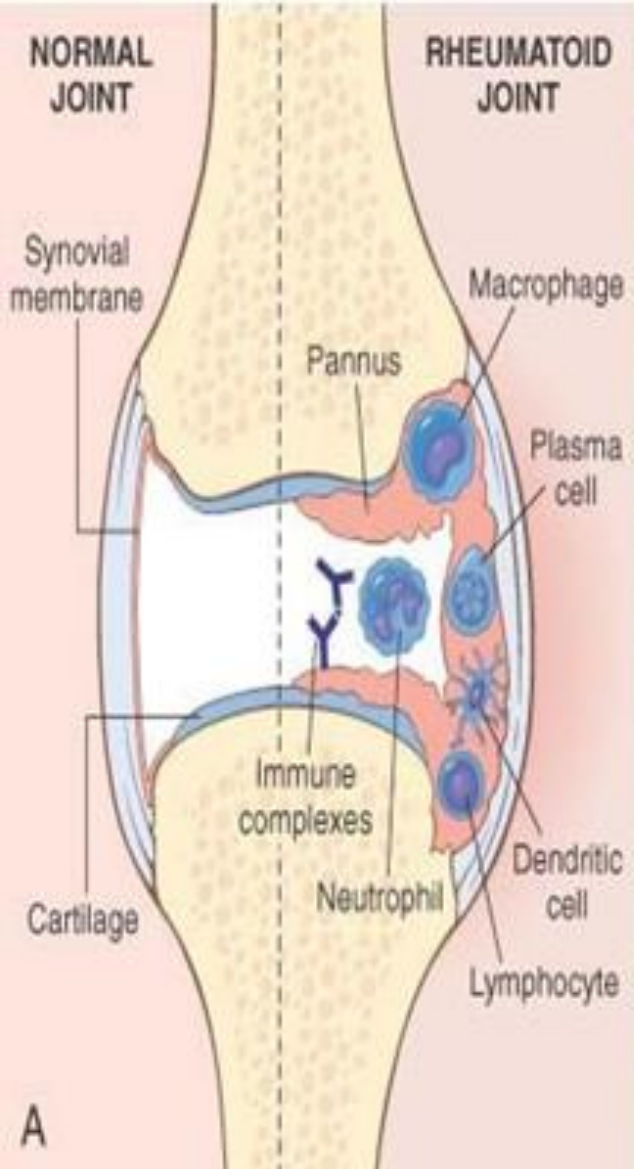




**SLE: Libman-Sacks  
endocarditis, vasculitis.**



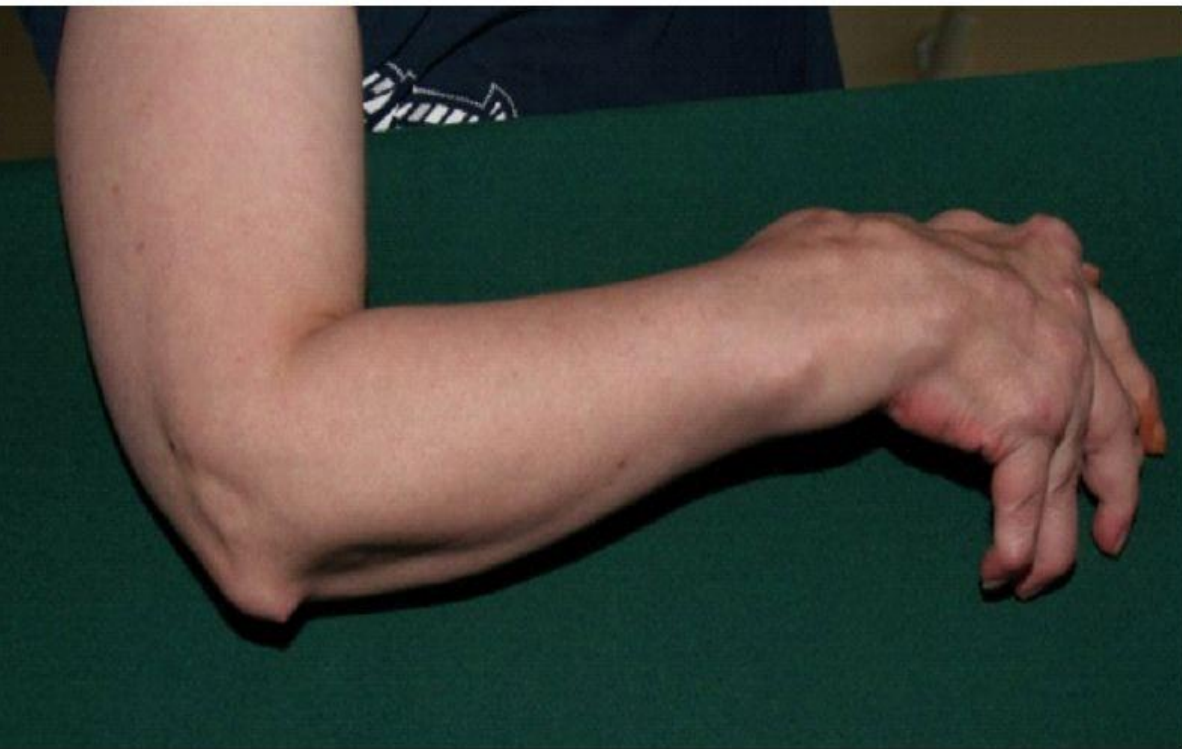
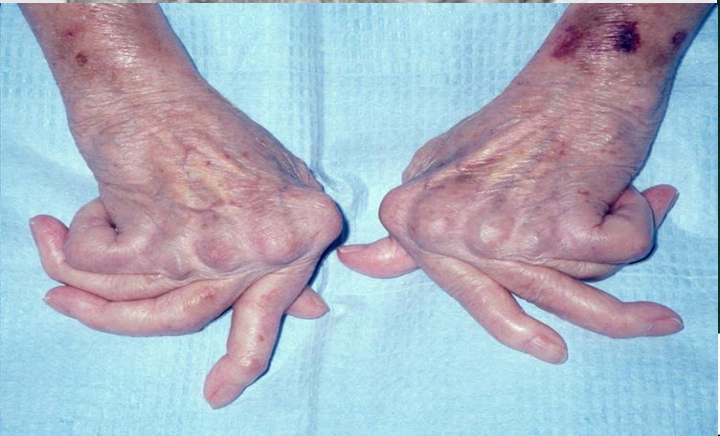
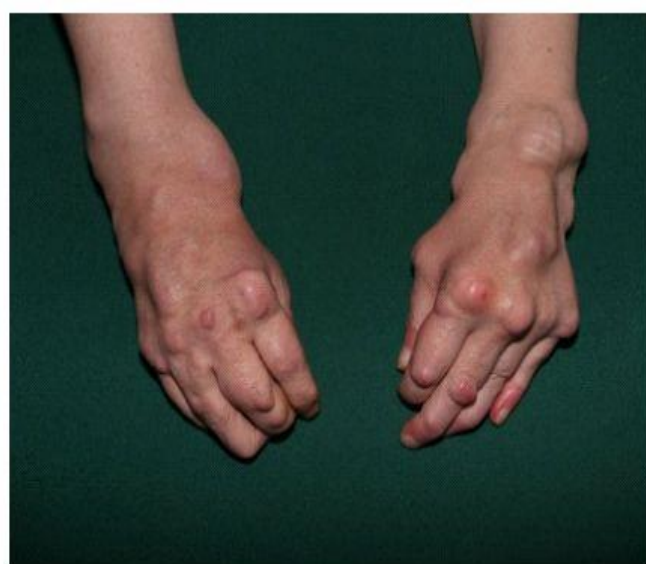
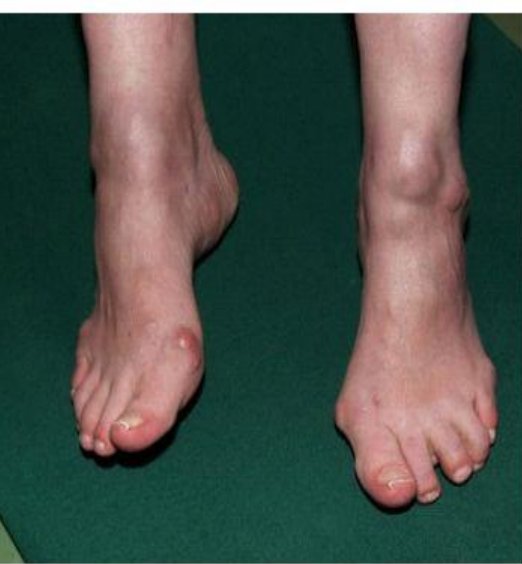
## Rheumatoid arthritis.

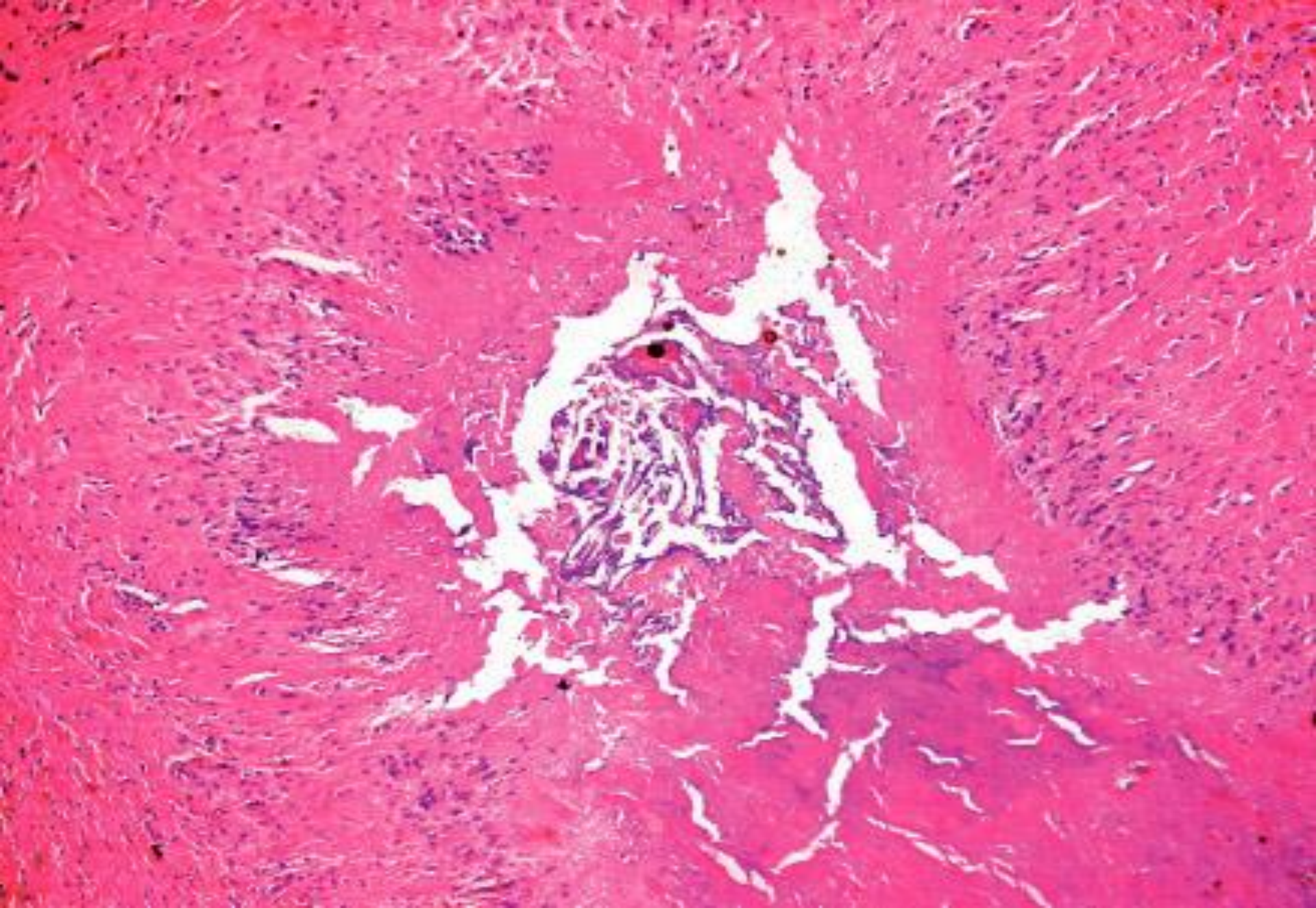
**The mechanism of the pannus appearance (granulation tissue) on the synovial membrane.**





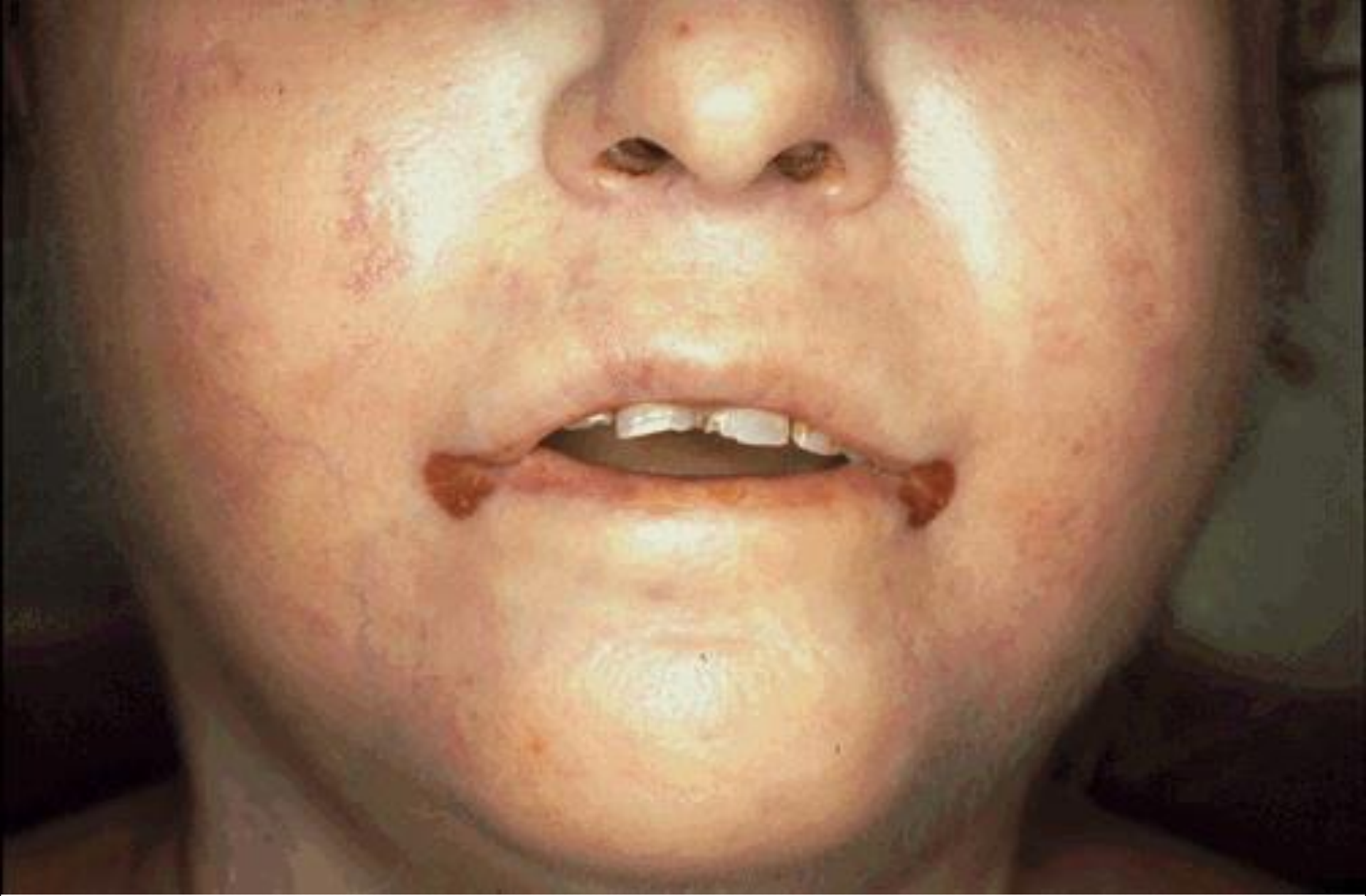**Rheumatoid arthritis**





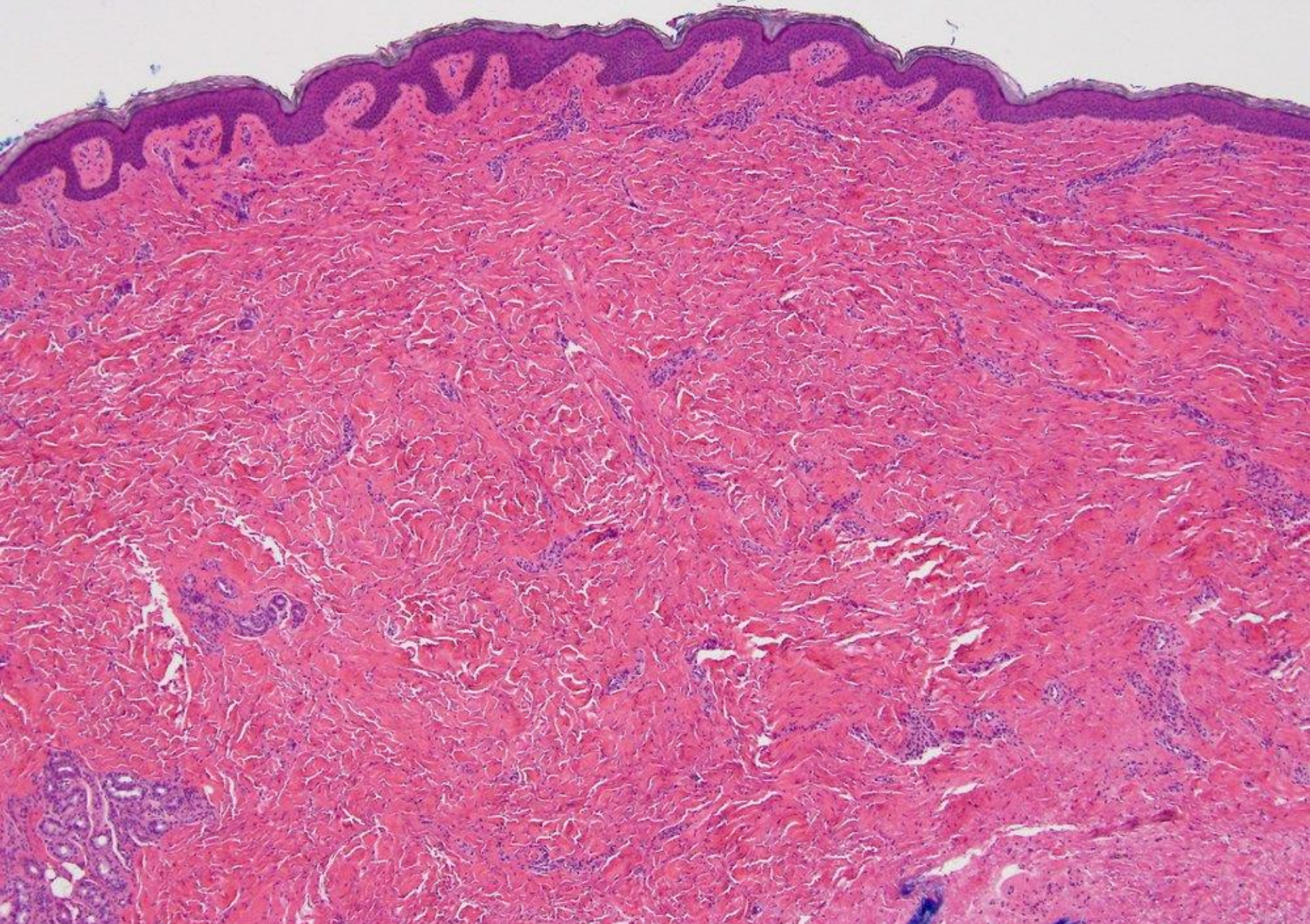
**Rheumatoid nodule. (*H-E stain*).**





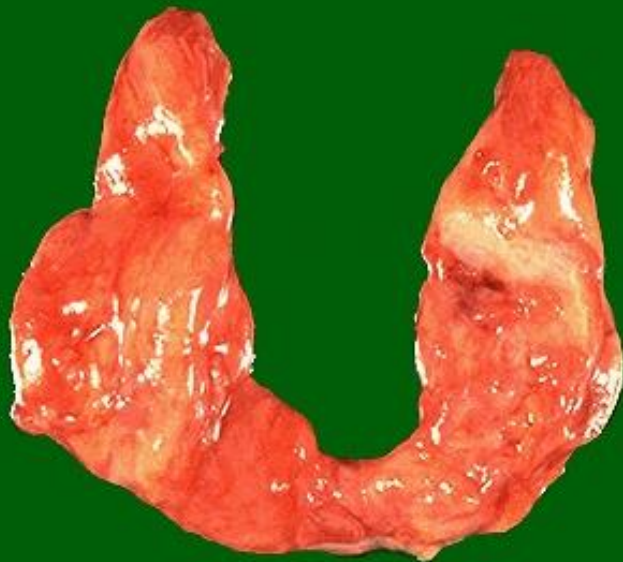
**Systemic sclerosis** (*thickening of the skin, reduction of elasticity and mobility, amimic face*).





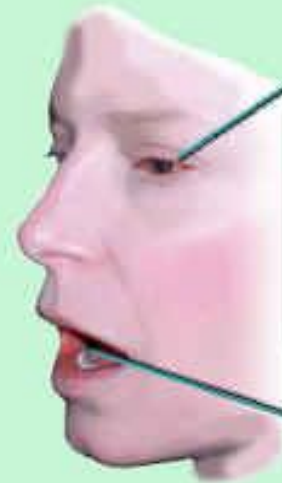**Systemic sclerosis (*hyalinosis of the connective tissue of the dermis*). (H-E stain).**



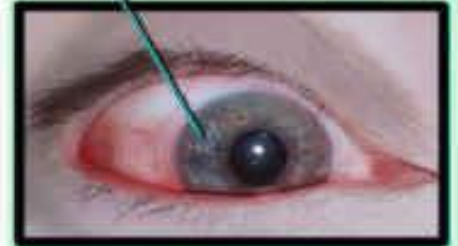


**Hashimoto's thyroiditis.**

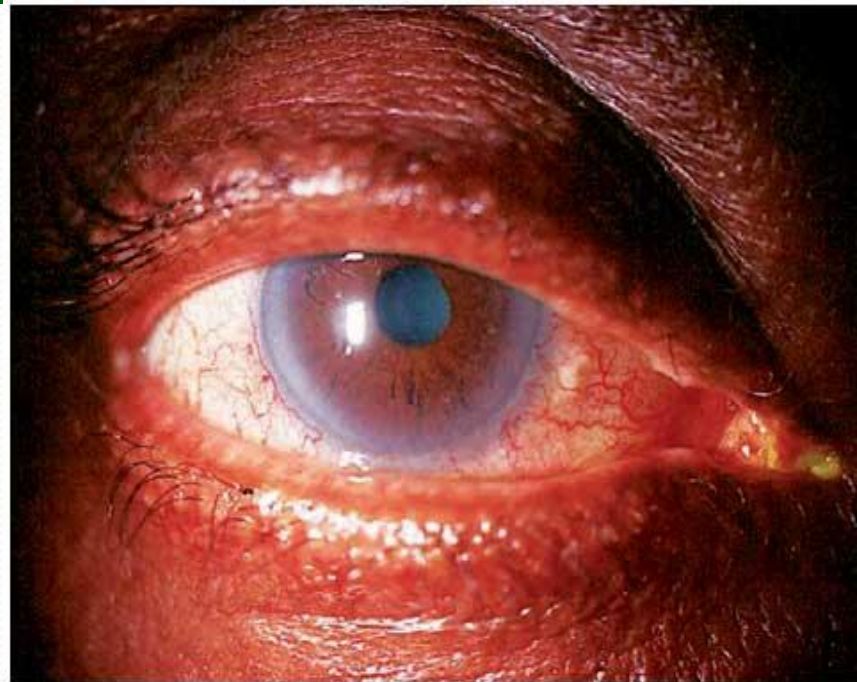## Sjögren's Syndrome Symptoms



Dry eyes resulting in damage to eye surface.



Dry mouth resulting in increased tooth decay.

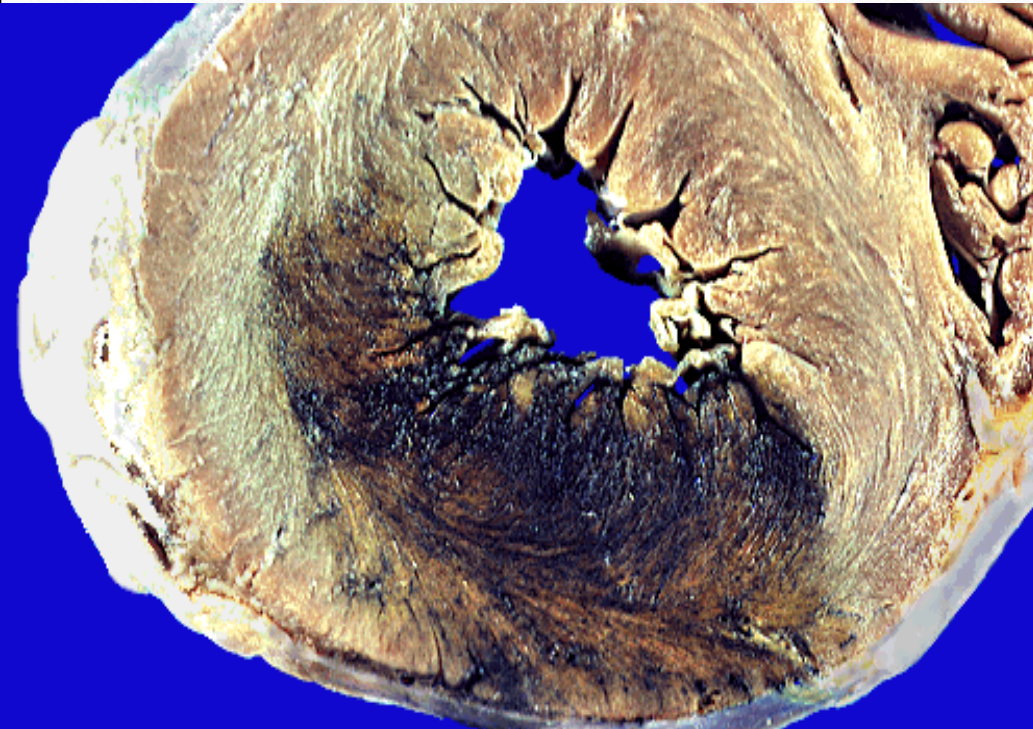


Patients with Sjögren's syndrome often exhibit inflammatory dry eye, as seen here.



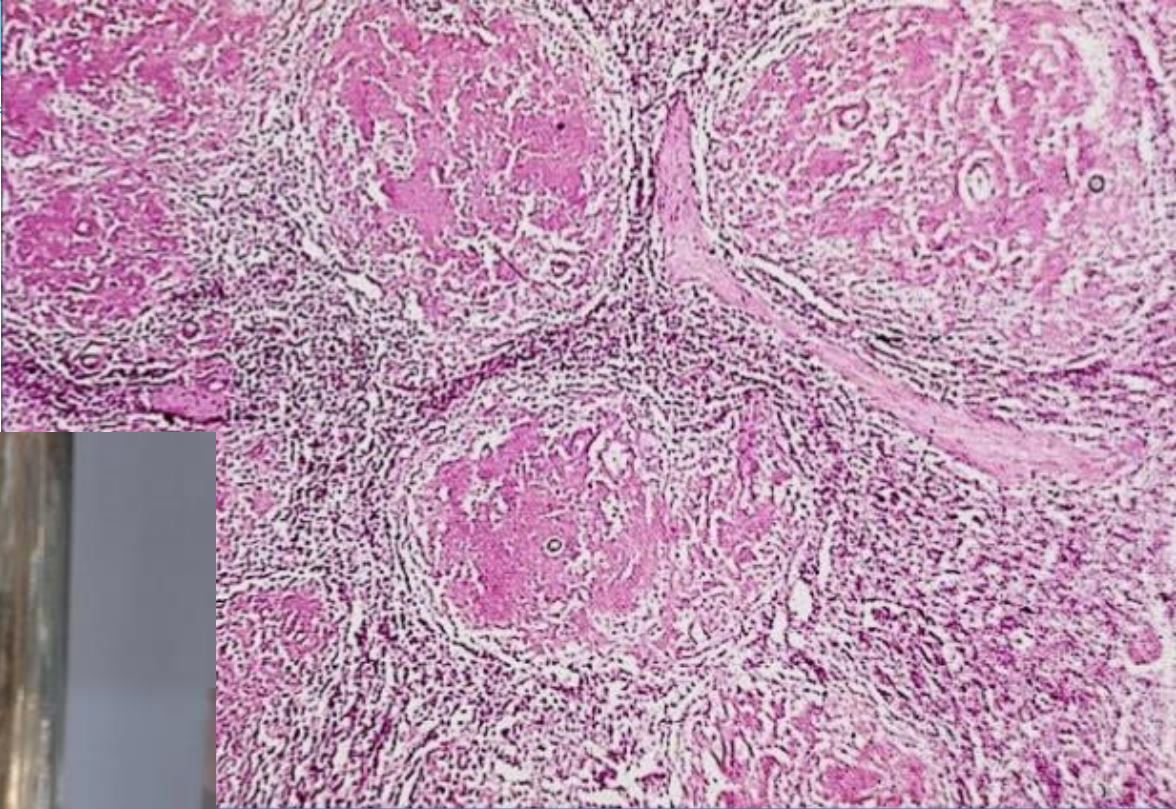
# Myocardial amyloidosis

## Macroscopic identification.



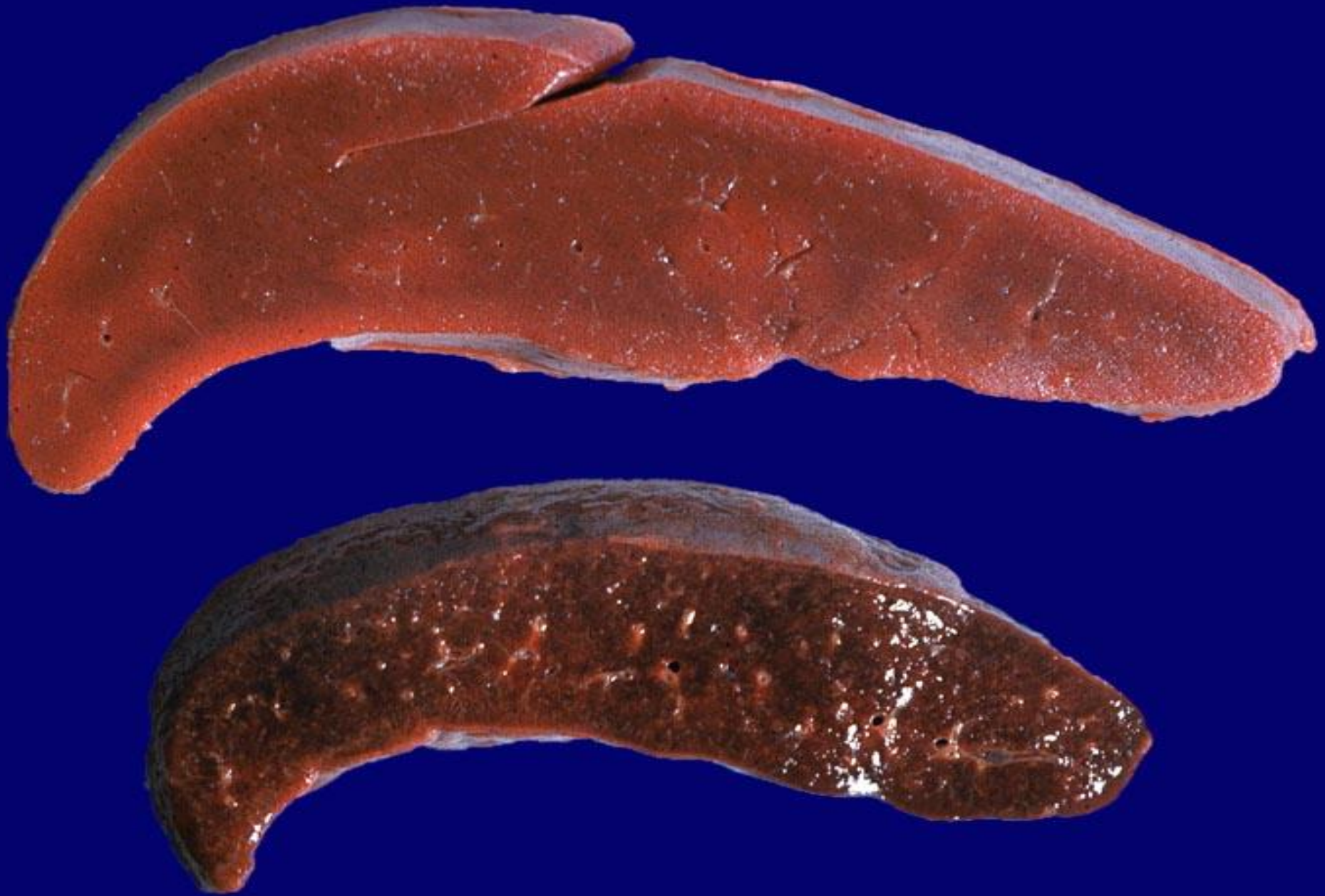**Virchow macroscopic reaction:** on successive application to the section surface of iodine or Lugol's solution and sulfuric acid (10%) the amyloid stains in blue-violet or dark green.





**Focal spleen amyloidosis (*sago spleen*).**





**Diffuse spleen amyloidosis.**  
*Image beneath - norm.*



# AUTO-IMMUNE DISEASES

- Failure of SELF RECOGNITION
- Failure of SELF TOLERANCE
- **TOLERANCE**
  - **CENTRAL** (Death of self reactive lymphocytes)
  - **PERIPHERAL** (anergy, suppression by T-cells, deletion by apoptosis, sequestration (Ag masking))
- **STRONG GENETIC PREDISPOSITION**
- **OFTEN RELATED TO OTHER AUTOIMMUNE DISEASES**
- **OFTEN TRIGGERED BY INFECTIONS**



# AUTO-IMMUNE DISEASES

- Central tolerance occurs during lymphocyte development and operates in the thymus and bone marrow. Here, T and B lymphocytes that recognize self antigens are deleted before they develop into fully immunocompetent cells, preventing autoimmunity.
- Peripheral tolerance is immunological tolerance developed after T and B cells mature and enter the periphery.

Acquired or induced tolerance refers to the immune system's adaptation to external antigens characterized by a specific non-reactivity of the lymphoid tissues to a given antigen that in other circumstances would likely induce cell-mediated or humoral immunity. One of the most important natural kinds of acquired tolerance is immune tolerance in pregnancy, where the fetus and the placenta must be tolerated by the maternal immune system.



# CLASSIC AUTOIMMUNE DISEASES (SYSTEMIC)

- **LUPUS (SLE) Systemic Lupus Erythematosus**
- **RHEUMATOID ARTHRITIS**
- **SJÖGREN SYNDROME**
- **SYSTEMIC SCLEROSIS (scleroderma)**
- **“collagen” diseases (term no longer used)**

Do not think that because the names of some of these SYSTEMIC auto-immune diseases seem to localize to certain areas, like joints, salivary glands, or skin, that they are NOT SYSTEMIC diseases.



# CLASSIC AUTOIMMUNE DISEASES (LOCAL)

- HASHIMOTO THYROIDITIS
- AUTOIMMUNE HEMOLYTIC ANEMIA
- MULTIPLE SCLEROSIS
- AUTOIMMUNE ORCHITIS
- GOODPASTURE SYNDROME
- AUTOIMMUNE THROMBOCYTOPENIA
- “PERNICIOUS” ANEMIA
- INSULIN DEPENDENT DIABETES MELLITUS
- MYASTHENIA GRAVIS
- GRAVES DISEASE

It is always dangerous to call a disease “local” because the more we study it, the more we realize it isn’t.

Nevertheless, this is the classic list of “local” autoimmune diseases.



# N.B.

- The list of diseases proven to be “autoimmune” grows by leaps and bounds every year!!!

Would it be fair to say EVERY disease is autoimmune? Probably NOT!

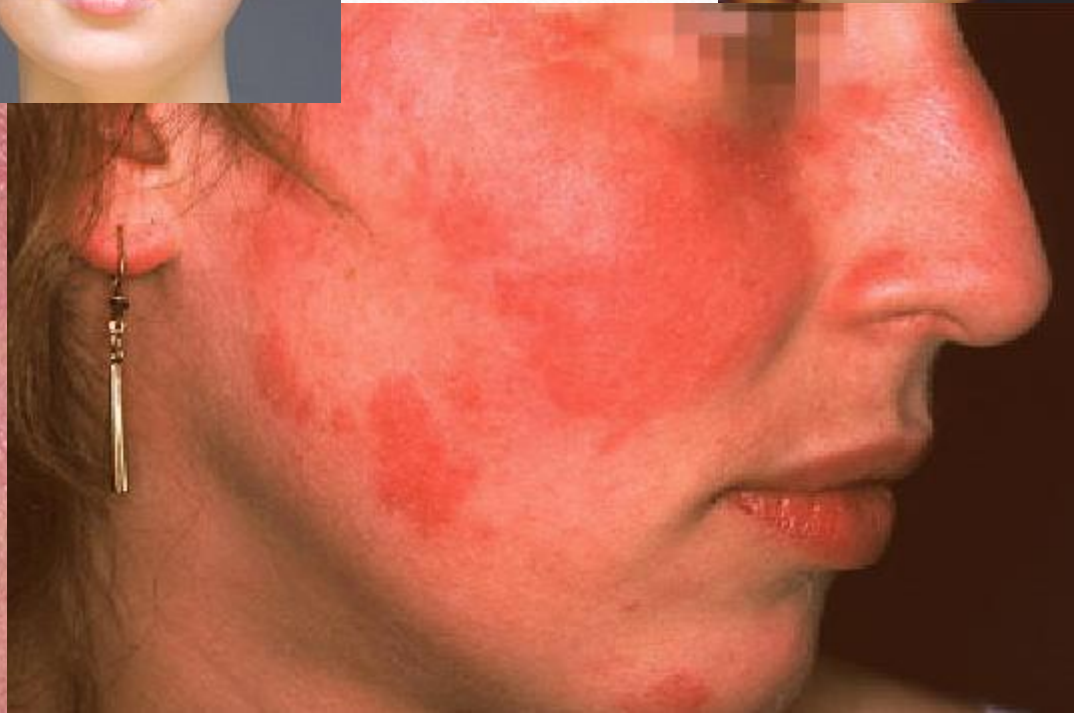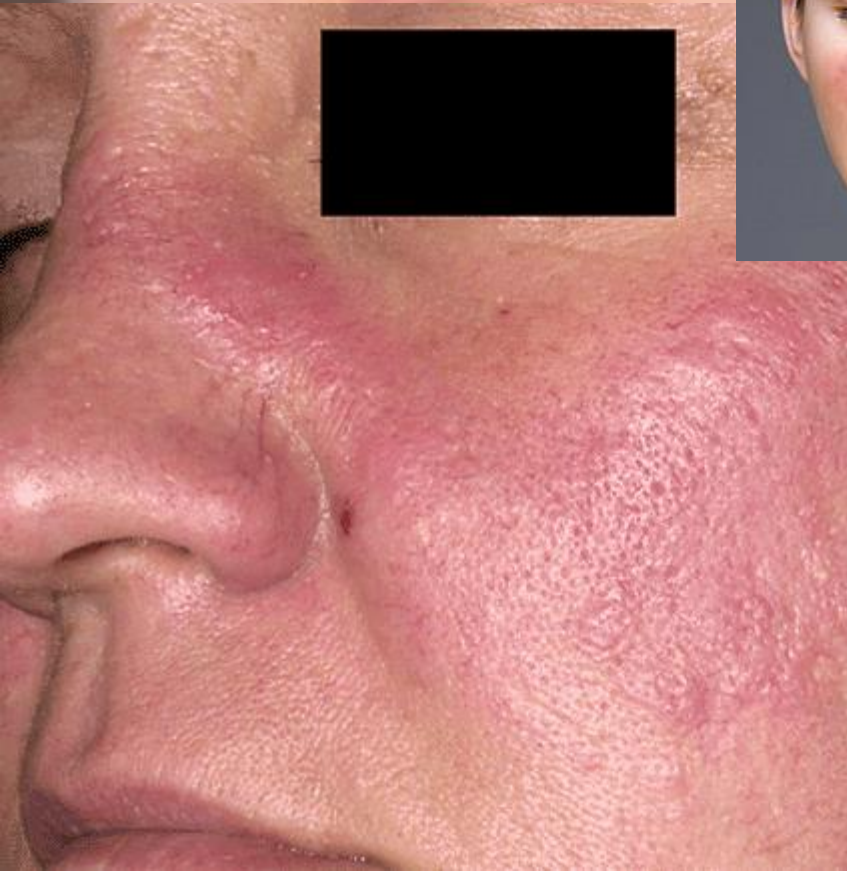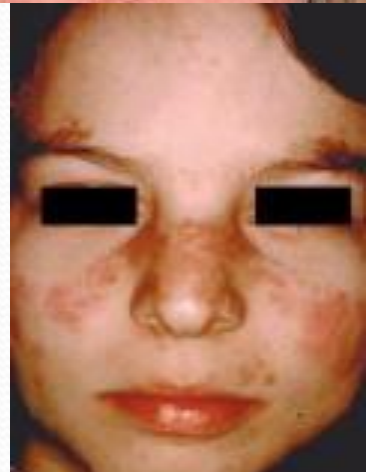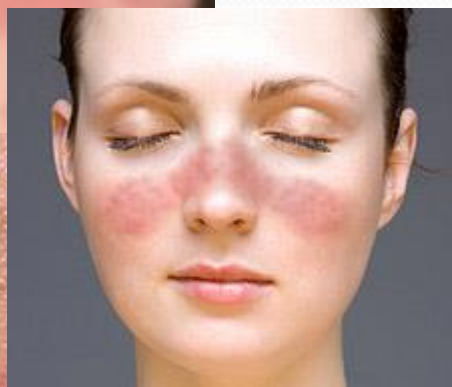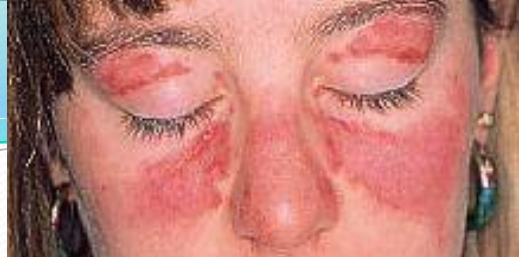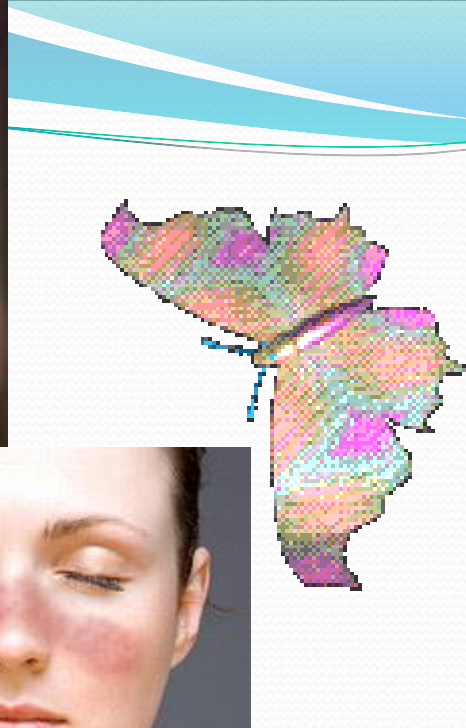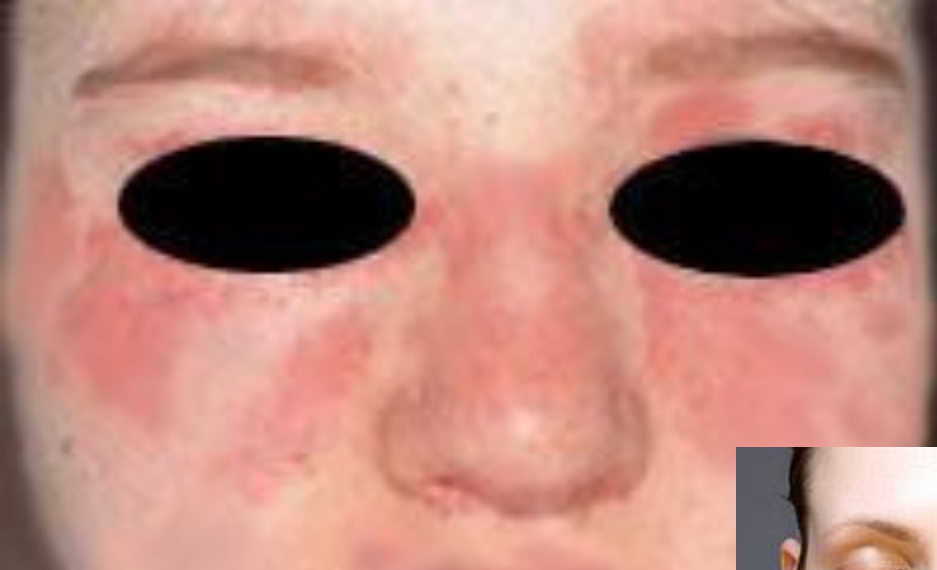Would it be fair to say almost every disease can result as a failure of some immune process? Probably!



# LUPUS (SLE)

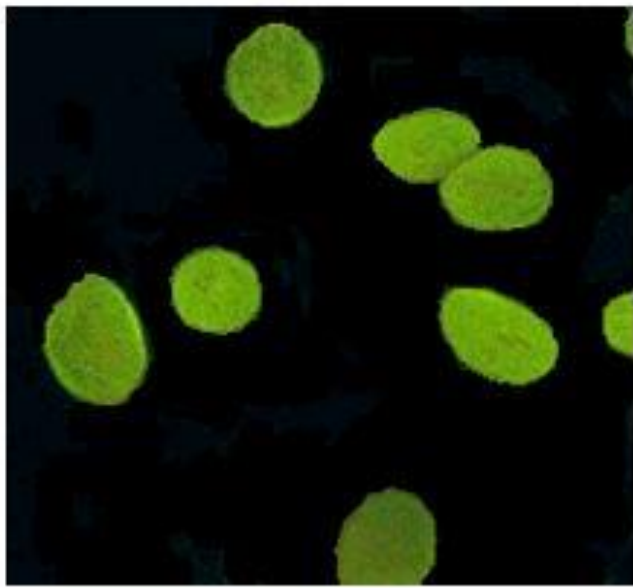
- **Etiology:** Antibodies (ABs) directed against the patient's own DNA, HISTONES, NON-histone RNA, and NUCLEOLUS
- **Pathogenesis:** Progressive DEPOSITION and INFLAMMATION to immune deposits, in skin, joints, kidneys, vessels, heart, CNS
- **Morphology:** “Butterfly” rash, skin deposits, glomerulonephritis (NOT discoid)
- **Clinical expression:** Progressive renal and vascular disease, POSITIVE A.N.A.



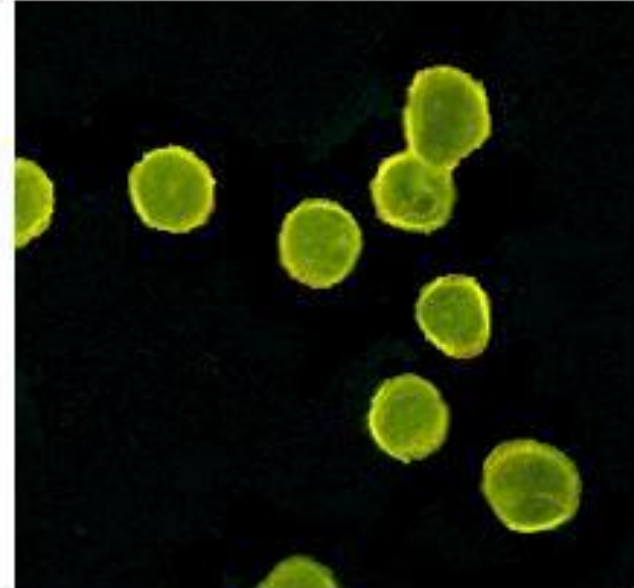




H  
O  
M  
O

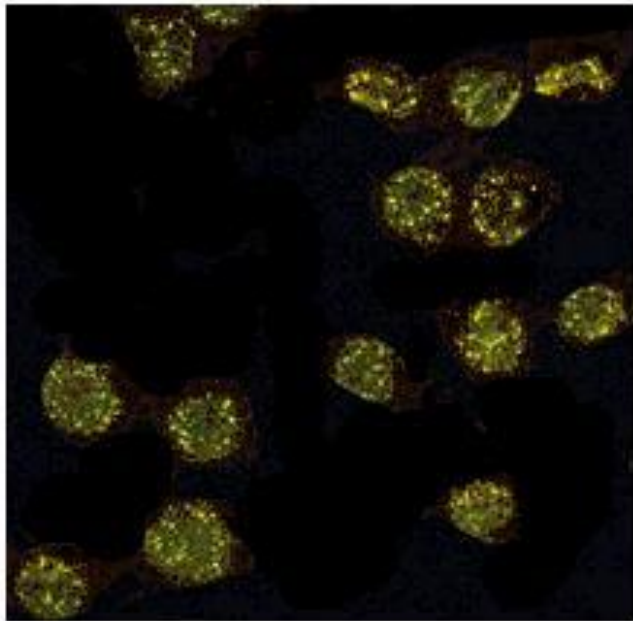


Homogenous pattern

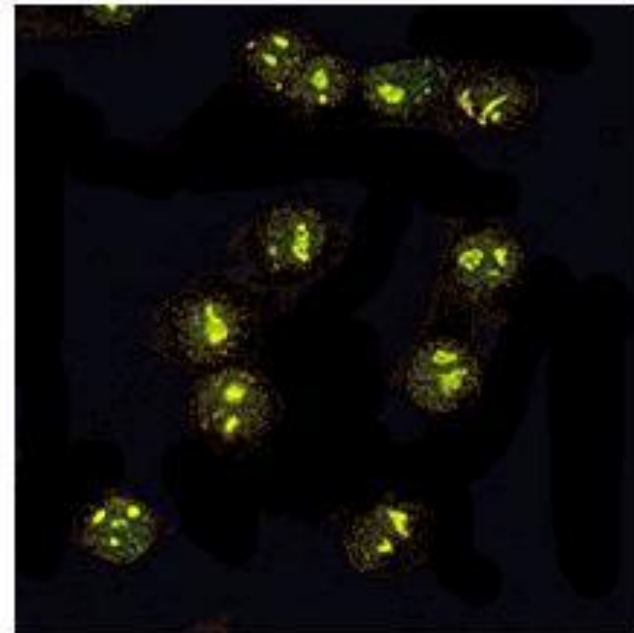


Rim pattern

S  
P  
E  
C  
K



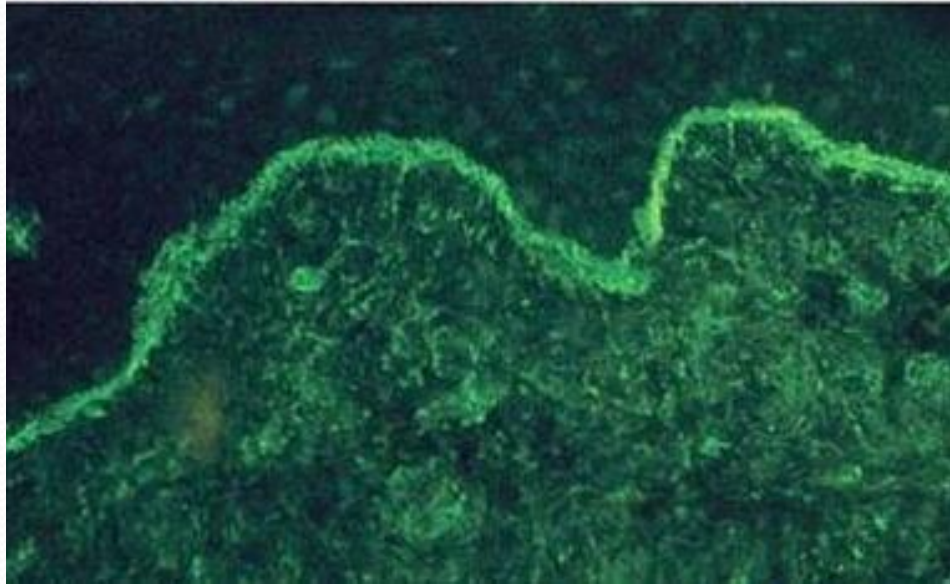
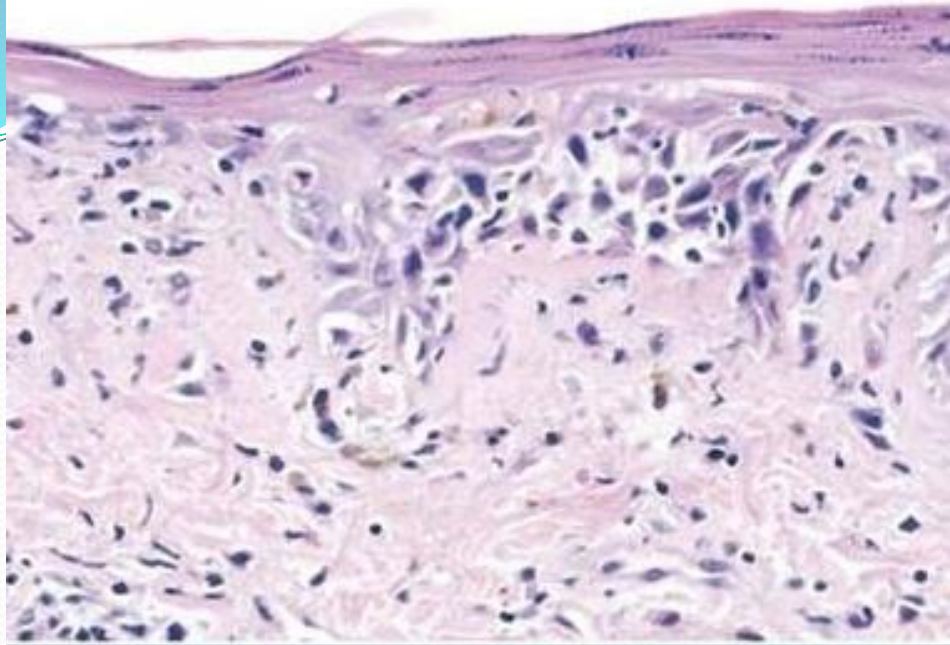
Speckled pattern



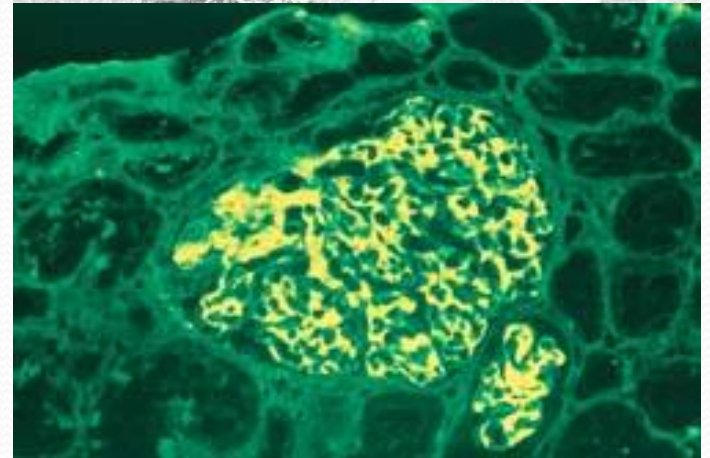
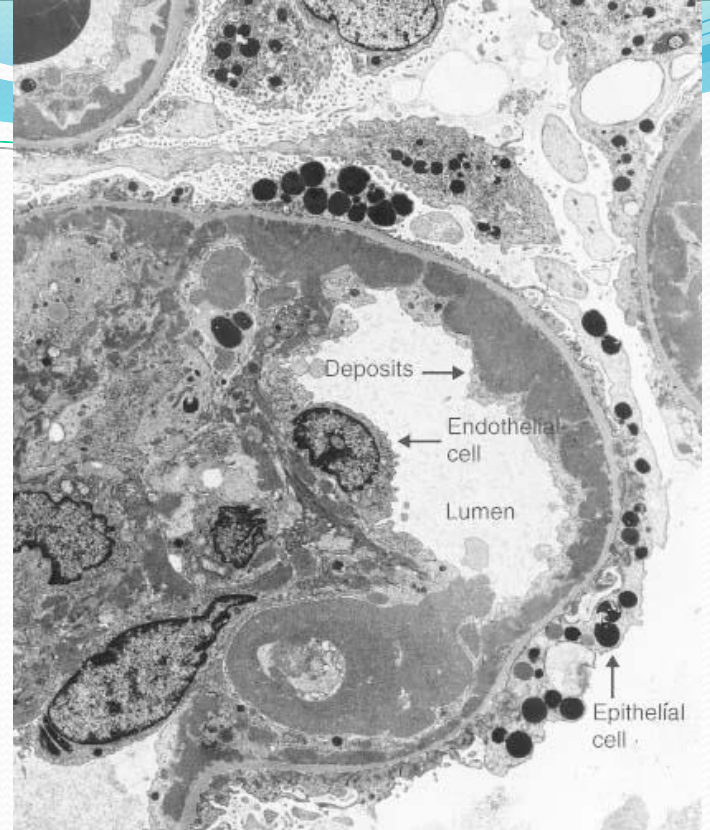
Nucleolar pattern

R  
I  
M  
  
N  
U  
C  
L  
E  
O  
L  
A  
R



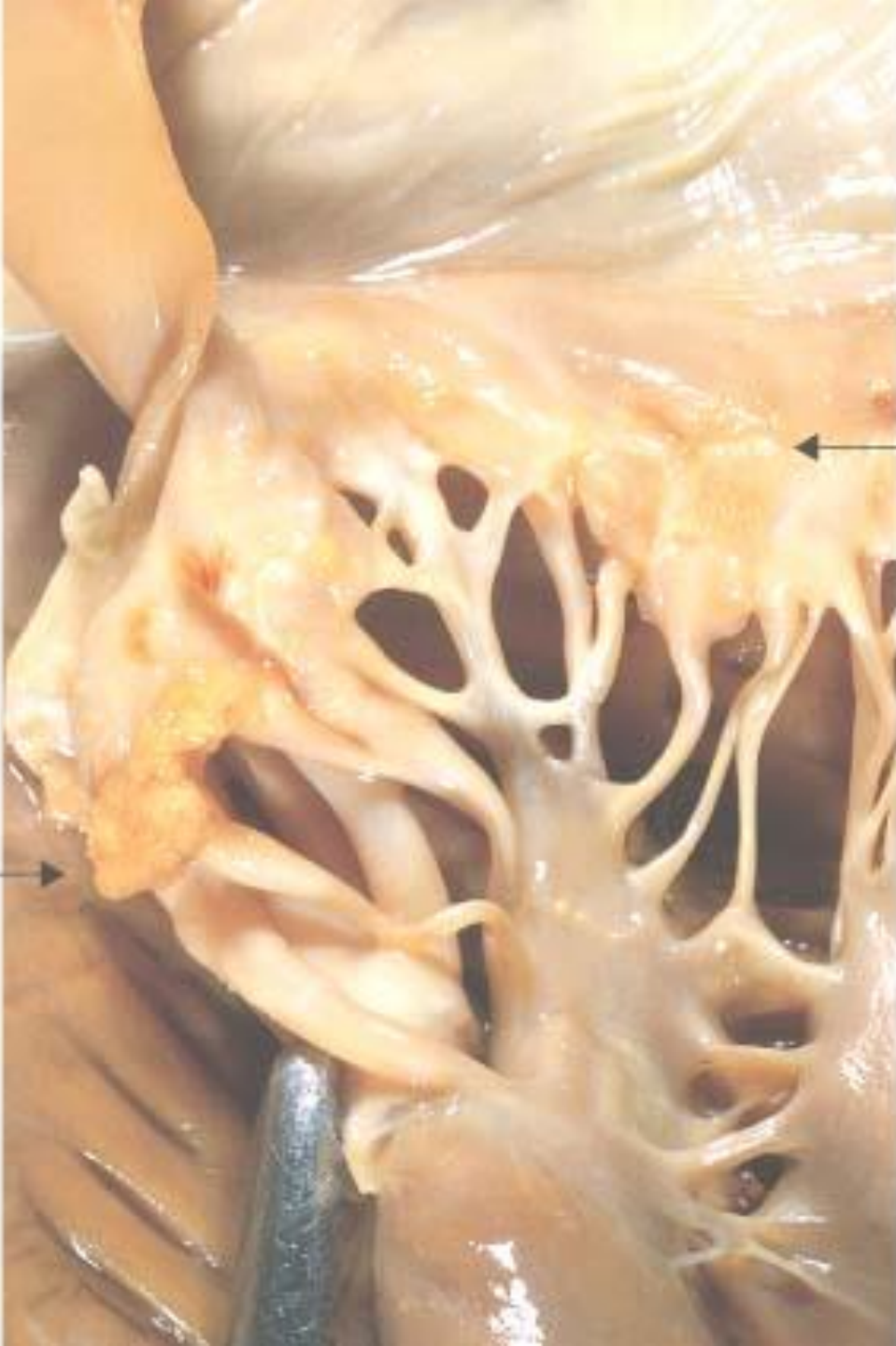


**SLE, SKIN**



**SLE, GLOMERULUS**





Vegetations

Libman-Sacks vegetations, also called Libman-Sacks endocarditis, are on **BOTH** sides of the leaflet.



**TABLE 6-10 -- Clinical and Pathologic Manifestations of Systemic Lupus Erythematosus**

<b>Clinical Manifestation</b>	<b>Prevalence in Patients, %</b>
<b>Hematologic</b>	<b>100</b>
<b>Arthritis</b>	<b>90</b>
<b>Skin</b>	<b>85</b>
<b>Fever</b>	<b>83</b>
<b>Fatigue</b>	<b>81</b>
<b>Weight loss</b>	<b>63</b>
<b>Renal</b>	<b>50</b>
<b>Central nervous system</b>	<b>50</b>
<b>Pleuritis</b>	<b>46</b>
<b>Myalgia</b>	<b>33</b>
<b>Pericarditis</b>	<b>25</b>
<b>Gastrointestinal</b>	<b>21</b>
<b>Raynaud phenomenon</b>	<b>20</b>
<b>Ocular</b>	<b>15</b>
<b>Peripheral neuropathy</b>	<b>14</b>

Renal failure in a young woman is always highly suspect of lupus.



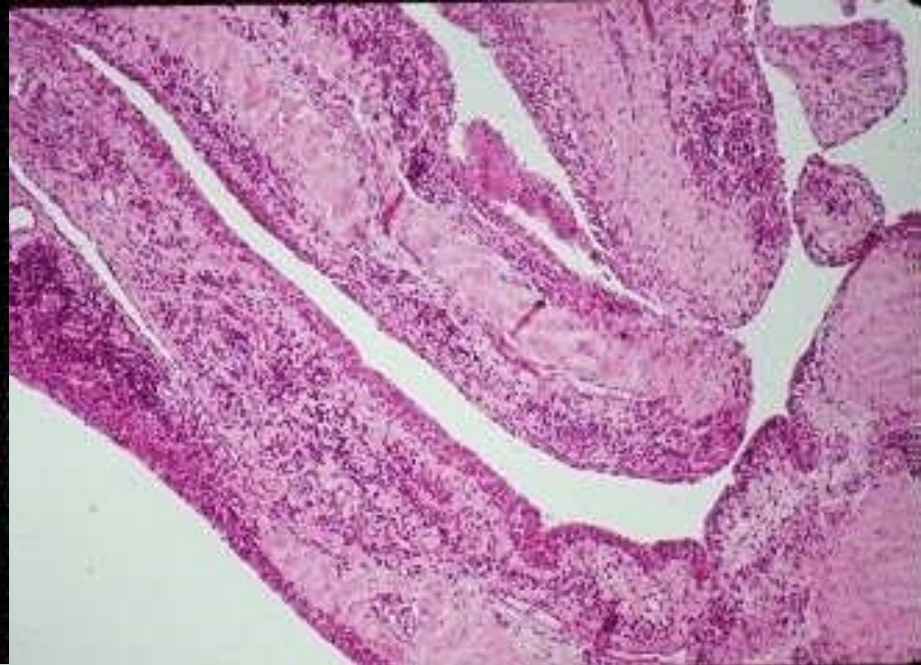
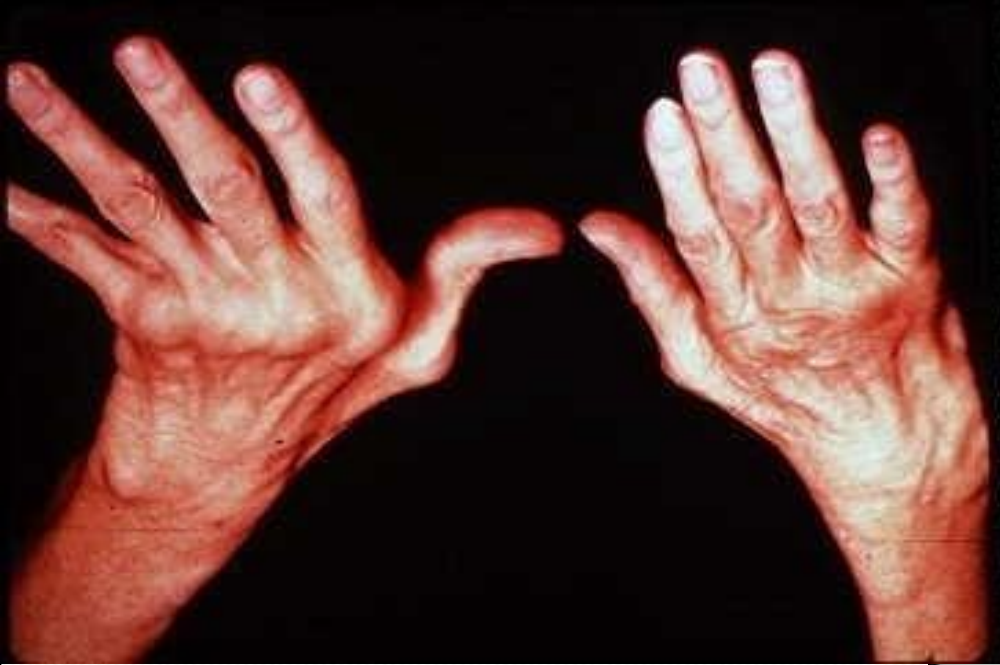# **MORE SYSTEMIC**

# **AUTOIMMUNE**

# **DISEASES**

- **RHEUMATOID ARTHRITIS**
- **SJÖGREN SYNDROME**
- **SCLERODERMA (SYSTEMIC SCLEROSIS)**





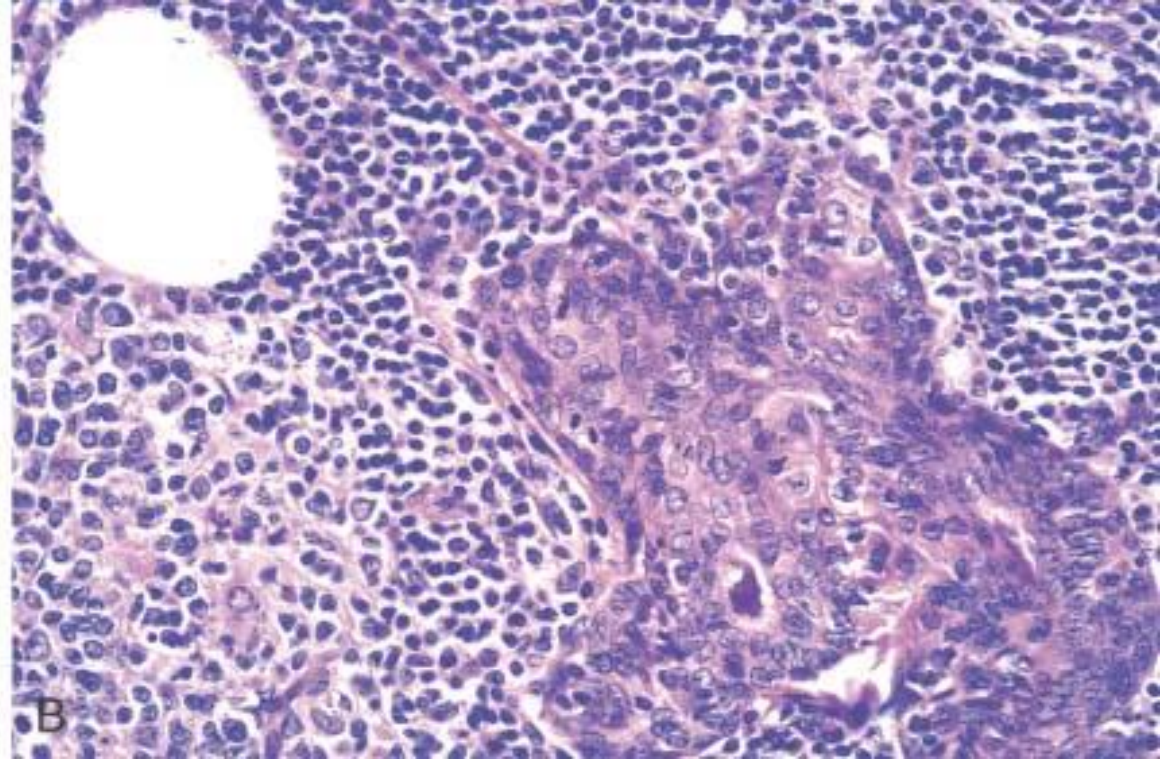
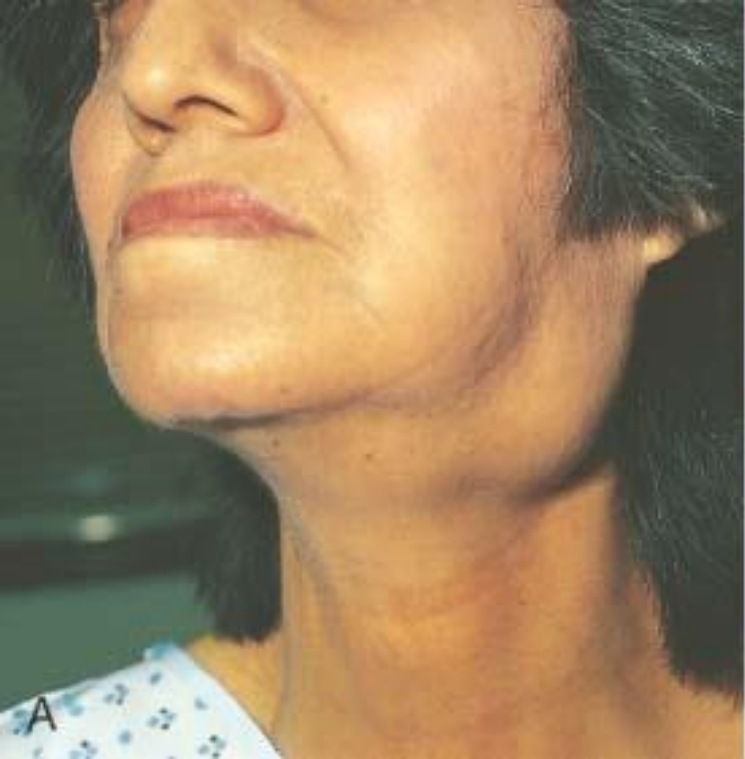**Rheumatoid factor** (RF or RhF) is an **autoantibody** (**antibody** directed against an organism's own tissues) most relevant in **rheumatoid arthritis**. It is an **antibody** against the Fc portion of **IgG**, which is itself an antibody.

In rheumatoid arthritis the primary areas of the body ravaged by autoimmune destruction are synovium and blood vessels.

↑  
**Destructive  
Rheumatoid Synovitis**

← **NORMAL Bi-Layered  
Synovium**

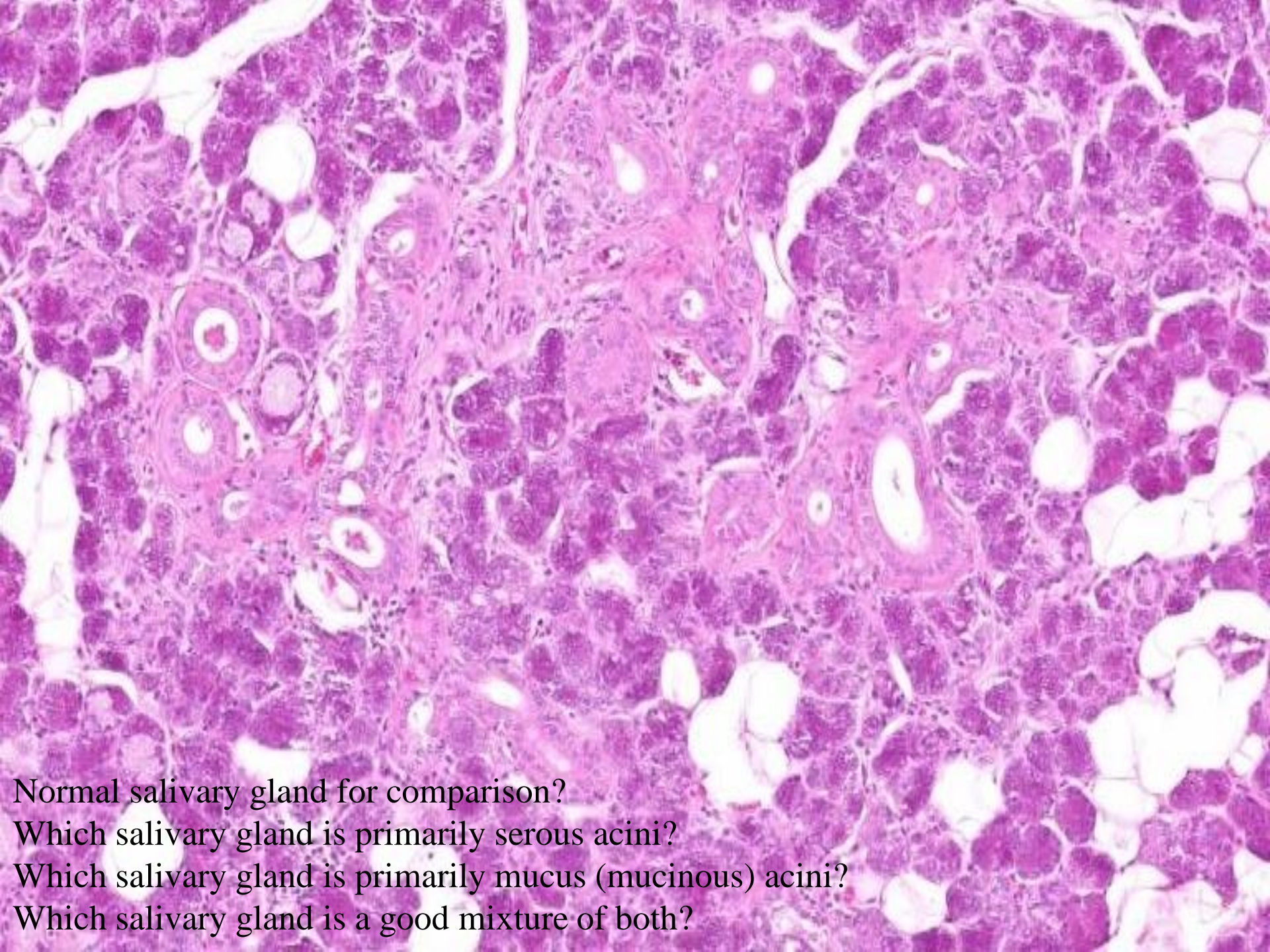




# SJÖGREN SYNDROME

Keratoconjunctivitis “sicca” (i.e., “dry” is another name for Sjögren Syndrome, another SYSTEMIC auto-immune disease.





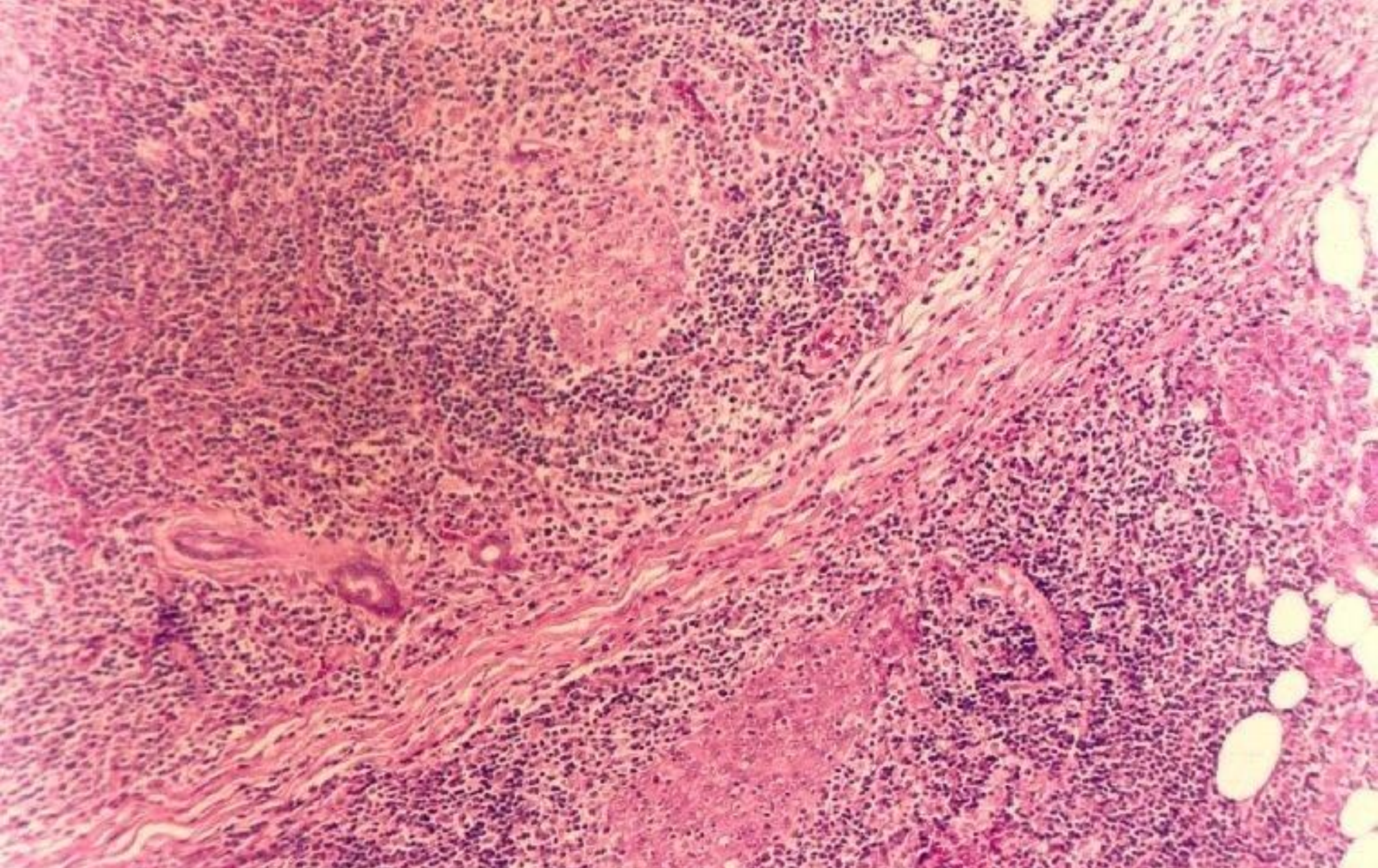
Normal salivary gland for comparison?

Which salivary gland is primarily serous acini?

Which salivary gland is primarily mucus (mucinous) acini?

Which salivary gland is a good mixture of both?

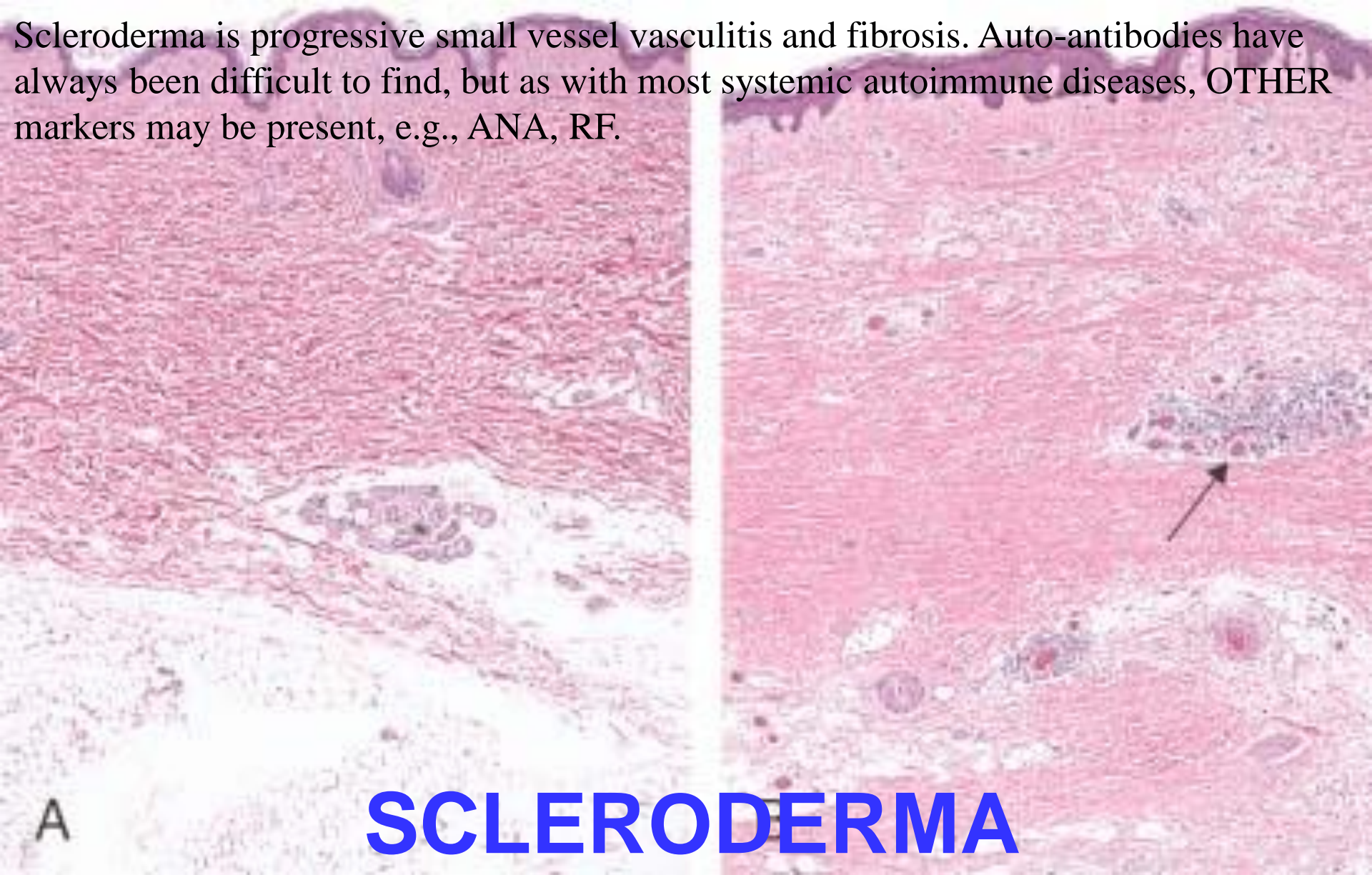




In this massively inflamed salivary gland you only see a few remnants of epithelial structures, i.e., ducts and acini. Would you also diagnose this as “severe chronic sialadenitis”?



Scleroderma is progressive small vessel vasculitis and fibrosis. Auto-antibodies have always been difficult to find, but as with most systemic autoimmune diseases, OTHER markers may be present, e.g., ANA, RF.

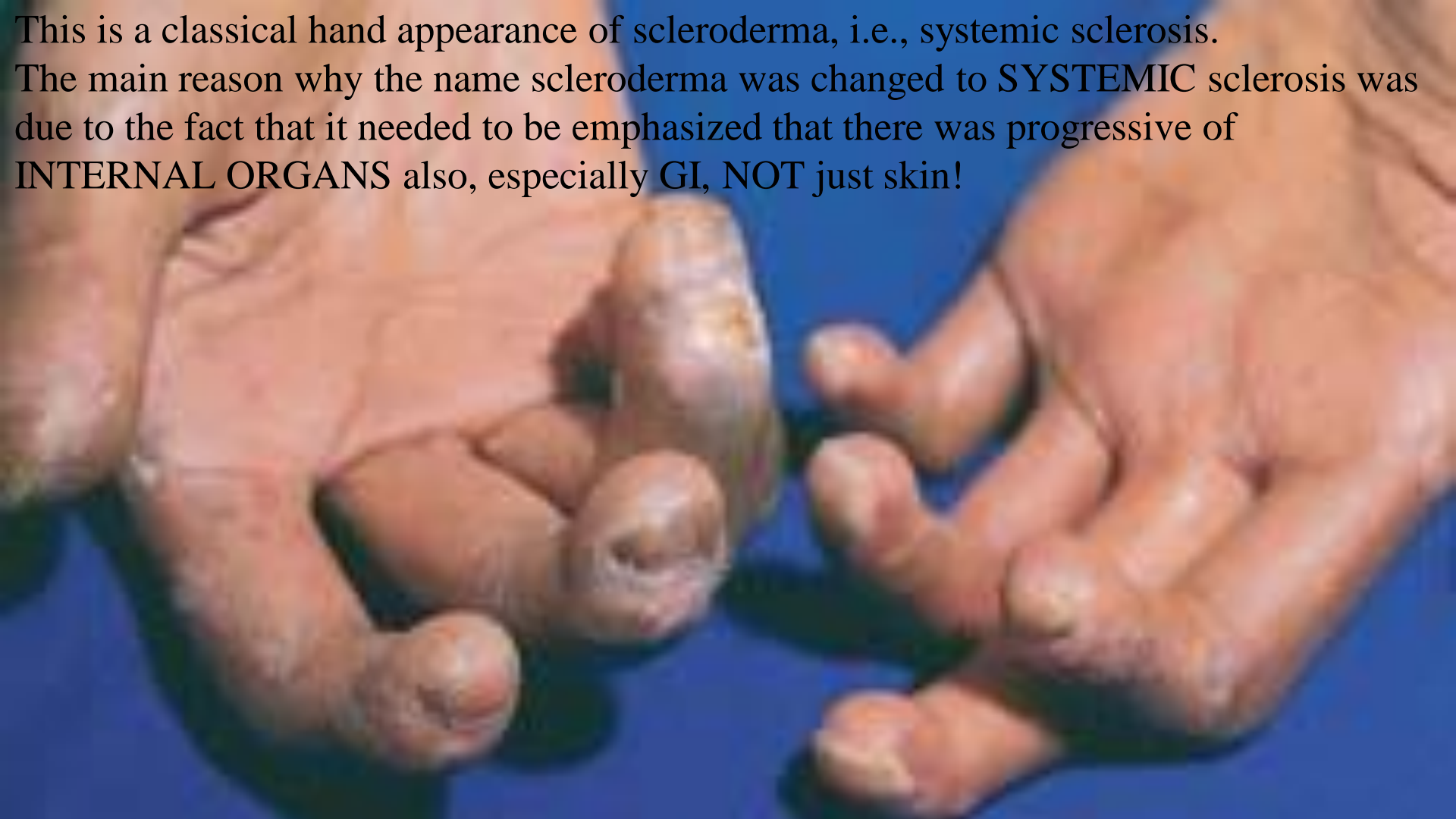

**SCLERODERMA**

**(SYSTEMIC SCLEROSIS)**



This is a classical hand appearance of scleroderma, i.e., systemic sclerosis. The main reason why the name scleroderma was changed to **SYSTEMIC** sclerosis was due to the fact that it needed to be emphasized that there was progressive of **INTERNAL ORGANS** also, especially GI, **NOT** just skin!



# **SYSTEMIC SCLEROSIS**

## **(SCLERODERMA)**



# **MORE AUTOIMMUNE DISEASES (LOCAL)**

- **HASHIMOTO THYROIDITIS**
- **AUTOIMMUNE HEMOLYTIC ANEMIA**
- **MULTIPLE SCLEROSIS**
- **AUTOIMMUNE ORCHITIS**
- **GOODPASTURE SYNDROME**
- **AUTOIMMUNE THROMBOCYTOPENIA (ITP)**
- **“PERNICIOUS” ANEMIA**
- **INSULIN DEPENDENT DIABETES MELLITUS (I)**
- **MYASTHENIA GRAVIS**
- **GRAVES DISEASE**



# Immuno**D**eficiency

## Syndromes (**-IDS**)

- PRIMARY (GENETIC)  
(**P-IDS?**)
- SECONDARY  
(**ACQUIRED**) (**A-IDS**)



# PRIMARY

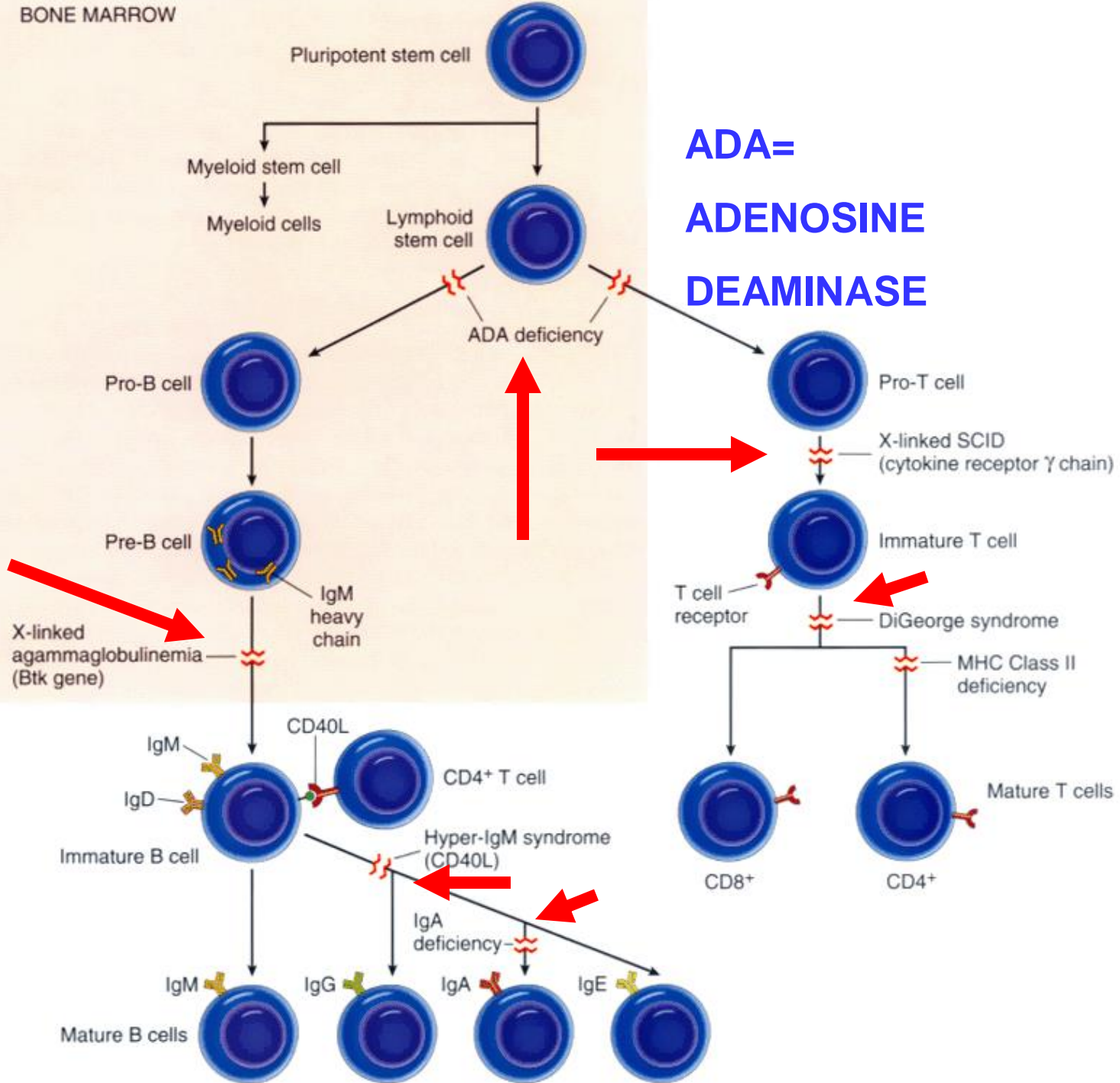
- CHILDREN with repeated, often severe infections, cellular AND/OR humoral immunity problems, autoimmune defects
- BRUTON (X-linked agammaglobulinemia)
- COMMON VARIABLE
- IgA deficiency
- Hyper-IgM
- DI GEORGE (THYMIC HYPOPLASIA) 22q11.2
- SCID (Severe Combined Immuno Deficiency)
- ...with thrombocytopenia and eczema (WISKOTT-ALDRICH)
- COMPLEMENT DEFICIENCIES



# PRIMARY

- **22q11.2 deletion syndrome**, also known as Velocardiofacial Syndrome, DiGeorge Syndrome and Strong Syndrome is a disorder caused by the deletion of a small piece of **chromosome 22**. The deletion occurs near the middle of the **chromosome** at a location designated q11.2. It has a prevalence estimated at 1:4000. Do you remember what CATCH is the mnemonic for? Hint: the “T” stands for “T”ymic aplasia.
- SCID: Chronic diarrhea, ear infections, recurrent *Pneumocystis jirovecii* pneumonia, and profuse oral **candidiasis** commonly occur. These babies, if untreated, usually die within 1 year due to severe, recurrent infections. However, treatment options are much improved since David Vetter, “the Boy in the Bubble”.
- **Wiskott-Aldrich syndrome (WAS)** is a rare **X-linked recessive** disease characterized by **eczema**, **thrombocytopenia** (low **platelet** count), **immune deficiency**, and bloody diarrhea (secondary to the thrombocytopenia). It is also sometimes called the *eczema-thrombocytopenia-immunodeficiency syndrome* in keeping with Aldrich's original description in **1954**.
- You should probably know the clinical presentation “profiles” of these patients with PIDS (PRIMARY Immune Deficiency Syndromes)
- Bruton’s: Males (of course) with infections, especially enteroviral, after a few months of life, after maternal antibodies are gone.
- COMMON VARIABLE: Most patients in 20’s, UTIs, LTIs
- IgA Deficiency: Usually NO symptoms
- Hyper IgM: Recurrent pyogenic infections, pneumonia, PCP, neutropenia, thrombocytopenia.
- DiGeorge: Birth defects, learning disabilities, infections, thymus problems. C-A-T-C-H
- SCID: Candidiasis, diaper rash, failure to thrive, “The Boy in the Bubble”







Previous slide is important for understanding the UNIFYING concepts between ALL the PRIMARY immunodeficiencies.

Bruton's x-linked agammaglobulemia: NO tyrosine kinase (BTK gene)

COMMON VARIABLE: Various genetic defects, both B and T cells involved.

IgA deficiency: Unknown

Hyper IgM: CD40-L gene defect

DiGeorge: 22q11 deletion, failure of development of 3<sup>rd</sup> and 4<sup>th</sup> pharyngeal pouch.

SCID: Early T-Cell failure. Would you think the "C" in combined stands for T, B, or T4, T8?

Would you imagine an ADA deficiency would be the worst of all possible defects?

Ans: YES

If there were no red arrows in this diagram, would it be a good diagram to explain lymphocyte "differentiation"? Ans: YES



# Examples of Infections in Immunodeficiencies

Pathogen Type	T-Cell-Defect	B-Cell Defect	Granulocyte Defect	Complement Defect
Bacteria	Bacterial sepsis	Streptococci, staphylococci, <i>Haemophilus</i>	Staphylococci, <i>Pseudomonas</i>	<b>Neisserial</b> infections, other pyogenic bacterial infections
Viruses	Cytomegalovirus, Epstein-Barr virus, severe varicella, chronic infections with respiratory and intestinal viruses	Enteroviral encephalitis		
Fungi and parasites	<i>Candida</i> , <i>Pneumocystis carinii</i>	Severe intestinal giardiasis	<i>Candida</i> , <i>Nocardia</i> , <i>Aspergillus</i>	
Special features	Aggressive disease with opportunistic pathogens, failure to clear infections	Recurrent sinopulmonary infections, sepsis, chronic meningitis		

This is a useful slide for understanding, VERY GENERALLY, which kinds of infections result from which kinds of deficiencies. As you can see, there is considerable overlap. Note that the RED pathogens are fairly typical for defects in the class of defects ABOVE them



# AIDS (SECONDARY IDS)

- Etiology: HIV
- Pathogenesis: Infection, Latency, Progressive T-Cell loss
- Morphology: MANY
- Clinical Expressions: Infections, Neoplasms, Progressive Immune Failure, Death, HIV+, HIV-RNA (Viral Load)

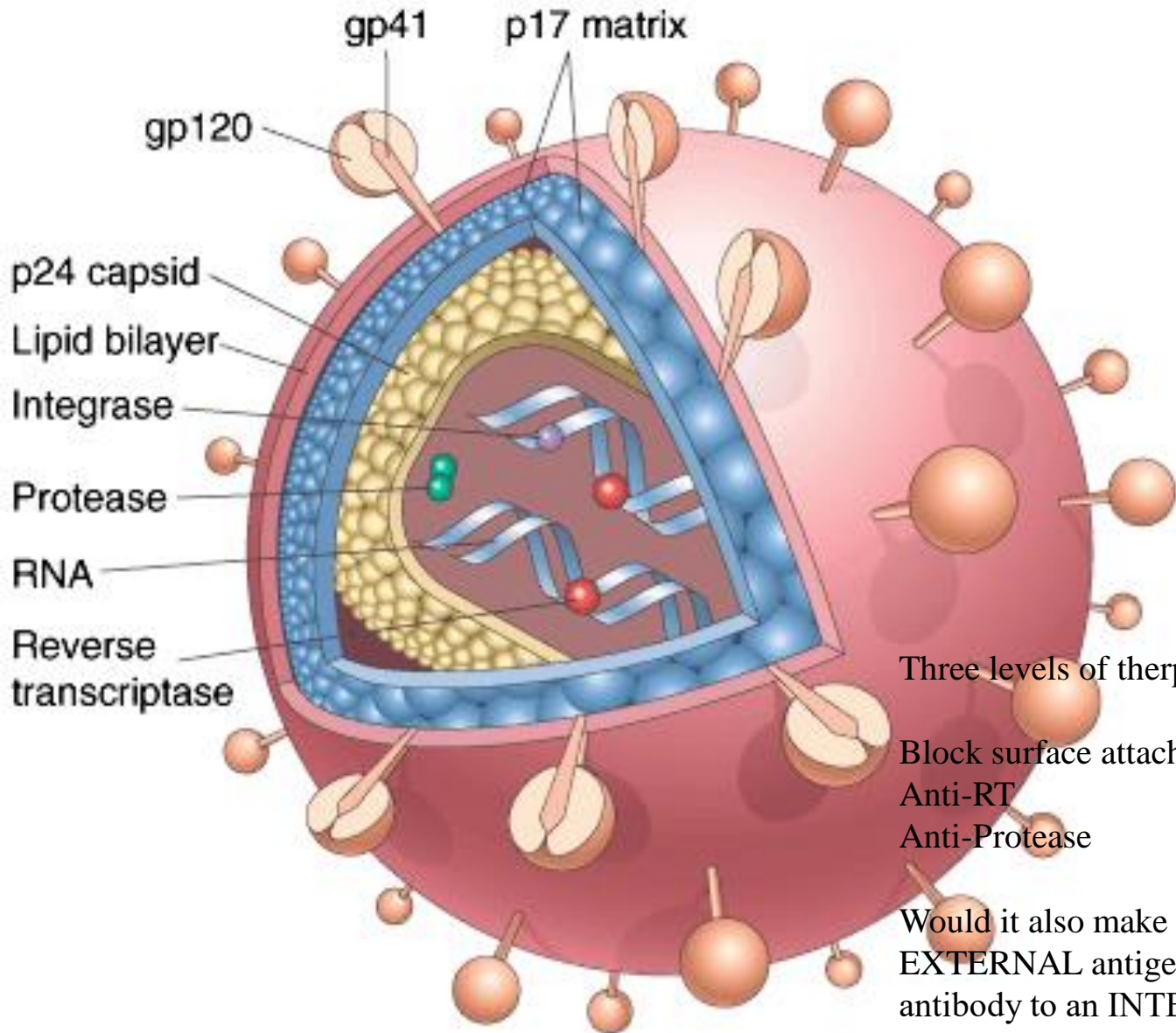


# EPIDEMIOLOGY

- **HOMOSEXUAL** (40%, and declining)
- **INTRAVENOUS DRUG USAGE** (25%)
- **HETEROSEXUAL SEX** (10% and rising)



# ETIOLOGY



Three levels of therapeutic rationale:

Block surface attachment

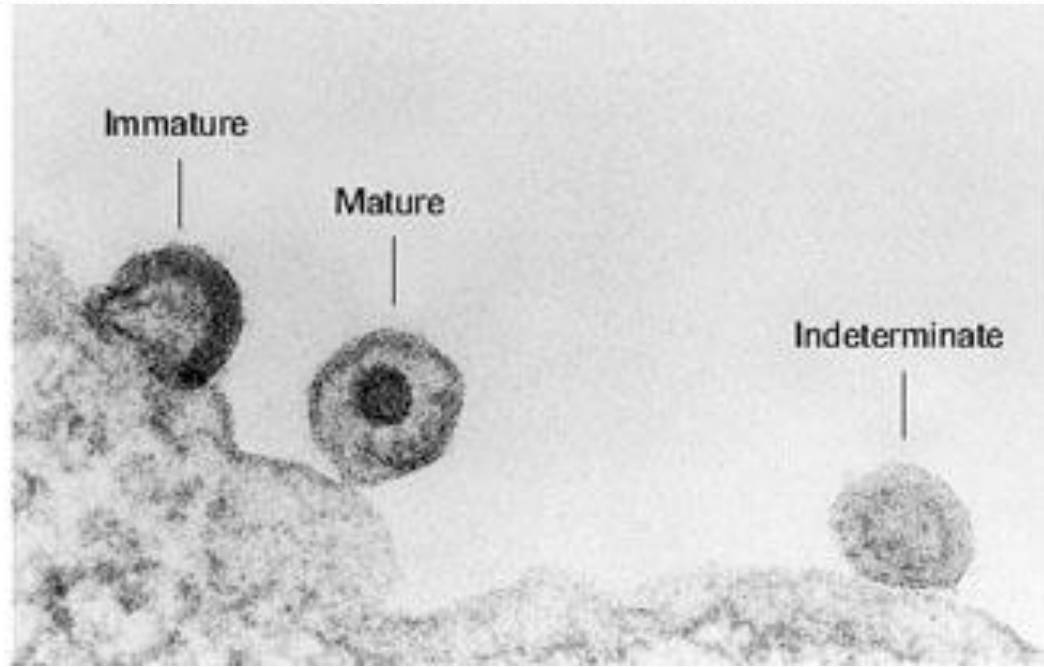
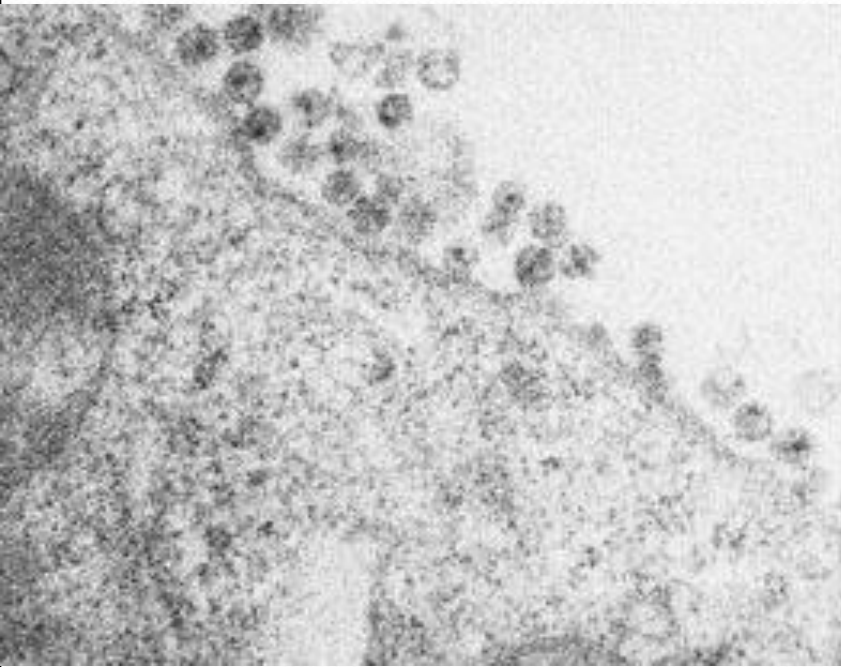
Anti-RT

Anti-Protease

Would it also make sense that an antibody to an EXTERNAL antigen become positive BEFORE an antibody to an INTERNAL (i.e., "core") antigen?



# PATHOGENESIS

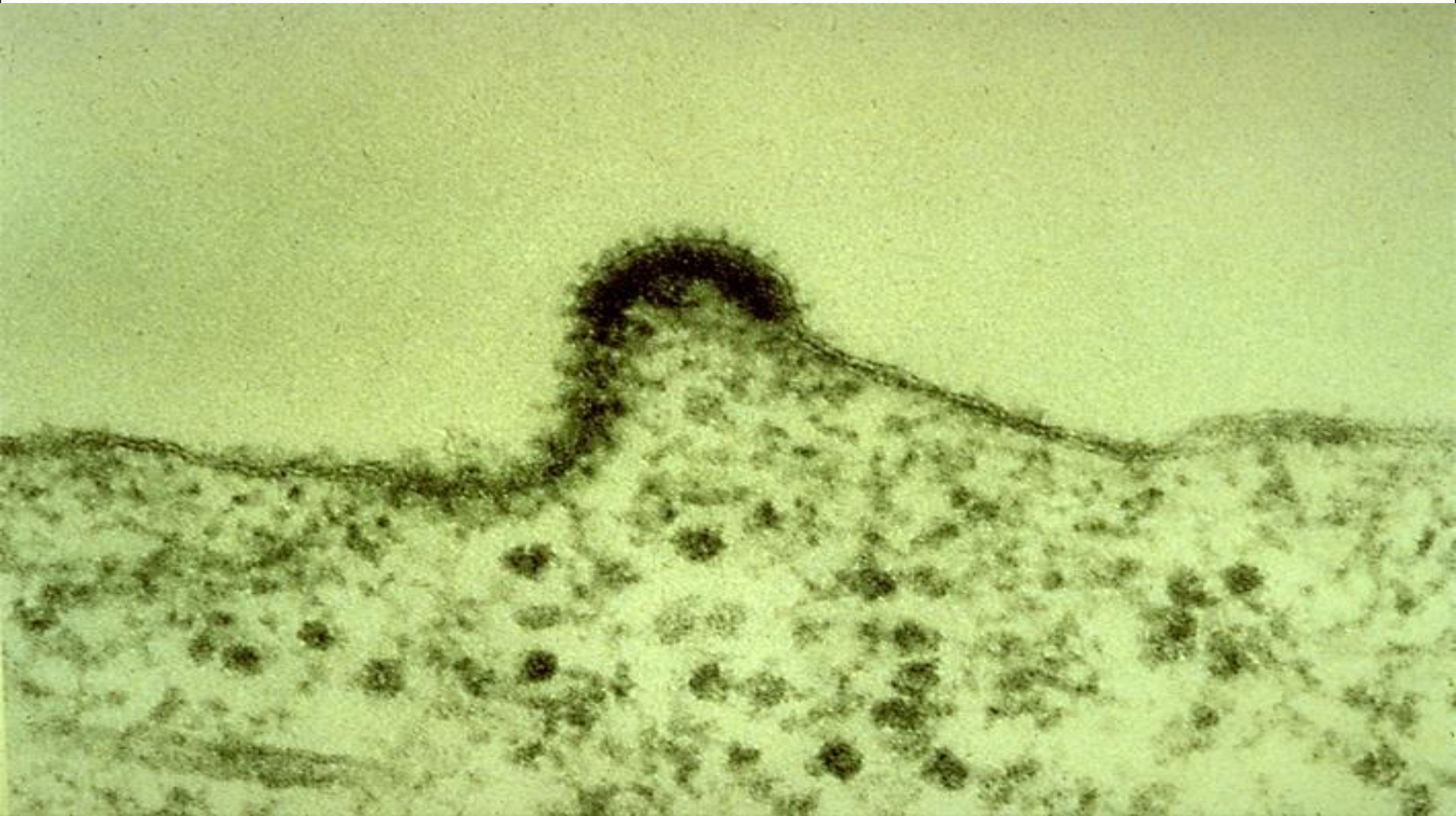


**ATTACHING**

**BUDDING**



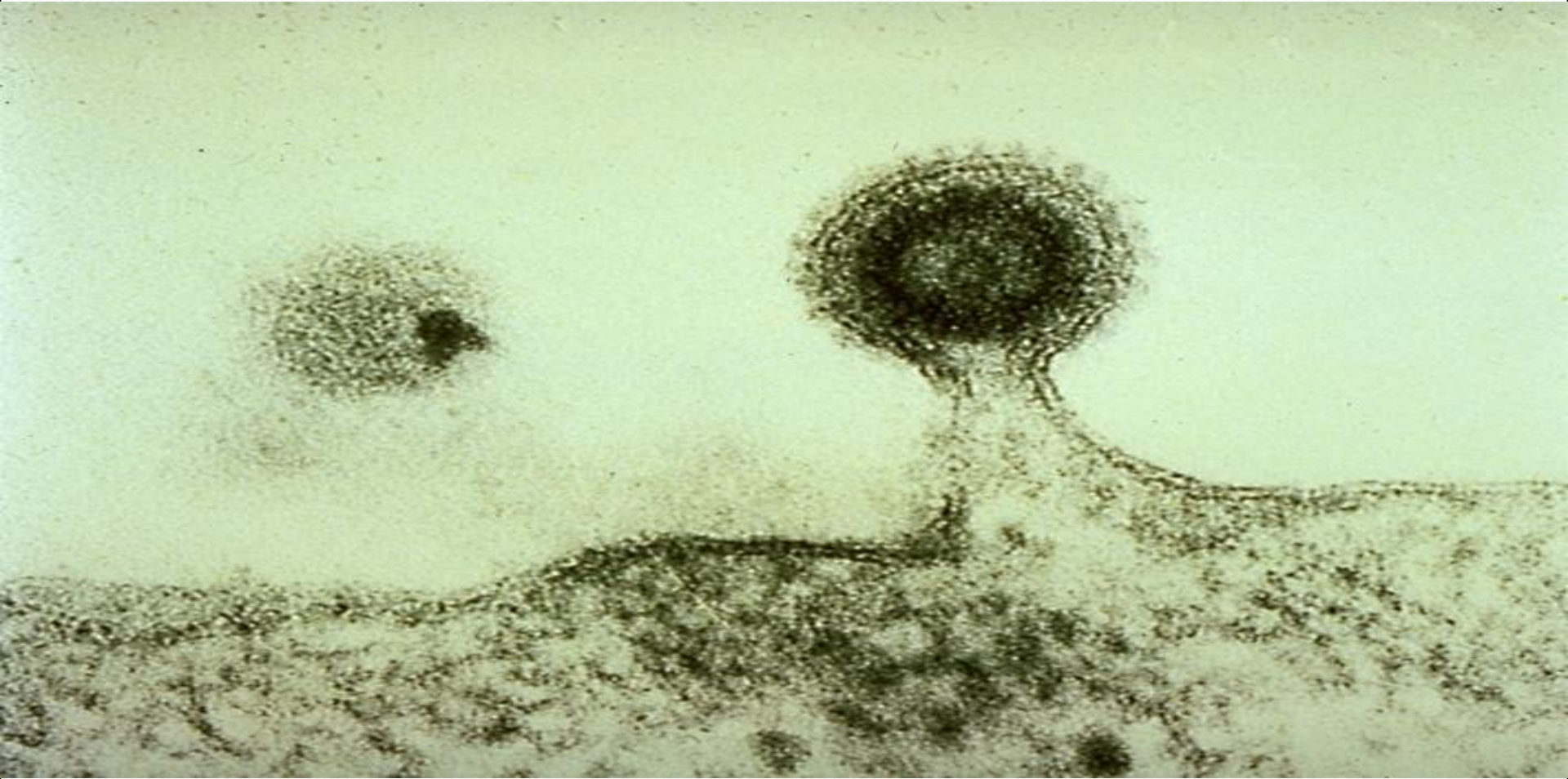
# PATHOGENESIS



**EARLY BUDDING**



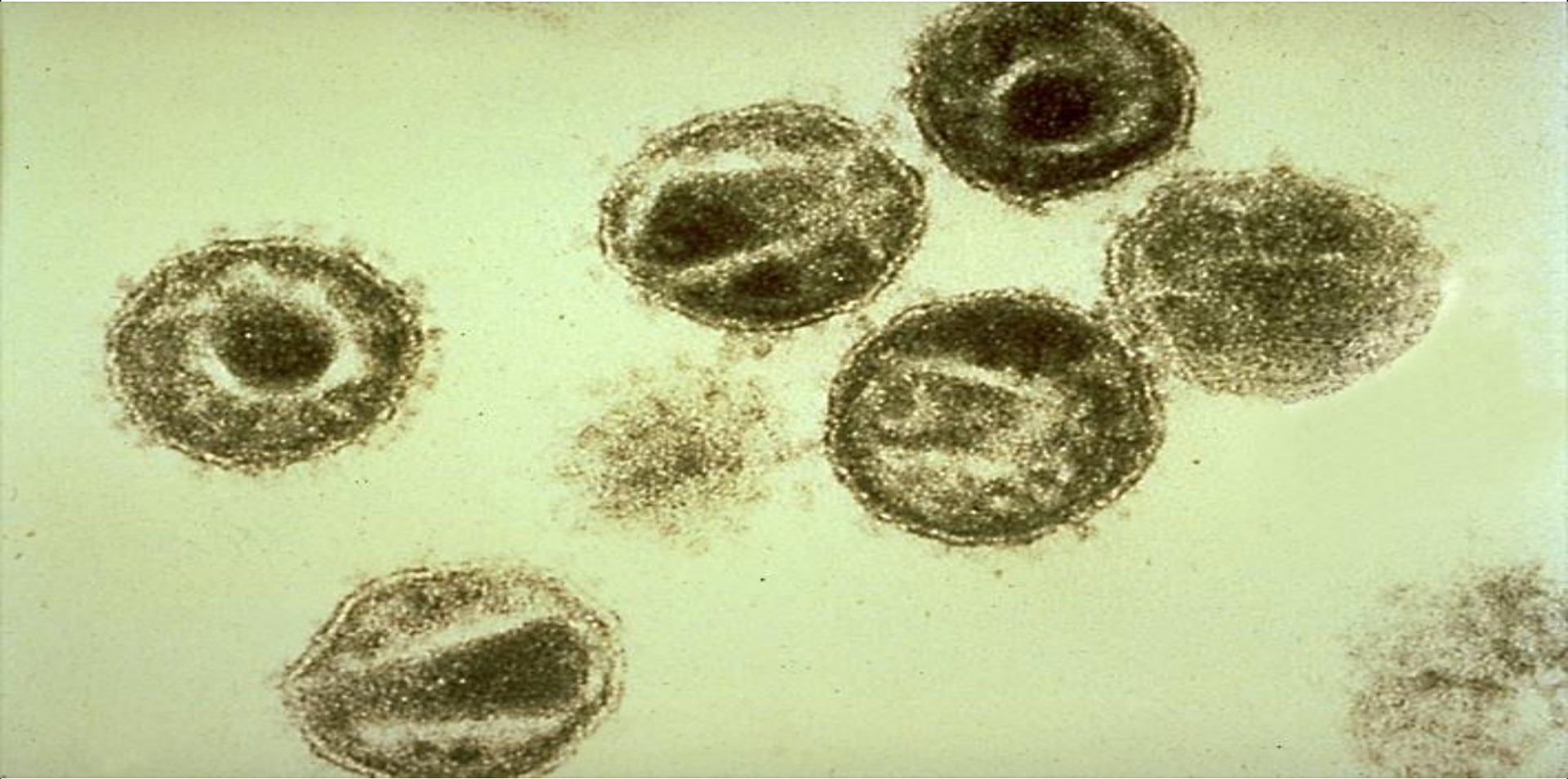
# PATHOGENESIS



**LATE BUDDING**



# PATHOGENESIS



**MATURE NEW VIRIONS**

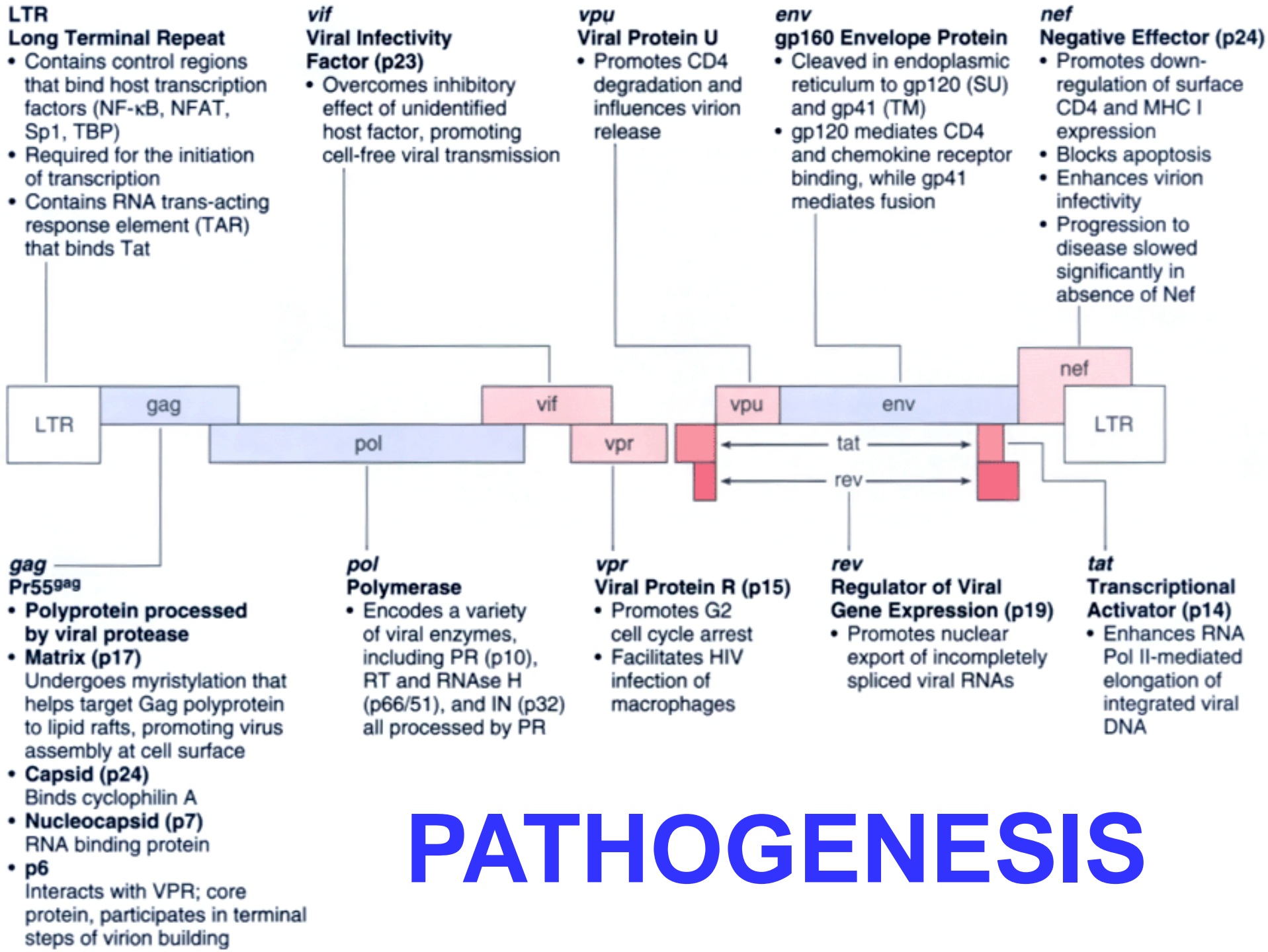


# REVERSE TRANSCRIPTASE

- The enzyme reverse transcriptase (RT) is used by retroviruses to transcribe their single-stranded RNA genome into single-stranded DNA and to subsequently construct a complementary strand of DNA, providing a DNA double helix capable of integration into host cell chromosomes.

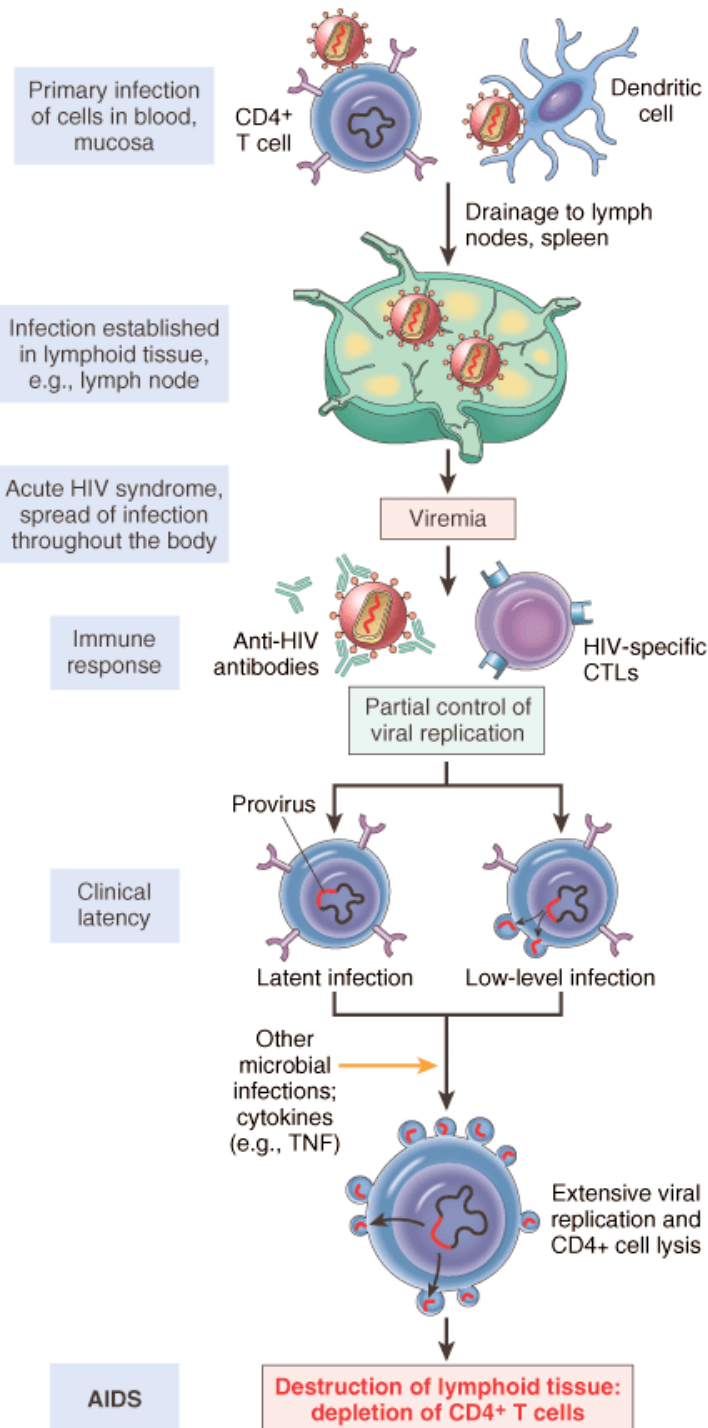
Hoping to understand the process of “reverse” transcription RNA→DNA.  
Reverse transcriptase creates single stranded DNA from a RNA template.







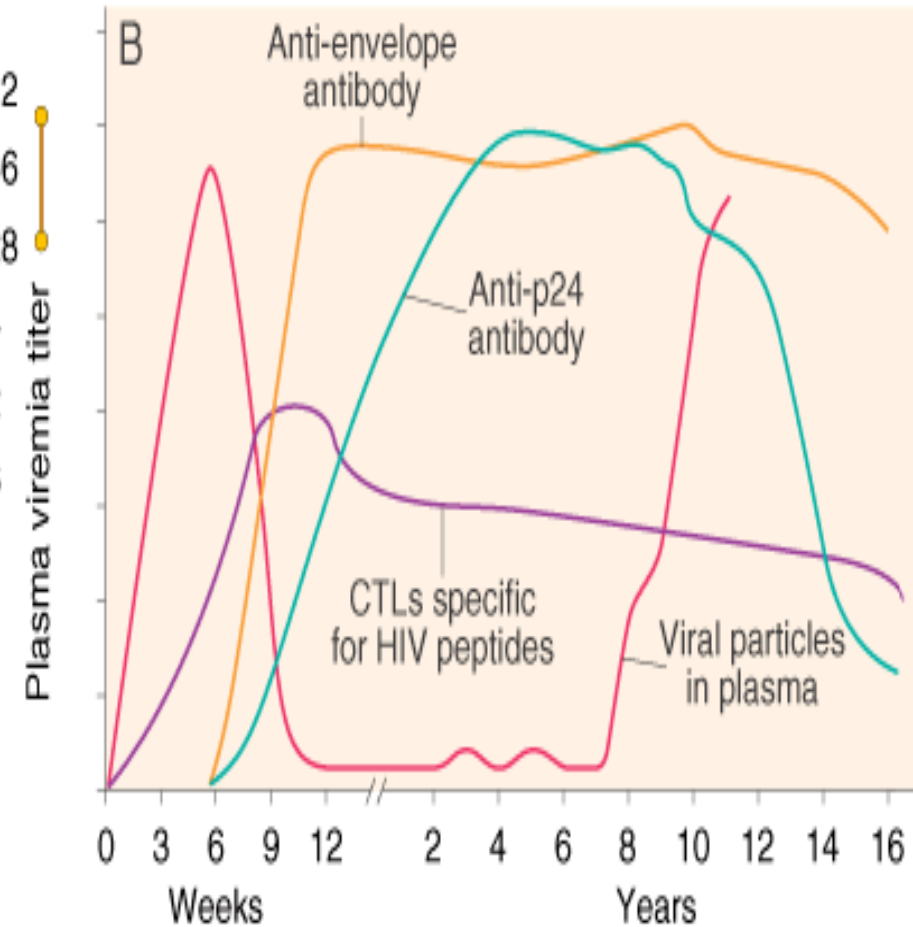
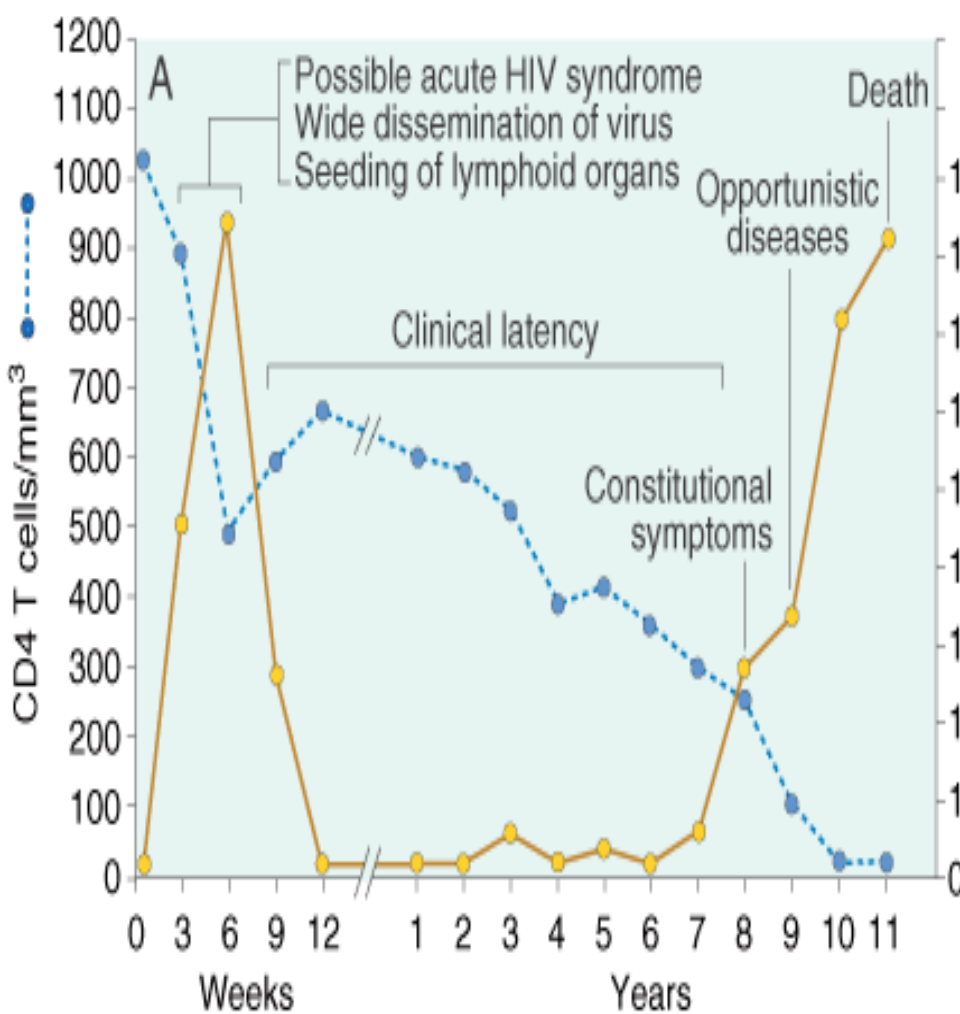
# PATHOGENESIS



- 1) PRIMARY INFECTION
- 2) LYMPHOID INFECTION
- 3) ACUTE SYNDROME
- 4) IMMUNE RESPONSE
- 5) LATENCY
- 6) AIDS

AIDS, rather than HIV infection, is characterized by multiple opportunistic infections. Where in this spectrum would the "HIV" (i.e. antibody) test be positive? When would the viral load (RNA) be the highest?





On the left is plotted CD4 cells and viremia (viral load), on the right are various antibodies.

In general, SURFACE antibodies appear earlier than deeper core antibodies. This is true of most viral illnesses, especially hepatitis.



# GENERAL IMMUNE

## ABNORMALITIES

- LYMPHOPENIA
- DECREASED T-CELL FUNCTION
- B-CELL ACTIVATION,  
POLYCLONAL
- ALTERED  
MONOCYTE/MACROPHAGE  
FUNCTION



# INFECTIONS

- Protozoal/Helminthic: Cryptosporidium, PCP (**P**neumocystis **C**arinii **P**neumonia), Toxoplasmosis
- Fungal: Candida, and the usual 3
- Bacterial: **T**B, Nocardia, Salmonella
- Viral: CMV, HSV, VZ (Herpes Family)

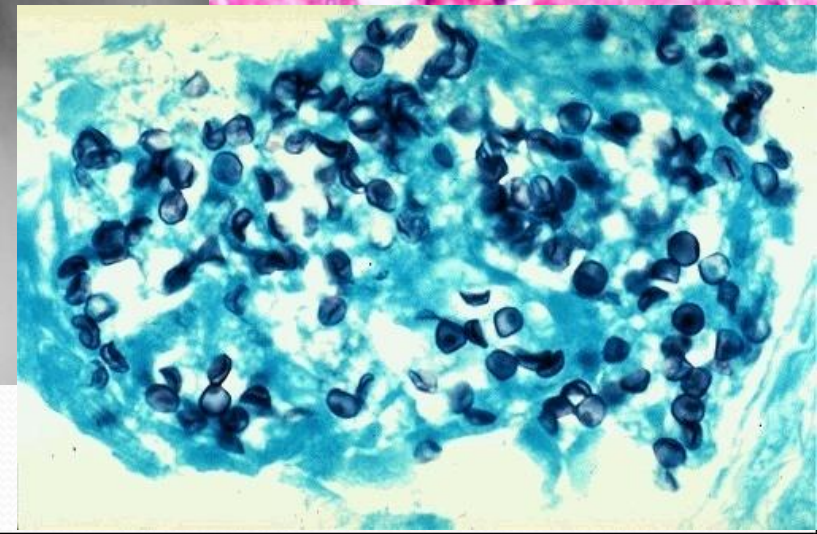
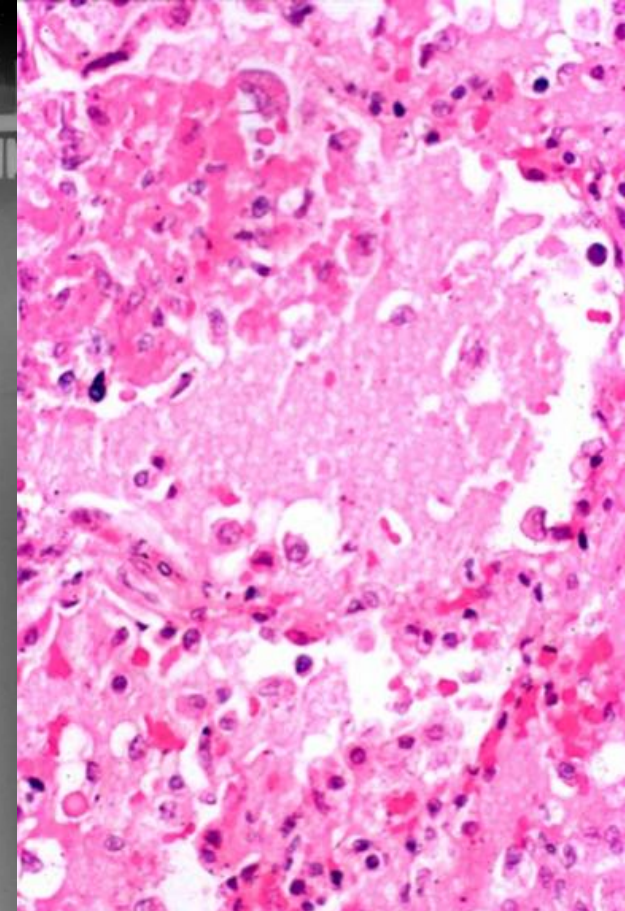
**Cryptosporidium** is a protozoan pathogen of the Phylum Apicomplexa and causes a diarrheal illness called cryptosporidiosis



Note BOTH the radiologists AND the pathologists use the word “WOOLY”. Why?

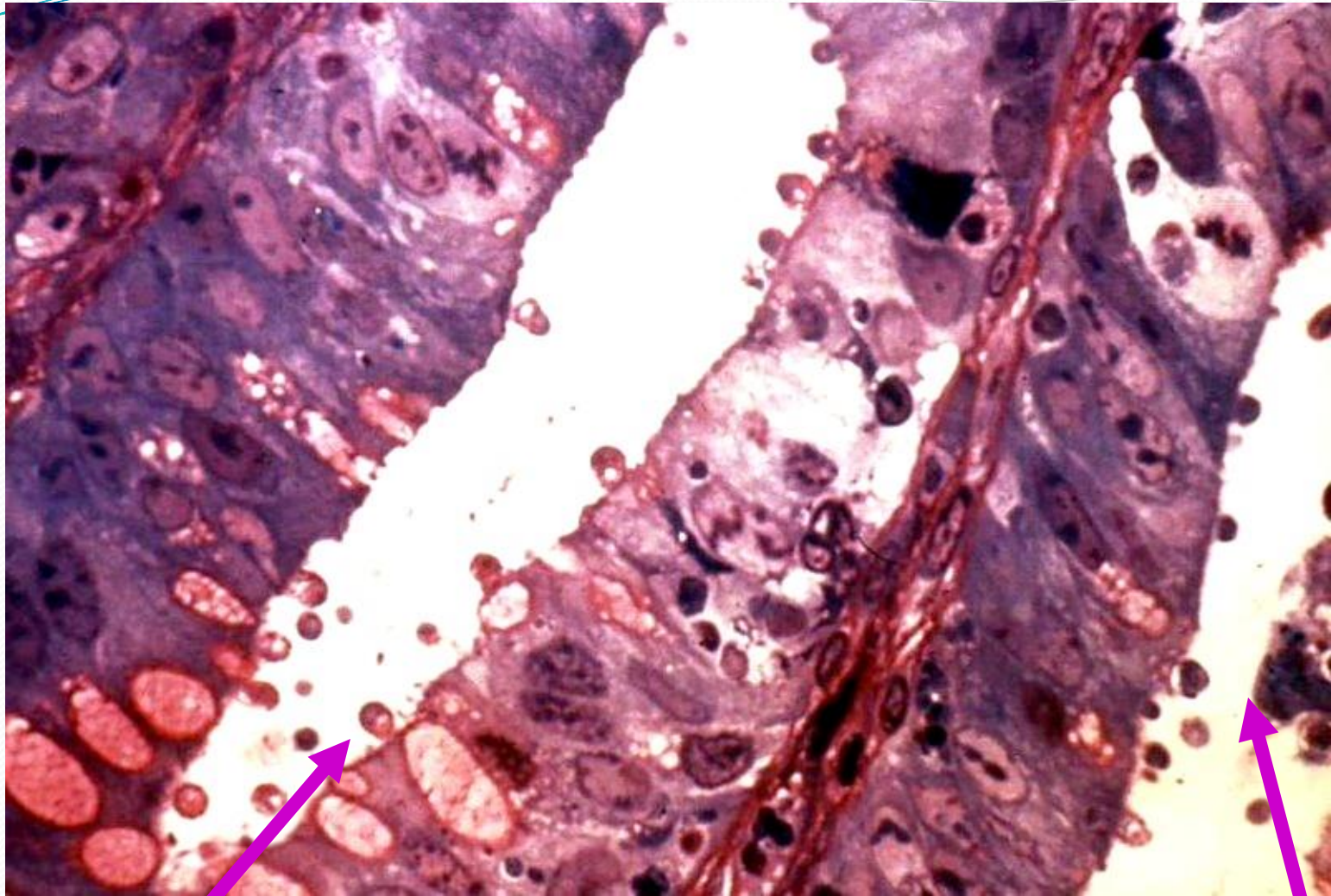
- 1) “Wooly” infiltrates on the chest x-ray, radiologically
- 2) Cotton “wooly” exudates in the alveoli, microscopically

**PCP**



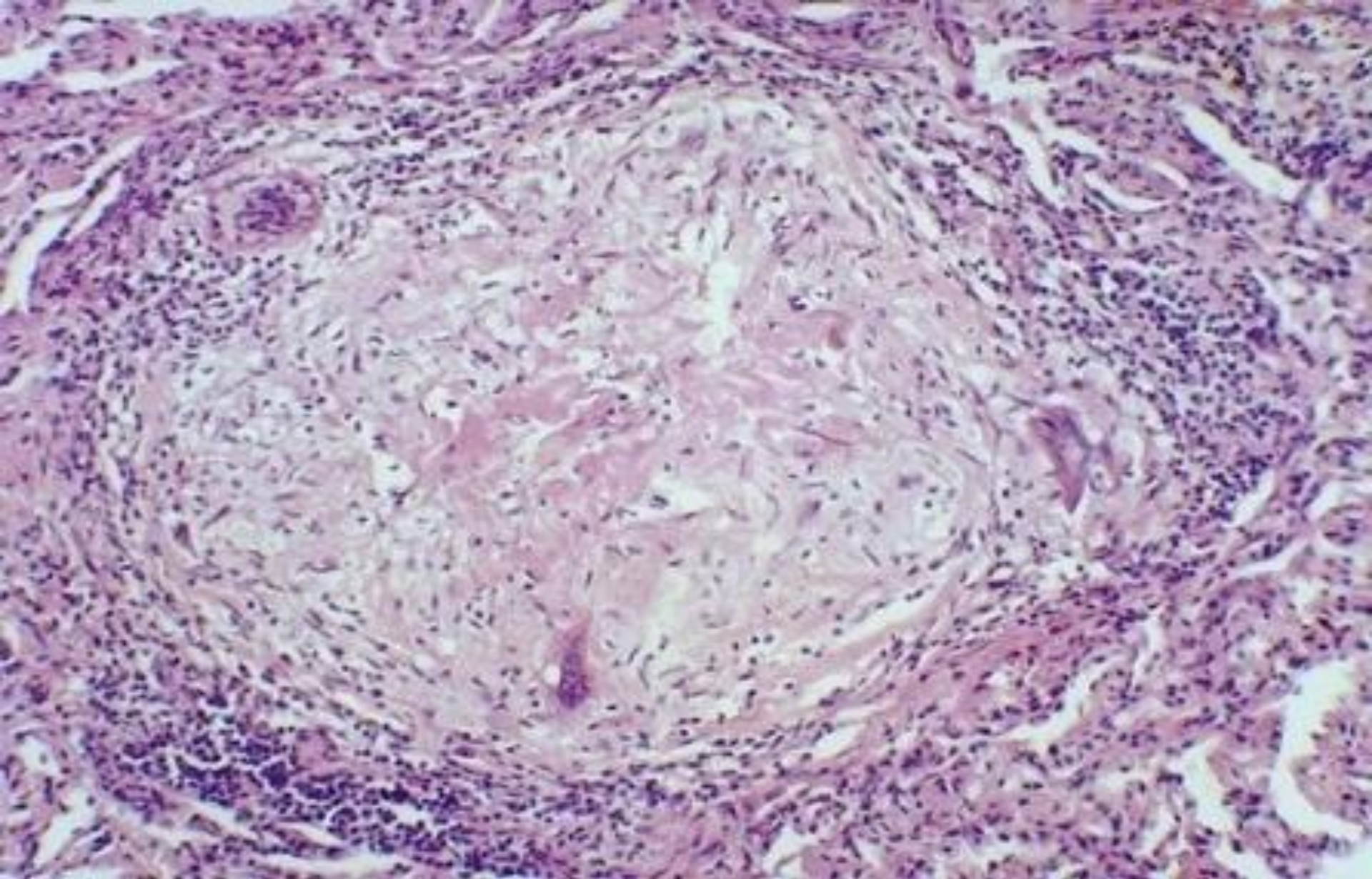


We are all exposed to the protozoan, and can tolerate it. AIDS patients have a much harder time.



**CRYPTOSPORIDIUM**





**CASEATING GRANULOMA**



# CANCERS of AIDS

- **KAPOSI SARCOMA**
- **B-CELL LYMPHOMAS**
- **CNS LYMPHOMAS**
- **CERVIX CANCER,  
SQUAMOUS CELL**



# AMYLOIDOSIS

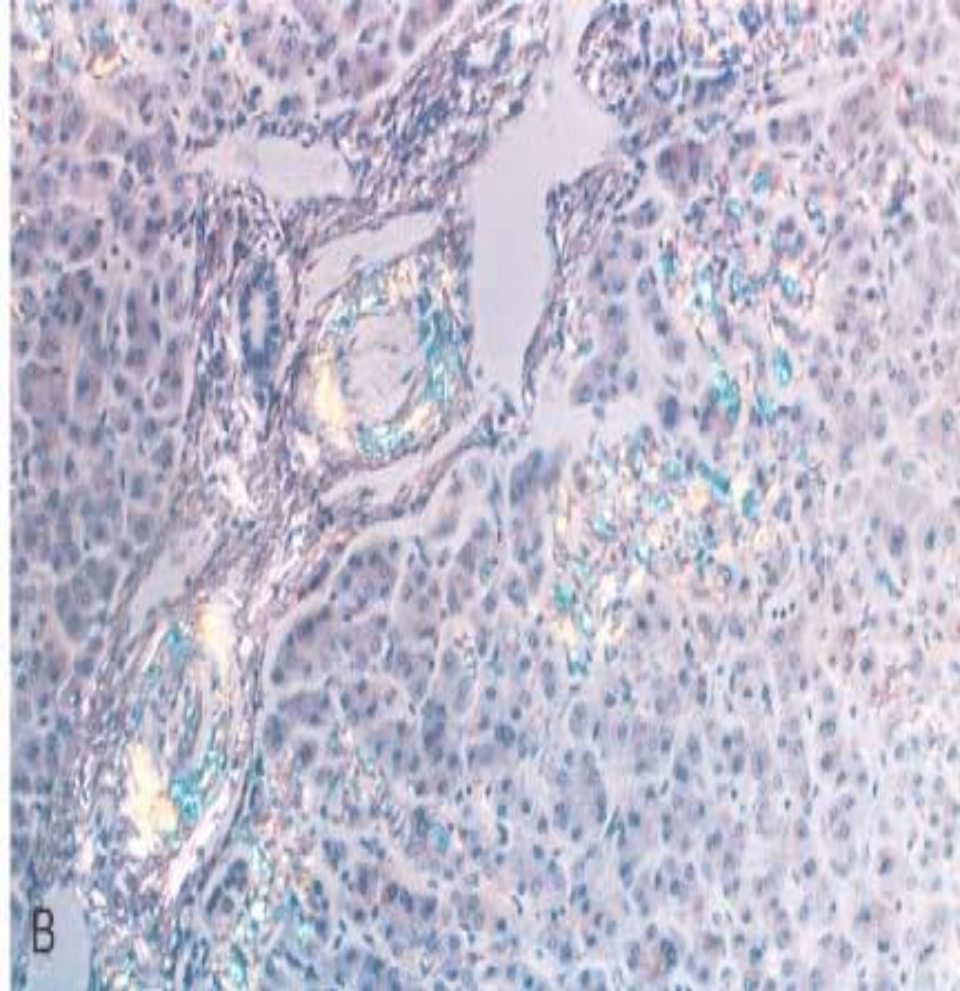
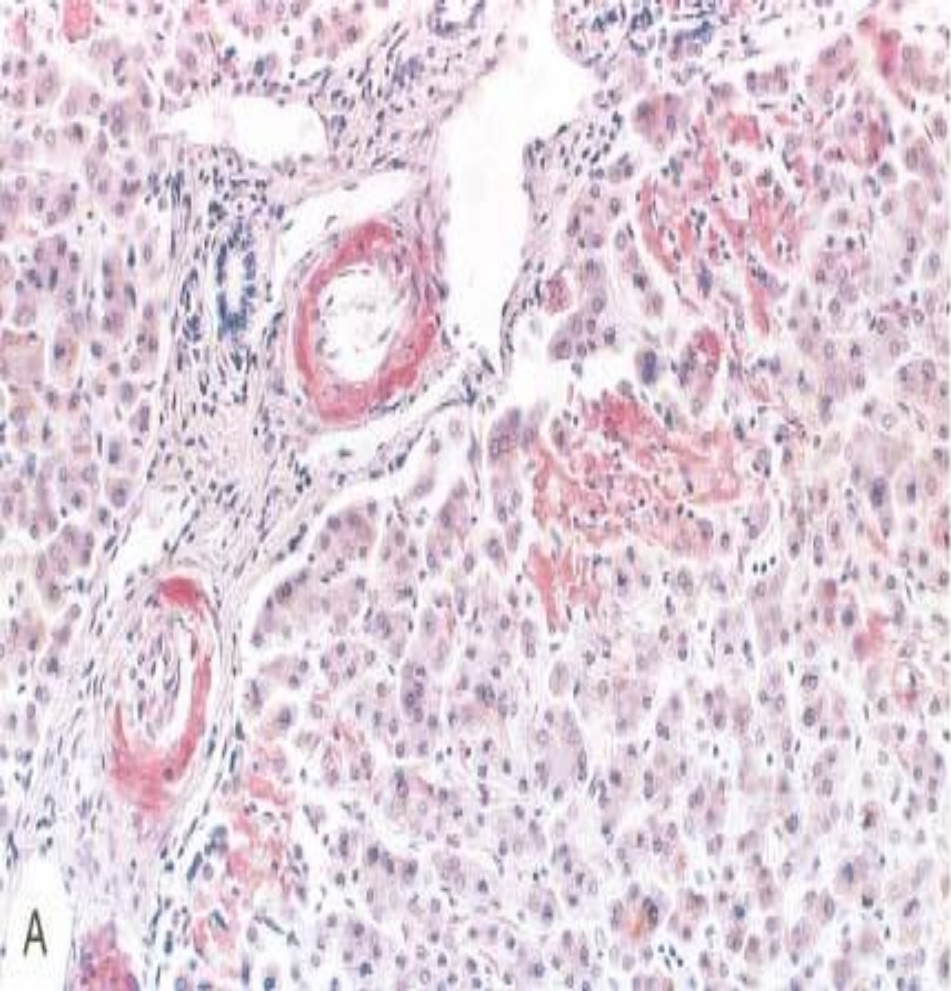
- **BUILDUP OF AMYLOID “PROTEIN”**
  - **AL (Amyloid Light Chain)**
  - **AA (NON-immunoglobulin protein)**
  - **A $\beta$  (Alzheimer’s)**
- **WHERE? BLOOD VESSEL WALLS, at first**
  - **KIDNEY**
  - **SPLEEN**
  - **LIVER**
  - **HEART**

Why is amyloid called amyloid? Because in the early days, it took up STARCH stains applied to GROSS specimens, e.g., IODINE stains.

But of course now we know it’s a PROTEIN, chiefly immunoglobulin protein chronic buildup.

It is therefore not surprising that diseases which have chronic immunoglobulin buildup over many years are associated with amyloidosis, i.e., multiple myeloma (also called plasma cell “dyscrasias”), granulomatous diseases, classically.





**CONGO RED STAIN, WITHOUT,  
and WITH, POLARIZATION**



# AMYLOID ASSOCIATIONS

- PLASMA CELL “DYSCRASIAS”, i.e., MULTIPLE MYELOMA
- CHRONIC GRANULOMATOUS DISEASE, e.g., TB
- HEMODIALYSIS
- HEREDOFAMILIAL
- LOCALIZED
- ENDOCRINE MEAs (Multiple Endocrine Adenomas)
- AGING

Diseases in which there is a cumulative buildup of immunoglobulin would be a setting for amyloidosis, so myelomas and chronic granulomatous diseases are at the top of the list.