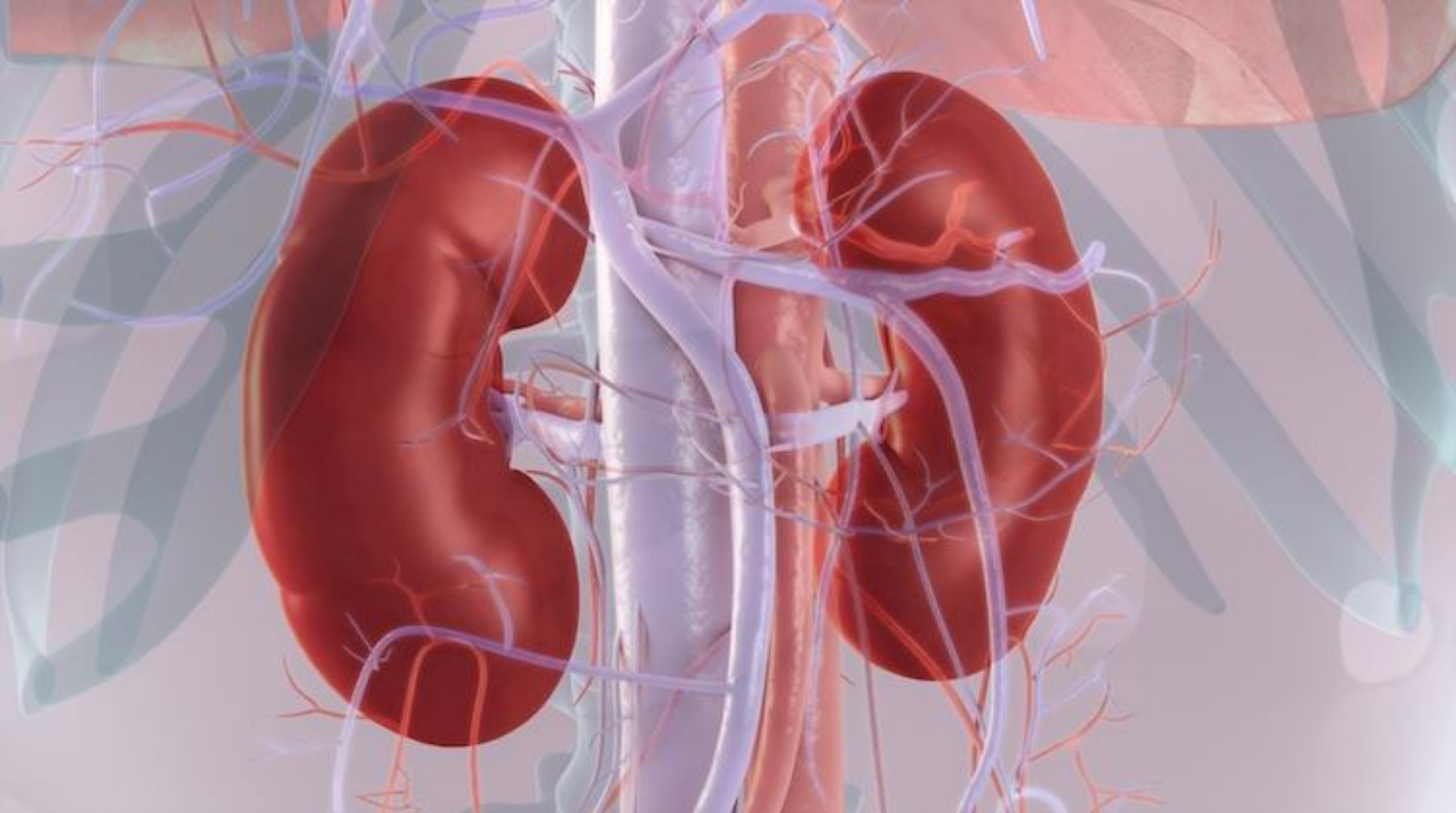

**Kidney disorders.**

## Kidney disorders.

### ***I. Microspecimens:***

#### **№ 70. Rapidly progressive (crescentic) glomerulonephritis. (H-E. stain).**

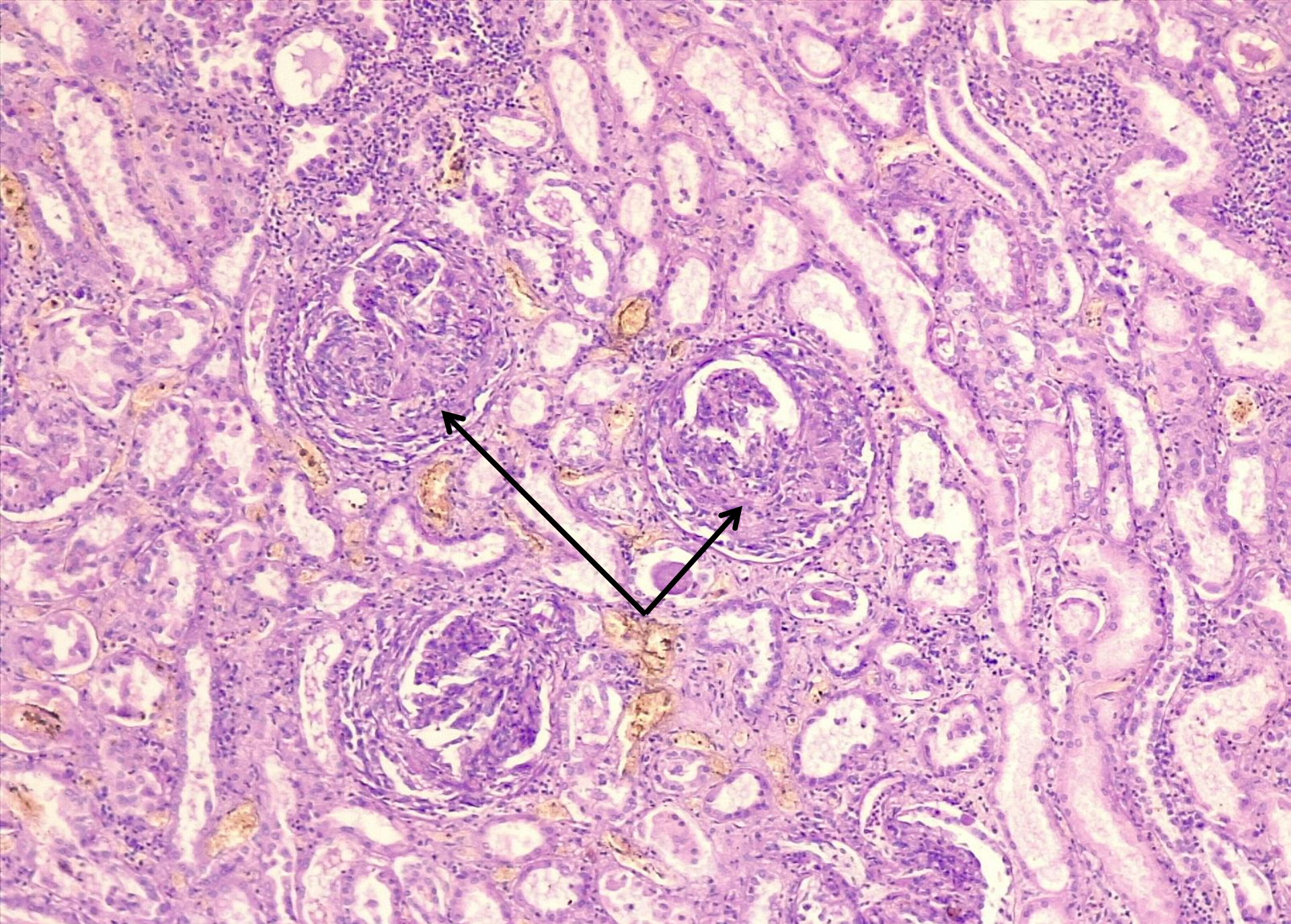
#### **Indications:**

1. Focal necrosis, proliferation of endothelial and glomerular mesangium.
2. Proliferation of parietal cells of capsule in shape of crescent.
3. Deposits of fibrin in the glomeruli.

In microspecimen, glomeruli are observed surrounded by thickening in shape of "crescent" of the outer parietal layer of glomerular capsule, which compresses the glomeruli, stenoses and obliterates the Bowman space (urinary space). In the crescent may be macrophages and fibrin. Some glomeruli are enlarged in size, with increased cellularity due to proliferation of endothelium and mesangiocytes with foci of necrosis, others are atrophied, deformed, with hyalinosis foci. In interstitium, dilation and hyperemia of the vessels, bleeding and lymphoid infiltration is observed. The tubules are not affected or may have signs of hyaline degeneration of the nephrocytes, in their lumen, protein cylinders.

*The crescents appear by proliferation of squamous epithelial cells of the parietal layer of the glomerular capsule, migration of monocytes/macrophages, neutrophilic leukocytes and fibrin exudation into the capsule space. Rapid growth and fibrosis of the crescents lead to complete filling of the urinary space, the respective nephron becoming dysfunctional. Because this form of glomerulonephritis is bilateral, diffuse, with 80% involvement of glomeruli, renal failure (in a few weeks or months) is rapidly established, and morphologically glomerulosclerosis and glomerulohyalinosis, tubal atrophy and progressive progressive kidney shrinkage develop.*

*Clinically manifested by nephritic syndrome: hematuria, proteinuria, cylindruria, oliguria, edema and hypertension. It is a clinical syndrome, which complicates different systemic diseases, and in many cases the origin is unknown (idiopathic glomerulonephritis). The predominant pathogenetic mechanism is the immune one, which can be of 3 types: type I - with anti-glomerular basement membrane (anti-GBM) antibodies (12% of cases), e.g. in Goodpasture syndrome, type 2 - with immune complexes (44% of cases), eg in systemic lupus erythematosus, some cases of poststreptococcal glomerulonephritis and type III - pauci immune type with anti-neutrophil cytoplasmic antibodies (ANCA) (44% of cases), e.g. in some systemic vasculitis. Complications: acute or chronic renal failure, cardiovascular failure, cerebral hemorrhage.*



**№ 70. Rapidly progressive (crescentic) glomerulonephritis. (H-E. stain).**

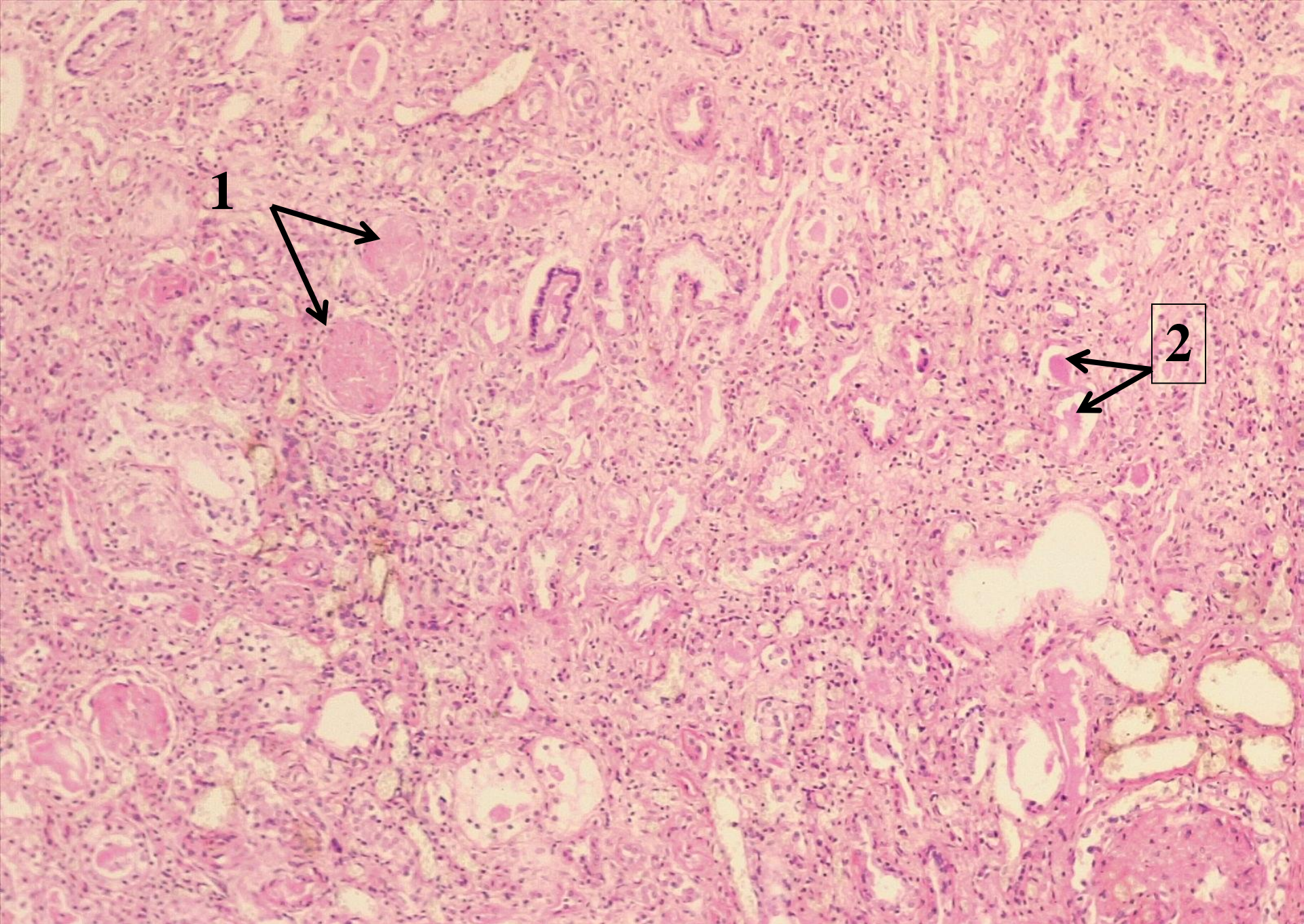
**№ 71. Chronic glomerulonephritis. (H-E. stain).**

**Indications:**

1. Atrophied glomeruli with sclerosis, hyalinosis and obliteration of capsule.
2. Proteic degeneration of tubules epithelium.
3. Dilated tubules with atrophied epithelium and proteic masses within lumen.

In microspecimen, atrophy, sclerosis and hyalinosis of the glomeruli it is noticed, some of them are substituted with connective tissue, being transformed into small scars (glomerulosclerosis), others look like hyaline spheres of homogeneously eosinophilic color (glomerulohyalinosis), the capsule is obliterated; most of the tubules are atrophied, some have the dilated lumen, the epithelium is flattened, in nephrocytes hyaline degeneration, in the lumen hyaline cylinders is observed. In the stroma interstitial fibrosis and mild lymphocytic inflammatory infiltrate is observed, arterioles are sclerosed and hyalinized, in the arteries of small and medium caliber fibrosis and intimal hyalinosis is noticed.

*Chronic glomerulonephritis evolves slowly over many years and ends with diffuse nephrosclerosis and granular shrinkage of kidney. The predominant pathogenetic mechanism is related to circulating immune complexes. It is the most common cause of chronic renal failure with azotemia and uremia. Other complications - cardiovascular failure and cerebral hemorrhage.*



**№ 71. Chronic glomerulonephritis. (H-E. stain).**

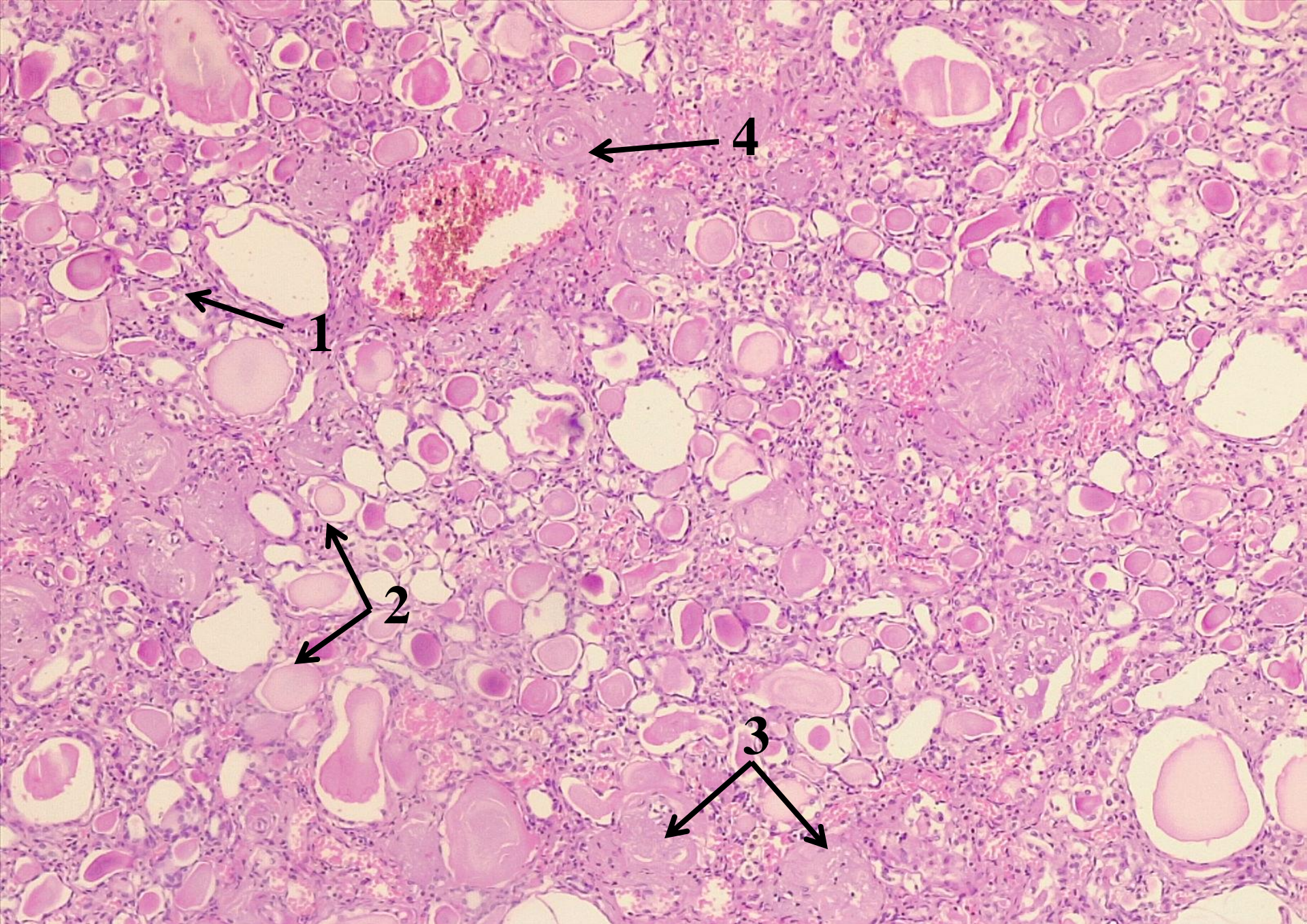
**№ 152. Chronic pyelonephritis. (H-E. stain).**

**Indications:**

1. Inflammatory cell infiltration into the stroma of the kidney (interstitial tissue).
2. Colloidal proteic masses within the dilated tubule lumen ("thyroidization").
3. Sclerosis of glomeruli.
4. Sclerosis of small and medium caliber arteries.

In stroma of the kidney moderate lymphocytic infiltration, foci of interstitial fibrosis, sclerosis and hyalinosis of some glomeruli, arteriolosclerosis and arteriolo-hyalinosis, sclerosis of small and medium arteries are noticed. Tubules are dilated, the epithelium is flattened, in their lumen are hyaline cylinders of homogeneous eosinophilic color, which resemble with colloid of thyroid follicles (thyroidization (thyroid-like appearance)).

*Chronic pyelonephritis is an infectious tubulointerstitial nephritis - the cause of 2-3% of all cases of chronic renal failure. There are two variants of chronic pyelonephritis: pyelonephritis associated with vesicoureteral reflux and obstructive pyelonephritis. In both forms a decisive role is played by urinary tract infection. Chronic pyelonephritis results in nephrosclerosis, macronodular shrinkage of kidney and chronic renal failure with azotemia and uremia. Other complications are related to nephrogenic hypertension: cardiovascular failure, myocardial infarction and cerebral hemorrhage.*



**№ 152. Chronic pyelonephritis. (H-E. stain).**

**№ 49. Clear cell renal cell carcinoma. (CCRCC). (H-E. stain).**

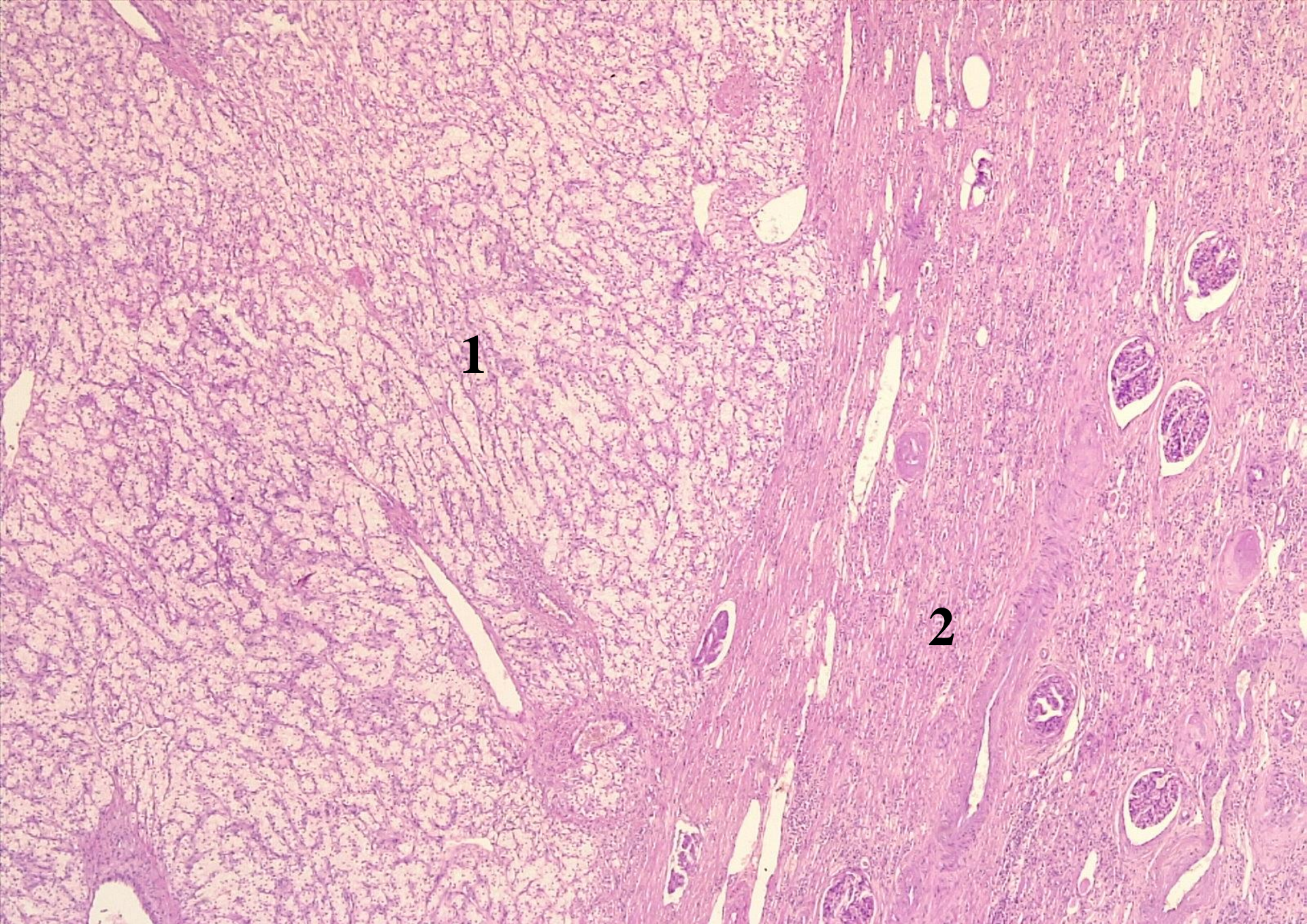
**Indications:**

1. Tumoral nodule:
  - a. cancerous cells with clear cytoplasm;
  - b. tumoral stroma with thin layers of connective tissue;
  - c. blood vessels with thinned walls.
2. Unchanged renal tissue.

In microspecimen is a well-defined tumor node, consisting of large, polygonal cells with clear cytoplasm (they contain lipids and glycogen, which dissolve in the process of histological processing of tissue fragments), arranged in alveolar, lobular or tubular pattern, separated by fine connective tissue septa, nuclei are small and round, peritumoral renal tissue is unchanged or slightly sclerosed.

*Clear cell carcinoma is the most common form of renal carcinoma (65%). It is located in the renal cortex and develops from the tubular epithelium.*





**№ 49. Clear cell renal cell carcinoma. (CCRCC). (H-E. stain).**

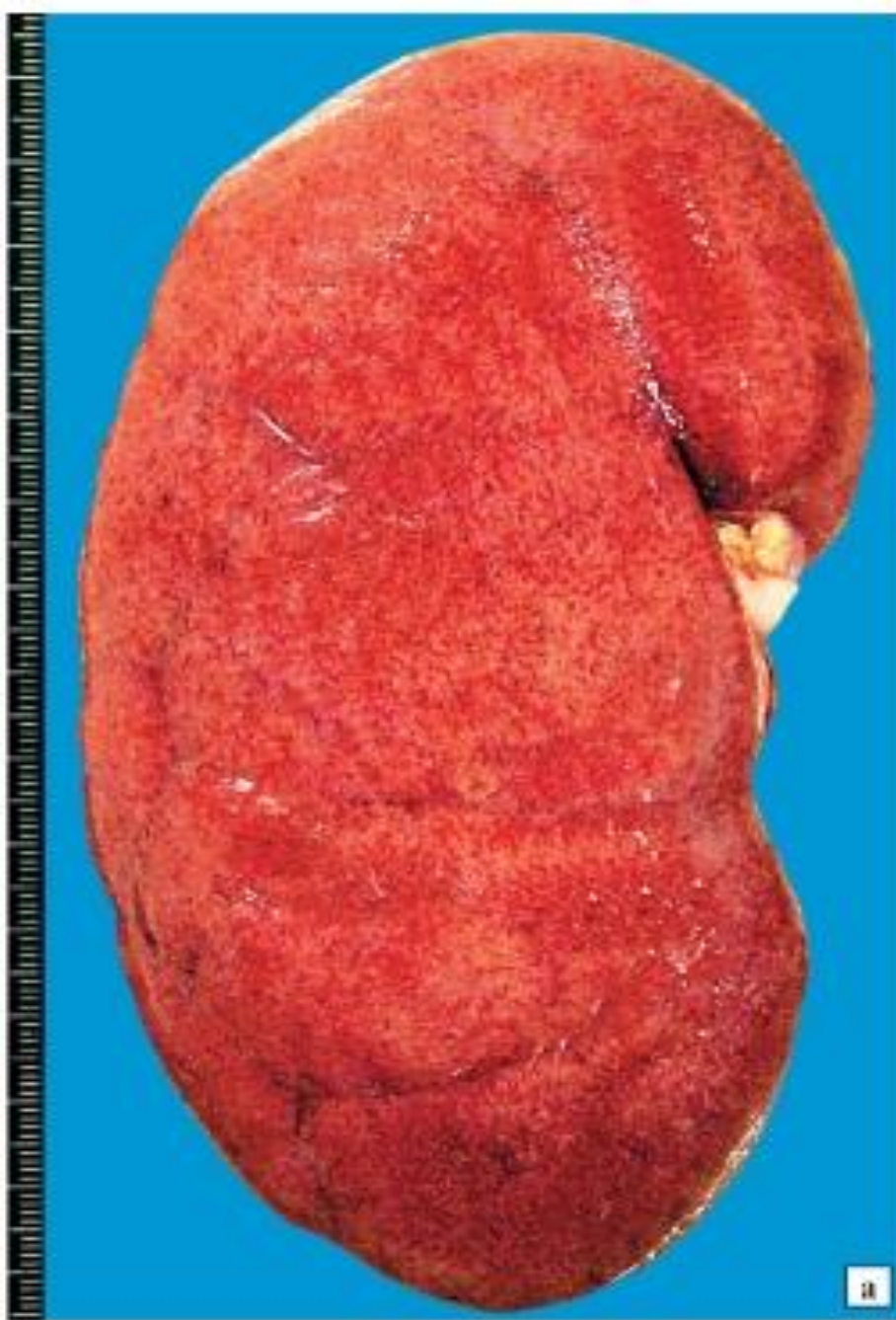
## ***II. Macrospecimens:***

### **№ 81. Acute glomerulonephritis.**

The kidney is enlarged in size, the capsule extended, the outer surface is with multiple punctiform haemorrhages ("flea bites"), on section cortex is well-delimited, swollen, opaque, gray-yellow, with multiple red dots, medullary layer is hyperemic of red dark color - "large mottled kidney".

*The most common cause of acute glomerulonephritis (in 90% of cases) is group A  $\beta$ -hemolytic streptococcus. It usually starts in 1-4 weeks after angina or skin infection, caused by a "nephritogenic" streptococcal strain. The immune mechanism consists of the storage of immune complexes on the subepithelial surface of the basement membranes of the glomerular capillaries, the immune complexes being composed of IgG, streptococcal proteins (antigen) and complement. In immunofluorescence and electron microscopy, the deposits of immune complexes have a granular appearance. Optical microscopy determines the increased cellularity of glomeruli, caused by proliferation of endotheliocytes and mesangiocytes and infiltration with neutrophilic and monocytic leukocytes. Clinically, it is manifested by nephritic syndrome: hematuria, proteinuria, edema and hypertension.*

*Consequences: in children - complete restoration in 90-95% of cases; in adults: a) complete restoration in 60% of cases, b) in 3-5% of patients, rapidly progressive glomerulonephritis develops and c) in 30% of patients, proteinuria, hematuria and hypertension are maintained for a long time.*



**№ 81. Acute glomerulonephritis.**

## **№ 82. Renal amyloidosis.**

The kidney is enlarged in size of dense consistency, gray yellowish color and lardy or waxy appearance, the surface is slightly wavy, on section layers are poorly delimited - "big white amyloidic kidney".

*Renal amyloidosis (amyloid nephropathy) is found in both primary amyloidosis, e.g., multiple myeloma (AL amyloidosis) and secondary amyloidosis, eg, purulent osteomyelitis, tuberculosis, bronchiectasis, rheumatoid arthritis (AA amyloidosis).*

*Clinically manifested by nephrotic syndrome: massive proteinuria (more than 3.5 g in 24 hours, hypoalbuminemia, generalized edema, hyperlipidemia and lipiduria, azotemia, hypertension (in 50% of cases).*

*Complications: renal failure, association of infections due to decreased immunity, cardiovascular insufficiency, predisposition to thrombosis of vessels due to loss with urine of immunoglobulins and anticoagulant system proteins.*

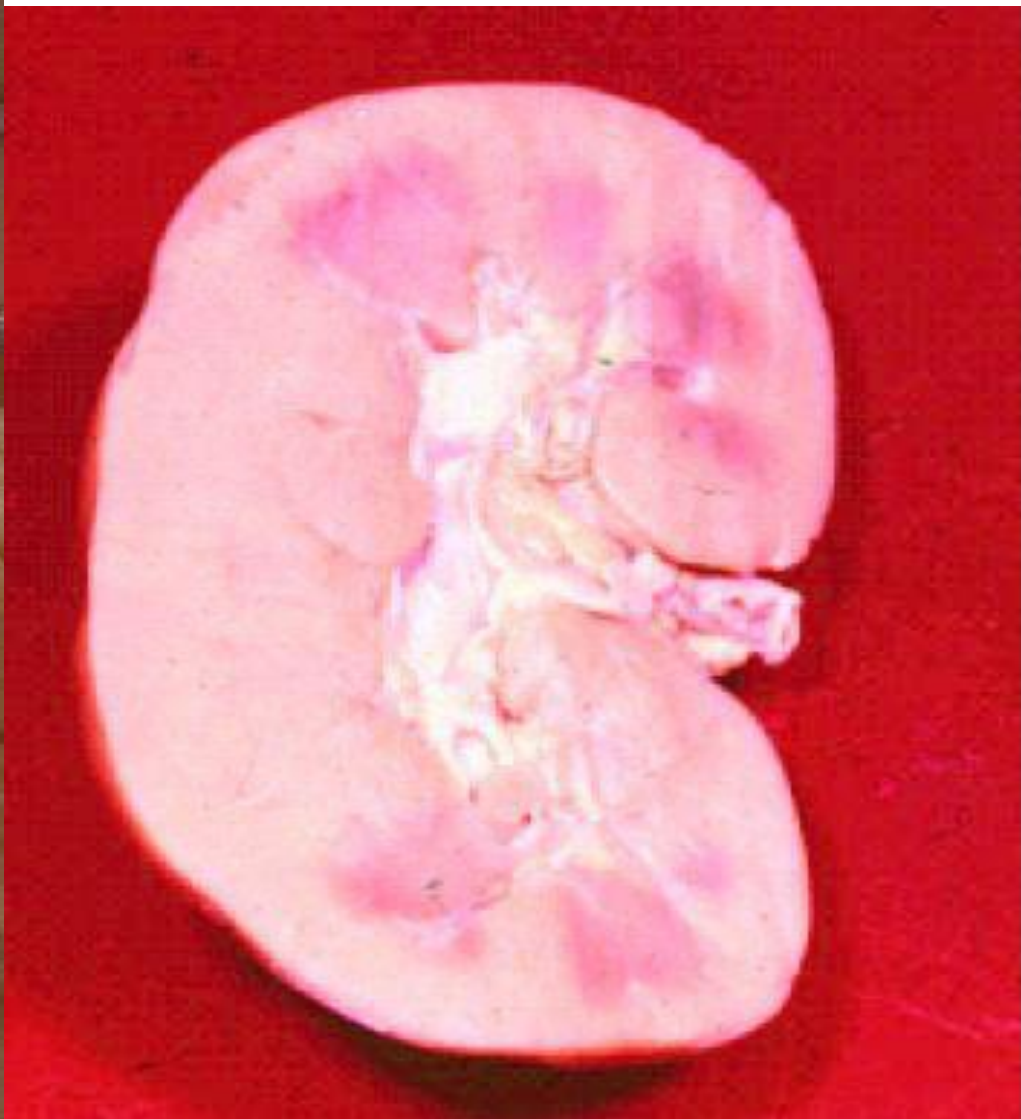## **№ 83. Wrinkled kidney.**

The kidney is decreased in size with granular / nodular surface, of dense consistency, gray-whitish color, on section macroscopic picture is erased.

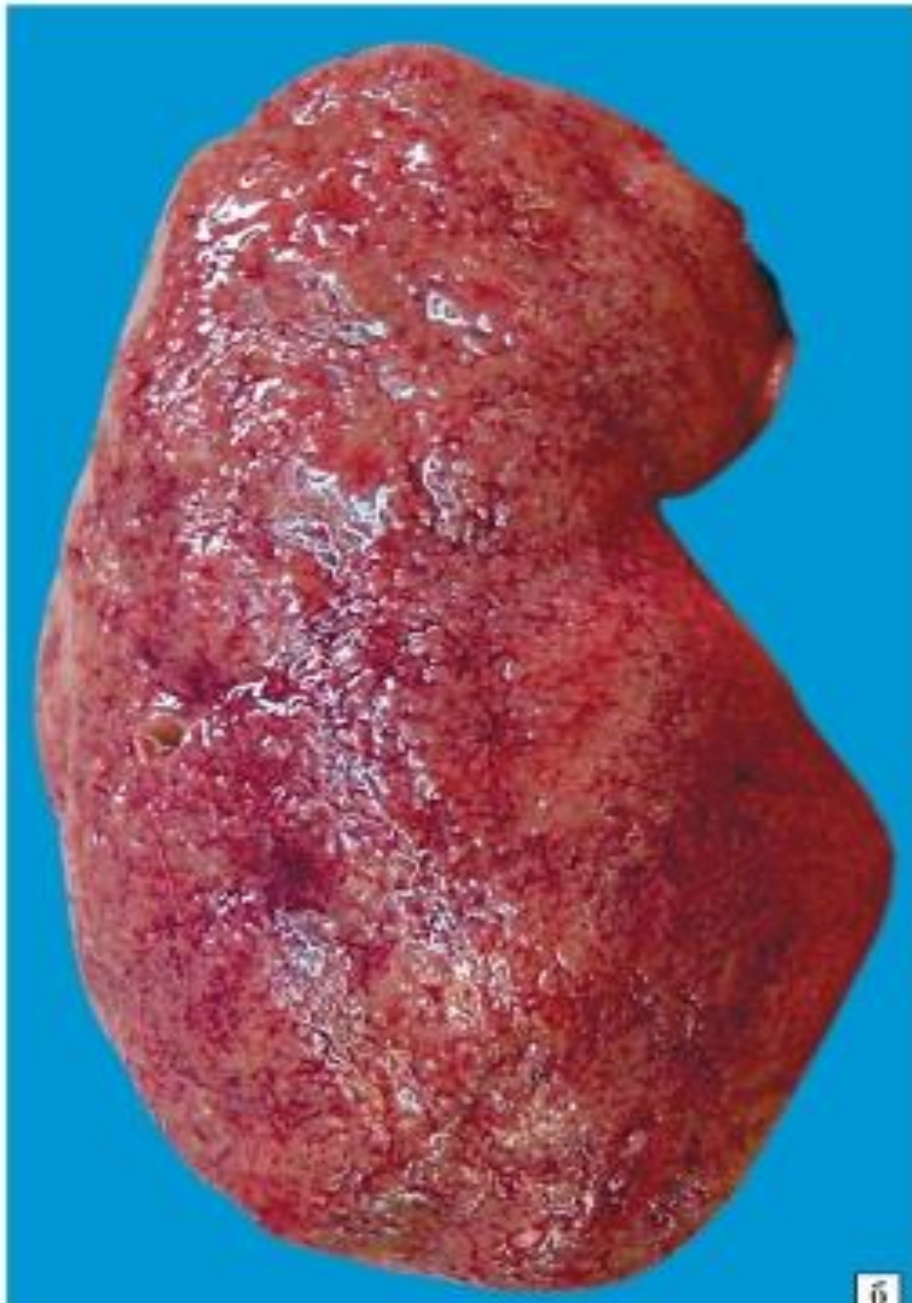*Shrinkage of kidney - nephrosclerosis - is observed both in renal disorders, eg, glomerulonephritis, renal amyloidosis, pyelonephritis, nephrolithiasis, tuberculosis, renal infarctions (so-called secondary nephrosclerosis), as well as in cardiovascular diseases, eg, atherosclerosis and hypertension (so-called primary nephrosclerosis). In kidney, atrophy of the parenchyma occurs, excessive proliferation of connective tissue and structural remodeling.*

*The exterior appearance of wrinkled kidneys is different depending on the process, which triggered nephrosclerosis: in hypertension and glomerulonephritis it is granular (micronodular), and in atherosclerosis, pyelonephritis, tuberculosis, amyloidosis, renal infarcts - macronodular.*

*Nephrosclerosis leads to progressive chronic renal failure.*



**№ 82. Renal amyloidosis.**



**№ 83. Wrinkled kidney.**

## № 87. Renal stones.

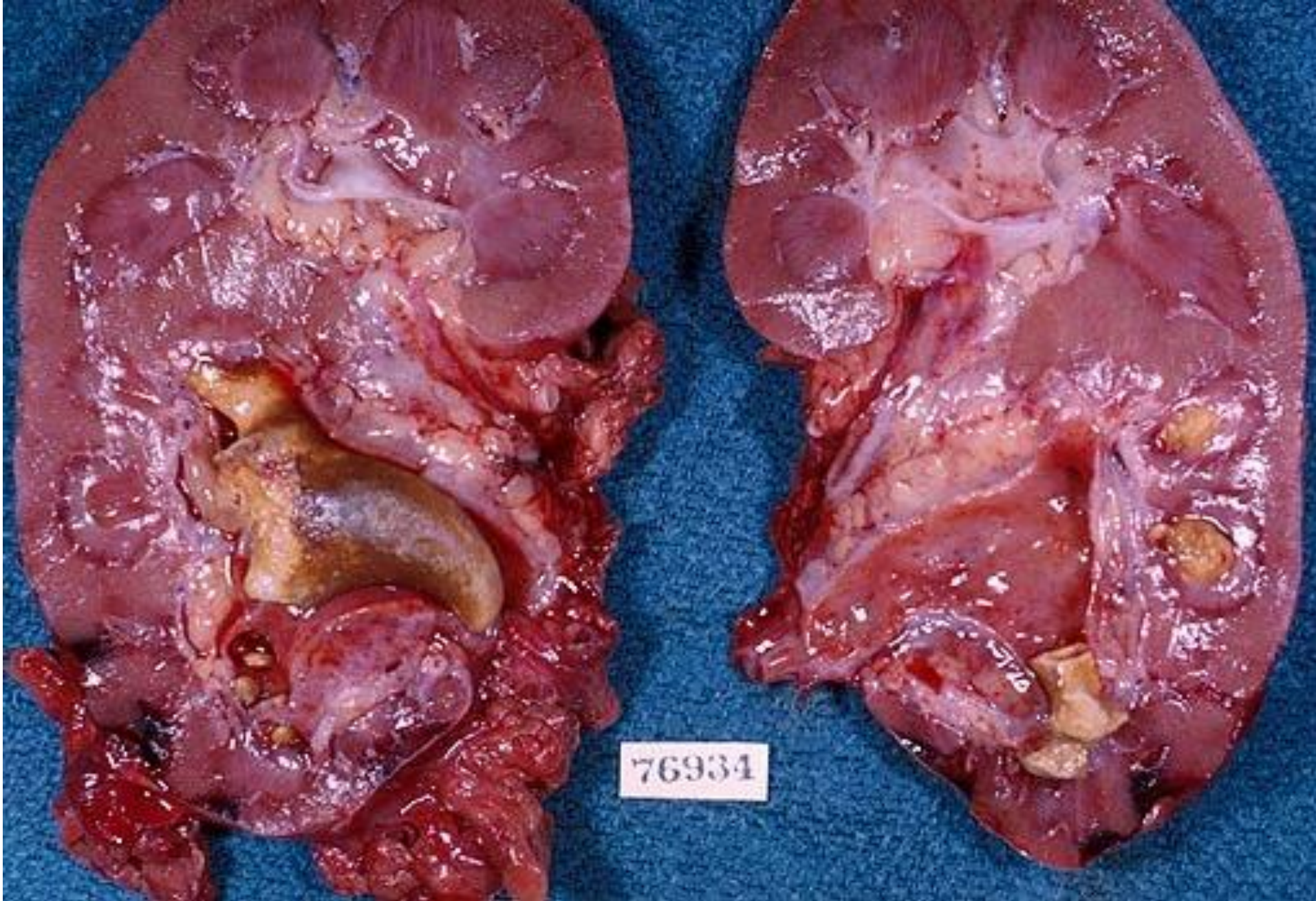
The renal pelvis and calyces are dilated, they contain multiple calculi, some are free, others - attached to pelvic and calyceal wall, the dimensions are from 2-3 mm to 1-2 cm, surface is smooth or irregular, rough, sometimes with branches, which takes shape of pelvis and calyces - coraliform calculi have white, yellow or brown color depending on the chemical composition.

*There are 3 main types of urinary calculi:*

*a) calcium calculi (calcium oxalates and phosphates), observed in ~ 75% of cases, have a granular-rough surface, brown color due to hemosiderin, which appears as a result of trauma of mucosa and repeated bleeding;*

*b) mixed calculi, so-called "struvite calculi" or "triple phosphates", consisting of magnesium ammonium phosphate; occur in ~ 15% of cases, especially in patients with urinary tract infections (Proteus vulgaris, Klebsiella, Staphylococcus); bacteria produce proteases, which cleave urea (infection-induced calculations); have a yellowish-white color;*

*c) uric acid calculi (urates) - appear as a result of hyperuricemia and hyperuricuria, which is observed in cases of primary or secondary gout in myeloproliferative diseases (eg, in leukemias), have a yellow-gray color. Complications: pyelonephritis, nephrosclerosis, macronodular shrinkage of kidney - if the process is bilateral - progressive chronic renal failure.*



76934

№ 87. Renal stones.



## **№ 88. Hydronephrosis.**

The kidney is enlarged in size, on section pelvis and calyces are dilated with sclerosed, whitish mucosa, parenchyma is atrophied, pyramids and the papillae are flattened.

*The most common causes:*

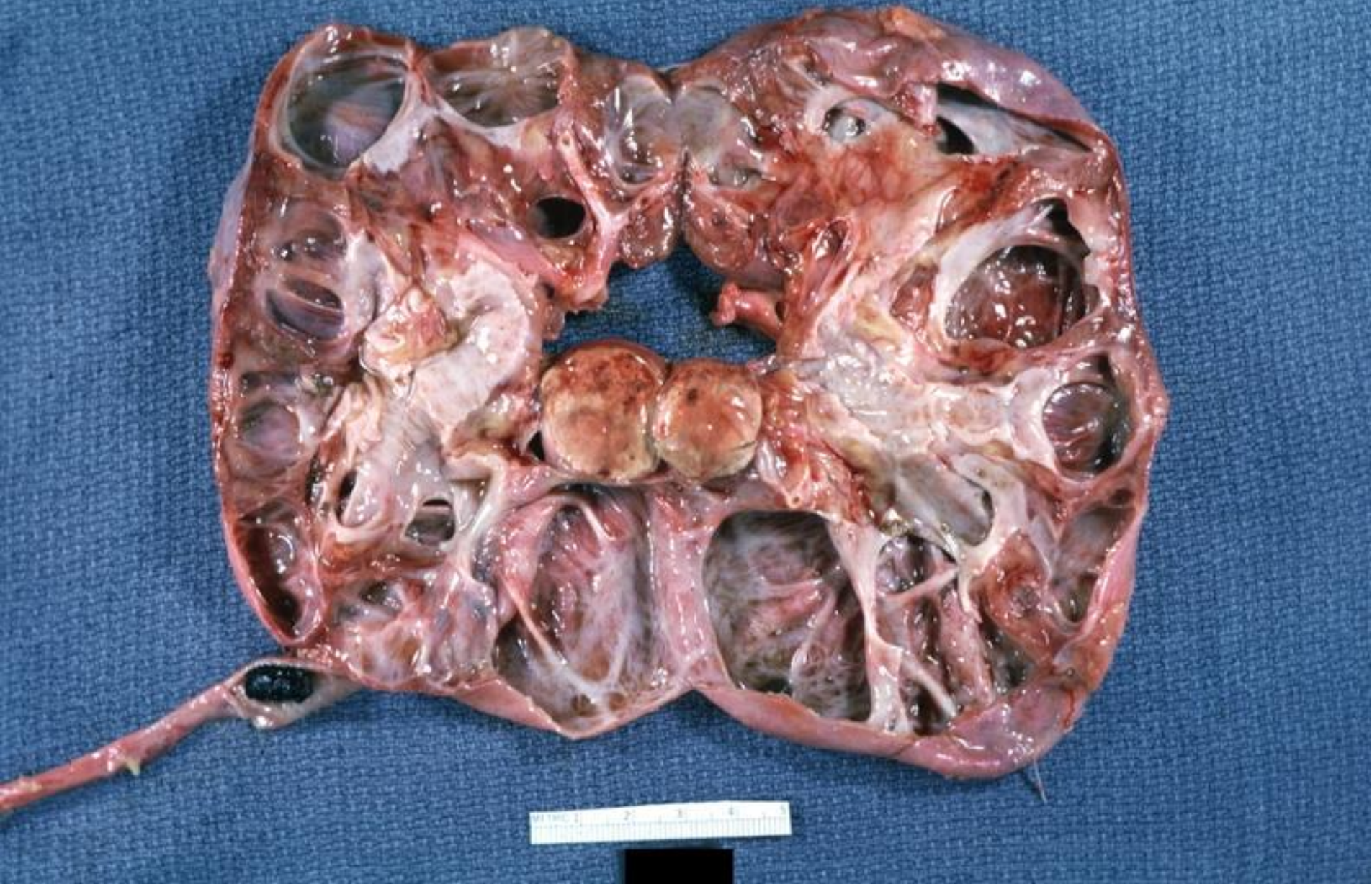- unilateral hydronephrosis: calculi, atresia, inflammatory strictures, tumors of the ureter, tumors of the urinary bladder or adjacent organs (uterine cervix, rectum, lymph nodes), retroperitoneal fibrosis;*
- bilateral hydronephrosis: atresia of ureter, bilateral pelvic / ureteral calculosis, urinary bladder and prostate carcinomas, prostatitis, stricture of the urethra.*

*Unilateral hydronephrosis leads to atrophy, nephrosclerosis and shrinkage of affected kidney and compensatory hyperplasia of the contralateral kidney, and bilateral hydronephrosis - kidney atrophy and sclerosis with progressive chronic renal failure.*

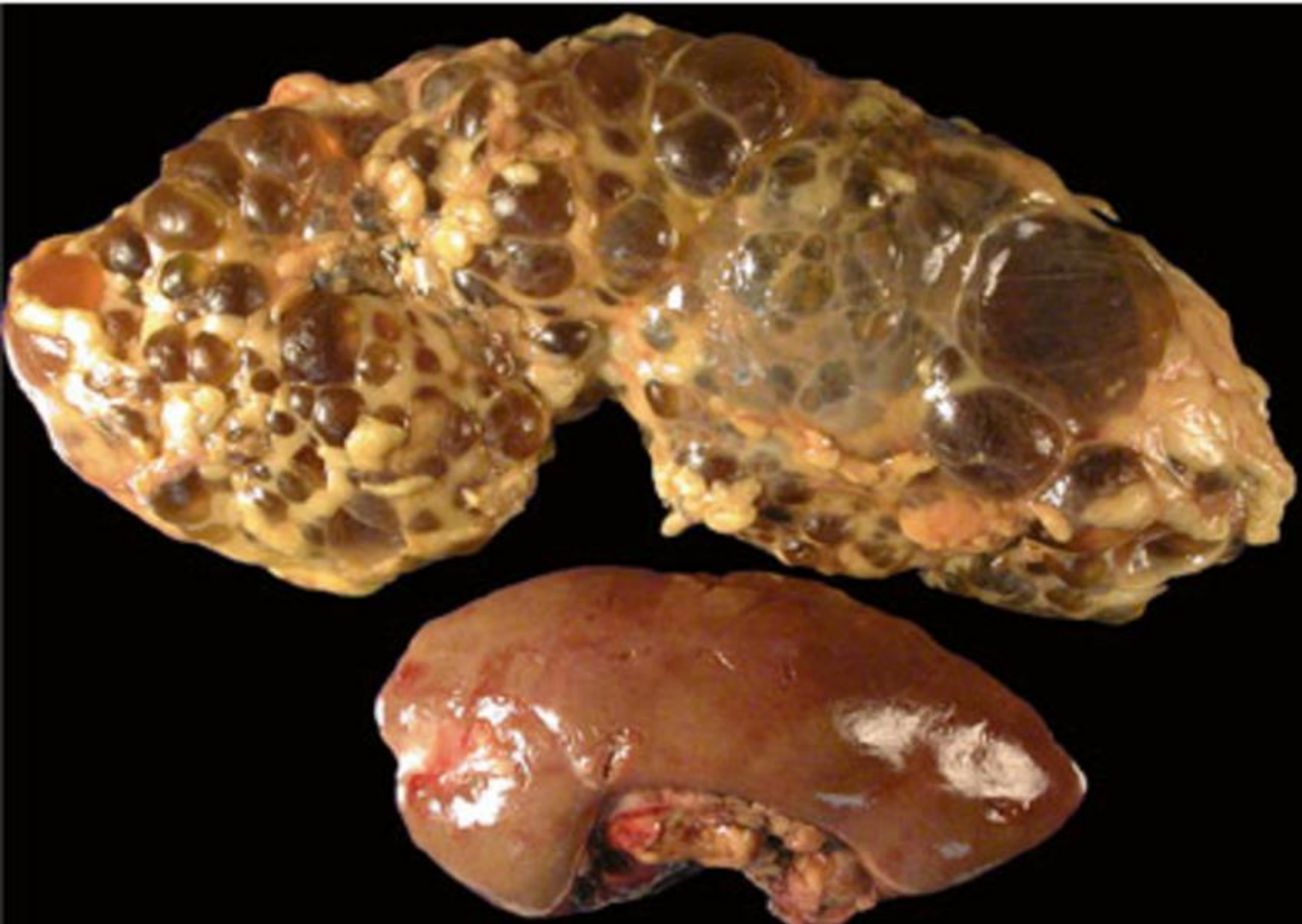## **№ 86. Polycystic kidney.**

The kidney has a large mass, consisting of round and oval cysts, with variable dimensions from 0.5 cm to 3-4 cm, thin walls, smooth internal surface and clear content, between cysts renal parenchyma is atrophic or even absent.

*It is the morphological substrate of adult polycystic kidney disease - a disorder with autosomal dominant transmission. It has an incidence of 1 in 500-1000 people and constitutes ~ 10% of the cases of chronic kidney disease. Cysts can form at any level of the nephron. In some cases it is associated with liver and pancreatic cysts. Complications: chronic renal failure, urinary tract infections (pyelonephritis), hypertension (cerebral hemorrhages).*



**№ 88. Hydronephrosis.**



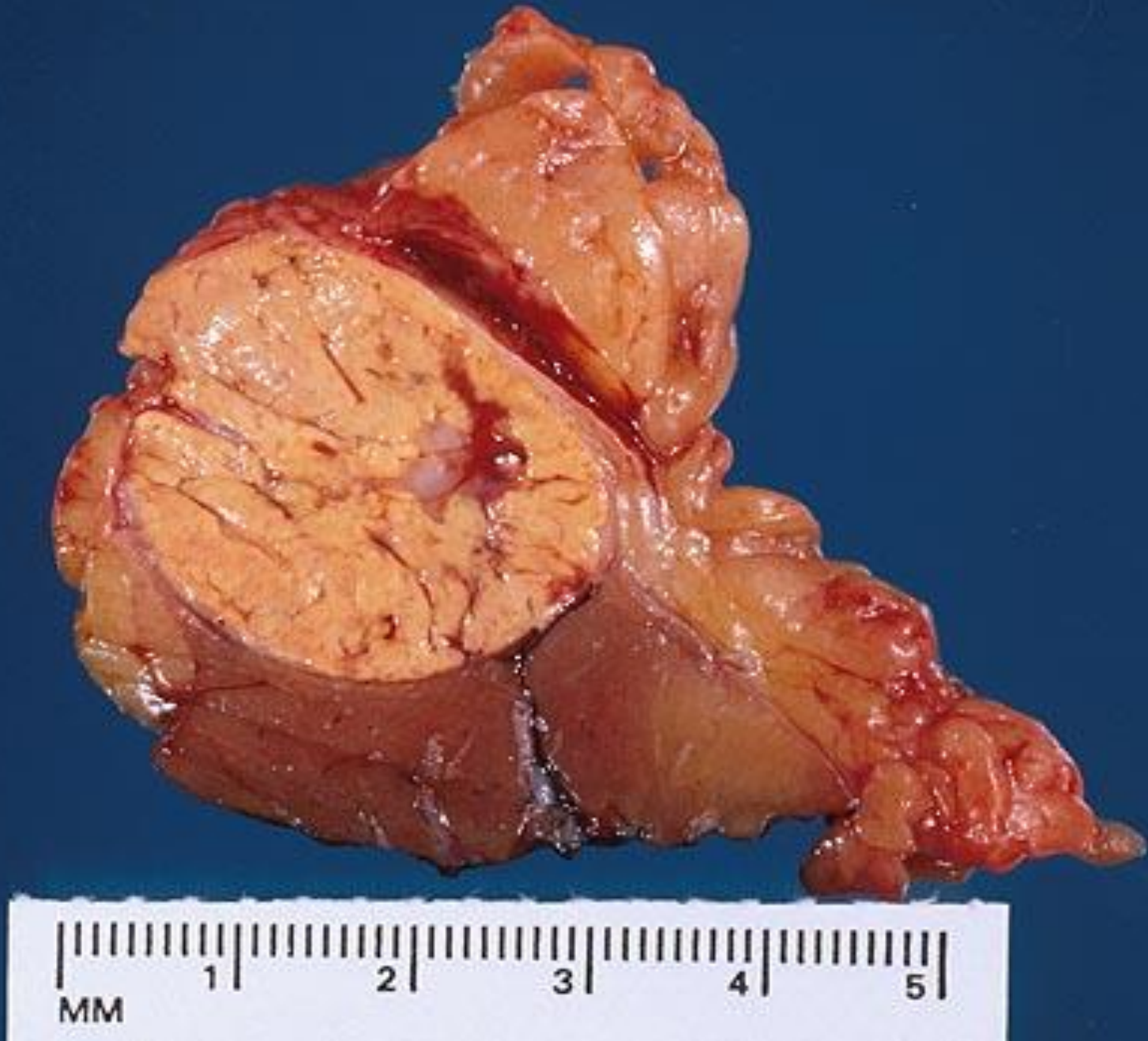
**№ 86. Polycystic kidney.**

## **№ 89. Renal carcinoma.**

In one of the poles of the kidney is a spherical tumoral formation, well contoured, diameter up to 10 cm, on section of yellow-orange color, mottled appearance, with foci of hemorrhage, necrosis and cysts; adjacent renal tissue is with normal structure.

*It constitutes 80-85% of the total malignancies of the kidney and 2-3% of the total number of cancers in adults. It is predominantly found in men (2: 1). Risk factors: smoking, occupational exposure to cadmium, cytogenetic abnormalities (commonly associated with von Hippel-Lindau disease), congenital or acquired renal polycystosis - complication of treatment with chronic dialysis. Common clinical symptoms: hematuria, pain in the lumbar region, different paraneoplastic manifestations caused by cancer cells secretion of hormones and growth factors, which may be the first clinical symptom of the tumor, eg: a) erythrocytosis (erythropoietin secretion), b) hypercalcemia (parathormone secretion), c) hypertension (renin secretion), d) amyloidosis.*

*Complications: a) invasion of the renal vein with tumor thrombosis, which can extend to the inferior vena cava and the right heart, b) invasion of the renal capsule, perirenal adipose tissue and adrenal tissue, c) invasion of the calyces, pelvis and ureter, d) hematogenous metastases in lungs, brain, bones, liver and lymphogenous in perirenal lymph nodes.*



**№ 89. Renal carcinoma.**

## **№ 91. Urinary bladder carcinoma.**

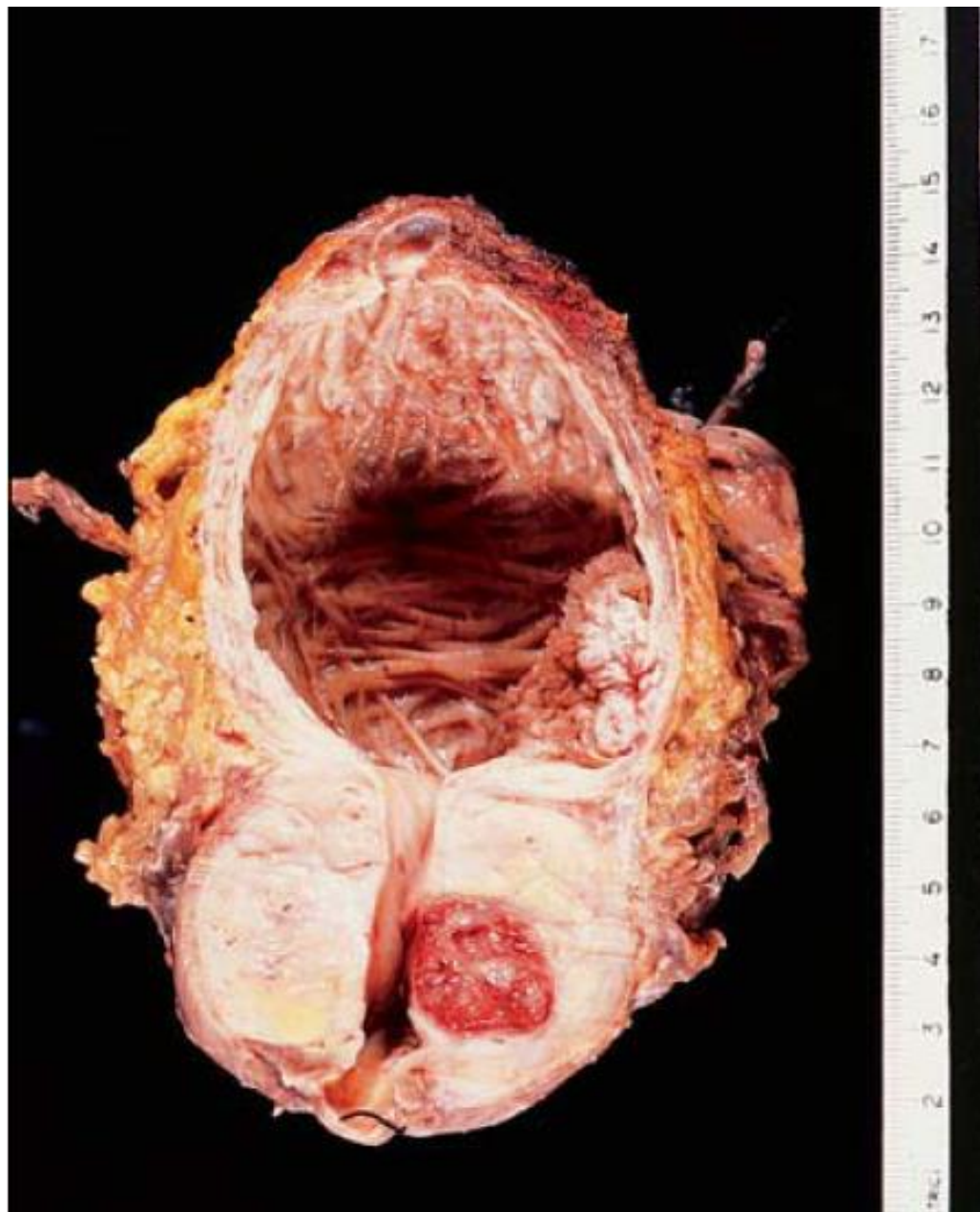
In urinary bladder is a tumor node, which has exophytic type of growth in the bladder cavity, up to 10 cm in diameter of rough surface.

*Histologically, the absolute majority of cases of urinary bladder carcinomas (90%) are urothelial carcinoma (old name - "carcinoma from transitional epithelium").*

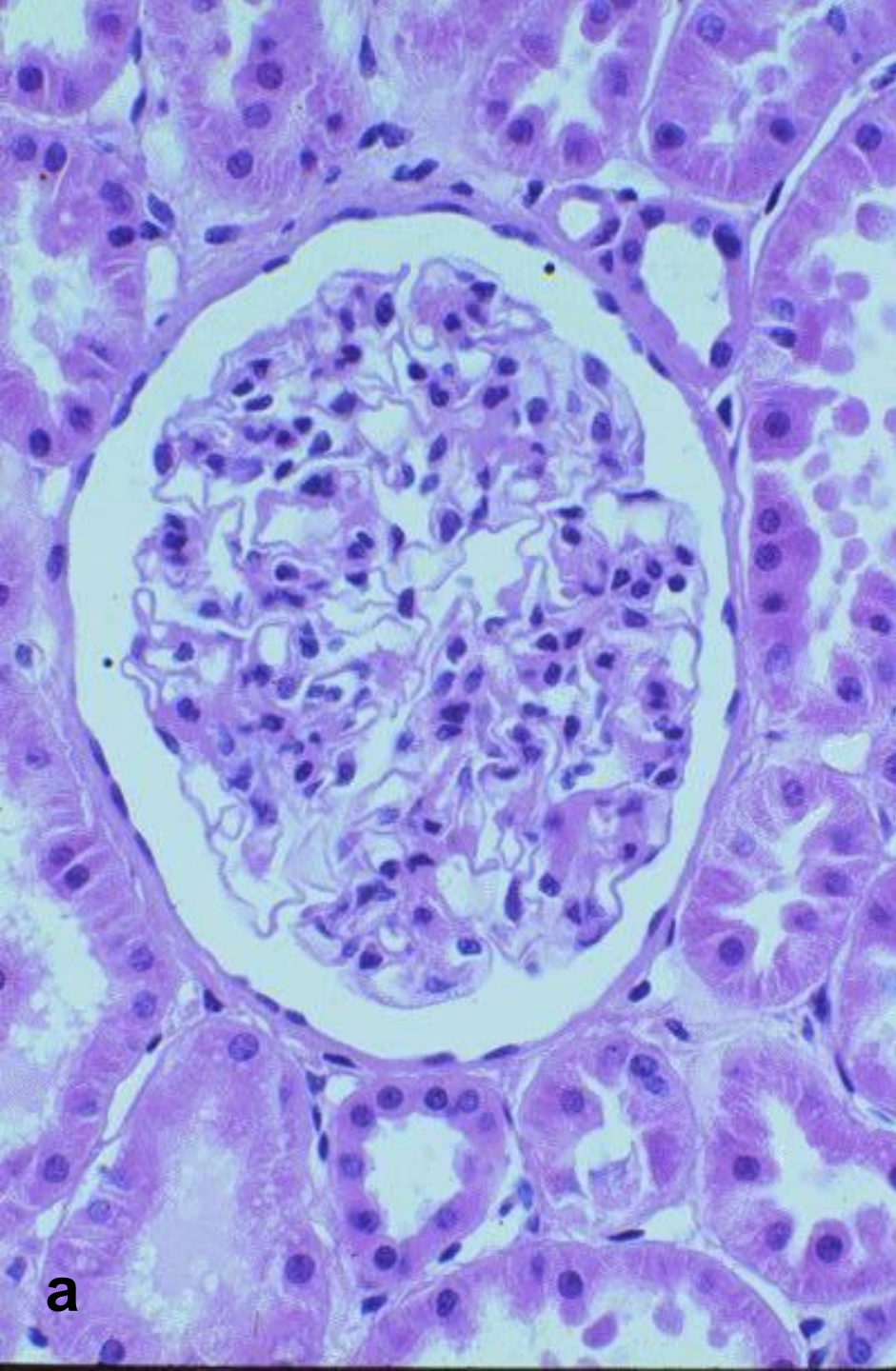
*It constitutes ~ 7% of the total number of cancers, being 3-4 times more frequent in men than in women. The main clinical symptoms are hematuria and dysuria. The most important risk factors are: a) smoking (the risk is 2-4 times higher than in non-smokers), b) occupational or environmental exposure to carcinogenic chemical factors (aniline dyes, arsenic), c) some drugs (phenacetin, cyclophosphamide), d) radiation therapy for prostate cancer, uterus, e) chronic cystitis, including infectious origin, f) urinary bladder extrusion (congenital anomaly).*

*Complications: ulceration, bleeding, purulent inflammation, invasion of adjacent organs - prostate, seminal vesicles, uterus, vagina, pelvic walls.*

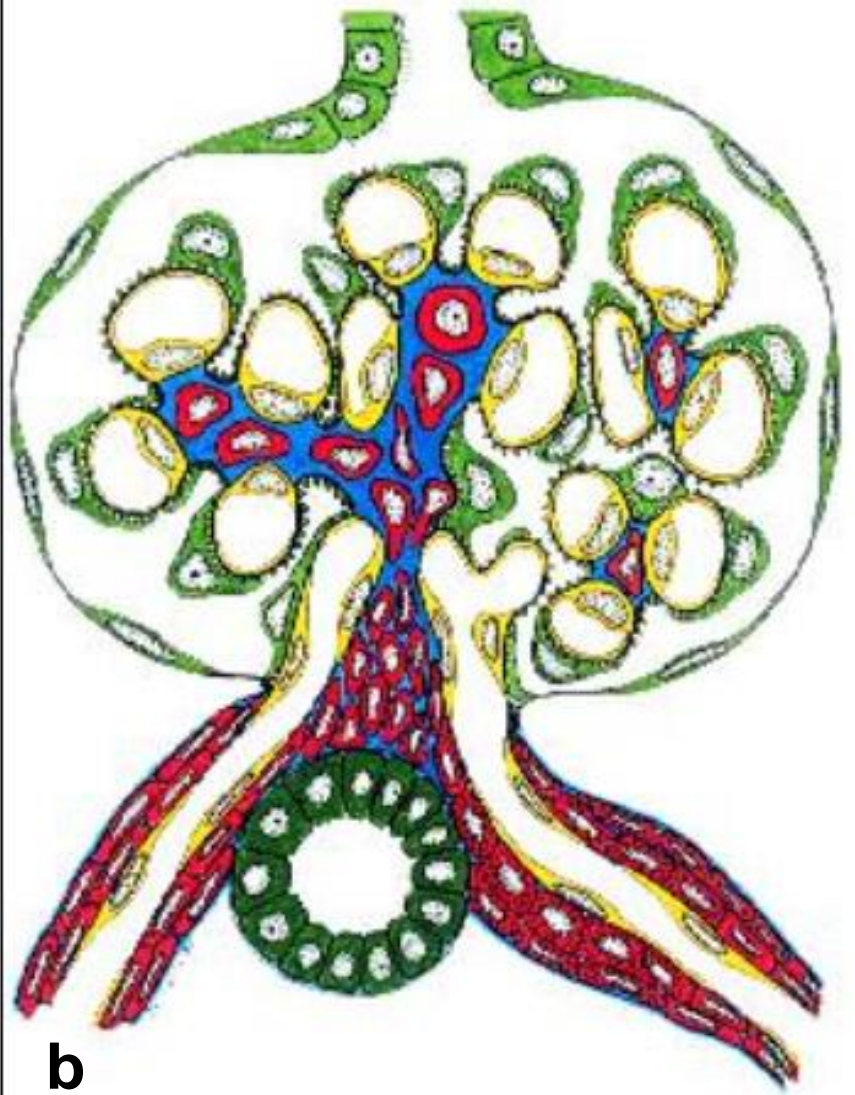
*Metastases: lymphogenous - in the iliac, paraaortal, paracaval lymph nodes; hematogenous - in the liver, lungs, bones.*



**№ 91. Urinary bladder carcinoma.**



a

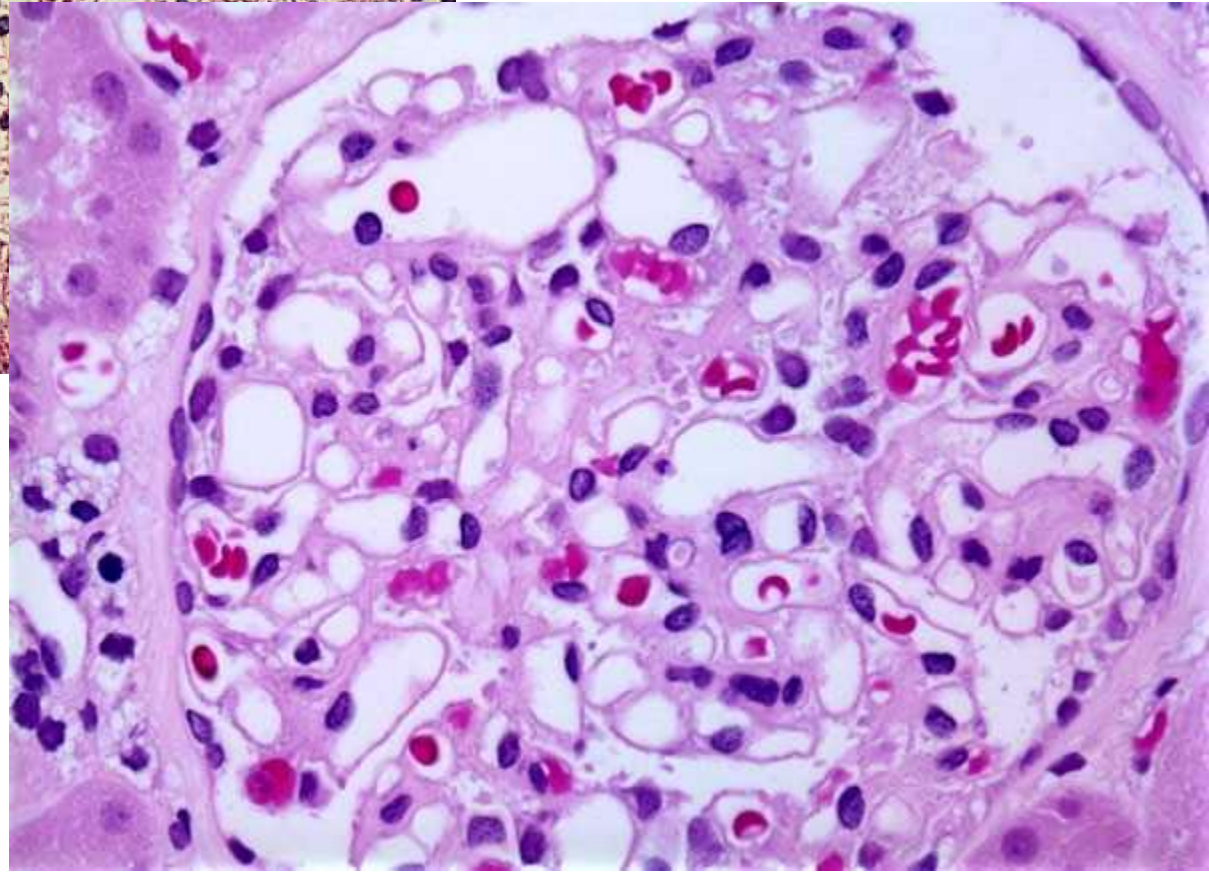
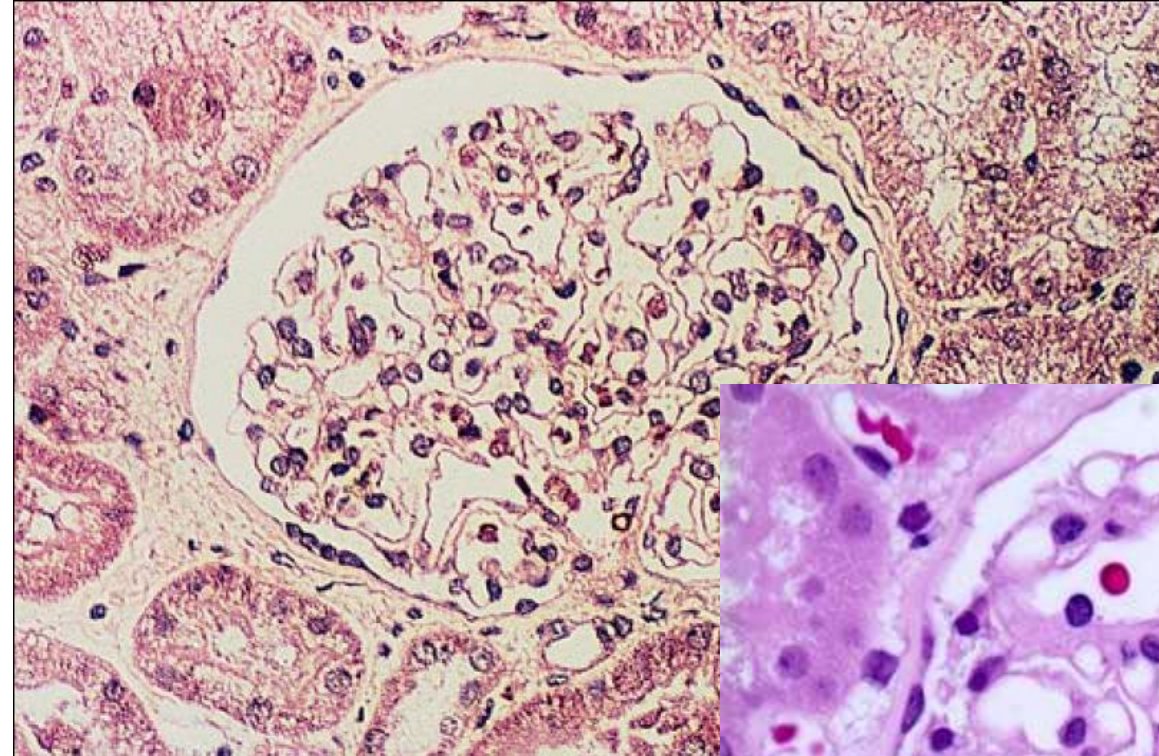


b

**Normal glomerulus;**

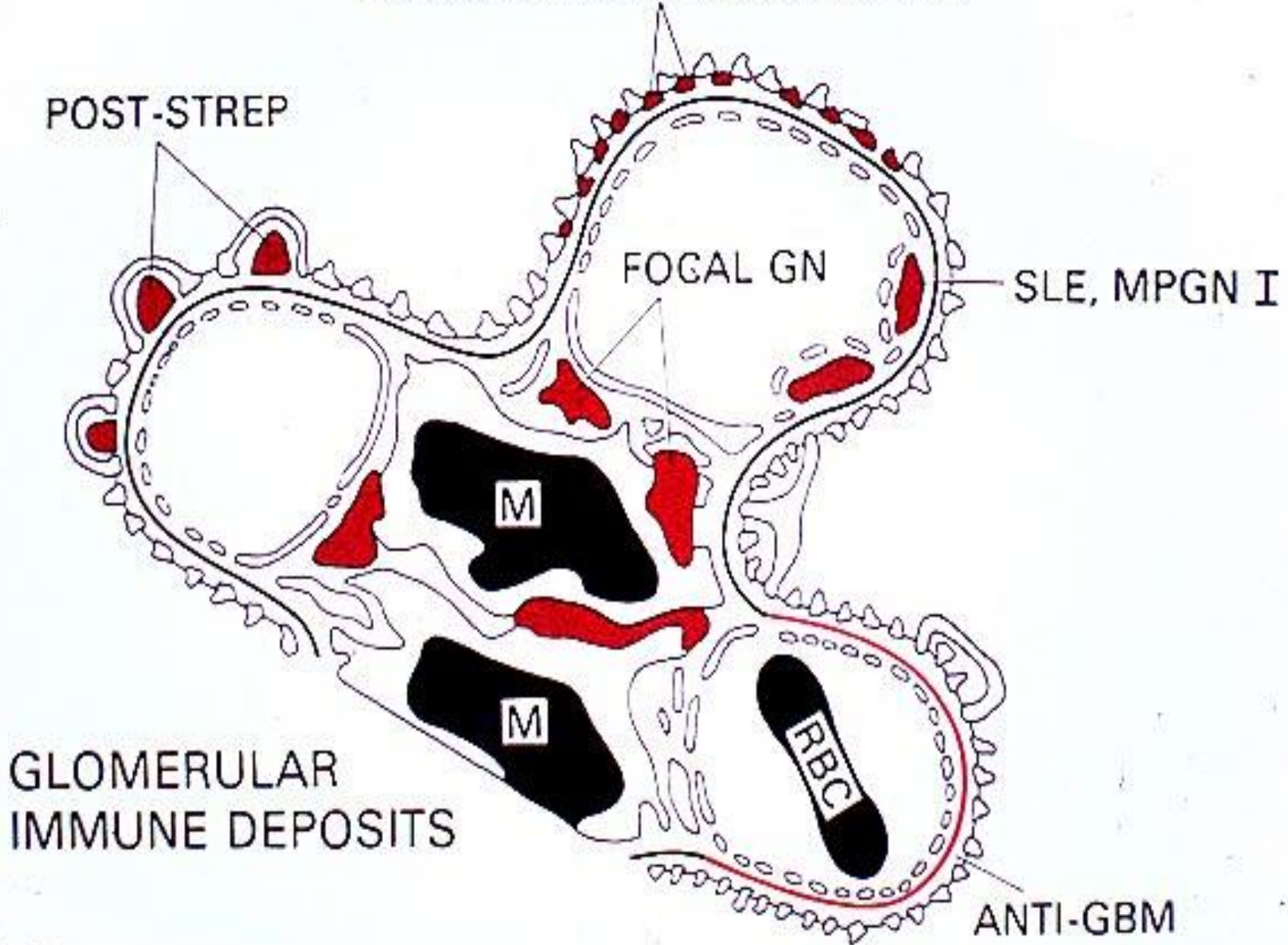
b - diagram (*podocytes*,  
*endotheliocytes*, *mesangocytes*,  
*mesangial matrix*)

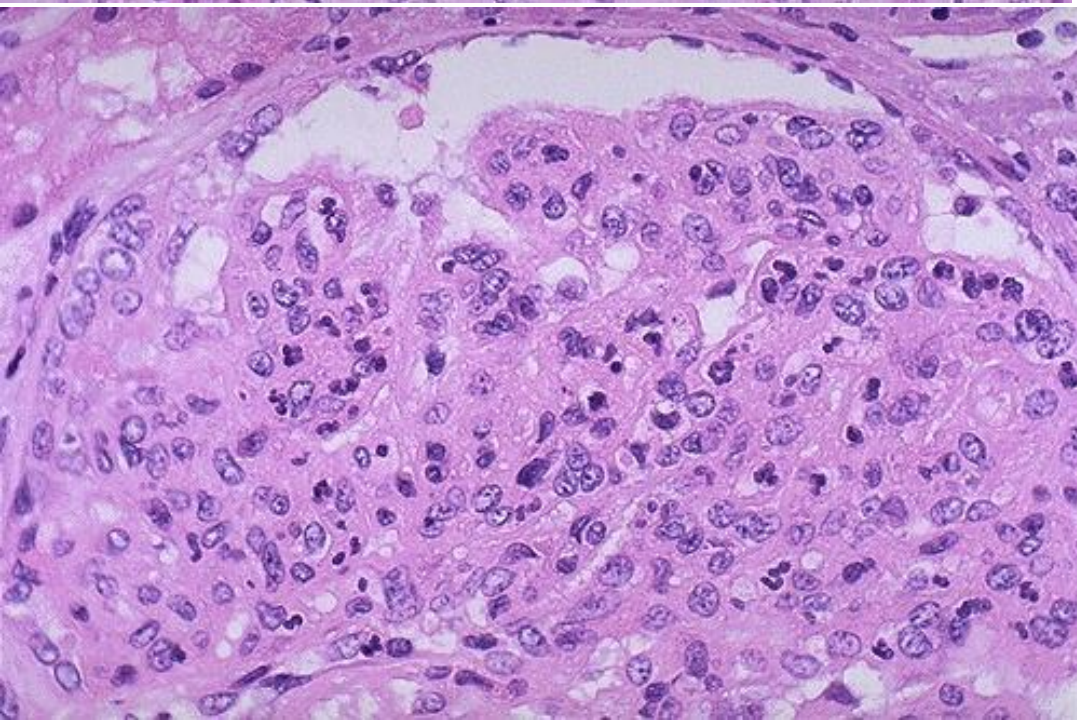
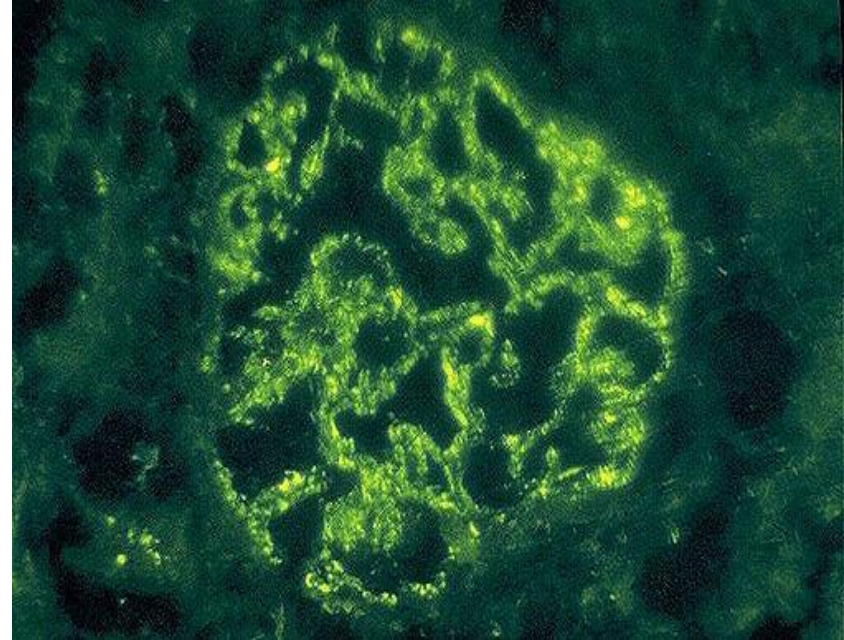
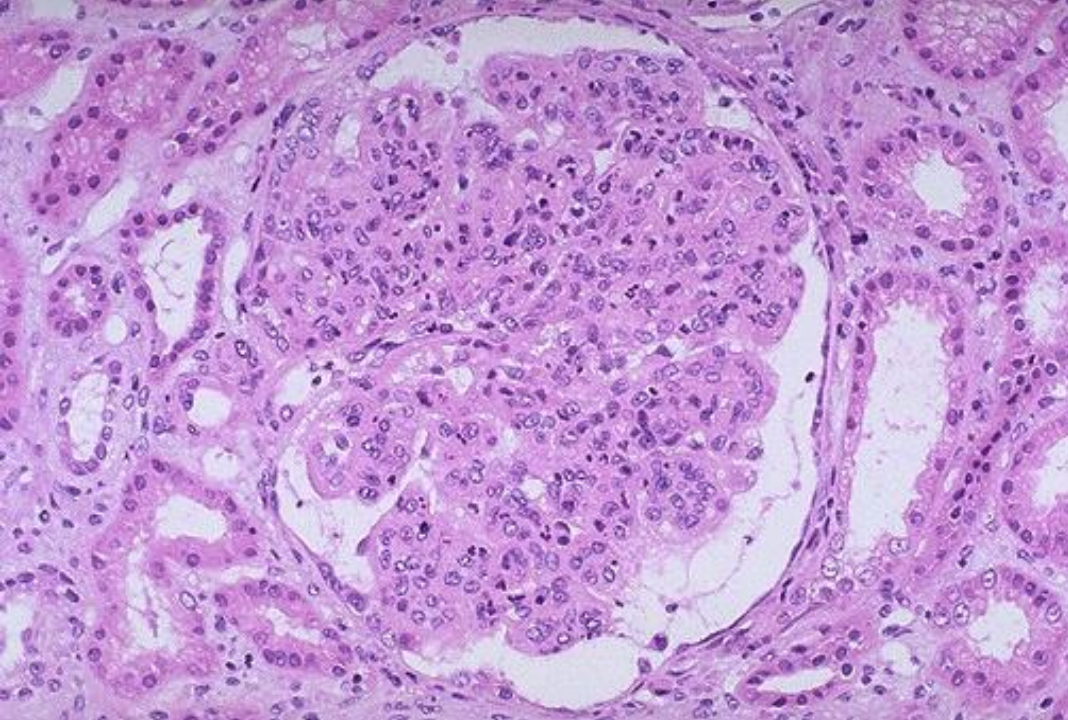




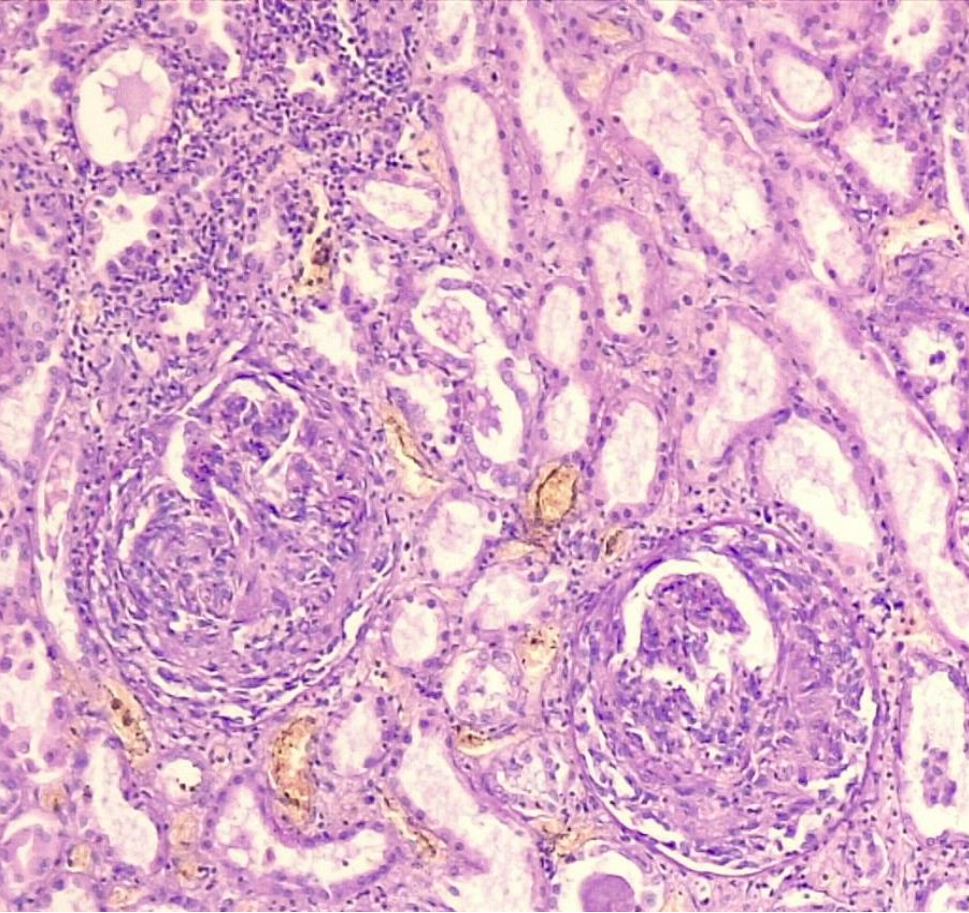
**Glomerulus in glomerulopathy with minimal changes, absence of morphological changes on light microscopy.**

# MEMBRANOUS NEPHROPATHY

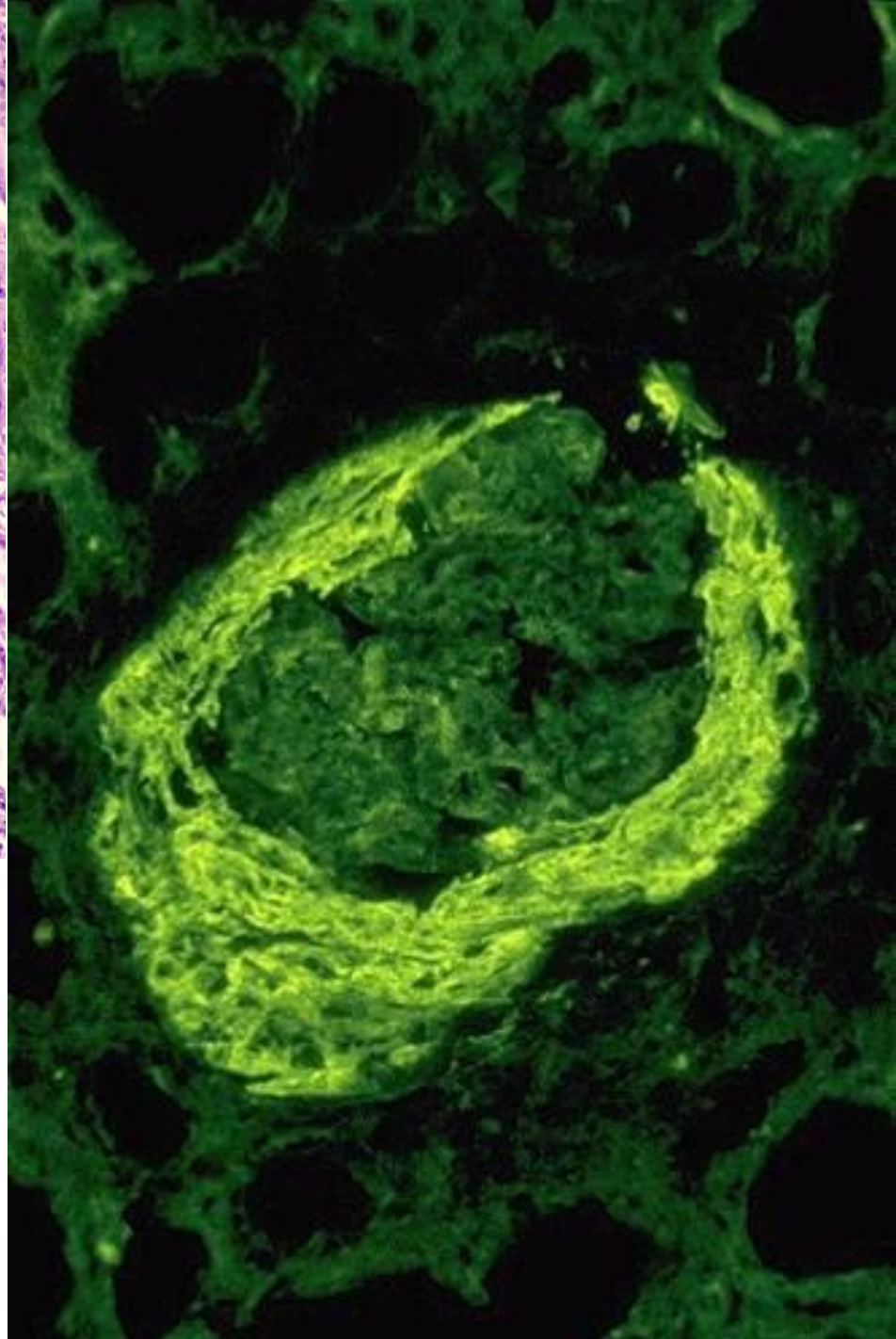


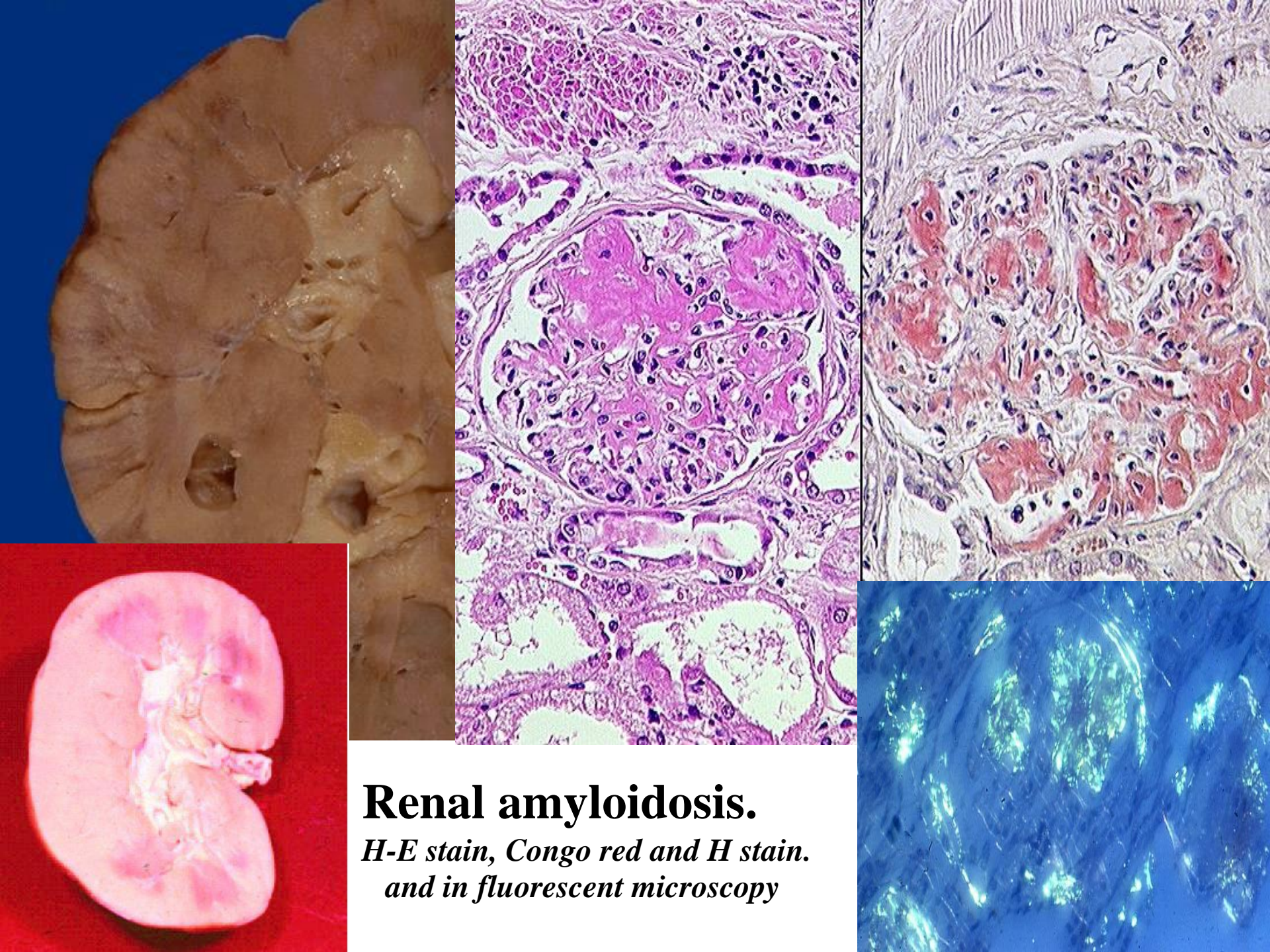


**Acute glomerulonephritis**  
*(increasing the cellularity of the  
glomerulus,  
neutrophil infiltration on  
immunofluorescent microscopy -  
“granular” deposits of immune  
complexes)*



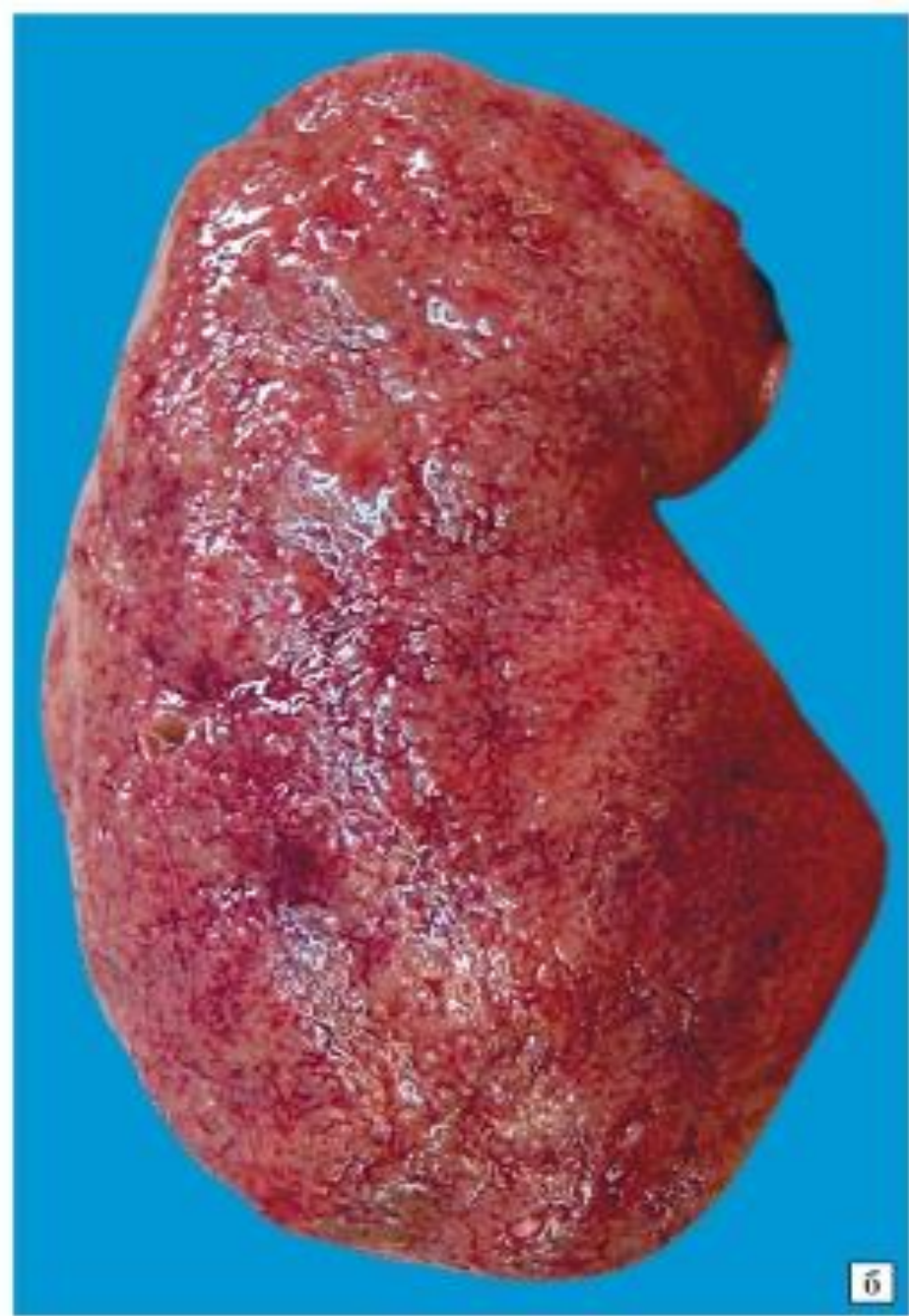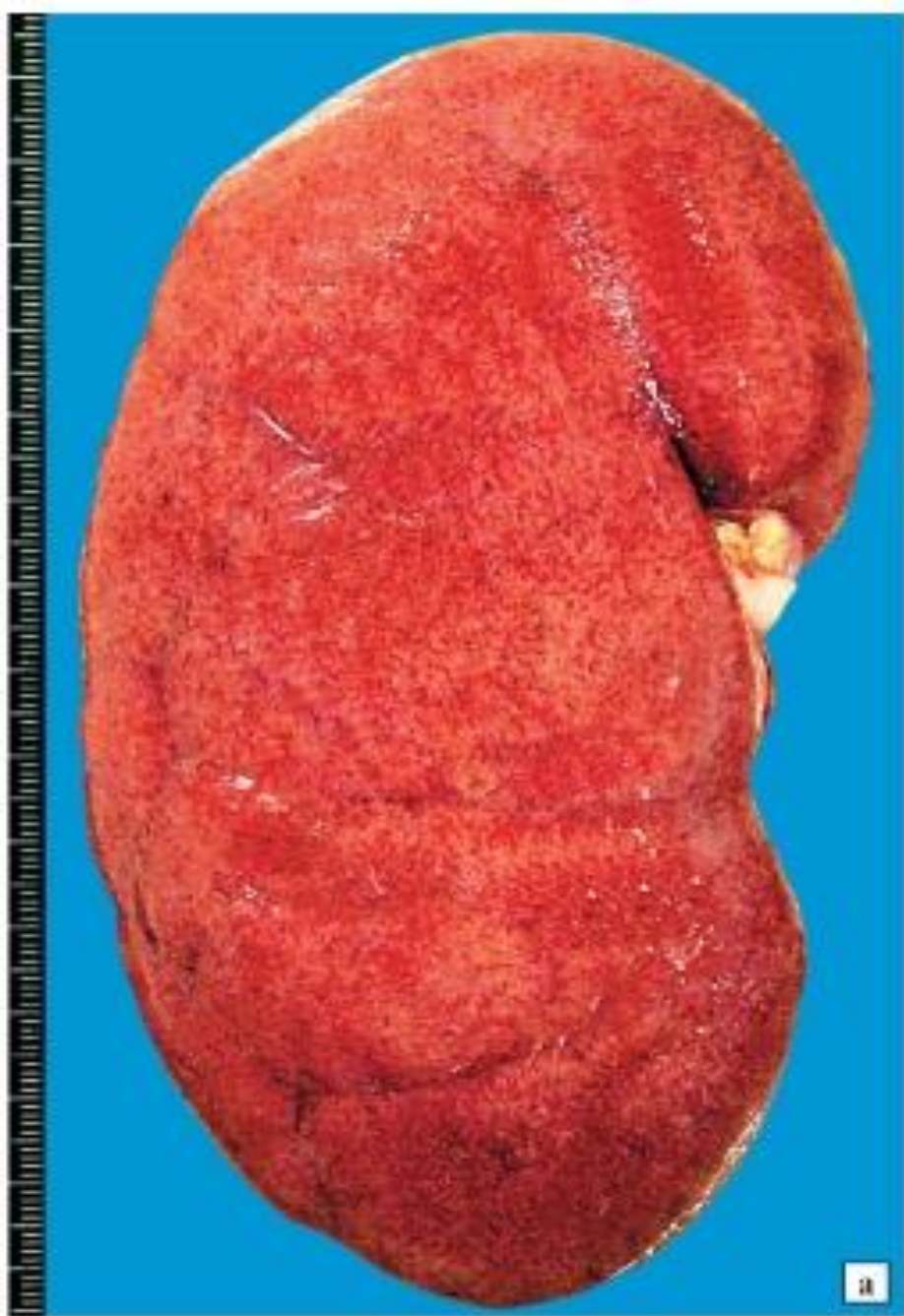
**Rapidly progressive  
glomerulonephritis**



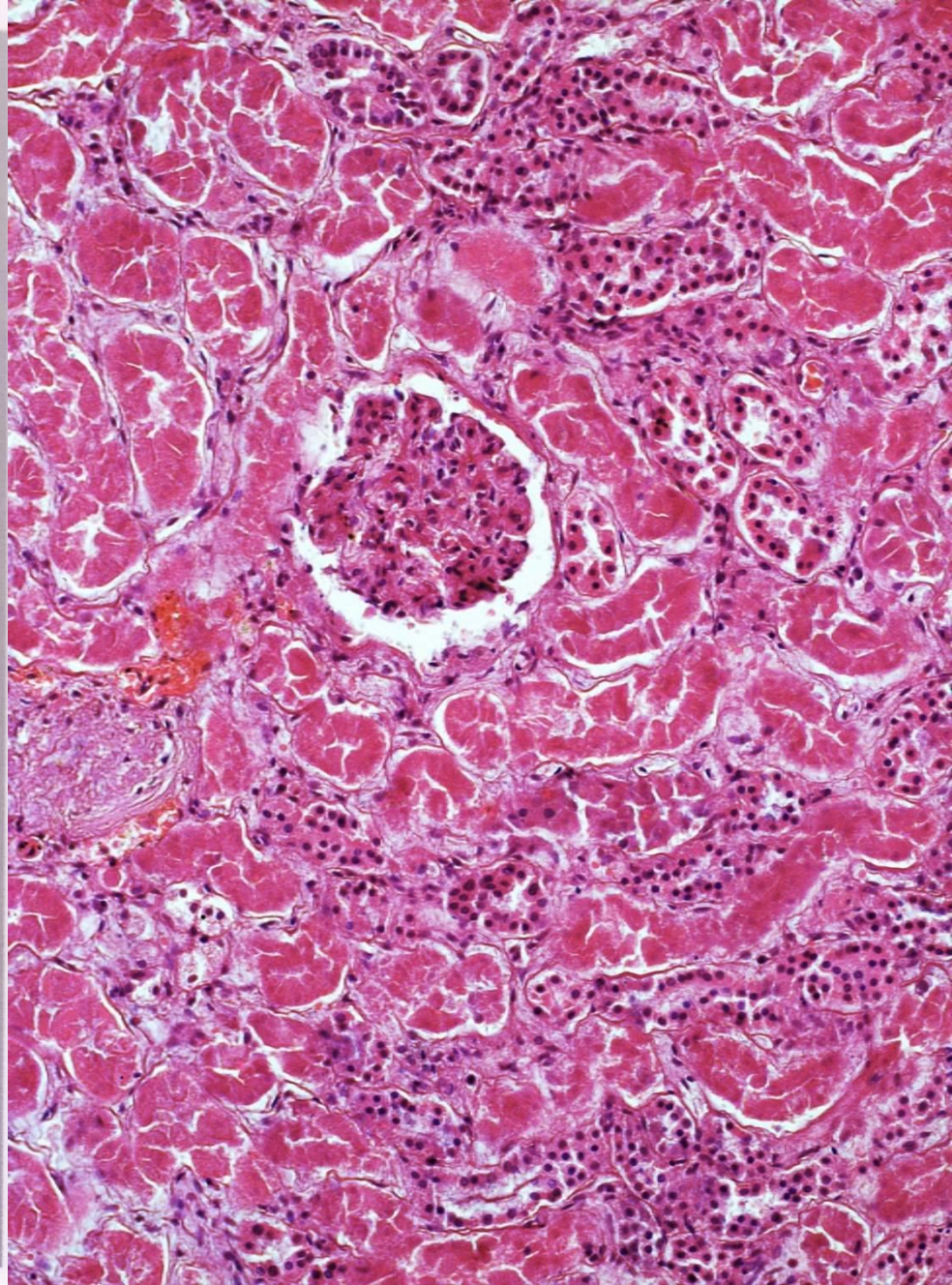
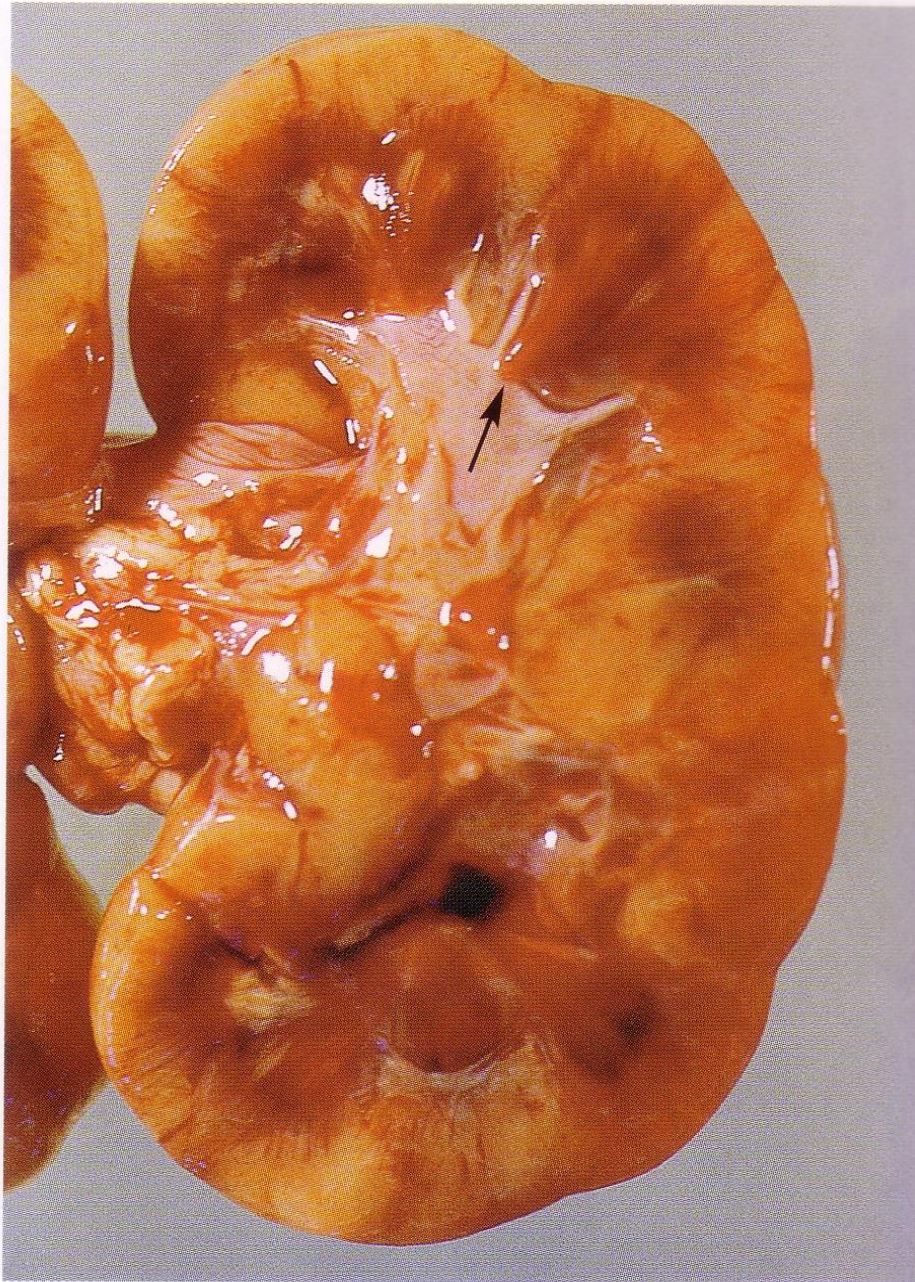

## **Renal amyloidosis.**

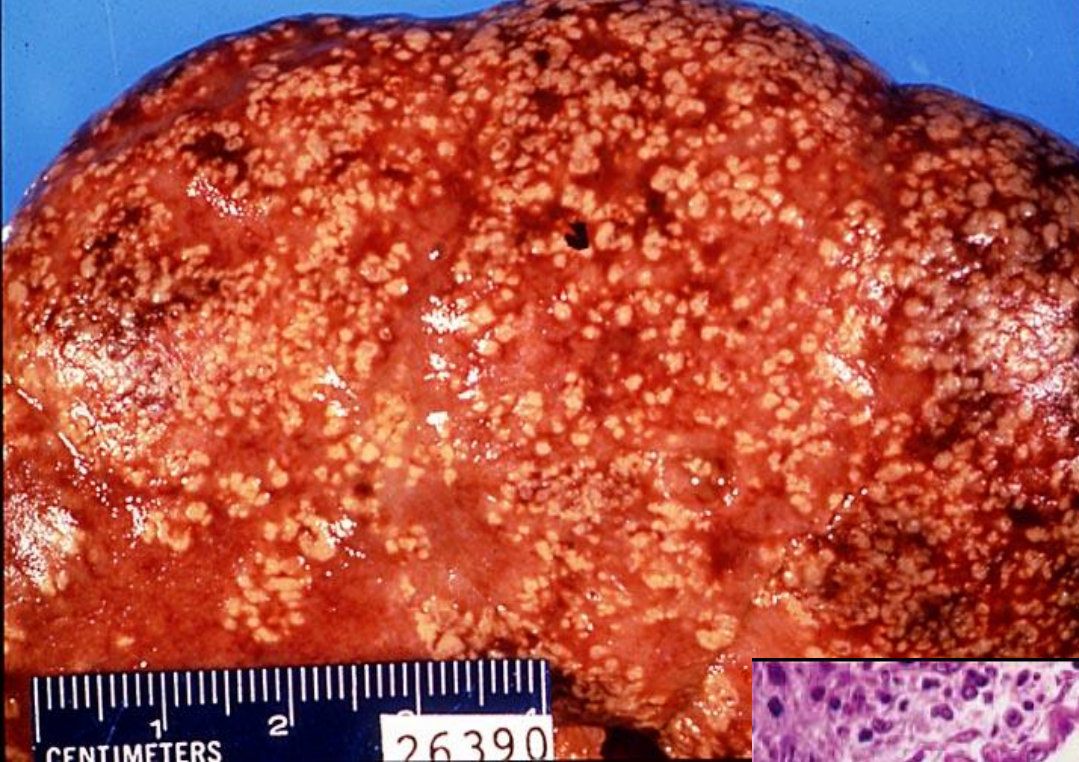
*H-E stain, Congo red and H stain.  
and in fluorescent microscopy*



**Acute glomerulonephritis (a) vs. chronic (b)**

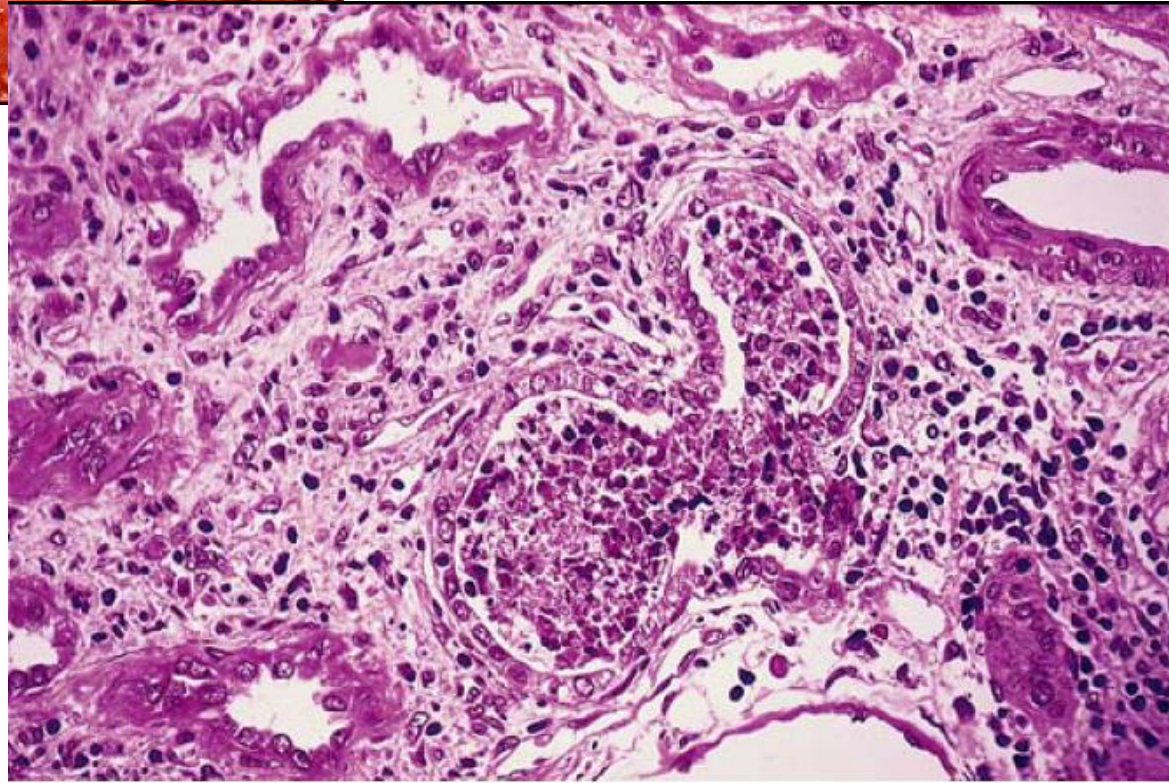


**Shock kidney**

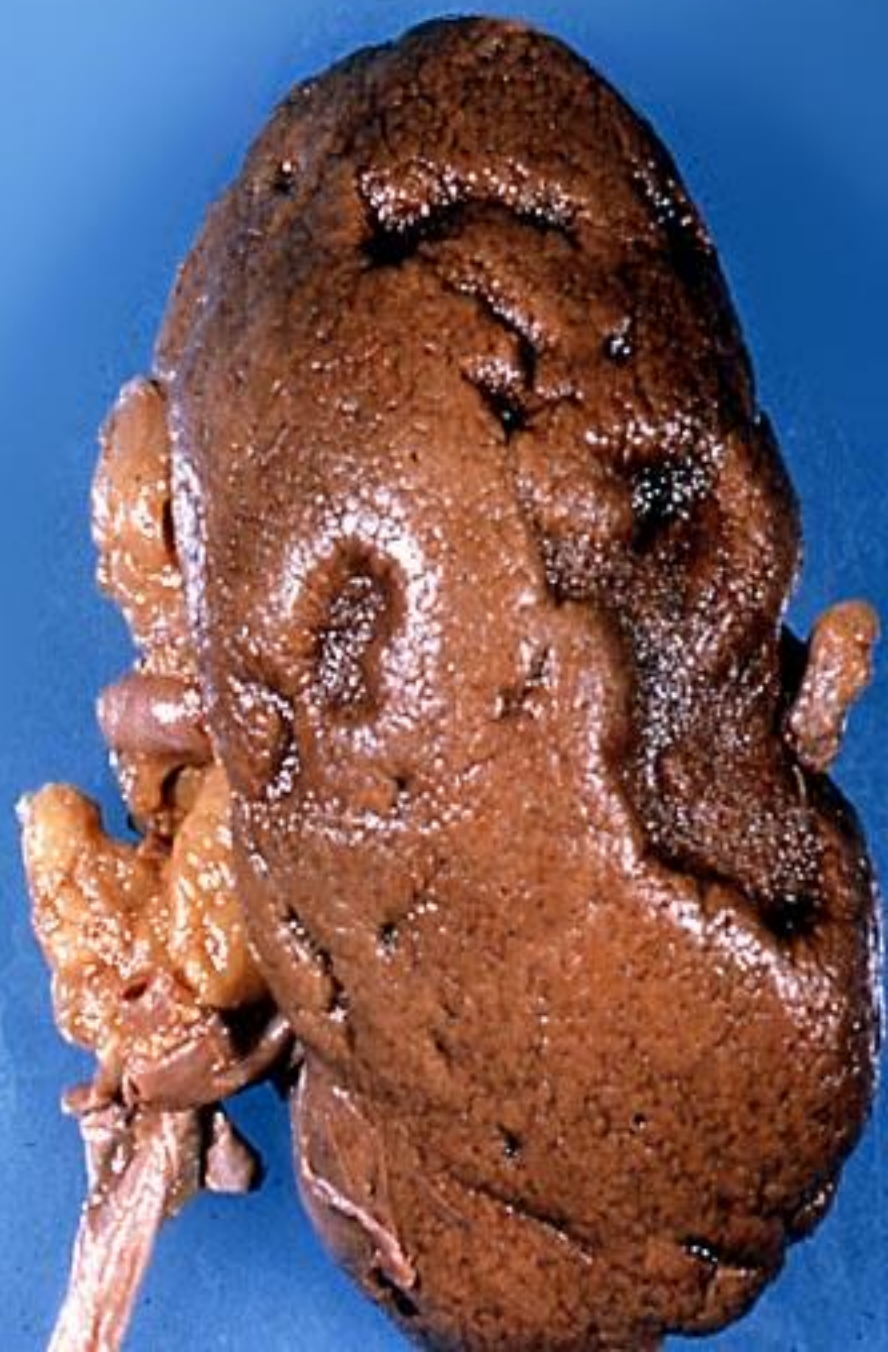
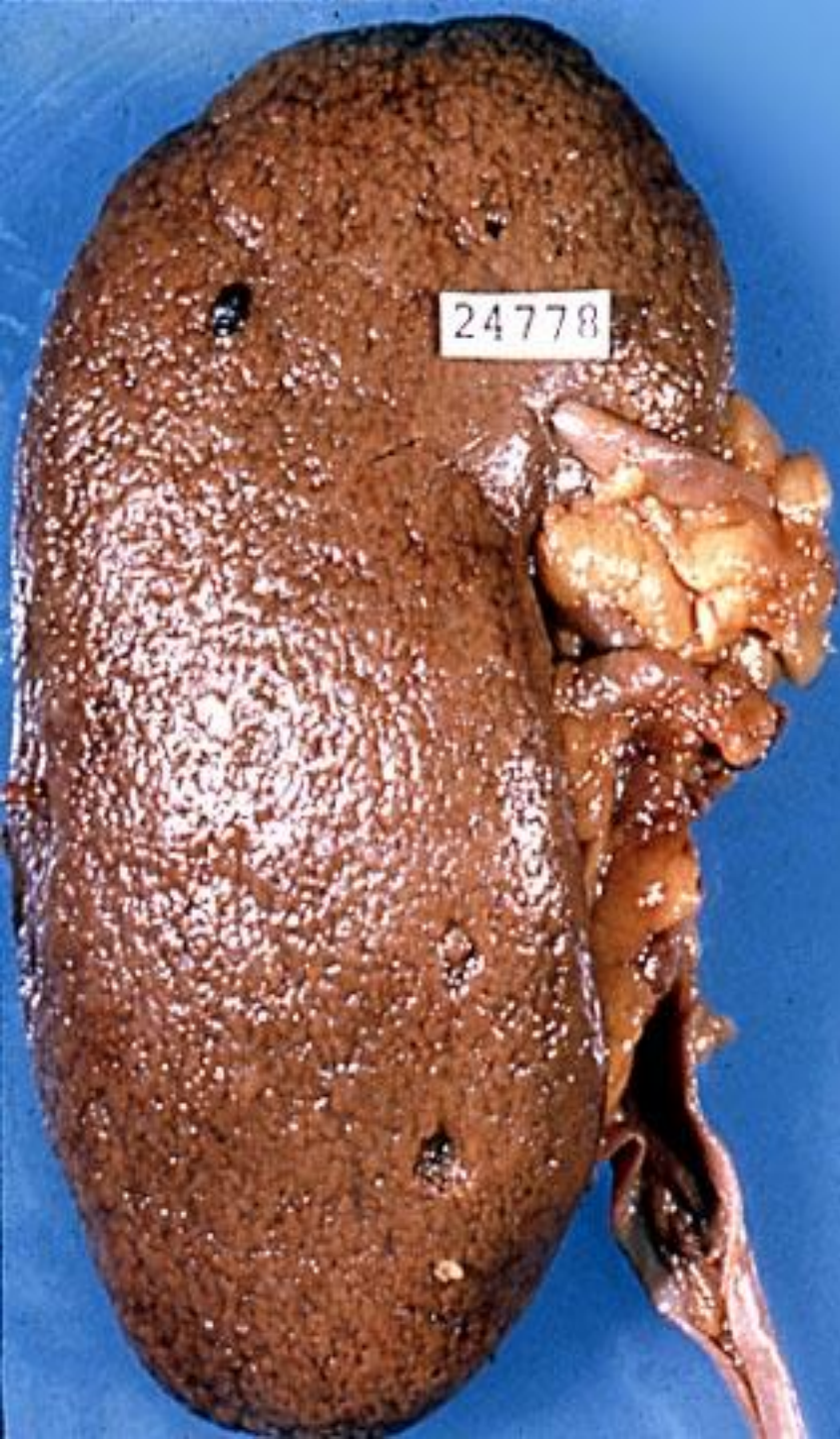
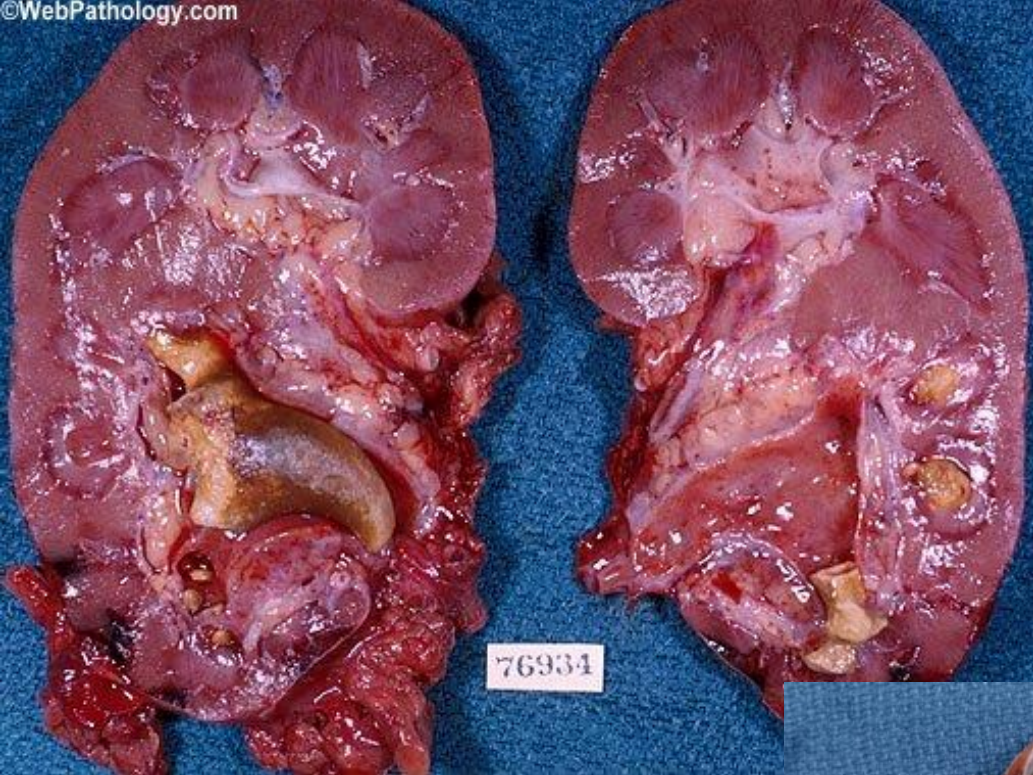
**Acute pyelonephritis,  
inflammatory infiltrate in  
the interstitium and lumen of  
the tubes.**

**Purulent acute pyelonephritis**



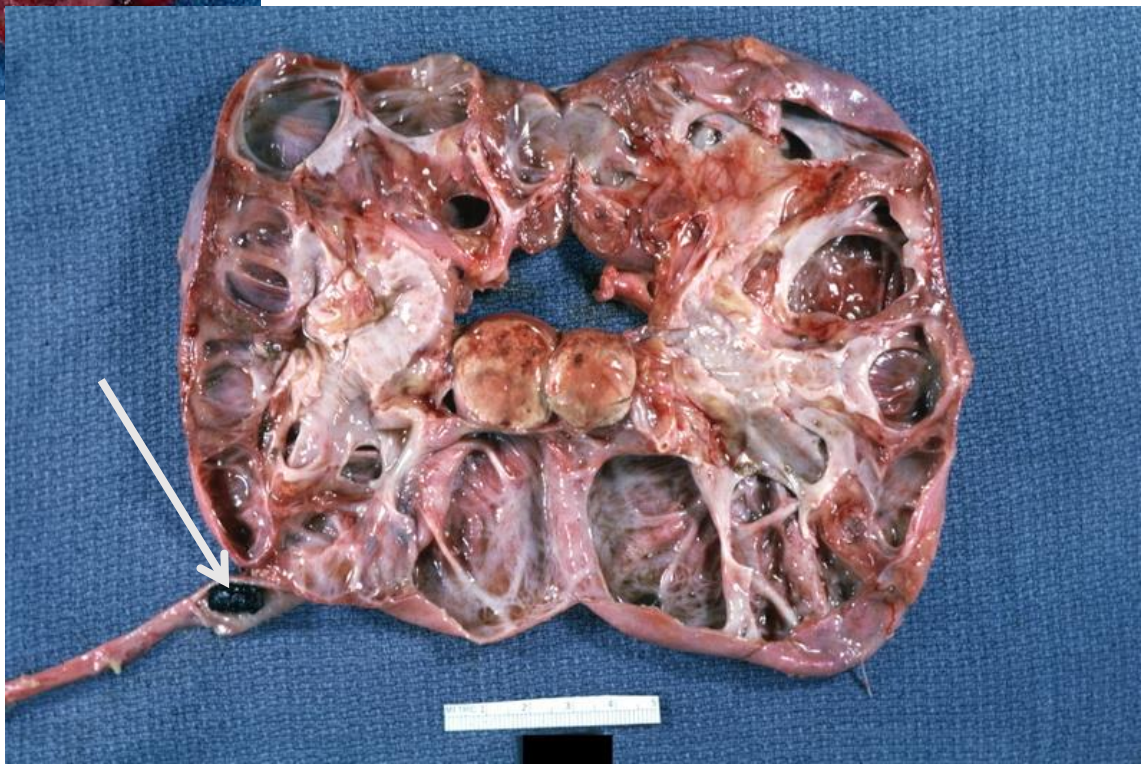


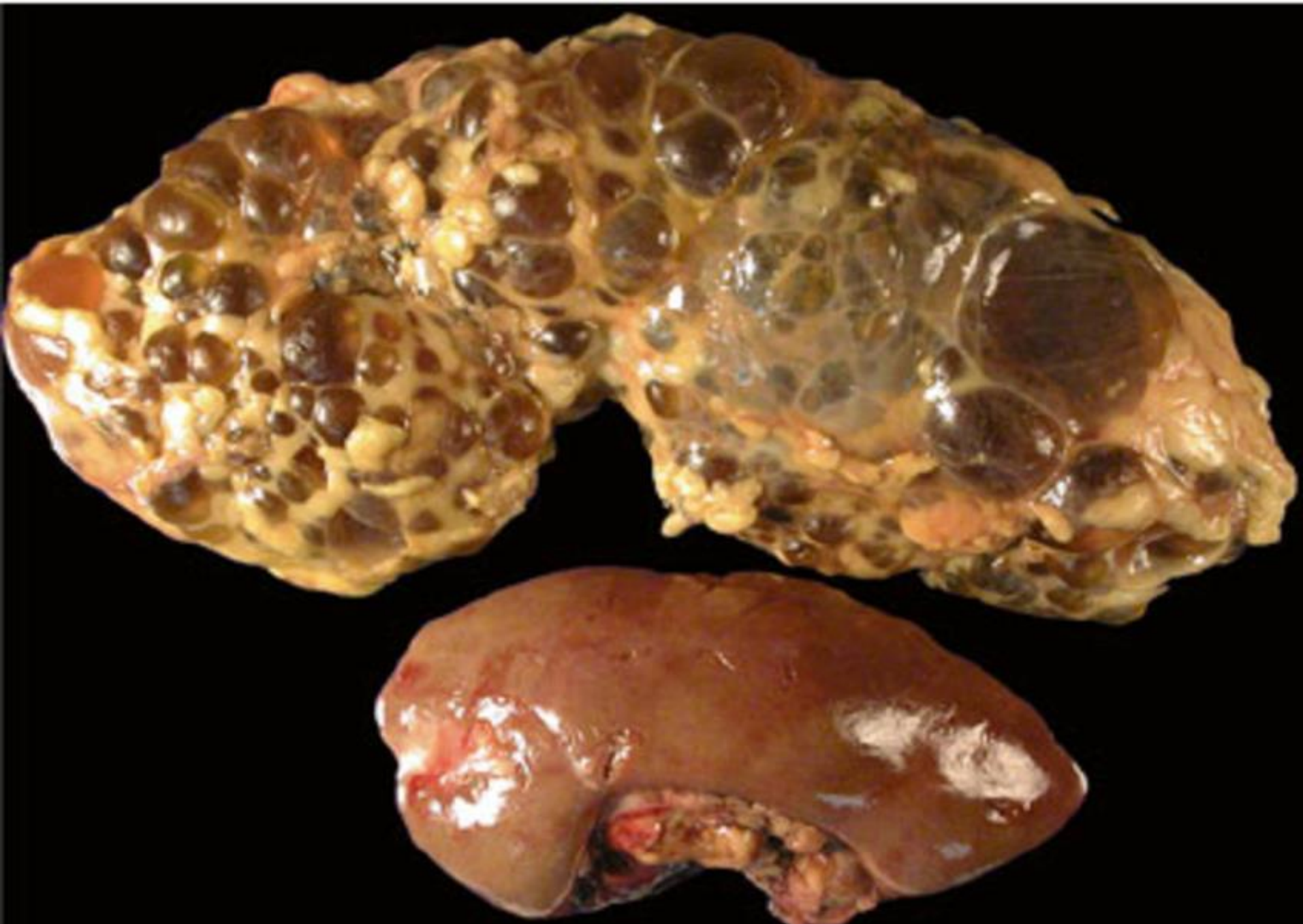



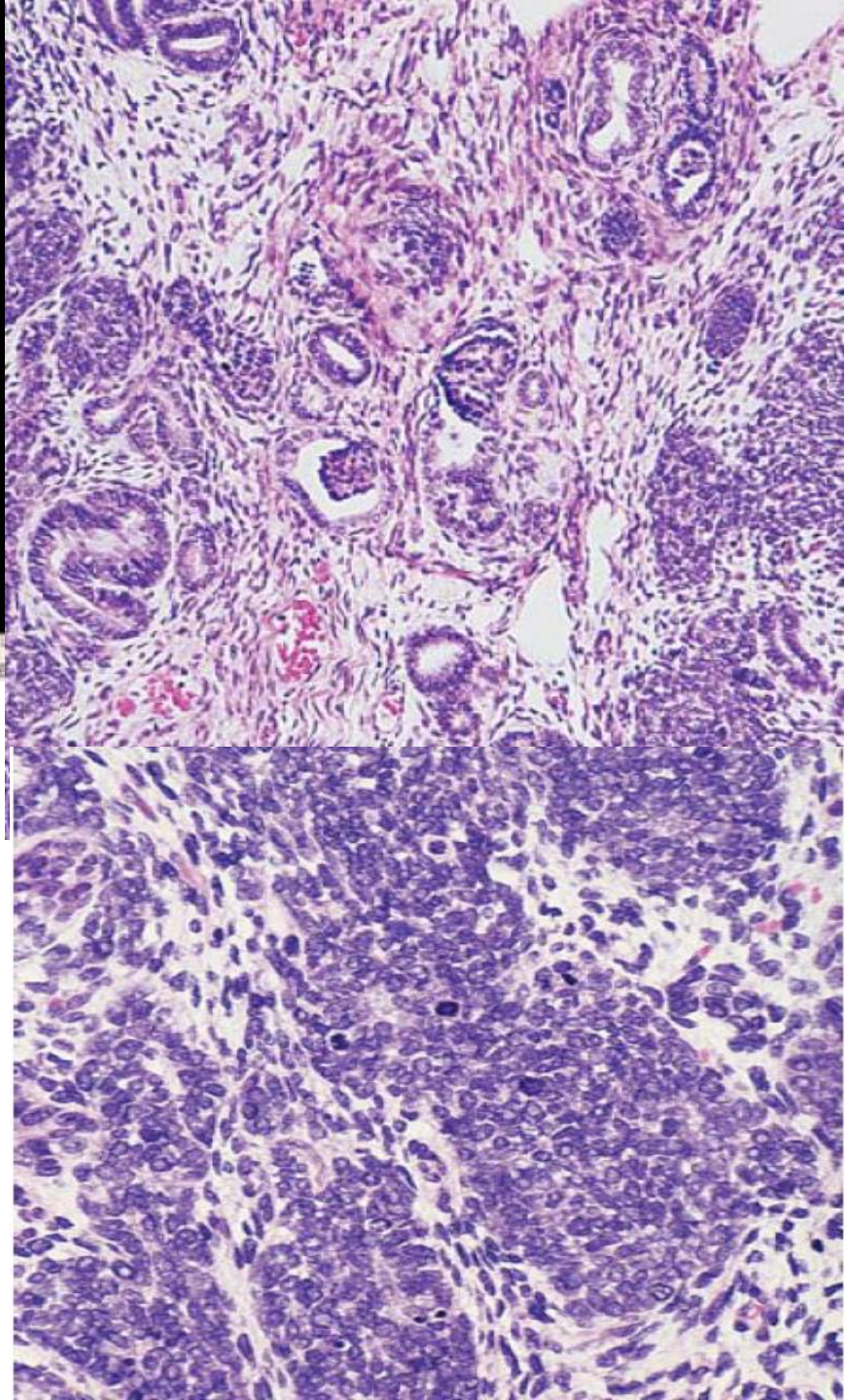
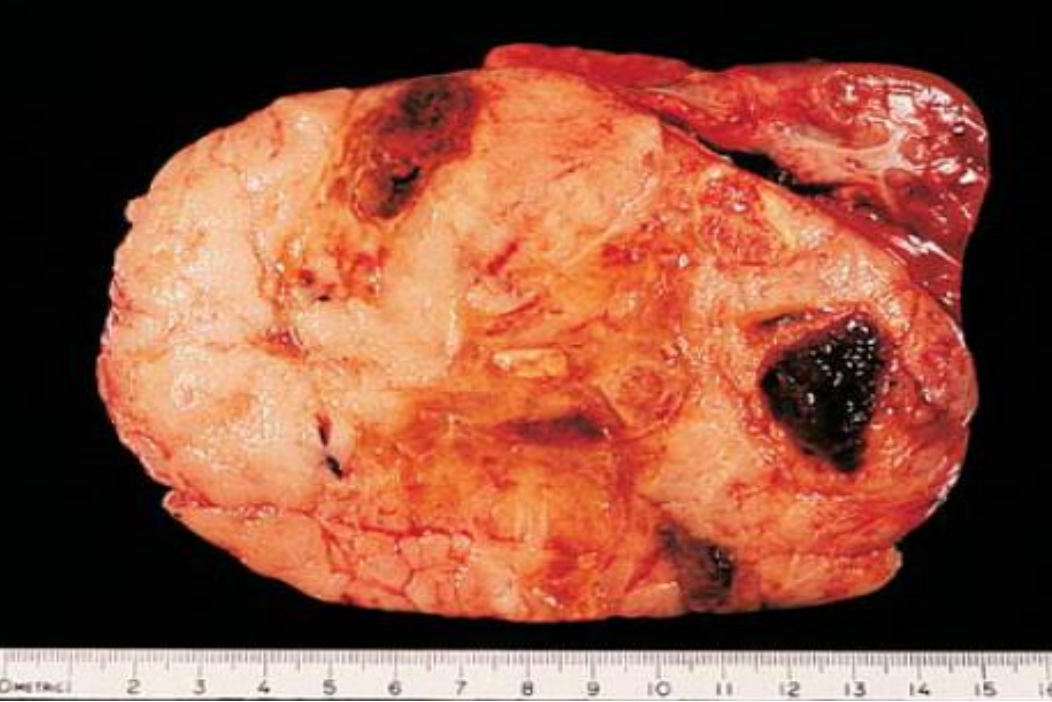
**Hydronephrosis  
(ureteral calculus).**

**Kidney stones,  
coral-shaped stone**


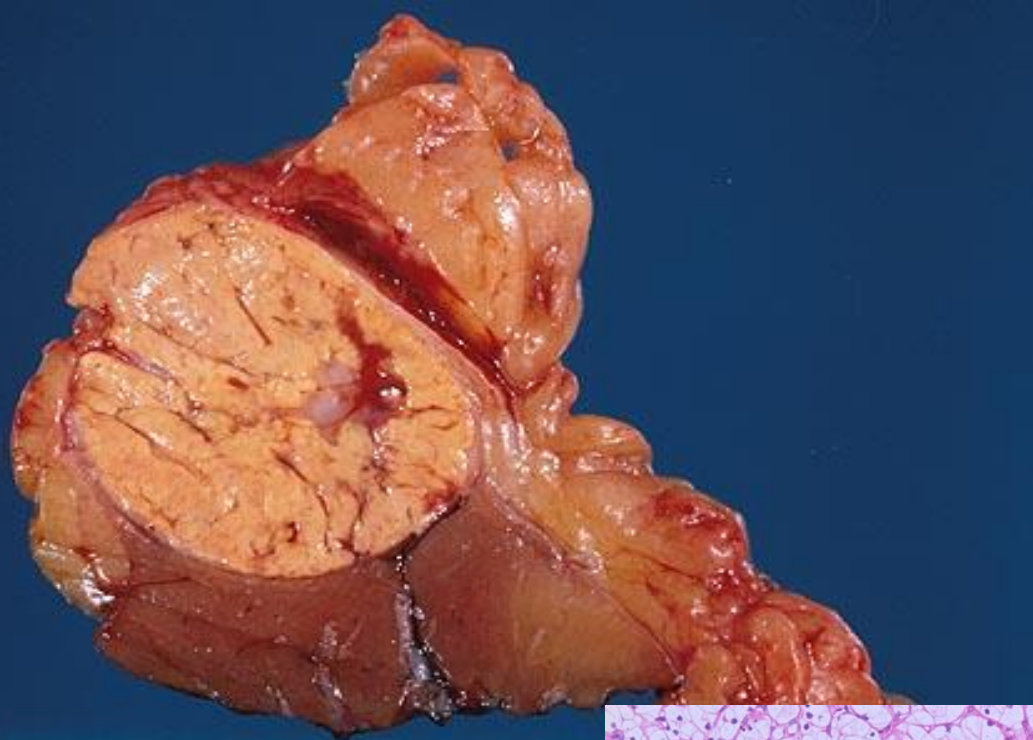




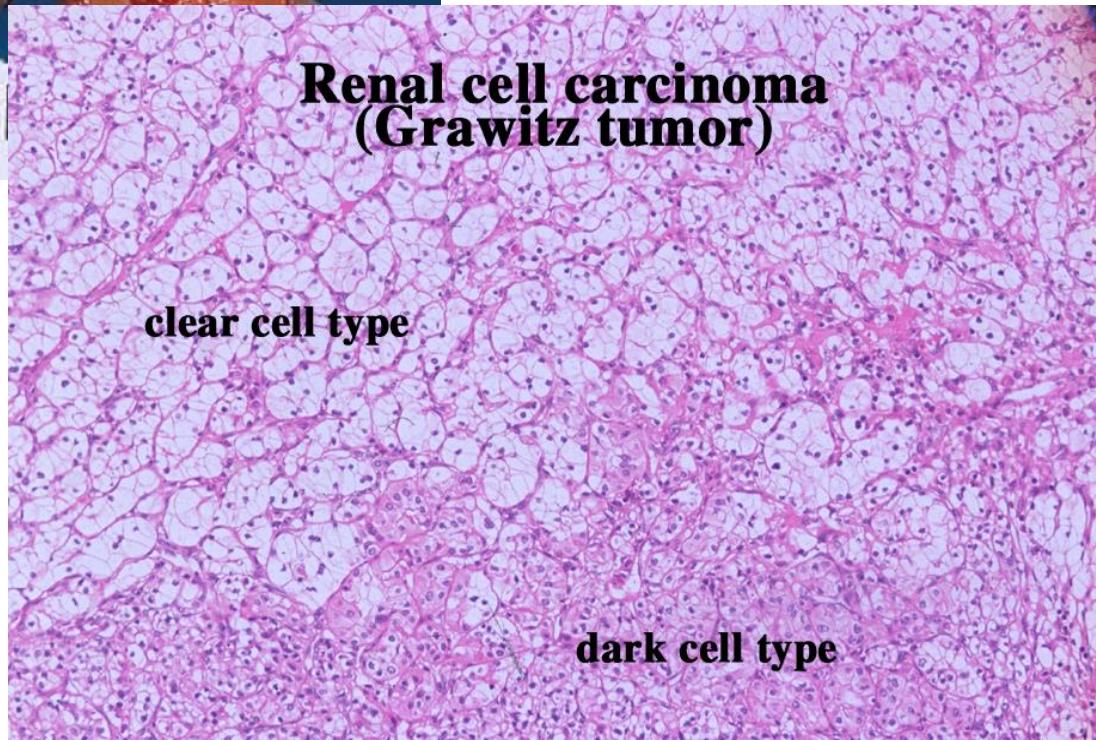
**Autosomal dominant polycystic kidney disease (ADPKD).**



**Wilms tumor (nephroblastoma)**



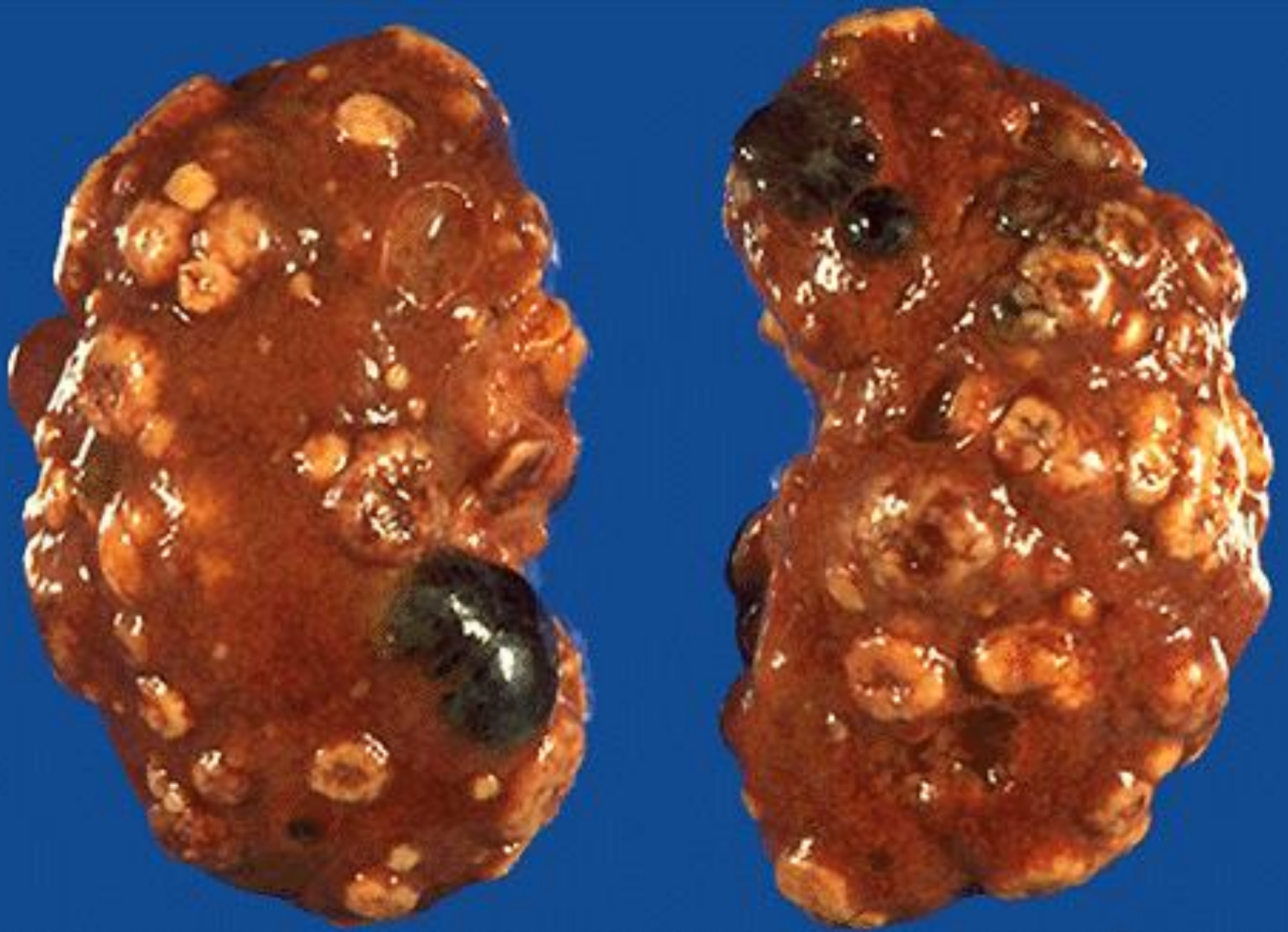
**Renal cell carcinoma.**



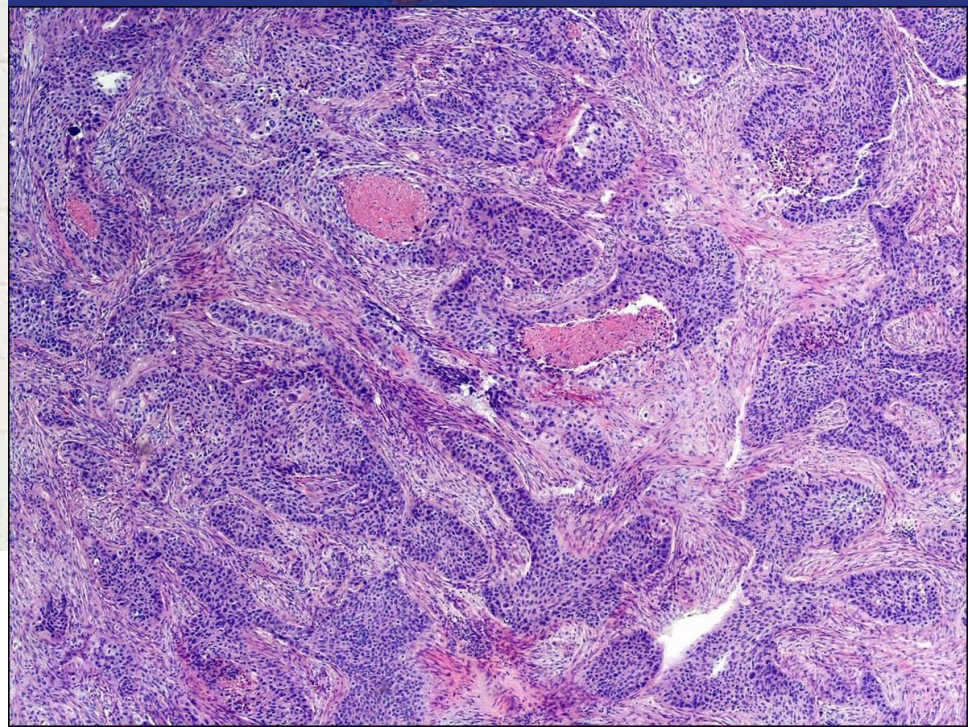
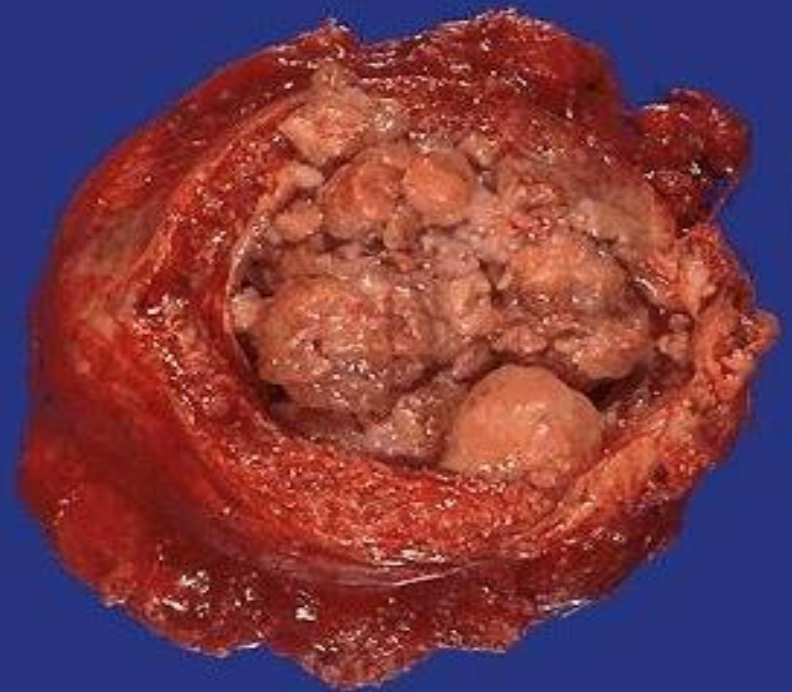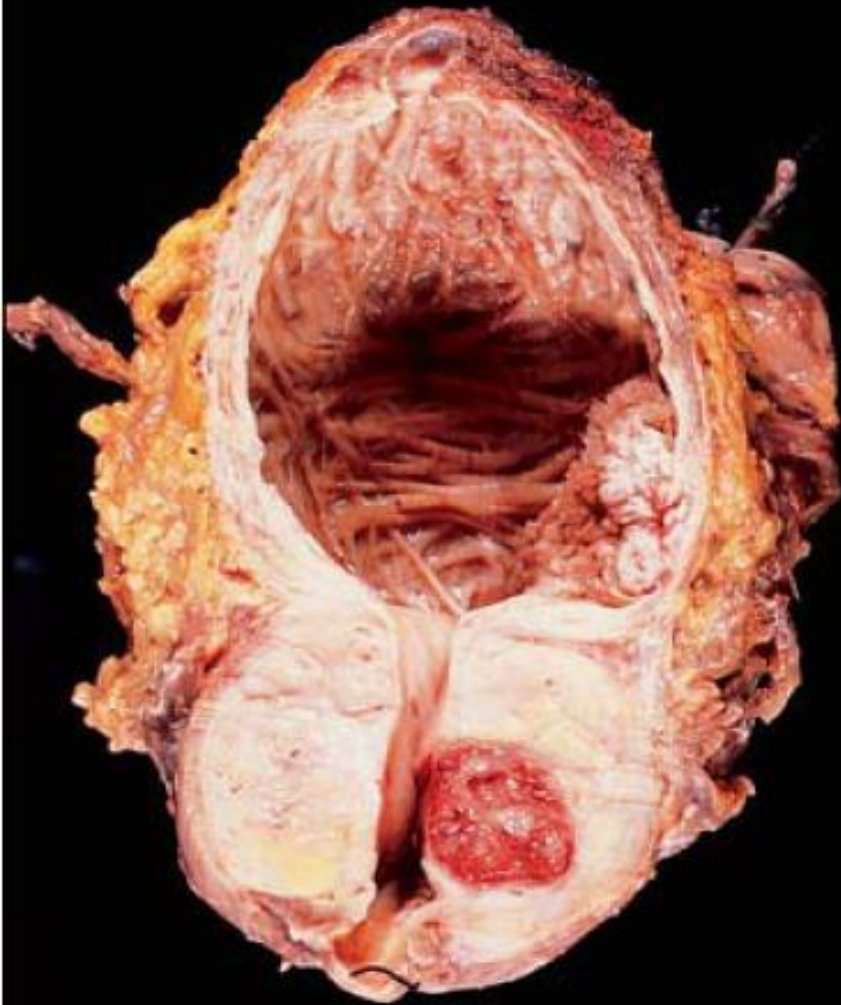
**Renal cell carcinoma  
(Grawitz tumor)**

**clear cell type**

**dark cell type**

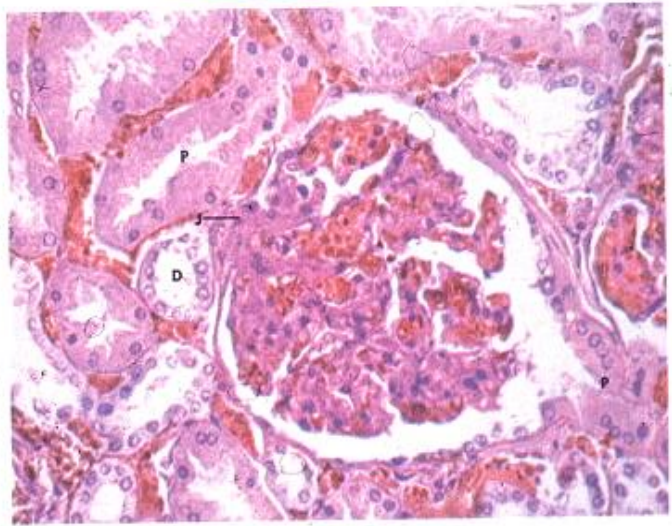
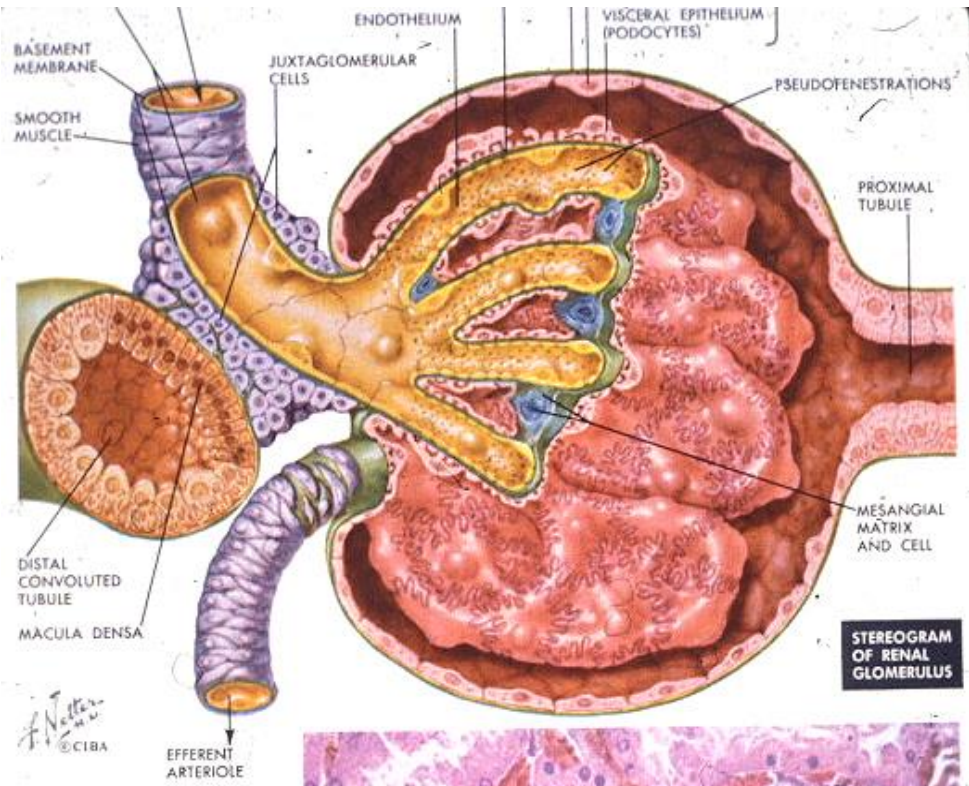


**Metastases of cancer into kidney**



**Urothelial carcinoma of the urinary bladder  
with exophytic, papillary growth  
(infarction in prostate)**

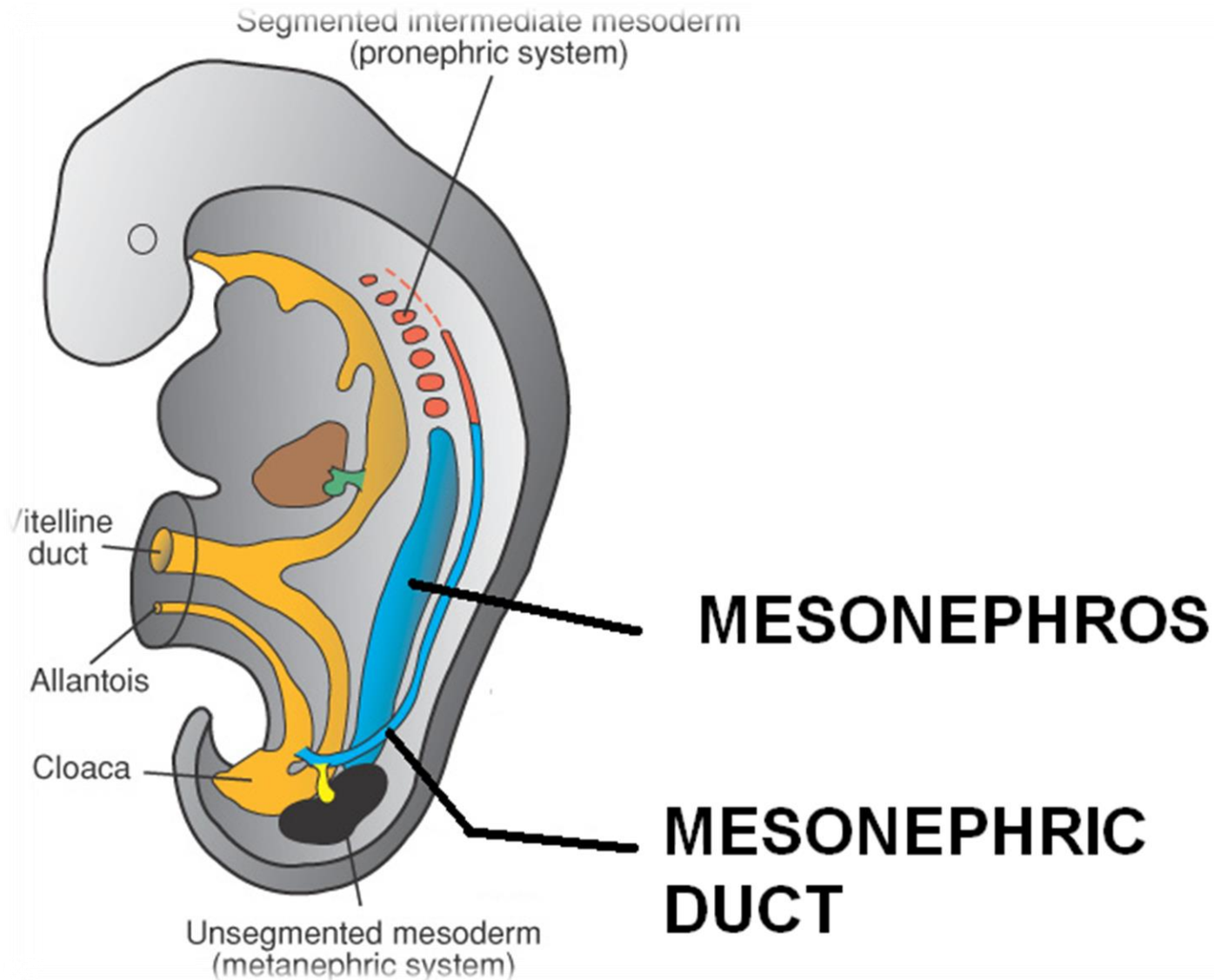
**MORE ACCURATELY  
BUT LESS POETICALLY,  
HUMAN *KIDNEYS*  
SERVE TO CONVERT  
MORE THAN 1700  
LITERS OF BLOOD PER  
DAY INTO ABOUT 1  
LITER OF URINE**

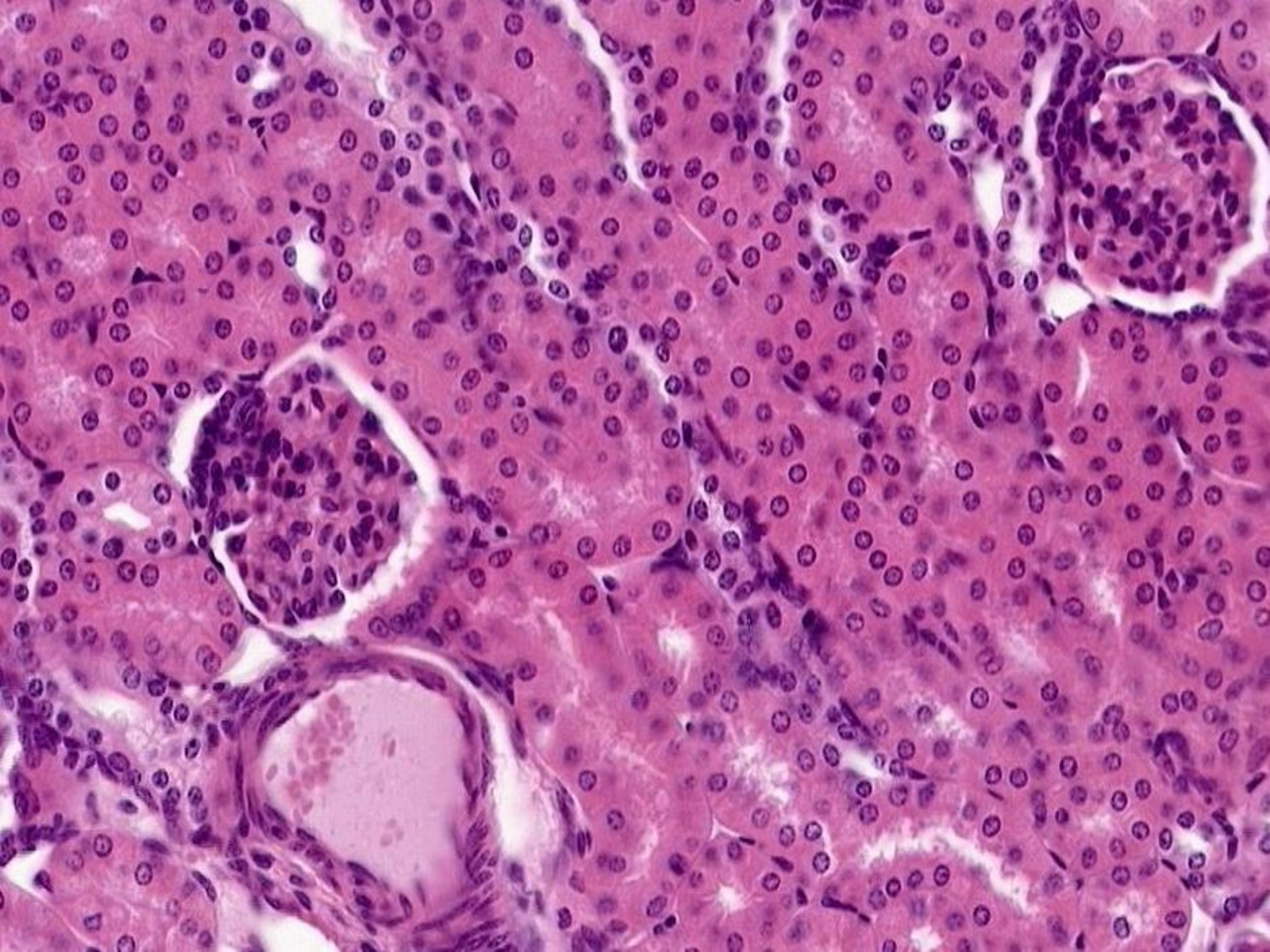


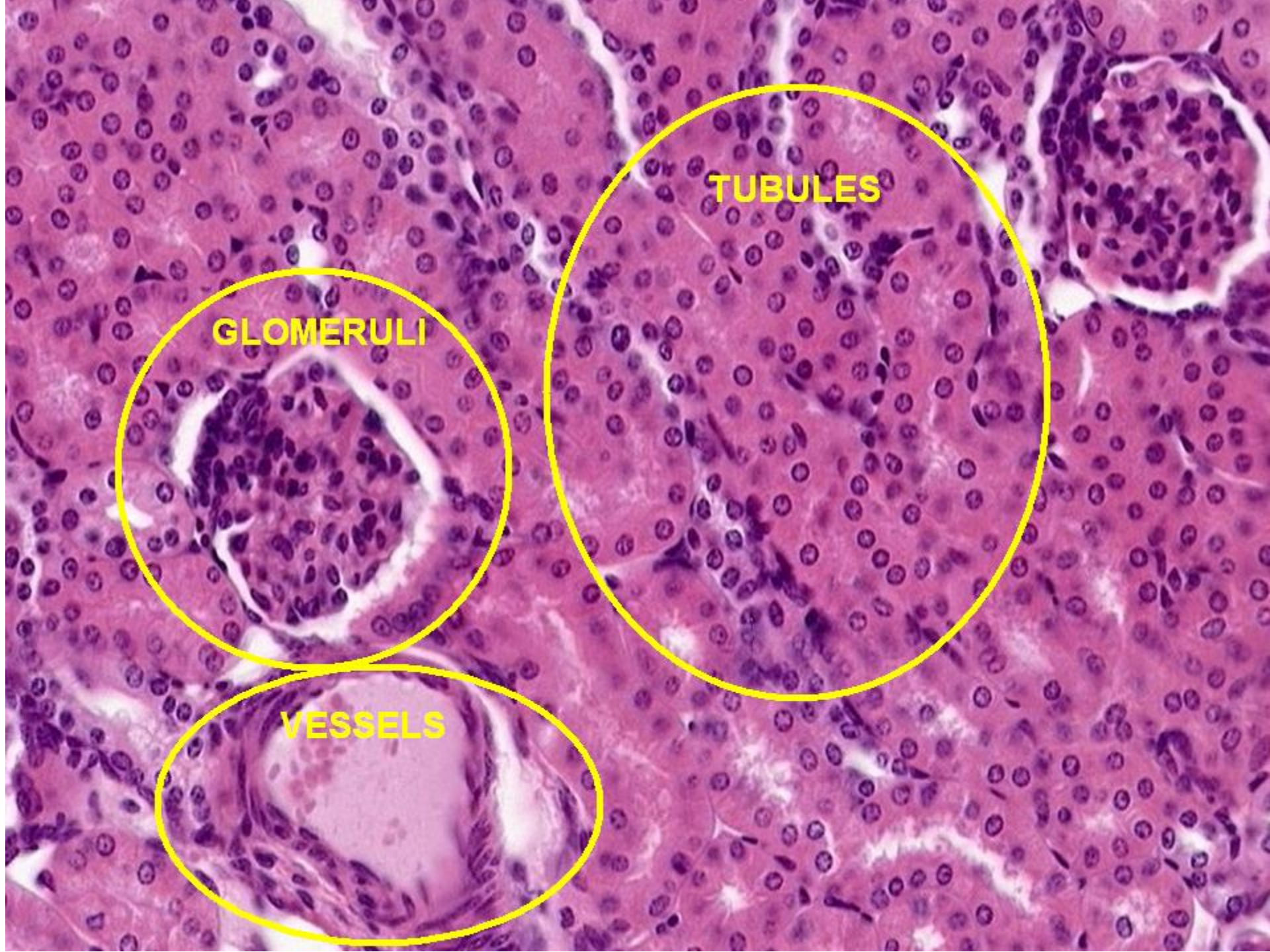
GLOMERULUS (HUMAN);  
H. & E. STAIN, X 350  
P=PROXIMAL TUBULE  
D=DISTAL TUBULE  
J=JUXTAGLOMERULAR  
CELLS



The human kidney is a product of the **metanephric** system.



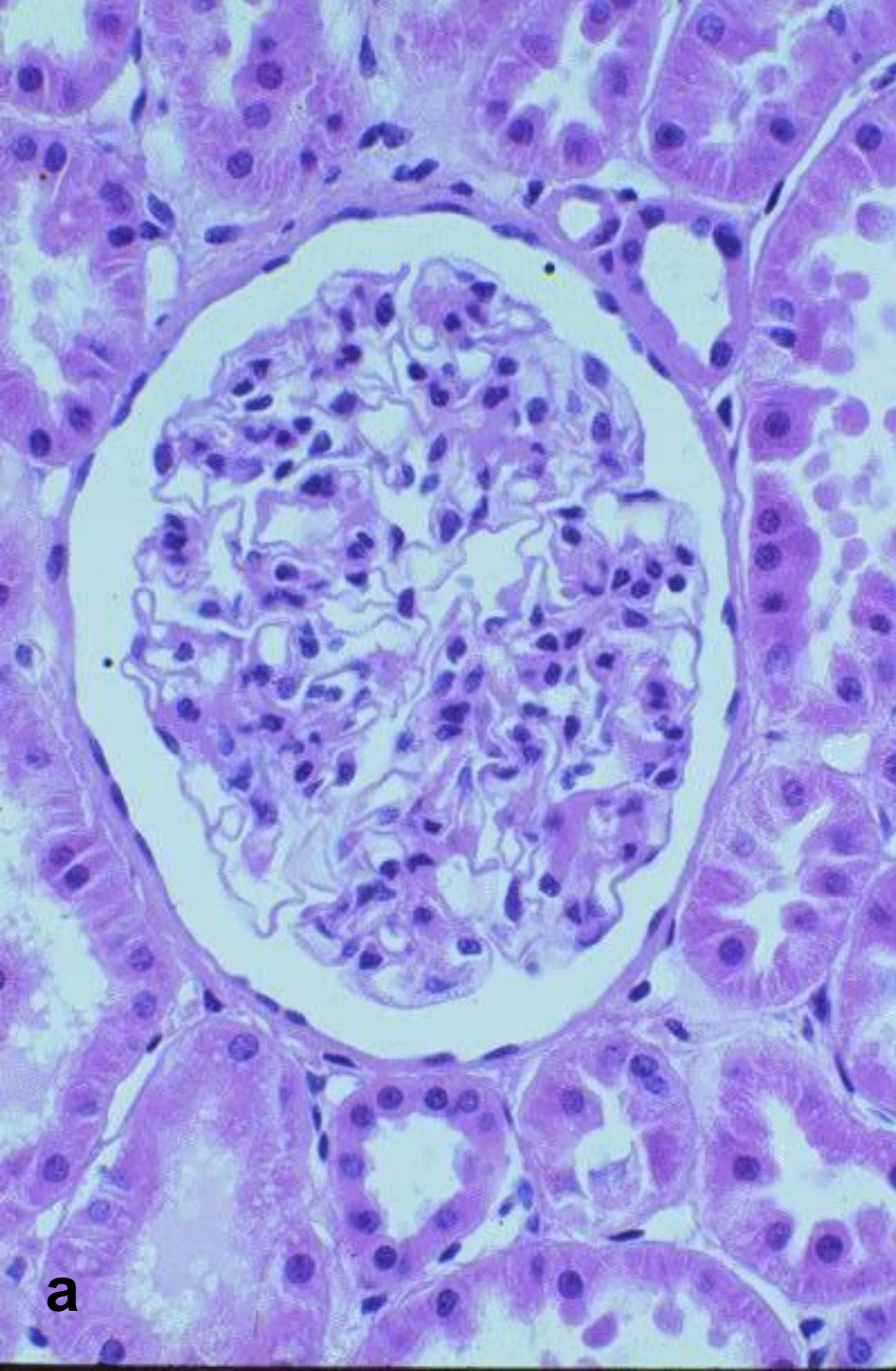




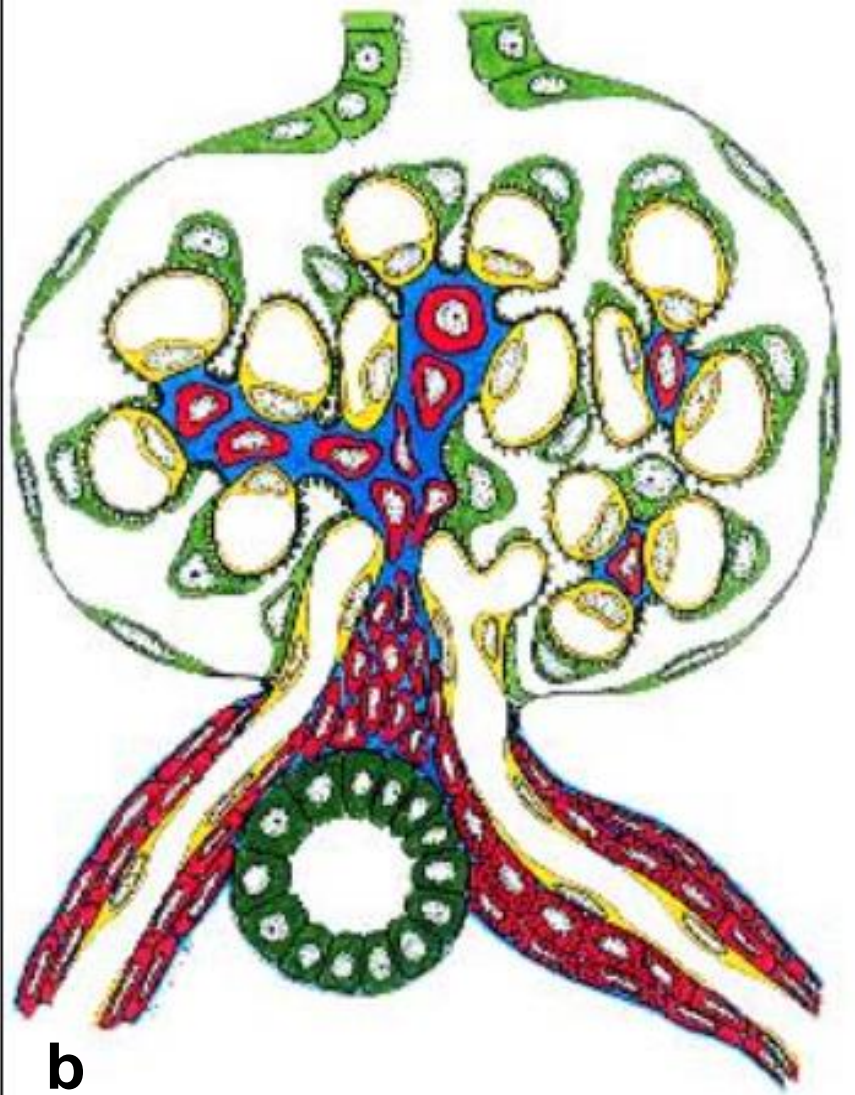
**TUBULES**

**GLOMERULI**

**VESSELS**

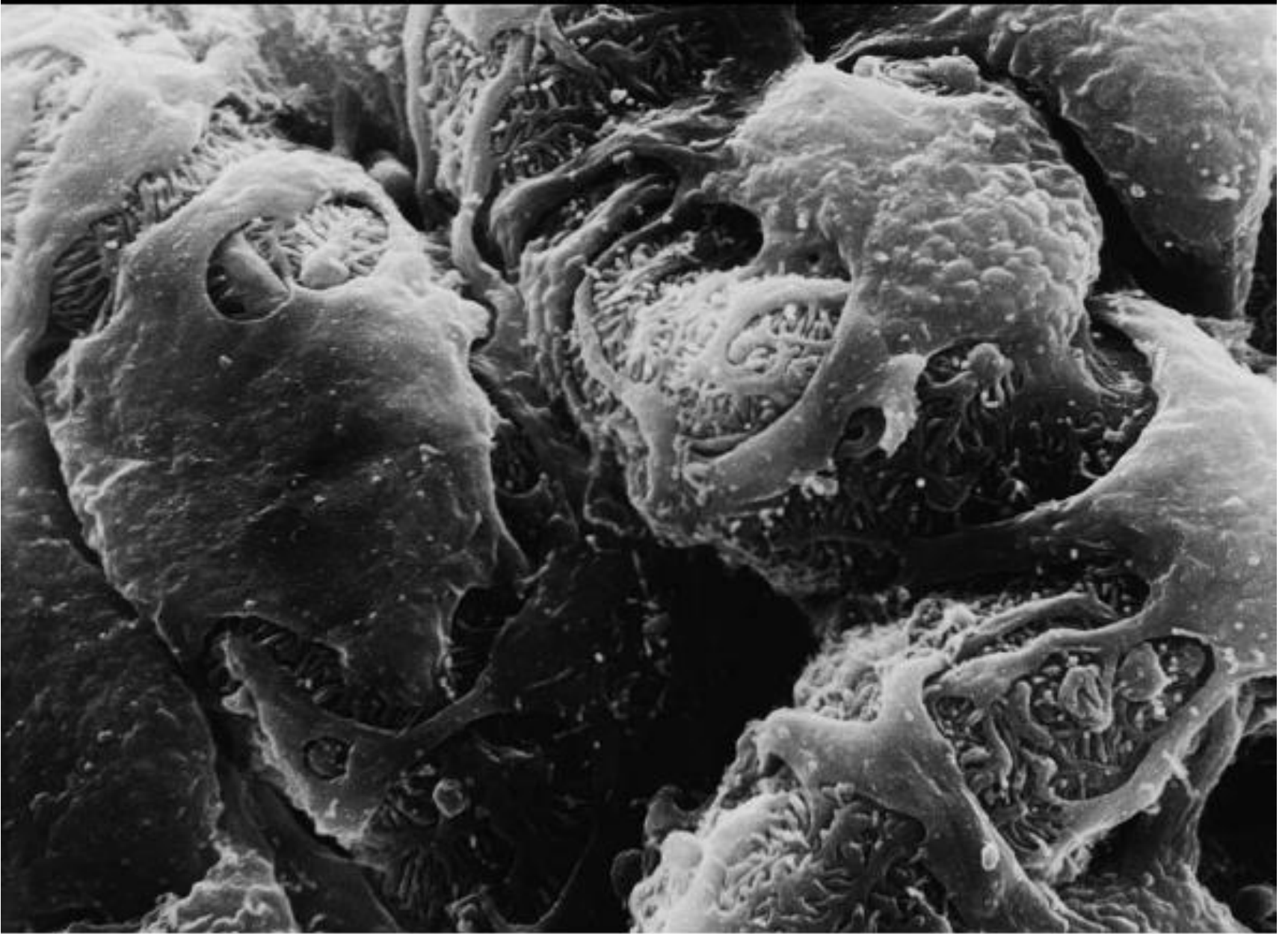


a

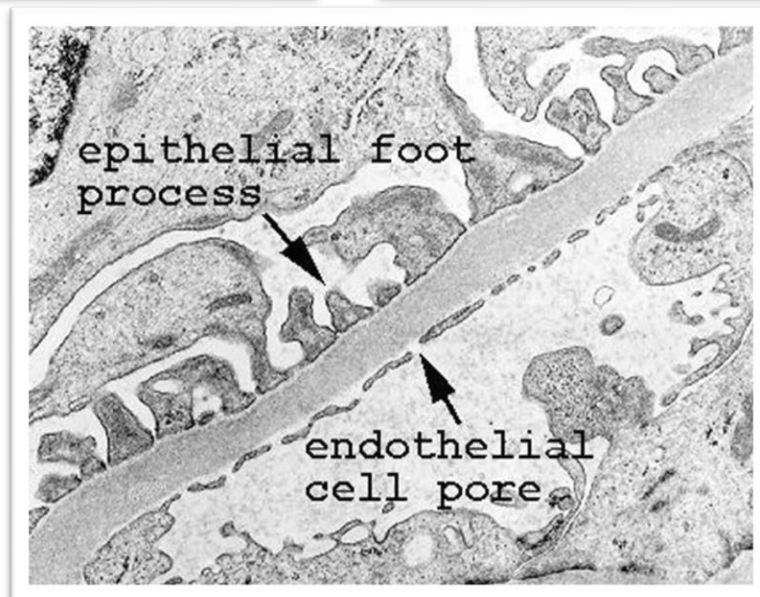
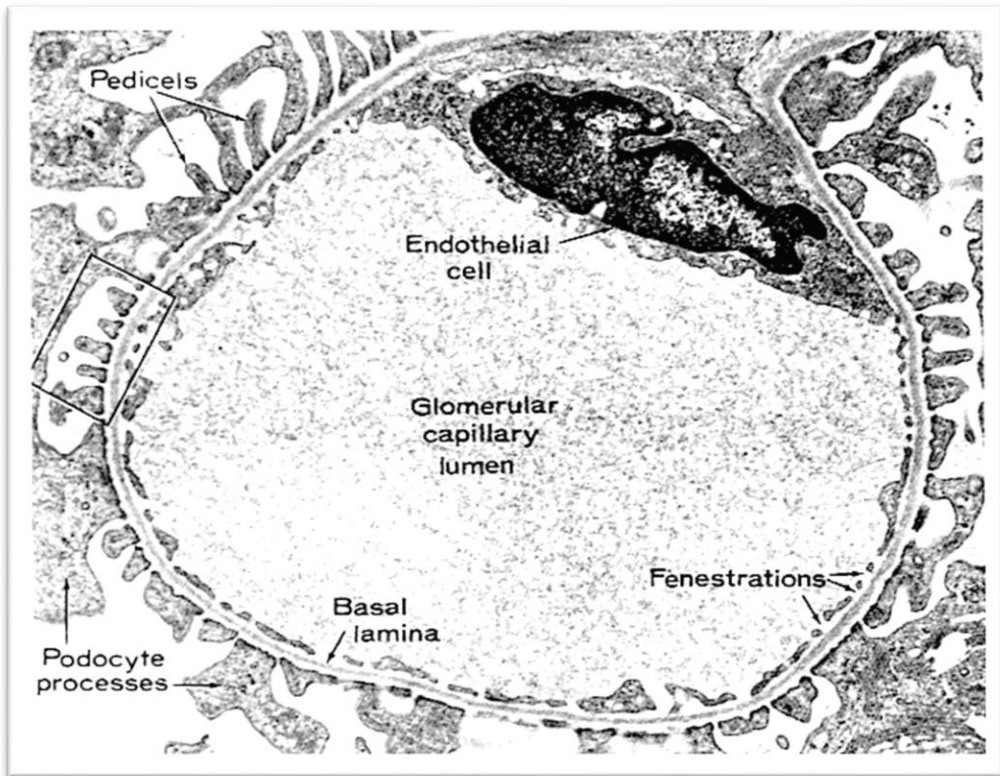
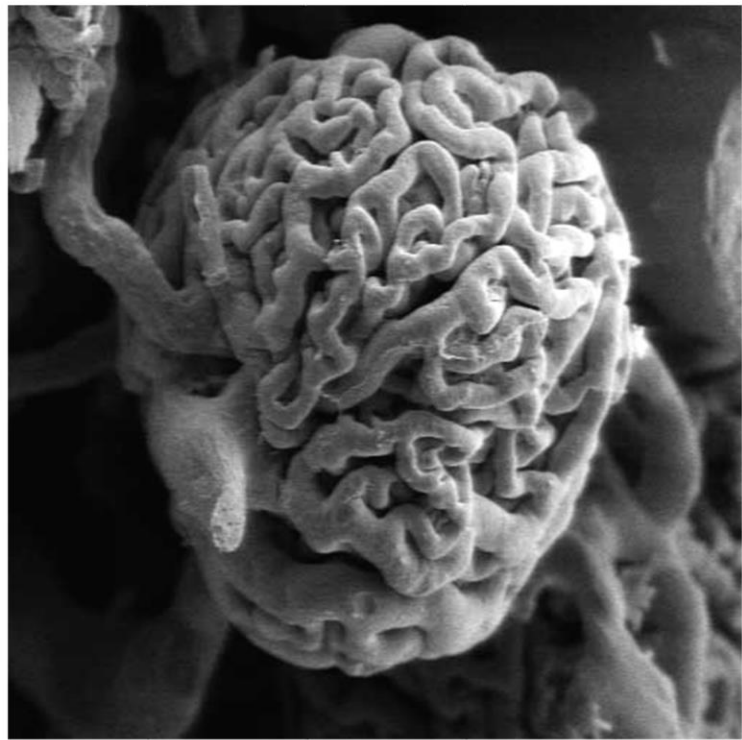


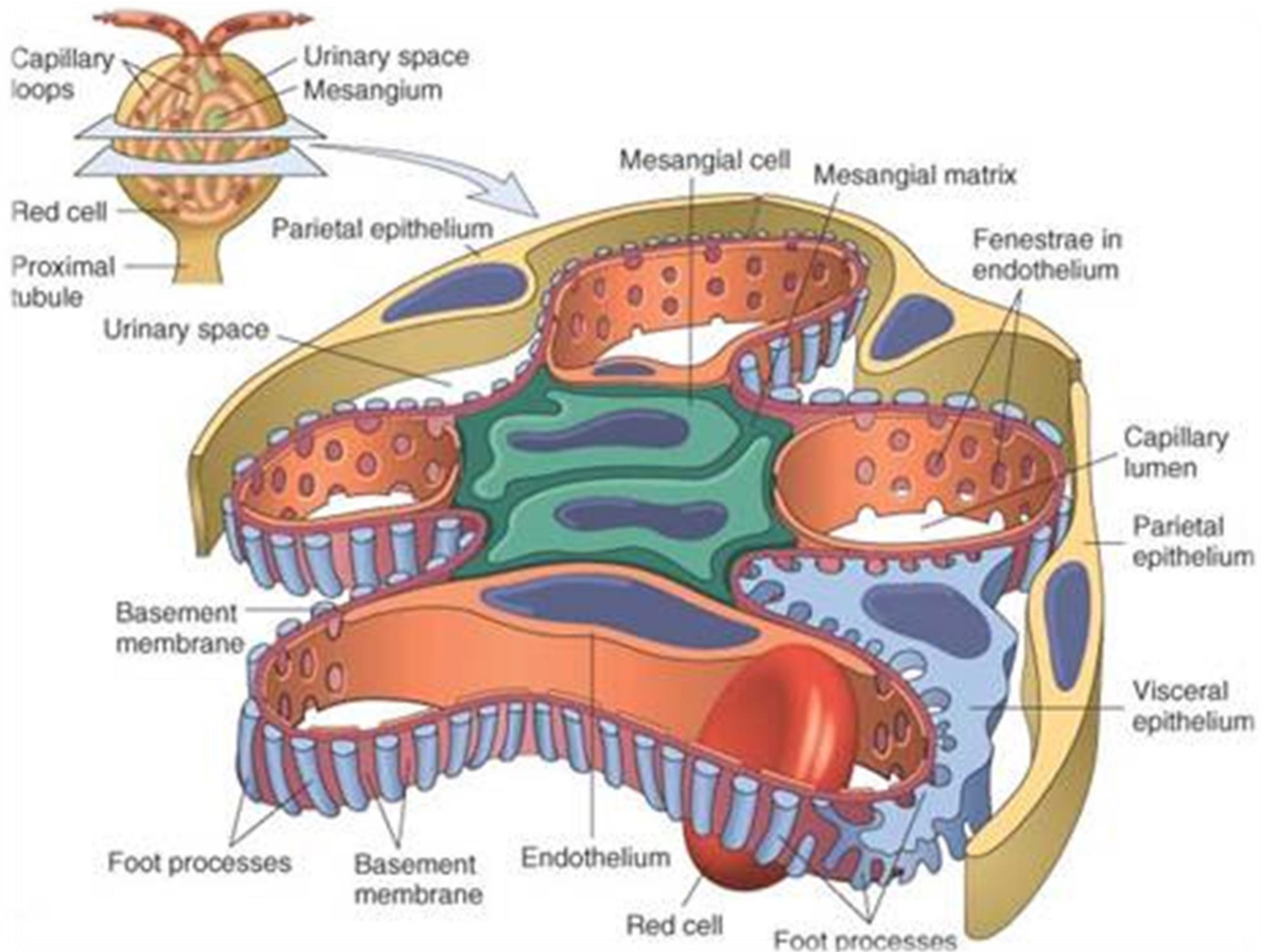
b

**a - Normal glomerulus;**  
b – diagram (*podocyte*,  
*endotheliocyte*, *mesangiocyte*,  
*mesangial matrix*)



**Capillary loops covered with epithelial cells  
(scanning electron microscopy)**





# RENAL PATHOLOGY

- **CONGENITAL**
- **“CYSTS”**
- **GLOMERULAR**
- **TUBULAR/INTERSTITIAL**
- **BLOOD VESSELS**
- **OBSTRUCTION**
- **TUMORS**



# CONGENITAL

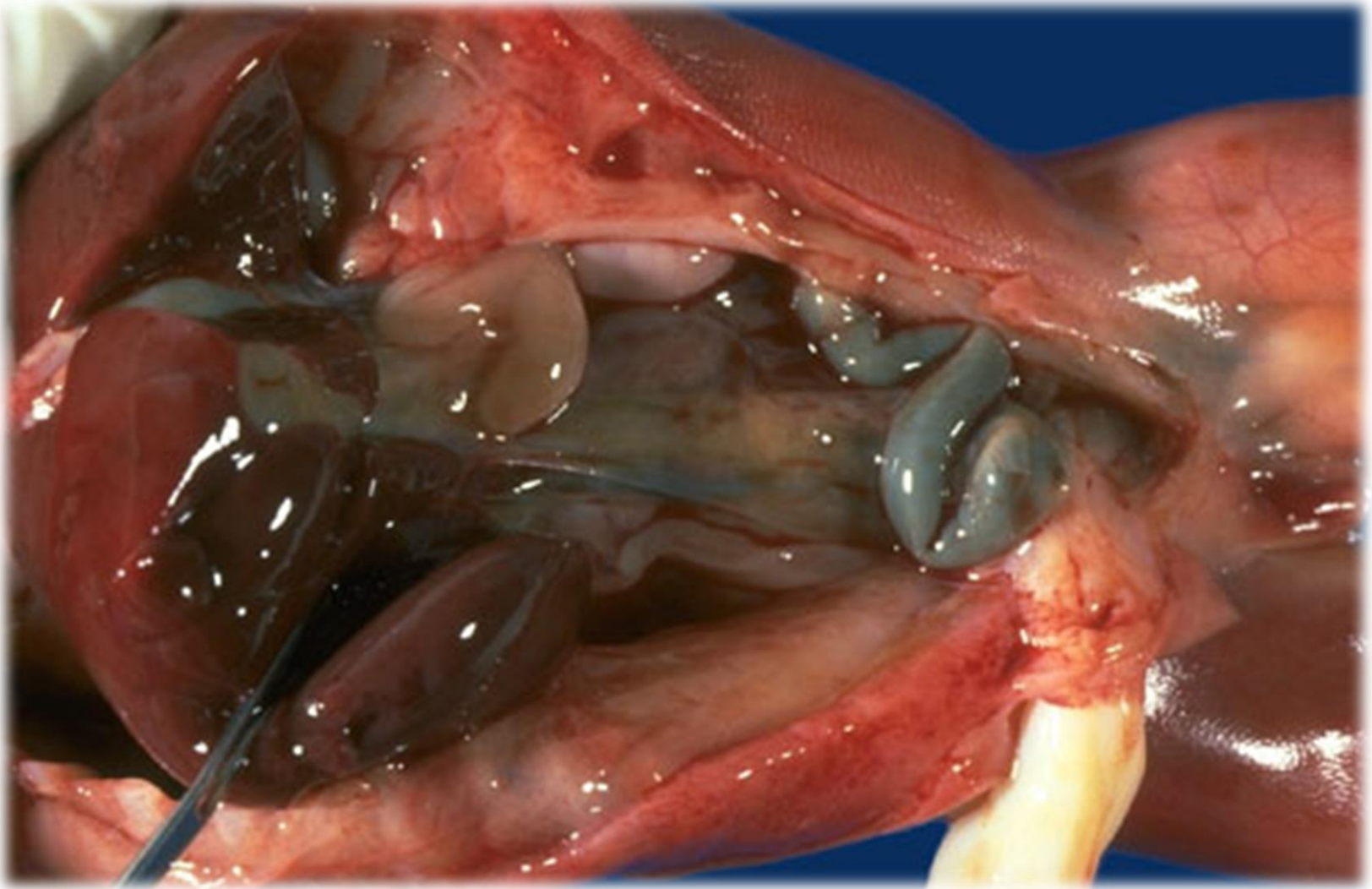
◎ **AGENESIS**

◎ **HYPOPLASIA**

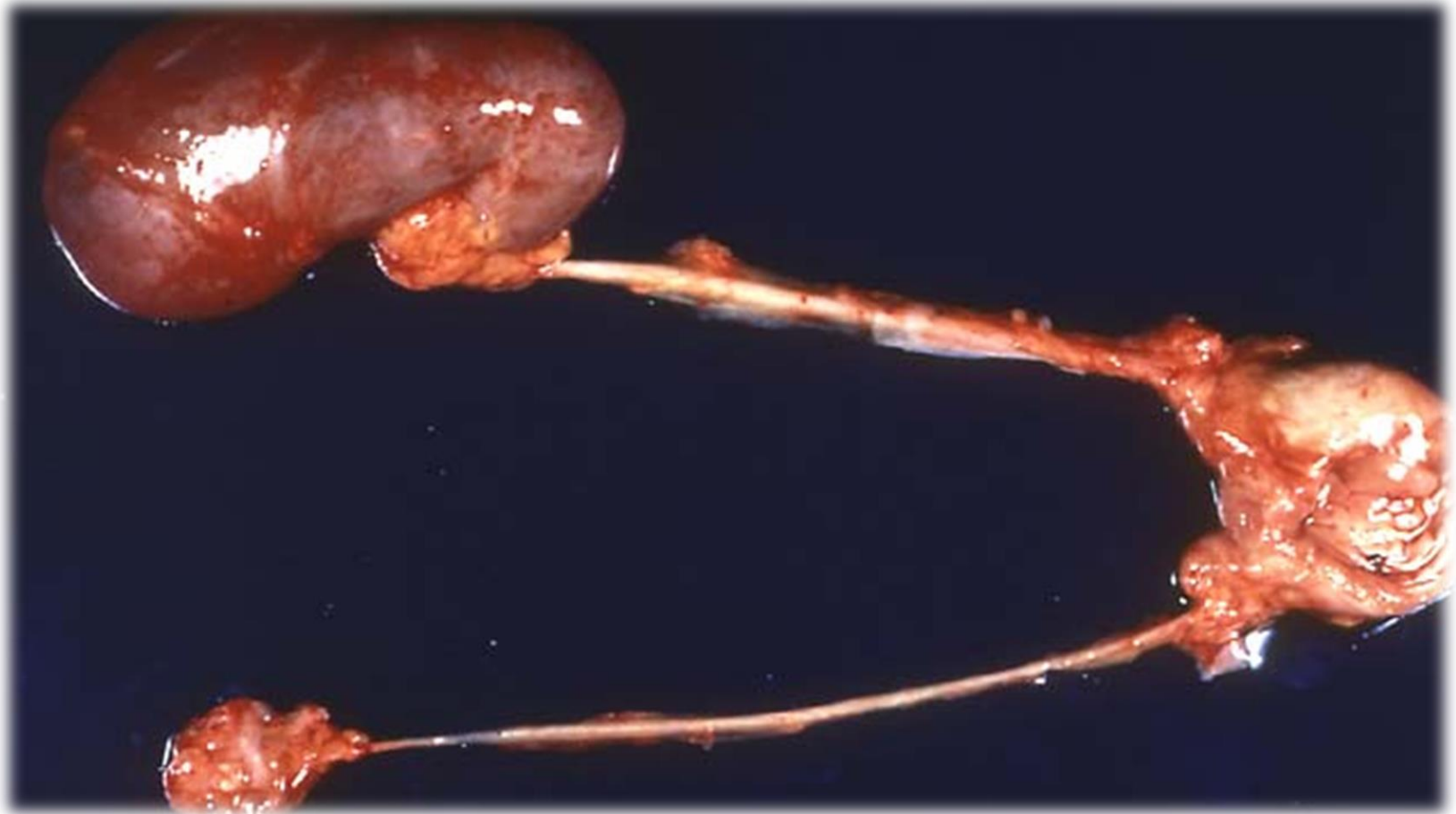◎ **ECTOPIC**

◎ **HORSESHOE**

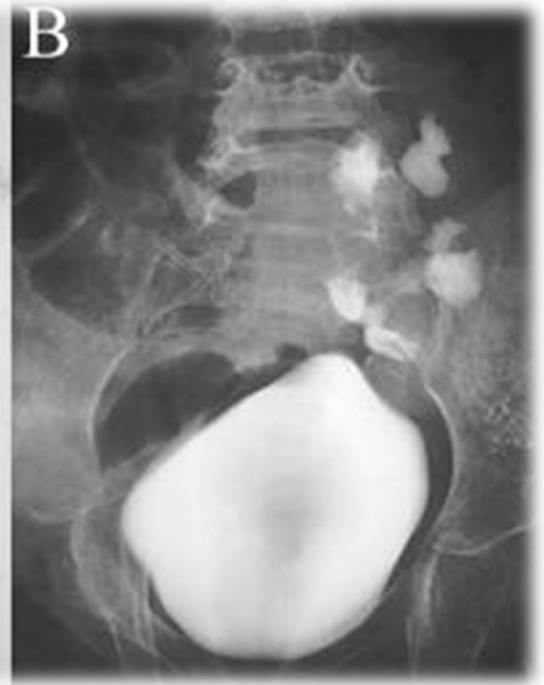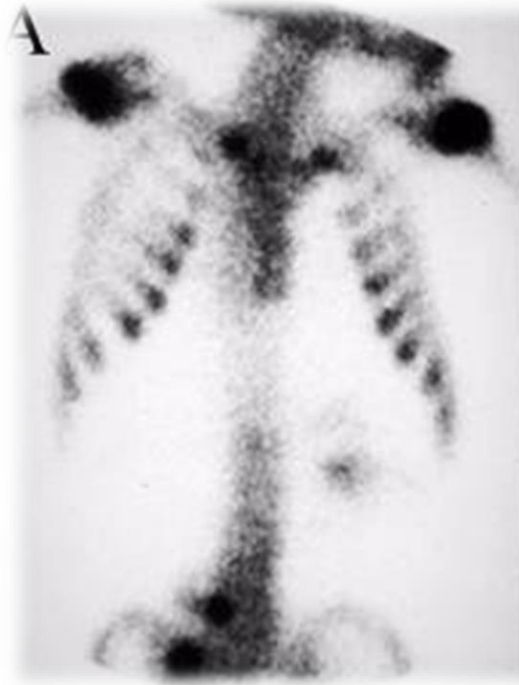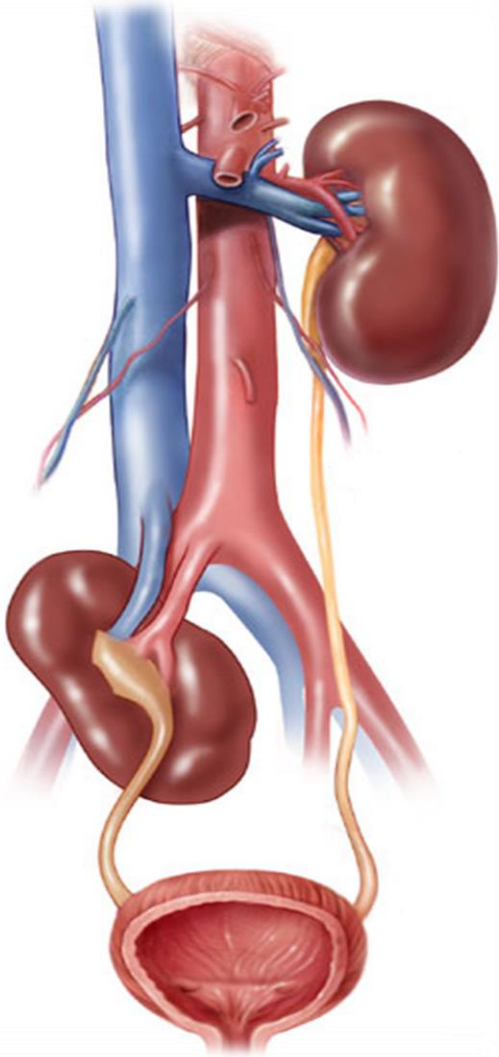
# AGENESIS



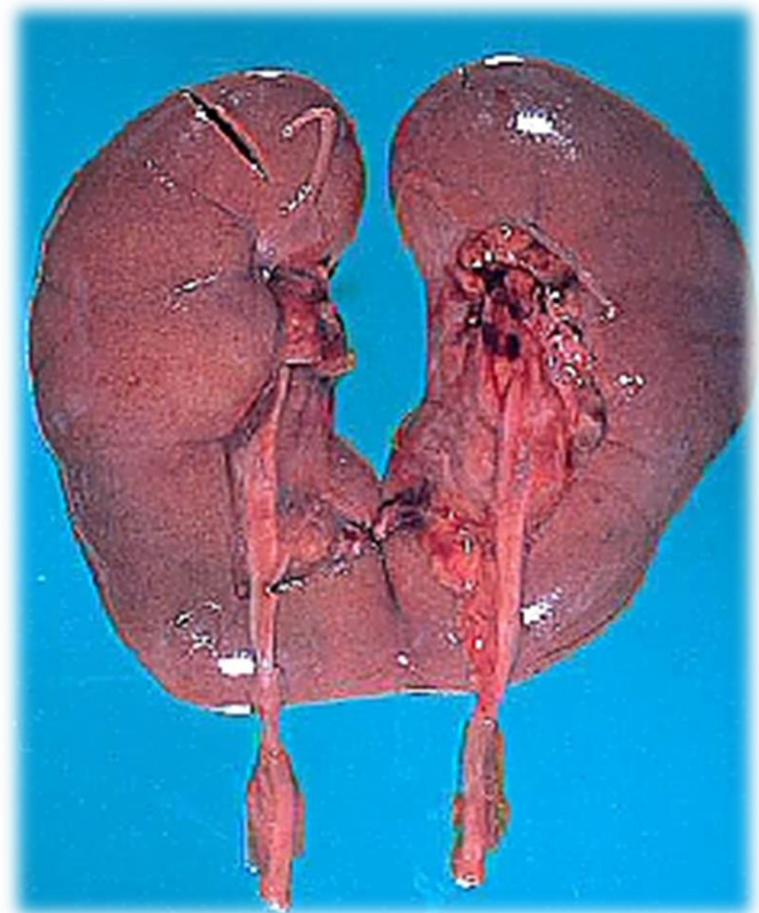
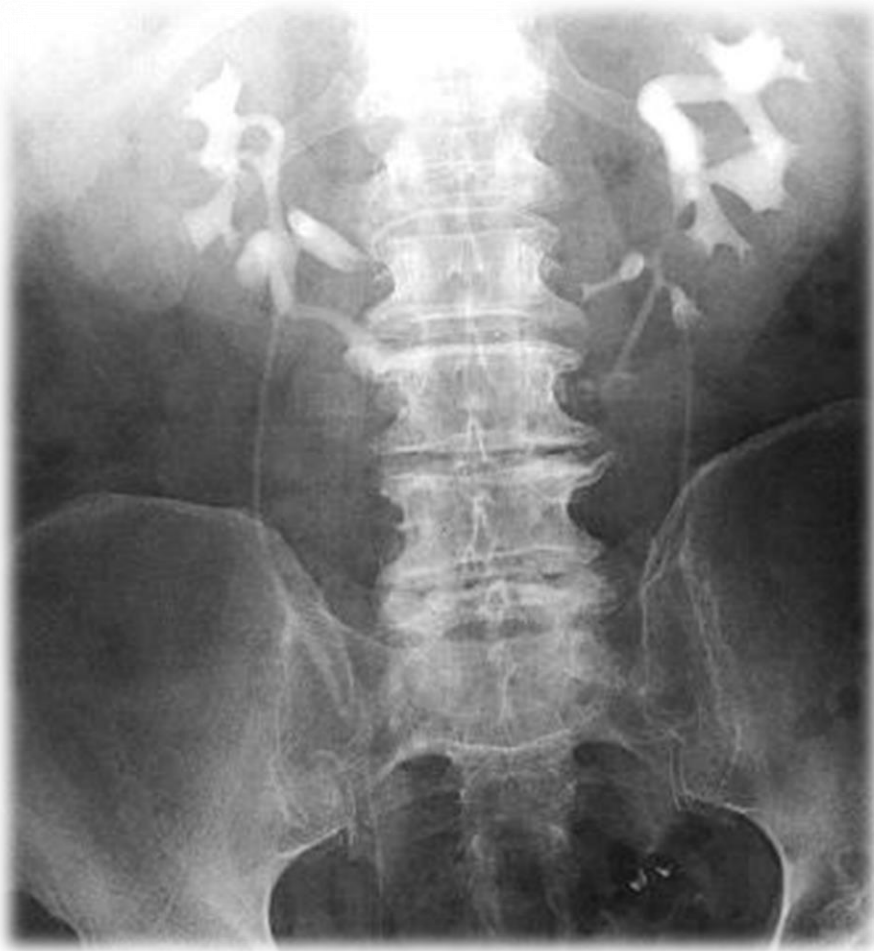# HYPOPLASIA



# ECTOPIC (usually PELVIC)



# HORSESHOE



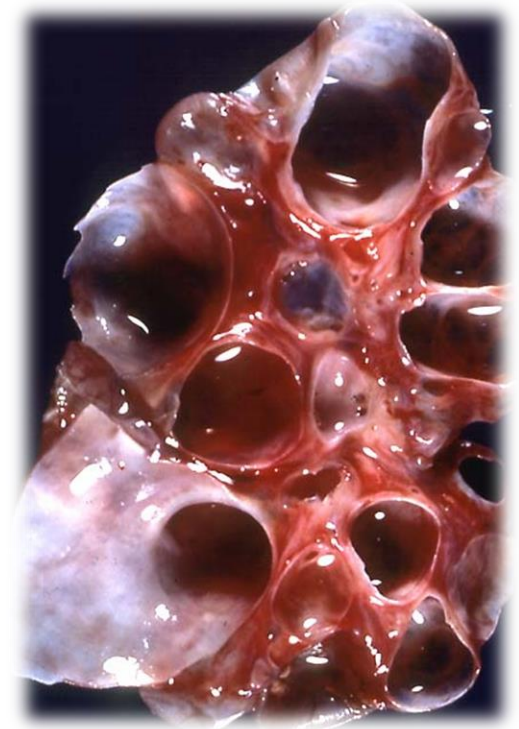
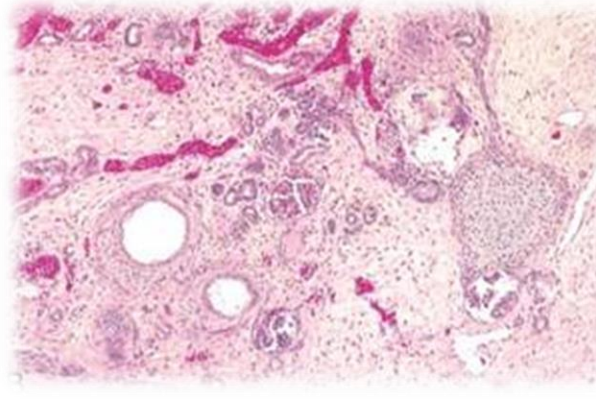
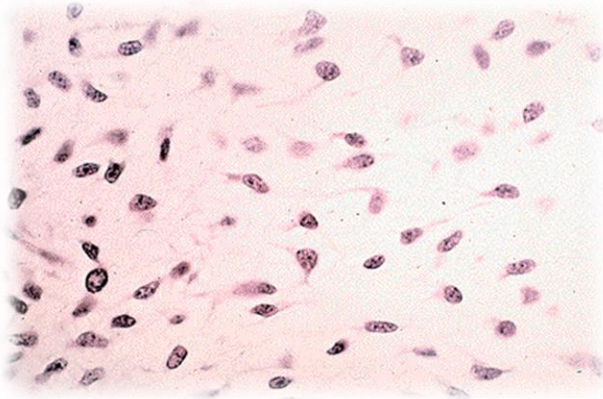
# CYSTIC DISEASES

- CYSTIC RENAL “DYSPLASIA”
- Autosomal DOMINANT (AD-ULTS)
- Autosomal RECESSIVE (CHILDREN)
- MEDULLARY
  - Medullary Sponge Kidney (MSK)
- ACQUIRED
- SIMPLE

# CYSTIC RENAL “DYSPLASIA”

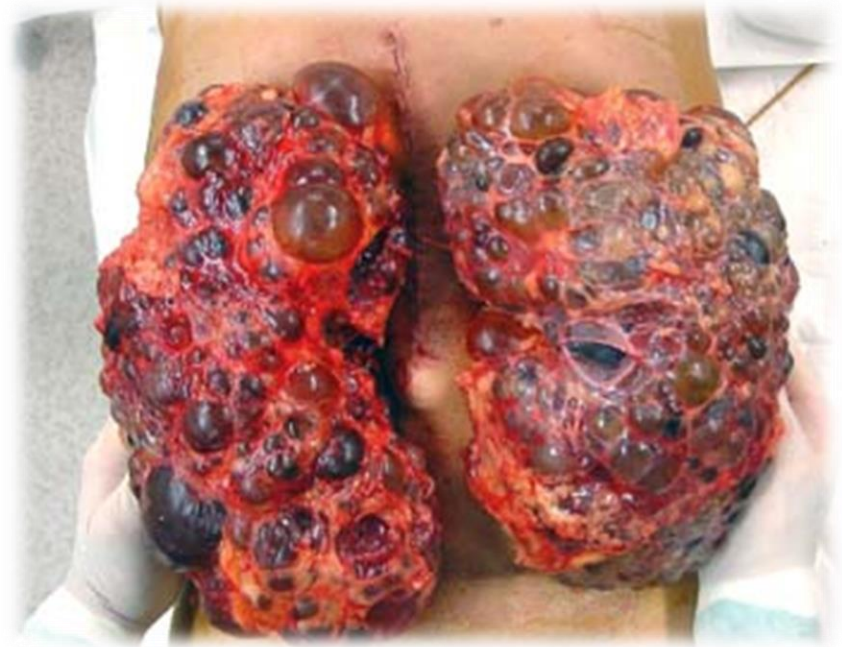
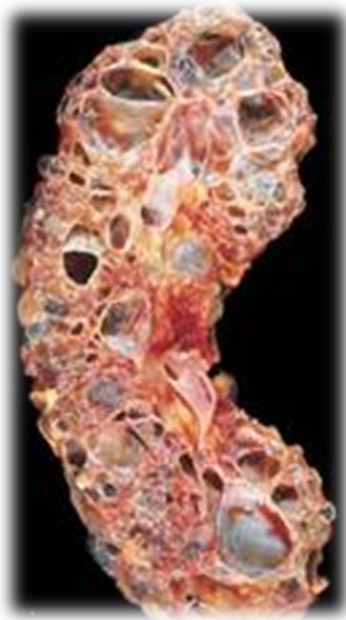
- ENLARGED
- UNILATERAL or BILATERAL
- CYSTIC
- Have “MESENCHYME”
- NEWBORNS
- VIRAL, GENETIC (rare)

Mutations in EYA1 or SIX1 genes have been associated with multicystic renal dysplasia.



# AUTOSOMAL DOMINANT

- HEREDITARY (ADPKD), chromosome – 16 PKD1 gene
- COMPLEX GENETICS
- RENAL FAILURE in 50's





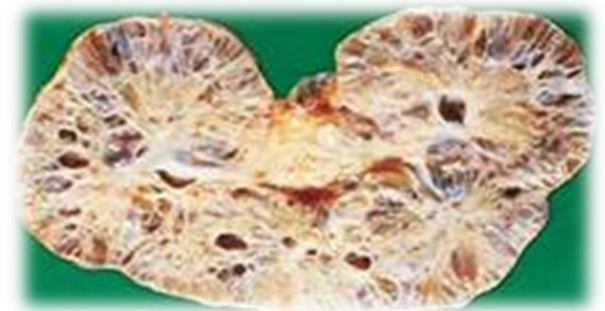# AUTOSOMAL RECESSIVE

◎ CHILDHOOD (ARPKD)

◎ KIDNEYS LOOK EXACTLY LIKE THE ADULT TYPE

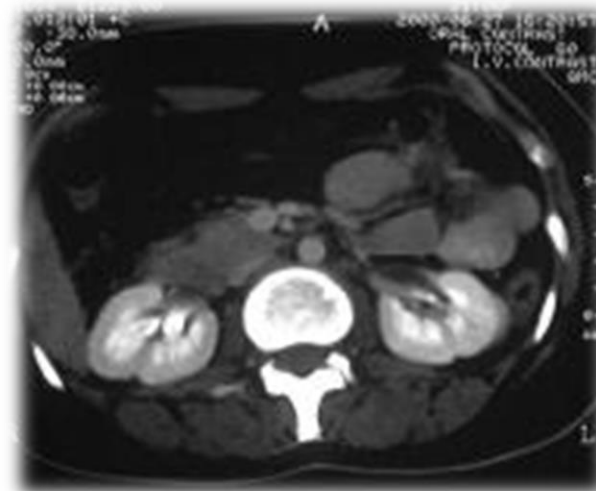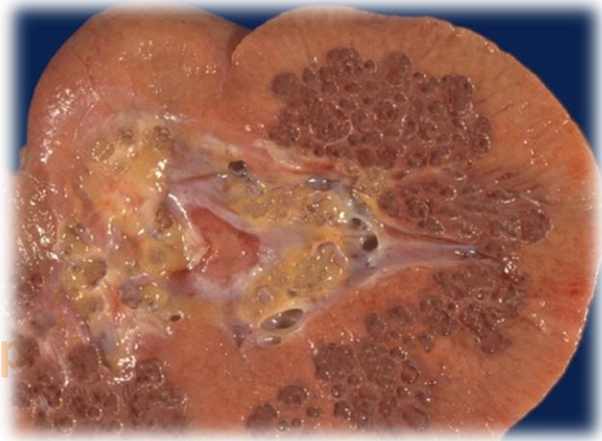
◎ PKHD1 chromosome – 6

◎ PATIENTS WHO SURVIVE OFTEN DEVELOP HEPATIC CYSTS



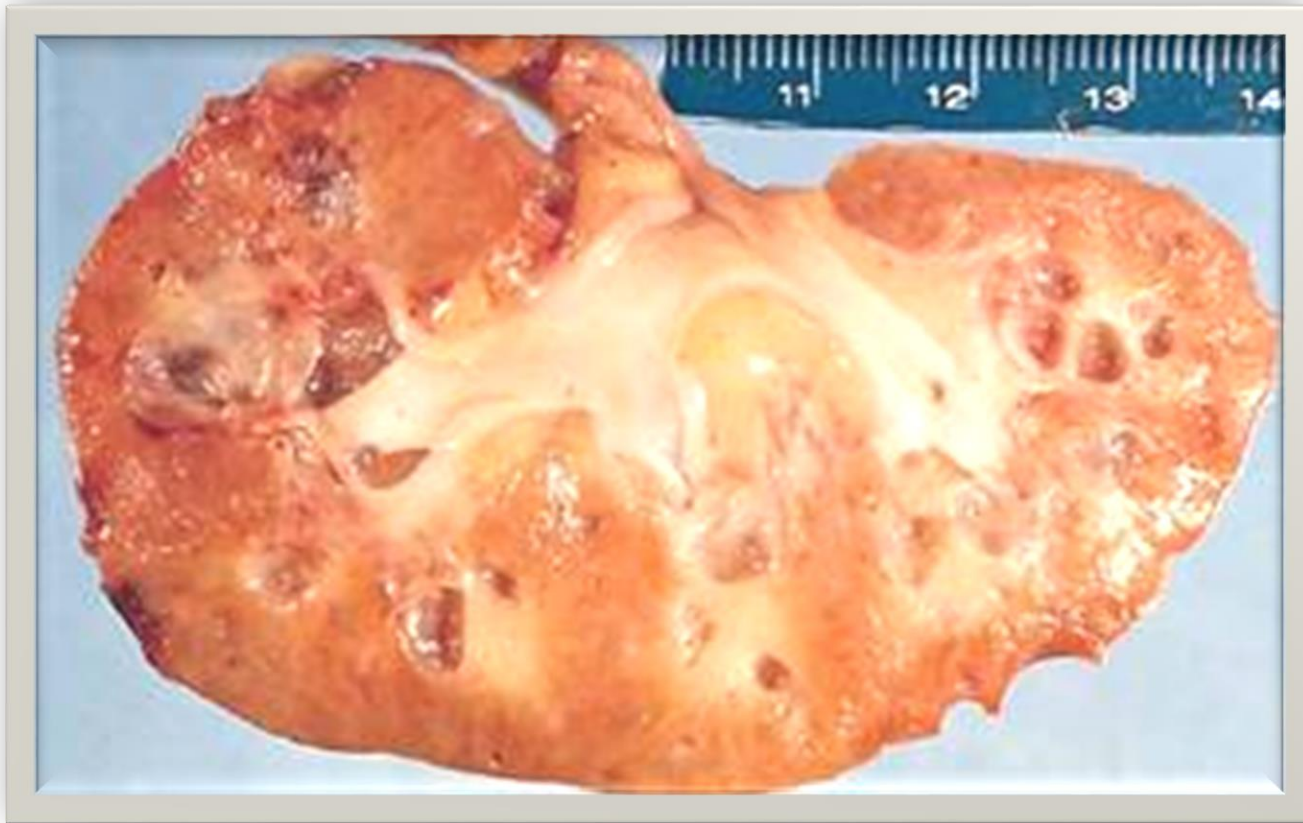
# MEDULLARY CYSTS

- MEDULLARY SPONGE KIDNEY (MSK), usually an incidental finding on CT or US



- Imp

# ACQUIRED (DIALYSIS)



# “SIMPLE” CYSTS

- Cortical
- Also called “retention” cysts
- Also “acquired”
- Incidental, asymptomatic
- VERY common

# MAJOR RENAL SYNDROMES

# NEPHROTIC SYNDROME

◎ **MASSIVE PROTEINURIA**

◎ **HYPOALBUMINEMIA**

◎ **EDEMA**

◎ **LIPIDEMIA/LIPIDURIA**

◎ **NUMEROUS CAUSES:**

- **MEMBRANOUS GN, MINIMAL CHANGE GN, FOCAL SEGMENTAL GS, MP GN,**
- **DIABETES, AMYLOIDOSIS, SLE, DRUGS (penicillins, heroin), INFECTIONS (malaria, syphilis, hepatitis B, AIDS, CARCINOMA, MELANOMA.**

# NEPHRITIC SYNDROME

- Macroscopic or microscopic hematuria
- Microscopic hematuria = observation of RBCs under the microscope
- Edema (mostly periorbital and also generalized)
- Oliguria (urine volume <400 ml/day)
- Hypertension (due to edema and oliguria)
- Mild to moderate proteinuria (<3.5 g/day) – usually in the non-nephrotic range (1-3g)





## **RAPIDLY PROGRESSIVE GLOMERULONEPHRITIS:**

It results in loss of kidney function in a few days or weeks and is manifested by an active sediment in the urine (hematuria with dysmorphic erythrocytes)

## **ACUTE RENAL INSUFFICIENCY:**

is dominated by oliguria or anuria with a recent onset of azotemia. This can result from glomerular insults such as (rapidly progressive glomerulonephritis with crescent, interstitial insults or acute tubular necrosis).

# UTI

it is characterized by bacteriuria and pyuria (bacteria and leukocytes in the urine). The infection can be symptomatic or asymptomatic and can affect the kidneys (pyelonephritis) or urinary bladder (cystitis).

## Nephrolithiasis

is manifested by renal colic and hematuria.

# CHRONIC RENAL FAILURE

***Fluid and Electrolytes:*** Edema, Hyperkalemia, Metabolic acidosis

***Calcium Phosphate and Bone:*** Hyperphosphatemia, Hypocalcemia, Secondary hyperparathyroidism, Renal osteodystrophy

***Hematologic:*** Anemia, Bleeding diathesis

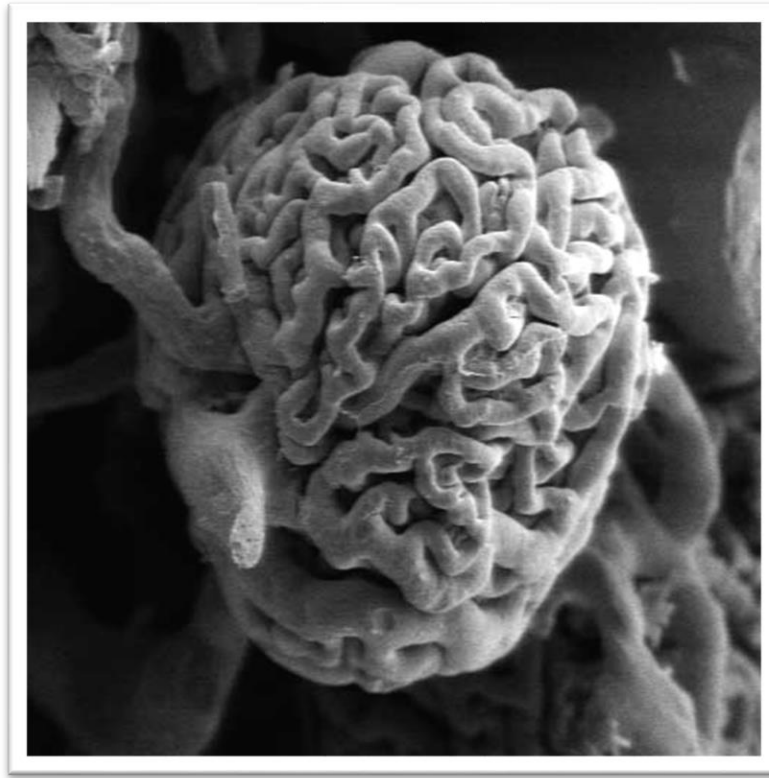
***Cardiopulmonary:*** Hypertension, Congestive heart failure, Pulmonary edema, Uremic pericarditis

***Gastrointestinal:*** Nausea and vomiting, Bleeding, Esophagitis, gastritis, colitis

***Neuromuscular:*** Myopathy, Peripheral neuropathy, Encephalopathy

***Dermatologic:*** **Sallow** (greenish-yellow) color, Pruritus, Dermatitis

# GLOMERULAR DISEASES

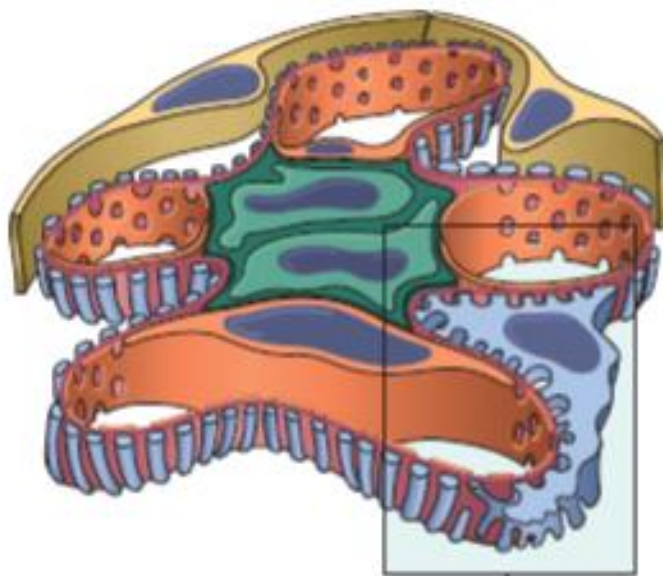


# PATHOGENESIS

- ⦿ Antibodies against inherent GBM
- ⦿ Antibodies against “planted” antigens
- ⦿ Trapping of Ag-Ab complexes
- ⦿ Antibodies against glomerular cells, e.g., mesangial cells, podocytes, etc.
- ⦿ Cell mediated immunity, i.e., sensitized T-cells as in TB

# MEDIATORS

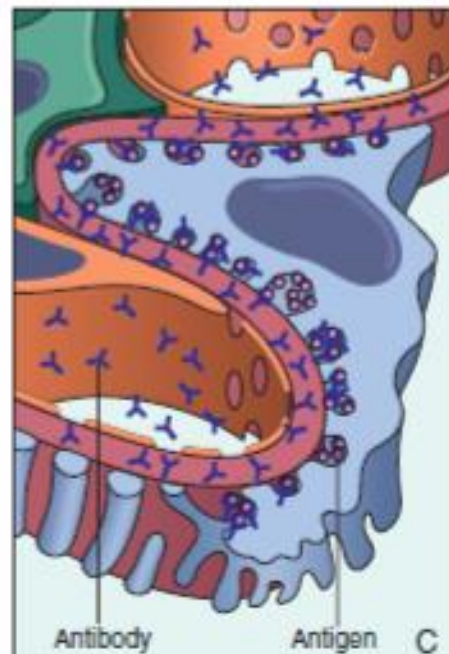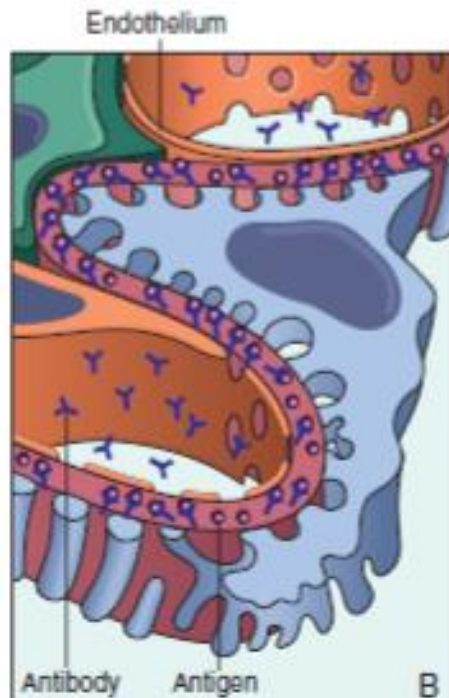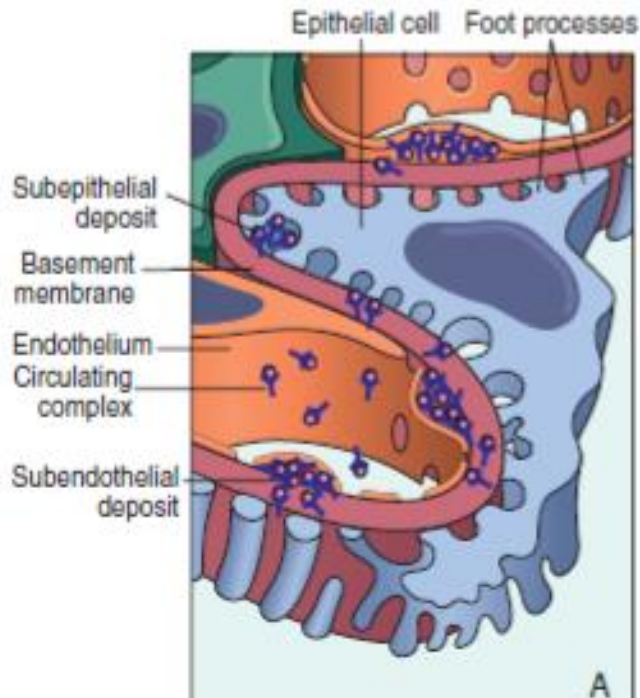
- NEUTROPHILS, MONOCYTES
- MACROPHAGES, T-CELLS, NK CELLS
- PLATELETS
- MESANGIAL CELLS
  
- SOLUBLE: CYTOKINES, CHEMOKINES,  
COAGULATION FACTORS



**CIRCULATING  
IMMUNE COMPLEX DEPOSITION**

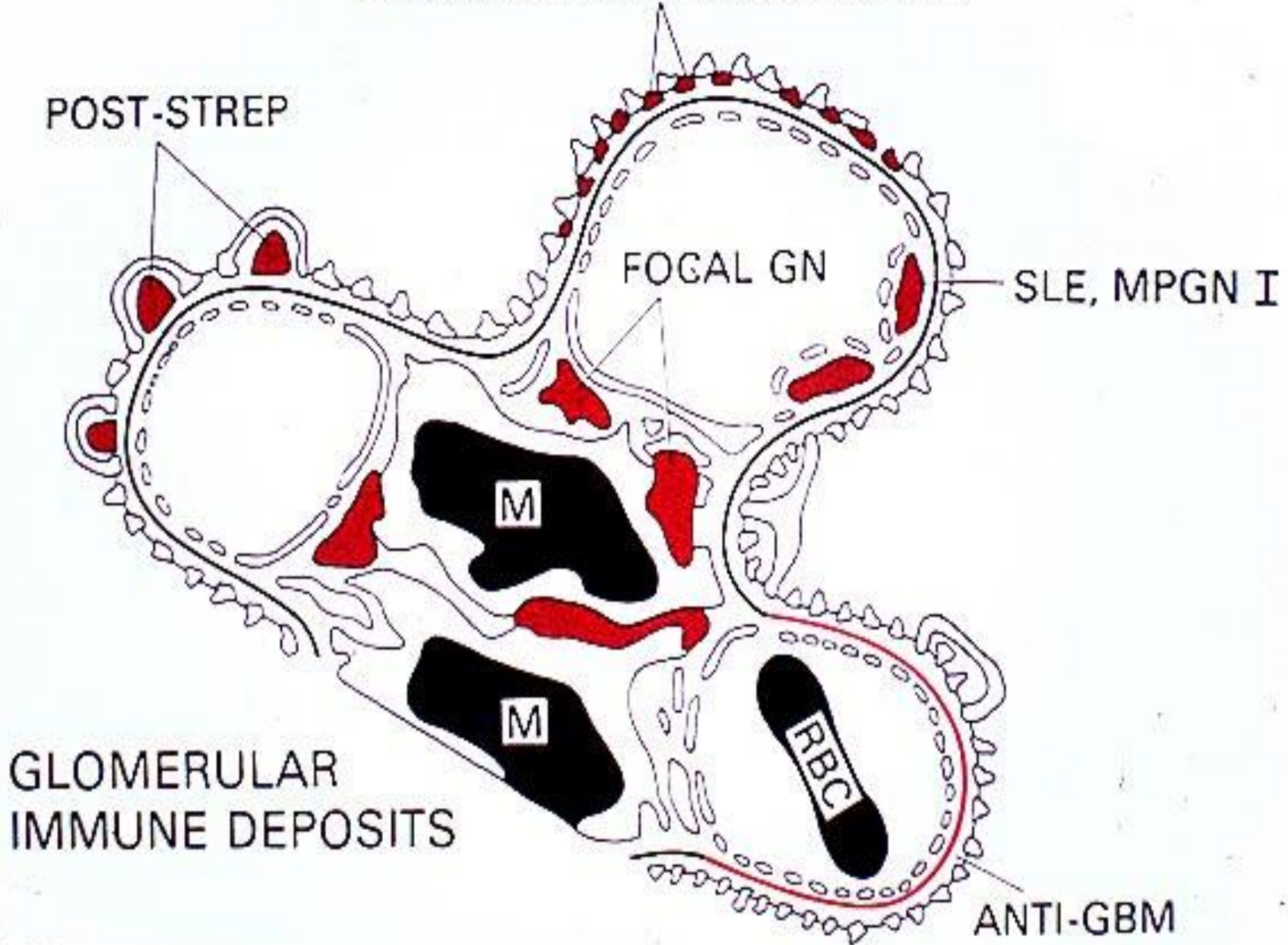
**IN SITU  
ANTI-GBM ANTIBODY**

**IN SITU  
ANTIBODY AGAINST  
GLOMERULAR ANTIGEN  
(MEMBRANOUS NEPHROPATHY)**



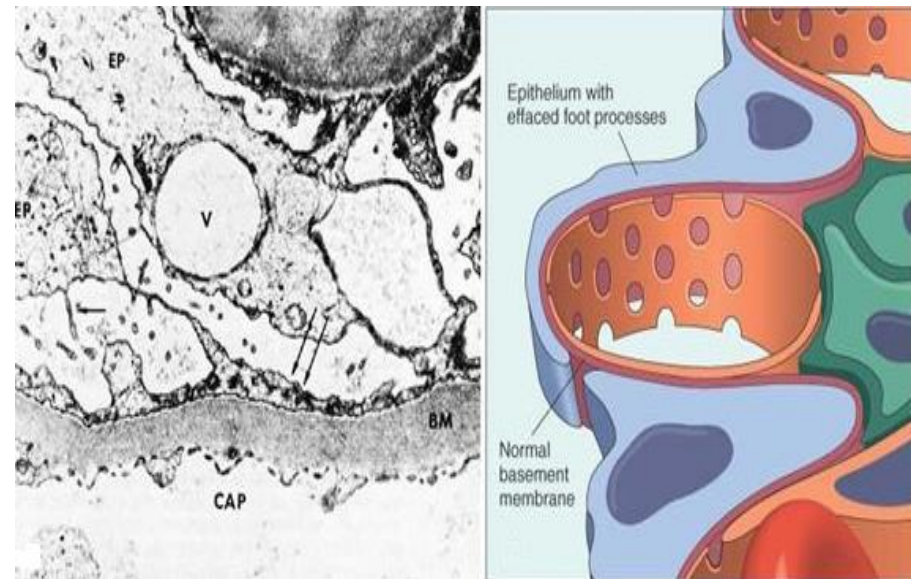
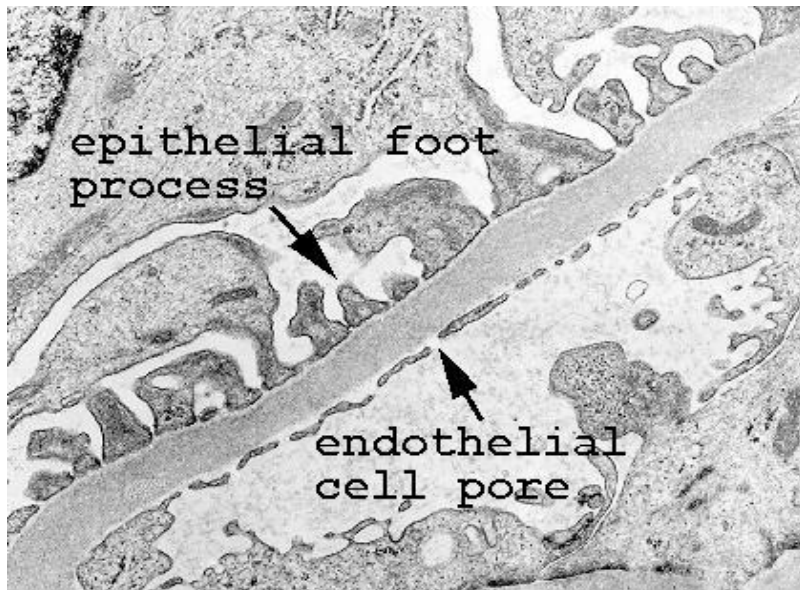


# MEMBRANOUS NEPHROPATHY

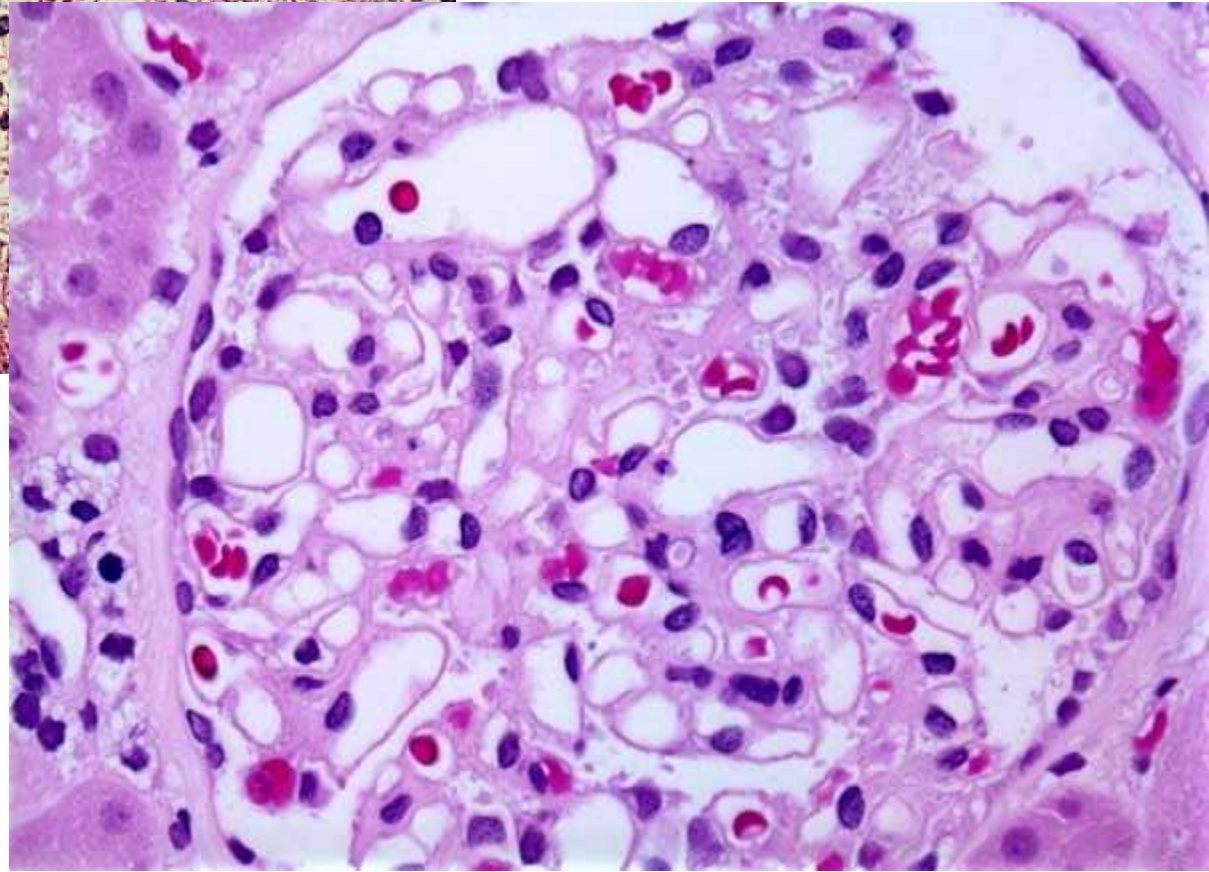
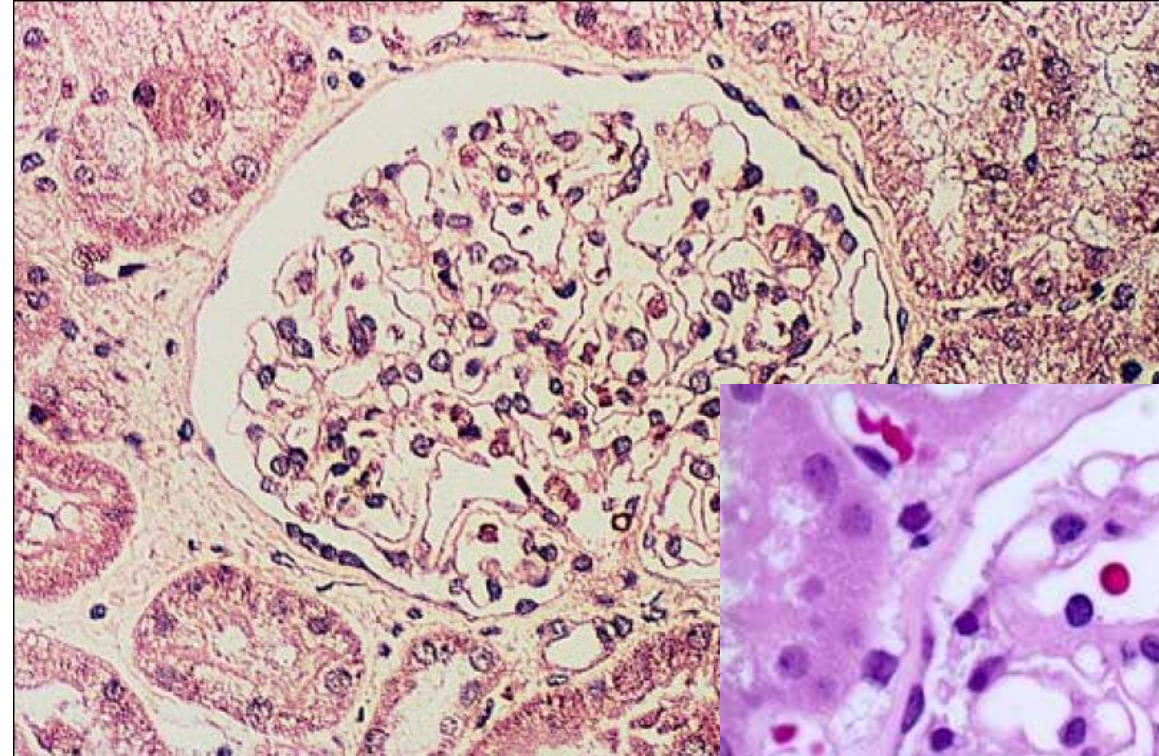


# MINIMAL CHANGE GLOM. (LIPOID NEPHROSIS)

- ⊙ MOST COMMON CAUSE of NEPHROTIC SYNDROME in CHILDREN
- ⊙ EFFACEMENT of FOOT PROCESSES



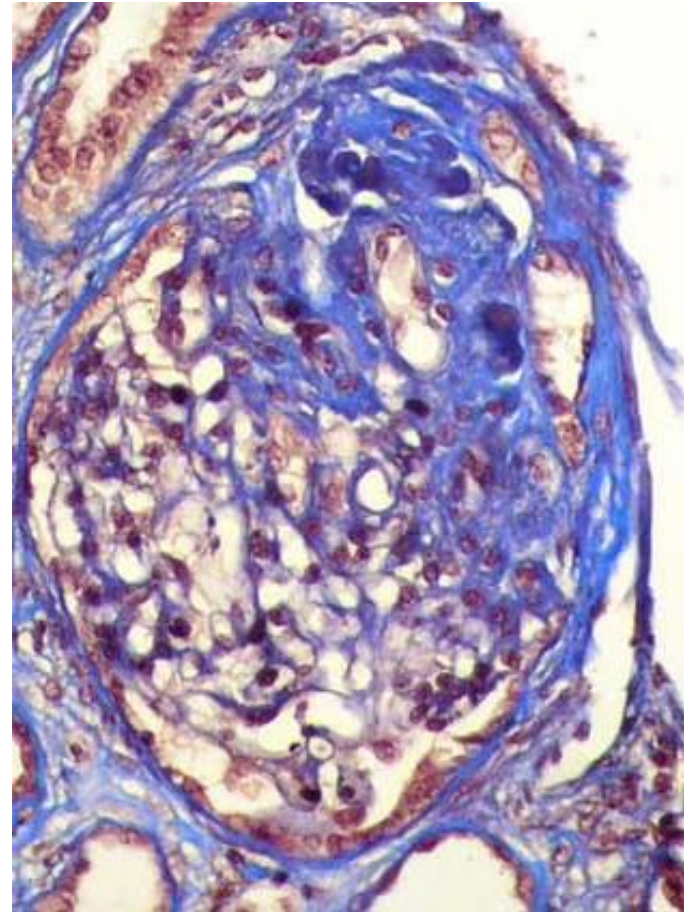
- Clinical signs. Despite pronounced proteinuria, renal function remains satisfactory, and hypertension and hematuria do not develop in most cases. Proteinuria is usually highly selective, the main filtered protein being albumin. The majority (> 90%) of children with minimally changing disease have a rapid response to corticosteroid therapy. However, proteinuria may recur, and some patients may develop or become resistance to corticosteroids. Despite these complications, the long-term prognosis of the disease is favorable and even hormonal forms dependent on the disease can be cured. The prognosis of the disease in adults is also favorable, despite the weaker effect of the therapy.



**The glomerulus in glomerulopathy with minimal changes, the absence of morphological changes in optical microscopy**

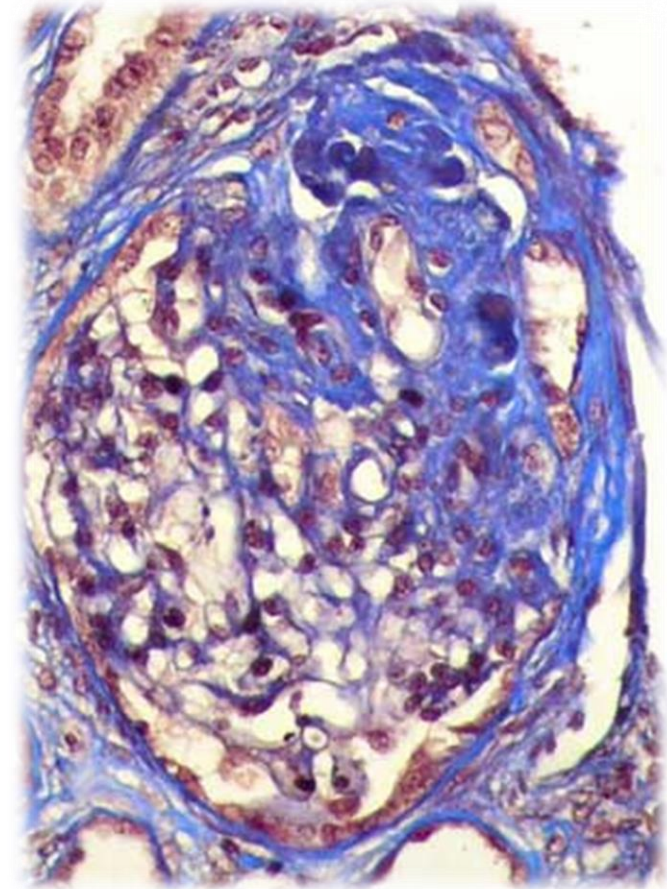
# FOCAL SEGMENTAL GLOMERULOSCLEROSIS

- **Just like its name**
  - **Focal**
  - **Segmental**
  - **Glomerulo-SCLEROSIS (NOT -itis)**
- **HIV, Heroine, Obesity**
- **Most common cause of ADULT nephrotic syndrome**



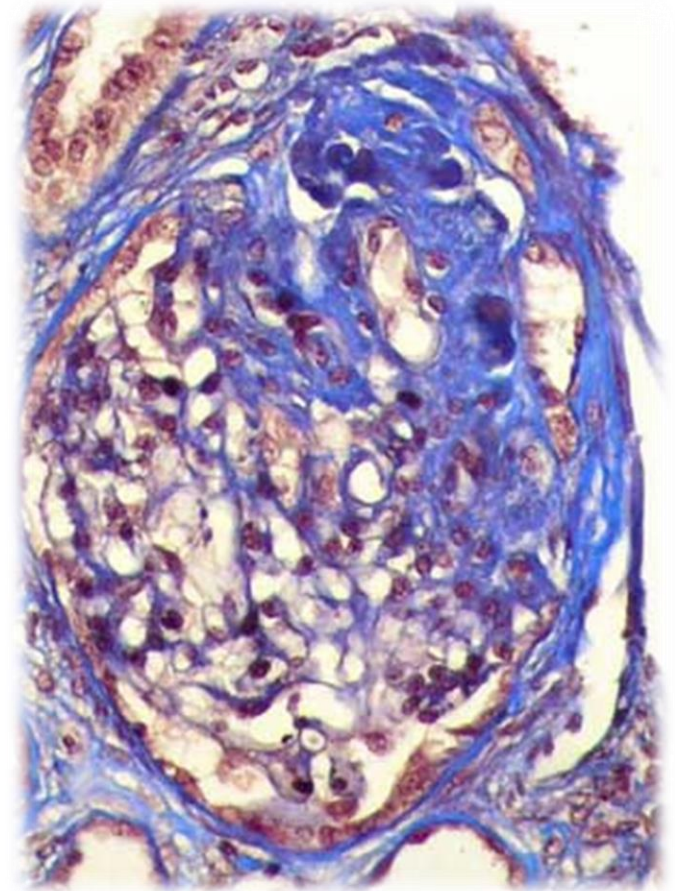
# FOCAL SEGMENTAL GLOMERULOSCLEROSIS

- In FSGS: (1) the frequency of hematuria is high, (2) proteinuria is more often non-selective; (3) poorer response to corticosteroid treatment; (4) progression to chronic nephropathy (at least 50% of patients develop terminal stage of chronic kidney disease within 10 years)



# FOCAL SEGMENTAL GLOMERULOSCLEROSIS

**Clinical signs.** In idiopathic FSGS, the likelihood of spontaneous regression is low, and the body's response to corticosteroid therapy is variable. In general, the prognosis in children is better than in adults. The progression of renal failure occurs at different rates. In approximately 20% of patients, an unusually rapid course of the disease with uncontrolled massive proteinuria and development of renal failure within 2 years is observed. After kidney transplantation, recurrence occurs in 25-50% of cases.



# Membranous nephropathy

- moderate, but > 60% persistent proteinuria
- 15% progress with nephrotic syndrome
- develops at 30-50 years old
- morphologically diffuse thickening of capillary walls in late stages.
- is characterized by the presence of subepithelial immunoglobulin deposits throughout GBM

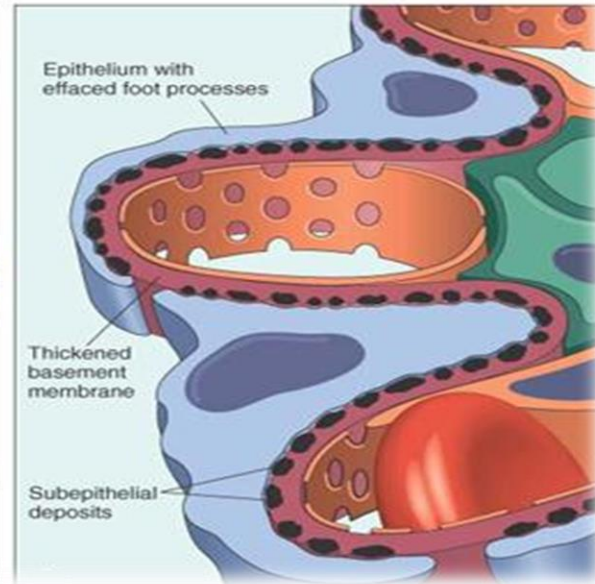
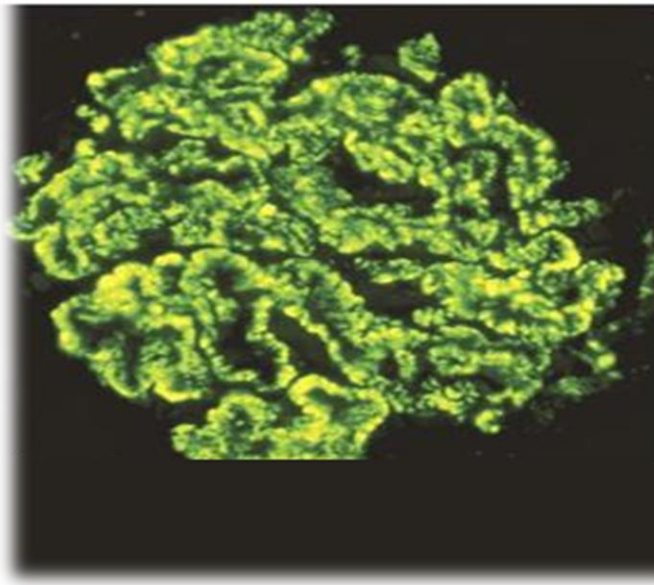
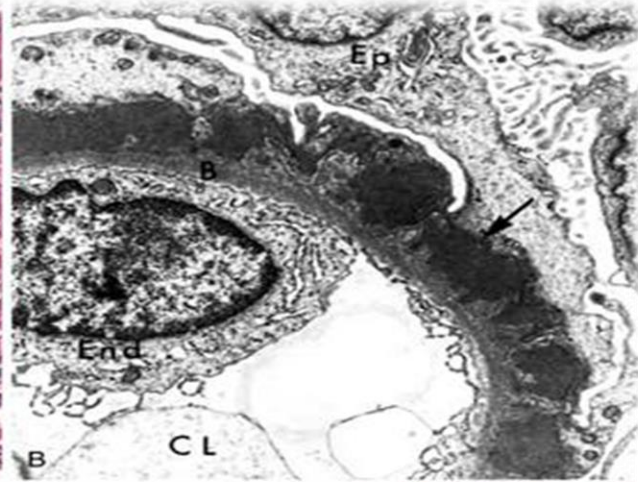
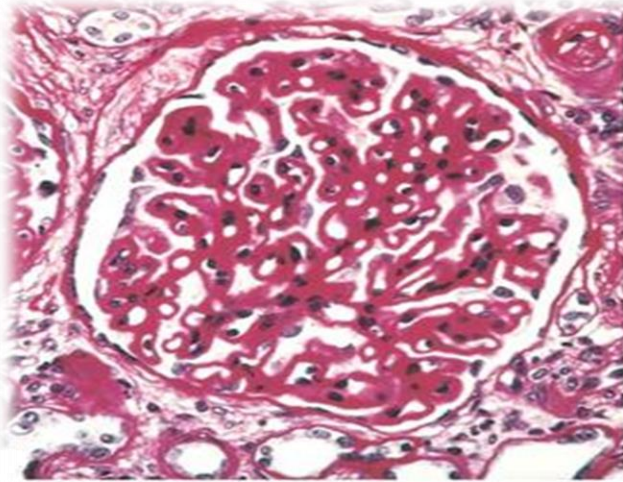


# Membranous nephropathy

1. Chronic hepatitis B, Syphilis. Schistosomiasis, Malaria
2. Pulmonary and colonic carcinoma, melanoma
3. SLE
4. Gold salts, mercury
5. Drugs (captopril, penicillins)
6. Diabetes mellitus, thyroiditis

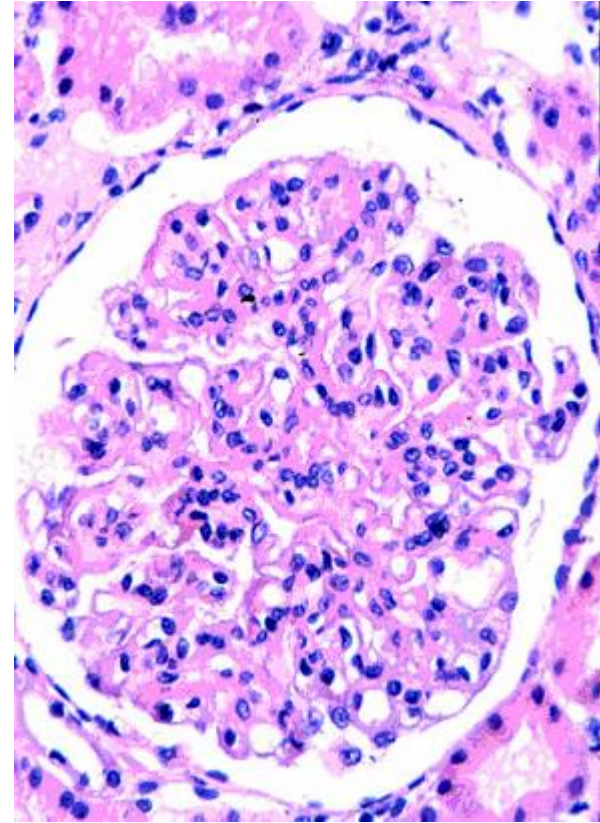
**In 85% it is idiopathic primary caused by antibodies that cross-react with antigens expressed by podocytes (phospholipase A2 receptor)**

# Nefropatie membranoasă



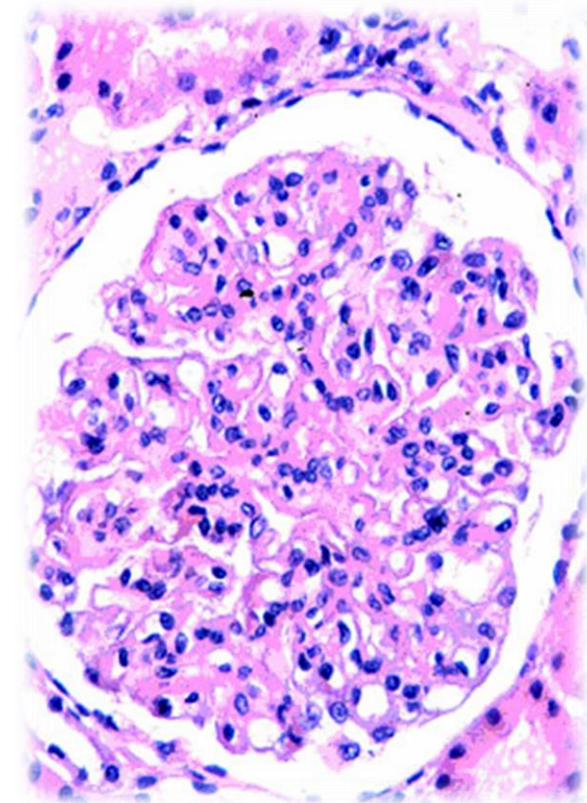
# MEMBRANOPROLIFERATIVE GLOMERULONEPHRITIS

- **MPGN can be idiopathic or due to chronic immune diseases Hep-C, alpha-1-antitrypsin deficiency, HIV, Malignancies**
- **GBM alterations**
- **Leukocyte infiltrations**
- **Predominant MESANGIAL involvement**



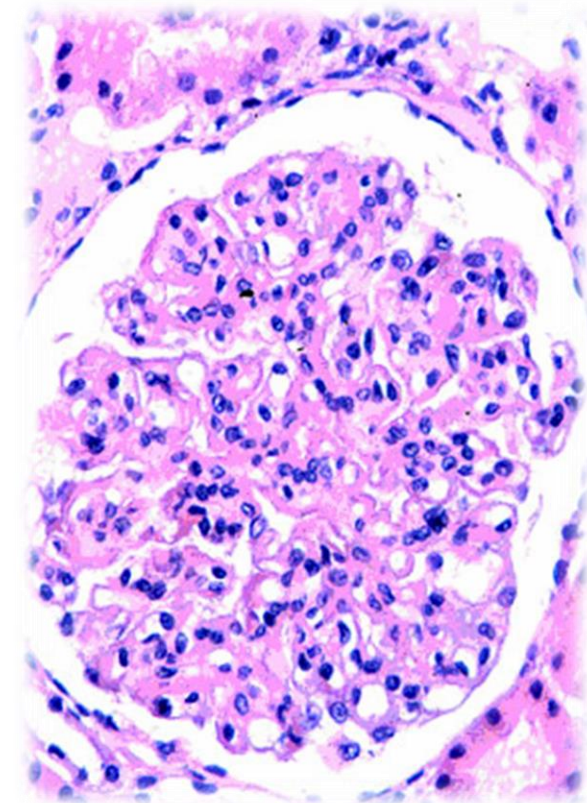
# MEMBRANOPROLIFERATIVE GLOMERULONEPHRITIS

- ◎ **MPGN of type I - immune complexes in glomerulus and classical and alternative pathways of activation of the complement system. The antigens involved in primary MPGN pathogenesis are not known. In many cases, they can be protein derivatives of hepatitis B or C virus.**



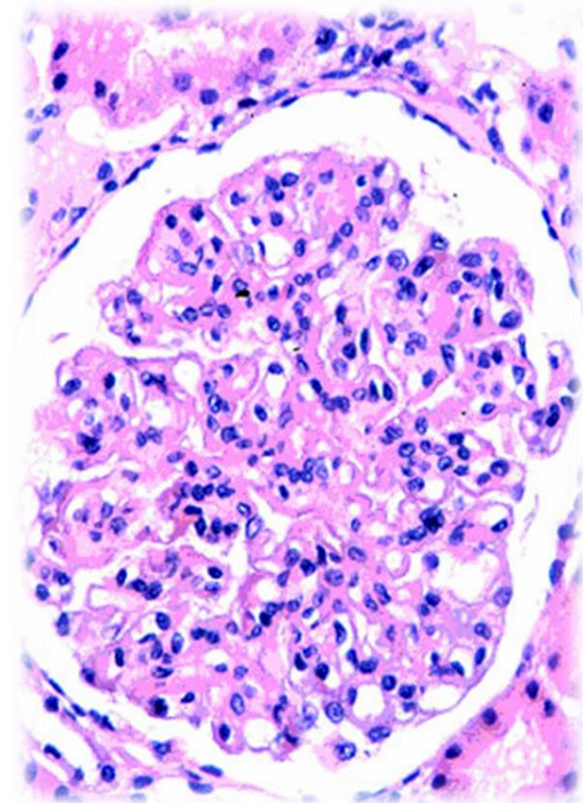
# MEMBRANOPROLIFERATIVE GLOMERULONEPHRITIS

- ◎ **Most patients with type II MPGN have changes that indicate an alternative way of activating the complement system. In these patients, the serum C3 level is reduced in the blood serum.**
- ◎ **C3 accumulates in glomeruli, IgG is absent**

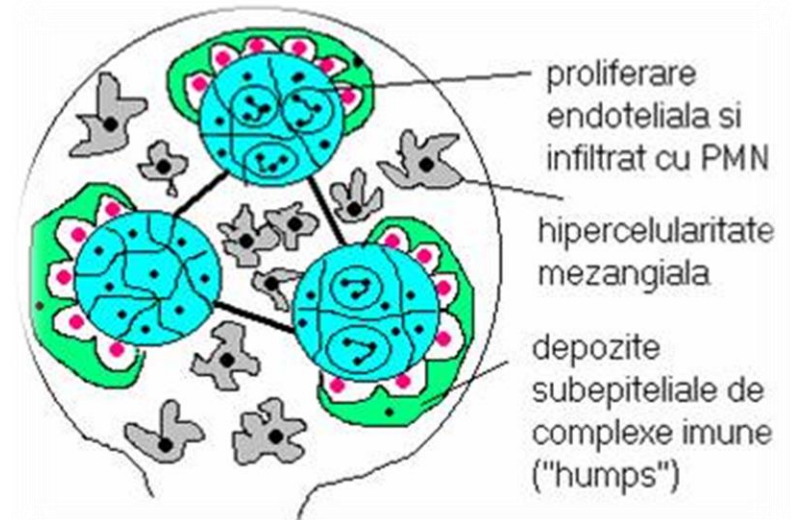
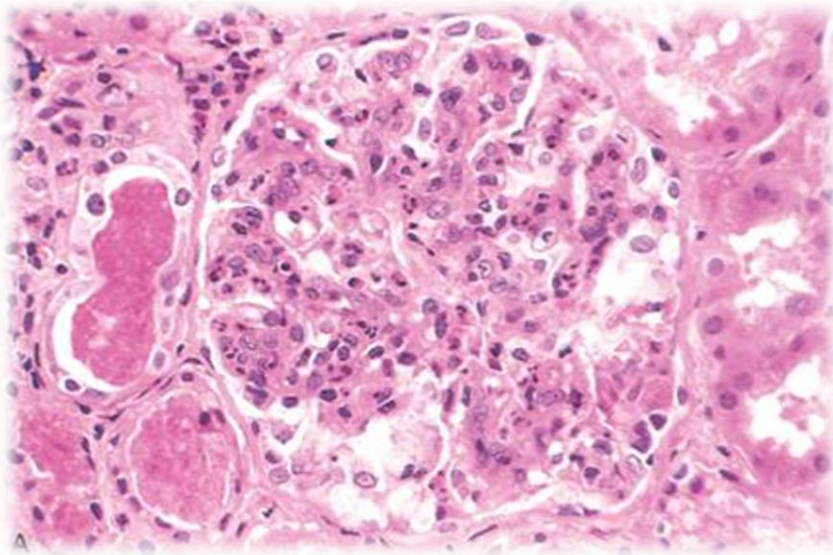
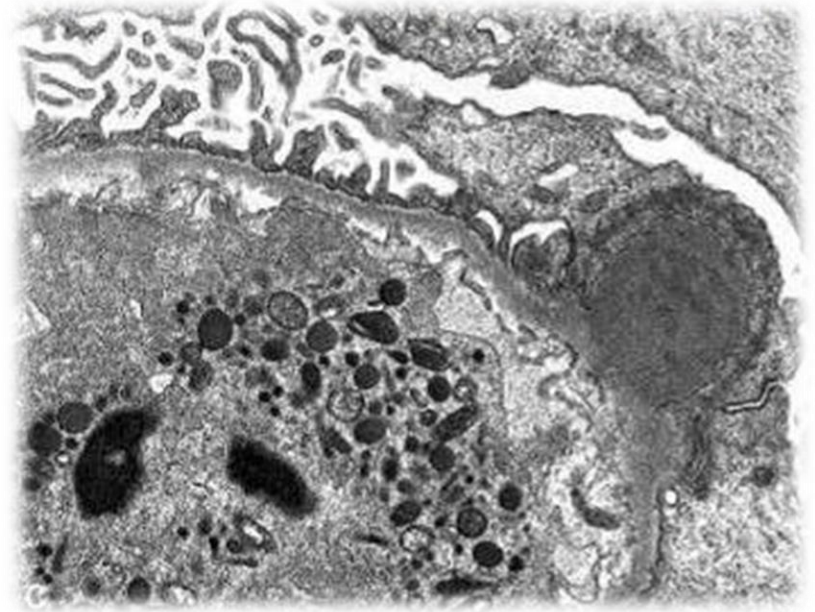


# MEMBRANOPROLIFERATIVE GLOMERULONEPHRITIS

- ◎ **Morphology.** In luminescent microscopy MPGN type I and MPGN type II do not differ. Glomeruli are increased in size and hypercellular.
- ◎ **Hypercellularity** is due to the proliferation of mesangial cells and so-called endocapillary proliferation, as well as leukocyte infiltration. Due to the proliferation of the mesangial cells and the growth of the mesangial matrix, glomeruli have a lobular feature.



# POST-INFECTIOUS GLOMERULONEFRITIS



# MORPHOLOGICAL MANIFESTATIONS

- **CELLULAR PROLIFERATION**
  - Mesangial
  - Endothelial
  - Nefrothelial
- leukocyte infiltration
- Crescent (rapidly progressive)
- Basement membrane thickening
- Hyalinisation
- SCLEROSIS



# POST-INFECTIOUS GLOMERULONEPHRITIS

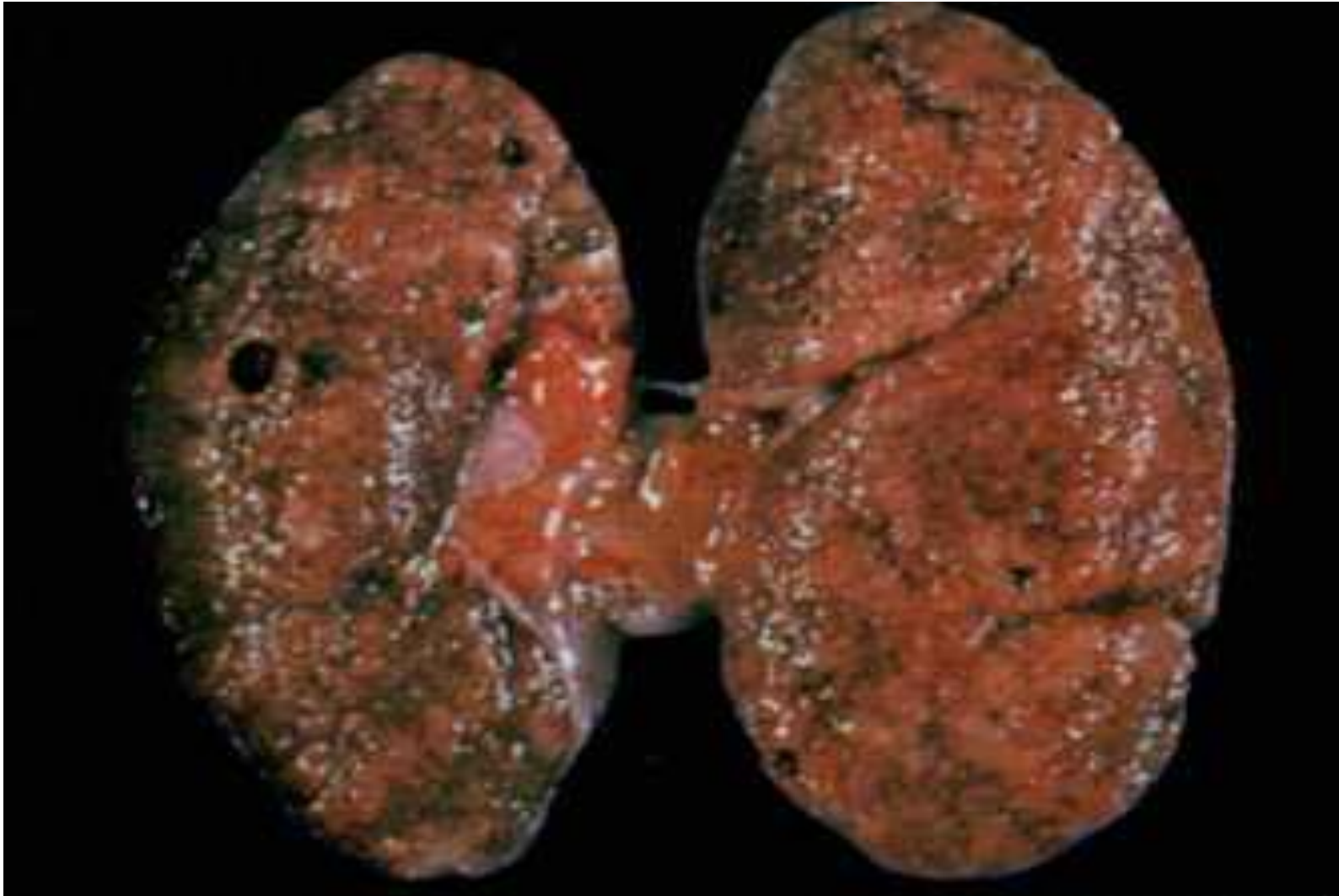
---

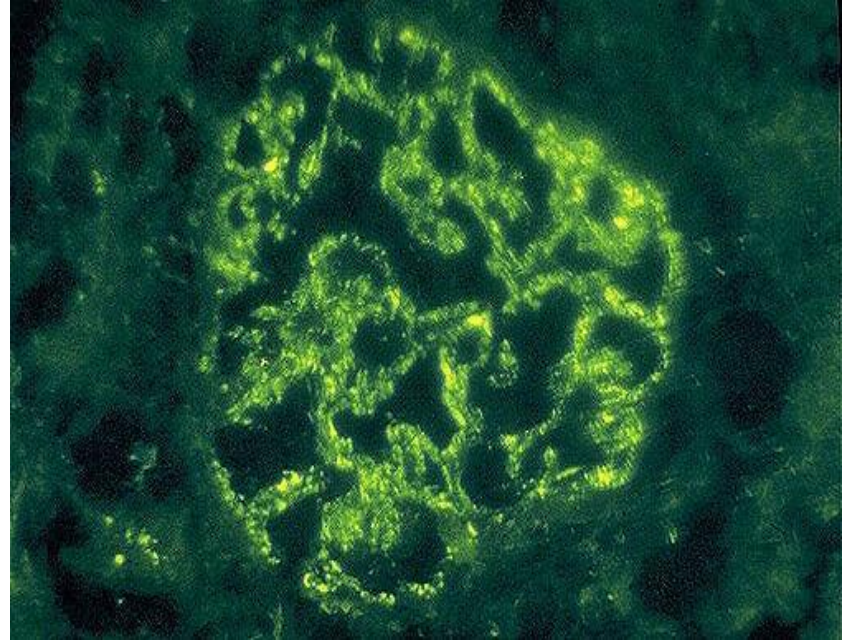
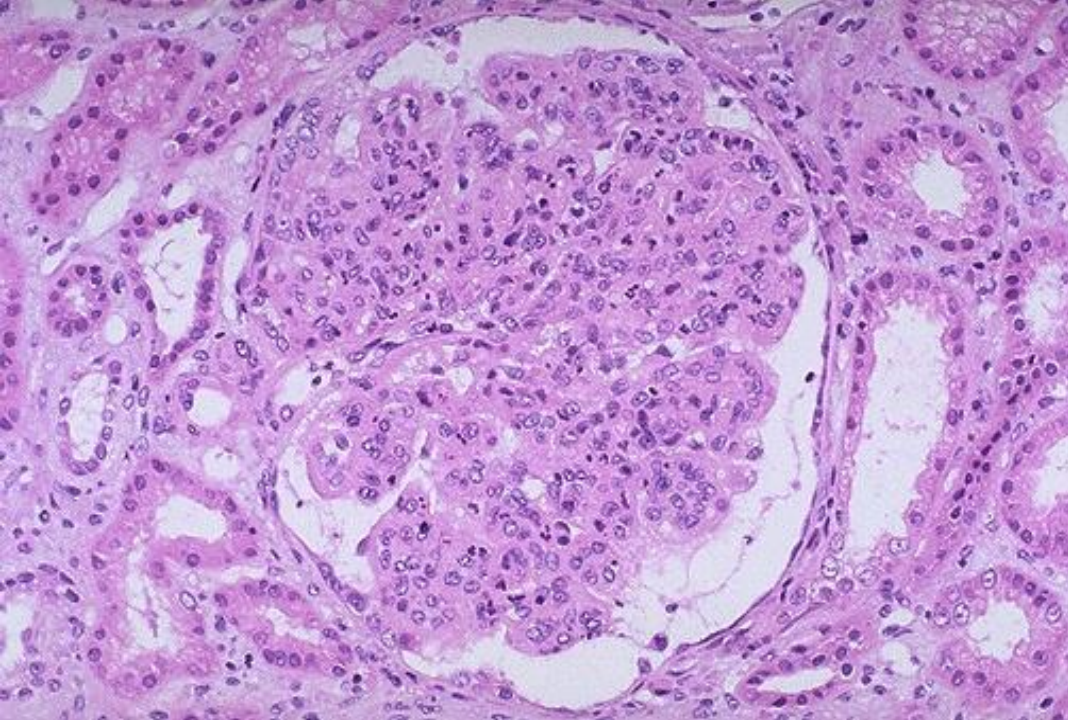
- CHILD AFTER STREPTOCOCCAL THROAT INFECTION
- IMMUNE COMPLEXES
- HYPERCELLULAR GLOMERULI
- SUBEPITHELIAL HUMPS

# ACUTE GLOMERULONEPHRITIS

- ⦿ Hematuria, Azotemia, Oliguria, in children following a strep infection
- ⦿ POSTSTREPTOCOCCAL (old term)
- ⦿ HYPERCELLULAR GLOMERULI
- ⦿ INCREASED ENDOTHELIUM AND MESANGIUM
- ⦿ IgG, IgM, C3 along GMB FOCALLY
- ⦿ 95% full recovery

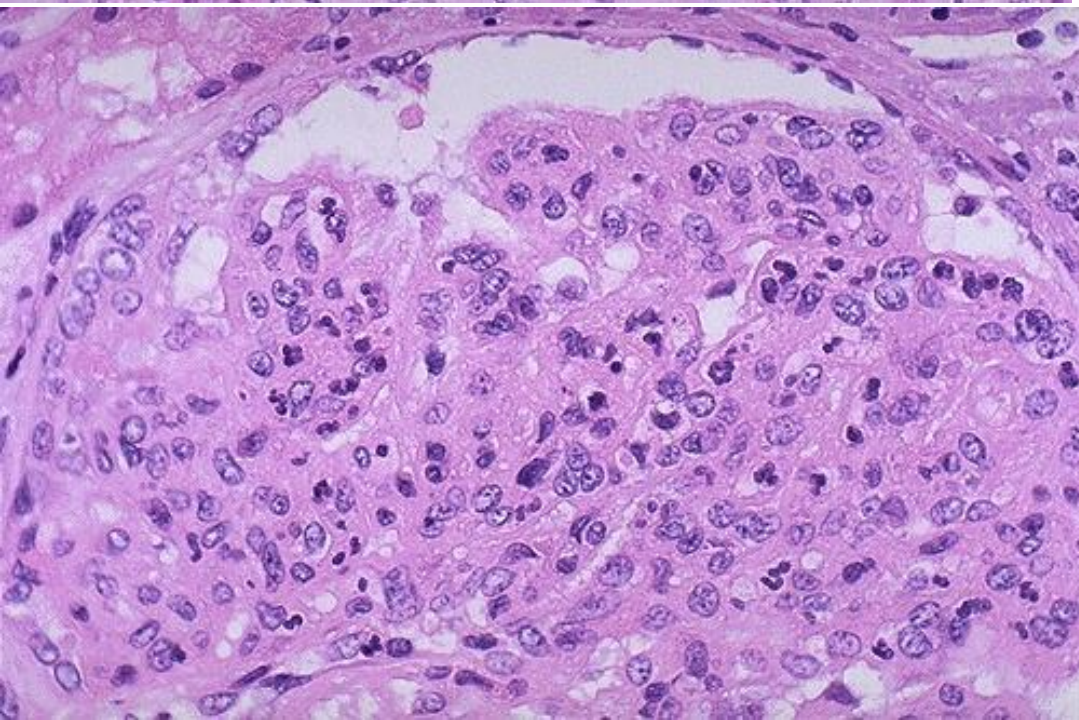
# ACUTE GLOMERULONEPHRITIS

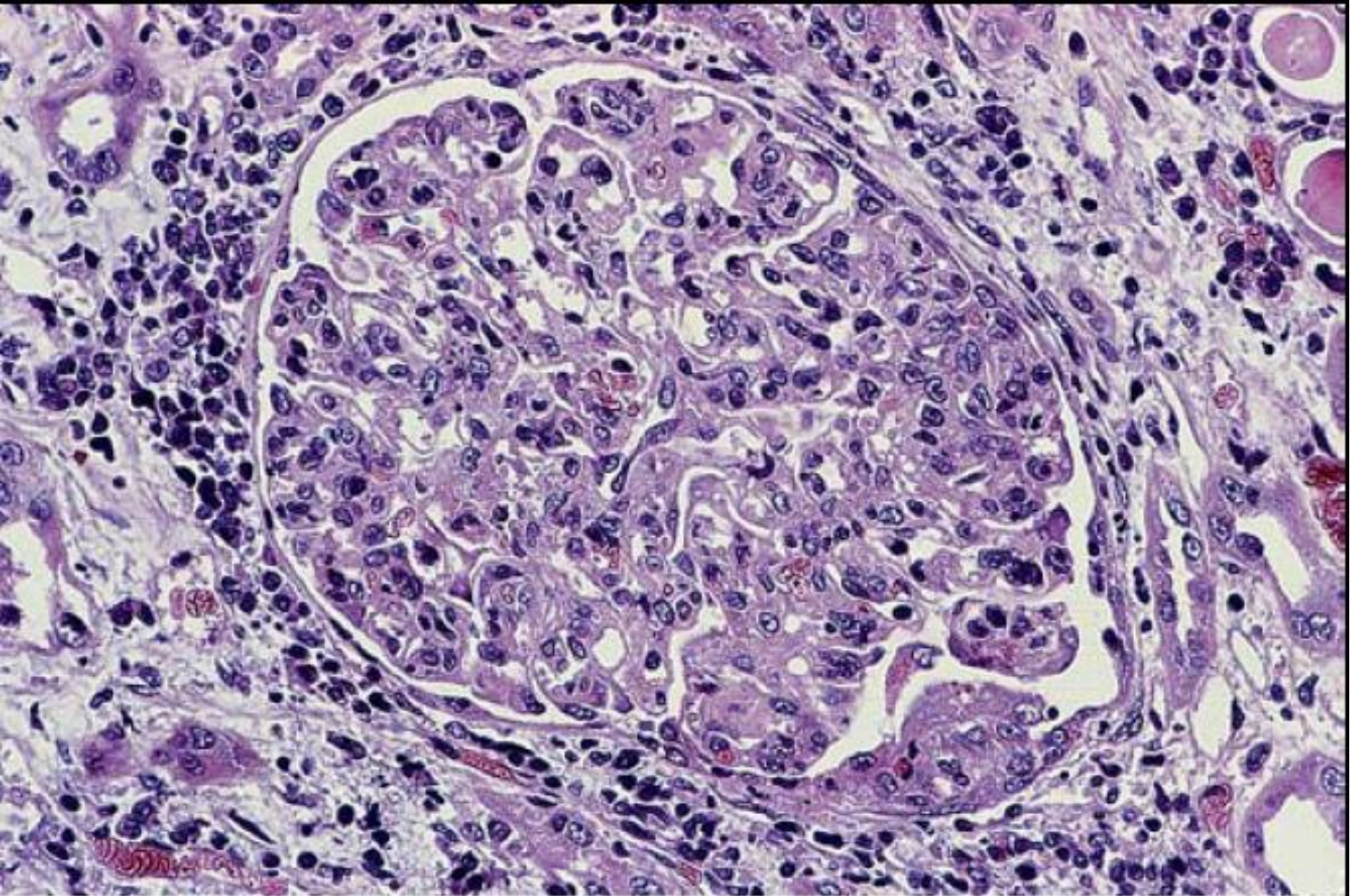




**Acute  
glomerulonephritis**

**(increased glomerular  
cellularity, neutrophil  
infiltration, on  
immunofluorescence  
microscopy - "granular"  
deposits of immune  
complexes)**





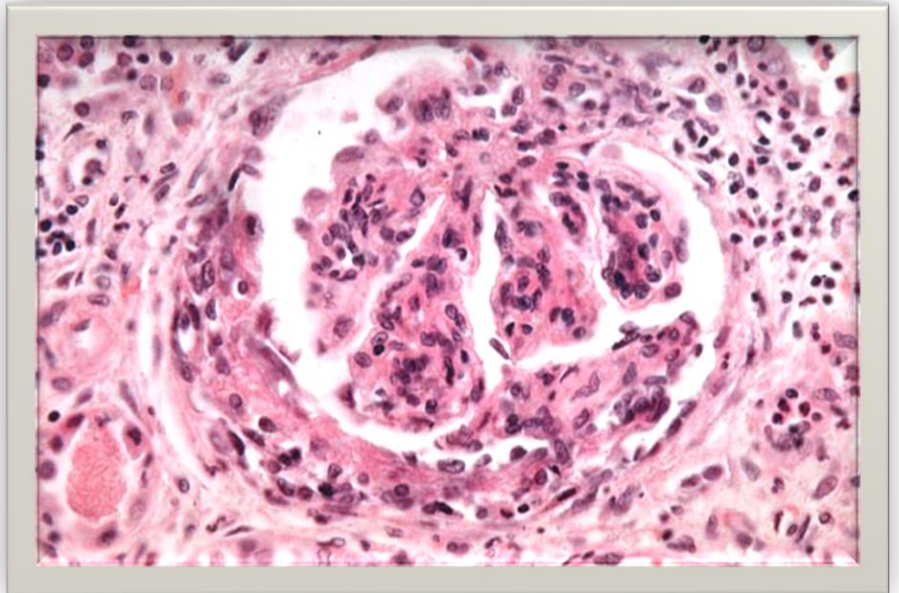
**Diffuse intracapillary glomerulonephritis, increased glomerular cellularity**

# RAPIDLY PROGRESSIVE GLOMERULONEPHRITIS

- **Clinical definition, NOT a specific pathologic one**

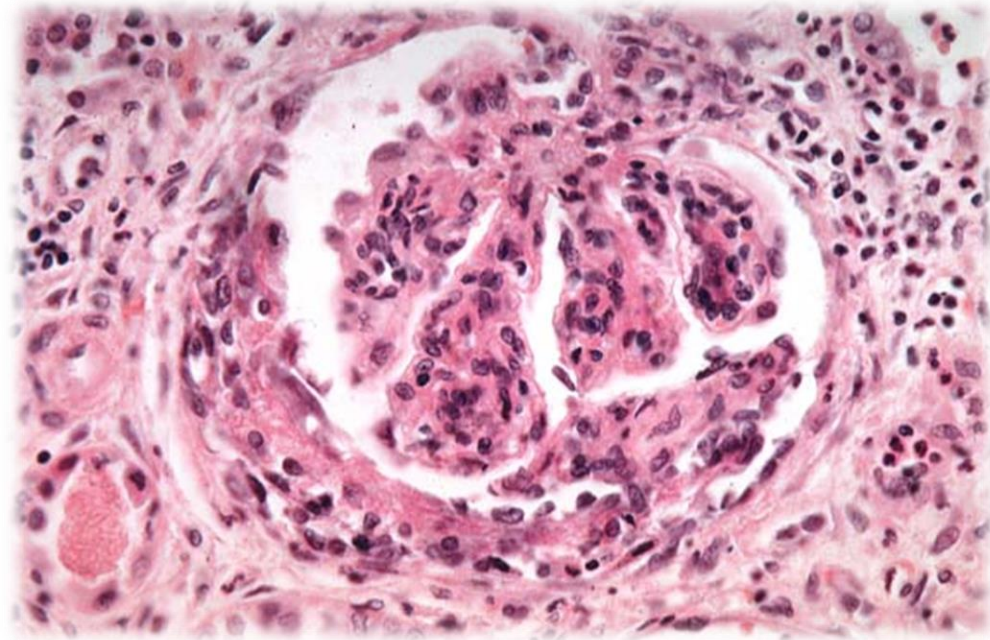
- **“CRESCENTIC”**

- **Anti-GBM Ab**
- **IMMUN CPLX**
- **Anti-Neut. Ab**



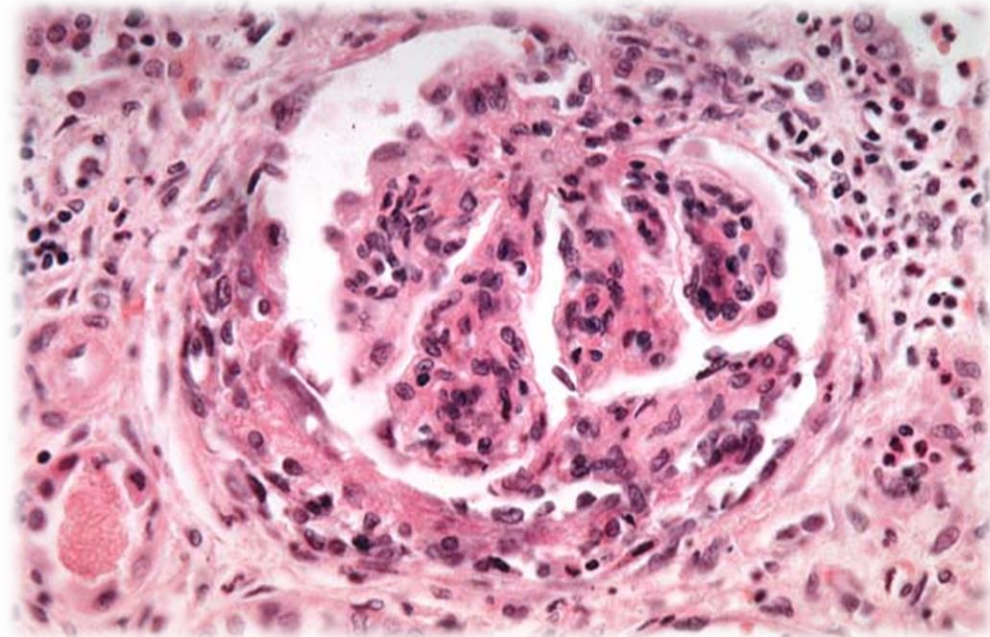
# RAPIDLY PROGRESSIVE GLOMERULONEPHRITIS

It is associated with severe glomerular lesions and is not a specific type of etiological glomerulonephritis. Clinically, this disease is characterized by a rapid progressive decline in renal function, with severe oliguria and signs of nephritic syndrome. RPGN in the absence of treatment results in renal failure for 1 month.



# RAPIDLY PROGRESSIVE GLOMERULONEPHRITIS

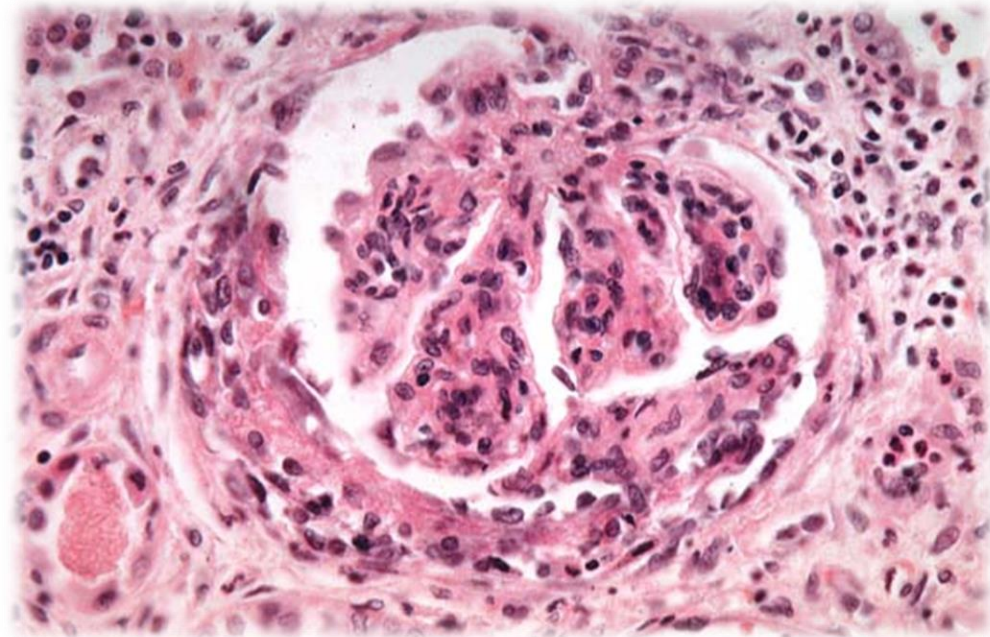
Type I RPGN is caused by antibodies to GBM components. Immunofluorescence reveals a linear distribution of IgG deposits and, in many cases, a component of the complementary system C3. In some patients, there is a cross-reaction of antibodies to the antigens of GBM and to basal membrane of the alveoli, leading to the development of Goodpasture syndrome (pulmonary hemorrhage and renal failure).





# RAPIDLY PROGRESSIVE GLOMERULONEPHRITIS

Type II is caused by the deposition of immune complexes and may be a complication of any variant of immune-mediated glomerulonephritis, including post-infectious glomerulonephritis, lupus glomerulonephritis, IgA nephropathy, Shönlein-Genouch purpura. In all these cases, the immunofluorescence examination showed granular deposits of immune complexes.



# RAPIDLY PROGRESSIVE GLOMERULONEPHRITIS

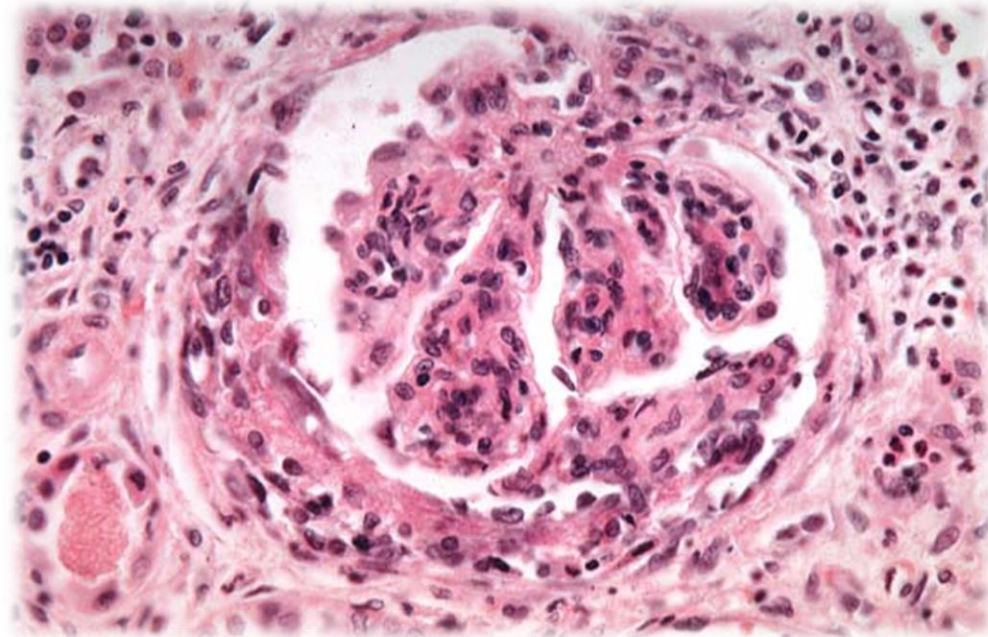
Type III Pauci-Immune (weakly immune), because the absence of antibodies to MBG components or immune complexes is typical. There are present p-ANCA and c-ANCA that play a role in the pathogenesis of vasculitis (systemic vasculitis, Wegener granulomatosis or microscopic polyangiitis) are detected in the majority of patients with this type of RPGN.

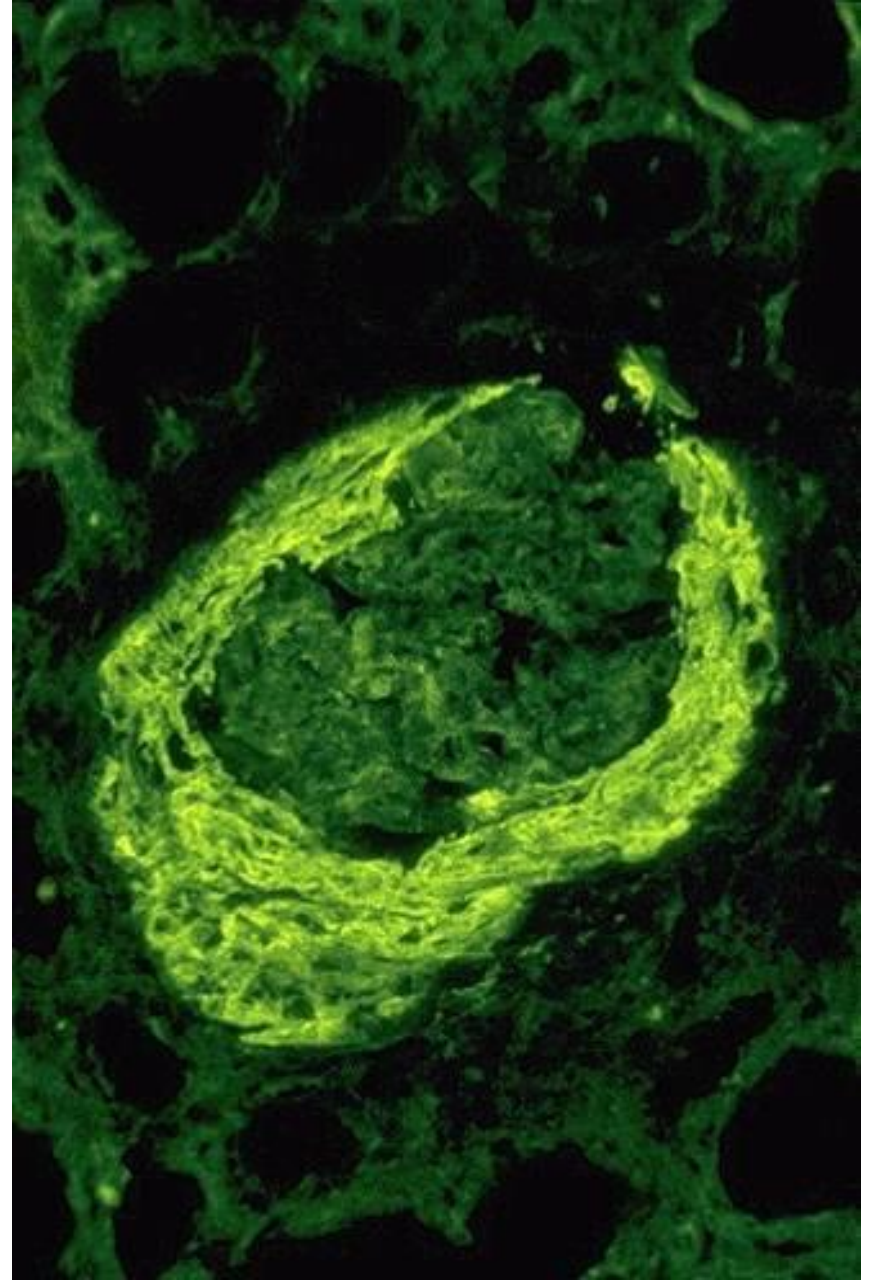
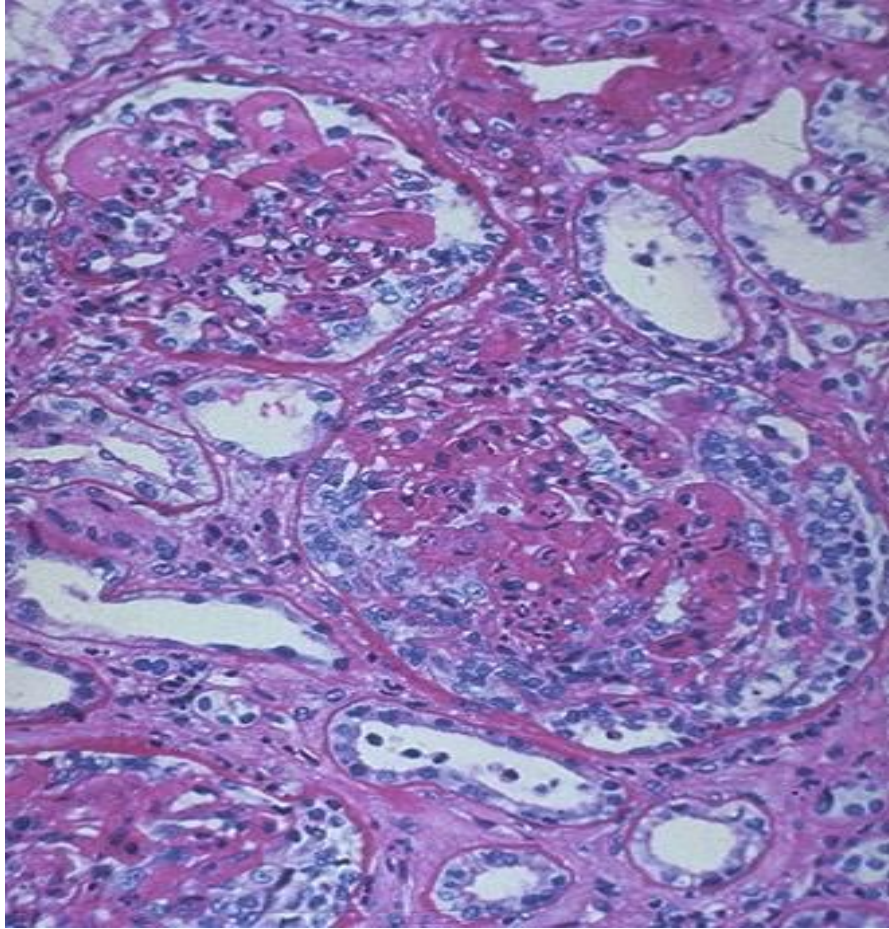
ANCA ( anti-neutrophil cytoplasmic **antibodies** ) associated with glomerulonephritis

Idiopathic glomerulonephritis

Wegener granulomatosis

Microscopic polyangiitis





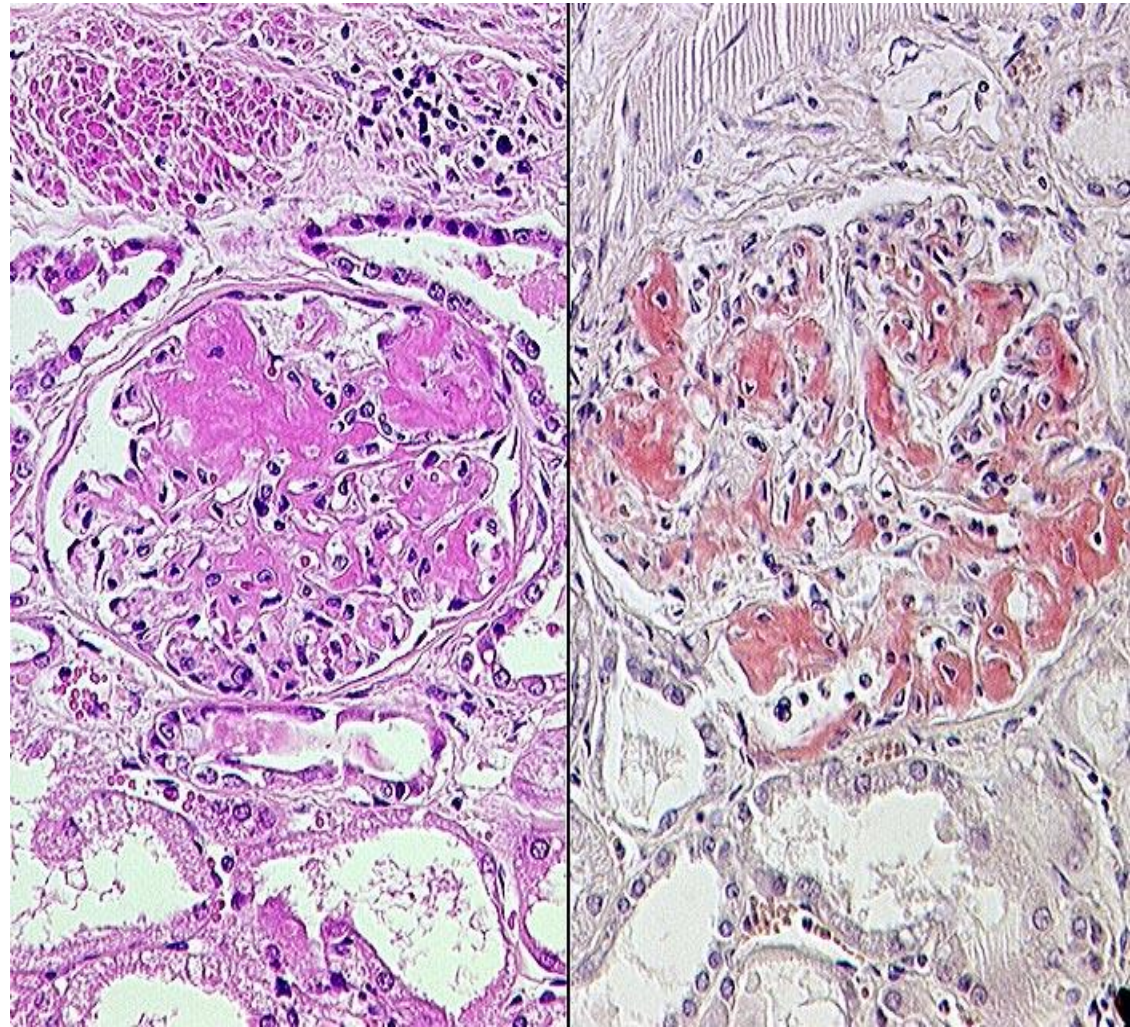
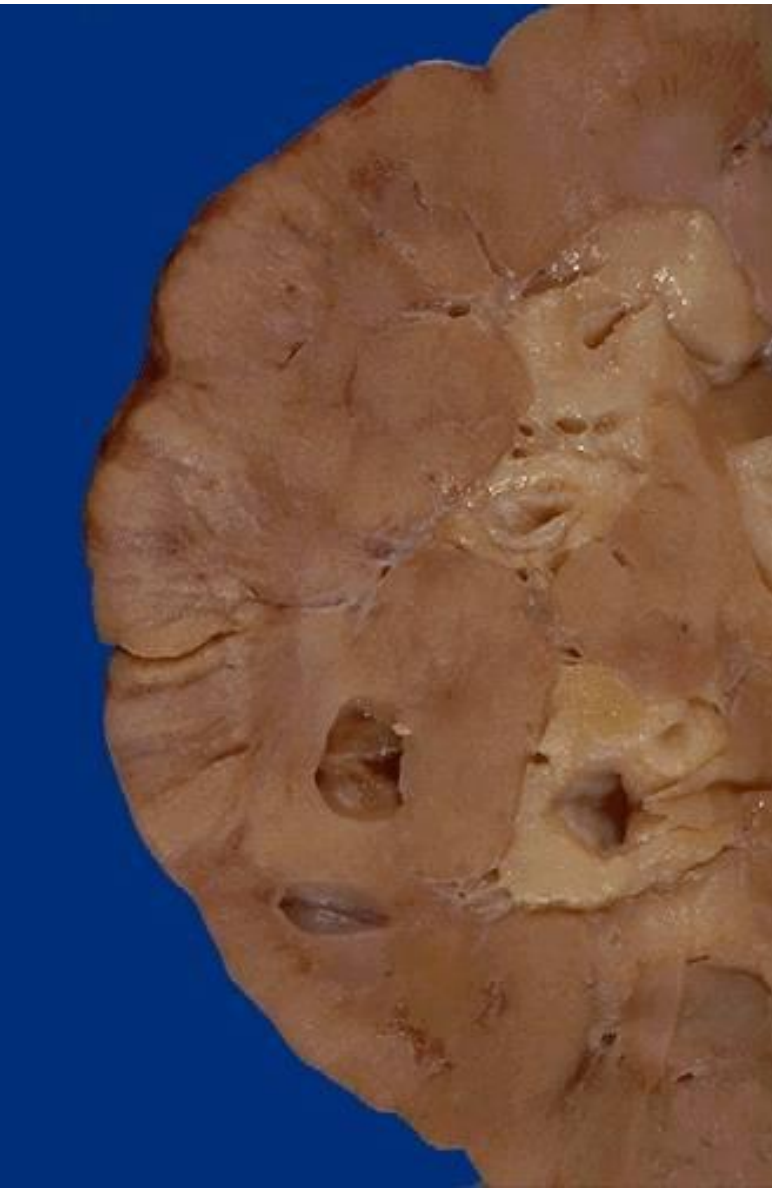**RAPIDLY PROGRESSIVE GLOMERULONEPHRITIS**

# CHRONIC GLOMERULONEPHRITIS

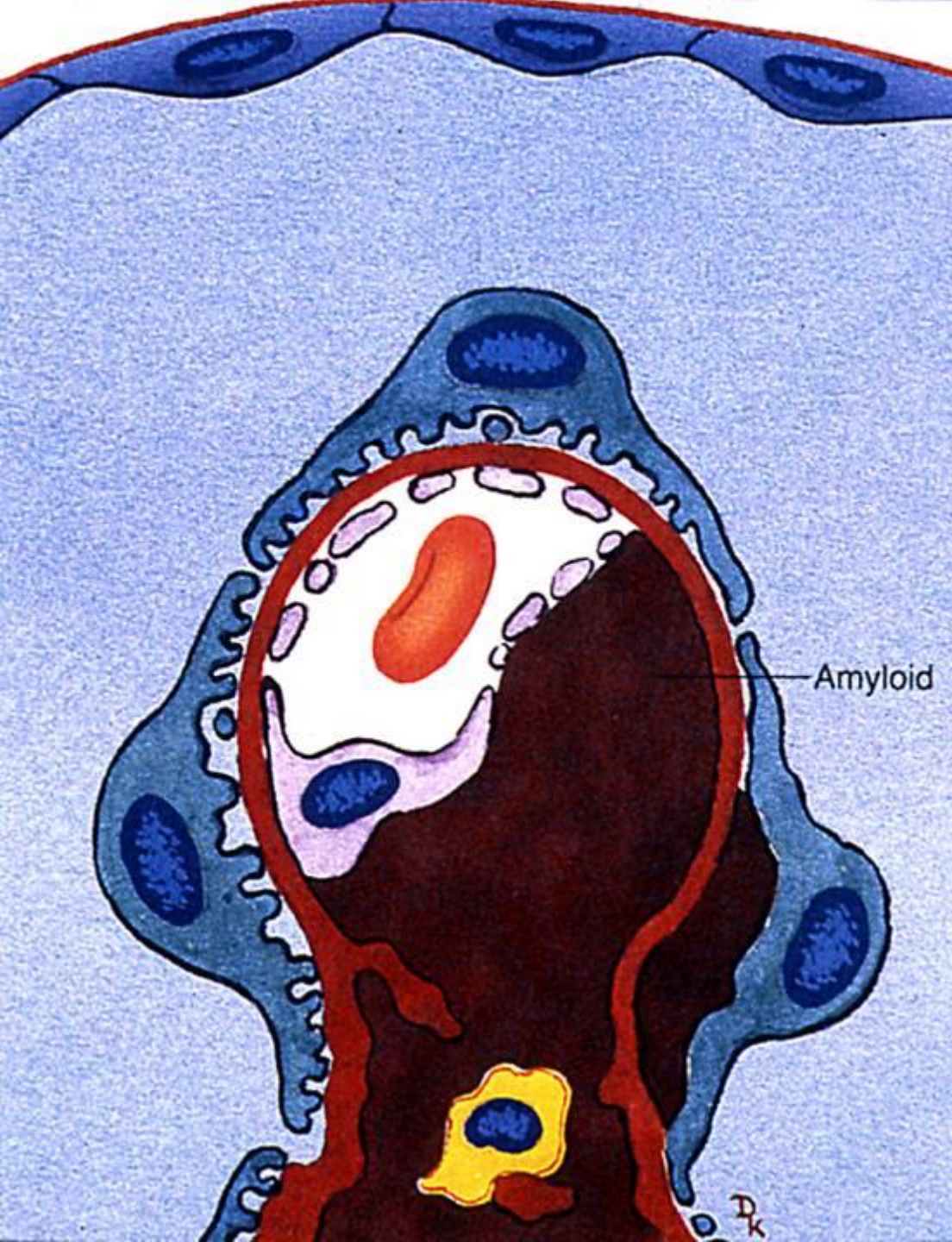
- **Can result from just about ANY of the previously described acute ones**
  - **THIN CORTEX**
  - **HYALINIZED (fibrotic) GLOMERULI**
  - **OFTEN SEEN IN DIALYSIS PATIENTS**

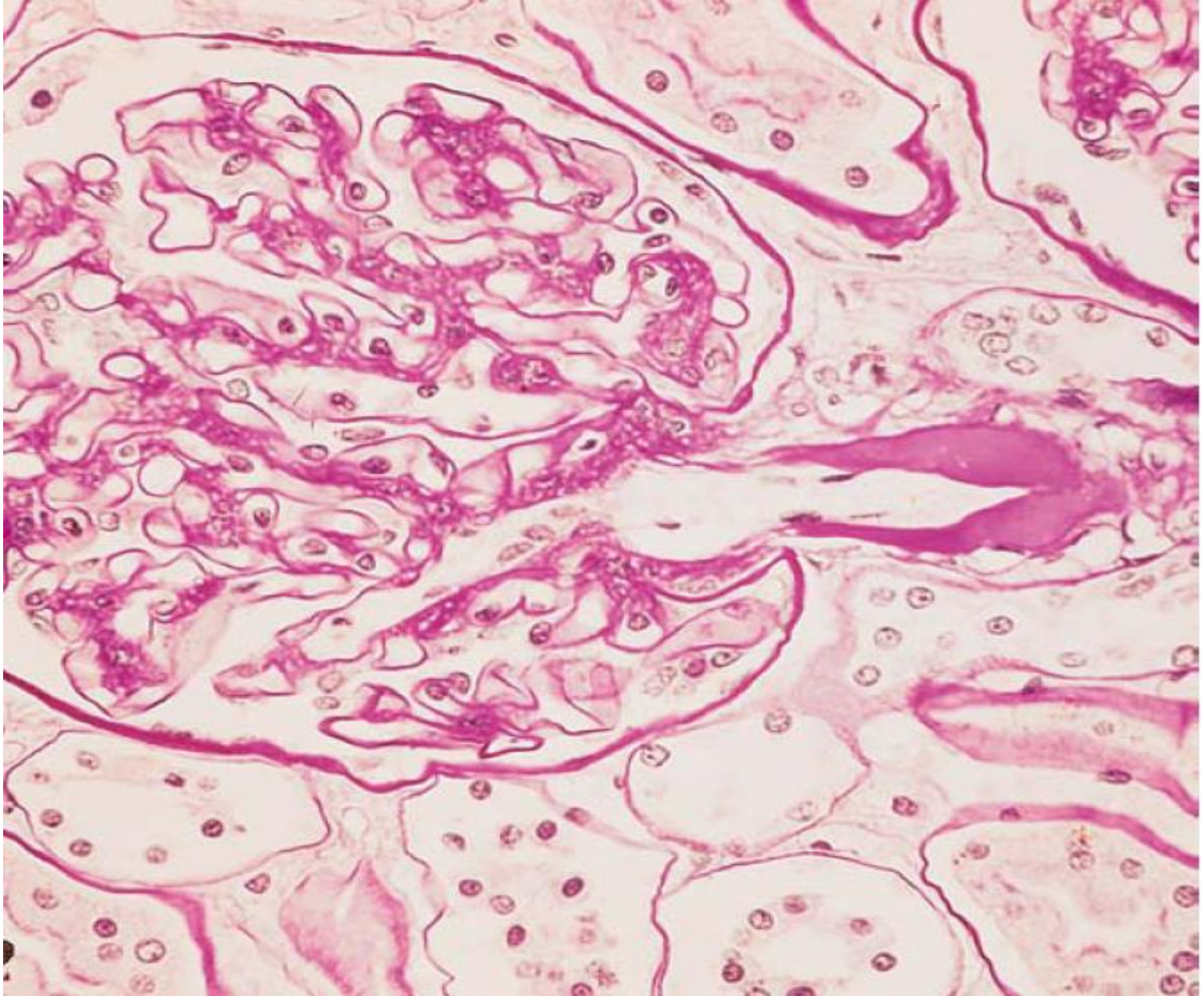
# SECONDARY (2º) GLUMERULONEPHROPATHIES

- **SLE**
- **Henoch-Schonlein Purpura (IgA-NEPH)**
- **BACTERIAL ENDOCARDITIS**
- **DIABETES (Nodular Glomerulosclerosis, or K-W Kidney)**
- **AMYLOIDOSIS**
- **GOODPASTURE**
- **WEGENER**
- **MYELOMA**



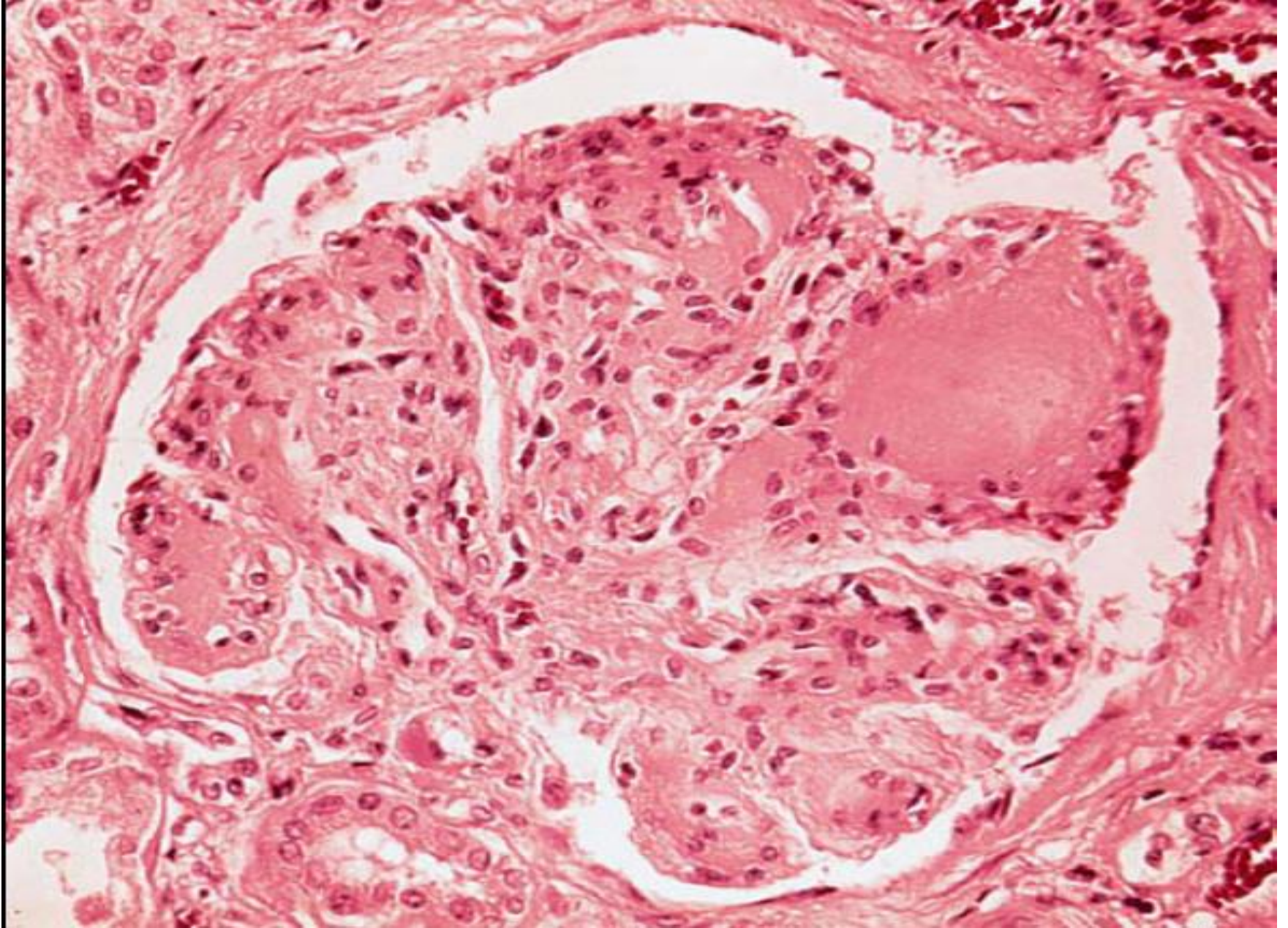
**Renal amyloidosis.  
H-E and Congo red stain**



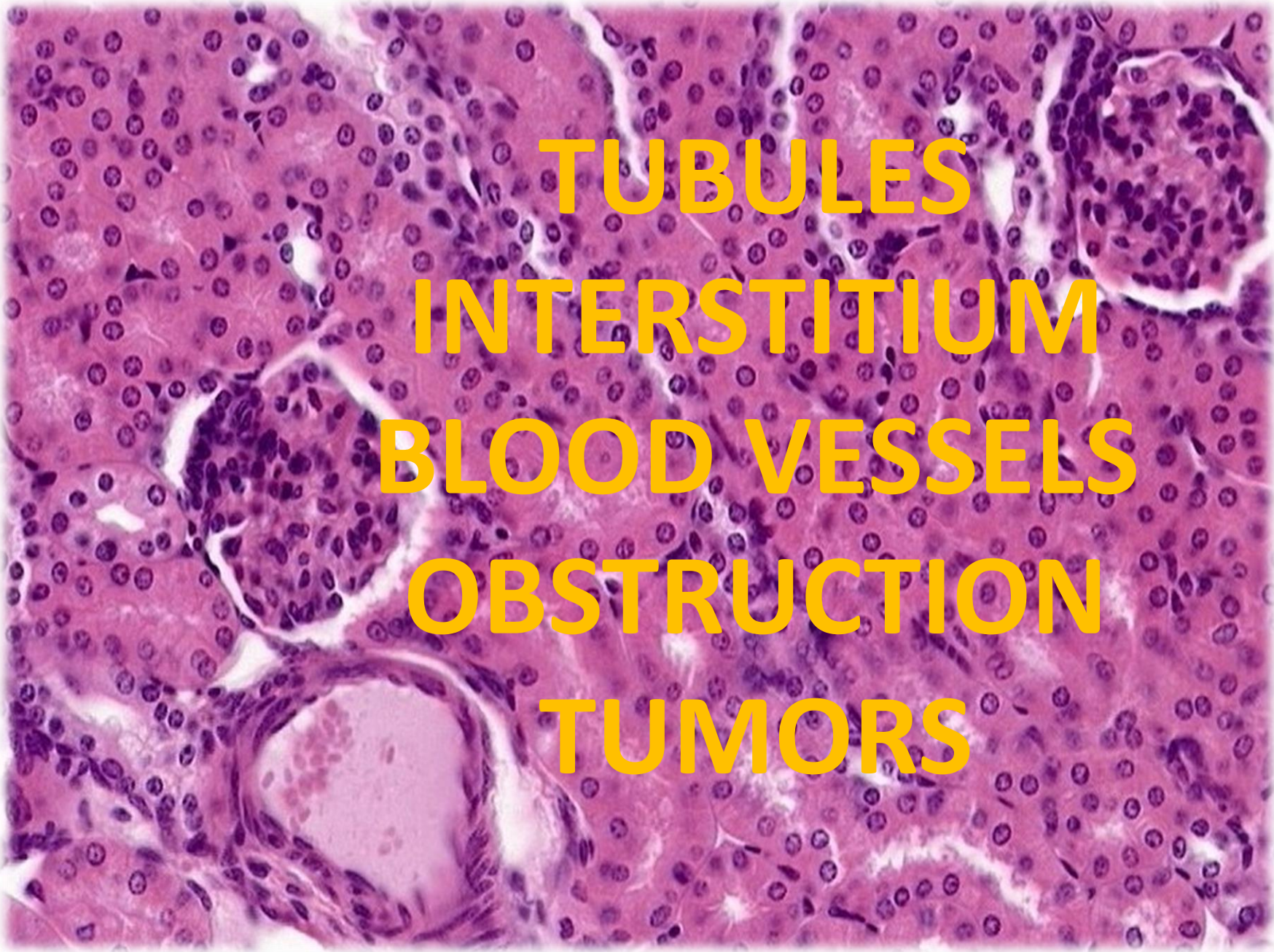


**Diabetic glomerulosclerosis, arterial hyalinosis and increase volume of glomerular matrix (PAS reaction)**





**Diabetic focal glomerulosclerosis.**



**TUBULES**  
**INTERSTITIUM**  
**BLOOD VESSELS**  
**OBSTRUCTION**  
**TUMORS**

This is a histological micrograph of kidney tissue, likely stained with hematoxylin and eosin (H&E). The image shows a dense population of tubules, which are the functional units of the kidney. The tubules are lined by a single layer of cuboidal epithelial cells. The interstitium, the space between the tubules, contains various cells and structures, including blood vessels. Some tubules appear dilated or obstructed, and there are areas that suggest the presence of tumors or other pathological changes. The overall appearance is that of a complex, organized tissue structure.

# TUBULAR DISEASES

- ◎ ACUTE TUBULAR NECROSIS
- ◎ TUBULOINTERSTITIAL NEPHRITIS
  - PYELONEPHRITIS
    - ACUTE
    - CHRONIC
  - DRUGS
  - TOXINS
- ◎ URATE NEPHROPATHY
- ◎ HYPERCALCEMIA/NEPHROCALCINOSIS
- ◎ MULTIPLE MYELOMA

# ACUTE TUBULAR NECROSIS

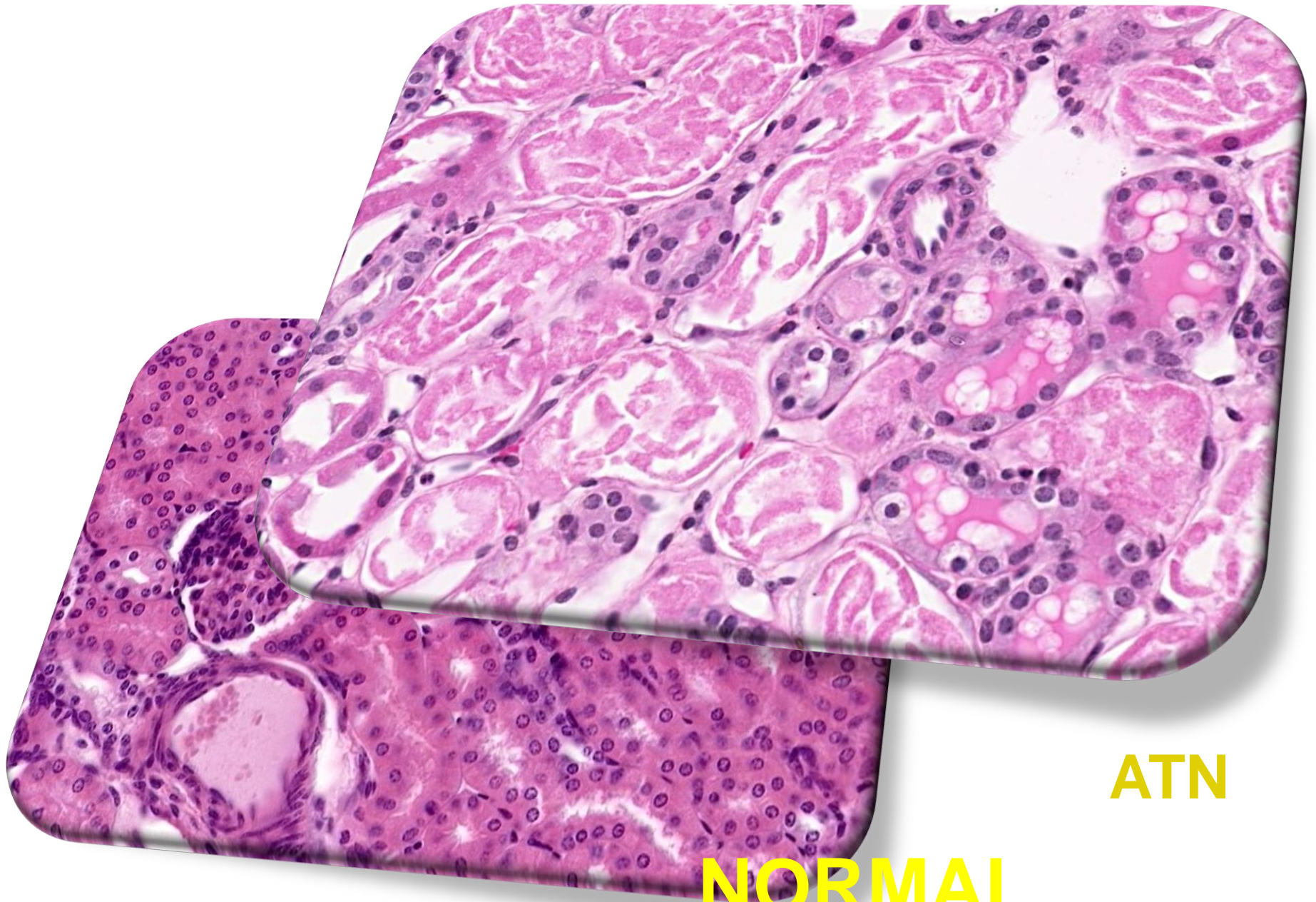
- Destruction of renal **TUBULAR** epithelium
- Loss of renal function
- 50% of **ACUTE** renal failure
- Two types:

## **ISCHEMIC** **NEPHROTOXIC**

-AMINOGLYCOSIDES

-AMPHOTERICIN B

-CONTRAST AGENTS



**ATN**

**NORMAL**

# ATN PATHOGENESIS

- **BLOOD FLOW DISTURBANCES  
(ISCHEMIC)**
- **TUBULAR INJURY  
(NEPHROTOXIC)**

# CLINICAL COURSE

## ⦿ INITIATION (36 hours)

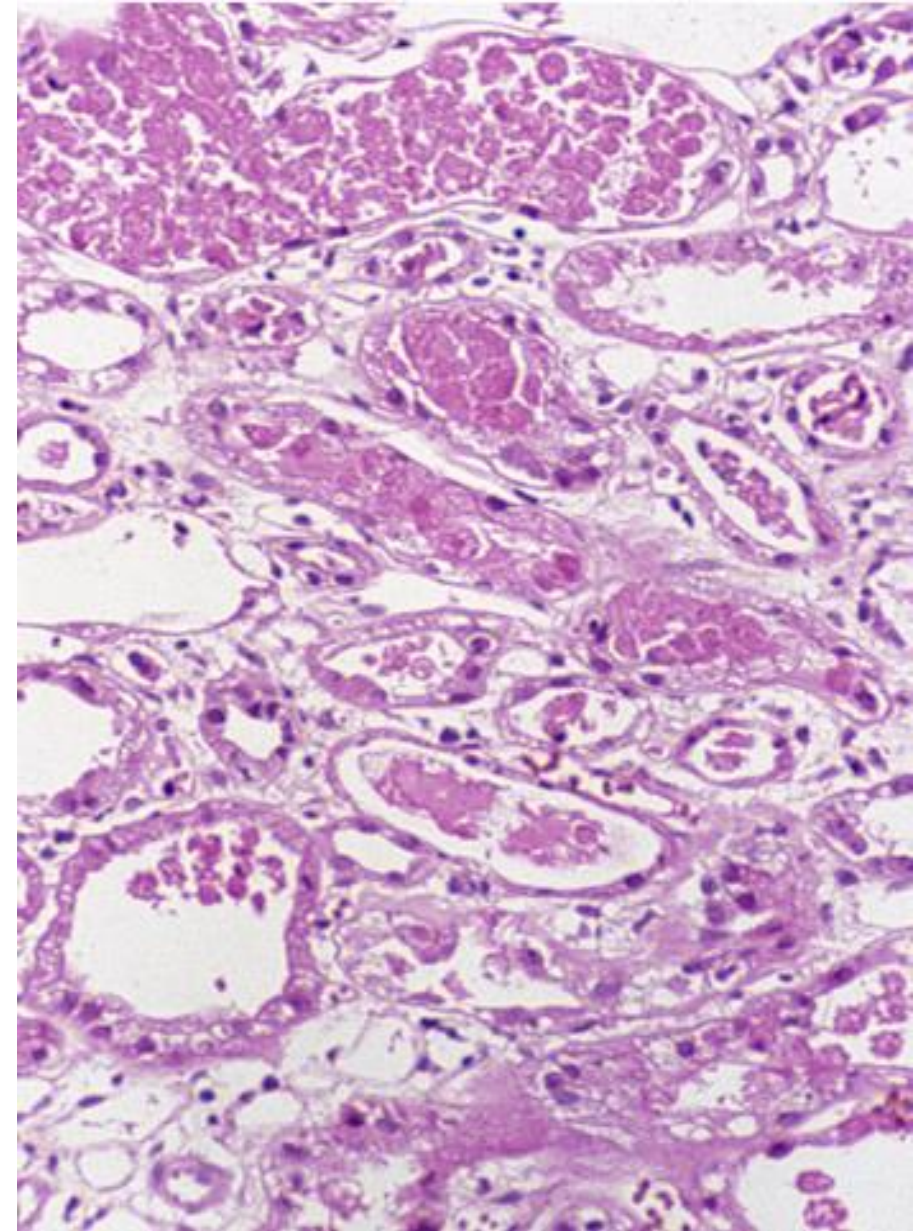
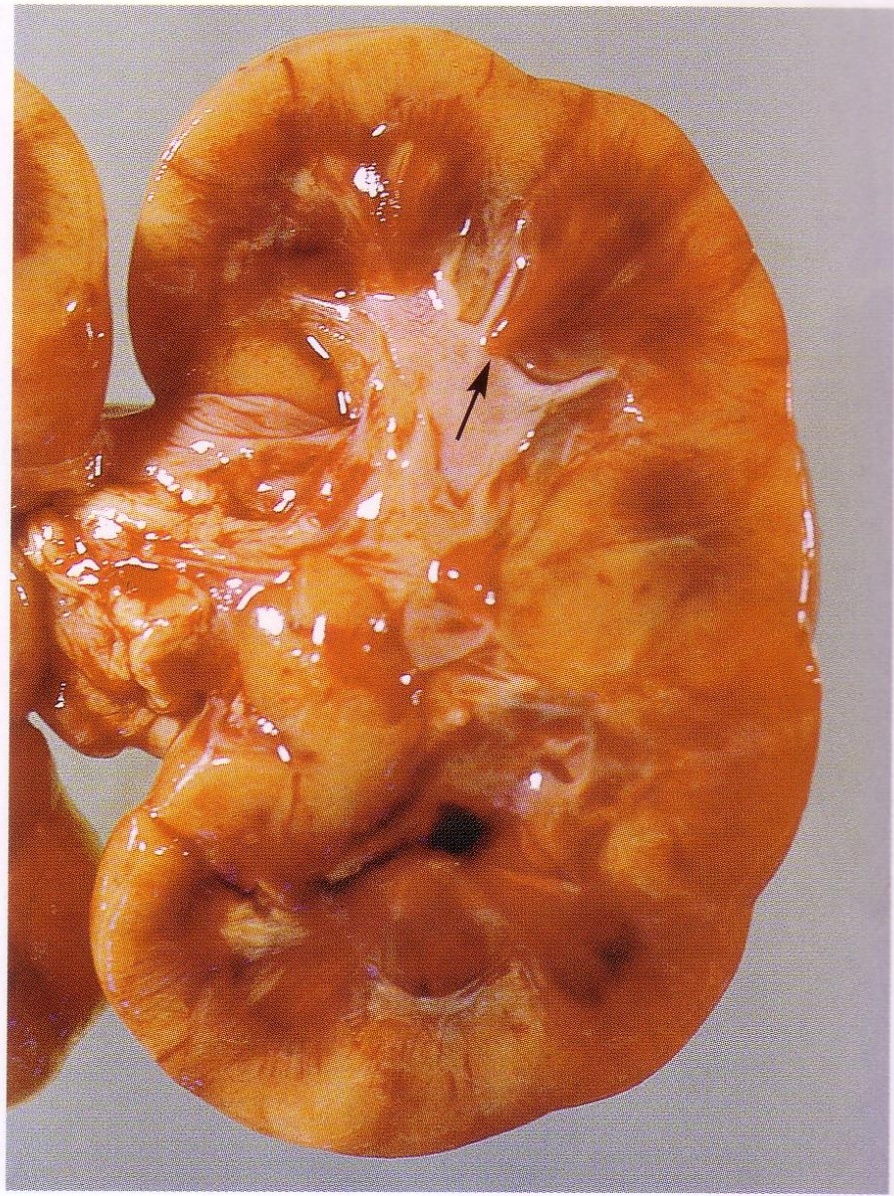- Mild OLIGURIA
- Mild AZOTEMIA

## ⦿ MAINTENANCE

- More OLIGURIA
- More AZOTEMIA
- DIALYSIS NEEDED

## ⦿ RECOVERY

- HYPOKALEMIA main problem
- CREATININE and Blood Urea Nitrogen return to normal



**Shock kidneys**

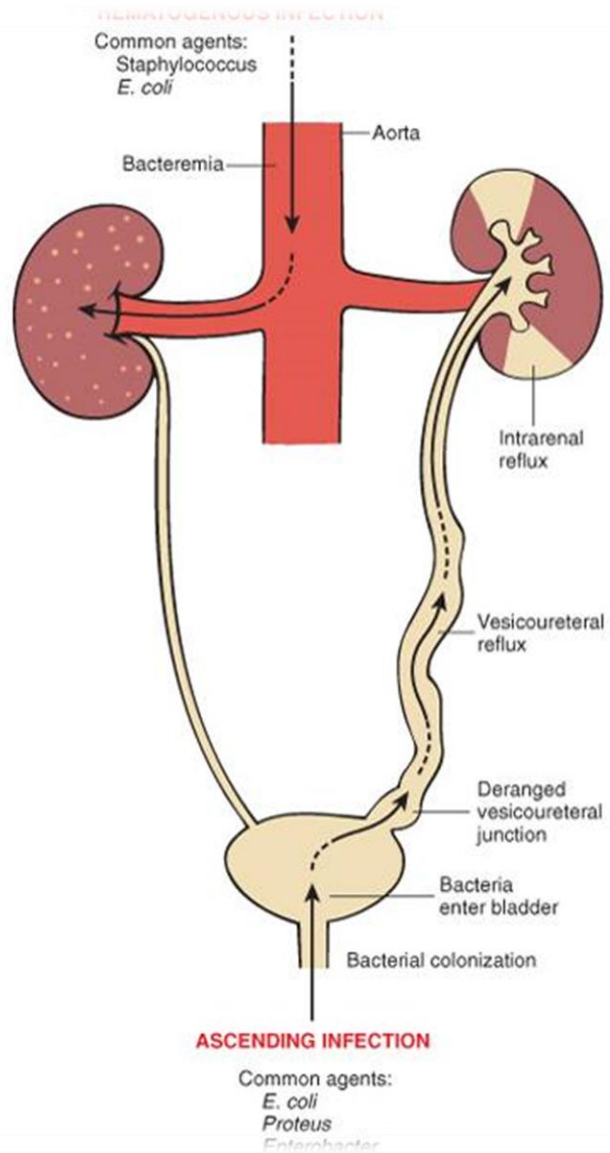


# TUBULO/INTERSTITIAL NEPHRITIS

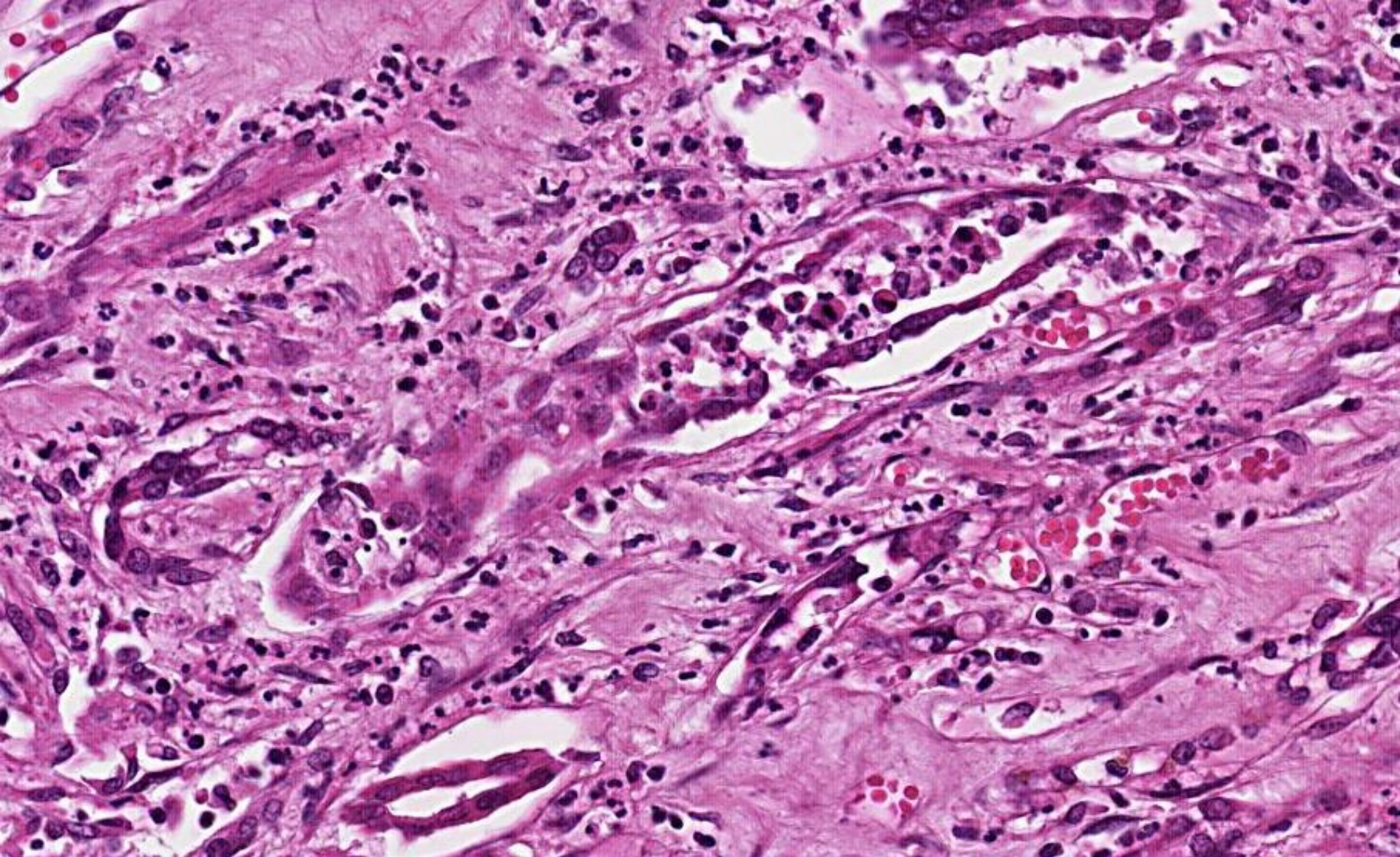
- **INFECTIONS, i.e., pyelonephritis**
- **TOXINS, heavy metals, chemo, NSAIDS**
- **METABOLIC, urates, Ca<sup>++</sup>, Oxalates**
- **PHYSICAL, obstruction, radiation**
- **IMMUNOLOGIC, esp. transplant rejection**

# PYELONEPHRITIS

- GI Gram NEGATIVES: E. COLI, Proteus, Klebsiella, Enterobacter, Strep. faecalis, usually “NORMAL” flora
- ASCENDING, by FAR, the most common, i.e., reflux, obstruction
- HEMATOGENOUS too
- ACUTE PYELONEPHRITIS, neutrophils
- CHRONIC PYELONEPHRITIS, lymphocytes, scars

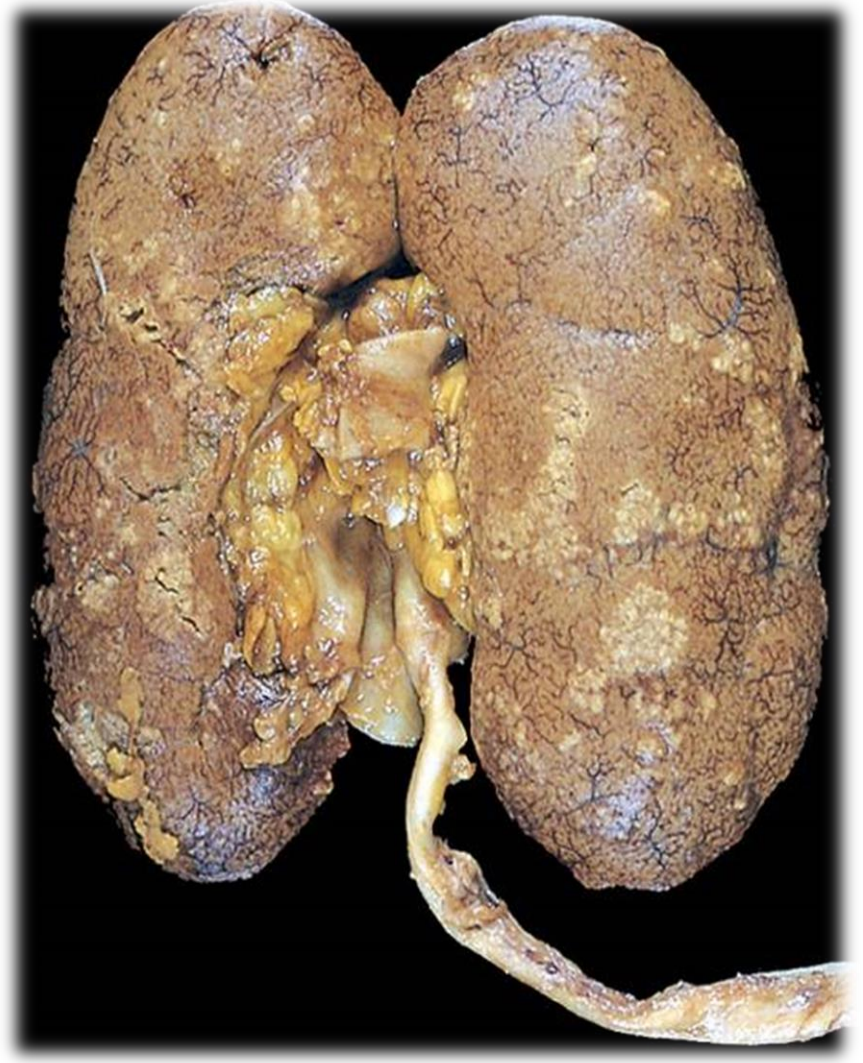
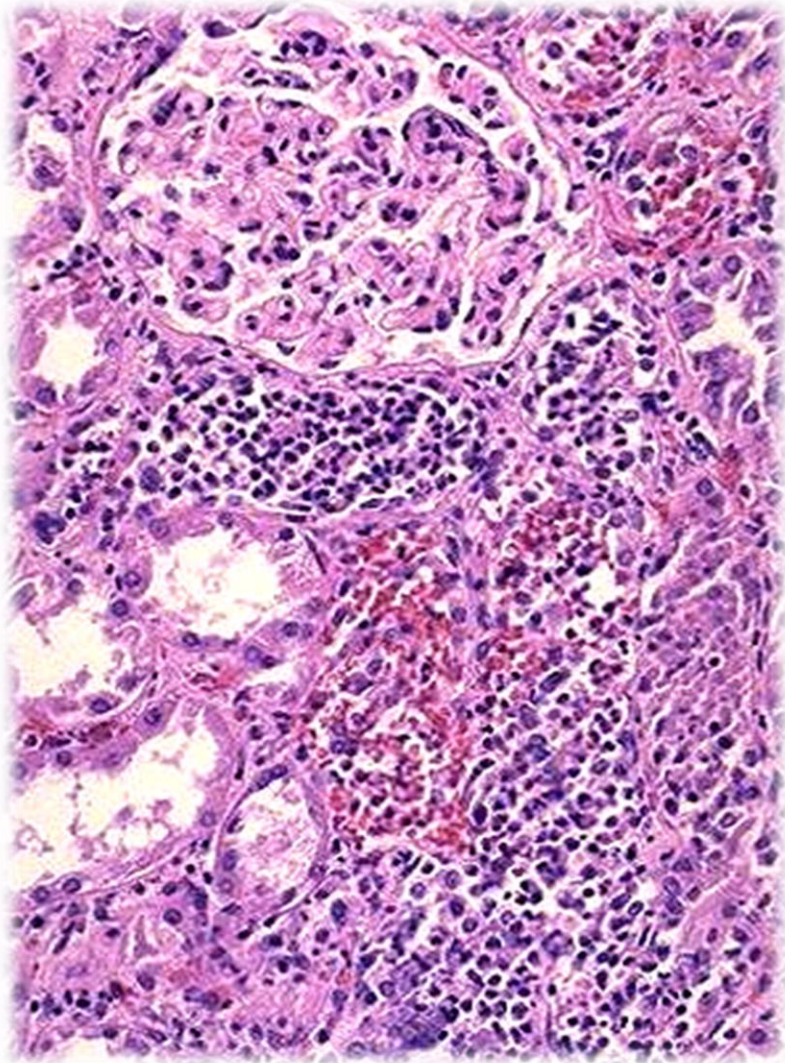


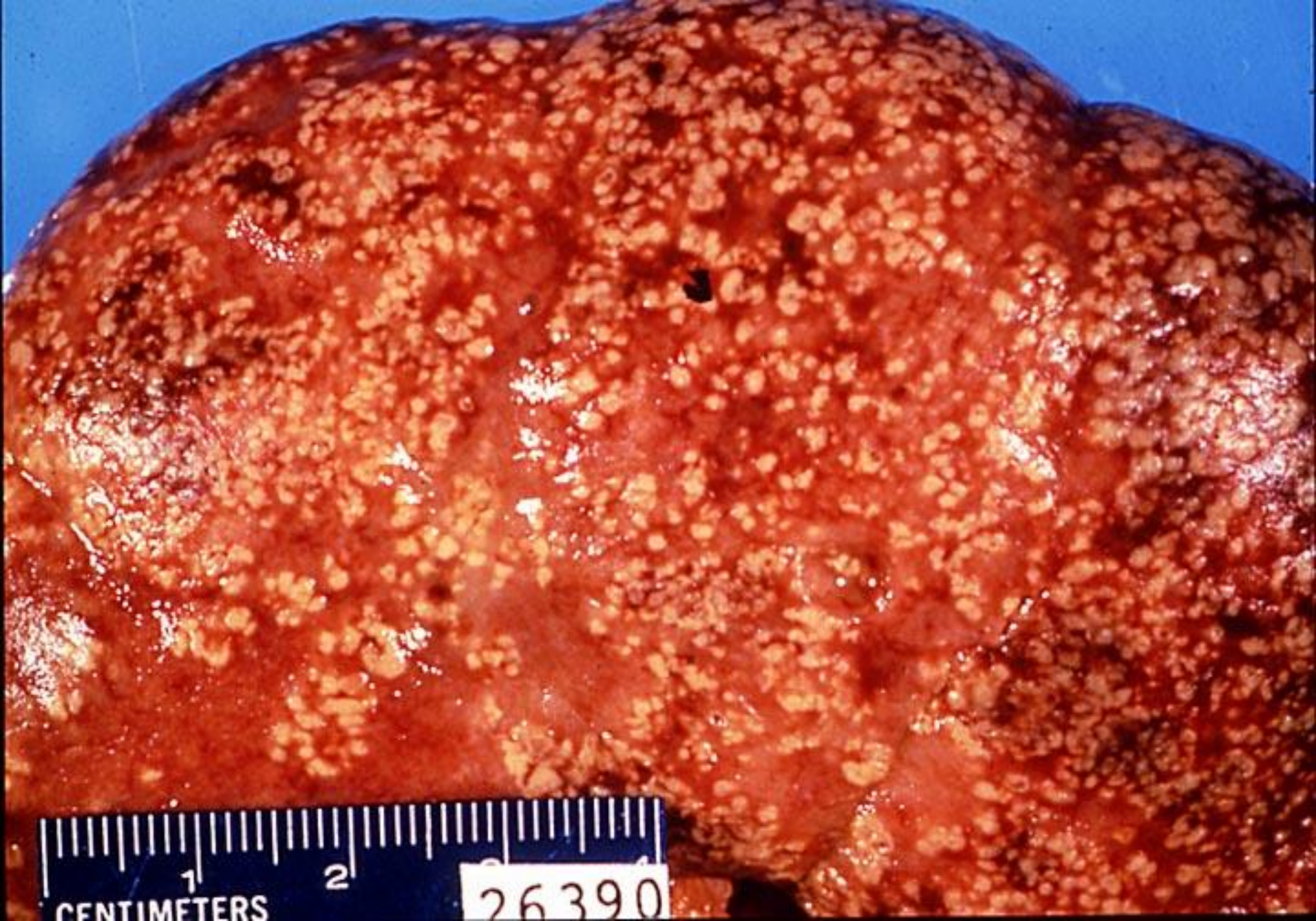
ASCENDING, by FAR, the most common, i.e., reflux, obstruction  
HEMATOGENOUS



ACUTE or CHRONIC PYELONEPHRITIS?

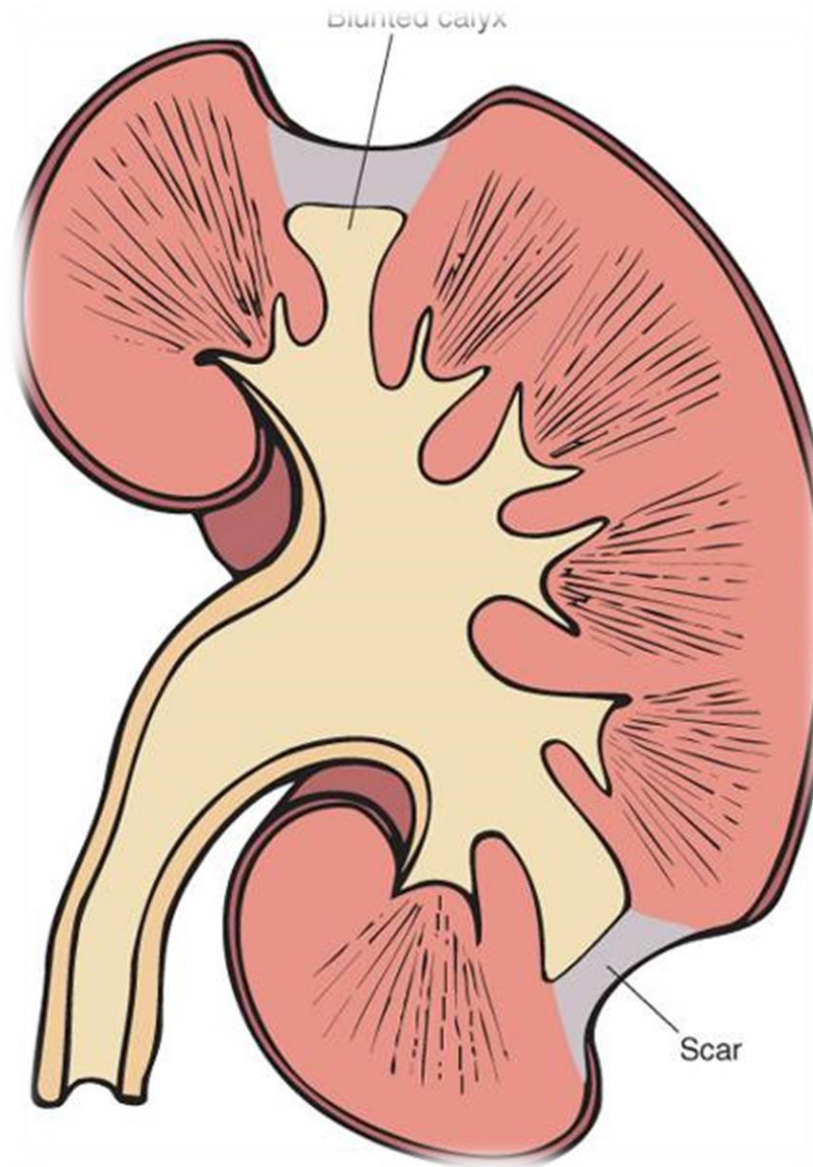
# ACUTE PYELONEPHRITIS WITH ABSCESES





**Acute purulent pyelonephritis**

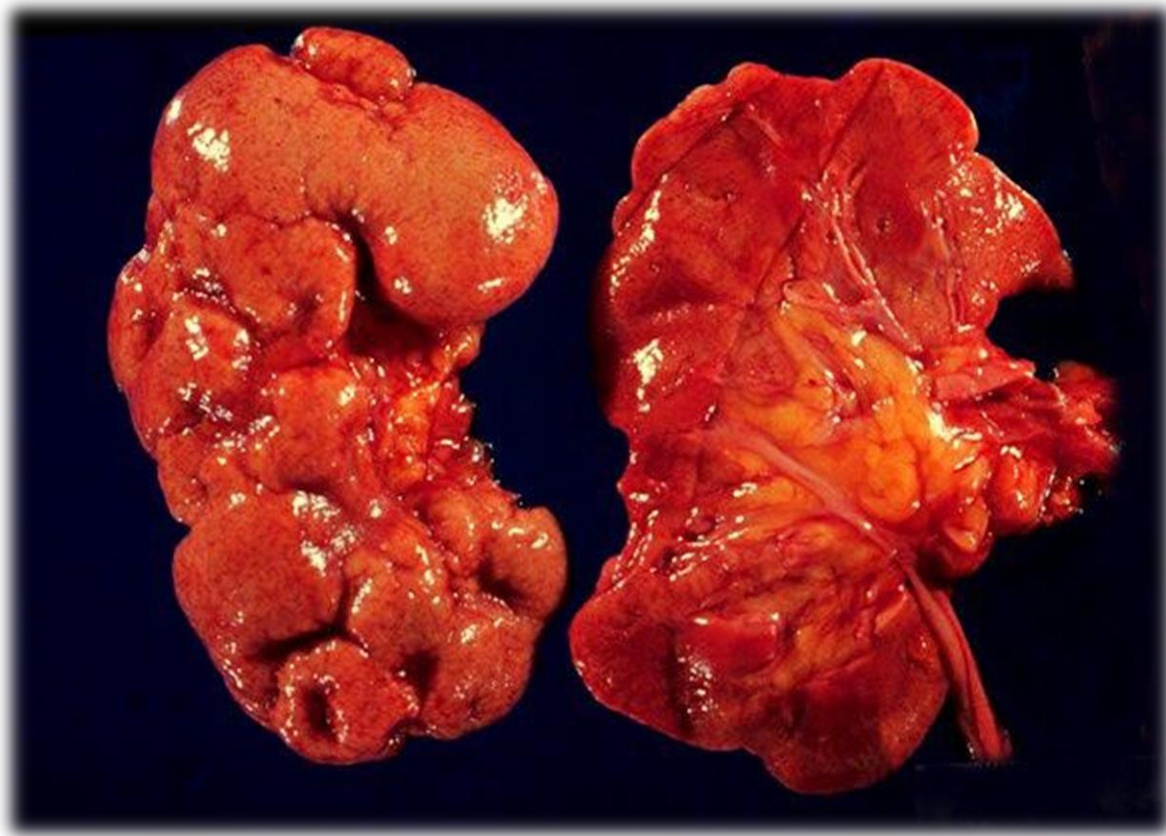# CHRONIC PYELONEPHRITIS



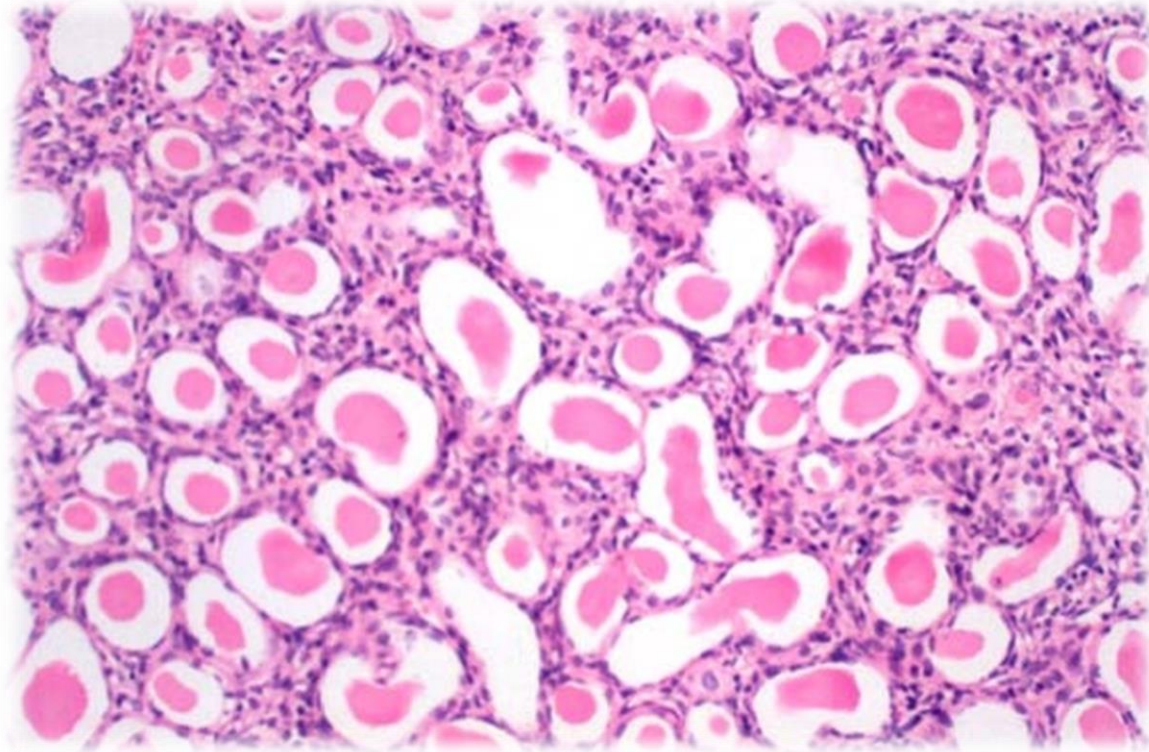




# ACUTE or CHRONIC PYELONEPHRITIS?



# “THYROIDIZATION” in CHRONIC PYELONEPHRITIS



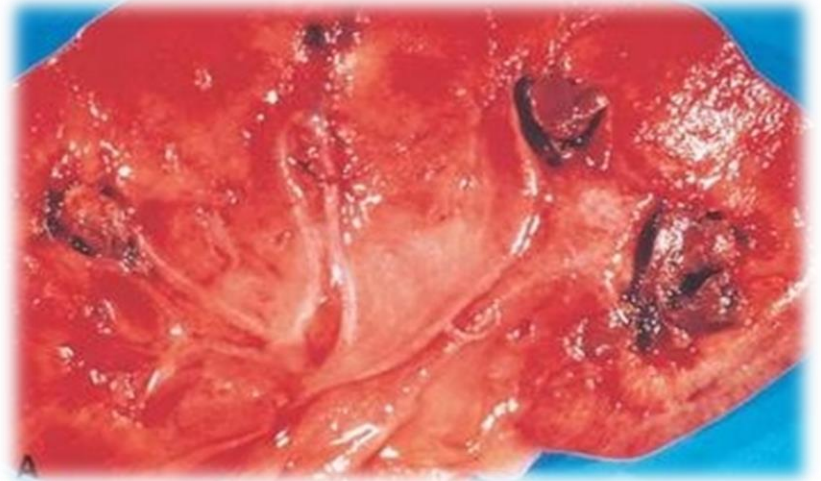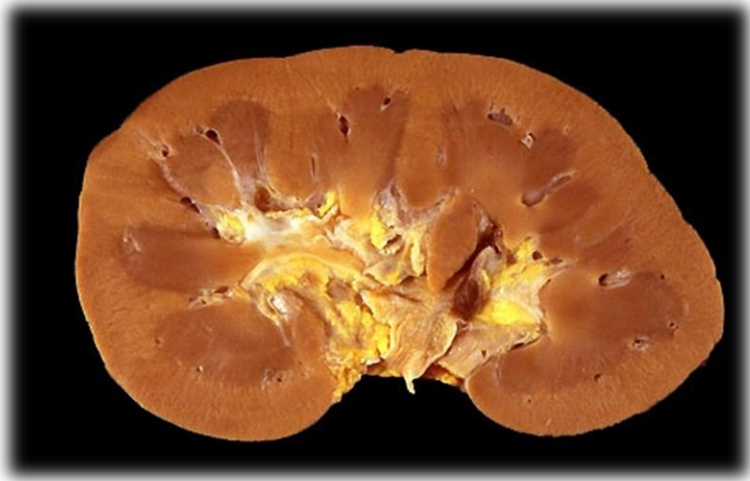# FACTORS

- ◎ **OBSTRUCTION: Congenital or Acquired**
- ◎ **INSTRUMENTATION**
- ◎ **VESICoureTERAL REFLUX**
- ◎ **PREGNANCY**
- ◎ **AGE, SEX, why sex? F>>>M**
- ◎ **PREVIOUS LESIONS**
- ◎ **IMMUNOSUPPRESION or IMMUNODEFICIENCY**

# ANALGESIC NEPHROPATHY

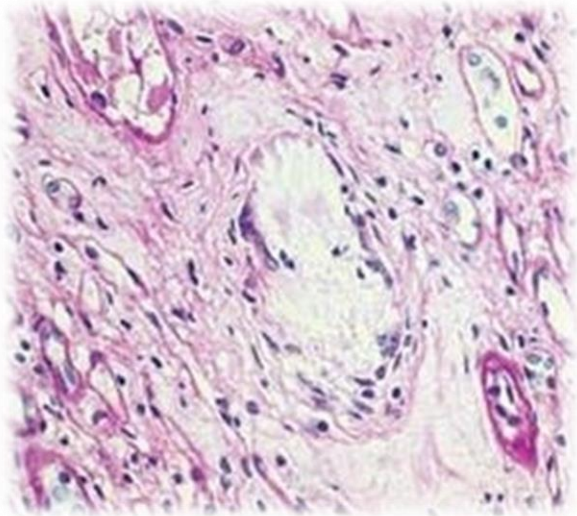
## ◎ ASPIRIN, TYLENOL, NSAIDS

- TUBULOINTERSTITIAL NEPHRITIS
- PAPILLARY NECROSIS

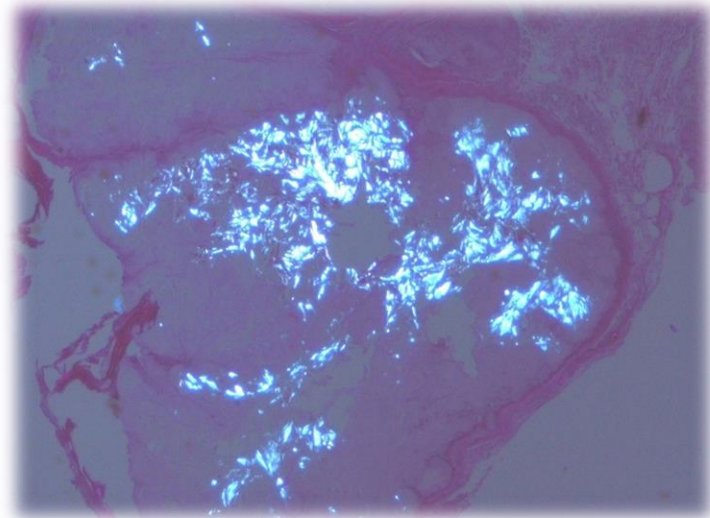


# URATE NEPHROPATHY

- ◎ Precipitation of Uric Acid Crystals in the TUBULES, especially in a LOWER than usual PH situation (mini-TOPHUS)



**H & E alcohol fixed**



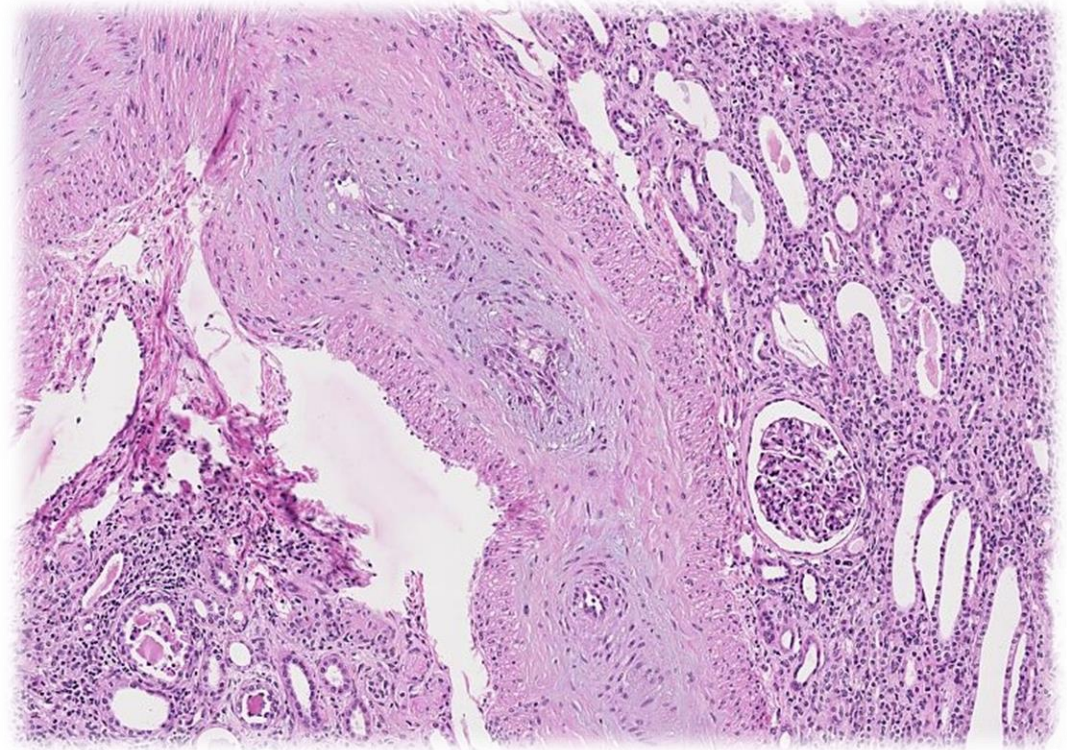
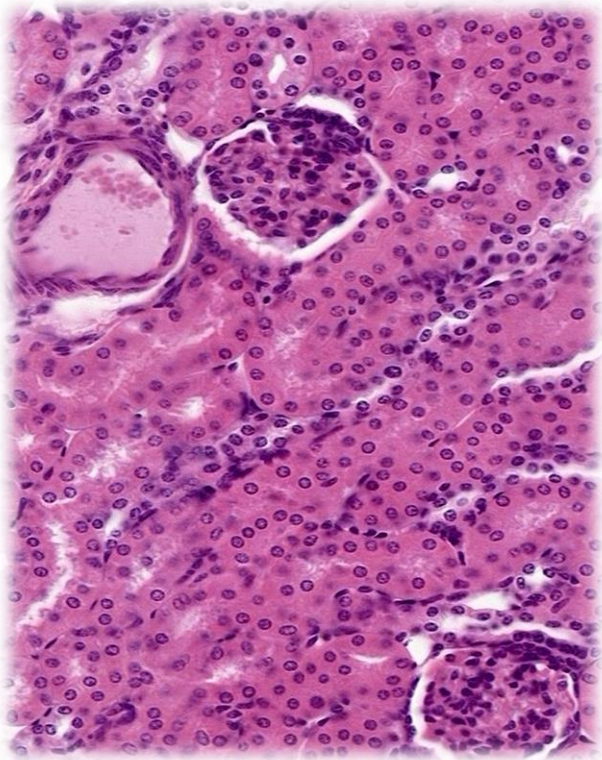
**POLARIZED LIGHT MICROSCOPY**

# VASCULAR DISEASES

- **BENIGN NEPHROSCLEROSIS**
- **MALIGNANT NEPHROSCLEROSIS (i.e., malignant hypertension)**
- **RENAL ARTERY STENOSIS**
- **THROMBOTIC MICROANGIOPATHIES**
  - Hemolytic-Uremic Syndromes, Child, Adult, TTP
- **THROMBI, EMBOLI, INFARCTS**
  - **SICKLE CELL**
  - **DIFFUSE CORTICAL NECROSIS**

# BENIGN NEPHROSCLEROSIS

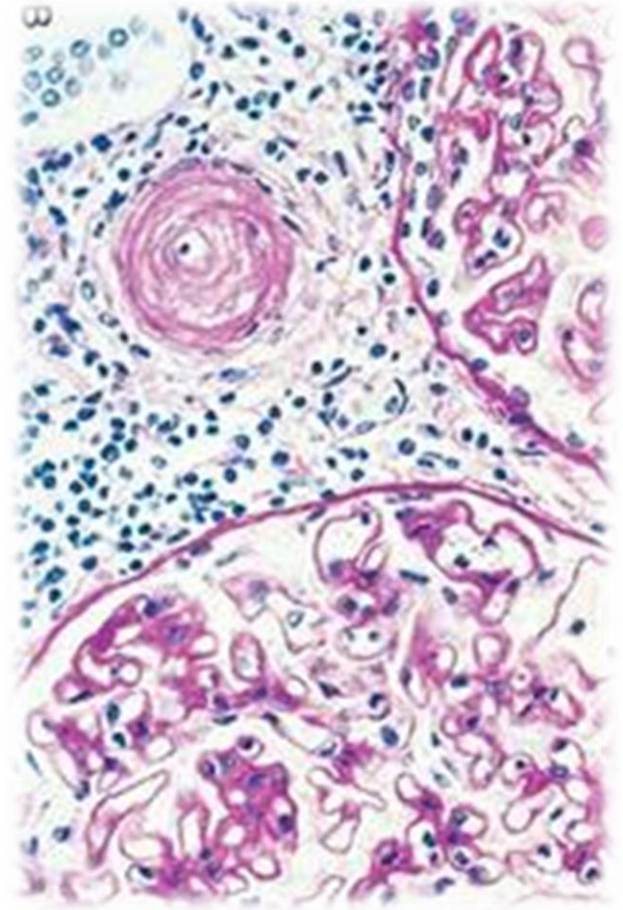
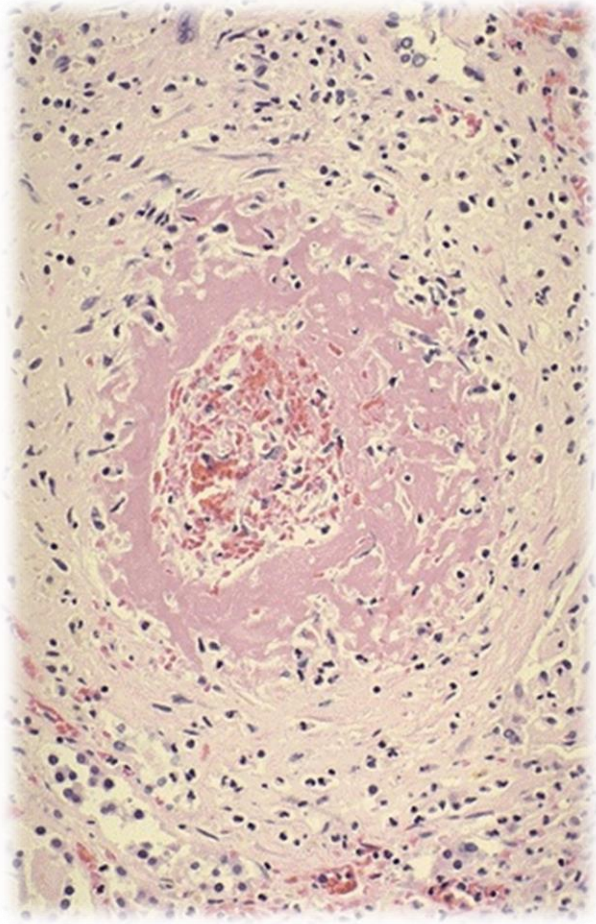
© Sclerosis, i.e., “hyalinization” of arterioles and small arteries, i.e., **arterio-, arteriolo-sclerosis**



# MALIGNANT NEPHROSCLEROSIS (i.e., malignant hypertension)

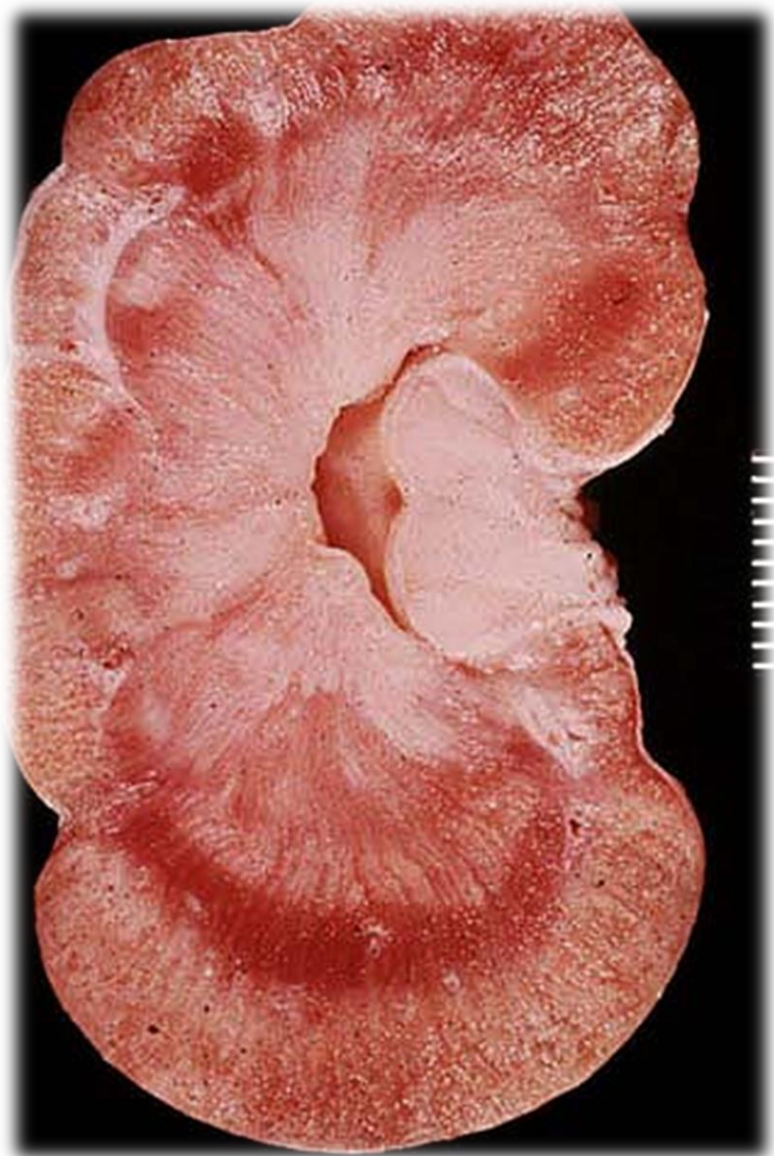
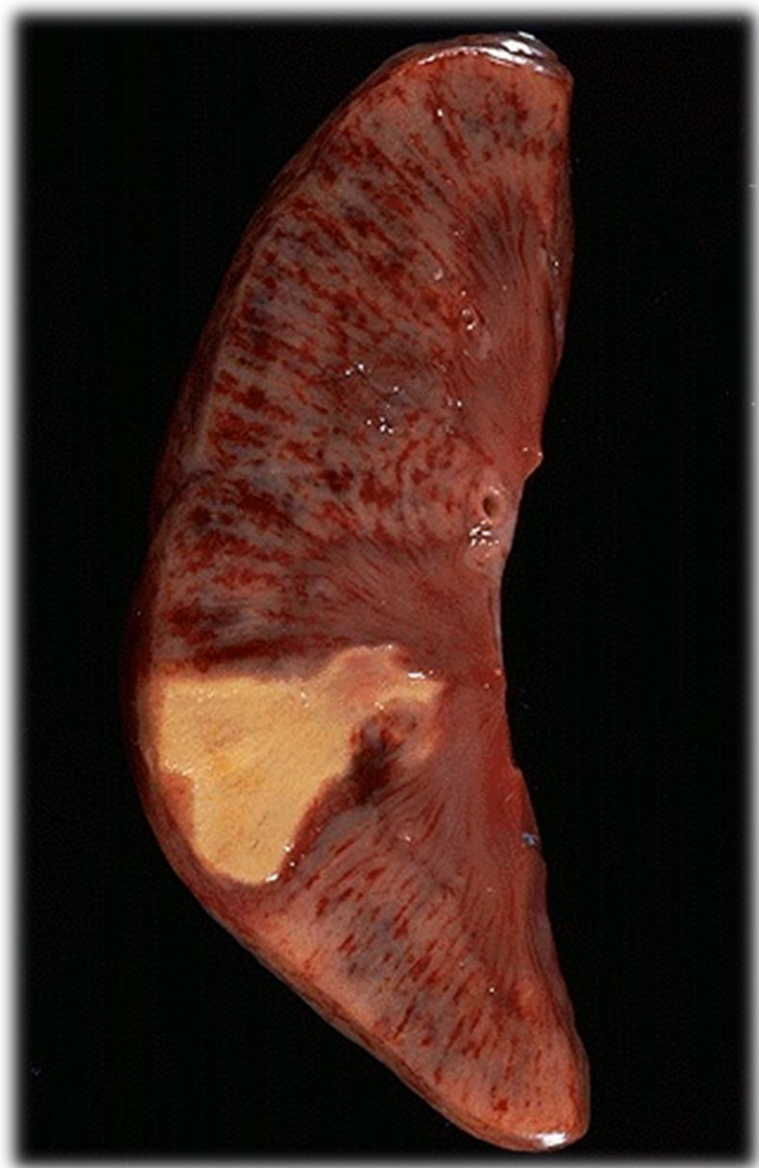
- **NOT a part of “routine” atherosclerosis**
- **By definition, associated with rapidly progressive hypertension (1-2% of HTN)**
- **VASCULAR DAMAGE**
- **FIBRINOID NECROSIS**
- **“ONION SKINNING”**
- **SIGNIFICANT LUMENAL NARROWING**

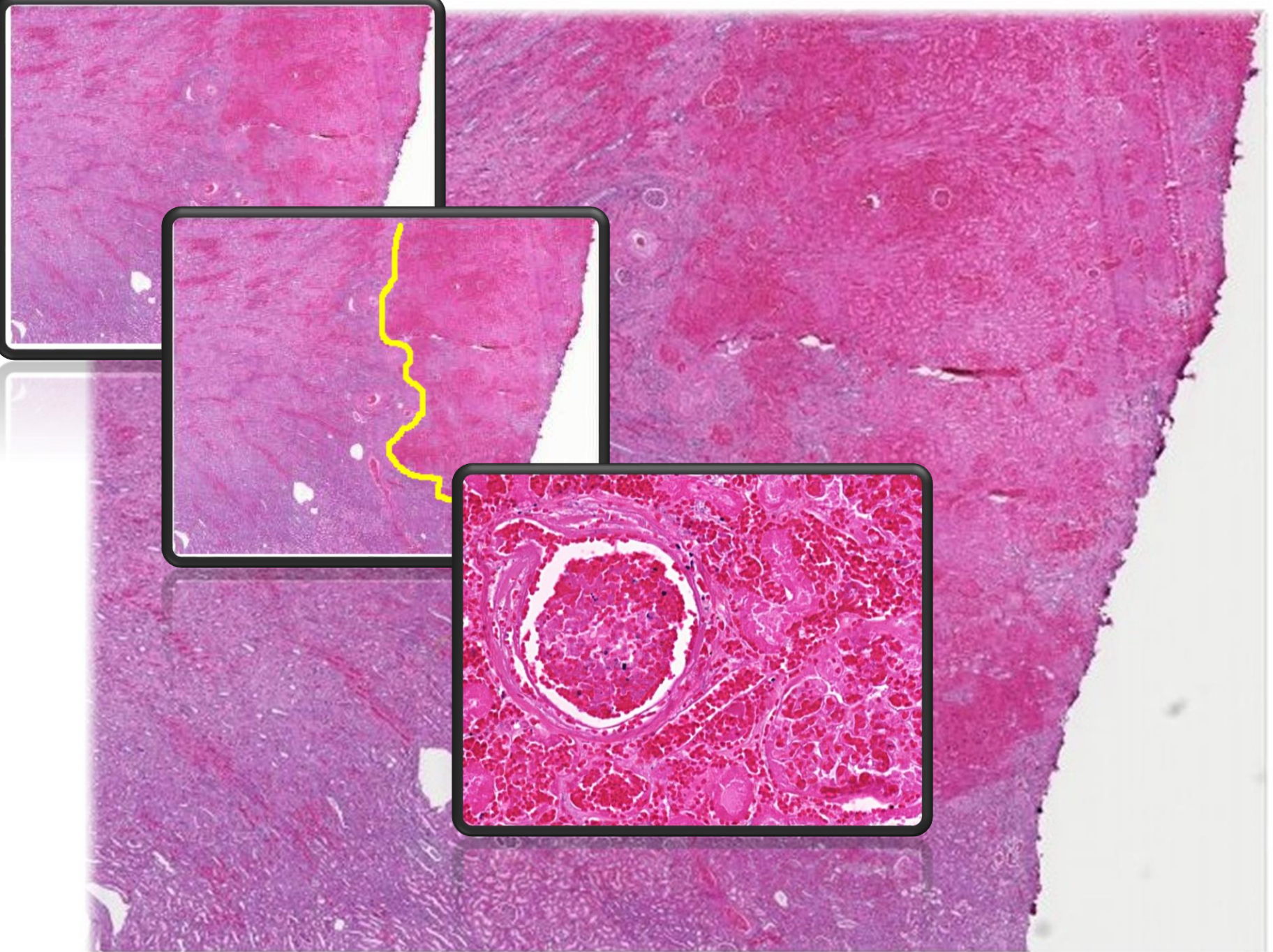




# RENAL INFARCTS

- **WEDGE SHAPED**
- **WELL DELINEATED**
- **“WHITE” (anemic) INFARCT**
- **Perhaps a little “YELLOW”**
- **HEAL WITH A SCAR**





# OBSTRUCTIONS

## ◎ UROLITHIASIS

◎ CONGENITAL

◎ PROSTATE ENLARGEMENT

◎ TUMORS

◎ INFLAMMATION

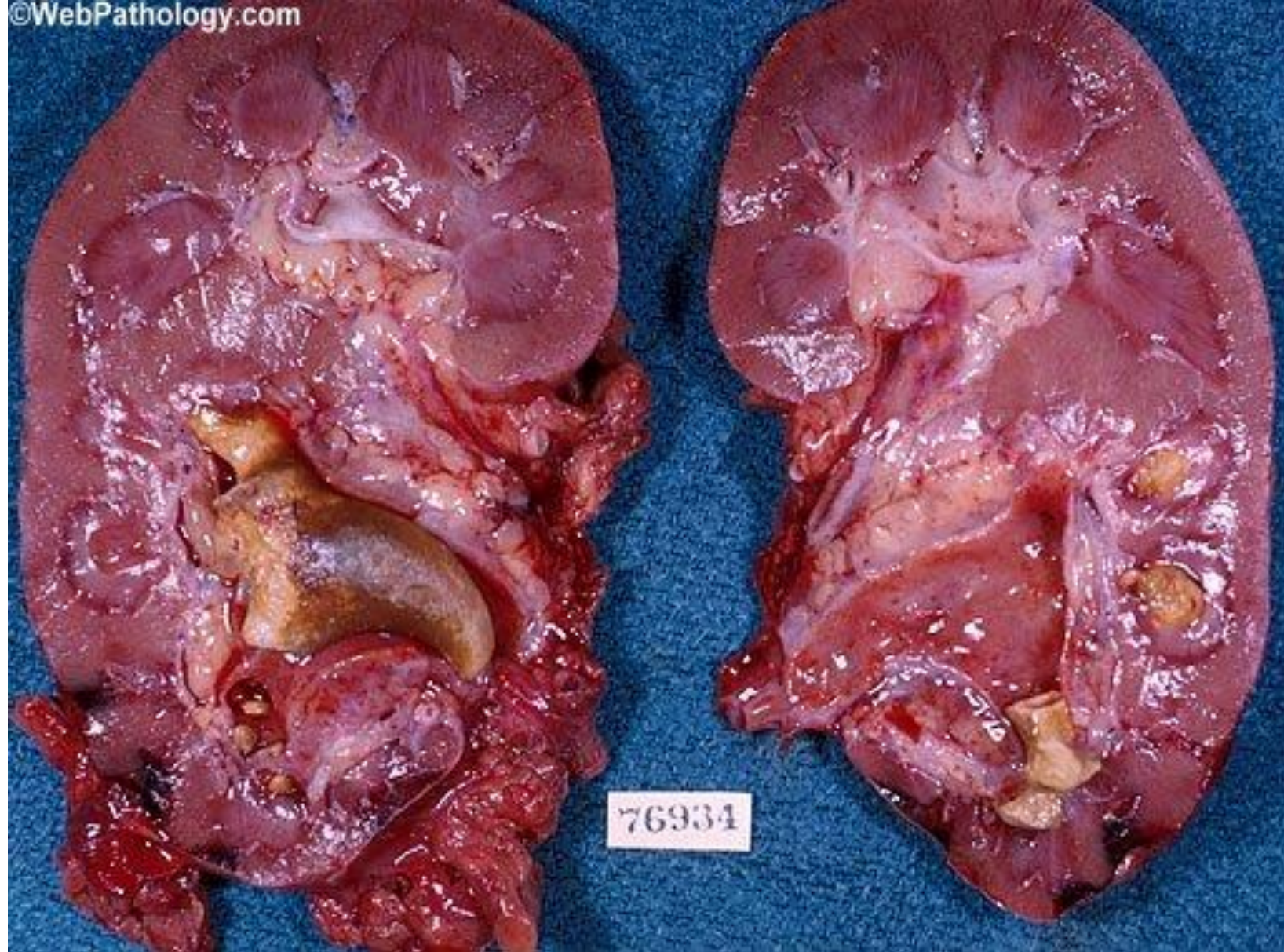
◎ SLOUGHED CLOTS, PAPILLAE

◎ PREGNANCY

◎ NEUROGENIC

# UROLITHIASIS

- **CALCIUM (OXALATE or PHOSPHATE)**  
**70%**
- **MAGNESIUM AMMONIUM  
PHOSPHATE 20%**
- **URIC ACID 10%**



76934

# TUMORS

## ◎ BENIGN

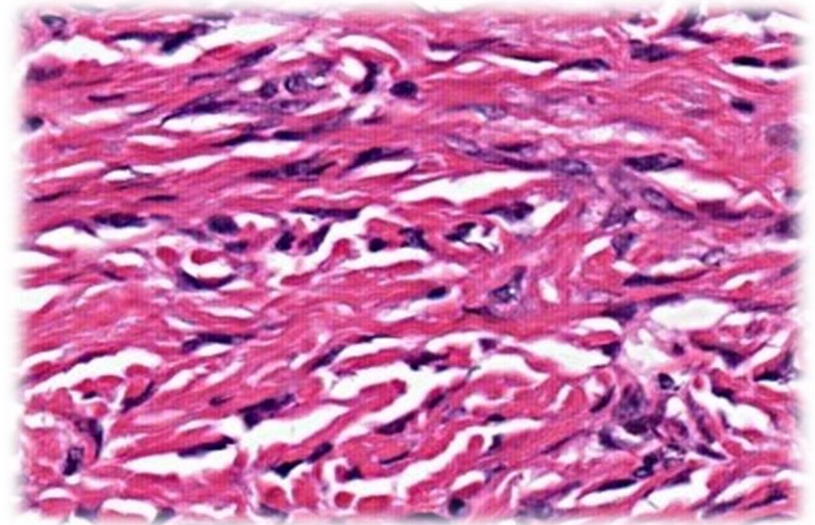
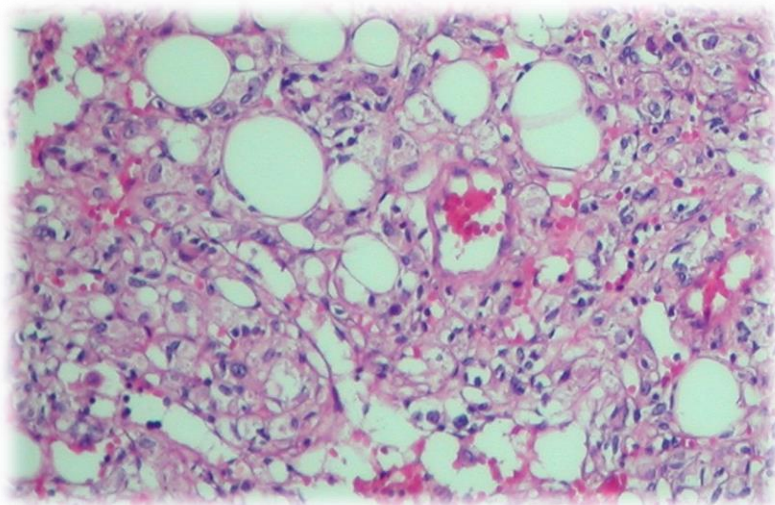
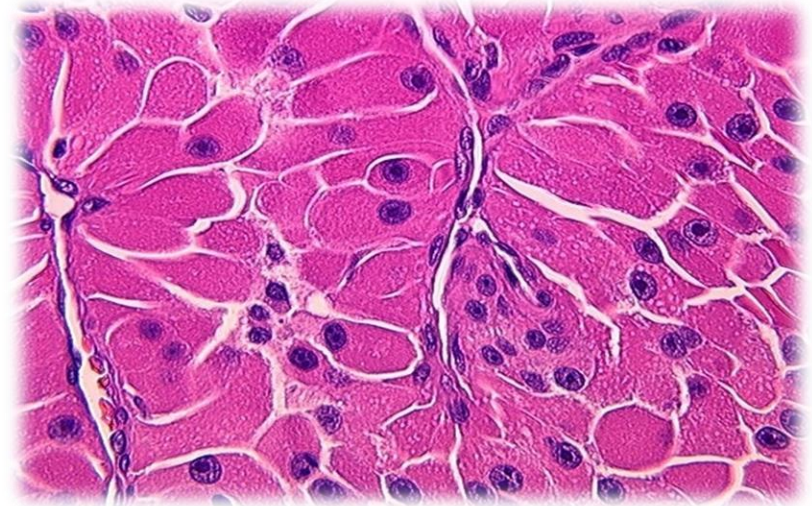
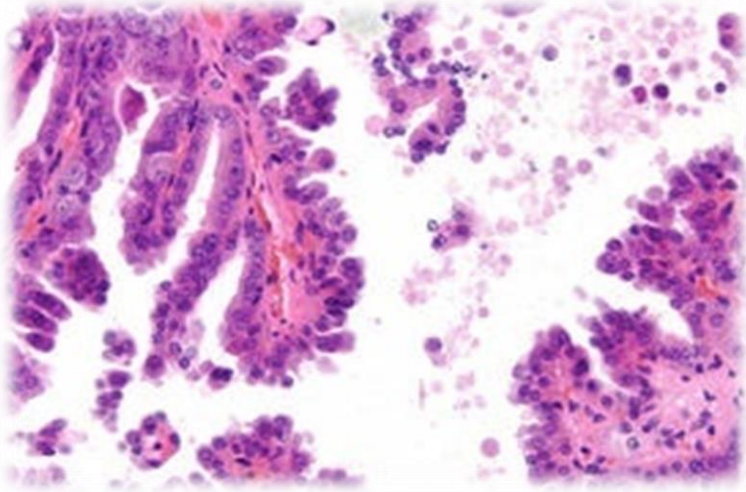
- Papillary Adenoma
- Fibroma/Hamartoma
- Angiomyolipoma
- Oncocytoma

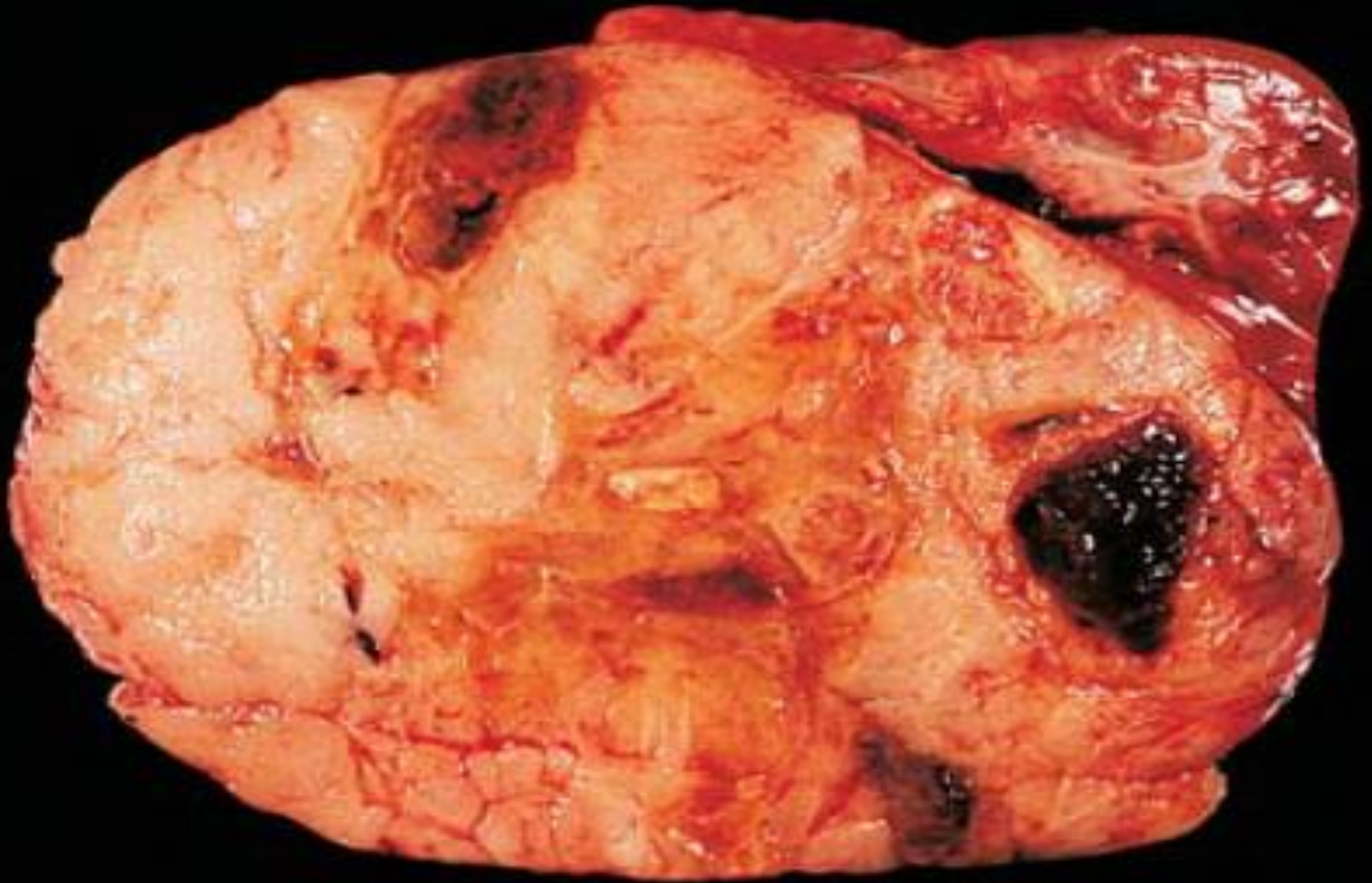
## ◎ MALIGNANT

- Renal Cell Carcinoma (Clear Cell Carcinoma, Adenocarcinoma, Hypernephroma)
- Urothelial (Transitional)

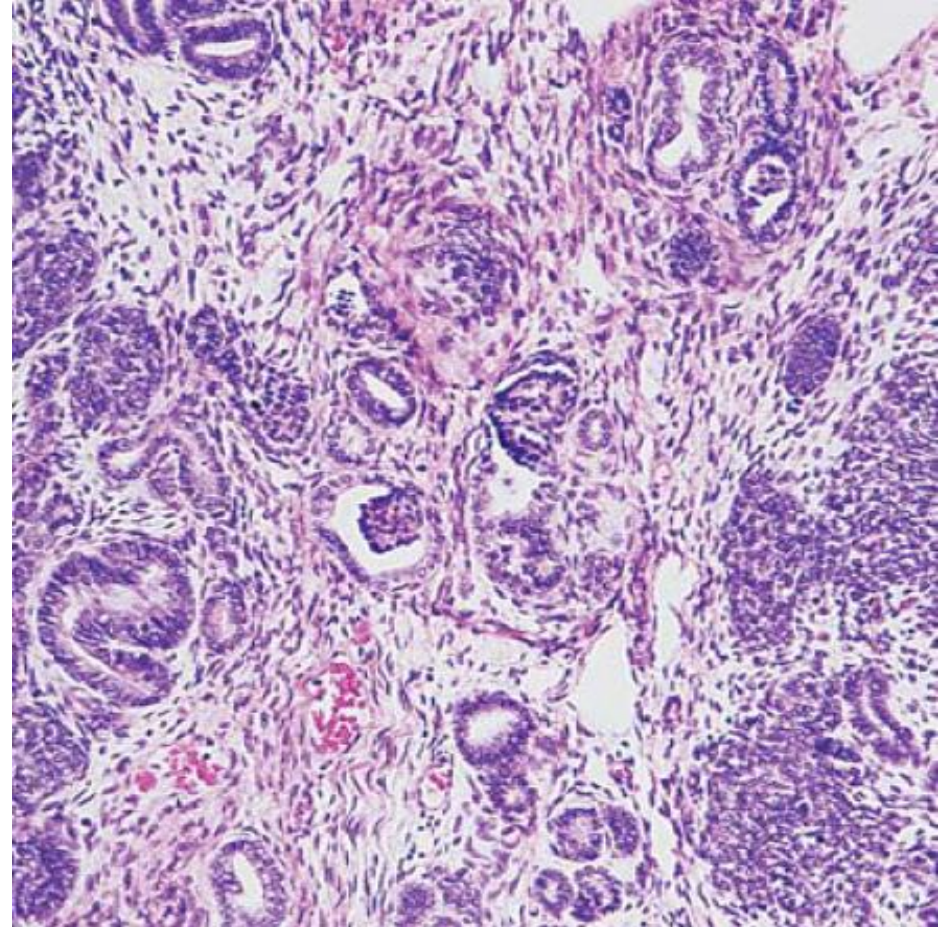
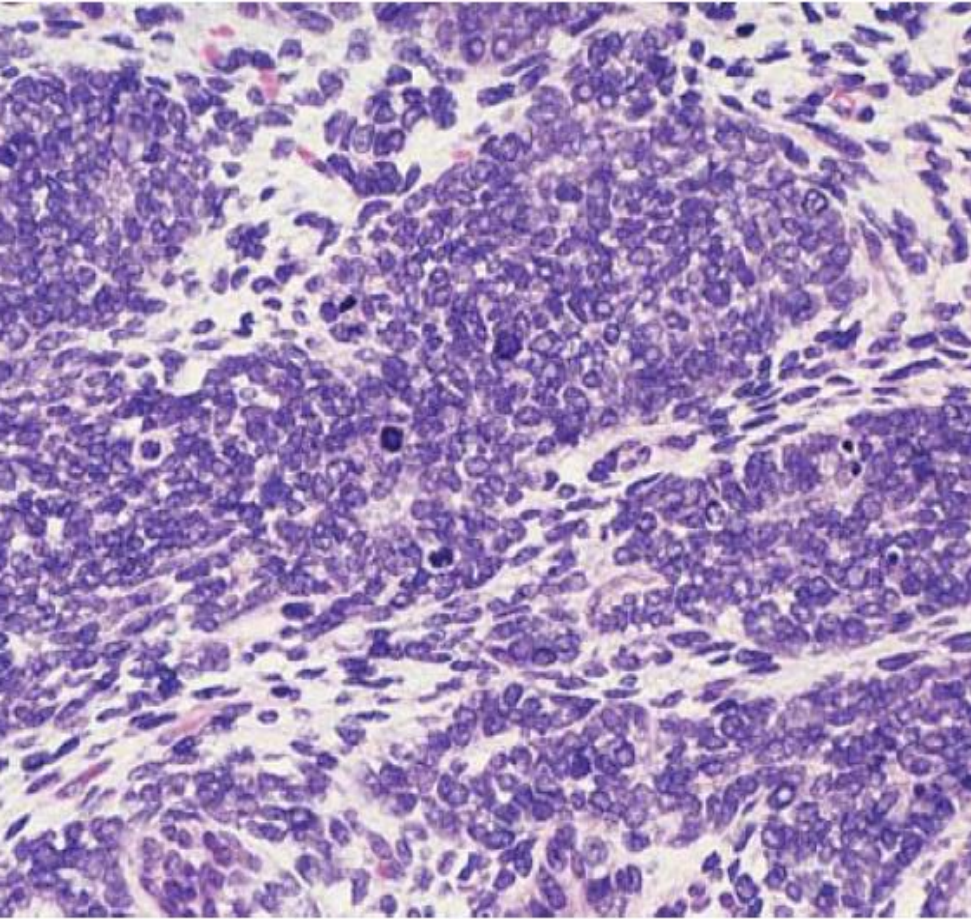


# Papillary Adenoma, Fibroma/Hamartoma, Angiomyolipoma, Oncocytoma





**Wilms tumor (nephroblastoma)**



## **Wilms tumor**

***( microscopic view  
showing a combination of metanephric blastema,  
stroma, epithelial tubular formation, and immature glomeruli)***

# RENAL CELL CARCINOMA

- ◎ **TOBACCO RELATED, STRONGLY**

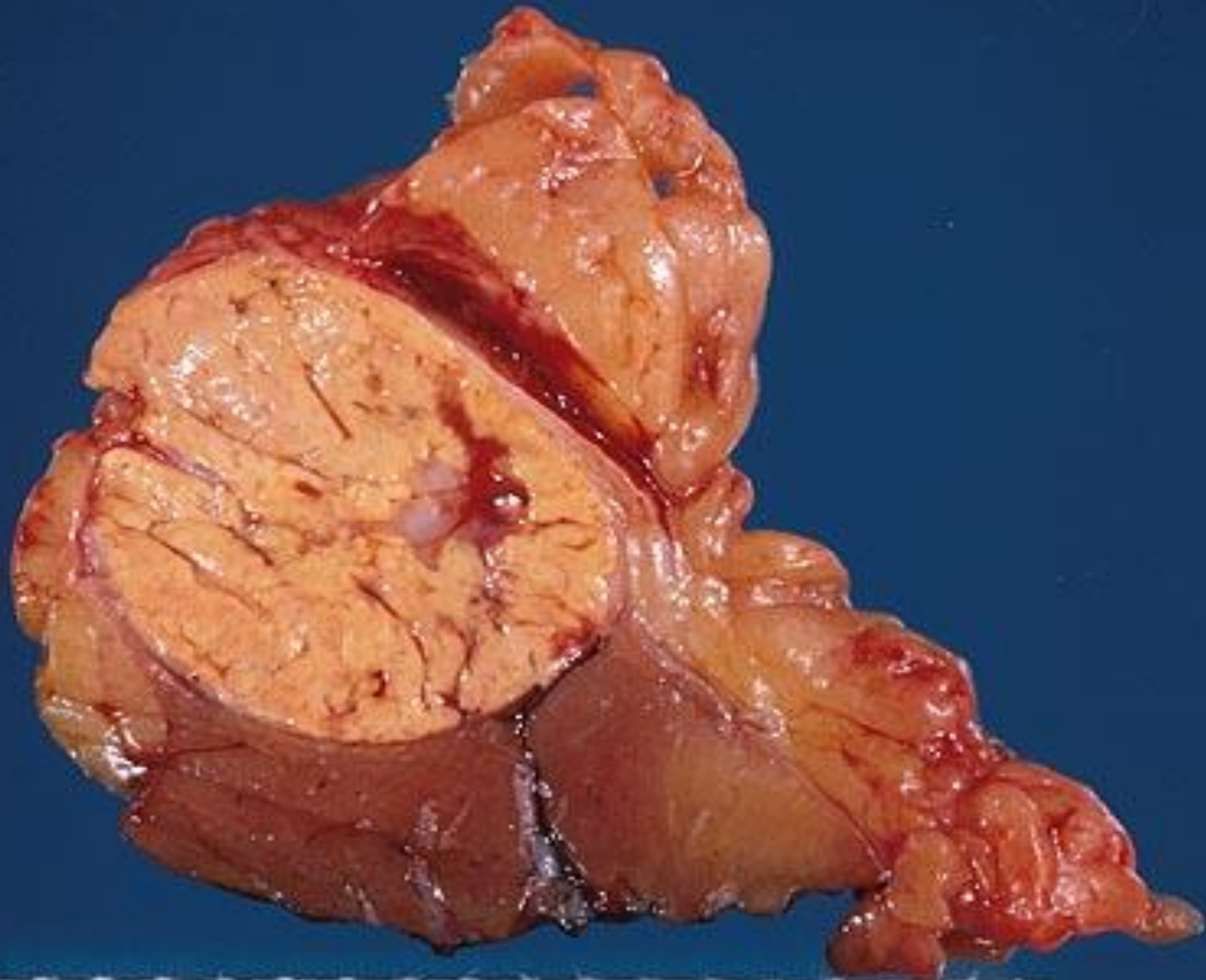
- ◎ **SOME HEREDITARY/FAMILIAL**

- ◎ **von Hippel-Lindau (VHL) VHL gene on chromosomal band 3p25**

- ◎ **MOST are “CLEAR CELL”, a few PAPILLARY**

- ◎ **YELLOW grossly, “CLEAR” cells microscopically**

- ◎ **STRONGLY tend to invade the renal VEIN early, in preference to lymphatics.**



MM 1 2 3 4 5

# **Renal cell carcinoma (Grawitz tumor)**

A histological micrograph of renal cell carcinoma, showing a dense population of tumor cells. The cells are arranged in a solid, nested pattern. The cytoplasm of the cells varies in appearance, with some being clear and others being dark, indicating different cellular components or stages of the tumor.

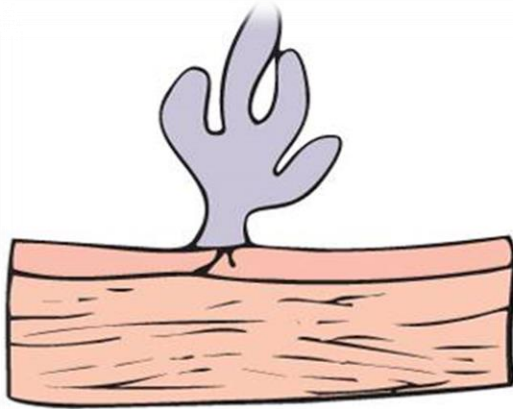
**clear cell type**

**dark cell type**

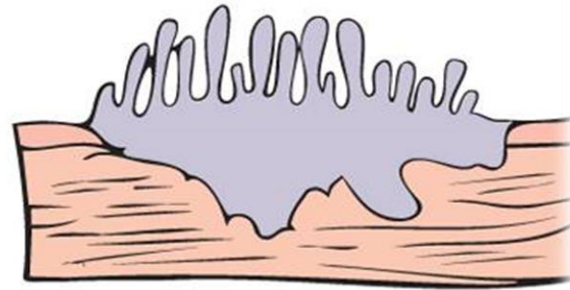# UROTHELIAL (TRANSITIONAL) RENAL CARCINOMAS

- ◎ In renal pelvis.
- ◎ 1/10 as common as renal cell carcinomas
- ◎ EXACTLY the same appearance as lower urinary tract carcinomas.
- ◎ MUCH more likely to obstruct the kidney than renal cell carcinomas.
- ◎ Associated with ureter and bladder carcinomas.

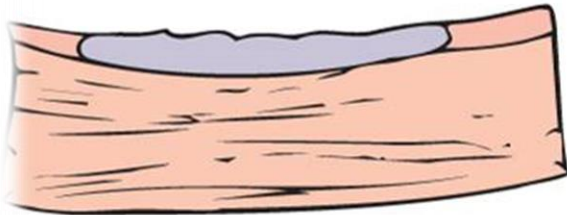
# RENAL CARCINOMAS



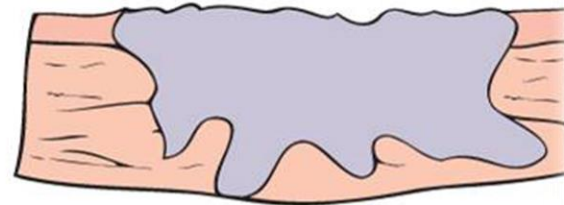
Papilloma-  
papillary carcinoma



Invasive  
papillary carcinoma

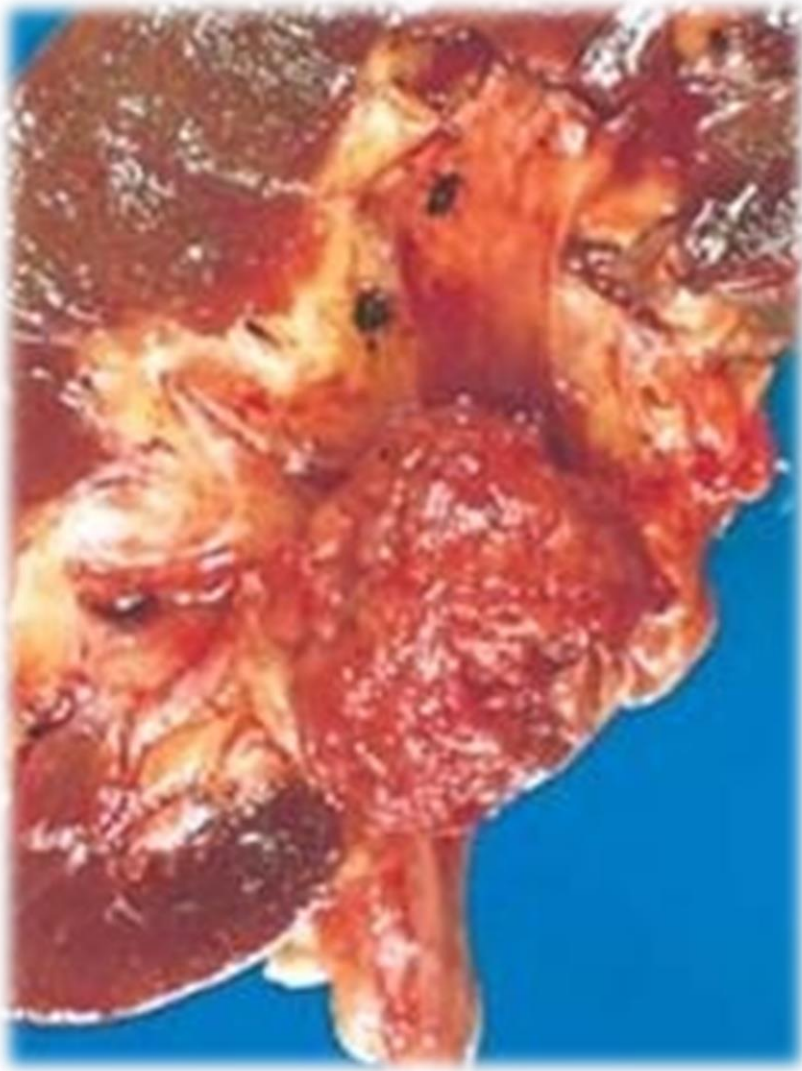

Flat noninvasive  
carcinoma



Flat invasive  
carcinoma





**The most likely place for a transitional (urothelial) carcinoma, is smack dab in the HILUM**

