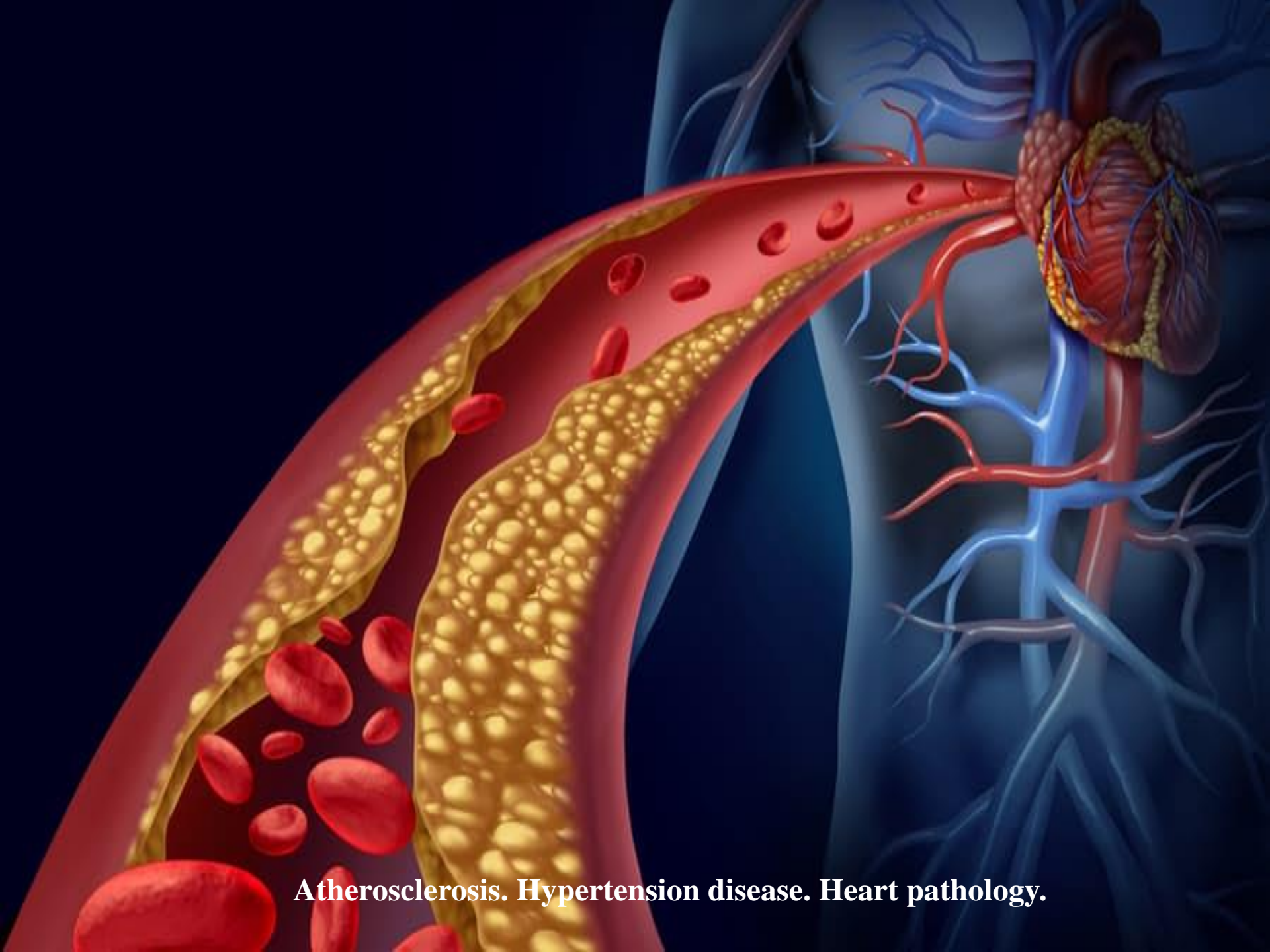

Atherosclerosis. Hypertension disease. Heart pathology.

Atherosclerosis. Hypertension disease. Heart pathology.

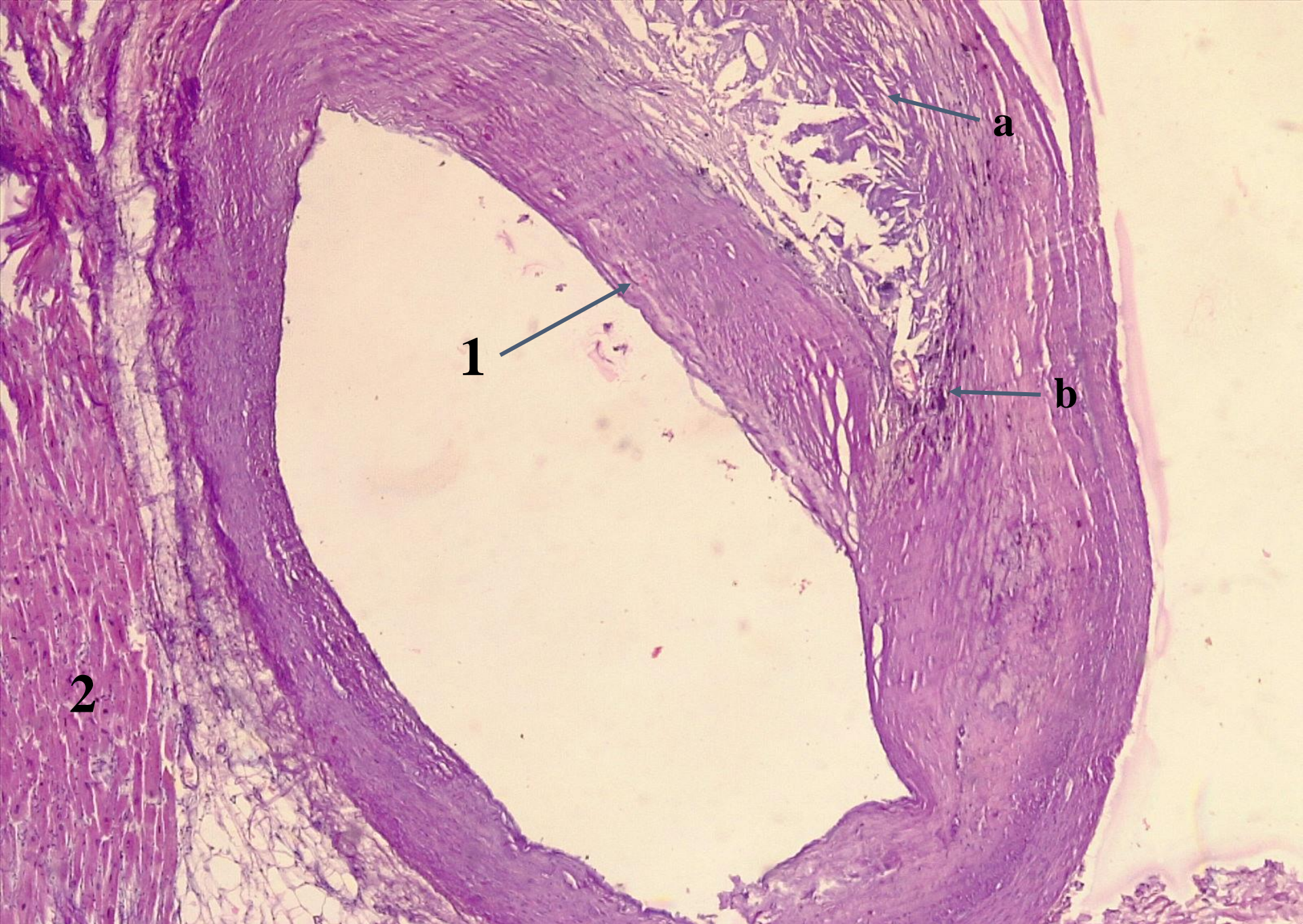
I. Microspecimens:

№ 155. Stenosing coronary atherosclerosis. (H-E stain). Indications:

1. Stenosing atherosclerotic plaque in the artery wall.
 - a. cholesterol crystals;
 - b. calcium deposits.
2. Adjacent heart muscle.

Cross section through the subepicardial coronary artery with the underlying myocardium. Grossly, it can be seen that the wall of the artery is unevenly thickened, the lumen stenotic, in some parts blue-violet calcium deposits. Atherosclerotic plaque - focal, eccentric thickening of the wall, separated from the lumen of the vessel by the fibrous capsule - a thick, dense layer of collagen fibers with diffuse hyaline, stained homogeneous eosinophil; in the center of the plate deposits of optically empty aciculate crystals empty of cholesterol, amorphous masses of lipids and weakly eosinophilic tissue detritus, around foam cells, fibrosis, granular deposits of calcium, lymphocytes, plasma cells. Myocardium with normal structure.

Atherosclerosis is manifested morphologically by the appearance in the arteries of large and medium caliber of focal thickening, dense of the intima, which stenoses the lumen, called atherosclerotic plaques, fibrous plaques, fibrolipids or atheromas. Microscopically the atheroma has the following structure: the luminal surface is covered by the fibrous capsule, made up of collagen fibers with diffuse hyaline, under the capsule the center or necrotic nucleus formed by necrotic residues, intra- and extracellular lipids (especially cholesterol and cholesterol esters), cells foamy (macrophages and smooth muscle cells, containing lipids), collagen, fragments of disintegrated elastic fibers, fibrin and other plasma proteins, macrophages, lymphocytes, calcium salts. At the periphery of the atheroma, neovascularization processes (neof ormation of blood vessels) are revealed. Deeper than the necrotic center is the atrophied and fibrous middle sheath. These components of the atheroma can be in different proportions. In "stable" atheromas, the fibrous capsule is thickened, dense, the necrotic center and inflammation are pronounced, the fibrosis process predominates. In "unstable", "vulnerable" atheromas, the capsule is thin, fine, the necrotic center rich in lipids, active inflammation, the plaques being susceptible to erosions, ulcerations, thrombosis, hemorrhages, which leads to acute ischemia of the tributary areas of the vessel. In coronary artery atherosclerosis stenosis leads to chronic ischemia and diffuse cardiosclerosis, and acute ischemia - to myocardial infarction.



№ 155. Stenosing coronary atherosclerosis. (H-E stain).

№ 67. Atherosclerotic microfocal cardiosclerosis. (*picrofucsin, van Gieson stain*).

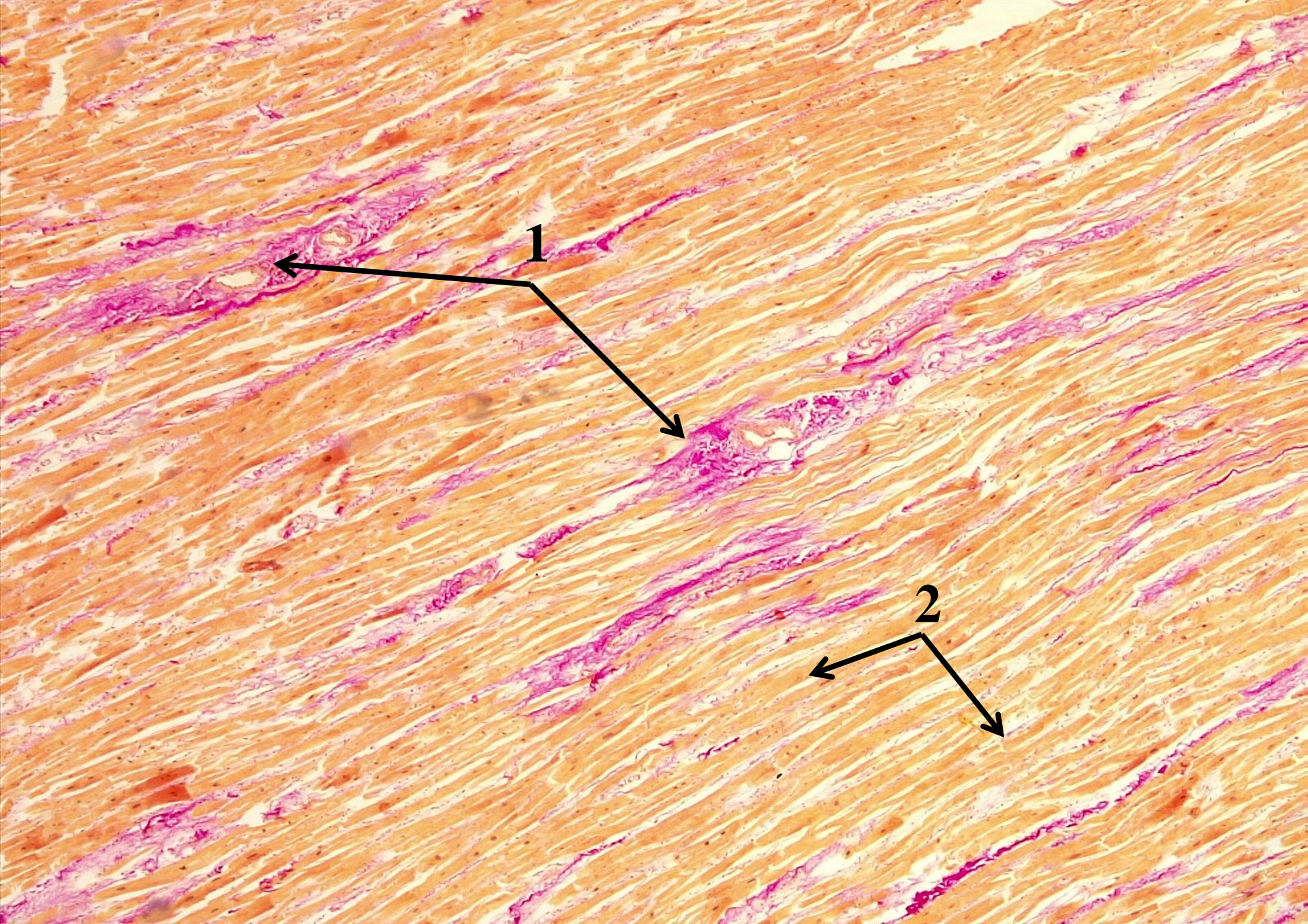
Indications:

1. Collagen fibers (colored in red).
2. Muscle fibers (colored in yellow).

Microscopically reveals multiple bundles of red collagen fibers, of different thickness, located among the myocardial fibers, predominantly perivascular, most cardiomyocytes have a normal appearance, cytoplasm colored yellow, some slightly atrophied.

Diffuse cardiosclerosis is a process of diffuse excessive proliferation of connective tissue in the heart wall. It is the morphological substrate of chronic ischemic heart disease, including ischemic heart disease. The main causative factor is stenotic atherosclerosis of the coronary arteries, chronic ischemia causing dystrophic and atrophic lesions of cardiomyocytes and proliferation of fibroconjunctival tissue. The process of sclerosis is more pronounced perivascular, around the small-caliber arteries. Possible complications: congestive heart failure, heart and conduction disturbances.

Diffuse cardiosclerosis can also develop from interstitial myocarditis, eg in rheumatism, diphtheria, influenza, measles, sepsis.



№ 67. Atherosclerotic microfocal cardiosclerosis. (*picrofucsin, van Gieson stain*).

№ 65. Acute myocardial infarction. (H-E stain). Indications:

1. Infarct area (karyolysis).
2. Adjacent myocardium.

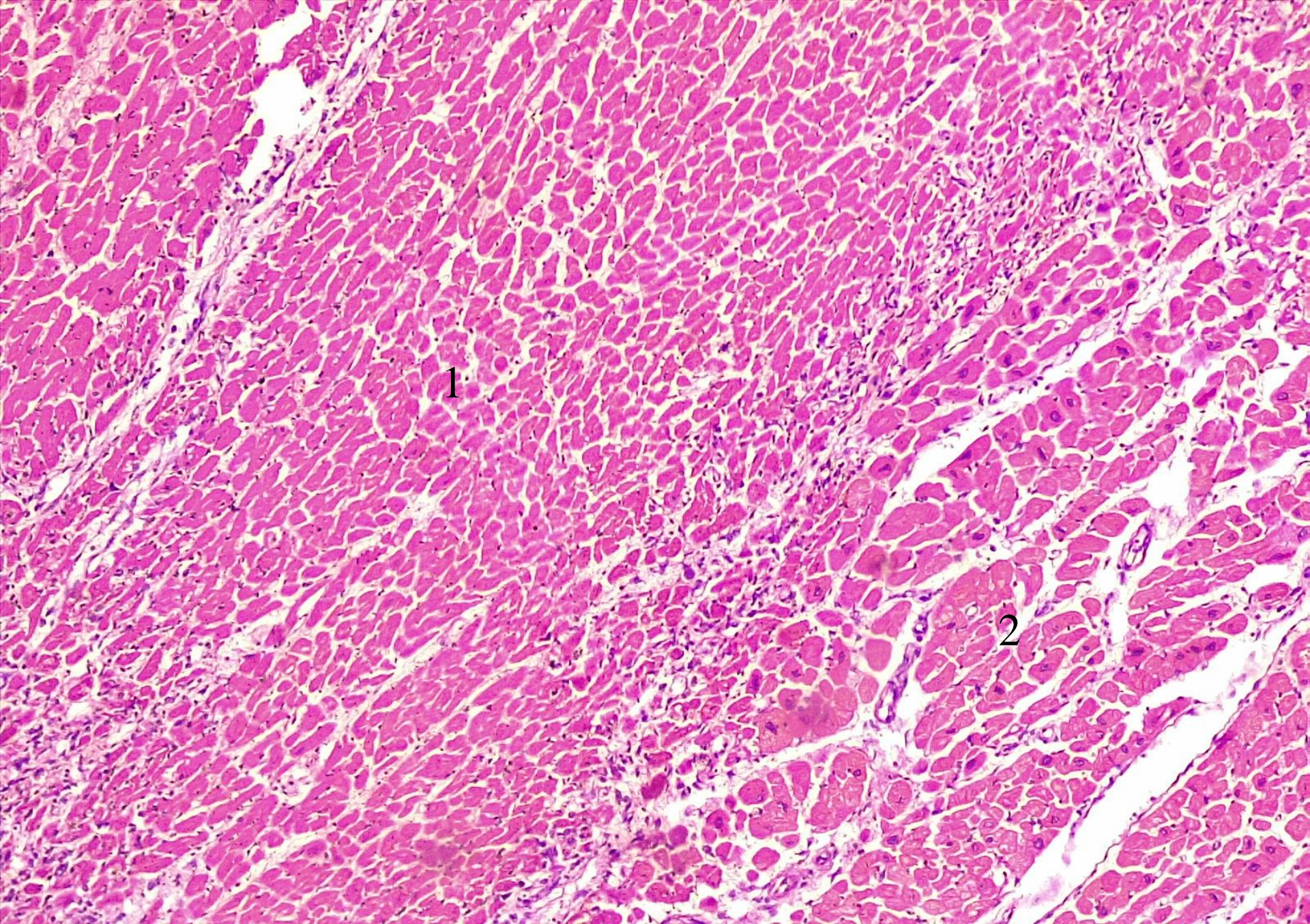
In the myocardium there are areas of necrosis with cardiomyocyte caryolysis, sarcoplasmic eosinophilia, some cells in disintegration (plasma-cytorexis), at the periphery of necrotic foci hemorrhages, leukocyte infiltration, in adjacent areas cardiomyocytes with stromal edema, 2 neighboring cells were detected - one necrotic, anucleated and another with a persistent nucleus.

№ 65a. Myocardial infarction in stage of organization. (H-E stain). Indications:

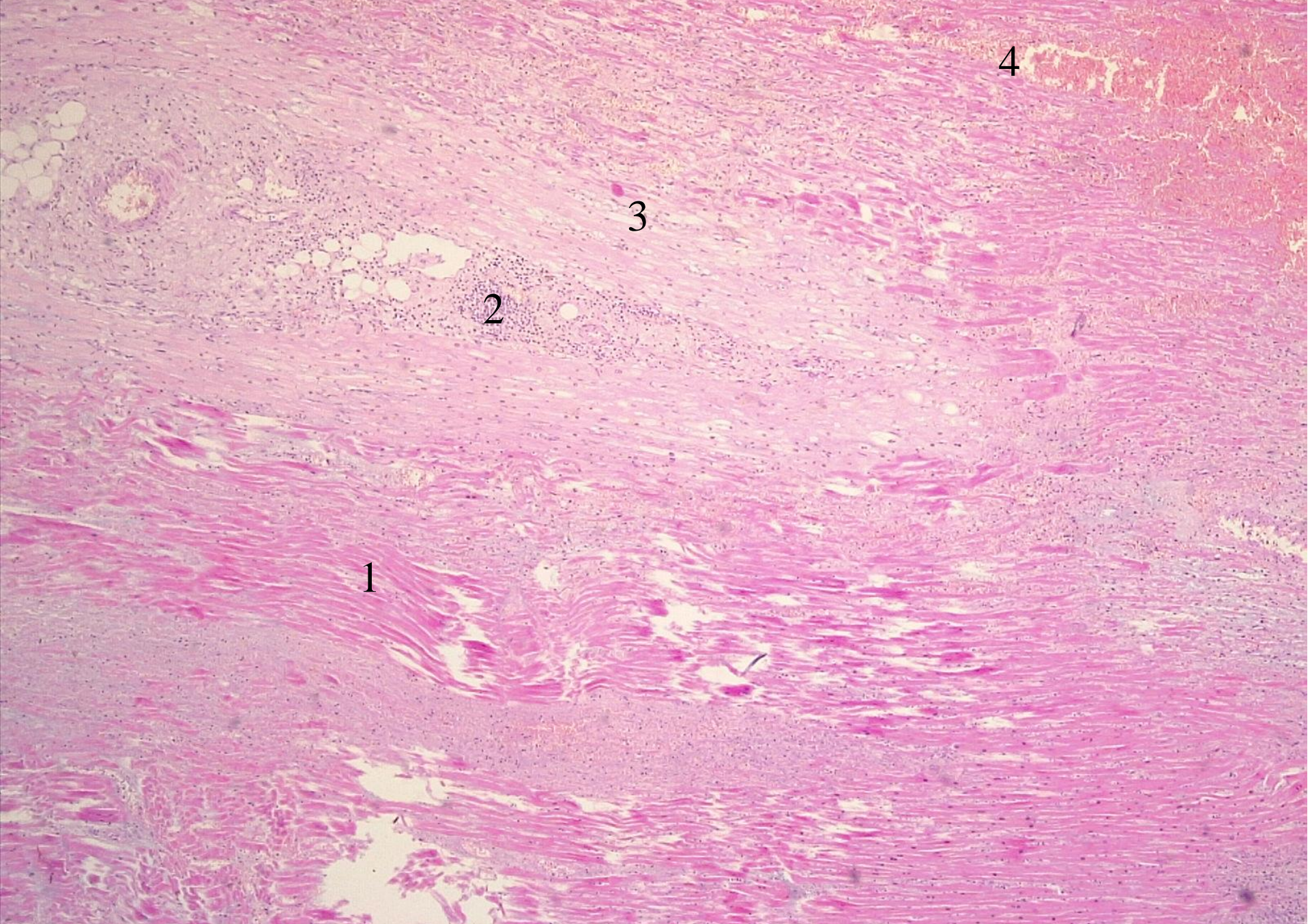
1. Infarct area.
2. Leukocyte infiltration at the periphery of the infarct area.
3. Granulation tissue around the area of necrosis.
4. Adjacent myocardium.

In the myocardium necrotic foci are detected with cardiomyocyte caryolysis, some cells with signs of plasma cytorexis, in some places form homogeneous, structured eosinophilic foci (necrotic detritus), leukocyte infiltration and hemorrhages are observed; these areas are surrounded by granular tissue rich in capillaries and cellular elements; in the adjacent heart muscle protein dystrophy of cardiomyocytes, stromal edema.

In the temporal evolution of myocardial infarction, the stage of necrosis and the stage of organization are distinguished. The stage of necrosis is manifested microscopically by cardiomyocyte caryolysis, their fragmentation, leukocyte infiltration, which reaches a maximum 48-72 hours after the onset of infarction, hyperemia of the vessels, hemorrhagic foci. Macroscopically, the area has an irregular shape, white-yellow color in the center and red edema on the periphery - white, ischemic infarction with hemorrhagic edema. Very rarely, in 1-2%, myocardial infarction can be hemorrhagic. The organization of the infarction shows the process of substituting the necrotic focus with granulation tissue. On the 4th day after onset, macrophages begin to appear in the area of necrosis, which performs the resorption of necrotic masses and gradually replaces the necrosis with granulation tissue, which penetrates from adjacent areas of the heart muscle. Subsequently, the granulation tissue matures, collagenizes and transforms into mature, dense scar fibroconjunctival tissue. The healing process of myocardial infarction with the development of post-infarction macrofocal atherosclerosis lasts on average 6-7 weeks, depending on the size of the infarction and the general condition of the body. Complications of acute myocardial infarction: a) cardiogenic shock, b) acute heart failure, c) pulmonary oedema, d) arrhythmias (ventricular fibrillation, asystole and a.), E) rupture of the ventricular wall with pericardial tamponade, f) fibrinous pericarditis, g) intracardiac wall thrombosis and thromboembolism and others.



№ 65. Acute myocardial infarction. (*H-E stain*).



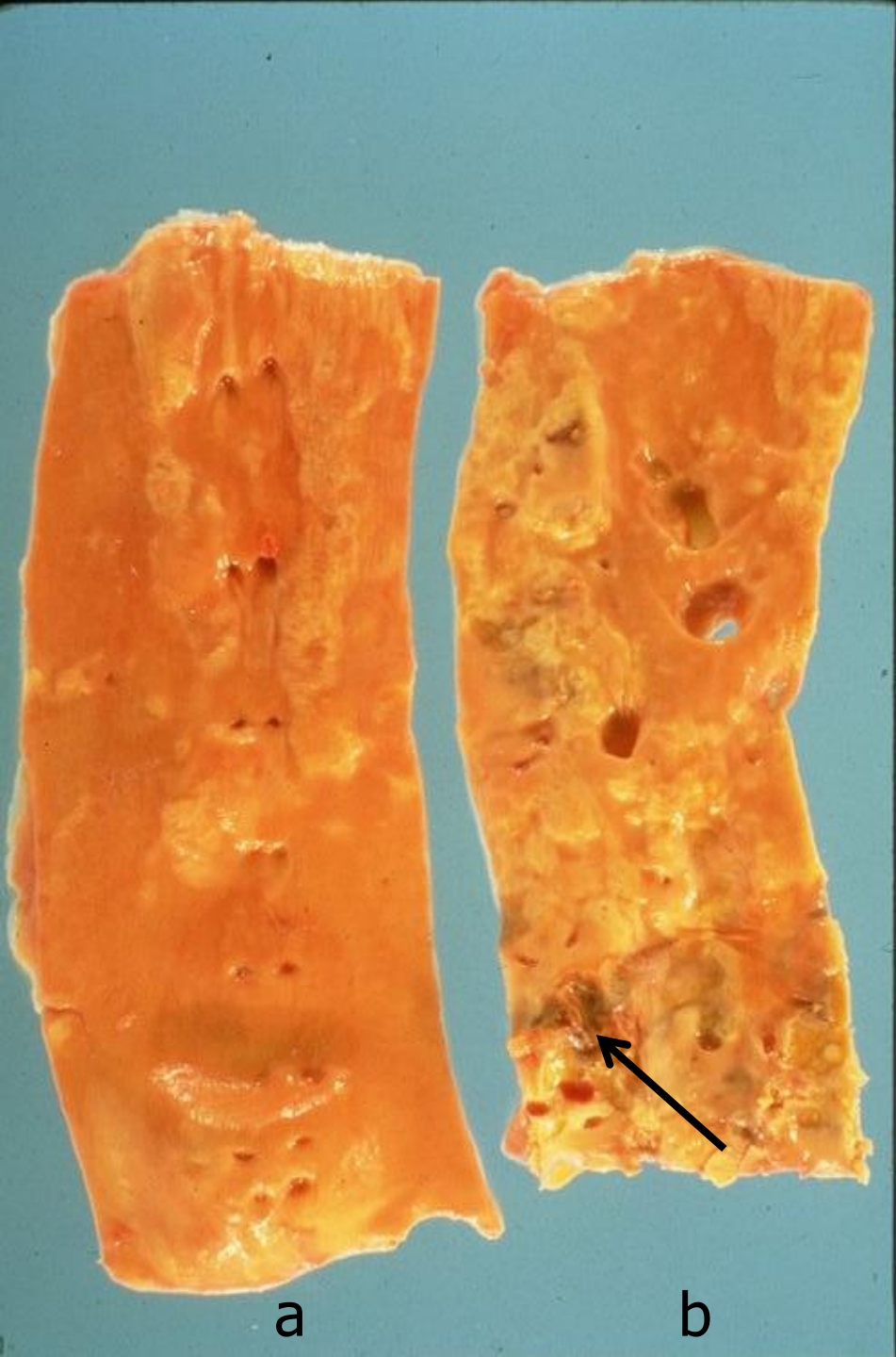№ 65a. Myocardial infarction in stage of organization. (*H-E stain*).

II. Macrospecimens:

№ 3. Atherosclerosis of the aorta (parietal thrombosis).

The intima of the aorta is irregular, with multiple atherosclerotic plaques in the form of focal thickenings, protruding on the surface of the intima, round or oval, diameter from a few mm to 1-1.5 cm, some confluent, yellowish-white color, are exulcerated plaques, covered with yellow granular atheromatous masses, in the thickness of the plates in places there are purplish intramural hemorrhages, there is a parietal thrombus, adherent to the intima, brown, dense consistency, embossed surface.

Atherosclerotic plaque is the main morphological substrate of atherosclerosis. Macroscopically, the process begins with the appearance of yellow spots, which gradually merge, forming elongated yellow lesions - lipid streaks, made up of foam cells, which contain lipids. Lipid streaks progress into fibrous or fibro-lipid atherosclerotic plaques, which have prominent focal thickenings of the intima, of dense consistency, white-yellow color, which appear as a result of proliferation of connective tissue around lipid deposits (liposclerosis), they are covered with a caps dense fibrous. Such plaques are called "stable". They stenose the lumen of the vessel, causing a certain degree of chronic arterial hypoperfusion, atrophic changes of the parenchyma and sclerosis in those areas. Stable plaques can last a long time.



№ 3. Atherosclerosis of the aorta (parietal thrombosis).

№ 121. Hemorrhage into the brain.

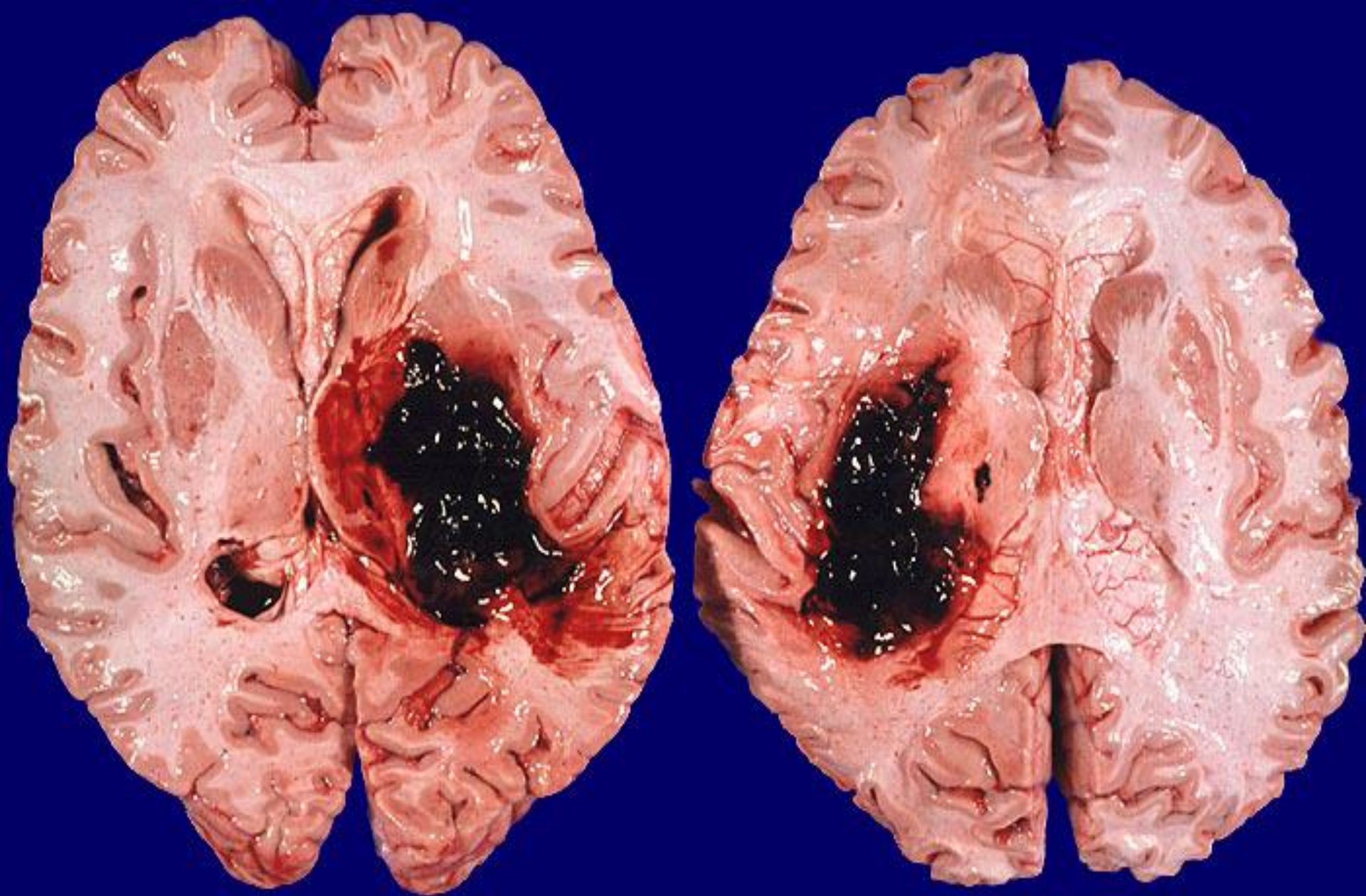
In the brain there is an accumulation of brown coagulated blood (hematoma), the adjacent brain tissue is softened, flaccid consistency.

Intracerebral hemorrhage is one of the manifestations of cerebrovascular disease and is the most common form of hemorrhagic stroke. The main cause is rupture of the arteries by microaneurysms and fibrinoid necrosis of the arterial walls. It is usually found in high blood pressure, which is the cause of death of about 15% of patients with chronic high blood pressure. The most common location is in the basal ganglia and thalamus - 65%, Varoli bridge - 15%, cerebellum - 10%. Hemorrhage causes both direct tissue damage and secondary ischemic damage by compressing adjacent brain tissue. The hematoma consists of blood clots and softened brain tissue. Clinically it is manifested by paralysis, aphasia. Consequences: fibro-glial organization, cystic cavities with rust walls and brown content due to the presence of hemosiderin. The most serious complication is bloodshed in the cerebral ventricles - a fatal complication.

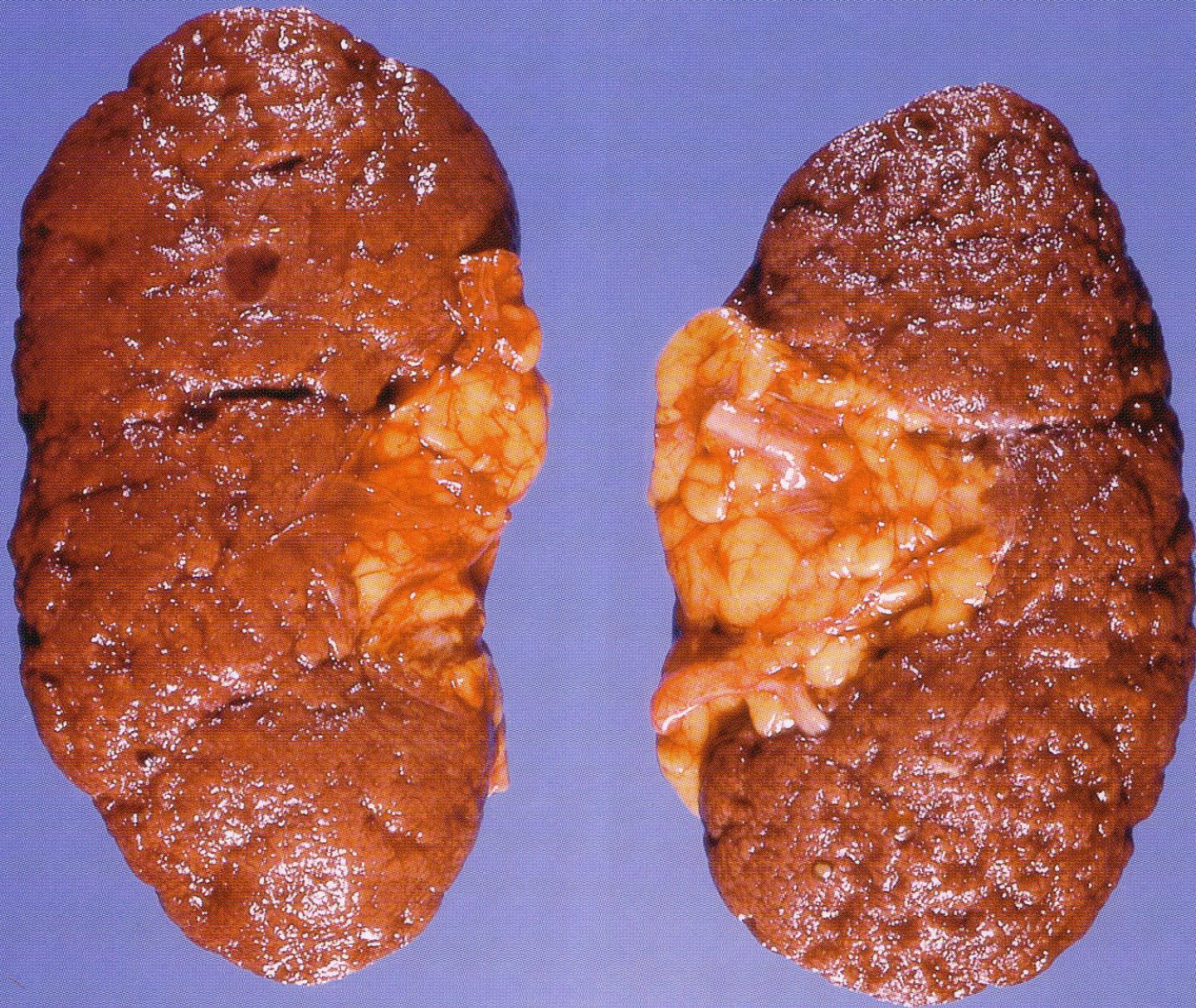№ 83. Rinichi ratatinat.

The kidney is reduced in size, the granular / nodular surface, the dense consistency, on cut-section the boundary between layers is not clear, the gray-whitish color.

Wrinkled kidney - nephrosclerosis - is seen in arterial atherosclerosis and hypertension - the so-called primary nephrosclerosis. In the kidneys there is atrophy of the parenchyma, excessive proliferation of connective tissue and structural remodeling. The external appearance of wrinkled kidneys is different depending on the size of the affected vessels: in hypertension it is granular due to the predominant damage of arterioles (microspecimen № 64), and in atherosclerosis - macronodular due to damage to large and medium arteries. Nephrosclerosis leads to progressive chronic renal failure and azotemic uremia.



№ 121. Hemorrhage into the brain.



№ 83. Wrinkled kidney.

№ 24. Heart rupture (left ventricle) in acute myocardial infarction.

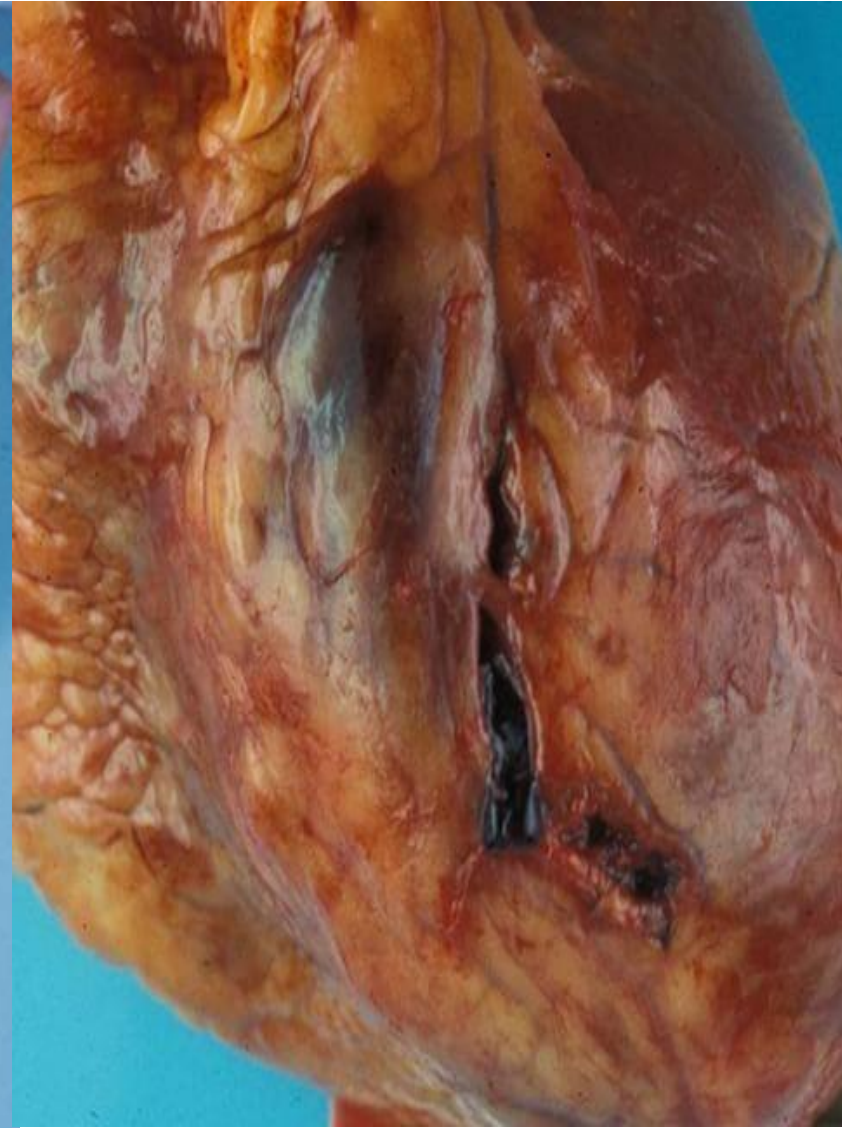
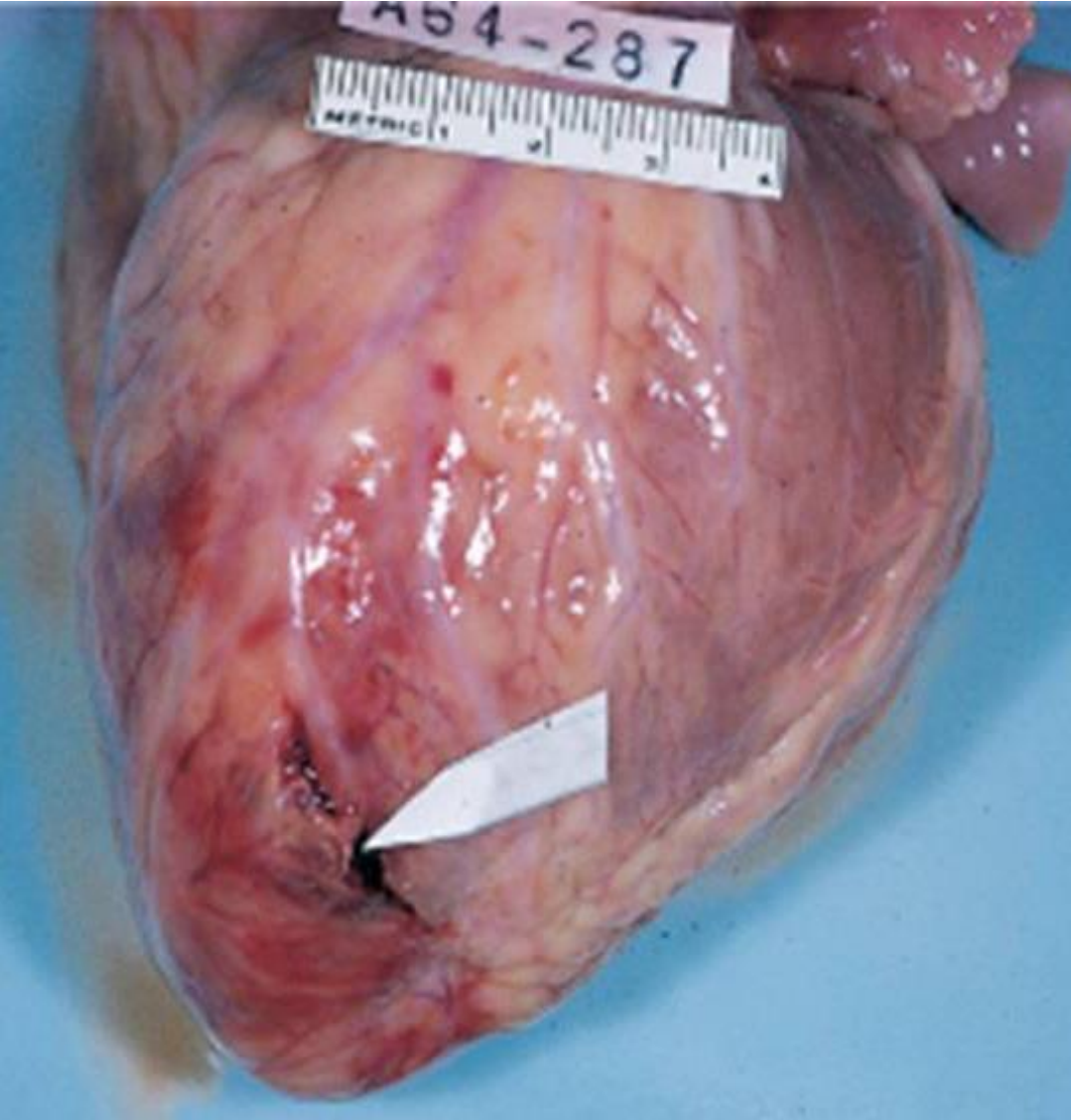
In the lower third of anterior wall of the left ventricle, a fissure with a length of 1.5-2 cm is observed, on the section it is seen that the fissure comprises the entire thickness of the ventricular wall, the edges are infiltrated with blood.

Rupture of the heart is the cause of death in 10% of the total number of patients who die from myocardial infarction. There is external and internal rupture. The rupture occurs in cases of macrofocal, transmural infarction, affecting at least 20% of the heart muscle, usually in the first days after the onset of the infarction (days 1-4), when the process of myomalacia develops - autolysis of the necrosis area under the influence of proteolytic enzymes of neutrophil leukocytes. The rupture occurs more frequently at the border between the area of necrosis and the persistent myocardium. The rupture in the center of the infarct area is observed more frequently in the second week, during the organization of the infarction. Most external ruptures of the heart occur in the left ventricle, anterior and lateral walls. Develops, hemopericardium and cardiac tamponade, which is fatal. Internal rupture refers to the interventricular septum and papillary muscles, leading to severe congestive heart failure. Heart rupture is more common in patients with primary myocardial infarction.

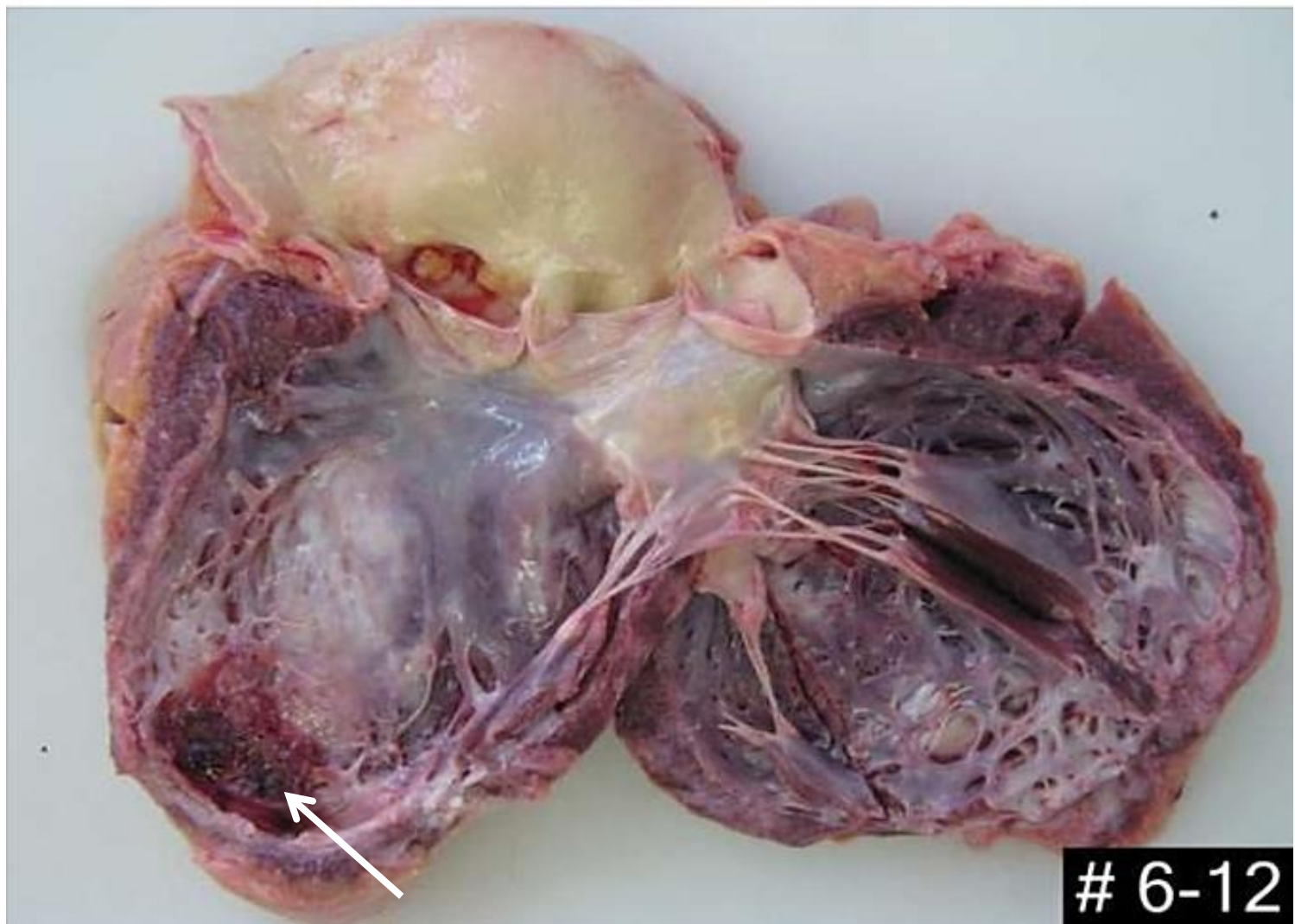№ 10. Chronic cardiac aneurysm with mural thrombosis.

In the antero-lateral wall of the left ventricle there is an aneurysmal dilation in form of a round sac, filled with thrombotic masses, the adjacent ventricular wall is thin, gray-whitish, with the appearance of scar tissue, the left ventricular wall in the basal region is hypertrophied.

Chronic cardiac aneurysm is a consequence of macrofocal, transmural myocardial infarction. It appears on the place of the massive post-infarct scar, several weeks or months after the healing of the acute infarction. The heart muscle in the infarct region is replaced with fibroconnective tissue. The post-infarct scar does not contract and under the action of intraventricular systolic pressure gradually thins and extends till the formation of aneurysm. In chronic cardiac aneurysm there is progressive congestive heart failure, rhythm and conductivity disorders, intracardiac thrombosis, thromboembolism, it is possible rupture of the wall with pericardial tamponade.



№ 24. Heart rupture (left ventricle) in acute myocardial infarction.



№ 10. Chronic cardiac aneurysm with thrombosis.

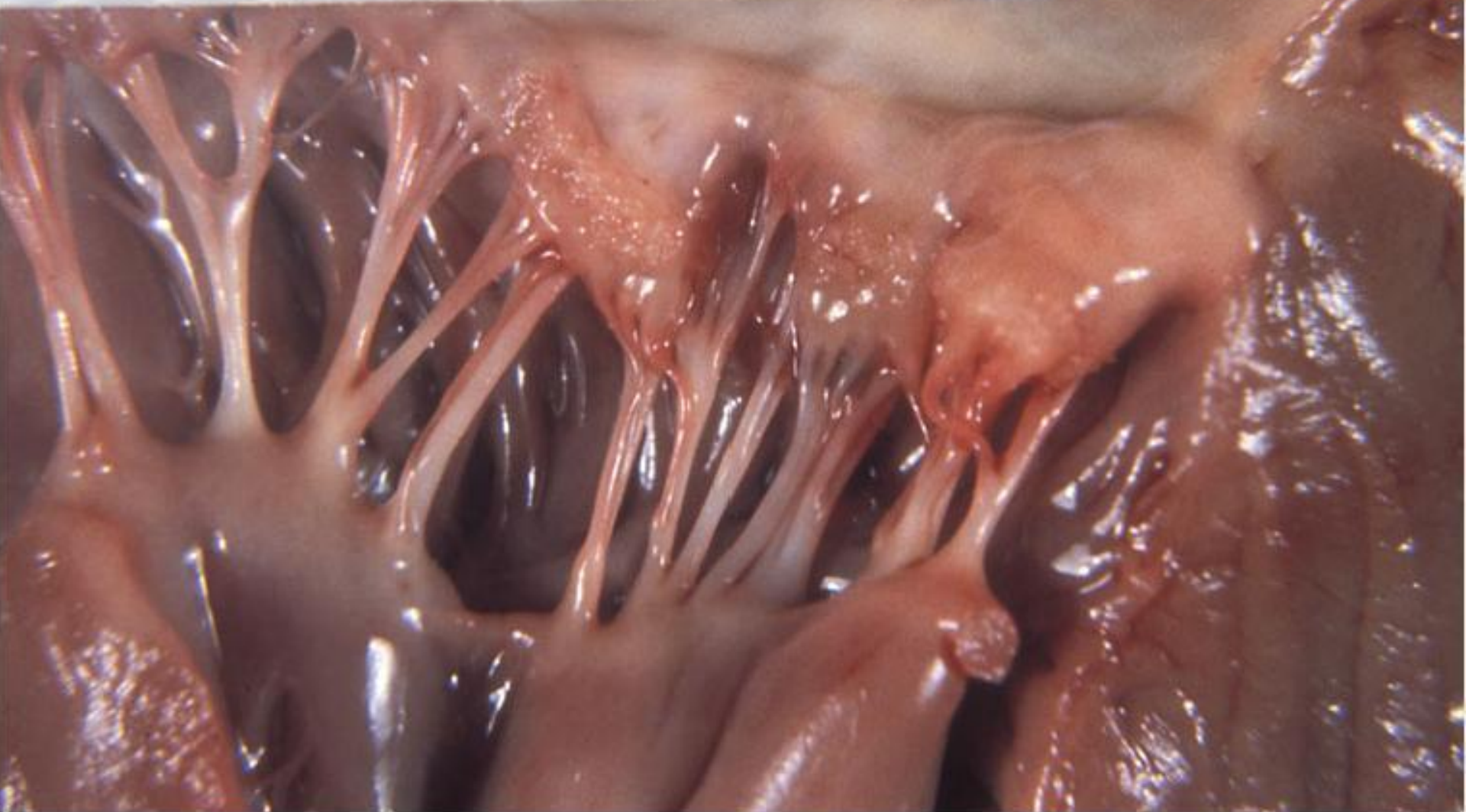№ 16. Verrucous acute endocarditis.

On the atrial surface of the mitral valve cusps there are fine thrombotic deposits (warts), brown in color, dense in consistency, which adhere closely to the valvular endocardium, located mainly on the free edge, closing the cusps; the cusps are thickened, deformed, the tendon cords also are thickened and fused.

Valvular endocarditis is a manifestation of rheumatic carditis. More frequently is affected mitral valve (~ 70%): concomitant mitral and aortic valve involvement occurs in (~ 25%), the tricuspid valve is less commonly involved, and the aortic valve is about (2%), and the pulmonary valve is practically not affected.

Acute valvulitis develops on free valves, is manifested by fibrinoid necrosis, inflammatory cellular infiltration, Aschoff granulomas, fibrin deposits in the form of warts with a diameter of 1-2 mm, arranged in a string along the closing edges of the valves, usually on the atrial surface of the atrioventricular valves and on the ventricular surfaces of the crescent valves, in the occurrence of these lesions reflects the role of the mechanical and hemodynamic factor. Chronic valvulitis is manifested by the organization of acute inflammation and fibrinous warts, the appearance of new, larger warts on the already deformed, thickened valves, sclerosis and retraction, shortening of the cusps and crescent leaves, their concretion, calcinosis. At the same time, the mitral valve become more thick, shorten and fuse the tendon cords, which together with the concretion of the cusps leads to the installation of a mitral stenosis with the appearance of a "fish mouth" or "buttonhole". The functional consequences consist of valvular insufficiency or stenosis and the gradual development of congestive heart failure.

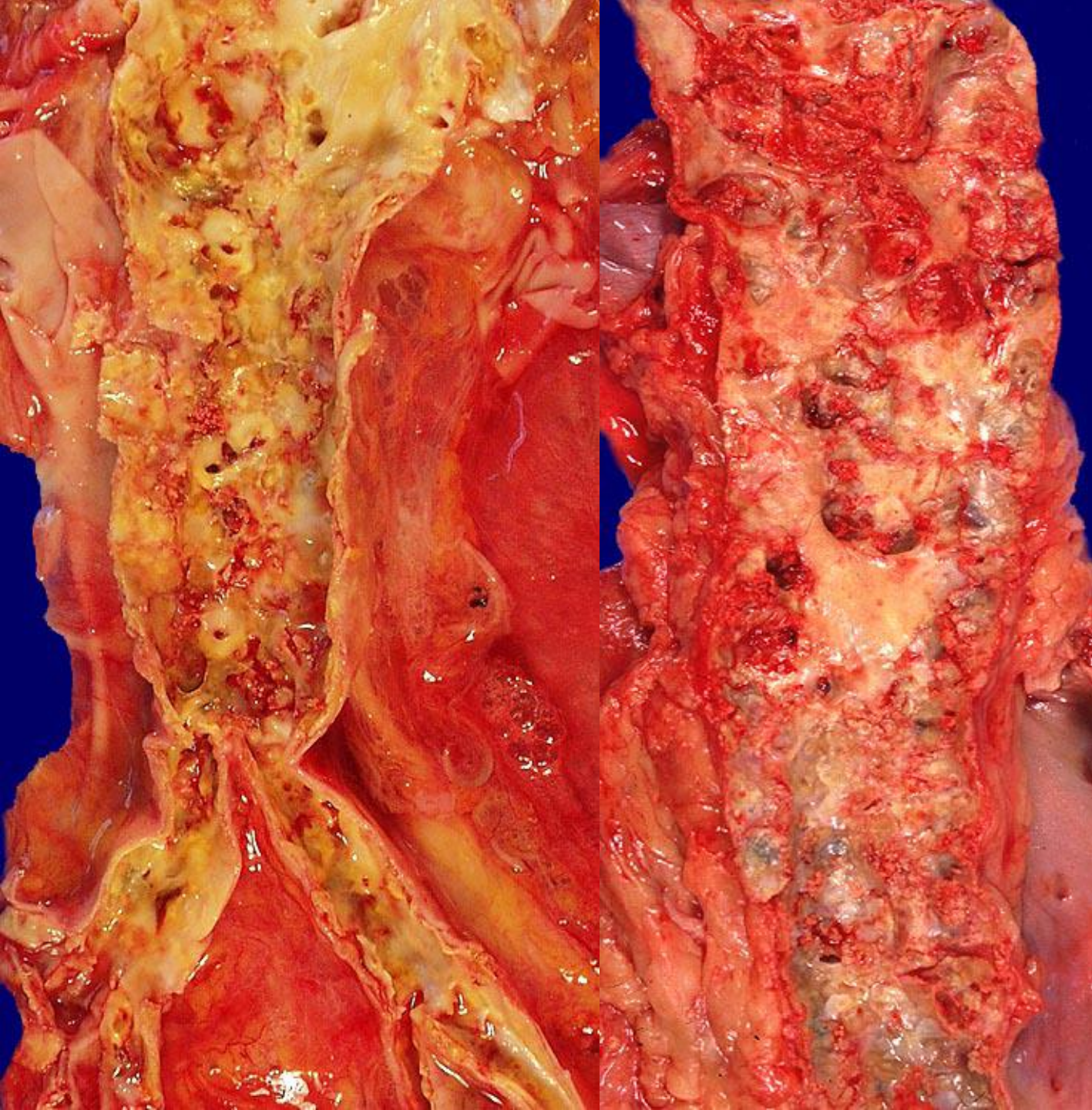TRIC 1 SYSTEM 2 3



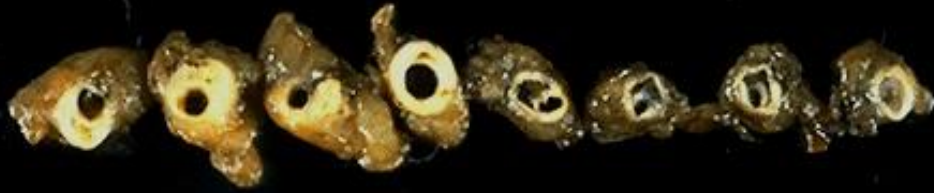№ 16. Verrucous acute endocarditis.



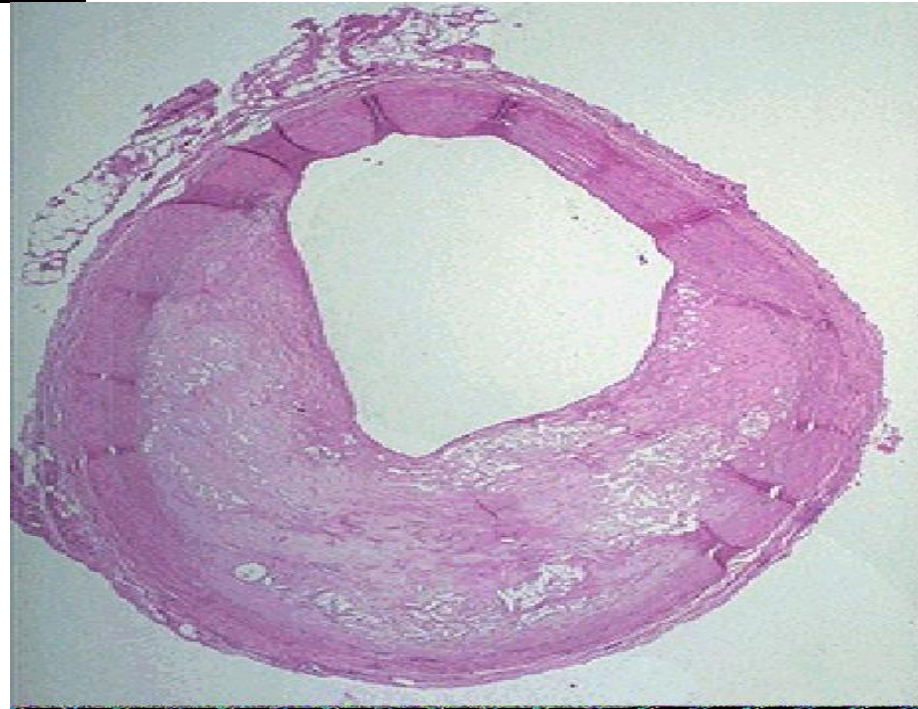Lipid spots

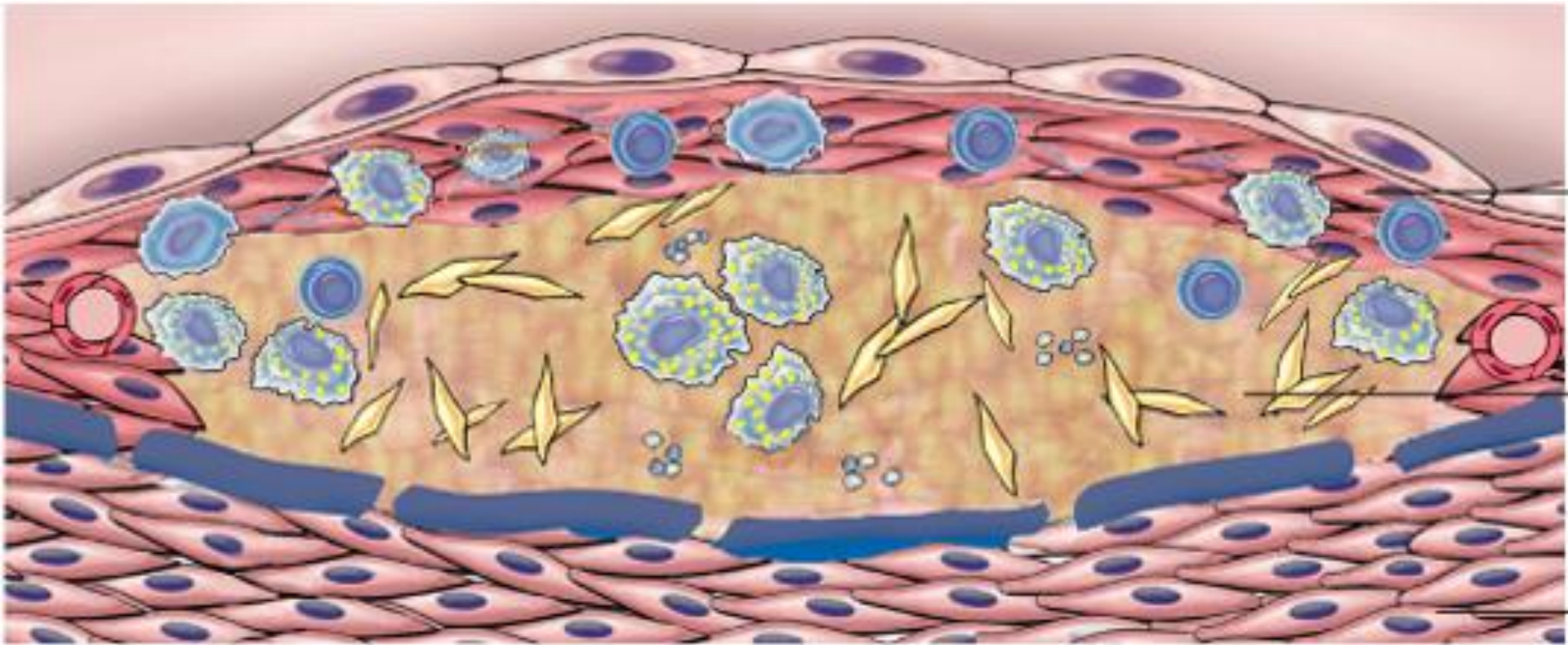


**Atheromatous
ulcerations in the
aorta.**

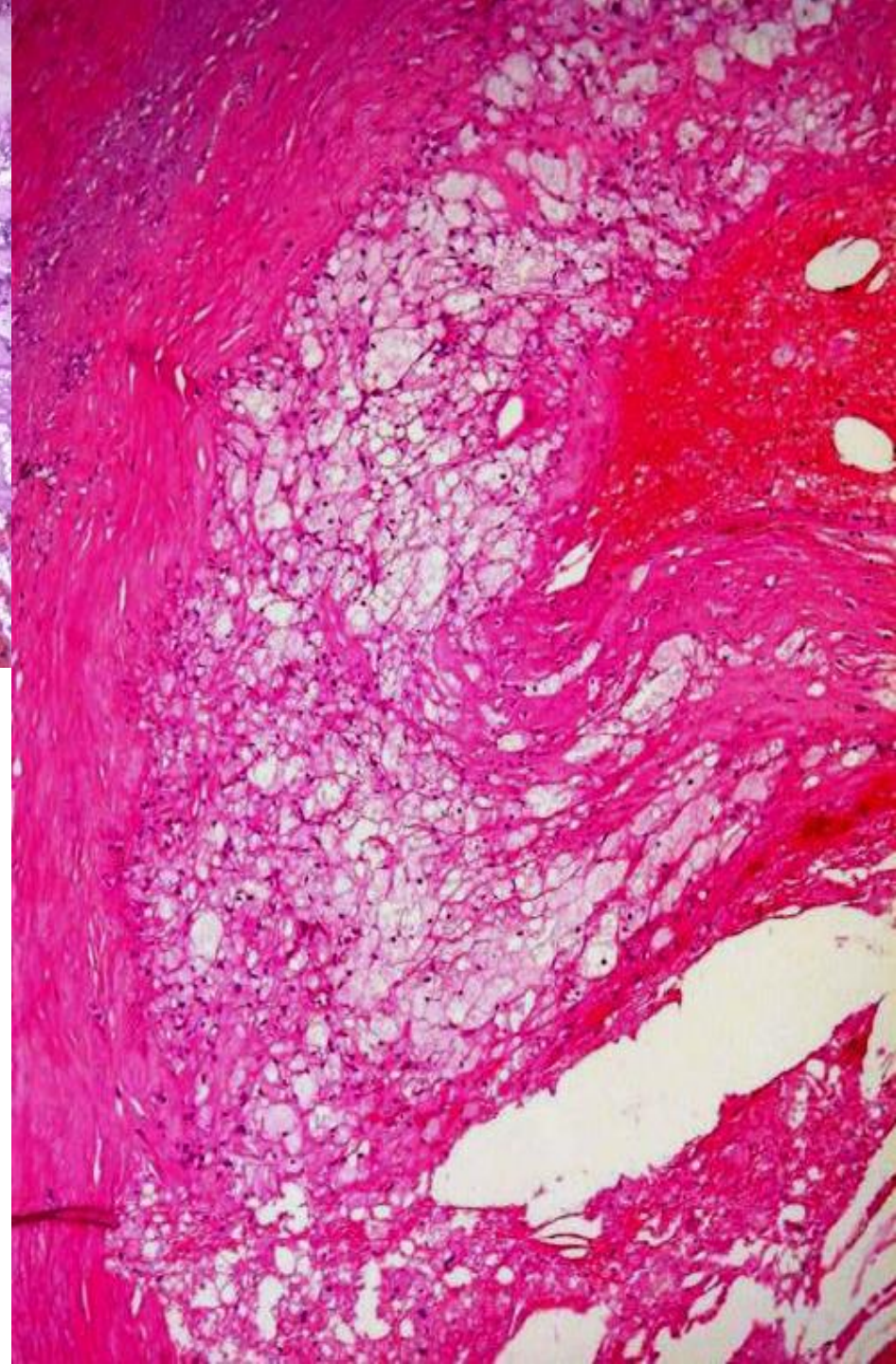
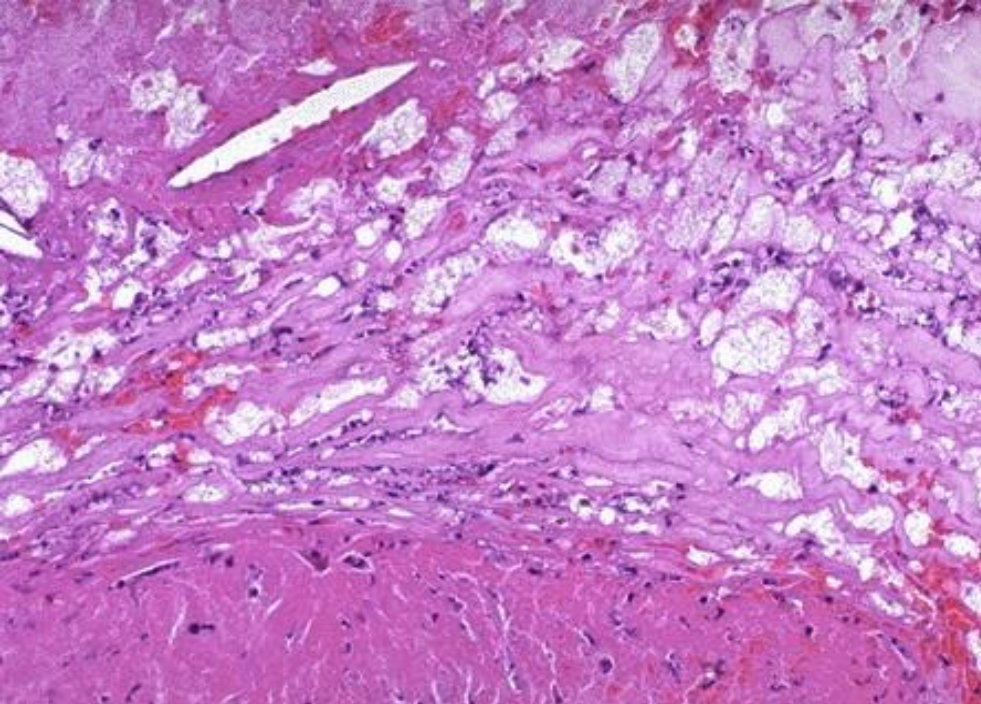


Stenosing atherosclerotic plaques.



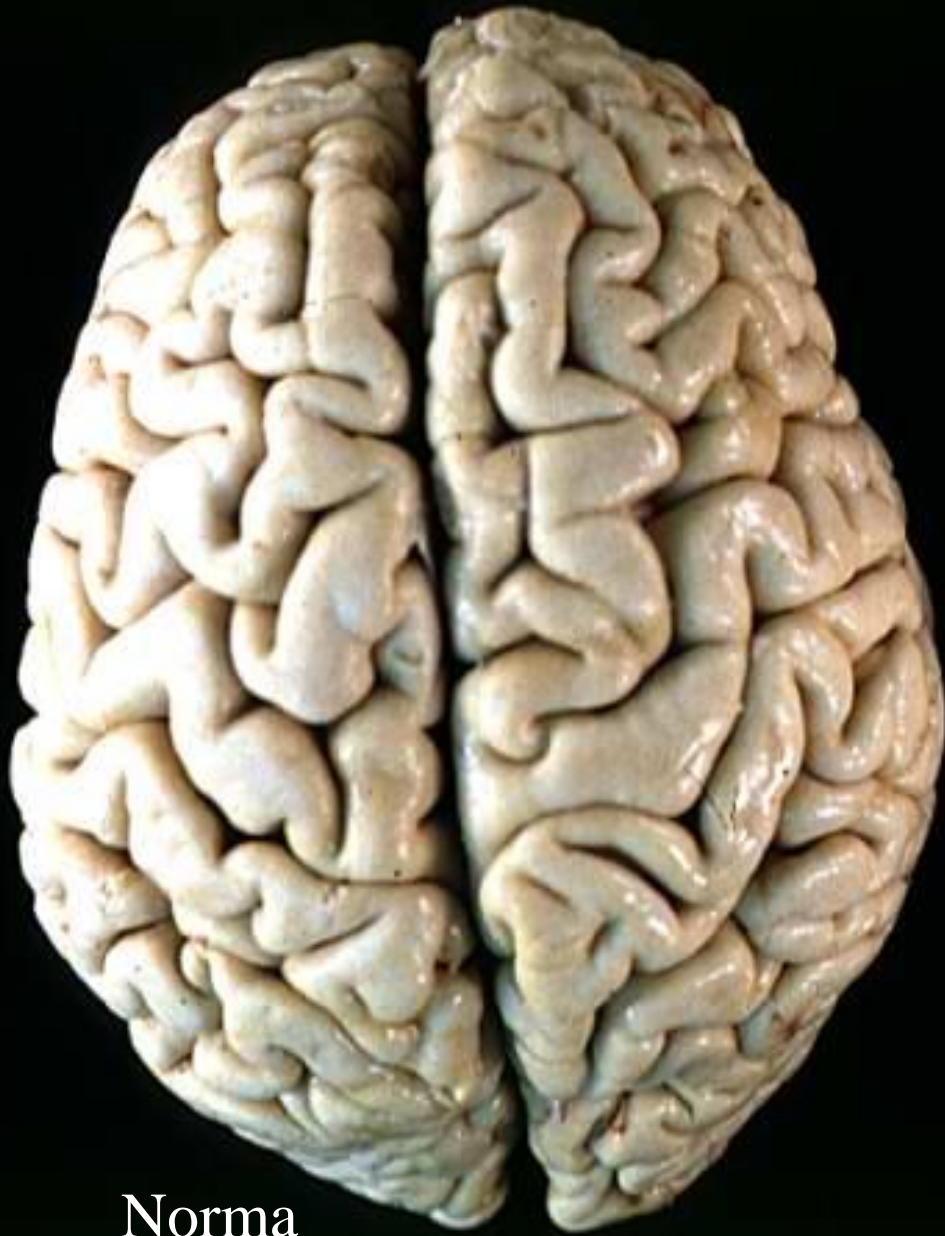

Structure of atherosclerotic plaque.

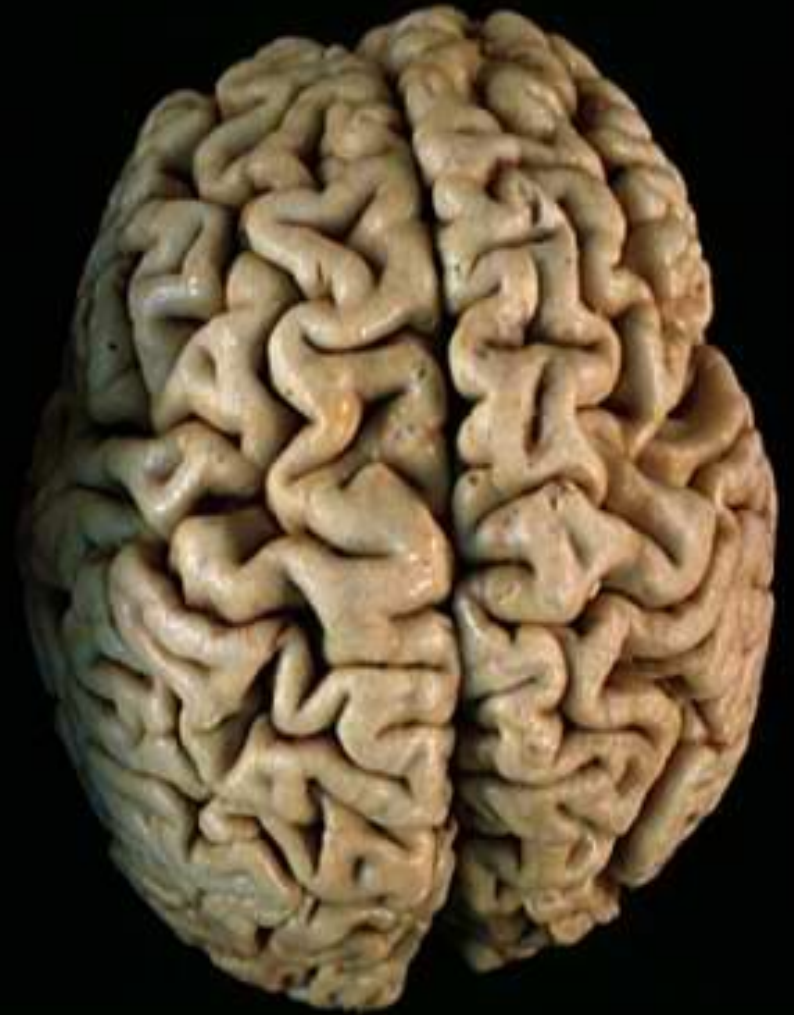

Atherosclerotic plaque:

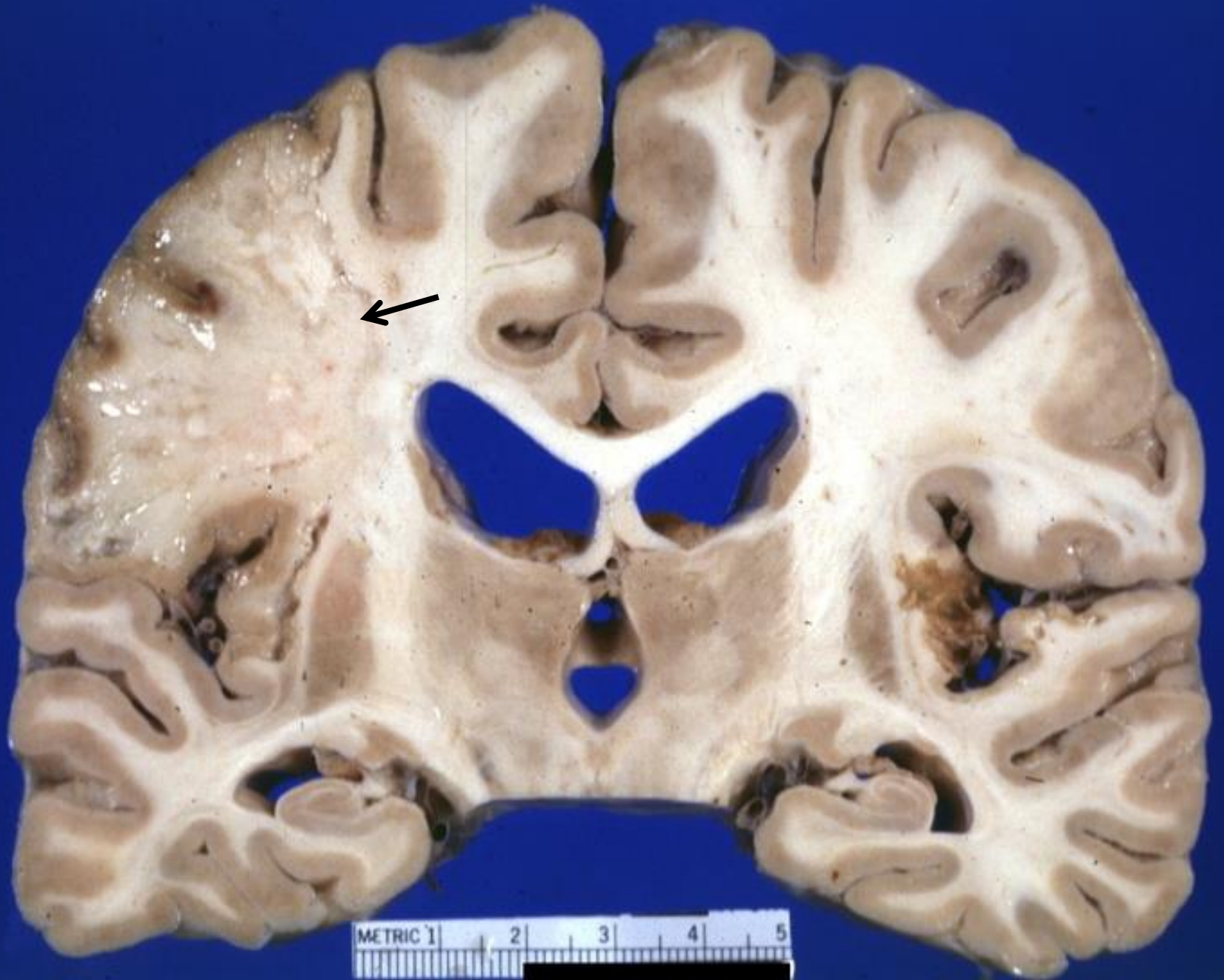(atheromatous detritus, cholesterol crystals, foam cells).



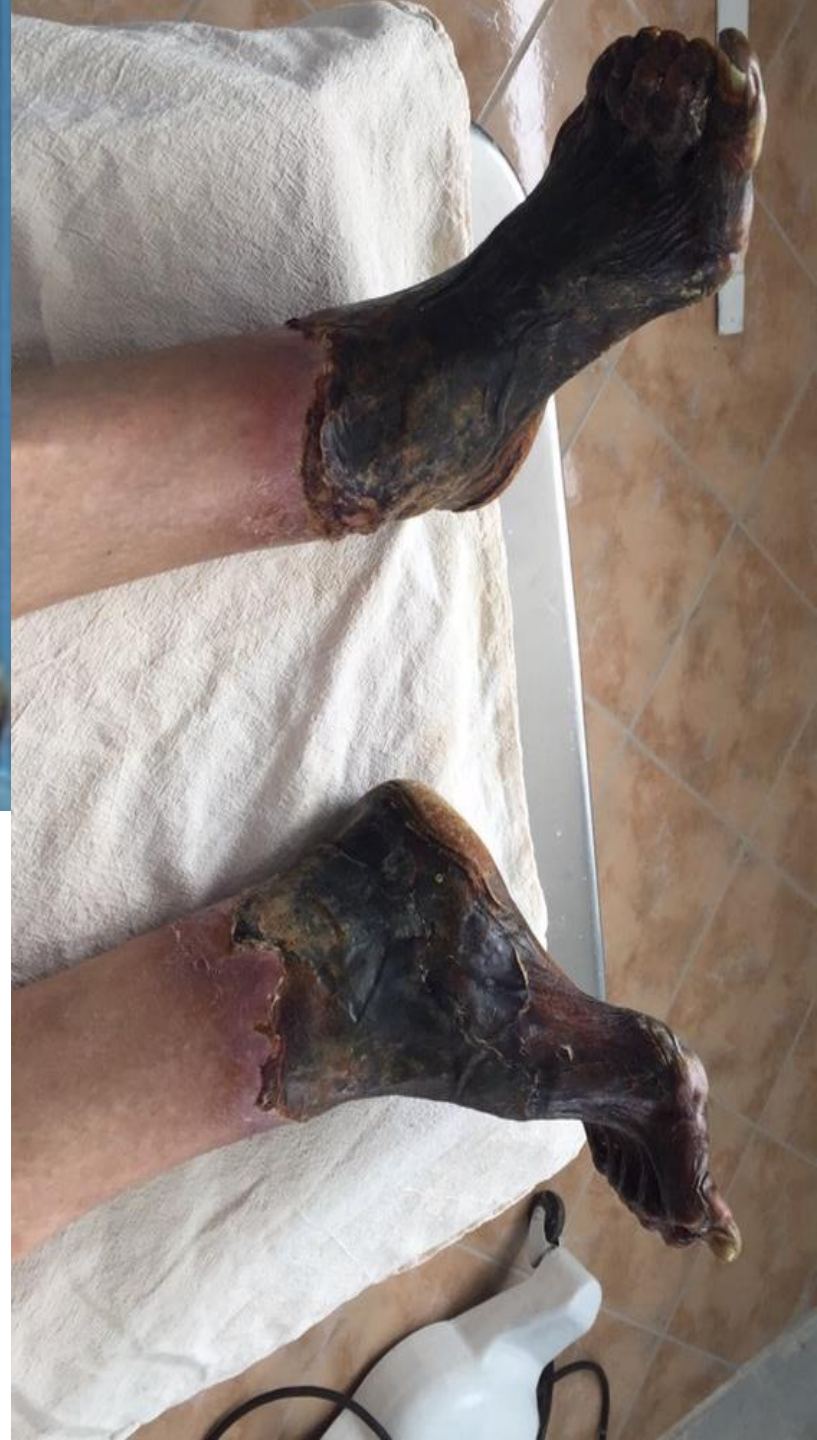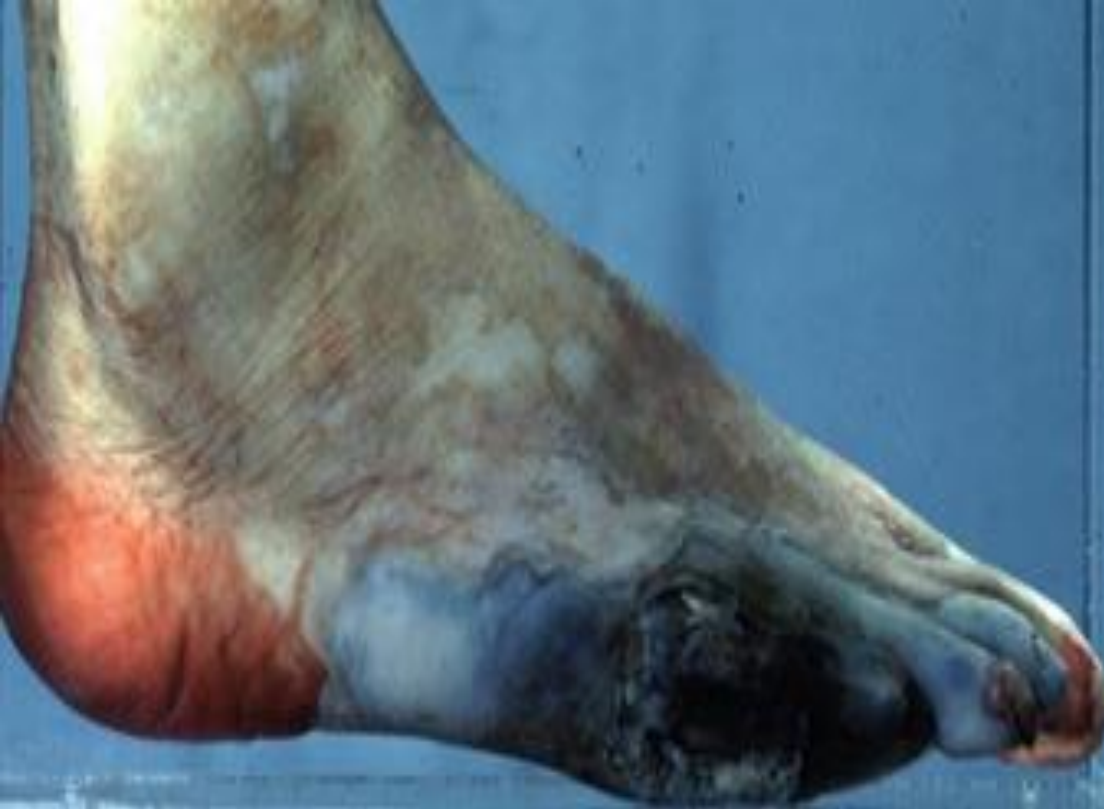Norma



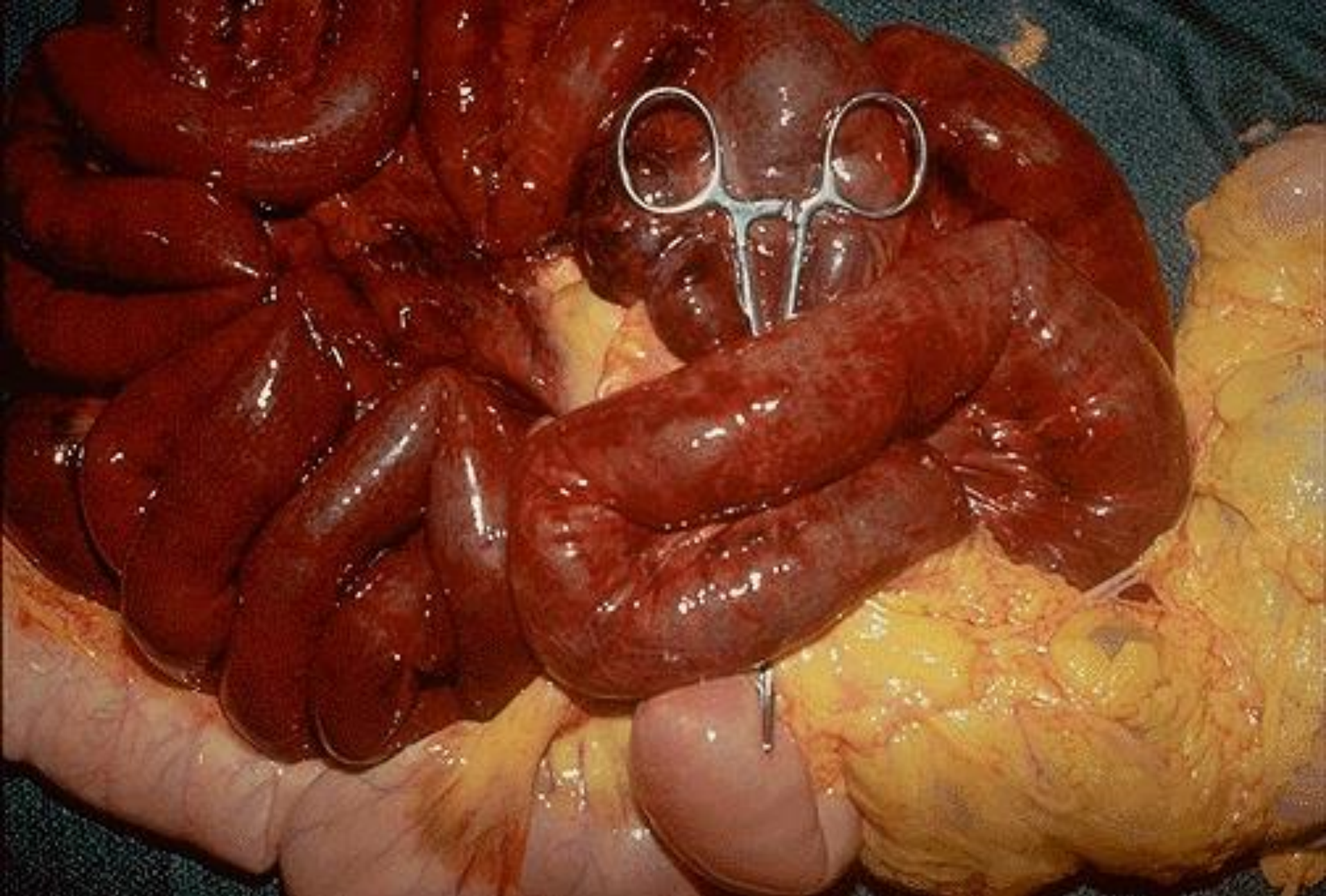
Brain atrophy.



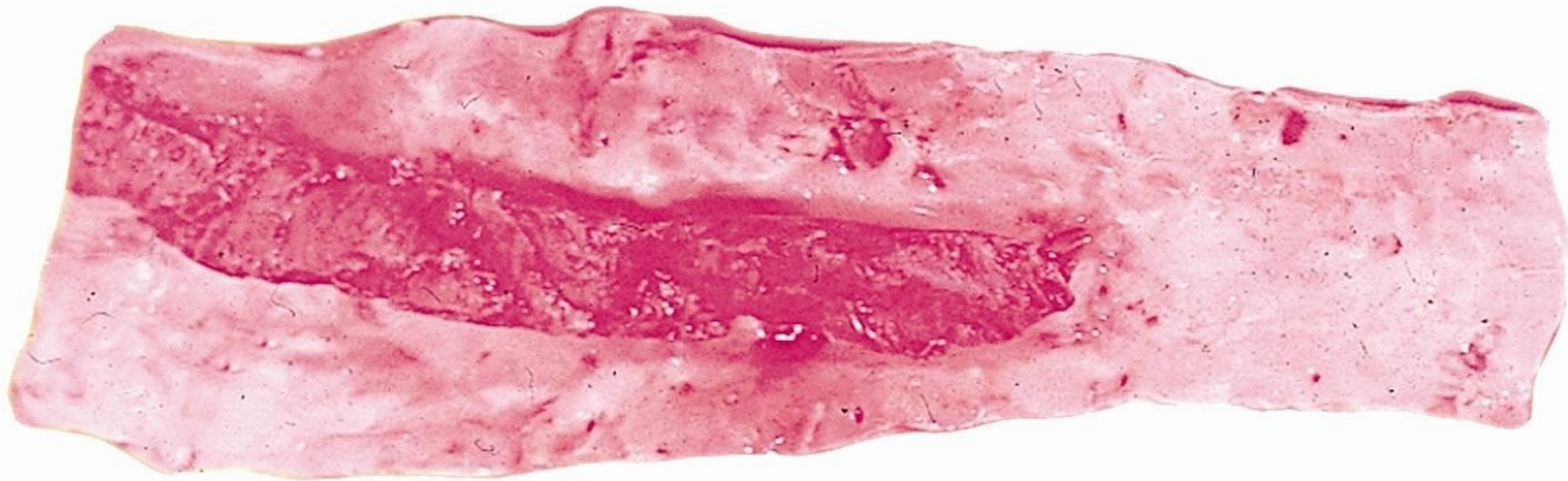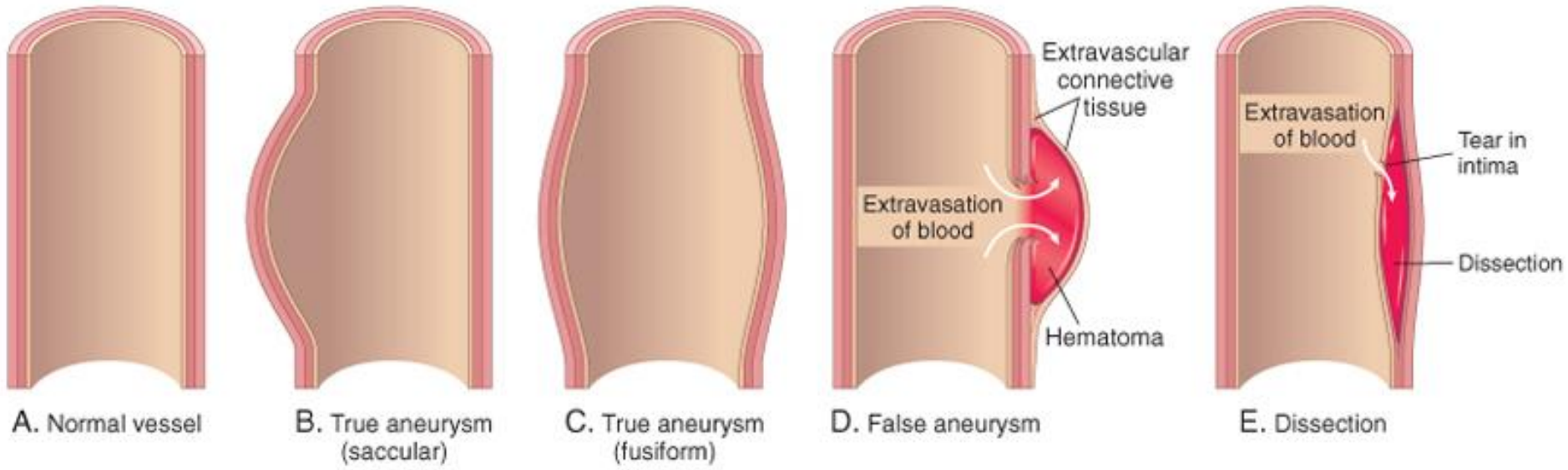
Cerebral ischemic infarction.



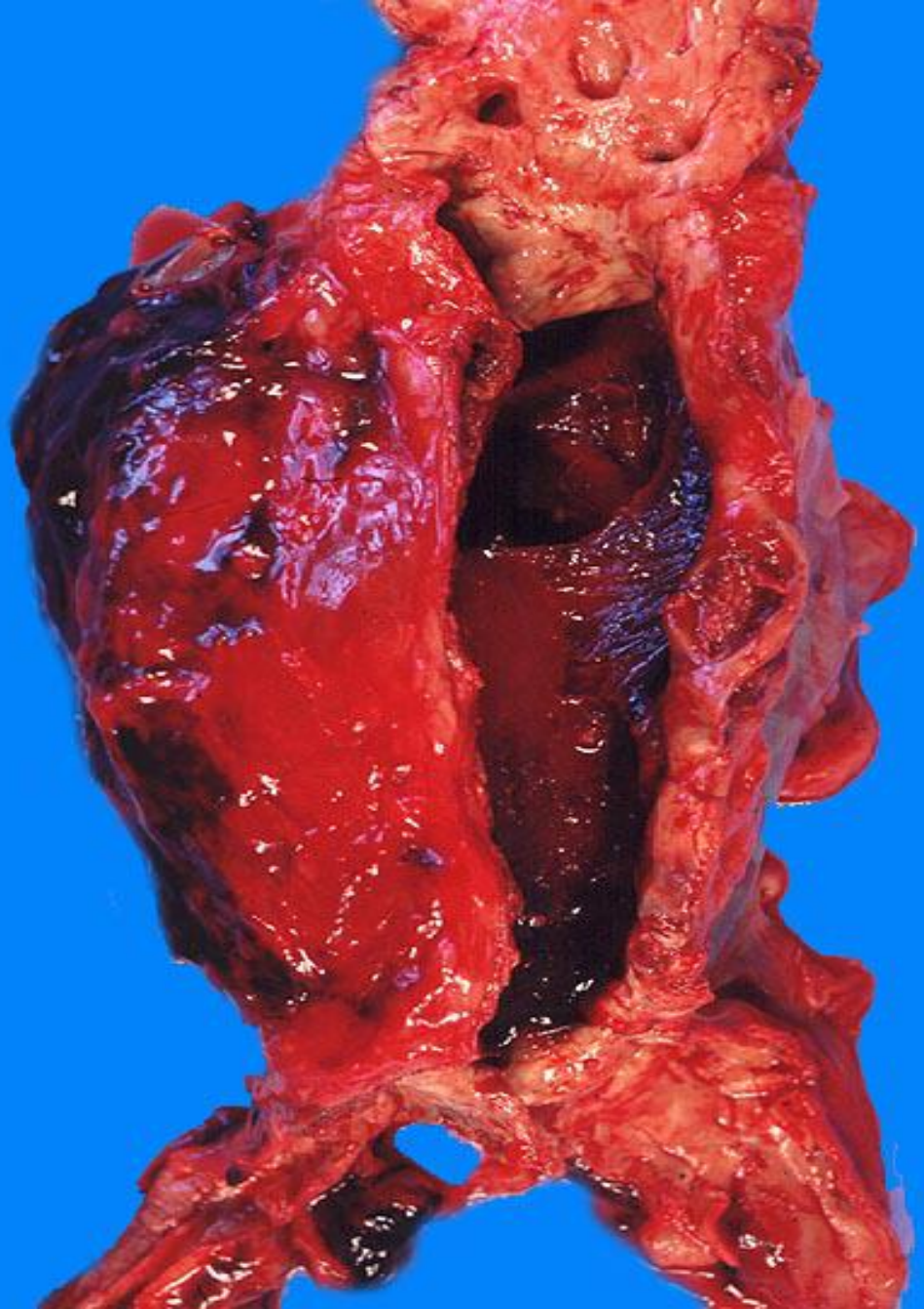
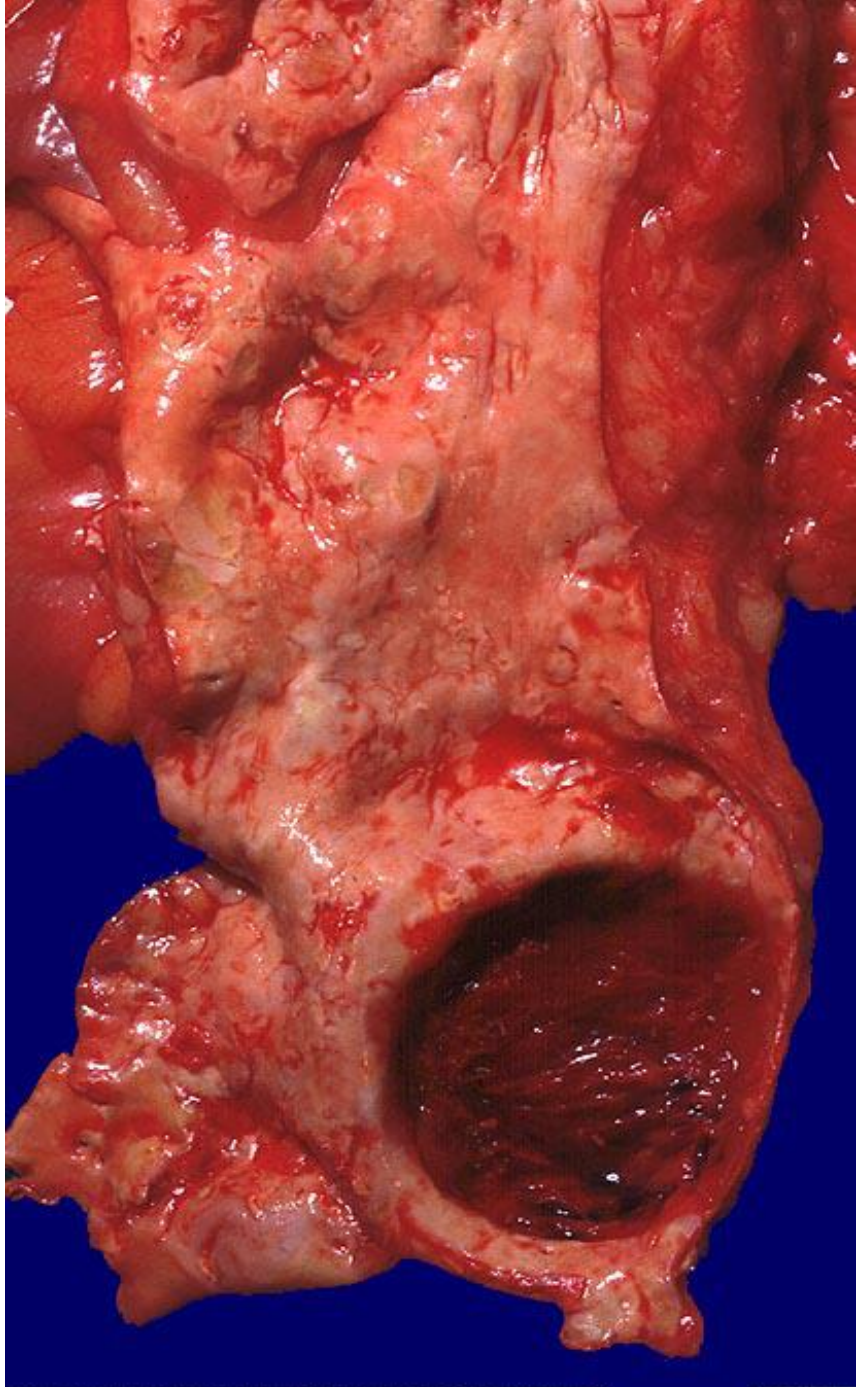
Atherosclerotic gangrene.



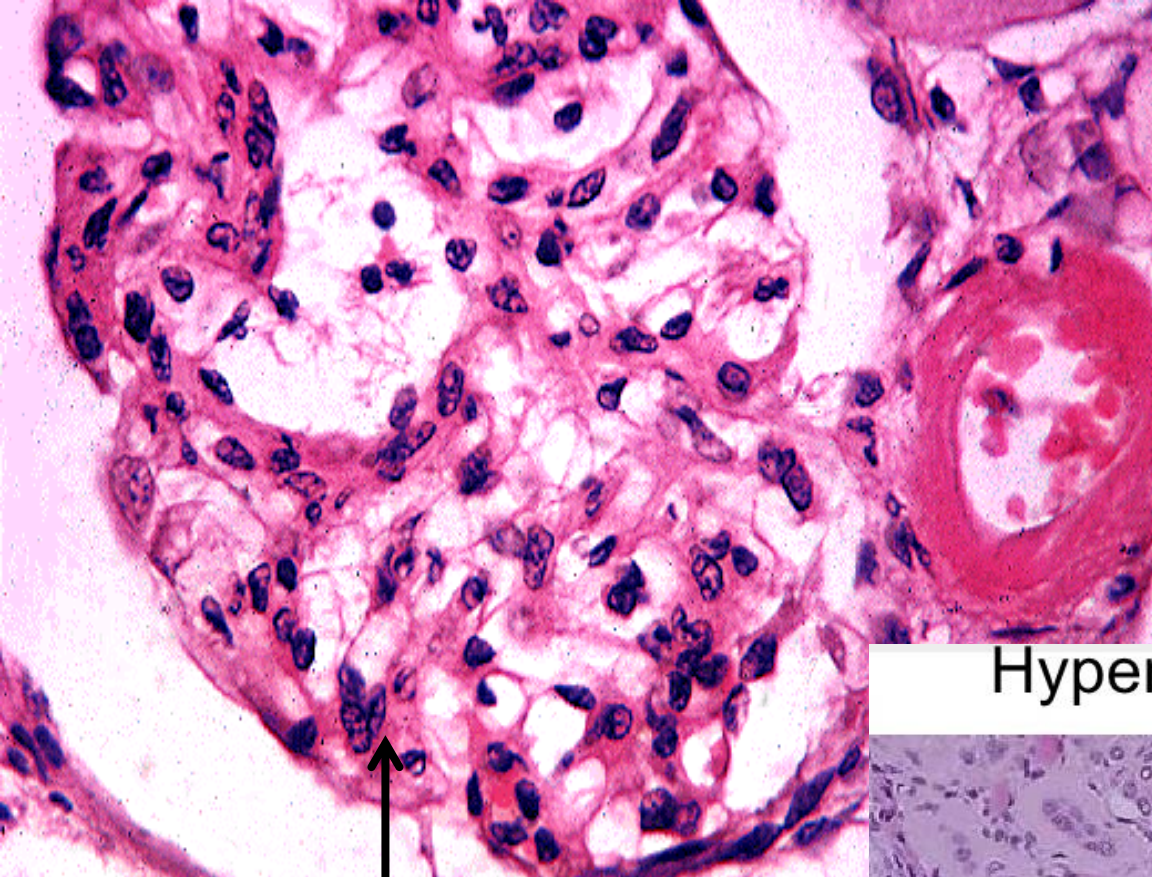
Intestinal gangrene.



Parietal thrombus in the abdominal aorta.



Aortic aneurysm with thrombosis.

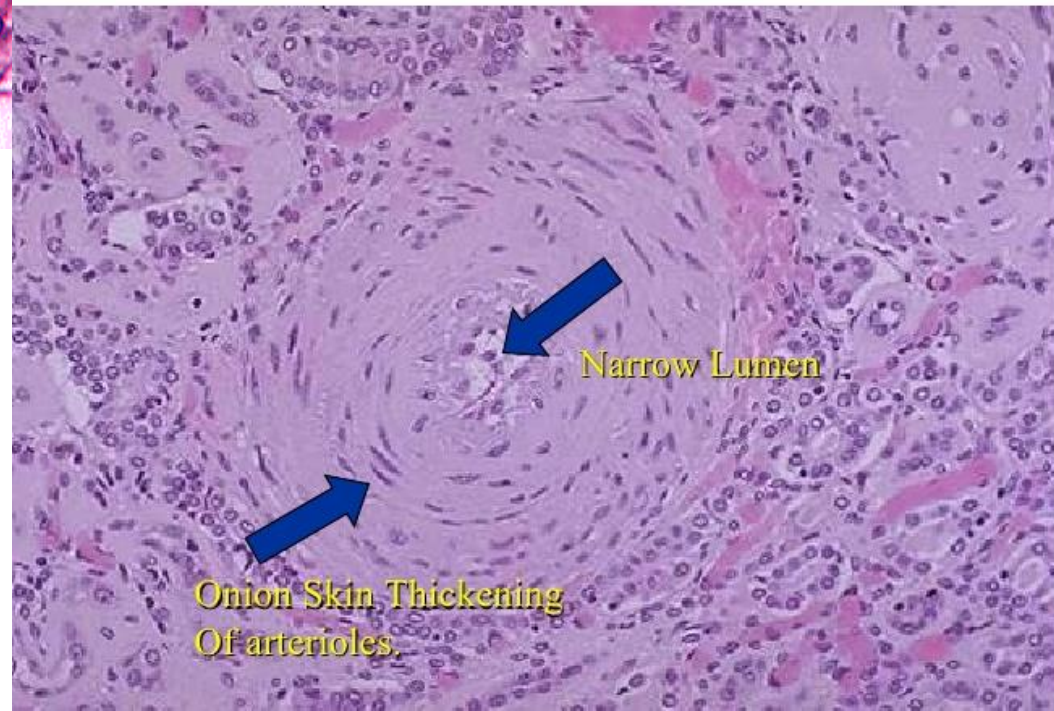


**Arteriolo-
hyalinosis
in hypertension**

**Hyperplasia of the elastic
membrane in hypertension**

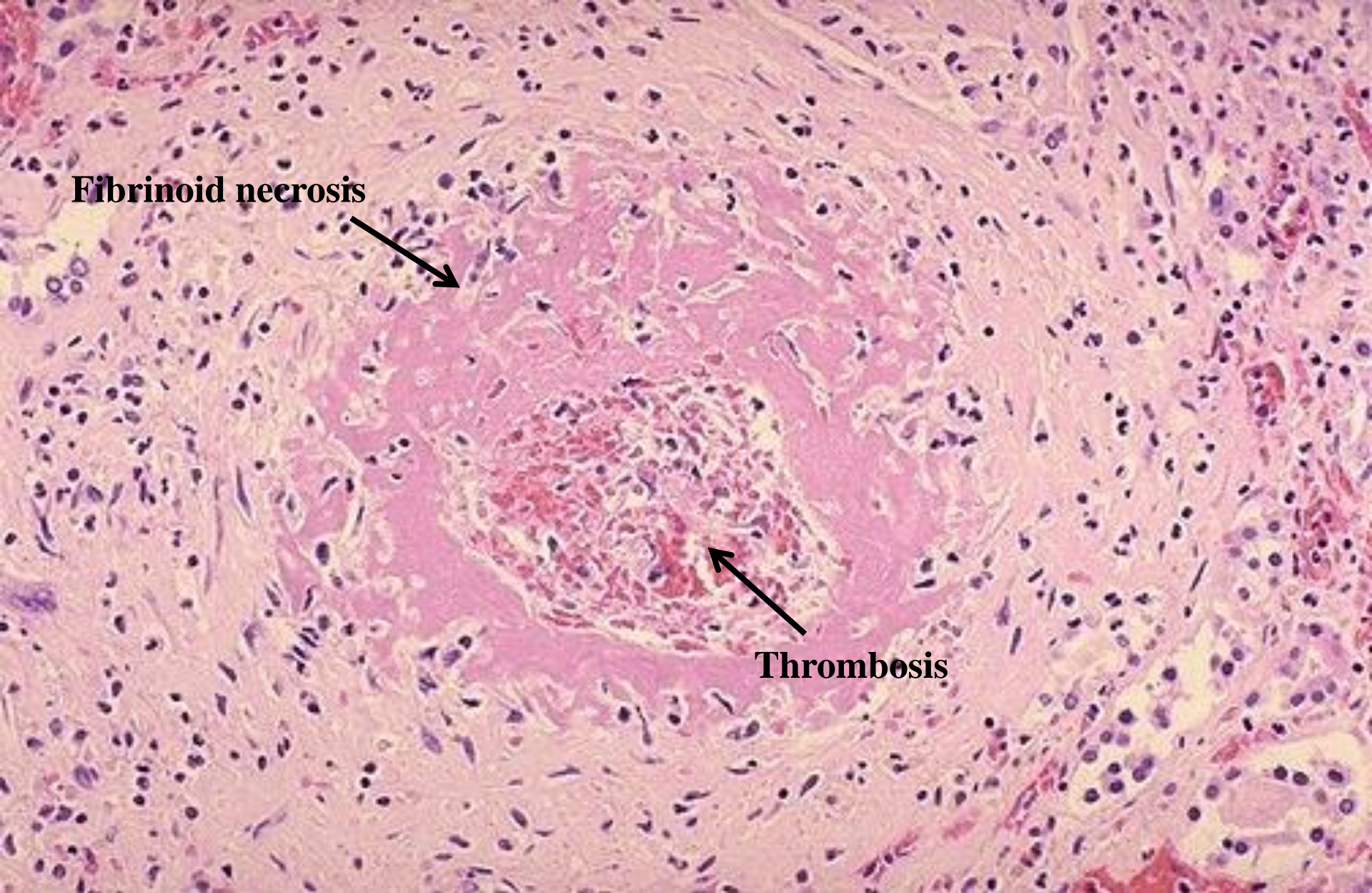

Hyperplastic Arteriolosclerosis:

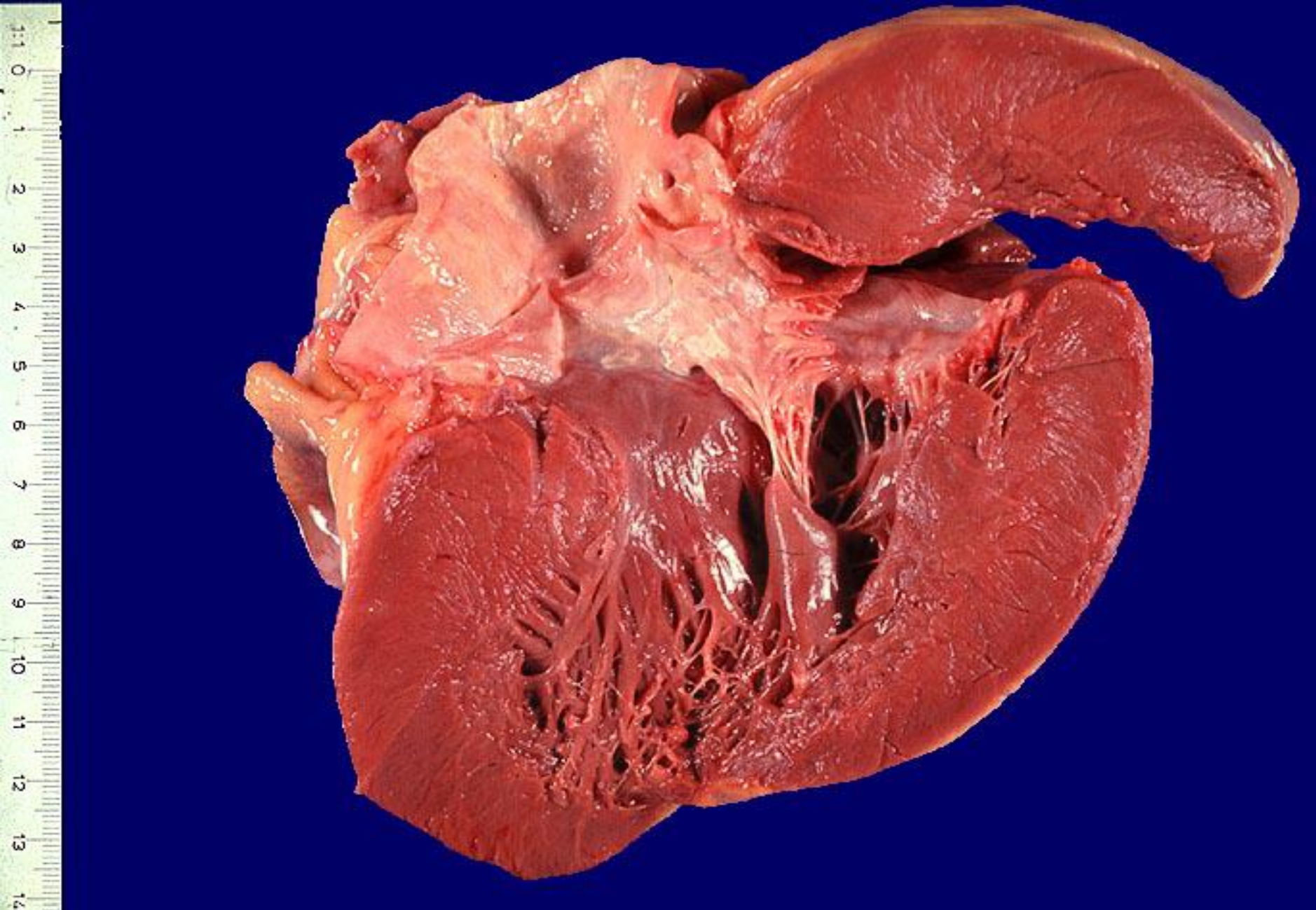


Narrow Lumen

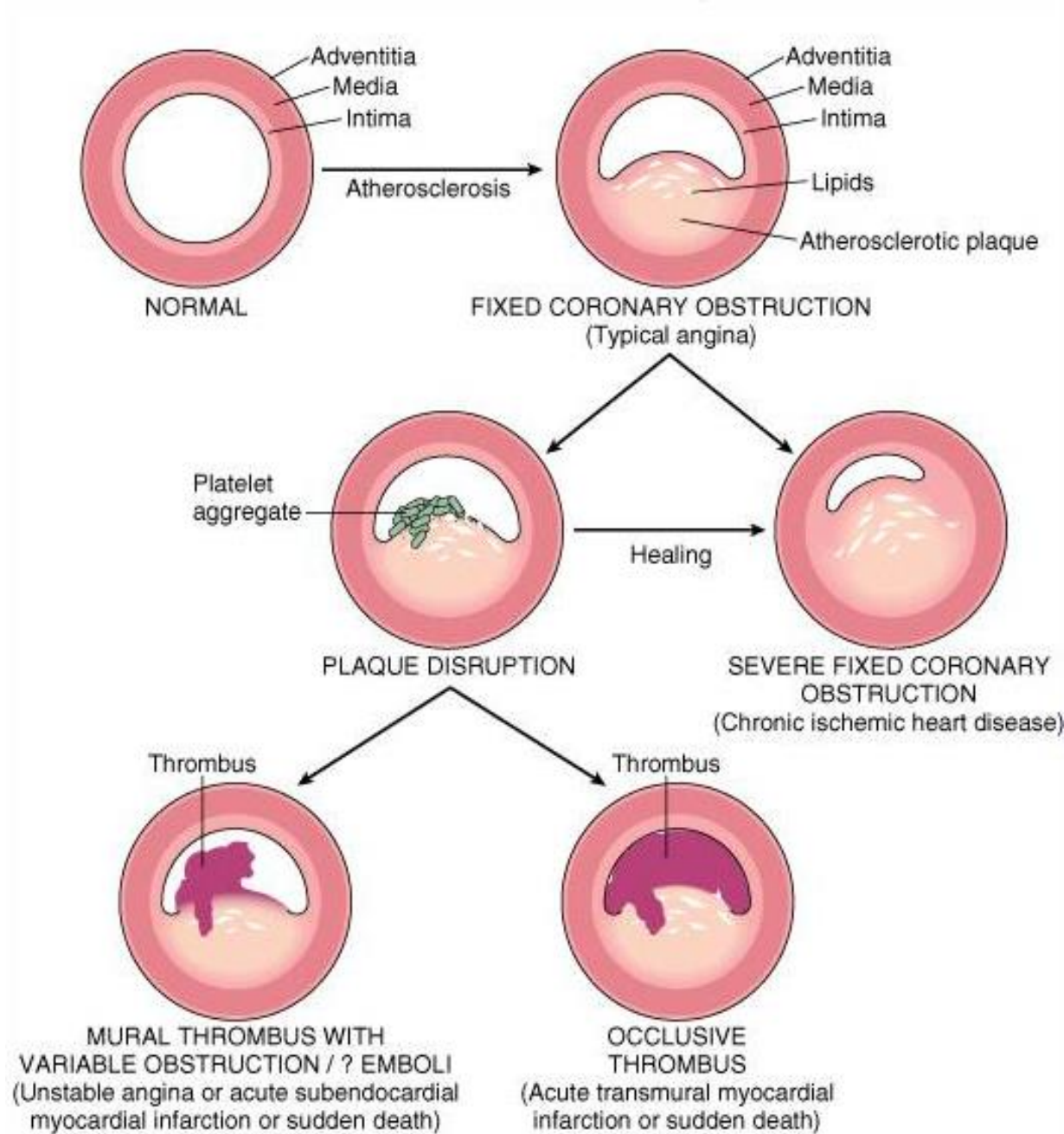
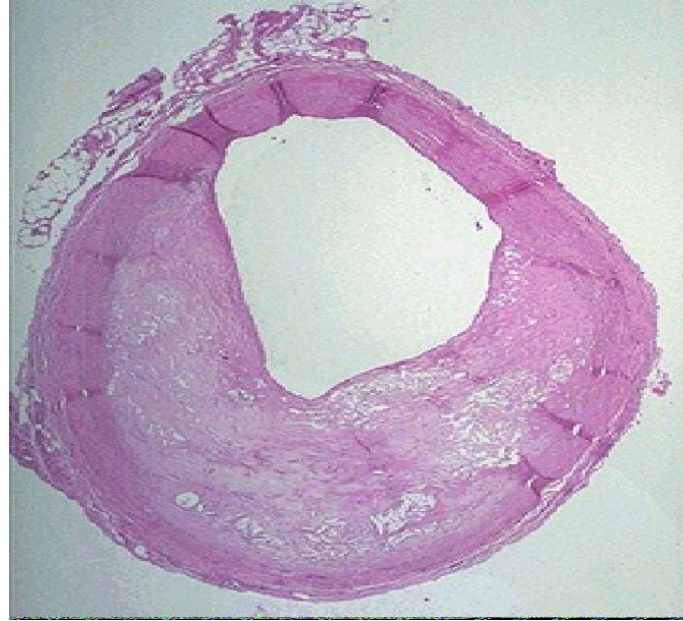**Onion Skin Thickening
Of arterioles.**



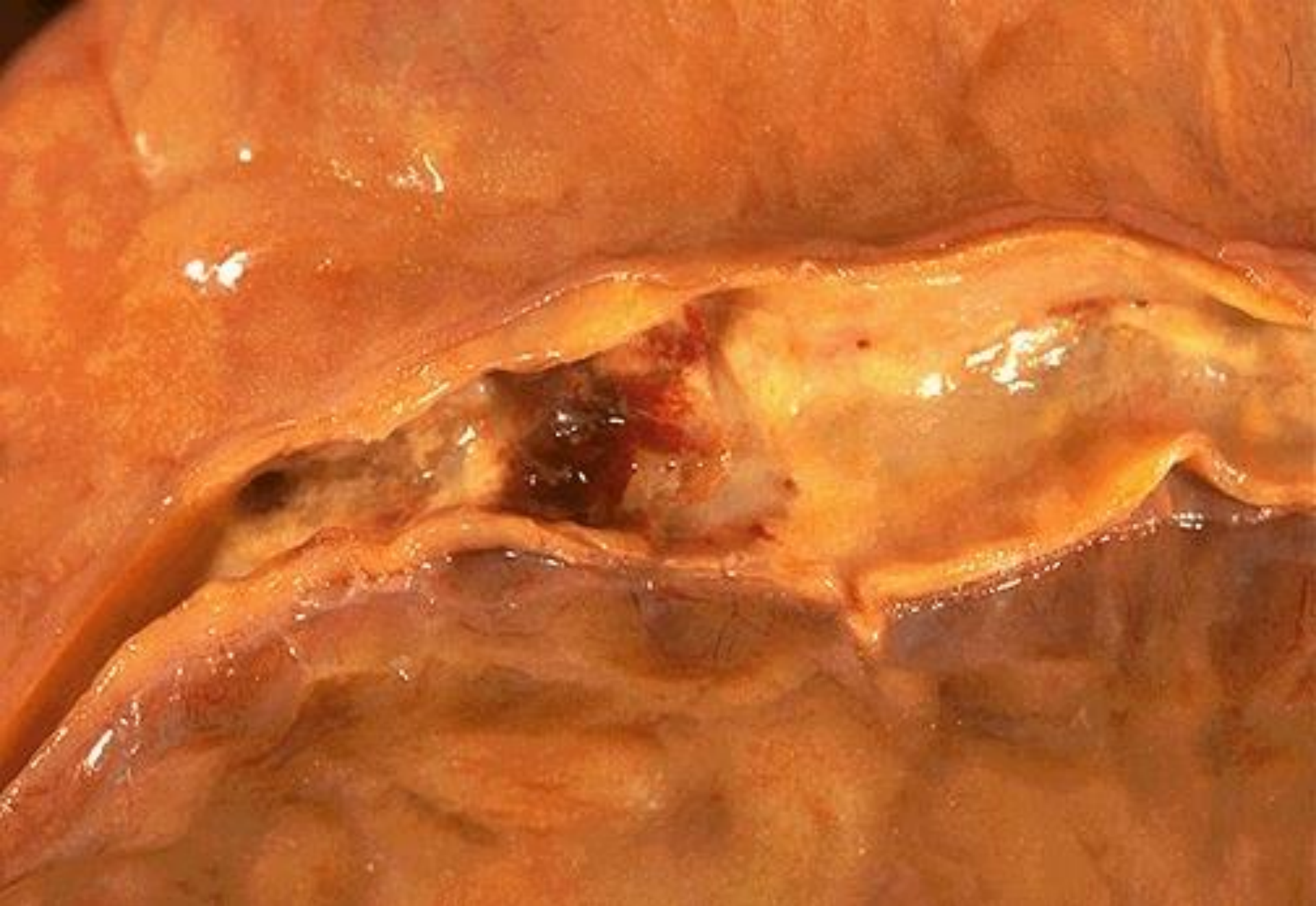
**Fibrinoid necrosis of the arterial wall in malignant hypertension
(*hypertensive crisis*).**



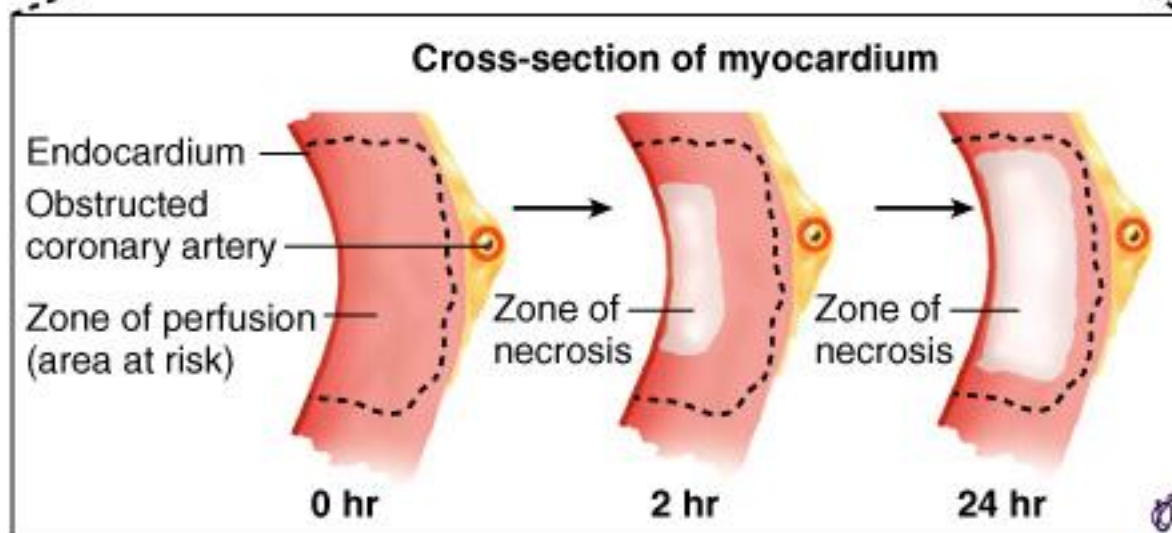
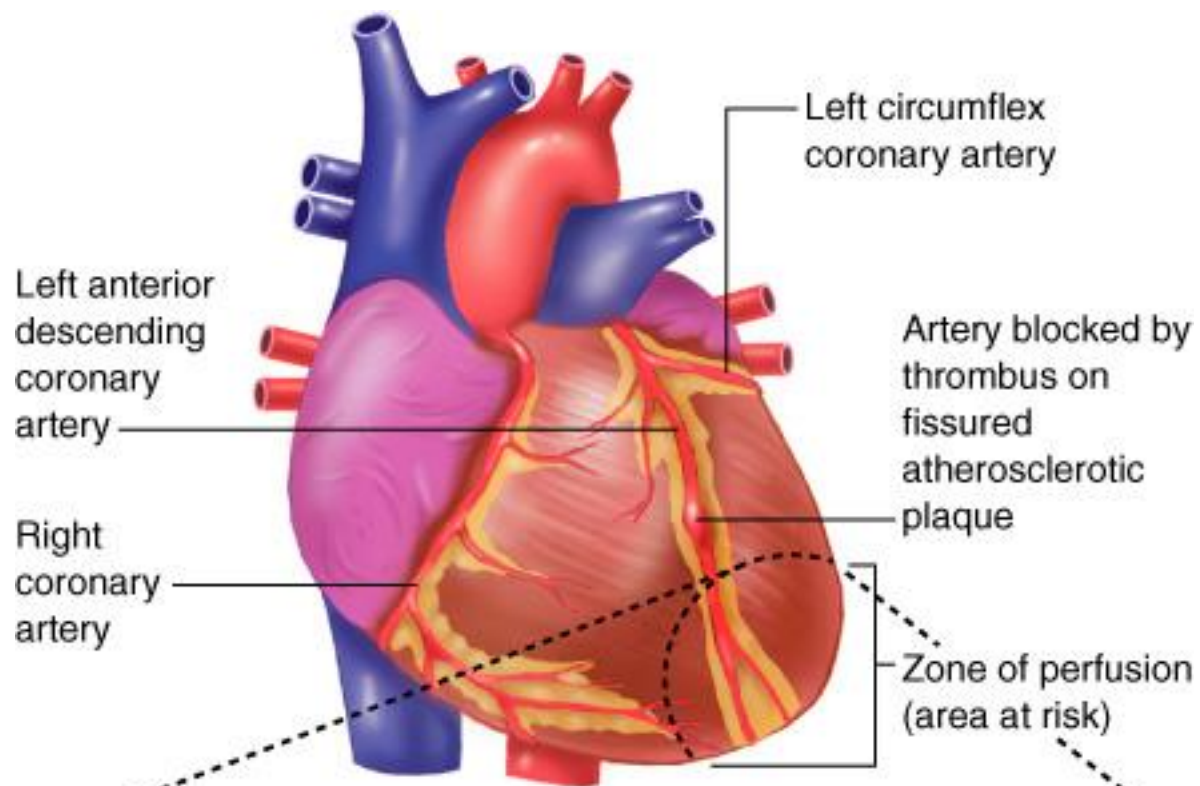
Hypertrophy of the left ventricle of the heart in hypertension.

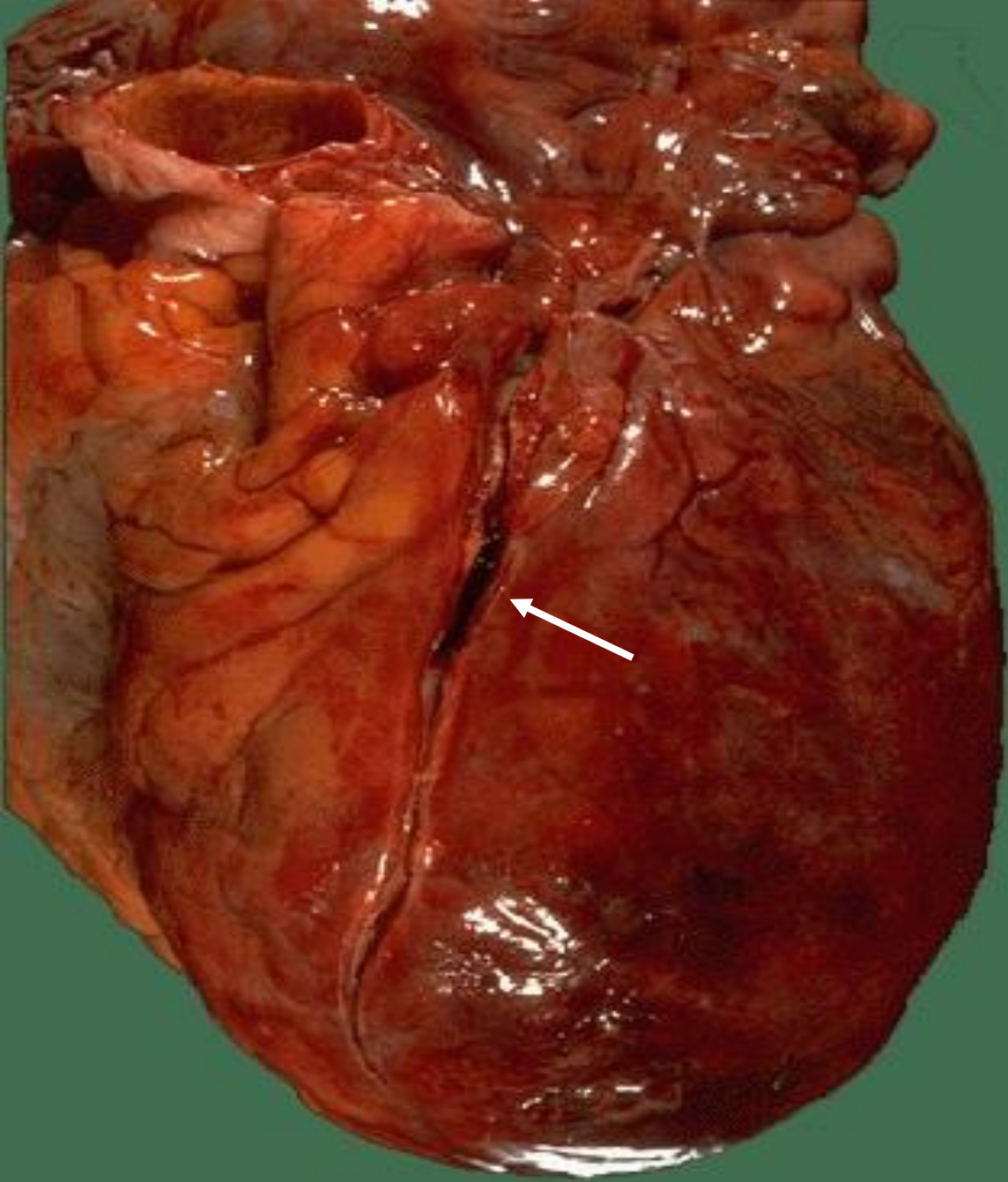


Scheme of the evolution and complications of coronary atherosclerosis.

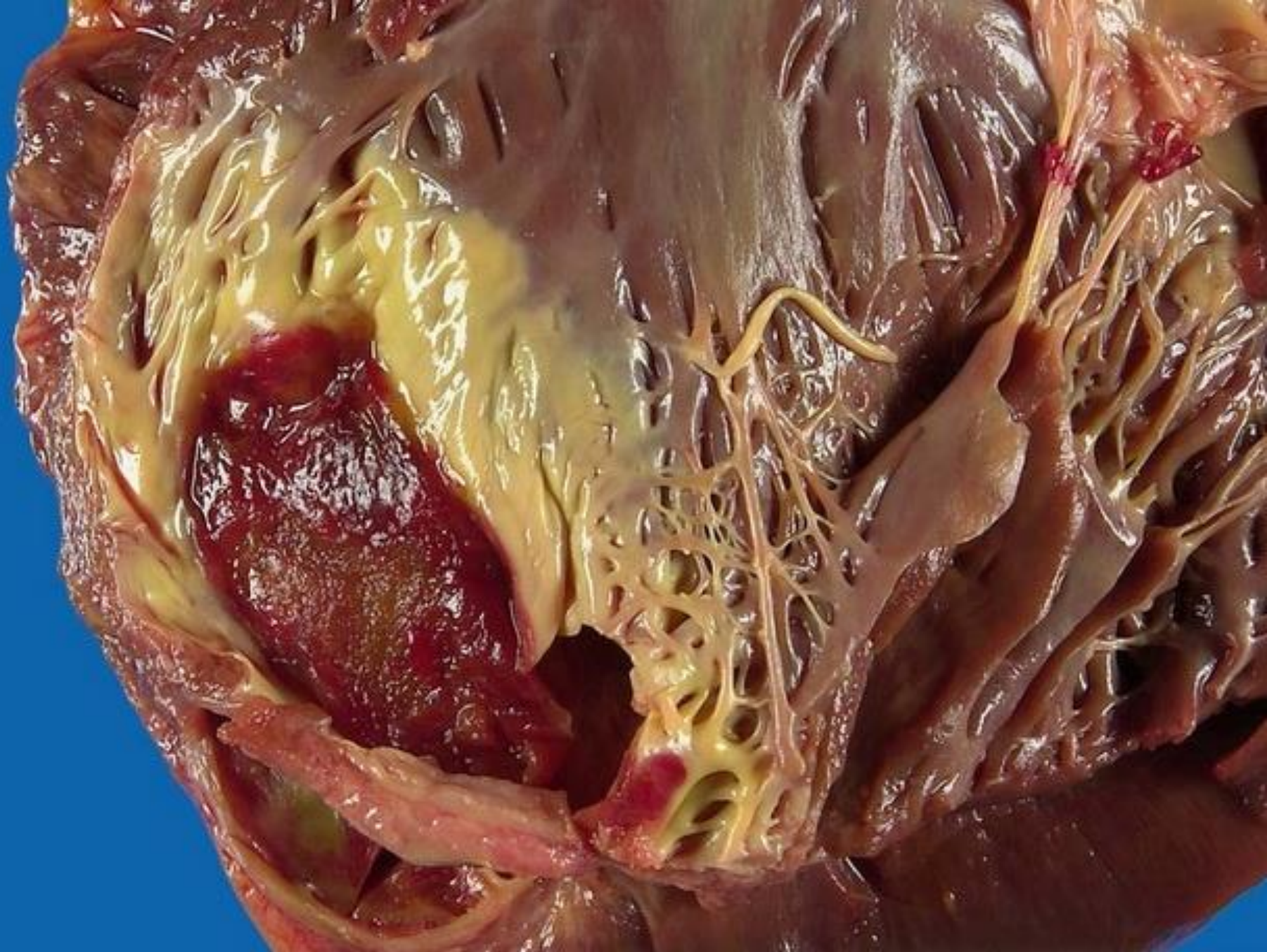


Coronary atherosclerosis, intramural hemorrhage.

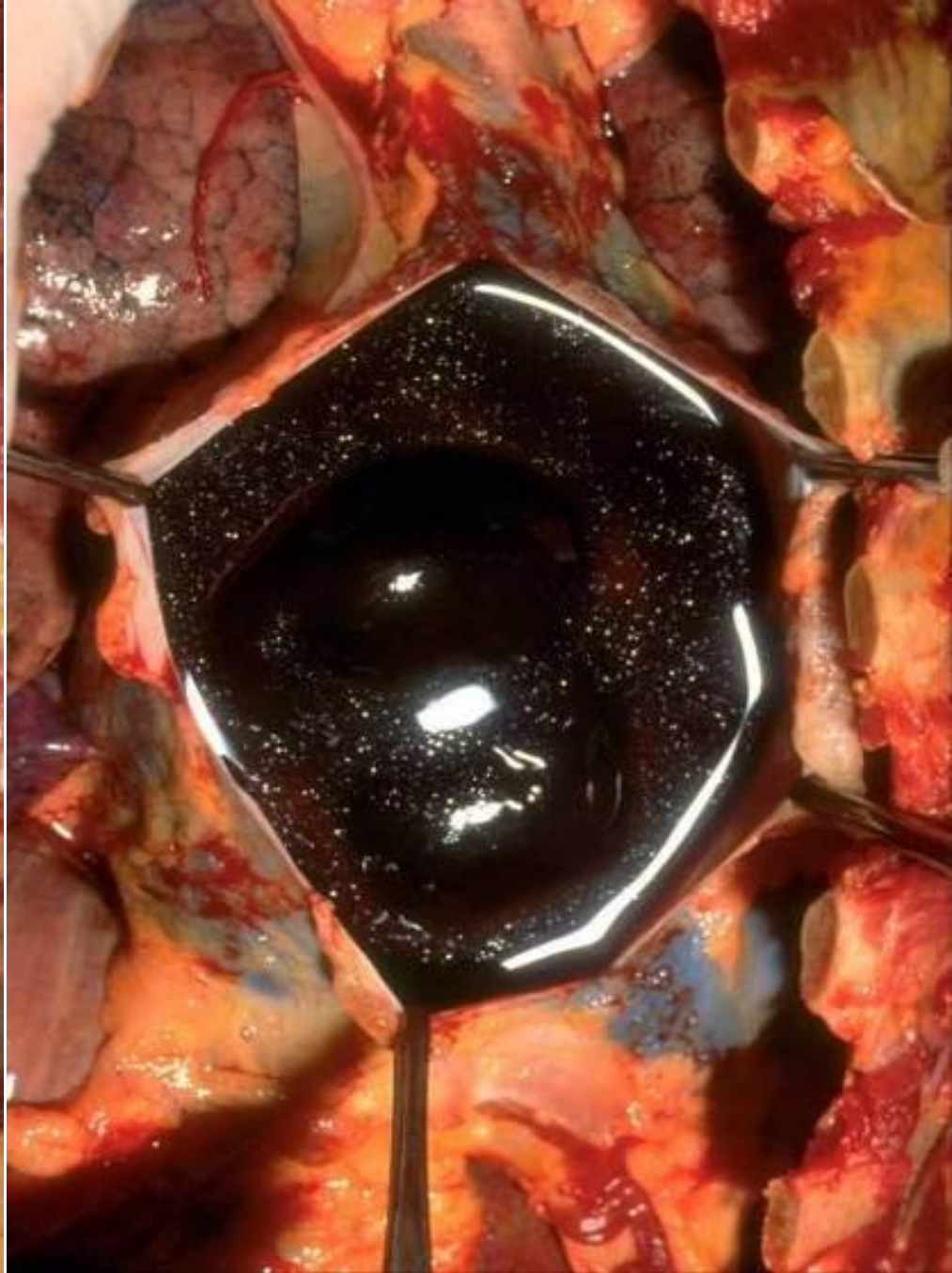
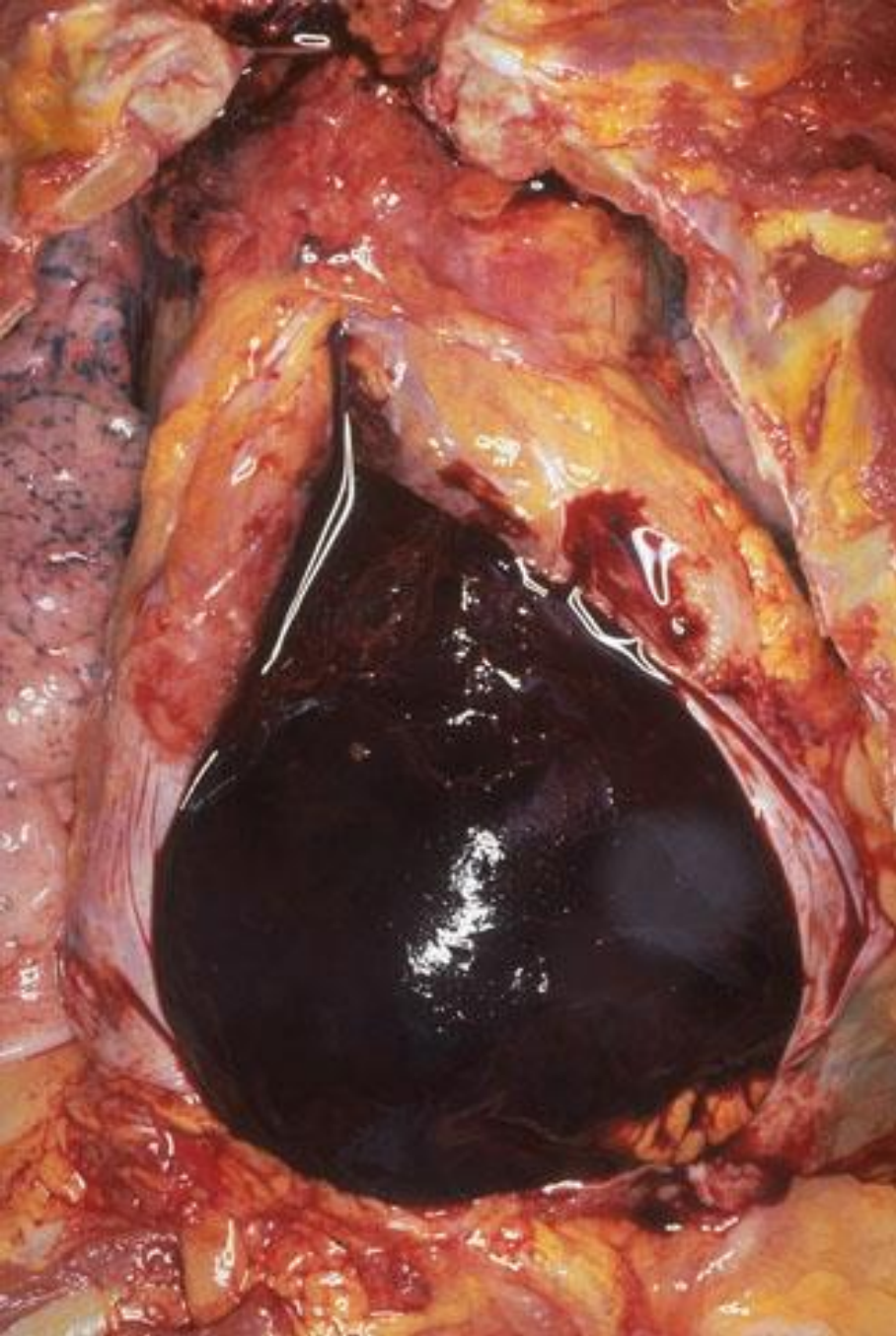


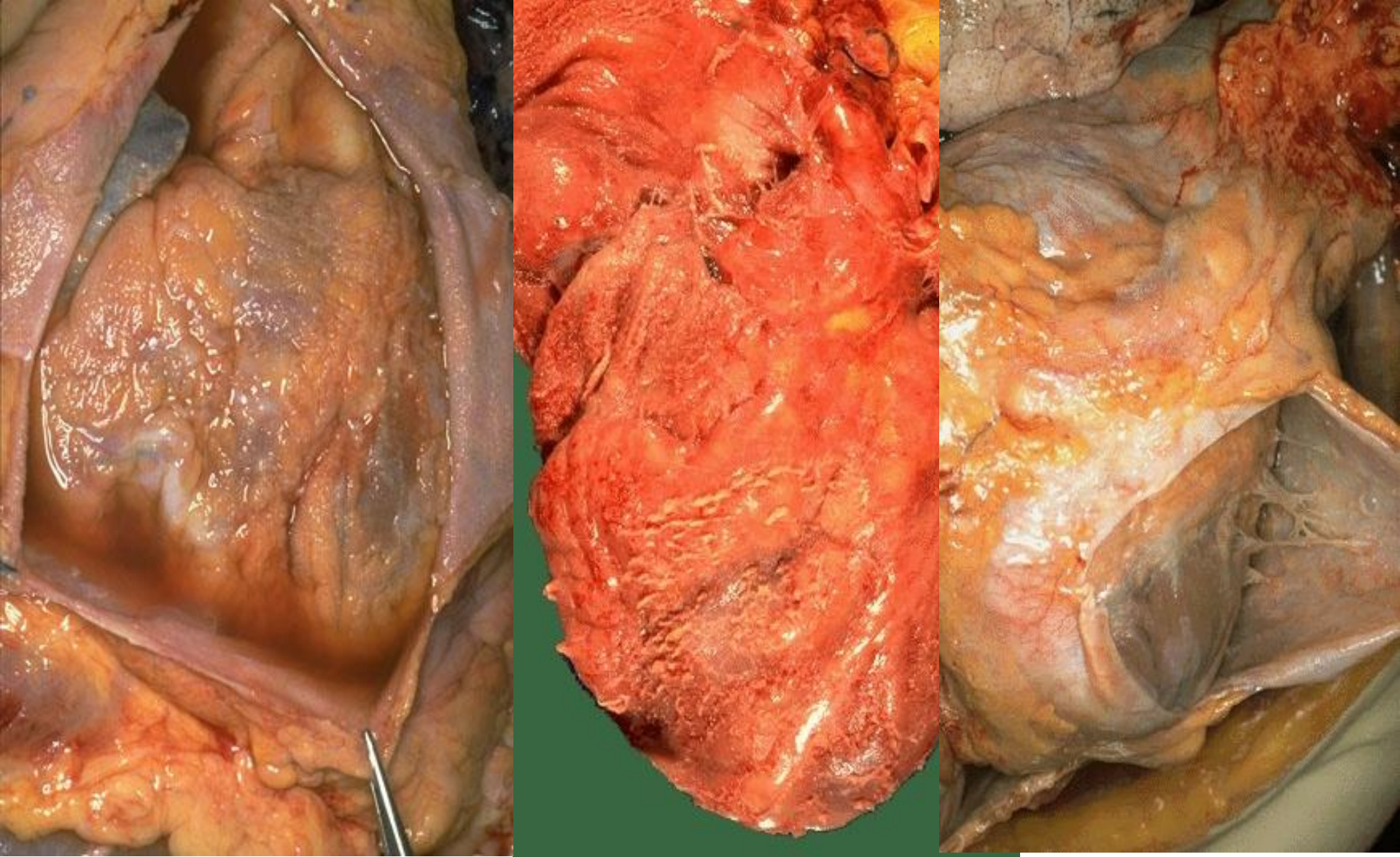Coronary thrombosis.



Myocardial infarction (mural thrombus).

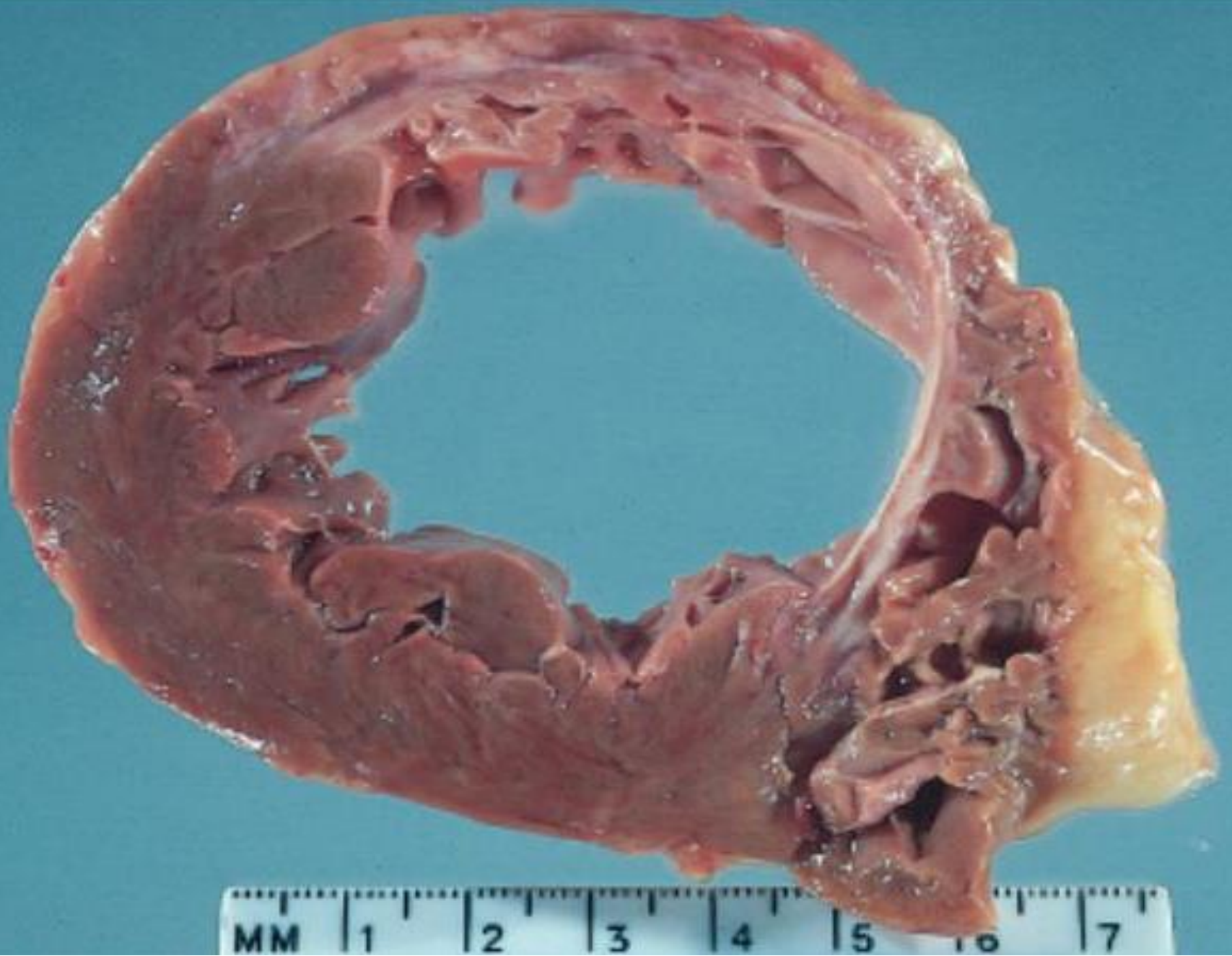

Hemopericardium.

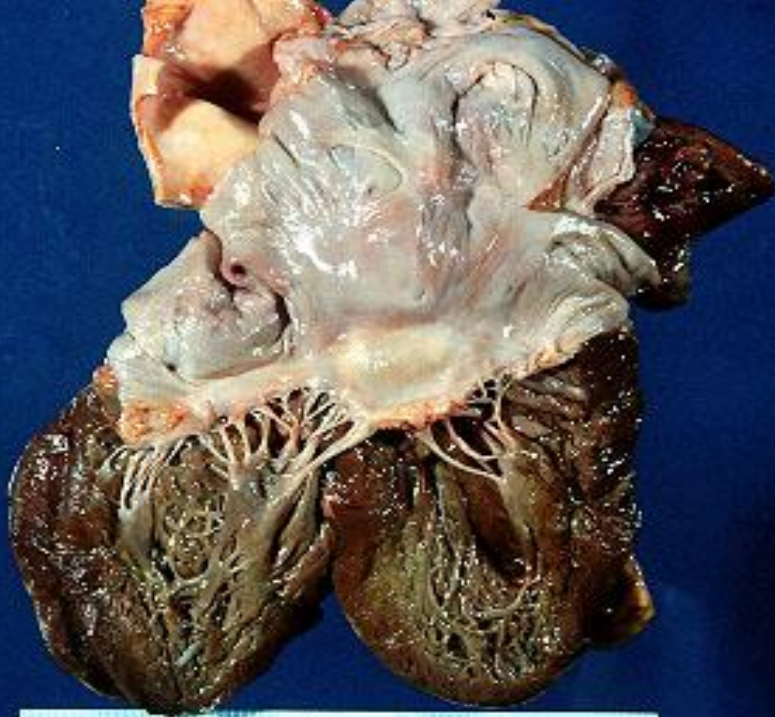

Fibrinous pericarditis: different developmental stages.

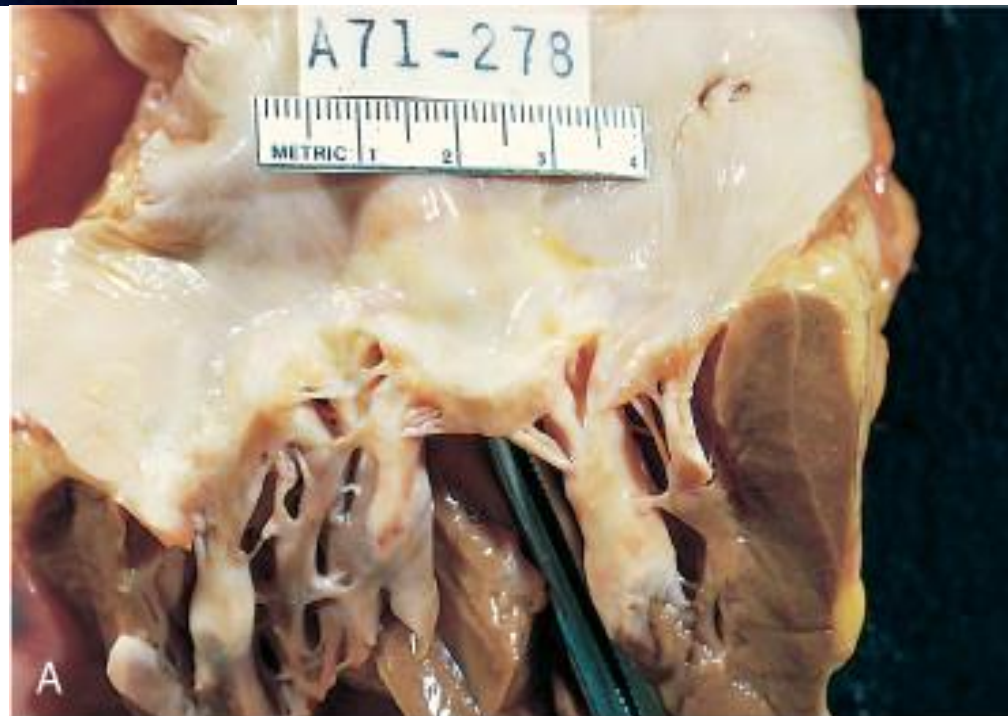
In the first image is an example of acute pericarditis with pericardial effusion, occurs at 2-4 days after transmural infarction in up to 15% of patients

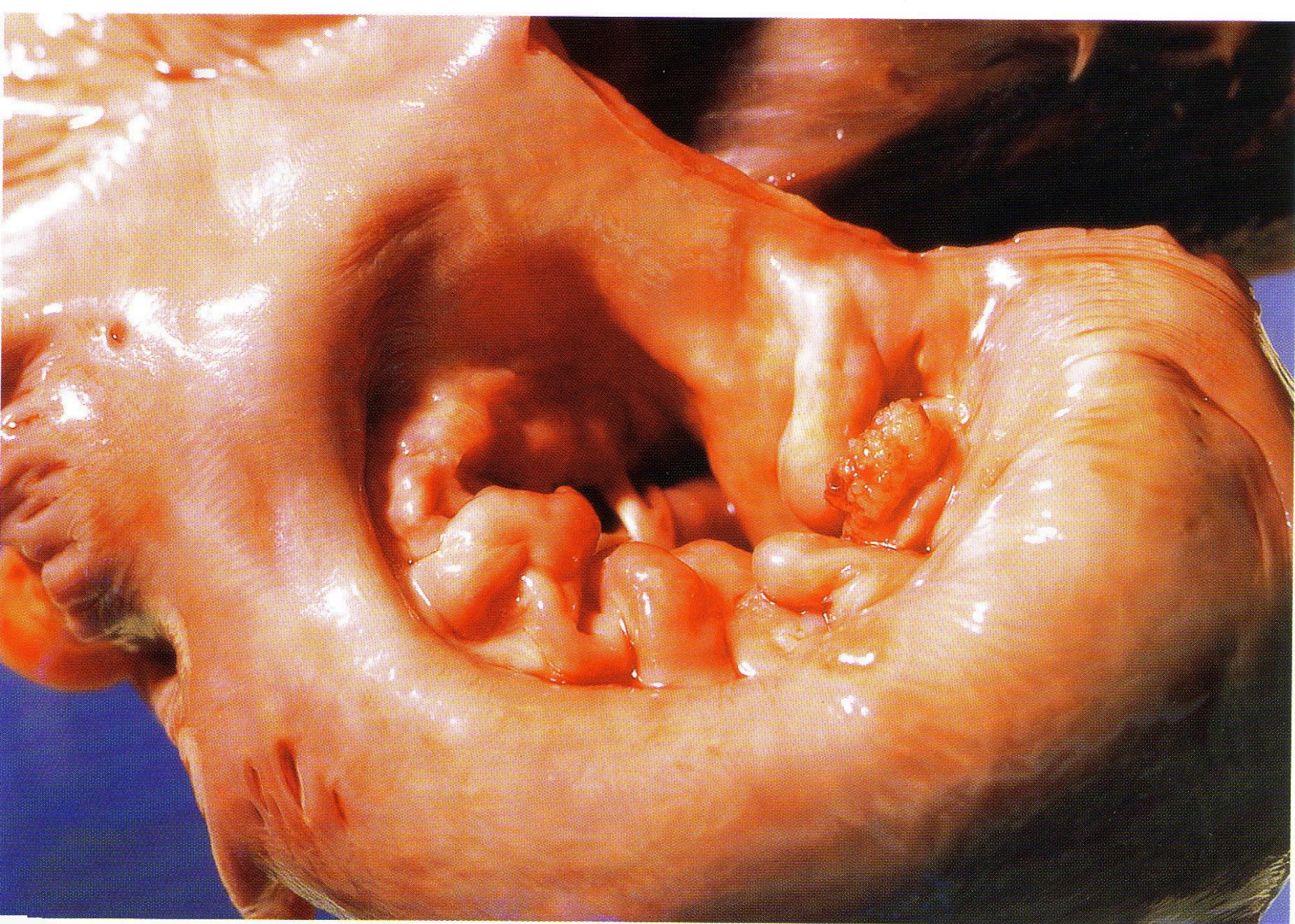


Postinfarction cardiosclerosis.

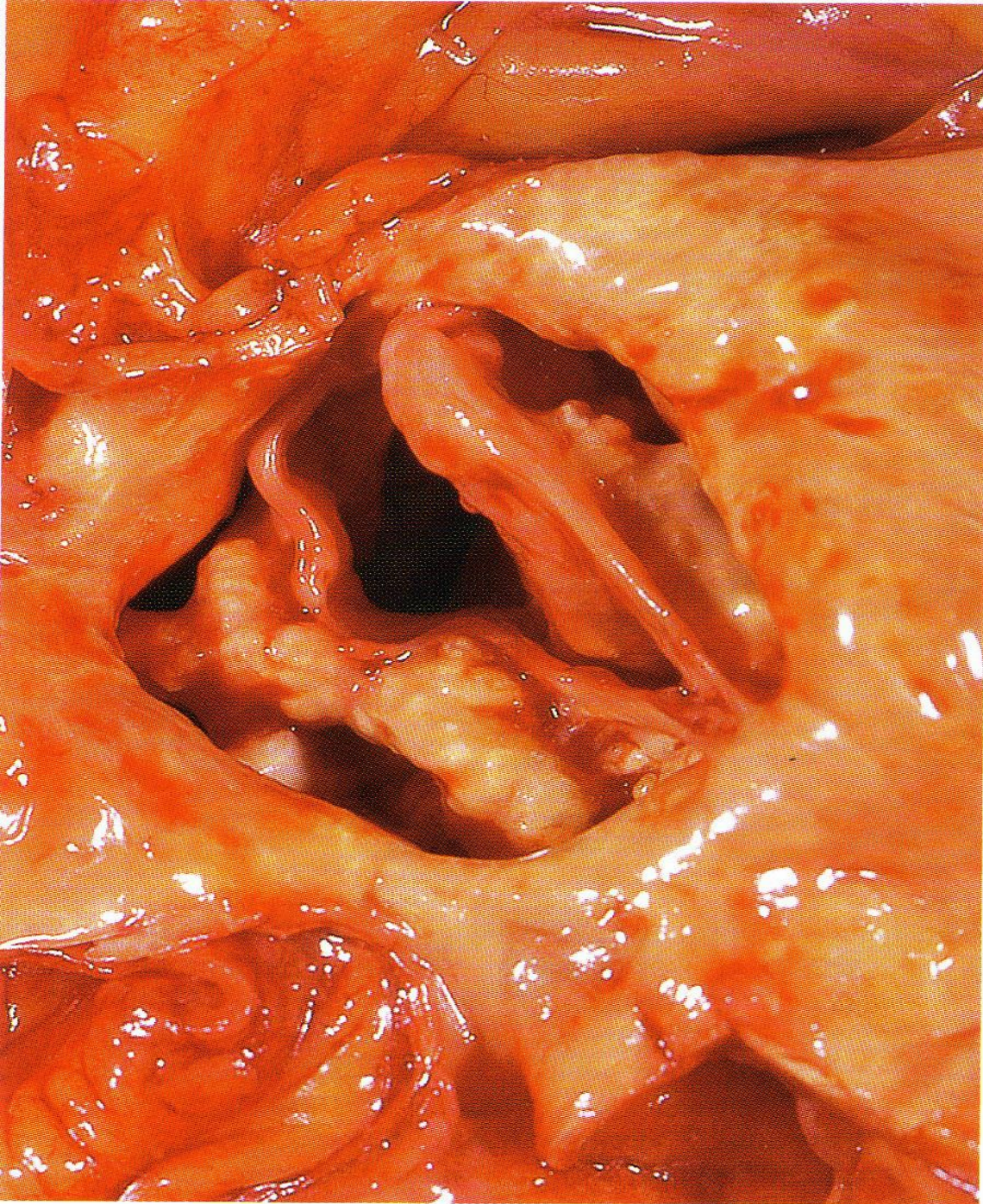


**Chronic verrucous
valvular endocarditis.**

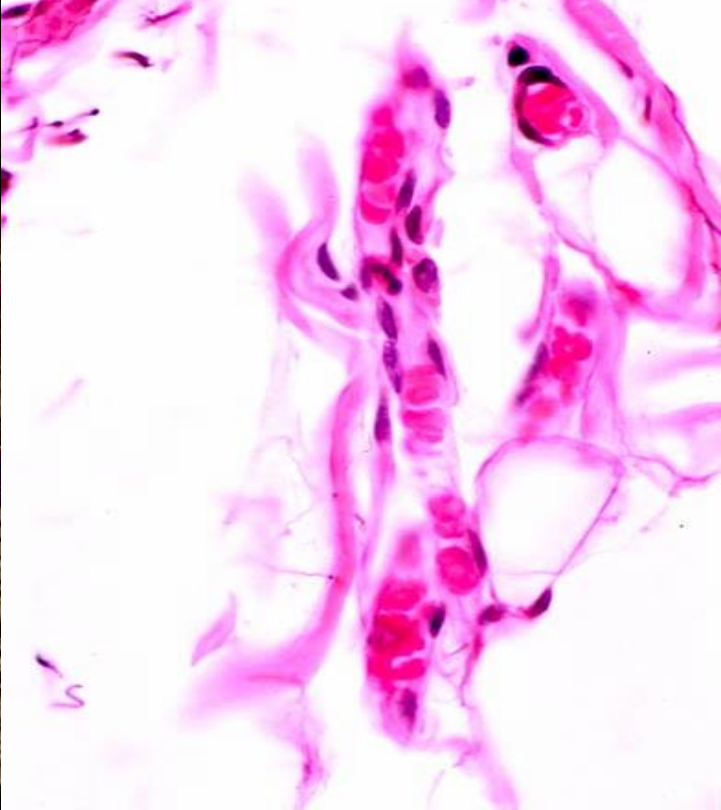
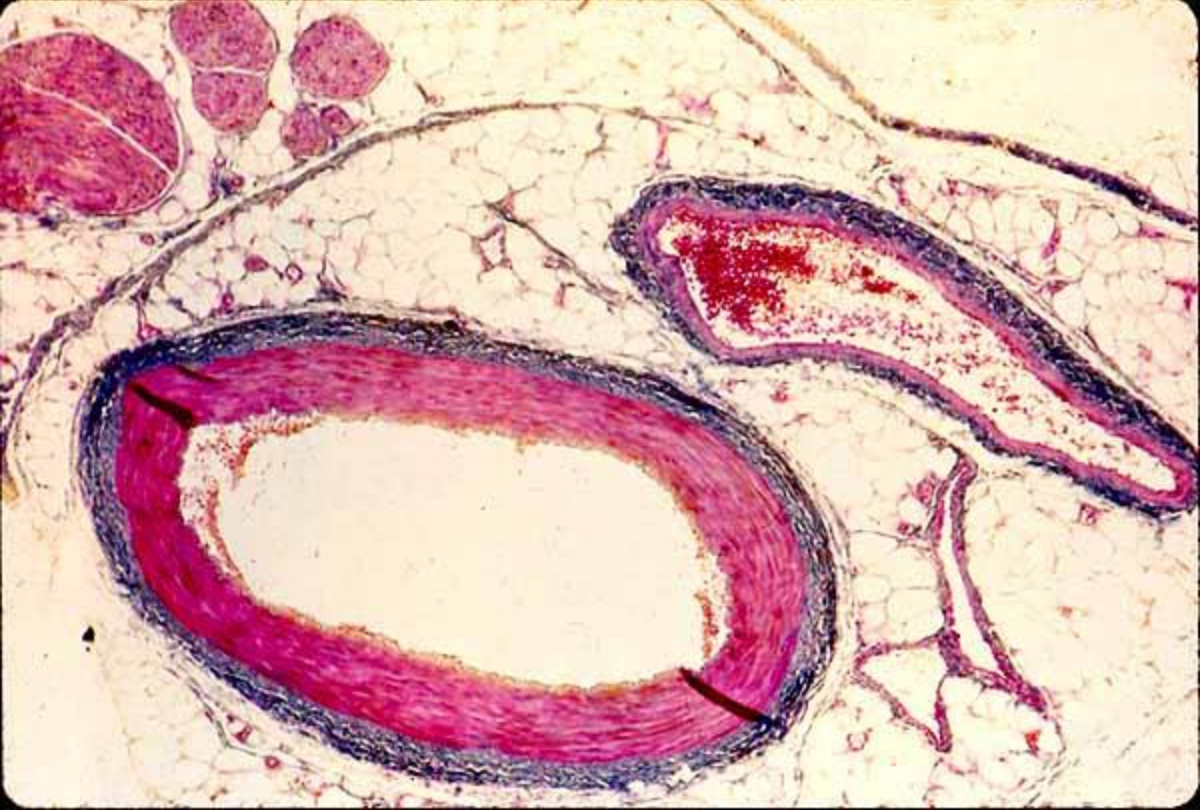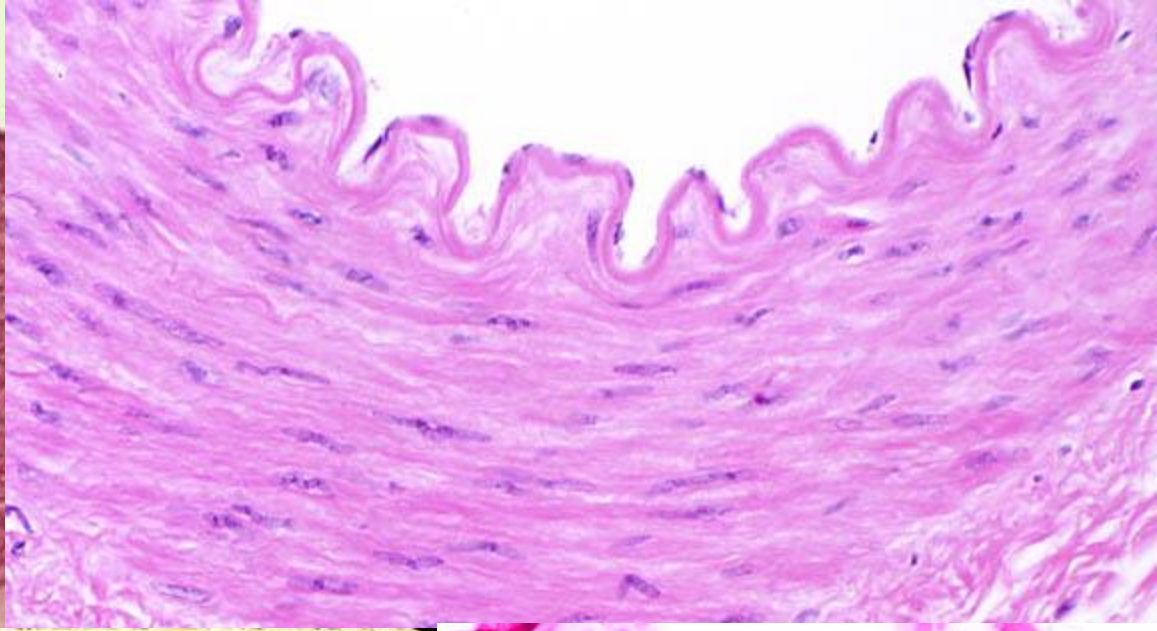
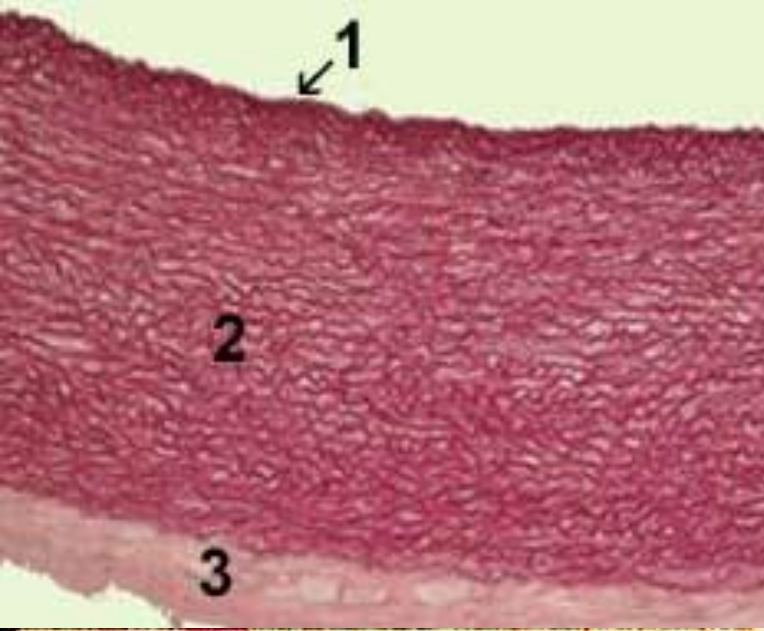




Mitral stenosis (*view from left atrium*).



Aortic stenosis.



COMPONENTS

- Intima, Media, Adventitia, M>A or A>M
- ENDOTHELIUM
- INTERNAL ELASTIC LAMINA
- ECM: Elastin (~aging), collagen, mucopolysaccharides
- Smooth Muscle
- Connective Tissue
- Fat



1) Blockage
(preceded by narrowing)

2) Rupture
Preceded by weakening)

TOPICS

- Vascular wall responses
- Congenital Anomalies
- Atherosclerosis
- Arteriosclerosis
- Hypertension
- Aneurysms
- Vasculitides
- Raynaud “phenomenon”
- Veins
- Lymphatics
- Tumors
- Interventions

DEFINITIONS

- **ARTERIO-sclerosis**
- **ATHERO-sclerosis**
- **Aneurysm**
- **Dissection**
- **Thrombus**
- **Hypertension**
- **Vasculitis/Vasculitides, infectious/NON-infectious (often-autoimmune)**
- **Varicosity**
- **DVT/Thrombo-phlebitis/Phlebo-thrombosis**

DEFINITIONS

- Lymphangitis
- Lymphedema
- Angioma/Hemangioma (generic)
- Lymphangioma
- Angiosarcoma (generic)
- Lymphangiosarcoma

NON-Specific Vascular Wall Response to Injury

- **Endothelial “activation”**
- **Smooth Muscle cell roles**
- **Development, Growth,
Remodeling**
- **Intimal “thickening”**

ENDOTHELIAL CELLS

- **Recall Jeckyl/Hyde concept: maintain hemostasis/cause thrombosis**
- Maintenance of Permeability Barrier
- Elaboration of Anticoagulant, Antithrombotic, Fibrinolytic Regulators
- Elaboration of Prothrombotic Molecules
- Extracellular Matrix Production (collagen, proteoglycans)
- Modulation of Blood Flow and Vascular Reactivity
- Regulation of Inflammation and Immunity
- Regulation of Cell Growth
- Oxidation of LDL

ENDOTHELIAL CELL

“ACTIVATORS” (Δ ?)

- Cytokines
- Bacterial Products
- Hemodynamic Forces
- Lipid Products
- Viruses
- Complement
- Hypoxia

VASCULAR SMOOTH MUSCLE

- Vasoconstriction
- Vasodilatation
- Make ECM:
 - Collagen
 - Elastin
 - Proteoglycans
- Regulated by:
 - PROMOTORS: PDGF, endothelin, thrombin, etc.
 - INHIBITORS: Heparan SO₄, NO, TGF- β

Vessel Growth & Remodeling

- **The sum total of all the factors and processes involved in tissue injury and the body's ability to grow vessels, develop new pathways, and re-perfuse areas in response to tissue and/or blood vessel injury.**

1. Migration of smooth muscle cells to the

2. Smooth muscle cell mitosis

3. Elaboration of extracellular matrix

Endothelium

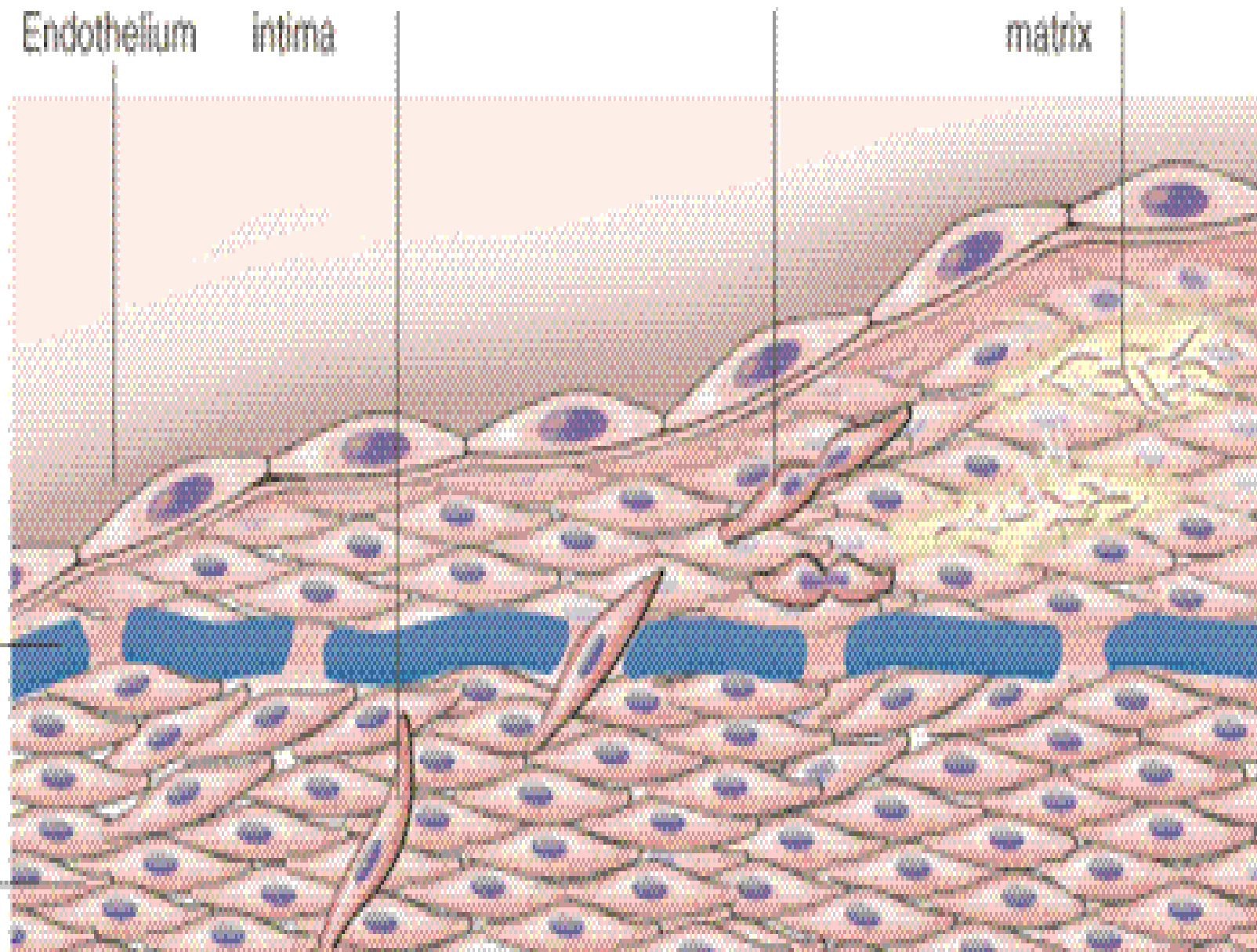
Intima

Intima

Media

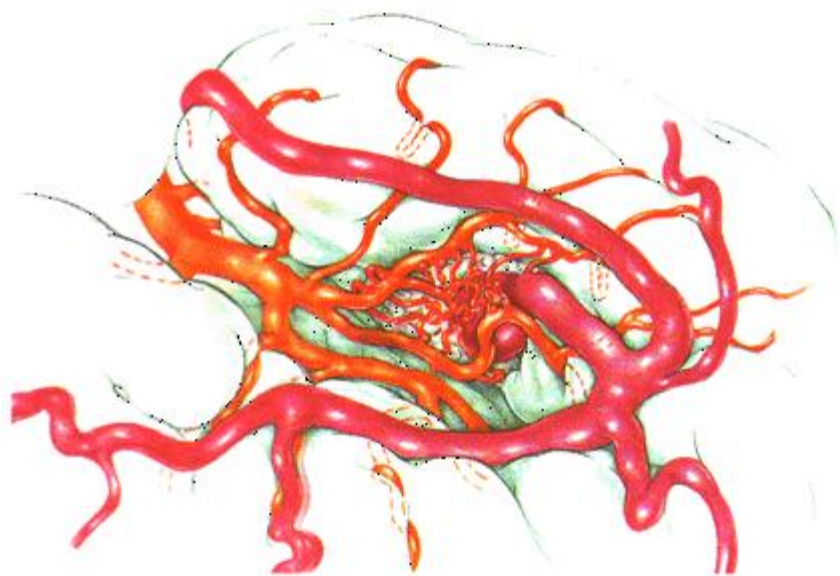
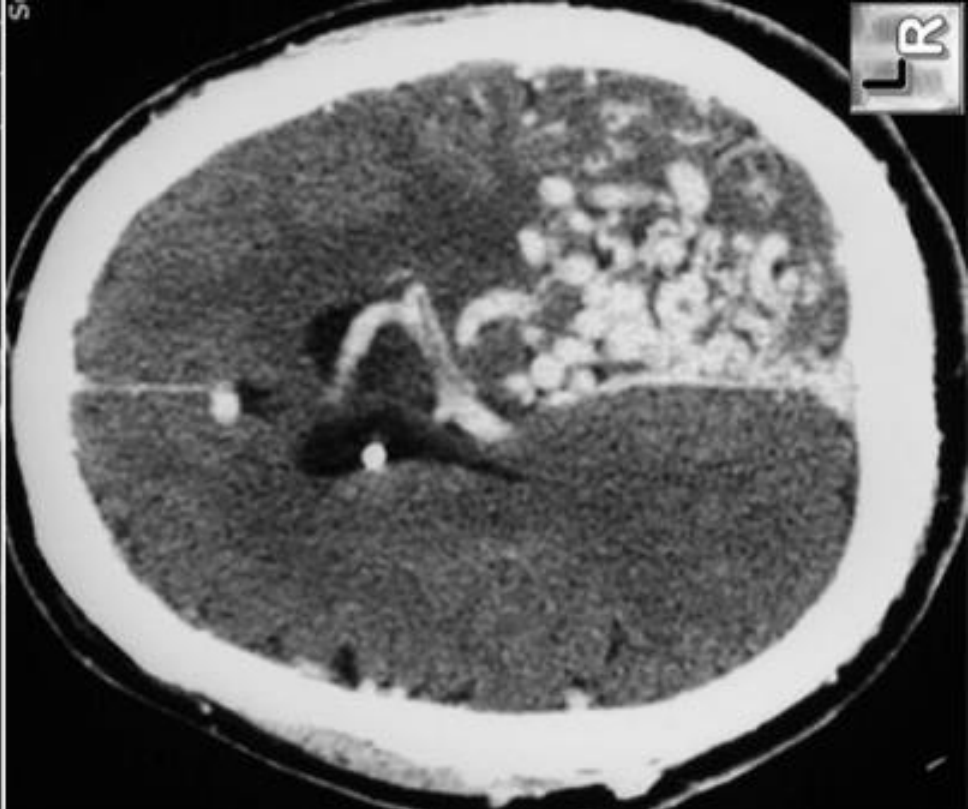
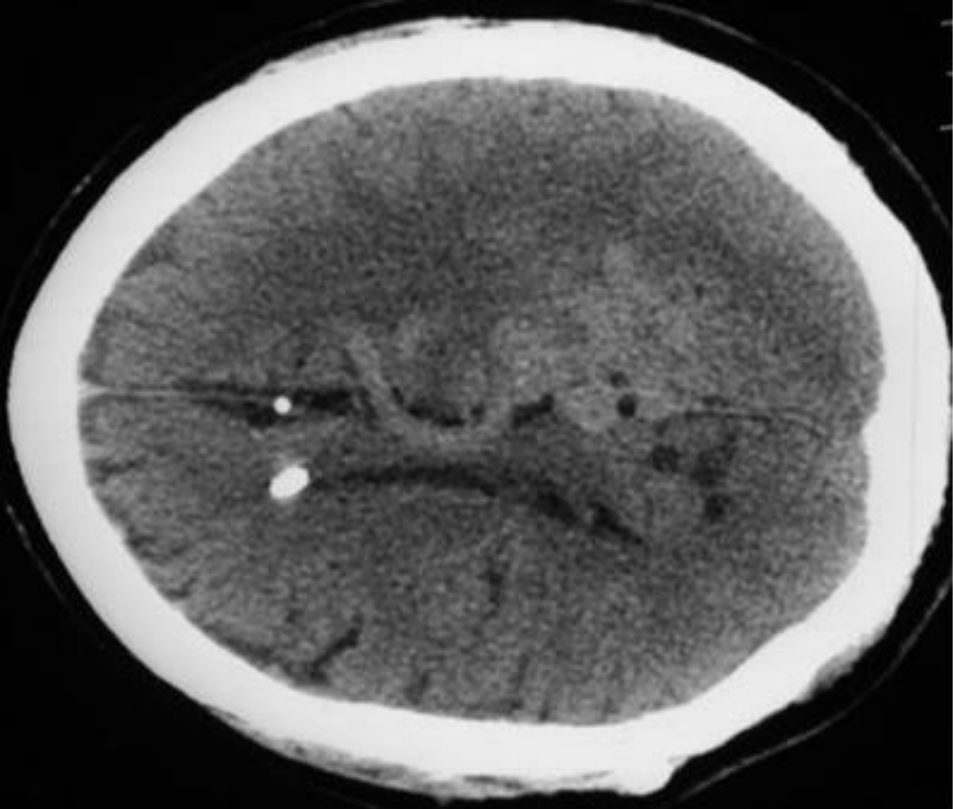
Internal elastic lamina

Smooth muscle cells



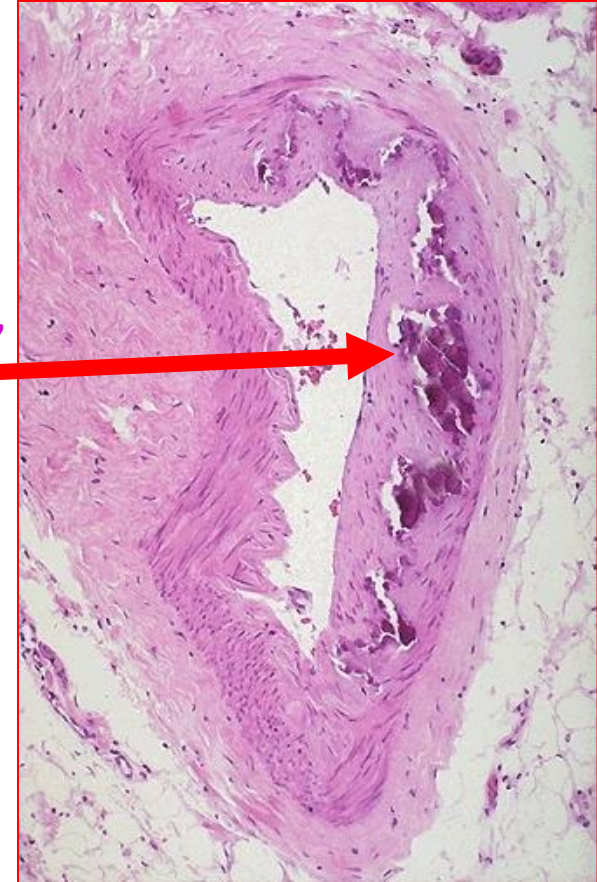
CONGENITAL ANOMALIES

- Arteriovenous fistulas
- Also called **ArterioVenous Malformation (AVM)**
- Common factor is abnormal communication between high pressure arteries and low pressure veins
- Usually congenital (malformation), but can be acquired by trauma or inflammation
- Most often described in the brain as an AVM
- Often asymptomatic or with hemorrhage or pressure effects



ARTERIO-SCLEROSIS

- **GENERIC** term for **ANYTHING** which **HARDENS** arteries
 - **Atherosclerosis (99%)**
 - **Mönckeberg medial calcific sclerosis (1%)**
- **Arterio****lo**sclerosis, involving small arteries and arterioles, generally regarded as **NOT** strictly being part of atherosclerosis, but more related to hypertension and/or diabetes



ATHEROSCLEROSIS

(classical)

- Etiology/Risk Factors
- Pathogenesis
- Morphology
- Clinical Expression

ATHEROSCLEROSIS

(ala Robbins)

- * Natural History
- * Epidemiology
- * Risk Factors
- * Pathogenesis
- * Other Factors
- * Effects
- * Prevention

* NATURAL HISTORY

Nomenclature and main histology	Sequences in progression	Main growth mechanism	Earliest onset	Clinical correlation
Type I (initial) lesion Isolated macrophage foam cells		Growth mainly by lipid accumulation	From first decade	Clinically silent
Type II (fatty streak) lesion Mainly intracellular lipid accumulation			From third decade	
Type III (intermediate) lesion Type II changes and small extracellular lipid pools				
Type IV (atheroma) lesion Type II changes and core of extracellular lipid		Accelerated smooth muscle and collagen increase	From fourth decade	Clinically silent or overt
Type V (fibroatheroma) lesion Lipid core and fibrotic layer, or multiple lipid cores and fibrotic layers, or mainly calcific, or mainly fibrotic				
Type VI (complicated) lesion Surface defect, hematoma-hemorrhage, thrombus		Thrombosis, hematoma		

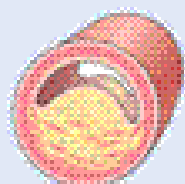
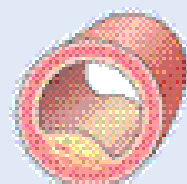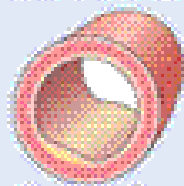

1) FATTY STREAK
(non-palpable, but a visible **YELLOW** streak)

2) ATHEROMA
(plaque) (palpable)

3) THROMBUS
(non-functional, symptomatic)

Pre-Clinical Phase
Usually young age

FATTY STREAK



NORMAL ARTERY

FIBROFATTY PLAQUE

**ADVANCED/
VULNERABLE PLAQUE**

At lesion-prone areas, and accelerated by risk factors:
Endothelial dysfunction
Monocyte adhesion/emigration
SMC migration to intima
SMC proliferation
ECM elaboration
Lipid accumulation

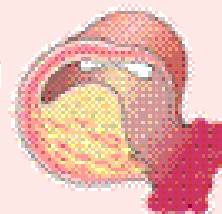Cell death/degeneration
Inflammation
Plaque growth
Remodeling of plaque and wall ECM
Organization of thrombus
Calcification

Clinical horizon

Clinical Phase
Usually middle age to elderly

Mural thrombosis
Embolization
Wall weakening

ANEURYSM AND RUPTURE




Plaque rupture
Plaque erosion
Plaque hemorrhage
Mural thrombosis
Embolization

OCCCLUSION BY THROMBUS



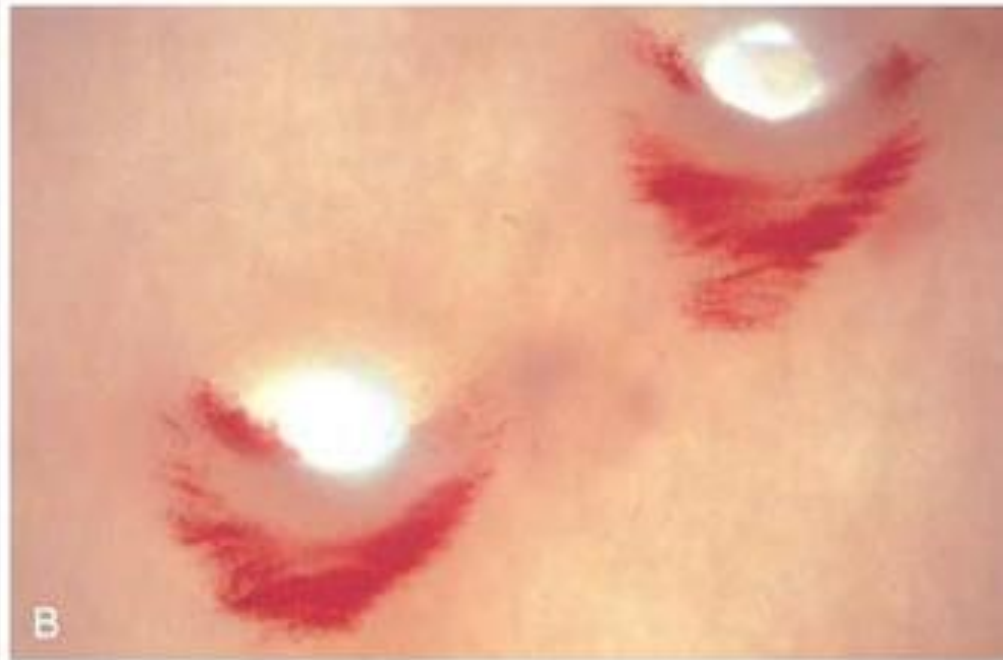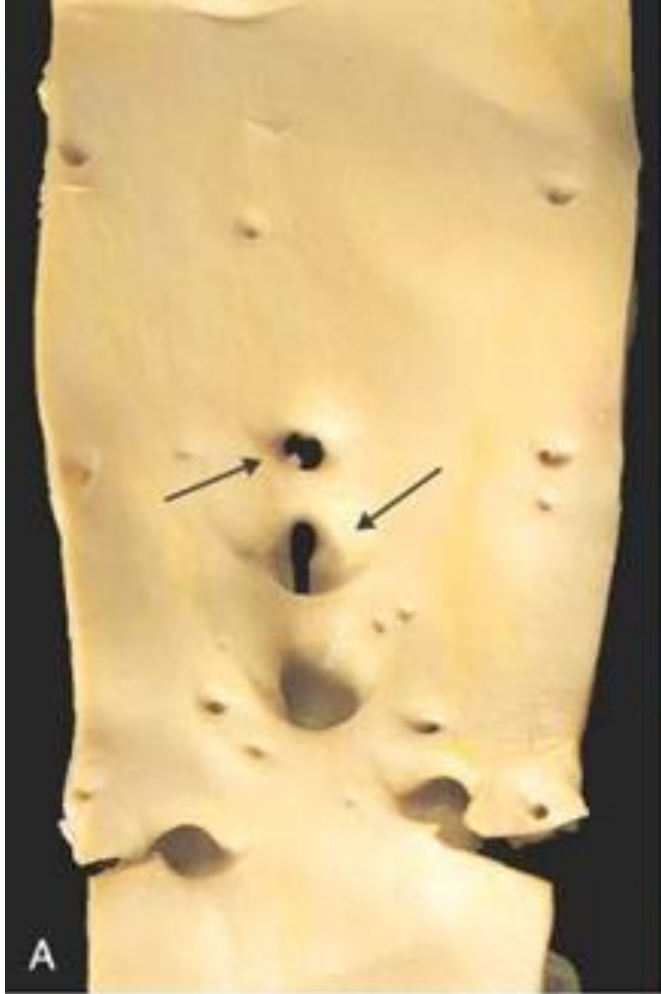Progressive plaque growth

CRITICAL STENOSIS

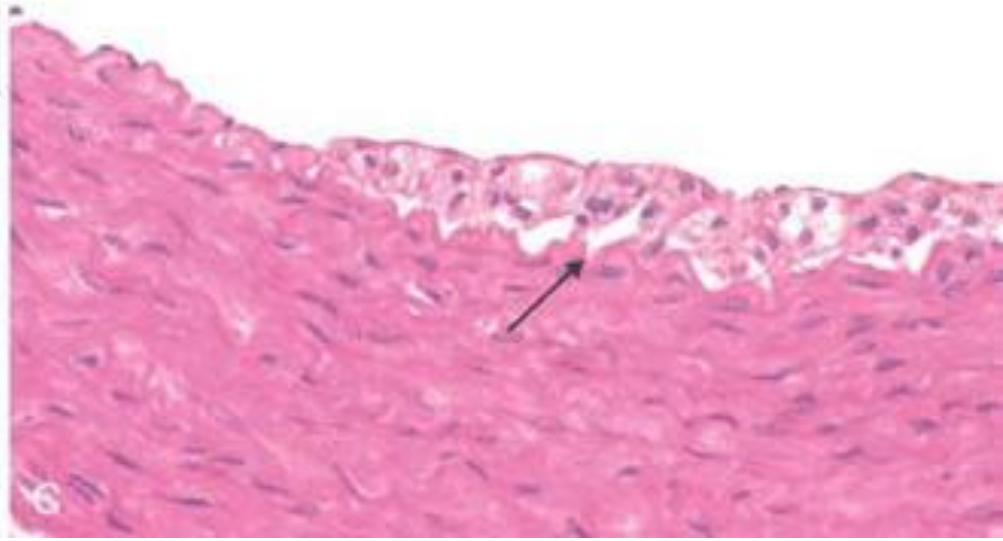


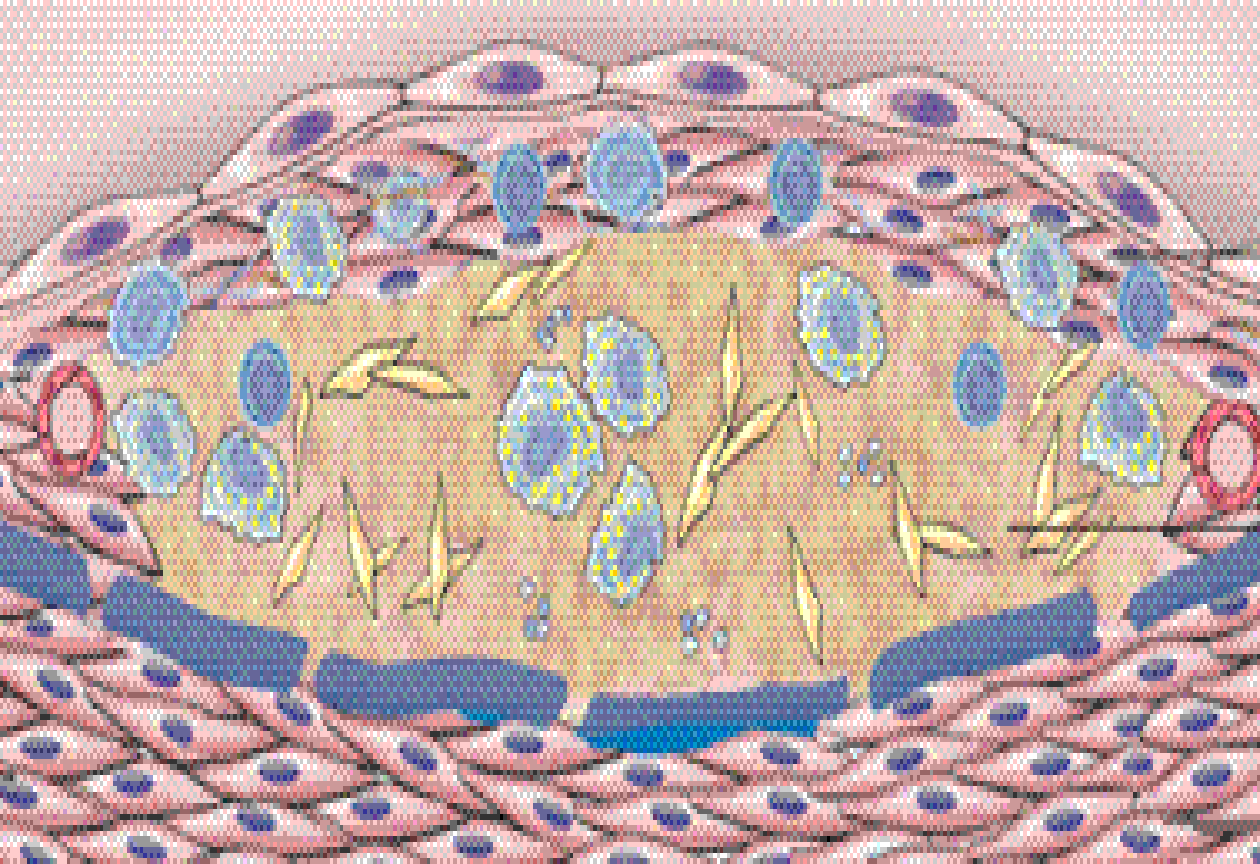
MORPHOLOGIC CONCEPTS

- Macrophages (really monocytes) infiltrate
- Intimal Thickening
- Lipid Accumulation
- Streak
- Atheroma
- Smooth Muscle Hyperplasia and Migration
- Fibrosis
- Calcification
- Aneurysm
- Thrombosis



FATTY STREAKS





FIBROUS CAP

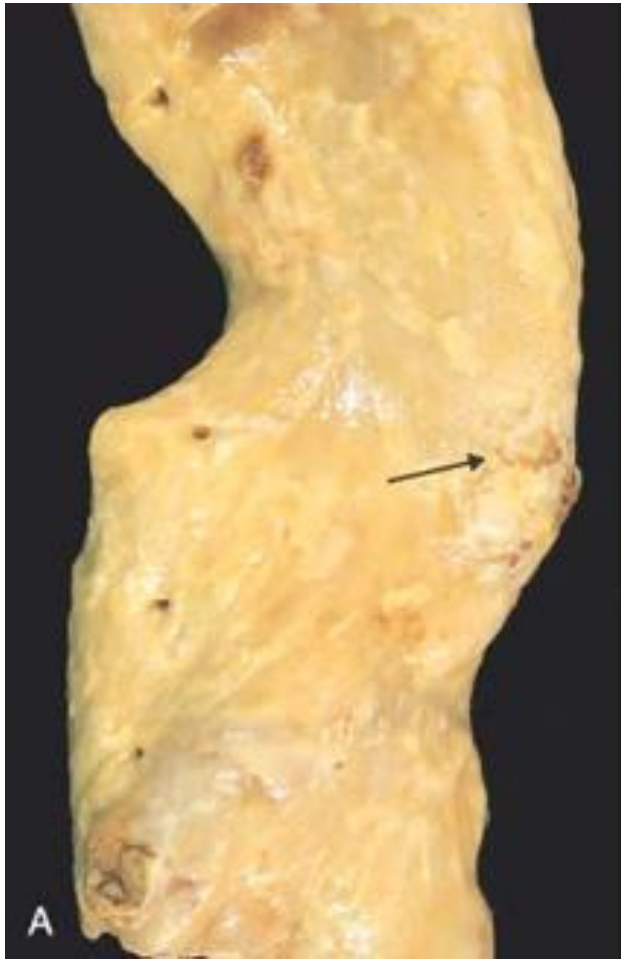(smooth muscle cells, macrophages, foam cells, lymphocytes, collagen, elastin, proteoglycans, neovascularization)

NECROTIC CENTER

(cell debris, cholesterol crystals, foam cells, calcium)

MEDIA

PLAQUE

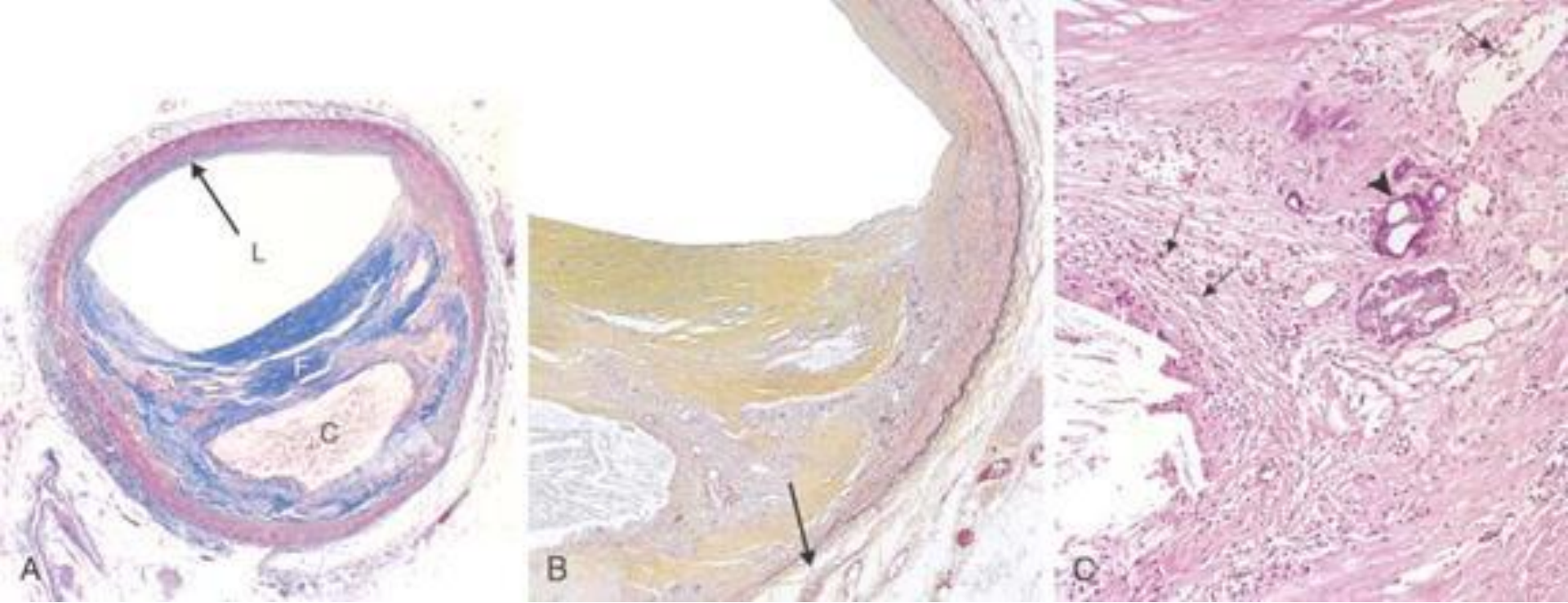


MILD

ADVANCED

ADVANCED FEATURES

- RUPTURE
- ULCERATION
- EROSION
- ATHEROEMBOLI
- HEMORRHAGE
- THROMBOSIS
- ANEURYSM



FUN THINGS TO FIND:

Lumen, Fibrous cap (fibrous plaque), Lipid core, External Elastic Membrane thinning/destruction, Calcification, Neovascularization

* EPIDEMIOLOGY & RISK FACTORS

Epid./RiskFactors

- Related to “development” of nation
- US highest
- 50-70% DECREASE 1963→2000. Why?
- AGE
- SEX, M>F until menopause, estrogen “protection”
- GENETICS

MAJOR

factors

- **Hyperlipidemia**
- **Hypertension**
- **Cigarette Smoking**
- **Diabetes Mellitus**

Risk Factors for Atherosclerosis

Major

NON-modifiable

Increasing age

Male gender

Family history

Genetic abnormalities

Modifiable

Hyperlipidemia

Hypertension

Cigarette smoking

Diabetes

Minor

Modifiable

Obesity

Physical inactivity

Stress ("type A" personality)

Postmenopausal estrogen deficiency

High carbohydrate intake

Alcohol

Lipoprotein Lp(a)

Hardened (trans)unsaturated fat intake

Chlamydia pneumoniae

MAJOR

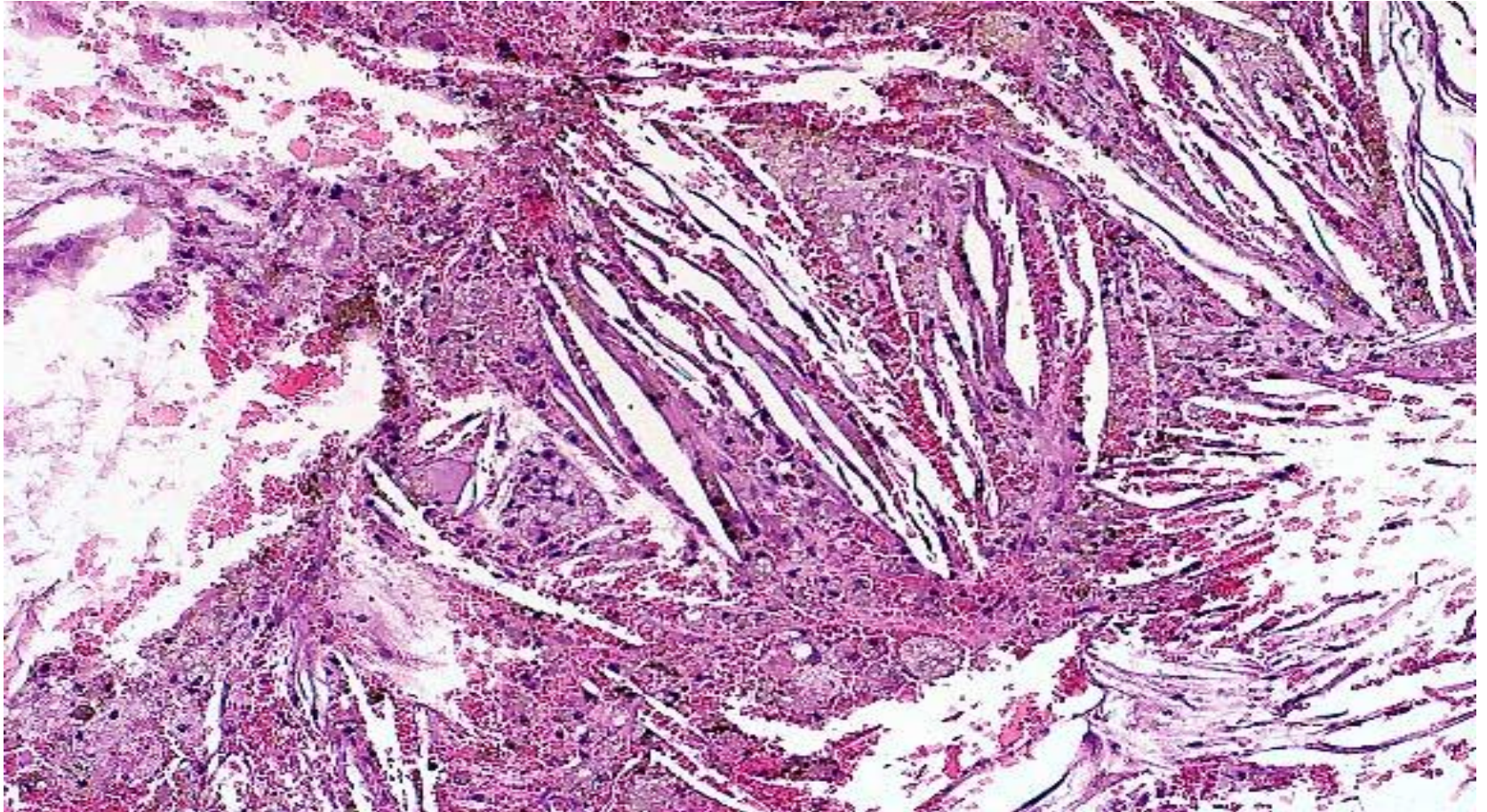
factors

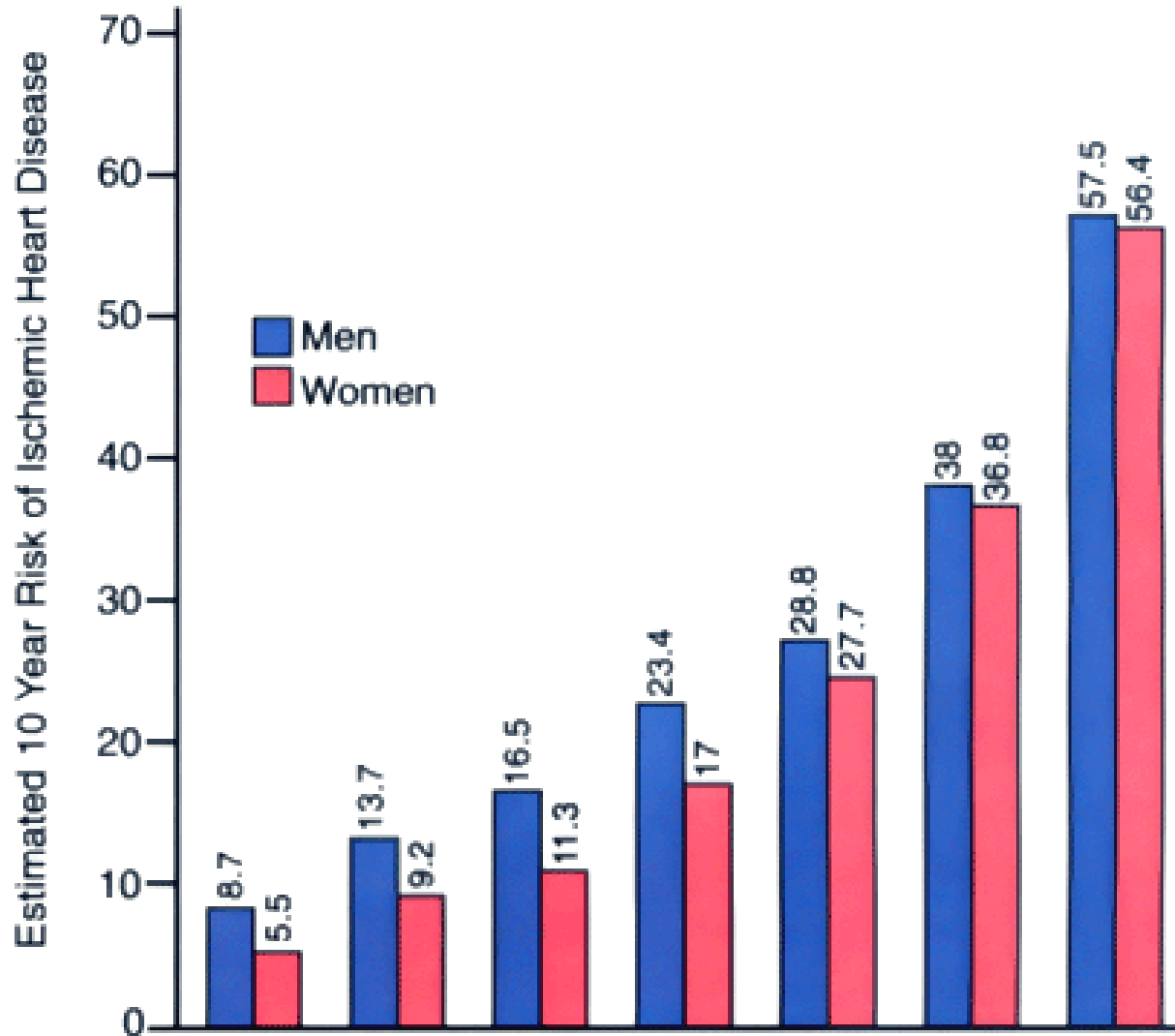
- Hyperlipidemia
- Hypertension
- Cigarette Smoking
- Diabetes Milletus

HYPERLIPIDEMIA

- Chiefly CHOLESTEROL, LDL>>>>HDL
- HDL mobilizes cholesterol FROM atheromas to liver
- LOW CHOLESTEROL diet is GOOD
- UNSATURATED fatty acids GOOD
- Omega-3 fatty acids GOOD
- Exercise GOOD

CHOLESTEROL CLEFTS

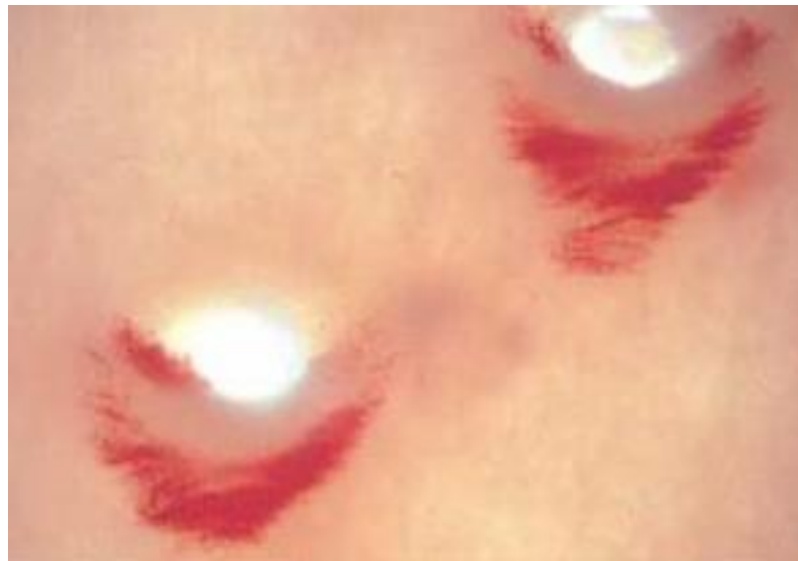



BP Systolic	120	160	160	160	160	160	160
Cholesterol	220	220	260	260	260	260	260
HDL-C	50	50	50	35	35	35	35
Diabetes	-	-	-	-	+	+	+
Cigarettes	-	-	-	-	-	+	+

HYPERTENSION

- **HYPERTENSION** causes **ATHEROSCLEROSIS. Why?**
- **ATHEROSCLEROSIS** causes **HYPERTENSION. Why?**



CIGARETTES

- What more needs to be said?



DIABETES

- If there was one disease which I could challenge you to, as a dare, to PROVE to me that was NOT EXACTLY **THE SAME** as atherosclerosis, it would be DIABETES! Any takers?

NON major factors

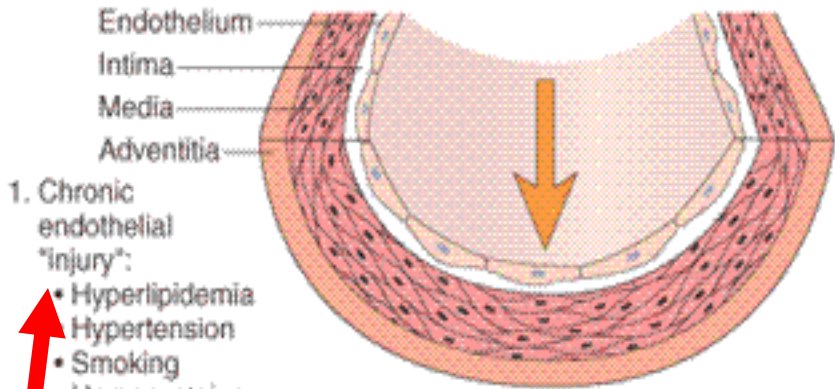
- **Homocysteinuria/homocysteinemia**, related to low B6 and folate intake
- **Coagulation defects**
- **Lipoprotein Lp(a)**, independent of cholesterol. Lp(a) is an altered form of LDL
- **Inadequate exercise, Type “A” personality, obesity** (independent of diabetes)
- **Protective effect of moderate alcohol?** Medical LIE, sponsored by the booze industry and alcoholic physicians!

PATHOGENESIS

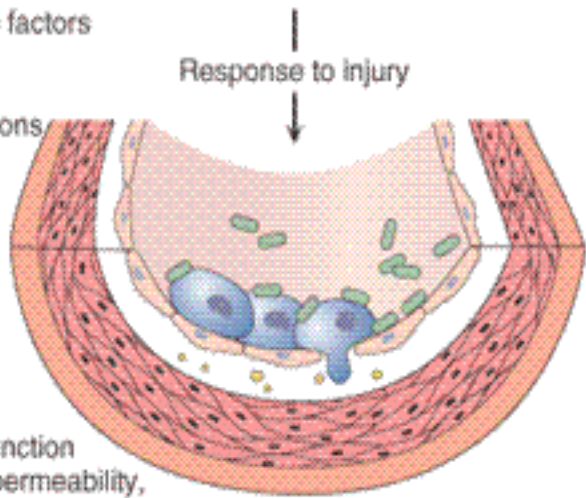
- *“atherosclerosis is a chronic inflammatory response of the arterial wall initiated by injury to the endothelium”*

PATHOGENESIS SAGA

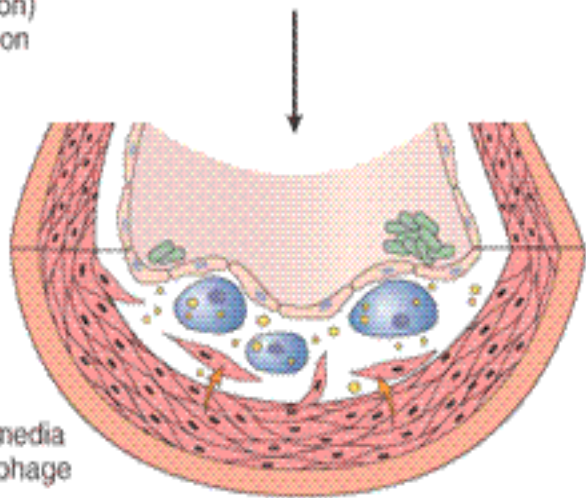
- Chronic endothelial injury→
- LDL, Cholesterol in arterial WALL→
- OXIDATION of lipoproteins→
- Monocytes migrate→ endothelium→*
- Platelet adhesion and activation→
- Migration of SMOOTH MUSCLE from media to intima to activate macrophages (foam cells)→
- Proliferation of SMOOTH MUSCLE and ECM→
- Accumulation of lipids in cells and ECM



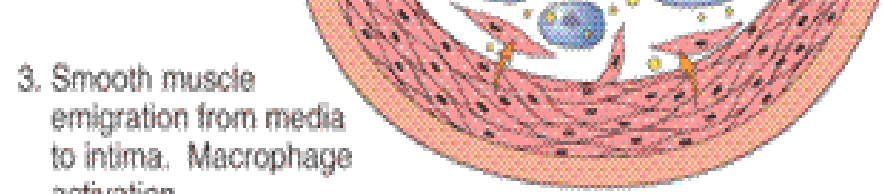1. Chronic endothelial "injury":
- Hyperlipidemia
 - Hypertension
 - Smoking
 - Homocysteine
 - Hemodynamic factors
 - Toxins
 - Viruses
 - Immune reactions



2. Endothelial dysfunction (e.g., increased permeability, leukocyte adhesion) Monocyte adhesion and emigration.

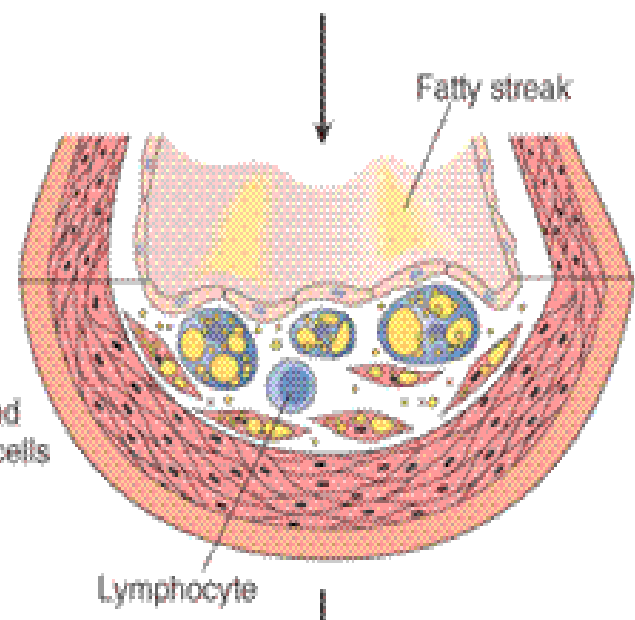


3. Smooth muscle emigration from media to intima. Macrophage activation.

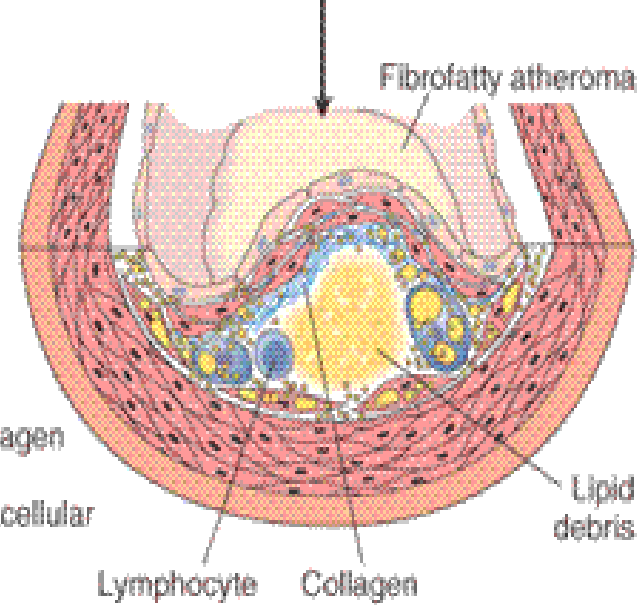


3. Smooth muscle emigration from media to intima. Macrophage activation.

4. Macrophages and smooth muscle cells engulf lipid



5. Smooth muscle proliferation, collagen and other ECM deposition, extracellular lipid

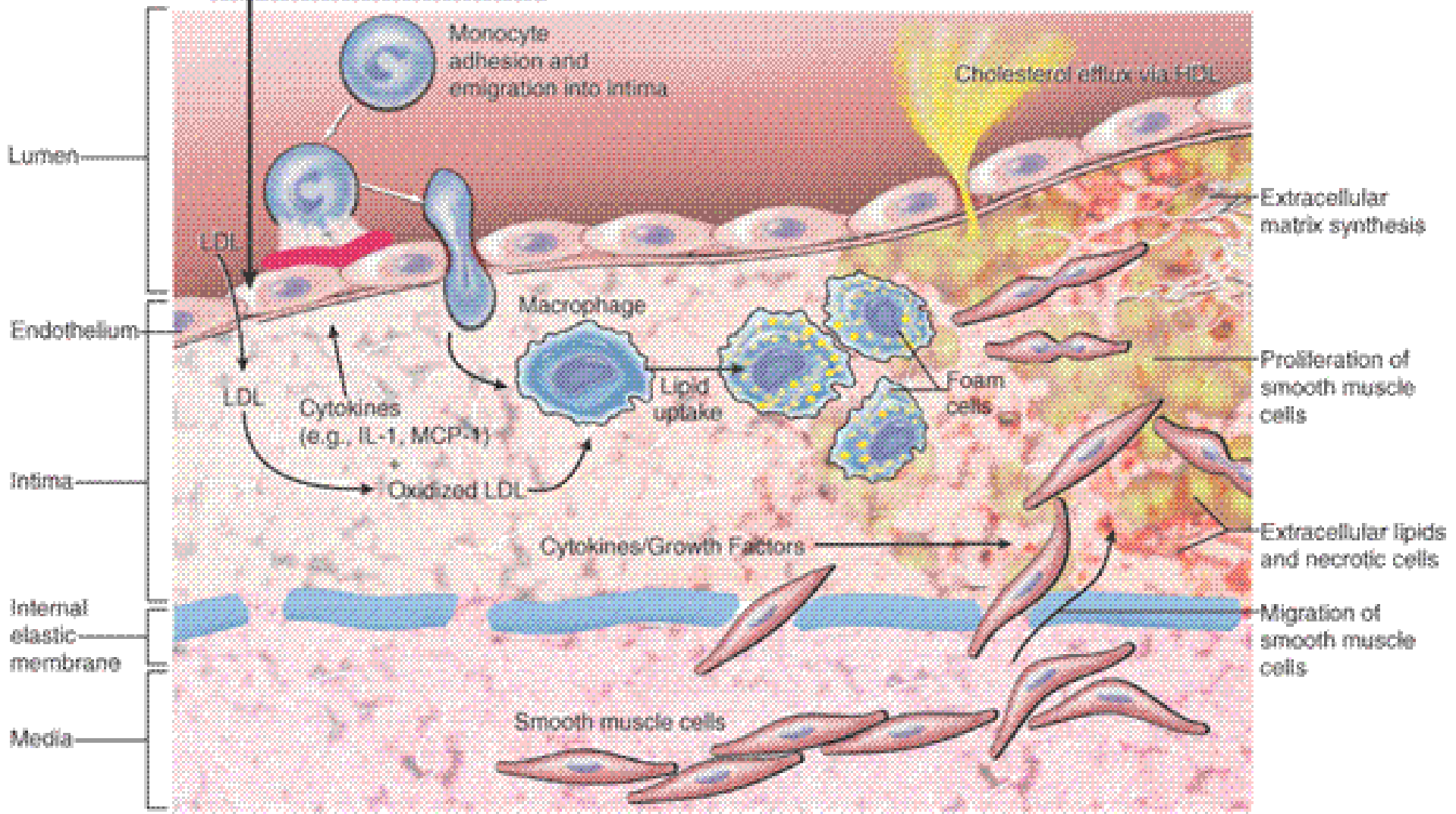


Main FOUR STARS of PATHOGENESIS SAGA

- 1) Endothelial Injury
- 2) Inflammation
- 3) Lipids
- 4) Smooth Muscle Cells, SMCs

Hyperlipidemia, Hypertension, Smoking, Toxins, Hemodynamic factors, Immune reactions, Viruses

Endothelial Injury/Dysfunction



Normal vessel → Progressive development of atherosclerotic plaque

Other Pathogenesis Considerations

- **Oligoclonality of cells in plaque**
- **Chlamydia, CMV as endothelial injurers**

PREVENTION PRINCIPLES

- Know what is preventable
- Know what is MAJOR (vs. minor)
- Know PRIMARY vs. SECONDARY principles
- Understand atherosclerosis begins in CHILDHOOD
- Risk factors in CHILDREN predict the ADULT profile
- Understand SEX, ETHNIC differences

NON ATHEROSCLEROSIS VASCULAR DISEASES

- **HYPERTENSION**
- **ANEURYSMS**
- **VASCULITIDES**
- **VEIN DISORDERS**
- **NEOPLASMS**

HYPERTENSION

- “ESSENTIAL” 95%
- “SECONDARY” 5%

SECONDARY

- **Renal**
 - Acute glomerulonephritis
 - Chronic renal disease
 - Polycystic disease
 - Renal artery stenosis
 - Renal artery fibromuscular dysplasia
 - Renal vasculitis
 - Renin-producing tumors
- **Endocrine**
 - Adrenocortical hyperfunction
 - (Cushing syndrome, primary aldosteronism, congenital adrenal hyperplasia, licorice ingestion)
 - Exogenous hormones (glucocorticoids, estrogen [including pregnancy-induced and oral contraceptives], sympathomimetics and tyramine-containing foods, monoamine oxidase inhibitors)
 - Pheochromocytoma, Acromegaly, Hypothyroidism (myxedema), Hyperthyroidism
 - Pregnancy-induced
- **Cardiovascular:** Coarctation of aorta, Polyarteritis nodosa (or other vasculitis)
 - Increased intravascular volume
- **MISC:** Increased cardiac output, Rigidity of the aorta, Neurologic, Psychogenic, Increased intracranial pressure, Sleep apnea, Acute stress, including, surgery

DEFINITION

- 140/90
- **SUSTAINED** diastolic >90
- **SUSTAINED** systolic >140

ALL Hypertension

$$BP = CO \times PR$$

HUMORAL FACTORS

Constrictors

Angiotensin II
Catecholamines
Thromboxane
Leukotrienes
Endothelin

Dilators

Prostaglandins
Kinins
NO

PERIPHERAL RESISTANCE

LOCAL FACTORS

Autoregulation
Ionic (pH, hypoxia)

NEURAL FACTORS

Constrictors

α -adrenergic

Dilators

β -adrenergic

BLOOD VOLUME

Sodium
Mineralocorticoids
Atriopeptin

BP = CARDIAC OUTPUT \times PERIPHERAL RESISTANCE

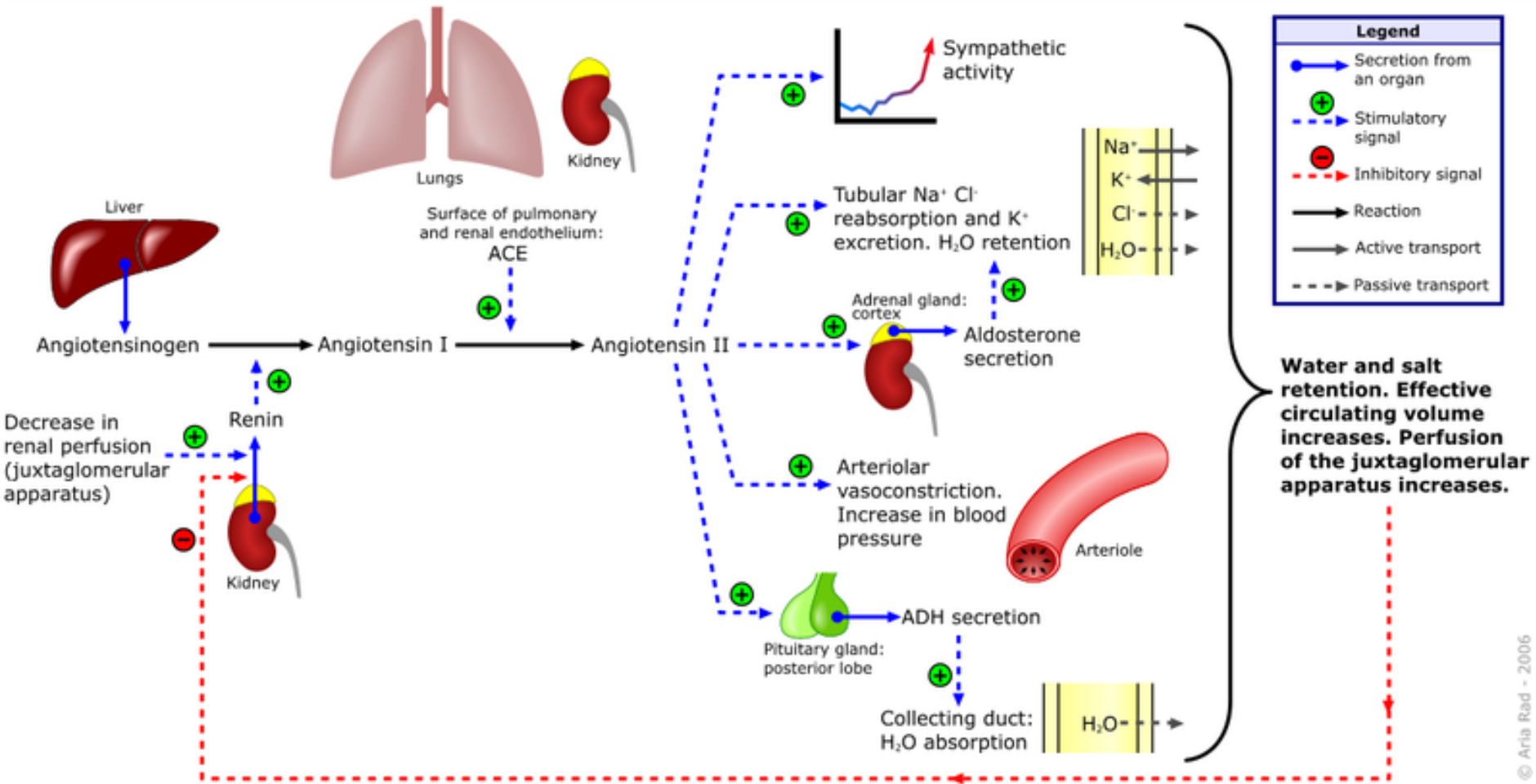
CARDIAC FACTORS

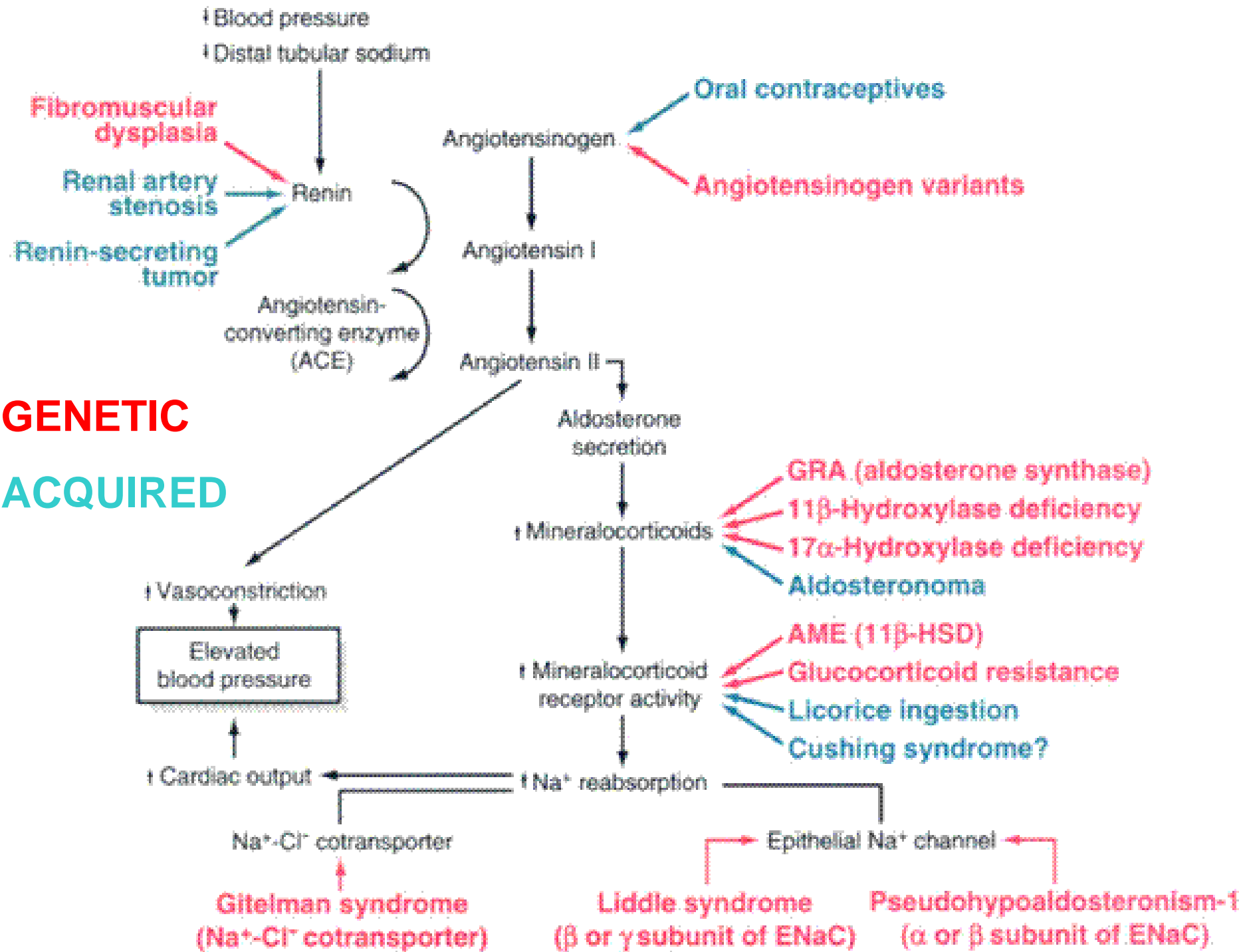
Heart rate
Contractility

Renin → Angiotensin → Aldosterone AXIS (RAAS)

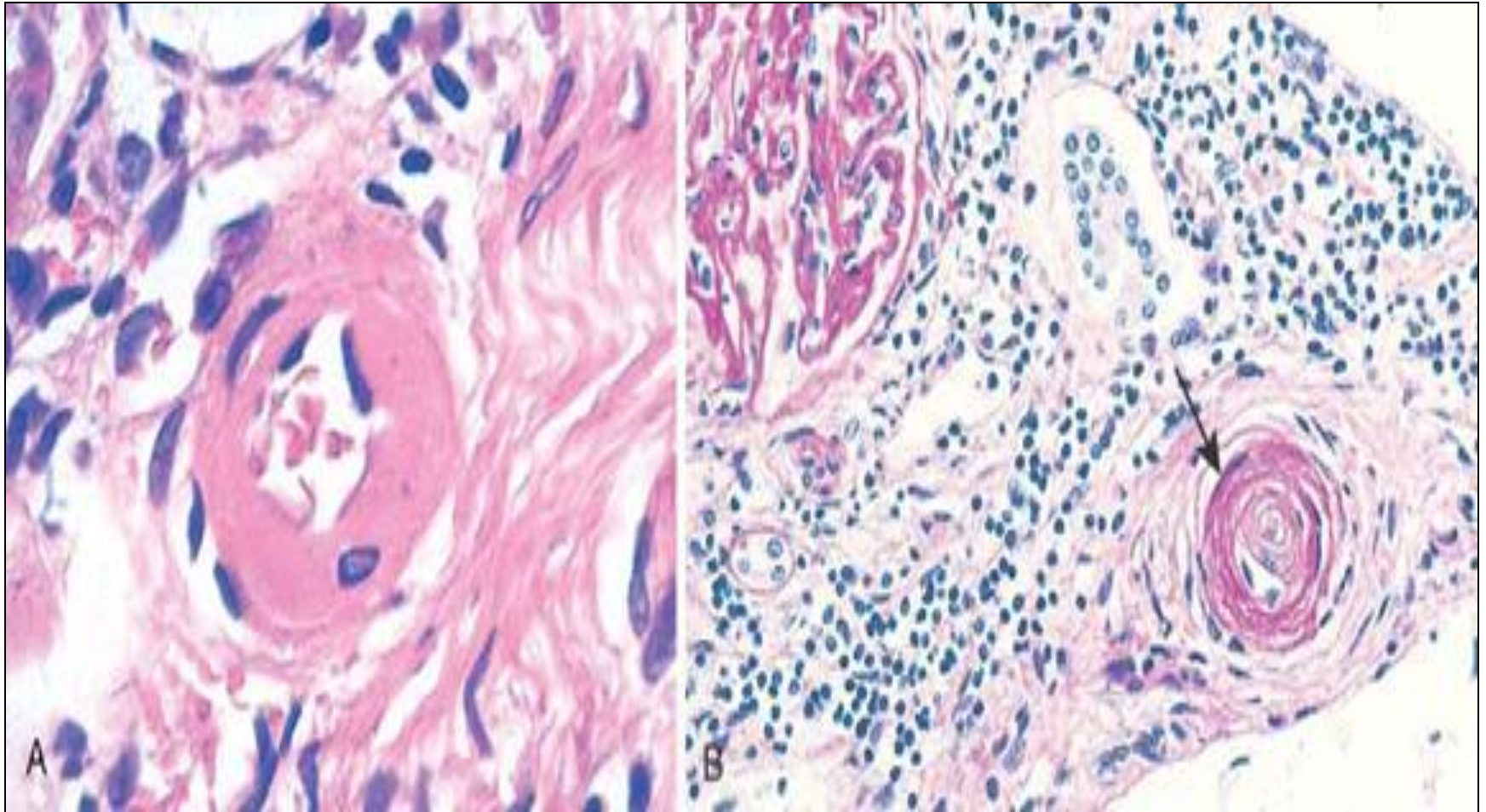
- If the perfusion of the juxtaglomerular apparatus in the kidneys decreases, then the juxtaglomerular cells release the enzyme renin.
- Renin cleaves an inactive peptide called angiotensinogen, converting it into angiotensin I.
- Angiotensin I is then converted to angiotensin II by angiotensin-converting enzyme (ACE), which is found mainly in lung capillaries.
- Angiotensin II is the major bioactive product of the renin-angiotensin system. Angiotensin II acts as an endocrine, autocrine/paracrine, and intracrine hormone.

Renin-angiotensin-aldosterone system





HISTOPATHOLOGY of ESSENTIAL HYPERTENSION



**“HYALINE” = BENIGN HTN. “HYPERPLASTIC” =
MALIGNANT HTN. SYS > 200**

1) ONION SKIN 2)

GENETIC


VS.

ENVIRONMENTAL


- GENETIC → UN-CONTROLLABLE
- ENVIRONMENTAL → CONTROLLABLE
 - STRESS
 - OBESITY
 - SMOKING
 - PHYSICAL ACTIVITY
 - NaCl INTAKE

ANEURYSMS

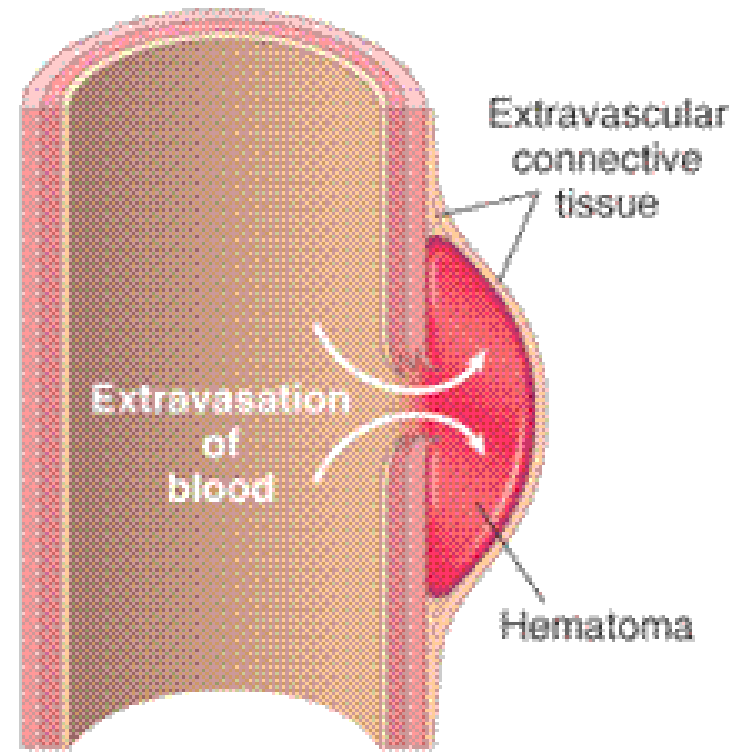
- TRUE vs. FALSE
- ATHEROSCLEROTIC
- NON-ATHEROSCLEROTIC
 - CONGENITAL
 - LUETIC (SYPHILITIC)
 - TRAUMATIC
 - “MYCOTIC” (MIS-leading term)
 - 2° to VASCULITIS
- SACULAR (i.e., “Berry”) vs. FUSIFORM
- DISSECTION vs. NON-DISSECTION



True aneurysm



Normal vessel



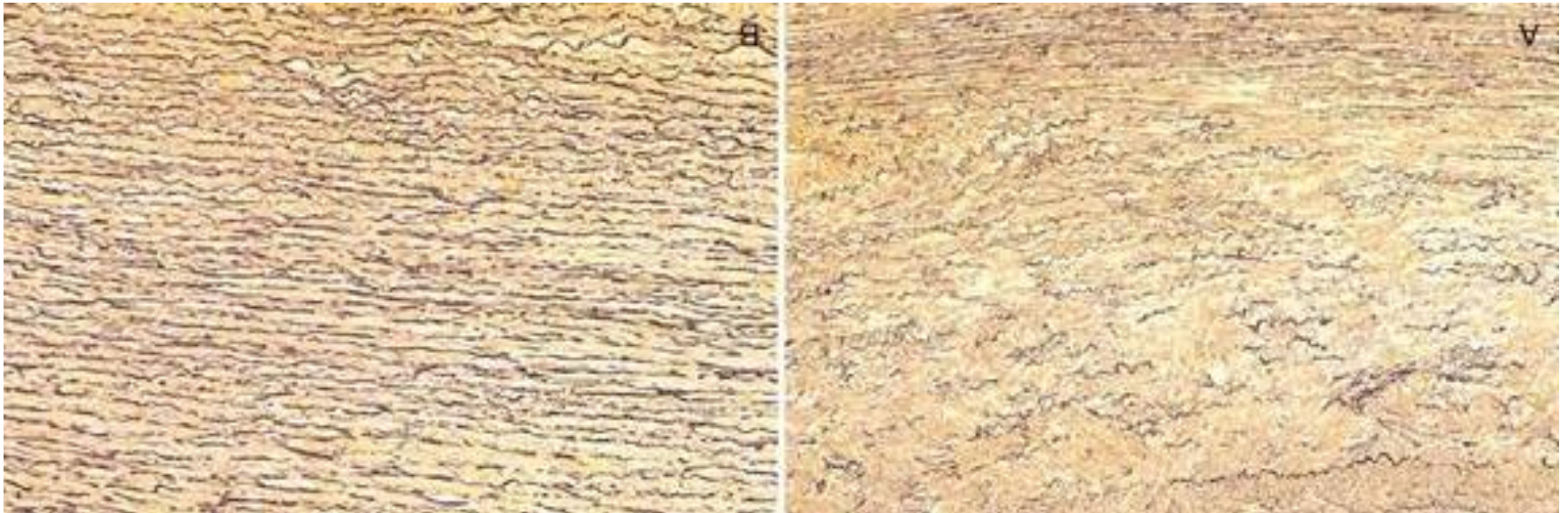
False aneurysm

ANEURYSMS

- 2 CAUSES:

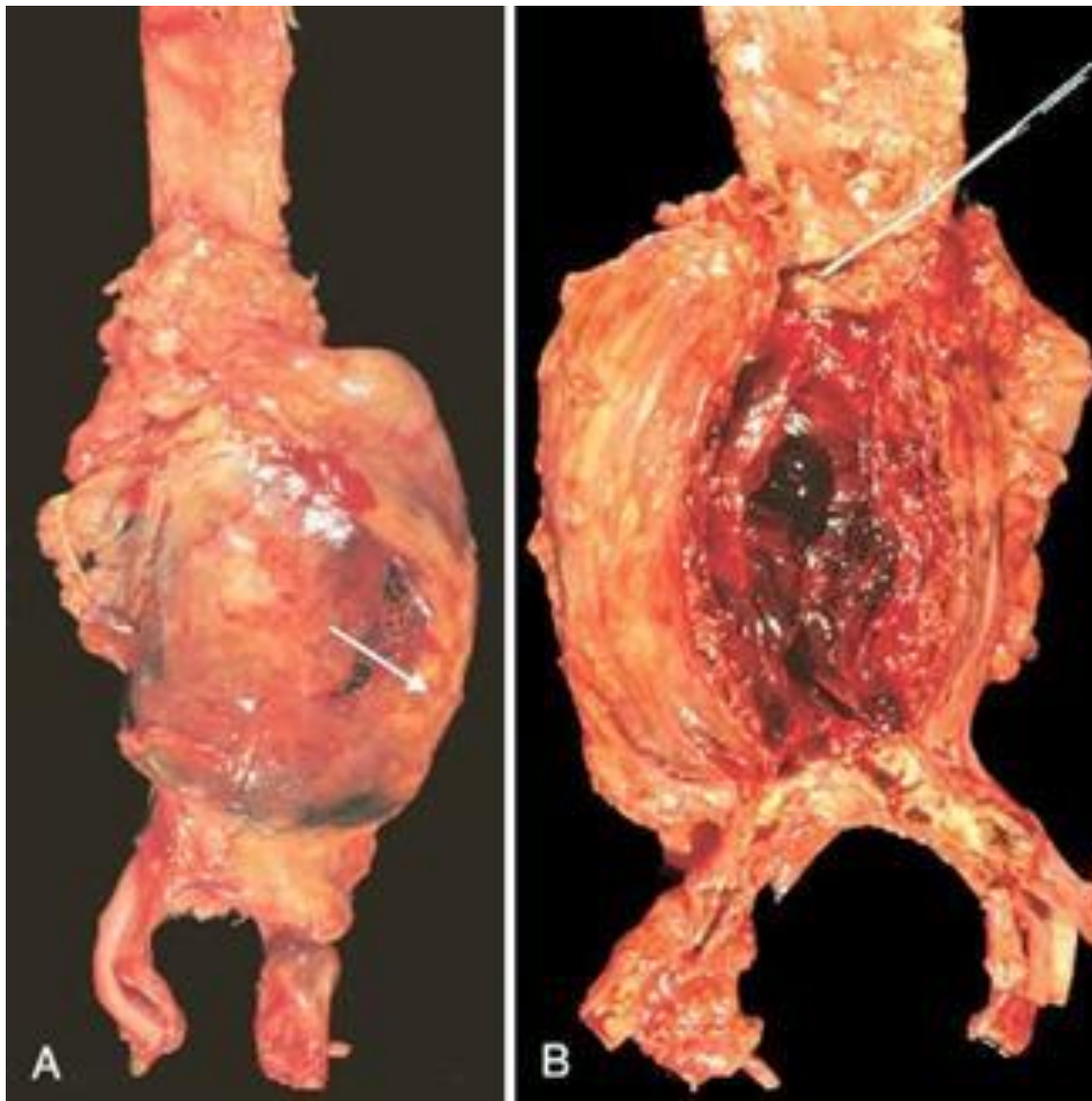
- 1) ATHEROSCLEROSIS

- 2) CYSTIC MEDIAL DEGENERATION (NECROSIS), can be familial



NORMAL elastic fibers

DISRUPTED, FRAGMENTED elastic fibers



Most abdominal aortic aneurysms (AAA) occur between the renal arteries and the bifurcation of the aorta

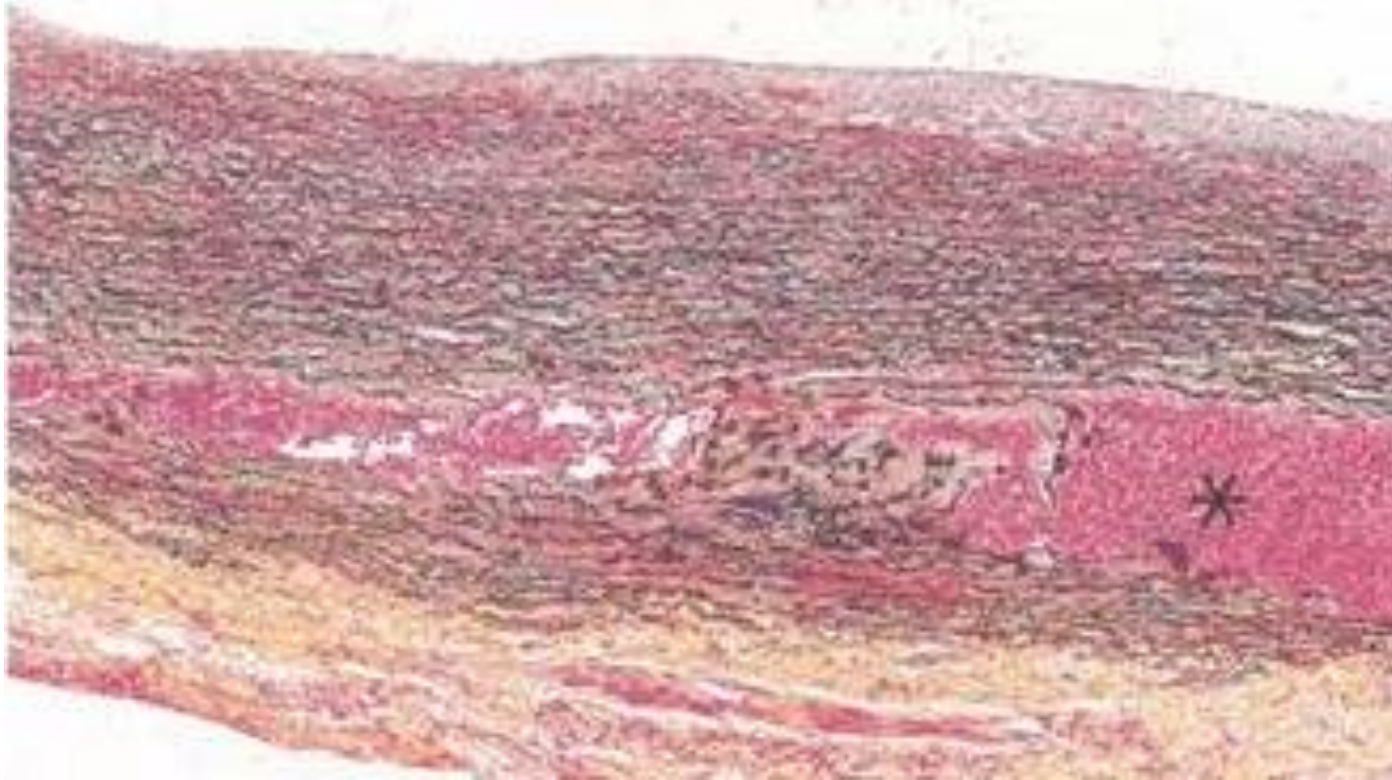
ANEURYSMS

(sequelae)

- RUPTURE
- OBSTRUCTION
- EMBOLISM
- COMPRESSION
 - URETER
 - SPINE
- MASS EFFECT

THORACIC ANEURYSMS

- **Encroachment**
- **Respiratory difficulties**
- **Dysphagia**
- **Cough**
- **Pain**
- **Aortic valve dilatation**
- **Rupture**



DISSECTION

ANEURYSMS

(luetic)

- **Chiefly thoracic**
- **Follows an AORTITIS**
 - **PLASMA CELLS predominate**

VASCULITIDES

- TEMPORAL “GIANT CELL” ARTERITIS
- TAKAYASU ARTERITIS
- POLY (PERI) ARTERITIS NODOSA
- KAWASAKI DISEASE
- WEGENER’S GRANULOMATOSIS
- THROMBOANGI(i)TIS OBLITERANS
(BUERGER[’s] DISEASE)
- OTHER
- INFECTIOUS

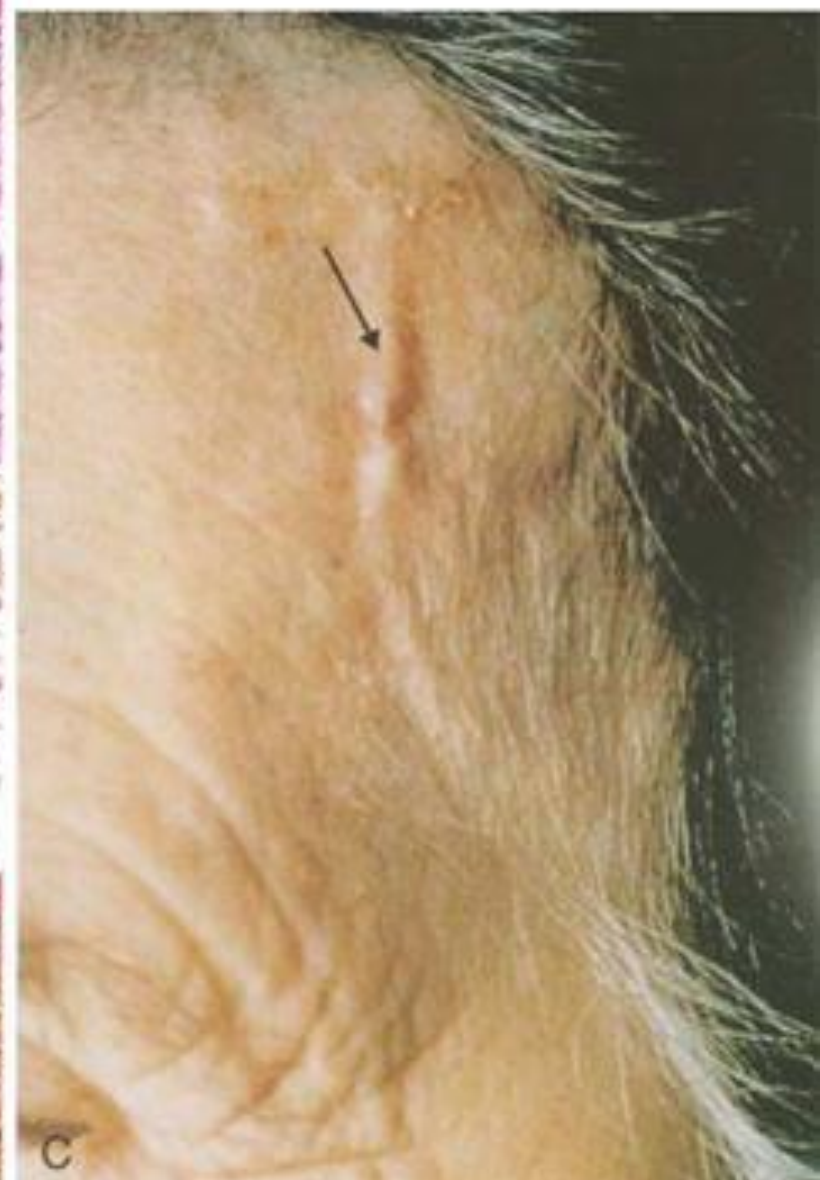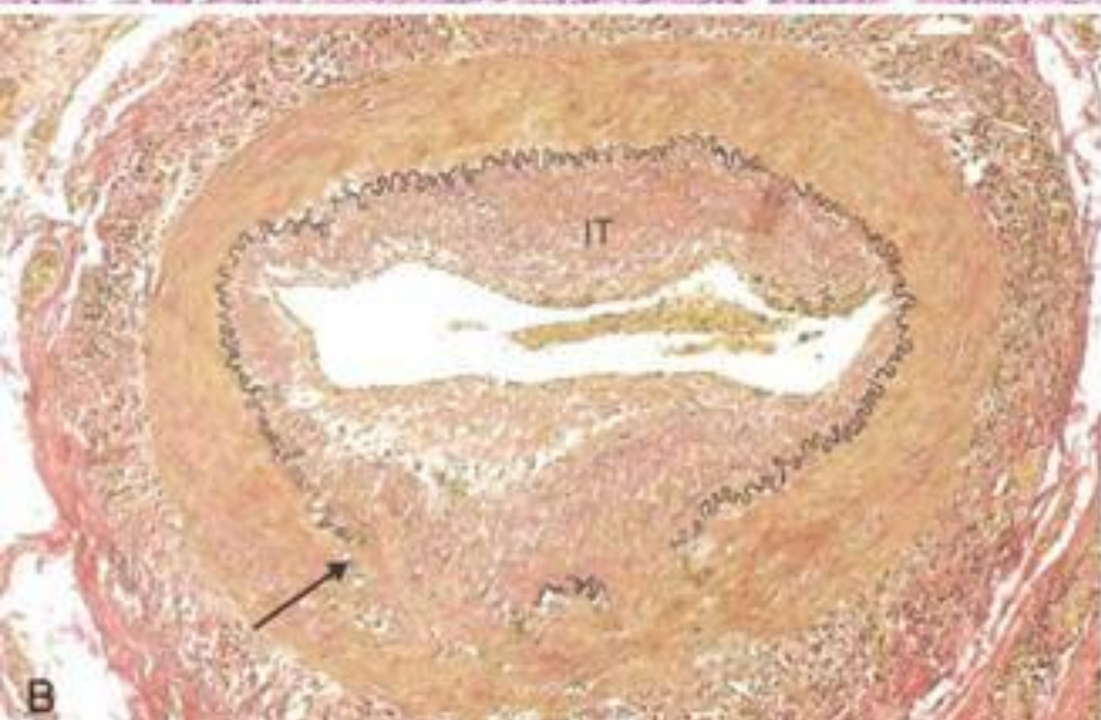
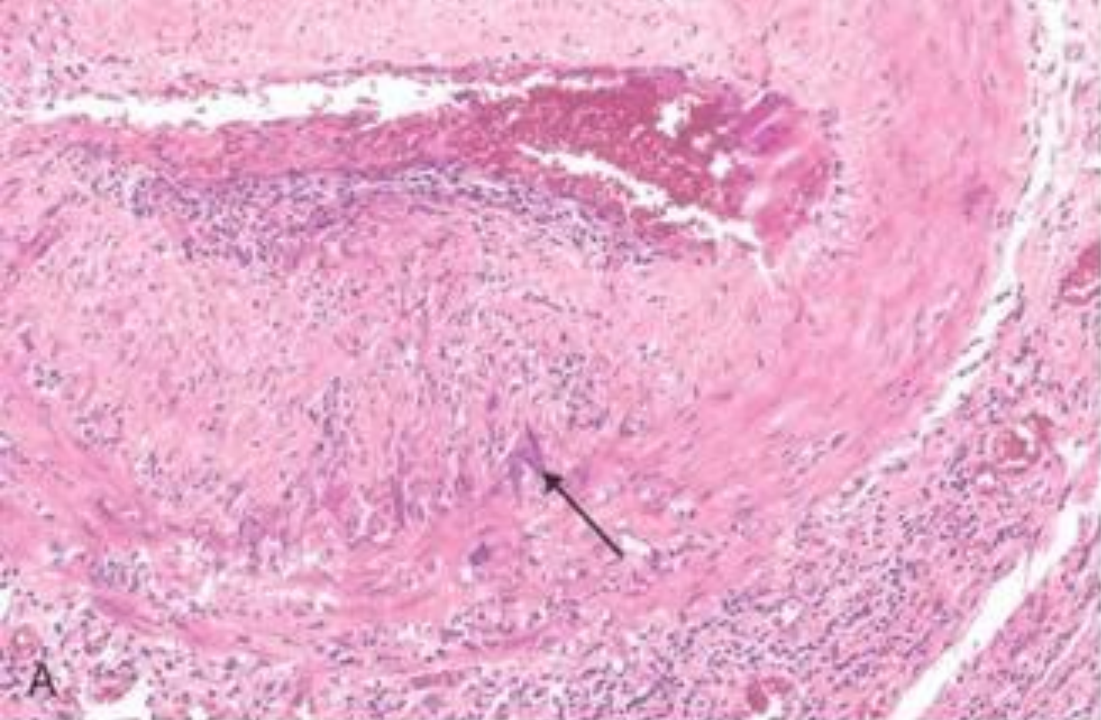
VASCULITIDES

- Chiefly arterial
- Infectious (5%) vs. Non-infectious (95%)
- NON-infectious are generally “AUTO”-IMMUNE. Why?
- Persistent findings:
 - Immune complexes
 - ANTI-NEUTROPHIL AB's (Wegener's, “Temporal”)
 - ANTI-ENDOTHELIAL CELL AB's (Kawasaki)
- Often DRUG related (Hypersensitivity, e.g.)

“TEMPORAL” ARTERITIS

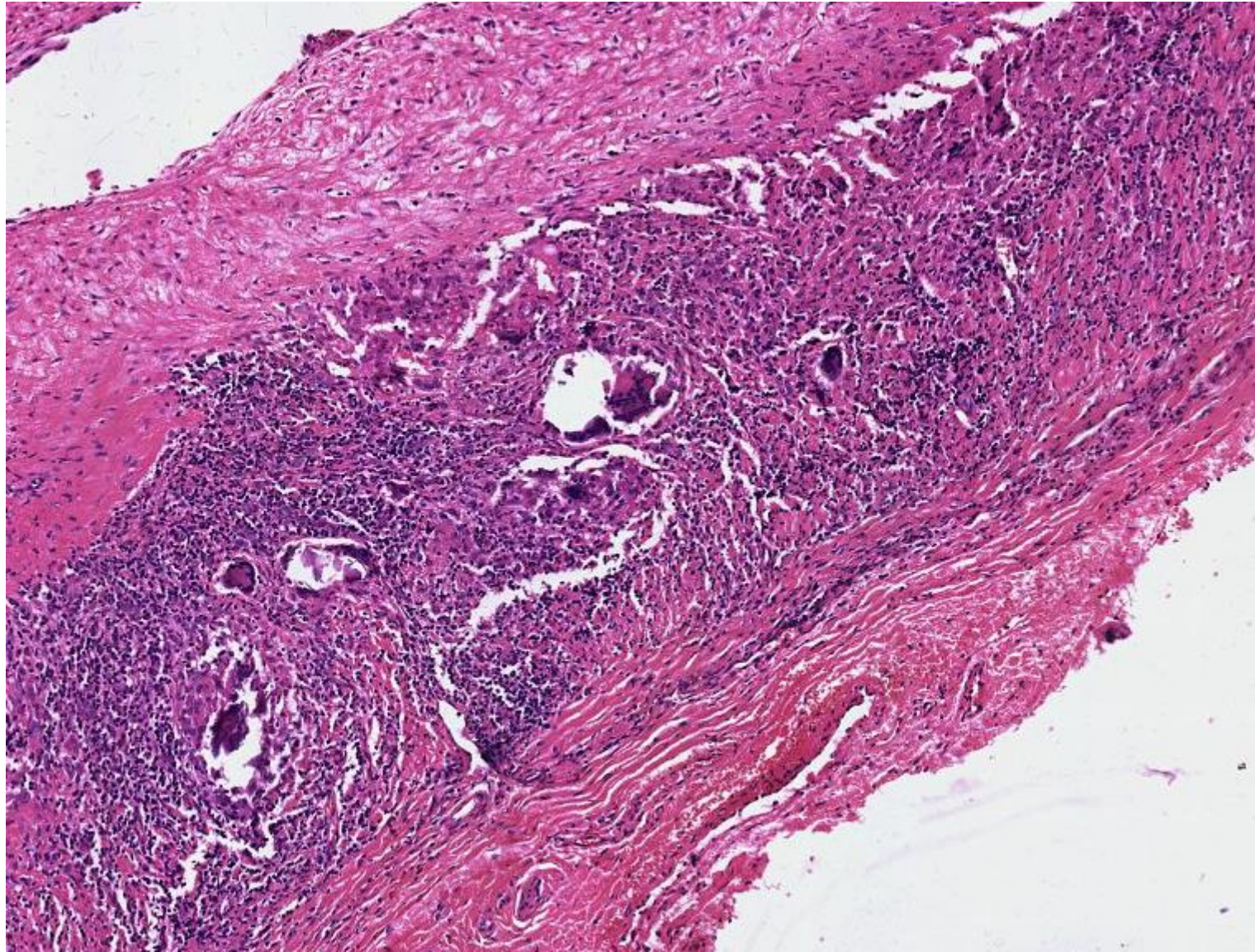
aka, Giant Cell Arteritis, GCA

- ADULTS
- Mainly arteries of the head and temporal arteries are the most visibly, palpably, and surgically accessible
- BLINDNESS most feared sequelae
- GRANULOMATOUS WALL inflammation diagnostic
- OFTEN associated with marked ESR elevation to be then known as POLYMYALGIA RHEUMATICA
- Anti-NEUTROPHIL AB's often POSITIVE



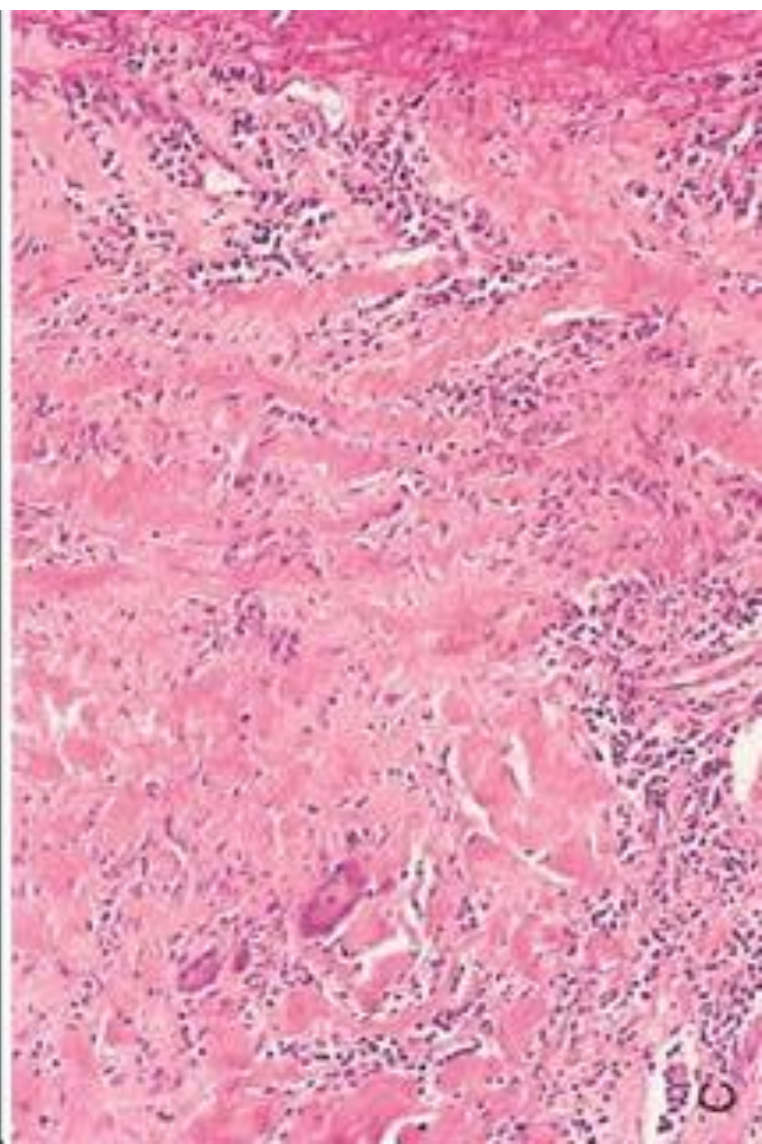
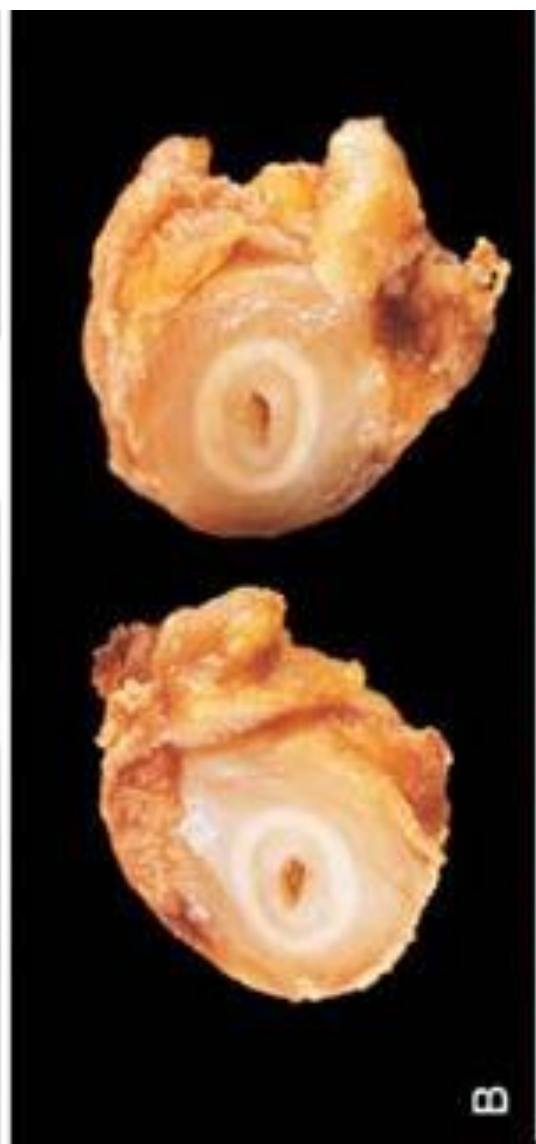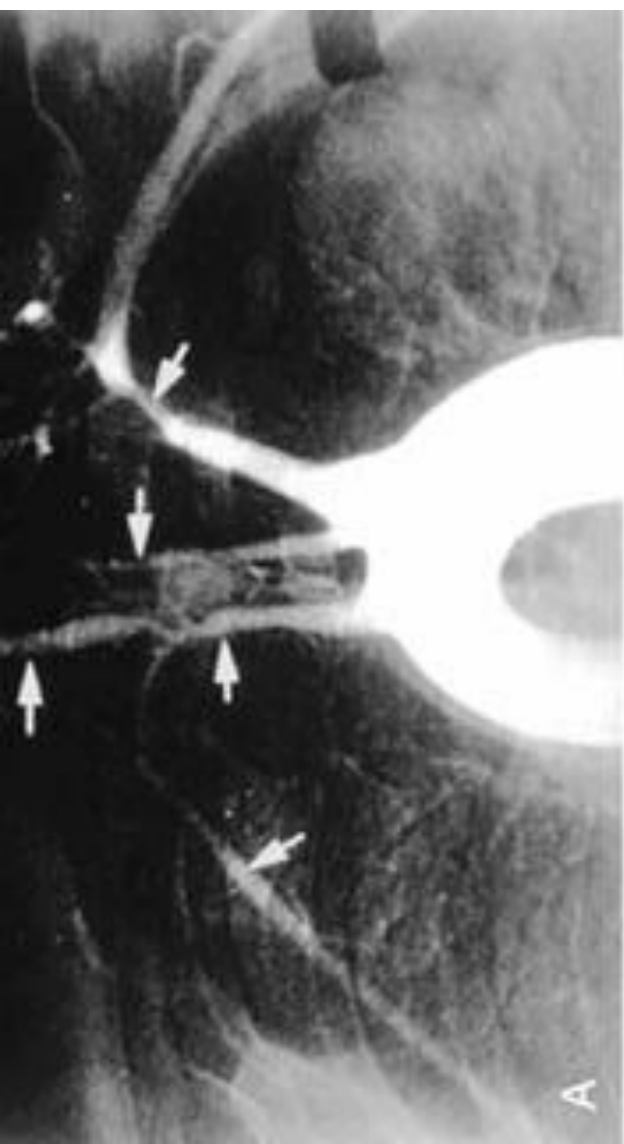TEMPORAL ARTERITIS

http://www.path.uiowa.edu/cgi-bin/pub/vs/fpx_gen.cgi?slide=623&viewer=java&view=0&lay=iowa



TAKAYASU ARTERITIS

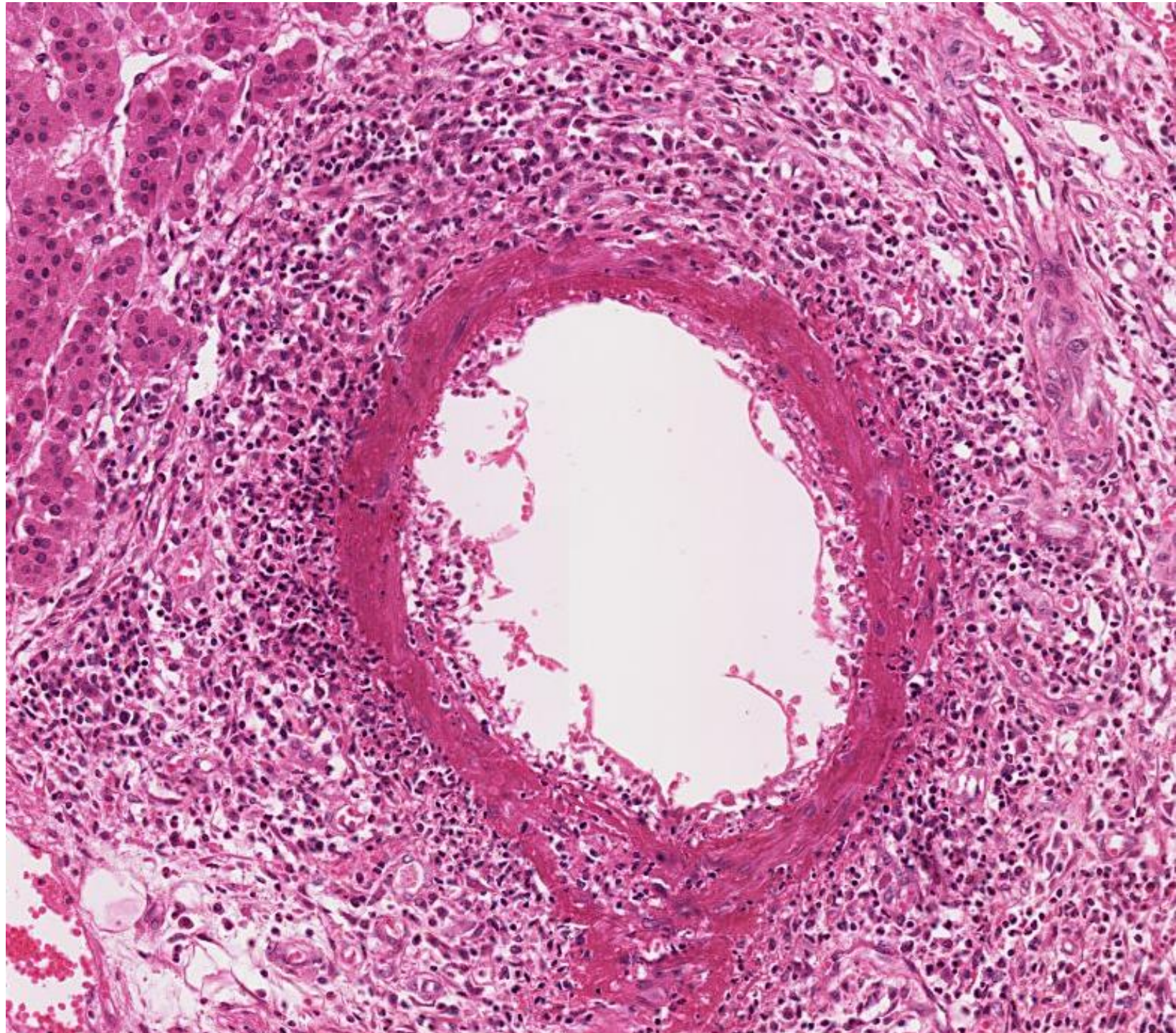
- Involves aortic arch and other heavily elastic arteries, i.e., chief thoracic aorta branches, most commonly young Asian women
- FEMALES <40
- “PULSELESS” disease
- NECROSIS, Giant Cells also



POLY-(Peri-) ARTERITIS NODOSA (PAN)

- ANY MEDIUM or SMALL artery
- OFTEN visceral arteries
- Infarcts, aneurysms, ischemia
- CLASSICAL AUTOIMMUNE disease
- SEGMENTAL, TRANSMURAL, NECROTIZING (fibrinoid) inflammation

http://www.path.uiowa.edu/cgi-bin/pub/vs/fpx_gen.cgi?slide=584&viewer=java&view=0&lay=iowa



KAWASAKI DISEASE

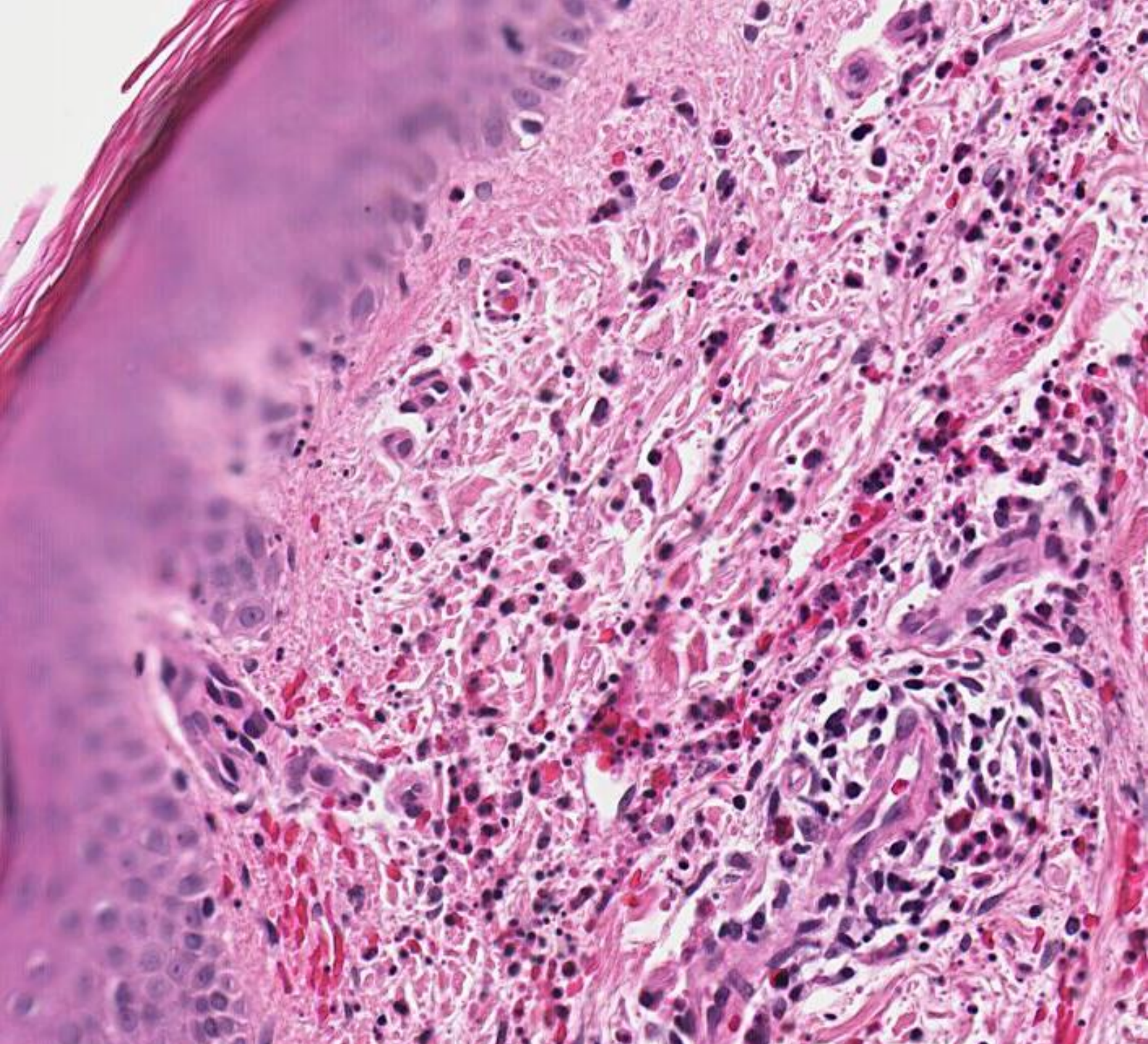
- CHILDREN <4
- CORONARY ARTERIES
- LEADING cause of ACQUIRED heart disease in children
- USA and JAPAN
- Fatal in only 1%

MICROSCOPIC POLYANGIITIS

HYPERSENSITIVITY VASCULITIS

LEUKOCYTOCLASTIC VASCULITIS

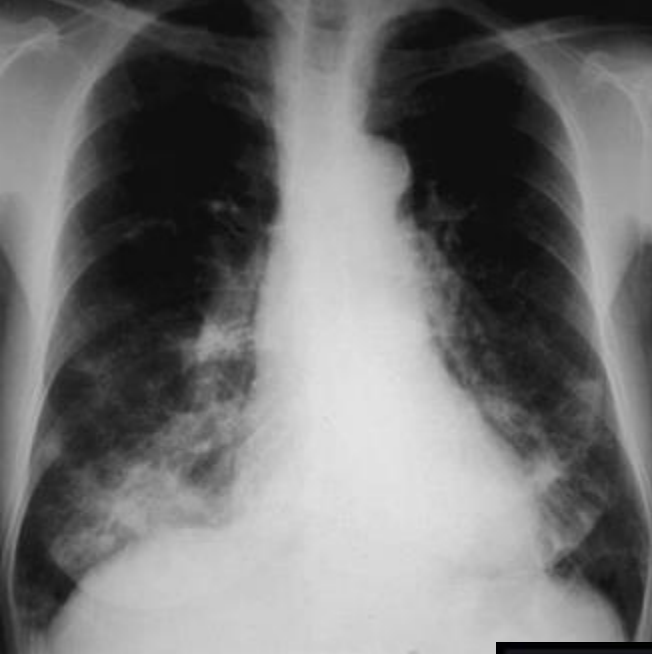- **SMALL** VESSELS OF ALL TYPES, e.g., capillaries and veins too
- **FRAGMENTED NEUTROPHILS**
 - aka, LEUKOCYTOCLASIA
 - aka, NUCLEAR “DUST”
 - Most are ALLERGIC reactions to allergens like penicillin or strep
 - DERMATOLOGIST’S DISEASE



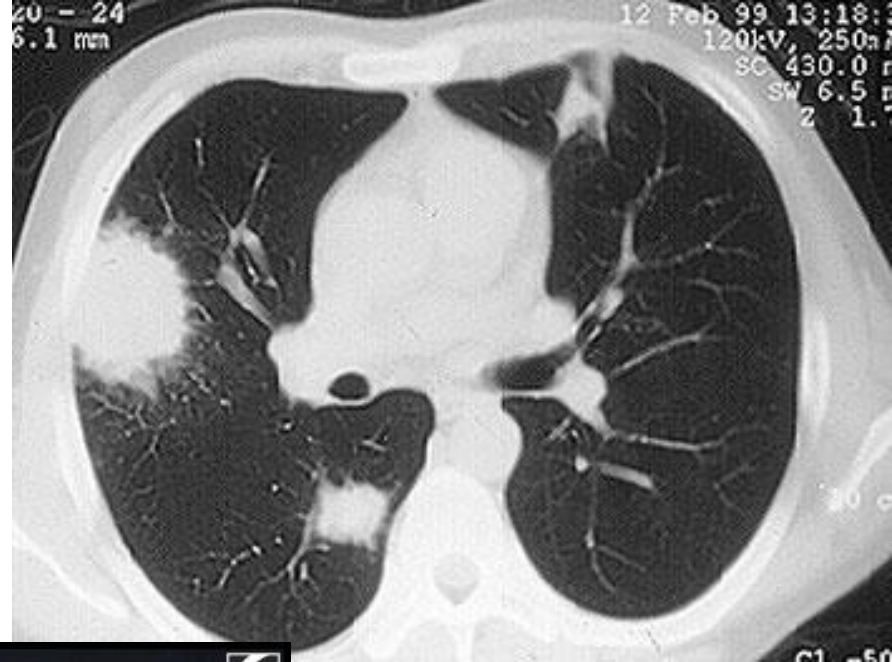
http://www.path.uiova.edu/cgi-bin/pub/vs/fpx_gen.cgi?slide=634&viewer=java&view=0&lay=iowa

WEGENER GRANULOMATOSIS

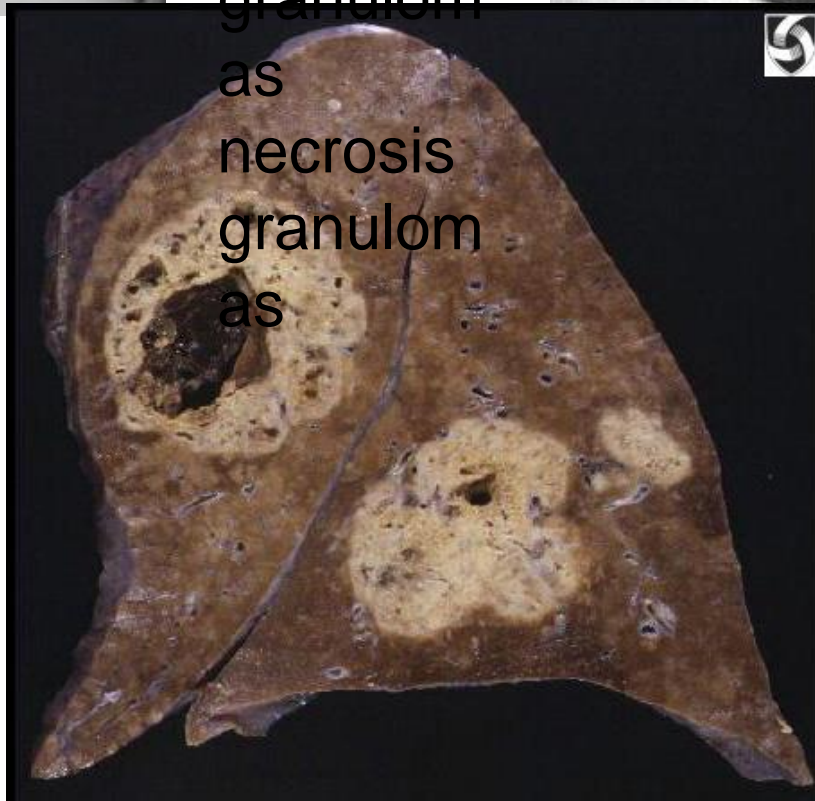
- M>F, often in 40's
- ACUTE NECROTIZING GRANULOMAS OF UPPER an LOWER respiratory tract
- NECROTIZING GRANULOMATOUS VASCULITIS of SMALL vessels of ALL types
- Often renal involvement, “crescentic” glomerulonephritis
- ANTI-NEUTROPHIL-CYTOPLASMIC-AB's usually present



necrosis
granulom
as
necrosis
granulom
as
necrosis
granulom
as



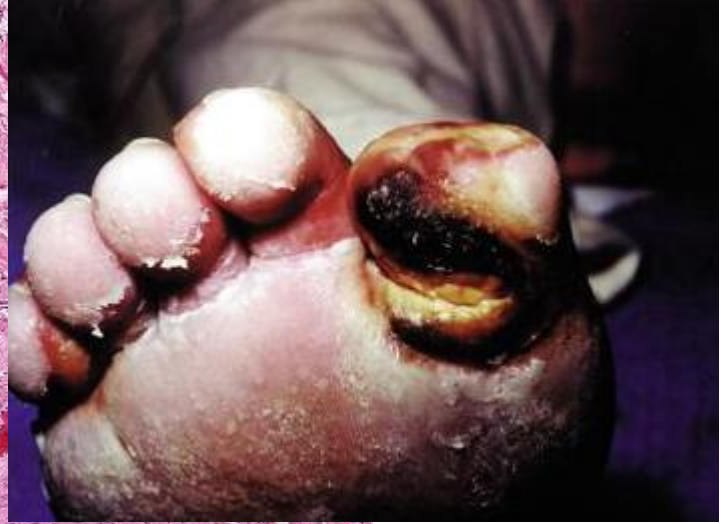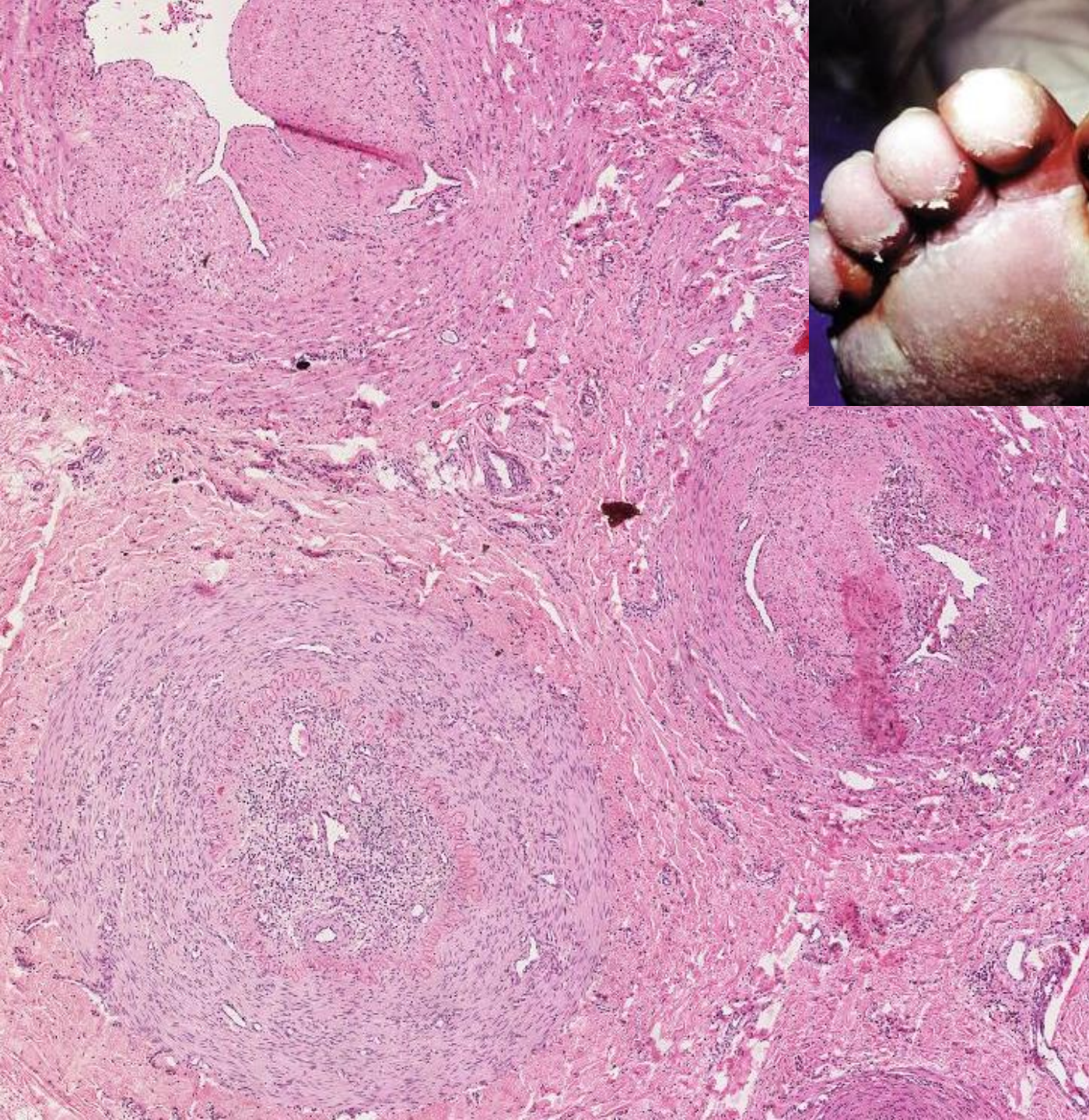
necrosis
granuloma
s
necrosis
granuloma
s
necrosis
granuloma
s



necrosis
granuloma
s
necrosis
granuloma
s
necrosis
granuloma

THROMBOANGIITIS OBLITERANS BUERGER('s) Disease

- 100% caused by cigarette smoking
- MEN>>>F, 30's, 40's
- Often arteries are 100% obliterated, hence the name "obliterans"
- EXTREMITIES most often involved



[http://www.pat
h.uiowa.edu/c
gi-bin-
pub/vs/fpx_ge
n.cgi?slide=7
04&viewer=ja
va&view=0&la
y=iowa](http://www.path.uiowa.edu/cgi-bin-pub/vs/fpx_general.cgi?slide=704&viewer=java&view=0&lay=iowa)

OTHER VASCULITIDES

- SLE

- RHEUMATOID ARTHRITIS

INFECTIOUS ARTERITIDES

- ASPERGILLIS
- MUCORMYCOSIS
- “MYCOTIC” ANEURYSMS

NON ATHEROSCLEROSIS VASCULAR DISEASES

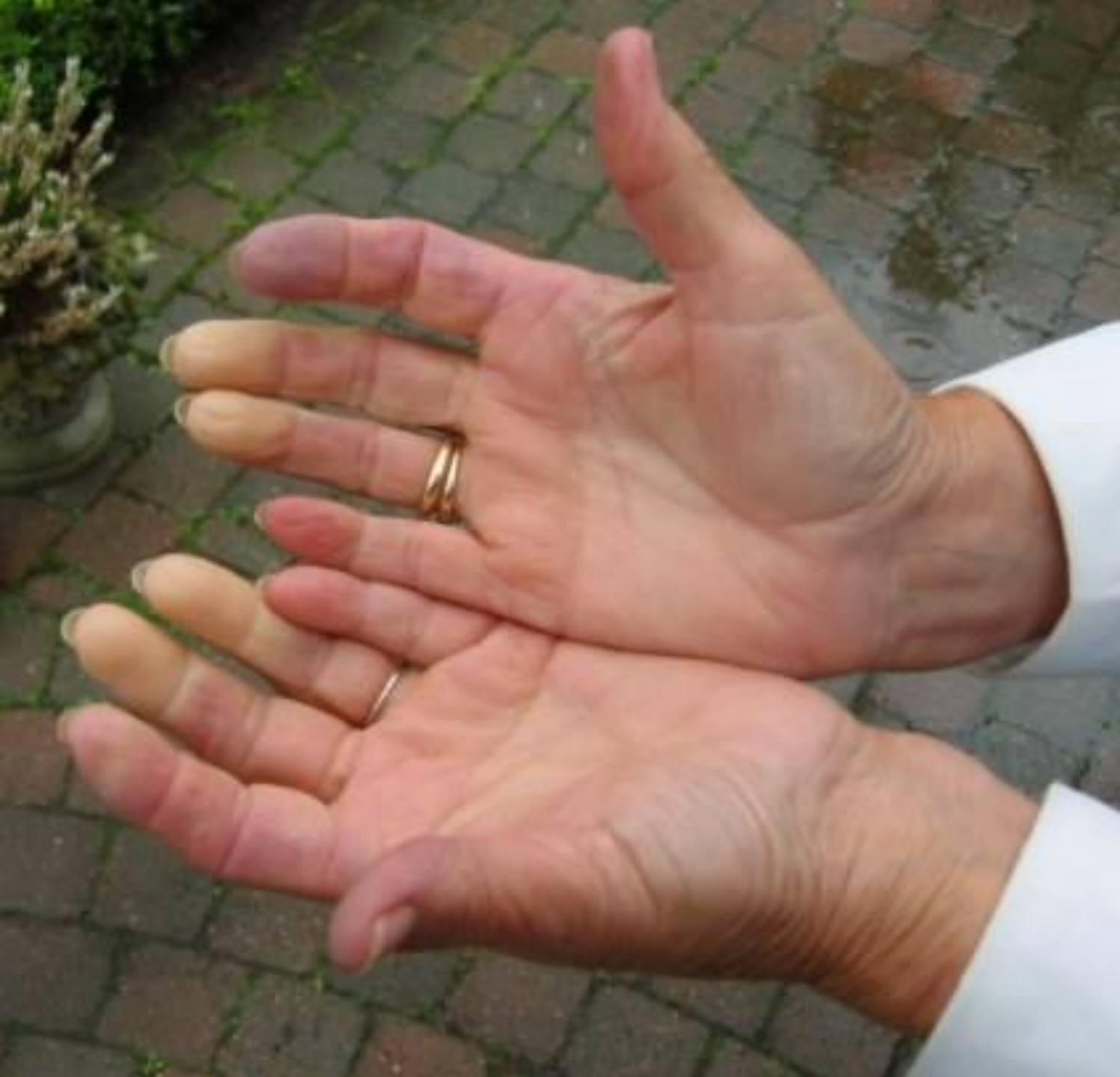- **HYPERTENSION**
- **ANEURYSMS**
- **VASCULITIDES**
- **VEIN DISORDERS**
- **NEOPLASMS**

FINAL TOPICS

- Raynaud Phenomenon
- Veins and Lymphatics
 - Varicosities
 - Thrombophlebitis/Phlebothrombosis
 - SVC/IVC syndromes
 - Lymphangitis
 - Lymphedema
- Tumors: Benign, Intermediate (Borderline), Malignant
- Vascular Interventions: Angioplasty, Stents, Grafts

Raynaud “Phenomenon”

- **PRIMARY: (formerly Raynaud “DISEASE”)**
 - Digital PALLOR→CYANOSIS→HYPEREMIA
 - (WHITE)→ (BLUE)→ (RED)
 - Vasoconstriction usually triggered by COLD, emotion
 - Can be tip of nose, not only digits
 - Self Limited, Gangrene UN-common
 - Arteries often do NOT show diagnostic pathology
- **SECONDARY: (formerly Raynaud “Phenomen.”)**
 - Atherosclerosos
 - SLE
 - Buerger Disease

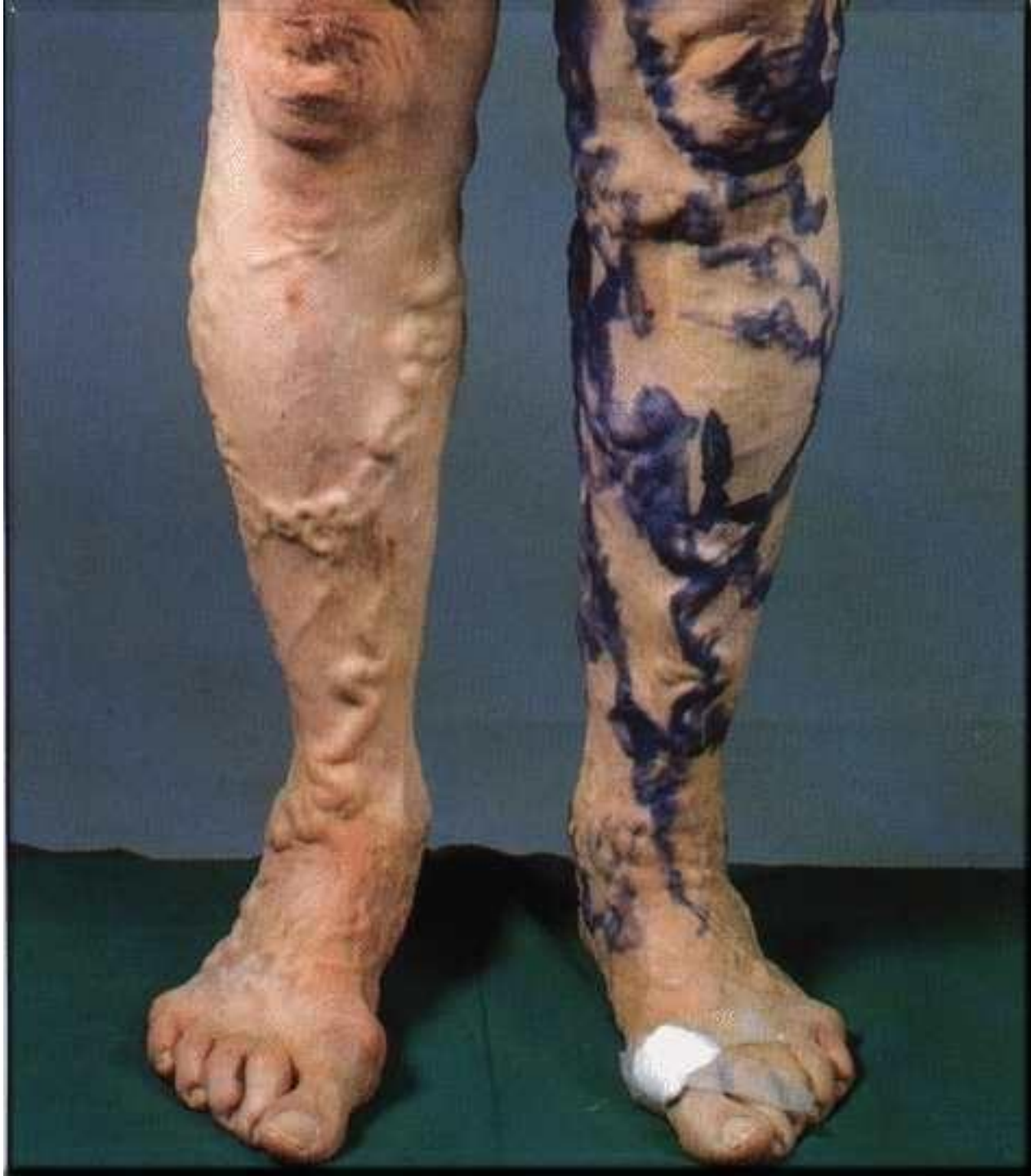

BLUE→

RED

“Varicose” Veins

- 20% of population, F>M
- Related to increased venous pressure, age, valve dysfunction
- Superficial veins of lower extremities most common
- PATH: 1) DILATED, 2) TORTUOUS, 3) ELONGATED, 4) SCARRED (phlebosclerosis), 5) CALCIFICATIONS, 6) NON-UNIFORM SMOOTH MUSCLE
- Conceptually like varices or hemorrhoids

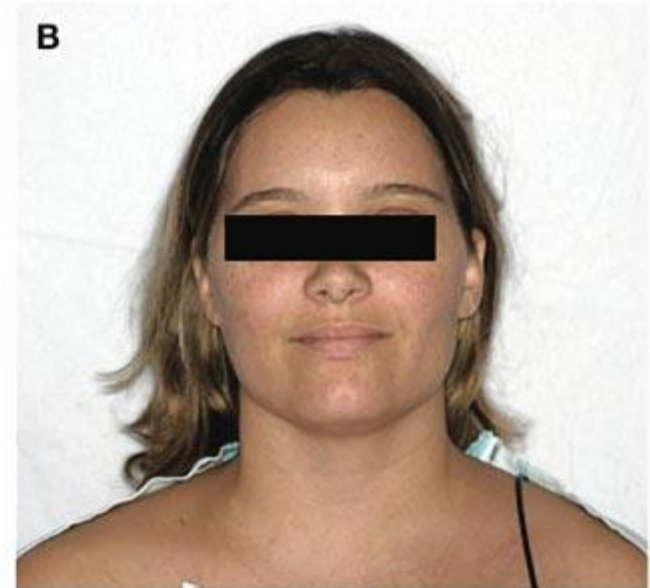
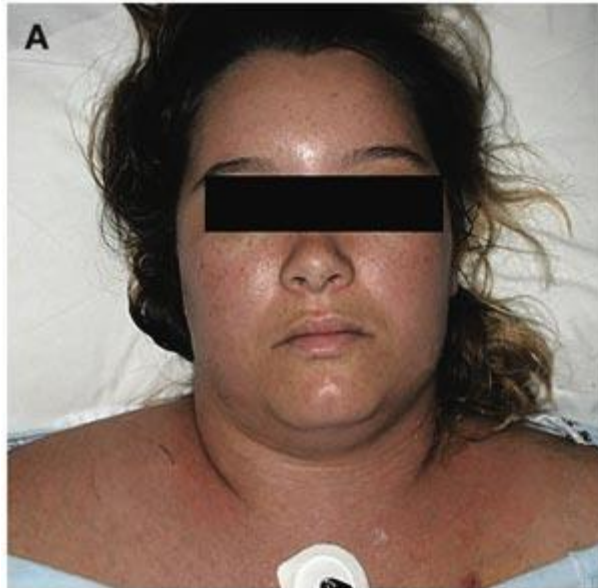
THROMBOPHLEBITIS

- 90% DEEP veins of the legs
- IDENTICAL to PHLEBOTHROMBOSIS
- Factors: CHF, Neoplasia (esp. GI, panc. Lung adenocarcinomas “migratory” thrombophlebitis), pregnancy, obesity, post-op, immobilization, or any of the parts of Virchow’s triangle
- Sequelae: PE most feared
- Symptoms: edema, cyanosis, heat, pain, tenderness, but usually.....NONE!!!

SVC SYNDROME

- Usually from bronchogenic CA or mediastinal lymphoma
- “DUSKY CYANOSIS” of:
 - Head
 - Neck
 - Arms

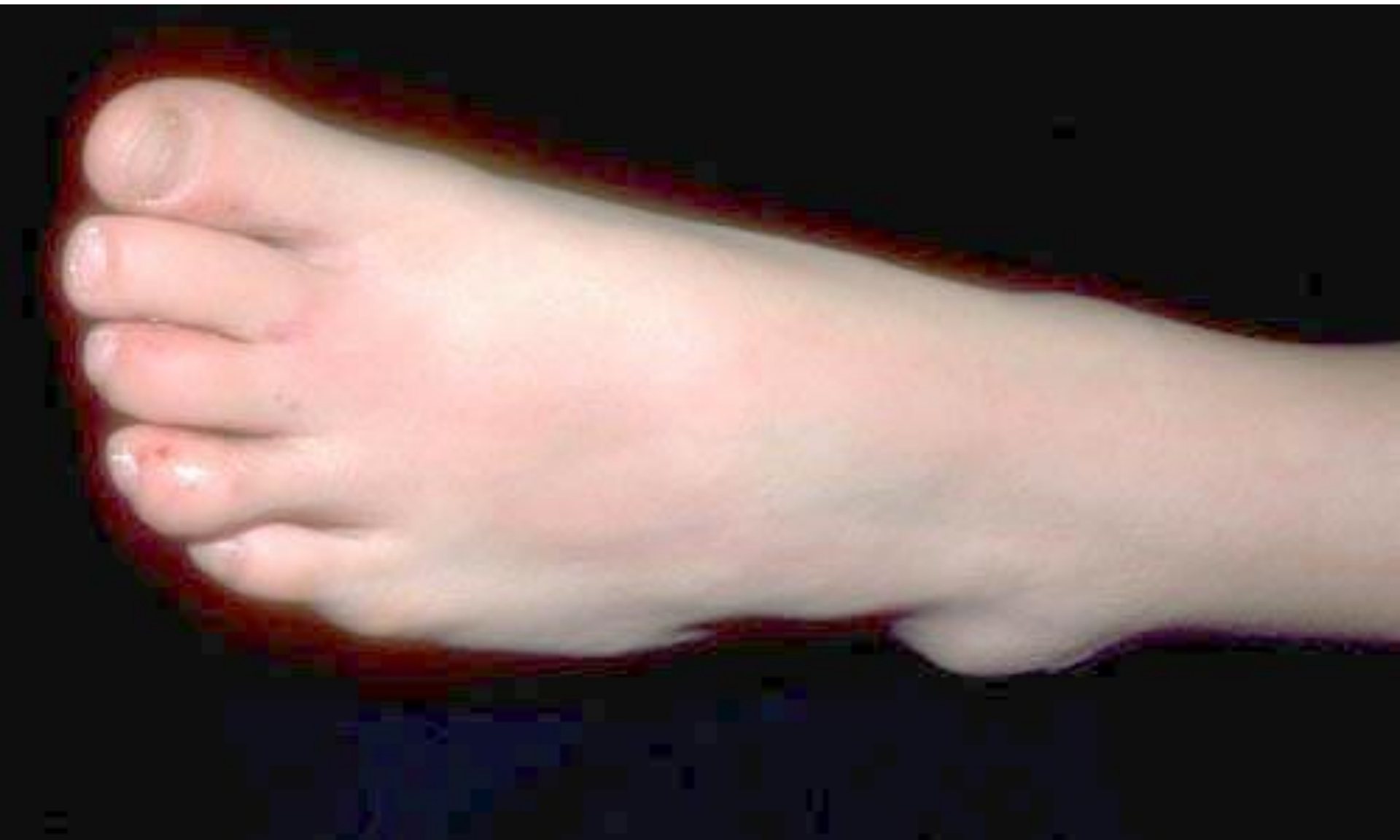

IVC SYNDROME

- Secondary to:
 - NEOPLASMS (external compression)
 - ASCENDING THROMBOSIS from FEMORALS, ILIACS
 - AAA, Gravid uterus
- Bilateral leg edema
- Massive proteinuria if renal veins involved (like nephrotic syndrome)

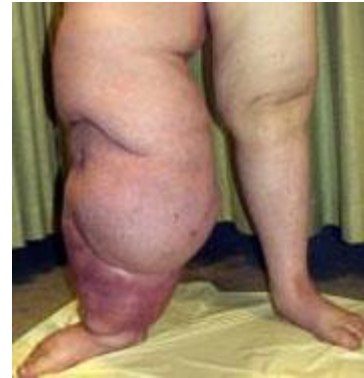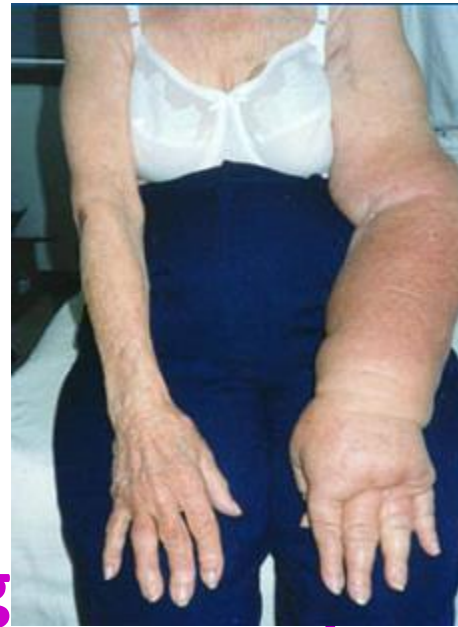LYMPHANGITIS

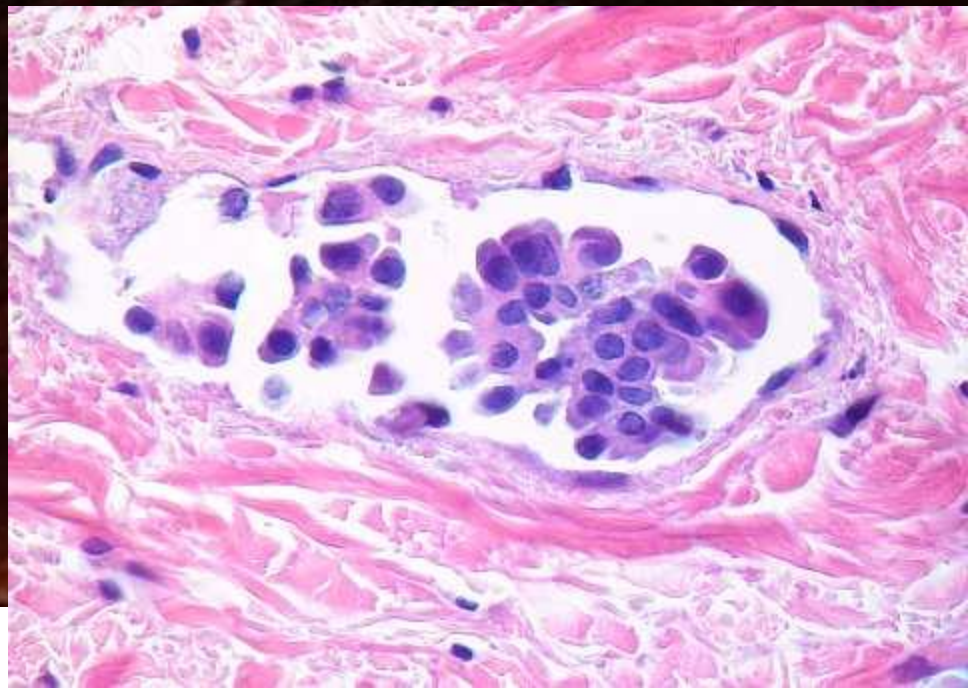
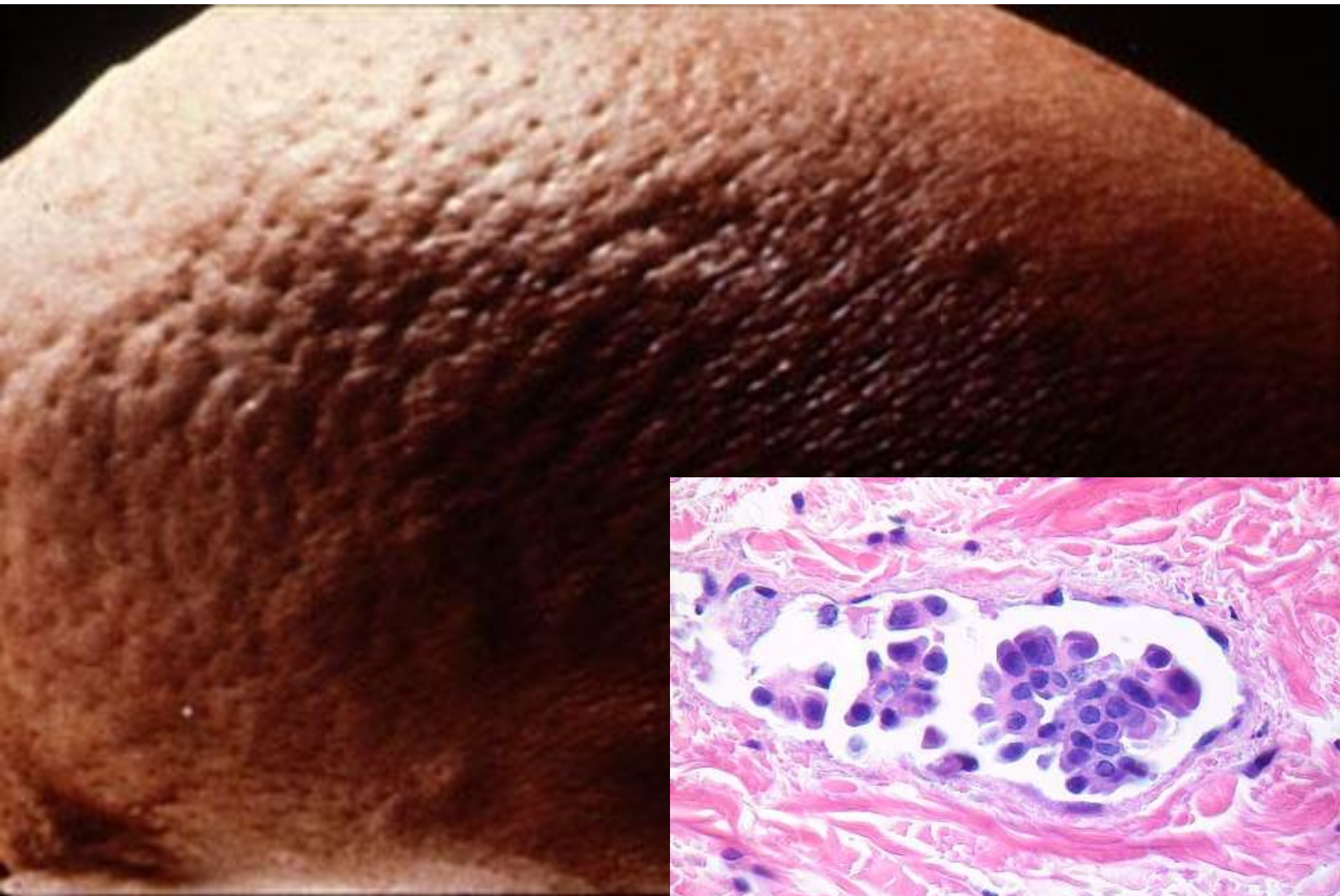
- From regional infections
- Group-A beta-hemolytic strep most common
- Lymphatics dilated, filled with WBCs
- Cellulitis usually present too
- Lymphadenitis also usually follows
- If lymph nodes cannot filter (process) antigens enough →
septicemia



LYMPHEDEMA

- Lymphatic channels blocked or scarred or absent:
 - Post surgical
 - Post radiation
 - Filariasis
 - Congenital
 - Tumoral (peau d'orange)





CHYLE

- CHYLOUS ASCITES
- CHYLOTHORAX
- CHYLOPERICARDIUM



Vascular TUMORS

- **BENIGN** (NEVER metastasize, in fact some are not even TRUE neoplasms, but hamartomas)
- **INTERMEDIATE** (rarely metastasize)
- **MALIGNANT** (FREQUENT and EARLY metastases, like any other sarcoma → lung)

BENIGN-----→MALIGNANT

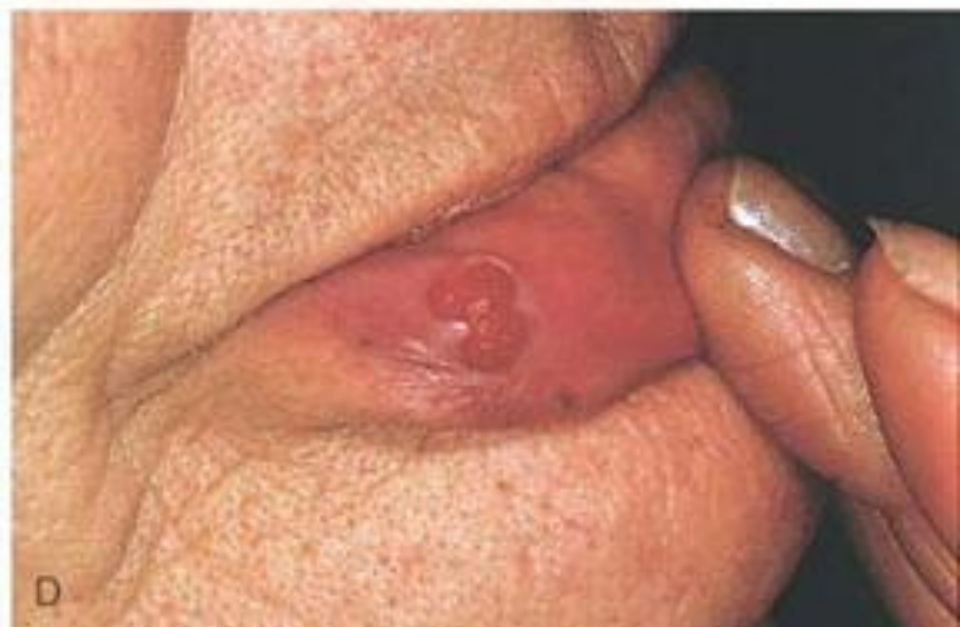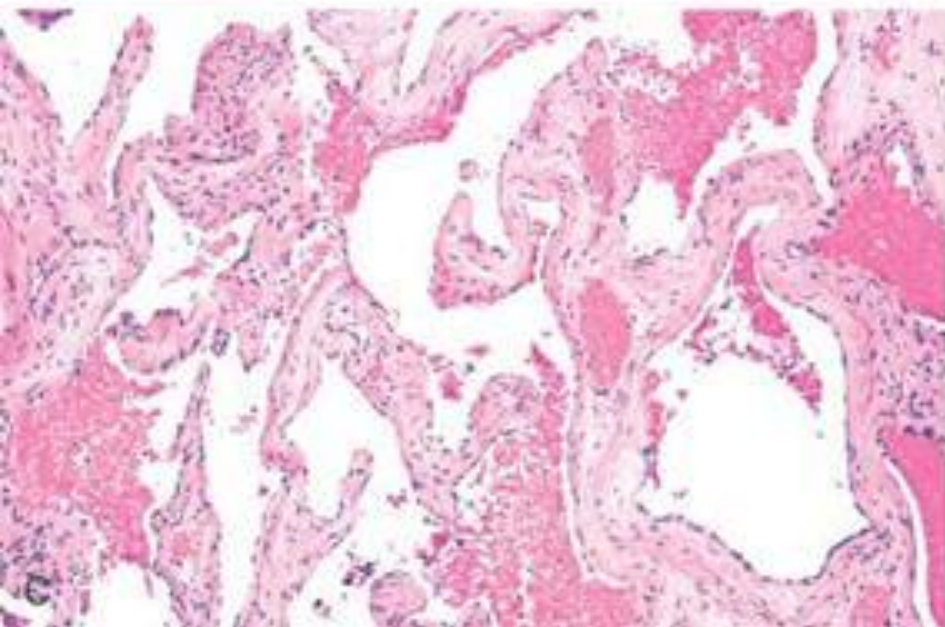
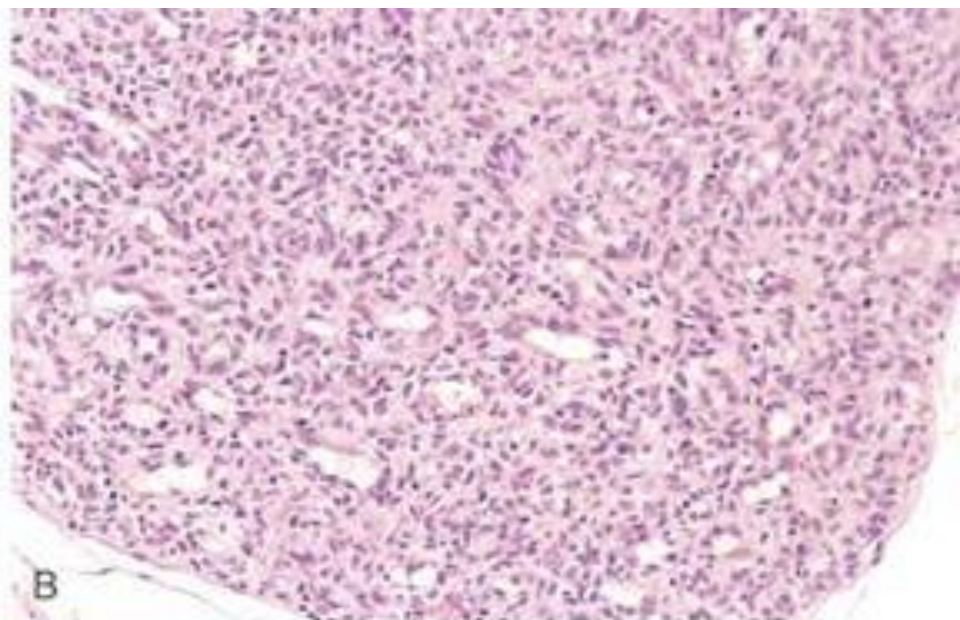
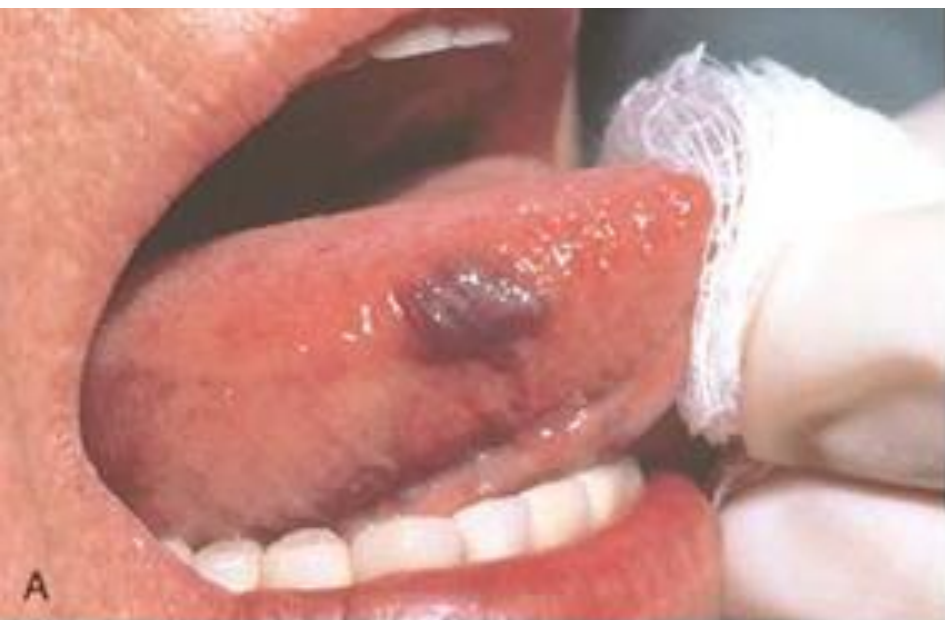Rare mitosis-----→Common mitosis

Mild, rare atypia-----→Frequent, severe atypia

**NO mets-----→Early, frequent mets
via BLOODSTREAM**

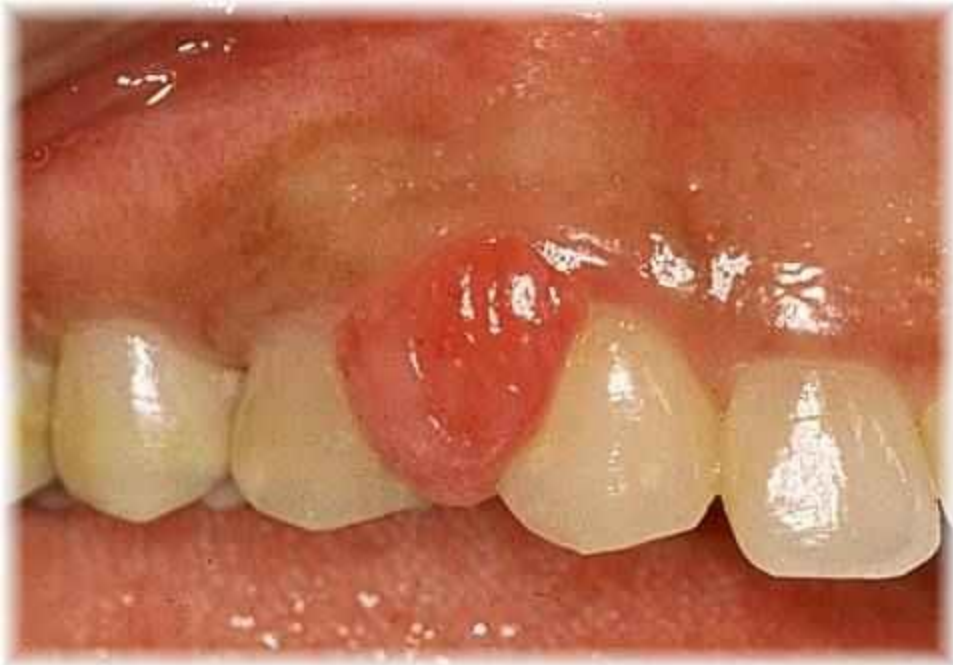HEMANGIOMA

- Often a generic term for ANY benign blood vessel tumor
- **CAPILLARY** (small vascular spaces)
 - Also called “juvenile”, often called “birth marks”
 - Usually regress with age
- **CAVERNOUS** (LARGE vascular spaces)
 - Also called “adult”
 - Usually do NOT regress



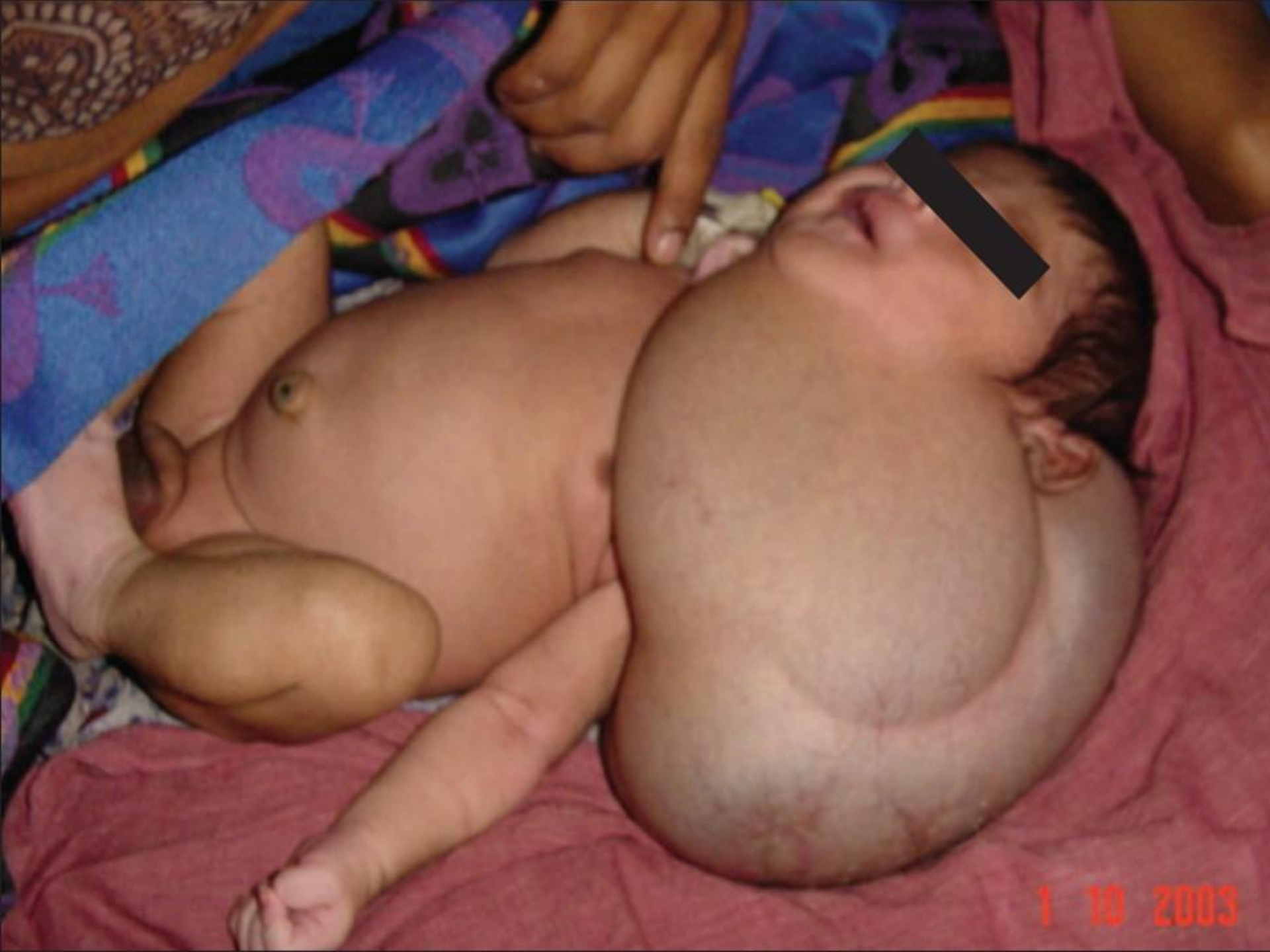PYOGENIC GRANULOMA

- ORAL CAVITY MOST COMMON
- Histology like capillary hemangioma
- Regress
- Indistinguishable from normal **granulation tissue**



LYMPHANGIOMA

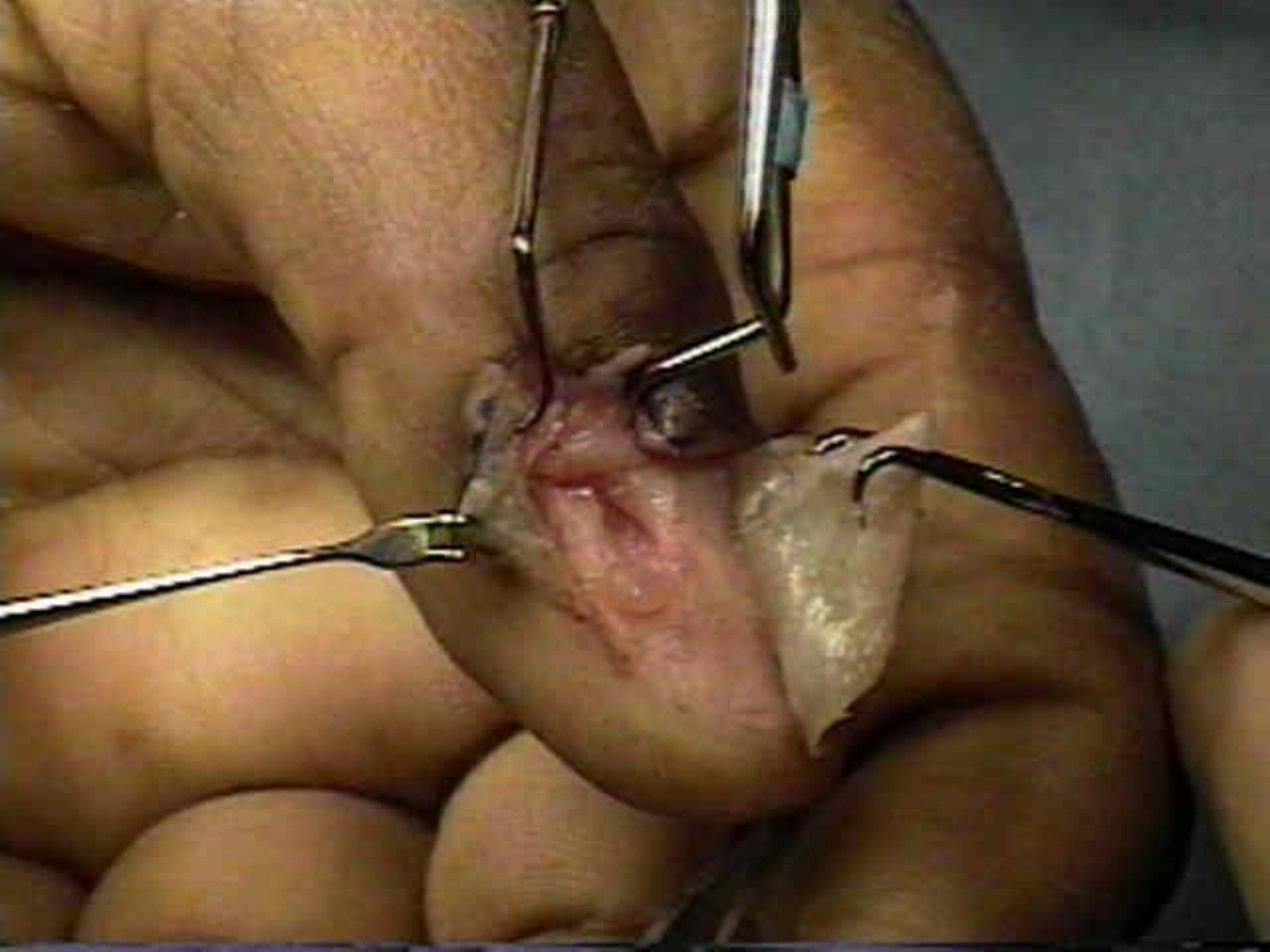- **Small 1-2 mm**
- **90% Head and neck region in kids <2**
- **Generally.....RARE**
- **When large size and/or spaces present often called “CYSTIC HYGROMA”**

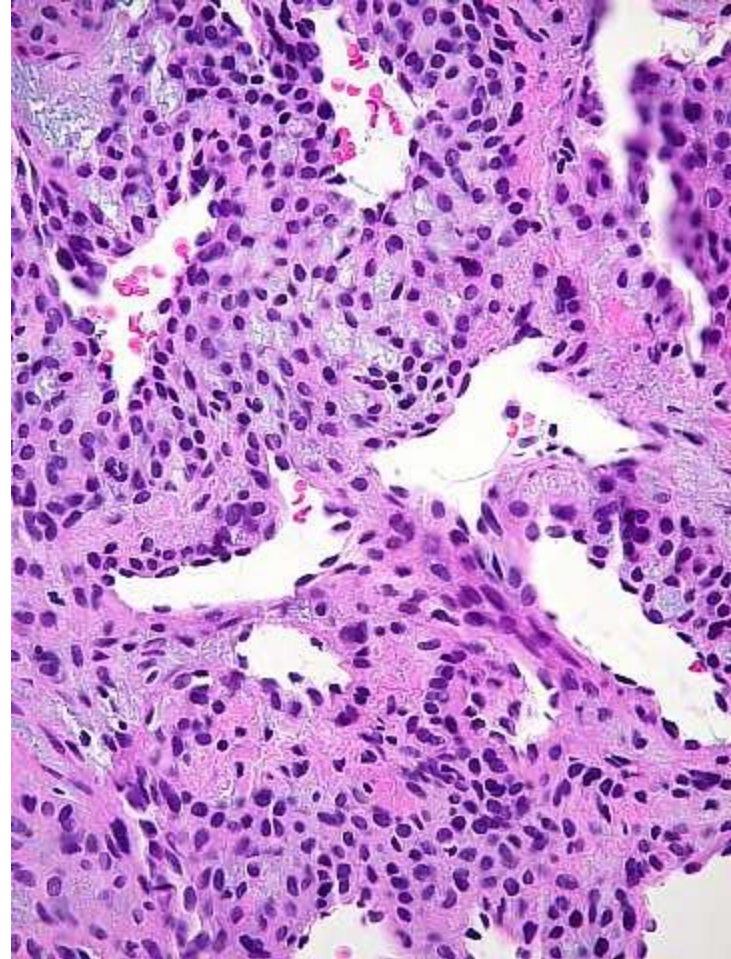
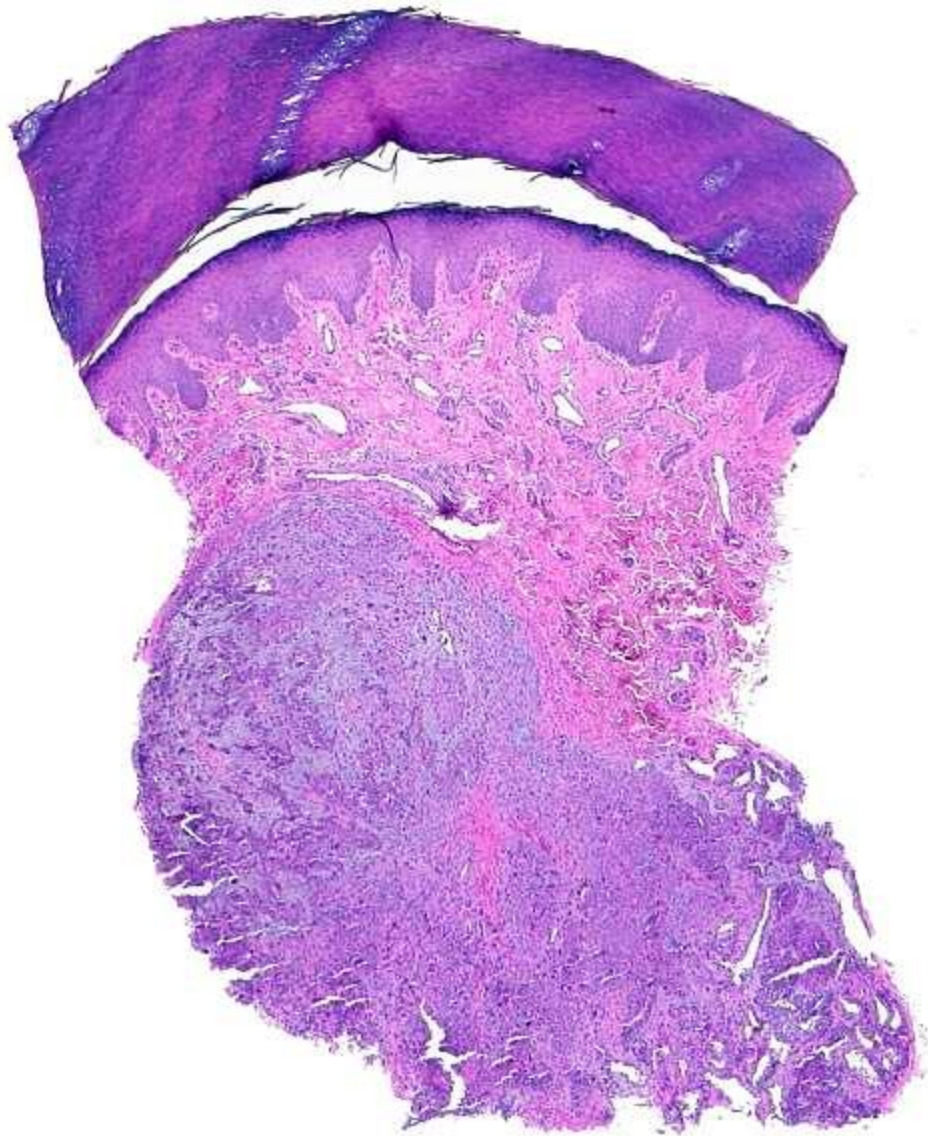

1 10 2003

GLOMUS TUMOR GLOMANGIOMA

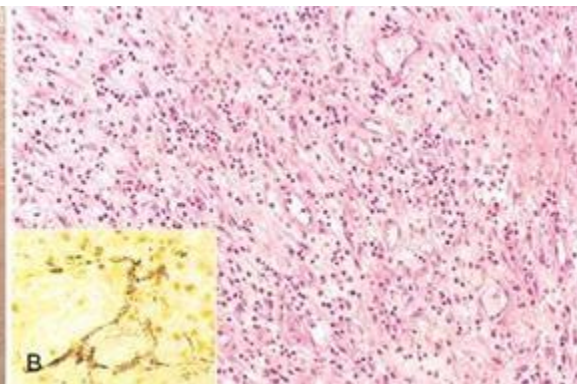
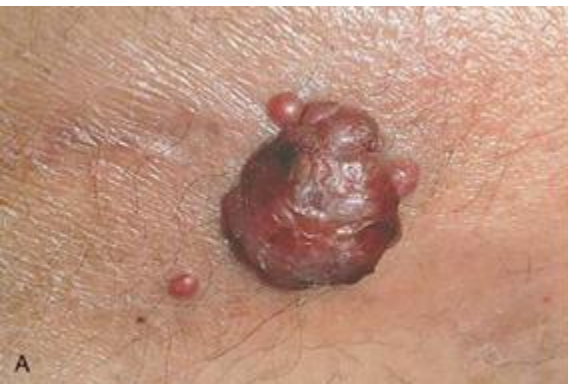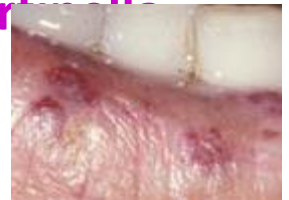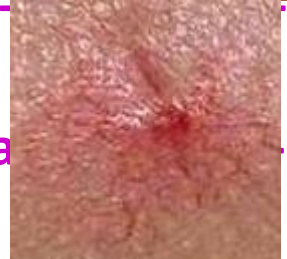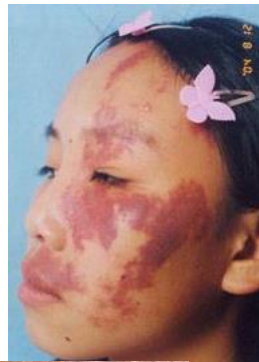- **1 cm**
- **Most commonly under nail**
- **Painful**





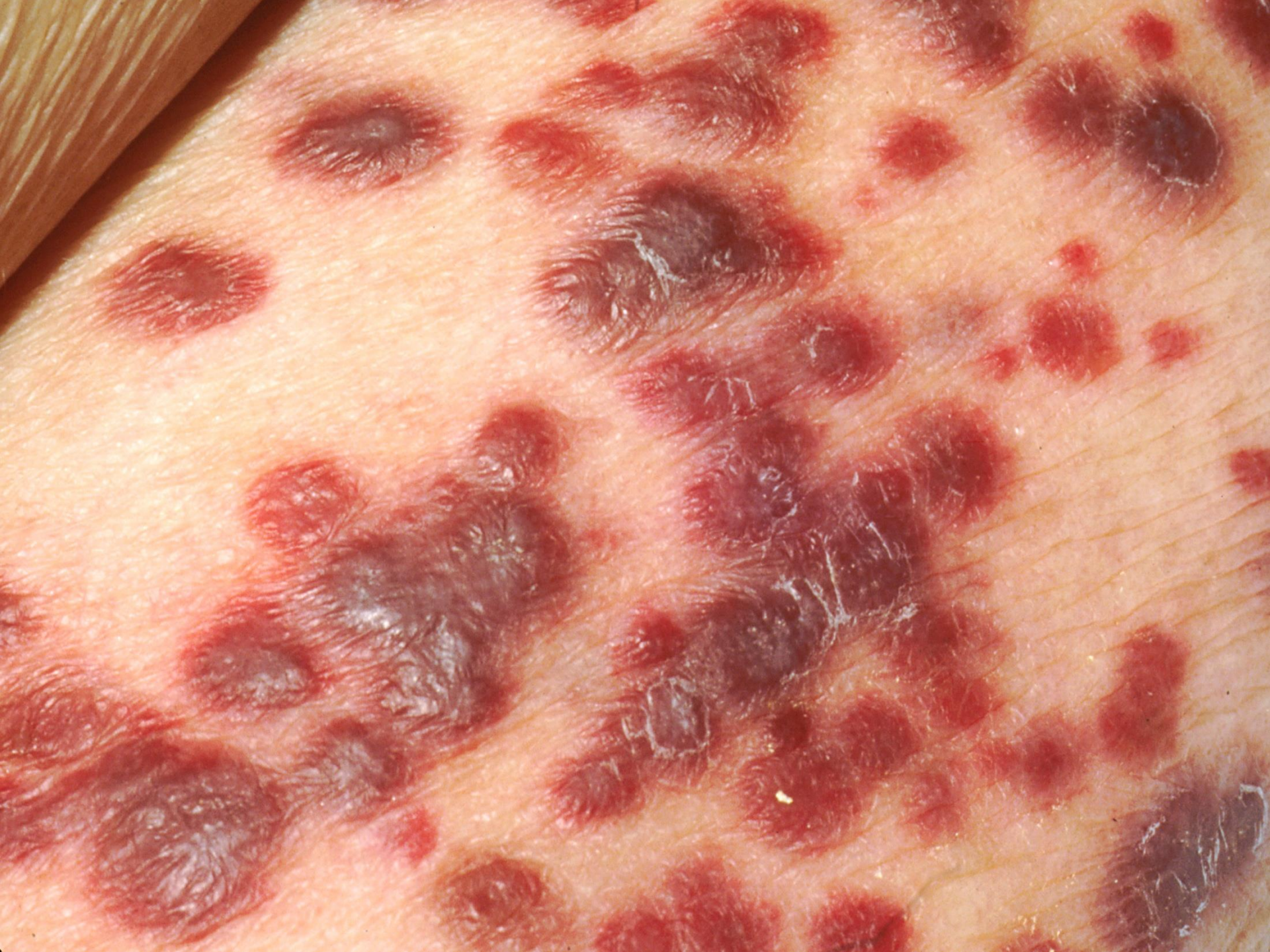MISC. "BENIGN" TUMORS

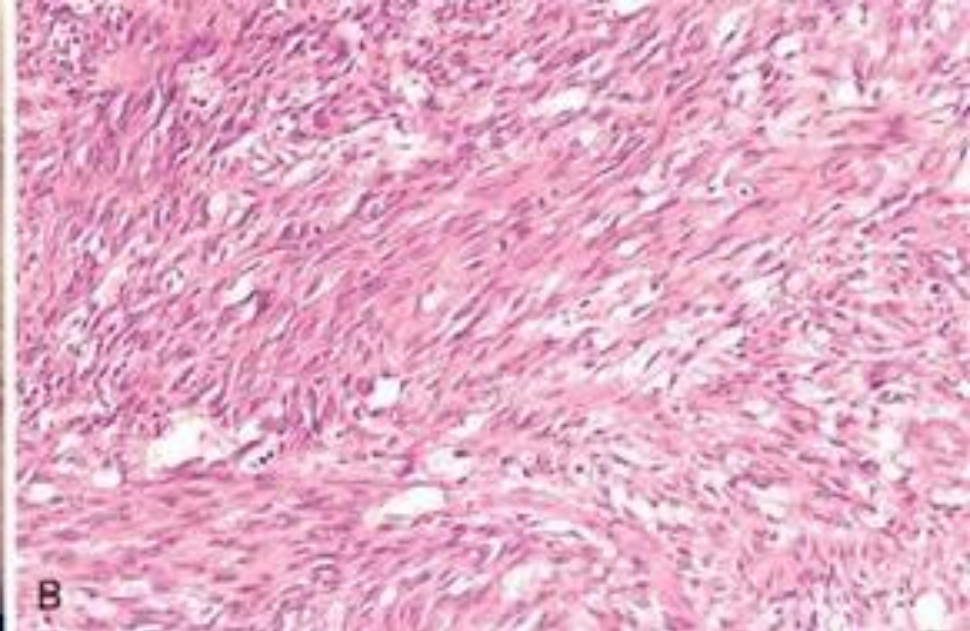
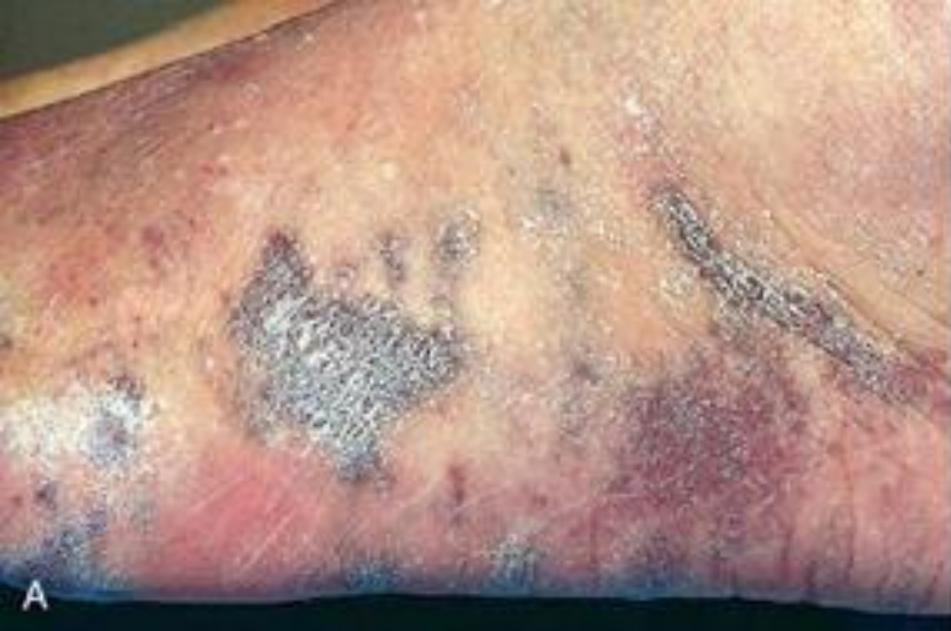- -ectasias, telangiectasias
- Nevus Flammeus, aka, port wine stain----→
- Spiders (spider telangiectasias), ass. W. pregnancy, cirrhosis-----
--→
- Osler-Weber-Rendu Disease (Hereditary Hemorrhagic Telangiectasia)
--→
- Bacillary Angiomatosis, in HIV patients, caused by bacilli of *Bartonella* species



INTERMEDIATE (BORDERLINE) VASCULAR NEOPLASMS

- Kaposi Sarcoma, **KS**
 - 1) Classic European, described 1872, NON-HIV
 - 2) African, pre-HIV, now HIV- and HIV+
 - 3) Transplant associated, HIV-
 - 4) AIDS KS, caused by HHV-8, aka KSHV
- PATCH → PLAQUE → NODULE
- **HEMANGIOENDOTHELIOMA (HETEROGENEOUS GROUP OF NEOPLASMS)**





Diagnosis of vascular neoplasms may require the use of endothelial cell markers such as Factor VIII or CD-31, especially if clear cut vascular spaces are difficult to see, especially if the tumor is UNDIFFERENTIATED enough to the degree that endothelial lined spaces are NOT clearly seen.

MALIGNANT VASCULAR TUMORS

• **ANGIOSARCOMA**

- May not look “vascular” at all
- Severe atypia
- Frequent and often bizarre mitoses
- Behave as any sarcoma might, i.e., early pulmonary metastases

• **HEMANGIOPERICYTOMA**

- HETEROGENOUS group of disorders
- Most commonly arising in pelvic retroperitoneum

VASCULAR INTERVENTIONS

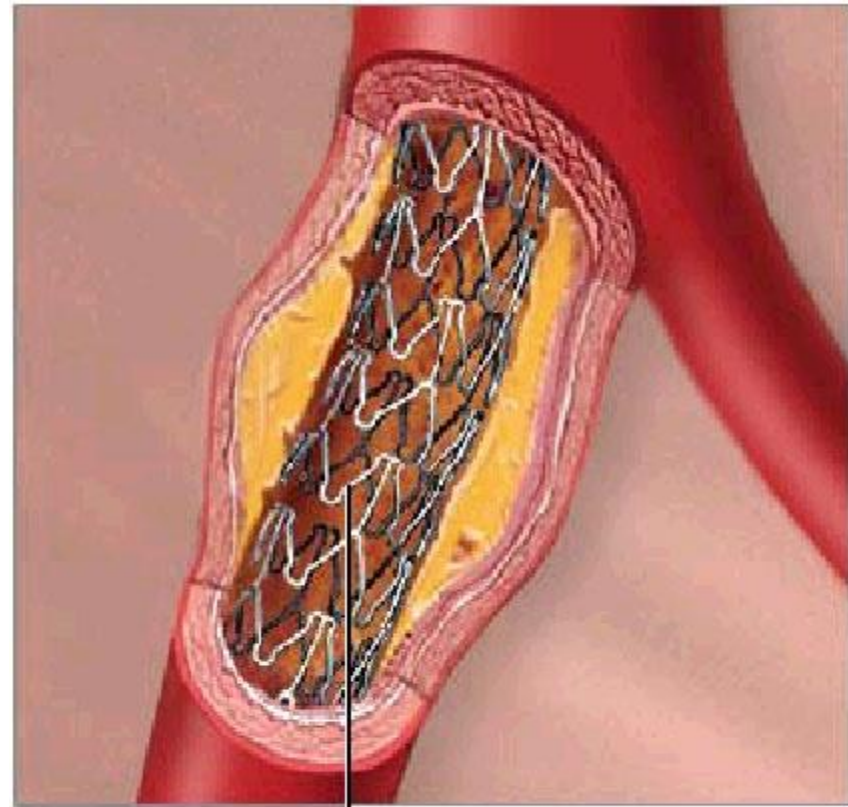
- **ANGIOPLASTY**
- **STENTS**
- **GRAFTS**
 - Autologous (saphenous v., internal mammary a.)
 - Synthetic (Teflon)

ANGIOPLASTIES

- **Plaque fracture (crackling sound)**
- **Dissection**
- **Arterial dilatation initially**
- **Restenosis ~ 6 months**

STENTS

- Metallic mesh
- Permanently placed
- Stays patent longer than angioplasty
- OFTEN DRUG COATED
- Goals:
 - Prevent thrombosis
 - Prevent spasm
 - Delay RE-stenosis



Coronary artery stent

GRAFTS

- 400,000 CABG grafts per year in USA
- Saphenous v. vs. Internal mammary a. (internal thoracic a.)
- 50% patent after 10 years, for saphenous v.
- 90% patent after 10 years, for mammary a.

- Endothelial and smooth muscle migration and proliferation key factors for success

THE HEART

- Normal

- Pathology

- Heart Failure: L, R

- Heart Disease

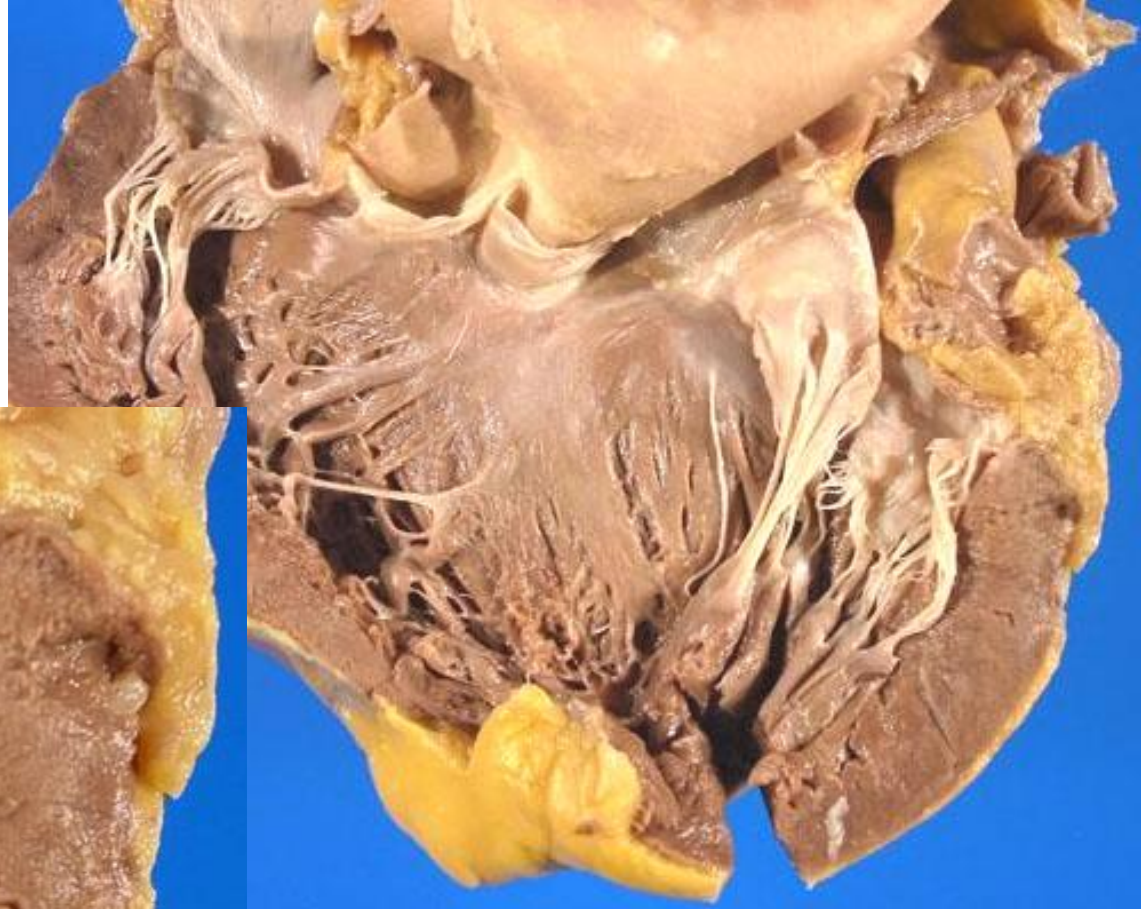
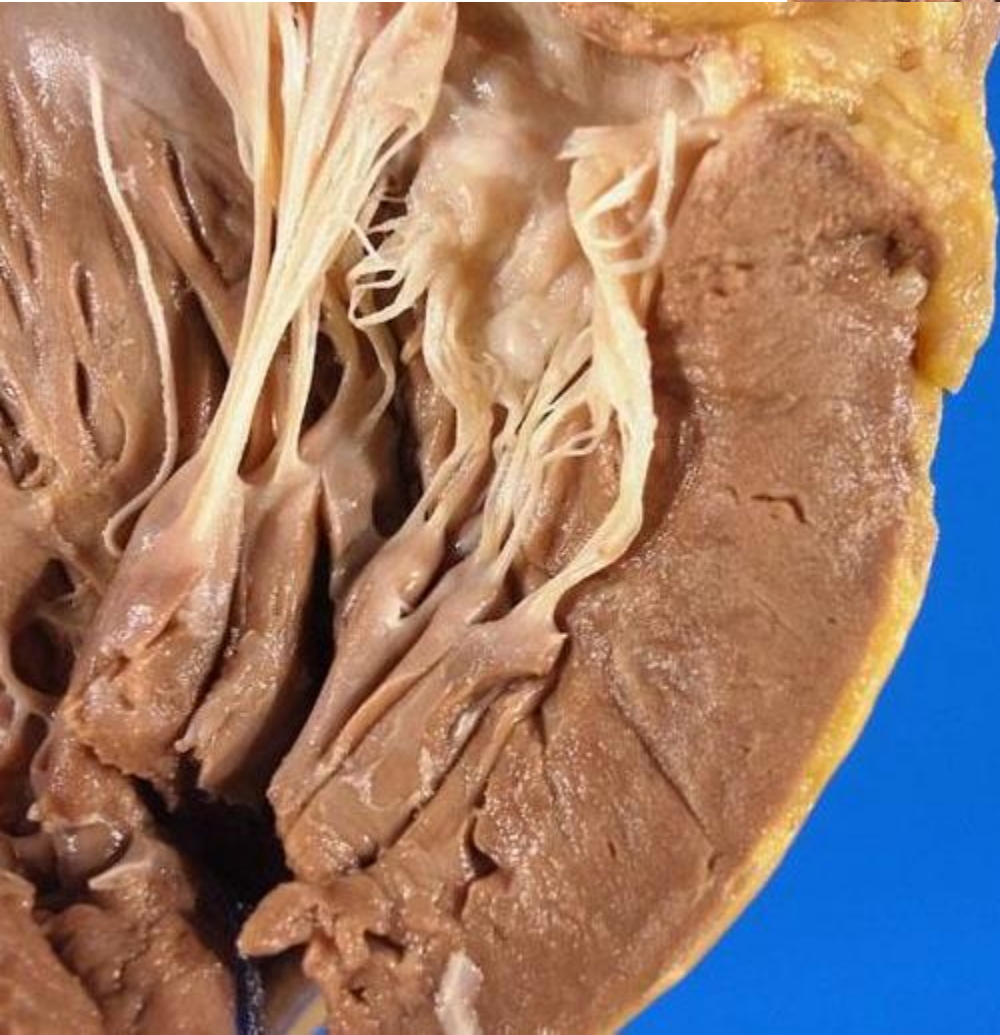- Congenital: L→R shunts, R→L shunts, Obstructive
- Ischemic: Angina, Infarction, Chronic Ischemia, Sudden Death
- Hypertensive: Left sided, Right sided
- Valvular: AS, MVP, Rheumatic, Infective, Non-Infective, Carcinoid, Artificial Valves
- Cardiomyopathy: Dilated, Hypertrophic, Restrictive, Myocarditis, Other
- Pericardium: Effusions, Pericarditis
- Tumors: Primary, Effects of Other Primaries
- Transplants

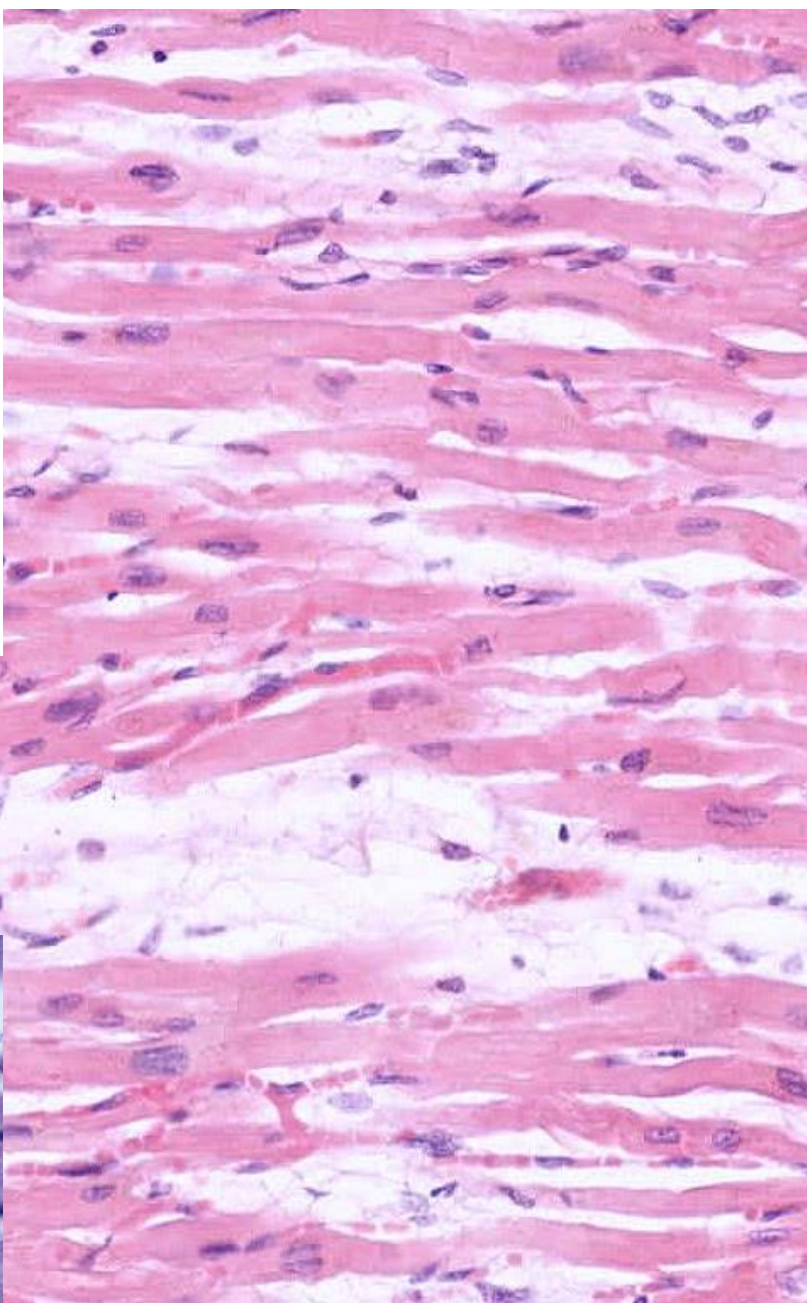
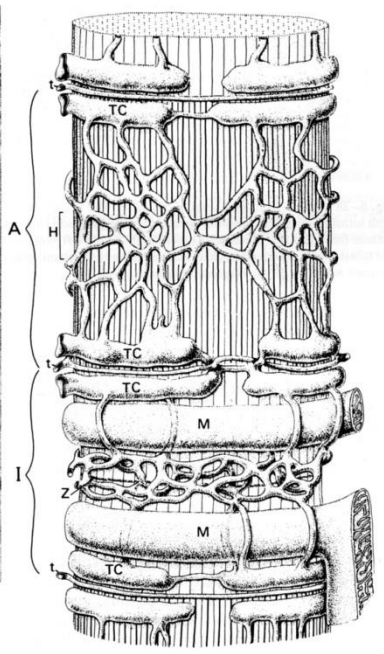
NORMAL Features

- 6000 L/day
- 250-300 grams
- 40% of all deaths (2x cancer)
- Wall thickness ~ pressure
- (i.e., a wall is only as thick as it has to be)
 - LV=1.5 cm
 - RV= 0.5 cm
 - Atria =.2 cm
- Systole/Diastole
- Starling's Law

TERMS

- **CARDIOMEGALY**
- **DILATATION**, any chamber, or all
- **HYPERTROPHY**, and chamber, or all





STRIATIONS

NUCLEUS

DISCS

SARCOLEMMA

SARC. RETIC.

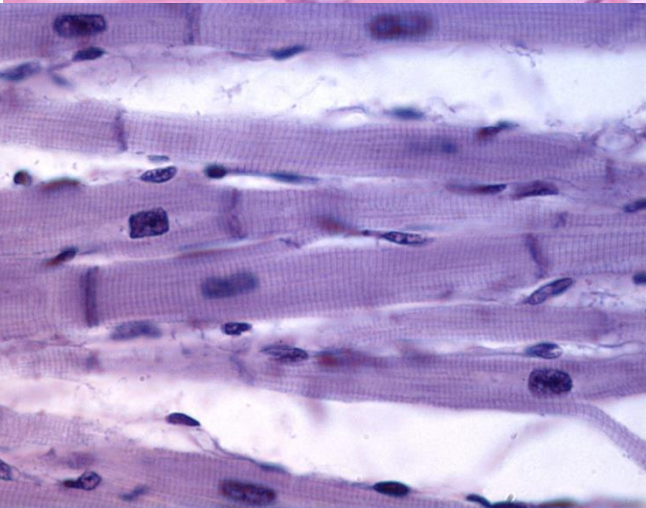
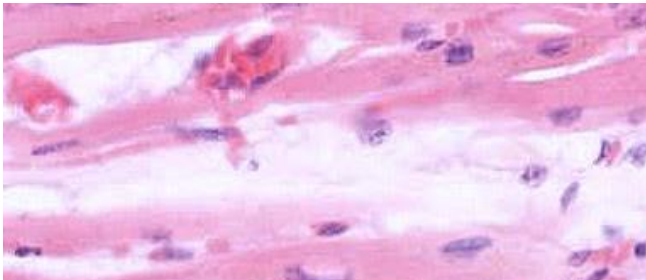
MITOCHONDRIA

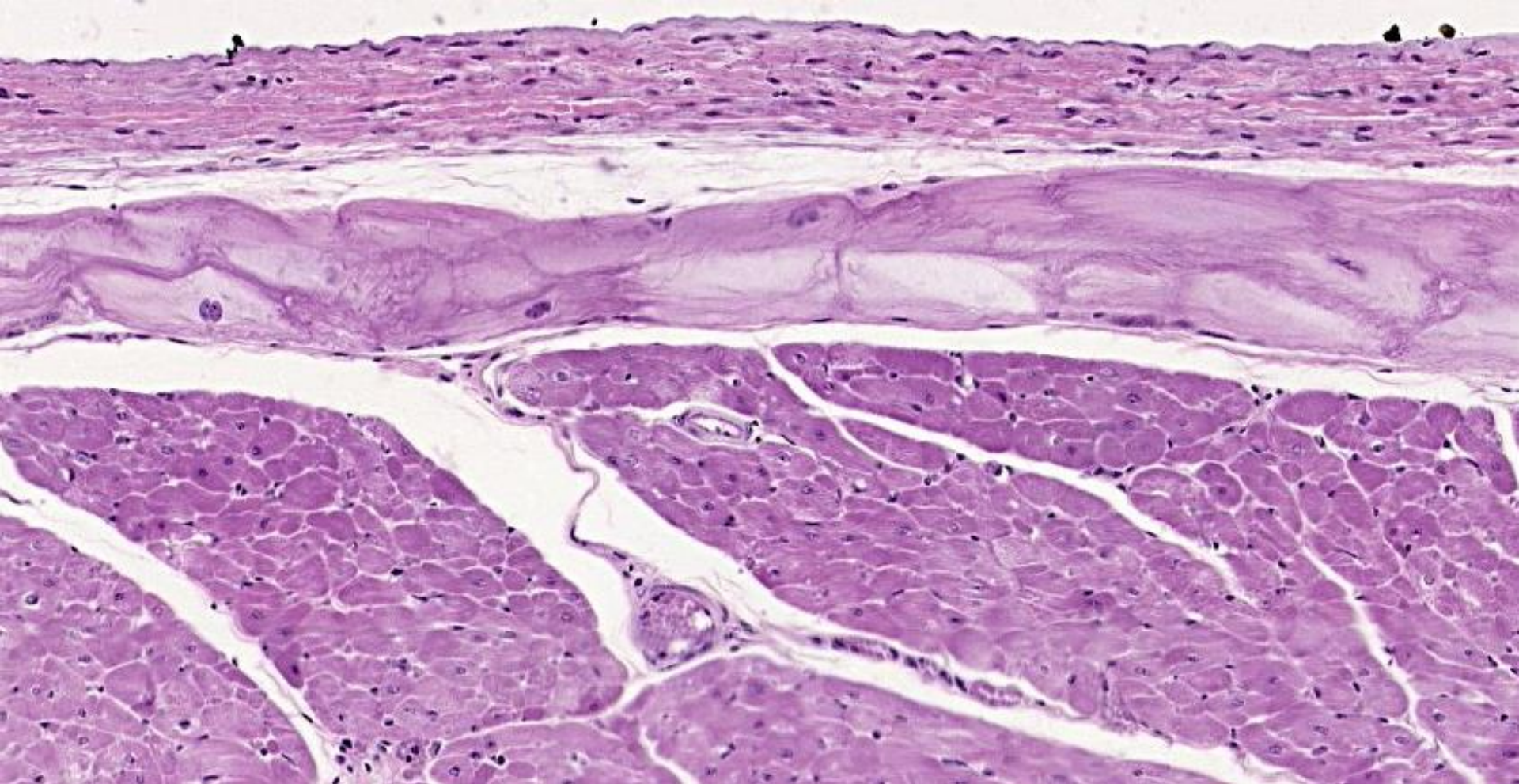
ENDOTHELIUM

FIBROBLASTS

GLYCOGEN

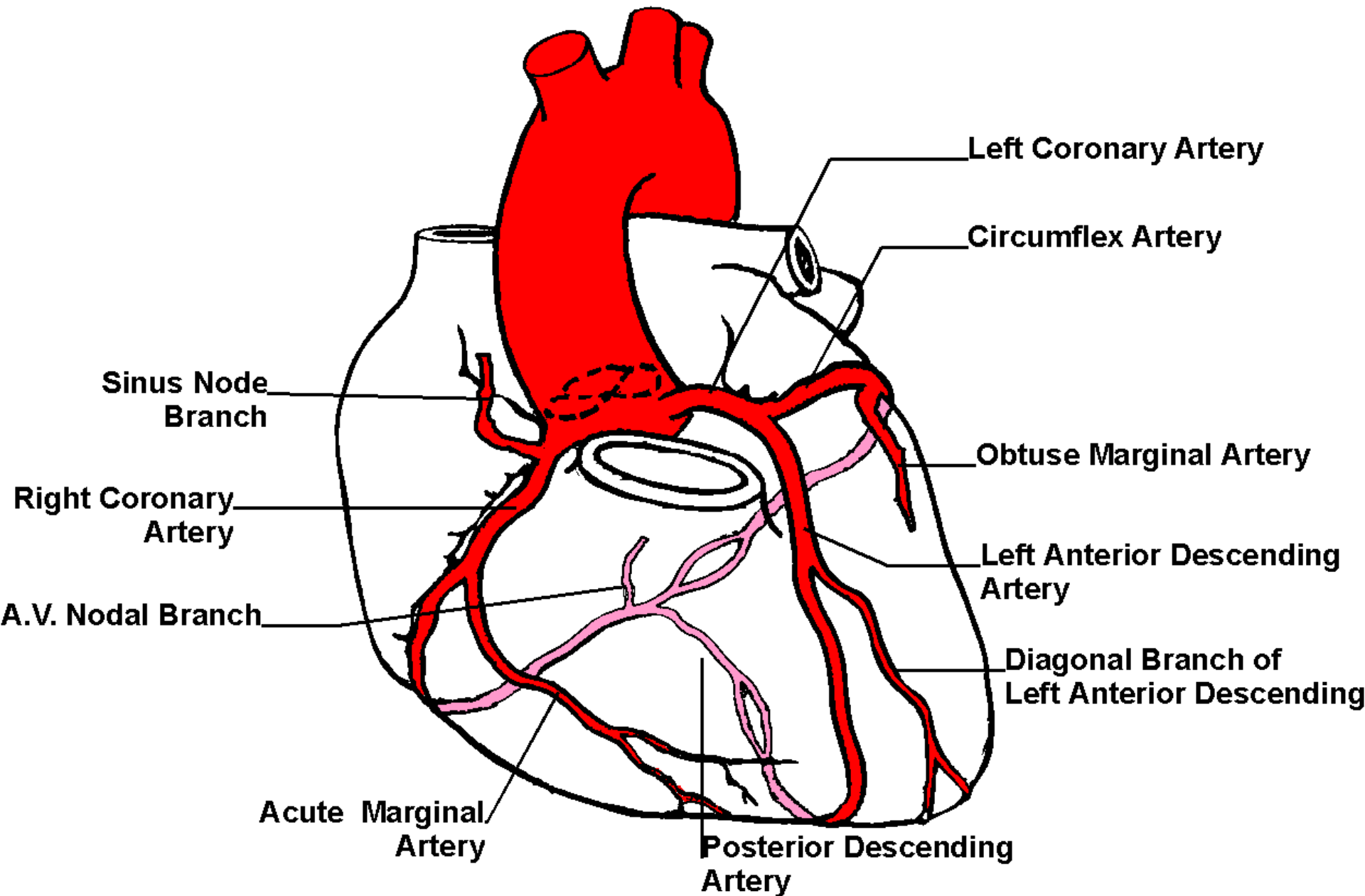
A.N.P.


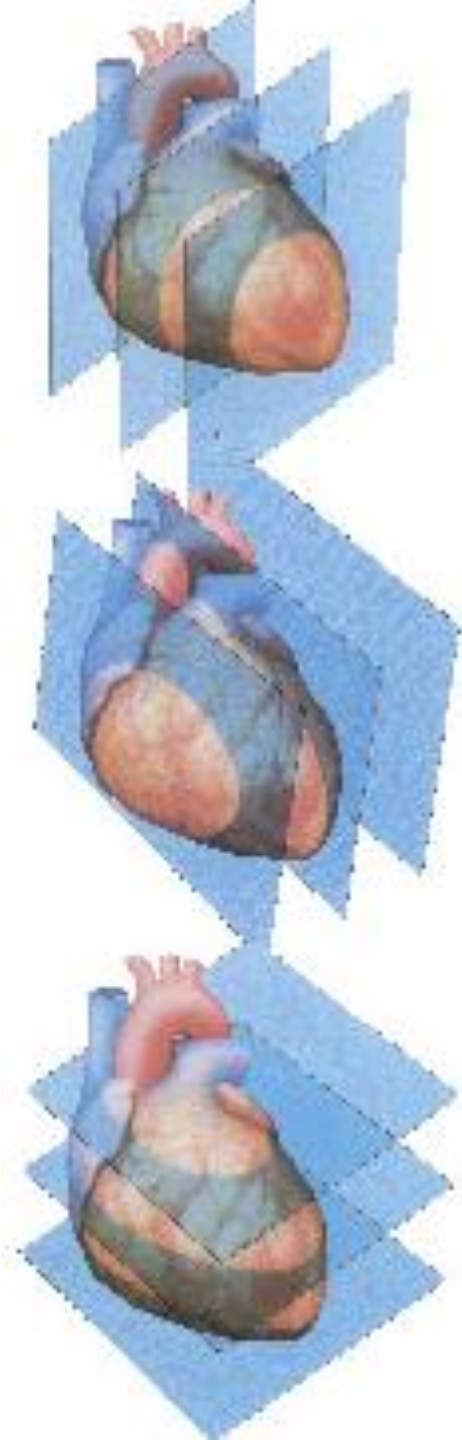




S.A. Node → AV Node → Bundle of HIS → L. Bundle, R. Bundle

Coronary Arteries





Anterior

Lateral

Posterior

Septal

VALVES

- AV:

- TRICUSPID

- MITRAL

- SEMILUNAR:

- PULMONIC

- AORTIC

CARDIAC AGING

Chambers

Increased left atrial cavity size

Decreased left ventricular cavity size

Sigmoid-shaped ventricular septum

Valves

Aortic valve calcific deposits

Mitral valve annular calcific deposits

Fibrous thickening of leaflets

Buckling of mitral leaflets toward the left atrium

Epicardial Coronary Arteries

Tortuosity

Increased cross-sectional

Calcific deposits

Atherosclerotic plaque

Myocardium

Increased mass

Increased subepicardial

fat
Brown atrophy

Lipofuscin deposition

Basophilic degeneration

Amyloid deposits

CARDIAC AGING

Aorta

Dilated ascending aorta with rightward shift

Elongated (tortuous) thoracic aorta

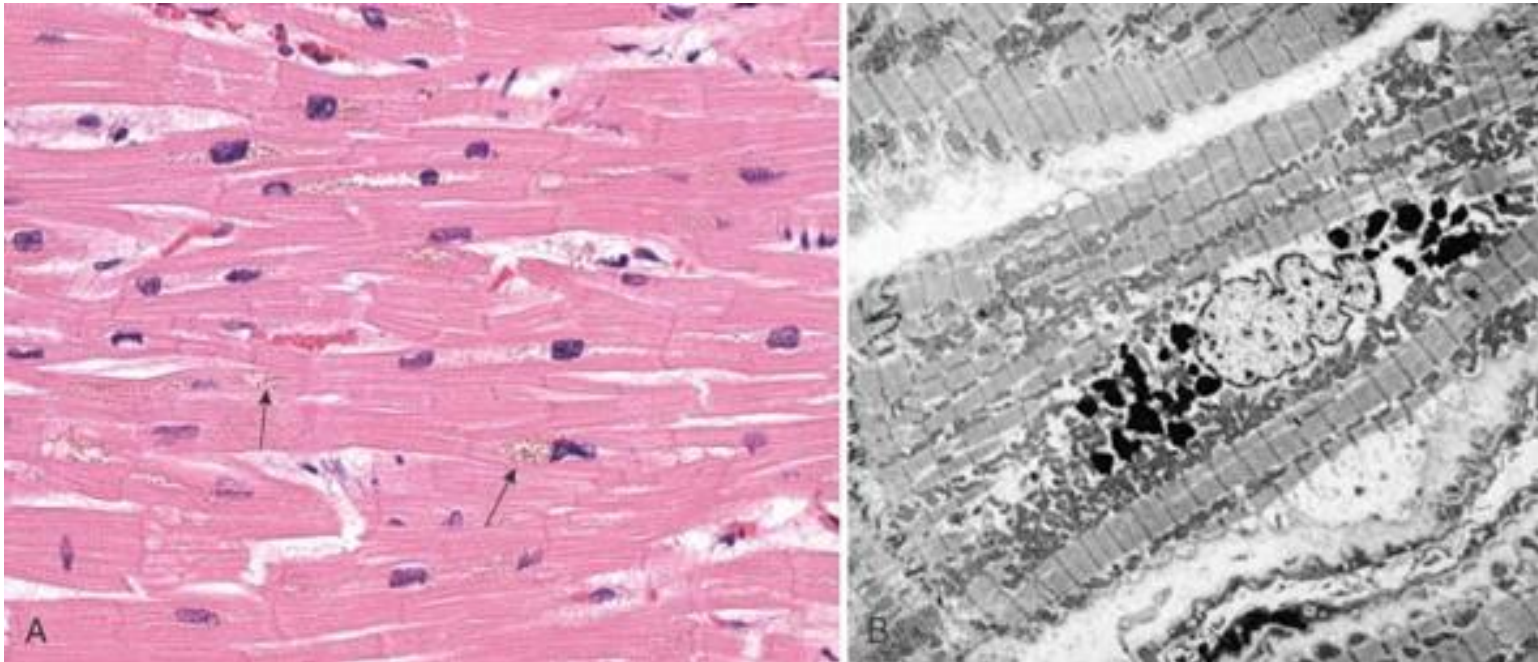
Sinotubular junction calcific deposits

Elastic fragmentation and collagen accumulation

Atherosclerotic plaque

BROWN

ATROPHY, HEART



LIPOFUCSIN

Pathologic Pump Possibilities

- Primary myocardial failure (MYOPATHY)
- Obstruction to flow (VALVE)
- Regurgitant flow (VALVE)
- Conduction disorders (CONDUCTION SYSTEM)
- Failure to contain blood (WALL INTEGRITY)

CHF

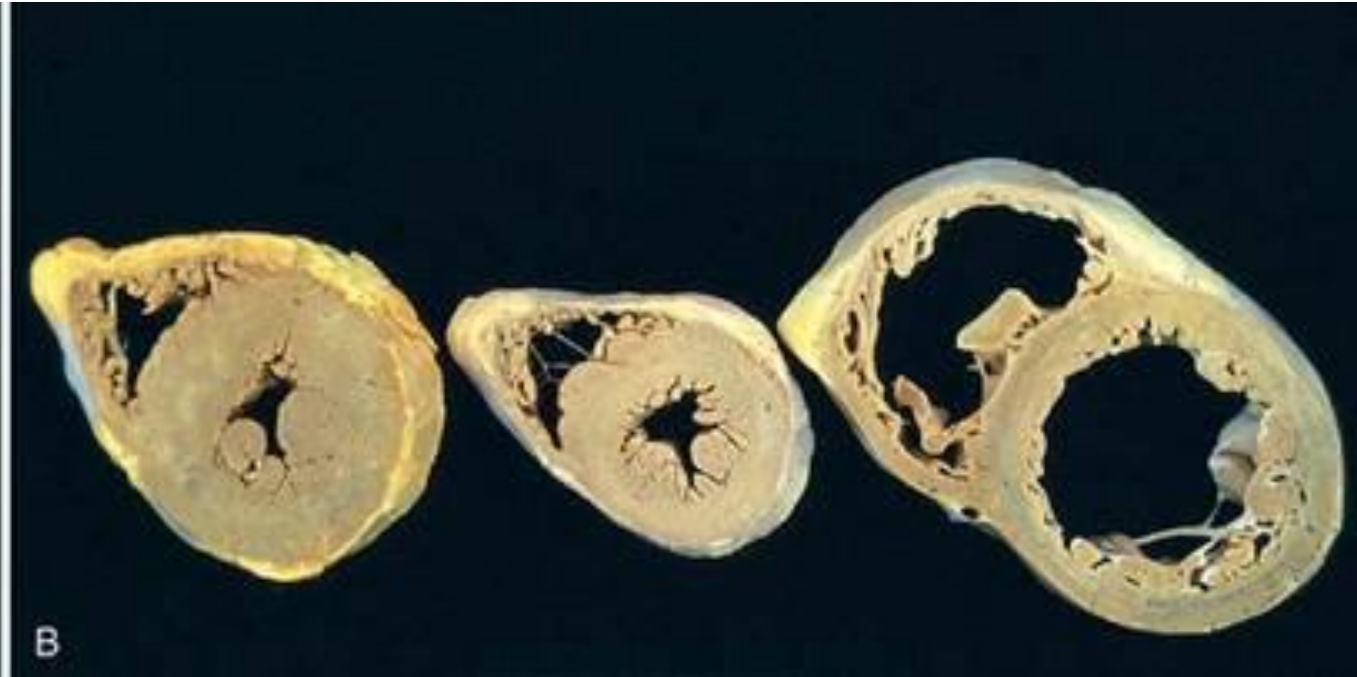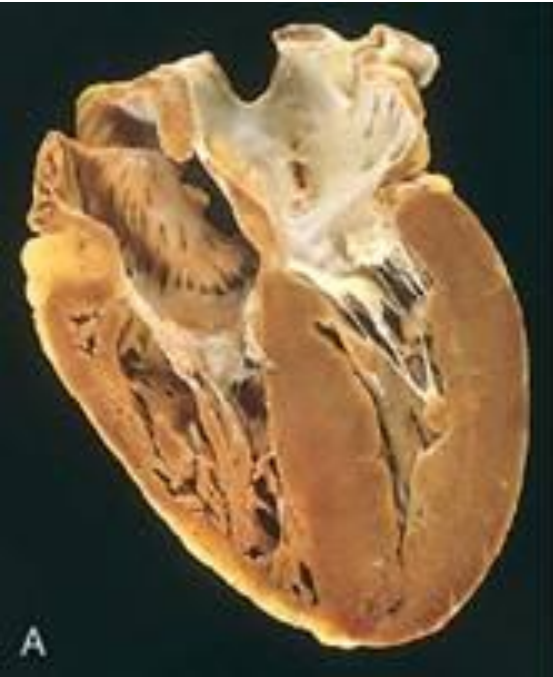- DEFINITION
- TRIAD
 - 1) TACHYCARDIA
 - 2) DYSPNEA
 - 3) EDEMA
- FAILURE of Frank Starling mechanism
- HUMORAL FACTORS
 - Catecholamines (nor-epinephrine)
 - Renin→Angiotension→Aldosterone
 - Atrial Natriuretic Polypeptide (ANP)
- **HYPERTROPHY and DILATATION**

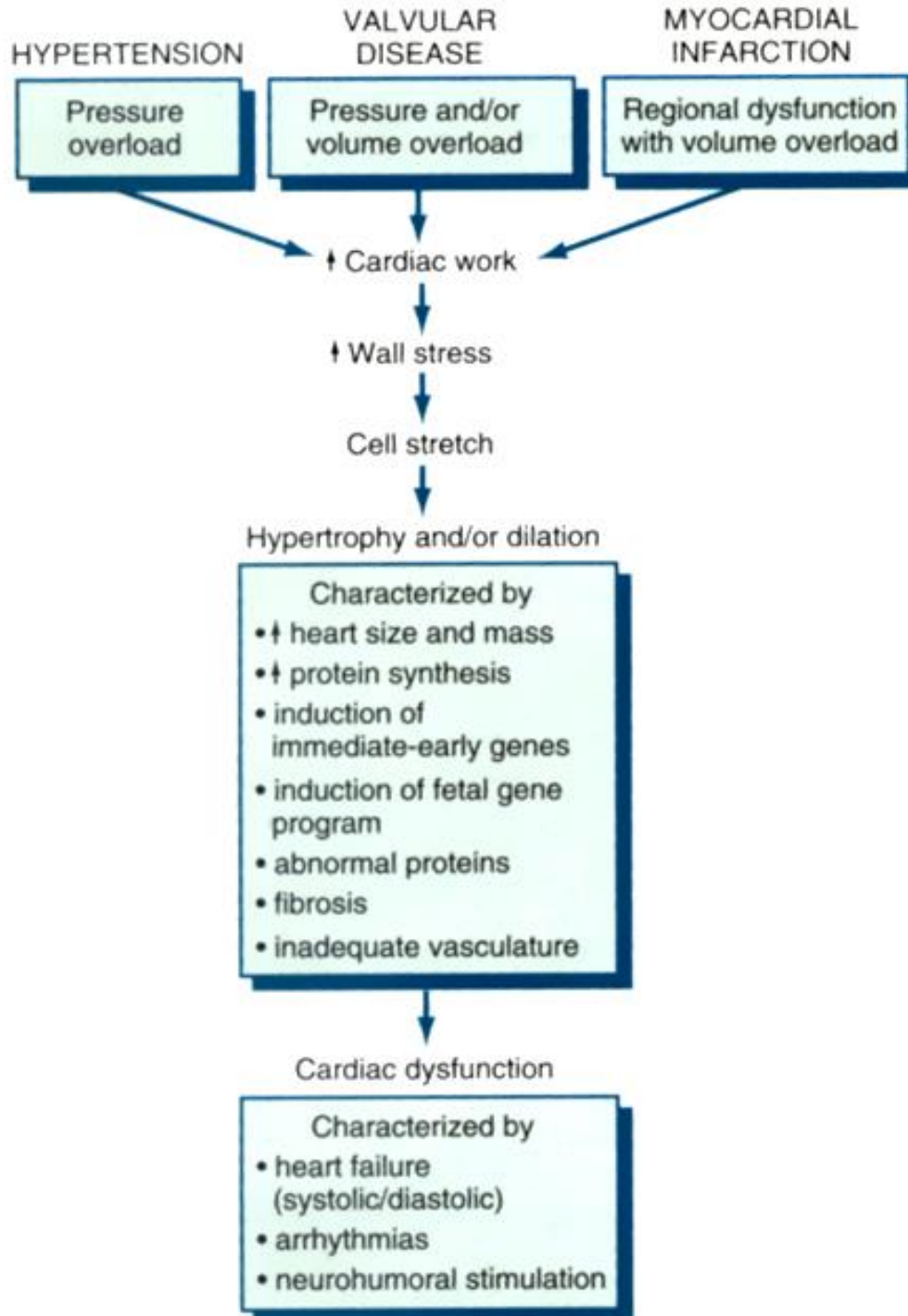
HYPERTROPHY

- PRESSURE OVERLOAD (CONCENTRIC)
- VOLUME OVERLOAD (CHF)

- LVH, RVH, atrial, etc.

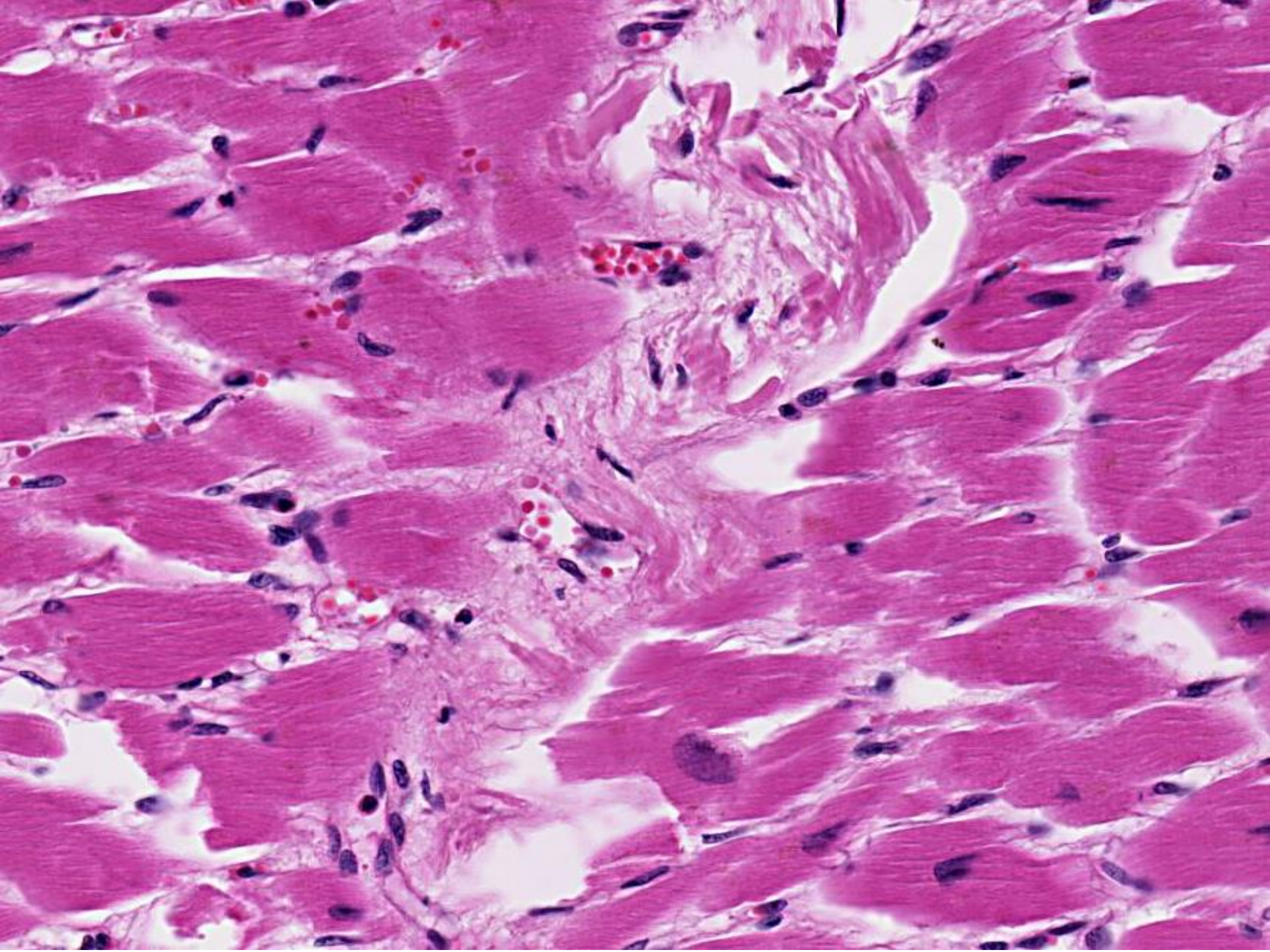
- 2X normal weight → ischemia
- 3X normal weight → HTN
- >3X normal weight → MYOPATHY, aortic regurgitation





CHF: Autopsy Findings

- Cardiomegaly
- Chamber Dilatation
- Hypertrophy of myocardial fibers, BOXCAR nuclei



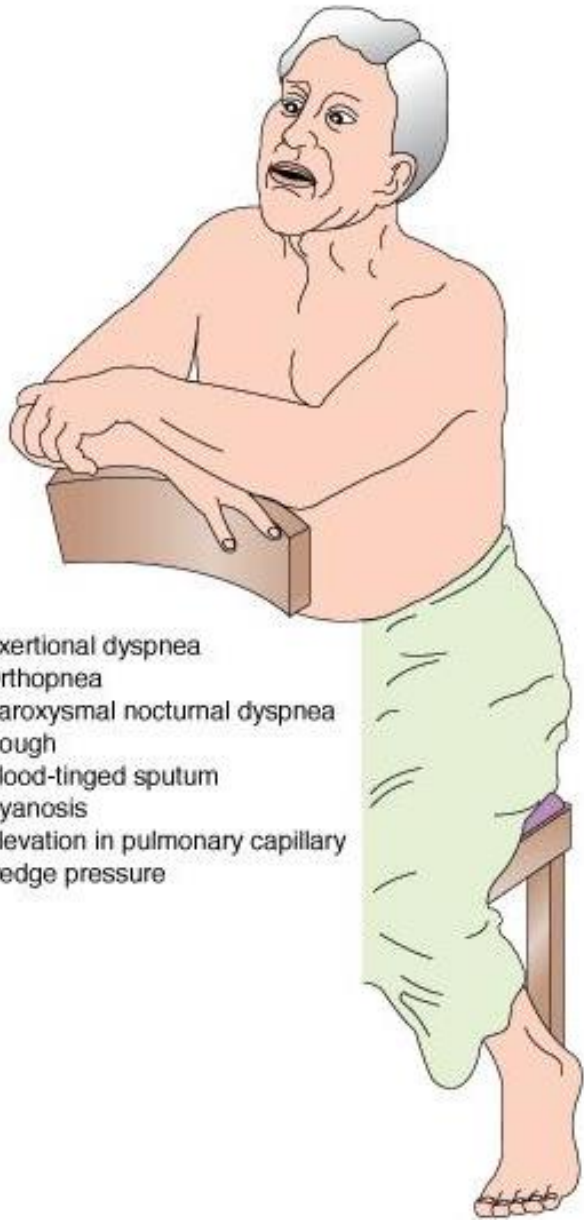
Left Sided Failure

- **Low output vs. congestion**
- **Lungs**
 - pulmonary congestion and edema
 - heart failure cells
- **Kidneys**
 - pre-renal azotemia
 - salt and fluid retention
 - renin-aldosterone activation
 - natriuretic peptides
- **Brain: Irritability, decreased attention, stupor → coma**

Left Heart Failure Symptoms

- **Dyspnea**
 - on exertion
 - at rest
- **Orthopnea**
 - redistribution of peripheral edema fluid
 - graded by number of pillows needed
- **Paroxysmal Nocturnal Dyspnea (PND)**

LEFT Heart Failure



- Exertional dyspnea
- Orthopnea
- Paroxysmal nocturnal dyspnea
- Cough
- Blood-tinged sputum
- Cyanosis
- Elevation in pulmonary capillary wedge pressure

Dyspnea

Orthopnea

PND (Paroxysmal Nocturnal Dyspnea)

Blood tinged sputum

Cyanosis

Elevated pulmonary
“WEDGE” pressure (PCWP)

Right Sided Heart Failure

- **Etiology**

- left heart failure
- cor pulmonale

- **Symptoms and signs**

- **Liver and spleen**

- passive congestion (nutmeg liver)
- congestive splenomegaly
- ascites

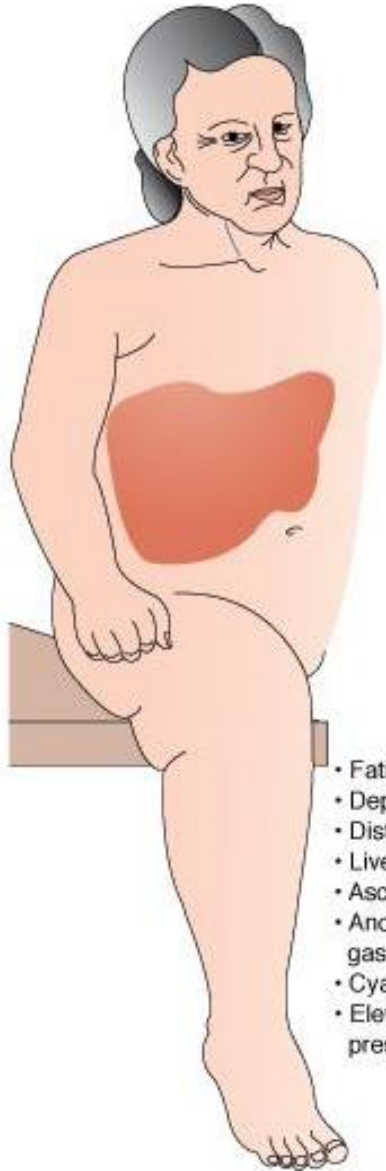
- **Kidneys**

- **Pleura/Pericardium**

- pleural and pericardial effusions
- transudates

- **Peripheral tissues**

RIGHT Heart Failure



- Fatigue
- Dependent edema
- Distention of the jugular veins
- Liver engorgement
- Ascites
- Anorexia and complaints of gastrointestinal distress
- Cyanosis
- Elevation in peripheral venous pressure

FATIGUE

“Dependent” edema

JVD

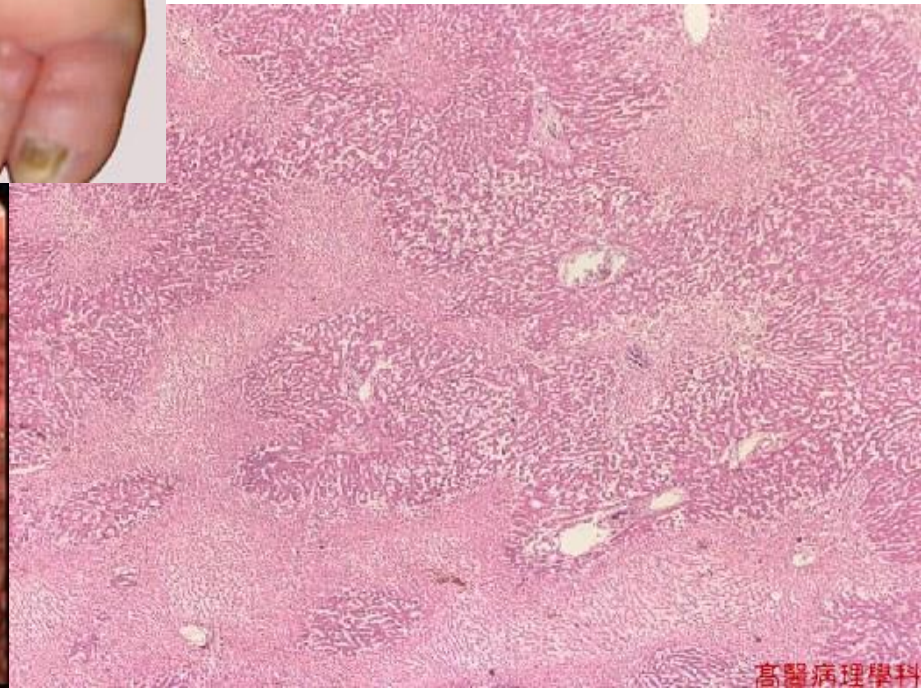
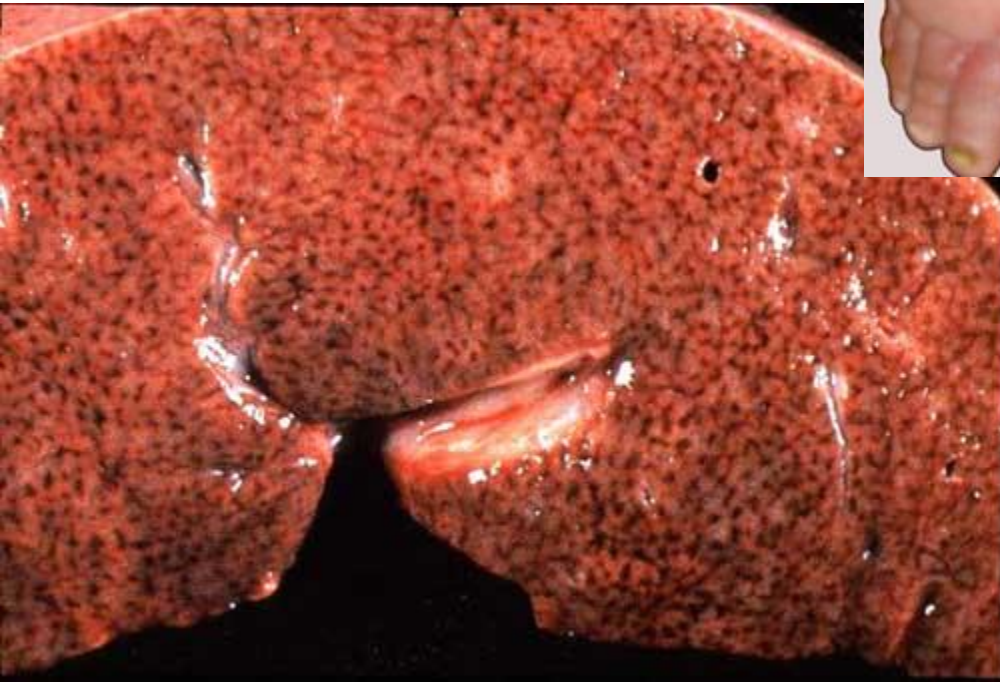
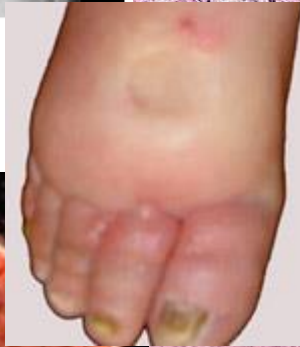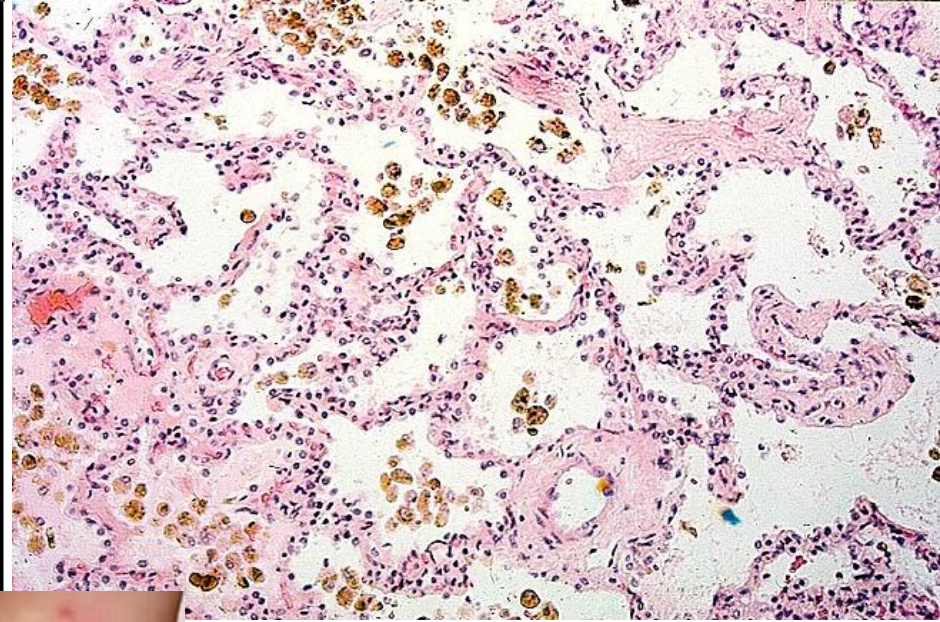
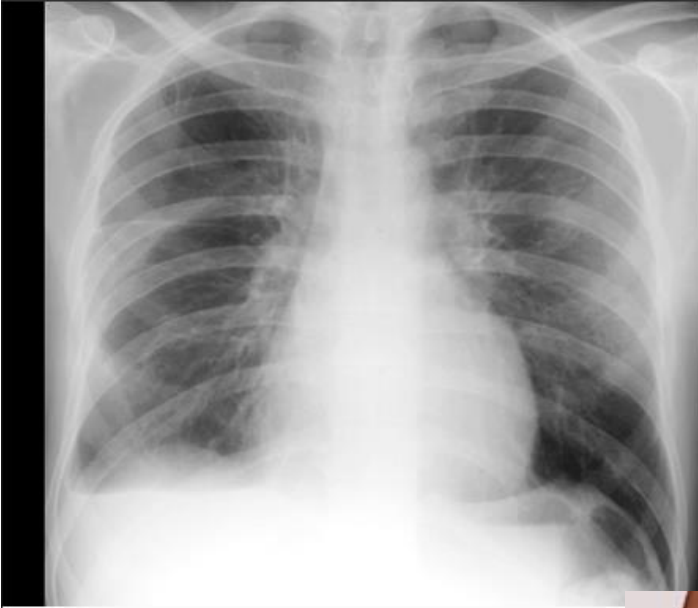
Hepatomegaly (congestion)

ASCITES, PLEURAL EFFUSION

GI

Cyanosis

Increased peripheral venous pressure (CVP)



HEART DISEASE

- **CONGENITAL (CHD)**

- ISCHEMIC (IHD)
- HYPERTENSIVE (HHD)
- VALVULAR (VHD)
- MYOPATHIC (MHD)

CONGENITAL HEART DEFECTS

- Faulty embryogenesis (week 3-8)
- Usually MONO-morphic (i.e., SINGLE lesion) (ASD, VSD, hypo-RV, hypo-LV)
- May not be evident until adult life (Coarctation, ASD)
- Overall incidence 1% of USA births
- INCREASED simple early detection via non invasive methods, e.g., US, MRI, CT, etc.

Malformation

Incidence per Million

Live Births %

Ventricular septal defect

4482 42

Atrial septal defect

1043 10

Pulmonary stenosis

836 8

Patent ductus arteriosus

781 7

Tetralogy of Fallot

577 5

Coarctation of aorta

492 5

Atrioventricular septal defect

396 4

Aortic stenosis

388 4

Transposition of great arteries

388 4

Truncus arteriosus

136 1

Total anomalous pulmonary venous

120 1

Transposition

GENETICS

- Gene abnormalities in only 10% of CHD
- Trisomies **21**, 13, 15, 18, XO
- Mutations of genes which encode for transcription factors → TBX5 → ASD, VSD
- → NKX2.5 → ASD
- Region of chromosome 22 important in heart development, 22q11.2 deletion → conotruncus, branchial arch, face

ENVIRONMENT

- RUBELLA
- TERATOGENS

CHD

- **L→R SHUNTS:** all “D’s” in their names
 - NO cyanosis
 - Pulmonary hypertension
 - SIGNIFICANT pulmonary hypertension is IRREVERSIBLE
- **R→L SHUNTS:** all “T’s” in their names
 - CYANOSIS (i.e., “blue” babies)
 - VENOUS EMBOLI become SYSTEMIC
- **OBSTRUCTIONS**

L → R

• ASD

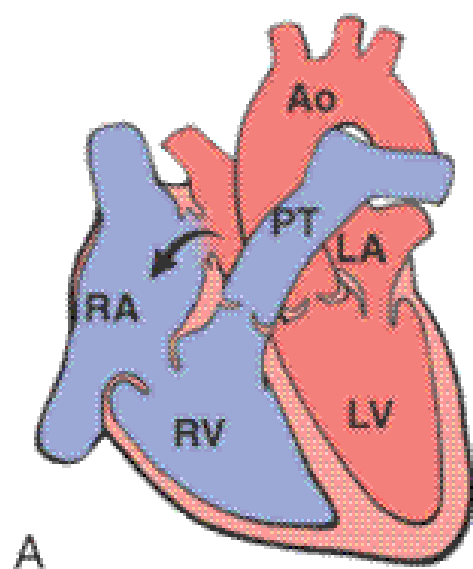
• VSD

• ASVD

• PDA

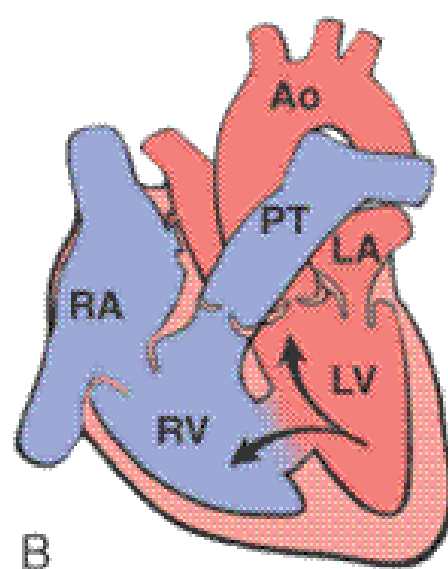
NON CYANOTIC

IRREVERSIBLE
PULMONARY
HYPERTENSION
IS THE MOST
FEARED
CONSEQUENCE



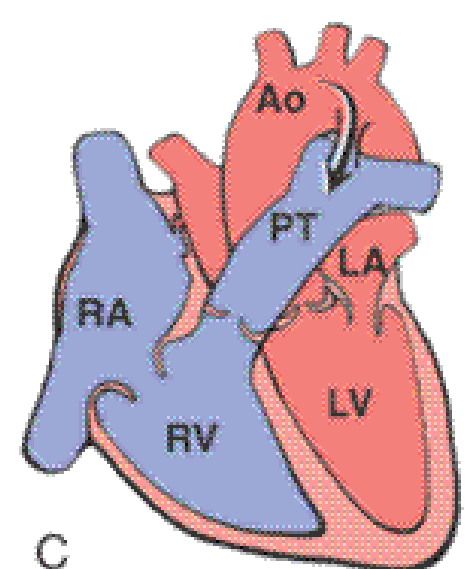
A

ASD



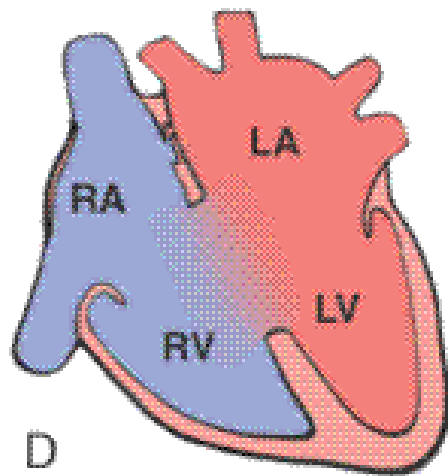
B

VSD



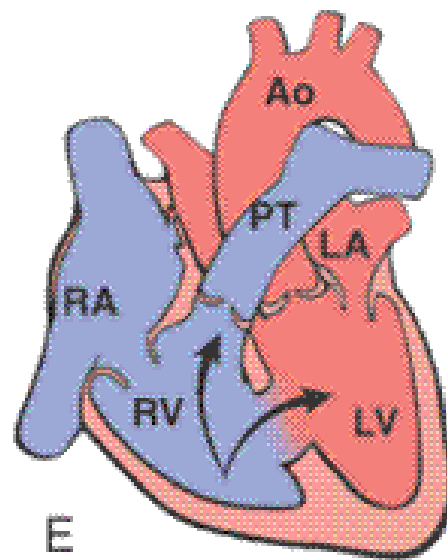
C

PDA



D

Complete Atrioventricular
Canal Defect



E

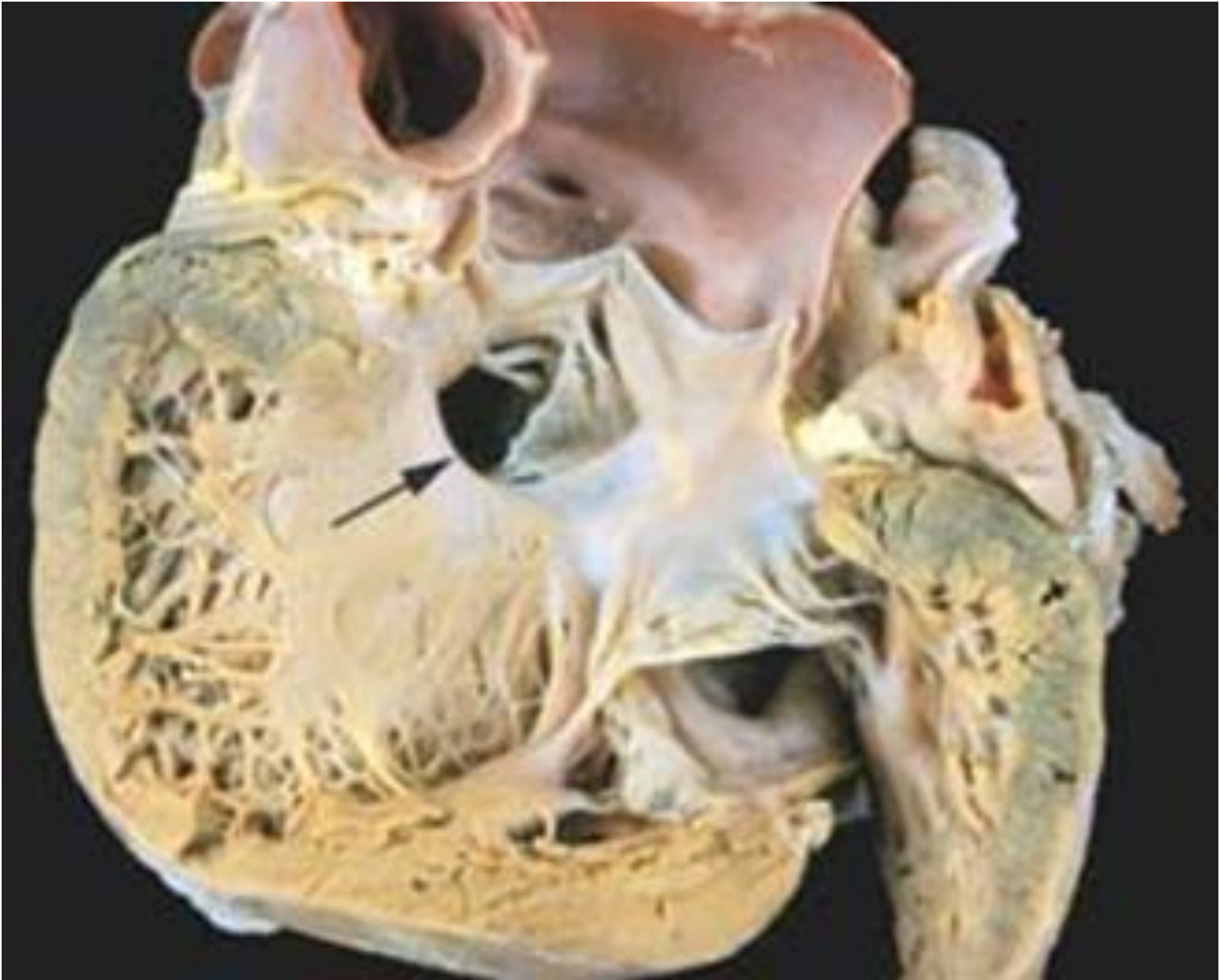
Large VSD with
Irreversible Pulmonary
Hypertension

ASD

- NOT patent foramen ovale
- Usually asymptomatic until adulthood
- **SECUNDUM** (90%): Defective fossa ovalis
- **PRIMUM** (5%): Next to AV valves, mitral cleft
- **SINUS VENOSUS** (5%): Next to SVC with anomalous pulmonary veins draining to SVC or RA

VSD

- By far, most common CHD defect
- Only 30% are isolated
- Often with TETRALOGY of FALLOT
- 90% involve the membranous septum
- If muscular septum is involved, likely to have multiple holes
- SMALL ones often close spontaneously
- LARGE ones progress to pulmonary hypertension



PDA

- 90% isolated
- HARSH, machinery-like murmur
- L→R, possibly R→L as pulmonary hypertension approaches systemic pressure
- Closing the defect may be life saving
- Keeping it open may be life saving (Prostaglandin E). Why?

AVSD

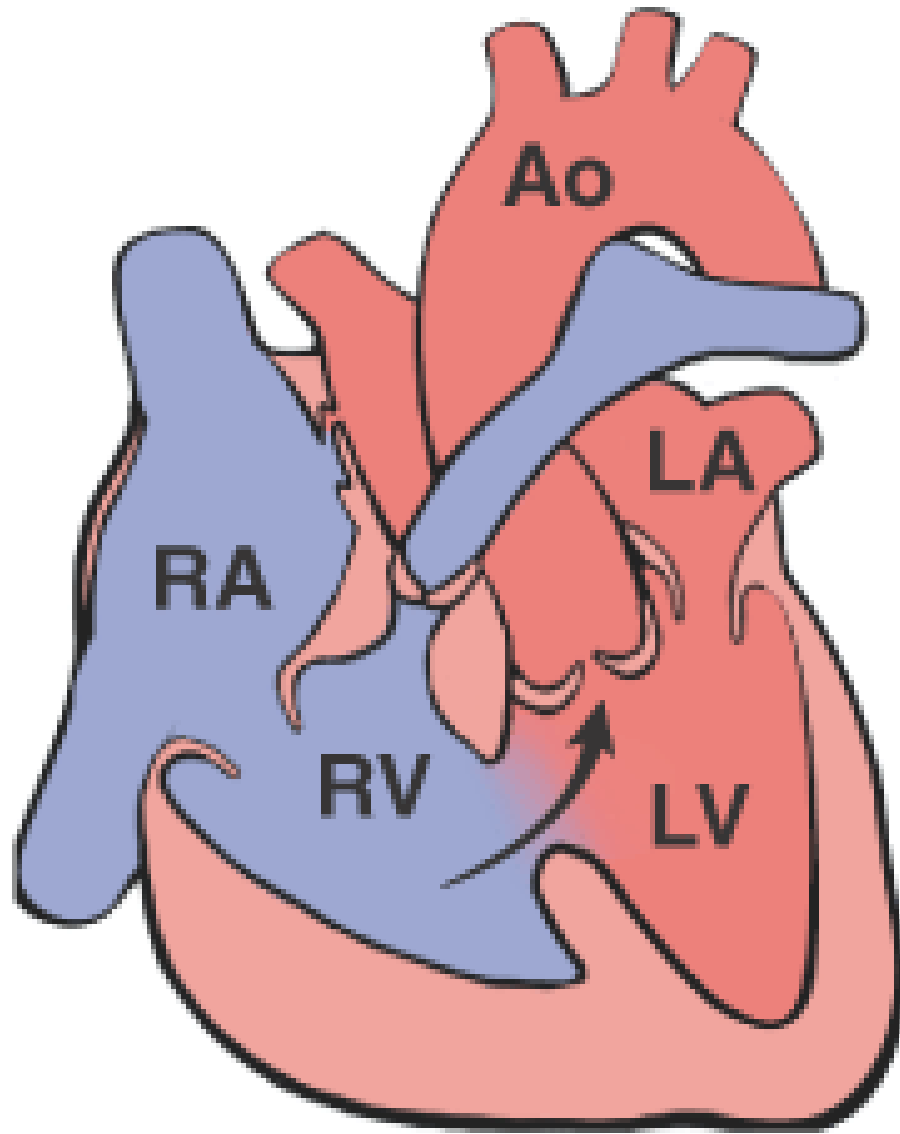
- Associated with defective, inadequate AV valves
- Can be partial, or COMPLETE (ALL 4 CHAMBERS FREELY COMMUNICATE)

R → L

- **Tetralogy of Fallot**
- **T**ransposition of great arteries
- **T**runcus arteriosus
- **T**otal anomalous pulmonary venous connection
- **T**ricuspid atresia

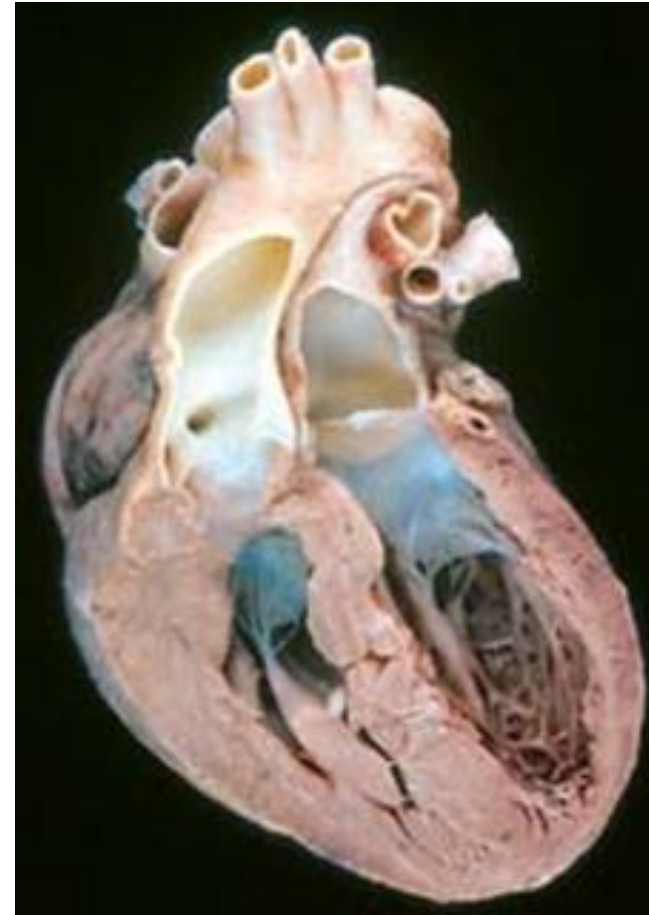
R→L SHUNTS

- **TETRALOGY of FALLOT most COMMON**
 - 1) VSD, large
 - 2) OBSTRUCTION to RV flow
 - 3) Aorta OVERRIDES the VSD
 - 4) RVH
 - SURVIVAL DEPENDS on SEVERITY of SUBPULMONIC STENOSIS
 - Can be a “PINK” tetralogy if pulmonic obstruction is small, but the greater the obstruction, the greater is the R→L shunt



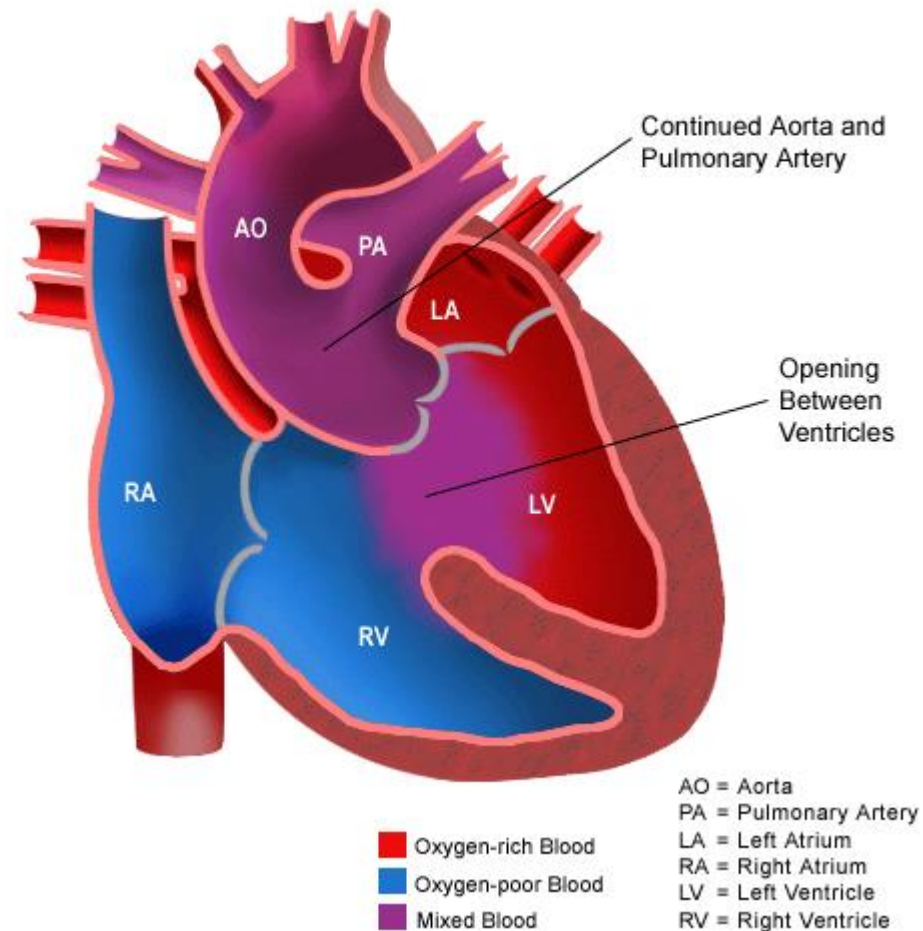
TGA (TRANSPOSITION of GREAT ARTERIES)

- NEEDS a SHUNT for survival
 - PDA or PFO (65%), “unstable” shunt
 - VSD (35%), “stable” shunt
 - RV > LV in thickness
 - Fatal in first few months
 - Surgical “switching”



TRUNCUS ARTERIOSUS

Truncus Arteriosus



TRICUSPID ATRESIA

- Hypoplastic RV
- Needs a shunt, ASD, VSD, or PDA
- High mortality

Total Anomalous Pulmonary Venous Connection (TAPVC)

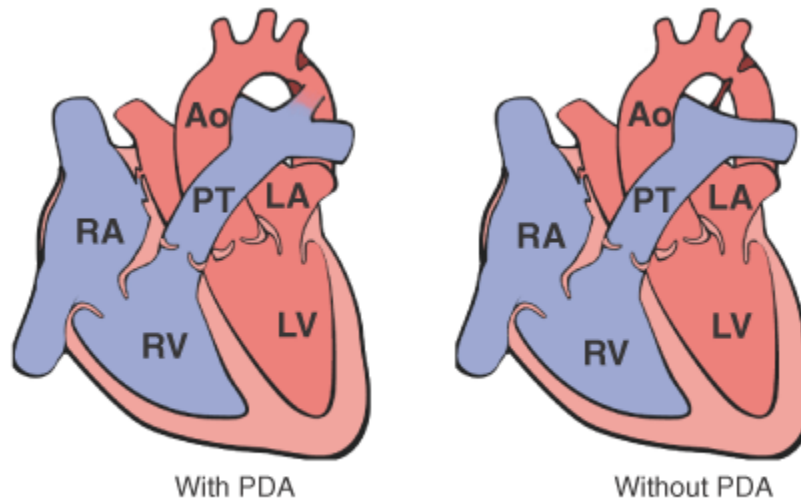
- PULMONARY VEINS do NOT go into LA, but into L. innominate v. or coronary sinus
- Needs a PFO or a VSD
- HYPOPLASTIC LA

OBSTRUCTIVE CHD

- **COARCTATION of aorta**
- **Pulmonary stenosis/atresia**
- **Aortic stenosis/atresia**

COARCTATION of AORTA

- M>F
- But XO's frequently have it
- INFANTILE FORM (proximal to PDA) (**SERIOUS**)
- ADULT FORM (CLOSED DUCTUS)
- Bicuspid aortic valve 50% of the time



Coarctation of Aorta

PULMONIC STENOSIS/ATRESIA

- If 100% atretic, hypoplastic RV with ASD
- Clinical severity ~ stenosis severity

AORTIC STENOSIS/ATRESIA

- **VALVULAR**
 - If severe, hypoplastic LV → fatal
- **SUB-valvular (subaortic)**
 - Aortic wall **THICK BELOW** cusps
- **SUPRA-valvular**
 - Aortic wall **THICK ABOVE** cusps in ascending aorta

HEART DISEASE

- CONGENITAL (CHD)

- **ISCHEMIC (IHD)**

- HYPERTENSIVE (HHD)

- VALVULAR (VHD)

- MYOPATHIC (MHD)

SYNDROMES of IHD

- Angina Pectoris: Stable, Unstable
- Myocardial Infarction (MI, AMI)
- Chronic IHD → CHF (CIHD)
- Sudden Cardiac Death (SCD)

- “Acute” Coronary Syndromes:
 - UNSTABLE ANGINA
 - AMI
 - SCD (Sudden Cardiac Death)

IHD RISK

- Number of plaques
- Distribution of plaques
- Size, structure of plaques

ACUTE CORONARY SYNDROMES

- *“The acute coronary syndromes are frequently initiated by an unpredictable and abrupt conversion of a stable atherosclerotic plaque to an unstable and potentially life-threatening atherothrombotic lesion through superficial erosion, ulceration, fissuring, rupture, or deep hemorrhage, usually with superimposed thrombosis.”*

EPIDEMIOLOGY

- ½ million die of IHD yearly in USA
- 1 million in 1963. Why?
 - Prevention of control controllable risk factors
 - Earlier, better diagnostic methods
 - PTCA, CABG, arrhythmia control
- **90%** of IHD patients have **ATHEROSCLEROSIS** (no surprise here)

ACUTE CORONARY SYNDROME FACTORS

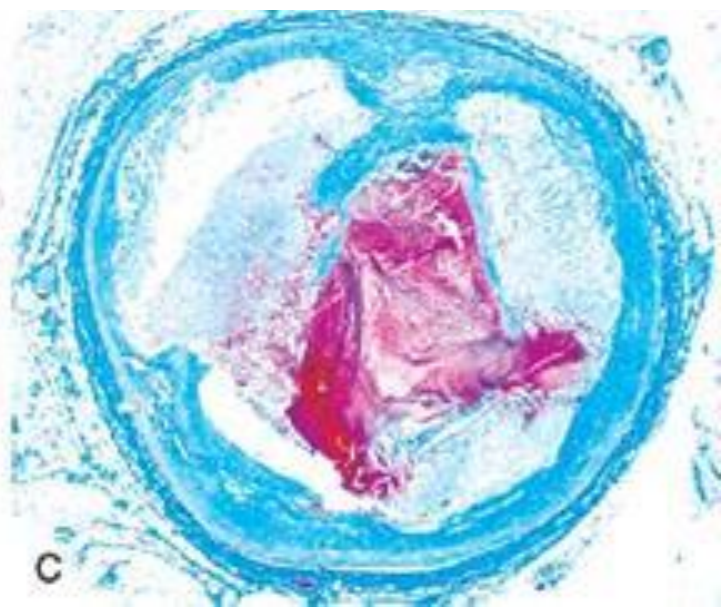
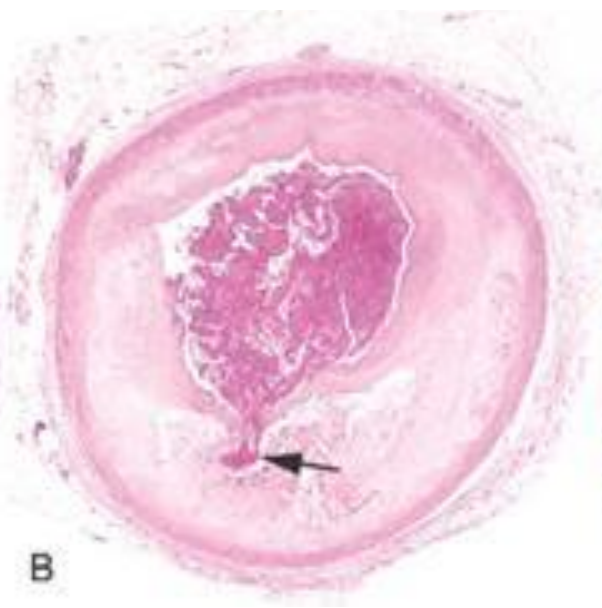
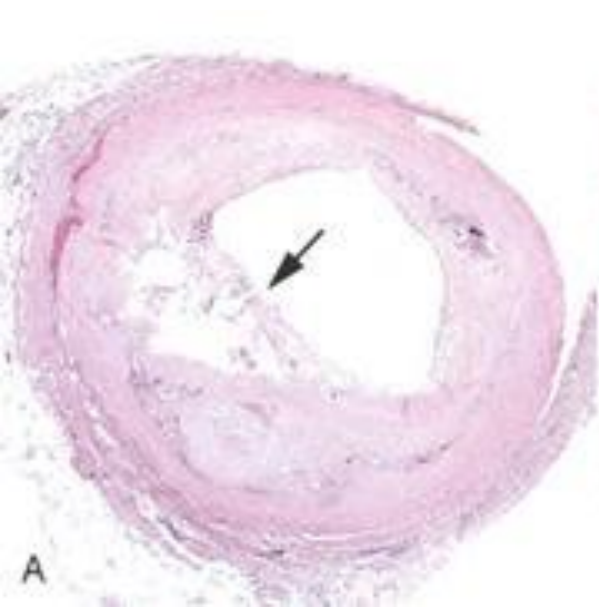
- ACUTE PLAQUE **CHANGE** *****
- Inflammation
- Thrombus
- Vasoconstriction

***** MOST IMPORTANT

ACUTE PLAQUE CHANGE

- Rupture/Refissuring
- Erosion/Ulceration, exposing ECM
- Acute Hemorrhage

NB: Plaques do NOT have to be severely stenotic to cause acute changes, i.e., 50% of AMI results from thromboses of plaques showing LESS THAN 50% stenosis



INFLAMMATION

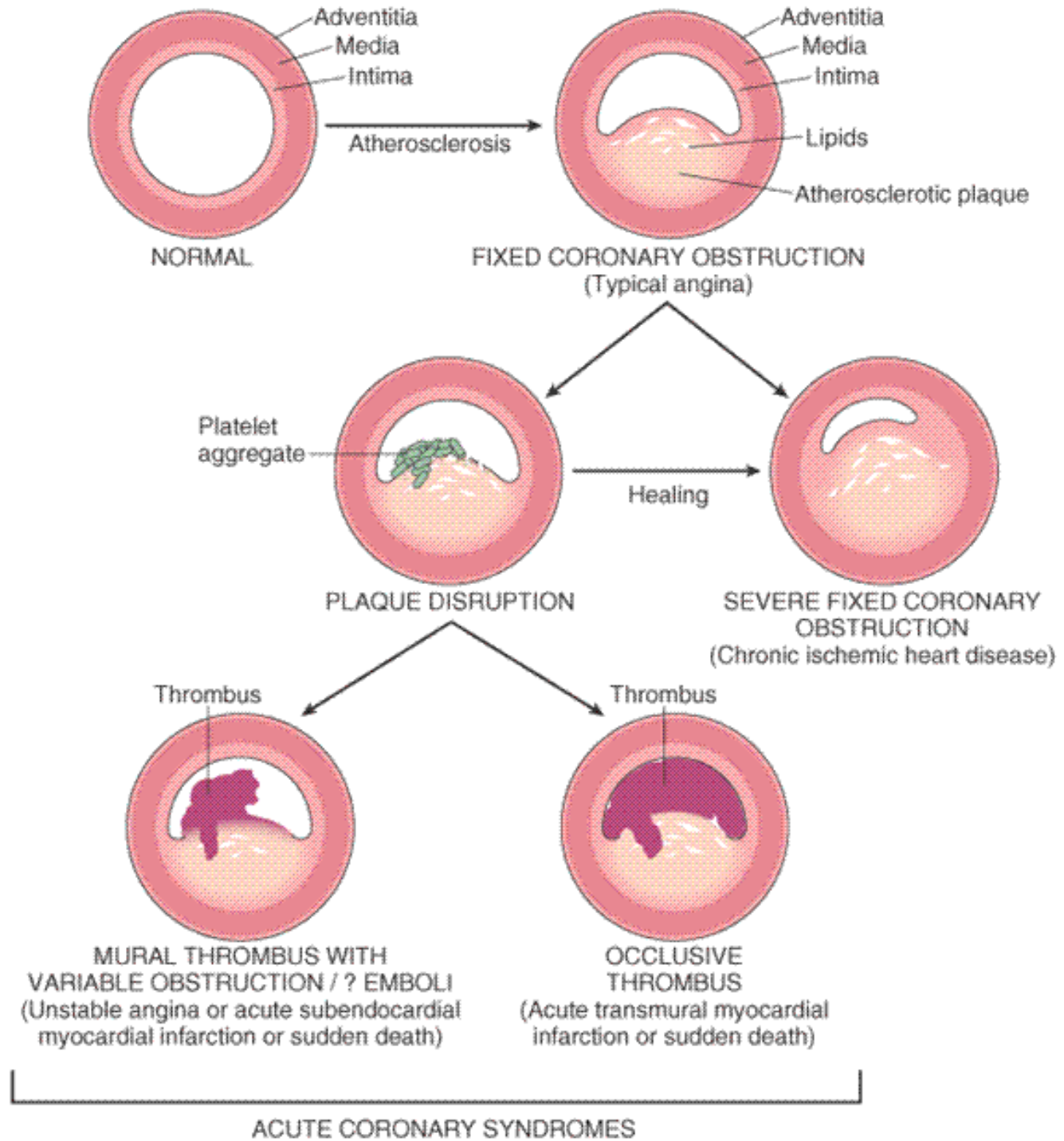
- Endothelial cells release CAMs, selectins
- T-cells release TNF, IL-6, IFN-gamma to stimulate and activate endothelial cells and macrophages
- CRP predicts the probability of damage in angina patients

THROMBUS

- Total occlusion
- Partial
- Embolization

VASOCONSTRICTION

- Circulating adrenergic agonists
- Platelet release products
- Endothelially released factors, such as endothelin



Coronary Artery Pathology in Ischemic Heart Disease

Syndrome	Stenoses	Plaque Disruption	Plaque-Associated Thrombus
Stable angina	>75%	No	No
Unstable angina	Variabl	Frequent	Nonocclusive, often with
Transmural myocardial infarction	Variabl	Frequent	Nonocclusive Occlusive thrombi
Subendocardial myocardial infarction	Variabl	Variable	Widely variable, may be absent, partial/complete, or
Sudden death myocardial infarction	Usuall y severe	Frequent	Often small platelet aggregates lysed or thrombi and/or thromboemboli

ANGINA PECTORIS

- Paroxysmal (sudden)
- Recurrent
- 15 sec. → 15 min.
- Reduced perfusion, but NO infarction
- **THREE TYPES**
 - **STABLE:** relieved by rest or nitro
 - **PRINZMETAL:** SPASM is main feature, responds to nitro, S-T elevation
 - **UNSTABLE** (crescendo, PRE-infarction, Q-wave angina): perhaps some thrombosis, perhaps some non transmural necrosis, perhaps some embolization, but **DISRUPTION** of PLAQUE is universally agreed upon

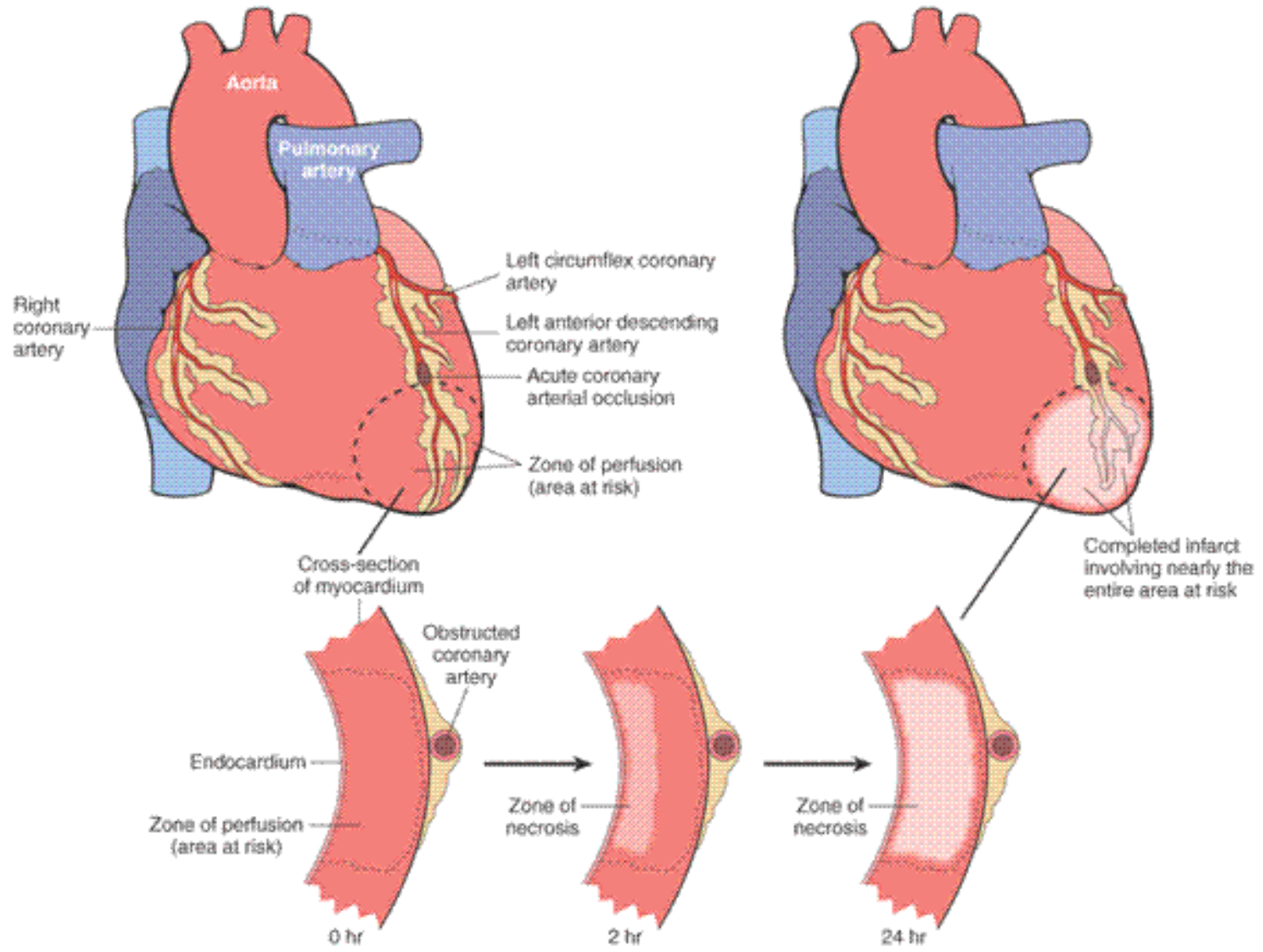
MYOCARDIAL INFARCTION

- Transmural vs. Subendocardial (inner 1/3)
- DUH! EXACT SAME risk factors as atherosclerosis
- Most are TRANSMURAL, and MOST are caused by coronary artery occlusion
- In the 10% of transmural MIs NOT associated with atherosclerosis:
 - Vasospasm
 - Emboli
 - UNexplained

MYOCARDIAL RESPONSE

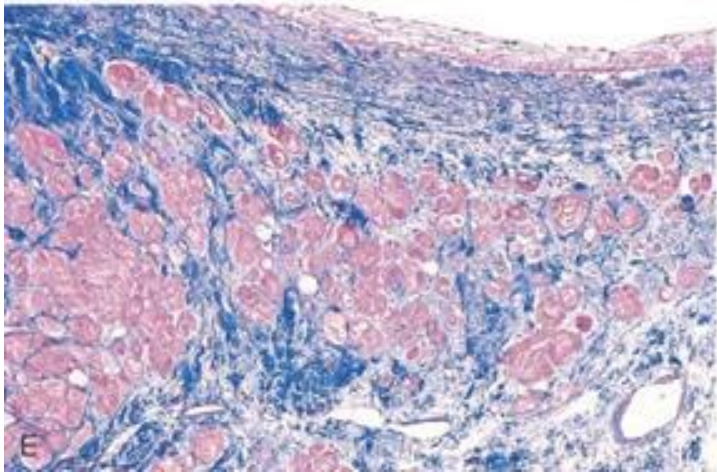
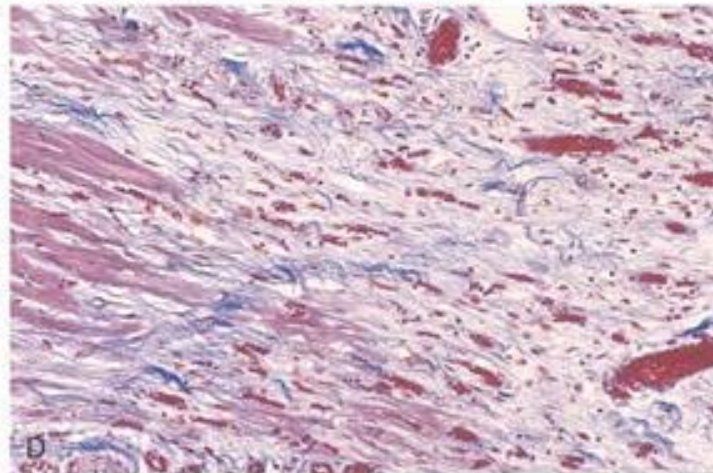
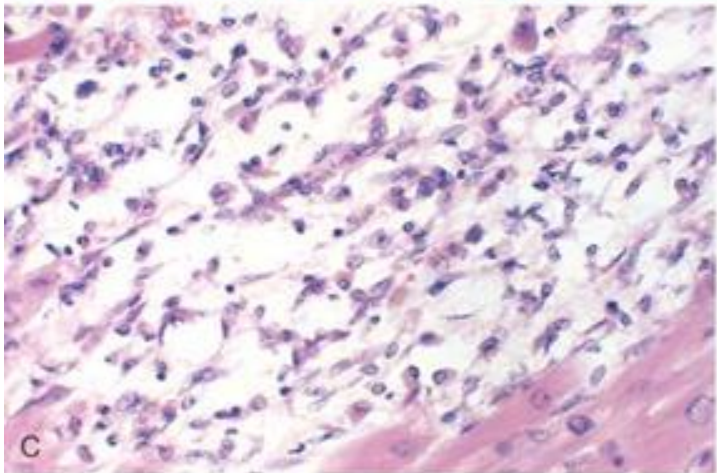
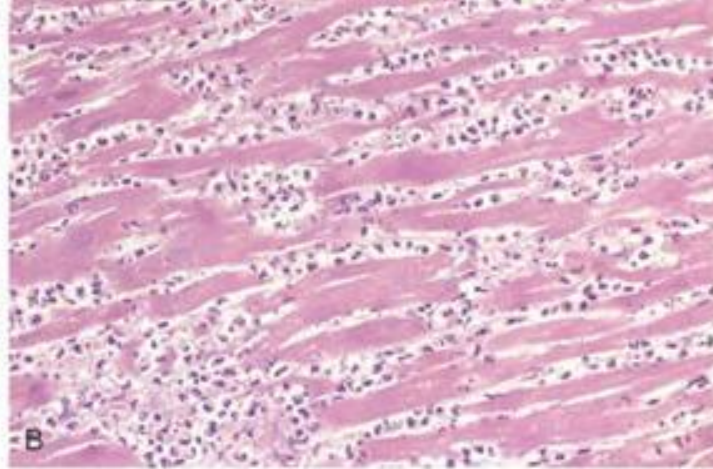
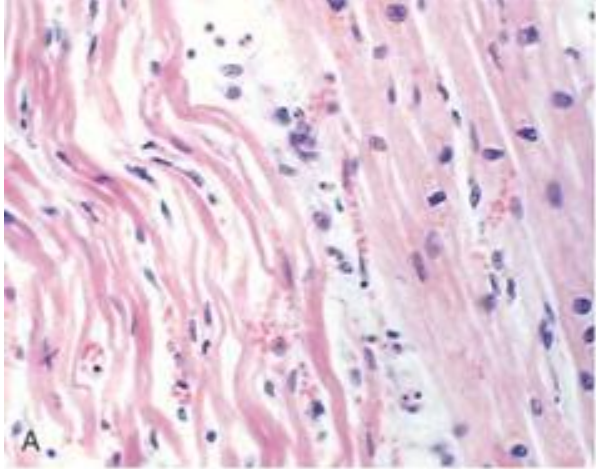
Feature	Time
Onset of ATP depletion	Seconds
Loss of contractility	<2 min
ATP reduced	
to 50% of normal	10 min
to 10% of normal	40 min
Irreversible cell injury	20–40 min
Microvascular injury	>1 hr

PROGRESSION OF NECROSIS



TIMING of Gross and Microscopic Findings

½–4 hr	None	Usually none; variable waviness of fibers at border
4–12 hr	Occasionally dark mottling	Beginning coagulation necrosis; edema; hemorrhage
12–24 hr	Dark mottling	Ongoing coagulation necrosis; pyknosis of nuclei; myocyte hypereosinophilia; marginal contraction band necrosis; beginning neutrophilic infiltrate
1–3 days	Mottling with yellow-tan infarct center	Coagulation necrosis, with loss of nuclei and striations; interstitial infiltrate of neutrophils
3–7 days	Hyperemic border; central yellow-tan softening	Beginning disintegration of dead myofibers, with dying neutrophils; early phagocytosis of dead cells by macrophages at infarct border
7–10 days	Maximally yellow-tan and soft, with depressed red-tan margins	Well-developed phagocytosis of dead cells; early formation of fibrovascular granulation tissue at margins
10–14 days	Red-gray depressed infarct borders	Well-established granulation tissue with new blood vessels and collagen deposition
2–8 wk	Gray-white scar, progressive from border toward core of infarct	Increased collagen deposition, with decreased cellularity
>2 mo	Scarring complete	Dense collagenous scar



1 day, 3-4 days, 7 days, weeks, months

RE-PERFUSION

- Thrombolysis
- PTCA
- CABG

- Reperfusion CANNOT restore necrotic or dead fibers, only reversibly injured ones

- REPERFUSION “INJURY”
 - Free radicals
 - Interleukins

AMI DIAGNOSIS

- SYMPTOMS
- EKG
- DIAPHORESIS
- (10% of MIs are “SILENT” with Q-waves)
- CKMB gold standard enzyme
- Troponin-I, Troponin-T better
- CRP predicts risk of AMI in angina patients

COMPLICATIONS

- **Wall motion abnormalities**
- **Arrhythmias**
- **Rupture (4-5 days)**
- **Pericarditis**
- **RV infarction**
- **Infarct extension**
- **Mural thrombus**
- **Ventricular aneurysm**
- **Papillary muscle dysfunction (regurgitation)**
- **CHF**

CIHD, aka, ischemic “cardiomyopathy”

- **Progress to CHF often with no pathologic or clinical evidence of localized infarction**
 - **Extensive atherosclerosis**
 - **No infarct**
 - **H&D present**

SUDDEN CARDIAC DEATH

- 350,000 in USA yearly from atherosclerosis
- NON-atherosclerotic sudden cardiac death includes:
 - Congenital coronary artery disease
 - Aortic stenosis
 - MVP
 - Myocarditis
 - Cardiomyopathy (sudden death in young athletes)
 - Pulmonary hypertension
 - Conduction defects
 - HTN, hypertrophy of UNKNOWN etiology

AUTOPSY findings in SCD

- >75% narrowing of 1-3 vessels
- Healed infarcts 40%
- “ARRHYTHMIA” is often a very convenient conclusion when no anatomic findings are present, i.e., “wastebasket” diagnosis

HEART DISEASE

- CONGENITAL (CHD)
- ISCHEMIC (IHD)
- **HYPERTENSIVE (HHD)**
- VALVULAR (VHD)
- MYOPATHIC (MHD)

HHD (Left)

- **DEFINITION:** Hypertrophic adaptive response of the heart, which can progress:
 - Myocardial dysfunction
 - Cardiac dilatation
 - CHF
 - Sudden death

NEEDED for DIAGNOSIS:

- LVH (LV>2.0 and/or Heart>500 gm.)
- HTN (>140/90)

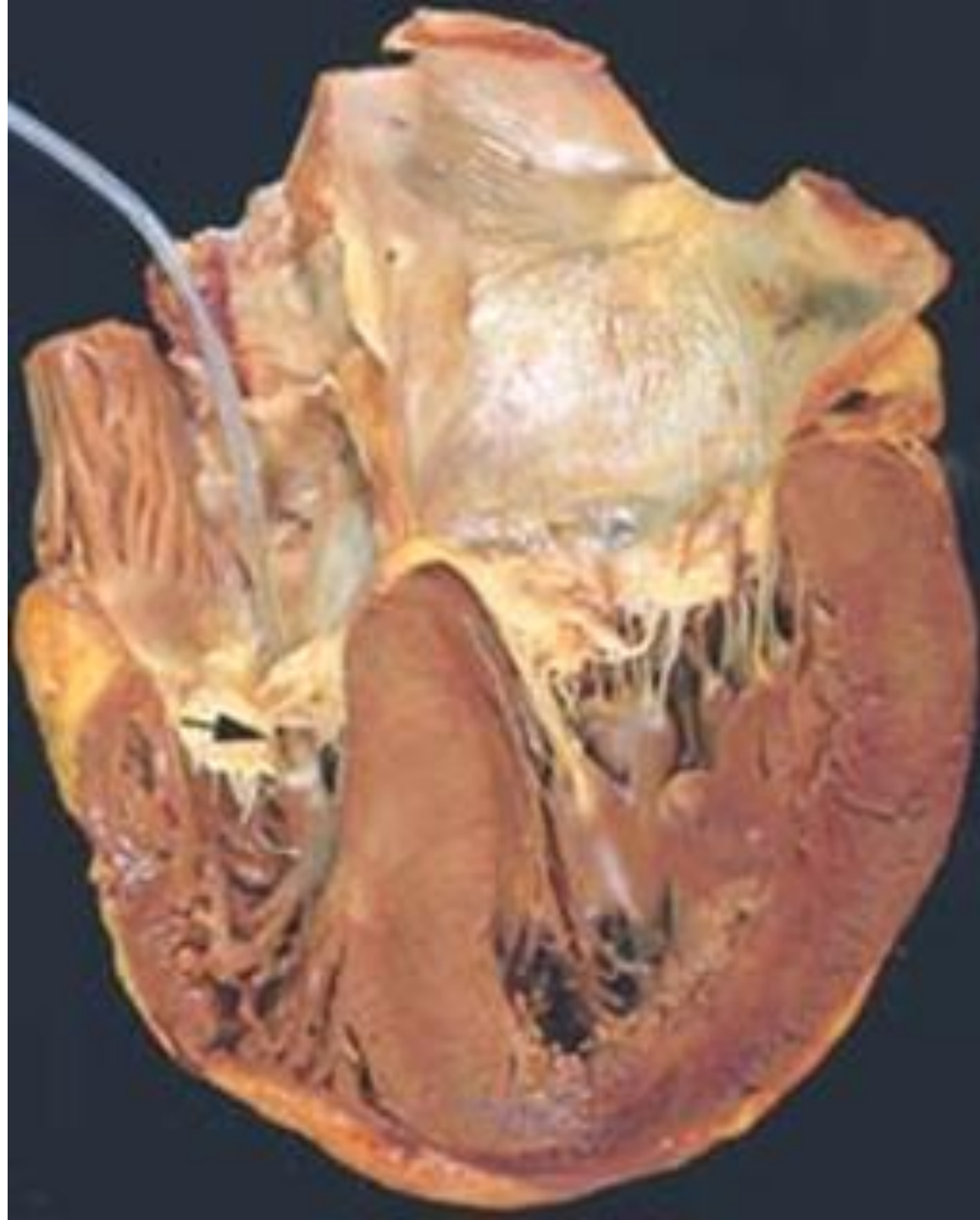PREVALENCE:

- **WHAT % of USA people have hypertension?**

PREVALENCE:

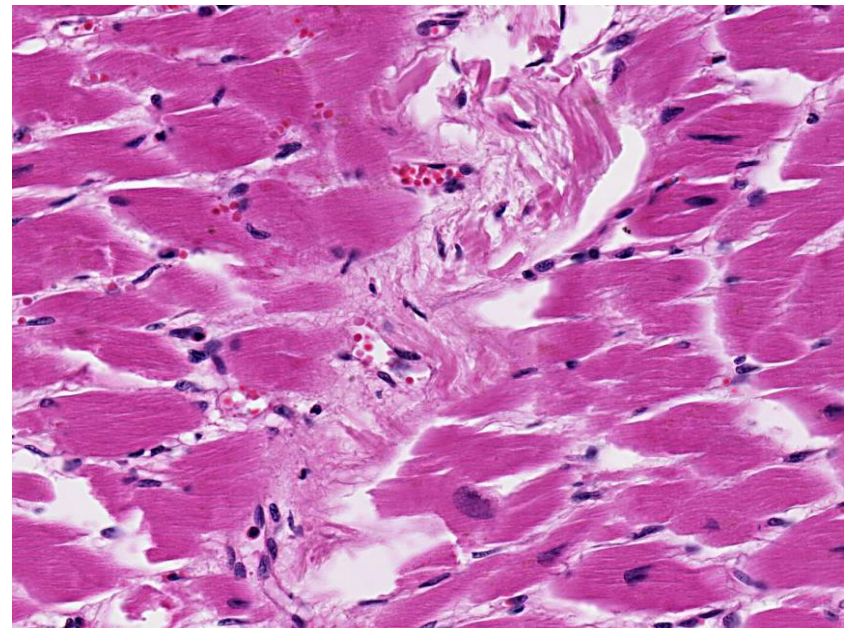
- WHAT % of USA people have hypertension?

- Answer: **25%**



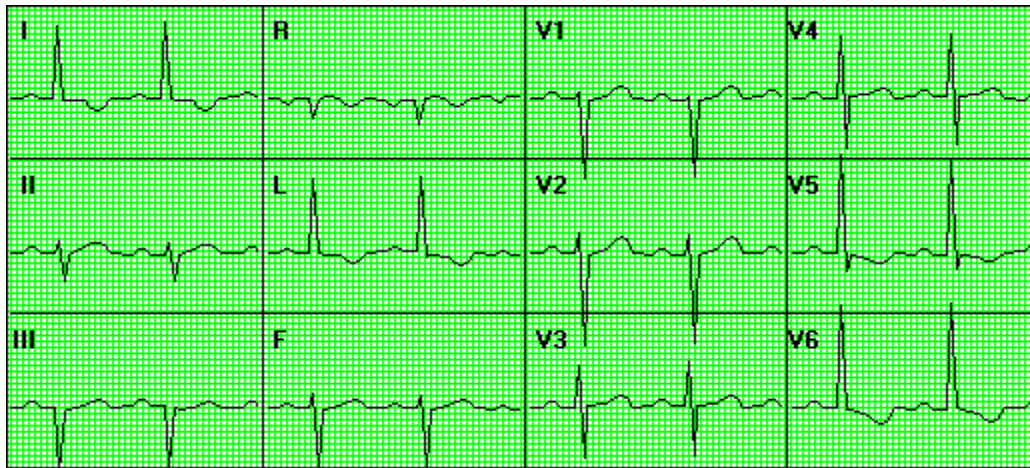
HISTOPATHOLOGY

- **INCREASED** FIBER (MYOCYTE) THICKNESS
- **INCREASED** nuclear size with increased “blockiness” (boxcar nucleus)



CLINICAL

- EKG



Summary of LVH

Criteria

- 1) $R-I + S-III > 25$ mm
- 2) $S-V1 + R-V5 > 35$ mm

3) ST-Ts in left leads

4) $R-L > 11$ mm

5) LAE + other criteria

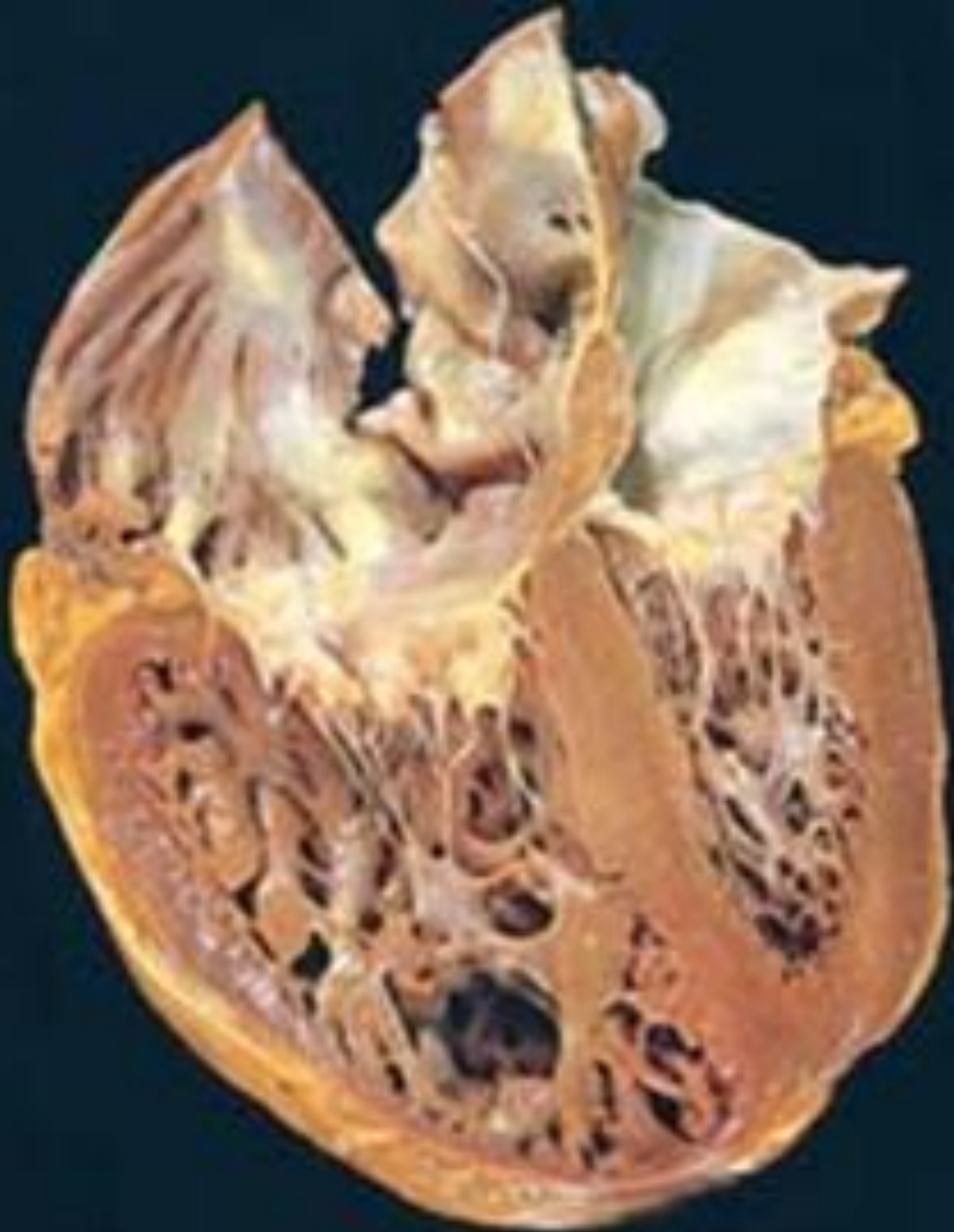Positive Criteria:

1=possible 2=probable
3=definite

ATRIAL FIBRILLATION

Why?

CHF, cardiac dilatation, pulmonary venous congestion and dilatation



COURSE:

- **NORMAL** longevity, death from other causes
- **Progressive IHD**
- **Progressive renal damage, hemorrhagic CVA** (Which arteries?)
- **CHF**

HHD (Right) = COR PULMONALE

- **ACUTE:** Massive PE
- **CHRONIC:** COPD, CRPD, Pulmonary artery disease, chest wall motion impairment

Diseases of the Pulmonary Parenchyma

Chronic obstructive pulmonary disease

Diffuse pulmonary interstitial fibrosis

Pneumoconioses

Cystic fibrosis

Bronchiectasis

Diseases of the Pulmonary Vessels

Recurrent pulmonary thromboembolism

Primary pulmonary hypertension

Extensive pulmonary arteritis

Disorders Affecting Chest

Movement

Kyphoscoliosis

Marked obesity (pickwickian syndrome)

Neuromuscular diseases

Disorders Inducing Pulmonary Arterial Constriction

Metabolic acidosis

Hypoxemia

HEART DISEASE

- CONGENITAL (CHD)
- ISCHEMIC (IHD)
- HYPERTENSIVE (HHD)
- **VALVULAR (VHD)**
- MYOPATHIC (MHD)

V_{alvular} HD

- **Opening problems: Stenosis**
- **Closing problems: Regurgitation or Incompetence**

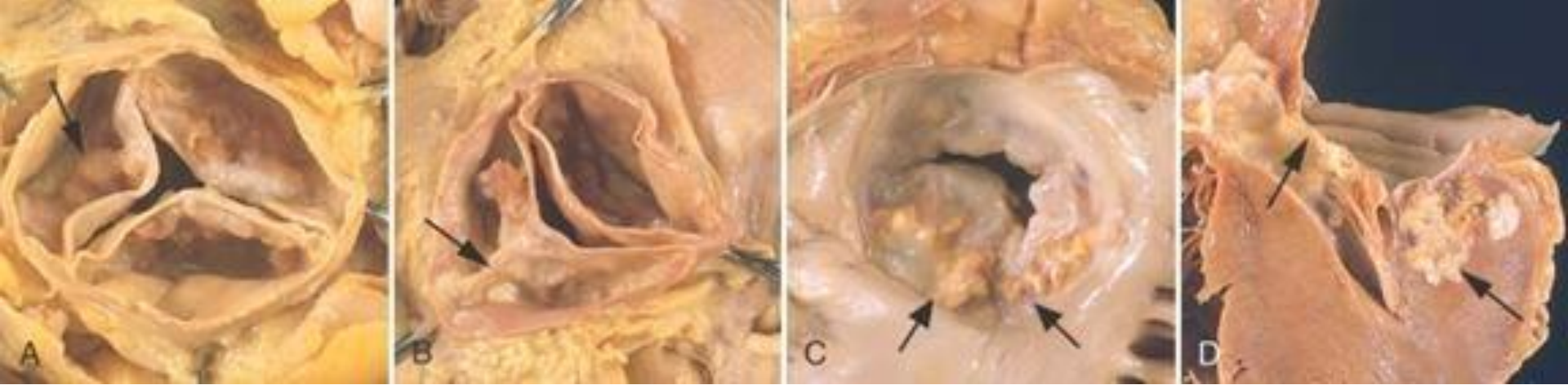
70% of all VHD

•AS

- Calcification of a deformed valve
- “Senile” calcific AS
- Rheum, Heart Dis.

•MS

- Rheumatic Heart Disease



AORTIC STENOSIS

2X gradient pressure

LVH, ischemia

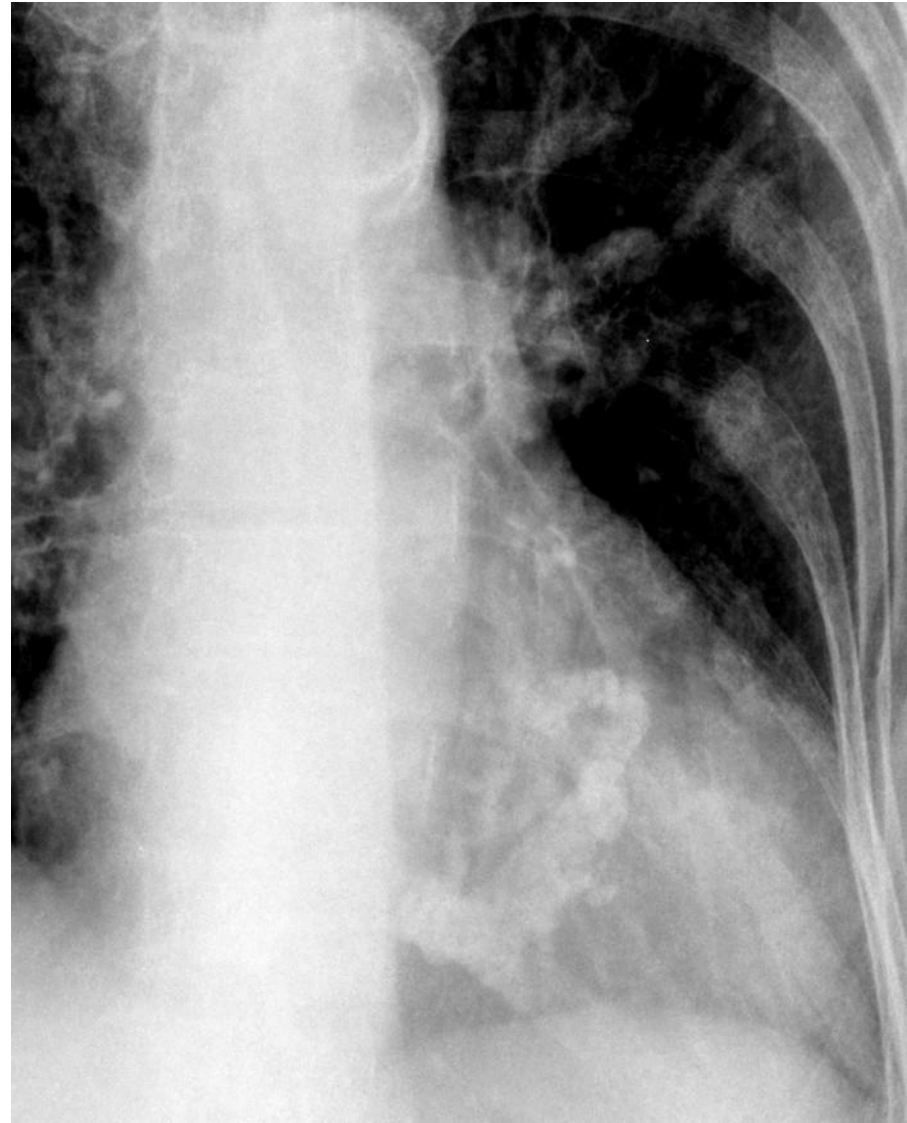
Cardiac decompensation, angina, CHF

50% die in 5 years if angina present

50% die in 2 years if CHF present

MITRAL ANNULAR CALCIFICATION

- Calcification of the mitral “skeleton”
- Usually NO dysfunction
- Regurgitation or Stenosis possible
- F>>M



REGURGITATIONS

• AR

- Rheumatic
- Infectious
- Aortic dilatations
 - Syphilis
 - Rheumatoid Arthritis
 - Marfan

• MR

• MVP

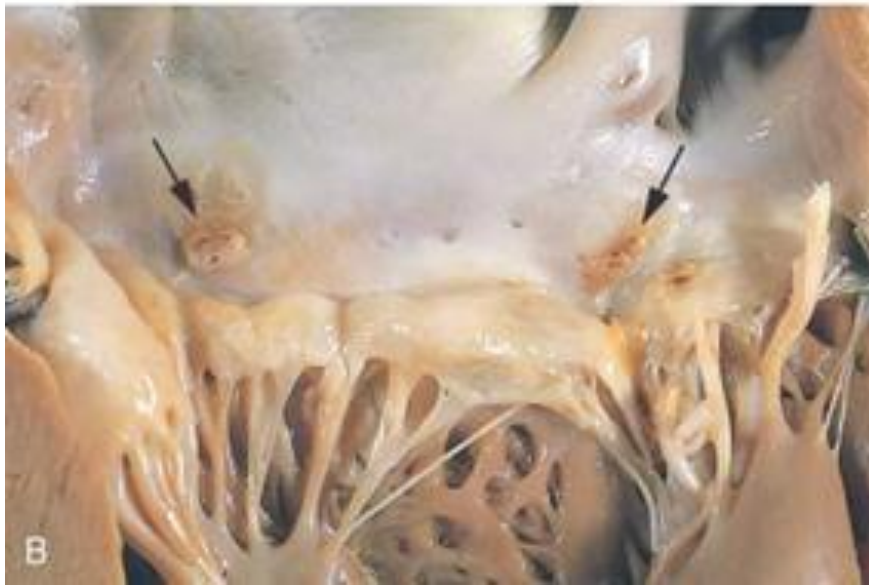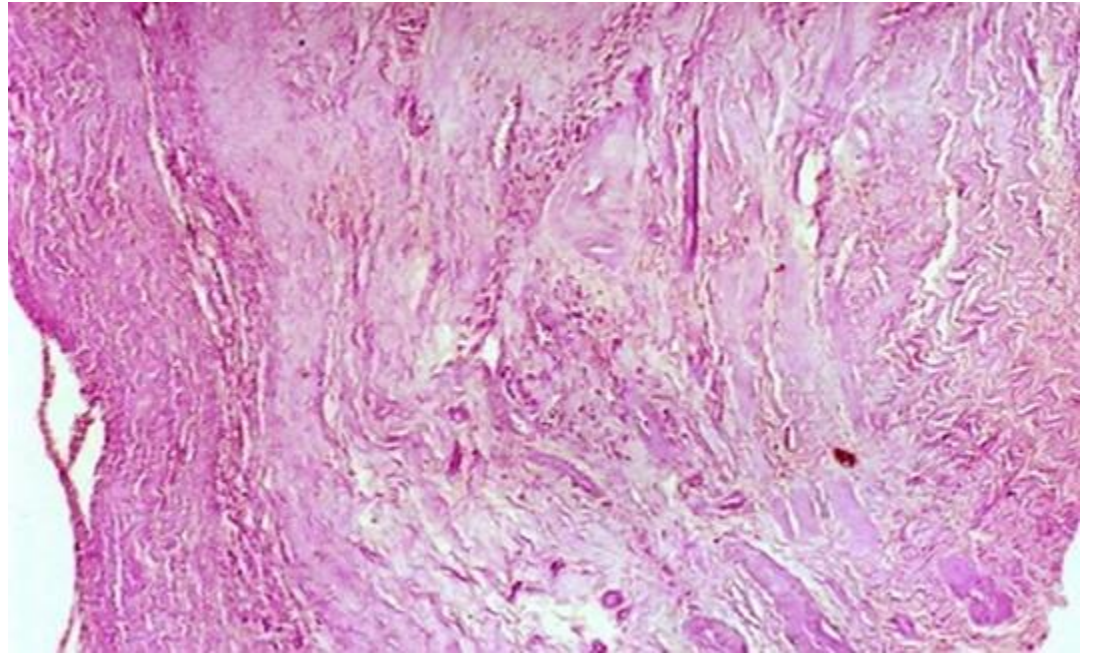
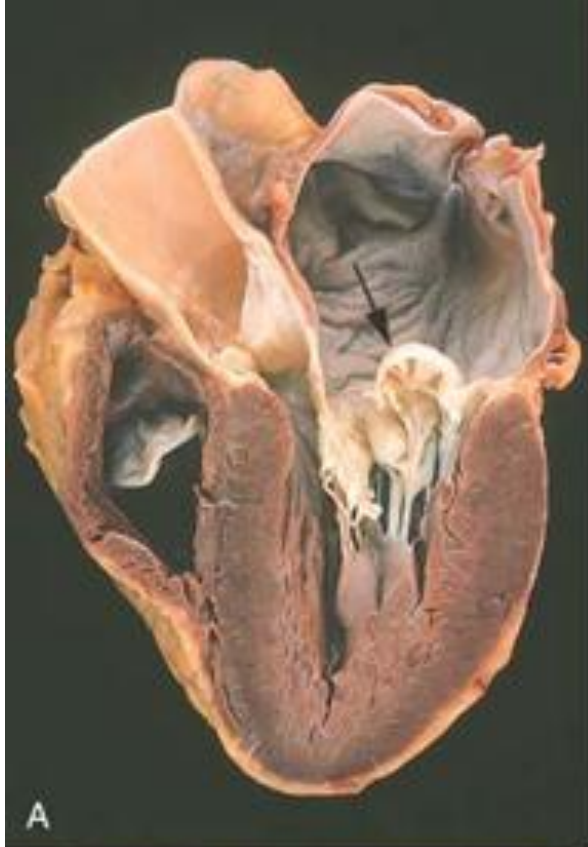- Infectious
- Fen-Phen
- Papillary muscles, chordae tendinae
- Calcification of mitral ring (annulus)

Mitral Valve Prolapse (MVP)

- MYXOMATOUS degeneration of the mitral valve
- Associated with connective tissue disorders
- “Floppy” valve
- 3% incidence, F>>M
- Easily seen on echocardiogram

MVP: CLINICAL FEATURES

- Usually asymptomatic
- Mid-systolic “click”
- Holosystolic murmur if regurg. present
- Occasional chest pain, dyspnea
- 97% NO untoward effects
- 3% Infective endocarditis, mitral insufficiency, arrhythmias, sudden death

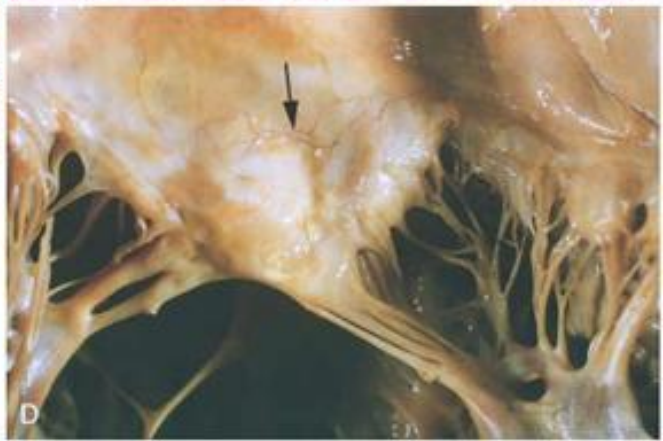
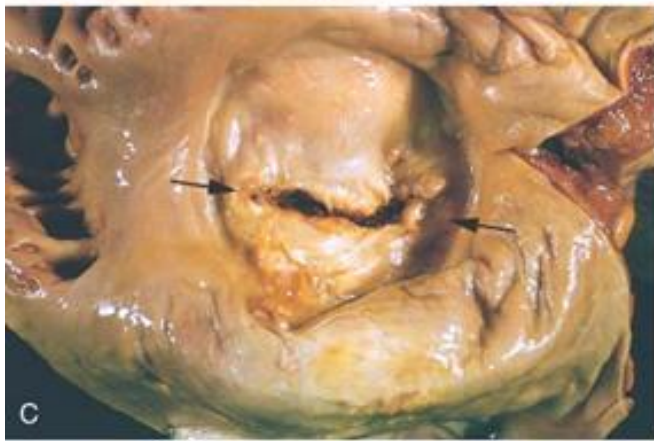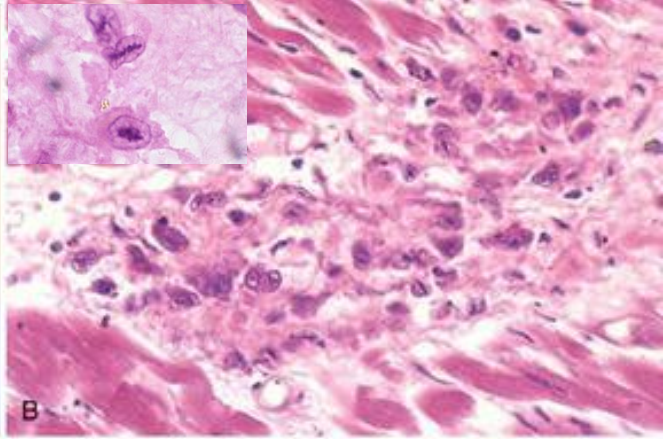
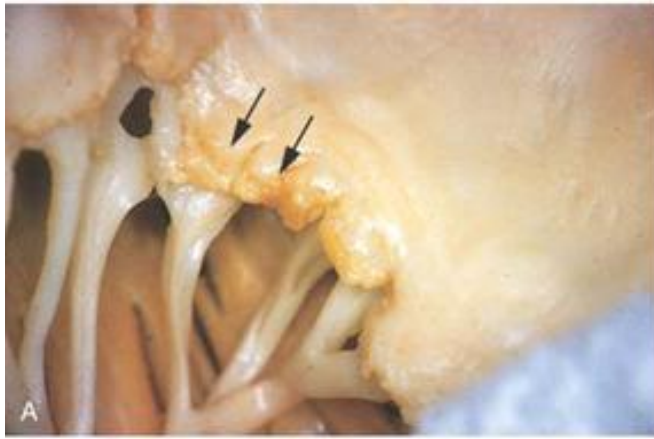


RHEUMATIC Heart Disease

- Follows a group A strep infection, a few weeks later
- DECREASE in “developed” countries
- PANCARDITIS

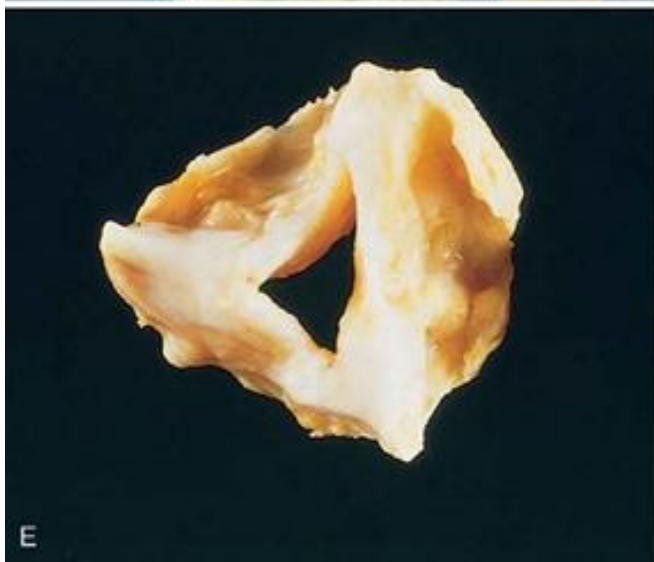
ACUTE:

- Inflammation
- Aschoff bodies
- Anitschkow cells
- Pancarditis
- Vegetations on chordae tendinae at leaflet junction



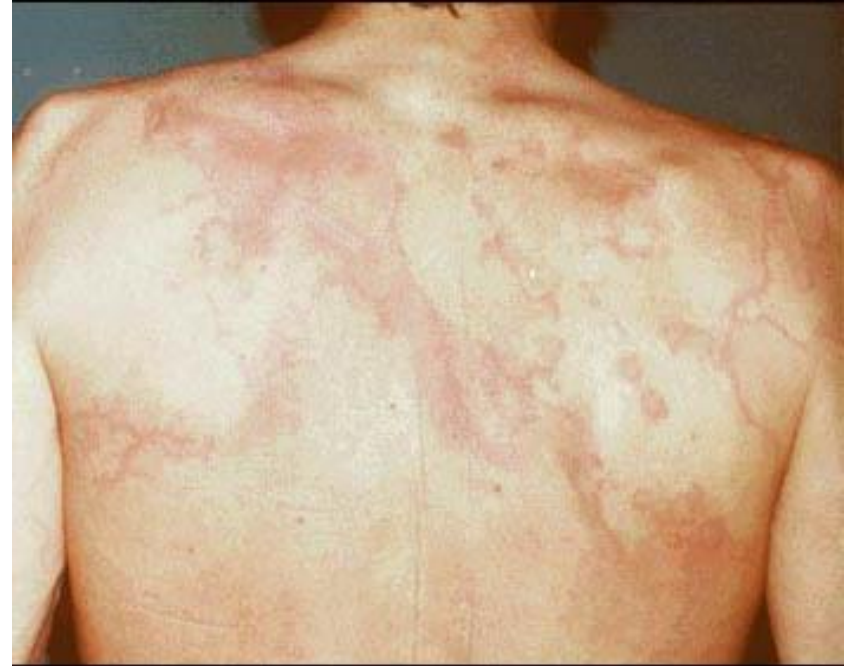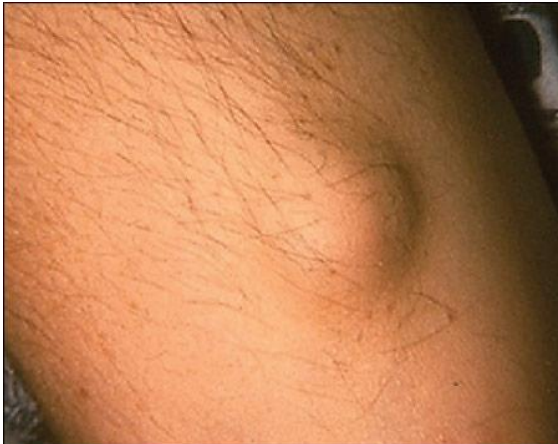CHRONIC:

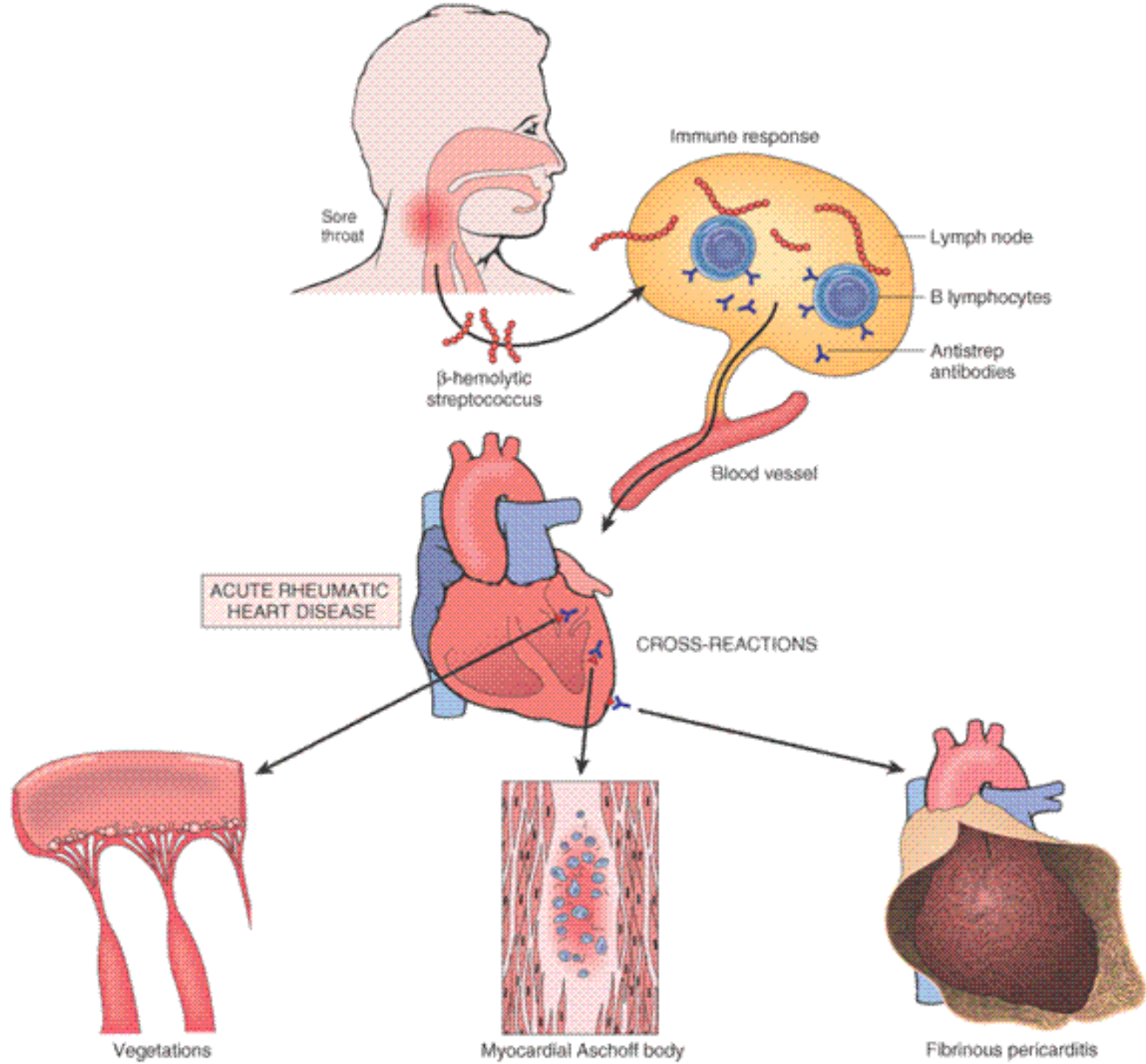
- THICKENED VALVES
- COMMISURAL FUSION
- THICK, SHORT, CHORDAE



CLINICAL FEATURES

- Migratory Polyarthritits
- Myocarditis
- Subcutaneous nodules
- Erythema marginatum
- Sydenham chorea





INFECTIOUS ENDOCARDITIS

- **Microbes**

- Usually **strep viridans**

- Often Staph aureus in IVD users

- Enterococci

- **HAČEK** (normal oral flora)

- Hemophilus influenzae

- Actinobacillus

- Cardiobacterium

- Eikenella

- Kingella

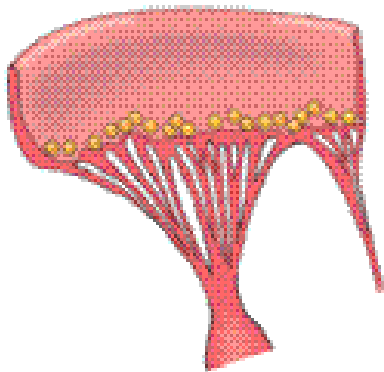
- Fungi, rickettsiae, chlamydia

INFECTIOUS ENDOCARDITIS

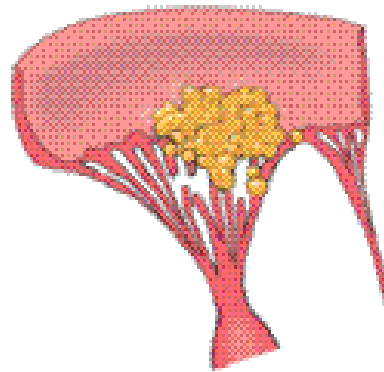
- **Acute: 50% mortality (course=days)**
- **SUB-acute: LOW mortality (course=weeks)**

VEGETATIONS

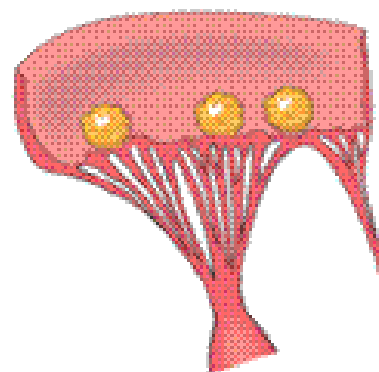
- INFECTIVE >5mm
- NON-Infective <5mm



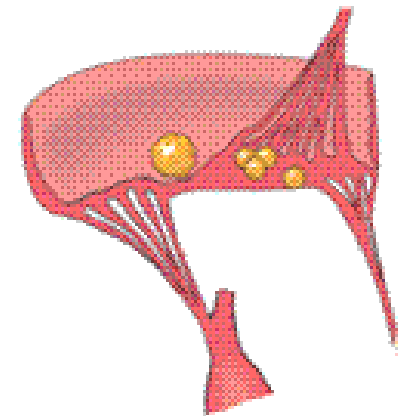
RHD



IE



NBTE

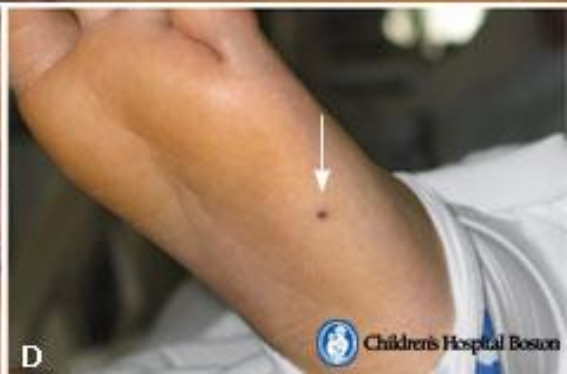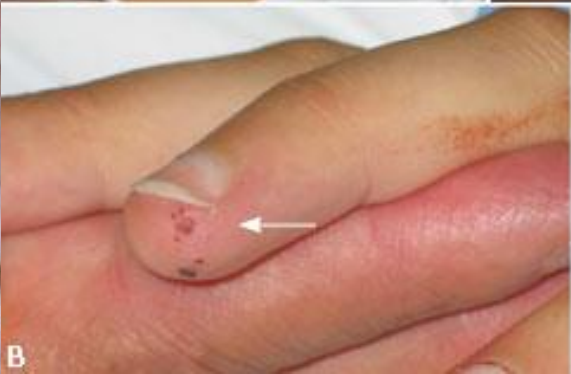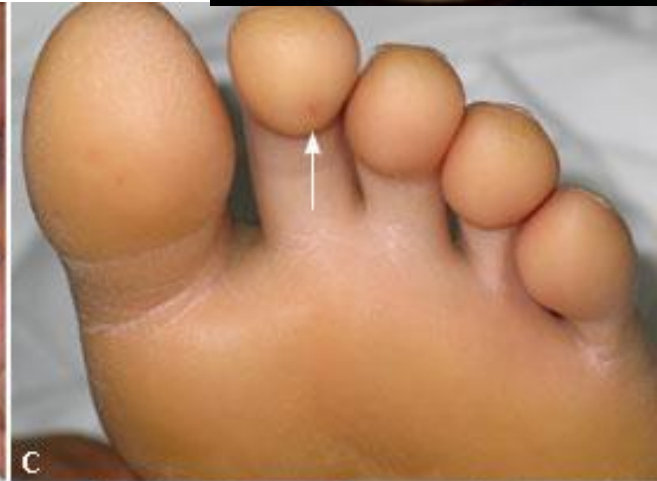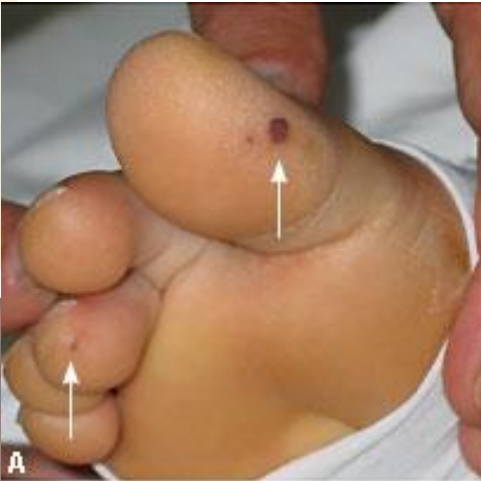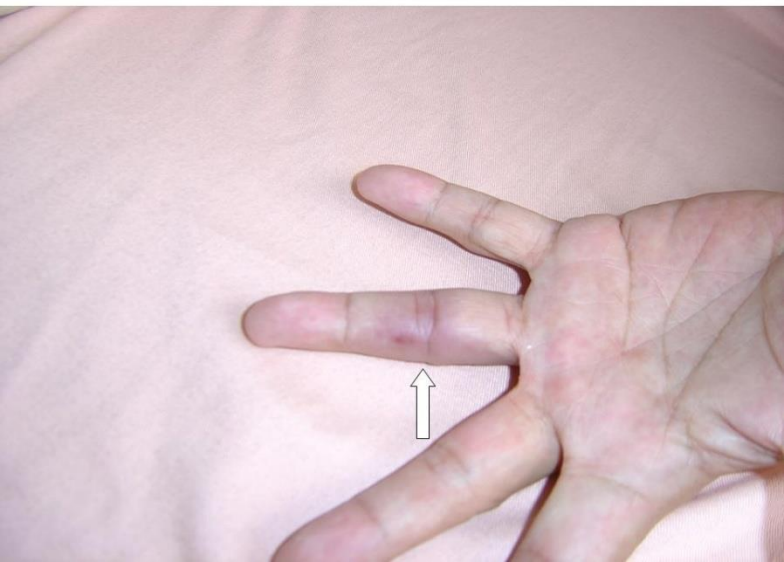


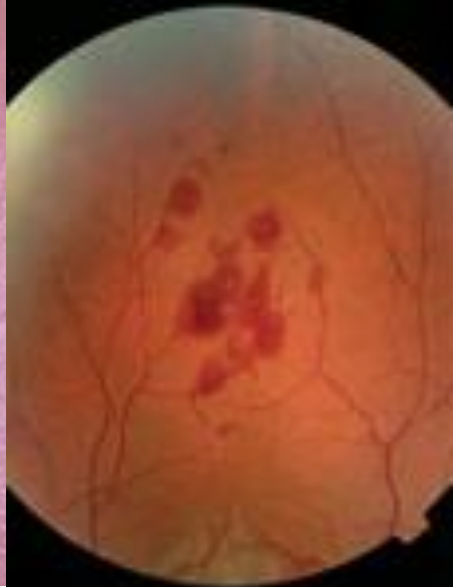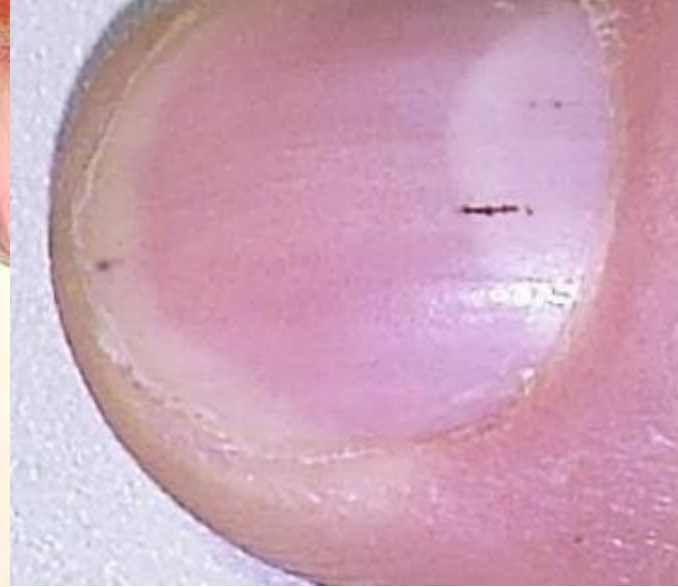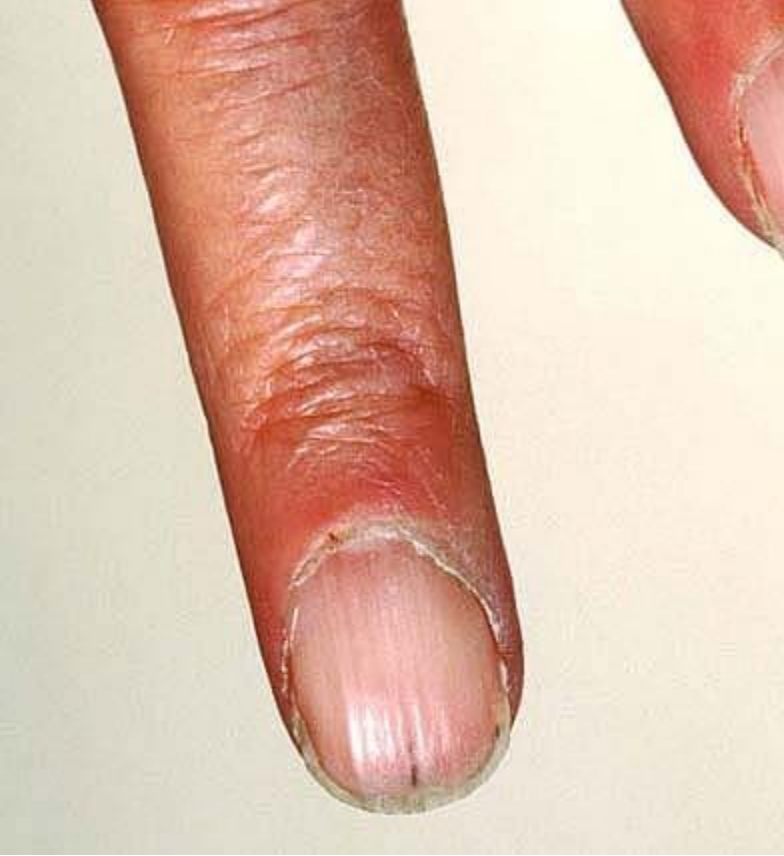LSE

DIAGNOSIS=MM_m, M_{mmm}, mmmmm

• MAJOR

- Positive blood culture(s) indicating characteristic organism or persistence of unusual organism
 - Echocardiographic findings, including valve-related or implant-related mass or abscess, or partial separation of artificial valve
 - New valvular regurgitation
-
- **minor**
 - Predisposing heart lesion or intravenous drug use
 - Fever
 - Vascular lesions, including arterial petechiae, subungual/splinter hemorrhages, emboli, septic infarcts, mycotic aneurysm, intracranial hemorrhage, Janeway lesions
 - Immunologic phenomena, including glomerulonephritis, Osler nodes, Roth spots, rheumatoid factor
 - Microbiologic evidence, including single culture showing uncharacteristic organism
 - Echocardiographic findings consistent with but not diagnostic of endocarditis, including new valvular regurgitation, pericarditis

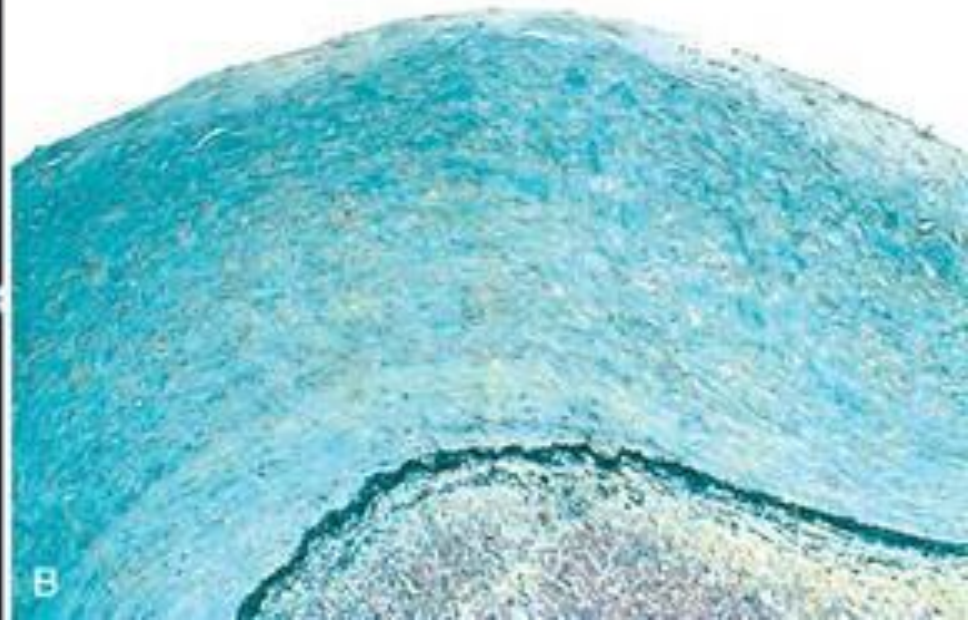
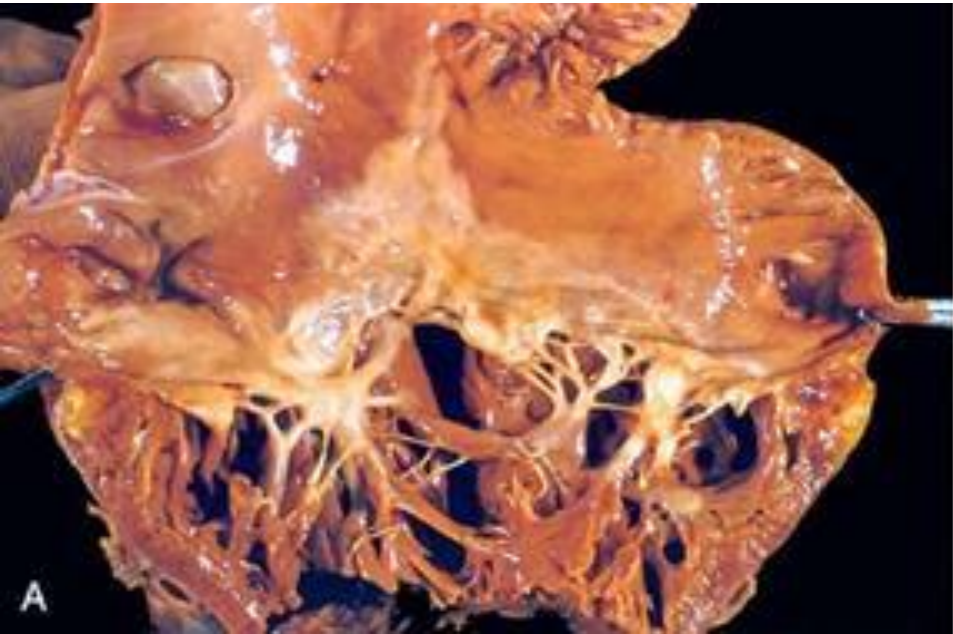


NON-infective VEGETATIONS

- <5 mm
- PE
- Trousseau syndrome (migratory thrombophlebitis with malignancies)
- s/p Swan-Ganz
- Libman-Saks with SLE (both sides of valve)

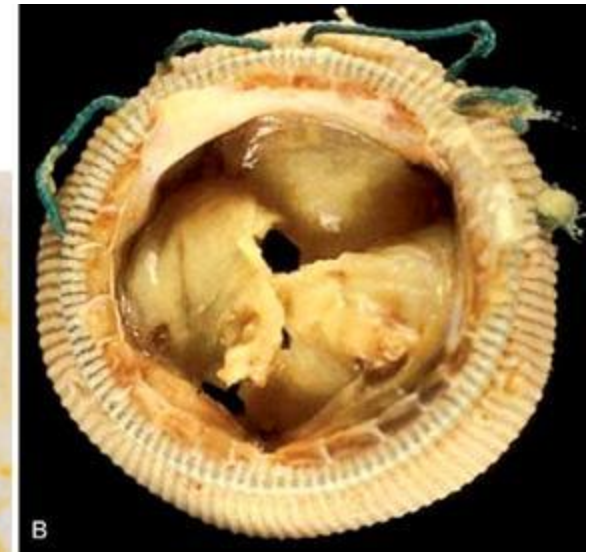
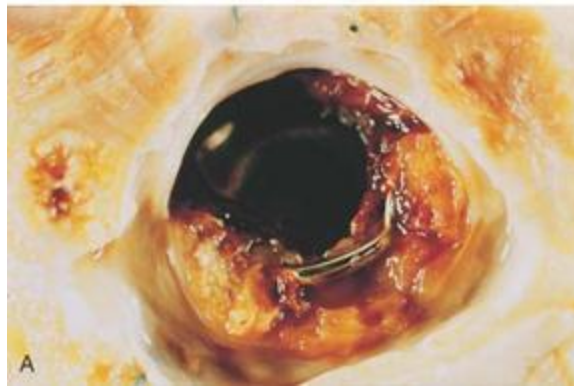Carcinoid Syndrome

- Episodic skin flushing
- Cramps
- Nausea & Vomiting
- Diarrhea
- ↑ serotonin, ↑ 5HIAA in urine
- **FIBROUS INTIMAL THICKENING**
 - RV, Tricuspid valve, Pulmonic valve (all RIGHT side)
 - Similar to what Fen-Phen does on the LEFT side



ARTIFICIAL VALVES

- Mechanical
- Xenografts (porcine)
- 60% have complications within 10 years

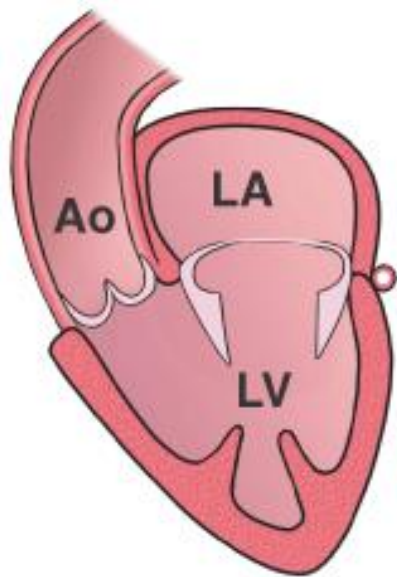


HEART DISEASE

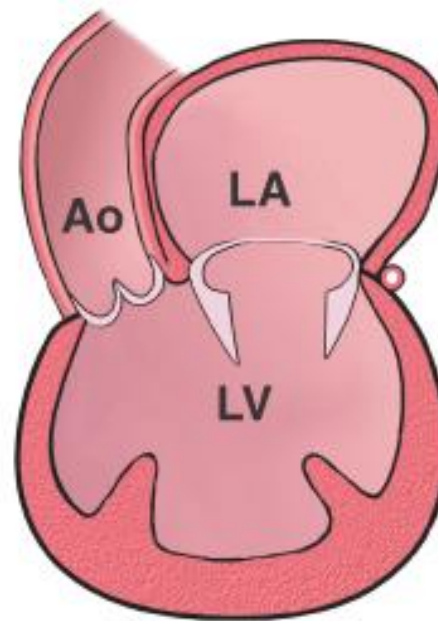
- CONGENITAL (CHD)
- ISCHEMIC (IHD)
- HYPERTENSIVE (HHD)
- VALVULAR (VHD)
- **MYOPATHIC (MHD)**
- PERICARDIAL DISEASE

CARDIOMYOPATHIES

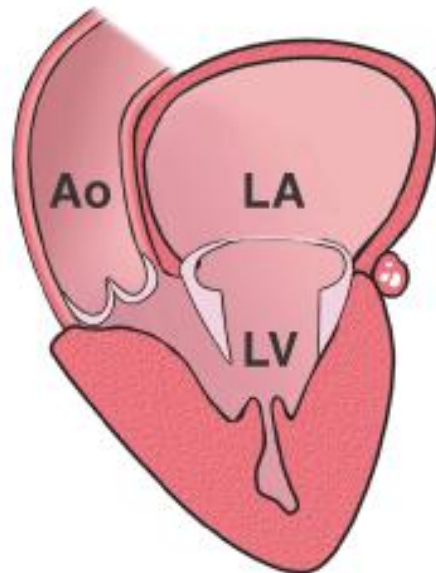
- Inflammatory
- Immunologic
- Metabolic
- Dystrophies
- Genetic
- Idiopathic
- DILATED (DCM)
 - SY-stolic dysfunction
- HYPERTROPHIC (HCM)
 - DIA-stolic dysfunction
- RESTRICTIVE (RCM)
 - DIA-stolic dysfunction



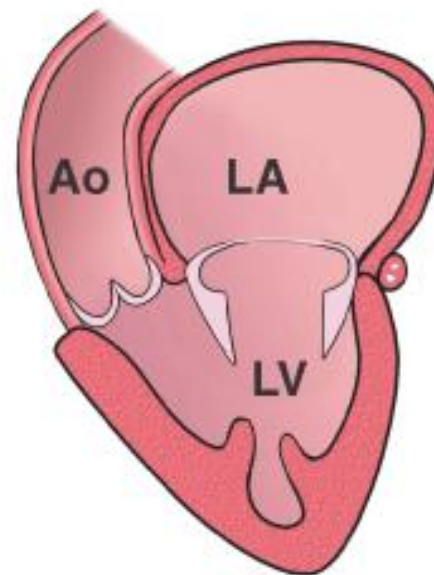
Normal



Dilated
cardiomyopathy



Hypertrophic
cardiomyopathy



Restrictive
cardiomyopathy

Functional Pattern	LVEF :	Mechanisms of Heart Failure	Causes	Indirect Myocardial Dysfunction (Not Cardiomyopathy)
Dilated	<40%	Impairment of contractility (systolic dysfunction)	Idiopathic; alcohol; peripartum; genetic; myocarditis; hemochromatosis; chronic anemia; doxorubicin (Adriamycin); sarcoidosis	Ischemic heart disease; valvular heart disease; hypertensive heart disease; congenital heart disease
Hypertrophic	50–80%	Impairment of compliance (diastolic dysfunction)	Genetic; Friedreich ataxia; storage diseases; infants of diabetic mothers	Hypertensive heart disease; aortic stenosis
Restrictive	45–90%	Impairment of compliance (diastolic dysfunction)	Idiopathic; amyloidosis; radiation-induced fibrosis	Pericardial constriction

Cardiac Infections

Viruses
Chlamydia
Rickettsia
Bacteria
Fungi
Protozoa

Neuromuscular Disease

Friedreich ataxia
Muscular dystrophy
Congenital atrophies

Immunologic

Myocarditis (several forms)
Post-transplant rejection

Toxins

Alcohol
Cobalt
Catecholamines
Carbon monoxide
Lithium
Hydrocarbons
Arsenic
Cyclophosphamide
Doxorubicin (Adriamycin) and daunorubicin

Storage Disorders and Other Depositions

Hunter-Hurler syndrome
Glycogen storage disease
Fabry disease
Amyloidosis

Metabolic

Hyperthyroidism
Hypothyroidism
Hyperkalemia
Hypokalemia
Nutritional deficiency (protein, thiamine, other avitaminoses)
Hemochromatosis

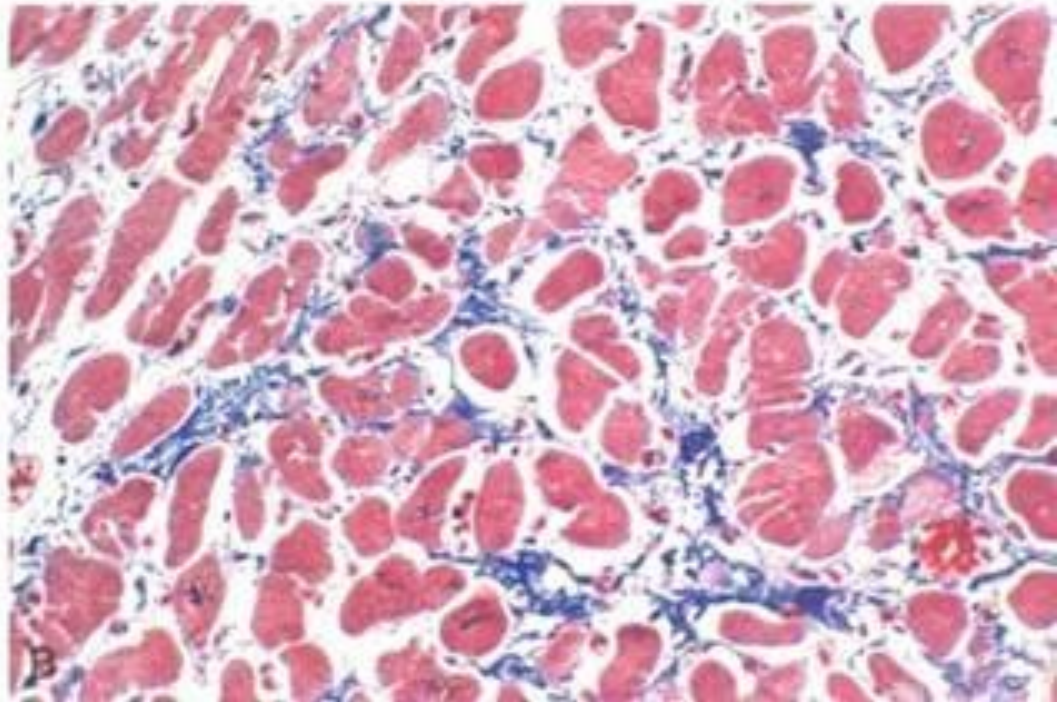
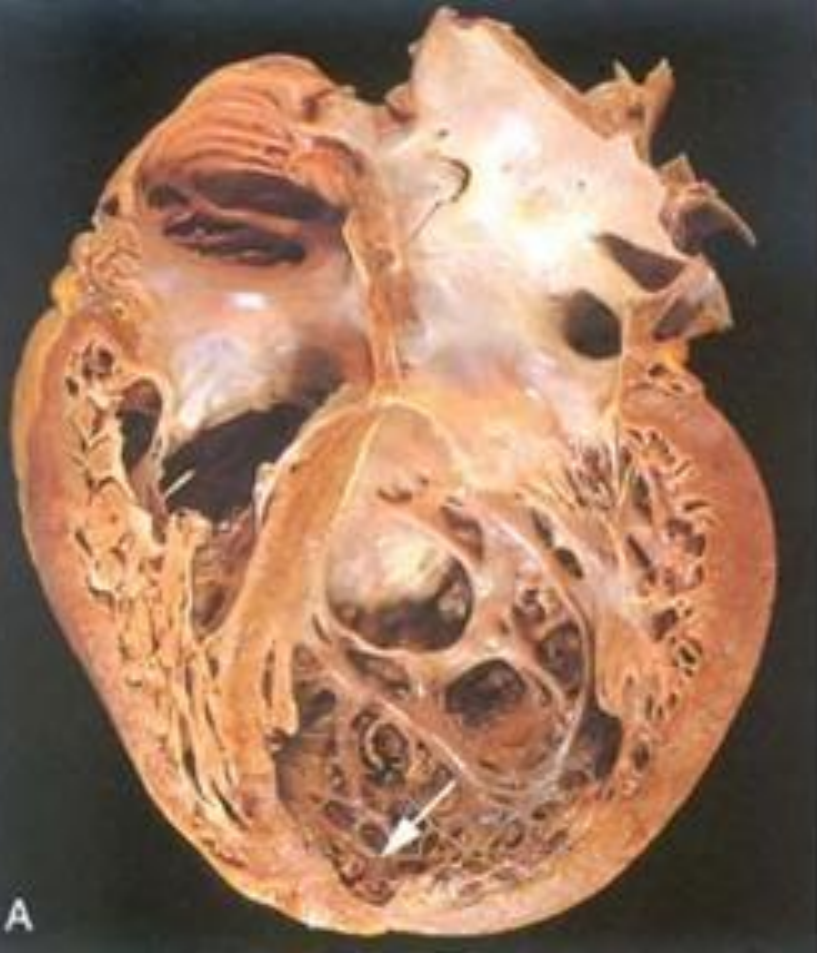Infiltrative

Leukemia
Carcinomatosis
Sarcoidosis
Radiation-induced fibrosis

DILATED cardiomyopathy

- Chamber thickness (not just LVH)
- Adults
- Progressively declining LVEF
- LVEF ~ prognosis
- 50% die in 2 years
- 3 Main causes
 - Myocarditis
 - ETOH
 - Adriamycin

DCM



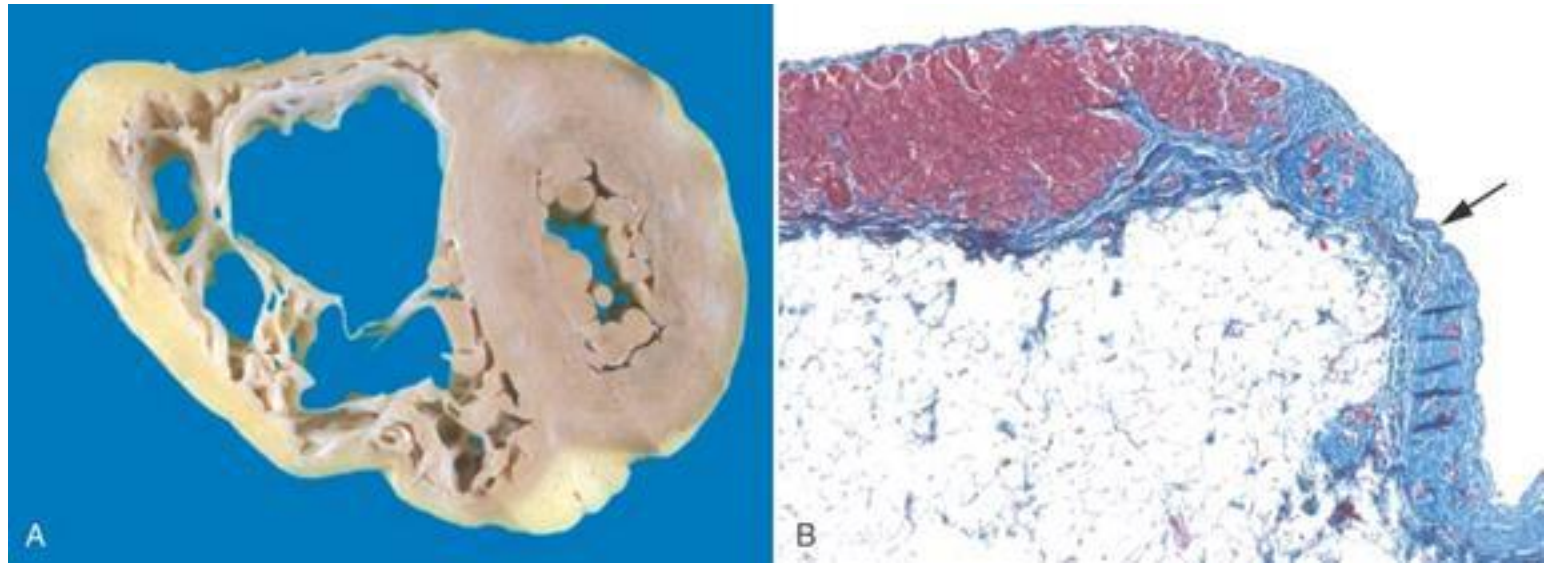
Path:

4 chamber dilatation

Hypertrophy

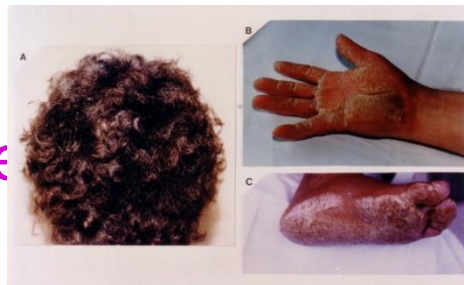Interstitial Fibrosis

Arrhythmogenic Right Ventricular Cardiomyopathy (Arrhythmogenic Right Ventricular Dysplasia)



This is an uncommon dilated cardiomyopathy predominantly RIGHT ventricle.

So is NAXOS syndrome



HYPERTROPHIC cardiomyopathy

- Also called IHSS, (**I**diopathic **H**ypertrophic **S**ubaortic **S**tenosis)

- **GENETIC** defects involving:

- Beta-myosin heavy chain

- Troponin T

- Alpha-tropomyosin

- Myosin binding protein C

- **PATHOLOGY:** Massive hypertrophy, Asymmetric septum, **DISARRAY** of myocytes, **INTERSTITIAL** fibrosis

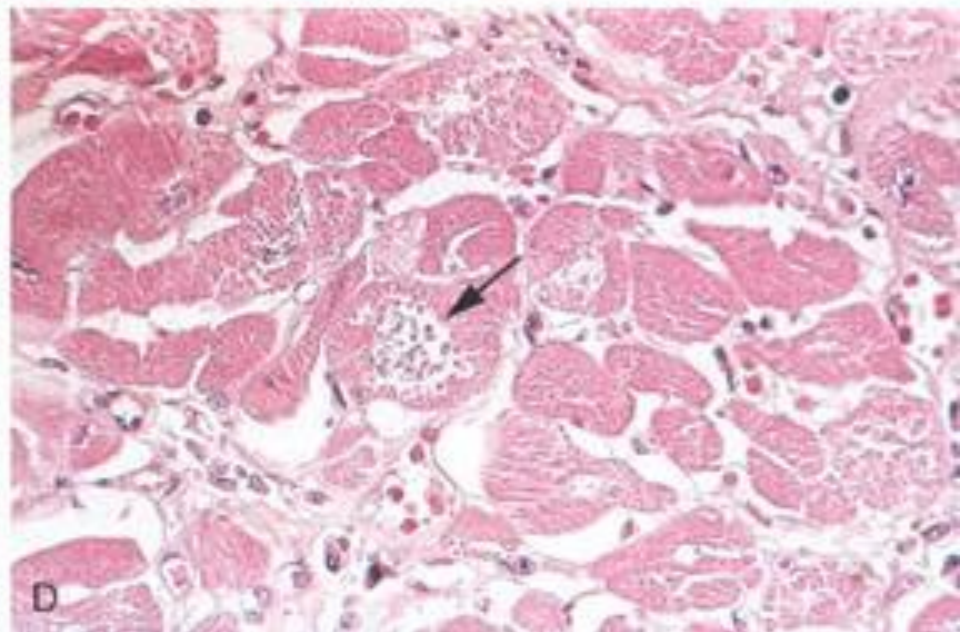
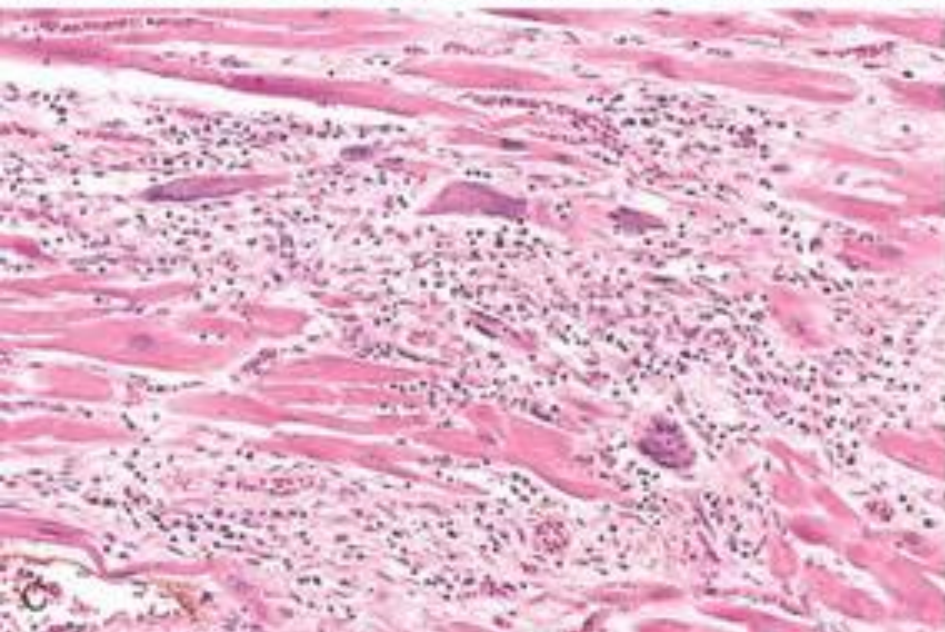
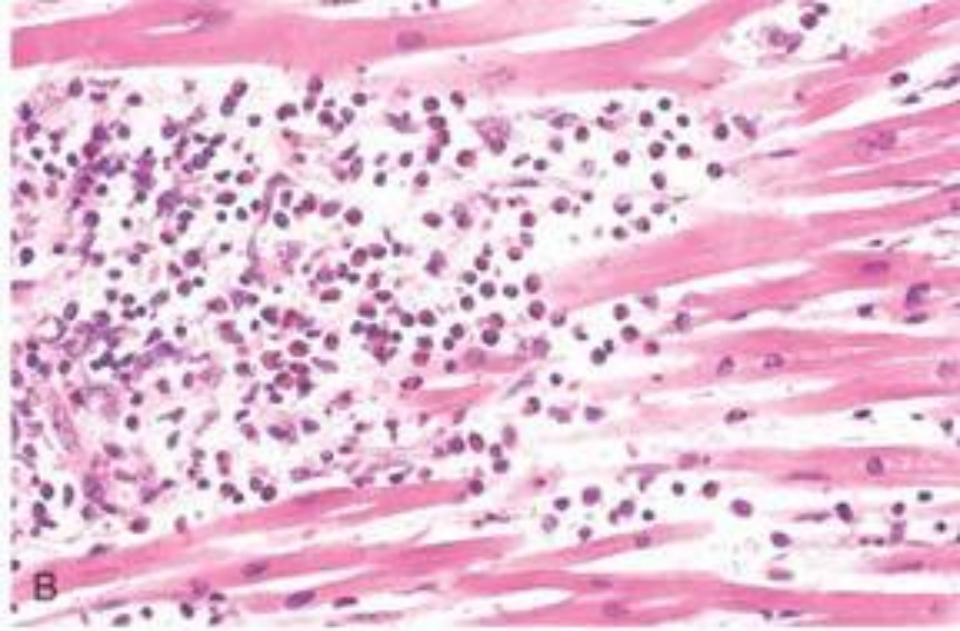
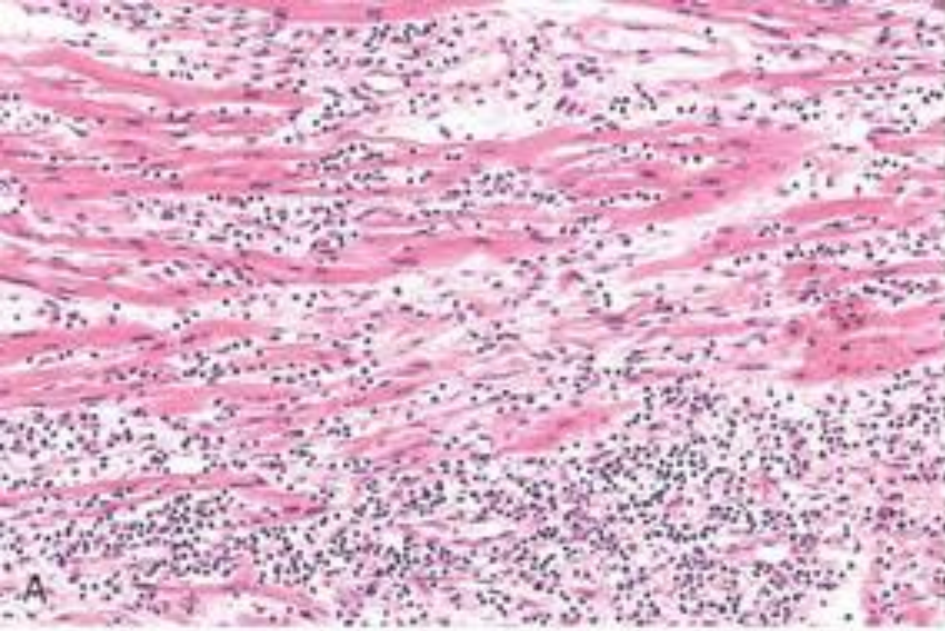
- **CLINICAL:** ↓ chamber volume, ↓ SV, ↓ diastolic filling

RESTRICTIVE cardiomyopathy

- (idiopathic)
- ↓ ventricular compliance
- Chiefly affects DIASTOLE
- NORMAL chamber size and wall thickness
- THREE similar diseases affecting predominantly the SUBENDOCARDIAL area:
 - Endomyocardial Fibrosis (African children)
 - Loeffler Endomyocarditis (eosinophilic leukemia)
 - Endocardial Fibroelastosis (infants)

MYOCARDITIS

- **INFLAMMATION of MYOCARDIUM**
- **Chiefly microbial**
 - **COXACKIE A & B, CMV, HIV**
 - **Trypanosoma cruzi (Chagas dis.), 80%**
 - **Trichinosis**
 - **Toxoplasmosis**
 - **Lyme disease (5%)**
 - **Diphtheria**
- **IMMUNE: Post-viral, rheumatic, SLE, drug hypersensitivity → alpha-methyl dopa, sulfas**



LYMPHOCYTIC INFILTRATES are the USUAL pattern of ALL myocarditis, but eosinophils, giant cells, and even trypanosomes

OTHER Myocarditides

- **Adriamycin**
- **Cyclophosphamide**
- **Catecholamines (Pheochromocytomas)**
- **Amyloid, systemic or primary cardiac**
 - Congo red stain: green birefringence with polarization
- **Amyloid, aging**
 - Congo red stain: green birefringence with polarization
- **Hemochromatosis (Prussian Blue)**
- **BOTH HYPER-, HYPO- -thyroidism**

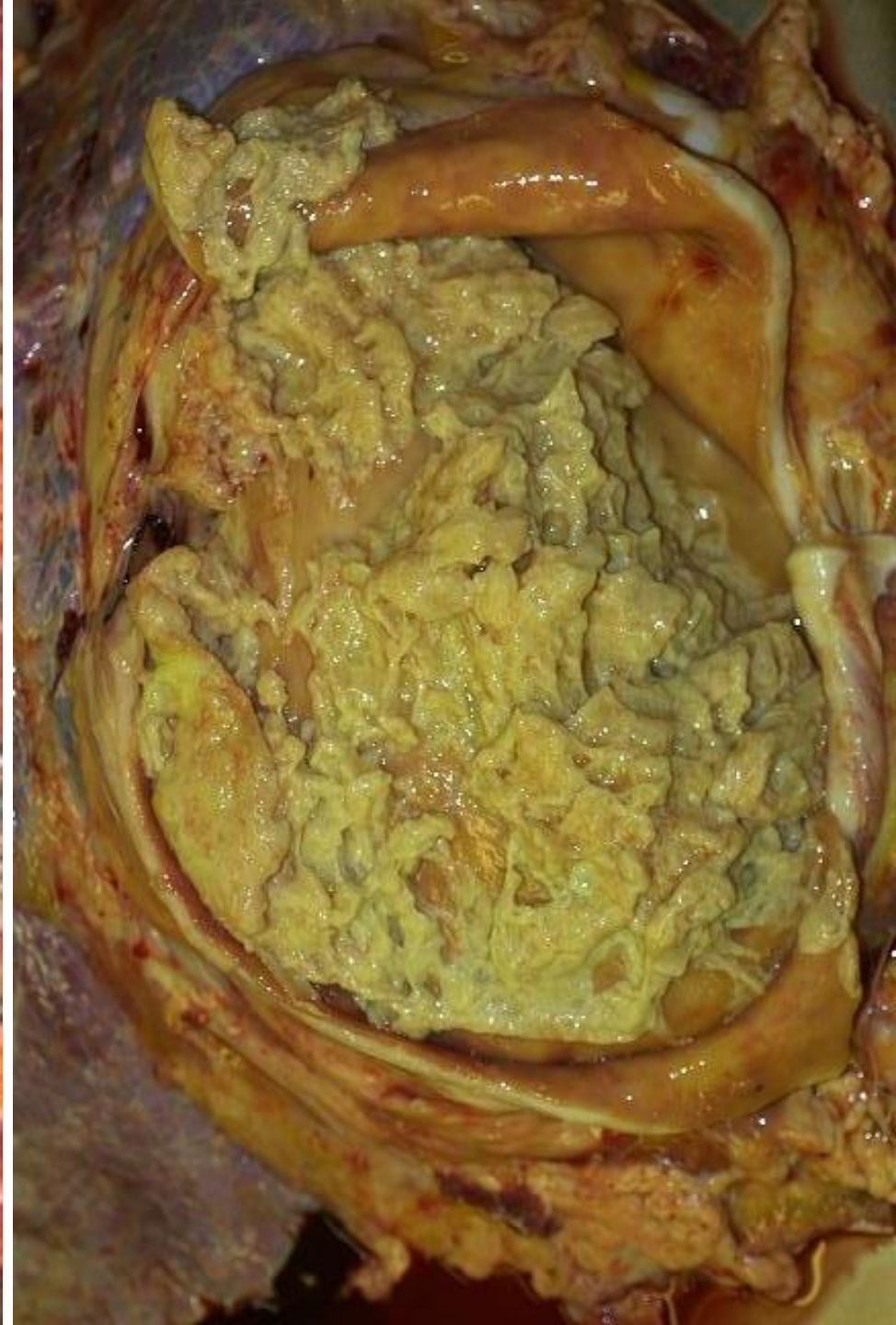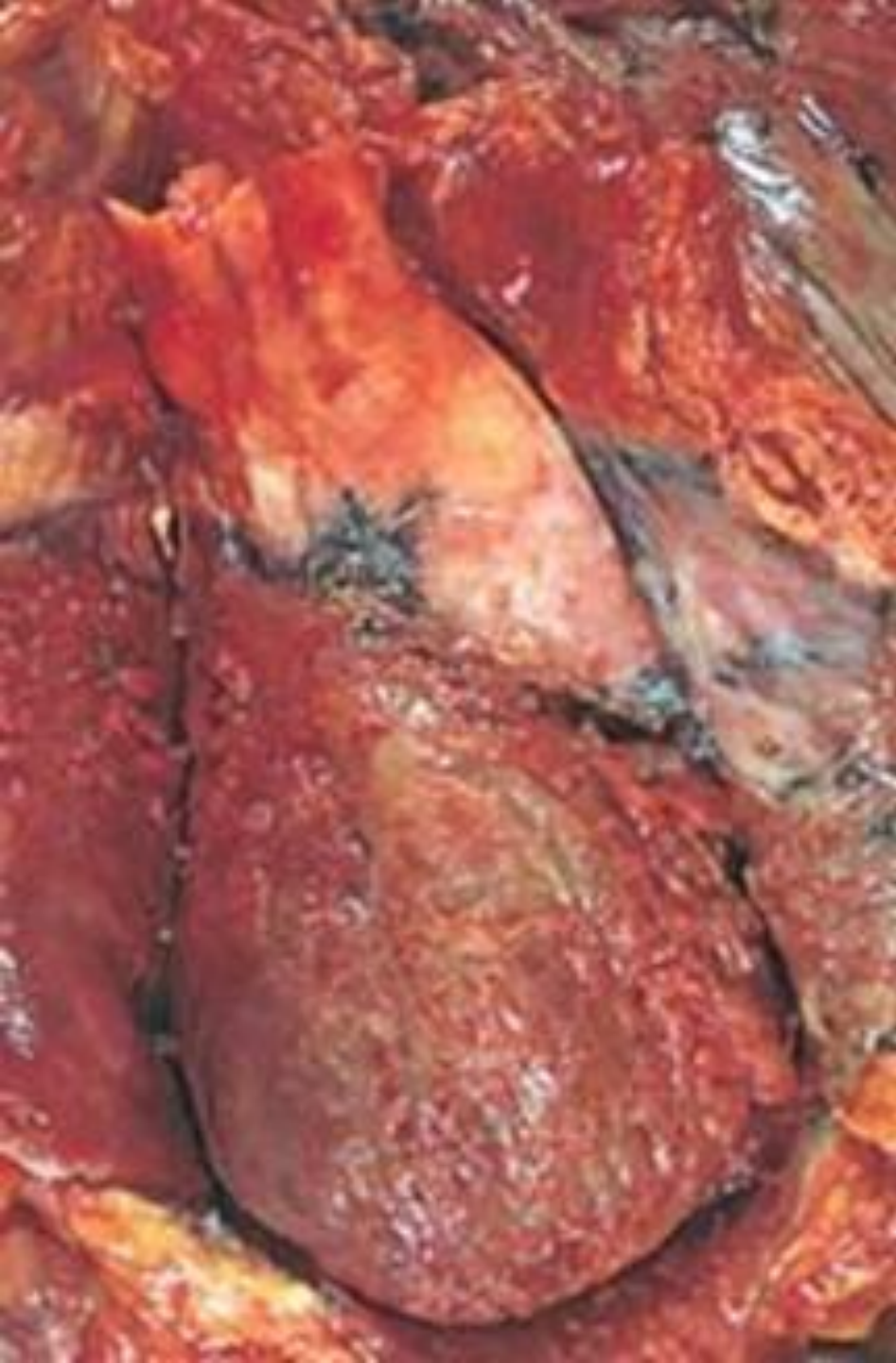PERICARDIUM

- **Normally 30-50 ml clear serous fluid**
 - Visceral (epicardium)
 - Parietal (Fibrous pericardium)

- **PERICARDIAL EFFUSIONS → TAMPONADE**
 - Ruptured MI
 - Traumatic perforation
 - Infective endocarditis
 - Ruptured aortic dissection

PERICARDITIS

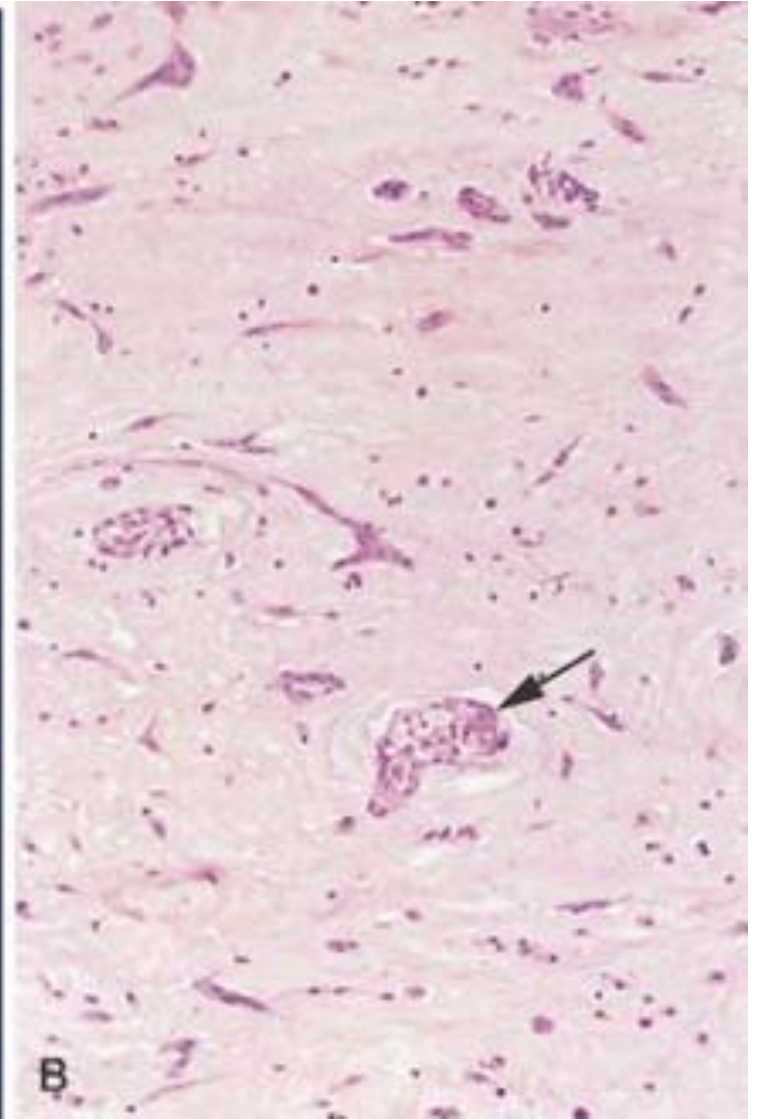
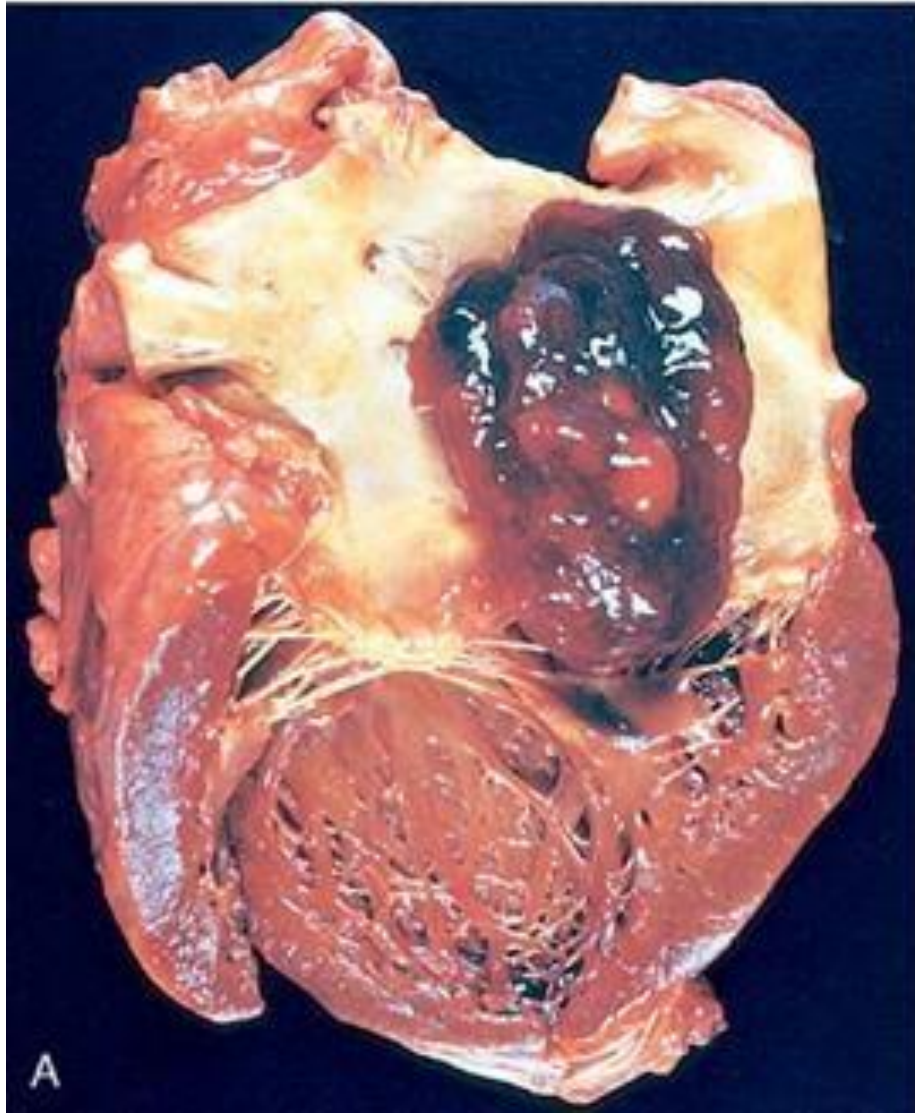
- **SEROUS:** Rheum. Fever (RF), SLE, scleroderma, tumors, uremia
- **FIBRINOUS:** MI (Dressler), uremia, radiation, RF, SLE, s/p open heart surgery
- **PURULENT:** infective, bacterial
- **HEMORRHAGIC:** Malignancy, TB
- **CASEOUS:** TB
- **CHRONIC:** (ADHESIVE, CONSTRICTIVE)



TUMORS

- 90% benign “mesenchymal”, i.e., stromal
 - **MYXOMAS (LEFT ATRIUM MOST COMMON)**
 - FIBROMAS
 - LIPOMAS
 - FIBROELASTOMAS
 - RHABDOMYOMA (Most common cardiac tumor in children)
- 10% SARCOMAS

MYXOMA



Cardiac effects of NON-cardiac tumors

- ***Direct Consequences of Tumor***
 - Pericardial and myocardial metastases
 - Large vessel obstruction
 - Pulmonary tumor emboli
- ***Indirect Consequences of Tumor (Complications of Circulating Mediators)***
 - Nonbacterial thrombotic endocarditis (NBTE)
 - Carcinoid heart disease
 - Pheochromocytoma-associated heart disease
 - Myeloma-associated amyloidosis
- ***Effects of Tumor Therapy***
 - Chemotherapy
 - Radiation therapy

CARDIAC TRANSPLANT PATHOLOGY

- **Most patients are on immunosuppressives**
- **5 year survival >60%**

CARDIAC TRANSPLANT PATHOLOGY

