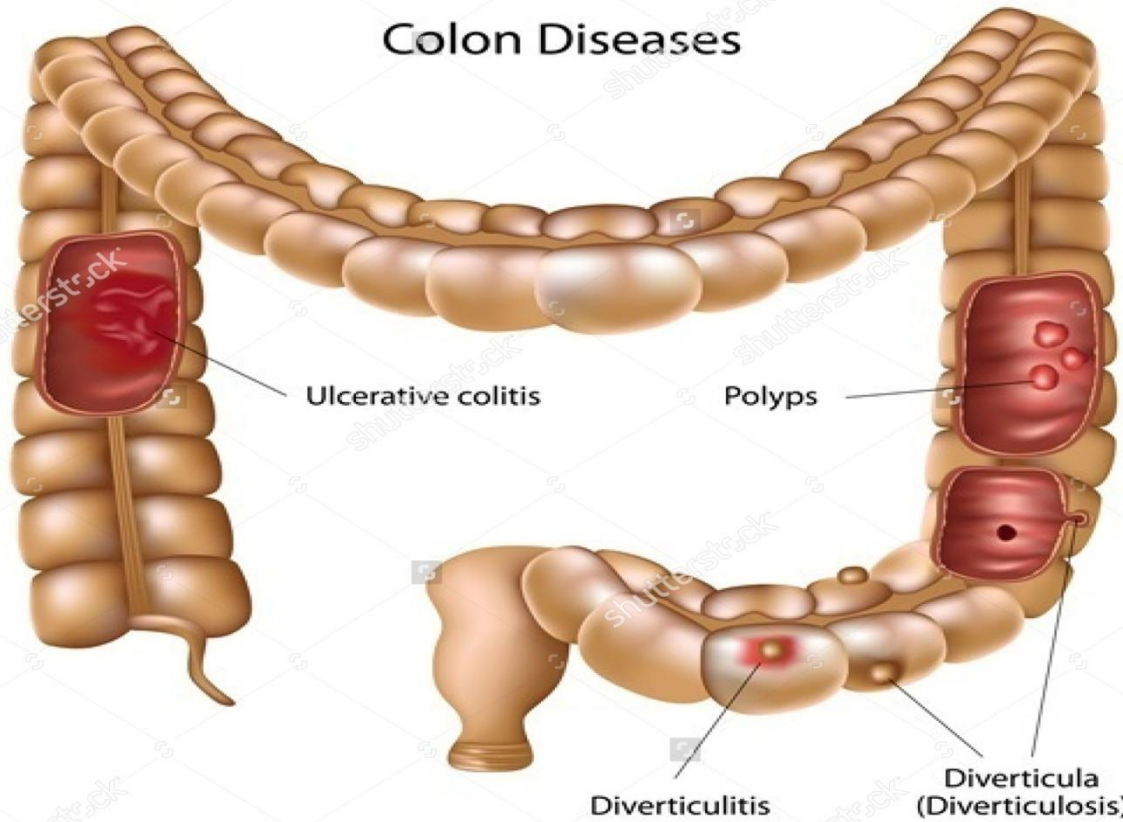
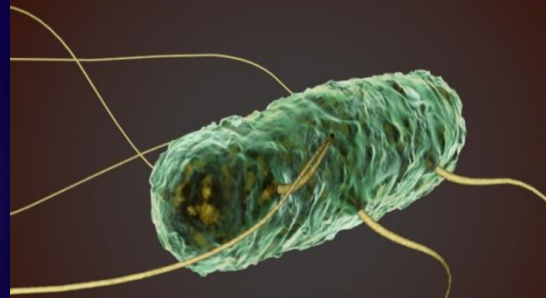
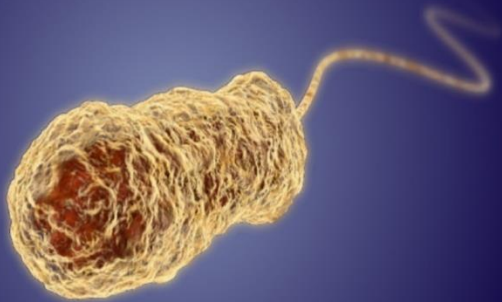
Colon Diseases



**Intestinal pathology.
Intestinal infections.**



vibrio cholerae bacteria

salmonella bacteria

Intestinal pathology. Intestinal infections.

I. Microspecimens:

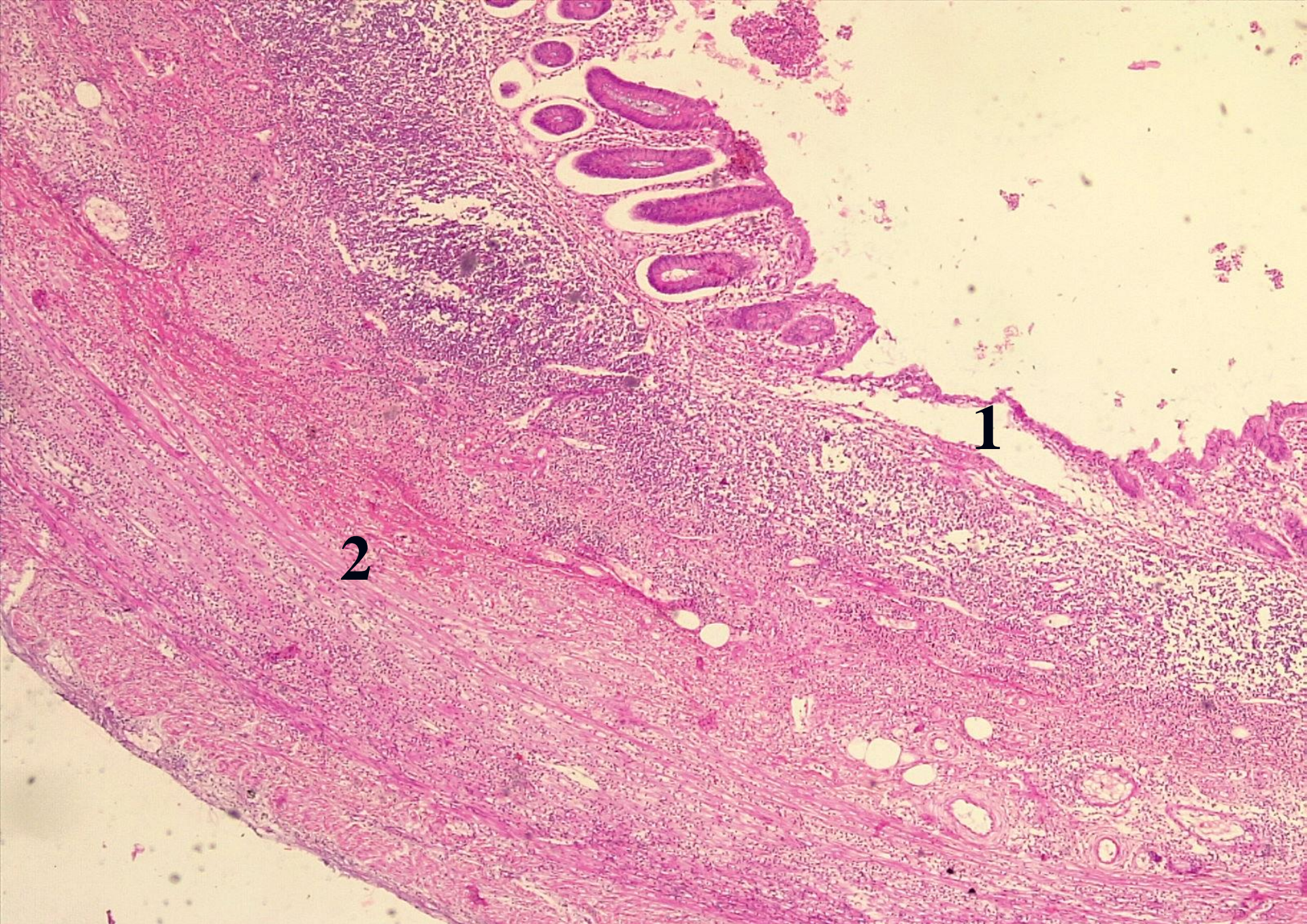
№ 88. Acute suppurative appendicitis. (*H-E. stain*).

Indications:

1. Ulcerative mucosal defects.
2. Diffuse neutrophilic infiltration of all layers of appendicular wall.

The lumen of the vermicular appendix is dilated, the wall thickened, edematous, are observed ulcerative defects in the mucosa, their bottom covered with necrotic masses and neutrophilic leukocytes, in the wall thickness diffuse infiltration with neutrophilic leukocytes is revealed, which extends in all layers, including the serous membrane, neutrophilic infiltration is more abundant in the muscular layer also there is dilatation and hyperemia of the vessels, hemorrhages, in the lumen neutrophilic leukocytes and necrotic masses.

The most common cause of acute appendicitis is obstruction of the lumen of the vermicular appendix, which can be caused by processes of fibrosis in the proximal portion, stones, including coprolites (starches), tumors, parasites, foreign bodies. These factors lead to retention of content and increased intraluminal pressure in the vermicular appendix, mucosal ischemia, epithelial damage, infection penetration, and the development of acute inflammation. The most important histological forms are: a) catarrhal appendicitis, b) phlegmonous, c) ulcero-phlegmonous and d) gangrenous. In some cases in the thickness of the appendix wall. can form microabscesses - apostematous appendicitis. Complications of acute appendicitis: a) perforation or self-amputation in gangrenous form with the development of localized or generalized peritonitis, b) spread of inflammation on the serous membrane - periappendicitis, mesenteryol - mesenteriolitis and check - perityphlitis, c) empyema (accumulation of pus in the appendicular lumen) d) abscesses in the right iliac fossa, in the pelvis between the bladder and rectum and subdiaphragm on the right, e) pielophlebitis (inflammation of the portal vein) with abscesses in the liver. Late complications: adhesions with the large omentum, small intestine, other organs and mucocele.



№ 88. Acute suppurative appendicitis. (*H-E. stain*).

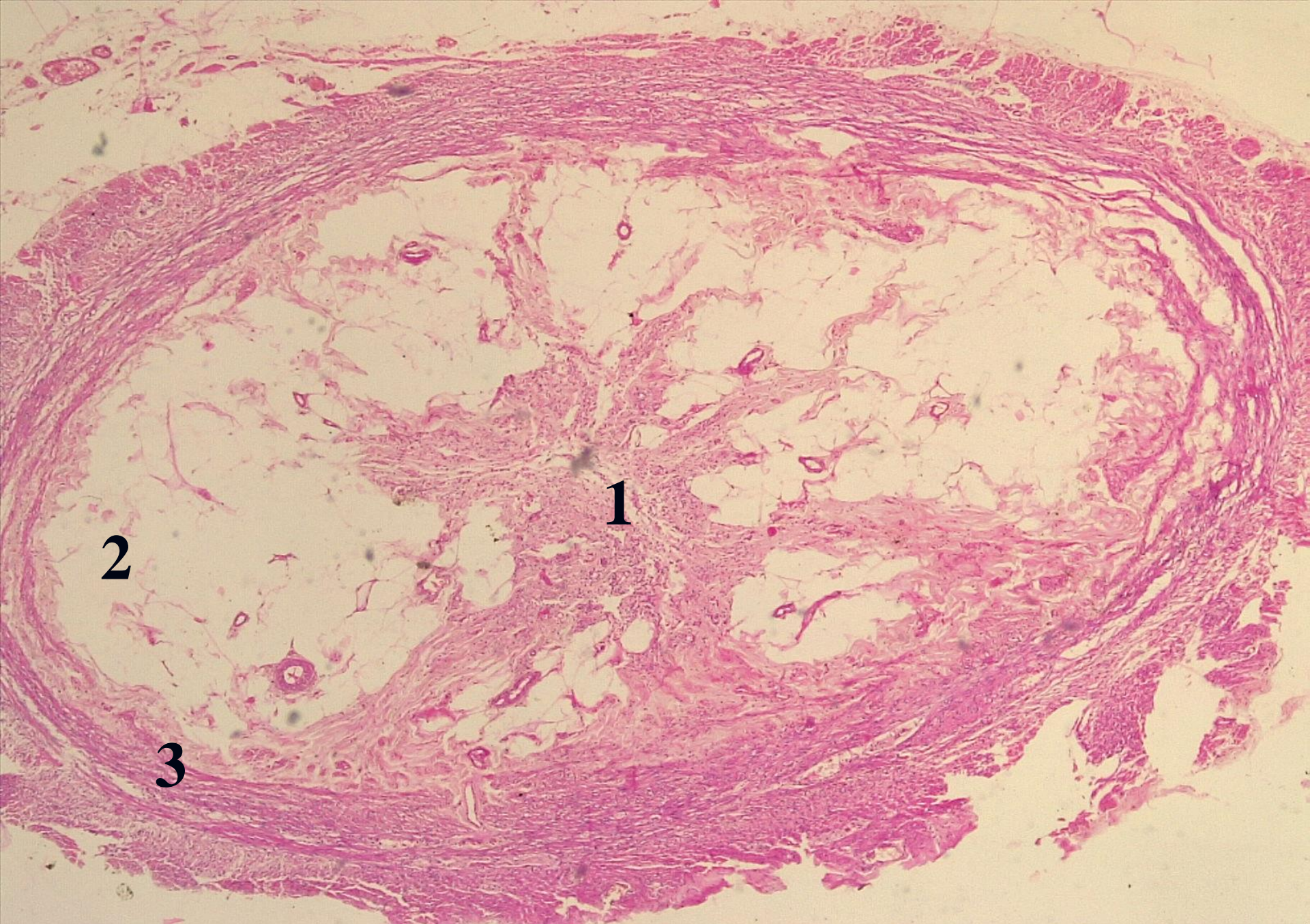
№ 88a. Chronic appendicitis. (H-E. stain).

Indications:

1. Occlusion of appendicular lumen.
2. Appendicular wall substituted by connective and fatty tissue.
3. Atrophied muscle layer.

The lumen of the vermicular appendix is obliterated with connective and adipose tissue, which have completely replaced the mucosa and submucosa, the muscular layer is atrophied.

Chronic appendicitis occurs as a result of acute appendicitis and is characterized by processes of sclerosis and atrophy of all layers of the wall, obliteration of the lumen may occur. In cases when the obliteration is at the level of the proximal portion of the appendix, the following may develop: a) appendicular hydrops (accumulation of serous fluid), b) mucocele (distension of the appendix with accumulation of mucus), c) myxoglobulosis (formation of mucus globules due to wall peristalsis), d) peritoneal pseudomixom in case of rupture of the mucocell wall and spread of mucus globules on the peritoneum (reminiscent of a myxoma), e) appendicular empyema in case of association of infection.



№ 88a. Chronic appendicitis. (H-E. stain).

№ 222. Appendiceal mucocele. (*H-E. stain*).

Indications:

1. Hyperplasia of glandular epithelium which secretes mucus.
2. Thinned muscle layer.
3. Mucus in the dilated lumen of the appendix.

The microspecimen has a portion of the mucocell wall; hyperplasia of the mucosecretory epithelium is revealed, which in some places forms papillary proliferations, blood vessels are dilated, hyperemic, foci of hemorrhages are observed in the eosinophilic colored mucus lumen. [*microspecimen № 88a*]

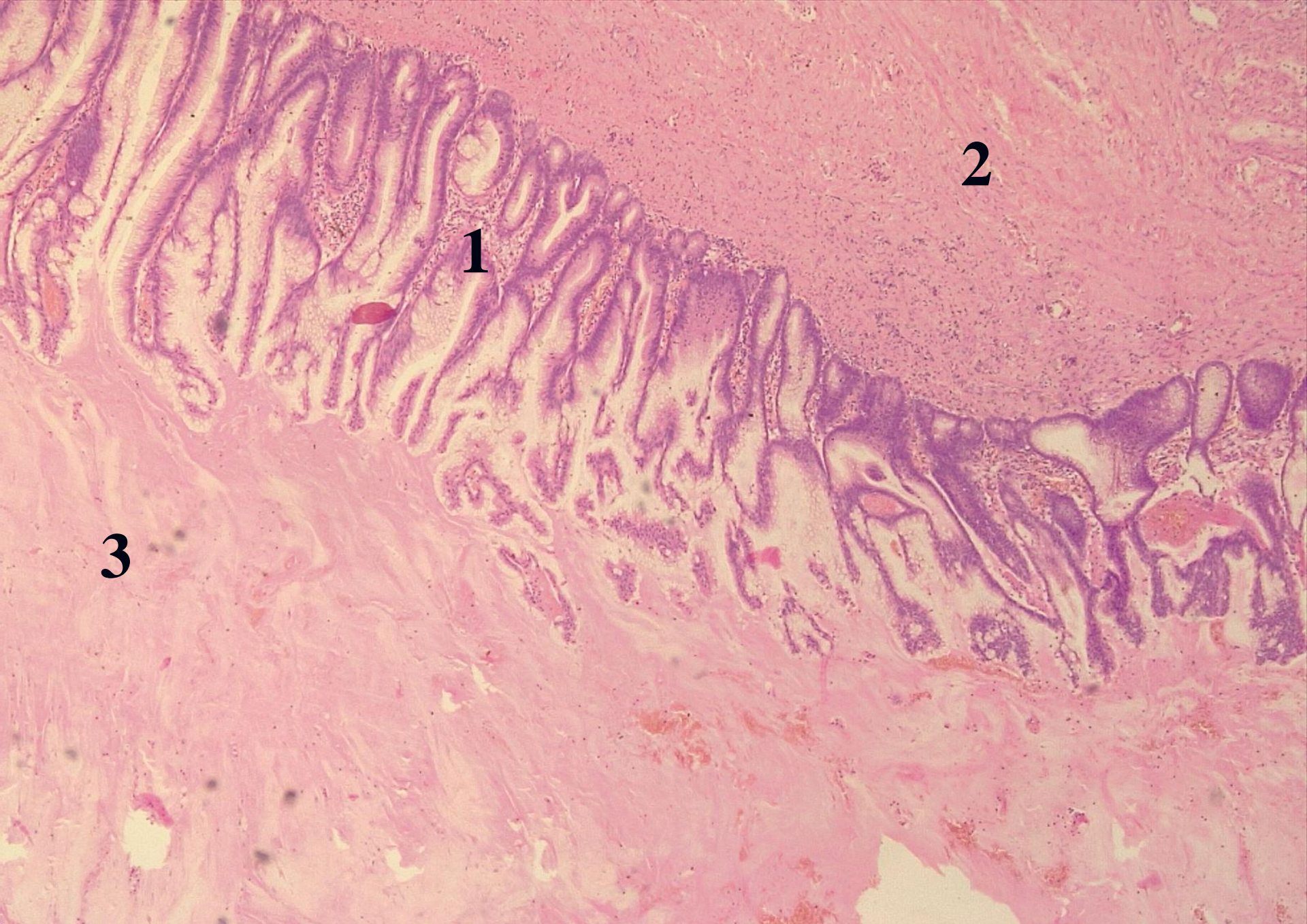
№ 48a. Mucinous carcinoma of the colon (signet-ring cell). (*H-E. stain*).

Indications:

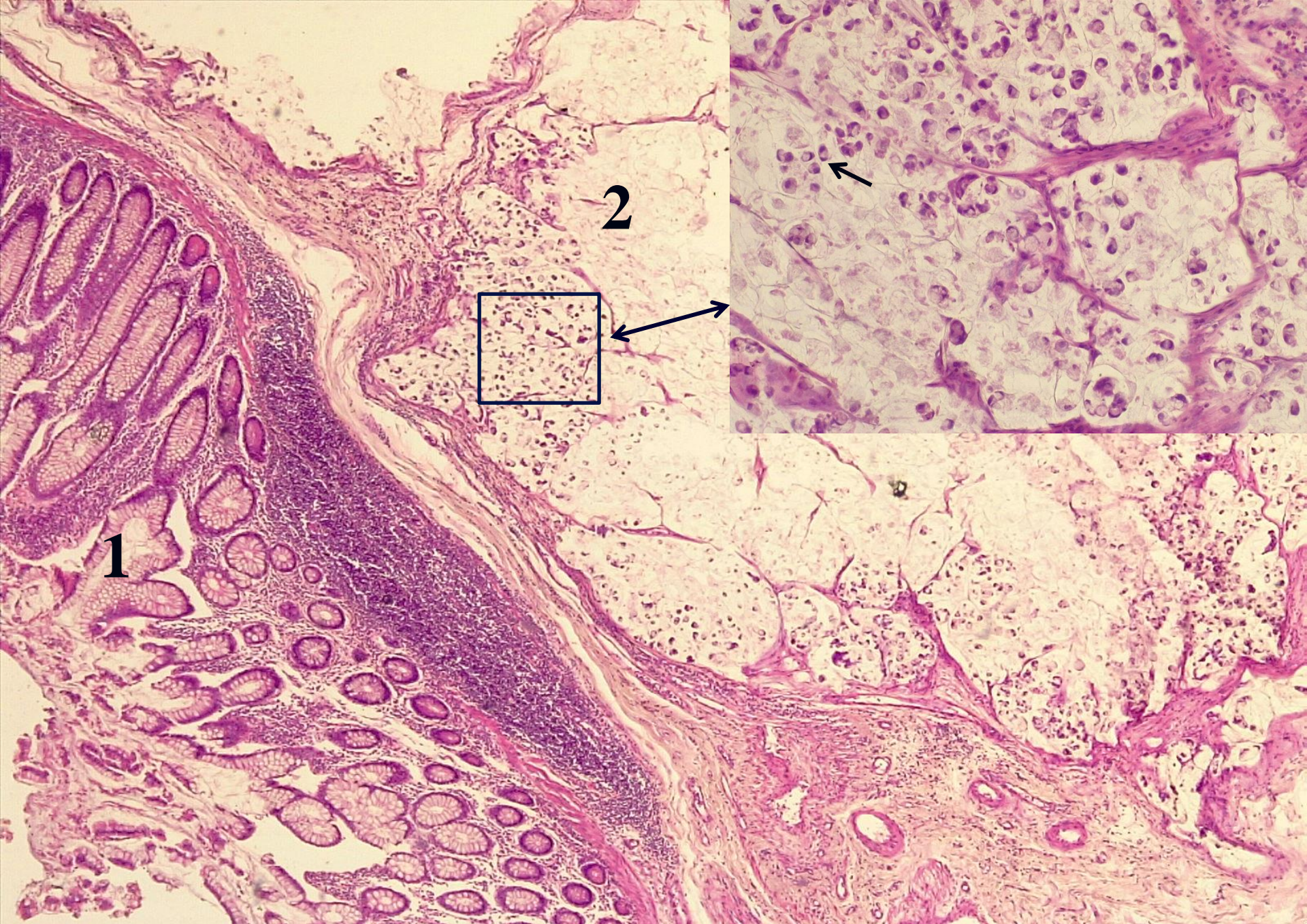
1. Intact mucosa.
2. Clusters of "signet ring cells" and mucous substance which infiltrate the intestinal wall.
3. Muscle layer.

In the colonic wall the mucosa has a normal structure, immediately below the mucosal muscle there are "lakes" of weakly basophilic colored mucus, in the mucus "floating" isolated cells and groups of "signet ring cells", round / oval shape, with abundant cytoplasm, the nucleus displaced to the membrane and flattened; in the adjacent tissue chronic inflammatory infiltration, predominantly lymphoid.

Signet ring cell carcinoma of colon is relatively rare, in about 1% of total cases. It is localised predominantly in the right colon. Macroscopically it looks like a gelatinous mass. It is distinguished by aggressive evolution, metastases appear quickly, multiple and in several organs.



№ 222. Appendiceal mucocele. (H-E. stain).



№ 48a. Mucinous carcinoma of the colon (signet-ring cell). (H-E. stain).

№ 94. Hyperplasia of mesenteric lymph node in typhoid fever. (H-E. stain).

Indications:

1. Clusters of typhoid cells.
2. Foci of necrosis.
3. Intact lymphoid tissue.

In the lymph node there are small foci of cells with rich cytoplasm, colored eosinophilic, slightly eccentric nucleus (typhoid cells), which form granulomas (granulomas or nodules), around them small lymphocytes, there are foci of necrosis, structured, anucleated, eosinophils.

In typhoid fever the lymph nodes have changes analogous to those in the small intestine (macrospecimen № 58). Necrotic lesions in nodules can cause peritonitis, especially when foci of necrosis are located subcapsularly. The most common consequences of typhoid lymphadenitis: the organization and petrification of foci of necrosis.

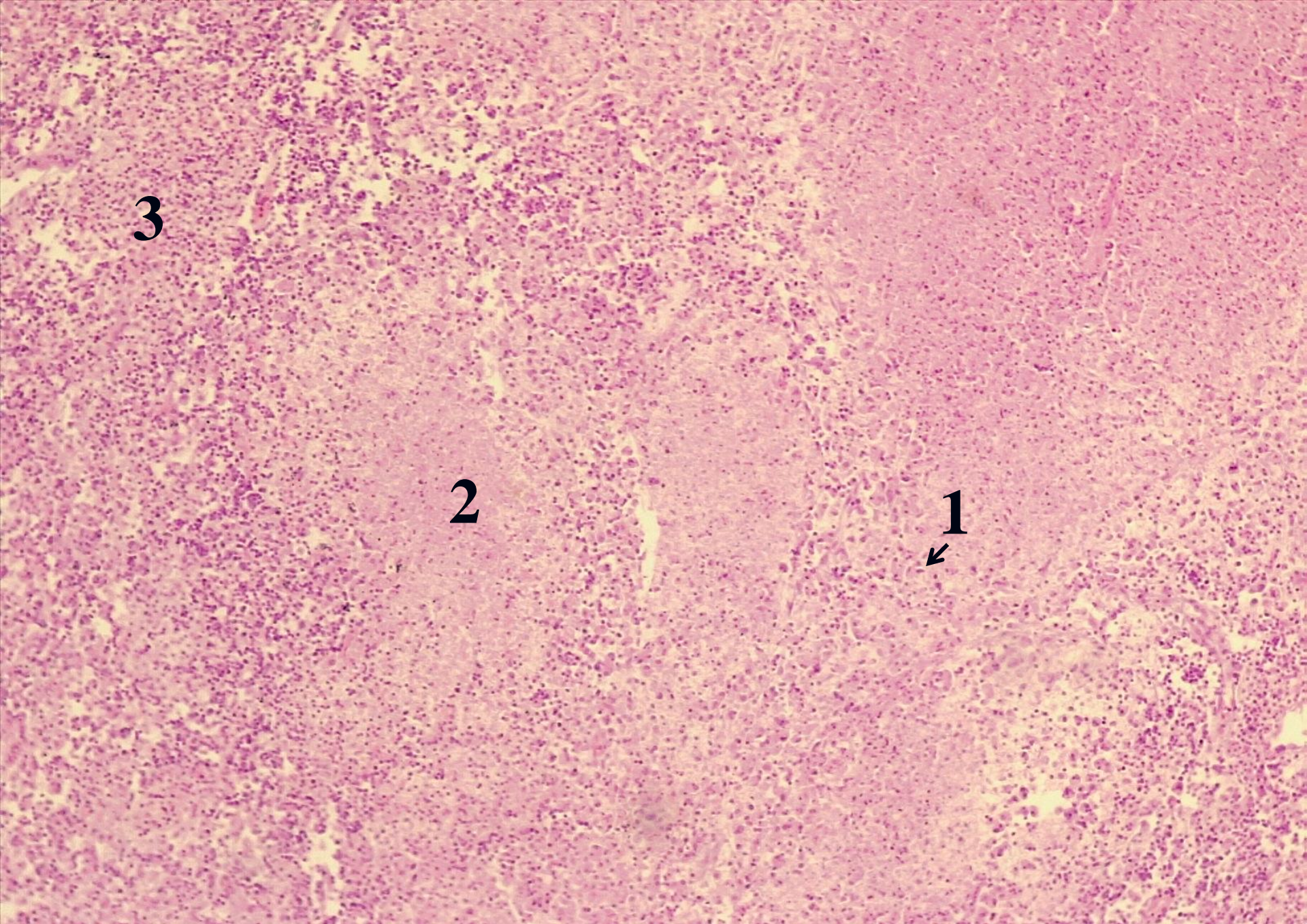
№ 15. Pseudomembranous colitis. (H-E. stain).

Indications:

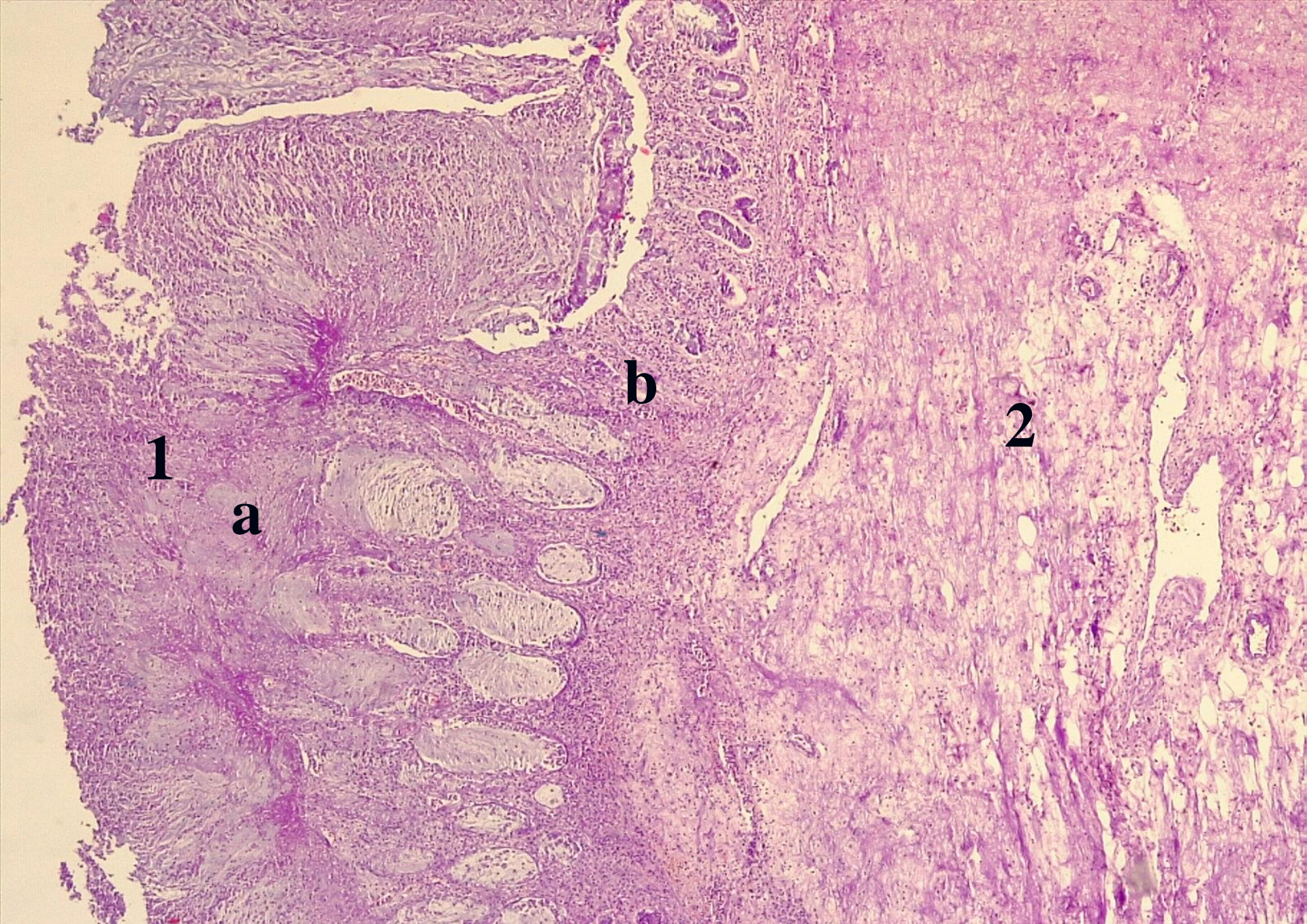
1. Pseudomembrane:
 - a. necrotic masses and fibrin with diffuse neutrophilic infiltration;
 - b. underlying tissue.
2. The muscular layer of the intestinal wall.

On the surface of the colonic mucosa there is a layer of fibrin with a mixture of necrotic masses, infiltrated with neutrophilic leukocytes and mucus, which is called "pseudomembranous" so as not to be confused with true anatomical membranes; the pseudomembrane in some places is detached from the remains of the underlying mucosa, which is mostly necrotic, only the contours of the basal portions of the crypts have been preserved, filled with muco-purulent exudate; the wall of the colon is edematous, with hemorrhages, dilated vessels, hyperemia.

Pseudomembranous colitis is most commonly caused by the pathogen Clostridium difficile, which eliminates toxins, which act on the lining of the colon and / or small intestine, causing acute pseudomembranous-looking colitis / enterocolitis. Macroscopically, the colonic mucosa is covered with a whitish-gray film, sometimes with a greenish tinge due to the impregnation with bile pigments. It is usually found in patients who use antibiotics for a long time, so it is also called "colitis associated with the administration of antibiotics." Other risk factors are old age, immunosuppression and hospitalization. The prevalent clinical symptom is diarrhea and dehydration.



№ 94. Hyperplasia of mesenteric lymph node in typhoid fever. (*H-E. stain*).



№ 15. Pseudomembranous colitis. (*H-E. stain*).

II. Macrospecimens:

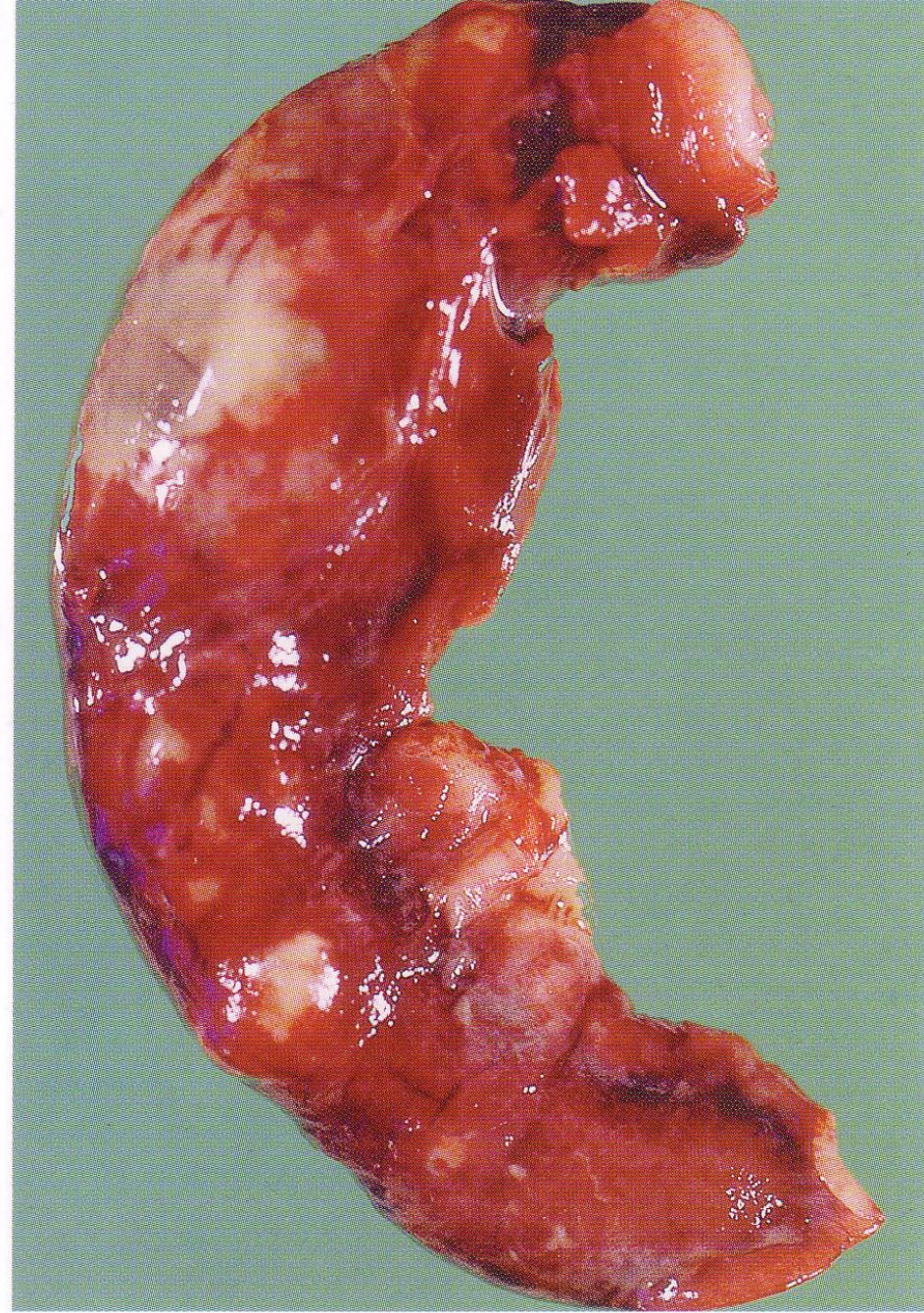
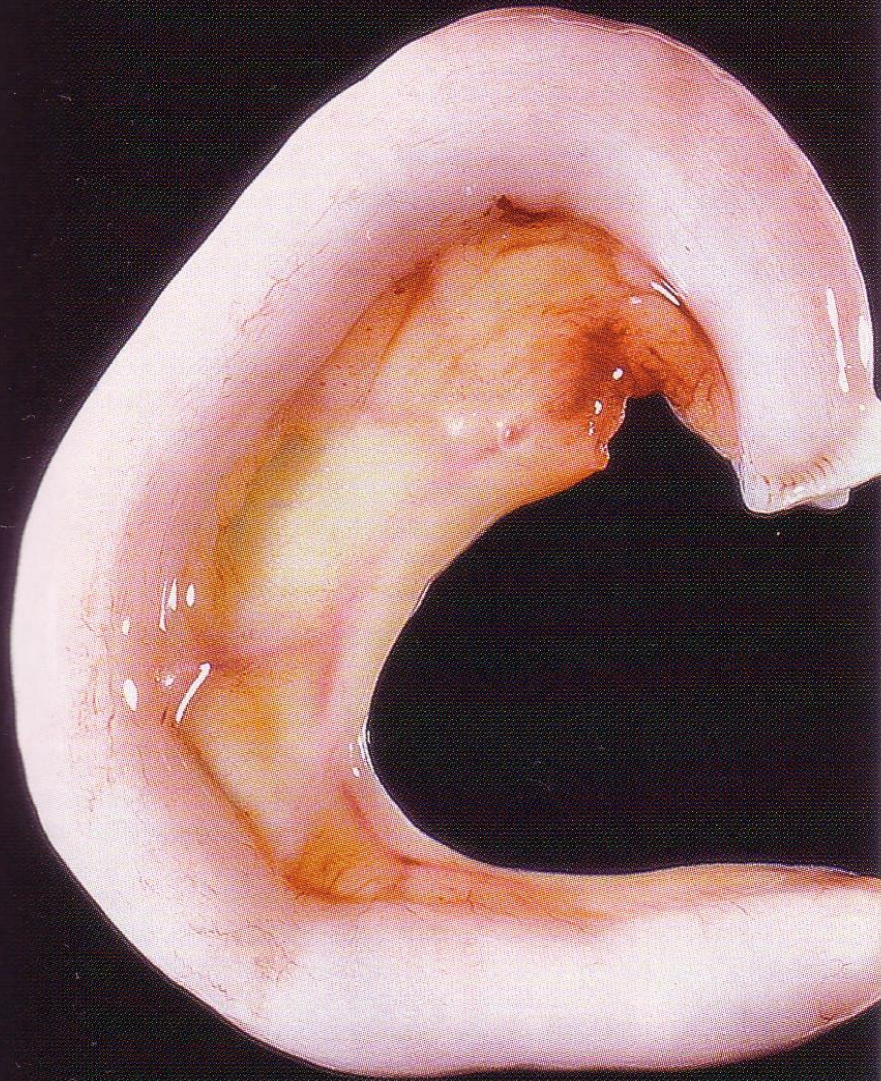№ 55. Acute suppurative appendicitis.

The vermicular appendix is dilated, the surface is matte, serous edematous, hyperemic, with hemorrhagic foci and whitish fibrin deposits, the mesentery is edematous, hyperemic, with hemorrhages and fibrin. [*microspecimen № 88*]

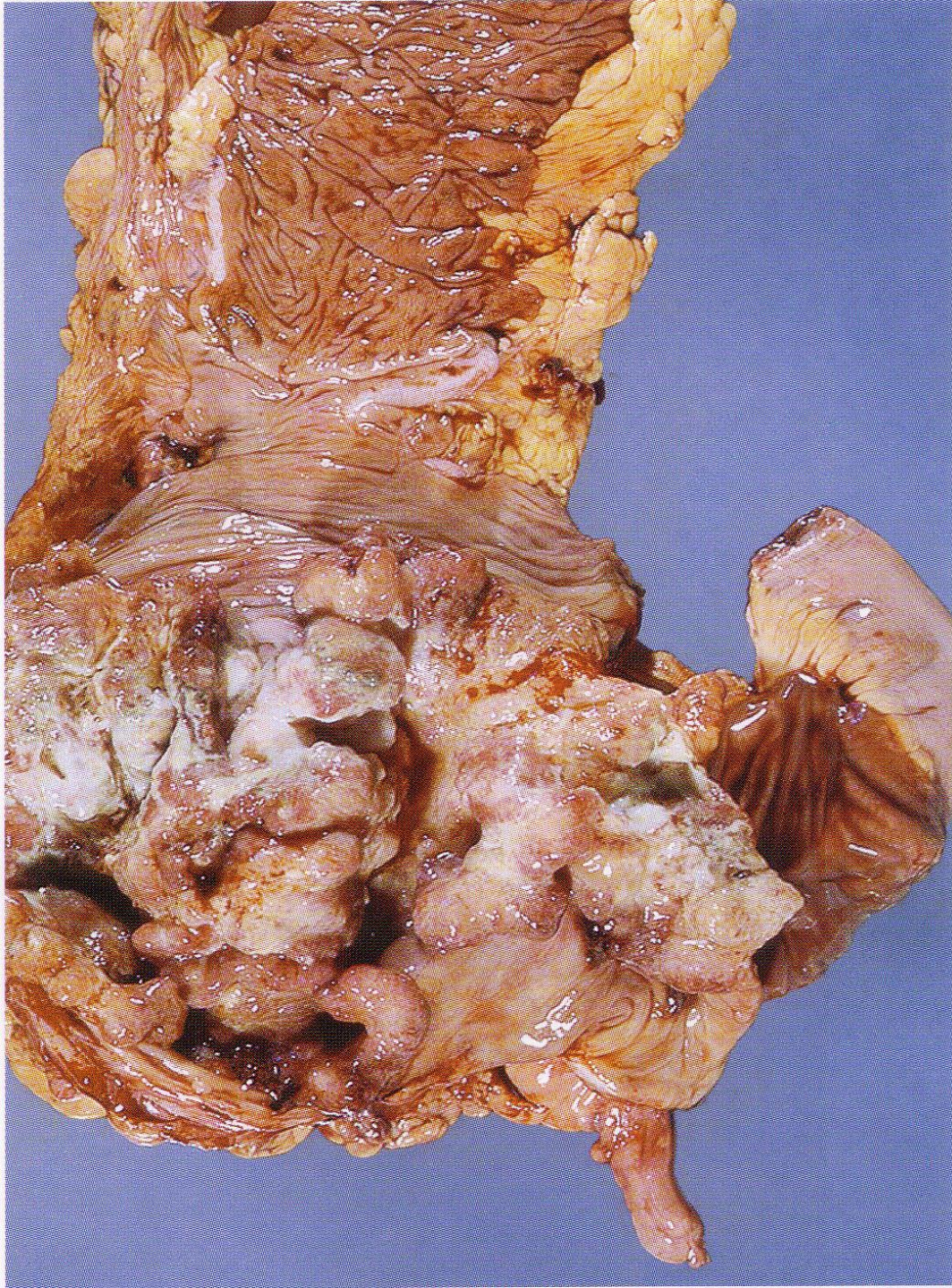
№ 61. Carcinoma of sigmoid colon.

In the colon there is a large tumor node, which grows exophyte, considerably stenoses the intestinal lumen, irregular surface, with areas of necrosis and ulceration, dense-elastic consistency, pinkish-whitish color.

Colon cancer is localised more frequently in descending order: in the rectum (60%), sigma, descending colon, cecum and ileocecal region, ascending colon, hepatic flexure and spinal flexure. It can be complicated by intestinal occlusion, hemorrhage, perforation and peritonitis, infiltration of adjacent tissues / organs, phlegmon. Metastases occur primarily by lymphogenesis in regional lymph nodes, and hematogenous metastases are relatively late and are more common in the liver, lungs, brain, bones and ovaries. Microscopically in the majority of cases (90-95%) colon cancer is adenocarcinoma. Among the precursors, adenomas, familial adenomatous polyposis, nonspecific ulcerative colitis and Crohn's disease are more common.



№ 55. Acute suppurative appendicitis.



№ 61. Carcinoma of sigmoid colon.

№ 58. Encephaloid modifications of Peyer's patches in typhoid fever.

Peyer's patches are enlarged in size, protrude on the surface of the intestinal mucosa, have a gray-pink color and plicated appearance, reminiscent of the brain surface, hence the name of this stage "encephaloid intumescence of Peyer's patches"; in some patches necrotic masses are observed, which partially detach, forming ulcerations, the edges of which are slightly elevated due to edema and inflammation; the ulcers have the length and shape of the Payer patches, on average 6-8 cm and are located along the longitudinal axis of the intestine; the adjacent mucosa is edematous and hyperemic.

Typhoid fever is caused by Salmonella typhi, it is transmitted by food. The first morphological changes occur in the Payer plates and solitary follicles, more pronounced in the ileum. Productive inflammation develops with the proliferation of monocytes and histiocytes, which replace lymphocytes; some monocytes turn into large macrophages, with clear cytoplasm, which phagocytose typhoid bacilli and are called typhoid cells, and their agglomerations form granulomas or typhoid nodules. Due to these proliferative processes, the encephalopathy of Payer plaques develops. Subsequently, necrosis of typhoid granulomas occurs, gradual detachment of necrotic masses and the appearance of ulcers, initially covered with necrotic masses ("dirty" ulcers), which after a week become clean, with a smooth bottom, presented by the muscular layer or deeper to the peritoneum ("clean" ulcers). Ulcers can be complicated by bleeding and perforation. Fine scars form on the site of the ulcers, which have the shape of Payer patches. General complications: pneumonia, cholecystitis, waxy necrosis of skeletal muscles, osteomyelitis, meningitis, sepsis.

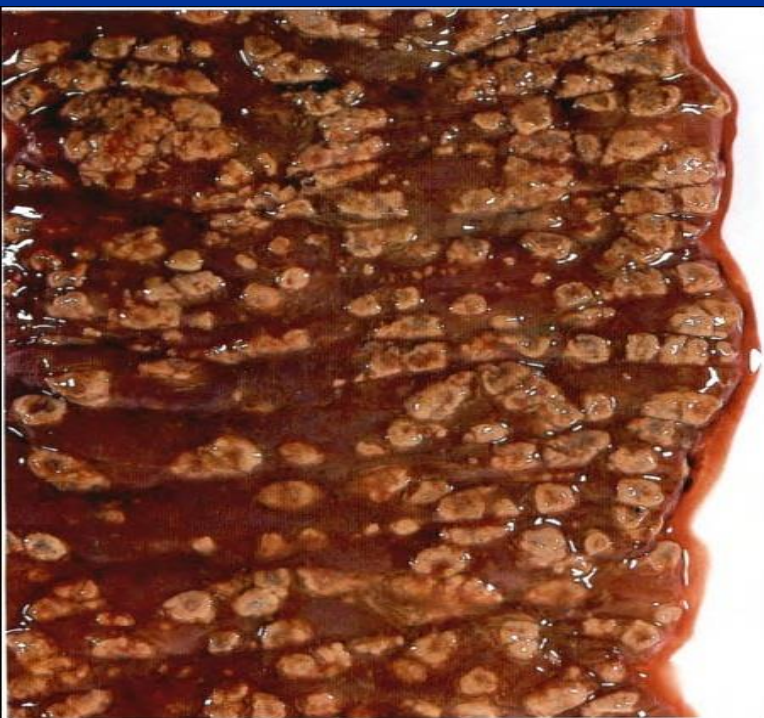
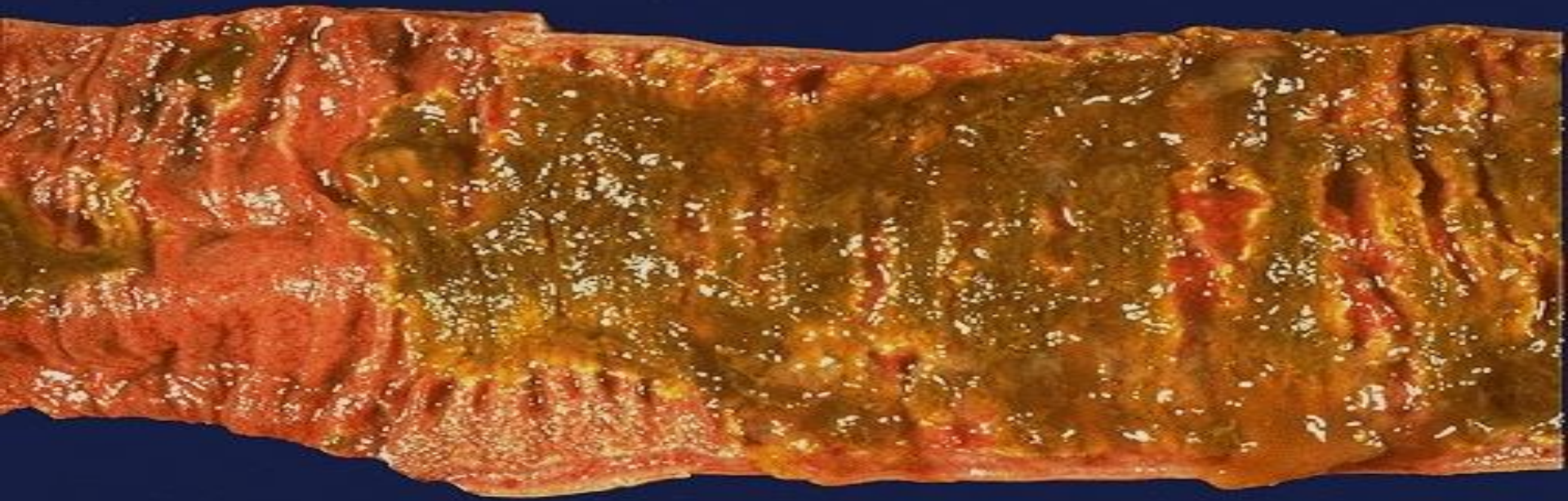

№ 58. Encephaloid modifications of Peyer's patches in typhoid fever.

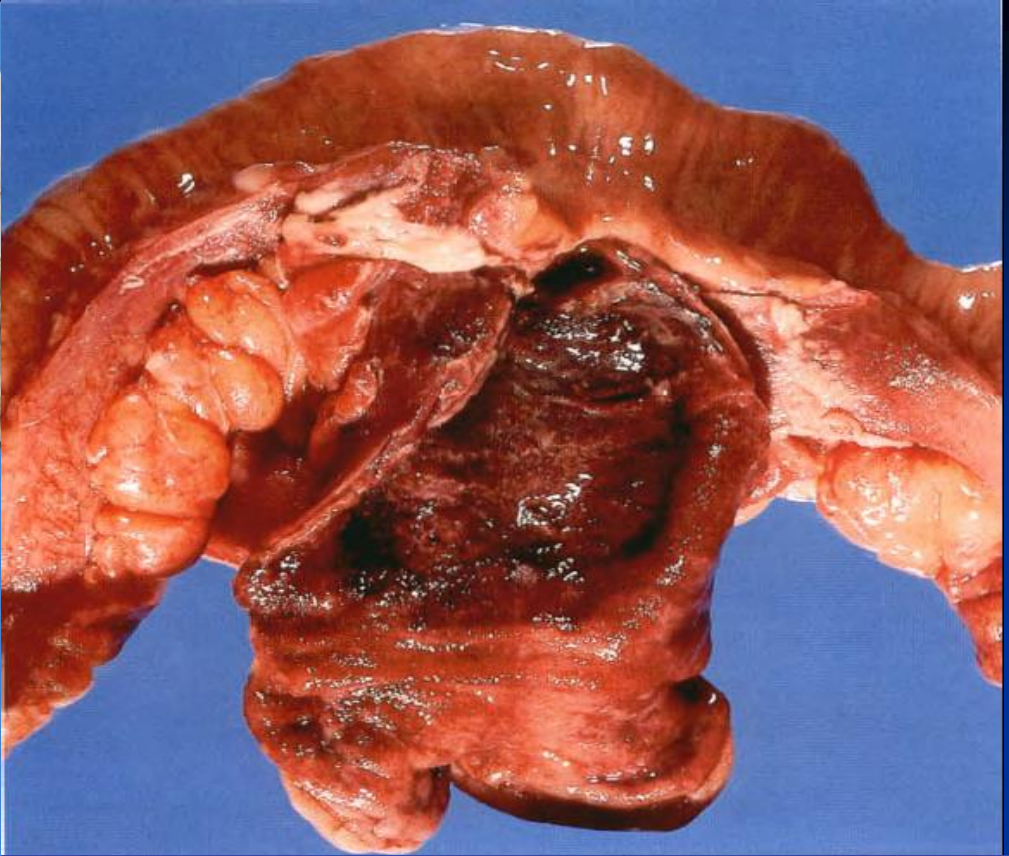
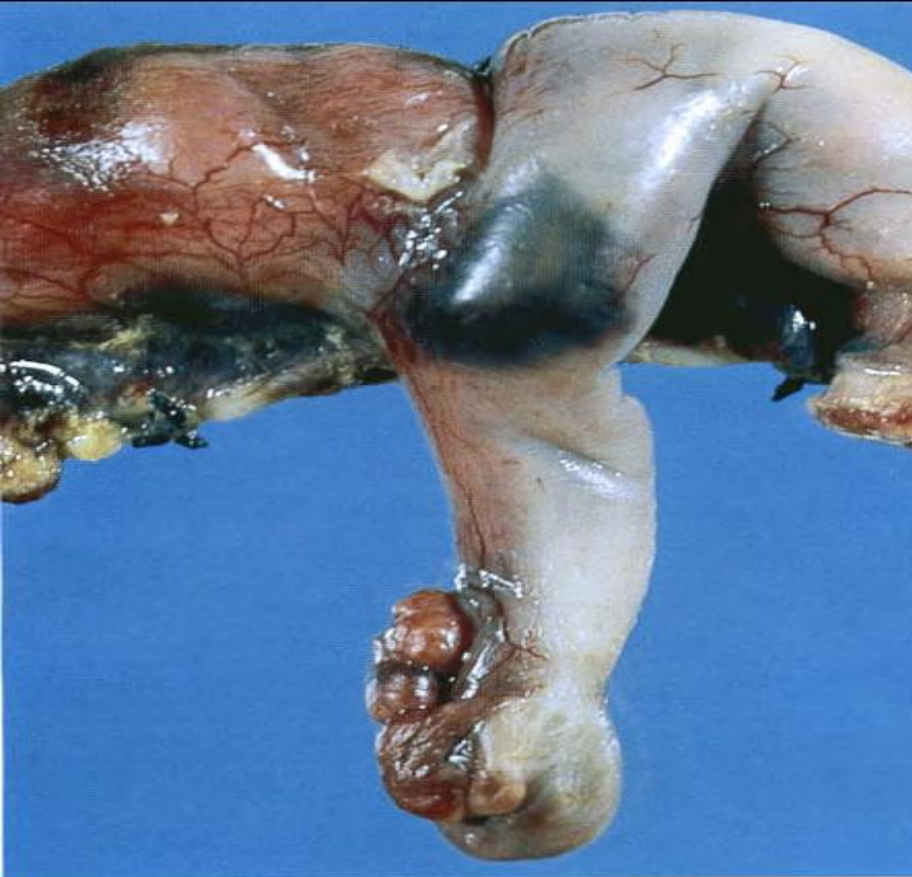№ 57. Fibrinous ulcerative colitis in schigellosis.

On the surface of the colonic mucosa there is a brown-gray fibrin film, the adjacent mucosa is edematous, hyperemic.

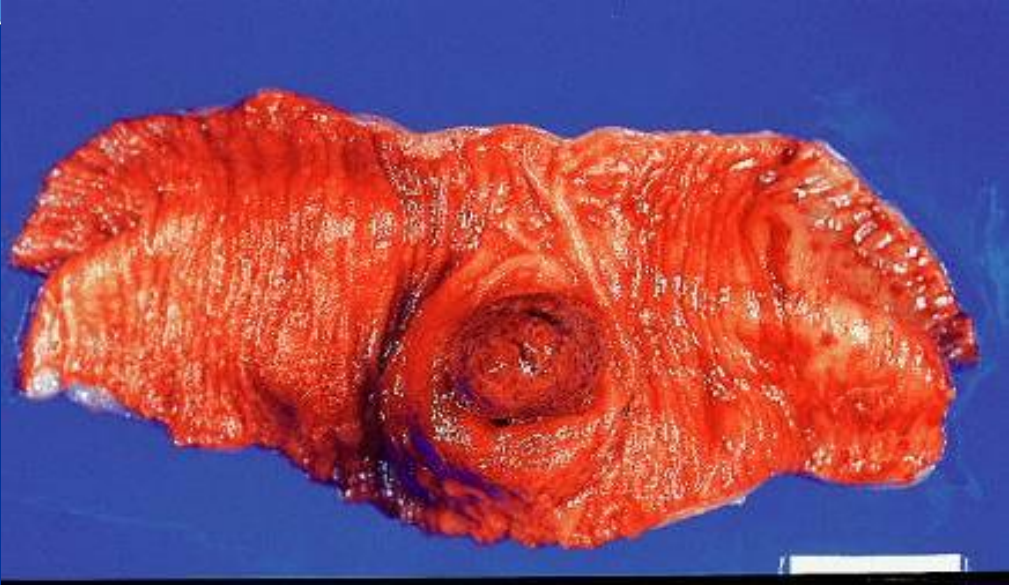Schigellosis is caused by the pathogen Schigella, the infection occurs through food (fecal-oral). It affects the left colon more, especially the recto-sigmoid portion. Locally, there are 4 stages of dysenteric colitis: a) catarrhal colitis, b) fibrinous colitis, c) ulcerative colitis and d) healing of ulcers. Fibrinous colitis replaces catarrhal colitis, usually in the 2nd week after the onset of the disease. Ulcers occur following the detachment of fibrinous pseudomembranes, are located more frequently in the rectum and sigmoid colon, have an irregular shape and can be extensive and deep. Local complications are perforation with the development of paraproctitis and peritonitis and intestinal hemorrhage. The most common general complications: reactive arthritis, conjunctivitis, urethritis. In patients with chronic Schigellosis may develop secondary amyloidosis.

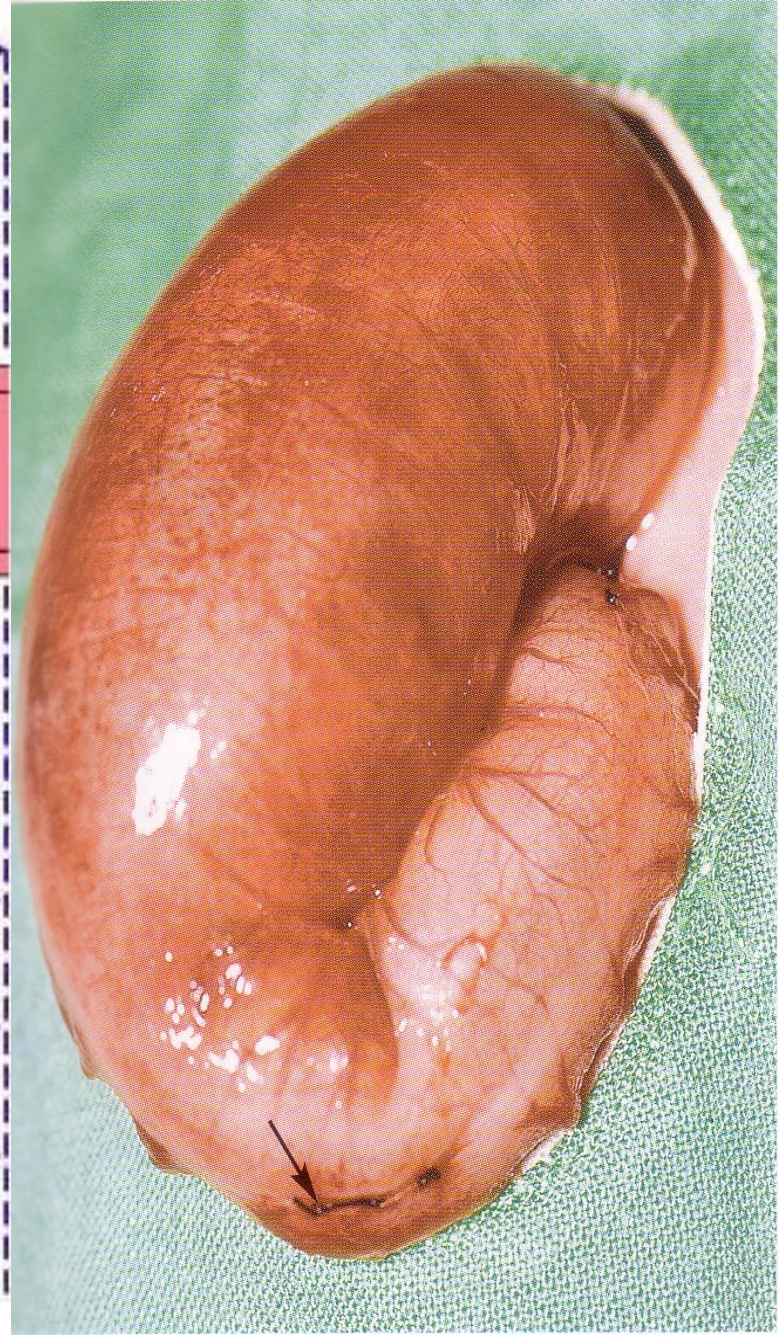
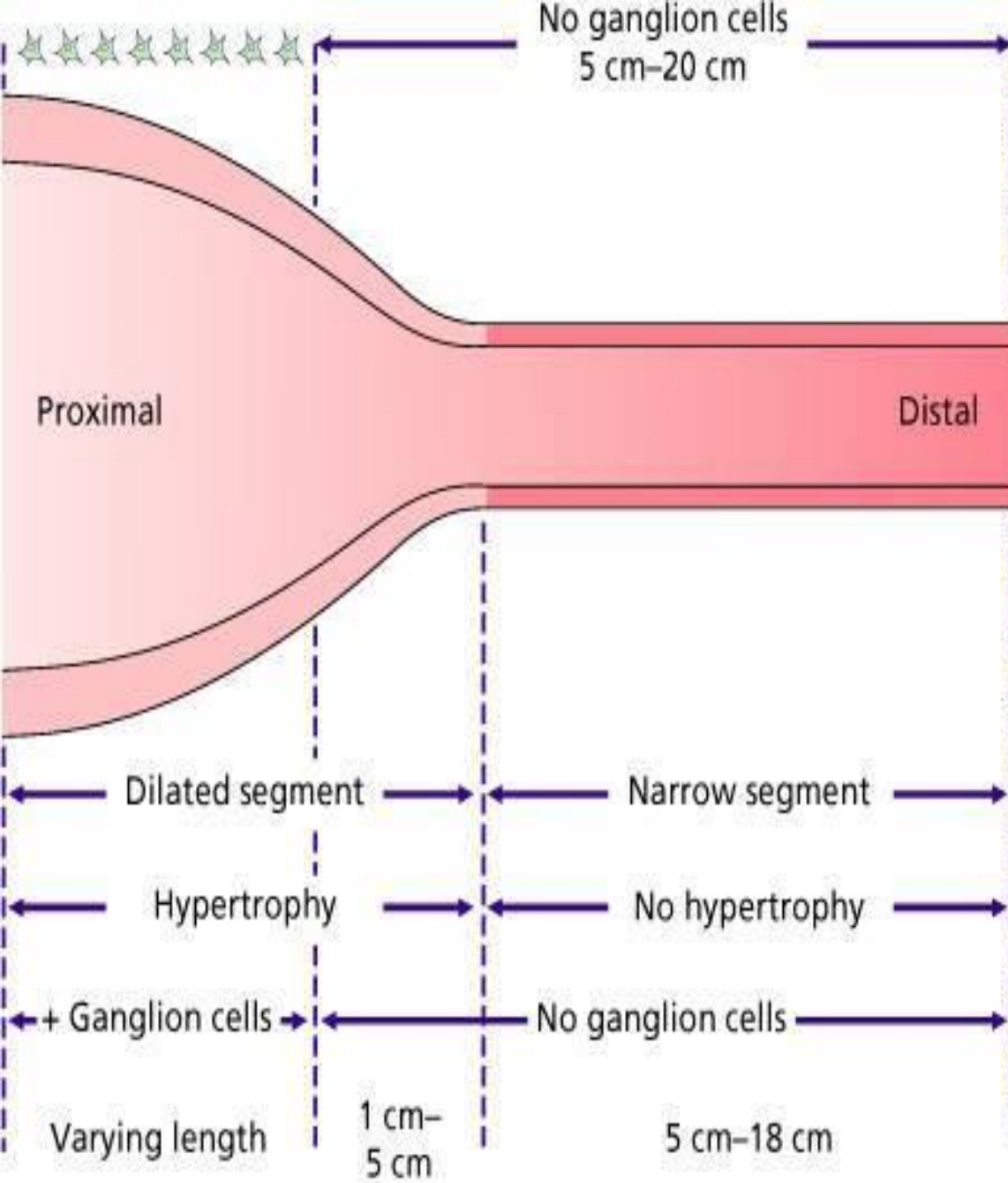


№ 57. Fibrinous ulcerative colitis in schigellosis.

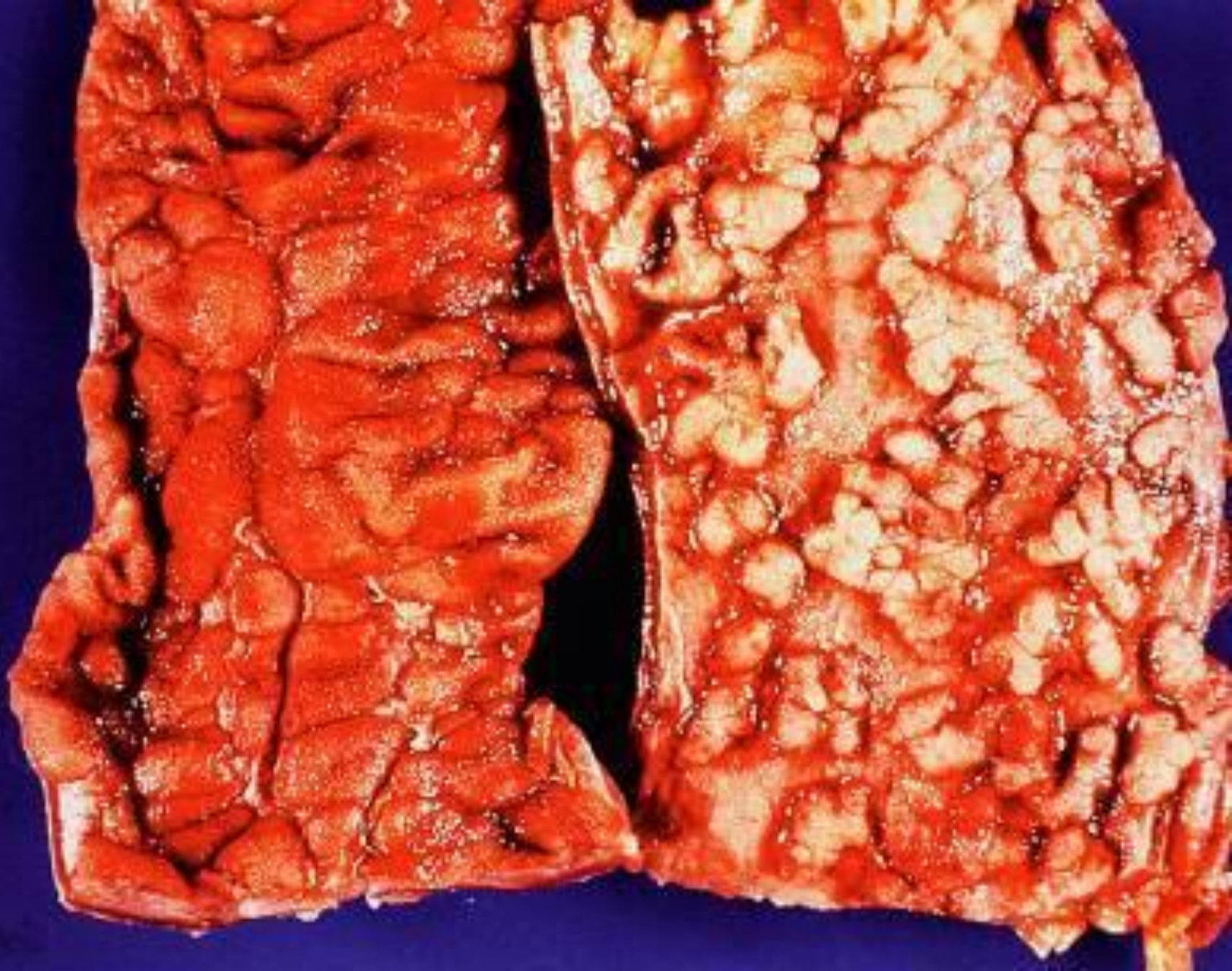


Meckel's diverticulum.

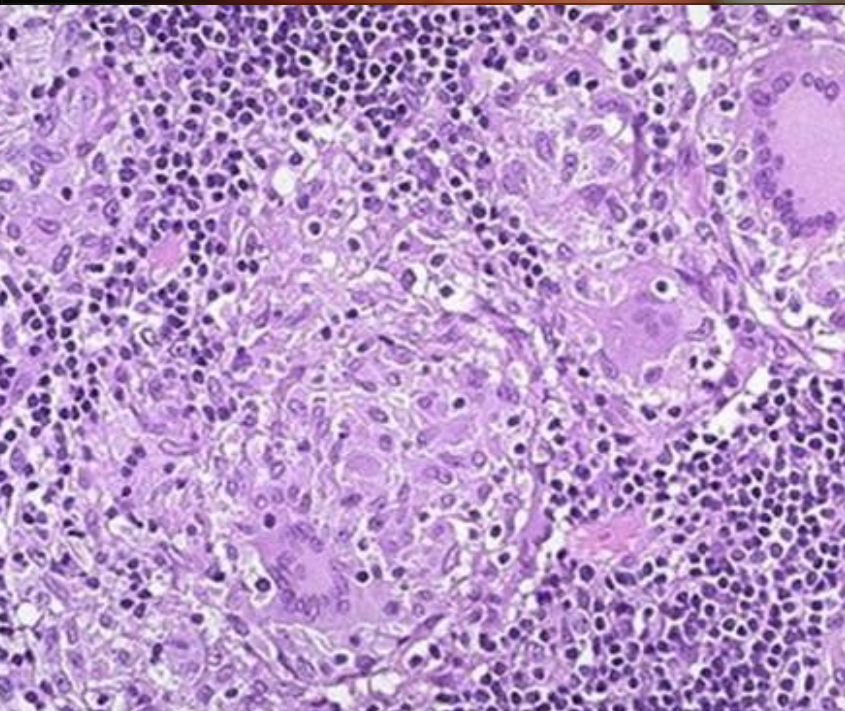
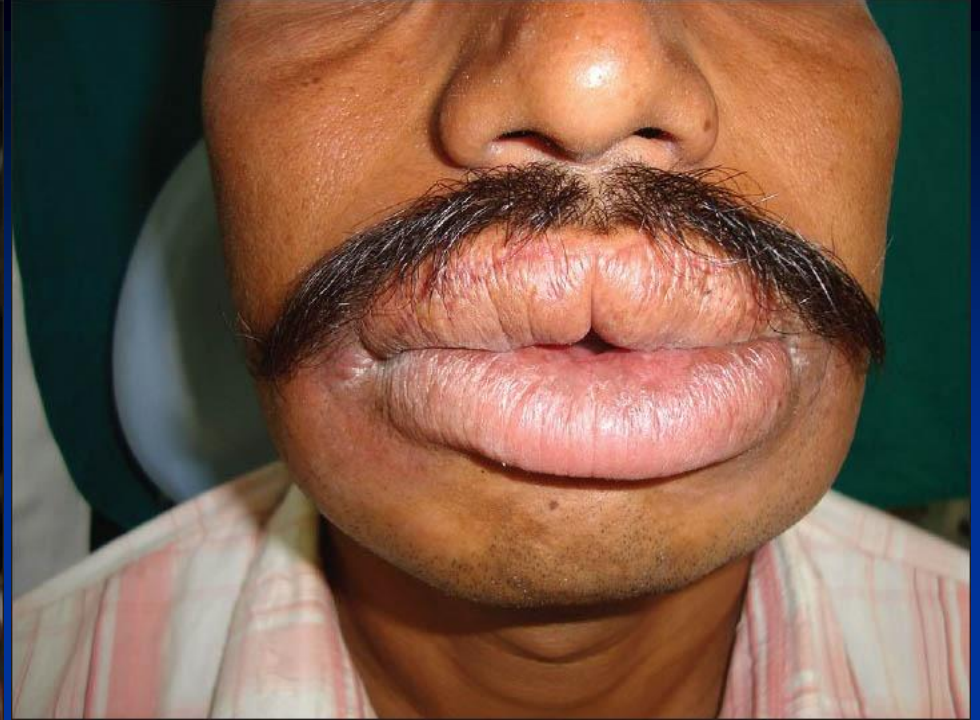
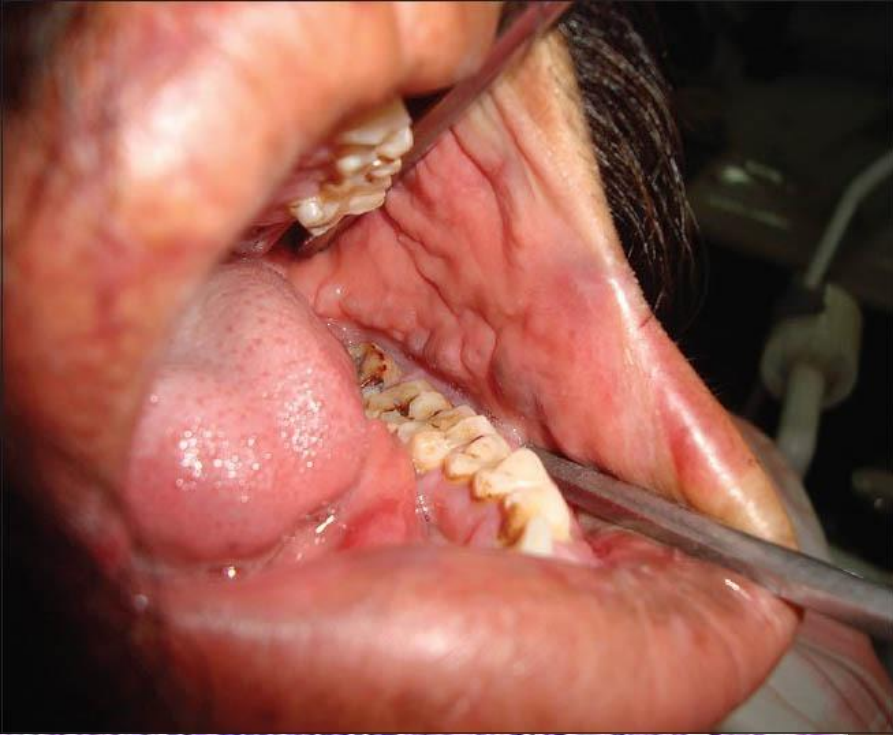


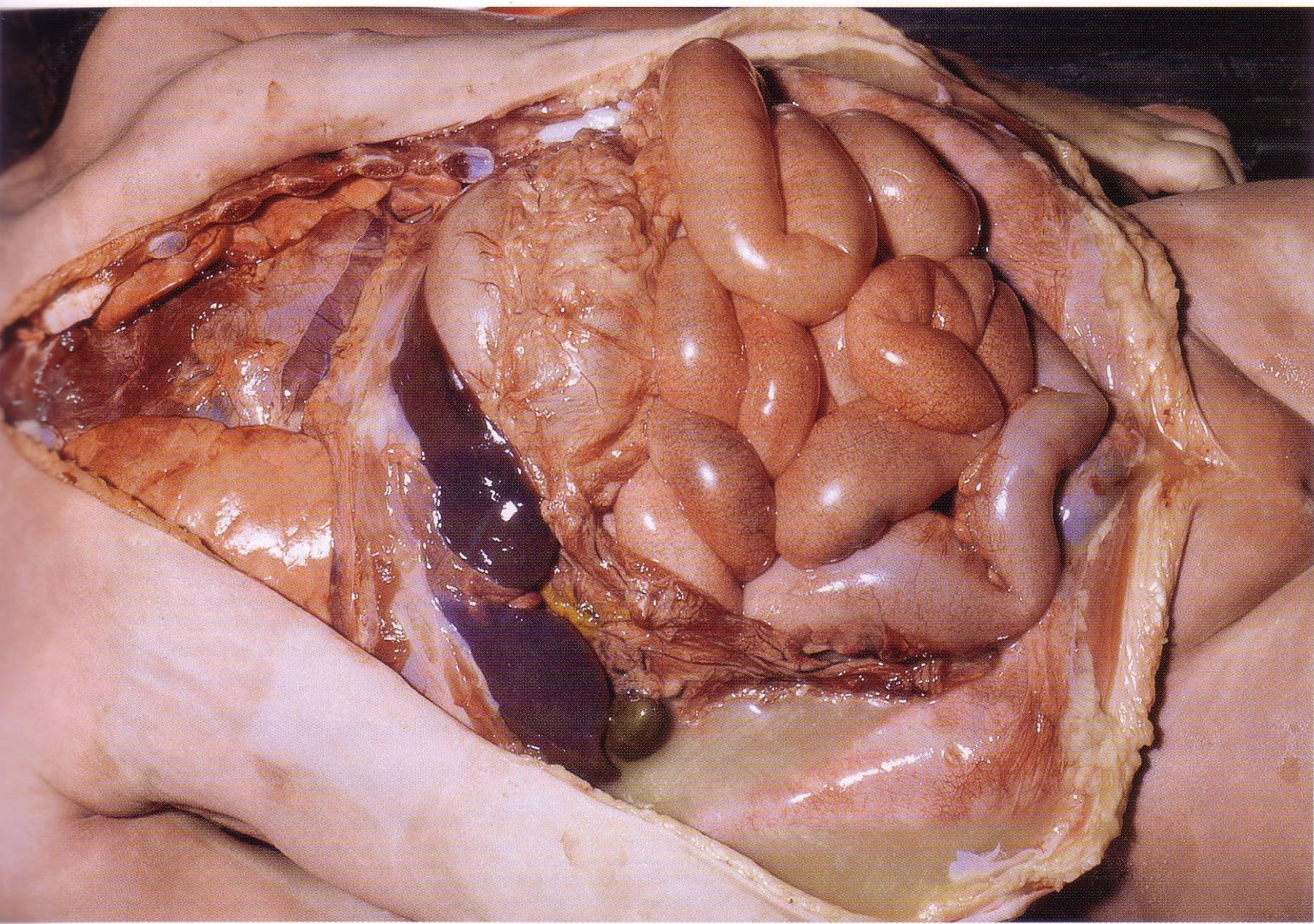
Scheme of large bowel involvement in Hirschsprung's disease.



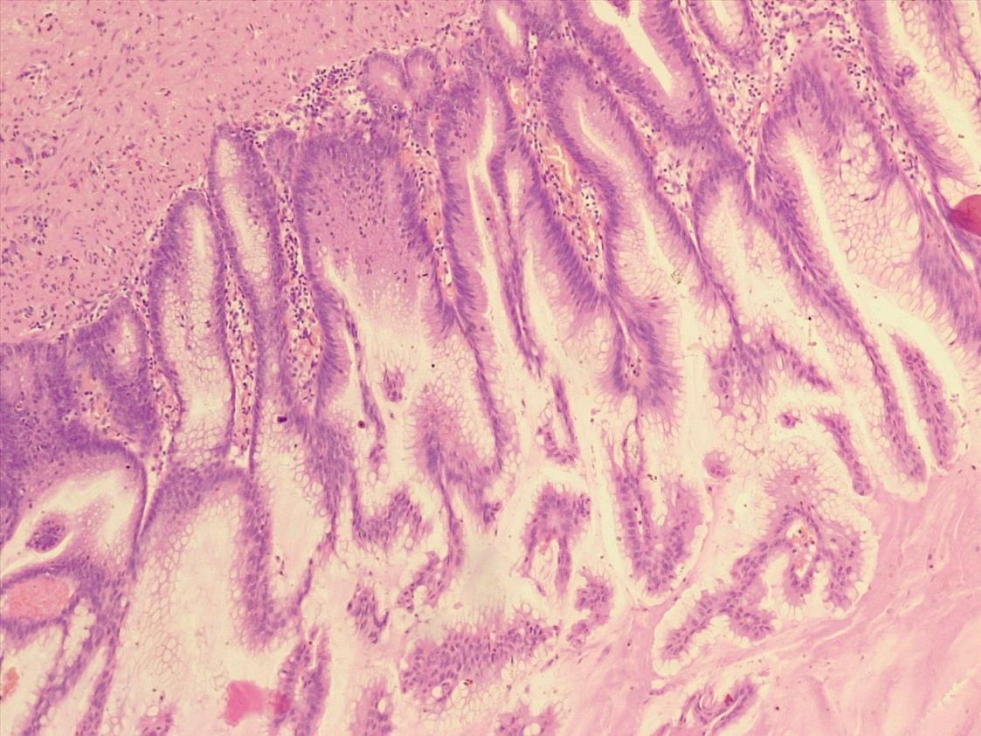
Crohn's disease vs. Nonspecific ulcerative colitis.



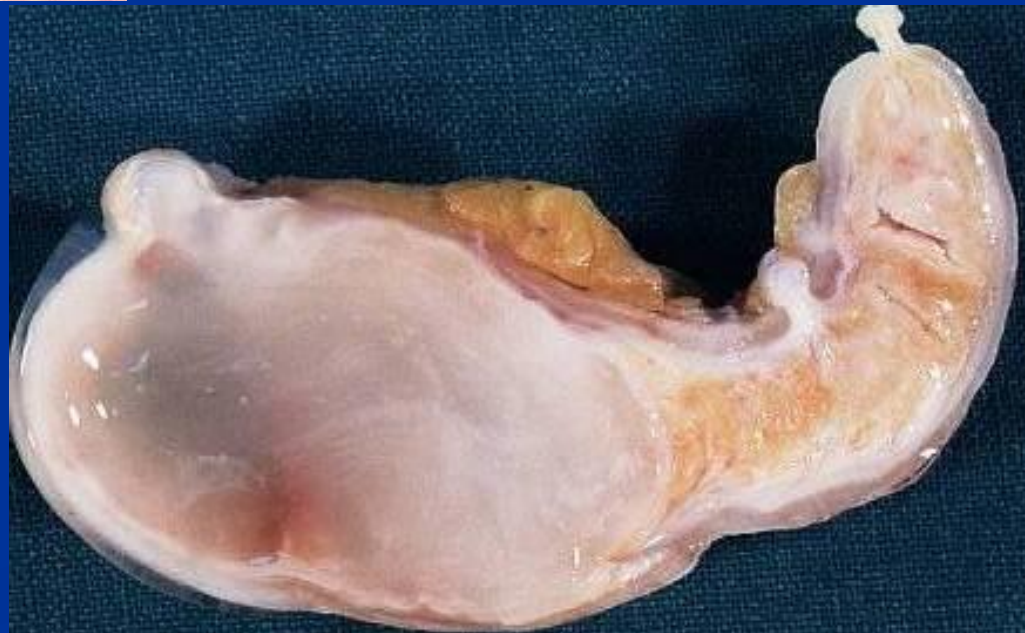Oral manifestations of Crohn's disease

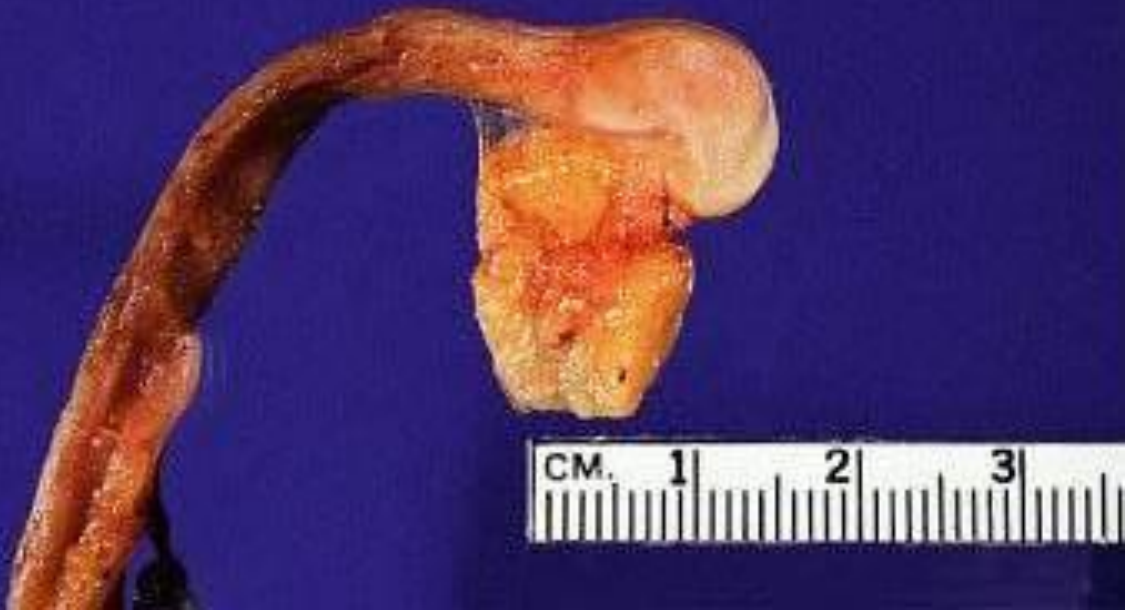

Purulent peritonitis - complication of acute appendicitis.

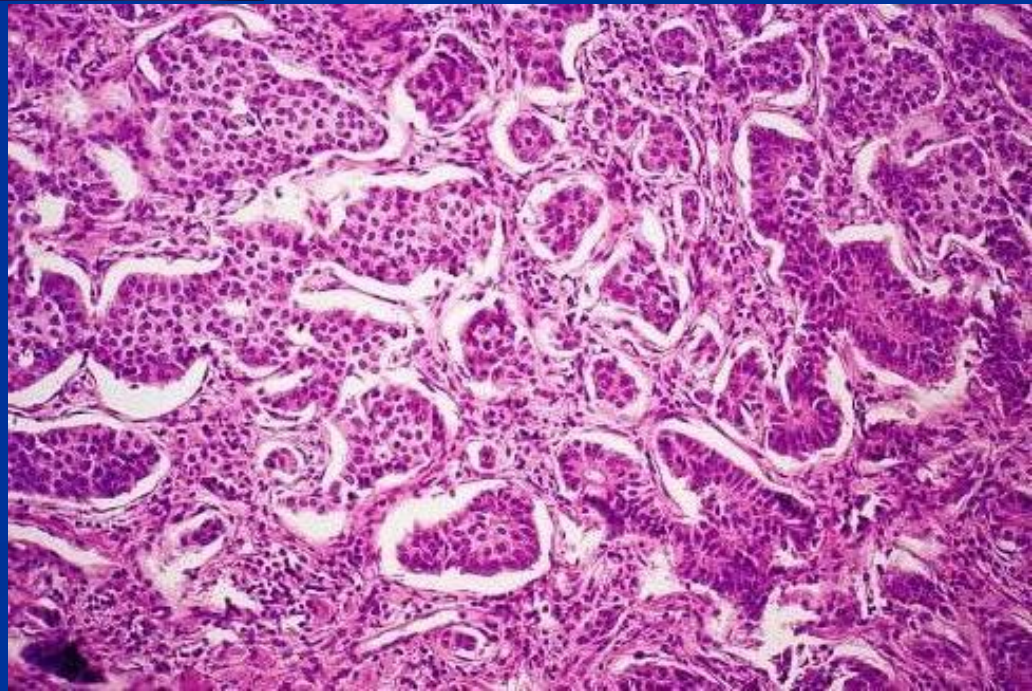


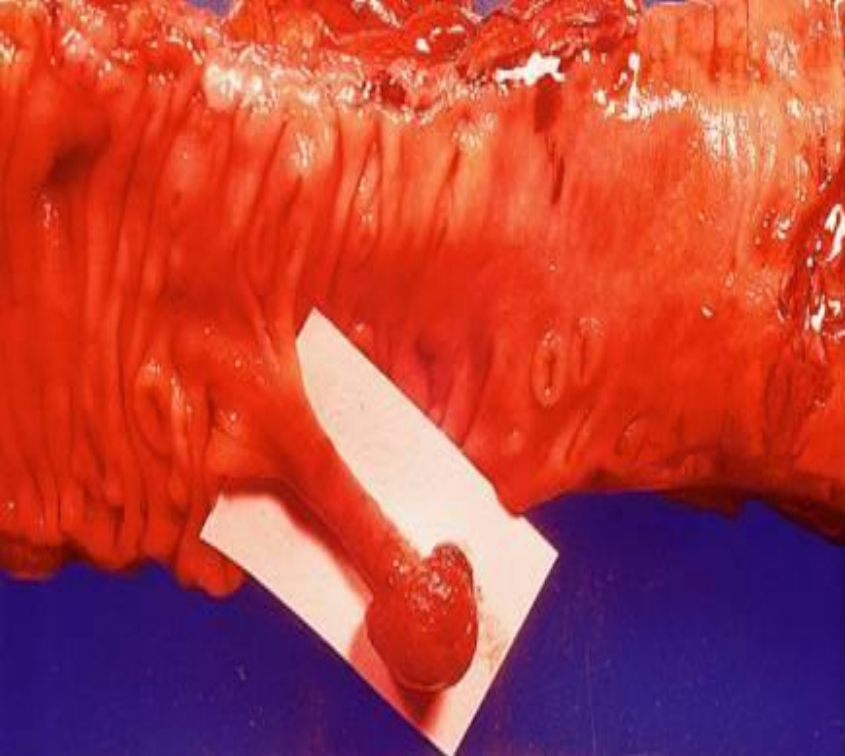
Mucocele of the appendix.



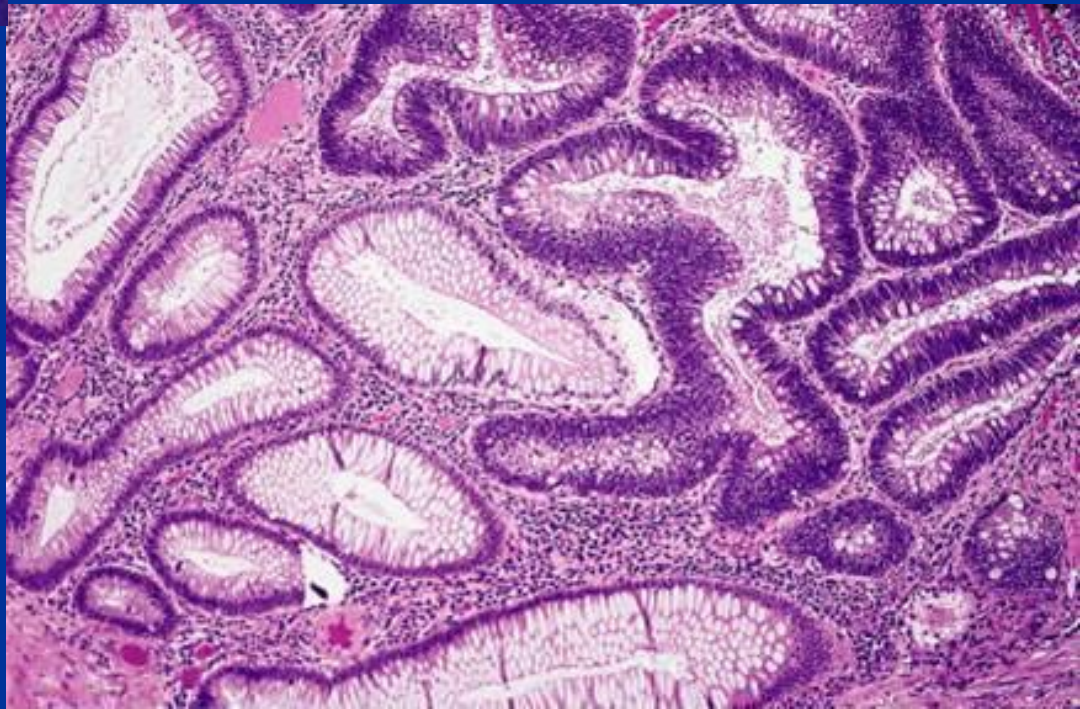


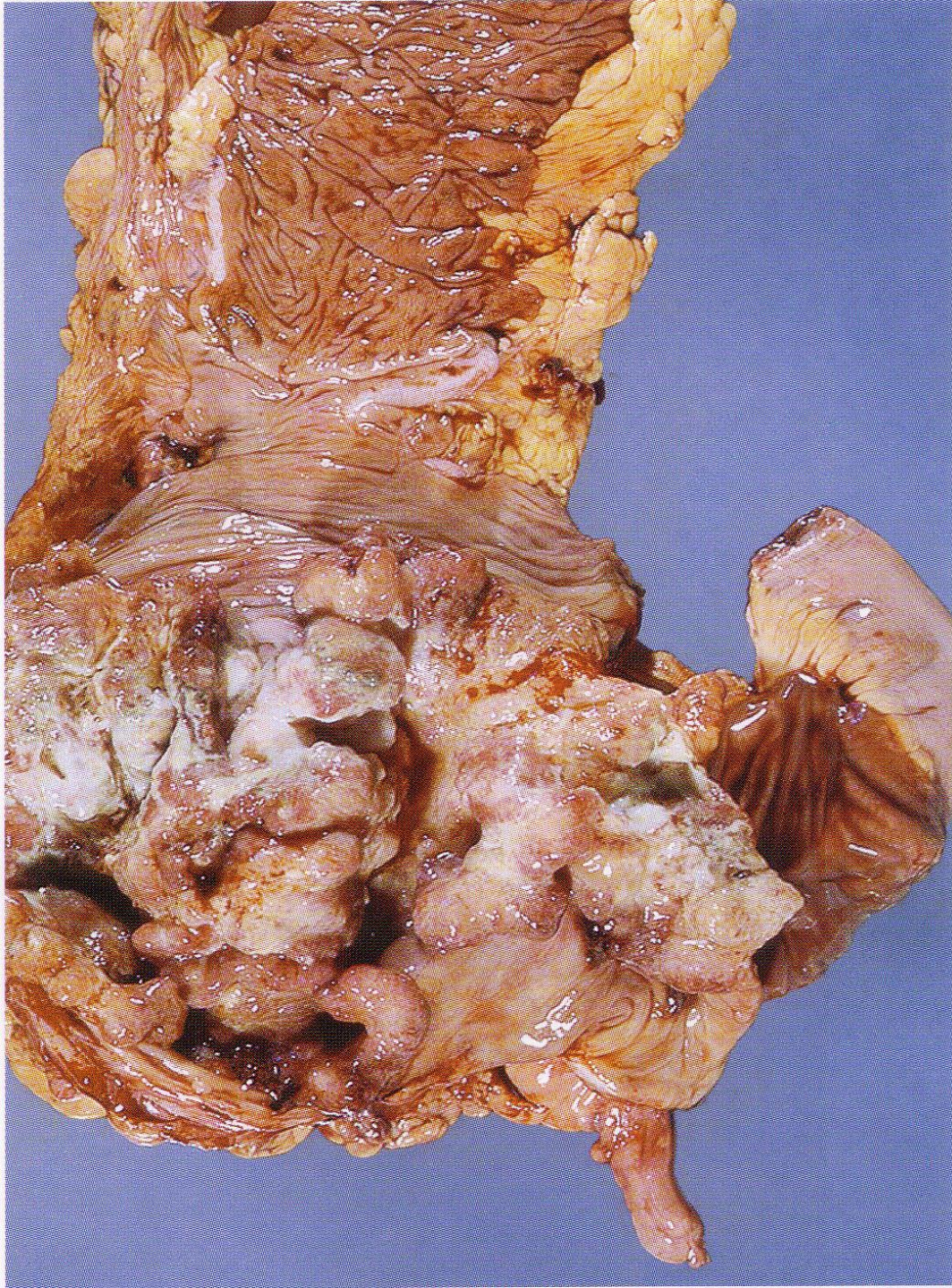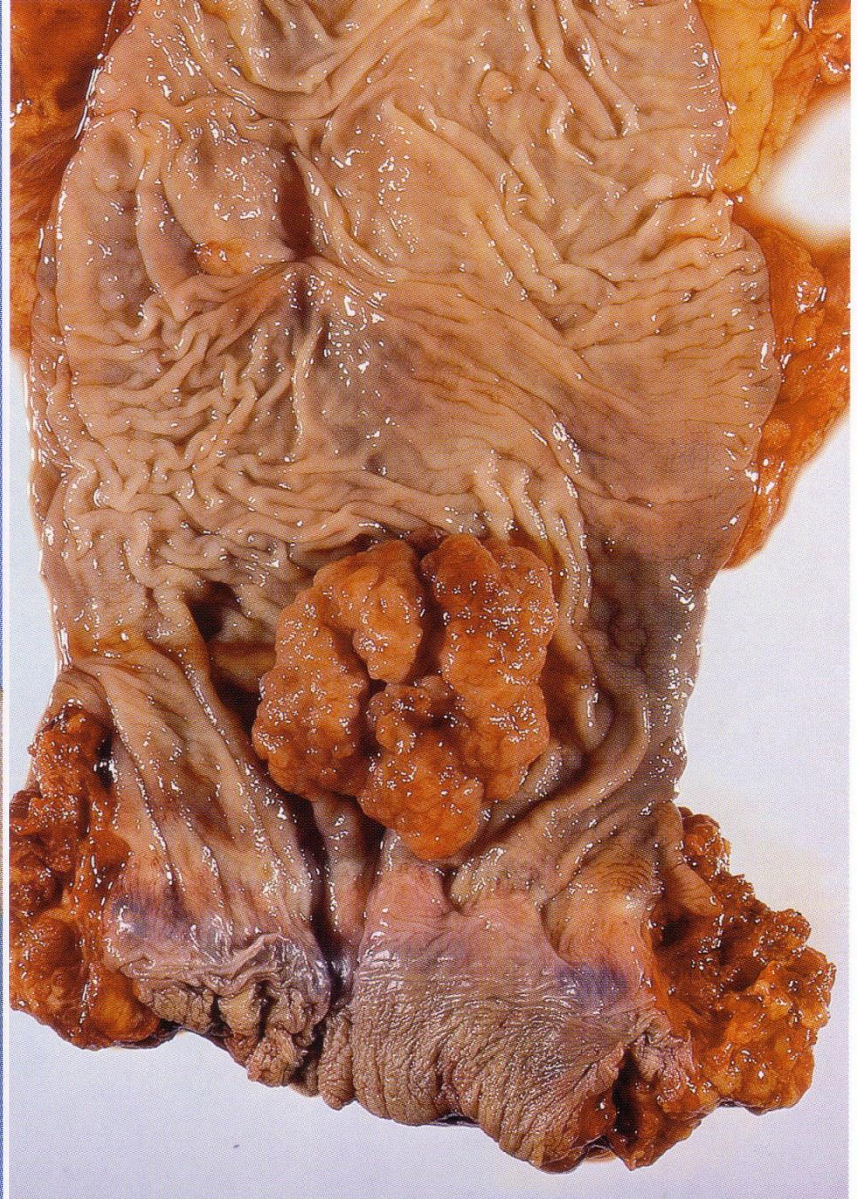
Appendicular carcinoid.





Tubulo-villous adenoma of the colon.





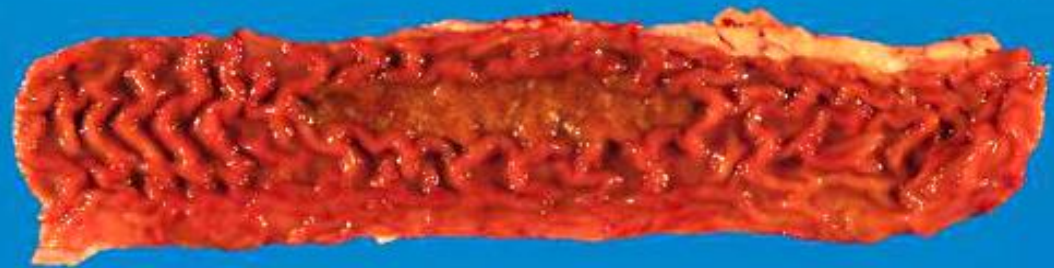**Carcinoma of the cecum
and rectum**



Peyer's patches necrosis in typhoid fever

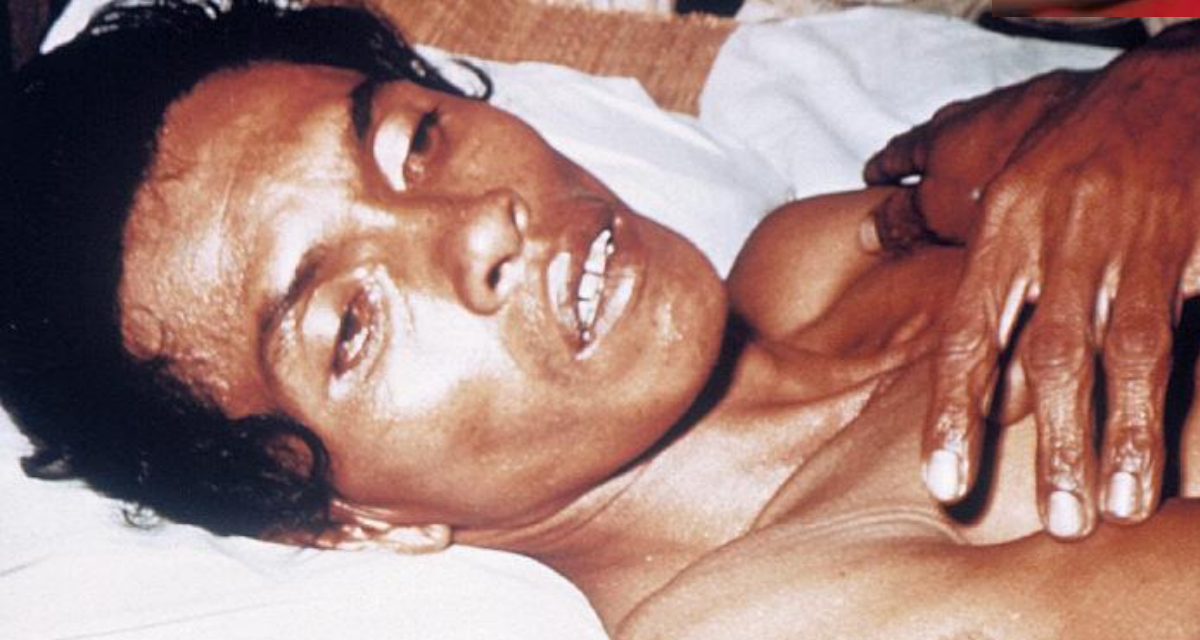
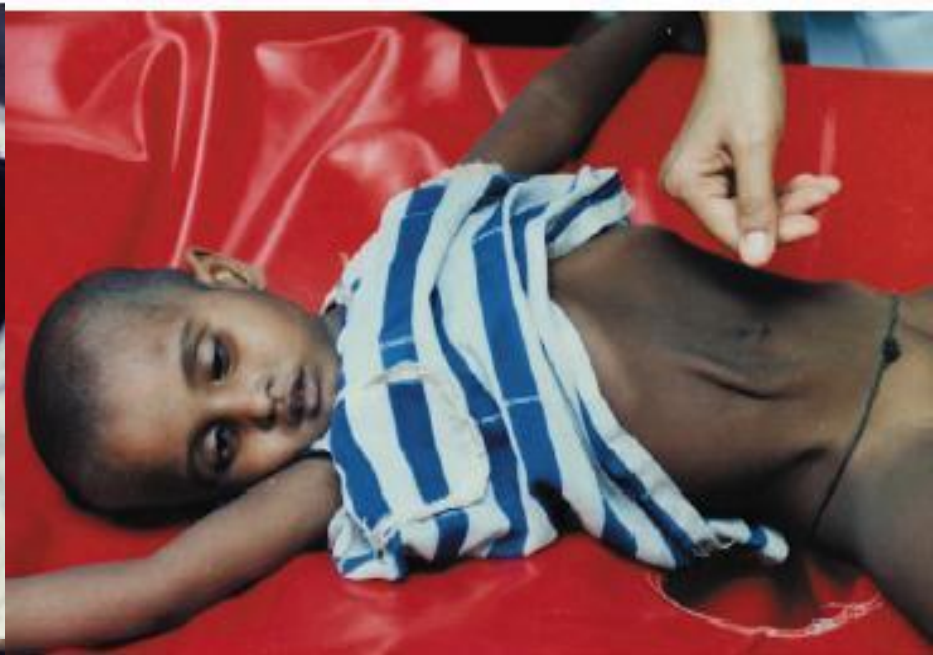
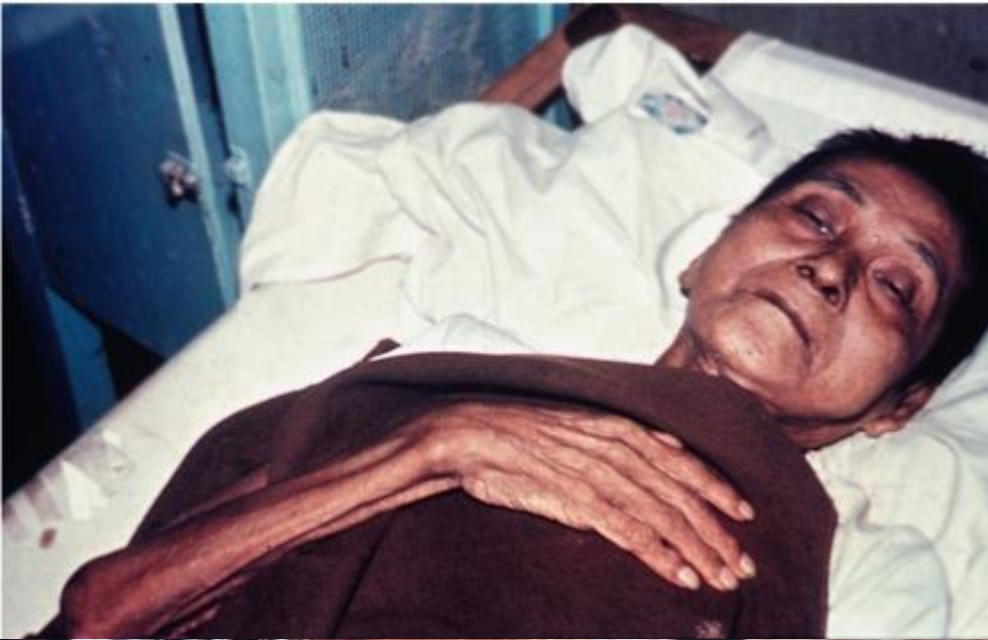Encephaloid modifications of Peyer's patches in typhoid fever.





The stage of ulcerations in typhoid fever.



A person with severe dehydration due to cholera - note the **sunken eyes** and decreased **skin turgor** which produces **wrinkled hands** and skin

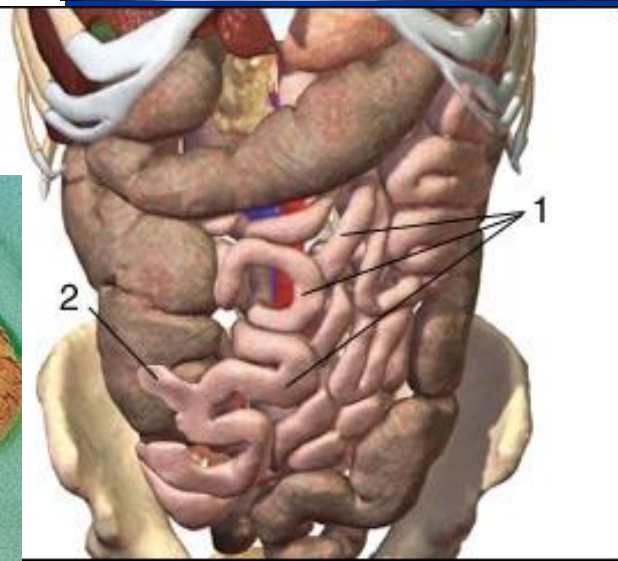
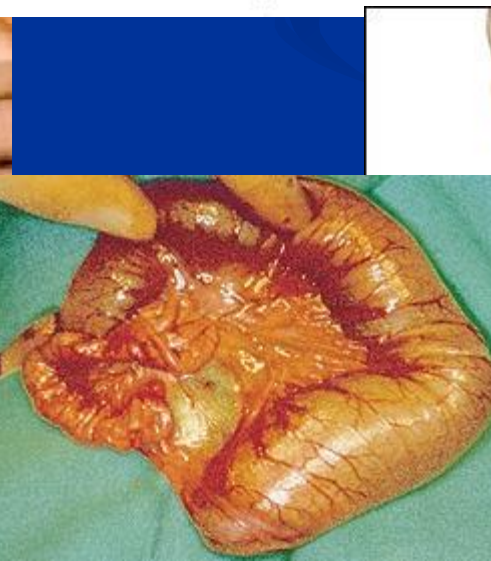
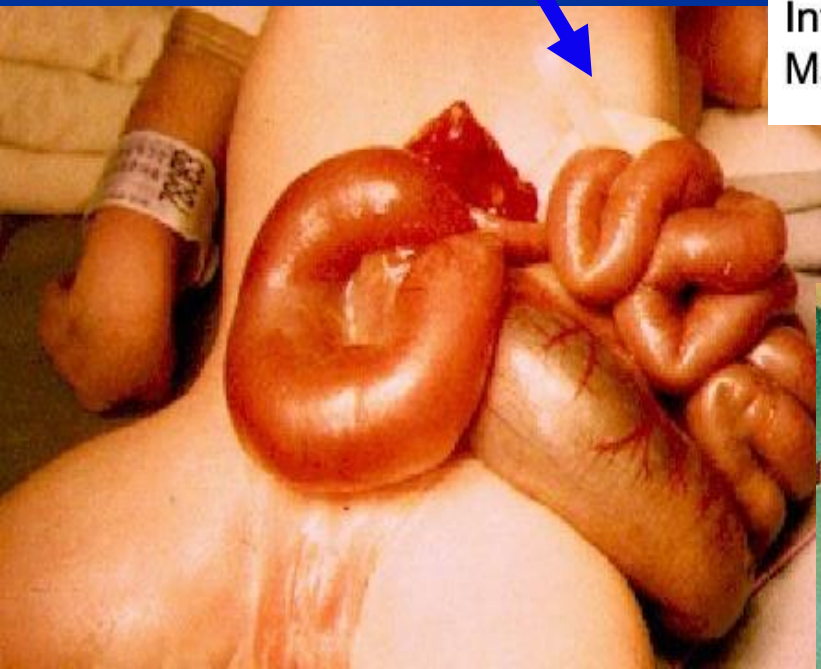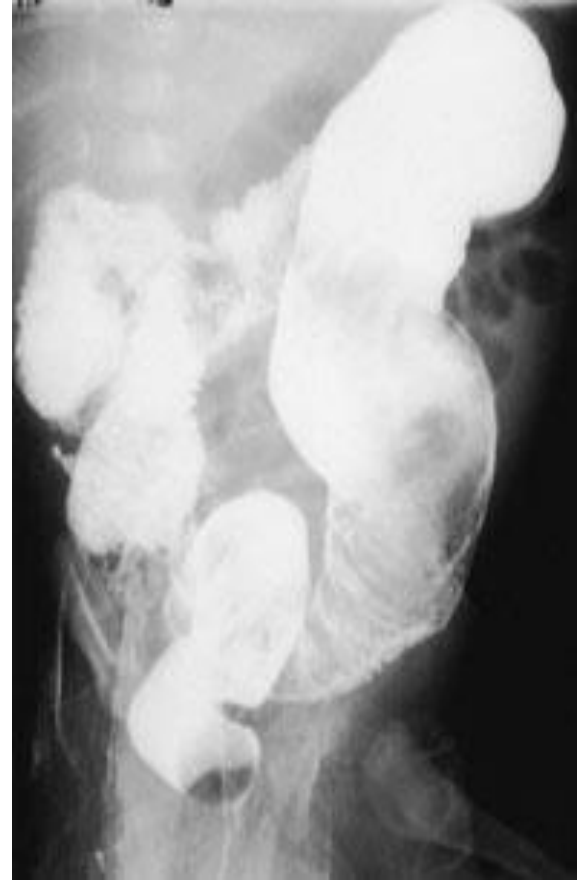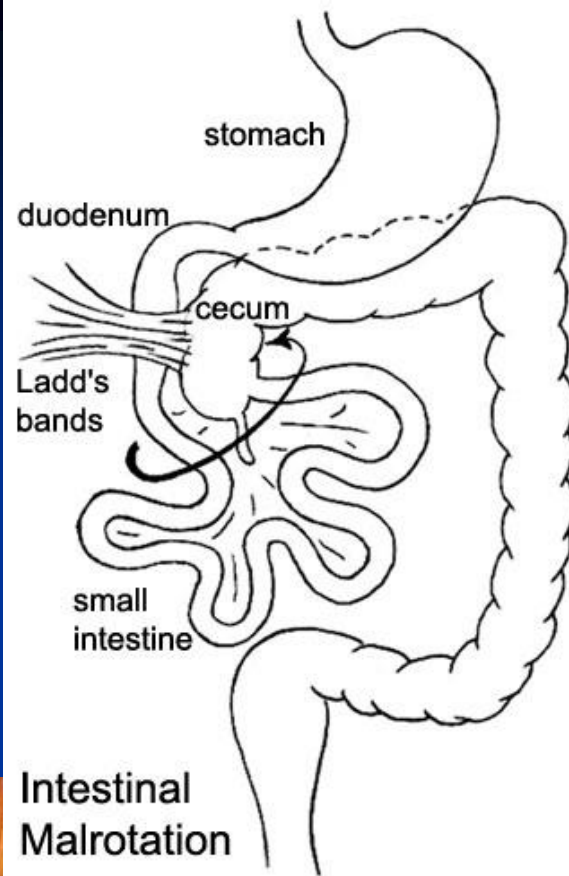
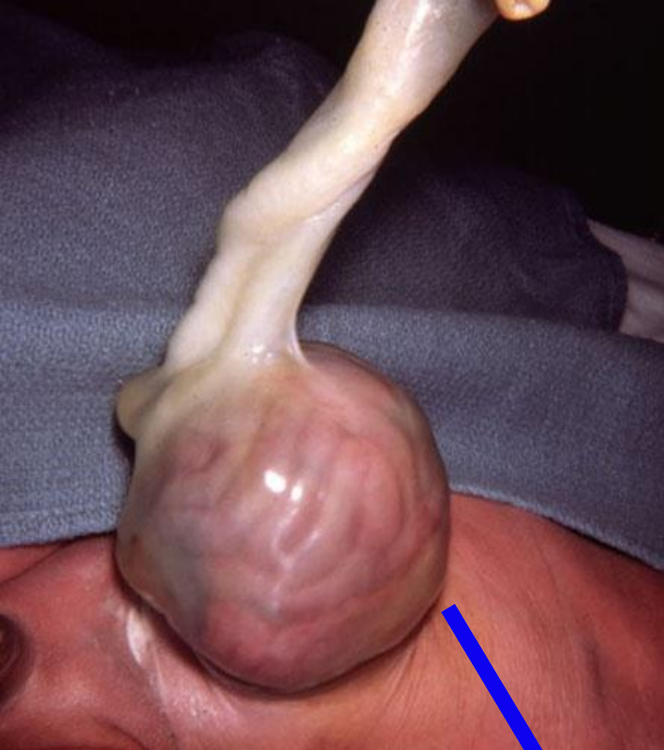Algid stage in cholera.

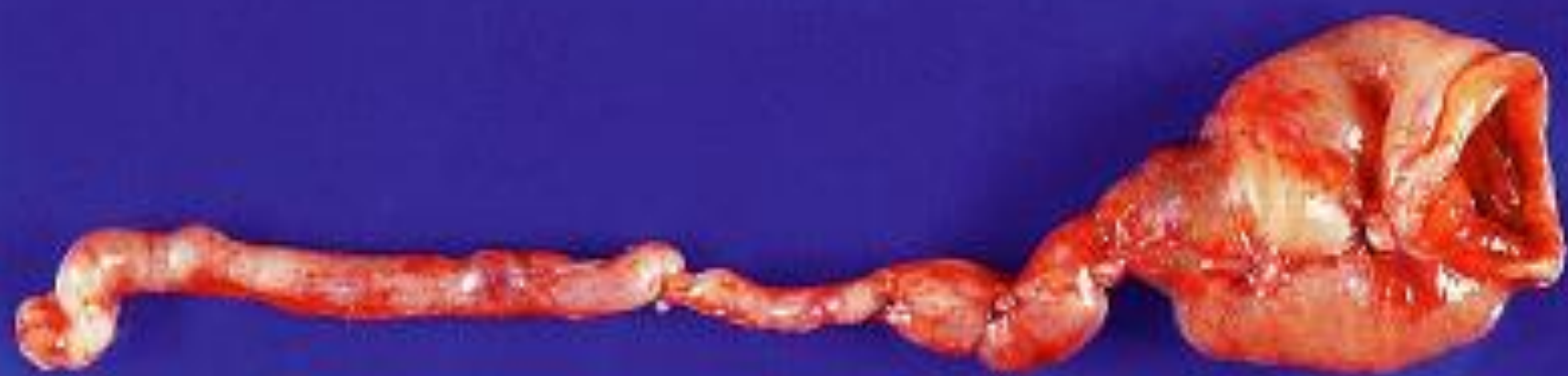SMALL/LARGE INTESTINE

- **NORMAL:** Anat., Vasc., Mucosa, Endocr., Immune, Neuromuscular.
- **PATHOLOGY:**
 - CONGENITAL
 - ENTEROCOLITIS: DIARRHEA, INFECTIOUS, OTHER
 - MALABSORPTION: INTRALUMINAL, CELL SURFACE, INTRACELL.
 - (I)IBD: CROHN DISEASE and ULCERATIVE COLITIS
 - VASCULAR: ISCHEMIC, ANGIODYSPLASIA, HEMORRHAGIC
 - DIVERTICULOSIS/-ITIS
 - OBSTRUCTION: MECHANICAL, PARALYTIC (ILEUS) (PSEUDO)
 - TUMORS: BENIGN, MALIGNANT, EPITHELIAL, STROMAL

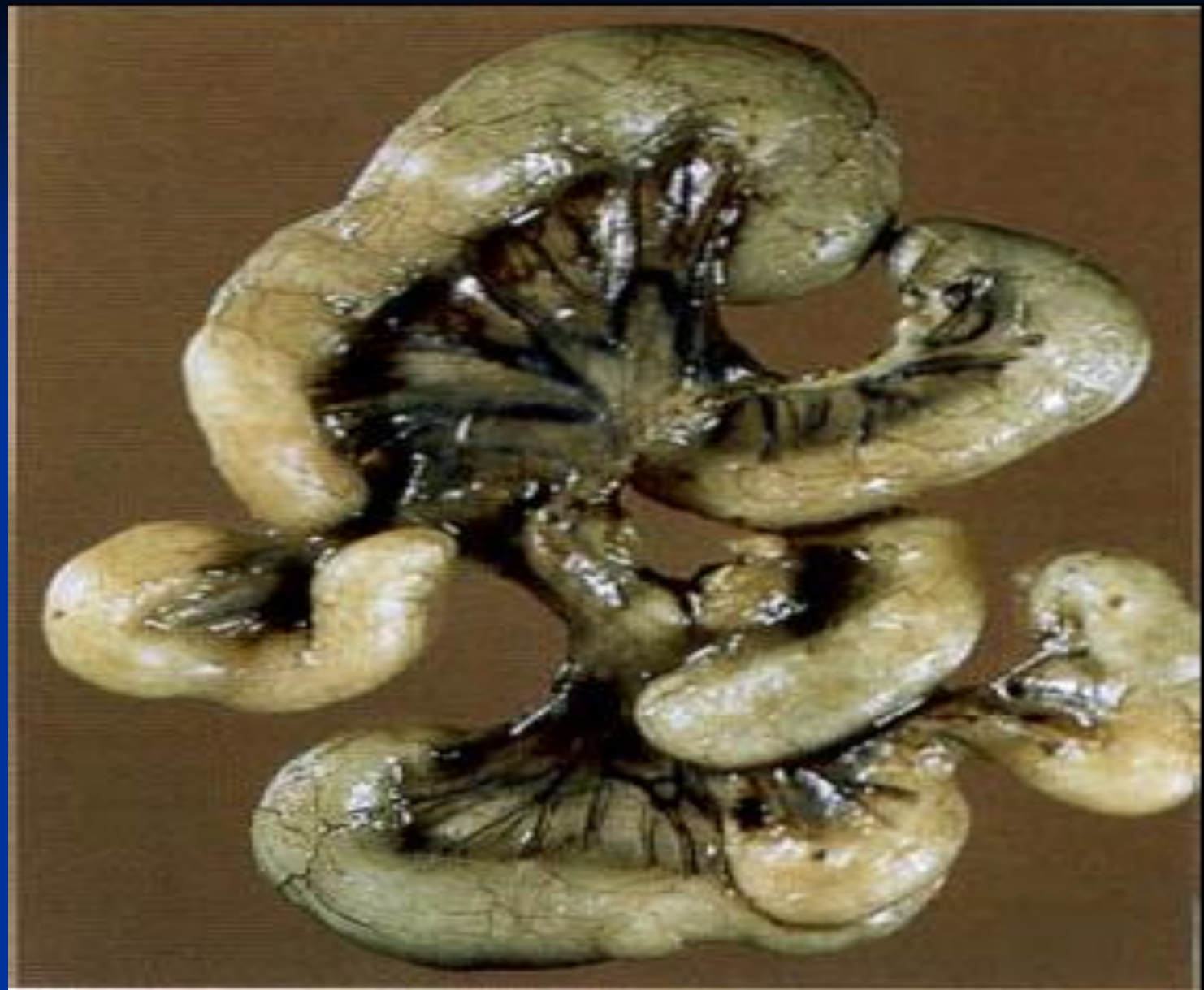CONGENITAL

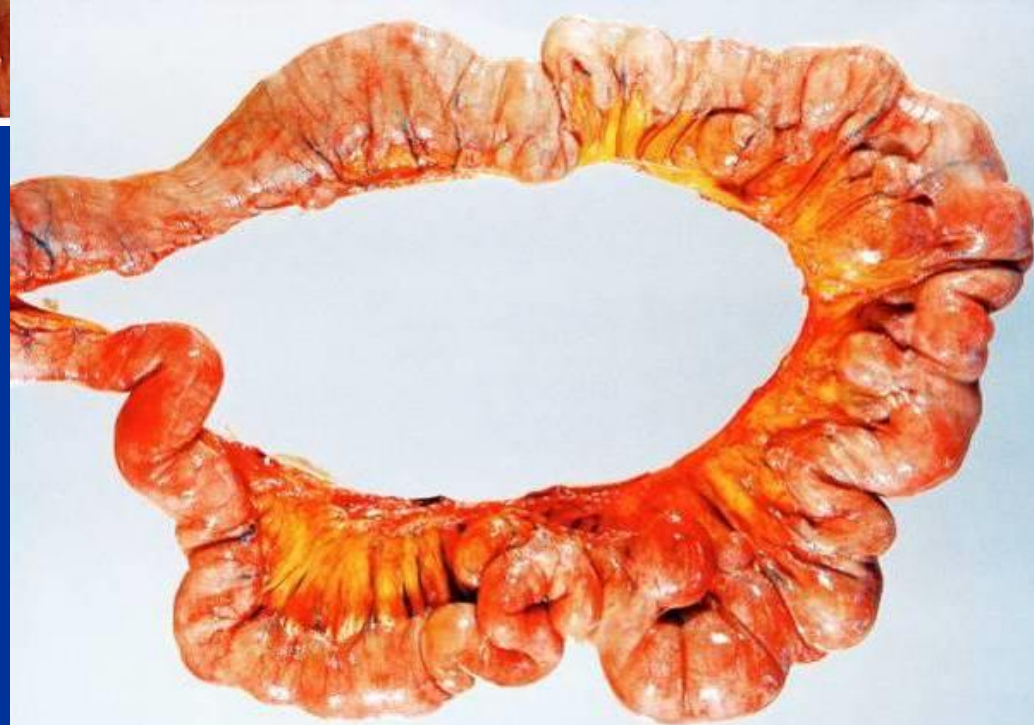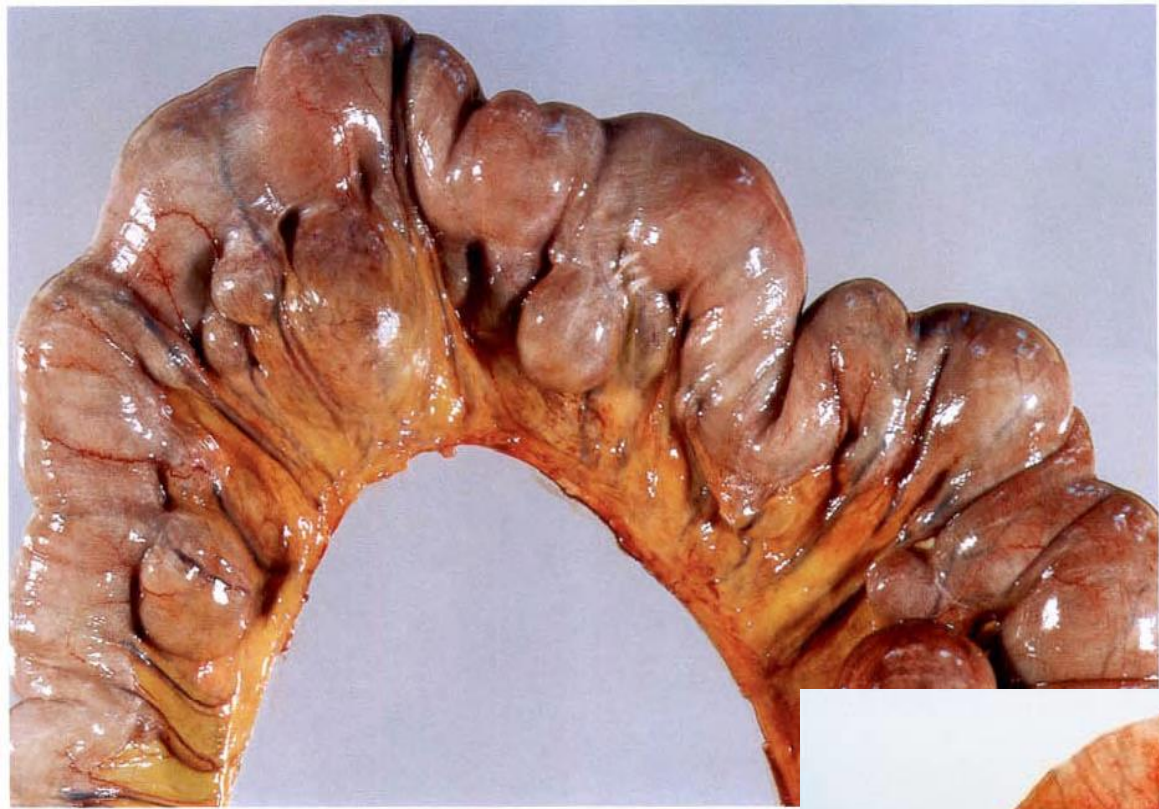- **DUPLICATION**
- **MALROTATION**
- **OMPHALOCELE**
- **ATRESIA/STENOSIS SPECTRUM**
- **MECKEL (terminal ileum, “vitelline” duct)**
- **AGANGLIONIC MEGACOLON
(HIRSCHSPRUNG DISEASE)**

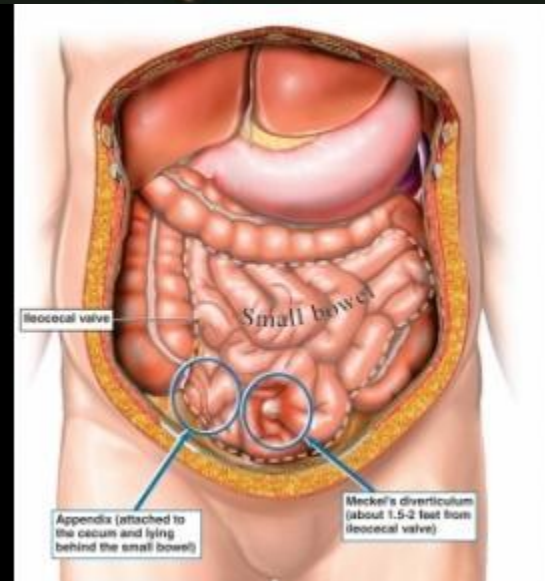
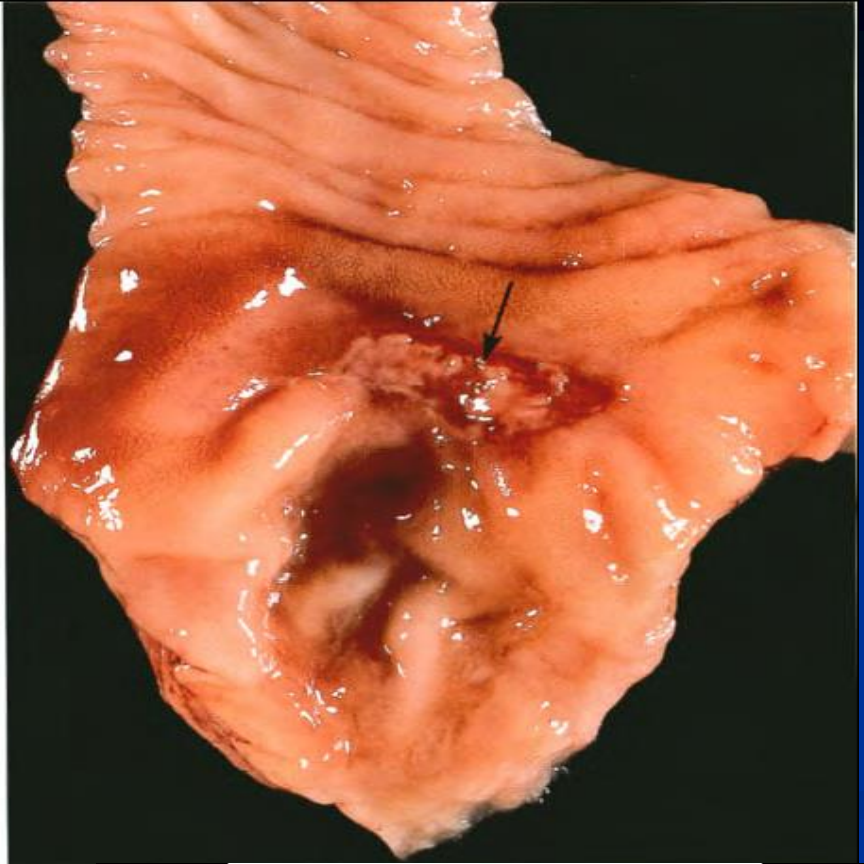
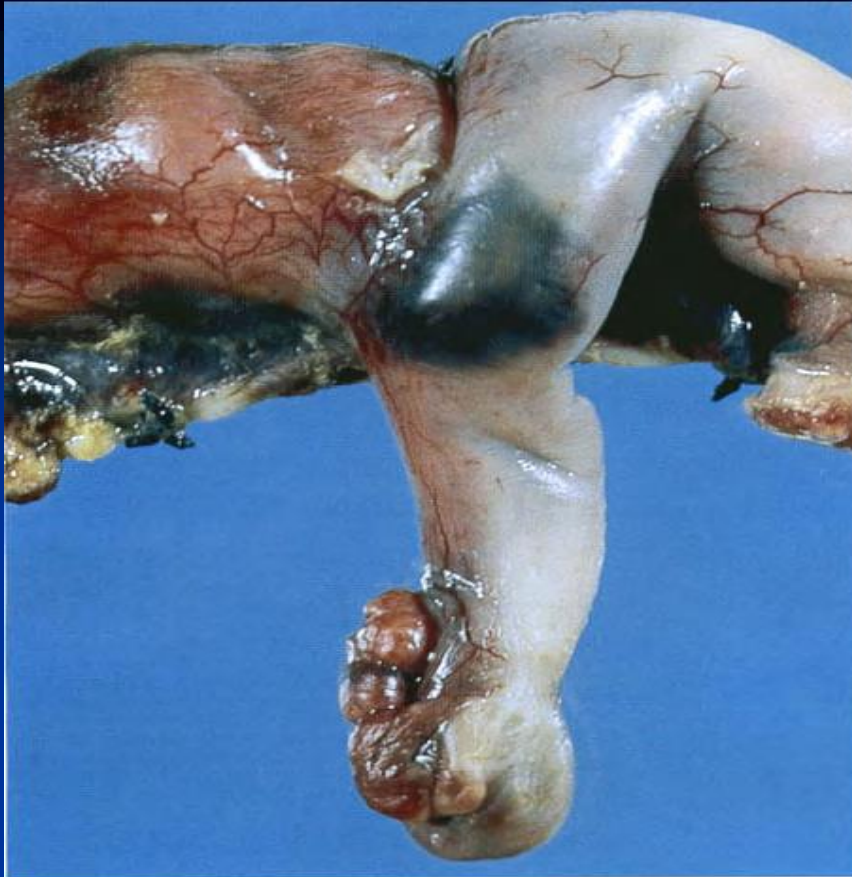


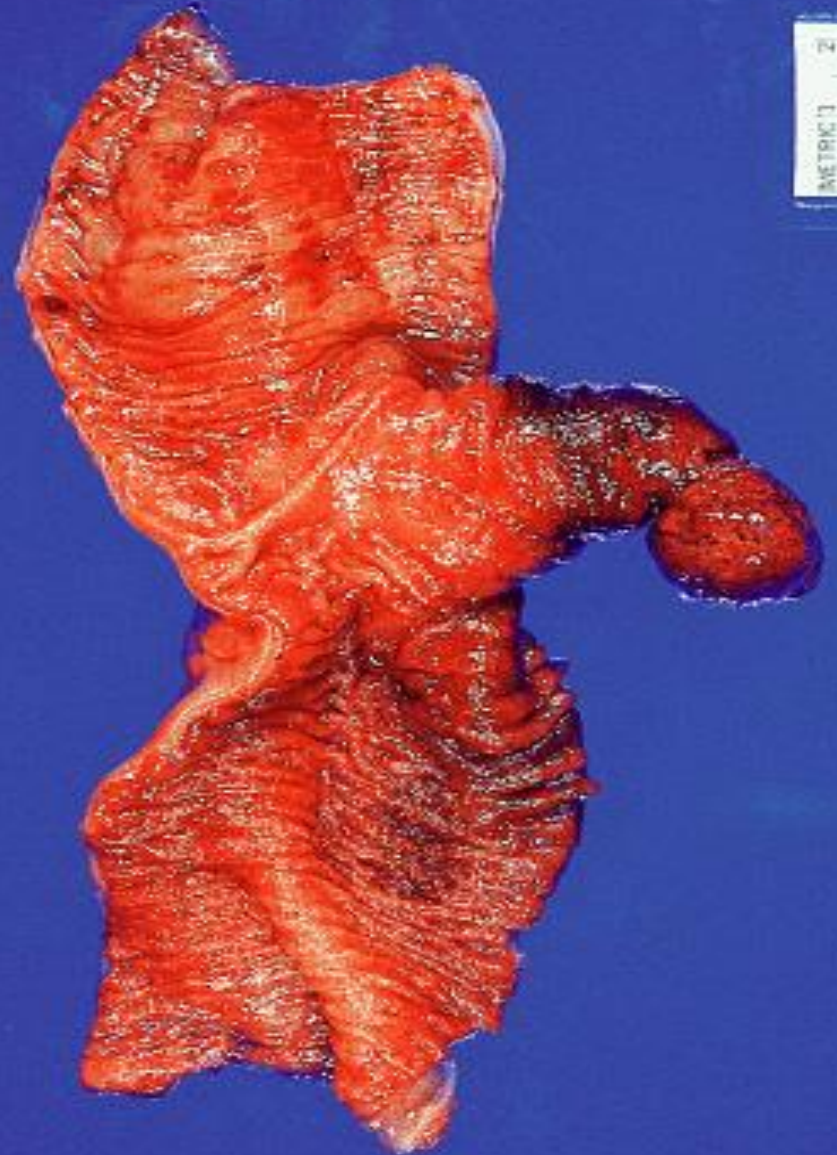
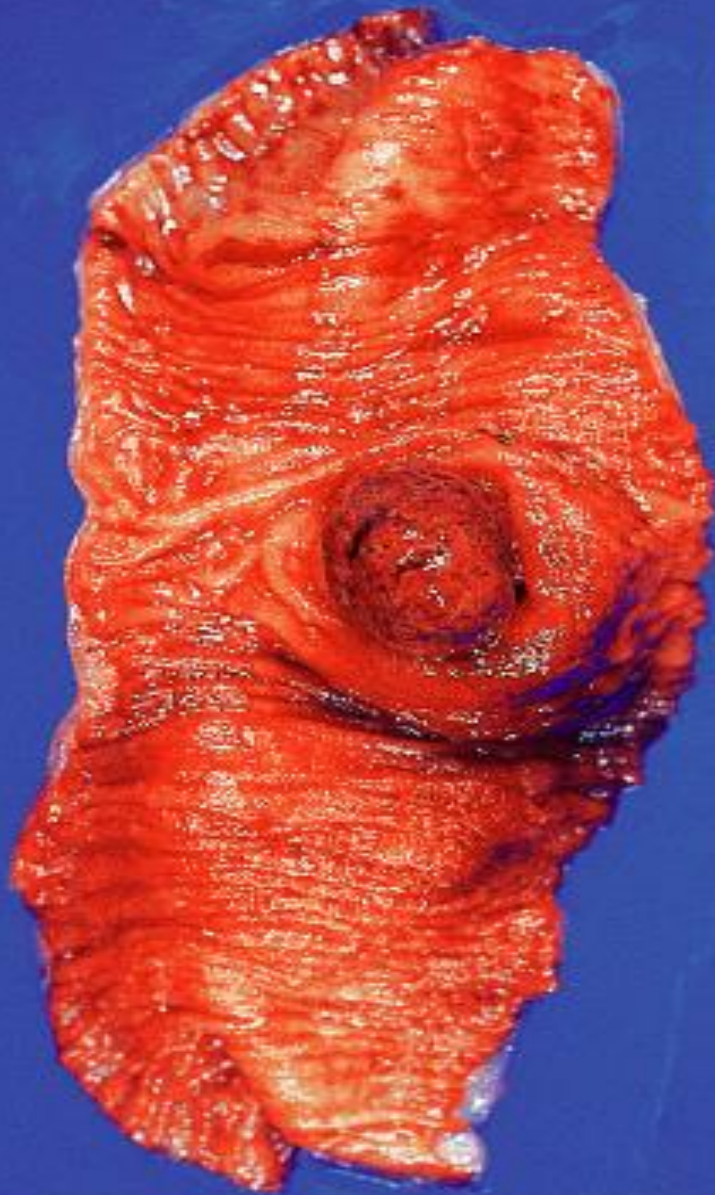© Elsevier Inc 2004 Rosai and Ackerman's Surgical Pathology 9e



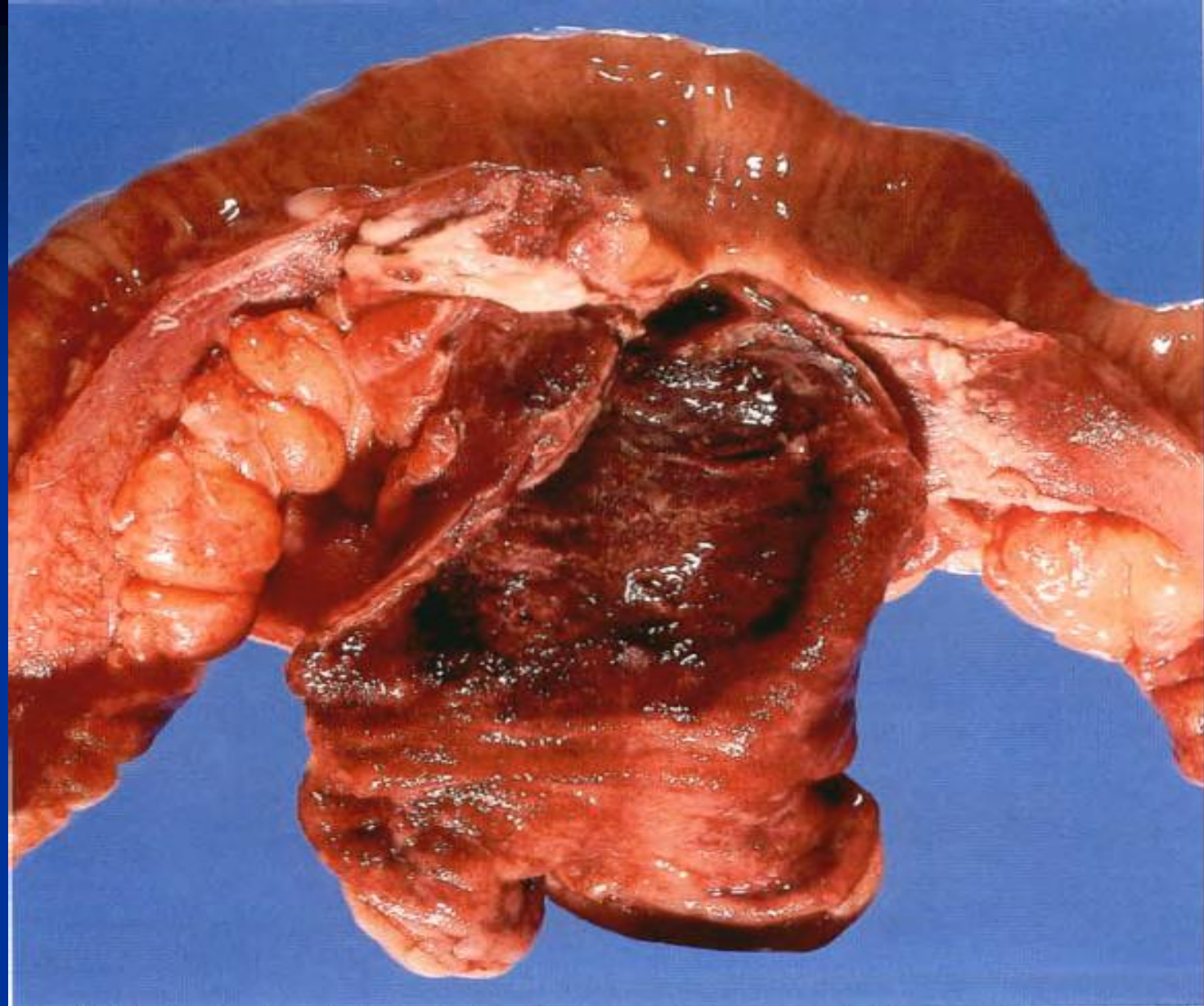


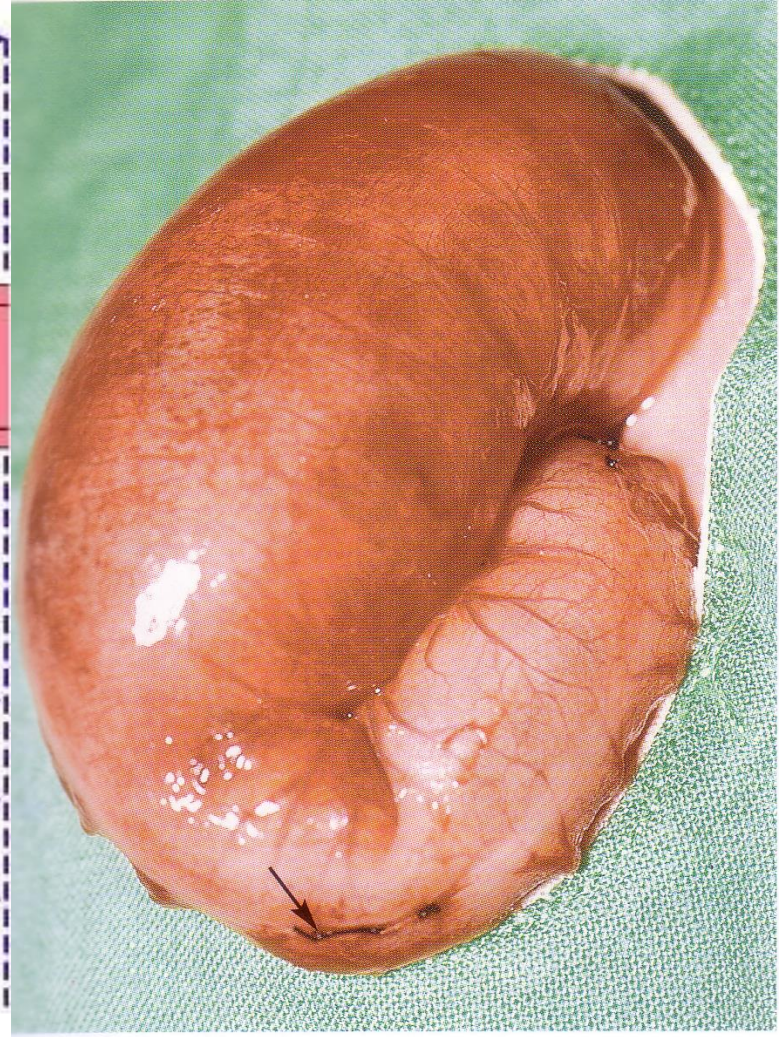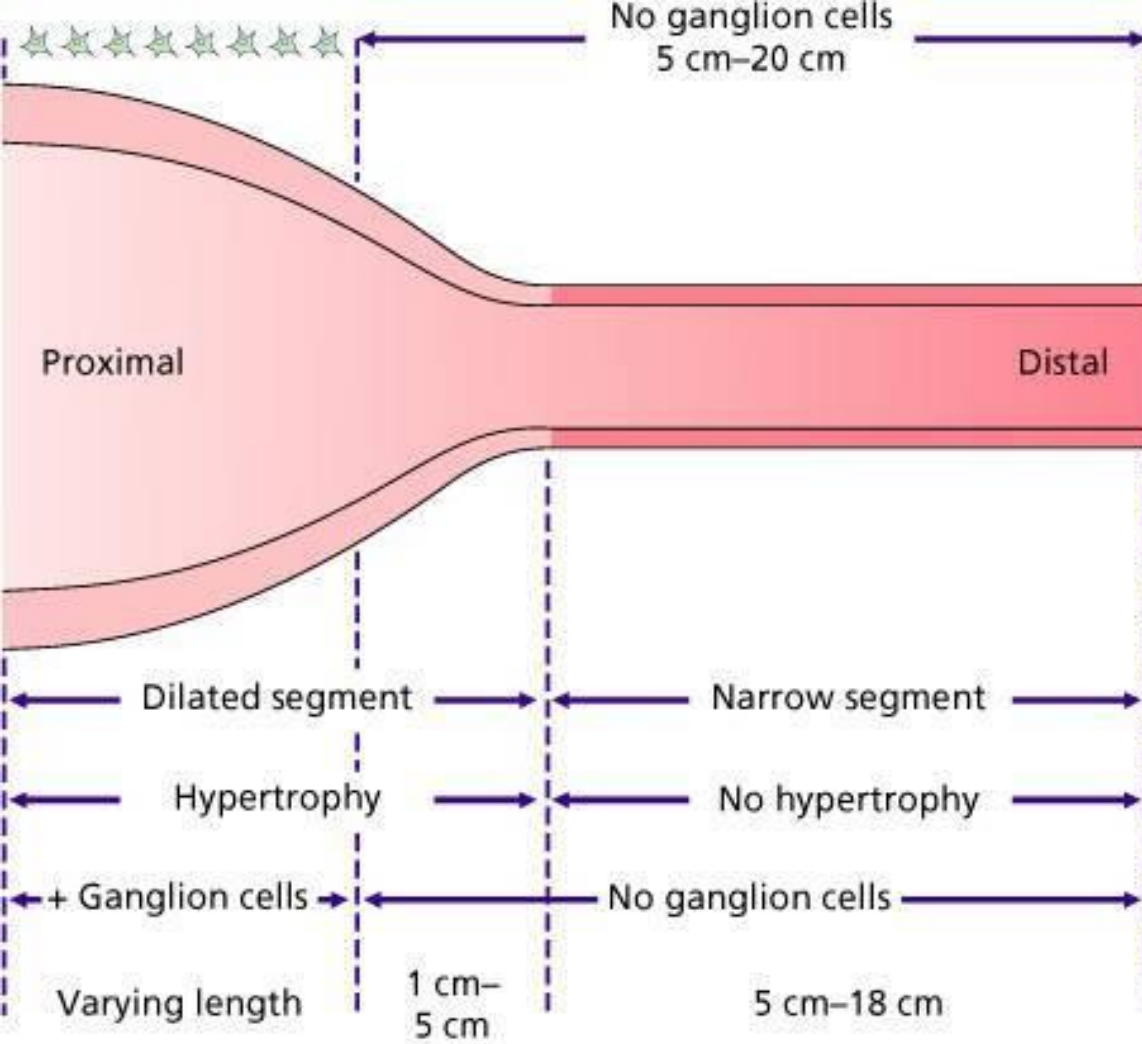




© Elsevier Inc 2004 Rosai and Ackerman's Surgical Pathology 9e

Intussusception of Meckel's diverticulum





Enterocolitis

- *Inflammation of the mucus membrane of small and large intestine*
- Infectious enterocolitis
- Drug related
- Radiation enterocolitis
- Ischemic bowel disease
- Lymphocytic colitis

Infectious enterocolitis

- Viral enterocolitis
 - Rotavirus
 - Immunosuppressed: CMV and adenovirus
- Bacterial enterocolitis
 - Three mechanisms of disease
 1. Ingestion of a preformed toxin in food
 - Staph aureus, vibrios, clostridium perfringens
 2. Infection by non-invasive toxigenic organism
 - E.coli, Vibrios cholerae
 3. Infection by enteroinvasive organism
 - Shigella, salmonella, E.coli, campylobacter, yersinia

Cholera

- **Vibrio cholerae (V. cholerae) is a gram-negative bacterium the causative agent of cholera. V. cholerae is transmitted primarily through contaminated water.**
- **Despite severe diarrhea, V. cholerae are non-invasive microorganisms that live and multiply in the lumen of the intestine.**
- **Vibrio cholera toxin causes a disease. The infection is enteric and usually occurs when drinking infected water. The incubation period lasts 3-5 days. "Alkalophilous" vibrios find the optimal environment in the small intestine. Here they multiply and secrete exotoxin (cholerogen).**
- **Under the influence of exotoxin, the epithelium of the mucous membrane secretes a large amount of isotonic fluid. Abundant secretion of fluid occurs as a result of the interaction of cholerogen with the enzyme systems of the cell; at the same time, the blockade of the "sodium pump" of the cell is important, which violates the reverse absorption of fluid from the intestinal lumen. Profuse diarrhea is associated with abundant secretion of fluid and a violation of its reverse absorption.**



A person with severe dehydration due to cholera - note the **sunken eyes** and decreased **skin turgor** which produces **wrinkled hands** and skin

Cholera

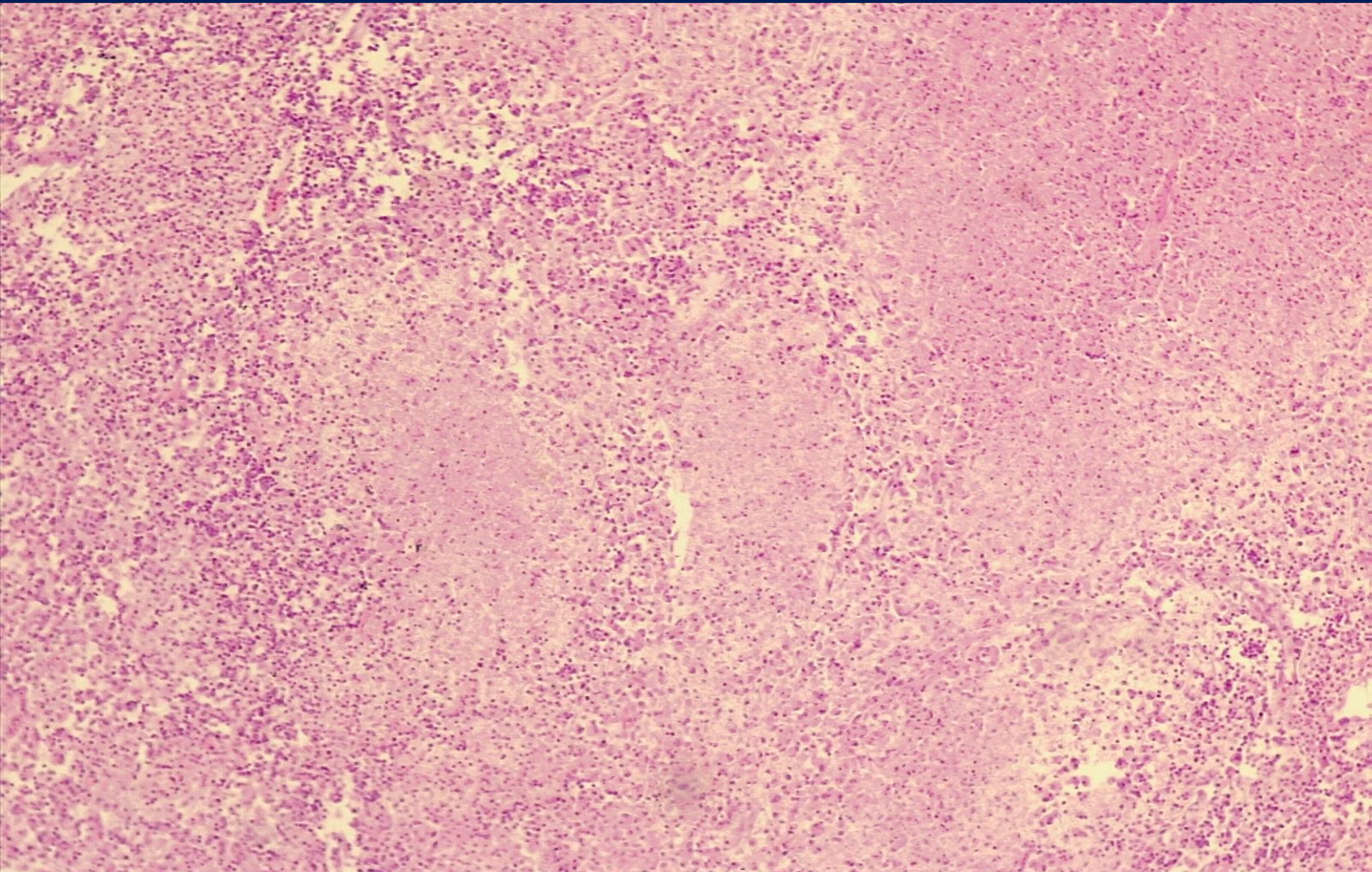
Shigellosis

- **Shigella (Shigella spp.)** Are gram-negative bacteria that were first isolated during the epidemic of red (bloody) diarrhea in Japan in 1897 (in Russia, the infection caused by shigella is called dysentery).
- Man is the only known reservoir of this microorganism. It has been established that 165 million new cases of shigellosis are recorded annually in the world.
- The infectious dose for Shigella is not more than a few hundred microorganisms, and 1 milliliter of feces in the acute period of the disease contains 10 millions microorganisms. As a result, shigella are quickly transmitted to humans by fecal-oral route or through contaminated water and products.

Typhoid fever

- Typhoid fever is an acute infectious disease from the intestinal group; typical anthroponosis. Caused by typhoid bacillus (*Salmonella typhi*).
- The source of infection is a sick person or a carrier, in the secretions of which (feces, urine, sweat) contains microbes. Infection occurs parenterally.
- The incubation period is 10-14 days. In the lower part of the small intestine, bacteria multiply, secrete endotoxins. From the intestine through the lymphatic paths, they enter the group lymphatic follicles (the so-called Peyer's patches) and solitary follicles, and then to the regional lymph nodes.
- Having overcome the lymphatic barrier, the pathogen enters the bloodstream. Bacteremia develops, which is especially pronounced during the 1st week of illness, when typhoid bacillus can be isolated from the blood (blood culture).

The stage of ulcer healing ends with the formation of tender scars in their place; the lymphoid tissue of the intestine is partially or completely restored, it becomes only slightly pigmented.

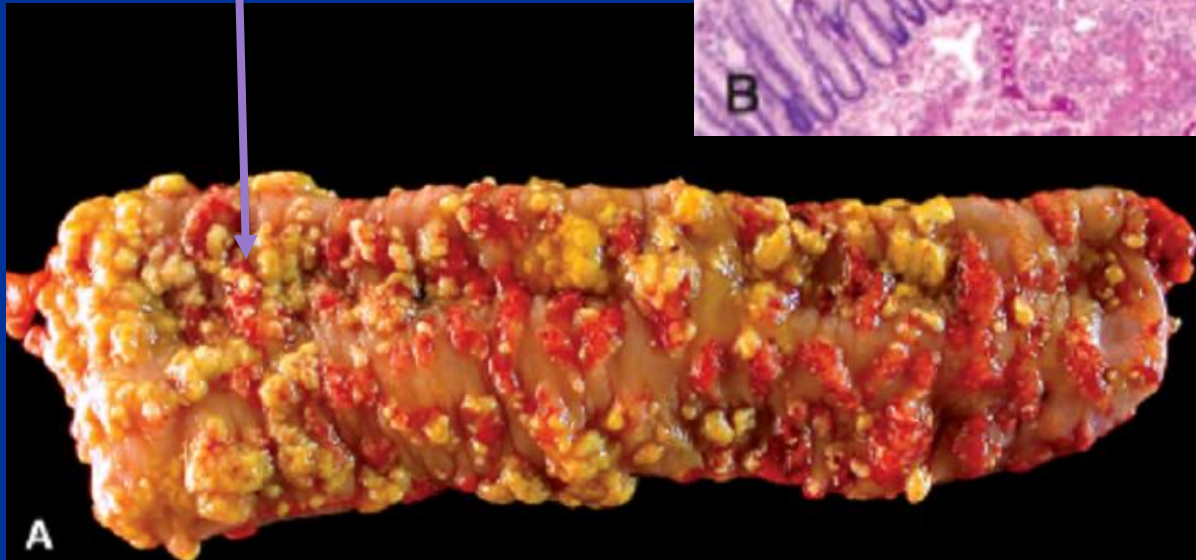
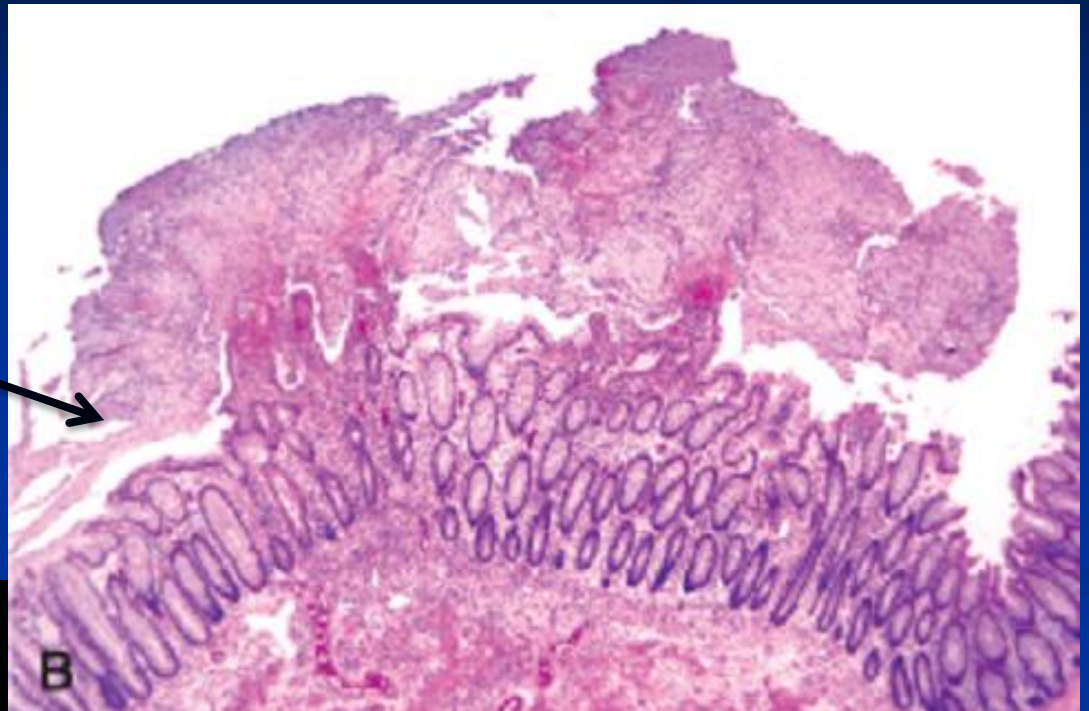


Infectious enterocolitis

- Pseudomembranous colitis
 - Exudative, fibrin-rich plaques (pseudomembrane) overlying sites of mucosal injury
 - Most associated antibiotic therapy
 - *Clostridium difficile*
 - Enterotoxin
 - Cytotoxin
 - Other - ischemia, anti-neoplastic drugs
- Parasitic
 - Amebiasis - *Entamoeba histolytic*
 - Giardiasis - *Giardia lamblia*
 - Cryptosporidiosis - *Cryptosporidium*
- Fungal
 - Candida

Pseudomembranous Colitis

Pseudomembrane



Non-infectious Colitis

- Drugs
- Radiation enterocolitis
- Ischemic Bowel Disease
 - Occlusive etiology
 - Non-Occlusive
- Collagenous colitis
- Lymphocytic colitis

Idiopathic Inflammatory Bowel Disease (IBD)

- *Chronic, relapsing inflammatory disorders of unknown origin*
- Crohn's Disease
- Ulcerative colitis

Crohn's vs UC

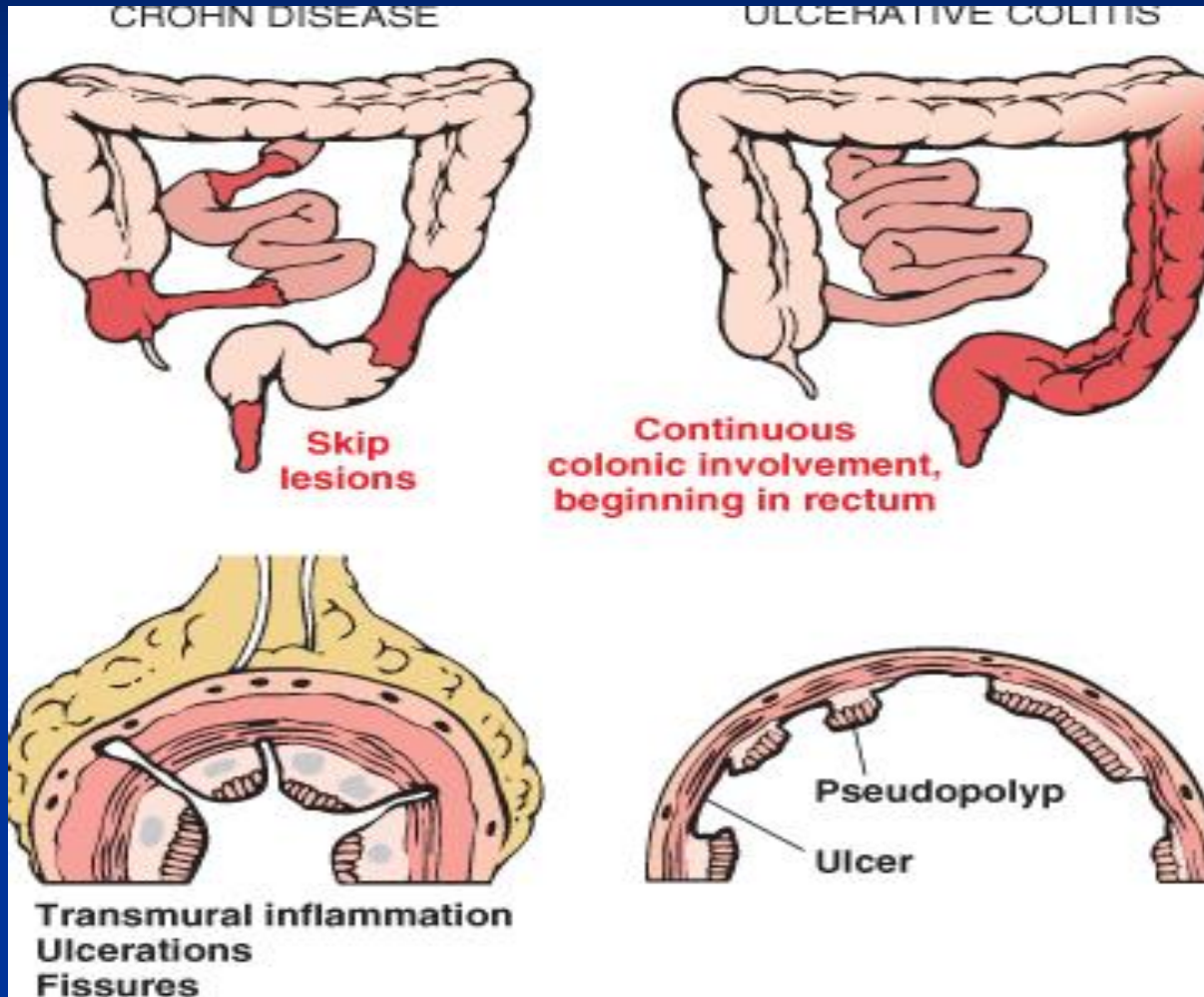
- Crohn's Disease

- Any part of GI tract
- Skip lesions
- Rectum spared
- Transmural inflammation
 - Fissures
 - Fistulas
- Strictures
- Granulomas
- Small increased risk CA
- Crypt abscess

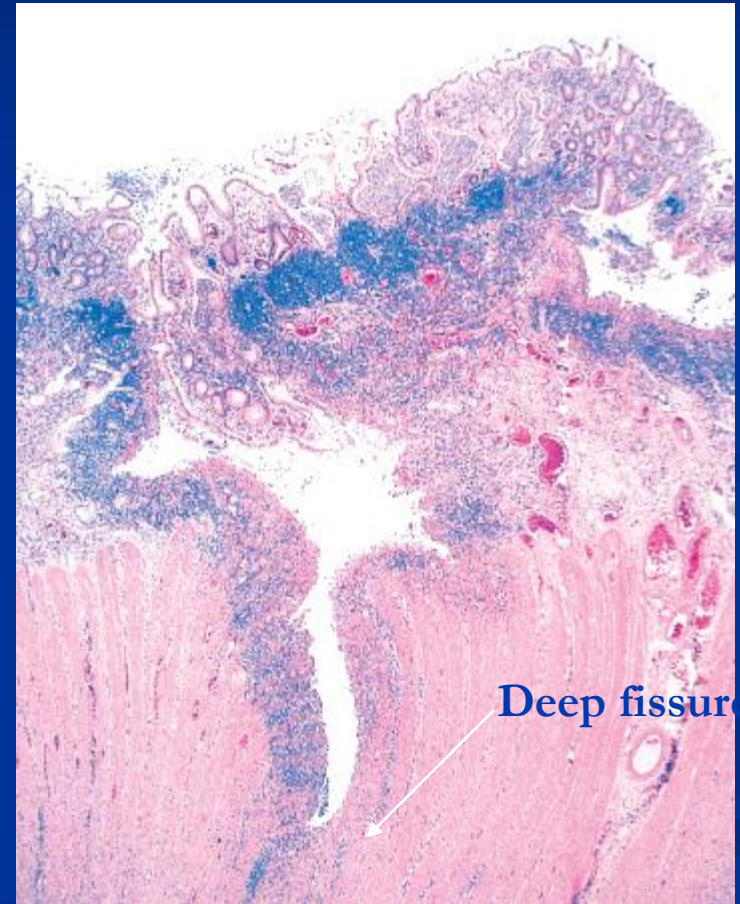
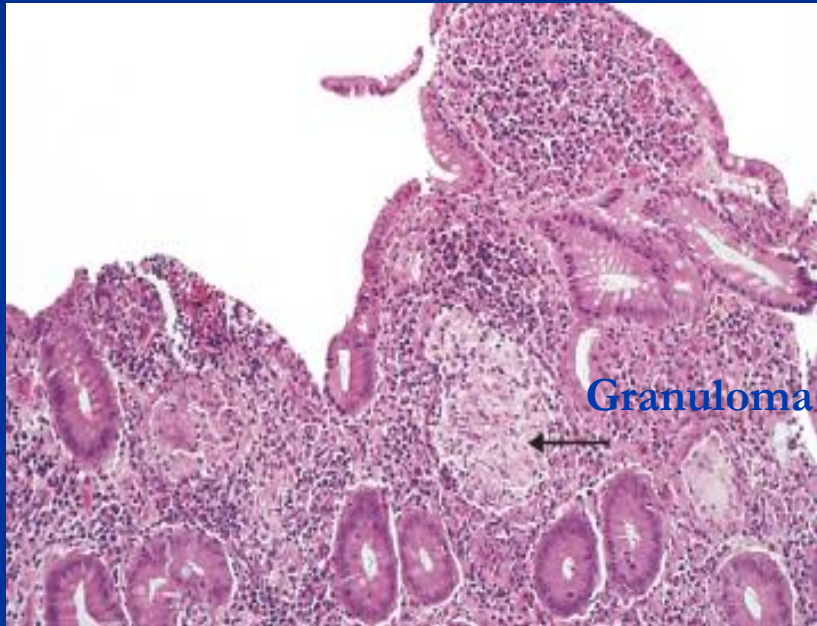
- Ulcerative Colitis

- Colon only
- Continuous
- Rectum always involved
- Mucosal inflammation
 - No fissures
 - No fistulas
- Strictures rare
- No granulomas
- > 10 % for 25 yr hx
- Crypt abscess

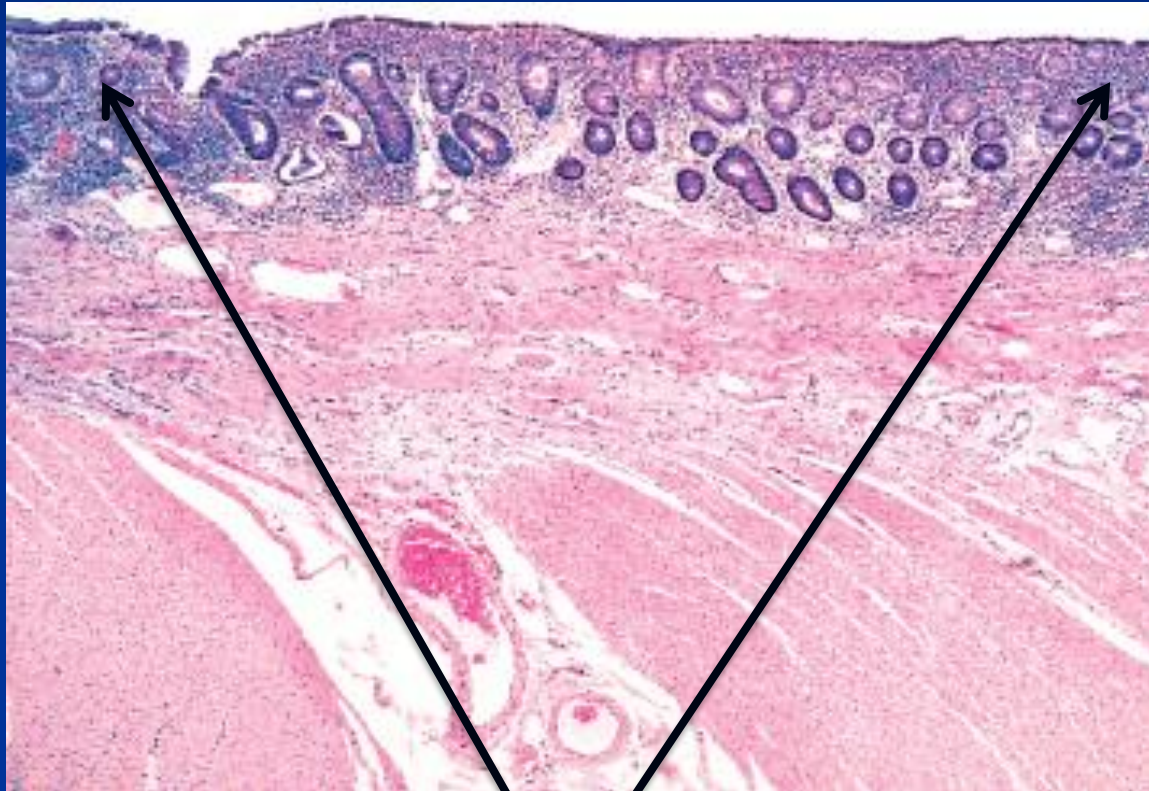
Crohn's vs UC



Crohn's Disease

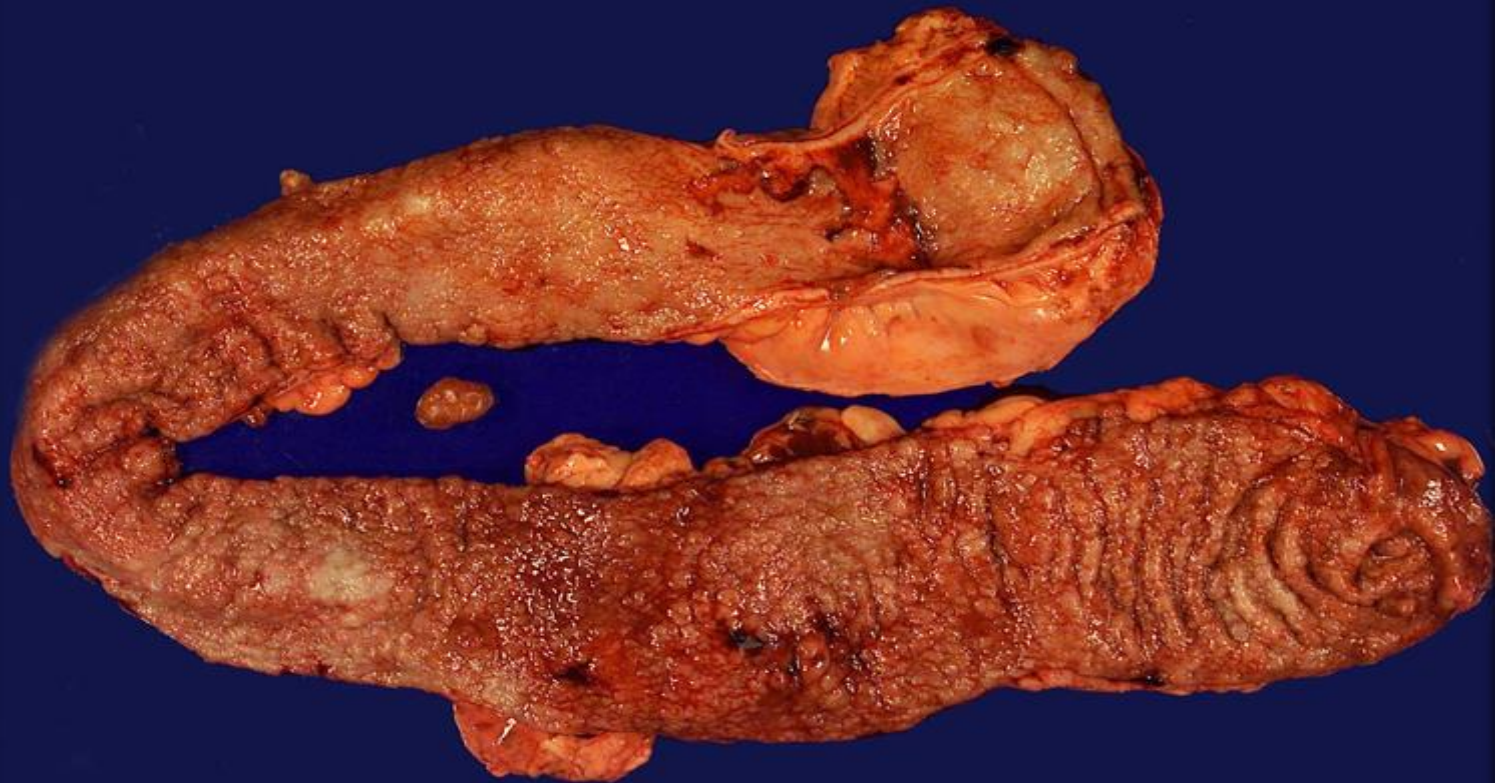

Ulcerative Colitis

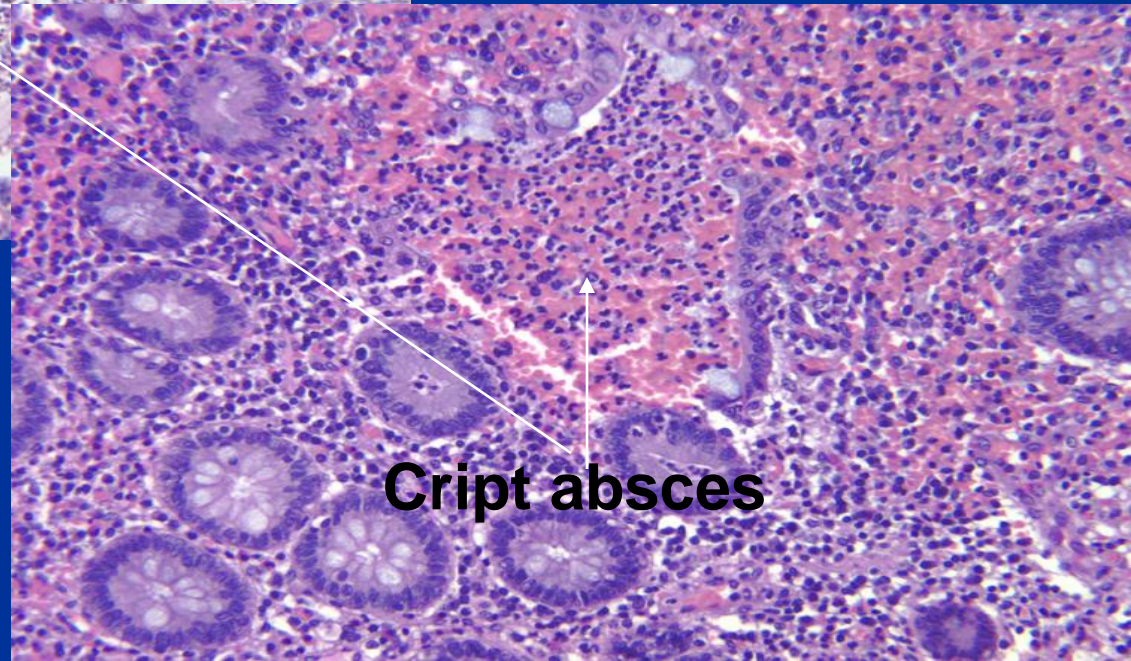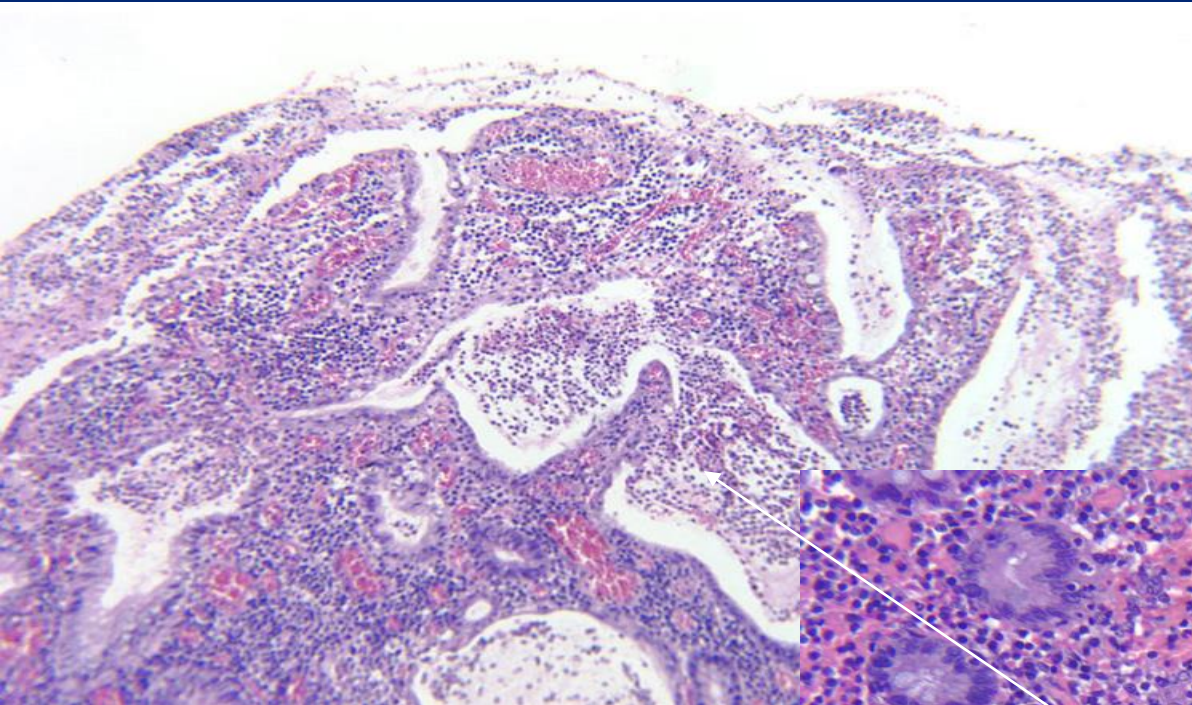


Isolated mucosal inflammation.

Ulcerative colitis. Continuous involvement starting at rectum and extending proximal.

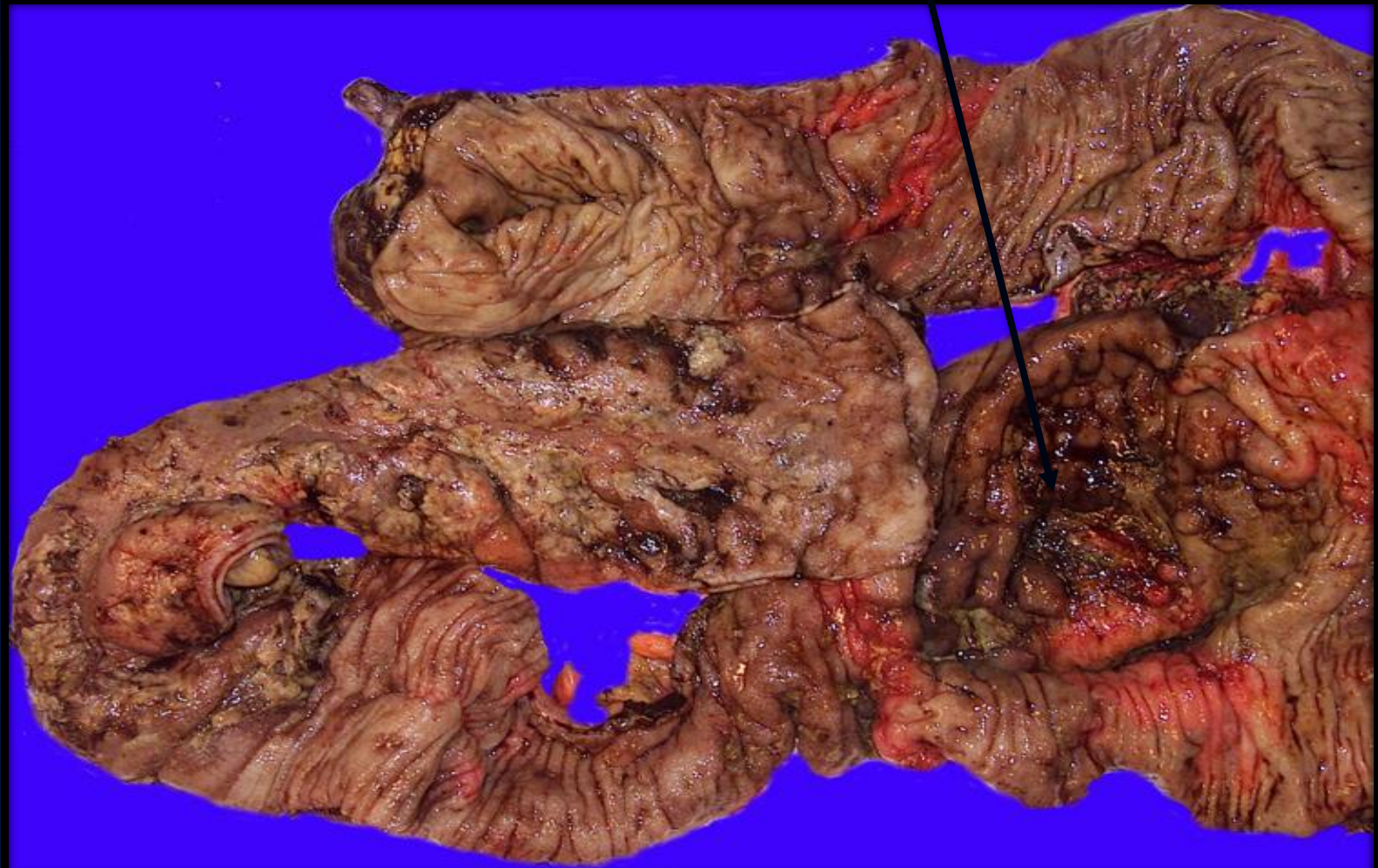


Crypt abscess

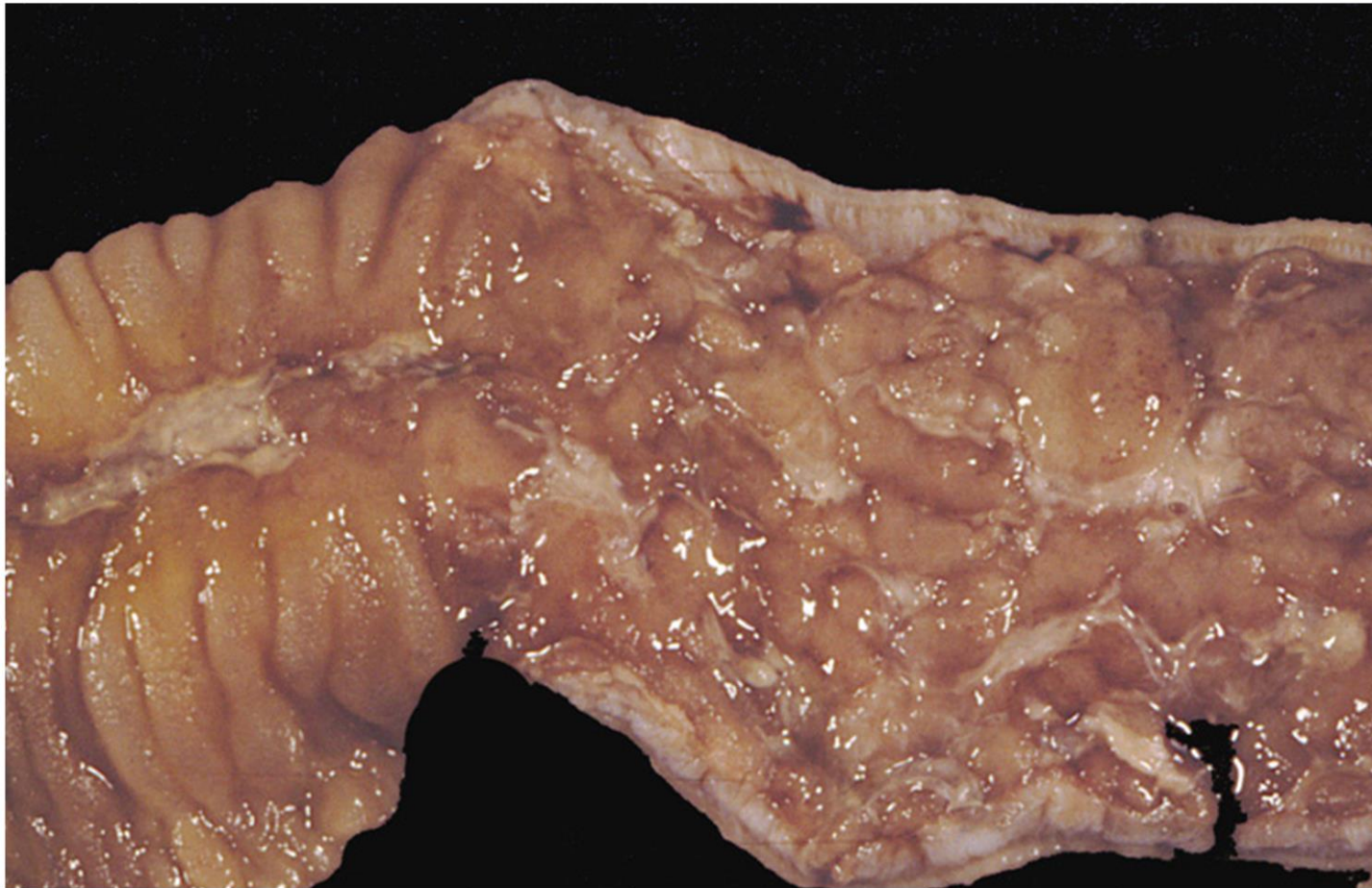

Cript absces

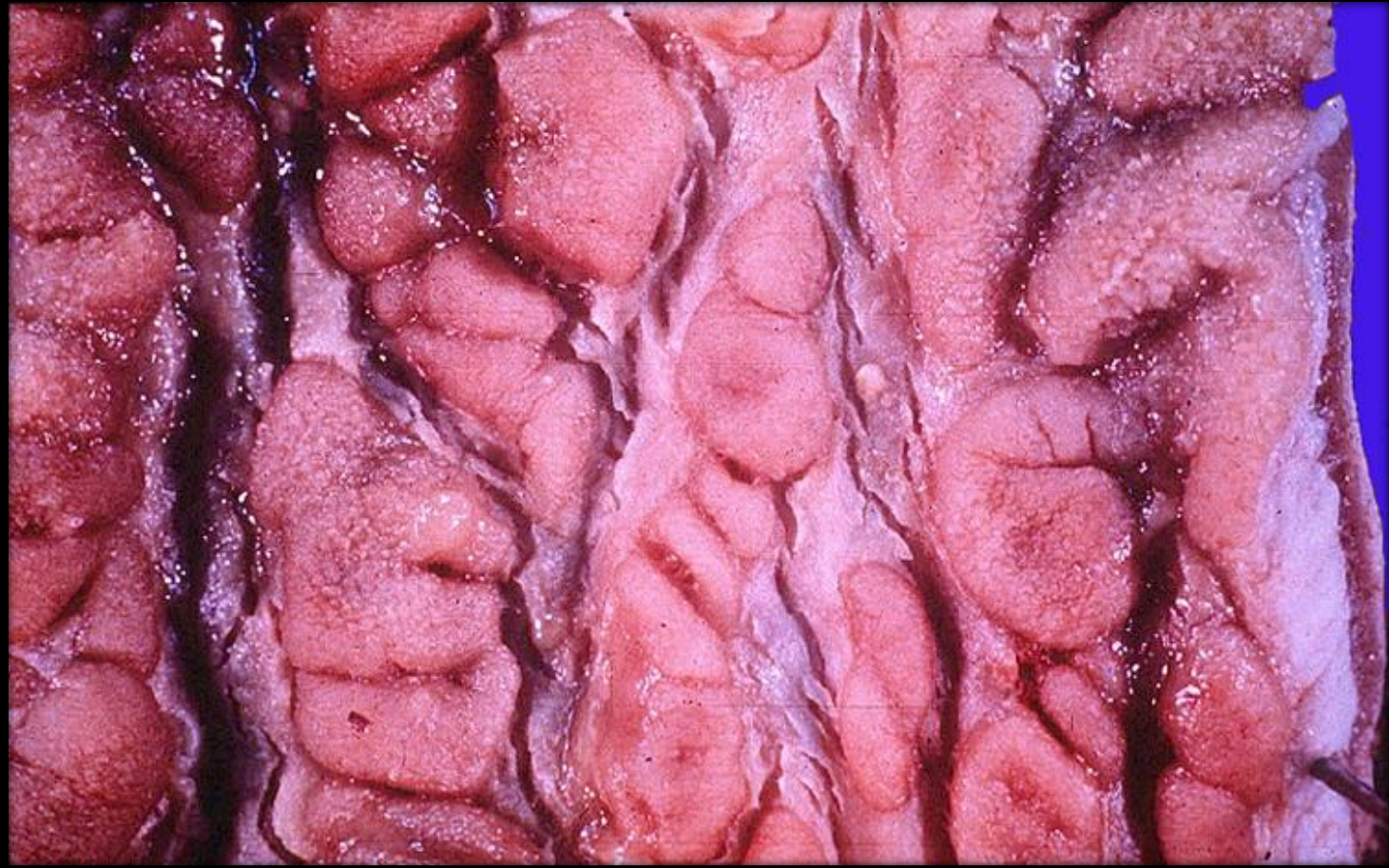
Toxic Megacolon



**“Cobblestone”. Serpiginous linear ulcers
surrounding normal mucosa**

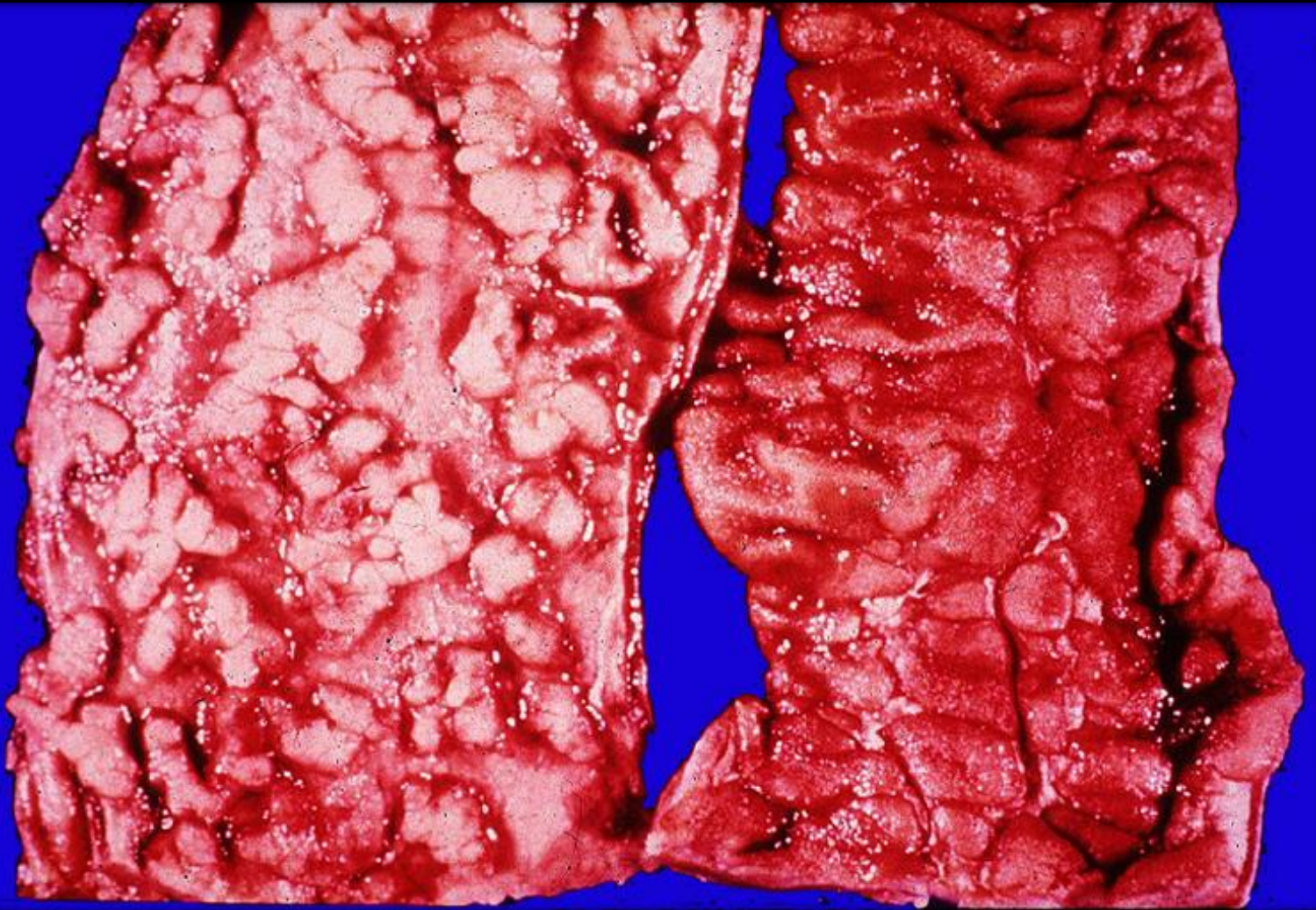


**Serpiginous linear ulcers
surrounding normal mucosa**

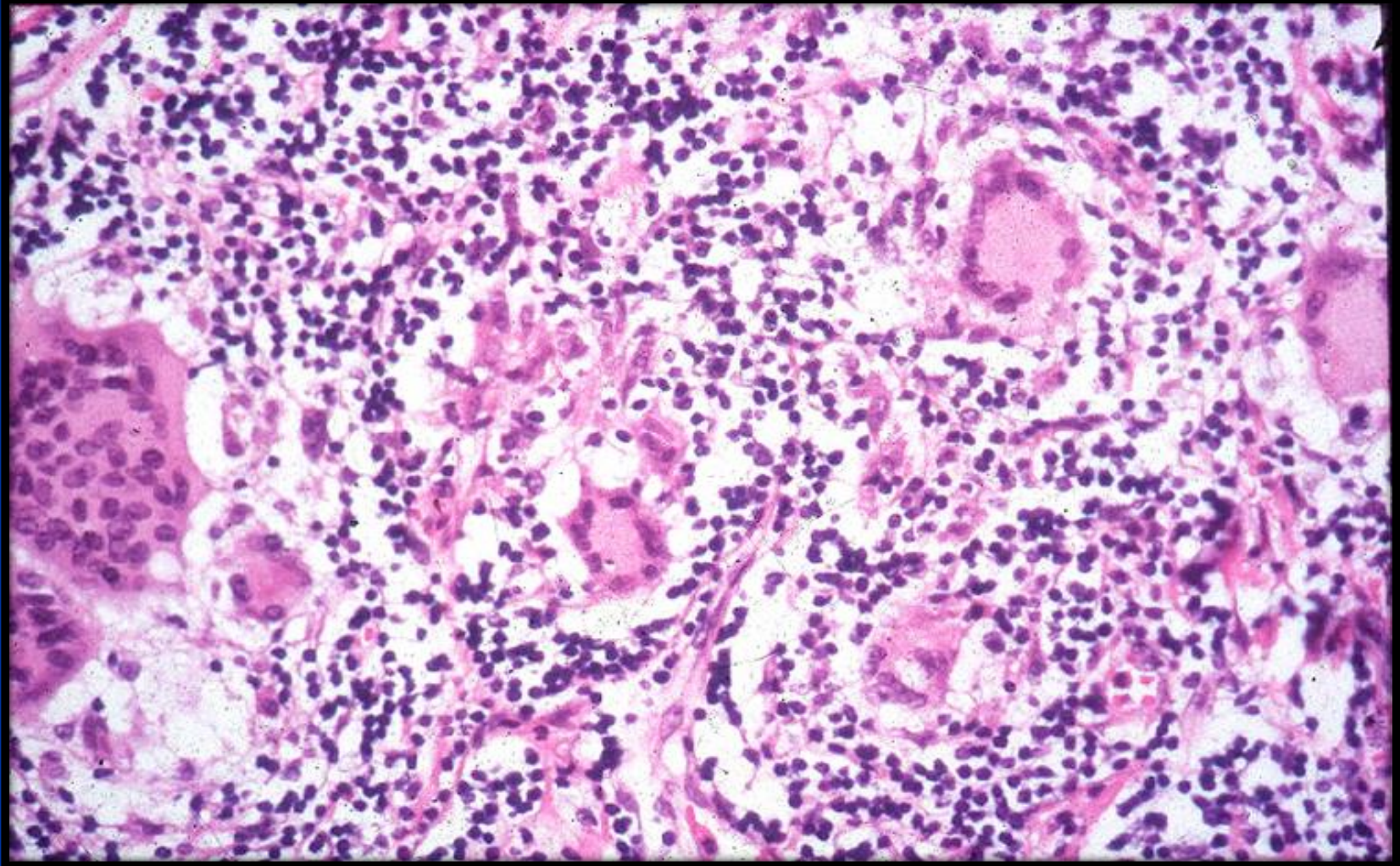


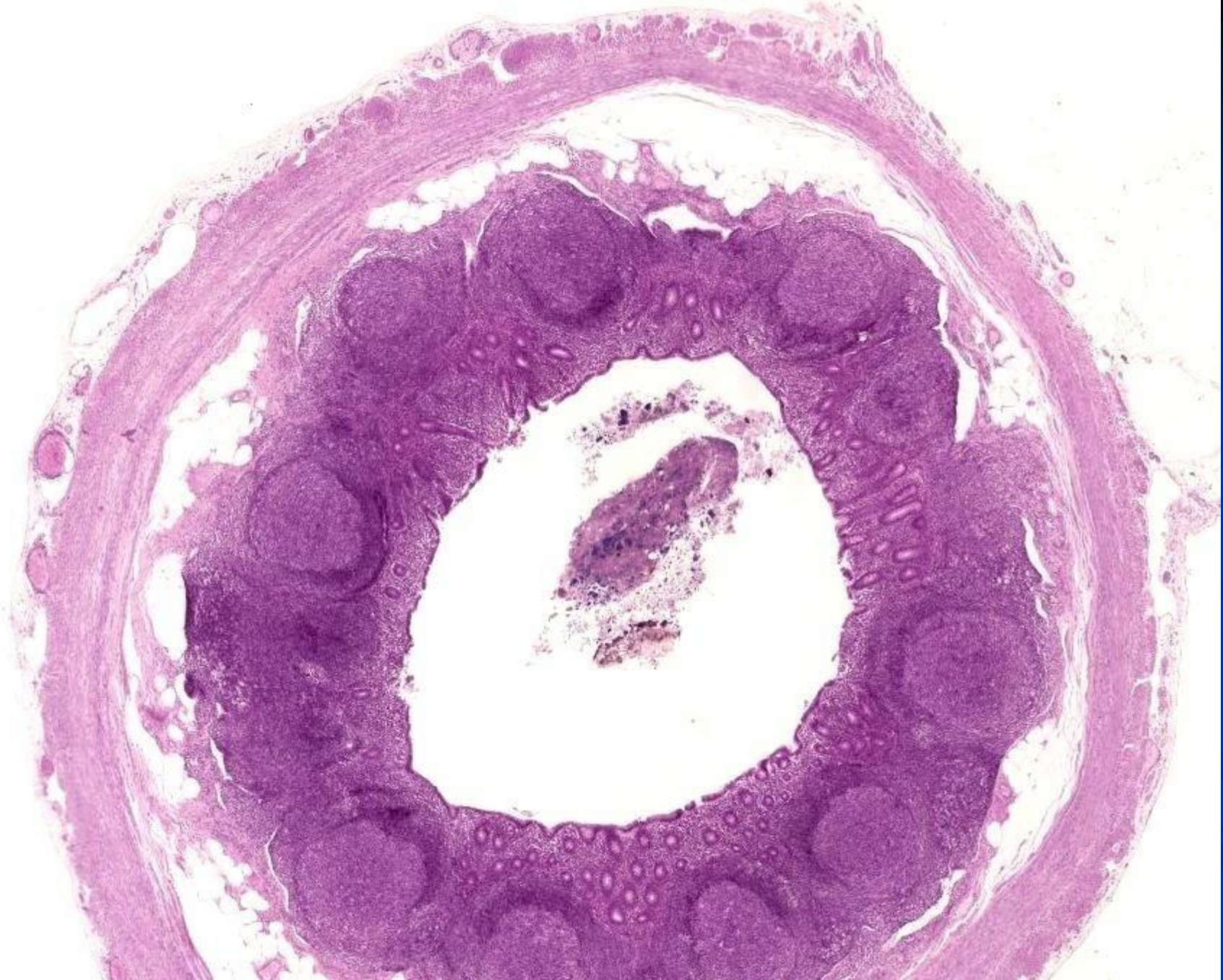Ulcerative Colitis

Crohn's Disease



Granulomas = Crohn's Disease



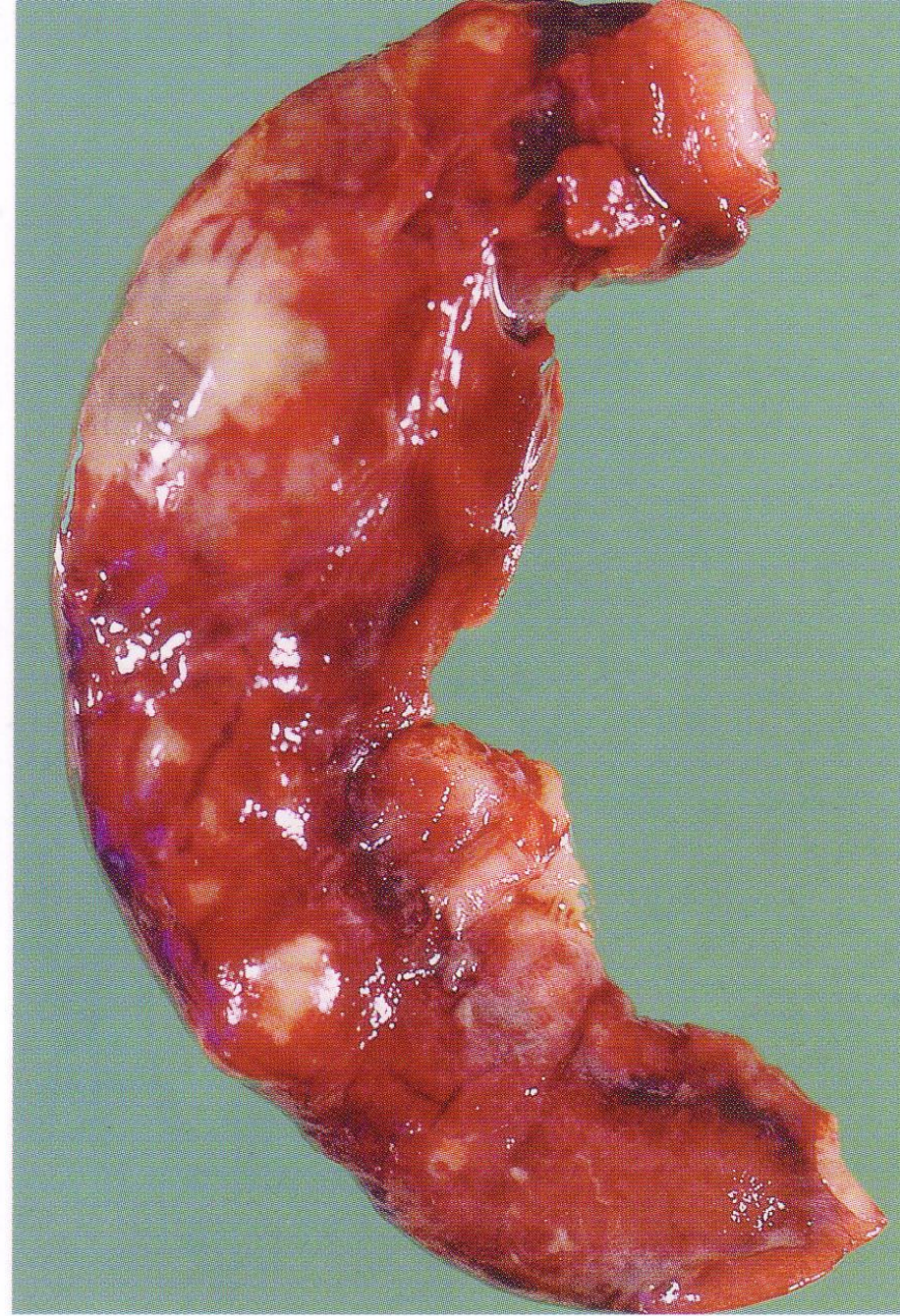


A
P
P
E
N
D
I
X

ANATOMY

- Junction of 3 tenia coli, variable in location
- All 4 layers, true serosa
- Thickest layer is submucosal lymphoid tissue

- APPENDICITIS (ACUTE)
- MUCOCELE
- MUCUS CYSTADENOMA
- MUCUS CYSTADENOCARCINOMA



Аппендицит.

ACUTE APPENDICITIS

- **GENERALLY**, a disease of **YOUNGER** people
- **OBSTRUCTION** by **FECALITH** the classic cause but fecaliths present only about half the time
- **EARLY APPENDICITIS:**
NEUTROPHILS → Mucosa, submucosa
- **NEED NEUTROPHILS** in the **MUSCULARIS** to confirm the **DIAGNOSIS**
- 25% normal rate, usually

Acute Appendicitis

Is the most common acute abdominal condition the surgeon is called on to treat.

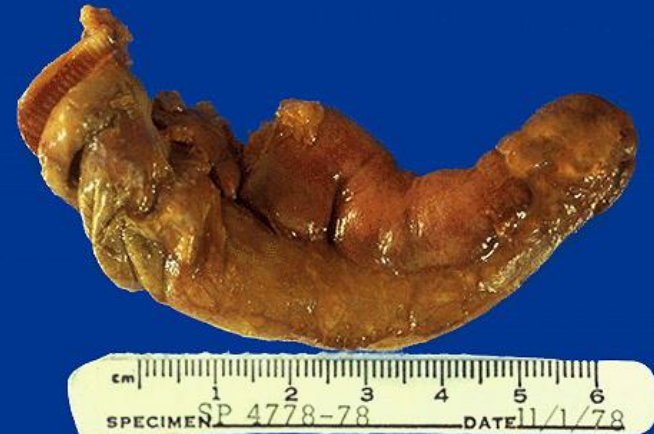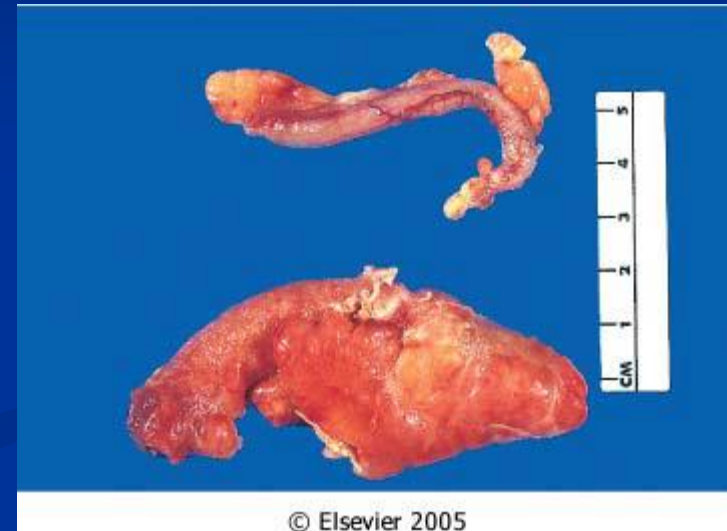
- Inflammation in the right lower quadrant
 - Adolescents and young adults

- Acute Simple Appendicitis
- Acute Suppurative Appendicitis
- Acute Gangrenous Appendicitis

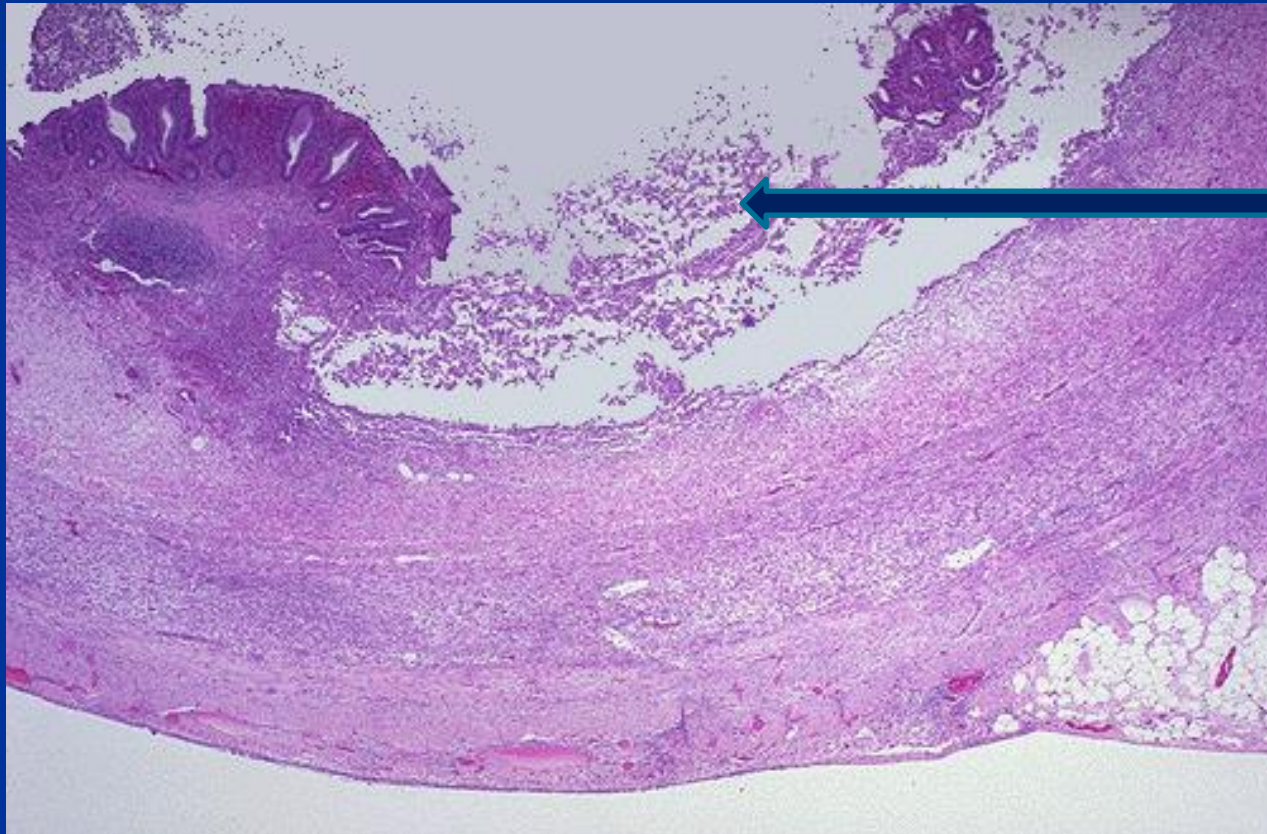
Morphology

Scant neutrophilic exudate throughout the mucosa, submucosa, and muscularis propria

- Subserosal vessels are congested
- Fibrinopurulent reaction over the serosa
- Abscess formation within the wall, along with ulcerations and foci of suppurative necrosis in the mucosa
- Green-black gangrenous necrosis through the wall, extending to the serosa



Microscopically, acute appendicitis is marked by mucosal inflammation and necrosis.



Purulent debris

Complications

- ❖ Rupture
- ❖ Suppurative peritonitis
- ❖ Pyelophlebitis with thrombosis of the portal venous drainage
- ❖ Chronic inflammation of the appendix
- ❖ Cystic fibrosis


Mucus “TUMORS”

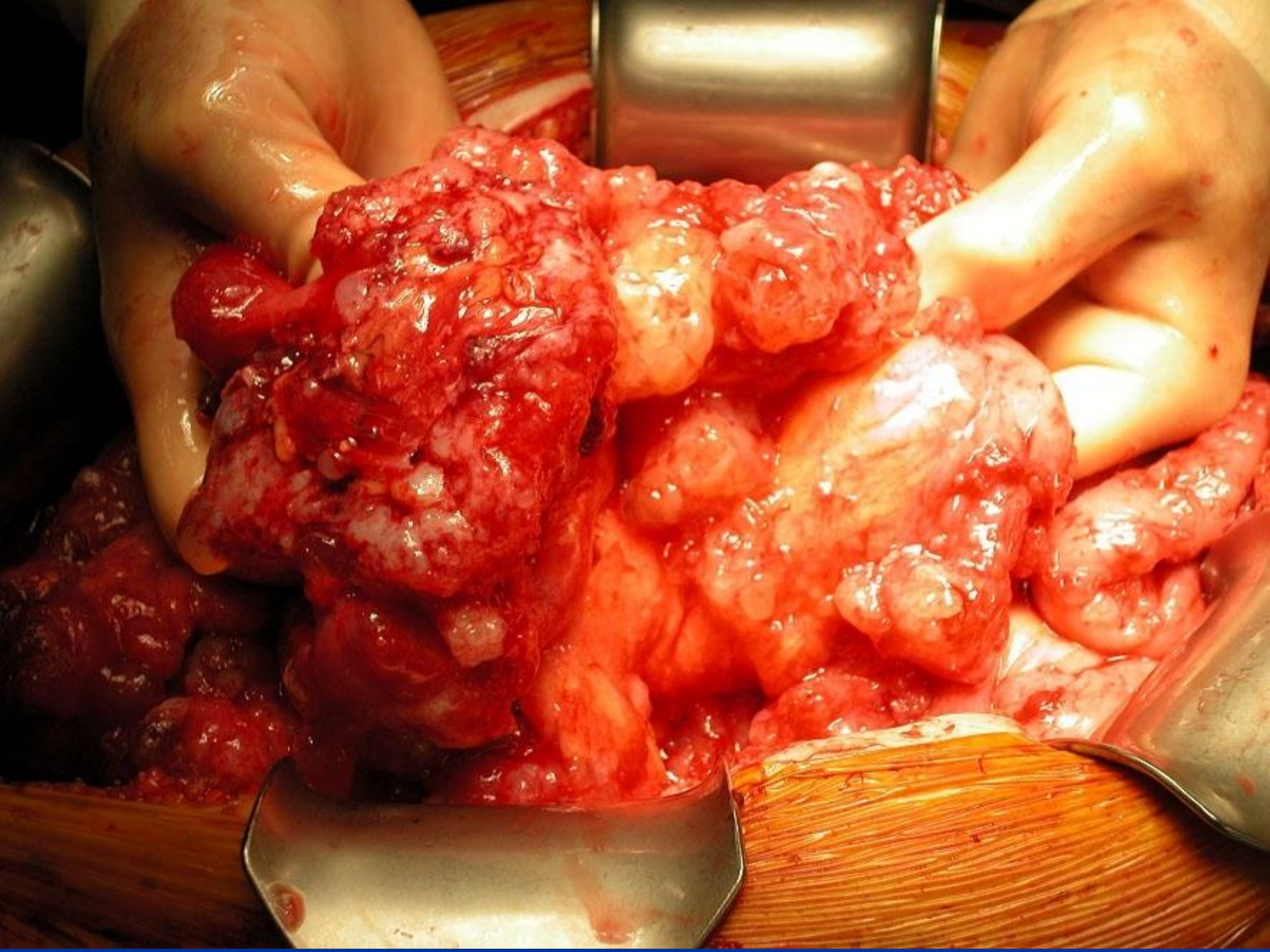
- Mucocele (common)
- Mucinous Cystadenoma (rather rare)
- Mucinous Cystadenocarcinoma (rare)

MUCOCELE

- COMMON CYST on APPENDIX filled with MUCIN
- Can RUPTURE to become:

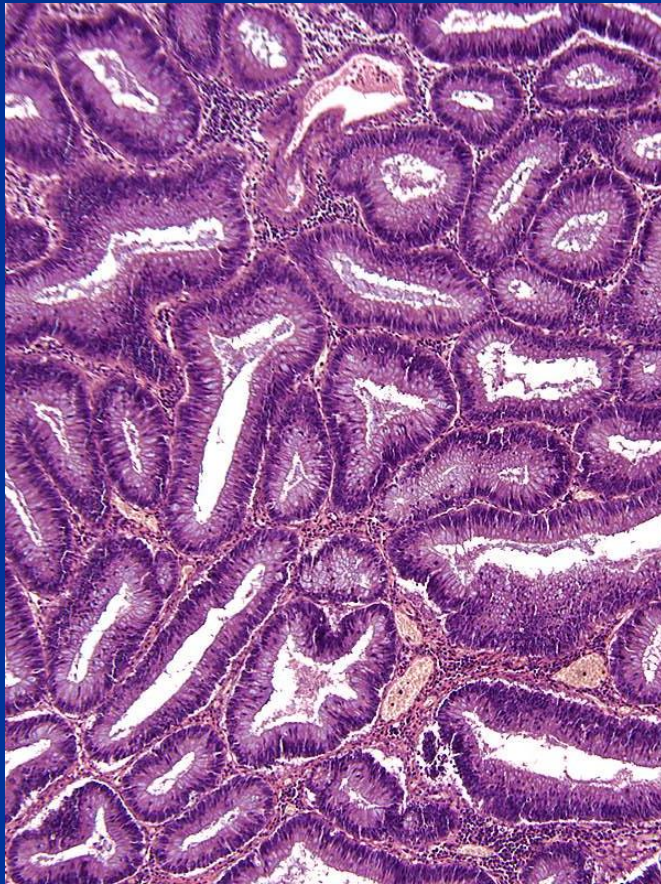
**PSEUDOMYXOMA
PERITONEII**



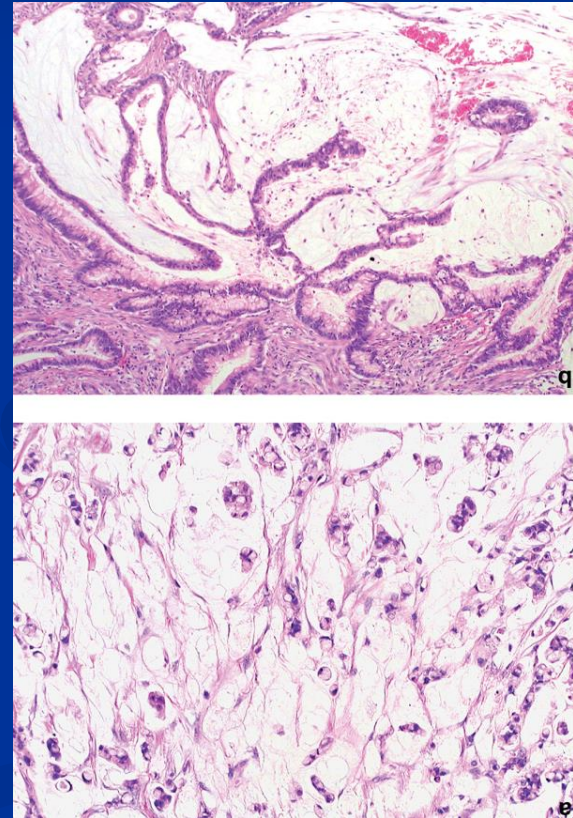


MUCINOUS CYSTADENO(CARCINO)MA

ADENOMA

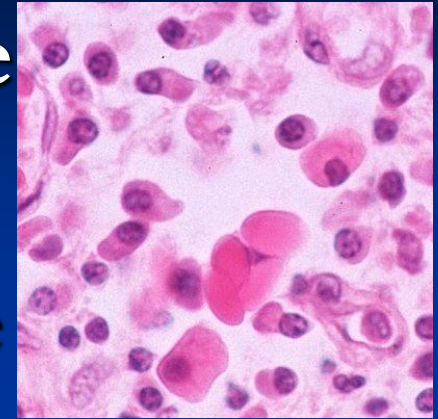

CARCINOMA



PERITONEUM

- Visceral, Parietal: all lined by me
- Peritonitis, acute:
 - Appendicitis, local or with rupture
 - Peptic ulcer, local or ruptured
 - Cholecystitis, local or ruptured
 - Diverticulitis, local or with rupture
 - Salpingitis → gonococcal or chlamydial, retrograde or perforated
 - Ruptured bowel due to any reason
 - Perforating abdominal wall injuries



PERITONITIS

- E. coli
- STREP
- S. aureus
- ENTEROCOCCUS

PERITONITIS, outcomes:

- Complete RESOLUTION
- Walled off ABSCESS
- ADHESIONS

Tumors of Small and Large Intestine



- Non-neoplastic polyps
- Hyperplastic
 - Hamartomatous polyps
 - Juvenile polyps
 - Peutz-Jeghers polyps
 - Inflammatory polyps
 - Lymphoid polyps
- Lymphoma
- Neoplastic epithelial tumors
 - Benign (Adenoma)
 - Malignant
 - Adenocarcinoma
 - Carcinoid
 - Squamous cell carcinoma (rectum)
- Mesenchymal lesions
 - GIST, lipoma

POLYPS

- ANY mucosal bulging, blebbing, or bump

- **HYPERPLASTIC** (NON-NEOPLASTIC)

- HAMARTOMATOUS (NON-NEOPLASTIC)

- **ADENOMATOUS** (TRUE

NEOPLASM, and regarded by many as “potentially” PRE-MALIGNANT as well)

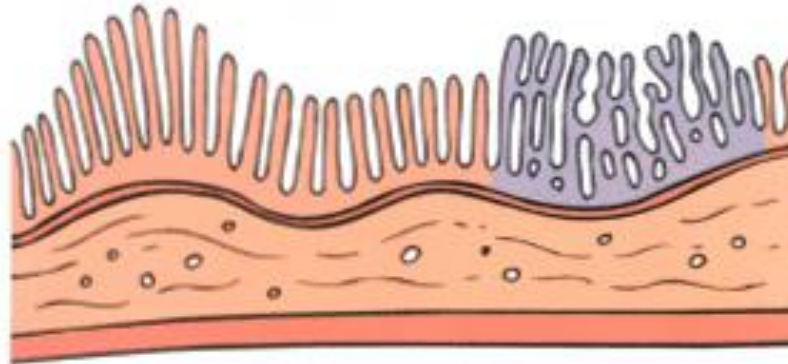
- SESSILE vs. PEDUNCULATED
- TUBULAR vs. VILLOUS

POLYPS

SESSILE POLYPS

Hyperplastic polyp

Adenoma



Mucosa

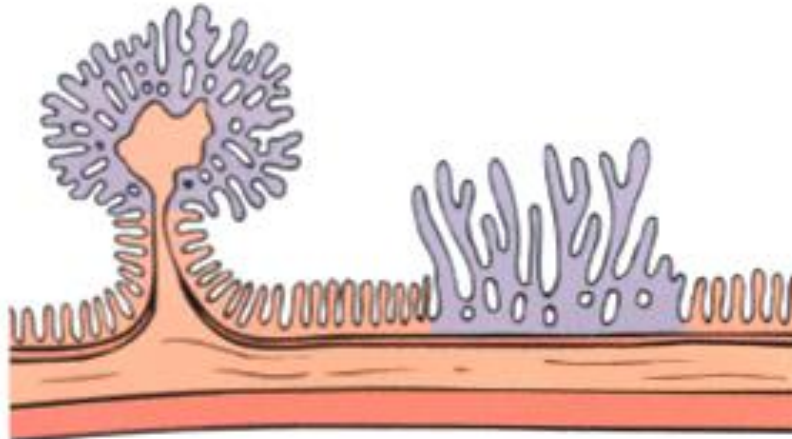
Submucosa

Muscularis propria

ADENOMAS

**Pedunculated
Tubular**

**Sessile
Villous**

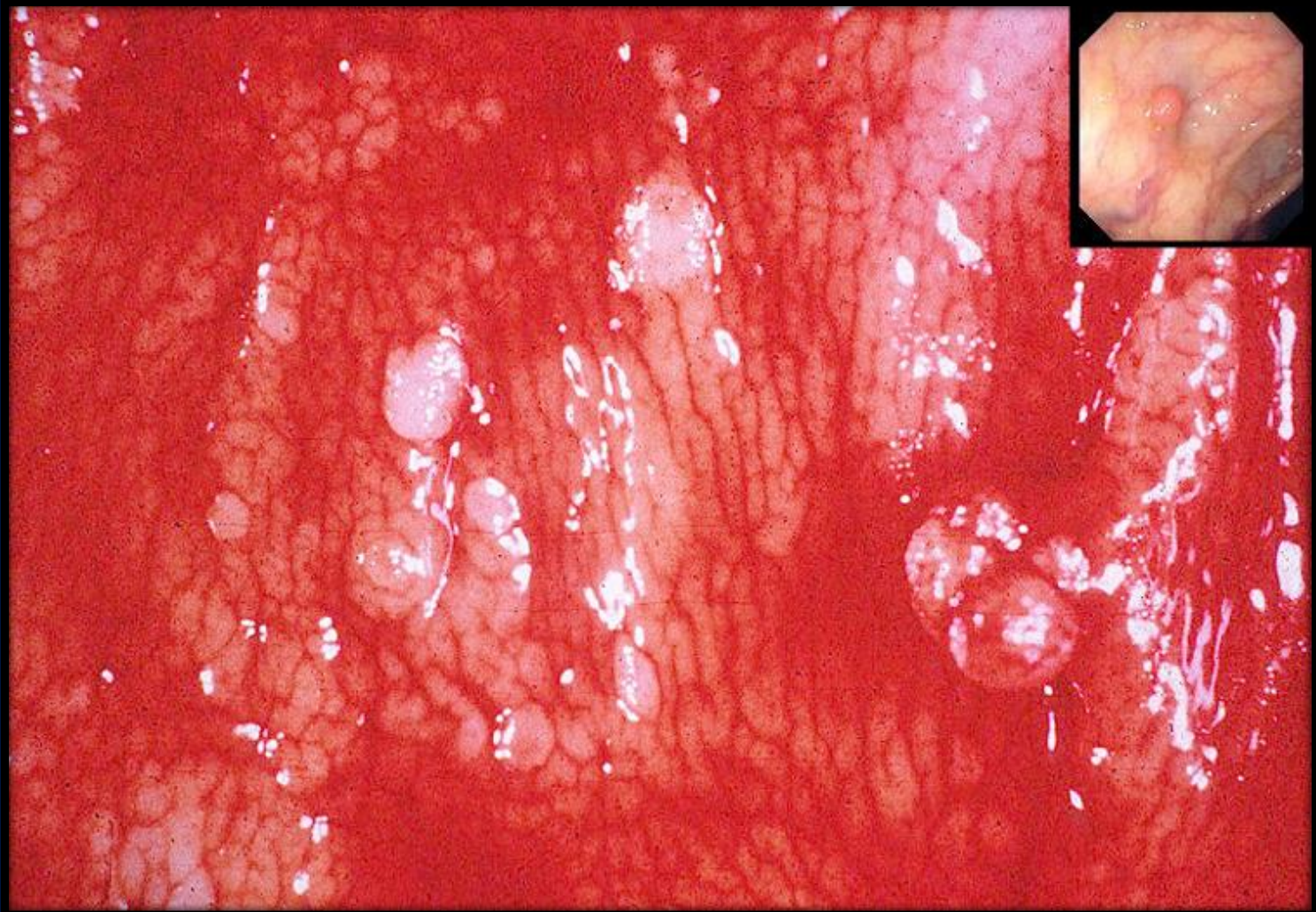


Mucosa

Submucosa

Muscularis propria

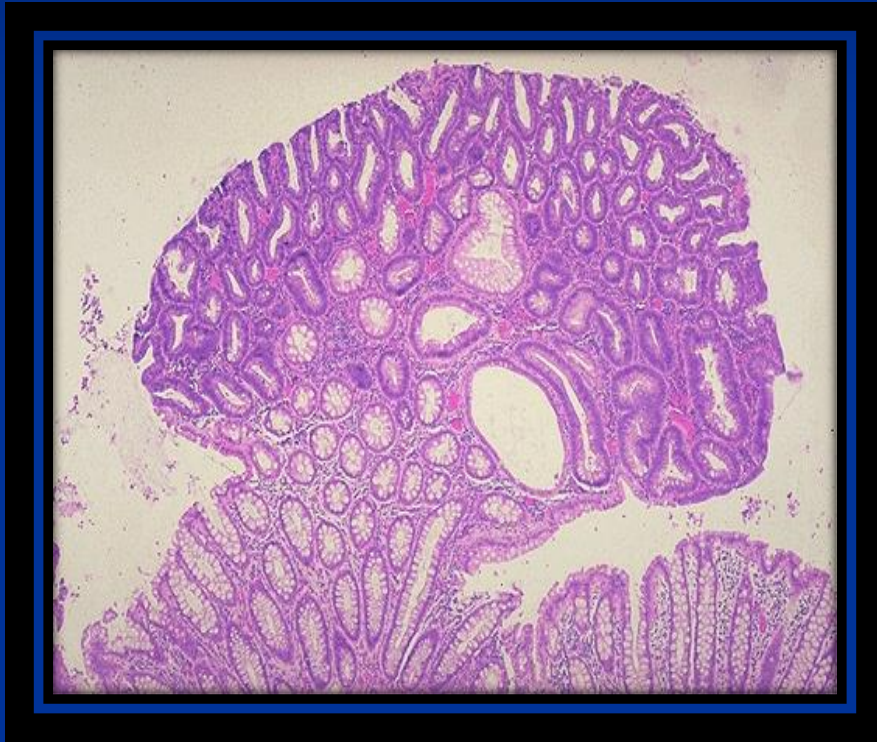
Hyperplastic Polyp



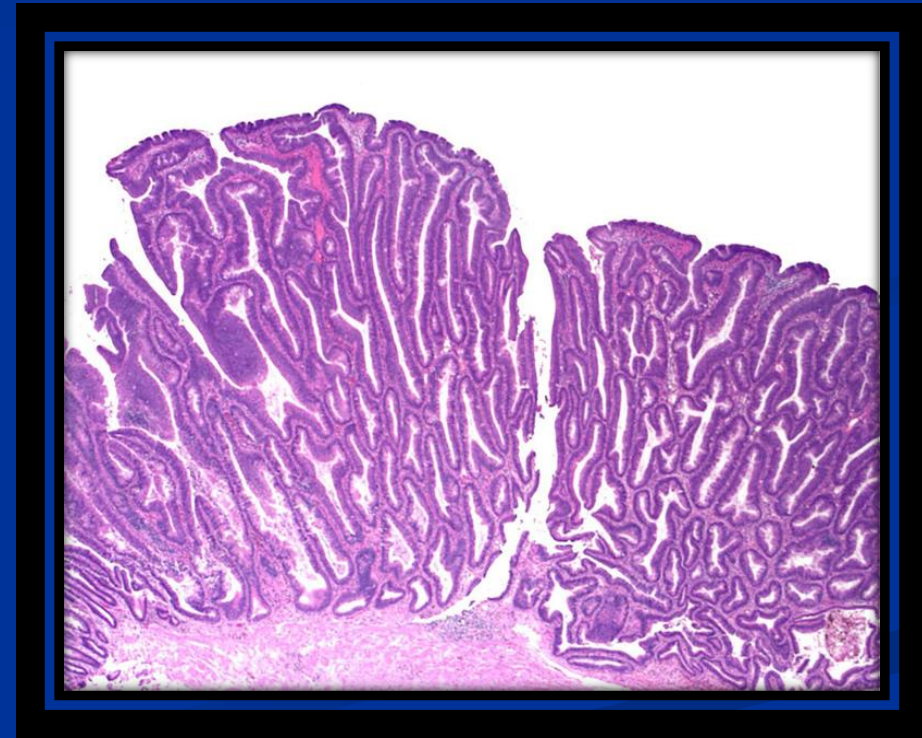
Pre-malignant Polyps

Adenomatous polyps

Tubular Adenoma



Villous Adenoma



Tubulovillous Adenoma

“FAMILIAL” NEOPLASMS

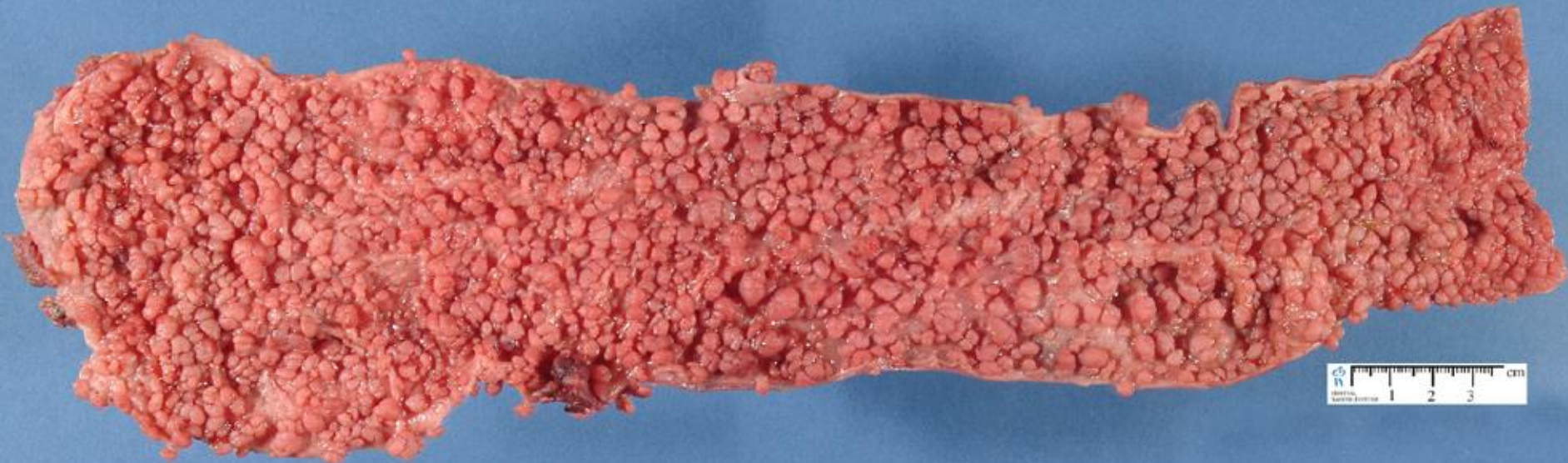- 1) POLYPOSIS (NON-NEOPLASTIC, hamartomatous)
- 2) POLYPOSIS (NEOPLASTIC, i.e., cancer risk). FAP.
- 3) HNPCC: (Hereditary Non Polyposis Colorectal Cancer)

Hereditary Syndromes.

Some syndromes are known, characterized by the presence of colon polyps and an increased incidence of colon cancer. These syndromes are based on clearly defined genetic disorders.

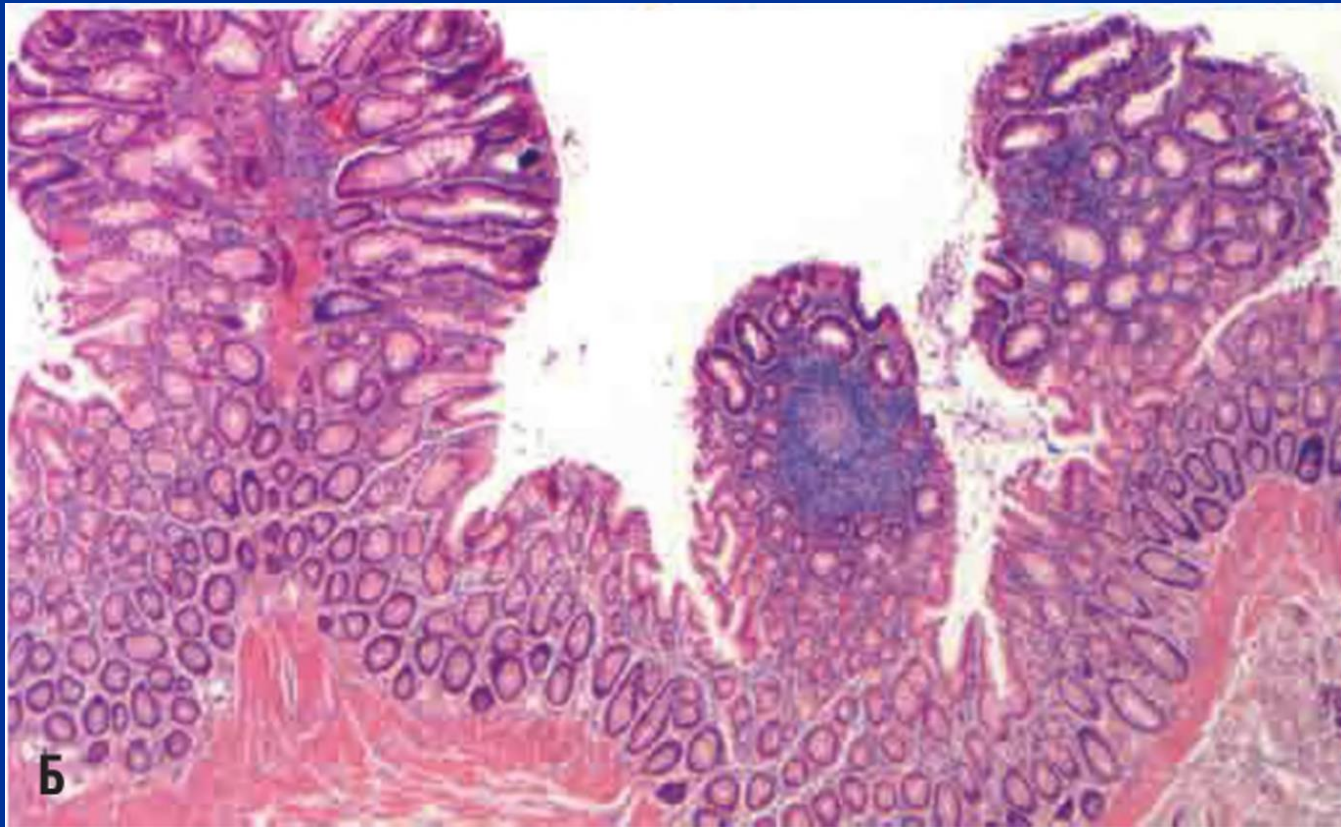
Familial adenomatous polyposis (FAP) is an autosomal dominant disease in which multiple colon adenomas develop in adolescents.

The diagnostic criterion for classic FAP is the presence in the colon of at least 100 polyps (their number can reach several thousand!)



Without treatment of FAP, colon adenocarcinomas develop in 100% of cases, often under the age of 30 years. That is why the standard treatment is prophylactic colon removal. This operation prevents the development of colon cancer, but the increased risk of developing neoplasms of other locations remains. For example, in areas adjacent to the ampulla of the Vater papilla, and adenomas may develop in the stomach.

It is important to note that in FAP flat adenomas predominate, and microadenomas consisting of only one or two dysplastic glands are often determined in areas of externally unchanged mucous membrane.



CANCER GENETICS

- Loss of APC gene
- Mutation of K-RAS
- Loss of SMADs (regulate transcription)
- Loss of p53
- Activation of TELOMERASE

CANCER RISK FACTORS

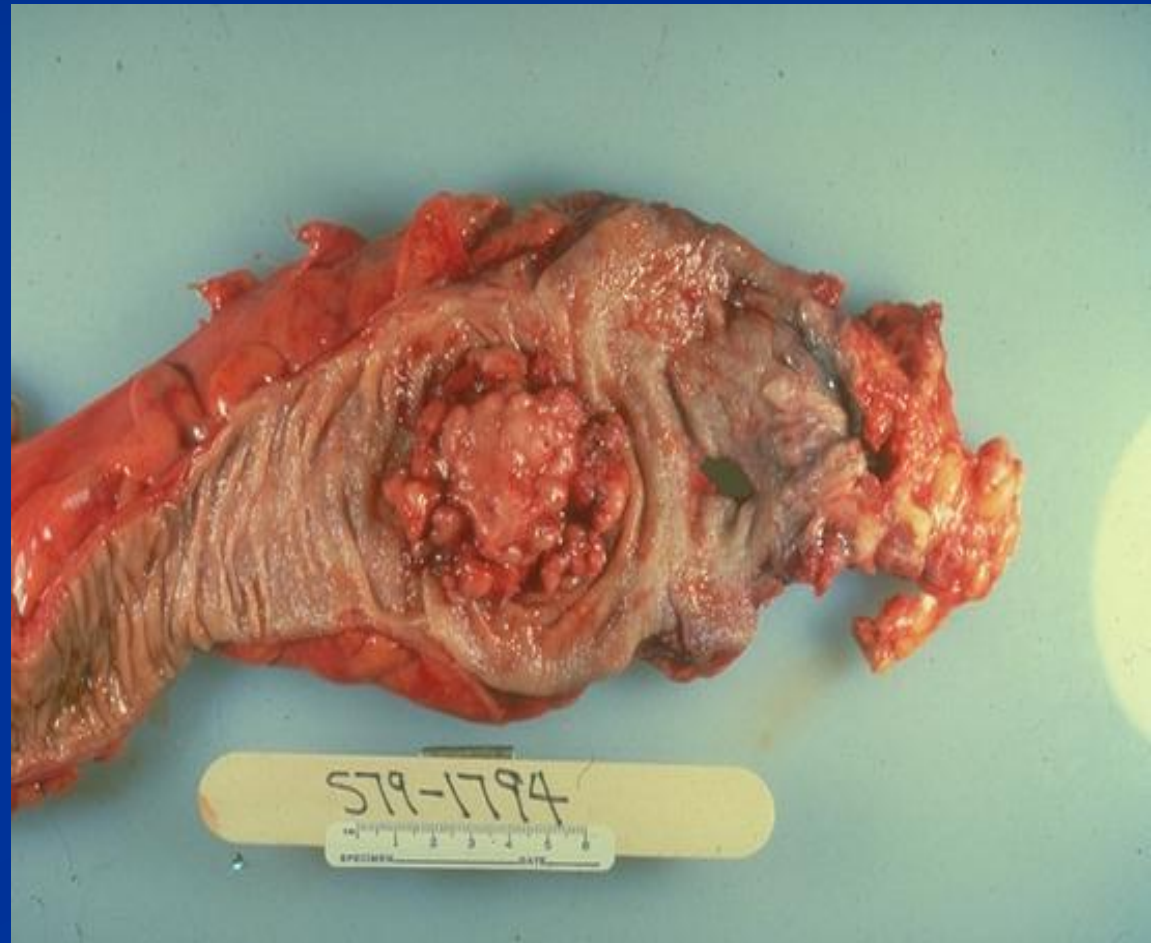
- Family history
- Age (rare <50)
- LOW fiber, HIGH meat, LONG transit time, refined carbs

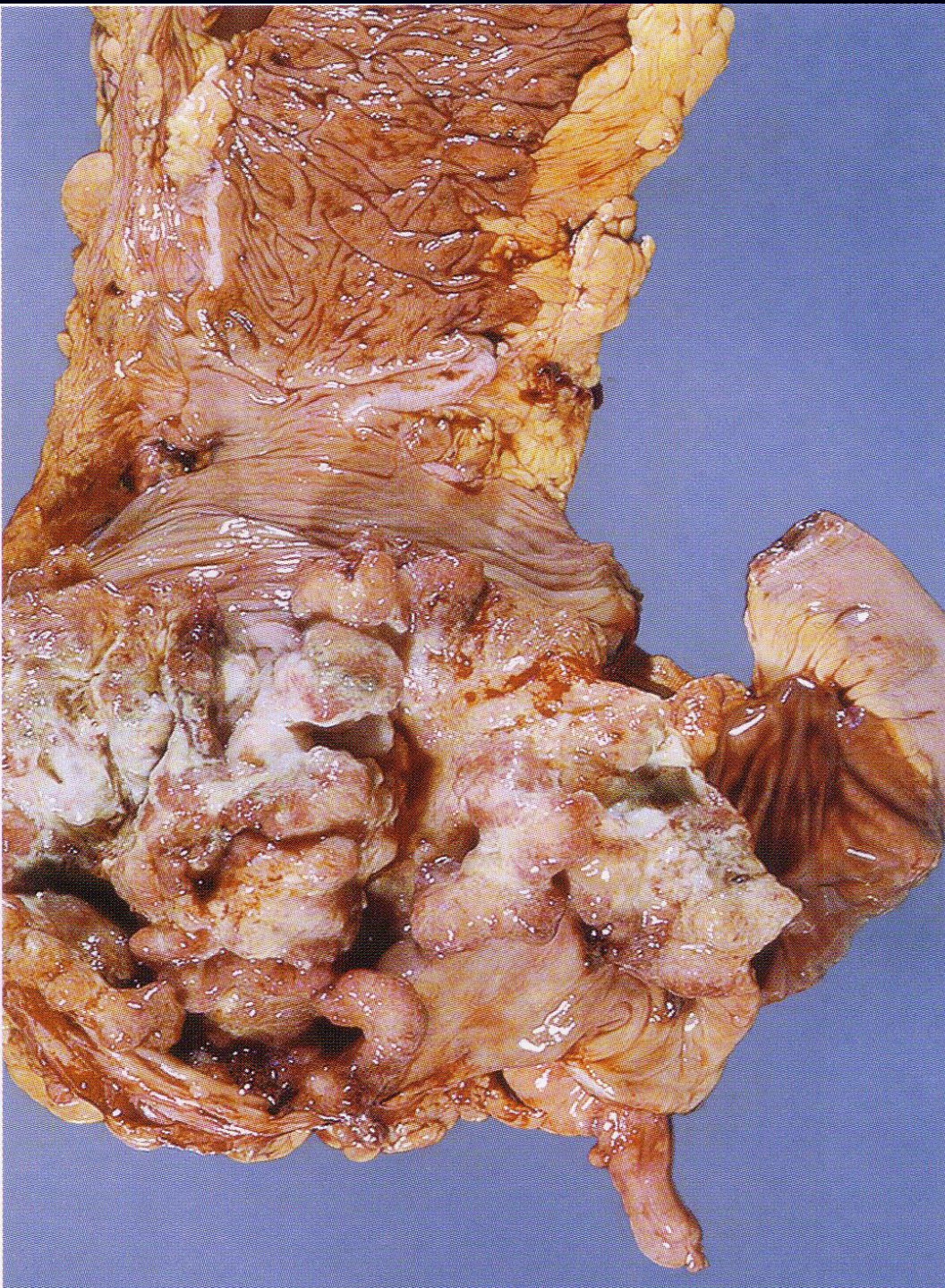
PATHOGENESIS

- From existing ADENOMATOUS POLYPS
- DE-NOVO

- DYSPLASIA → INFILTRATION → METASTASIS

Features of the diet that affect the incidence of colon cancer are low fiber intake and high intake of refined carbohydrates and fats. It is assumed that a decrease in fiber intake decreases the rate of movement of feces and disrupts the composition of the intestinal microflora. These changes can lead to the accumulation of potentially toxic products of bacterial metabolism, which for a long time come into contact with the mucous membrane of the colon.



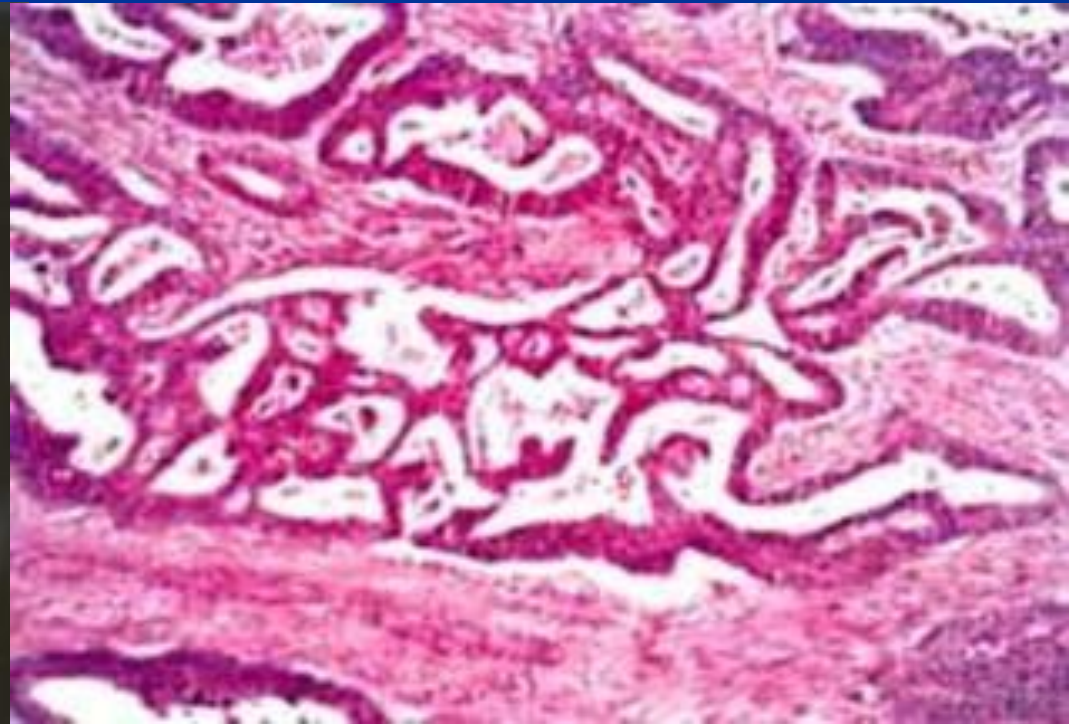
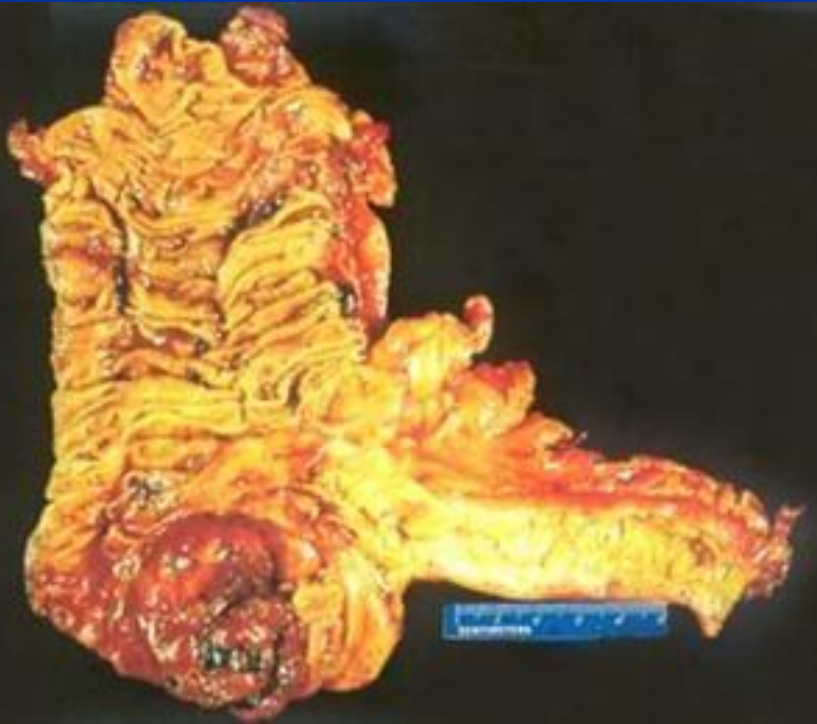

Adenocarcinoma

Colon adenocarcinoma is the most common malignant tumor of the gastrointestinal tract. In contrast, in the small intestine, which accounts for 75% of the entire gastrointestinal tract, benign and malignant tumors are extremely rare.

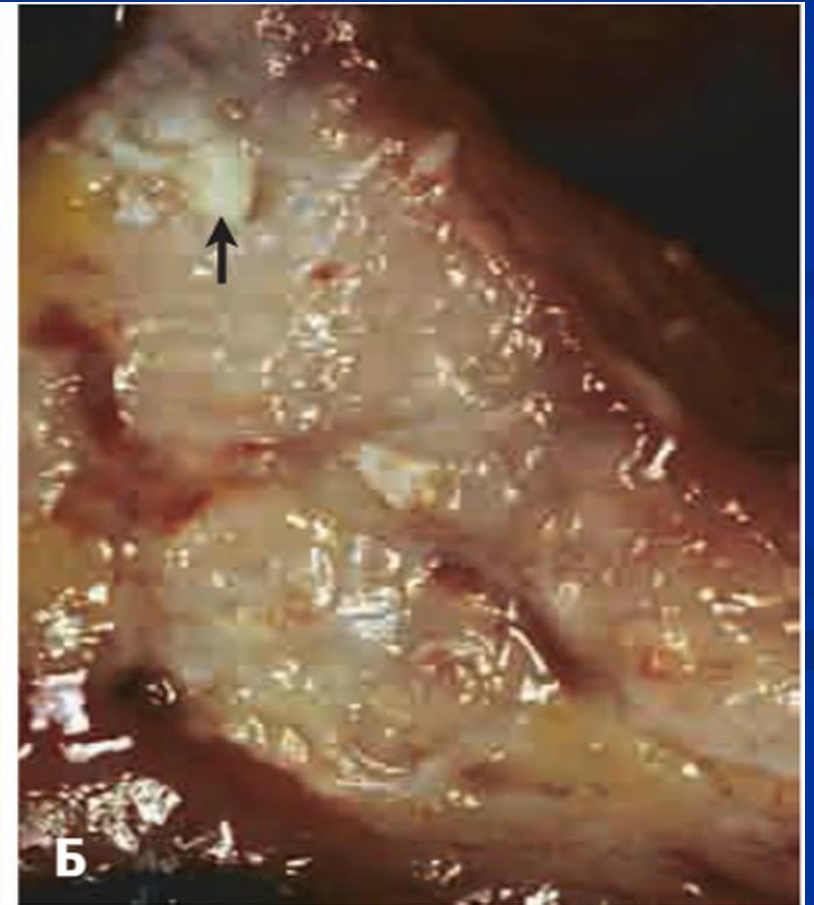
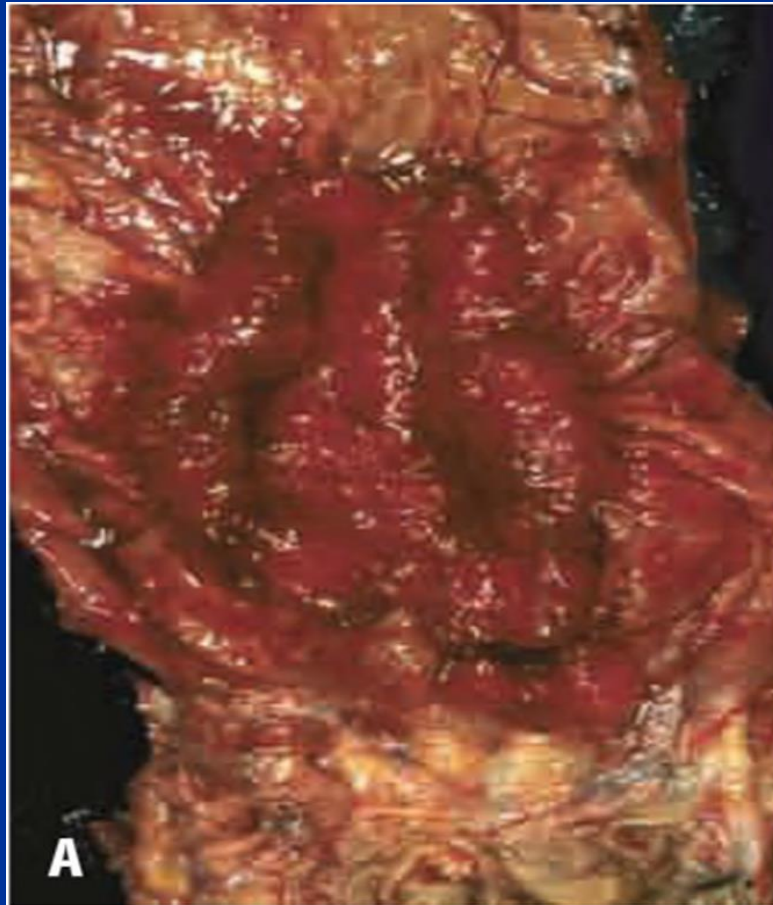
GROWTH PATTERNS

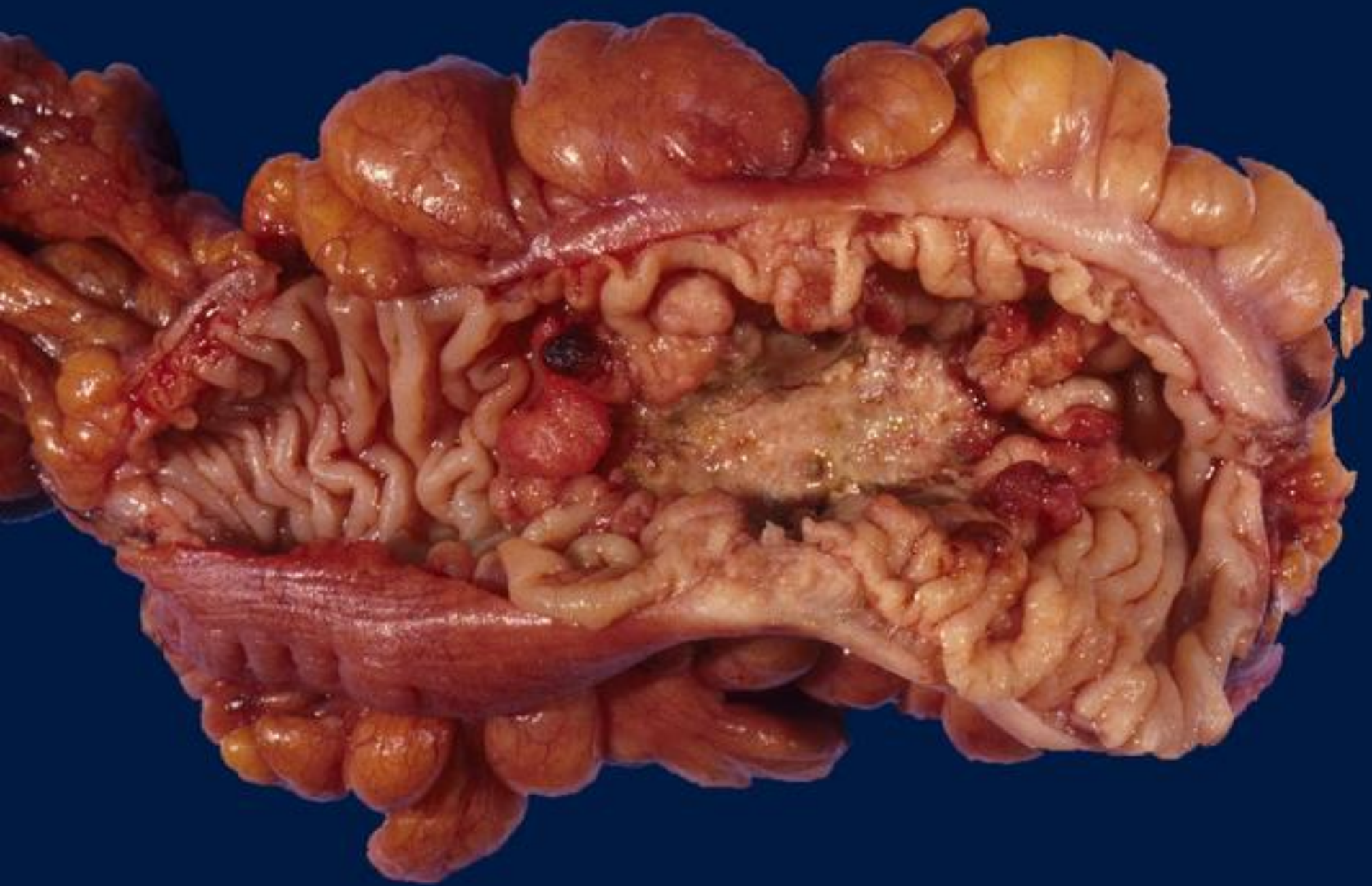- POLYPOID
- ANNULAR, CONSTRICTING
- DIFFUSE

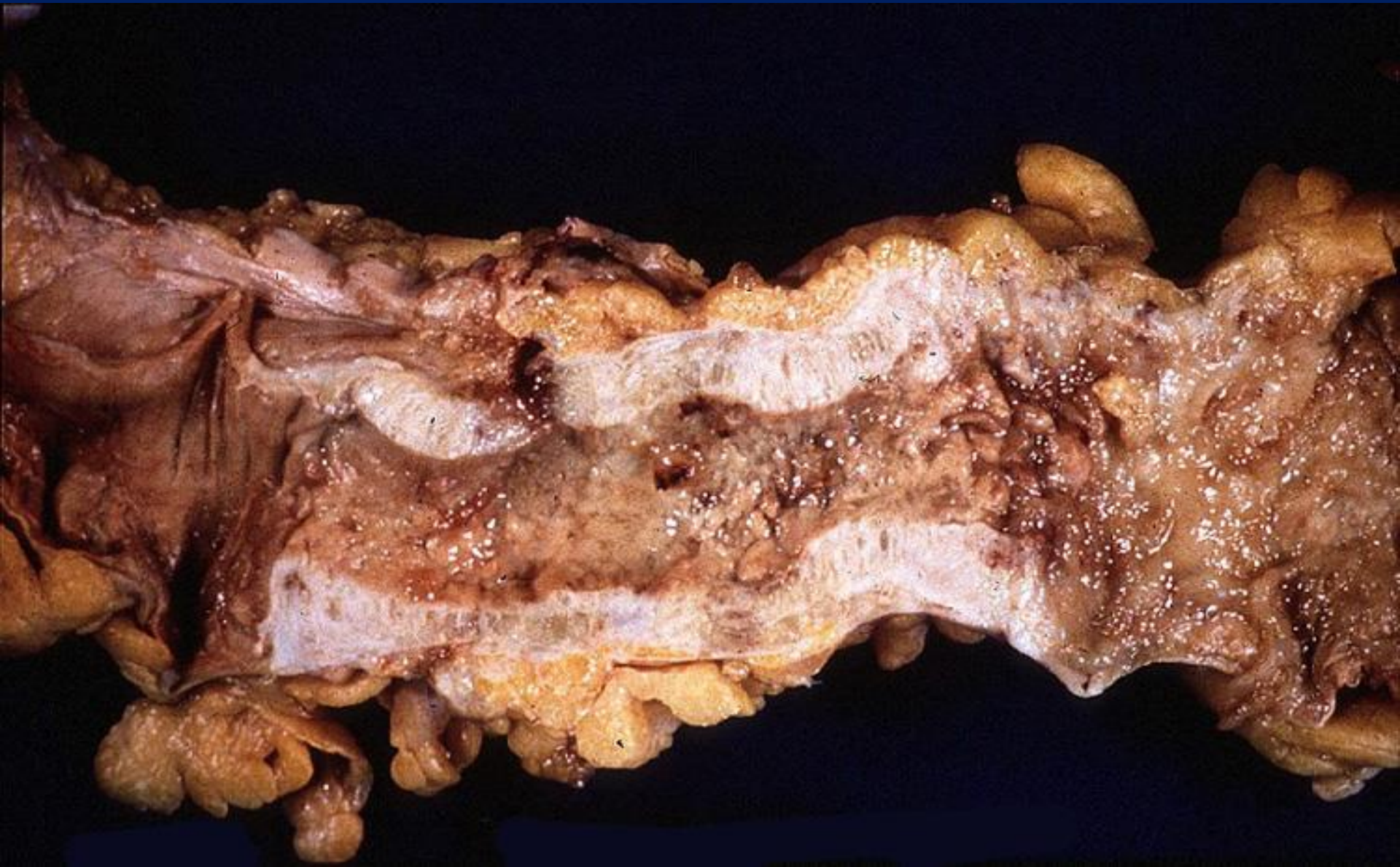

Morphology. Adenocarcinomas with almost the same frequency affect all parts of the colon. Tumors of the proximal colon usually grow in the form of polypoid exophytic masses spreading along one wall of the cecum or ascending colon. Such tumors rarely lead to intestinal obstruction.

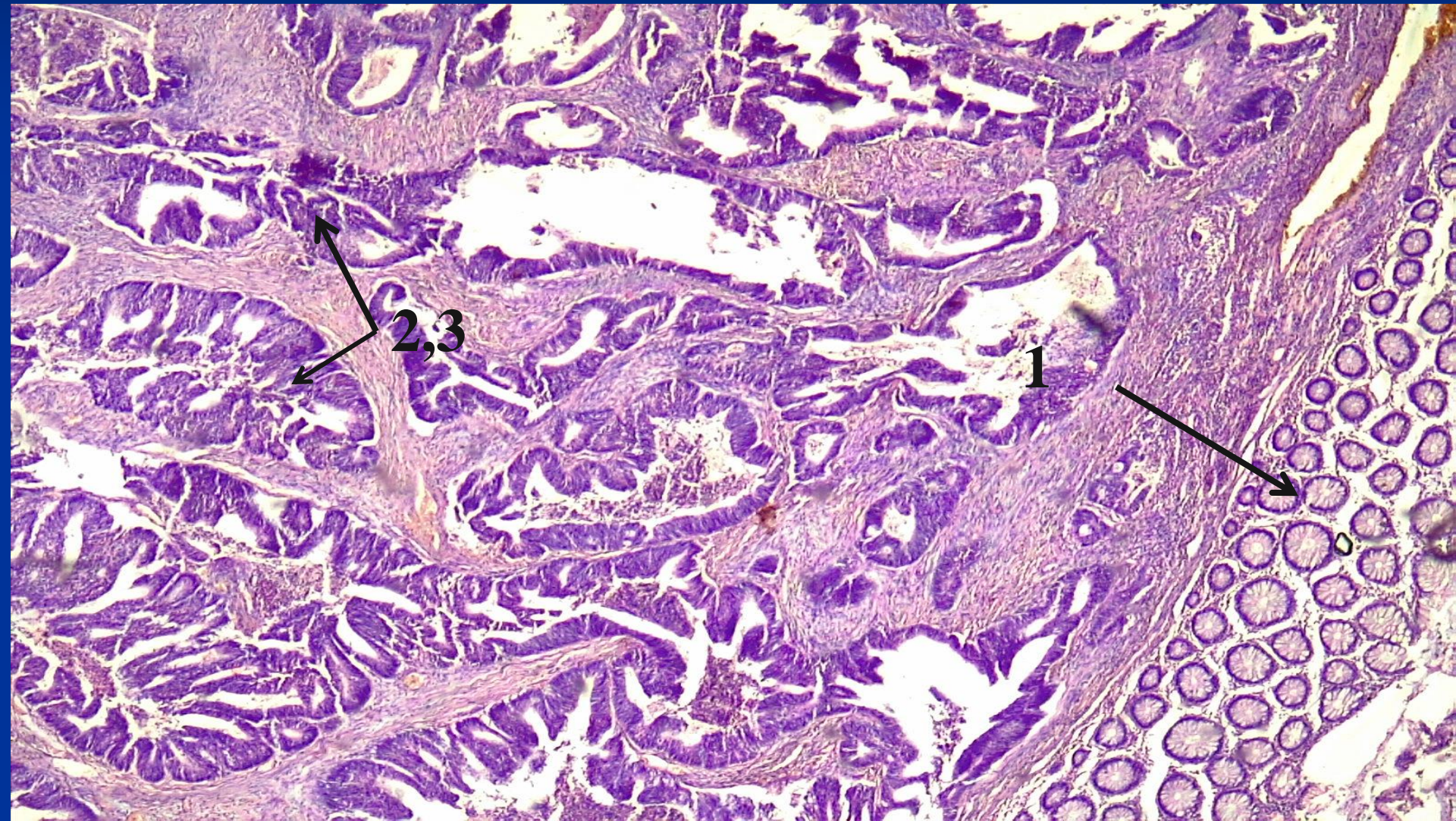
On the contrary, tumors of the distal colon usually have the form of ring-shaped formations and lead to a narrowing of the lumen of the intestine and sometimes to intestinal obstruction. In both cases, tumors grow over time into the wall of the colon and upon palpation are determined in the form of dense masses.



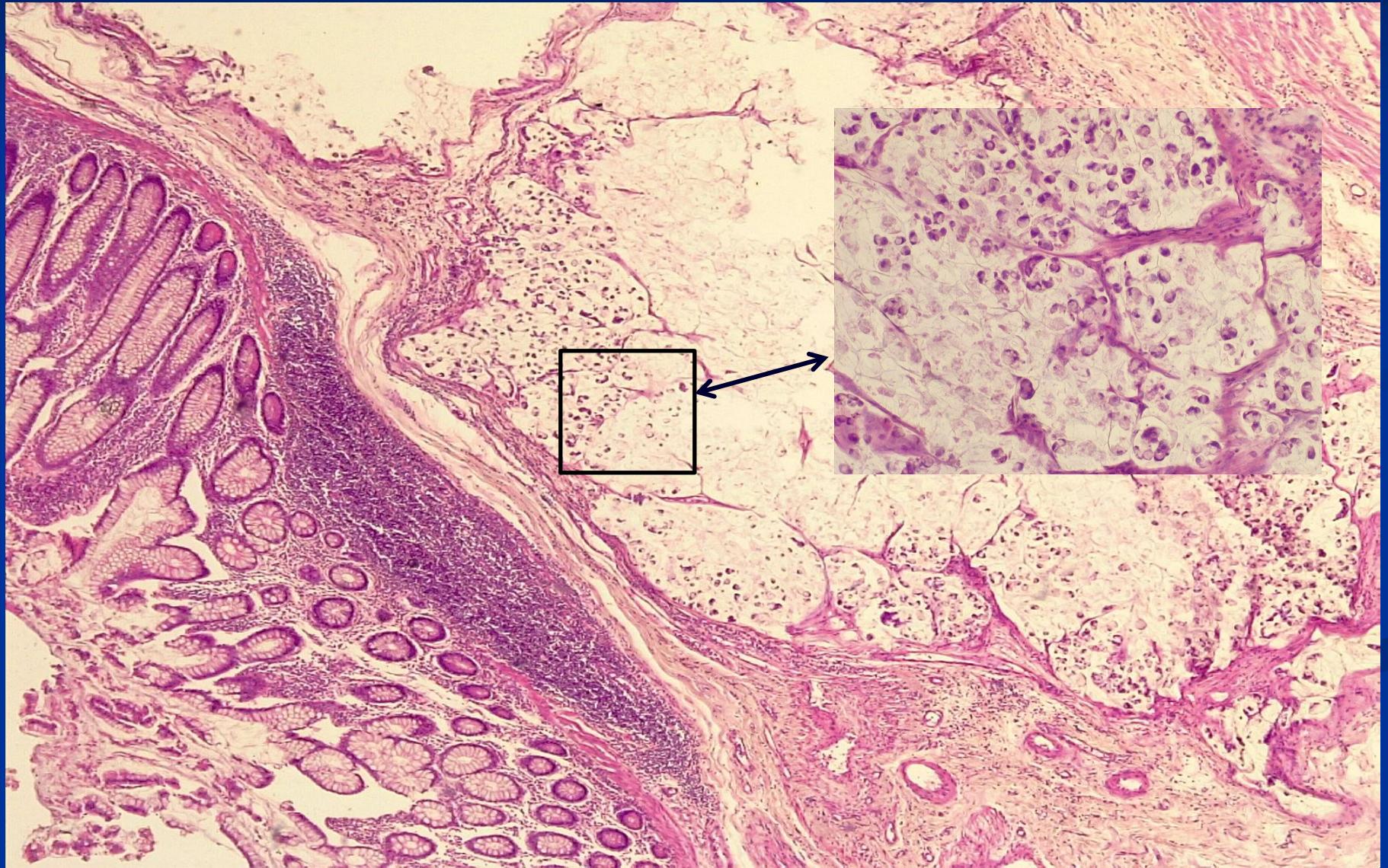




General histological characteristics of adenocarcinomas of the distal and proximal colon are similar. Most tumors consist of tall cylindrical cells resembling the dysplastic epithelium found in adenomas. The invasive component of these tumors causes a pronounced desmoplastic reaction of the stroma, which provides a characteristic dense consistency.



Some low-grade tumors form just a few glands, while others can produce mucus that builds up in the intestinal wall. Such adenocarcinomas have a poor prognosis. Tumors can also consist of signet ring cells, similar to those in similar tumors of the stomach.



Tumor Stage

Histologic Features of the Neoplasm

Tis	Carcinoma in situ (high-grade dysplasia) or intramucosal carcinoma (lamina propria invasion)
T1	Tumor breaches the musc. Muc. invades into submucosa
T2	Extending into the muscularis propria but not penetrating through it
T3	Penetrating through the muscularis propria into subserosa
T4	Tumor directly invades other organs or structures
Nx	Regional lymph nodes cannot be assessed
N0	No regional lymph node metastasis
N1	Metastasis in 1 to 3 lymph nodes
N2	Metastasis in 4 or more lymph nodes
Mx	Distant metastasis cannot be assessed
M0	No distant metastasis
M1	Distant metastasis

OTHER TUMORS

- **CARCINOID**, with or without syndrome
- **LYMPHOMA (MALTOMAS, B-Cell)**
- **LEIOMYOMA/-SARCOMA**
- **LIPOMA/-SARCOMA**

ANAL CANAL CARCINOMAS

- MORE LIKELY TO BE SQUAMOUS, or “basaloid”
- WORSE IN PROGNOSIS
- HPV RELATED