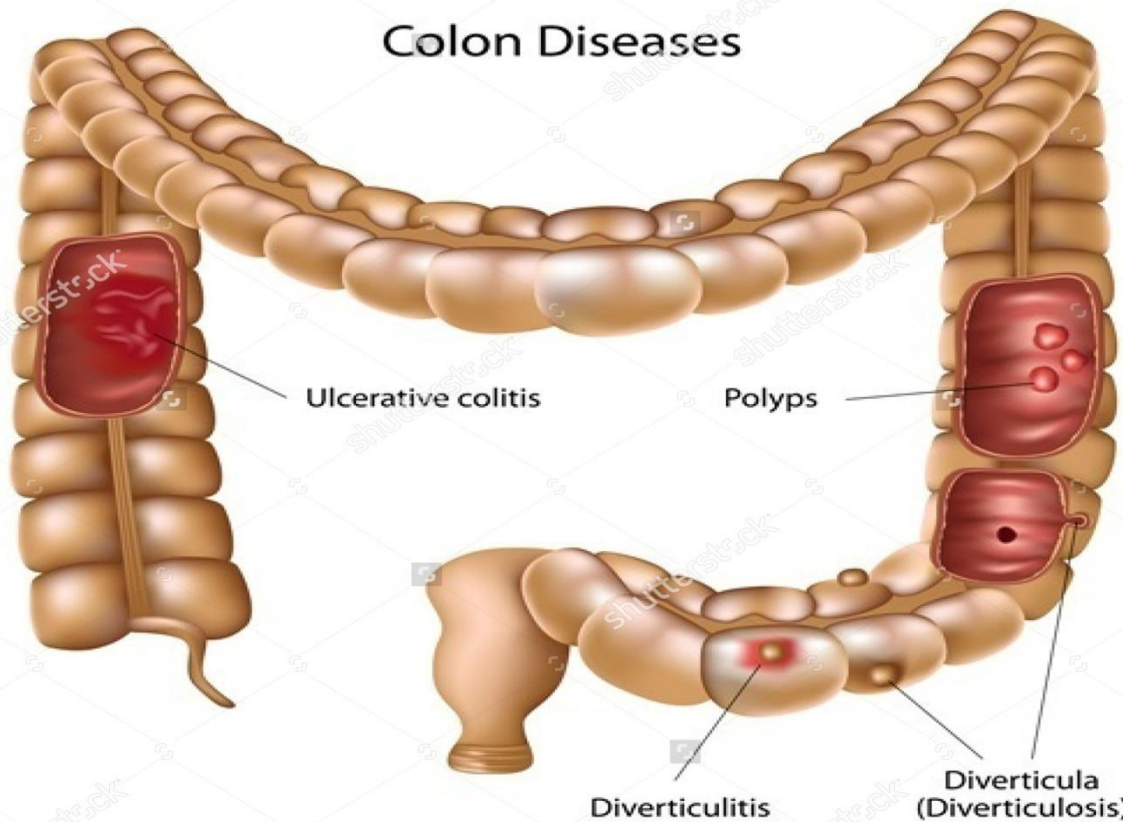
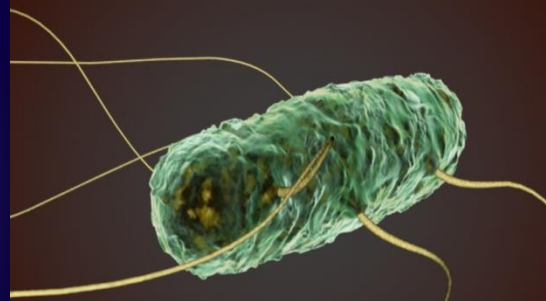
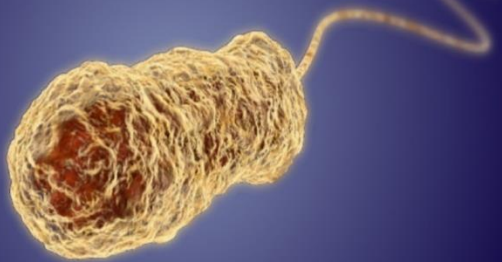
## Colon Diseases



**Intestinal pathology.  
Oral manifestations of  
intestinal pathologies**



**vibrio cholerae bacteria**

**salmonella bacteria**

## Intestinal pathology. Oral manifestations of intestinal pathologies.

### *I. Microspecimens:*

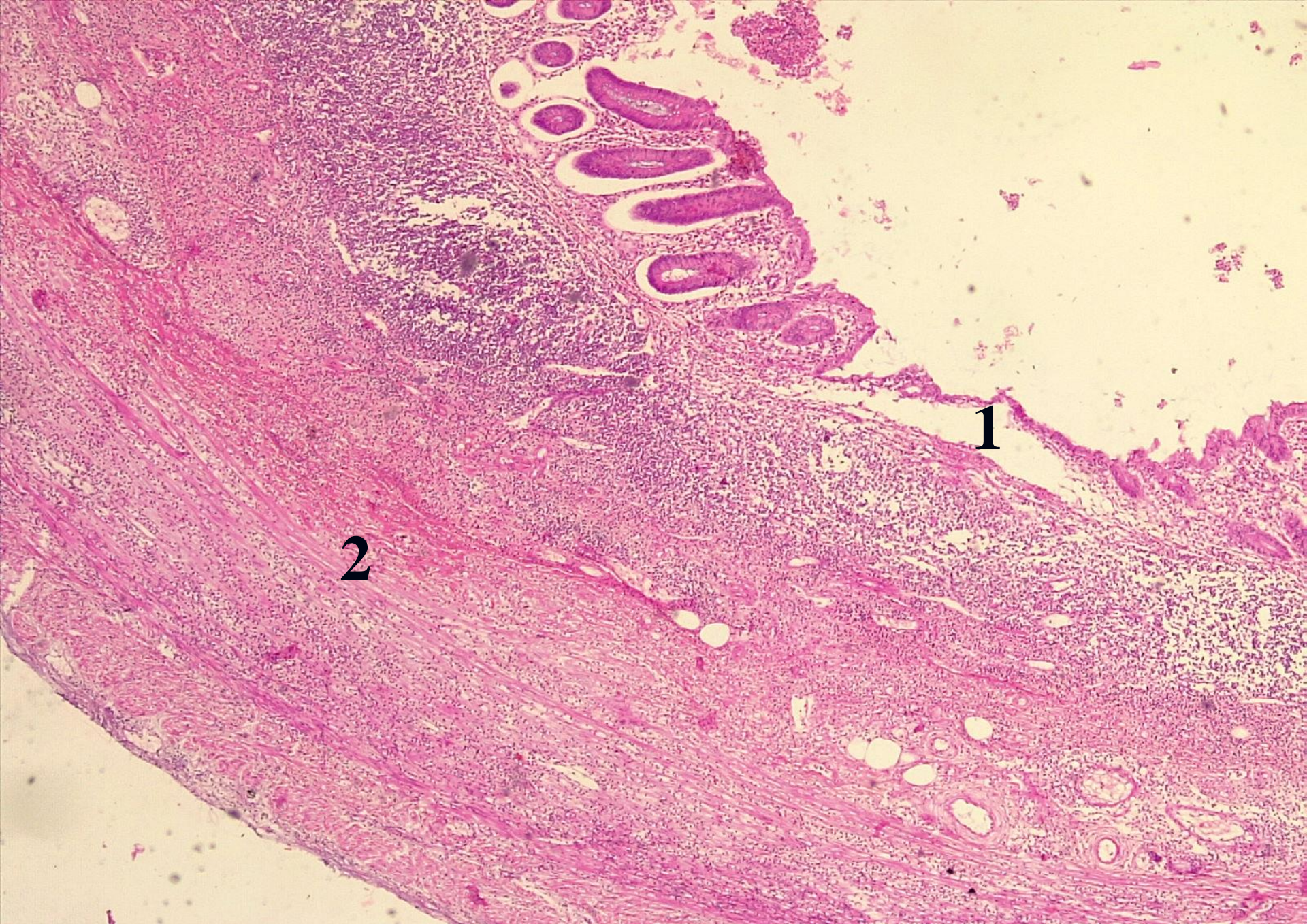
**№ 88. Acute suppurative appendicitis.** (*H-E. stain*).

### Indications:

1. Ulcerative mucosal defects.
2. Diffuse neutrophilic infiltration of all layers of appendicular wall.

The lumen of the vermicular appendix is dilated, the wall thickened, edematous, are observed ulcerative defects in the mucosa, their bottom covered with necrotic masses and neutrophilic leukocytes, in the wall thickness diffuse infiltration with neutrophilic leukocytes is revealed, which extends in all layers, including the serous membrane, neutrophilic infiltration is more abundant in the muscular layer also there is dilatation and hyperemia of the vessels, hemorrhages, in the lumen neutrophilic leukocytes and necrotic masses.

*The most common cause of acute appendicitis is obstruction of the lumen of the vermicular appendix, which can be caused by processes of fibrosis in the proximal portion, stones, including coprolites (starches), tumors, parasites, foreign bodies. These factors lead to retention of content and increased intraluminal pressure in the vermicular appendix, mucosal ischemia, epithelial damage, infection penetration, and the development of acute inflammation. The most important histological forms are: a) catarrhal appendicitis, b) phlegmonous, c) ulcero-phlegmonous and d) gangrenous. In some cases in the thickness of the appendix wall. can form microabscesses - apostematous appendicitis. Complications of acute appendicitis: a) perforation or self-amputation in gangrenous form with the development of localized or generalized peritonitis, b) spread of inflammation on the serous membrane - periappendicitis, mesenteryol - mesenteriolitis and check - perityphlitis, c) empyema (accumulation of pus in the appendicular lumen) d) abscesses in the right iliac fossa, in the pelvis between the bladder and rectum and subdiaphragm on the right, e) pielophlebitis (inflammation of the portal vein) with abscesses in the liver. Late complications: adhesions with the large omentum, small intestine, other organs and mucocele.*



№ 88. Acute suppurative appendicitis. (*H-E. stain*).

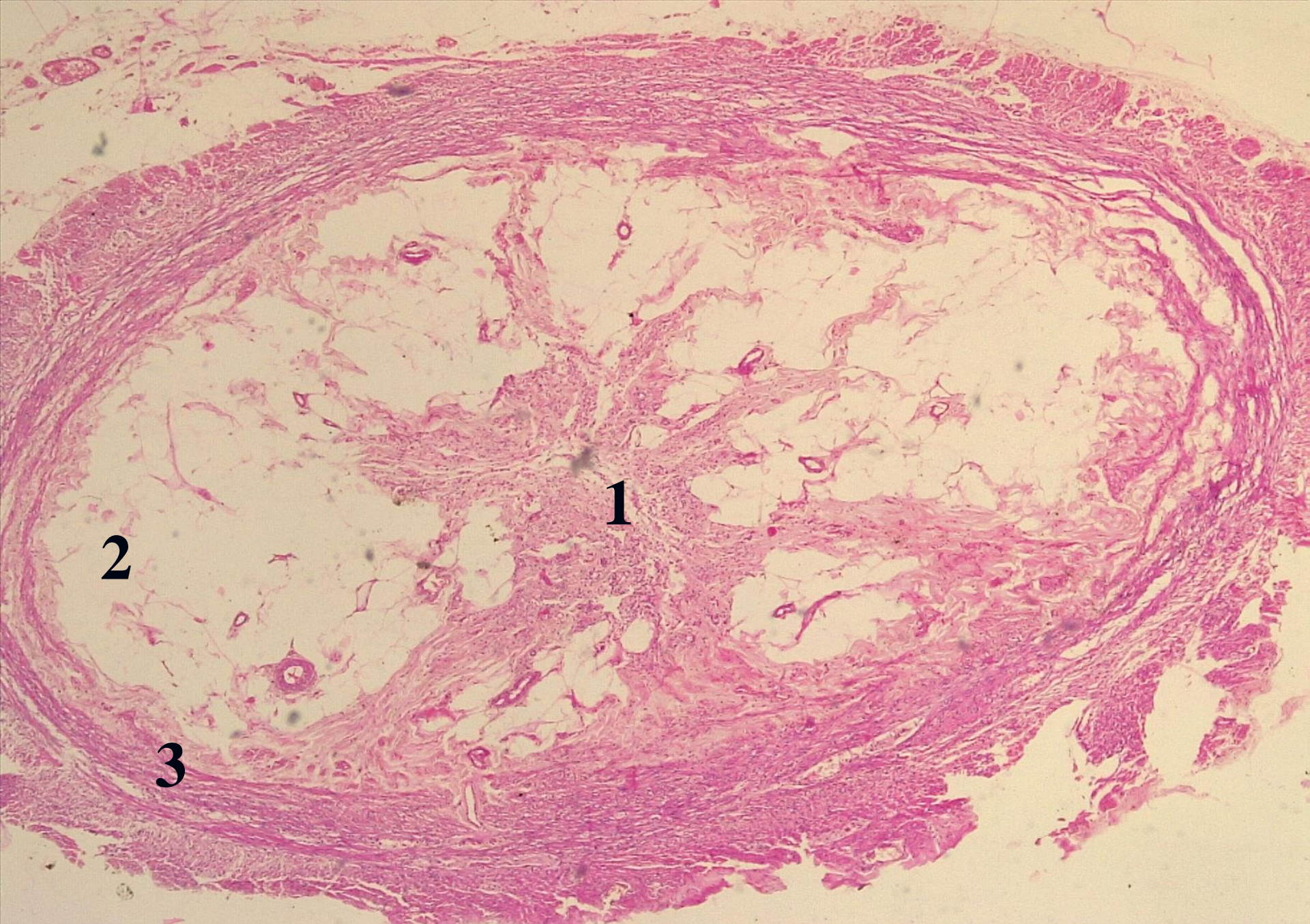
**№ 88a. Chronic appendicitis.** (*H-E. stain*).

**Indications:**

1. Occlusion of appendicular lumen.
2. Appendicular wall substituted by connective and fatty tissue.
3. Atrophied muscle layer.

The lumen of the vermicular appendix is obliterated with connective and adipose tissue, which have completely replaced the mucosa and submucosa, the muscular layer is atrophied.

*Chronic appendicitis occurs as a result of acute appendicitis and is characterized by processes of sclerosis and atrophy of all layers of the wall, obliteration of the lumen may occur. In cases when the obliteration is at the level of the proximal portion of the appendix, the following may develop: a) appendicular hydrops (accumulation of serous fluid), b) mucocele (distension of the appendix with accumulation of mucus), c) myxoglobulosis (formation of mucus globules due to wall peristalsis), d) peritoneal pseudomixom in case of rupture of the mucocell wall and spread of mucus globules on the peritoneum (reminiscent of a myxoma), e) appendicular empyema in case of association of infection.*



**№ 88a. Chronic appendicitis. (H-E. stain).**

**№ 222. Appendiceal mucocele.** (*H-E. stain*).

**Indications:**

1. Hyperplasia of glandular epithelium which secretes mucus.
2. Thinned muscle layer.
3. Mucus in the dilated lumen of the appendix.

The microspecimen has a portion of the mucocell wall; hyperplasia of the mucosecretory epithelium is revealed, which in some places forms papillary proliferations, blood vessels are dilated, hyperemic, foci of hemorrhages are observed in the eosinophilic colored mucus lumen. [*microspecimen № 88a*]

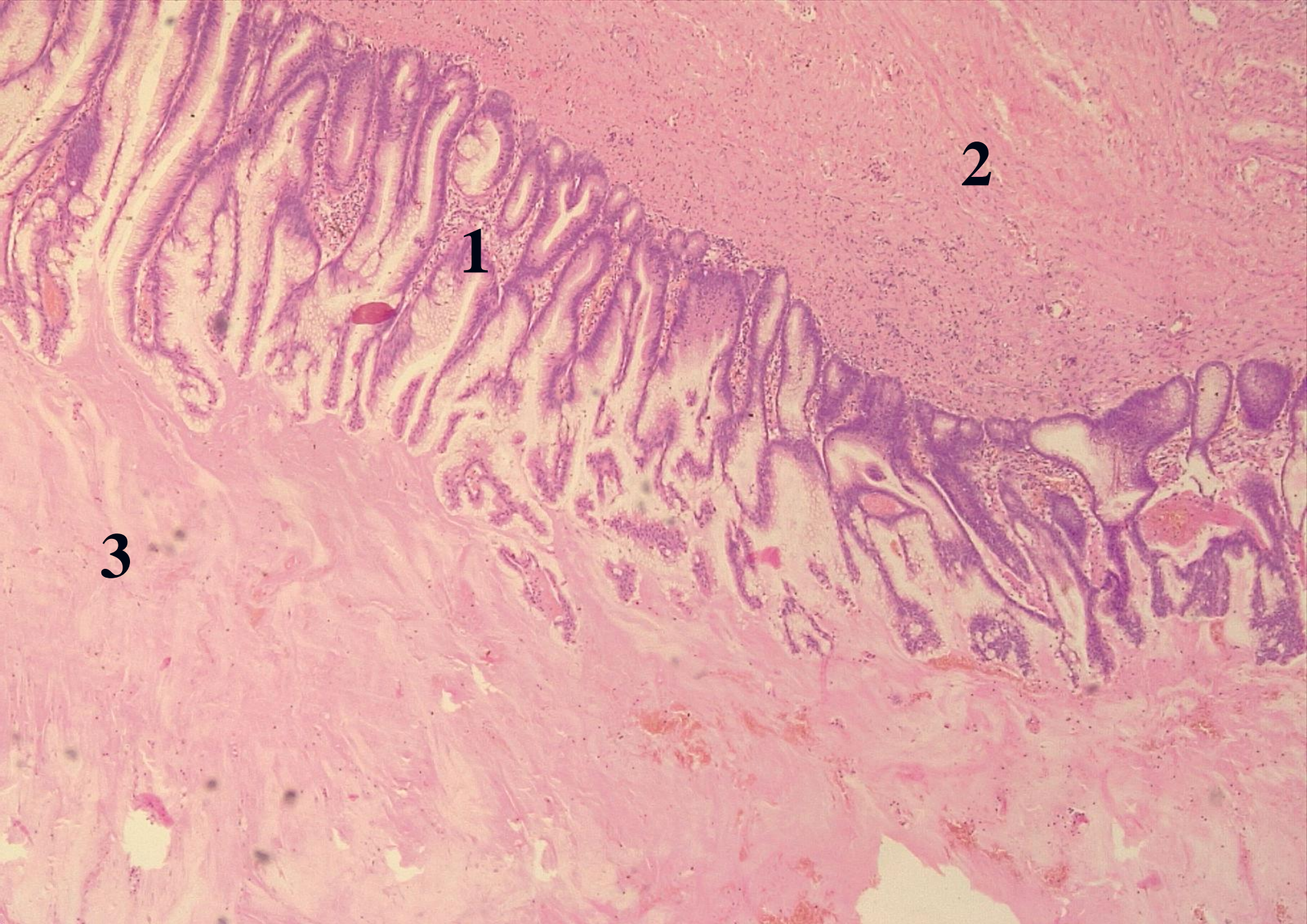
**№ 48a. Mucinous carcinoma of the colon (signet-ring cell).** (*H-E. stain*).

**Indications:**

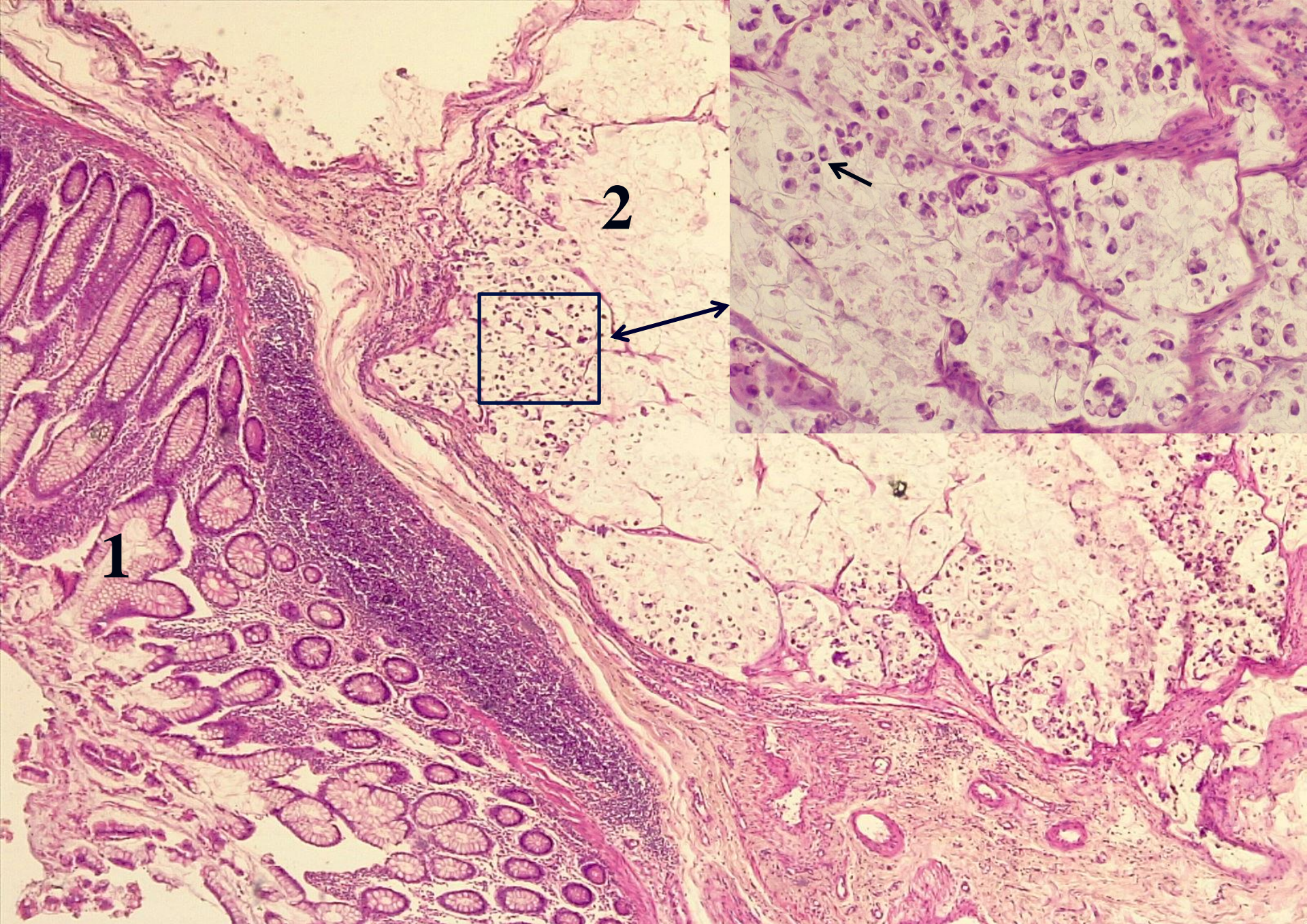
1. Intact mucosa.
2. Clusters of "signet ring cells" and mucous substance which infiltrate the intestinal wall.
3. Muscle layer.

In the colonic wall the mucosa has a normal structure, immediately below the mucosal muscle there are "lakes" of weakly basophilic colored mucus, in the mucus "floating" isolated cells and groups of "signet ring cells", round / oval shape, with abundant cytoplasm, the nucleus displaced to the membrane and flattened; in the adjacent tissue chronic inflammatory infiltration, predominantly lymphoid.

*Signet ring cell carcinoma of colon is relatively rare, in about 1% of total cases. It is localised predominantly in the right colon. Macroscopically it looks like a gelatinous mass. It is distinguished by aggressive evolution, metastases appear quickly, multiple and in several organs.*



**№ 222.** Appendiceal mucocele. (*H-E. stain*).



**№ 48a. Mucinous carcinoma of the colon (signet-ring cell). (H-E. stain).**



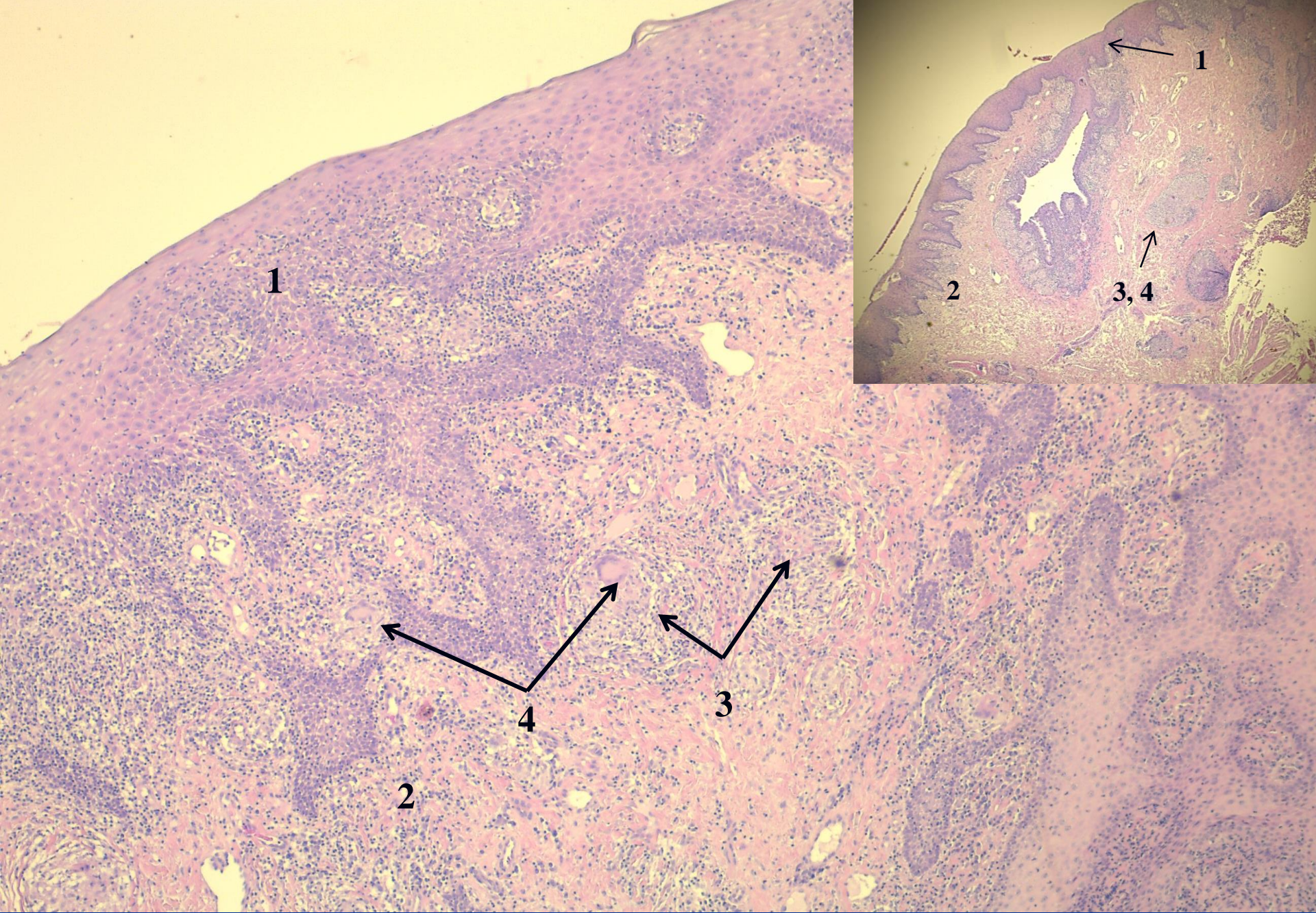
**No OP 31. Crohn's disease with oral manifestations. (H-E stain).**

**Indications:**

1. Stratified squamous epithelium with scattered lymphocytes.
2. Underlying fibrous connective tissues with chronic inflammatory cell infiltrate.
3. Noncaseating granulomas.
4. Giant cells.

Histopathologic images of the right mandibular gingiva, showing stratified squamous epithelium with scattered lymphocytes. The underlying fibrous connective tissue is characterized by the presence of a non-uniform chronic inflammatory infiltrate and well-defined, noncaseating granulomas composed of epithelioid histiocytes, lymphocytes and giant cells.

*Crohn's disease (CD) is an immune-mediated disorder of the gastrointestinal (GI) tract which, along with ulcerative colitis, comprises the two major subsets of the inflammatory bowel disease (IBD). The underlying etiology is poorly understood but likely involves defects in mucosal immunity and intestinal epithelial barrier function in a genetically susceptible individual, leading to an inappropriate inflammatory response to intestinal microbes. The lesions of CD can involve any portion of the alimentary tract from the mouth to anus. Extraintestinal sites such as the skin, joints, and eyes may be affected as well. The most common presenting symptoms are periumbilical abdominal pain and diarrhea associated with recalcitrant fevers, malaise, fatigue, and anorexia. Oral involvement is identified in up to 80% of patients and may precede GI involvement in some cases.*



No OP 31. Crohn's disease with oral manifestations. (H-E stain).

## ***II. Macrospecimens:***

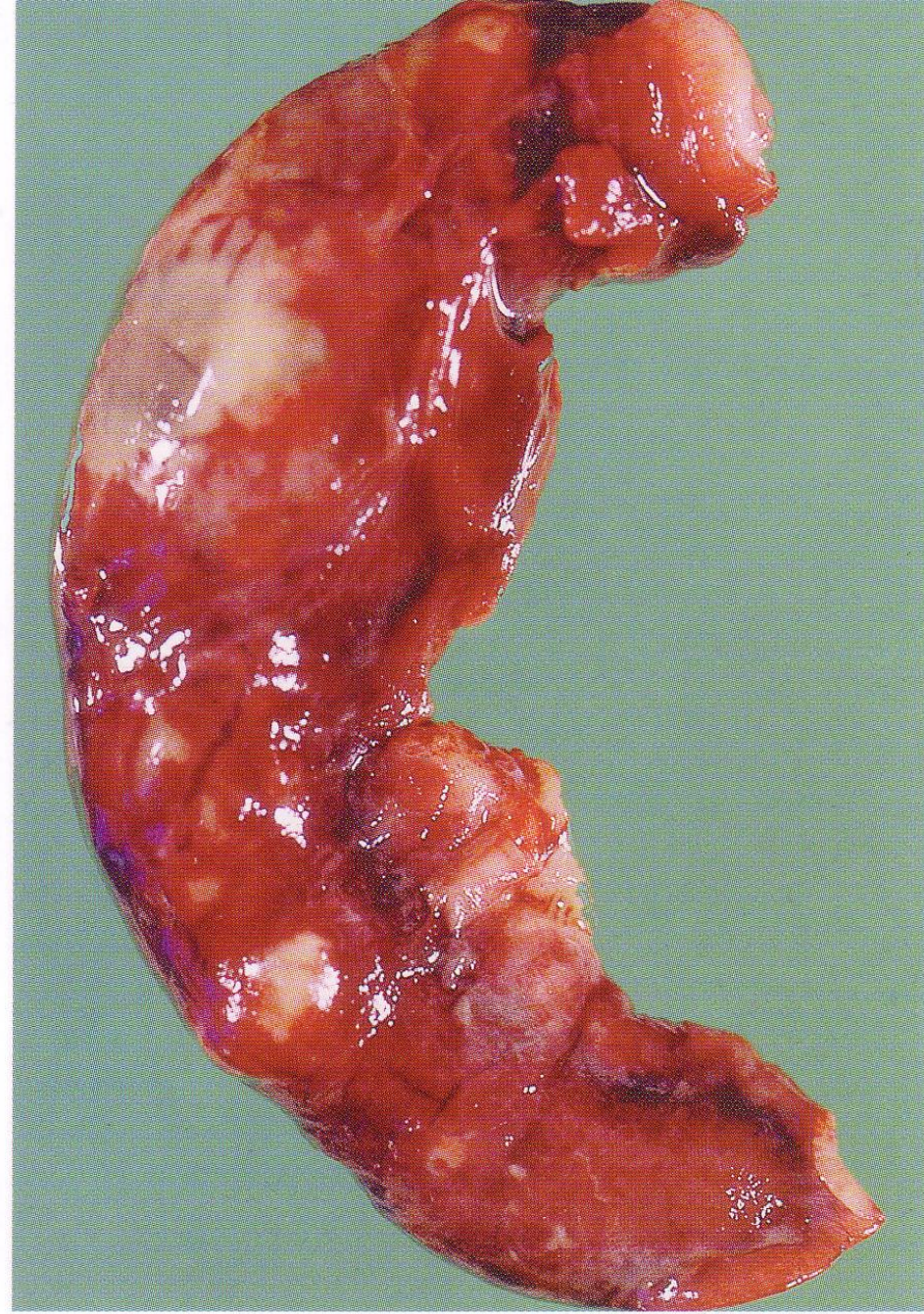
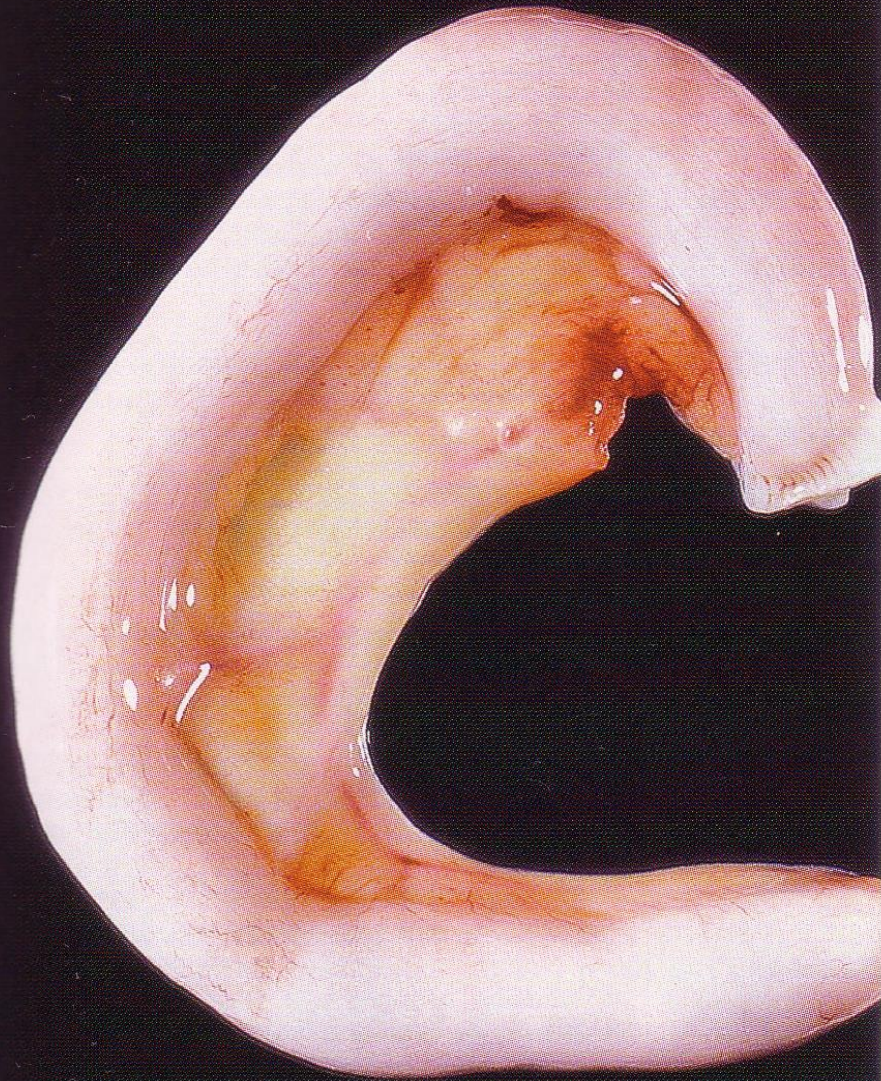
### **№ 55. Acute suppurative appendicitis.**

The vermicular appendix is dilated, the surface is matte, serous edematous, hyperemic, with hemorrhagic foci and whitish fibrin deposits, the mesentery is edematous, hyperemic, with hemorrhages and fibrin. [*microspecimen № 88*]

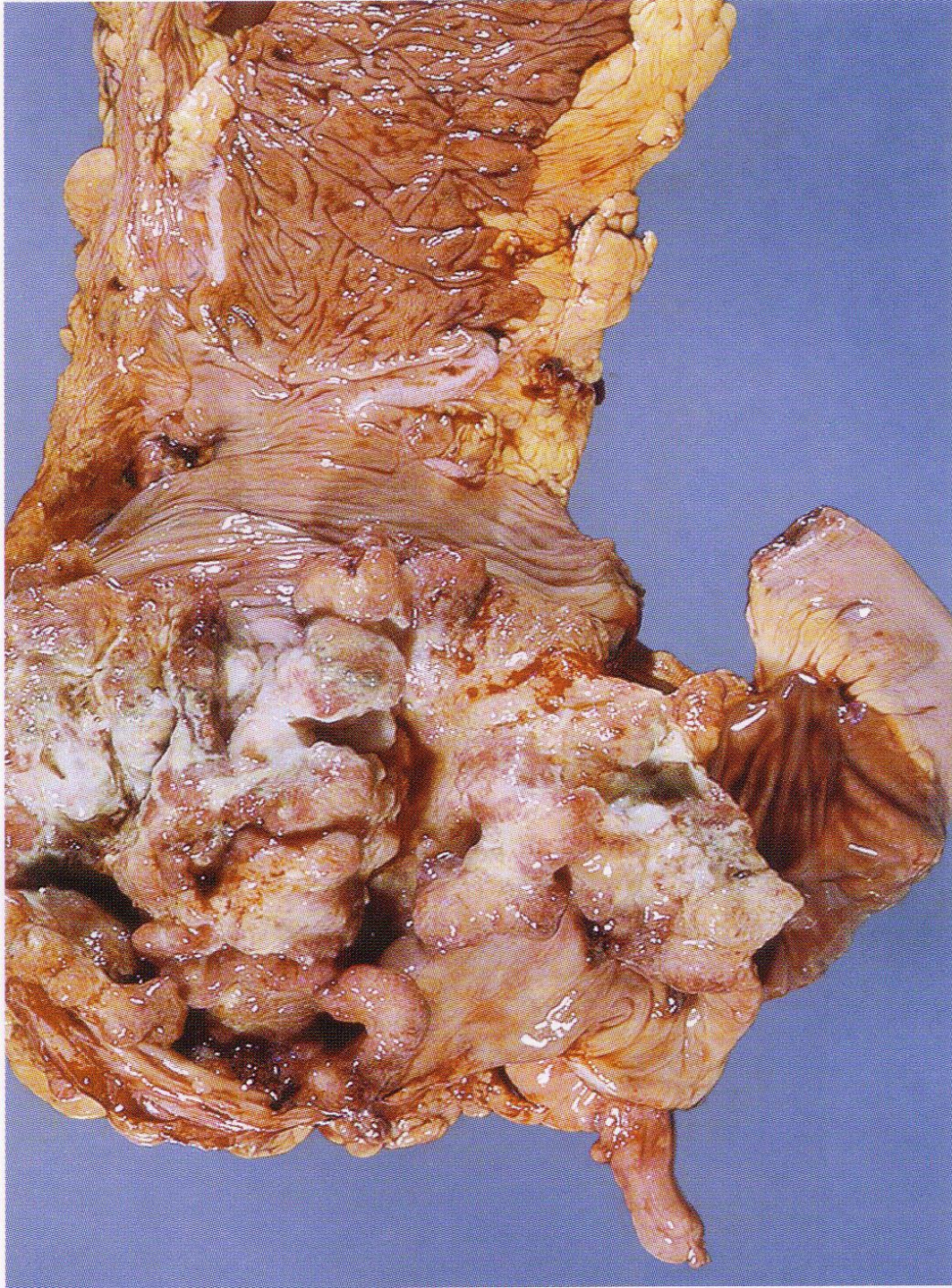
### **№ 61. Carcinoma of sigmoid colon.**

In the colon there is a large tumor node, which grows exophyte, considerably stenoses the intestinal lumen, irregular surface, with areas of necrosis and ulceration, dense-elastic consistency, pinkish-whitish color.

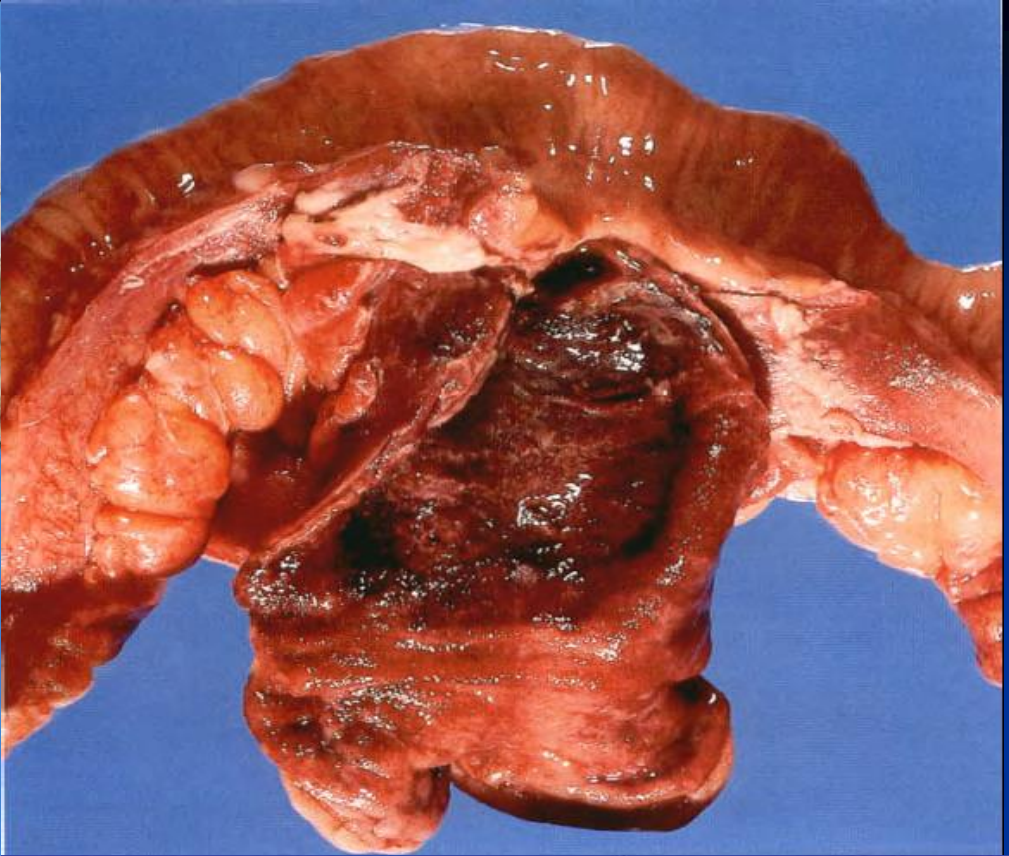
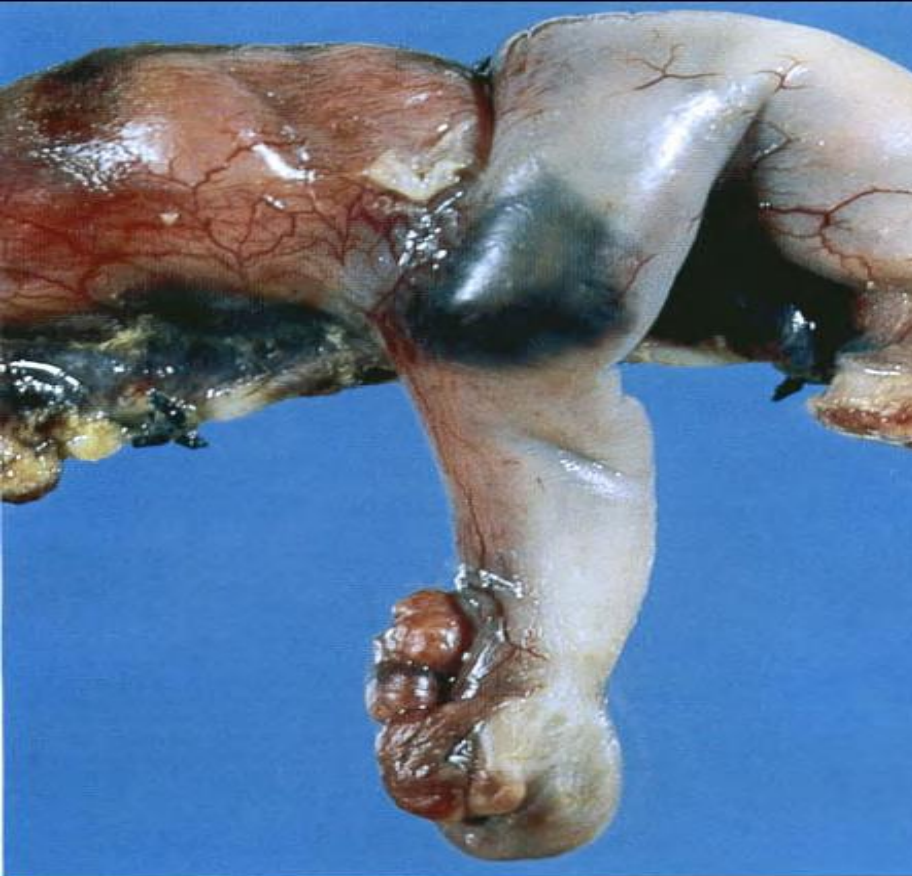*Colon cancer is localised more frequently in descending order: in the rectum (60%), sigma, descending colon, cecum and ileocecal region, ascending colon, hepatic flexure and spinal flexure. It can be complicated by intestinal occlusion, hemorrhage, perforation and peritonitis, infiltration of adjacent tissues / organs, phlegmon. Metastases occur primarily by lymphogenesis in regional lymph nodes, and hematogenous metastases are relatively late and are more common in the liver, lungs, brain, bones and ovaries. Microscopically in the majority of cases (90-95%) colon cancer is adenocarcinoma. Among the precursors, adenomas, familial adenomatous polyposis, nonspecific ulcerative colitis and Crohn's disease are more common.*



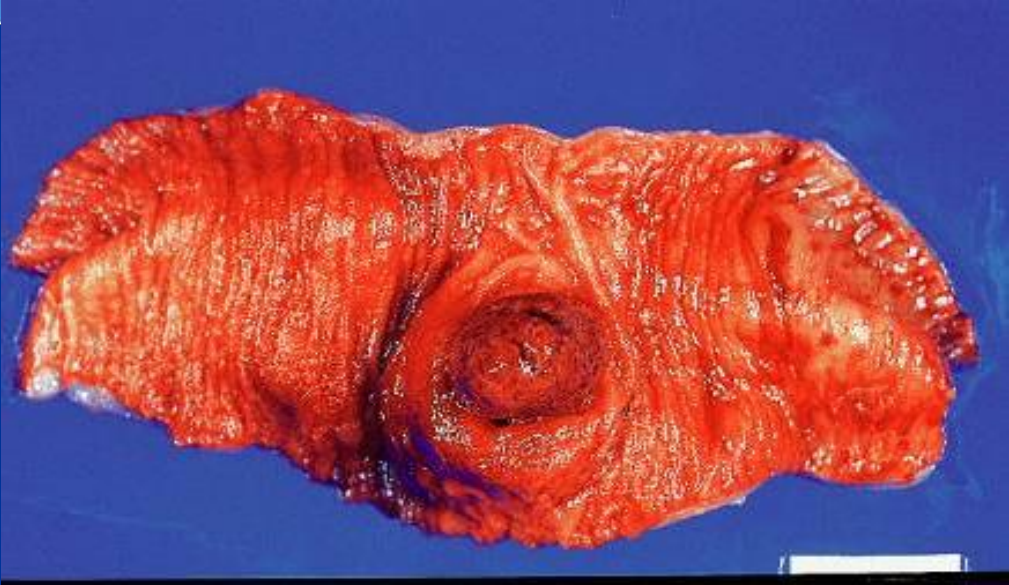№ 55. Acute suppurative appendicitis.

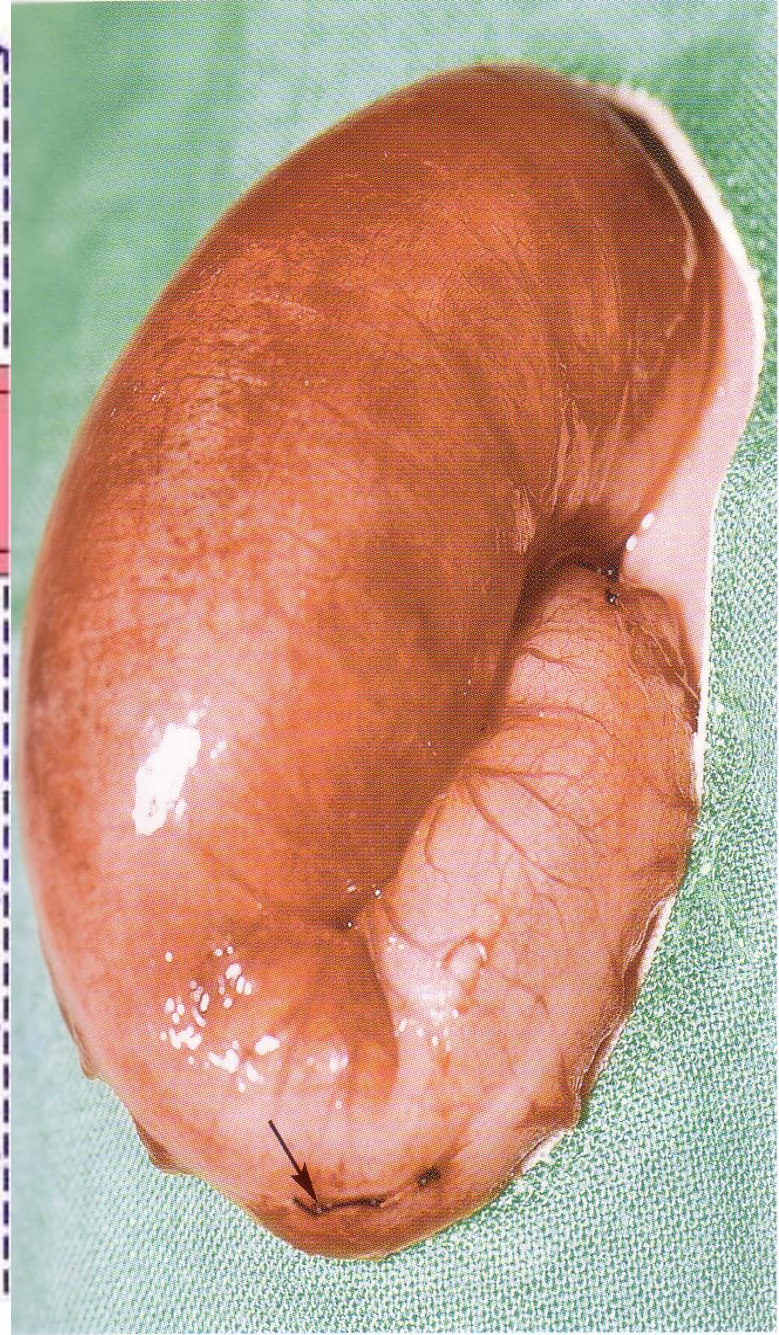
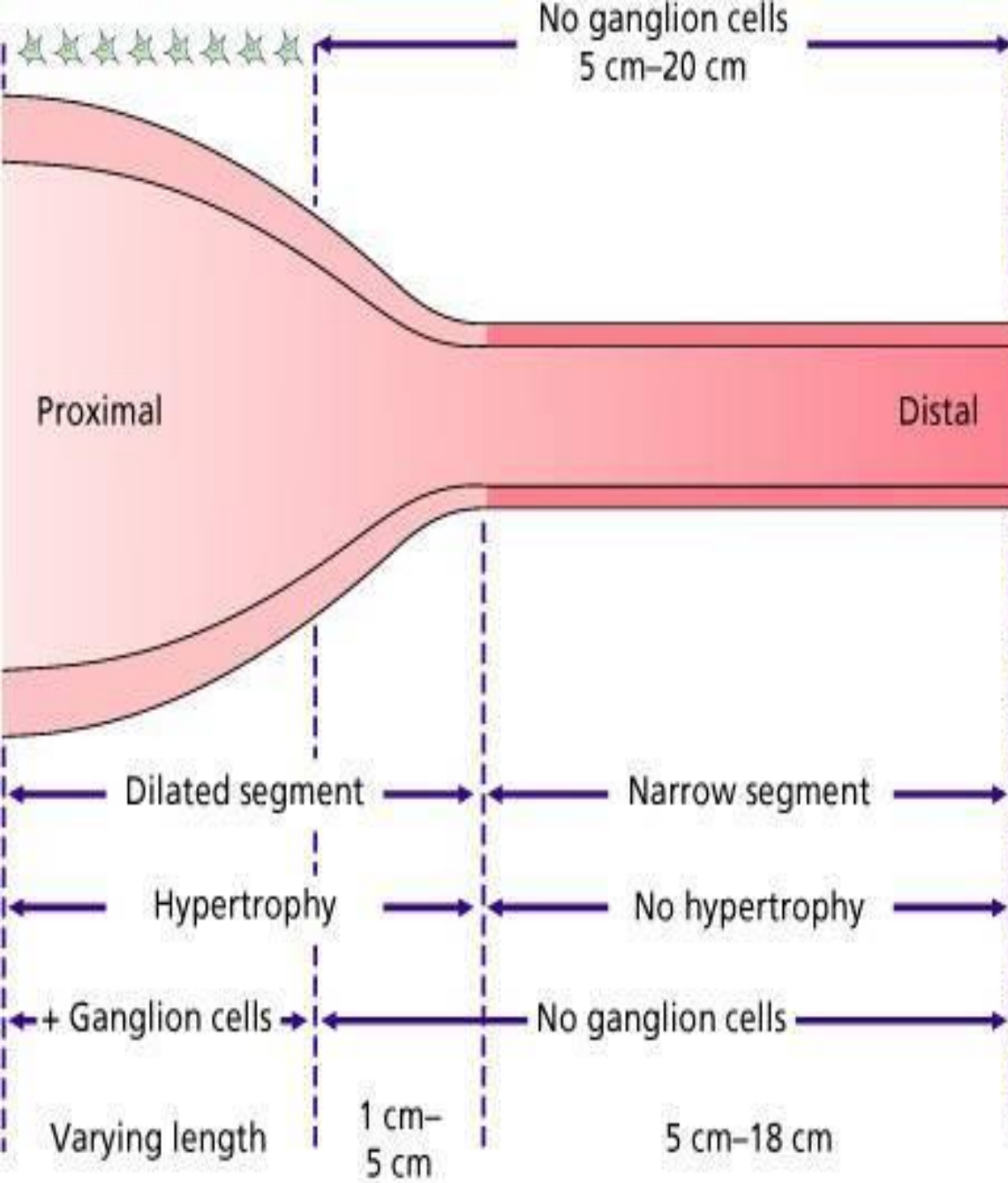


**№ 61. Carcinoma of sigmoid colon.**

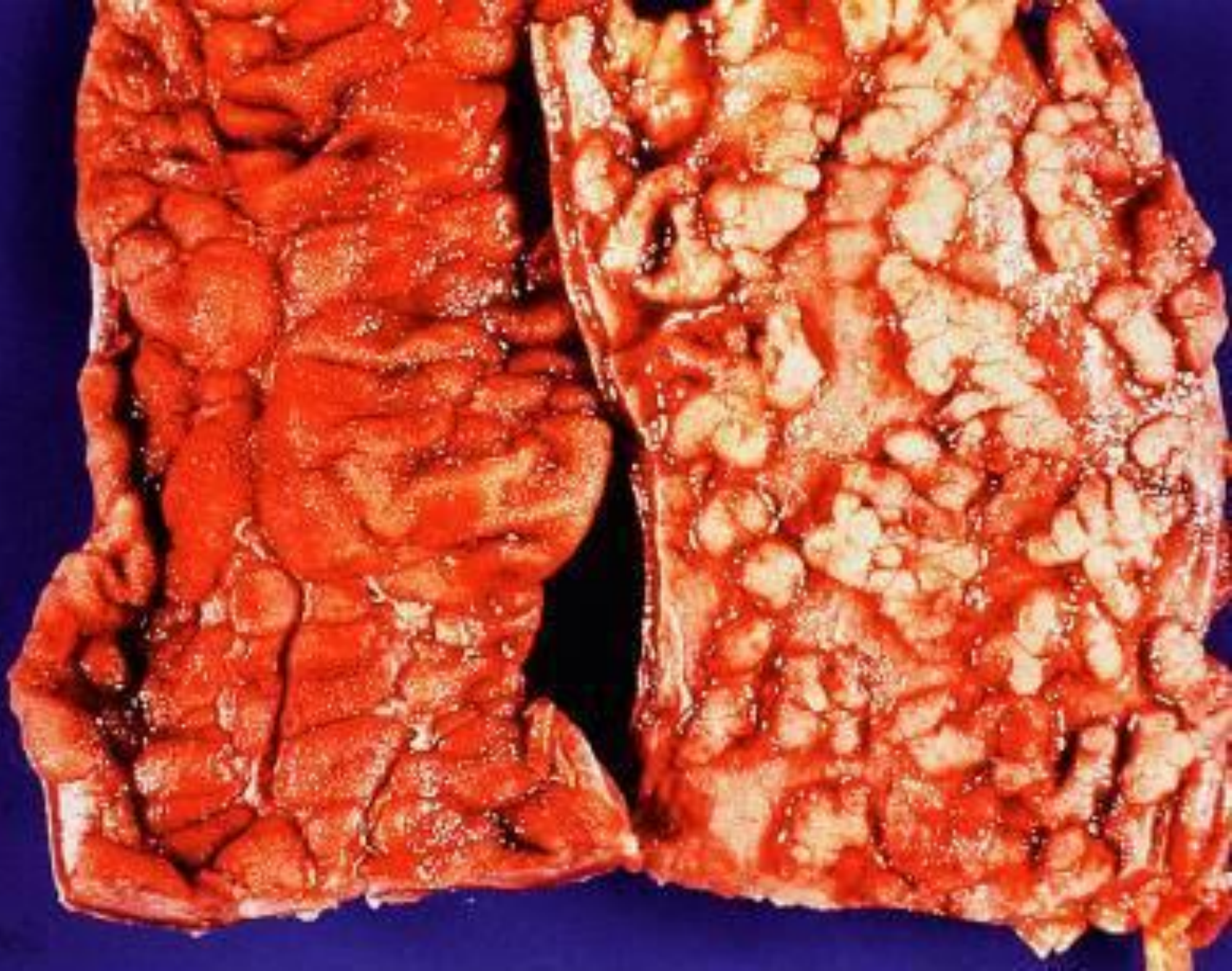


**Meckel's diverticulum.**



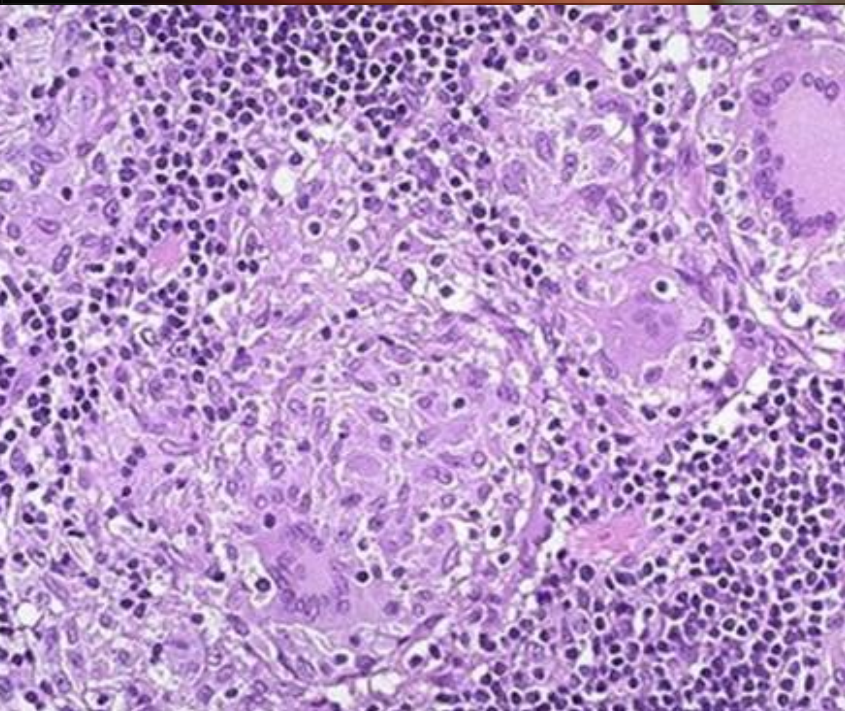
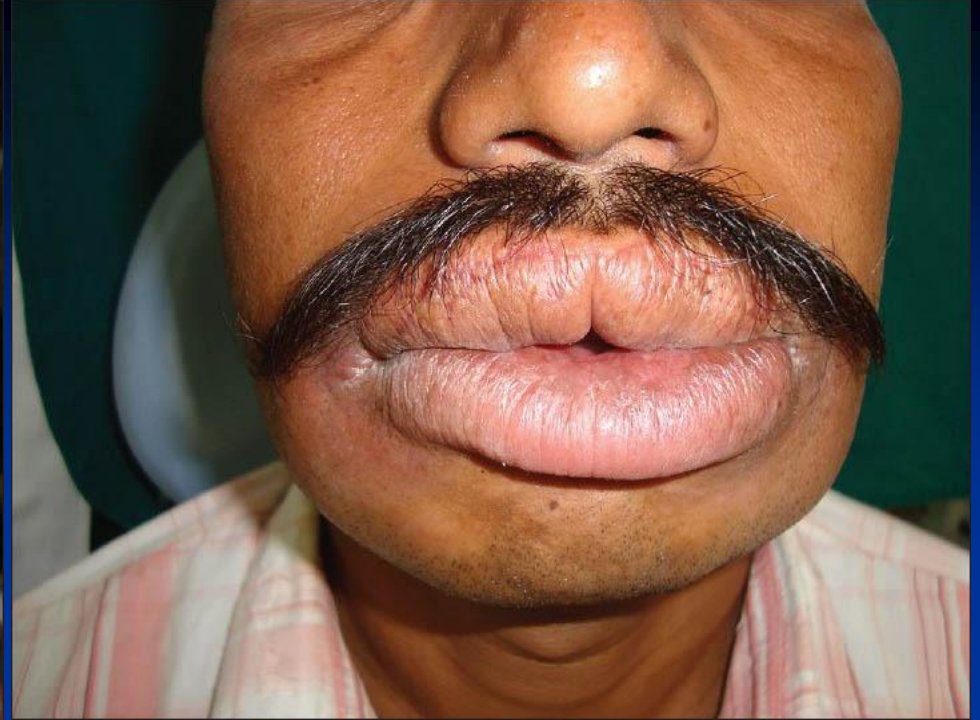
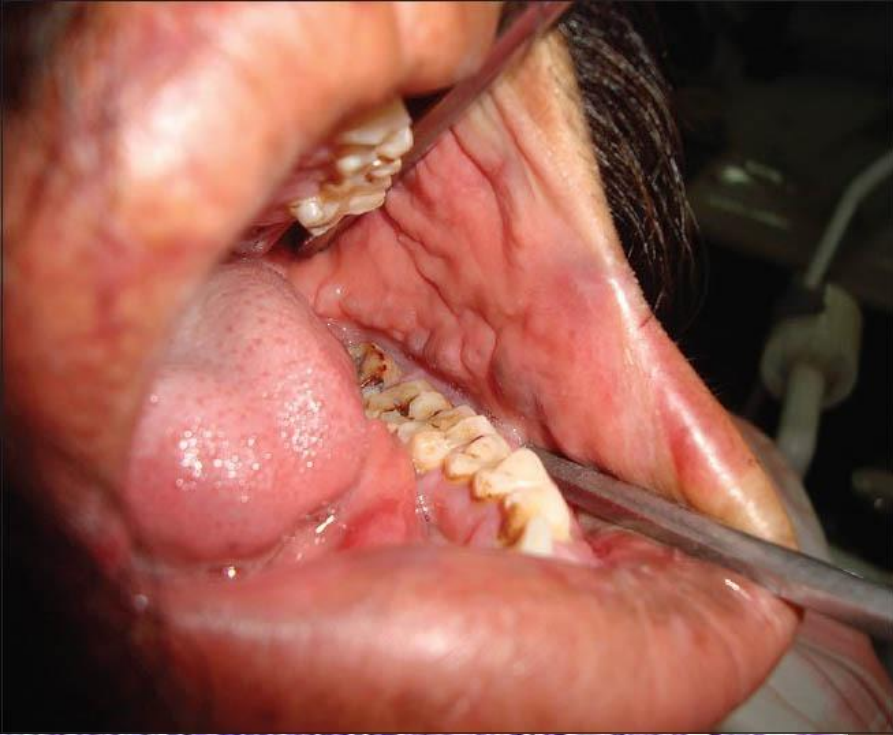
**Scheme of large bowel involvement in Hirschprung's disease.**

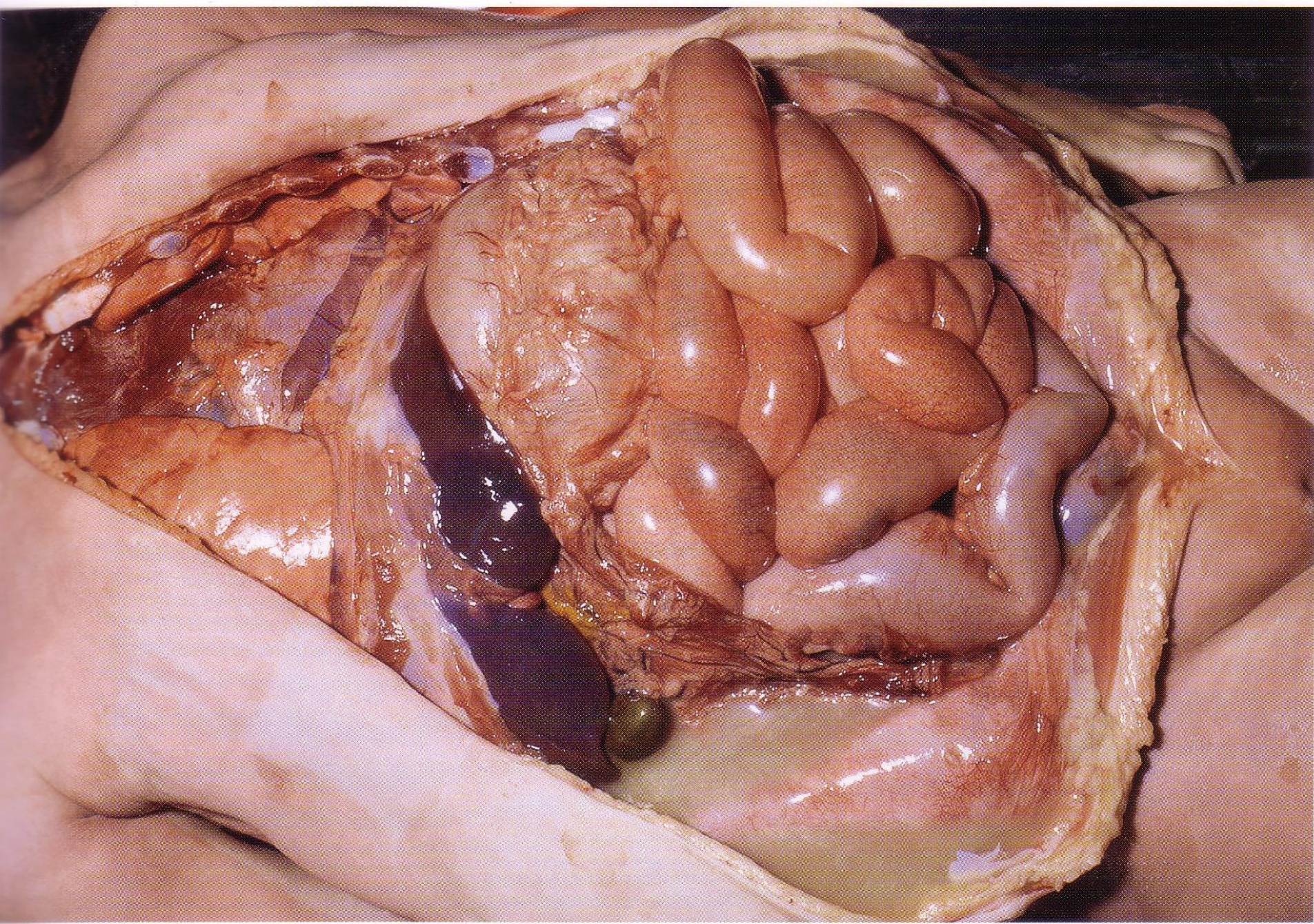


**Crohn's disease vs. Nonspecific ulcerative colitis.**

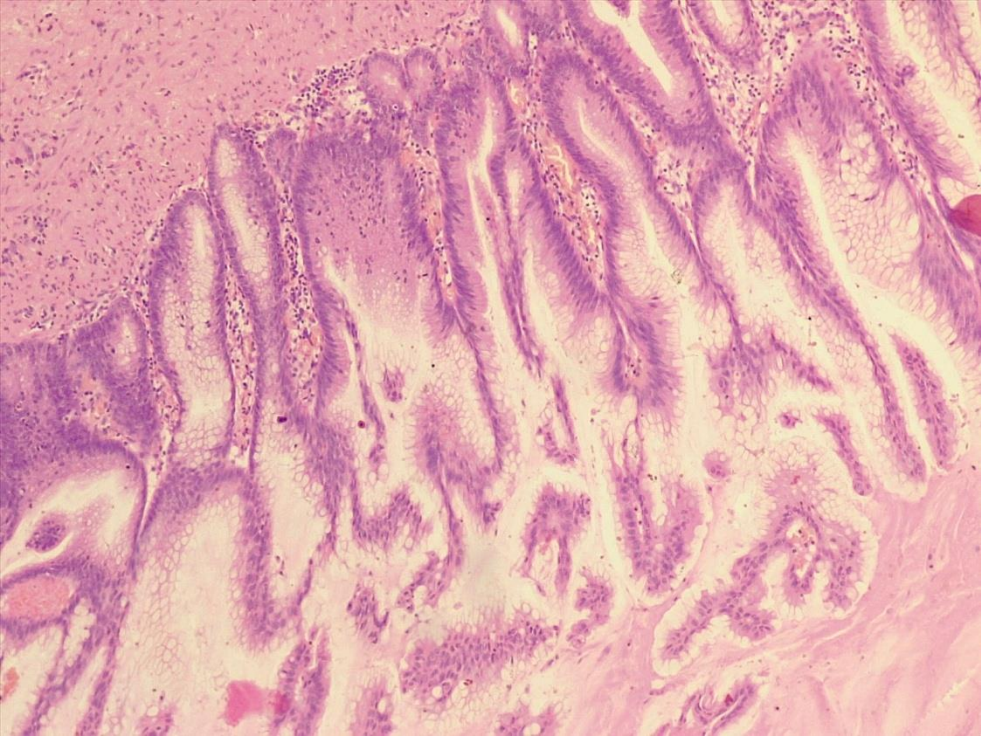




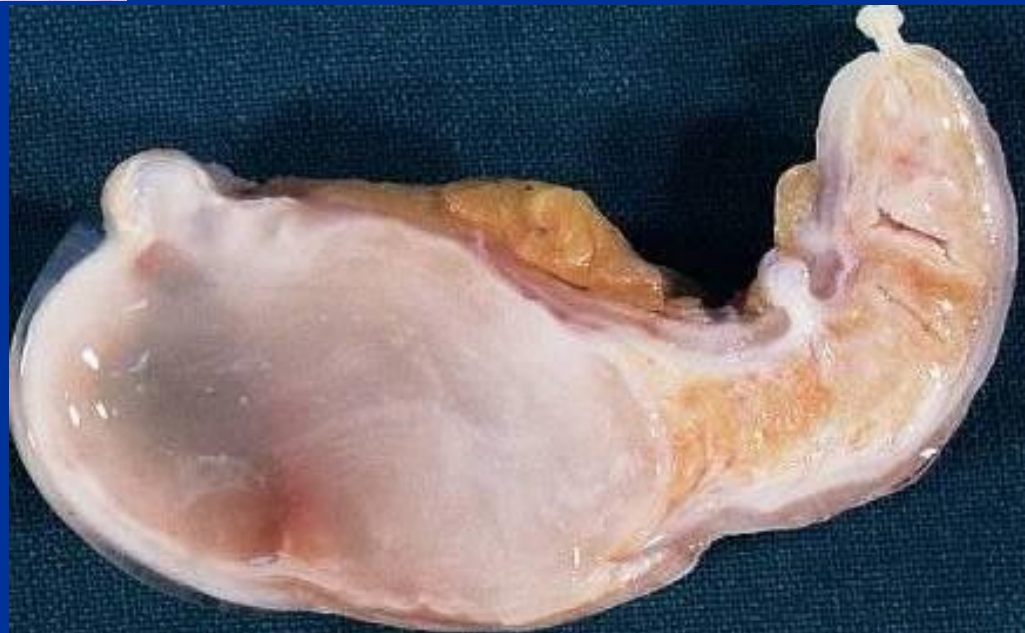**Oral manifestations of Crohn's disease**

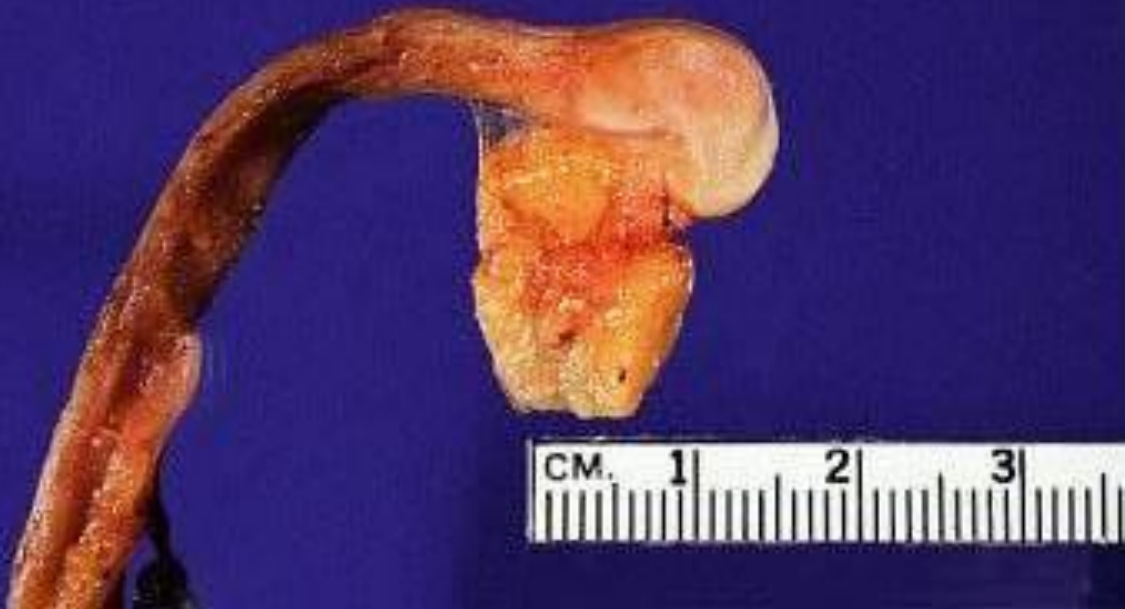

**Purulent peritonitis - complication of acute appendicitis.**

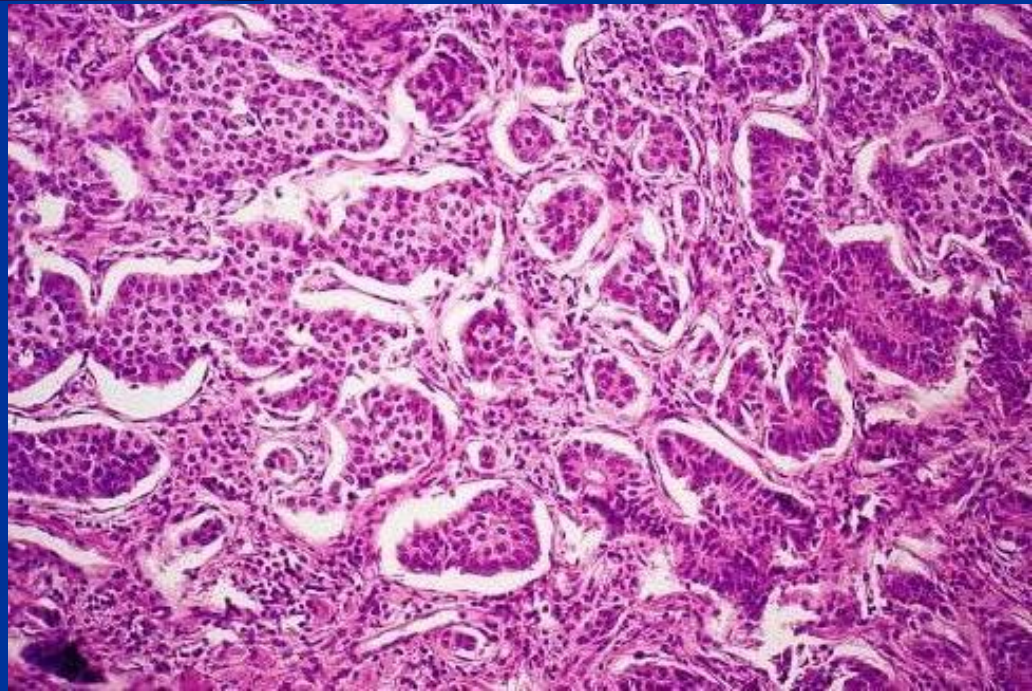


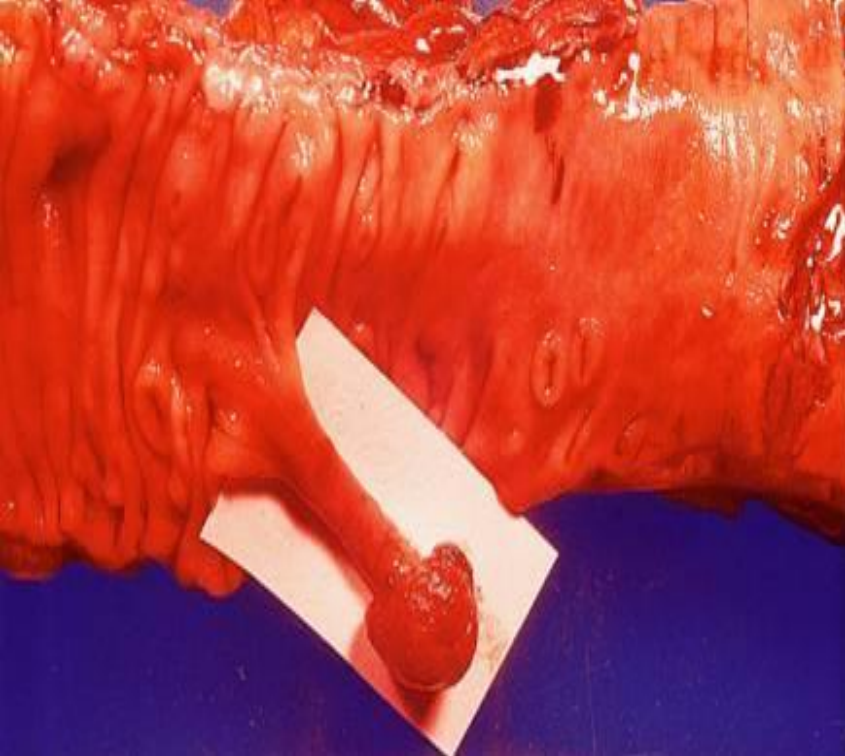
**Mucocele of the appendix.**



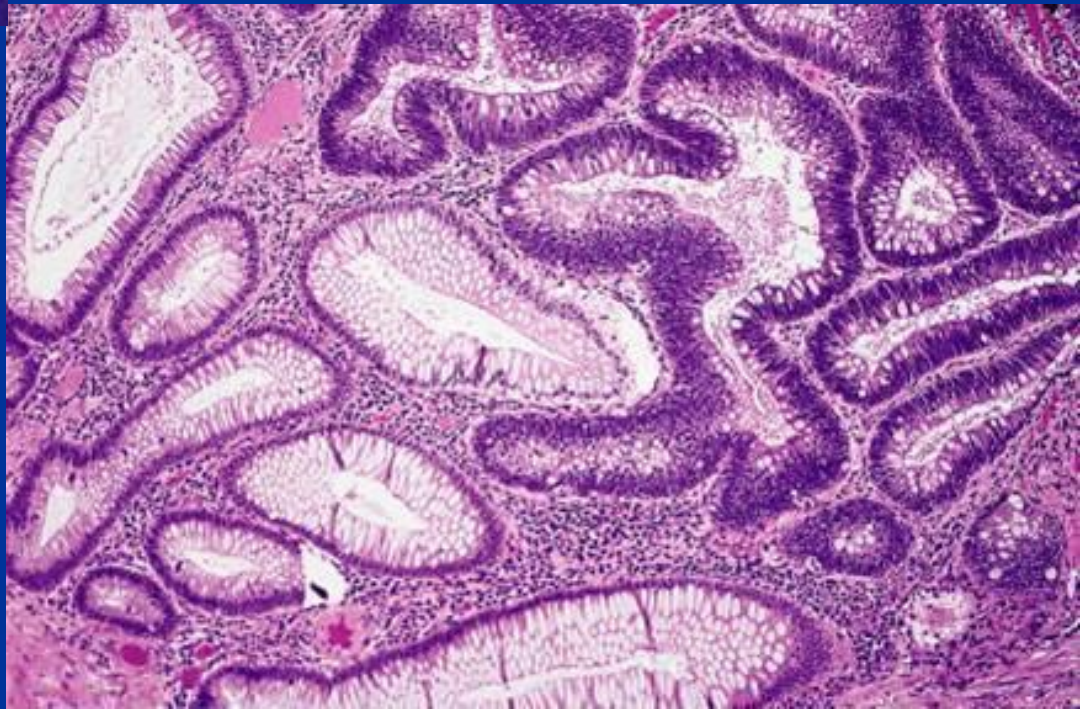


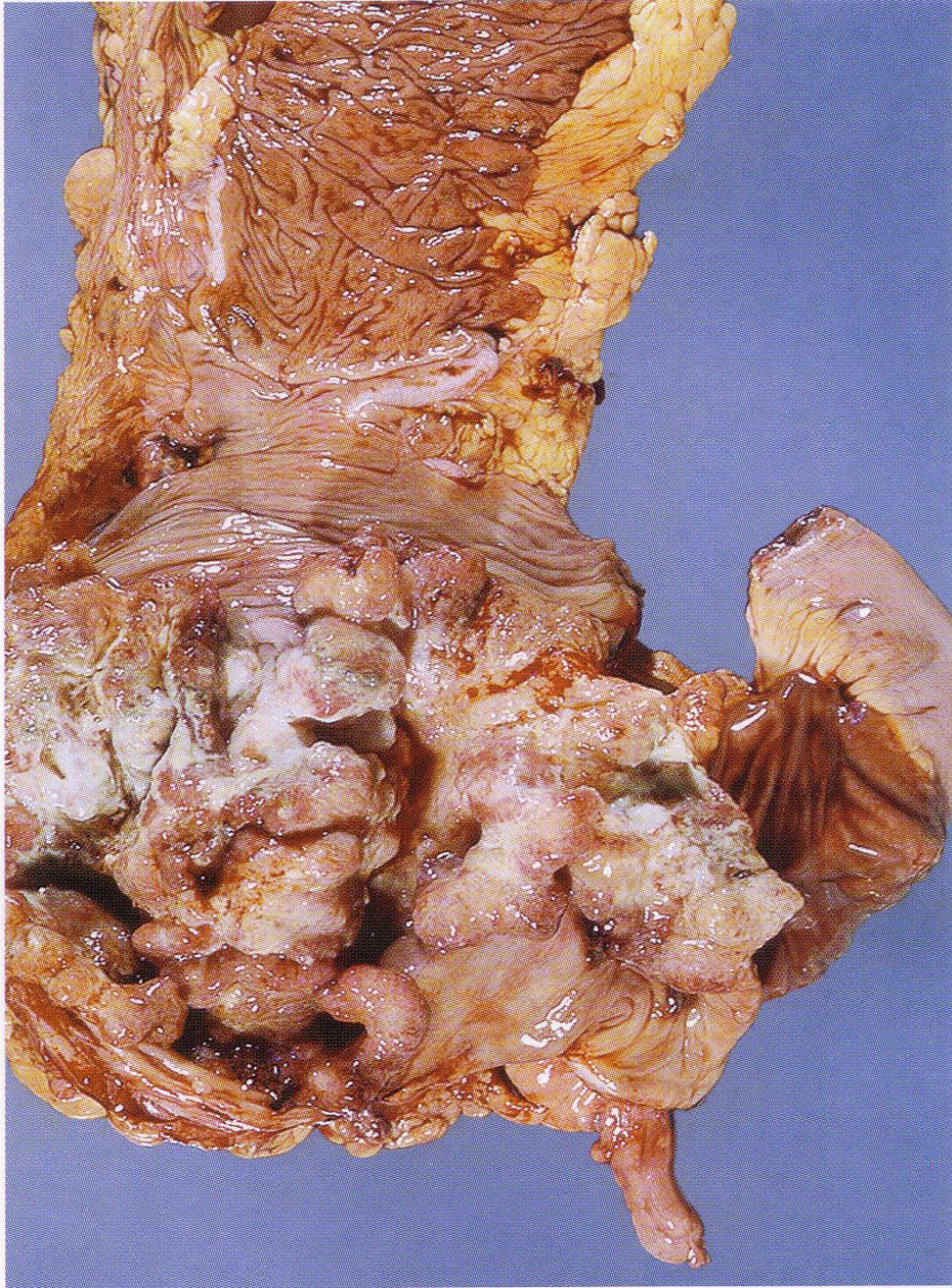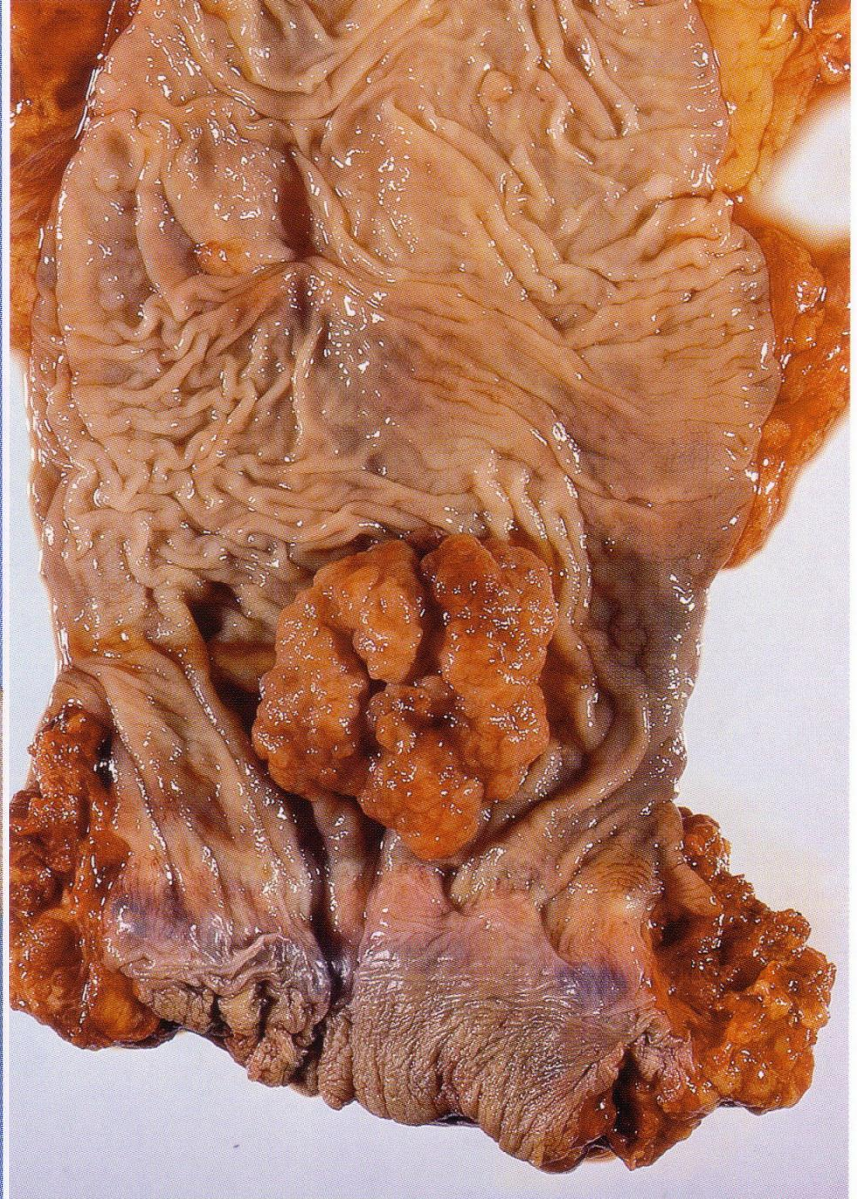
**Appendicular carcinoid.**





**Tubulo-villous adenoma of the colon.**





**Carcinoma of the cecum  
and rectum**

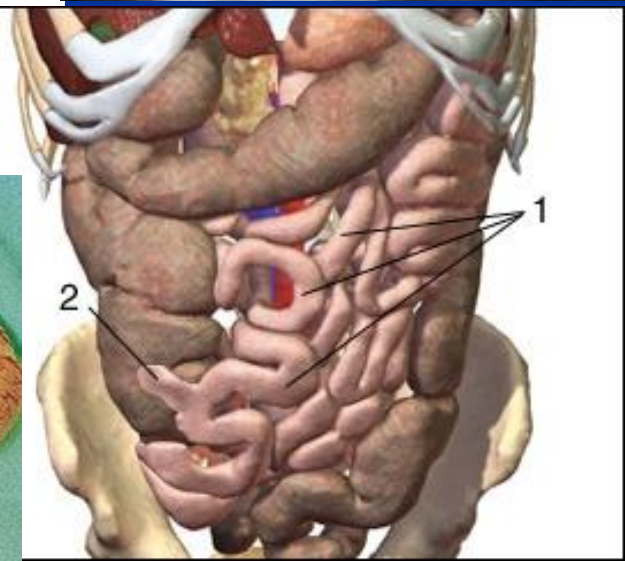
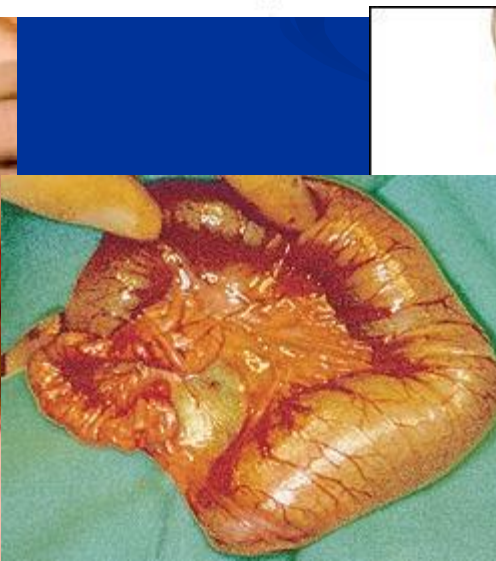
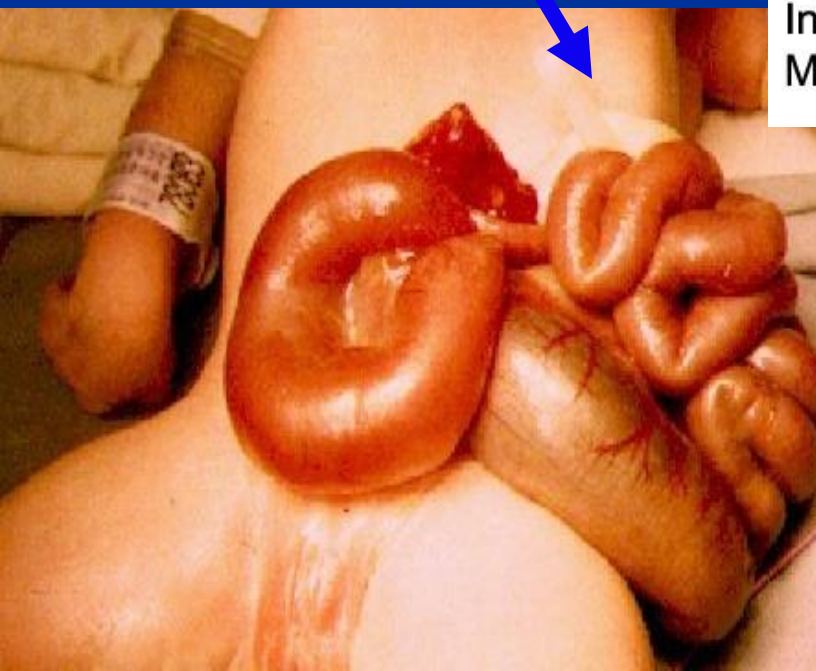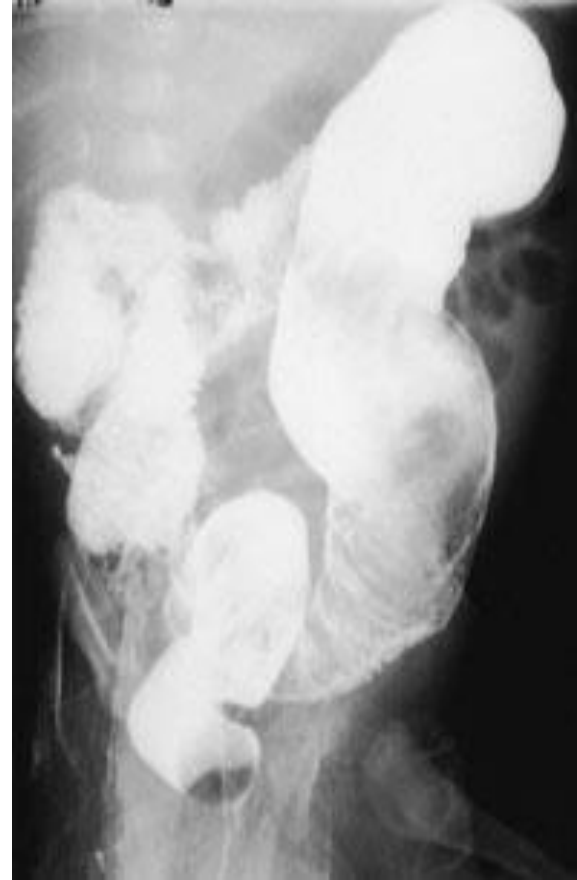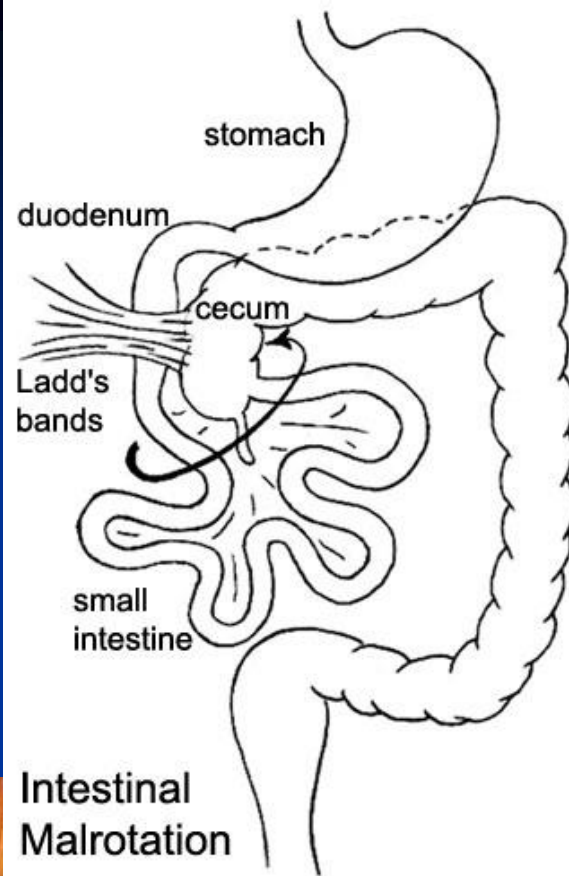
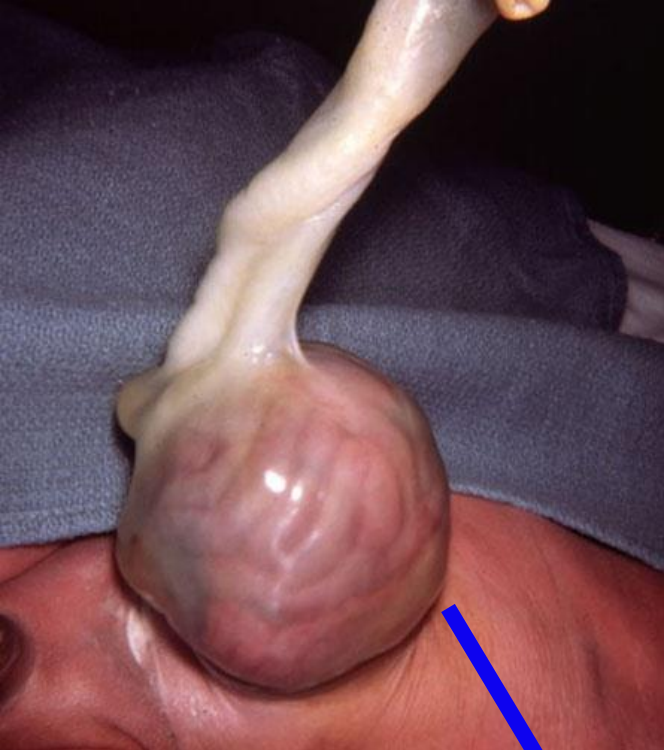# SMALL/LARGE INTESTINE

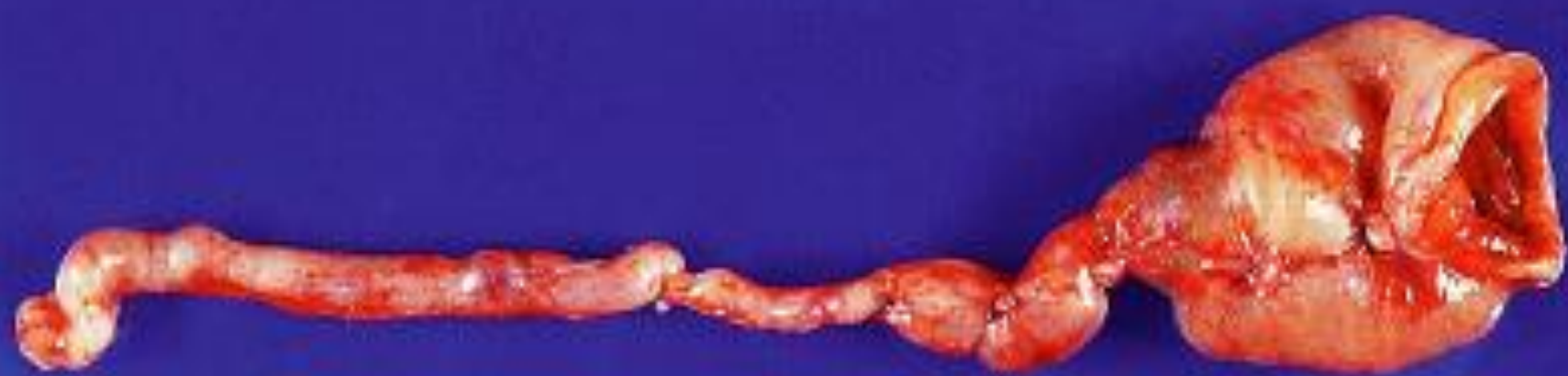- **NORMAL:** Anat., Vasc., Mucosa, Endocr., Immune, Neuromuscular.
- **PATHOLOGY:**
  - CONGENITAL
  - ENTEROCOLITIS: DIARRHEA, INFECTIOUS, OTHER
  - MALABSORPTION: INTRALUMINAL, CELL SURFACE, INTRACELL.
  - (I)IBD: CROHN DISEASE and ULCERATIVE COLITIS
  - VASCULAR: ISCHEMIC, ANGIODYSPLASIA, HEMORRHAGIC
  - DIVERTICULOSIS/-ITIS
  - OBSTRUCTION: MECHANICAL, PARALYTIC (ILEUS) (PSEUDO)
  - TUMORS: BENIGN, MALIGNANT, EPITHELIAL, STROMAL

# CONGENITAL

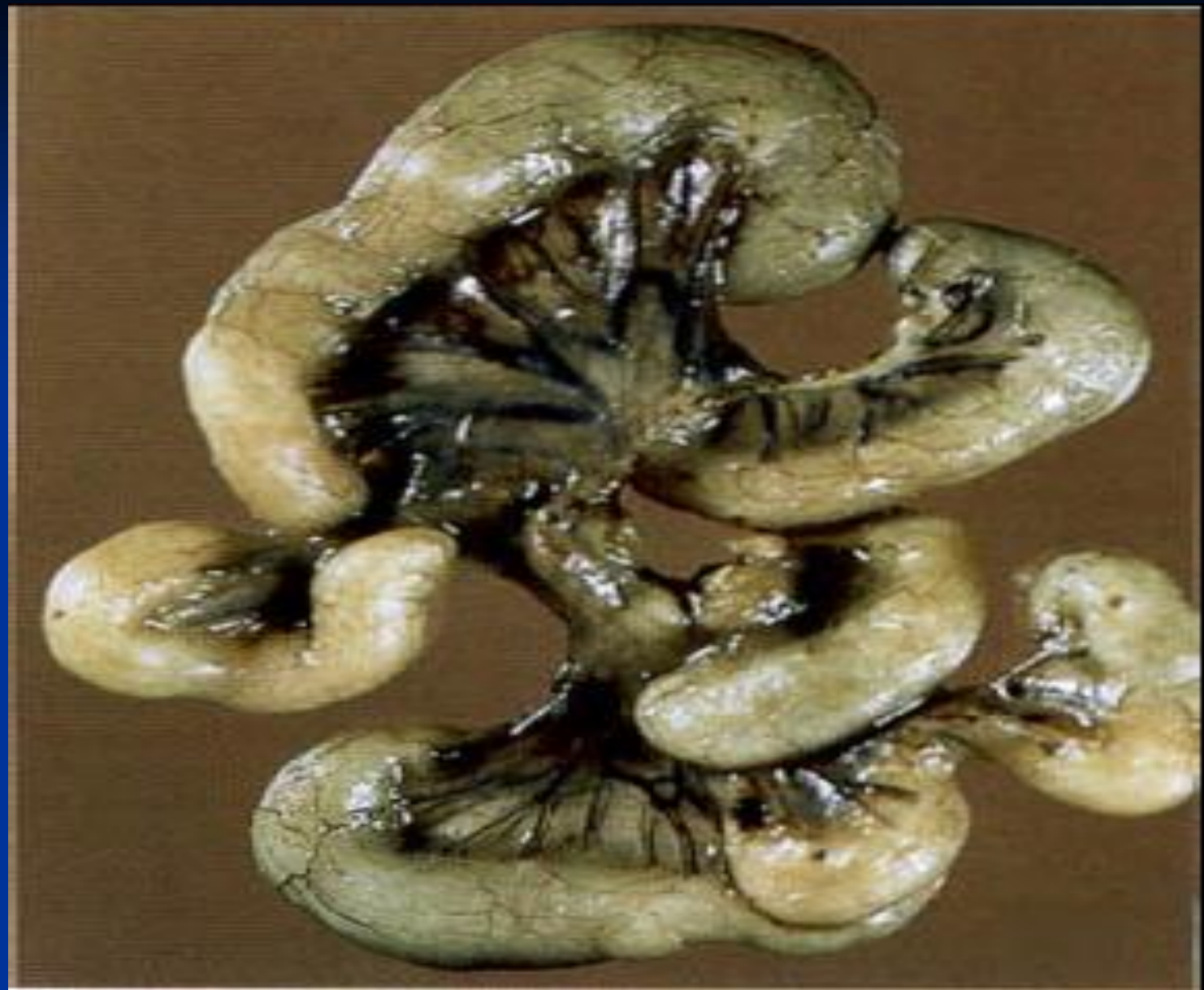- **DUPLICATION**
- **MALROTATION**
- **OMPHALOCELE**
- **ATRESIA/STENOSIS SPECTRUM**
- **MECKEL (terminal ileum, “vitelline” duct)**
- **AGANGLIONIC MEGACOLON (HIRSCHSPRUNG DISEASE)**

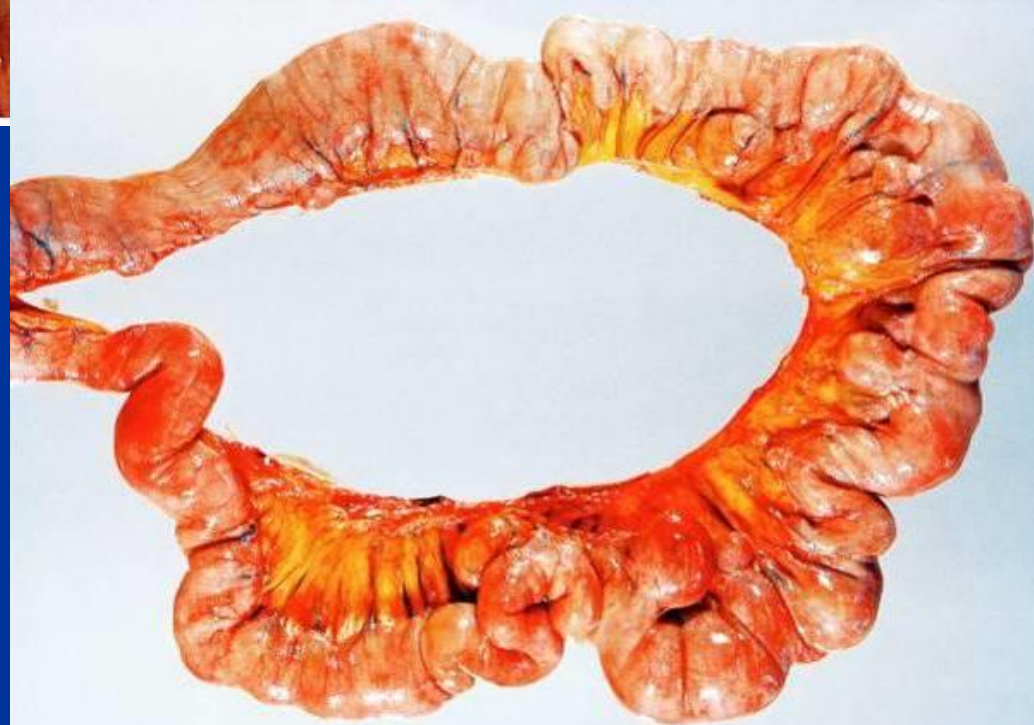
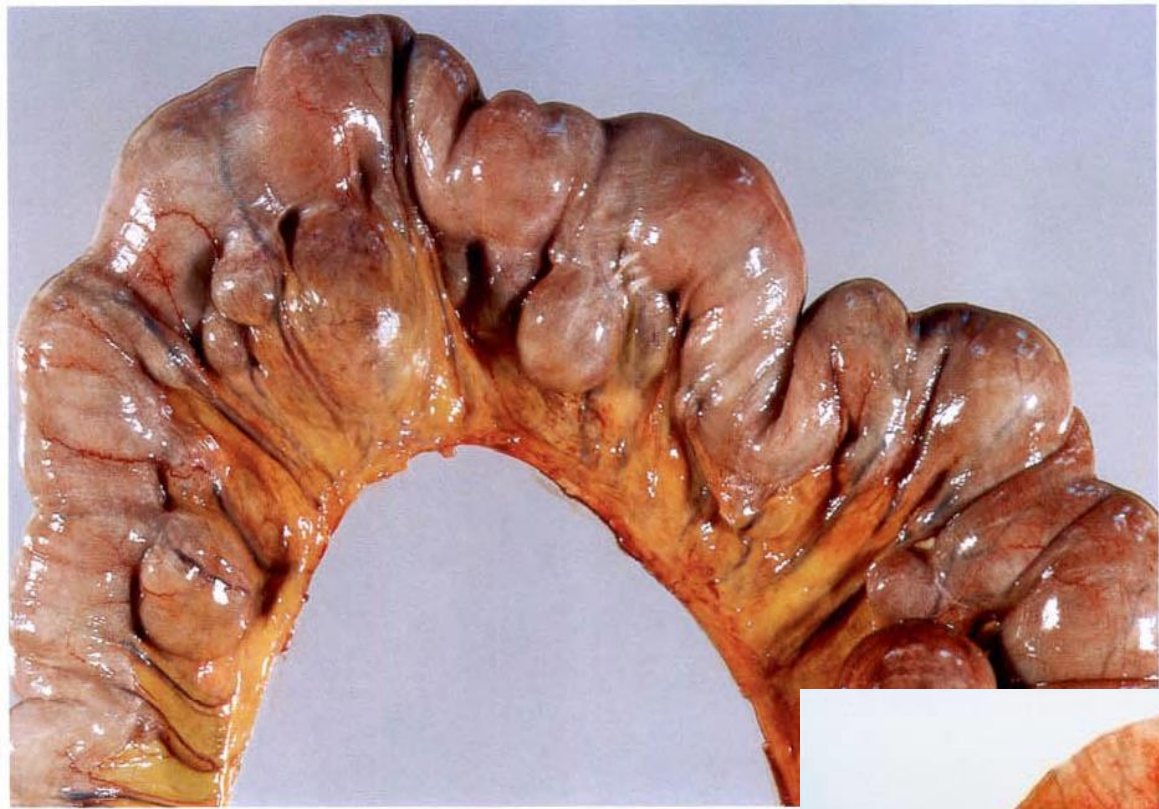
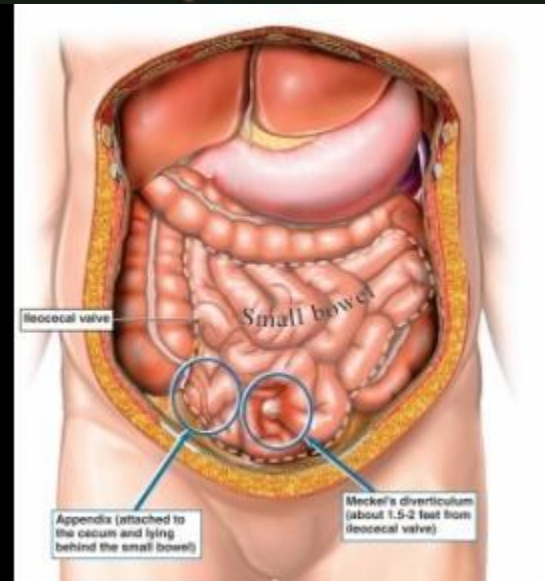
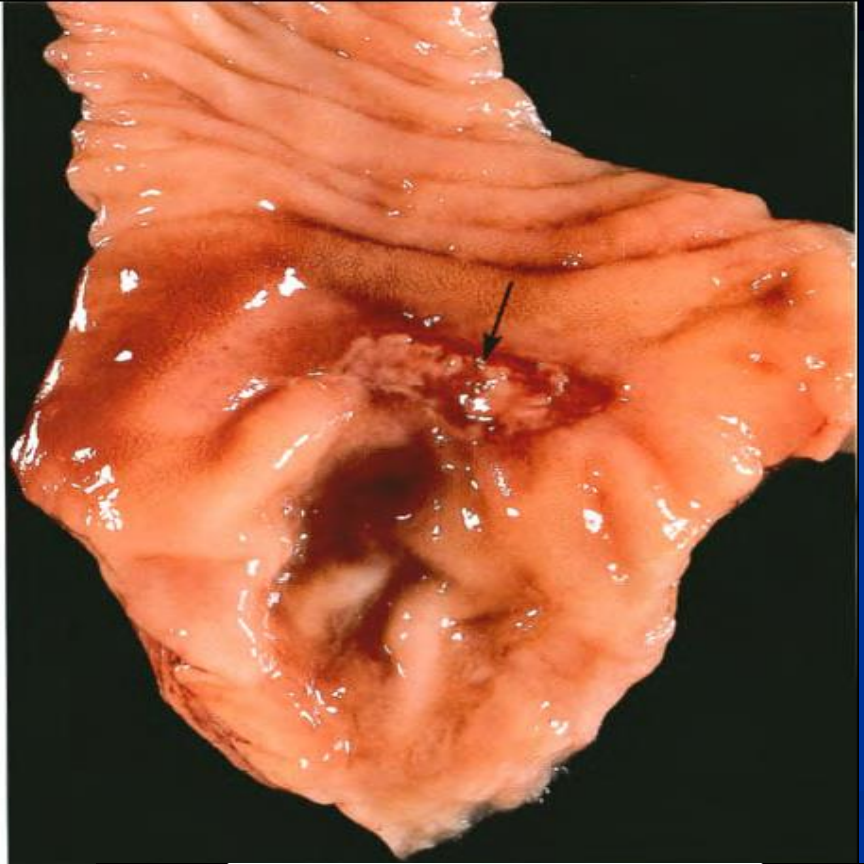


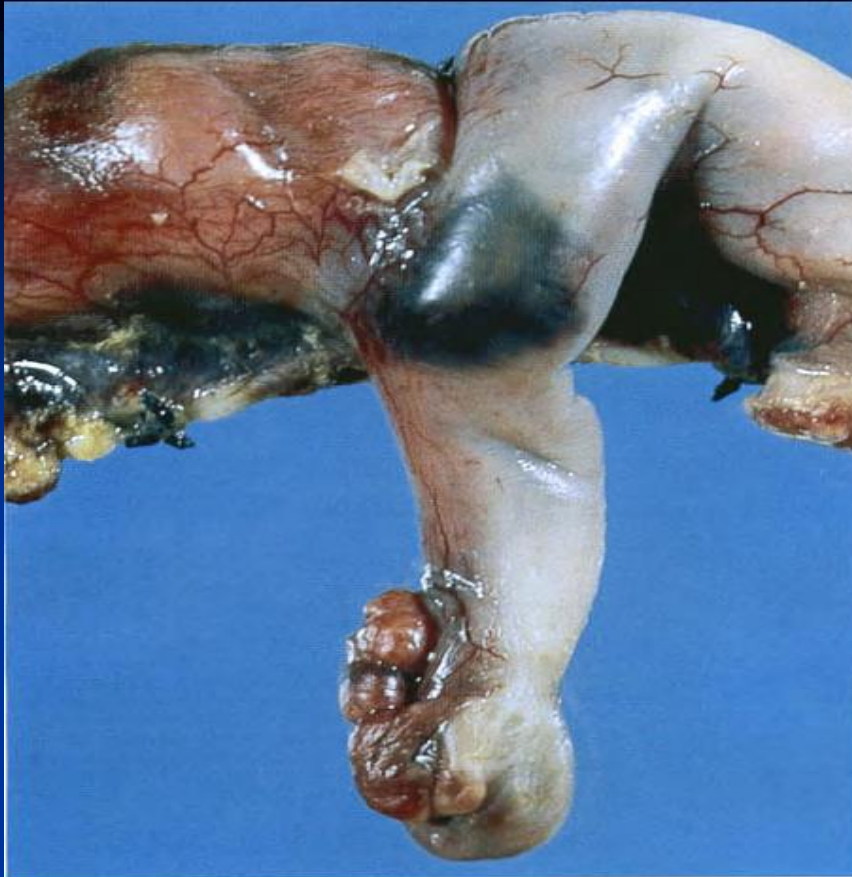

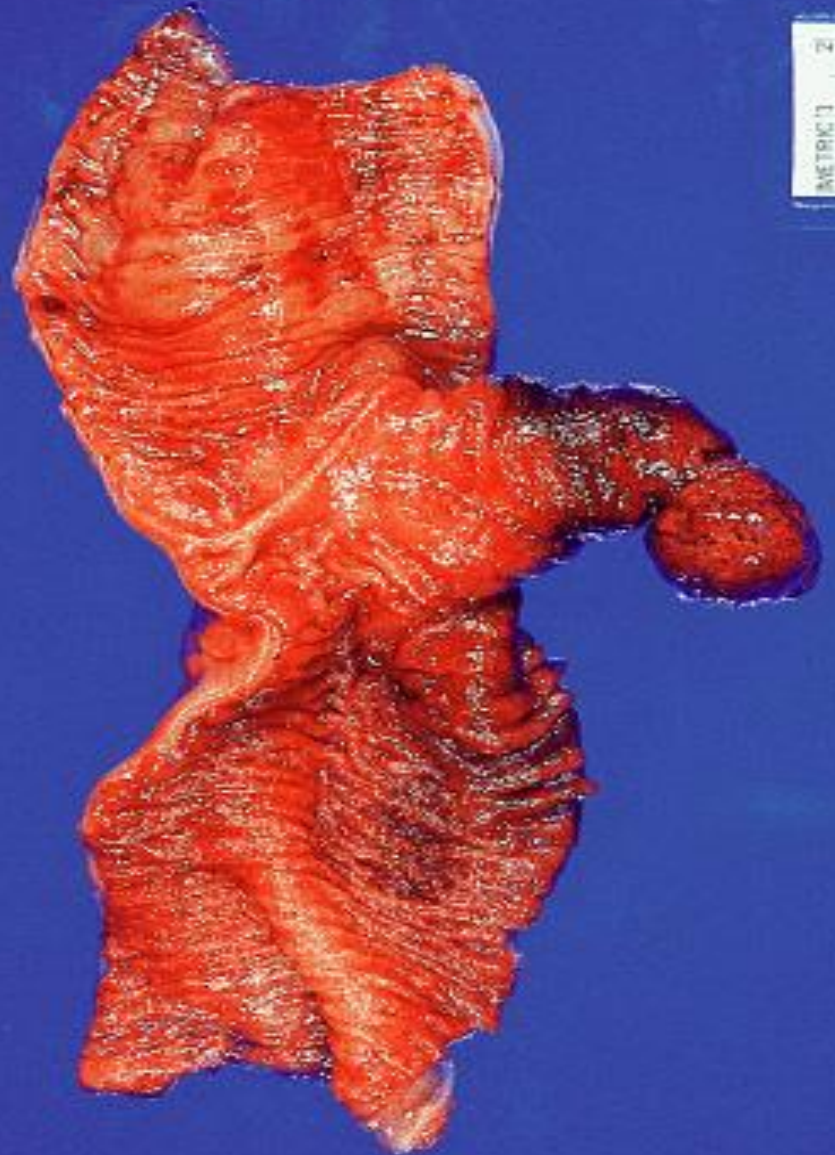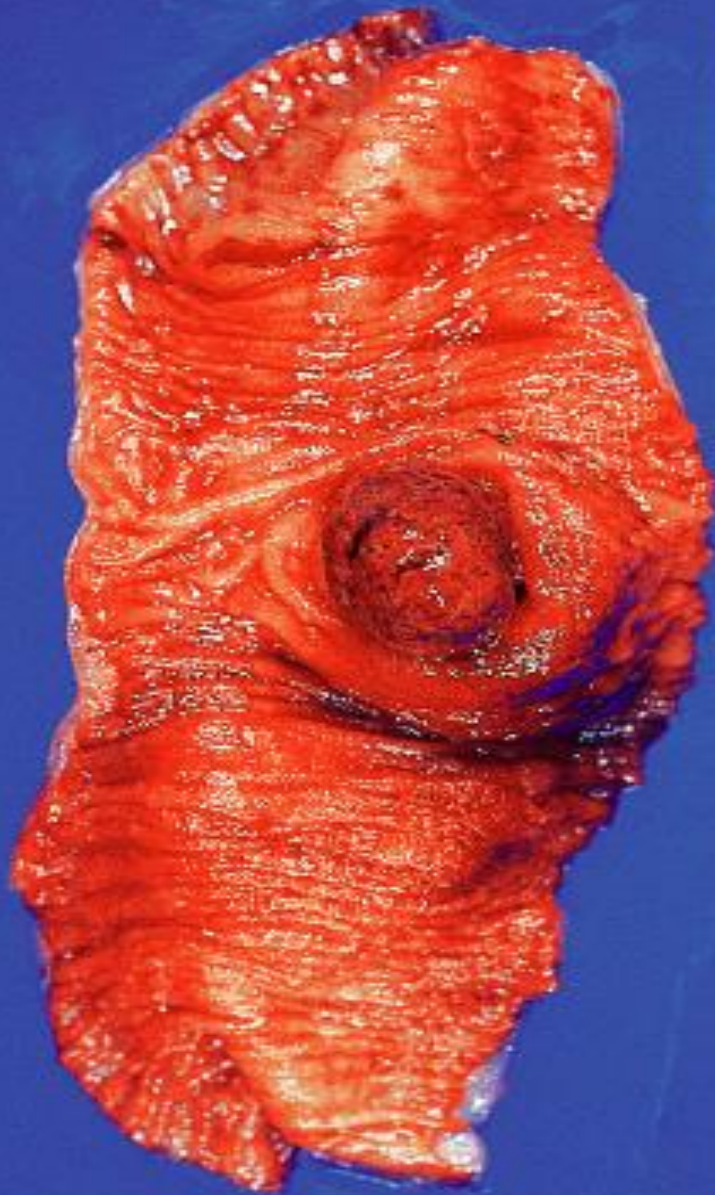© Elsevier Inc 2004 Rosai and Ackerman's Surgical Pathology 9e



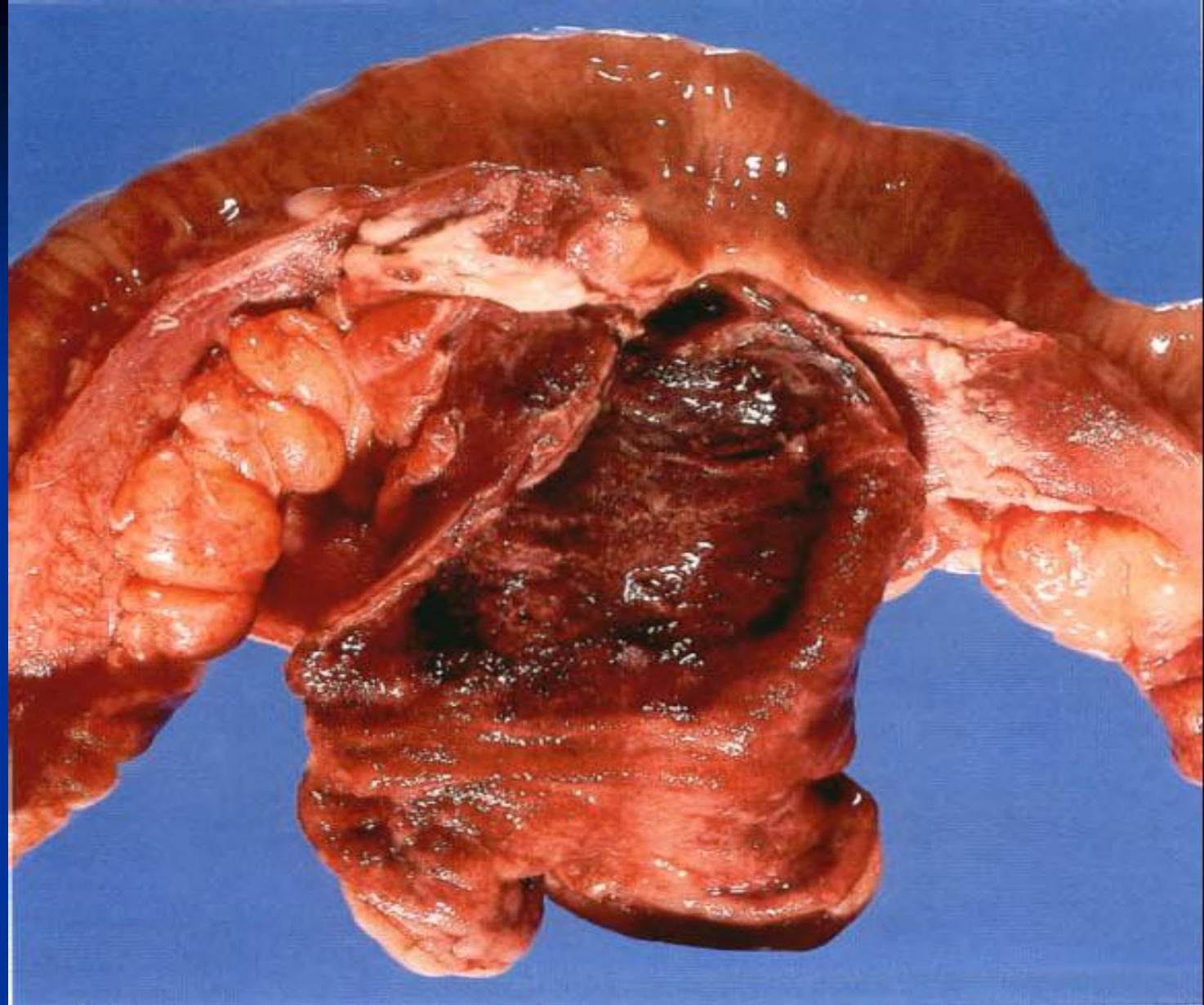


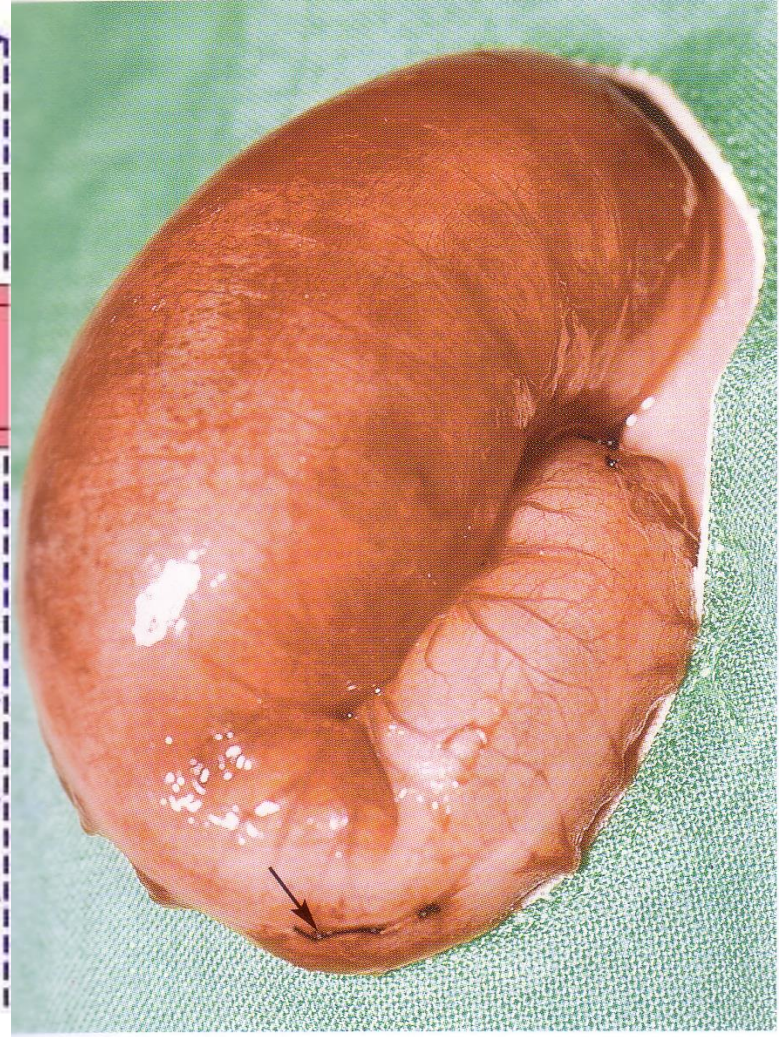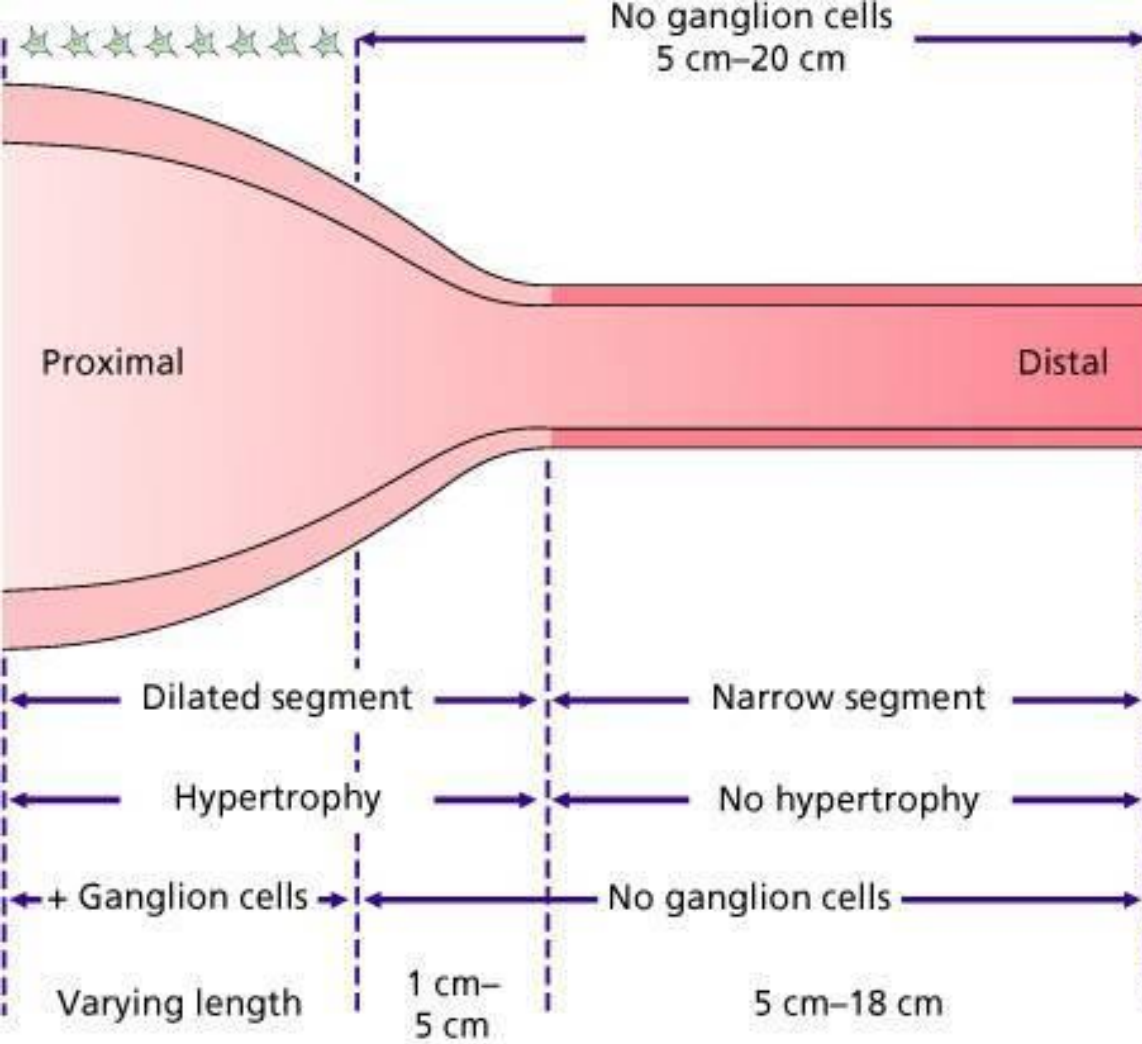




© Elsevier Inc 2004 Rosai and Ackerman's Surgical Pathology 9e

Intussusception of Meckel's diverticulum







# Enterocolitis

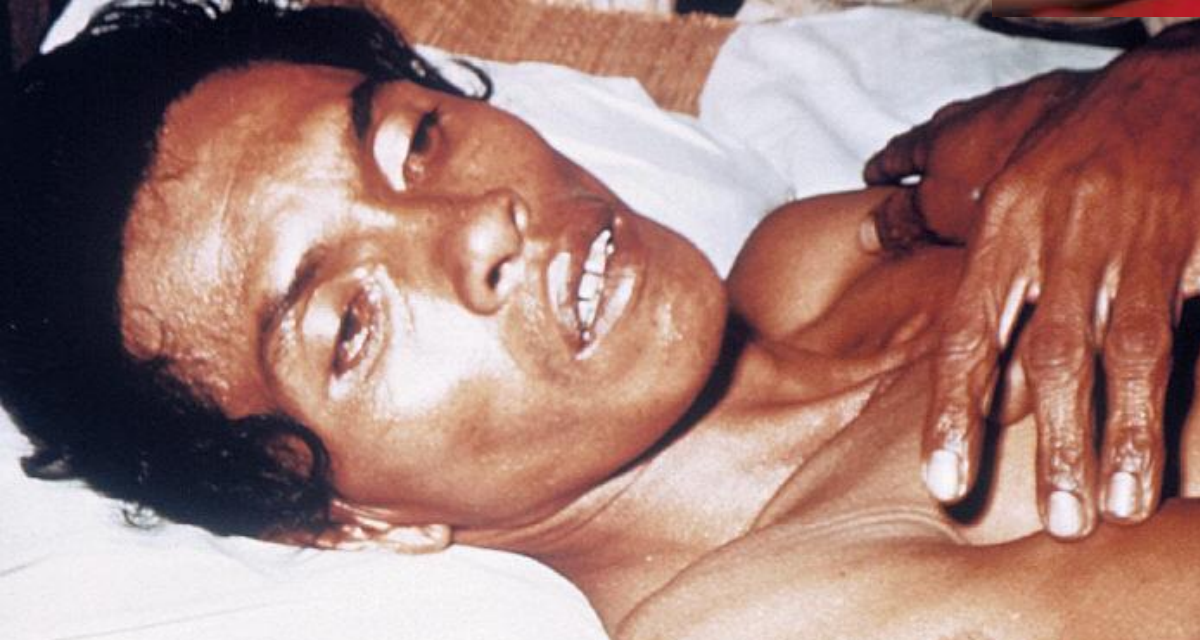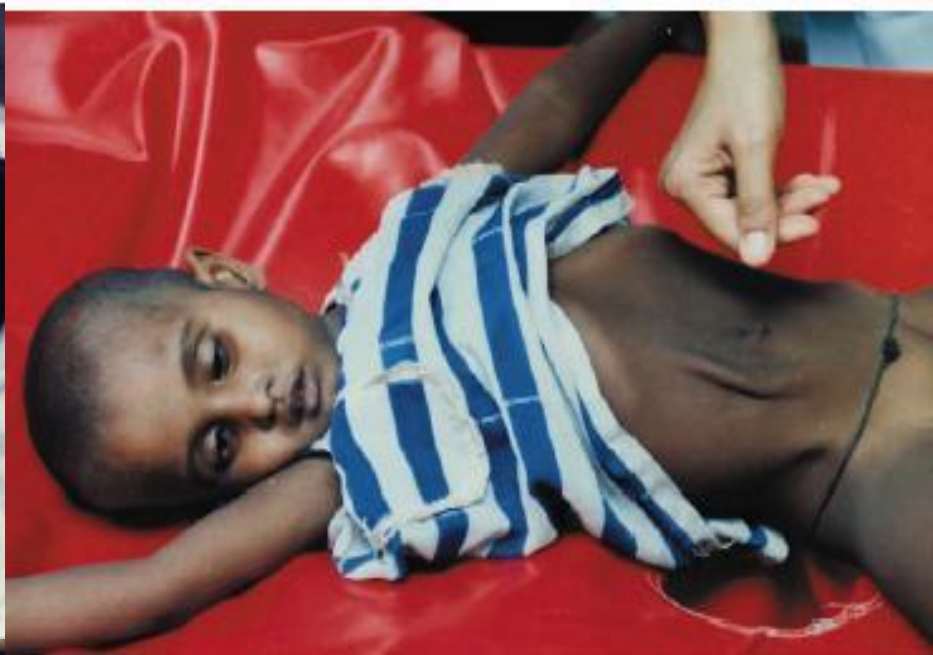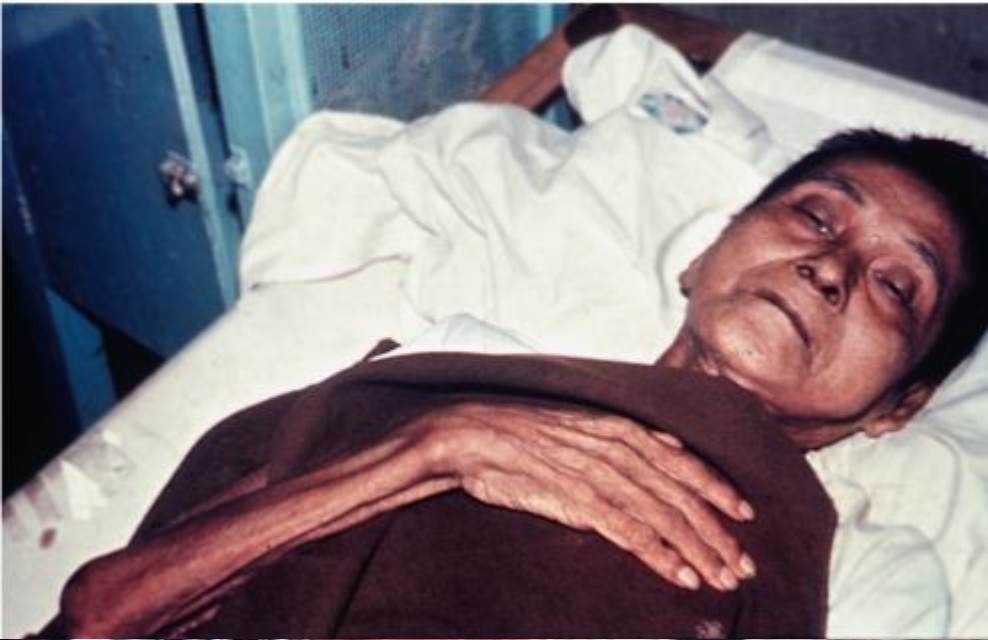- *Inflammation of the mucus membrane of small and large intestine*
- Infectious enterocolitis
- Drug related
- Radiation enterocolitis
- Ischemic bowel disease
- Lymphocytic colitis

# Infectious enterocolitis

- Viral enterocolitis
  - Rotavirus
  - Immunosuppressed: CMV and adenovirus
- Bacterial enterocolitis
  - Three mechanisms of disease
    1. Ingestion of a preformed toxin in food
      - Staph aureus, vibrios, clostridium perfringens
    2. Infection by non-invasive toxigenic organism
      - E.coli, Vibrios cholerae
    3. Infection by enteroinvasive organism
      - Shigella, salmonella, E.coli, campylobacter, yersinia

# Cholera

- **Vibrio cholerae (V. cholerae) is a gram-negative bacterium the causative agent of cholera. V. cholerae is transmitted primarily through contaminated water.**
- **Despite severe diarrhea, V. cholerae are non-invasive microorganisms that live and multiply in the lumen of the intestine.**
- **Vibrio cholera toxin causes a disease. The infection is enteric and usually occurs when drinking infected water. The incubation period lasts 3-5 days. "Alkalophilous" vibrios find the optimal environment in the small intestine. Here they multiply and secrete exotoxin (cholero-gen).**
- **Under the influence of exotoxin, the epithelium of the mucous membrane secretes a large amount of isotonic fluid. Abundant secretion of fluid occurs as a result of the interaction of cholero-gen with the enzyme systems of the cell; at the same time, the blockade of the "sodium pump" of the cell is important, which violates the reverse absorption of fluid from the intestinal lumen. Profuse diarrhea is associated with abundant secretion of fluid and a violation of its reverse absorption.**



A person with severe dehydration due to cholera - note the **sunken eyes** and decreased **skin turgor** which produces **wrinkled hands** and skin

## Cholera

# Shigellosis

- **Shigella (Shigella spp.)** Are gram-negative bacteria that were first isolated during the epidemic of red (bloody) diarrhea in Japan in 1897 (in Russia, the infection caused by shigella is called dysentery).
- Man is the only known reservoir of this microorganism. It has been established that 165 million new cases of shigellosis are recorded annually in the world.
- The infectious dose for Shigella is not more than a few hundred microorganisms, and 1 milliliter of feces in the acute period of the disease contains 10 millions microorganisms. As a result, shigella are quickly transmitted to humans by fecal-oral route or through contaminated water and products.

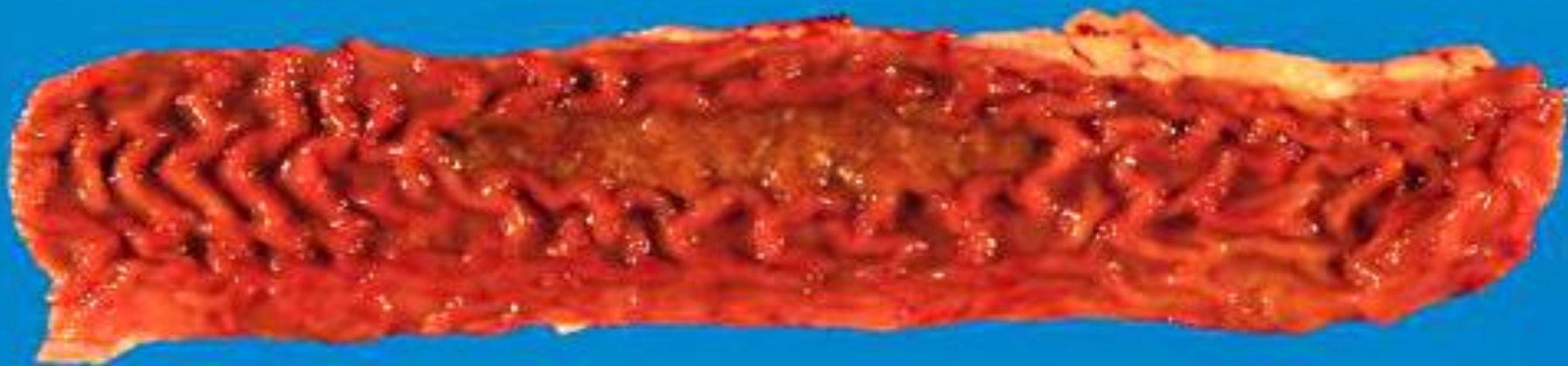# Typhoid fever

- Typhoid fever is an acute infectious disease from the intestinal group; typical anthroponosis. Caused by typhoid bacillus (*Salmonella typhi*).
- The source of infection is a sick person or a carrier, in the secretions of which (feces, urine, sweat) contains microbes. Infection occurs parenterally.
- The incubation period is 10-14 days. In the lower part of the small intestine, bacteria multiply, secrete endotoxins. From the intestine through the lymphatic paths, they enter the group lymphatic follicles (the so-called Peyer's patches) and solitary follicles, and then to the regional lymph nodes.
- Having overcome the lymphatic barrier, the pathogen enters the bloodstream. Bacteremia develops, which is especially pronounced during the 1st week of illness, when typhoid bacillus can be isolated from the blood (blood culture).

# Typhoid fever



# Typhoid fever





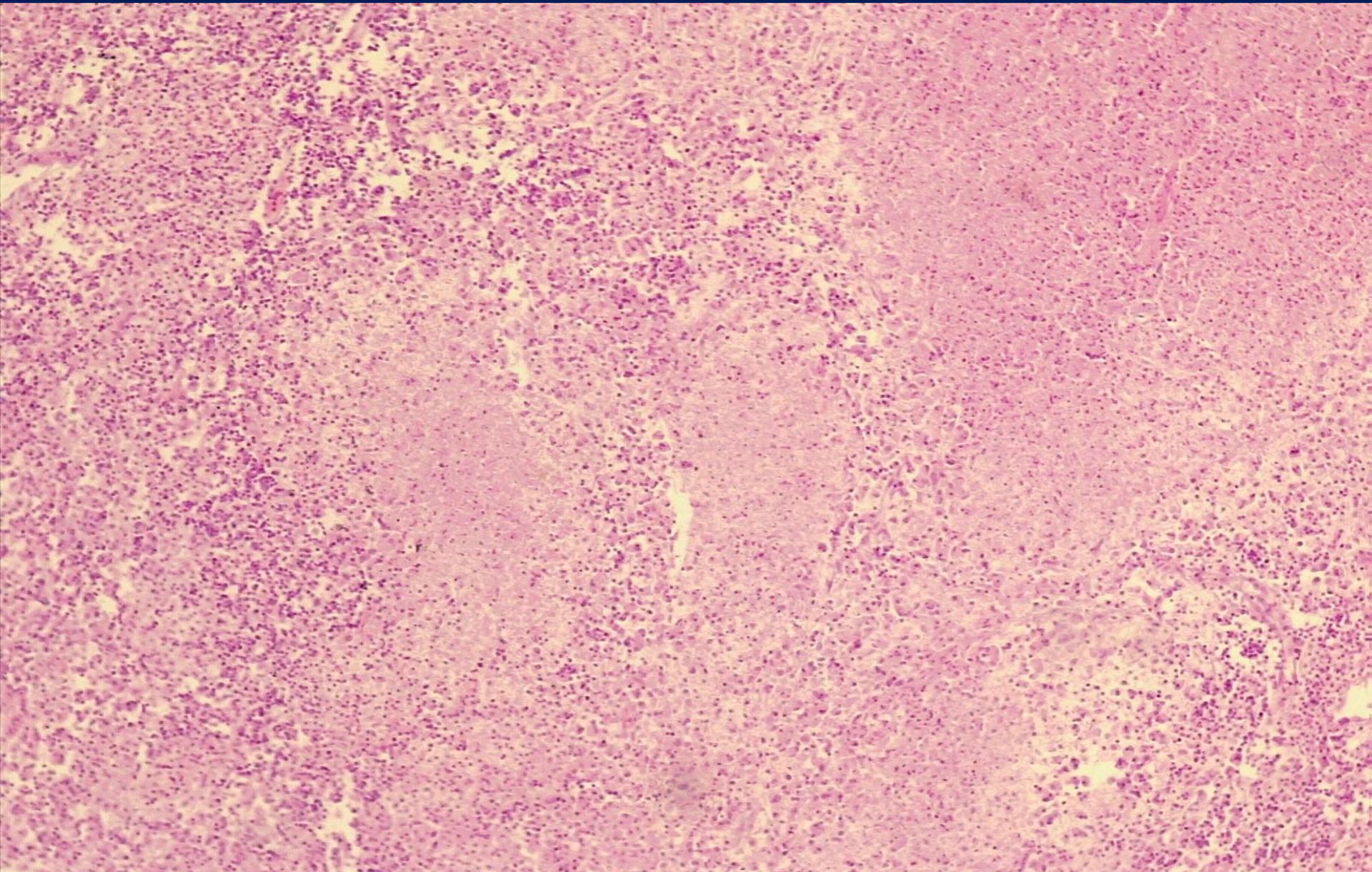
# Typhoid fever



# Typhoid fever



The stage of ulcer healing ends with the formation of tender scars in their place; the lymphoid tissue of the intestine is partially or completely restored, it becomes only slightly pigmented.

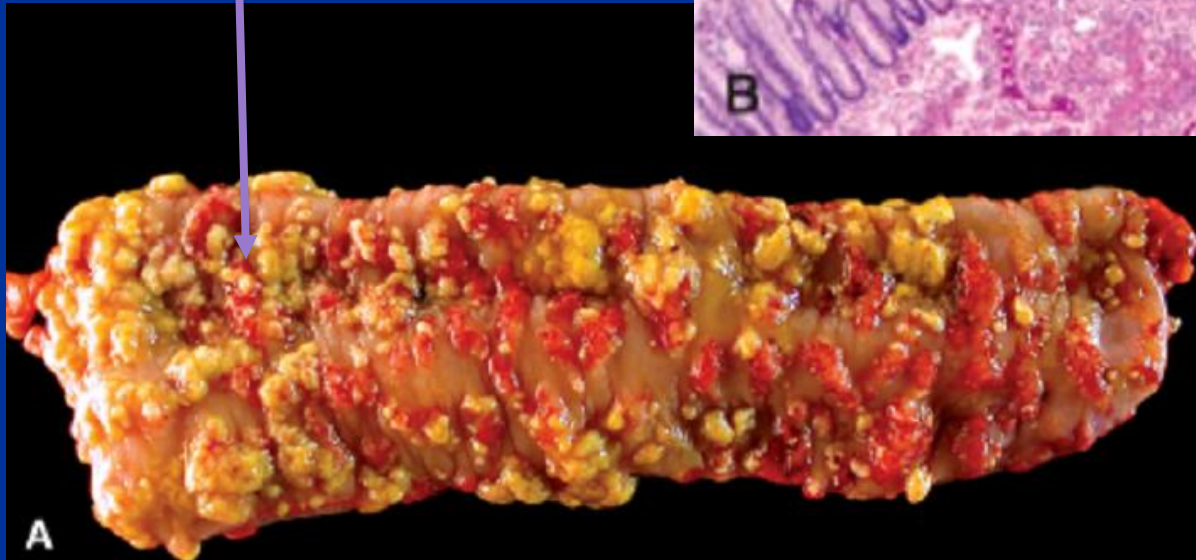
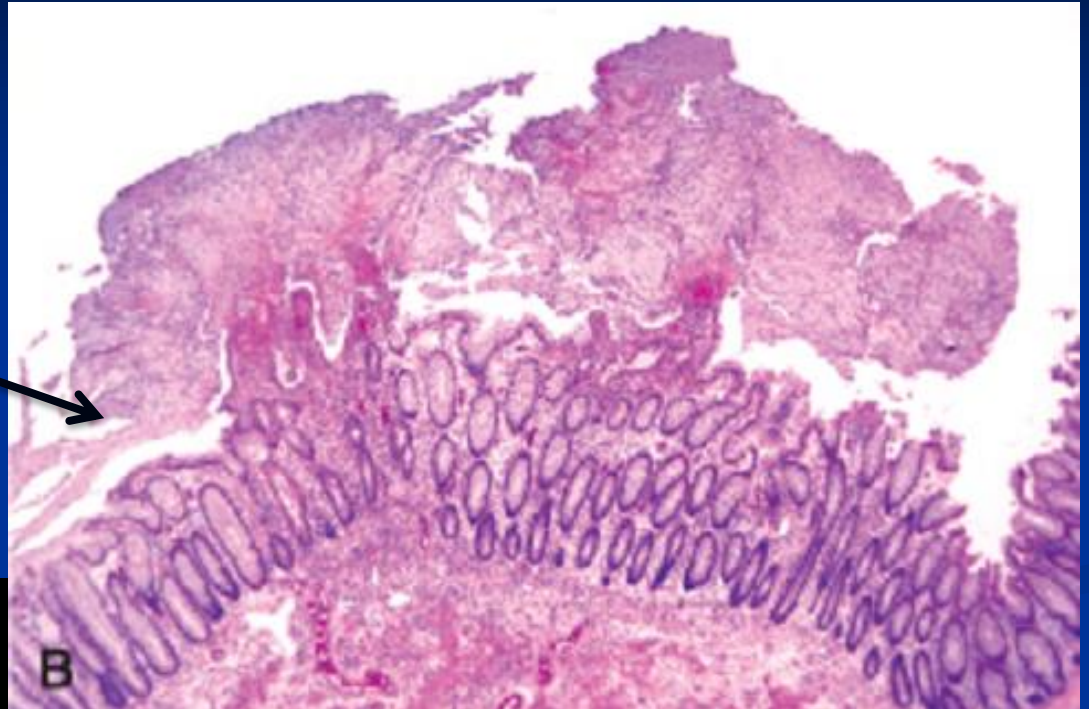


# Infectious enterocolitis

- Pseudomembranous colitis
  - Exudative, fibrin-rich plaques (pseudomembrane) overlying sites of mucosal injury
  - Most associated antibiotic therapy
  - *Clostridium difficile*
    - Enterotoxin
    - Cytotoxin
  - Other - ischemia, anti-neoplastic drugs
- Parasitic
  - Amebiasis - *Entamoeba histolytic*
  - Giardiasis - *Giardia lamblia*
  - Cryptosporidiosis - *Cryptosporidium*
- Fungal
  - Candida

# Pseudomembranous Colitis

Pseudomembrane



# Non-infectious Colitis

- **Drugs**
- **Radiation enterocolitis**
- **Ischemic Bowel Disease**
  - **Occlusive etiology**
  - **Non-Occlusive**
- **Collagenous colitis**
- **Lymphocytic colitis**

# **Idiopathic Inflammatory Bowel Disease** (IBD)

- *Chronic, relapsing inflammatory disorders of unknown origin*
- **Crohn's Disease**
- **Ulcerative colitis**

# Crohn's vs UC

## • Crohn's Disease

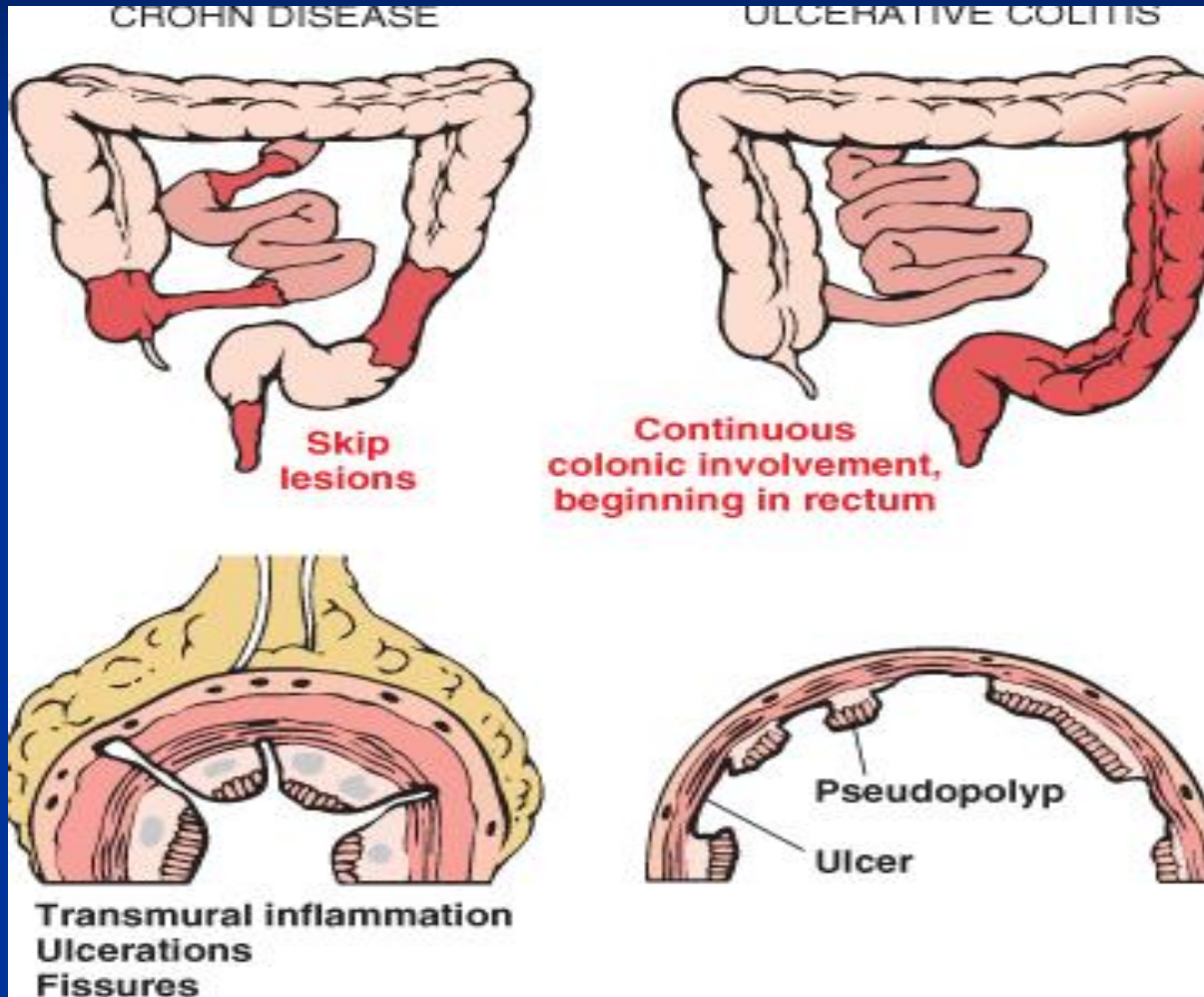
- Any part of GI tract
- Skip lesions
- Rectum spared
- Transmural inflammation
  - Fissures
  - Fistulas
- Strictures
- Granulomas
- Small increased risk CA
- Crypt abscess

## • Ulcerative Colitis

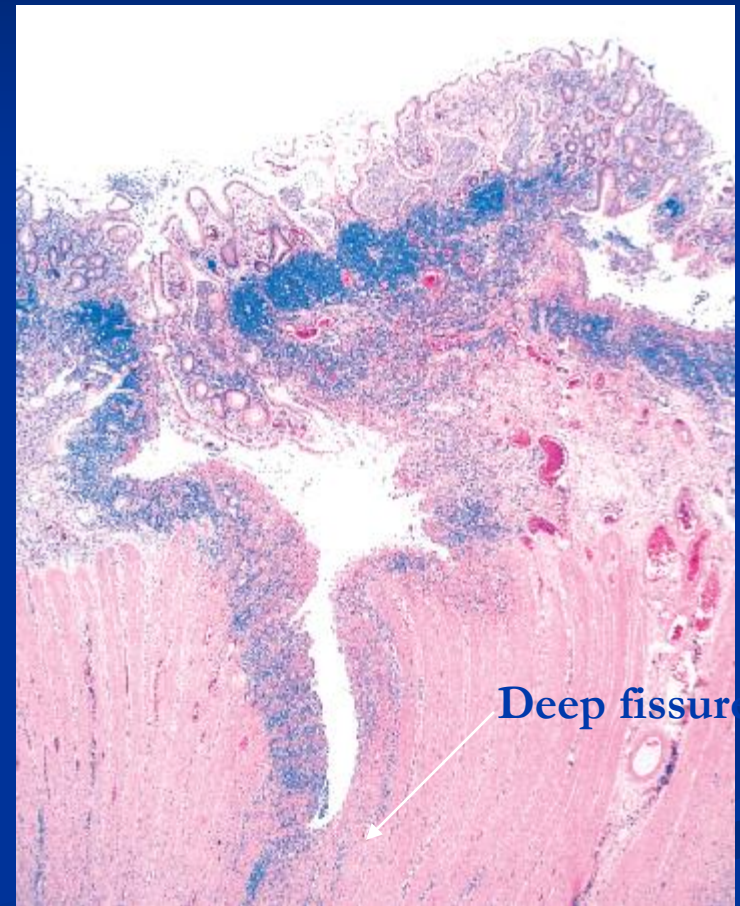
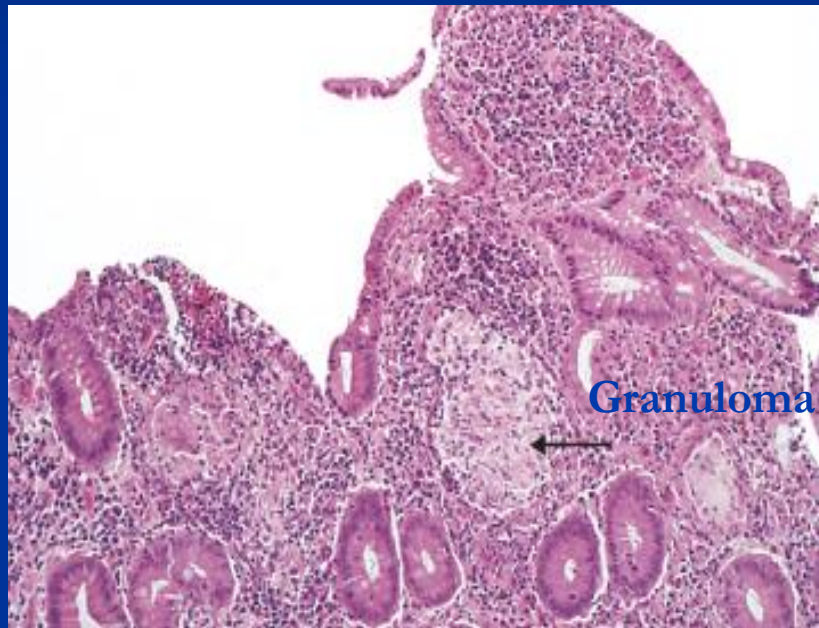
- Colon only
- Continuous
- Rectum always involved
- Mucosal inflammation
  - No fissures
  - No fistulas
- Strictures rare
- No granulomas
- > 10 % for 25 yr hx
- Crypt abscess



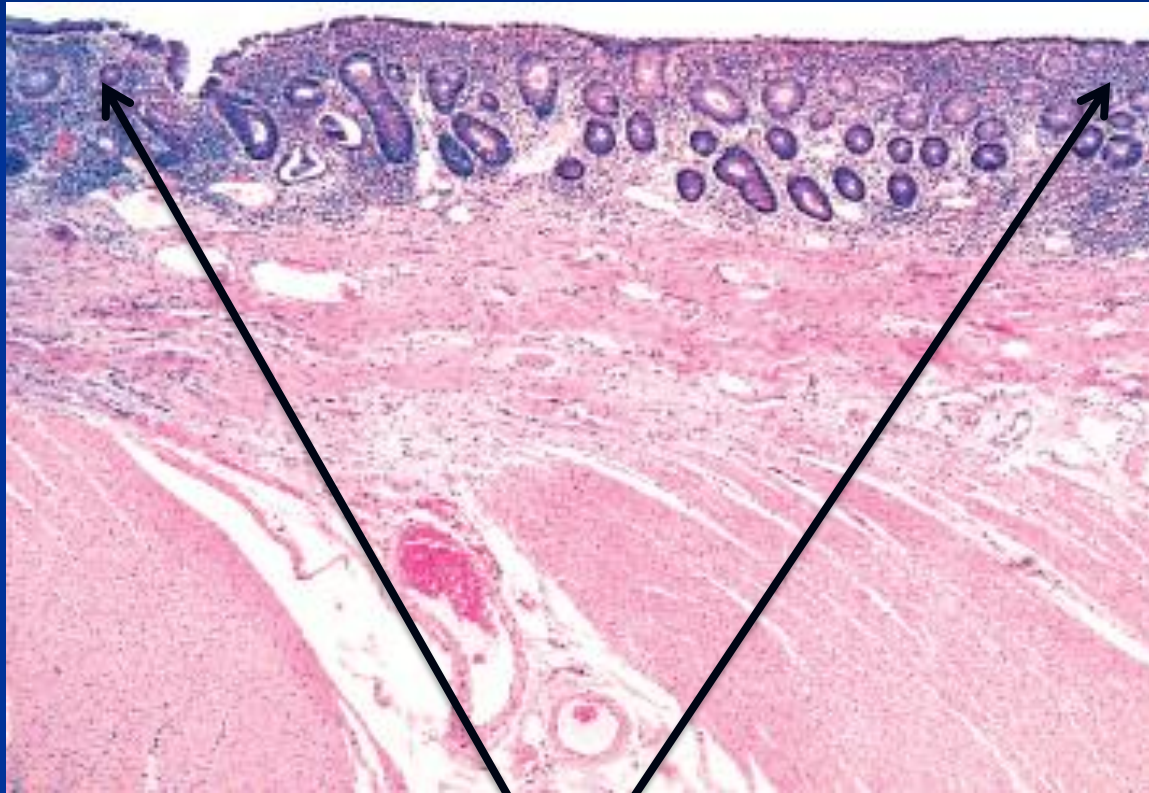
# Crohn's vs UC



# Crohn's Disease

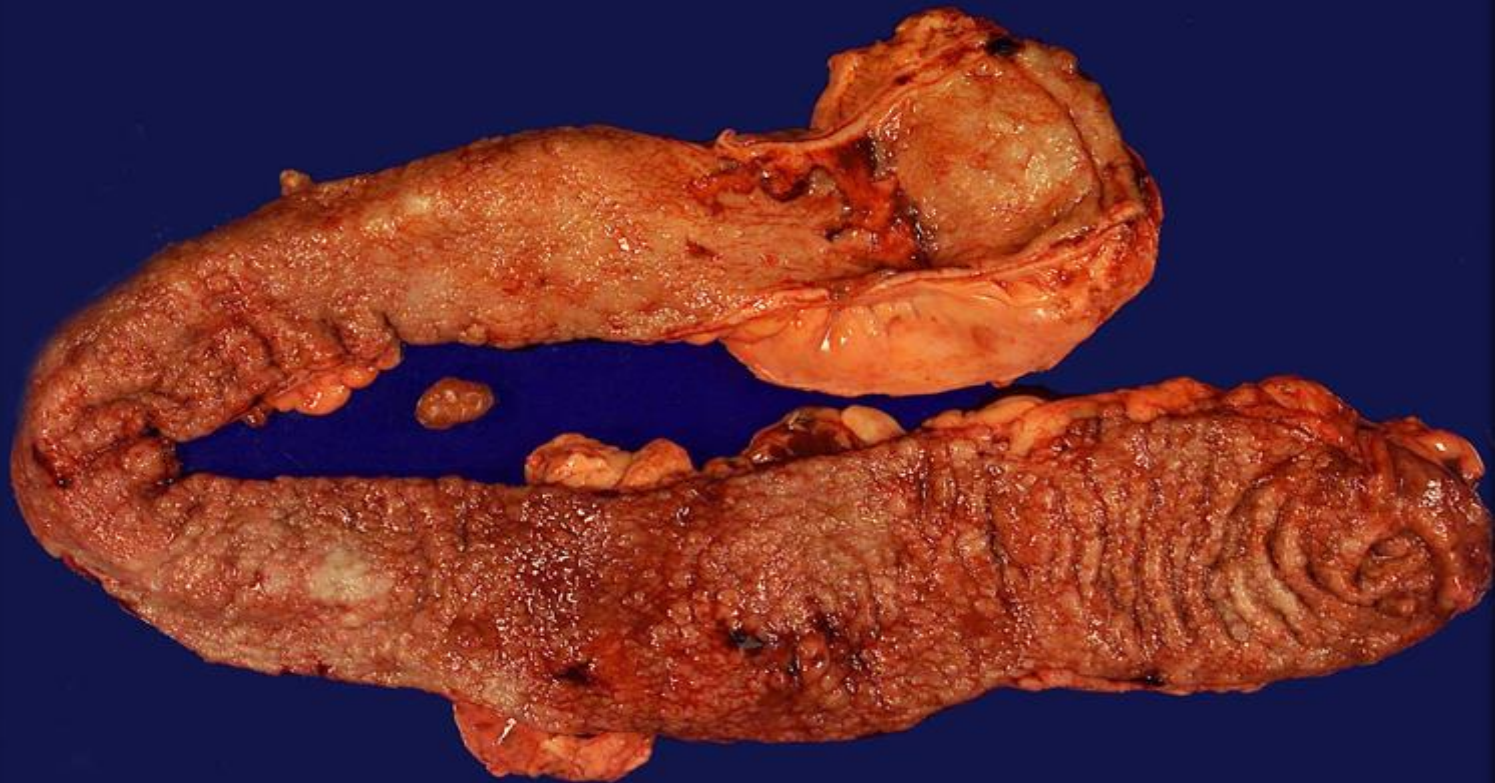


# Ulcerative Colitis

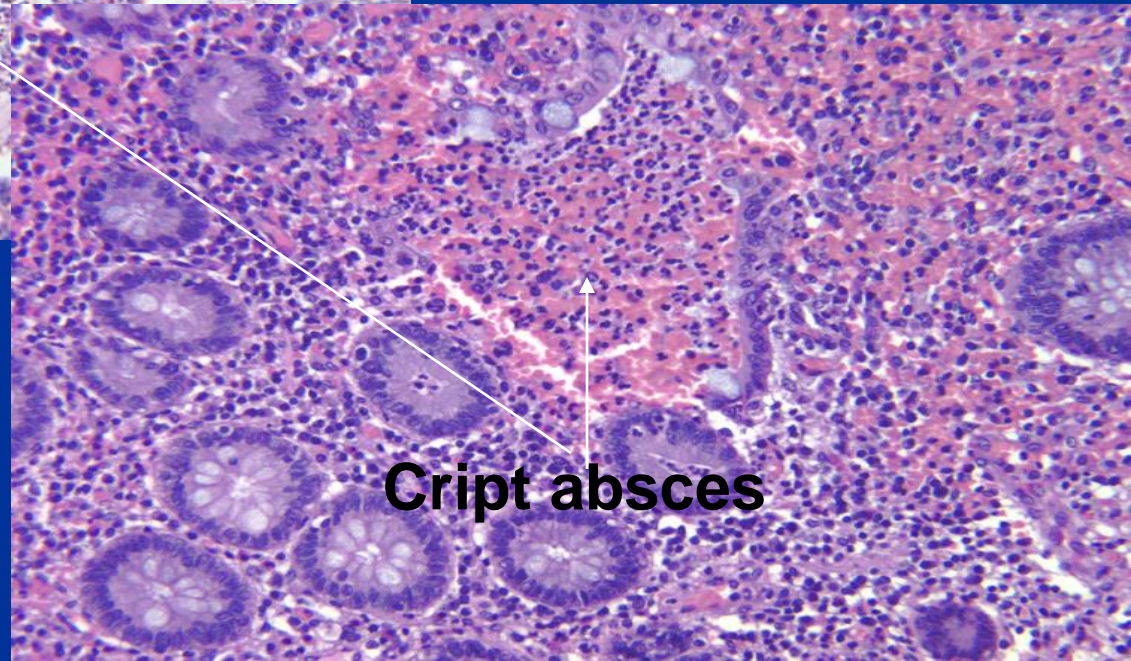
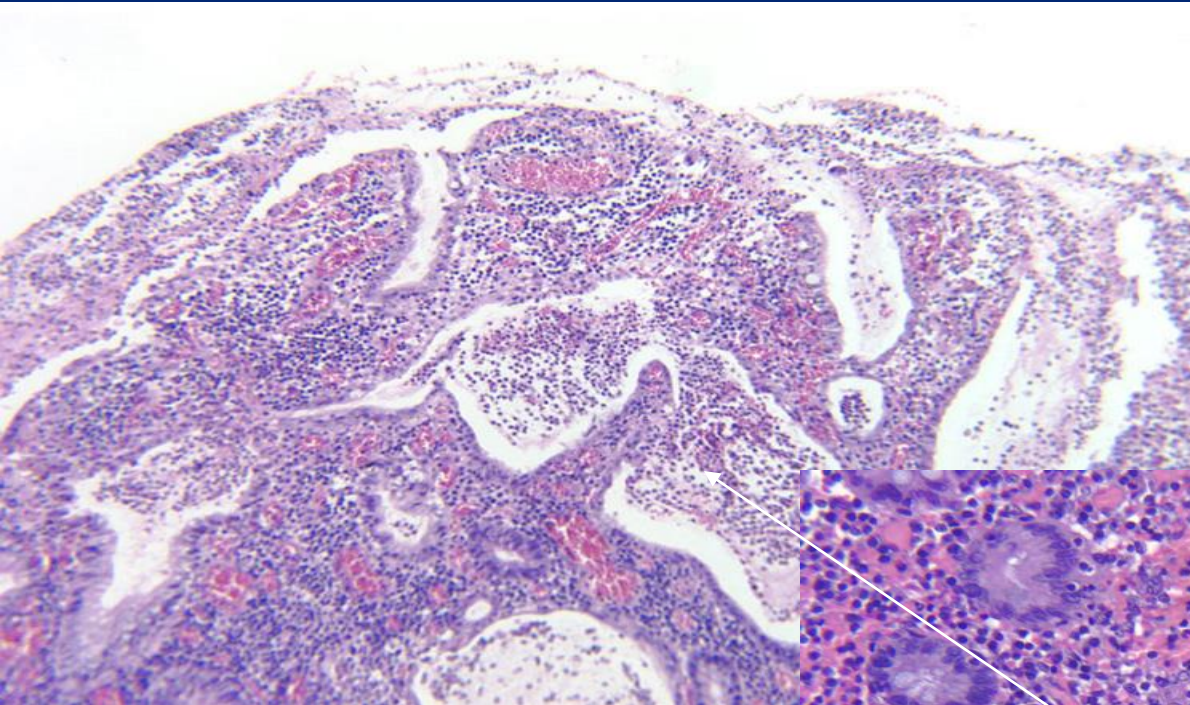


Isolated mucosal inflammation.

**Ulcerative colitis. Continuous involvement starting at rectum and extending proximal.**

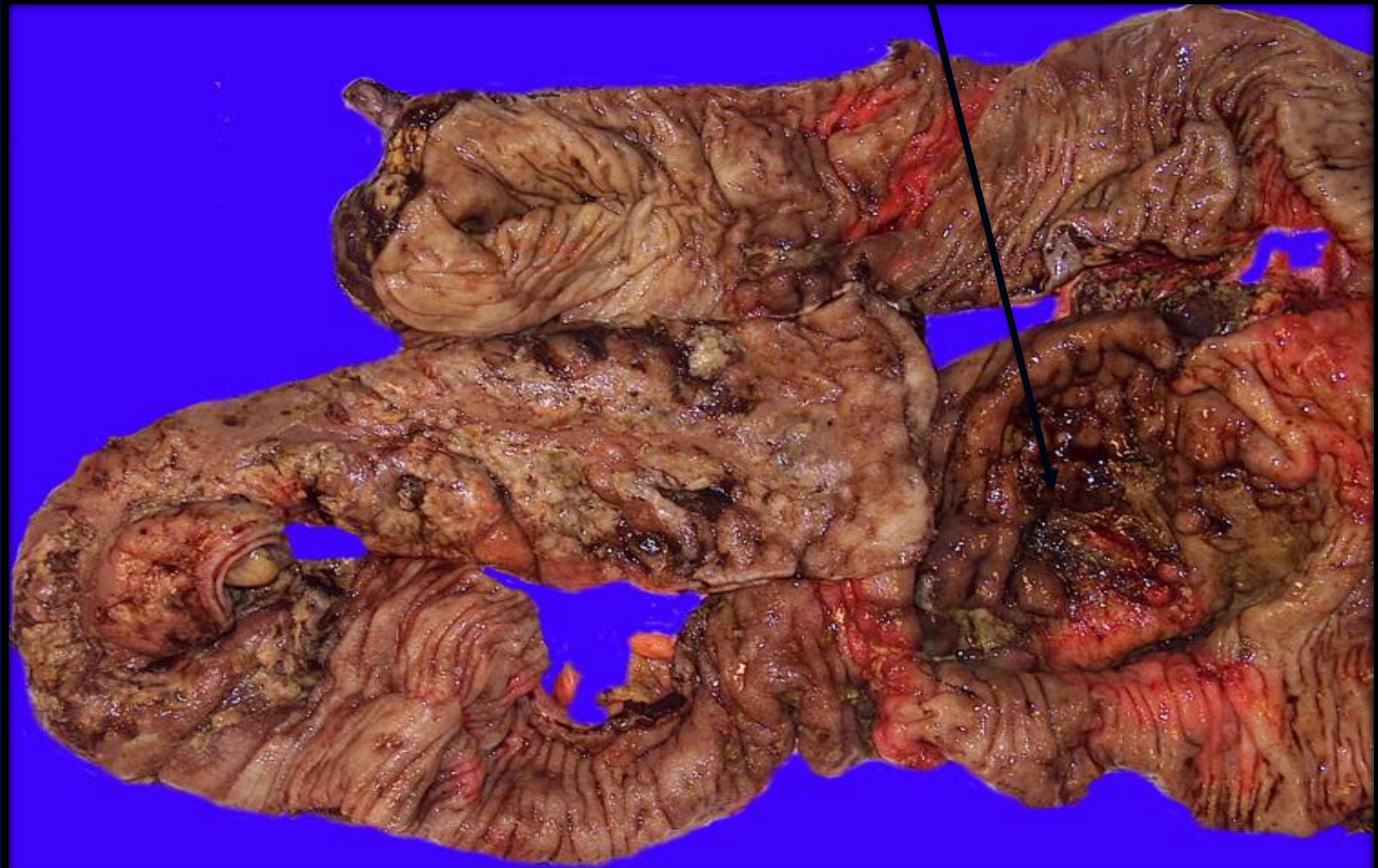


# Crypt abscess

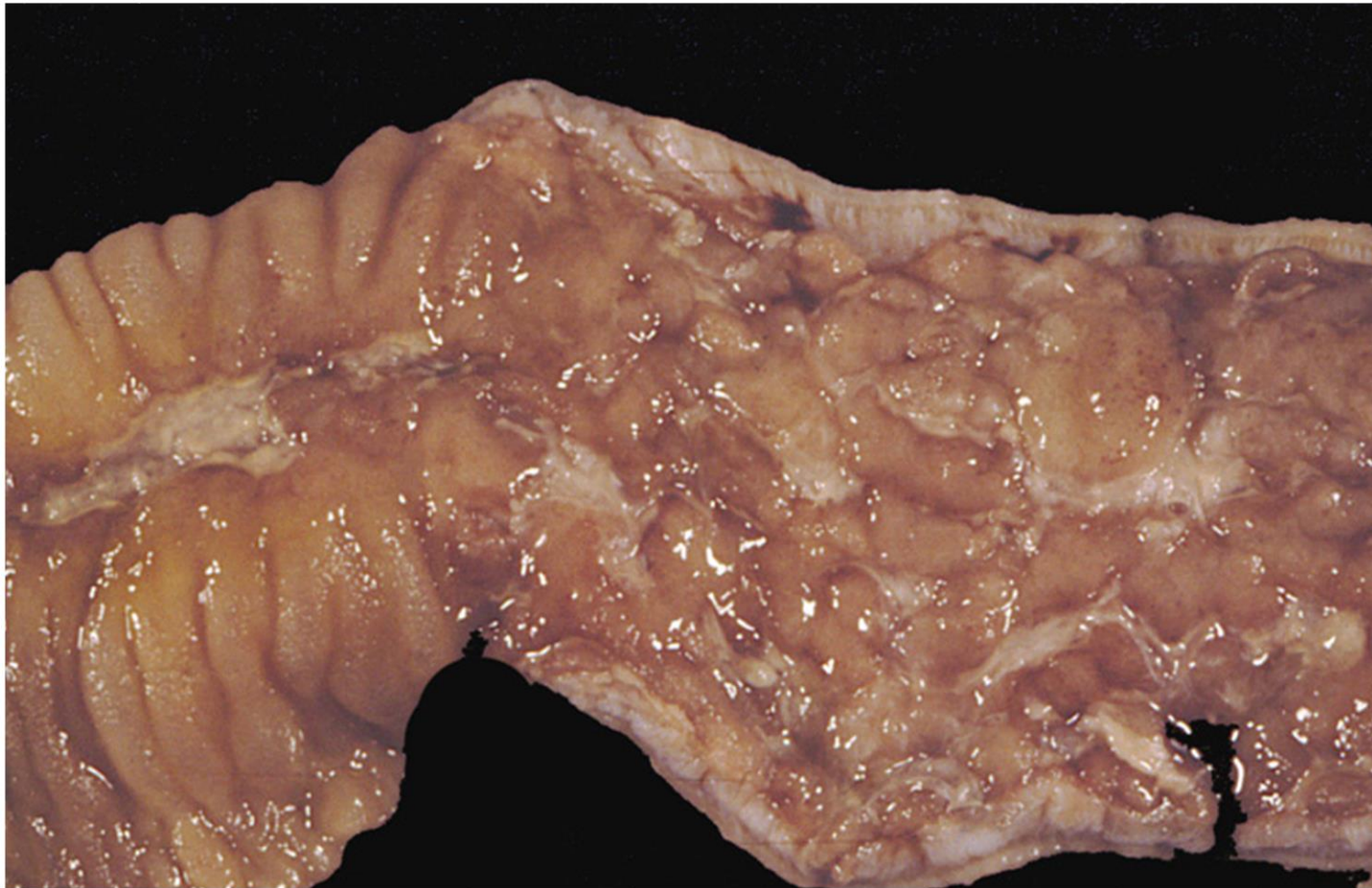

Cript absces

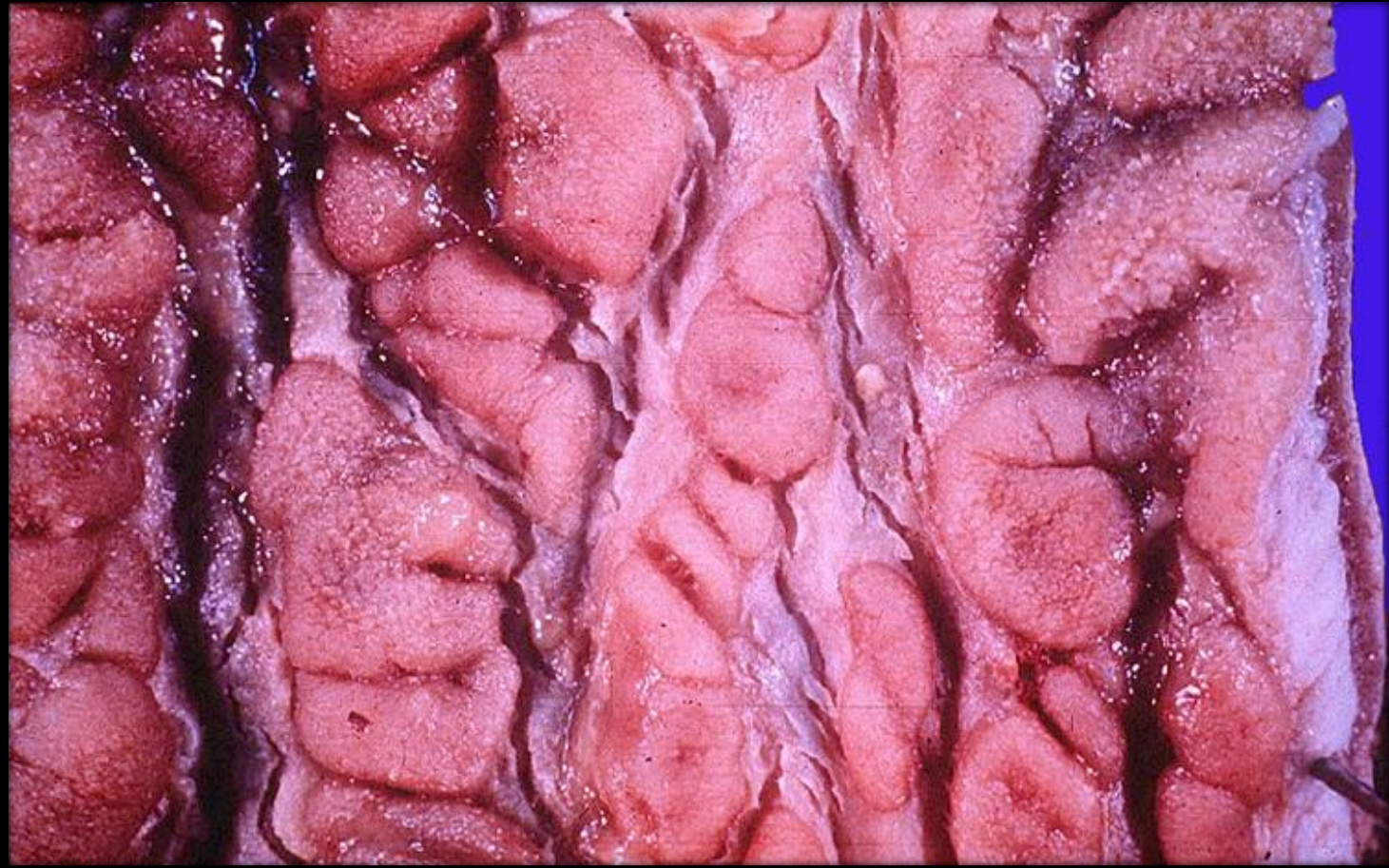
# Toxic Megacolon



**“Cobblestone”. Serpiginous linear ulcers  
surrounding normal mucosa**



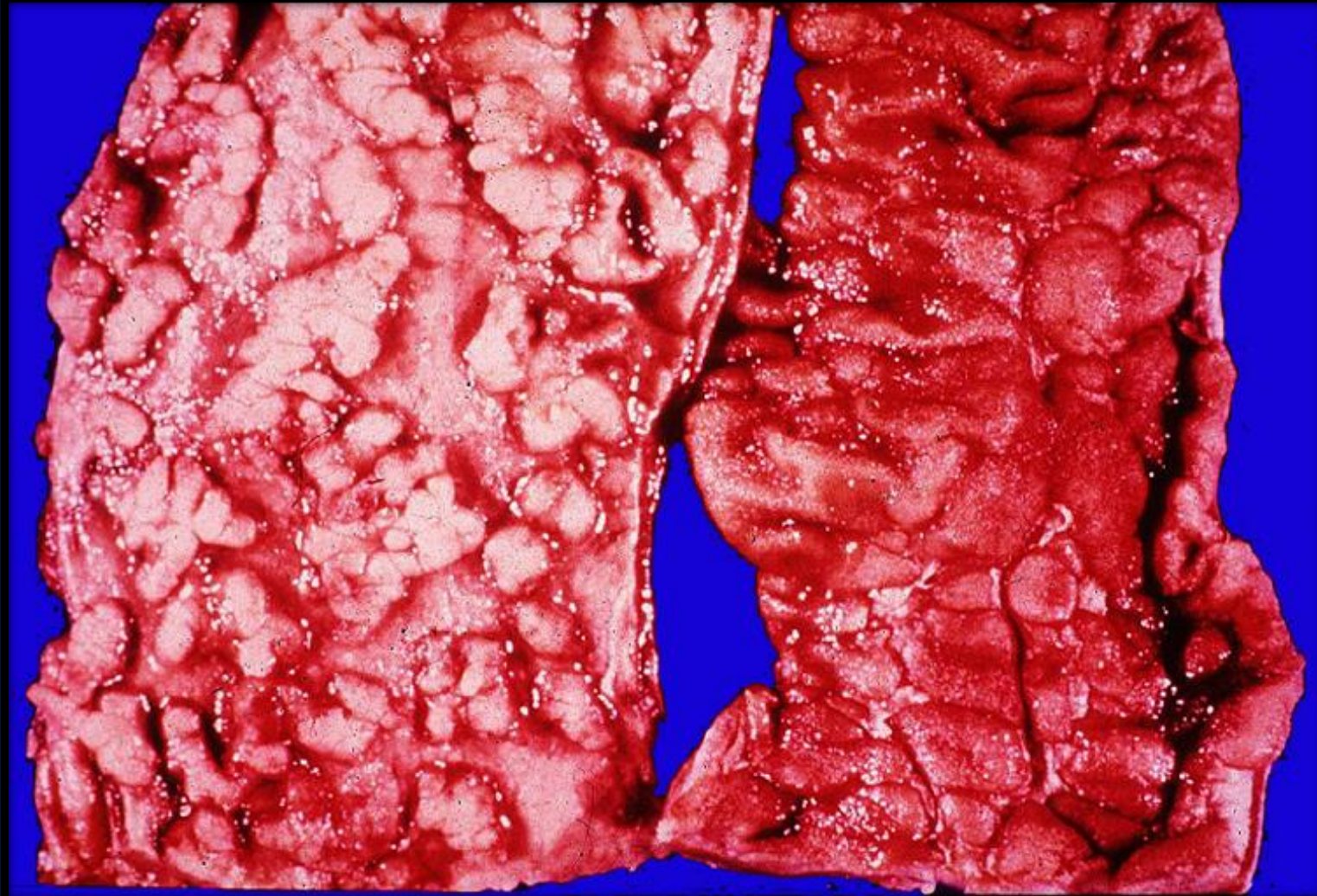
**Serpiginous linear ulcers  
surrounding normal mucosa**



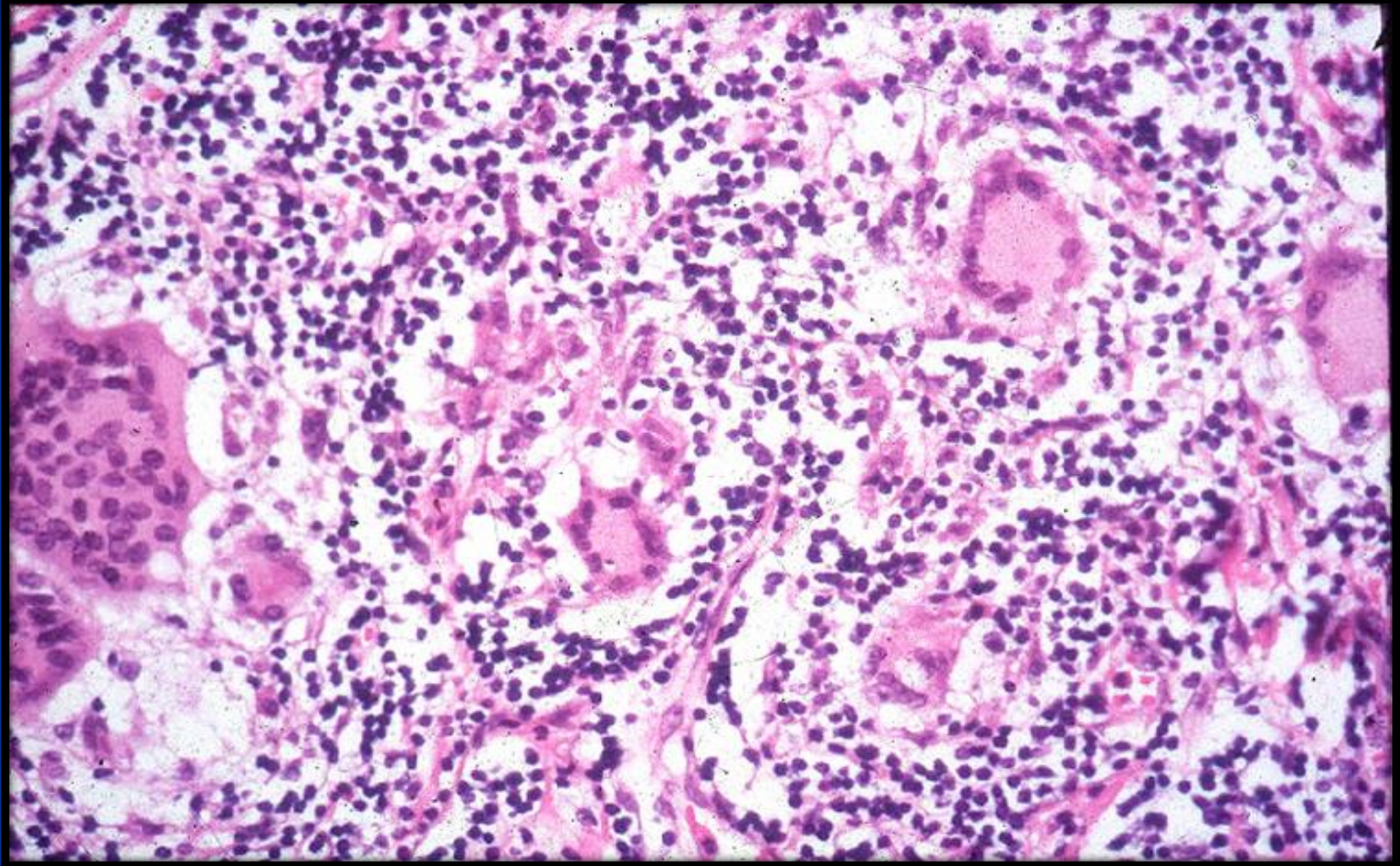


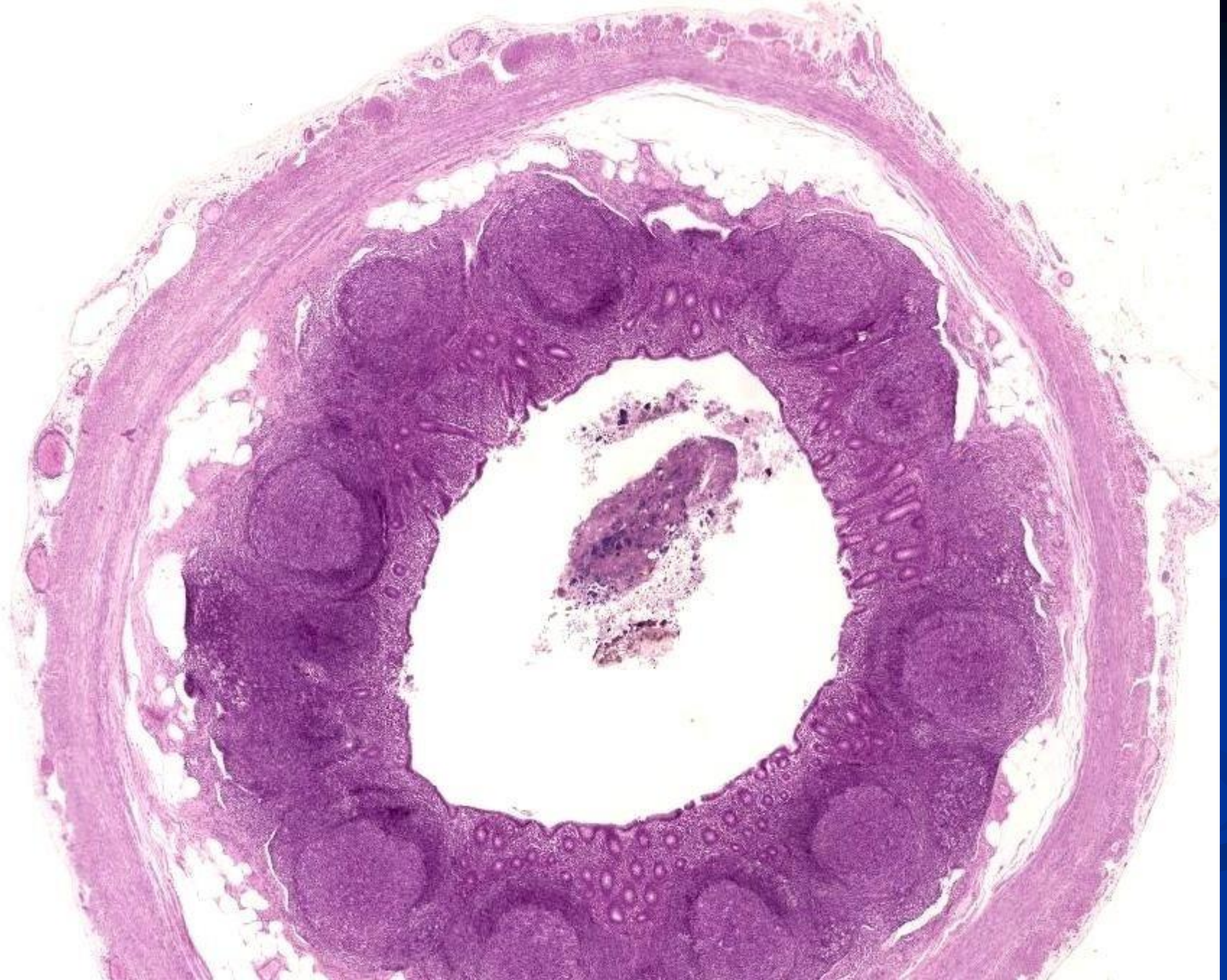**Ulcerative Colitis**

**Crohn's Disease**



# Granulomas = Crohn's Disease

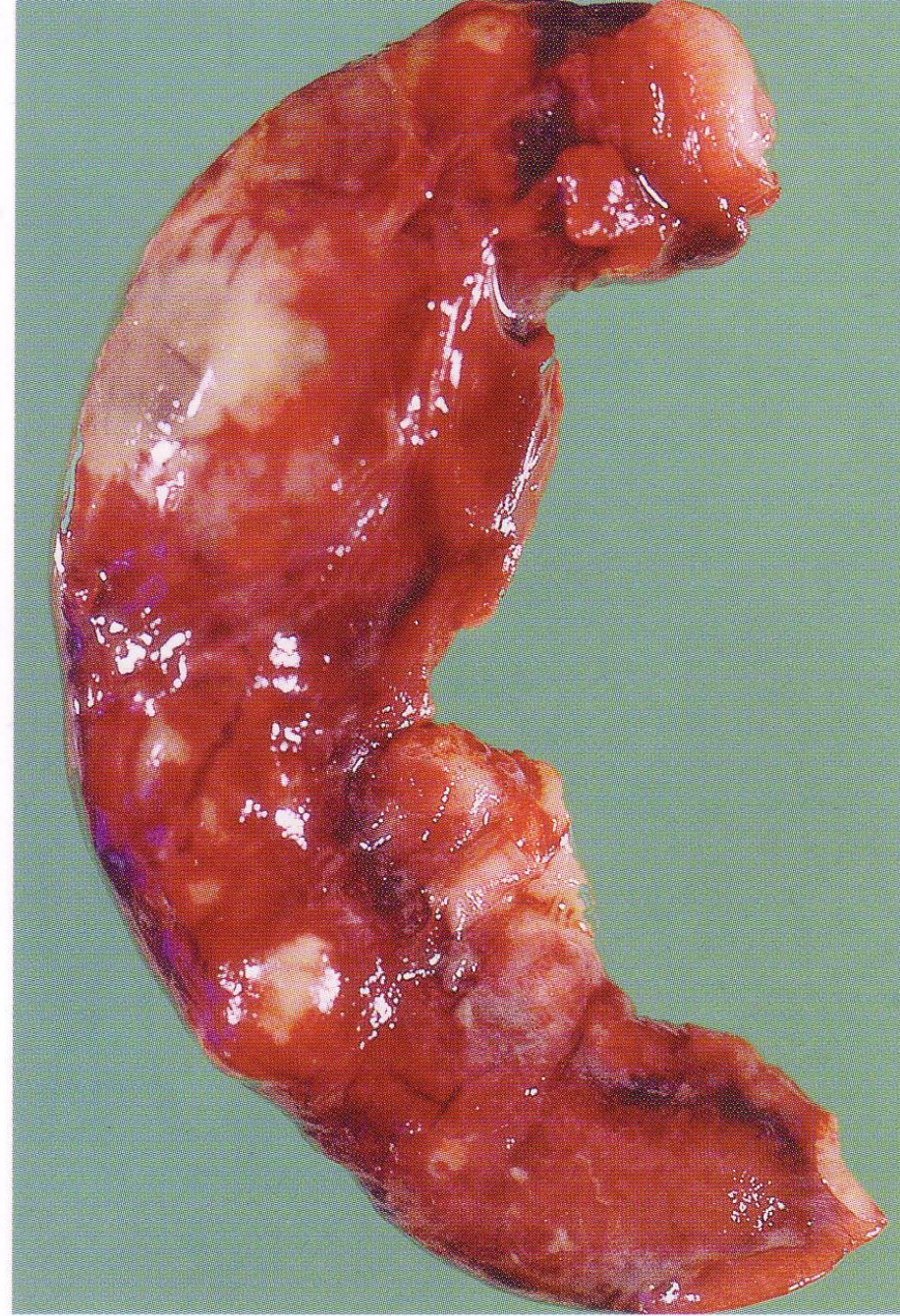




A  
P  
P  
E  
N  
D  
I  
X

# ANATOMY

- Junction of 3 tenia coli, variable in location
- All 4 layers, true serosa
- Thickest layer is submucosal lymphoid tissue
  
- APPENDICITIS (ACUTE)
- MUCOCELE
- MUCUS CYSTADENOMA
- MUCUS CYSTADENOCARCINOMA



**Аппендицит.**

# ACUTE APPENDICITIS

- **GENERALLY**, a disease of **YOUNGER** people
- **OBSTRUCTION** by **FECALITH** the classic cause but fecaliths present only about half the time
- **EARLY APPENDICITIS:**  
**NEUTROPHILS** → Mucosa, submucosa
- **NEED NEUTROPHILS** in the **MUSCULARIS** to confirm the **DIAGNOSIS**
- 25% normal rate, usually

# Acute Appendicitis

Is the most common acute abdominal condition the surgeon is called on to treat.

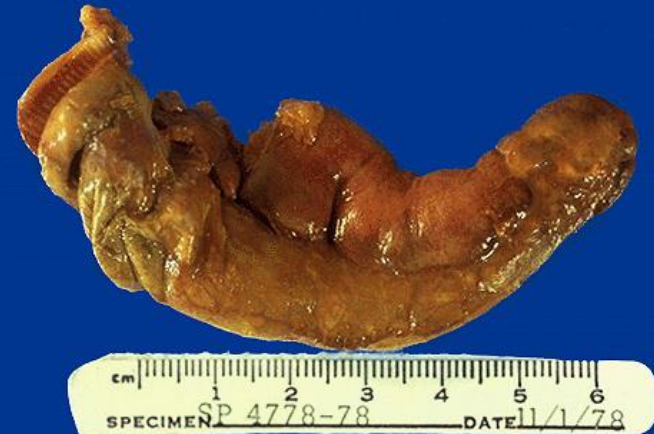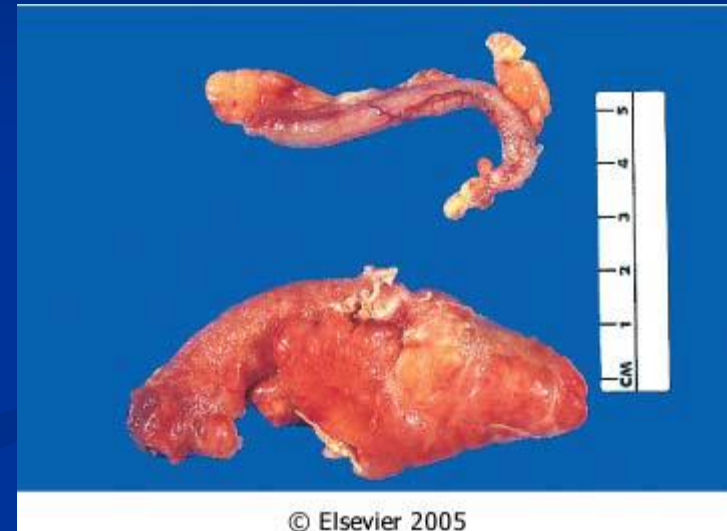
- Inflammation in the right lower quadrant
  - Adolescents and young adults

- Acute Simple Appendicitis
- Acute Suppurative Appendicitis
- Acute Gangrenous Appendicitis

# Morphology

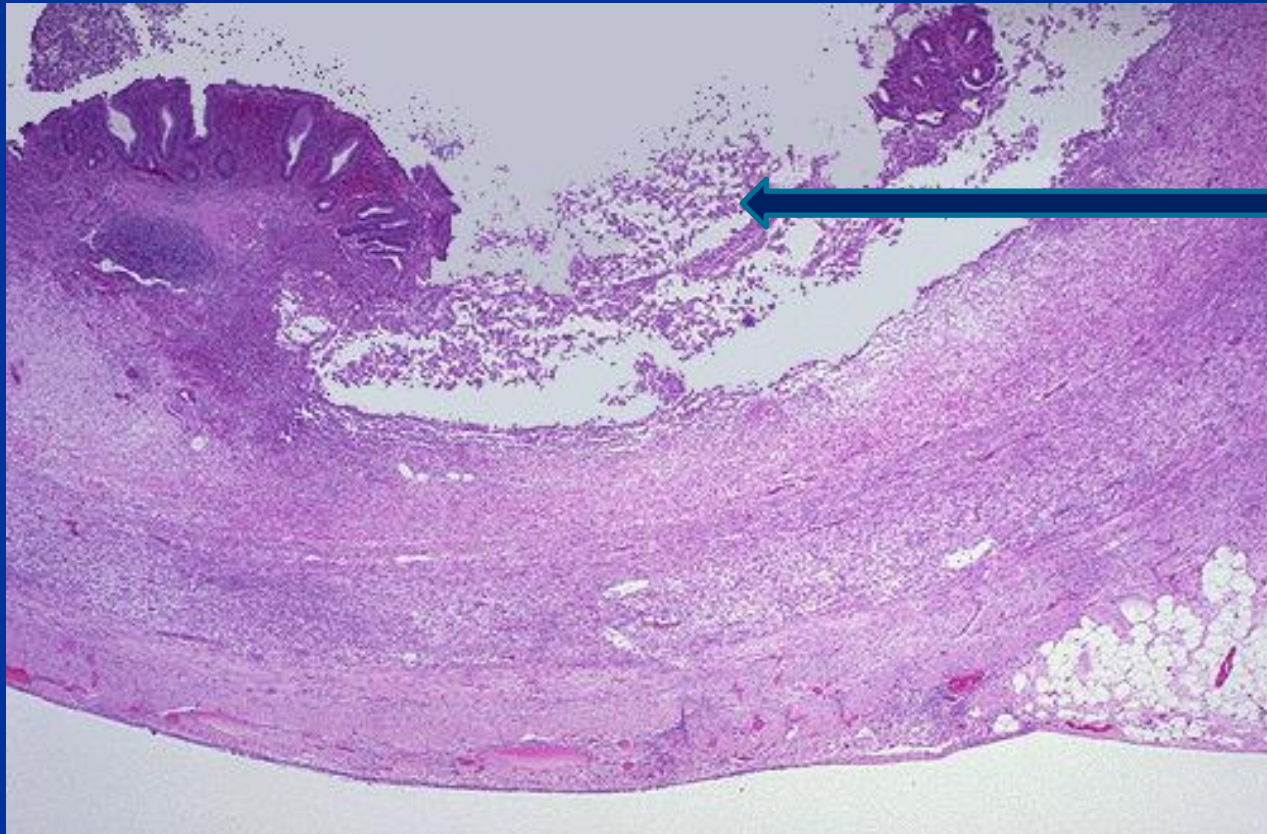
Scant neutrophilic exudate throughout the mucosa, submucosa, and muscularis propria

- Subserosal vessels are congested
- Fibrinopurulent reaction over the serosa
- Abscess formation within the wall, along with ulcerations and foci of suppurative necrosis in the mucosa
- Green-black gangrenous necrosis through the wall, extending to the serosa






Microscopically, acute appendicitis is marked by mucosal inflammation and necrosis.



Purulent debris



# Complications

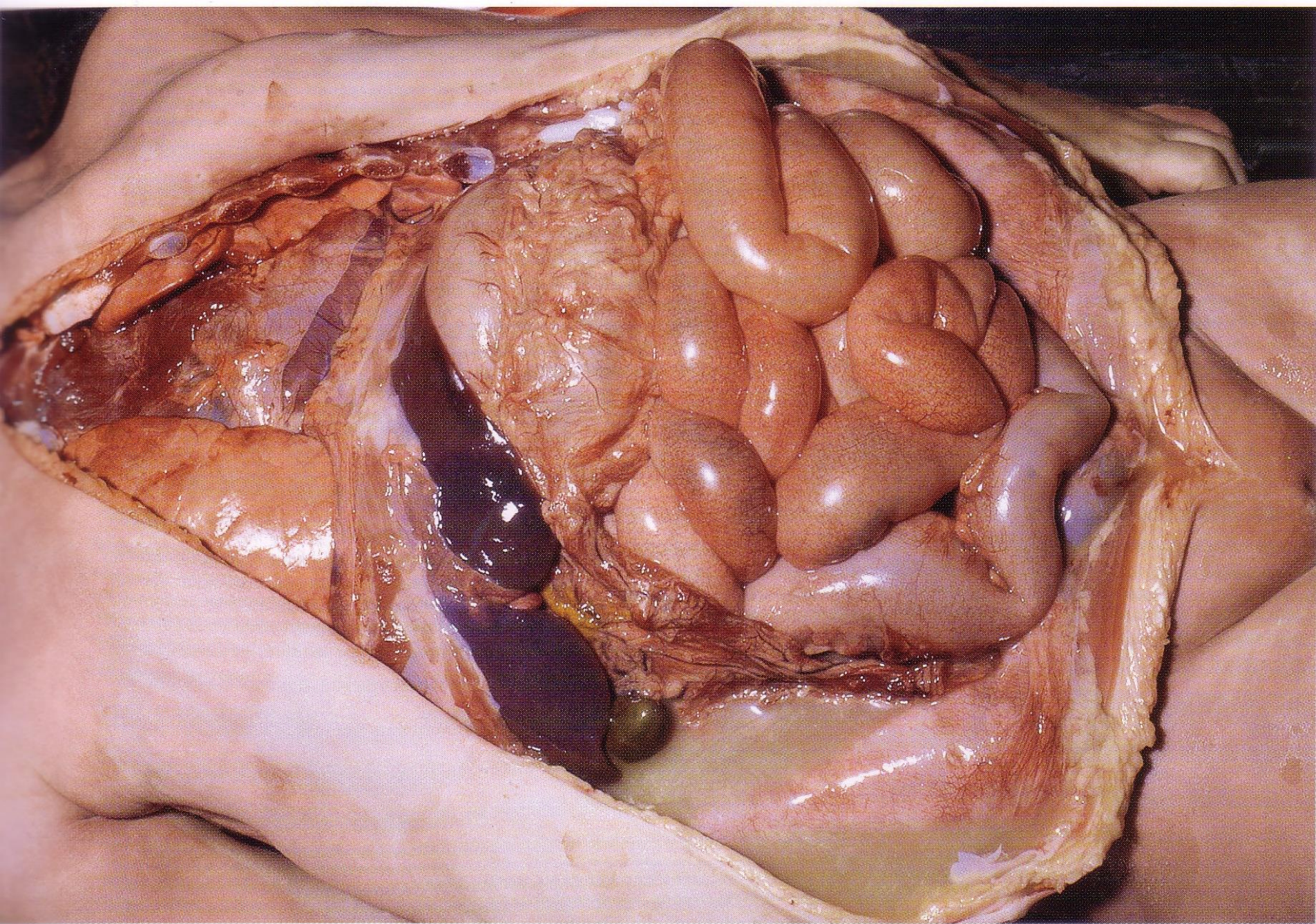
**Rupture**

**Suppurative peritonitis**

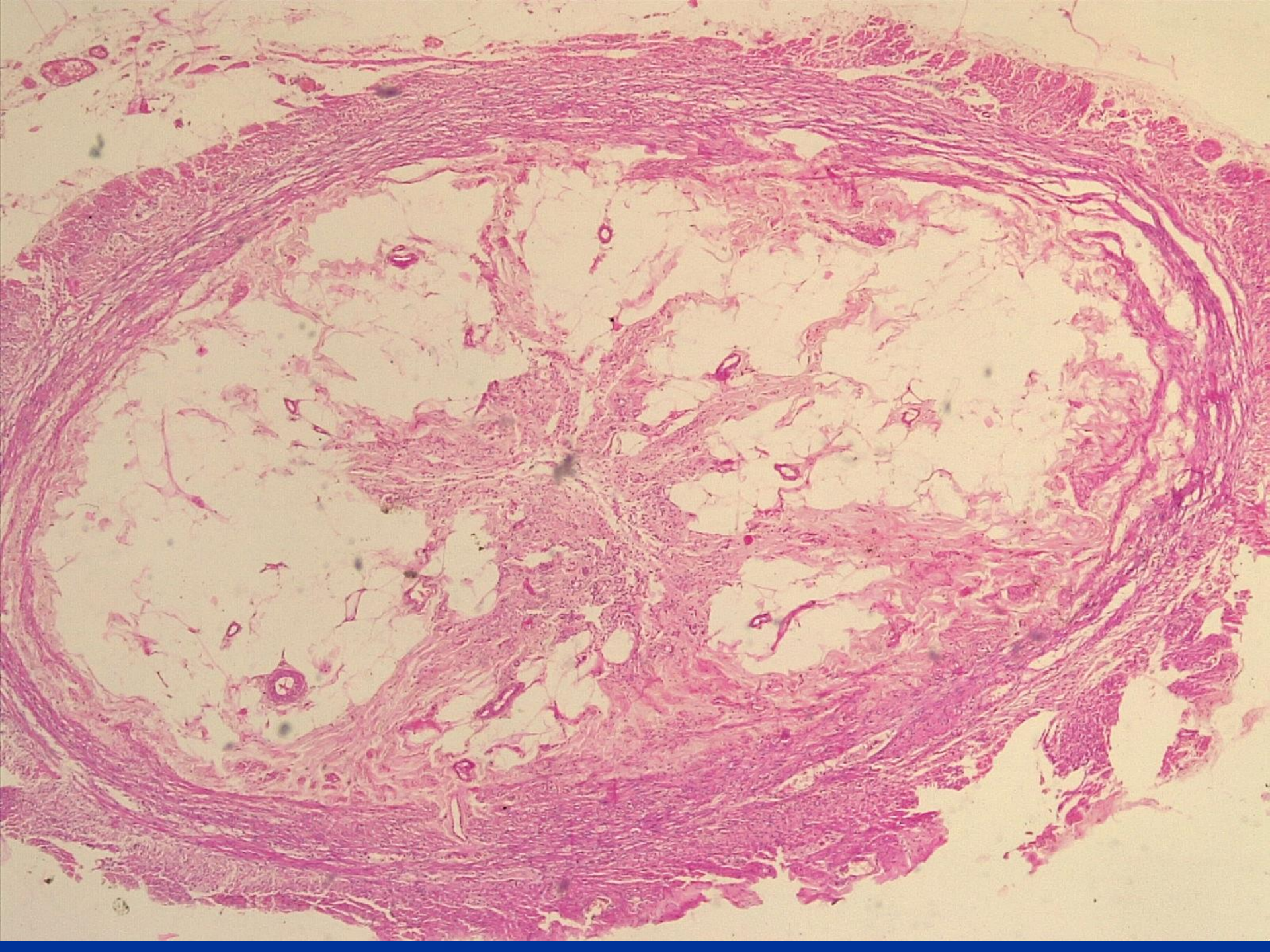
**Pyelophlebitis with thrombosis of  
the portal venous drainage**

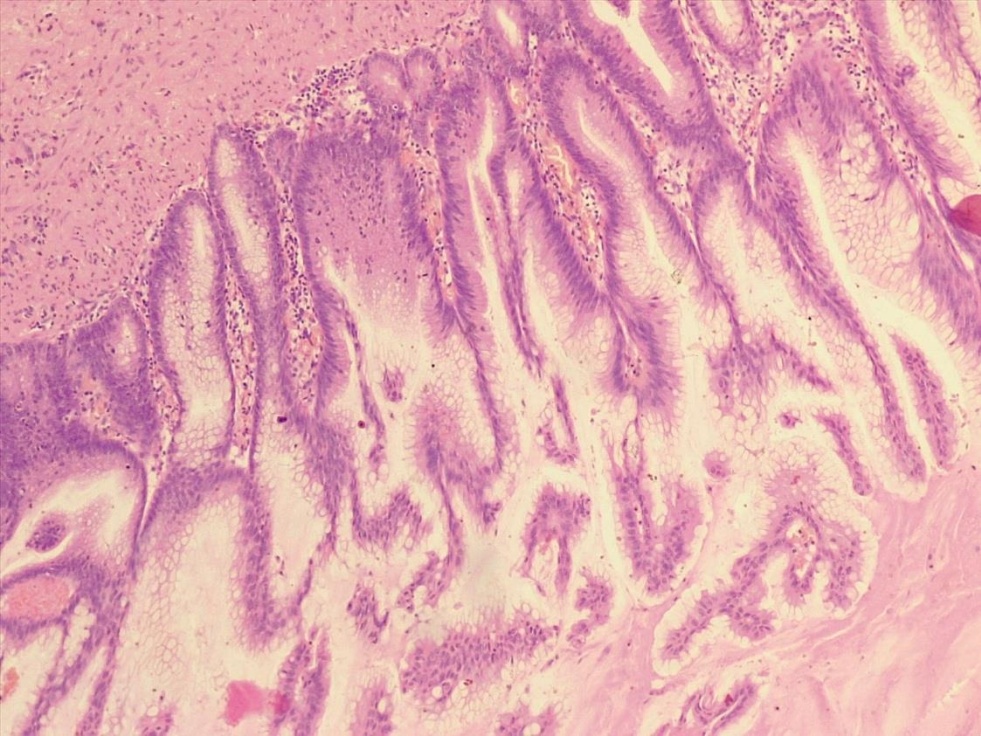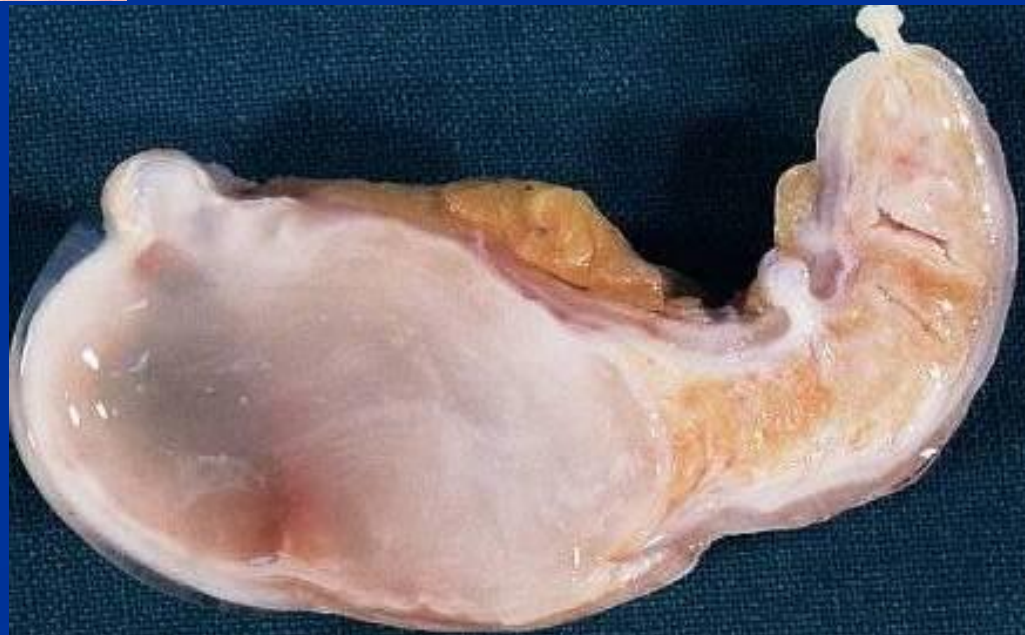
**Chronic inflammation of the  
appendix**

**Cystic fibrosis**



**Гнойный перитонит - осложнение острого аппендицита.**






# Mucus “TUMORS”

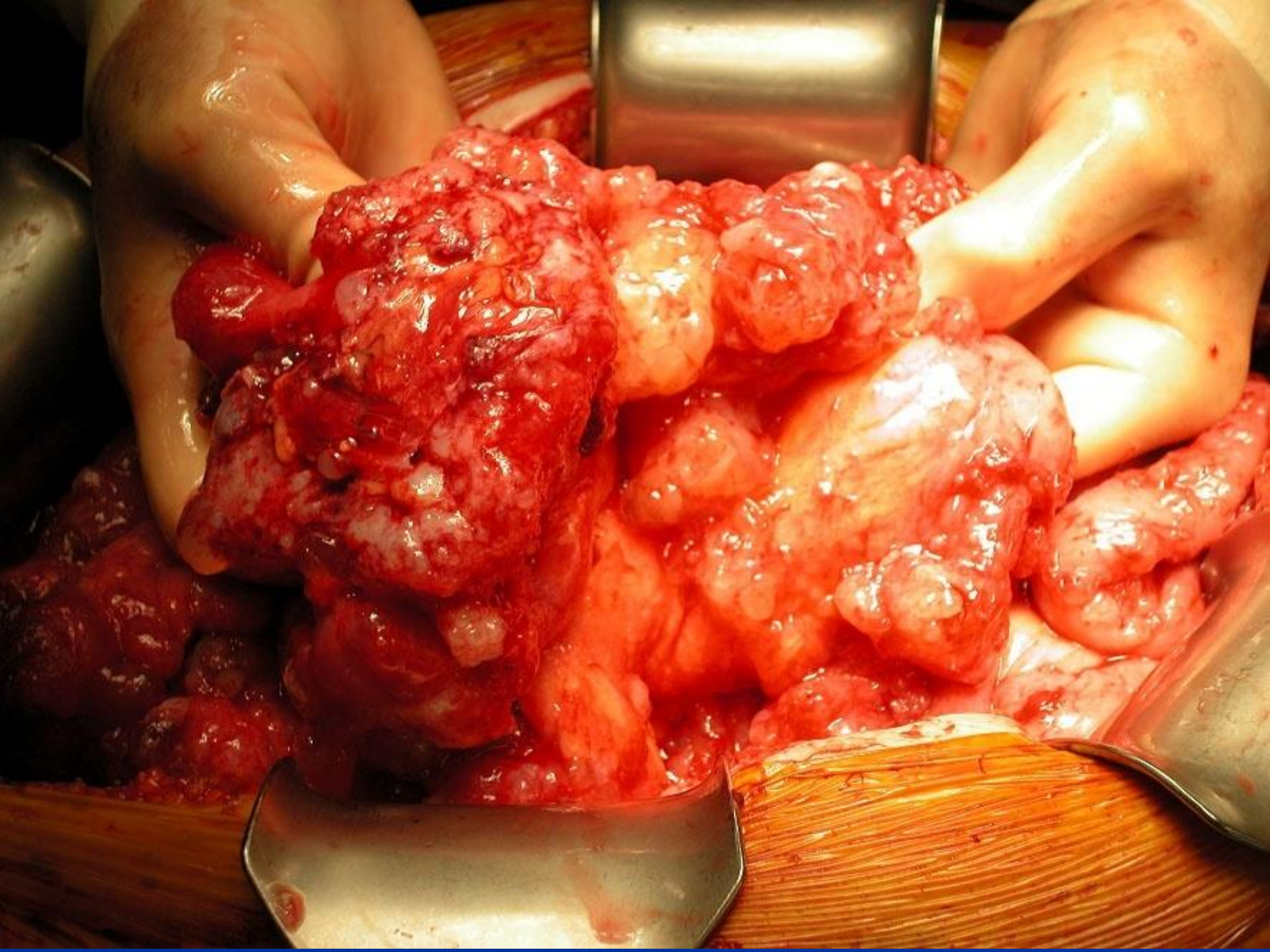
- Mucocele (common)
- Mucinous Cystadenoma (rather rare)
- Mucinous Cystadenocarcinoma (rare)

# MUCOCELE

- COMMON CYST on APPENDIX filled with MUCIN
- Can RUPTURE to become:

**PSEUDOMYXOMA  
PERITONEII**

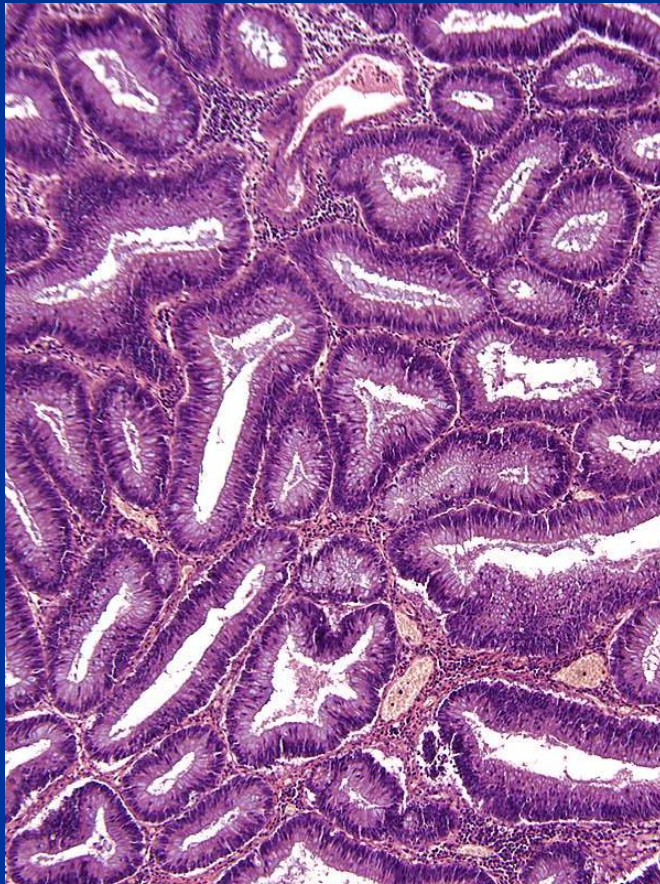




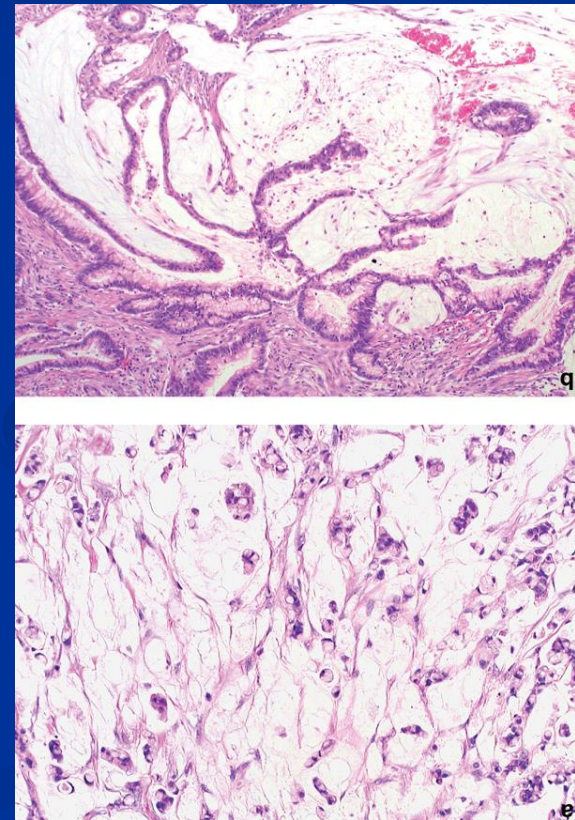


# MUCINOUS CYSTADENO(CARCINO)MA

## ADENOMA

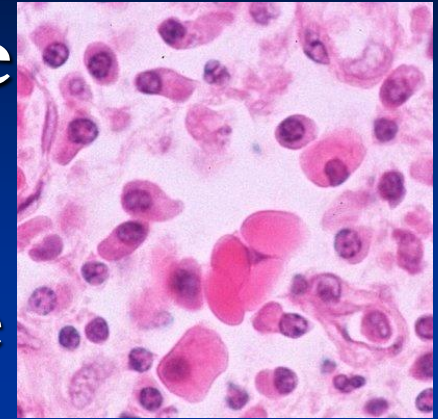

## CARCINOMA



# PERITONEUM

- Visceral, Parietal: all lined by me
- Peritonitis, acute:
  - Appendicitis, local or with rupture
  - Peptic ulcer, local or ruptured
  - Cholecystitis, local or ruptured
  - Diverticulitis, local or with rupture
  - Salpingitis → gonococcal or chlamydial, retrograde or perforated
  - Ruptured bowel due to any reason
  - Perforating abdominal wall injuries



# PERITONITIS

- E. coli
- STREP
- S. aureus
- ENTEROCOCCUS

# PERITONITIS, outcomes:

- Complete RESOLUTION
- Walled off ABSCESS
- ADHESIONS

# Tumors of Small and Large Intestine

---

- Non-neoplastic polyps
- Hyperplastic
  - Hamartomatous polyps
    - Juvenile polyps
    - Peutz-Jeghers polyps
  - Inflammatory polyps
  - Lymphoid polyps
- Lymphoma
- Neoplastic epithelial tumors
  - Benign (Adenoma)
  - Malignant
    - Adenocarcinoma
    - Carcinoid
    - Squamous cell carcinoma (rectum)
- Mesenchymal lesions
  - GIST, lipoma

# POLYPS

- ANY mucosal bulging, blebbing, or bump

- **HYPERPLASTIC** (NON-NEOPLASTIC)

- **HAMARTOMATOUS** (NON-NEOPLASTIC)

- **ADENOMATOUS** (TRUE

NEOPLASM, and regarded by many as “potentially” PRE-MALIGNANT as well)

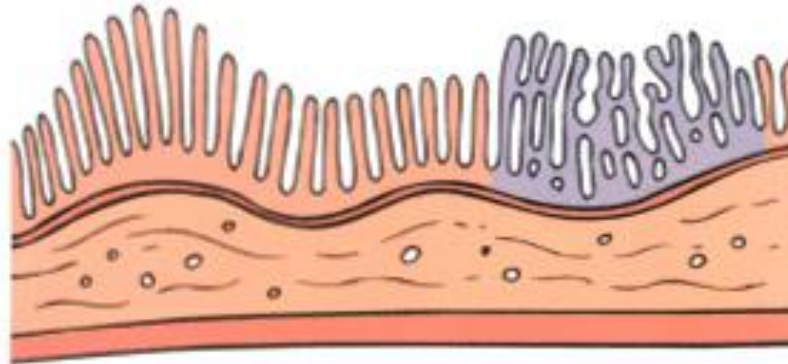
- **SESSILE** vs. **PEDUNCULATED**
- **TUBULAR** vs. **VILLOUS**

# POLYPS

## SESSILE POLYPS

**Hyperplastic polyp**

**Adenoma**



Mucosa

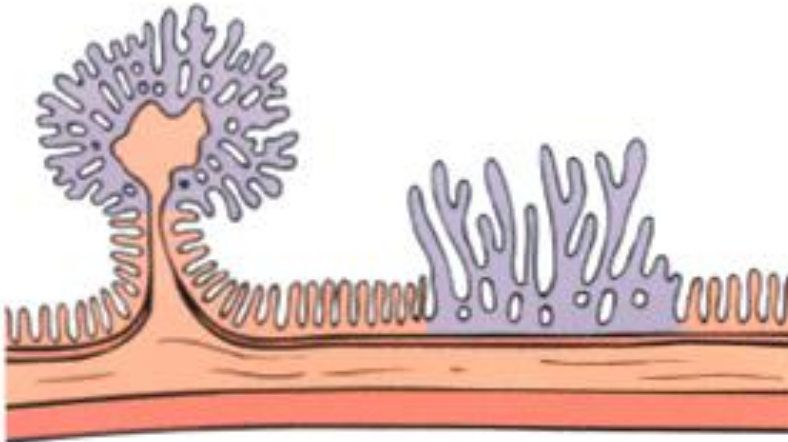
Submucosa

Muscularis propria

## ADENOMAS

**Pedunculated  
Tubular**

**Sessile  
Villous**

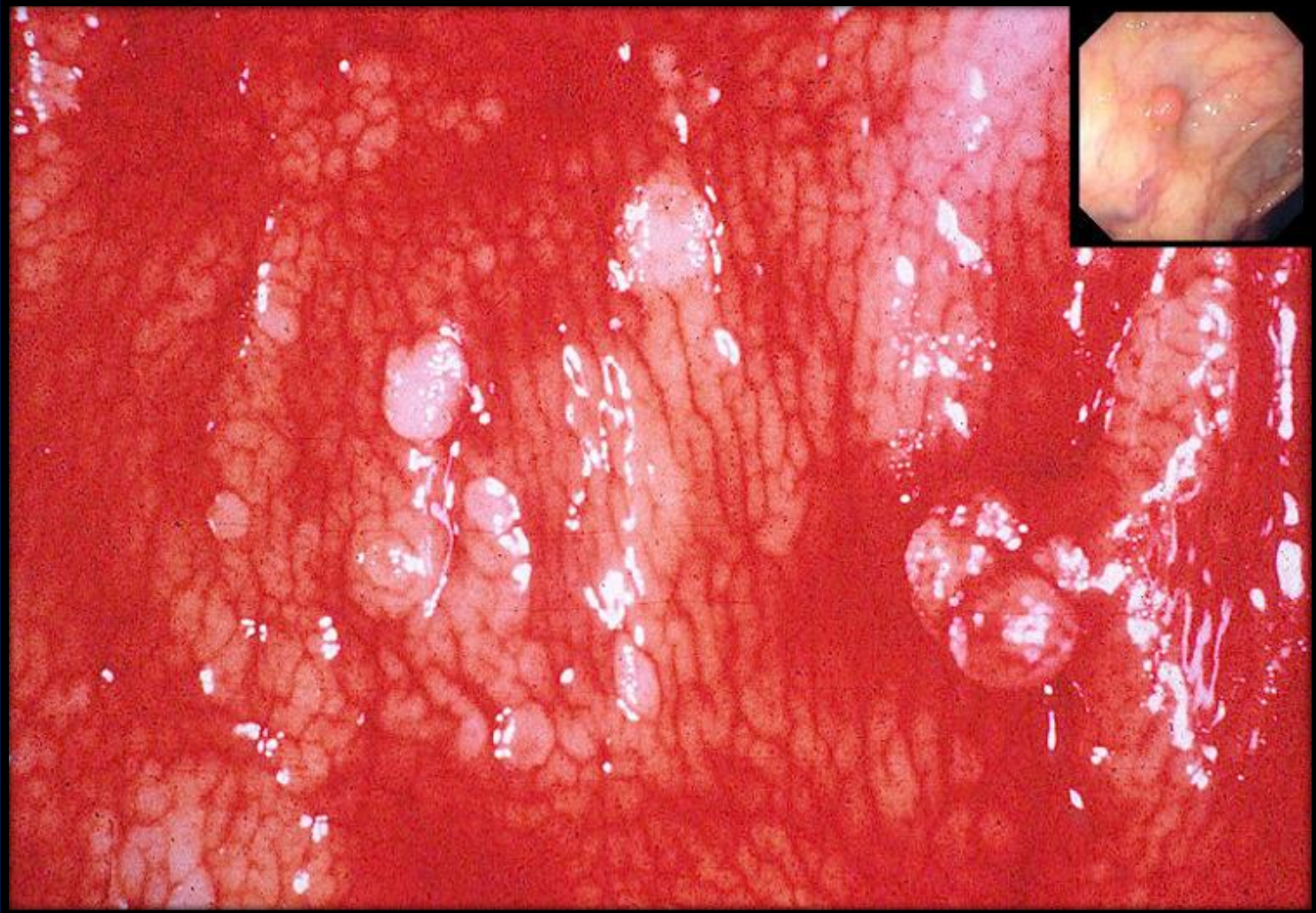

Mucosa

Submucosa

Muscularis propria

# Hyperplastic Polyp

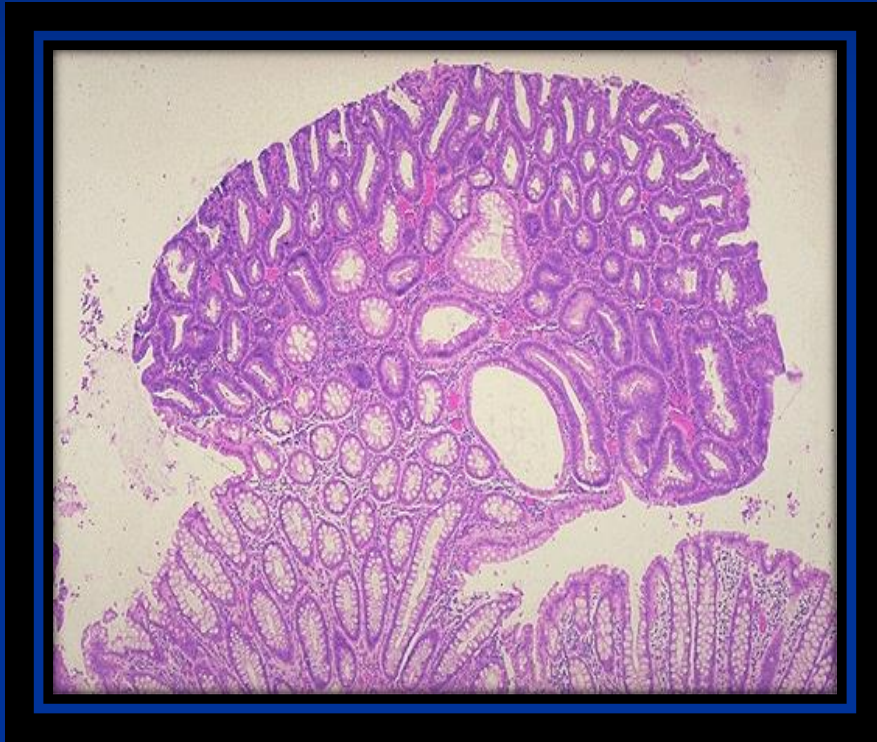




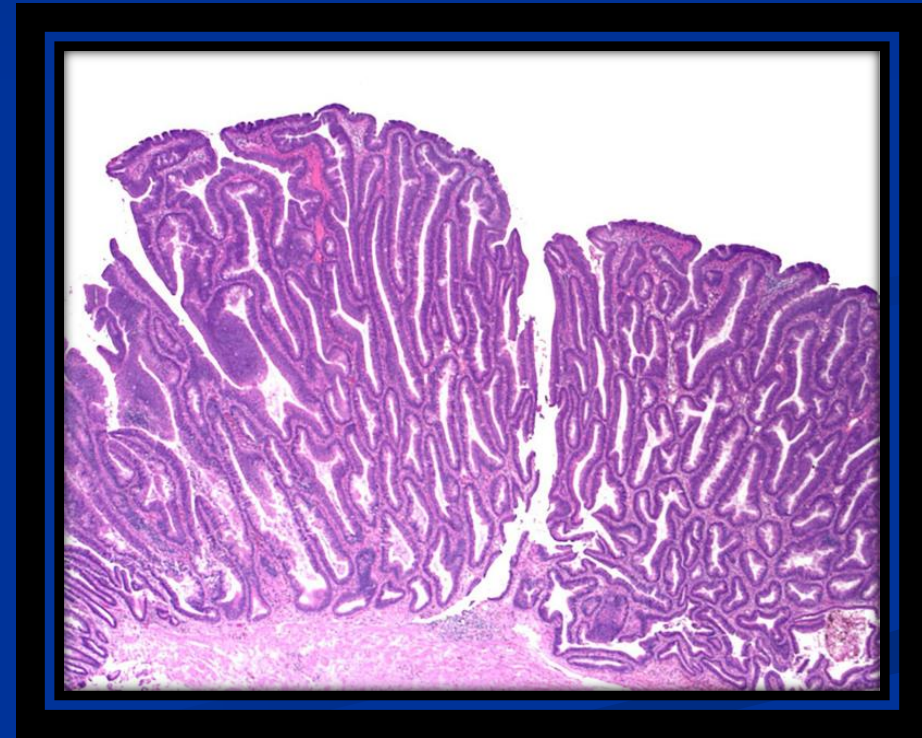
# Pre-malignant Polyps

## *Adenomatous polyps*

### Tubular Adenoma



### Villous Adenoma



### Tubulovillous Adenoma

# “FAMILIAL” NEOPLASMS

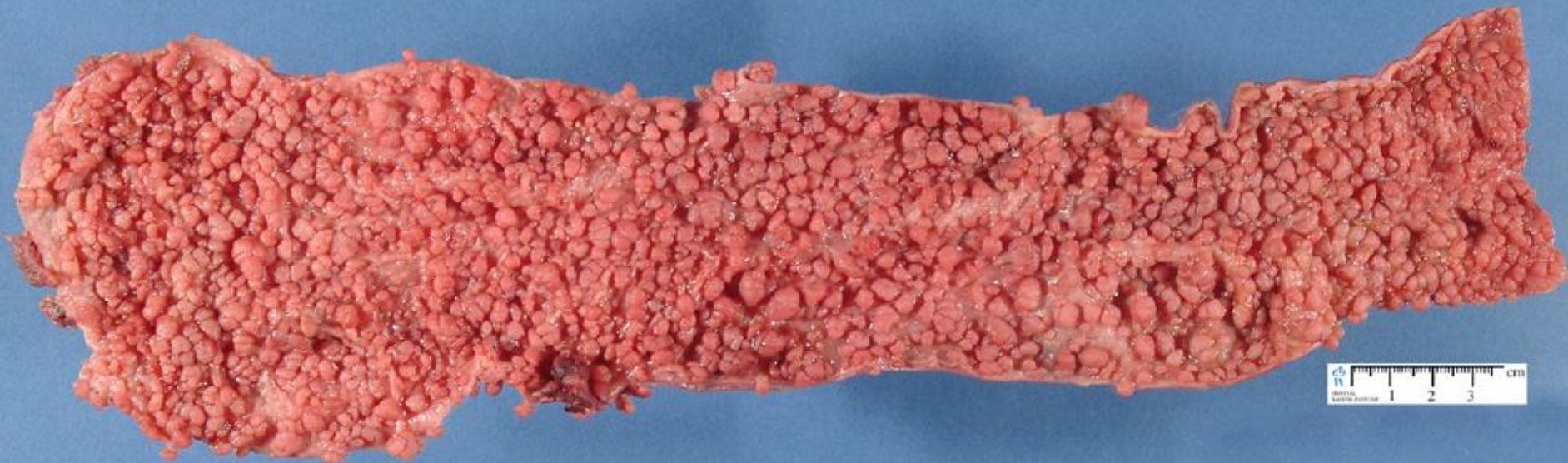- 1) POLYPOSIS (NON-NEOPLASTIC, hamartomatous)
- 2) POLYPOSIS (NEOPLASTIC, i.e., cancer risk). FAP.
- 3) HNPCC: (Hereditary Non Polyposis Colorectal Cancer)

# Hereditary Syndromes.

Some syndromes are known, characterized by the presence of colon polyps and an increased incidence of colon cancer. These syndromes are based on clearly defined genetic disorders.

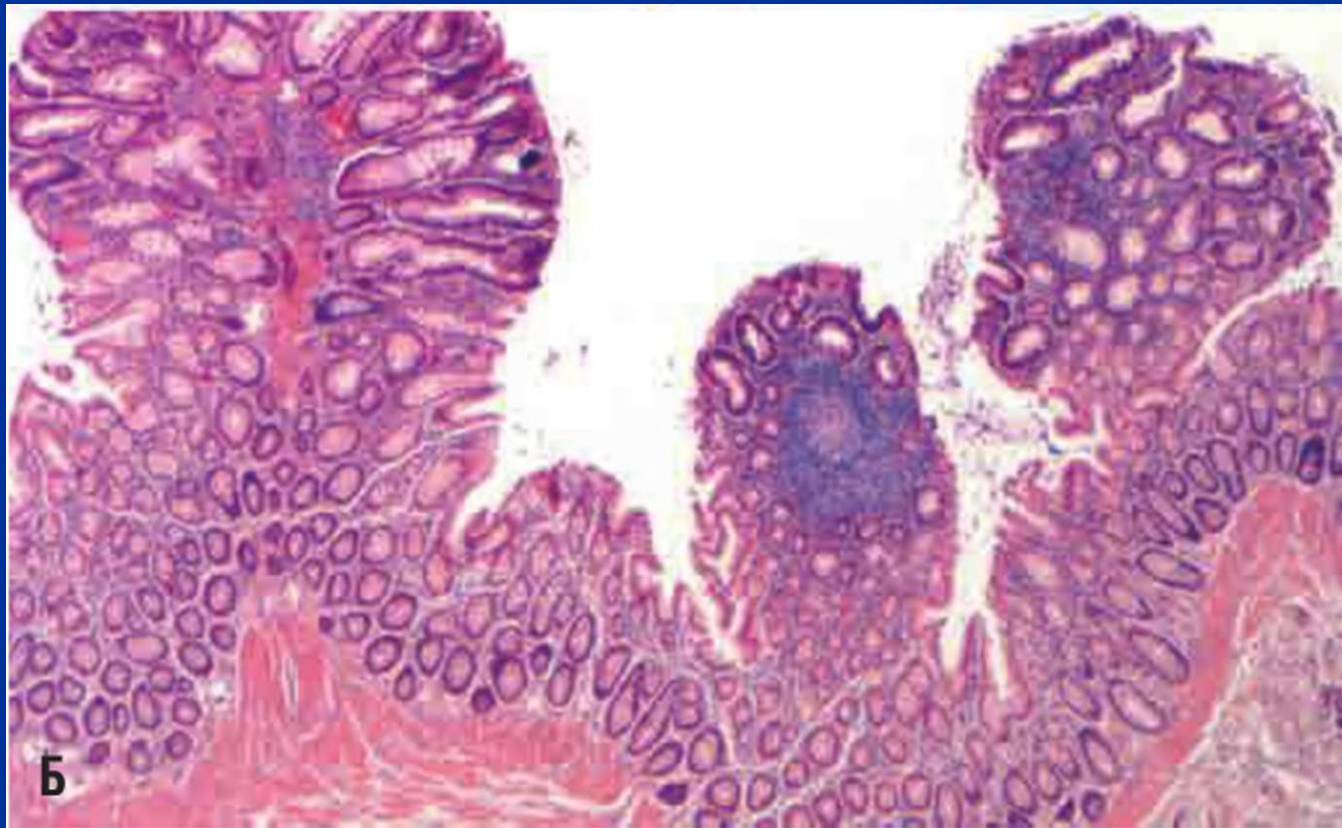
Familial adenomatous polyposis (FAP) is an autosomal dominant disease in which multiple colon adenomas develop in adolescents.

The diagnostic criterion for classic FAP is the presence in the colon of at least 100 polyps (their number can reach several thousand!)



Without treatment of FAP, colon adenocarcinomas develop in 100% of cases, often under the age of 30 years. That is why the standard treatment is prophylactic colon removal. This operation prevents the development of colon cancer, but the increased risk of developing neoplasms of other locations remains. For example, in areas adjacent to the ampulla of the Vater papilla, and adenomas may develop in the stomach.

It is important to note that in FAP flat adenomas predominate, and microadenomas consisting of only one or two dysplastic glands are often determined in areas of externally unchanged mucous membrane.



# CANCER GENETICS

- Loss of APC gene
- Mutation of K-RAS
- Loss of SMADs (regulate transcription)
- Loss of p53
- Activation of TELOMERASE

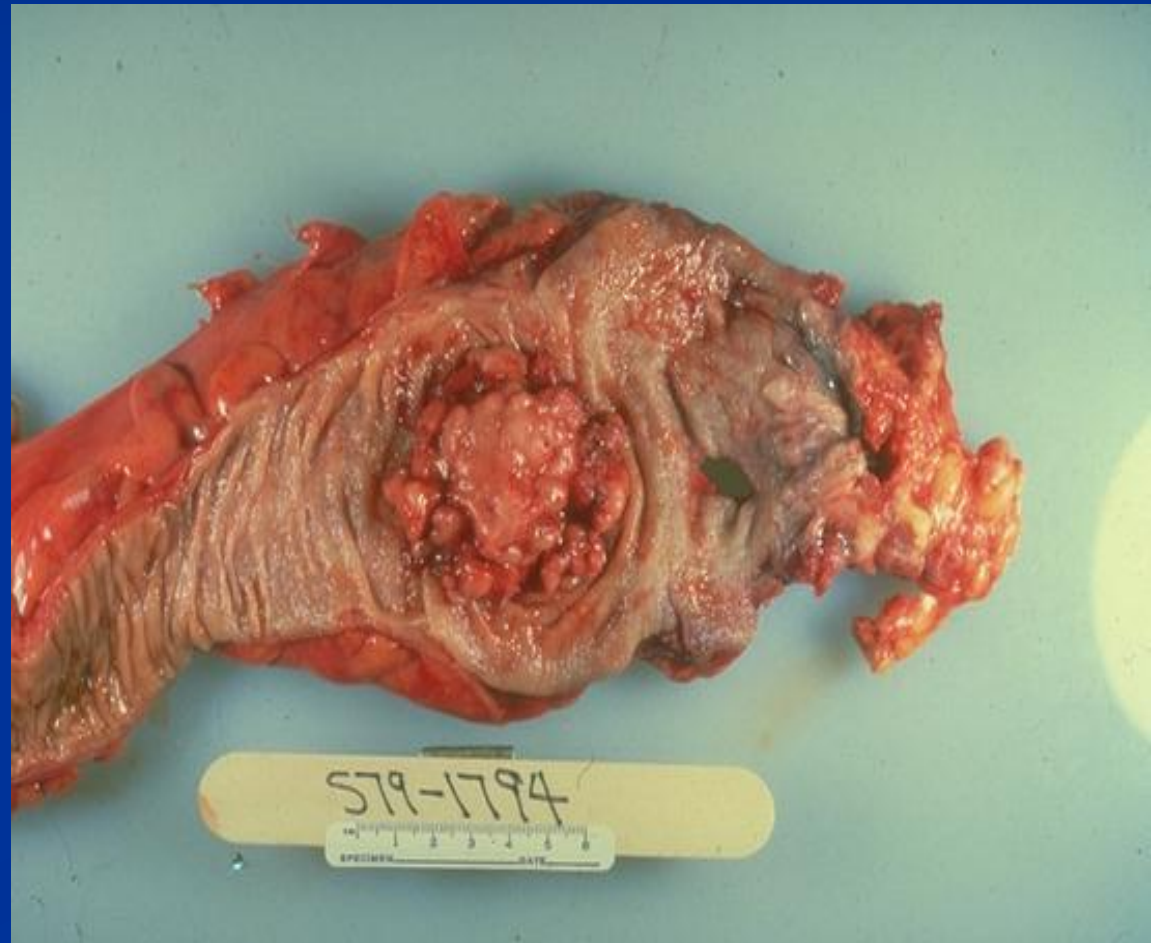
# CANCER RISK FACTORS

- Family history
- Age (rare <50)
- LOW fiber, HIGH meat, LONG transit time, refined carbs

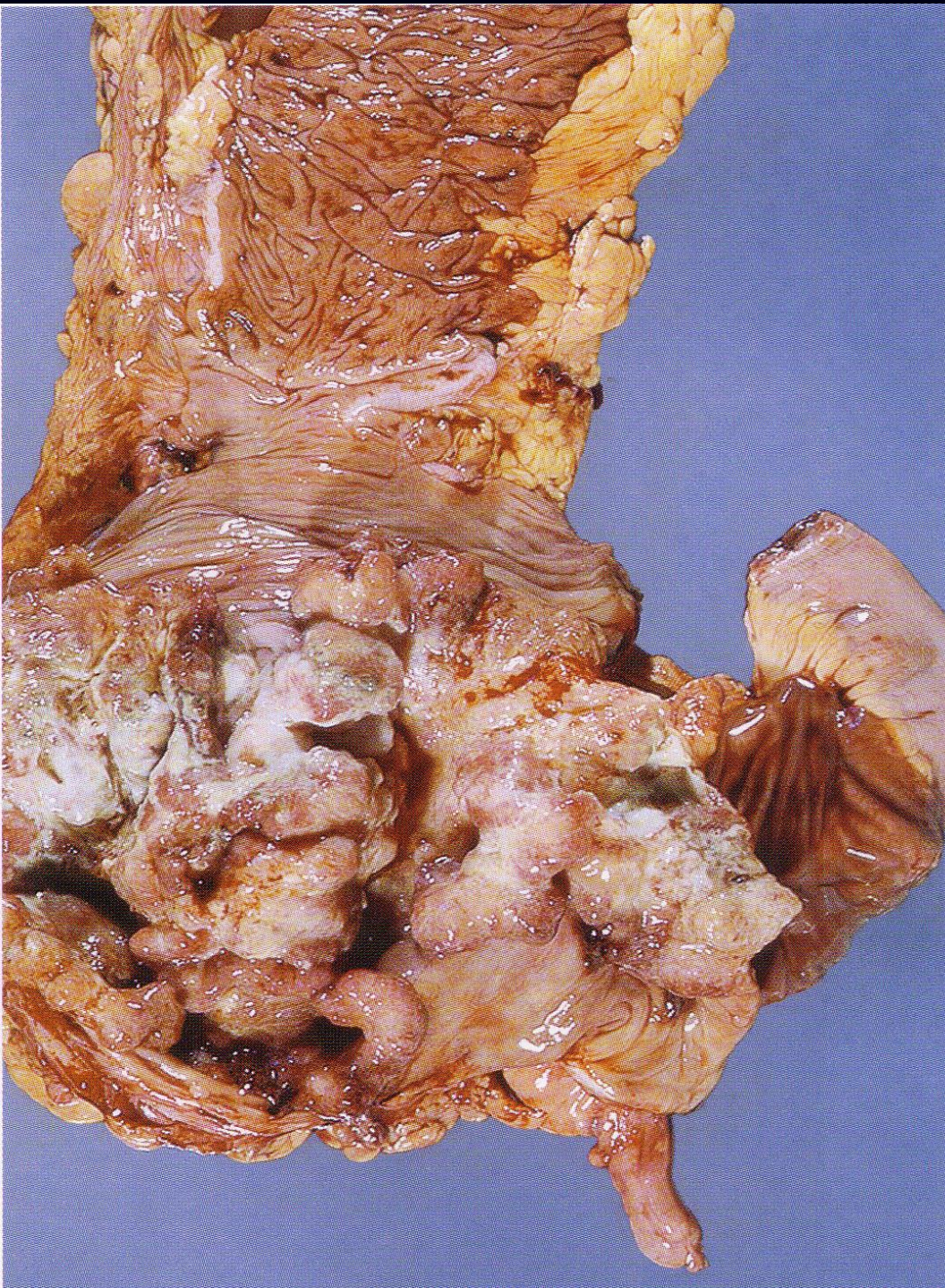
# PATHOGENESIS

- From existing ADENOMATOUS POLYPS
- DE-NOVO
  
- DYSPLASIA → INFILTRATION → METASTASIS

Features of the diet that affect the incidence of colon cancer are low fiber intake and high intake of refined carbohydrates and fats. It is assumed that a decrease in fiber intake decreases the rate of movement of feces and disrupts the composition of the intestinal microflora. These changes can lead to the accumulation of potentially toxic products of bacterial metabolism, which for a long time come into contact with the mucous membrane of the colon.





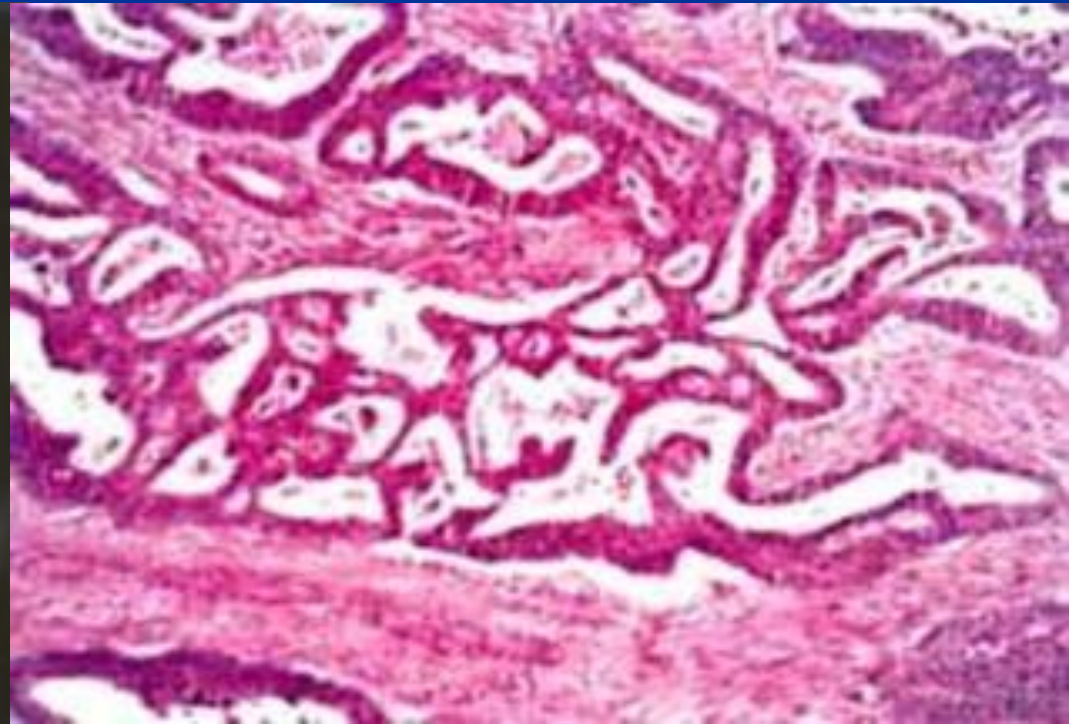
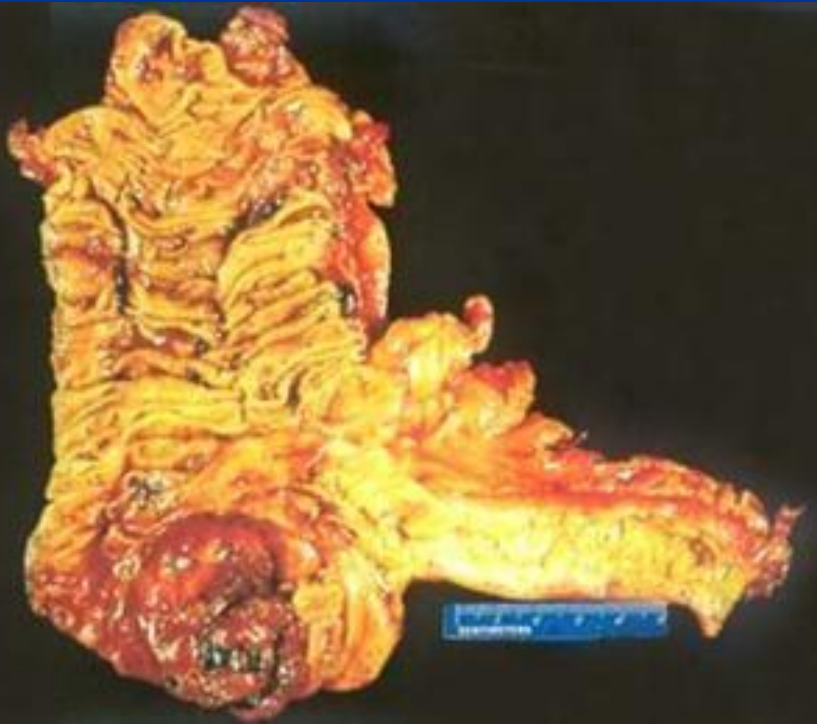

# Adenocarcinoma

Colon adenocarcinoma is the most common malignant tumor of the gastrointestinal tract. In contrast, in the small intestine, which accounts for 75% of the entire gastrointestinal tract, benign and malignant tumors are extremely rare.

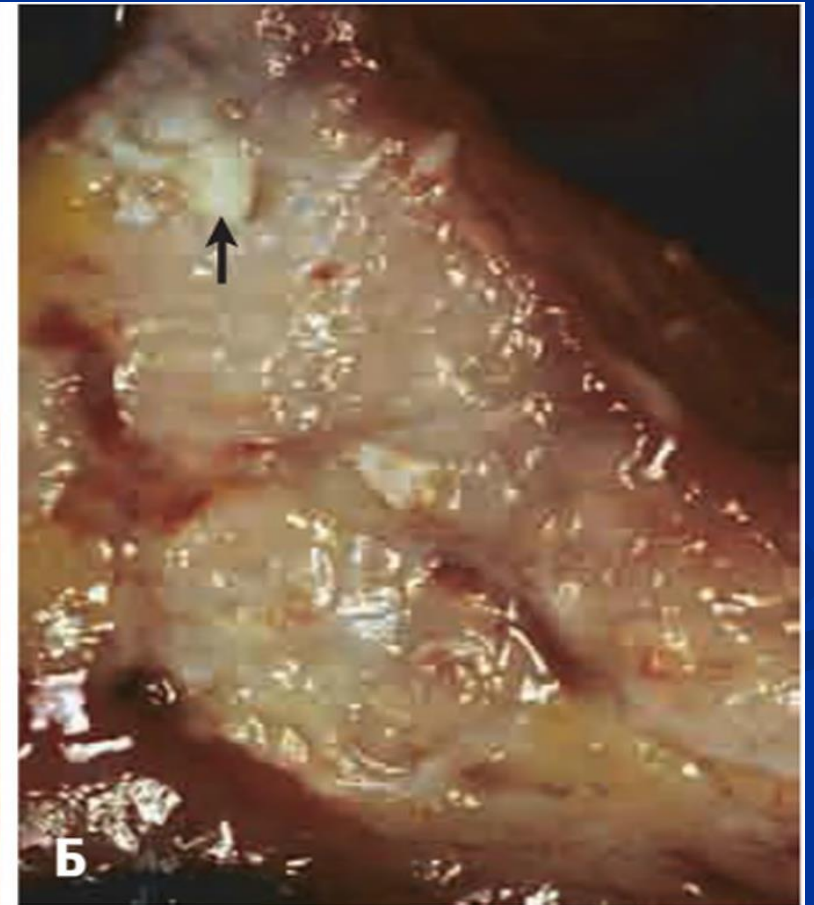
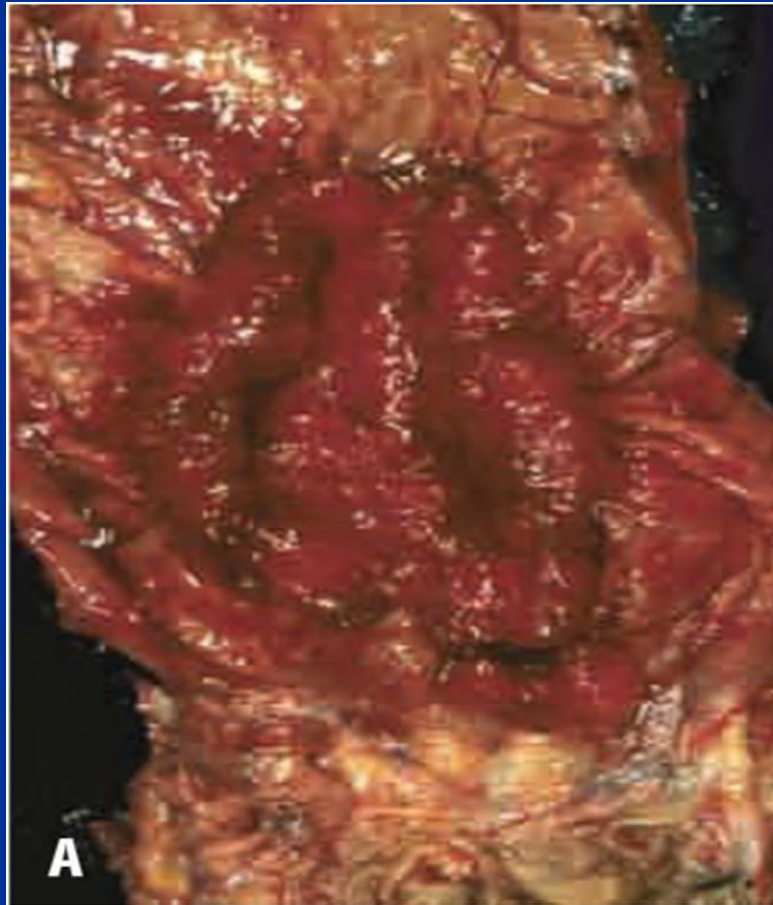
# GROWTH PATTERNS

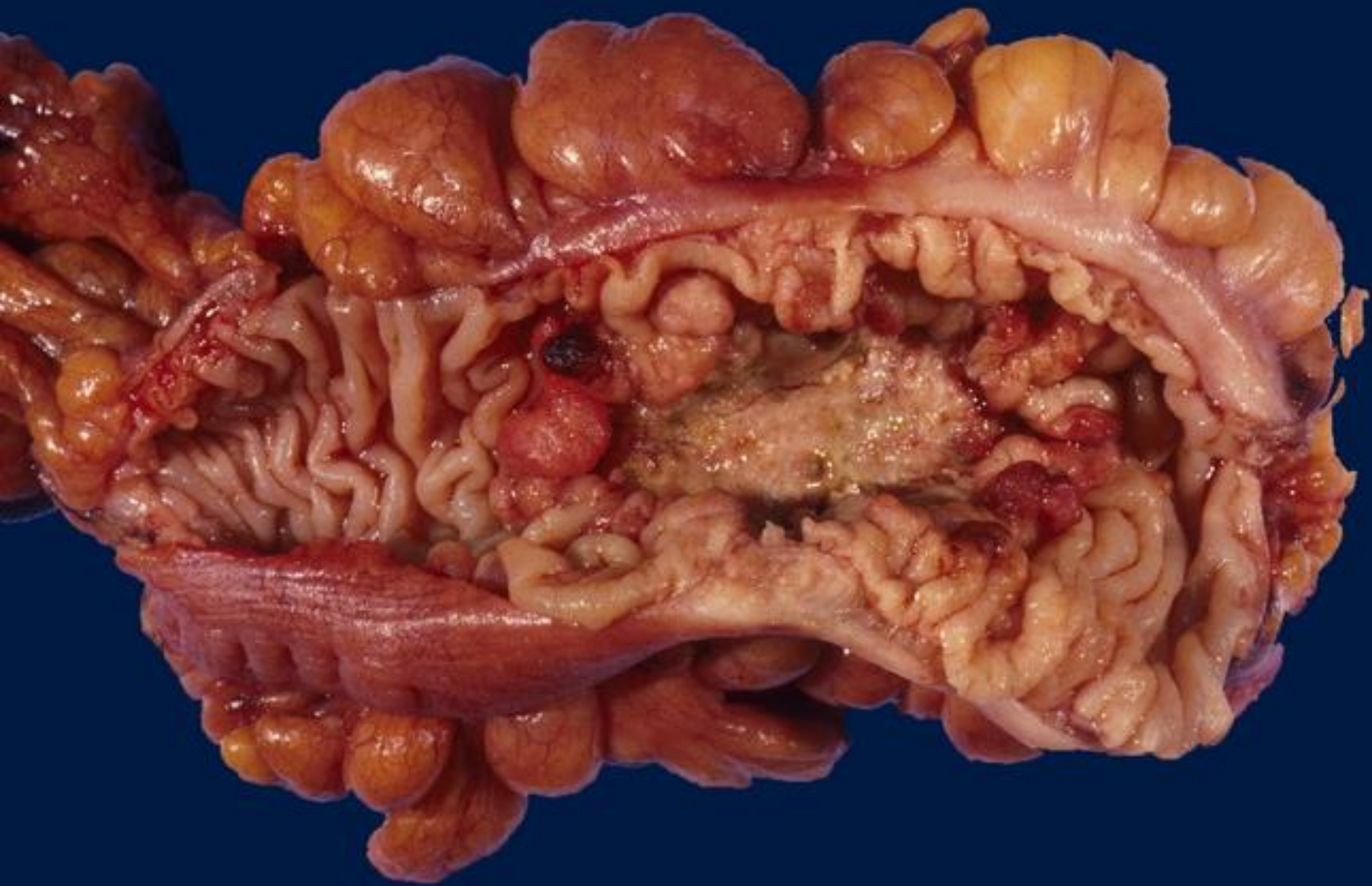
- POLYPOID
- ANNULAR, CONSTRICTING
- DIFFUSE

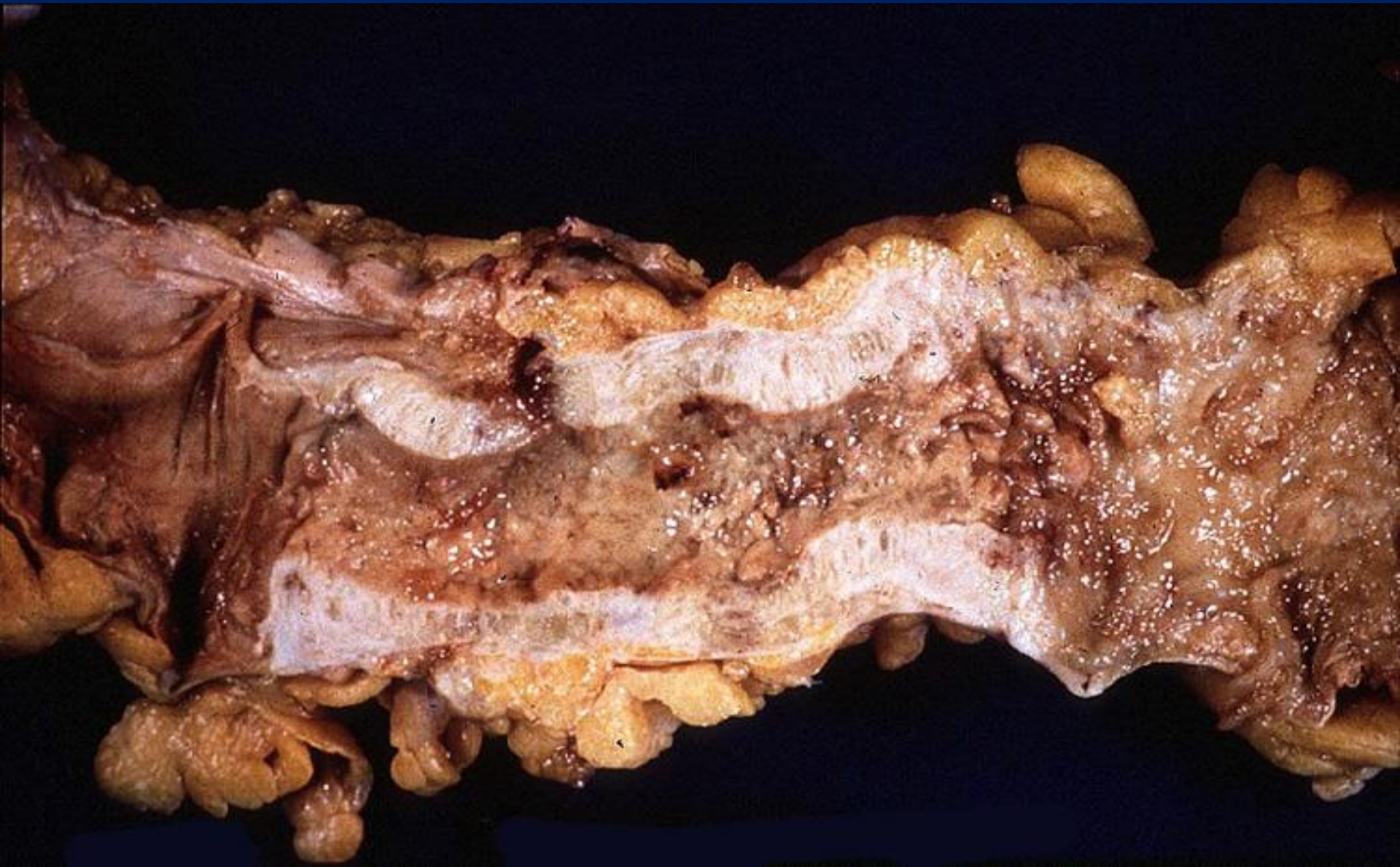

**Morphology.** Adenocarcinomas with almost the same frequency affect all parts of the colon. Tumors of the proximal colon usually grow in the form of polypoid exophytic masses spreading along one wall of the cecum or ascending colon. Such tumors rarely lead to intestinal obstruction.

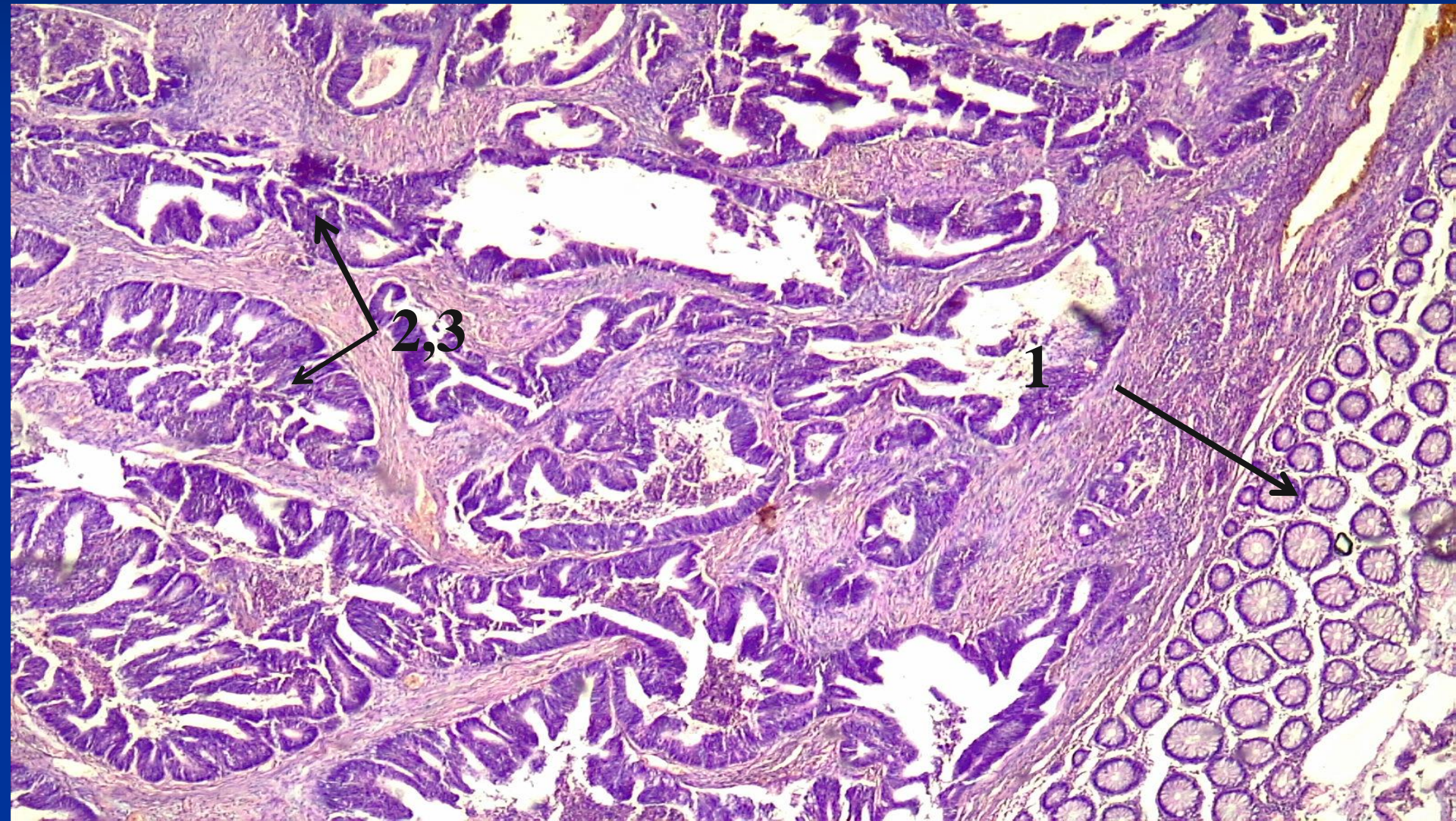
On the contrary, tumors of the distal colon usually have the form of ring-shaped formations and lead to a narrowing of the lumen of the intestine and sometimes to intestinal obstruction. In both cases, tumors grow over time into the wall of the colon and upon palpation are determined in the form of dense masses.



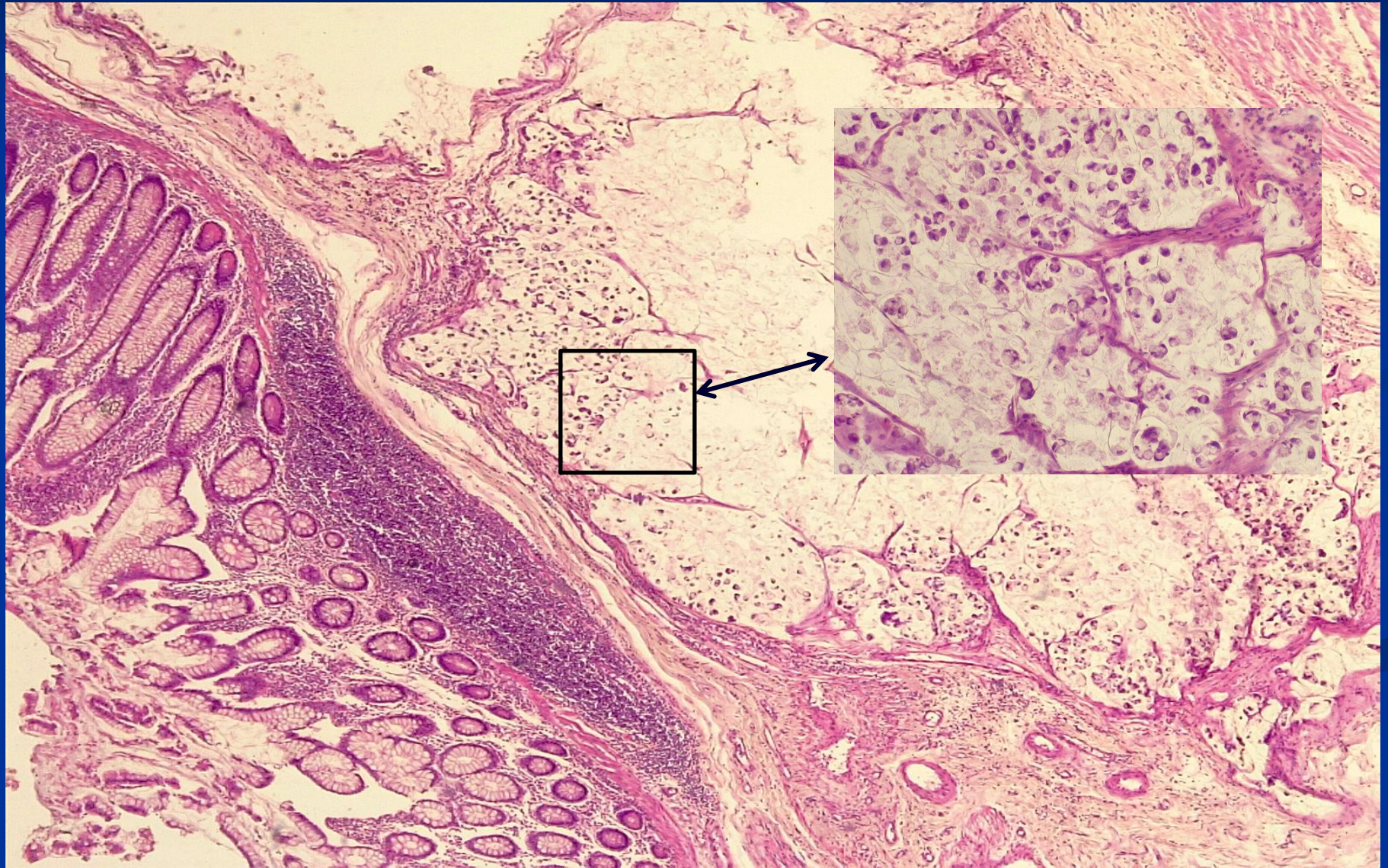




General histological characteristics of adenocarcinomas of the distal and proximal colon are similar. Most tumors consist of tall cylindrical cells resembling the dysplastic epithelium found in adenomas. The invasive component of these tumors causes a pronounced desmoplastic reaction of the stroma, which provides a characteristic dense consistency.



Some low-grade tumors form just a few glands, while others can produce mucus that builds up in the intestinal wall. Such adenocarcinomas have a poor prognosis. Tumors can also consist of signet ring cells, similar to those in similar tumors of the stomach.



## Tumor Stage

## Histologic Features of the Neoplasm

<b>Tis</b>	<b>Carcinoma in situ (high-grade dysplasia) or intramucosal carcinoma (lamina propria invasion)</b>
<b>T1</b>	<b>Tumor breaches the musc. Muc. invades into submucosa</b>
<b>T2</b>	<b>Extending into the muscularis propria but not penetrating through it</b>
<b>T3</b>	<b>Penetrating through the muscularis propria into subserosa</b>
<b>T4</b>	<b>Tumor directly invades other organs or structures</b>
<b>Nx</b>	<b>Regional lymph nodes cannot be assessed</b>
<b>N0</b>	<b>No regional lymph node metastasis</b>
<b>N1</b>	<b>Metastasis in 1 to 3 lymph nodes</b>
<b>N2</b>	<b>Metastasis in 4 or more lymph nodes</b>
<b>Mx</b>	<b>Distant metastasis cannot be assessed</b>
<b>M0</b>	<b>No distant metastasis</b>
<b>M1</b>	<b>Distant metastasis</b>



# OTHER TUMORS

- **CARCINOID**, with or without syndrome
- **LYMPHOMA (MALTOMAS, B-Cell)**
- **LEIOMYOMA/-SARCOMA**
- **LIPOMA/-SARCOMA**

# ANAL CANAL CARCINOMAS

- MORE LIKELY TO BE SQUAMOUS, or “basaloid”
- WORSE IN PROGNOSIS
- HPV RELATED