

Acute pulmonary pathology. Air-transmitted infections.

I. Microspecimens:

№ 73. Lobar pneumonia (grey hepatization stage). (H-E stain).

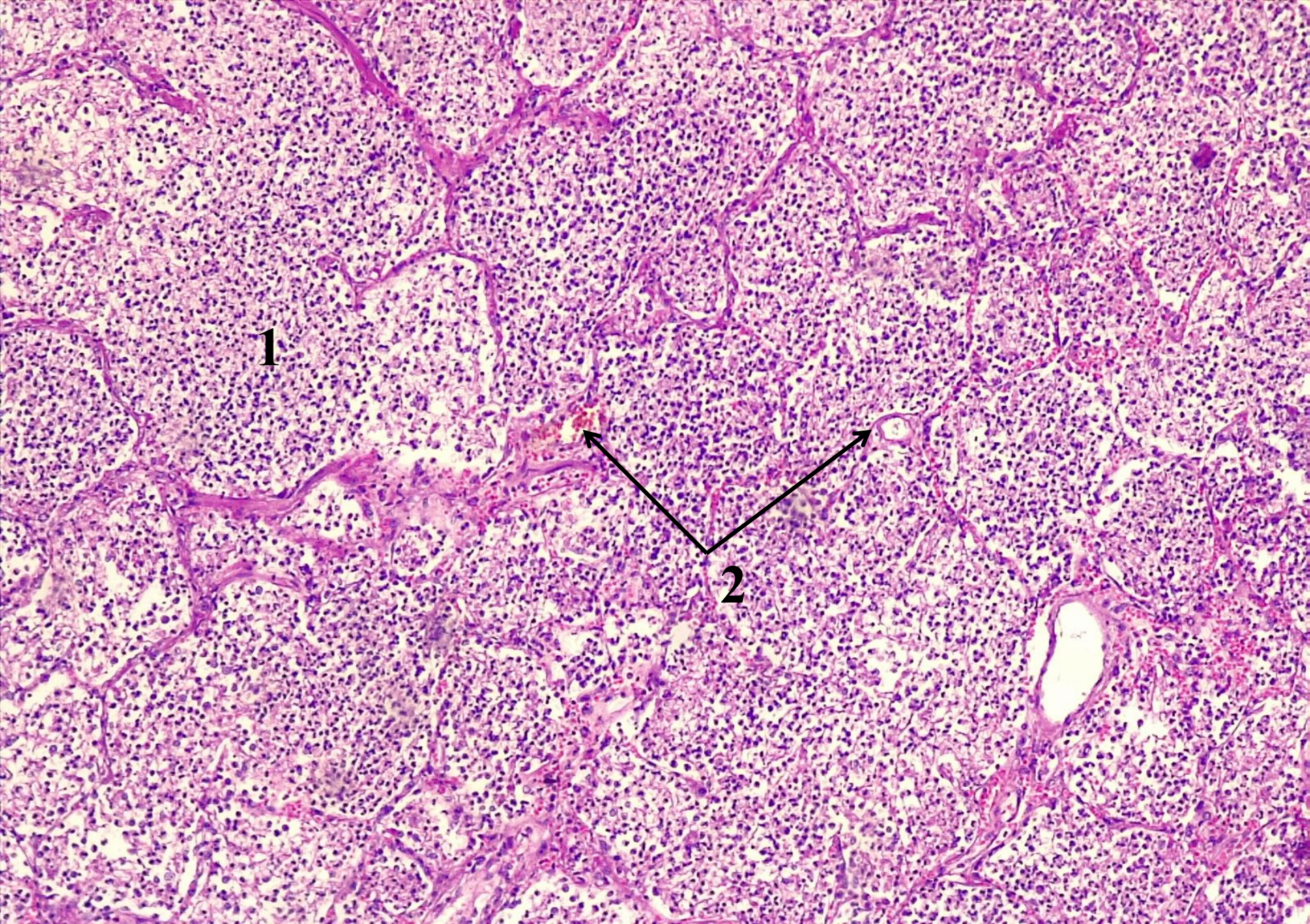
Indications:

1. Exudate into lumen of alveoli:
 - a. fibrin strands; b. neutrophils; c. alveolar macrophages.
2. Hyperemic vessels in interalveolar septa.

In microspecimen it is observed that all alveoli are dilated, unventilated, filled with an exudate consisting of eosinophilic colored fibrin filaments, neutrophilic leukocytes and an insignificant number of alveolar macrophages; the interalveolar septa are thickened, the blood vessels are dilated, hyperemic.

The gray hepatization stage of lobar pneumonia (macroscopic appearance - macrospecimen № 33) is installed over 4-5 days from the onset of the disease. Subsequently, in uncomplicated cases, on the 8-9th day begins the lysis of the exudate by the fibrinolytic action of leukocytes and macrophages and its elimination by lymphatic drainage and sputum. Finally, there is purification of the affected lung and restoration of aeration, which can last 1-3 weeks.

Pleural fibrinous exudate is resorbed or organized with the formation of fibrous adhesions between the pleural sheets. In about 3% of cases the alveolar exudate does not liquefy and is replaced by granulation tissue, which turns into mature fibrillar connective tissue - post-pneumonic fibrosis. Other possible lung complications are pulmonary abscess and pleural empyema. Extrapulmonary complications: purulent pericarditis, mediastinitis, bacterial endocarditis, hematogenous spread of infection with the development of otitis media, meningitis, brain abscess, purulent arthritis. Complications usually develop in patients with low immunity.



№ 73. Lobar pneumonia (*grey hepatization stage*). (*H-E stain*).

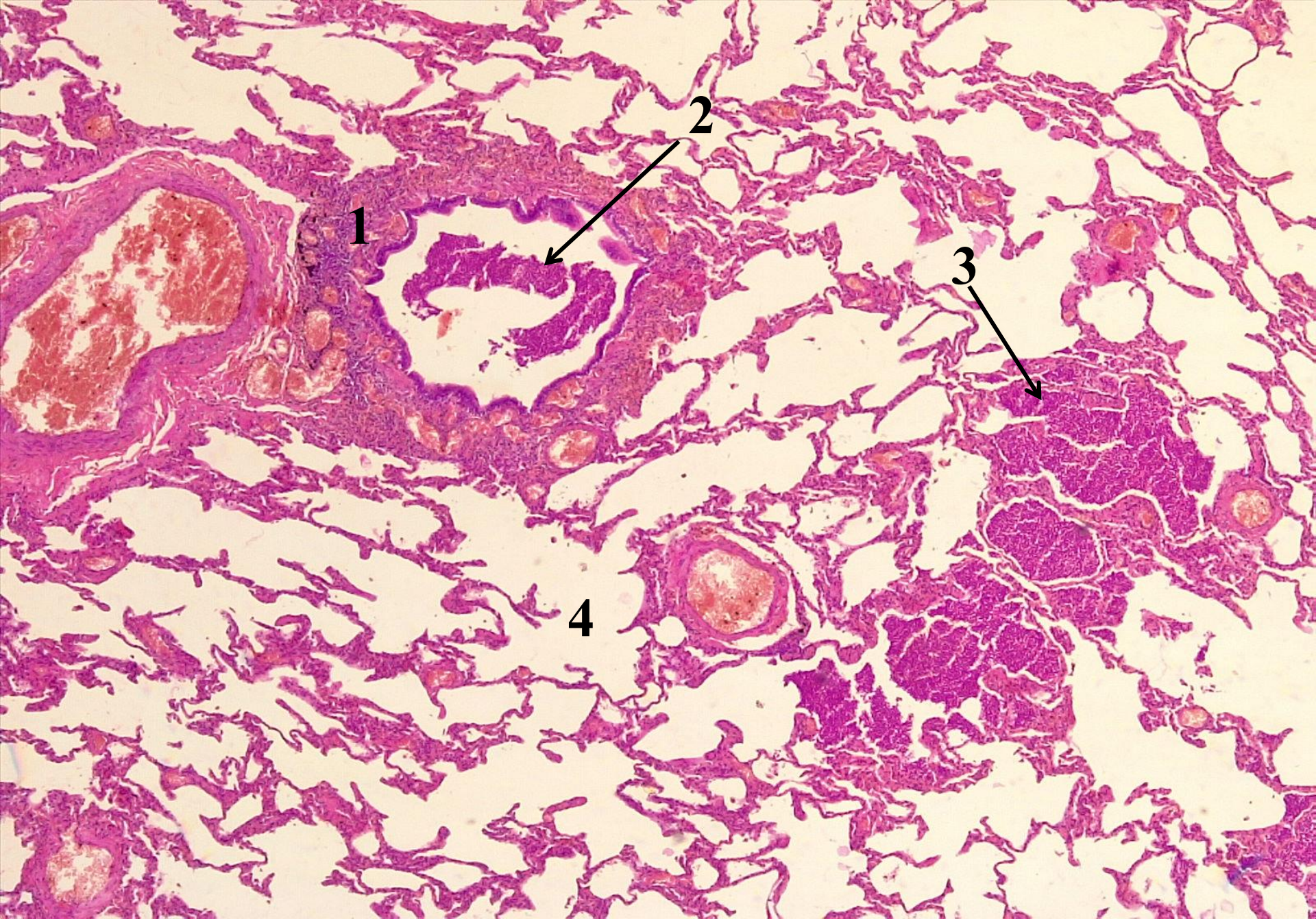
№ 74. Bronchopneumonia (*focal pneumonia*). (*H-E stain*).

Indications:

1. Inflammatory infiltrate in the wall of small caliber bronchus (bronchiolus).
2. Exudate into the lumen of the bronchi.
3. Predominantly leukocytic exudate around the bronchi into the alveoli.
4. Unchanged alveoli.

In the lumen of small caliber bronchi (bronchioles) is observed predominantly leukocytic (neutrophilic) exudate, the epithelium in some places is desquamated, the walls are thickened, in their thickness is inflammatory infiltrate rich in lymphocytes and macrophages, dilated and hyperemic blood vessels; around these bronchi or in their vicinity are unventilated foci, the alveoli contain abundant leukocytic (neutrophilic) exudate, in the adjacent areas some alveoli are dilated.

Bronchopneumonia is the most common form of pneumonia, which begins with the initial inflammation of the bronchi and bronchioles with subsequent expansion into the adjacent alveoli (broncho-alveolitis). Inflammation can spread endobronchially, e.g. in catarrhal or peribronchial bronchitis / bronchiolitis, e.g. in destructive purulent bronchitis / bronchiolitis; it can also occur hematogenously when the infection is generalized, e.g. septic pneumonia. Inflammation is unevenly distributed, there may be foci spread in several lung lobes, primarily in the lower ones. It is a polyetiological condition, the most common being of bacterial origin (staphylococci, streptococci, pneumococci, Klebsiella pneumoniae), but it can also be caused by viruses (eg, influenza, measles), fungi, mycoplasmas. Intraalveolar exudate has a polymorphic composition, containing serous fluid, mucus, neutrophil leukocytes, macrophages, erythrocytes, fibrin, desquamated epithelial cells. It is much more common in the extremes ages (the elderly and children). A favorable role is played by aspiration (aspiration pneumonia), pulmonary stasis (hypostatic pneumonia), surgery (postoperative pneumonia), immunodeficiency states (immunodeficiency pneumonia). Complications of bronchopneumonia are identical to those of lobar pneumonia (microspecimen № 73). In cases of subpleural localization of pneumonic foci, fibrinous pleuritis may develop, and bronchiectasis may occur in connection with the destruction of the walls of the bronchi / bronchioles.



№ 74. Bronchopneumonia (*focal pneumonia*). (H-E stain).

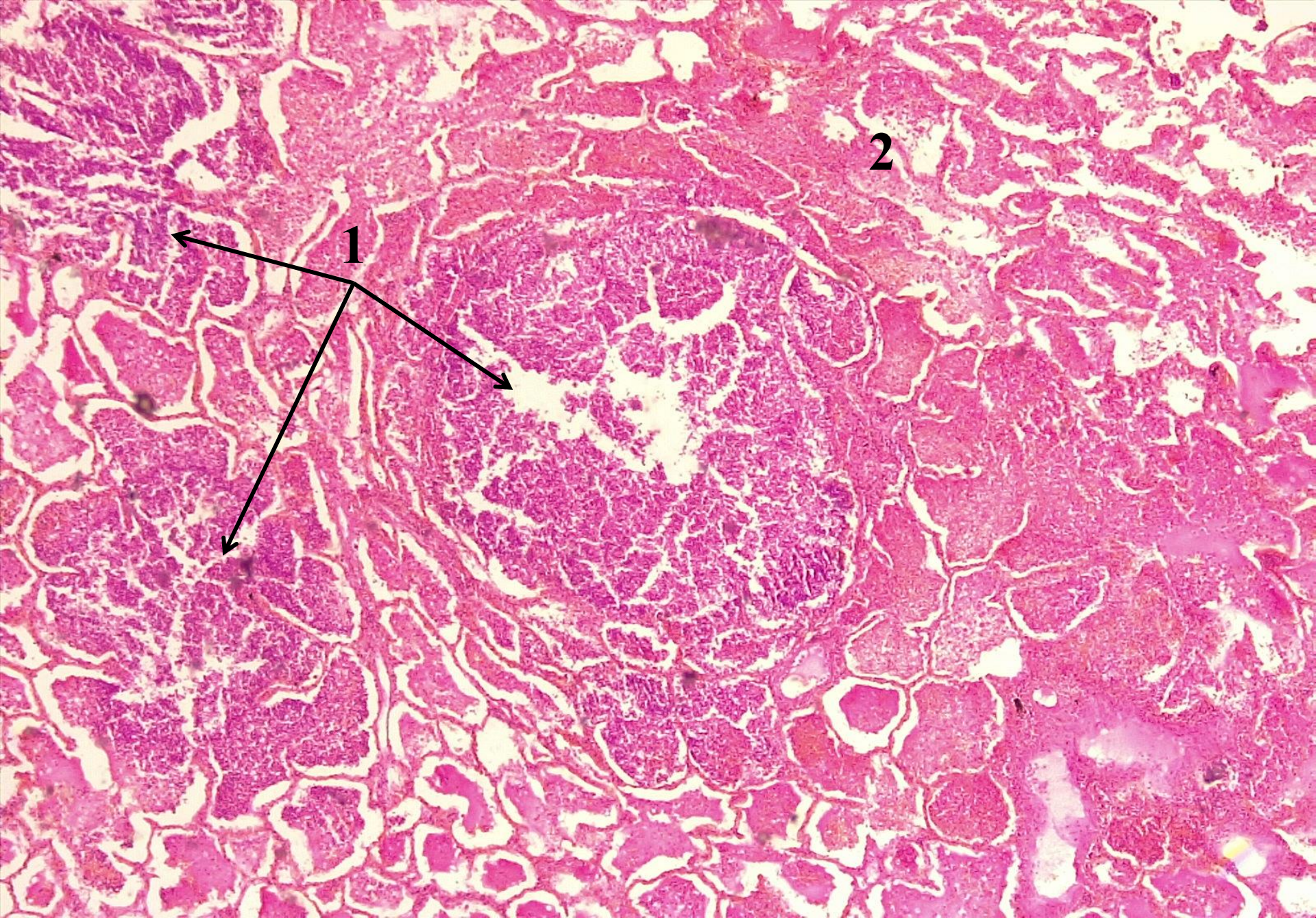
№ 126. Bronchopneumonia with abscess formation. (*H-E stain*).

Indications:

1. Focus of purulent inflammation with lysis of the lung parenchyma (abscess).
2. Adjacent alveoli with inflammatory exudate.

In microspecimen are extensive areas of pneumonia with abundant intraalveolar exudate of fibrin and neutrophilic leukocytes; in these areas there are several foci of different sizes, in which the interalveolar septa are necrotic and lysed, forming cavities with purulent content (microabscesses).

Bronchopneumonia with abscess formation is usually caused by staphylococci and streptococci. Abscesses occur as a result of necrosis, destruction and lysis of necrotic tissue. Necrosis is due to the direct harmful action on the tissues of toxins of pyogenic bacteria, as well as circulatory disorders related to vessel thrombosis and their compression by inflammatory edema. Histolysis occurs by proteolytic enzymes elimination by neutrophil leukocytes. It is more common in patients with various comorbidities, eg, congestive heart failure, chronic lung disease, diabetes, immunodeficiency, especially in elderly. It is often followed by a viral infection due to the association of the secondary bacterial infection. Consequences: organization, calcification of abscesses, chronic evolution (chronic abscess).



№ 126. Bronchopneumonia with abscess formation. (H-E stain).

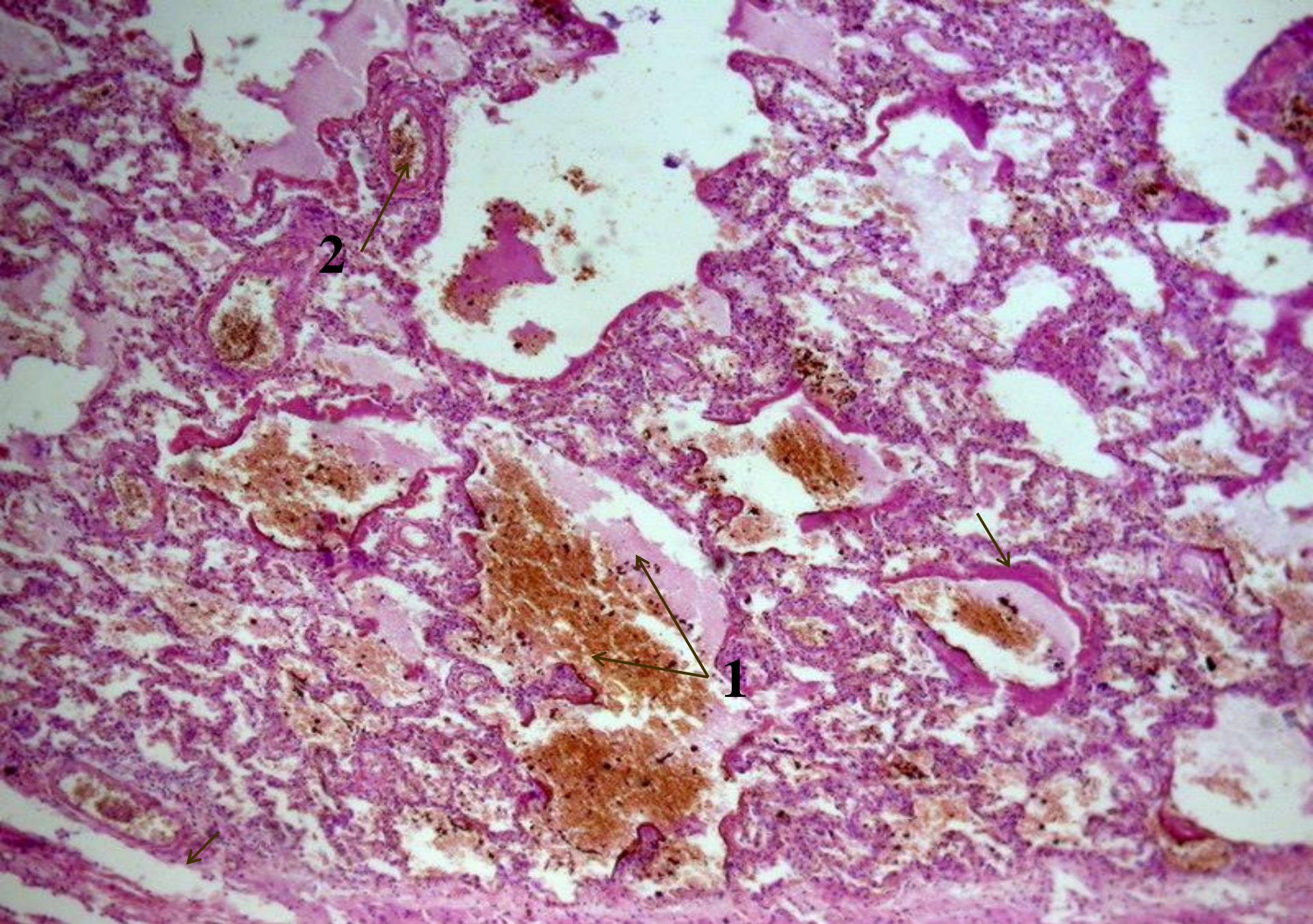
№ 106. Hemorrhagic pneumonia in influenza. (H-E stain).

Indications:

1. Inflammatory exudate into lumen of alveoli:
 - a. erythrocytes; b. serous fluid.
2. Adjacent lung tissue with hyperemic vessels.

In the alveoli is present exudate, consisting of eosinophilic colored serous fluid and erythrocytes, in some alveoli the serous fluid predominates, in others - erythrocytes; in many alveoli the walls are covered with a homogeneous, eosinophilic membrane, consisting of fibrin and coagulated plasma proteins (hyaline membranes); the blood vessels are dilated and hyperemic.

Pneumonia develops in severe forms of the flu. The influenza virus exerts a cytopathic (cytolytic) action on the airway epithelium, causing degeneration, necrosis and desquamation, as well as vasopathic and vasoparalytic action with severe circulatory disorders (hyperemia, stasis, and hemorrhage). These peculiarities of the virus condition the sero-hemorrhagic character of influenza pneumonias. The alternation of foci of pneumonia with foci of compensatory emphysema and atelectasis gives the lung a mottled appearance, hence the name "big mottled lung in flu". The virus also has a pronounced immunosuppressive effect, which determines the association of the secondary infection. Possible complications: pulmonary edema, acute respiratory failure and abscesses development.



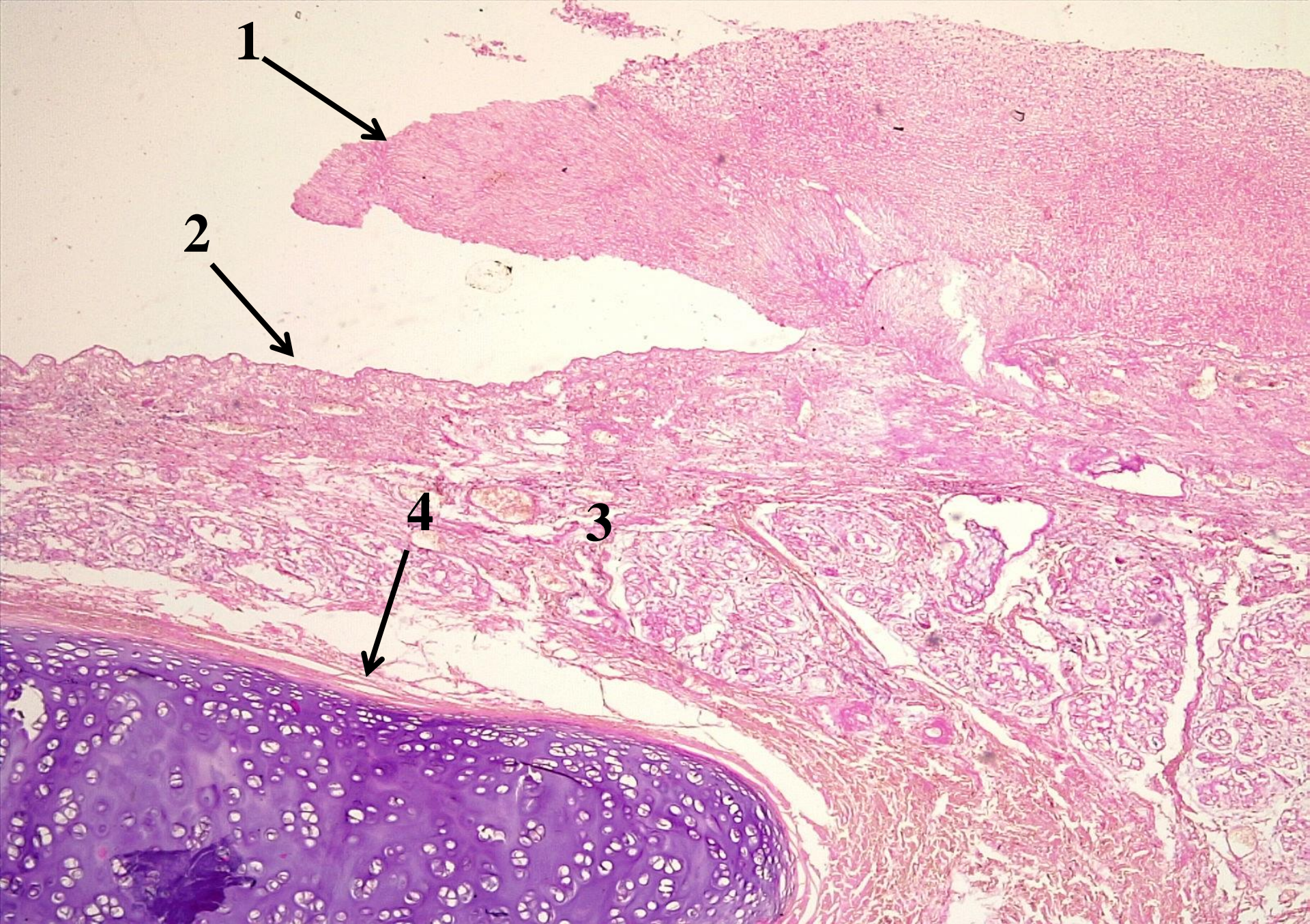
№ 106. Hemorrhagic pneumonia in influenza. (H-E stain).

№ 99. Croupous tracheitis in diphtheria. (*H-E stain*). Indications:

1. Fibrin deposits on the mucosa of the trachea.
2. Ulceration of the mucosa.
3. Edema and hemorrhage in submucosal layer.
4. Cartilaginous rings of the trachea.

The tracheal mucosa and submucosa are edematous, hyperemic, hemorrhagic foci are observed, the epithelium is sometimes necrotic and desquamated, forming ulcerative defects, covered with a layer of fibrin with a mixture of neutrophilic leukocytes and necrotic masses, which form a pseudomembrane.

Diphtheria is an acute infectious disease caused by the diphtheria bacillus - Corynebacterium diphtheriae, which eliminates exotoxin. The local effect of exotoxin consists of epithelial necrosis, extravasation of fibrinogen and the formation of pseudomembranes, consisting of fibrin and necrotic masses with a mixture of leukocytes, which macroscopically have a whitish-yellow color. Because the tracheal mucosa adheres loosely to the underlying connective tissue, the pseudomembranes are easily removed and expectorated by sputum (croupous fibrinous inflammation). Due to this fact in diphtheria, which affects the larynx, trachea and bronchi, no general intoxication is observed. There may be complications associated with the removal of pseudomembranes: laryngospasm, airway obstruction, pneumonia.



№ 99. Croupous tracheitis in diphtheria. (H-E stain).

II. Macrospecimens:

№ 33. Lobar pneumonia.

The affected lobe is enlarged in size, non-aerated, of firm consistency (similar to the consistency of the liver), on the section it has a granular appearance, gray color due to the storage in alveoli of fibrinous exudate with a rich content of neutrophils and macrophages; fine deposits of fibrin (parapneumonic fibrinous pleuritis) are observed on the pleura. [microscopic appearance - microspecimen № 73]

№ 31. Bronchopneumonia (focal pneumonia).

On cross section of the lung, single or multiple non-aerated foci are observed, sizes from 1-2 to 3-4 cm, slightly elevated of gray-yellow color, the adjacent lung tissue is normal or slightly edematous. [microscopic appearance - microspecimen № 74]

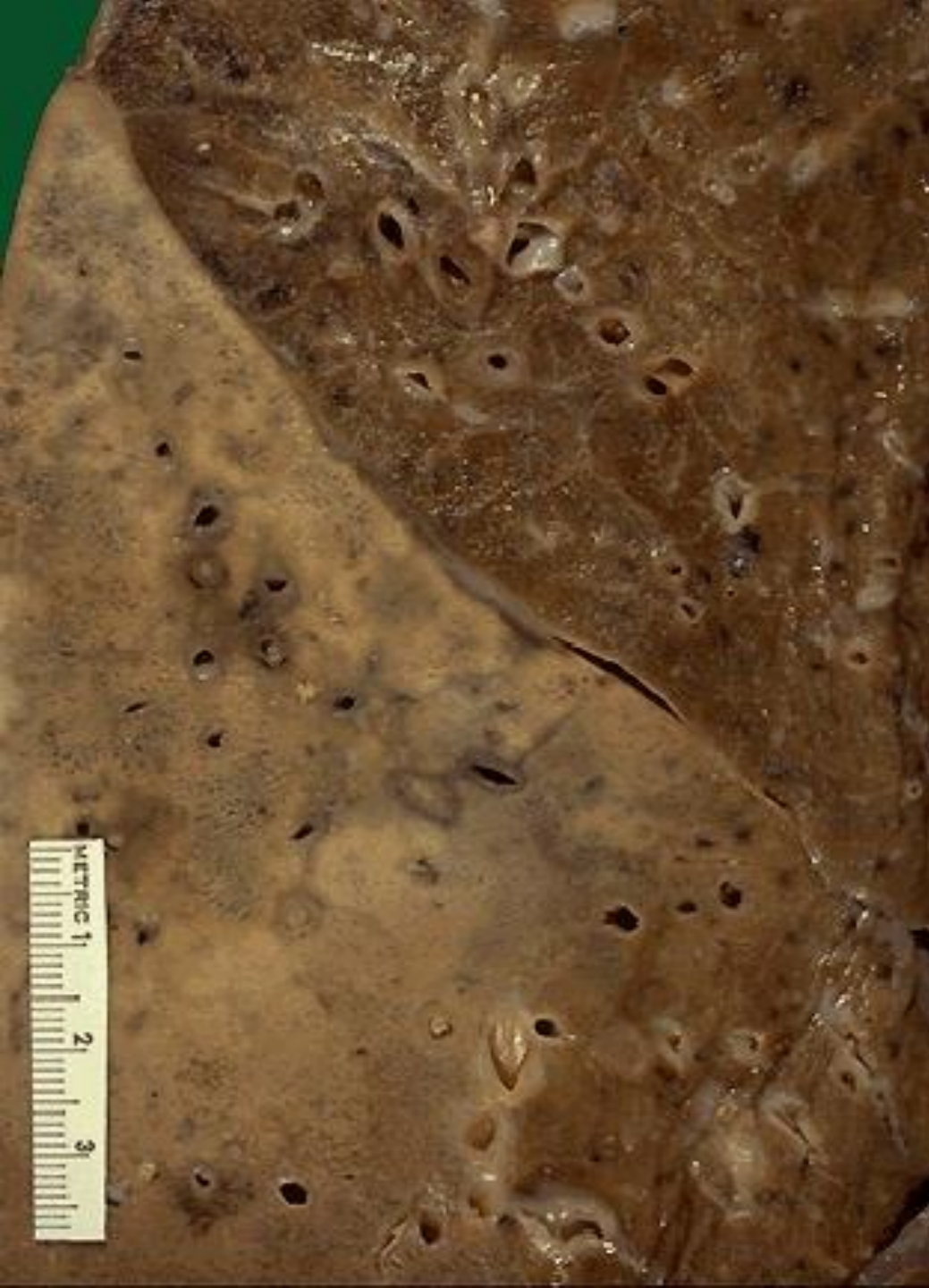
№ 32. Bronchopneumonia with abscess formation.

On the cross section disseminated foci of whitish-gray color are observed with a diameter of up to 2-3 cm, slightly elevated, separated by intact lung tissue. In some of these foci are irregularly shaped cavities, varying in size from 0.5 to 1-1.5 cm, filled with pus or without content - abscesses. In the pleura, in the case of subpleural localization of foci of pneumonia may be fibrin deposits. [microscopic appearance - microspecimen № 126]

№ 34. Fibrinous pleuritis.

The visceral sheet of the pleura is matte, covered with a thin membrane of whitish fibrin, sometimes glued to the pleura, and sometimes detached, which gives it a rough appearance.

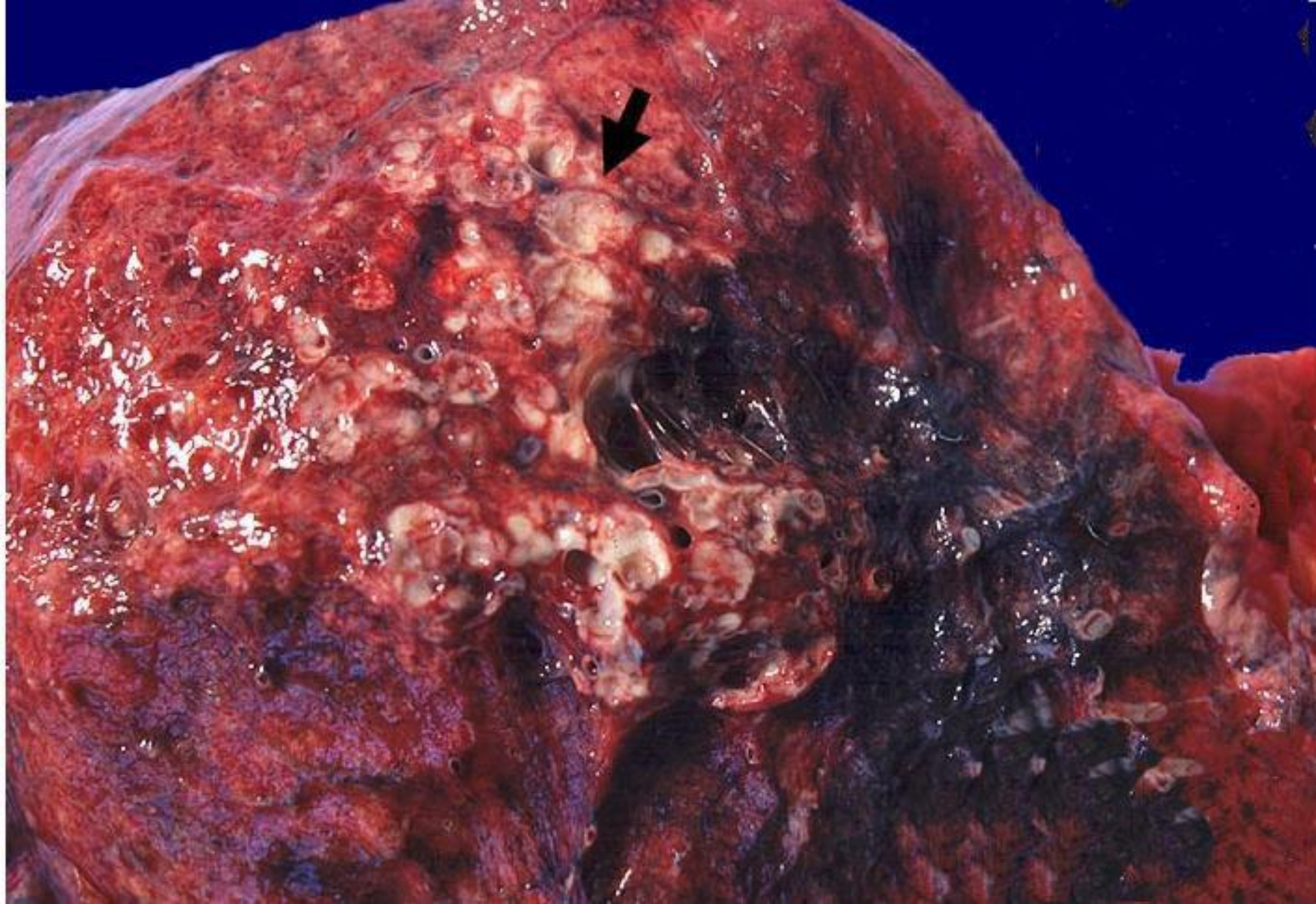
Fibrinous pleuritis in most cases is of infectious origin and is found in pneumonia, especially lobar, tuberculosis, infarction, lung abscess and bronchiectasis. It is also observed in some rheumatic diseases (rheumatoid arthritis, systemic lupus erythematosus), in uremia, cancer metastases. Manifested at auscultation by pleural rubbing noise. Consequences: resorption of exudate or fibrous organization with the appearance of adhesions between the pleural sheets with partial or total obliteration of the cavity. The formation of adhesions in the pleura reduces the amplitude of respiratory movements of the lungs.



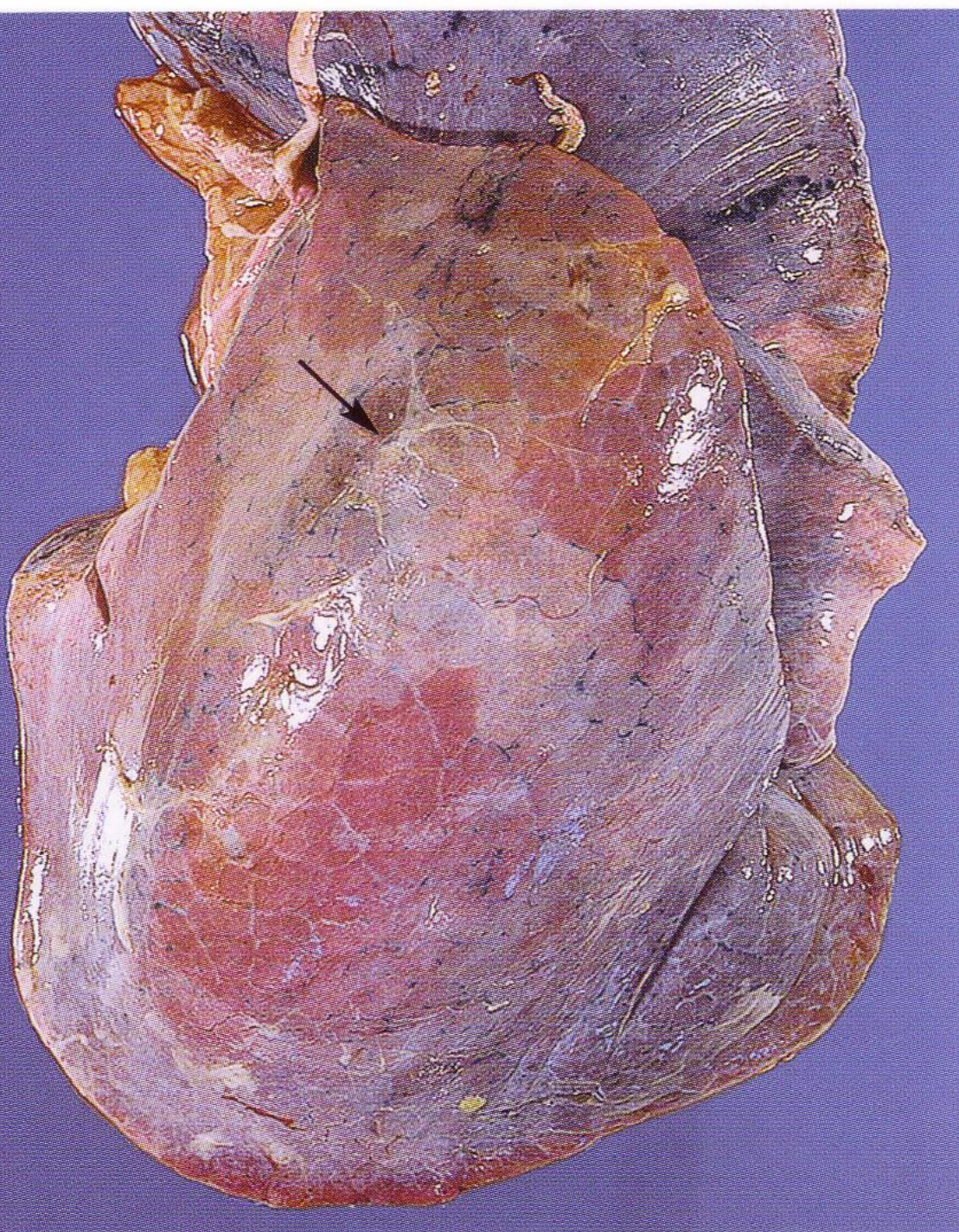
№ 33. Lobar pneumonia.



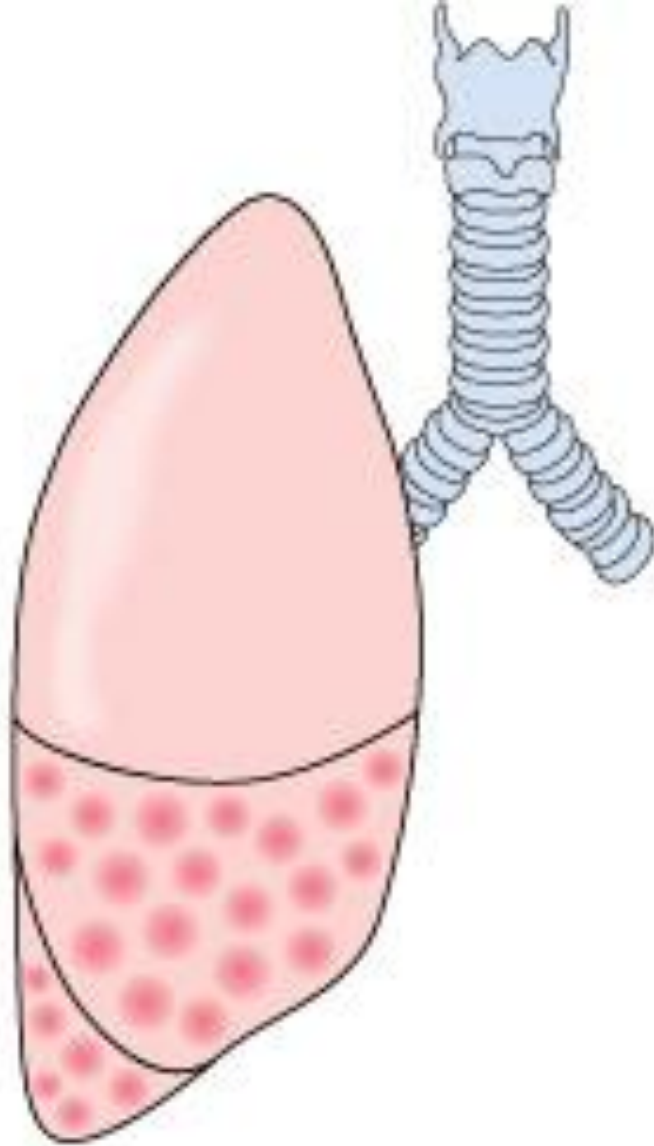
№ 31. Bronchopneumonia (focal pneumonia).



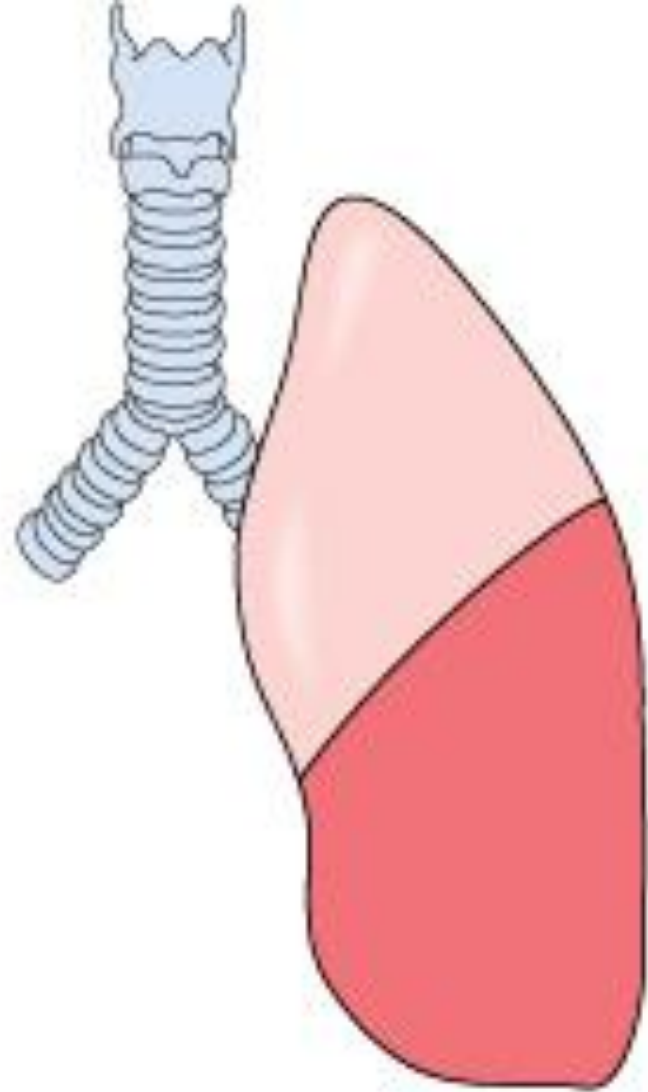
№ 32. Bronchopneumonia with abscess formation.



№ 34. Fibrinous pleuritis.

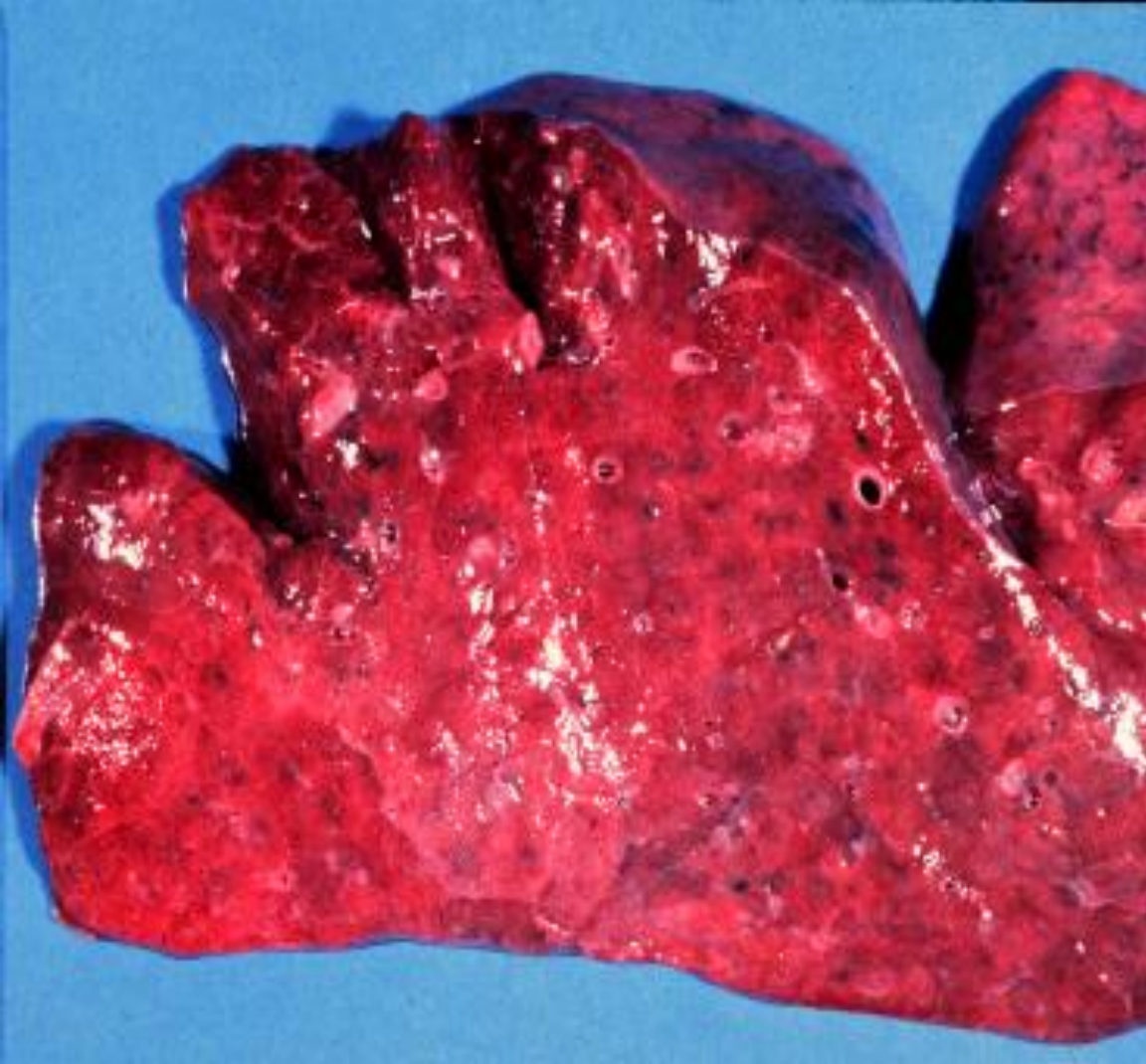

Bronchopneumonia

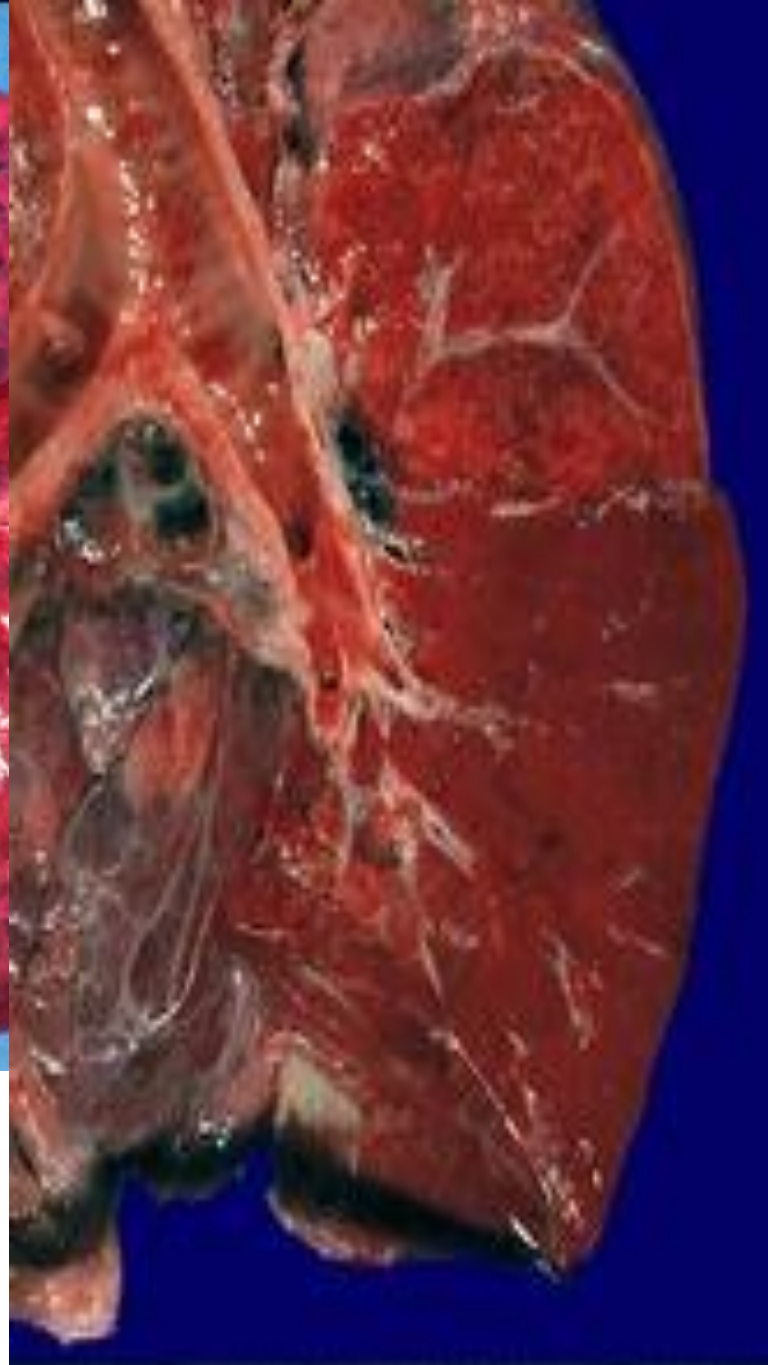

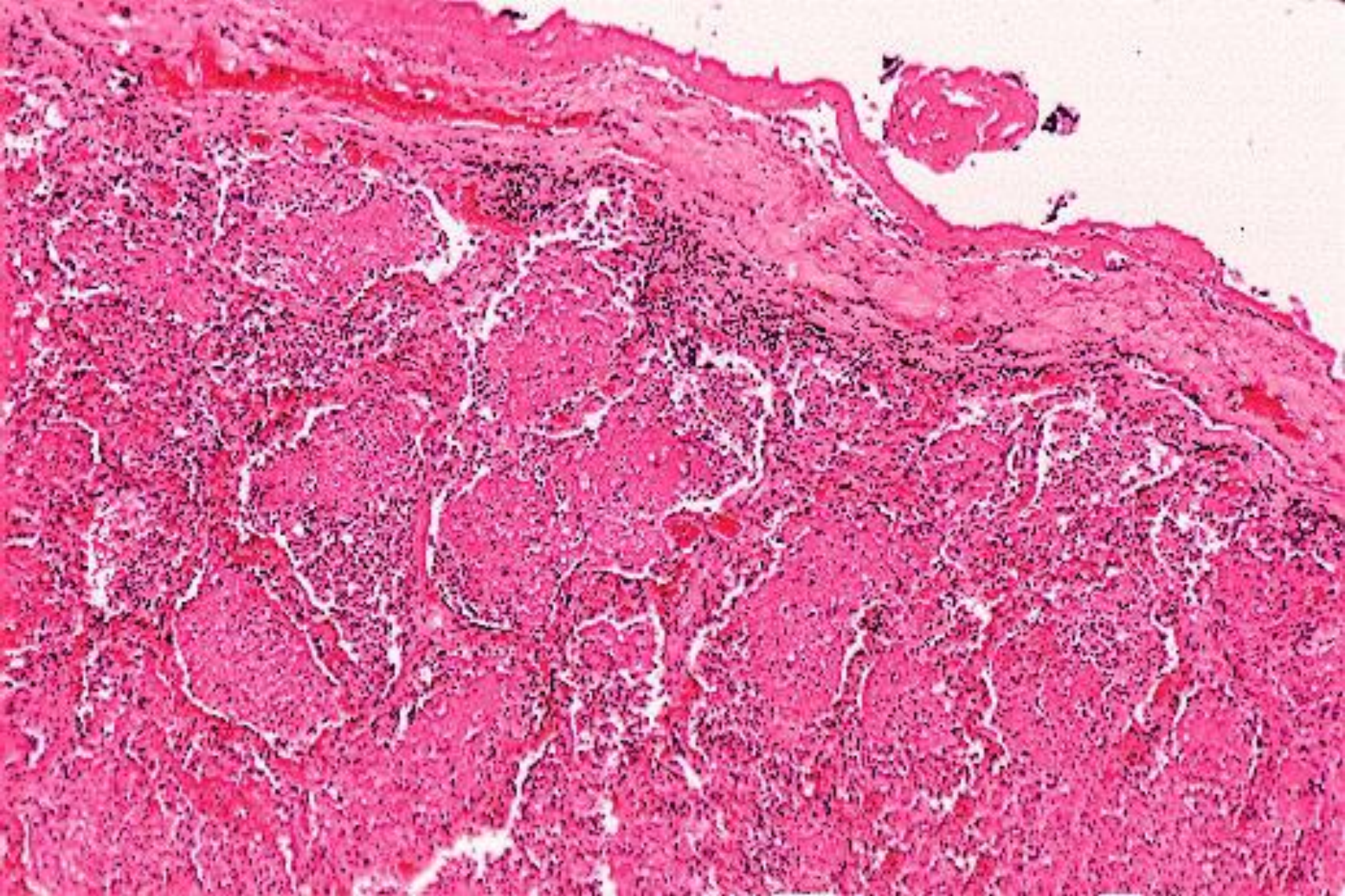
Lobar pneumonia

Schematic representation of bronchopneumonia and lobar pneumonia.

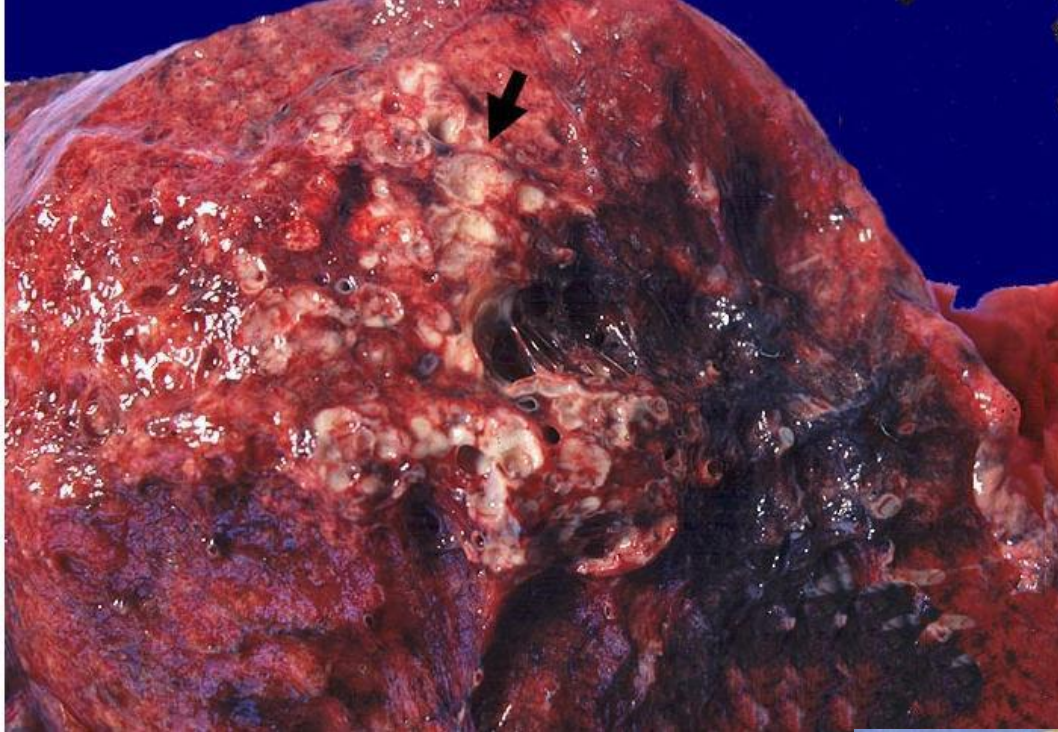


**Lobar pneumonia,
red hepatization stage.**

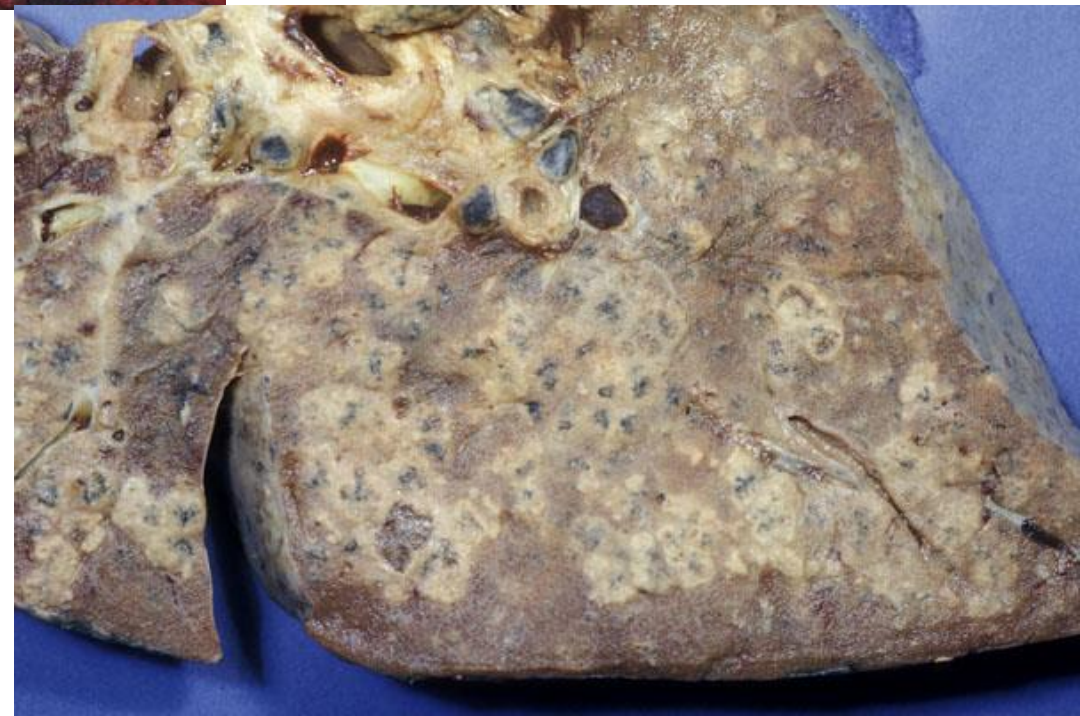

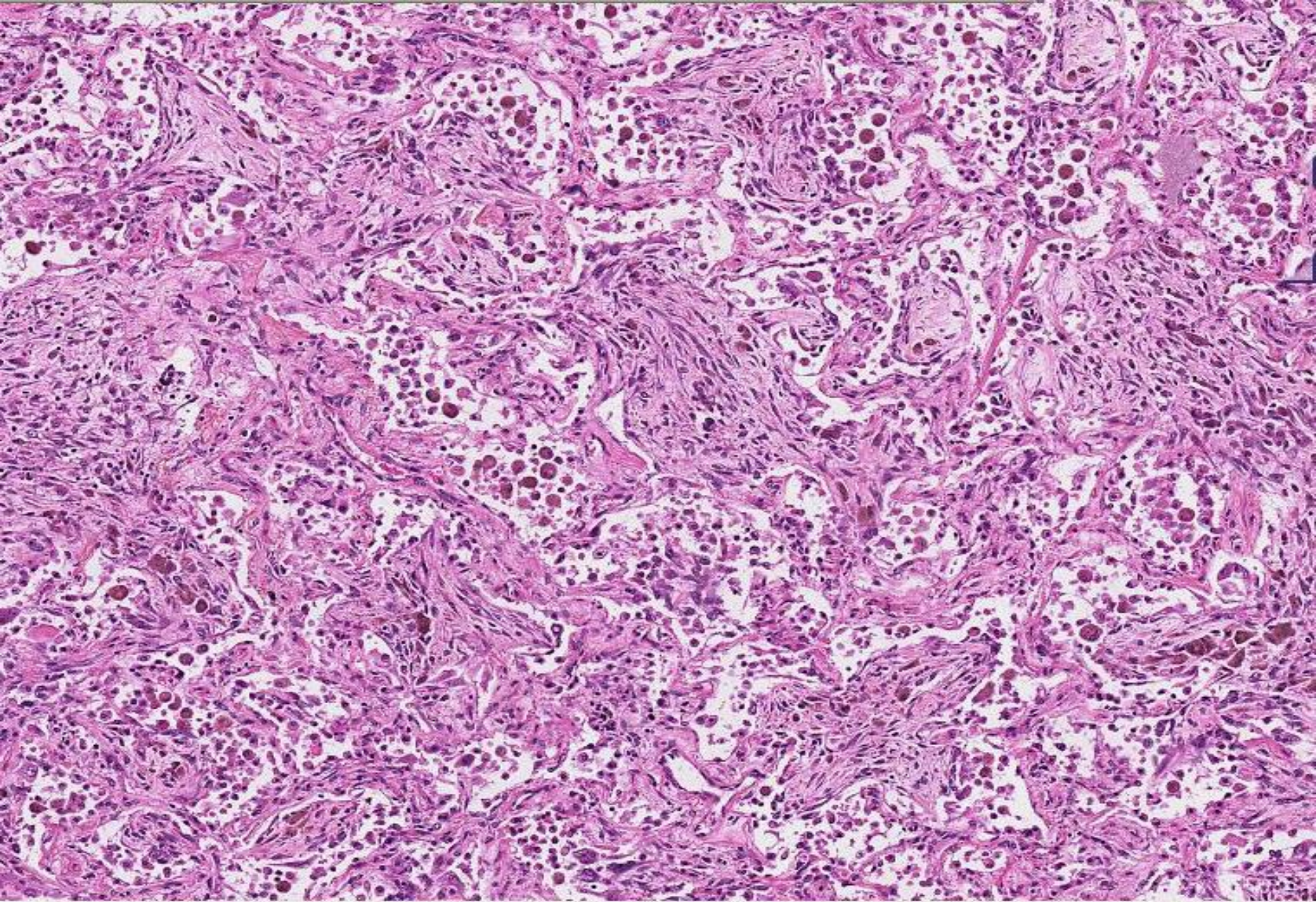


Lobar pneumonia, fibrino-leukocytic exudate in the alveoli, fibrinous pleurisy. (*H-E stain*).

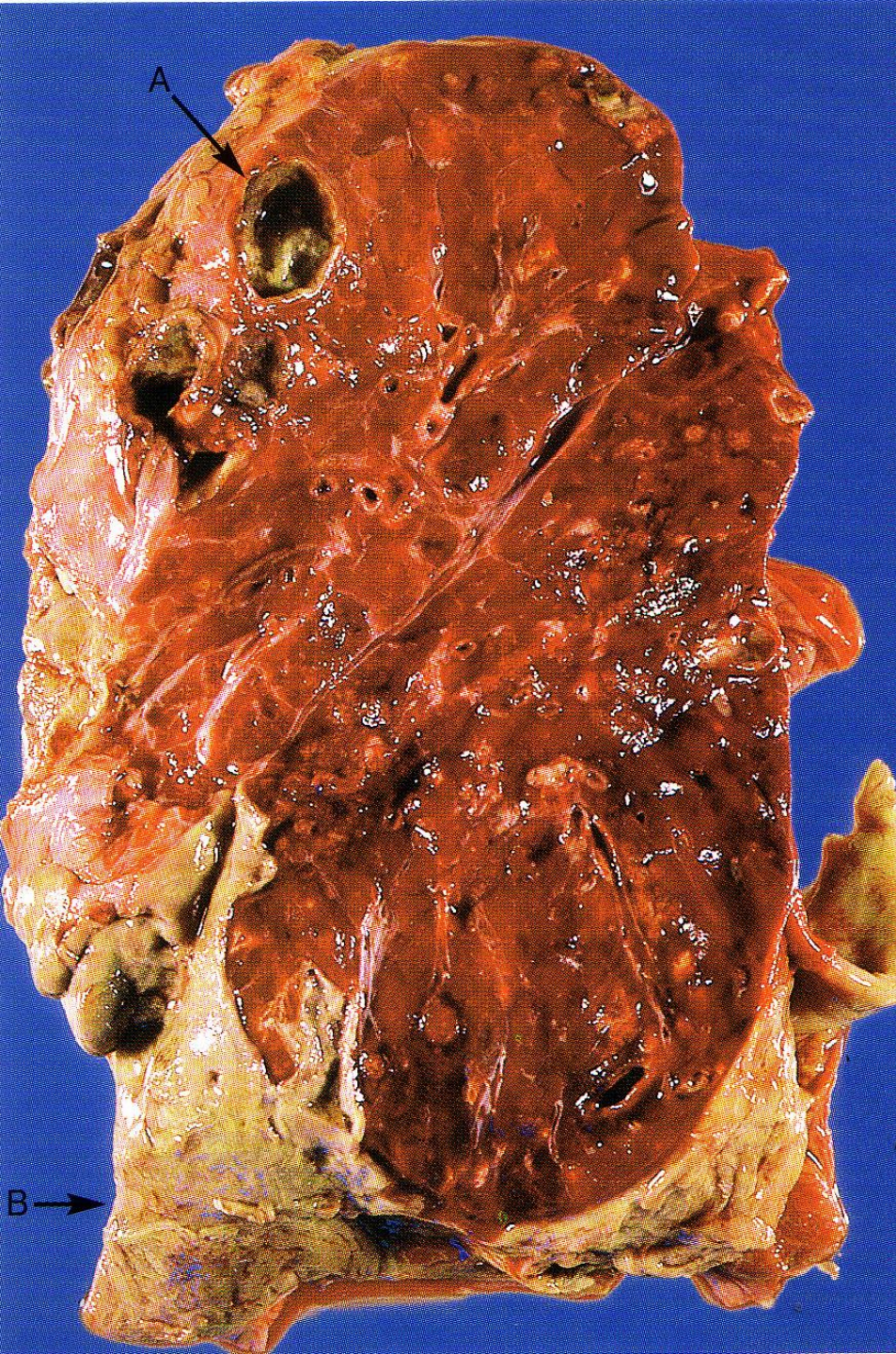

**Bronchopneumonia
with abscess formation.**

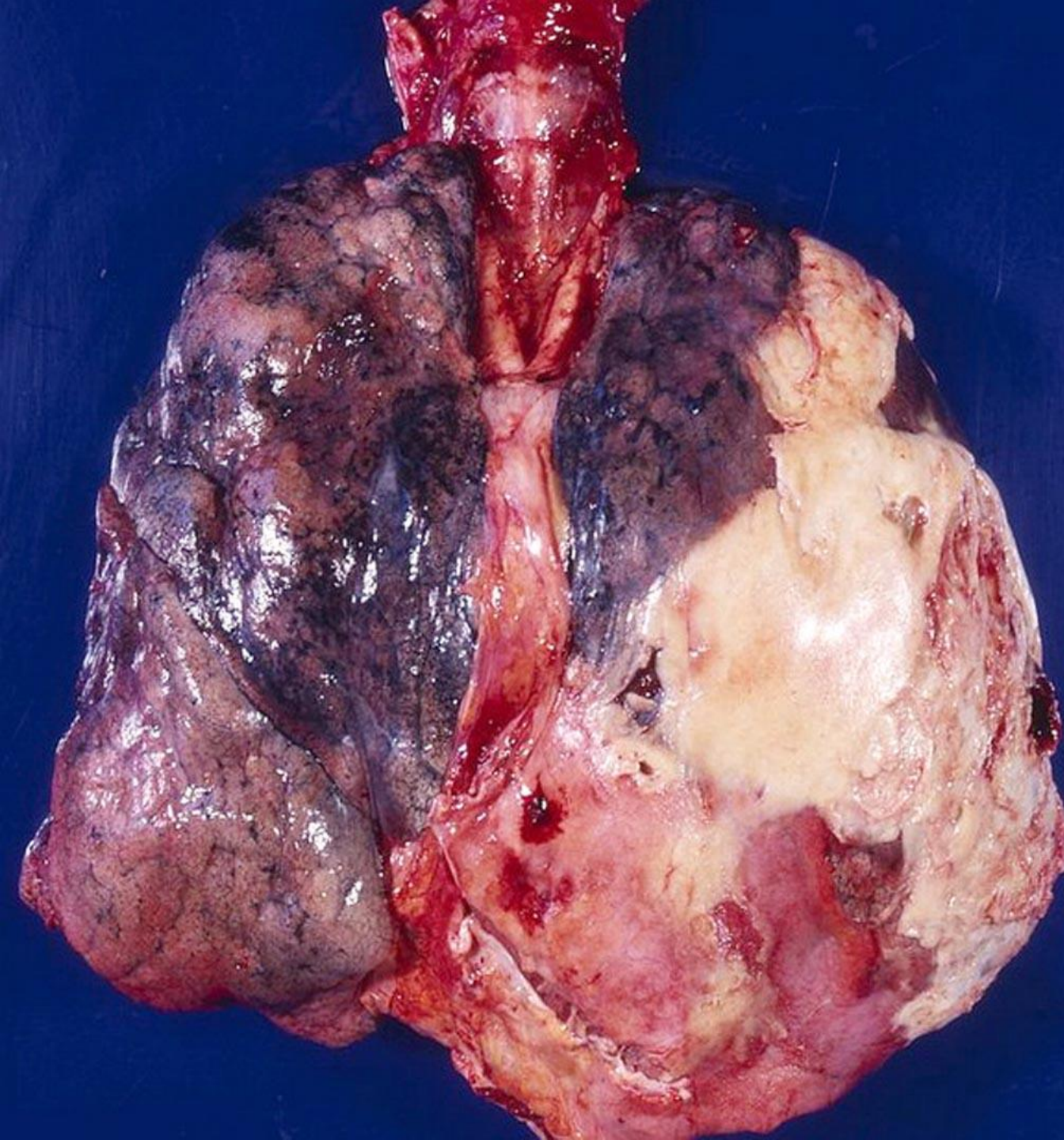




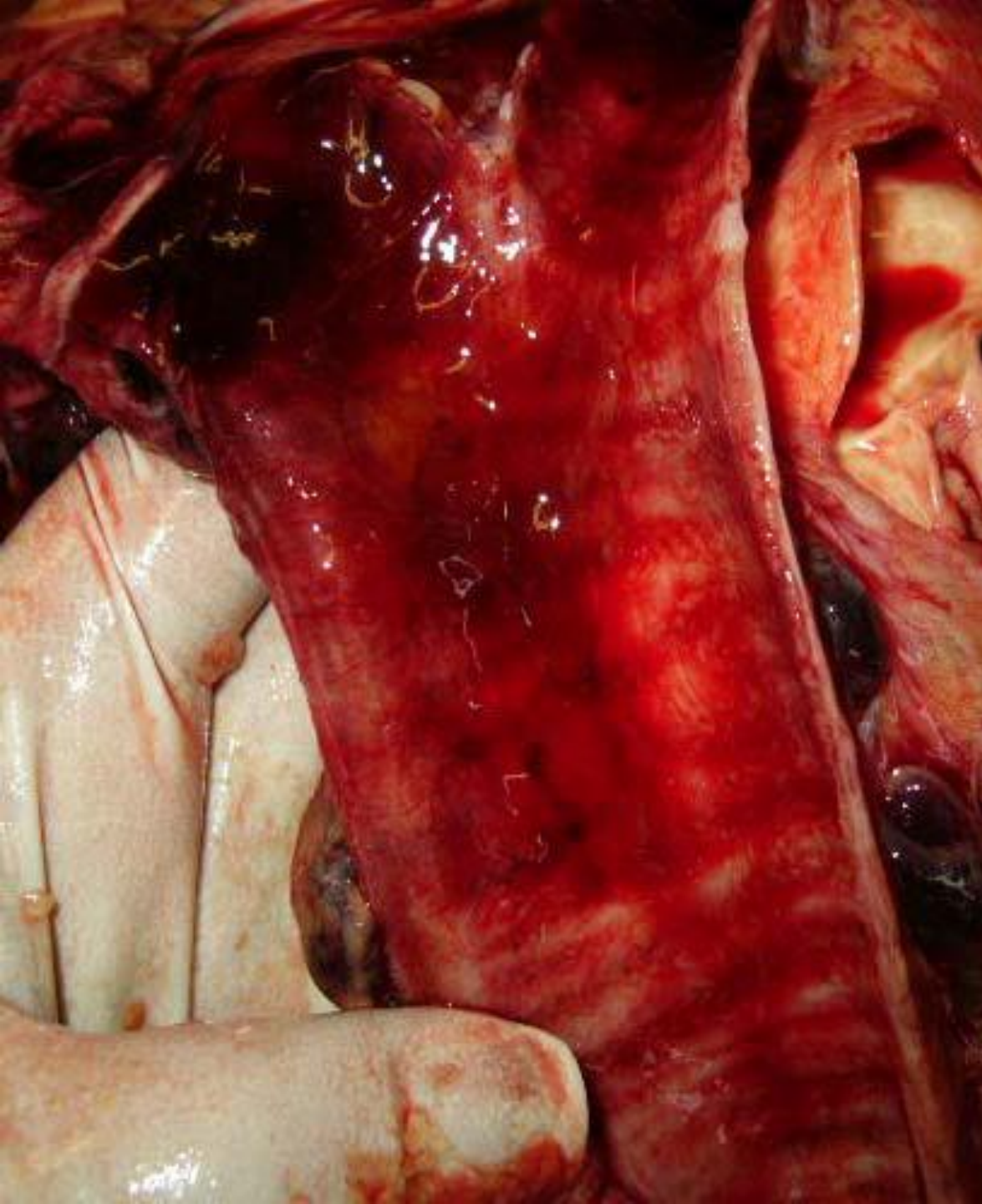
Pneumonia with exudate organization. (*H-E stain*).



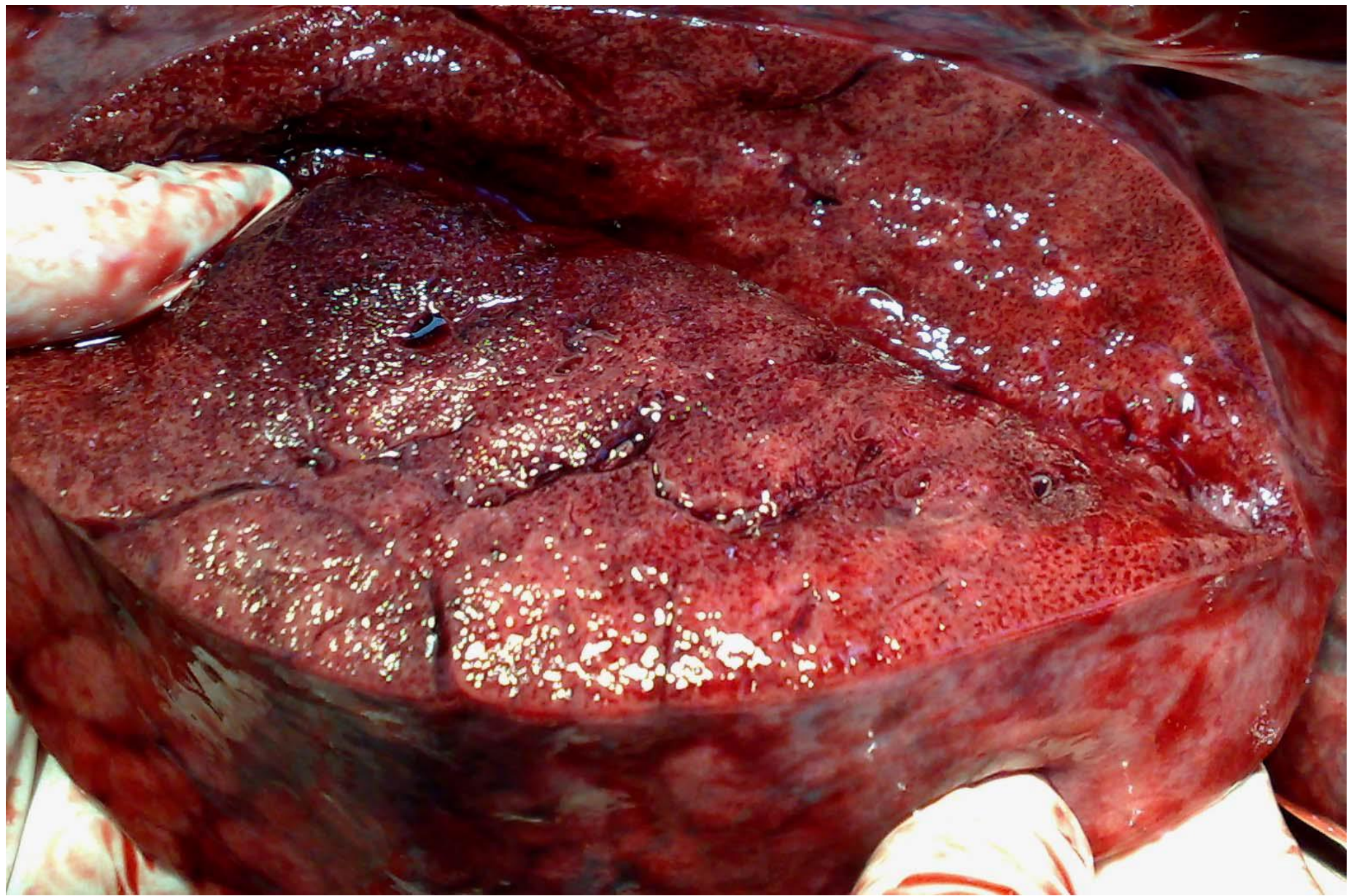
**Lung abscess (A),
Purulent pleurisy (B).**



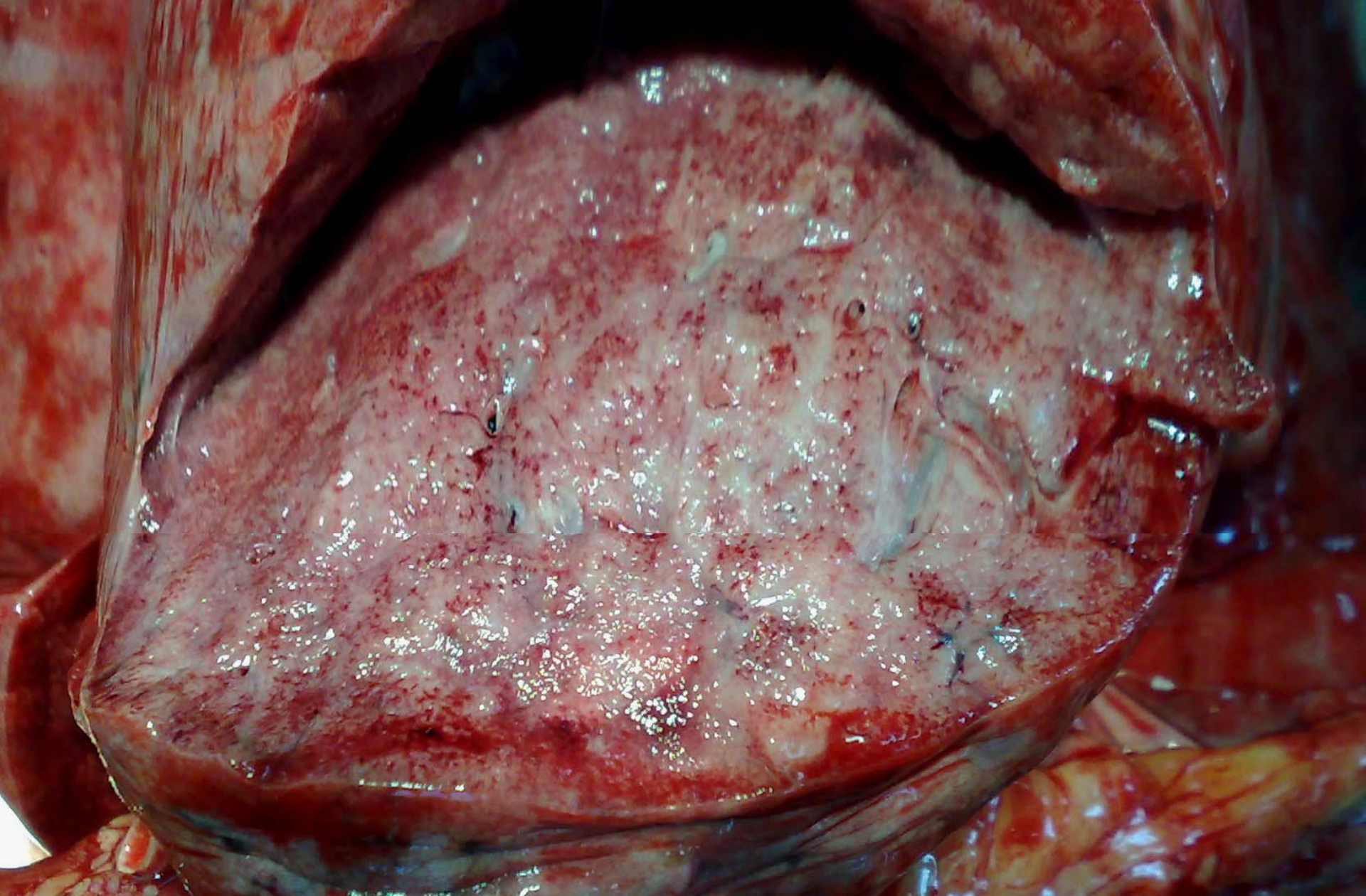
**Purulent pleurisy,
pleural empyema.**



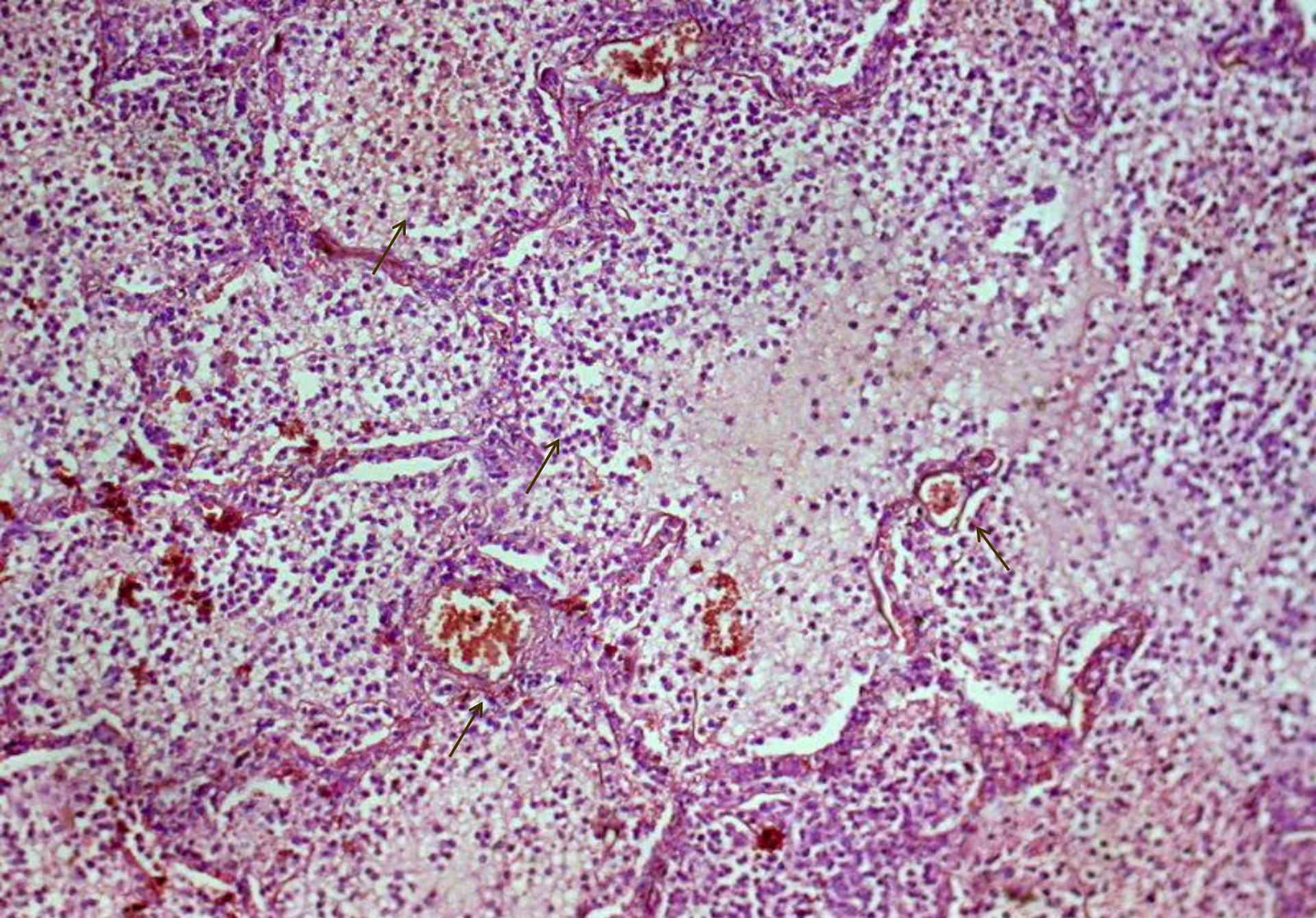
**Influenza
hemorrhagic
tracheobronchitis.**



Big mottled lung in influenza.

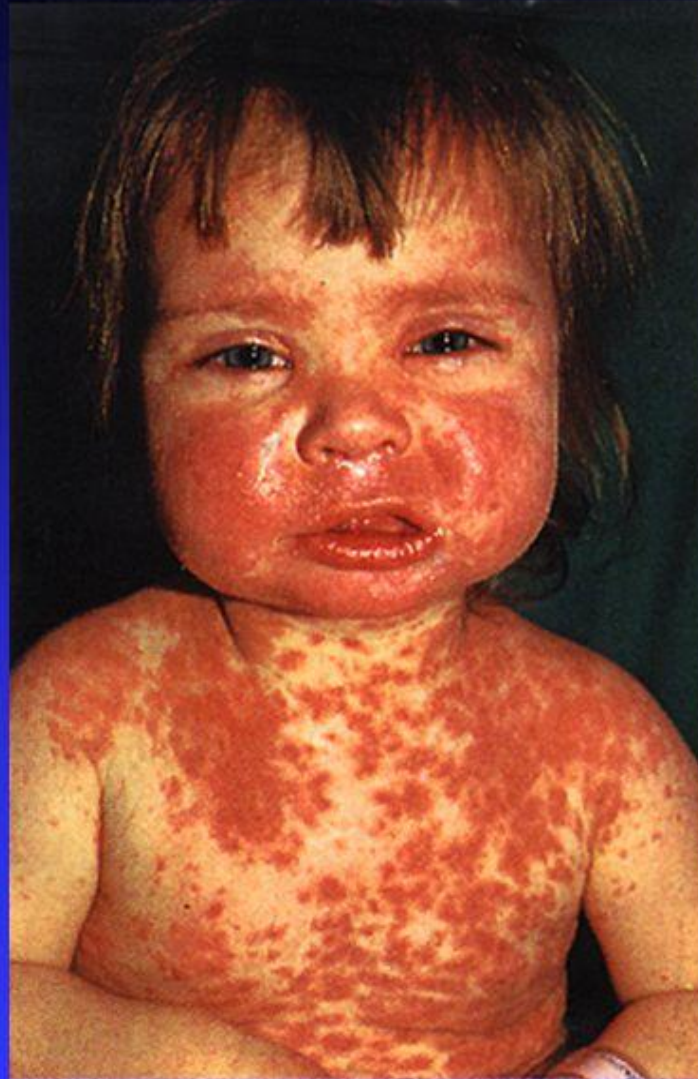

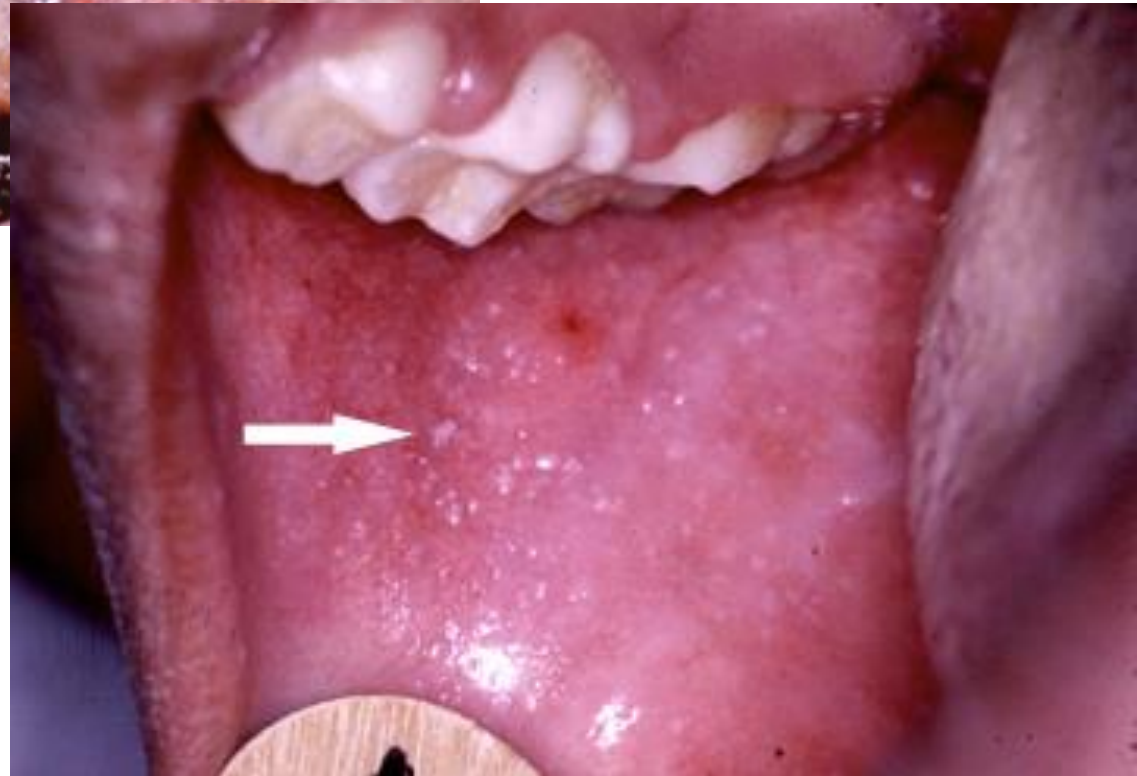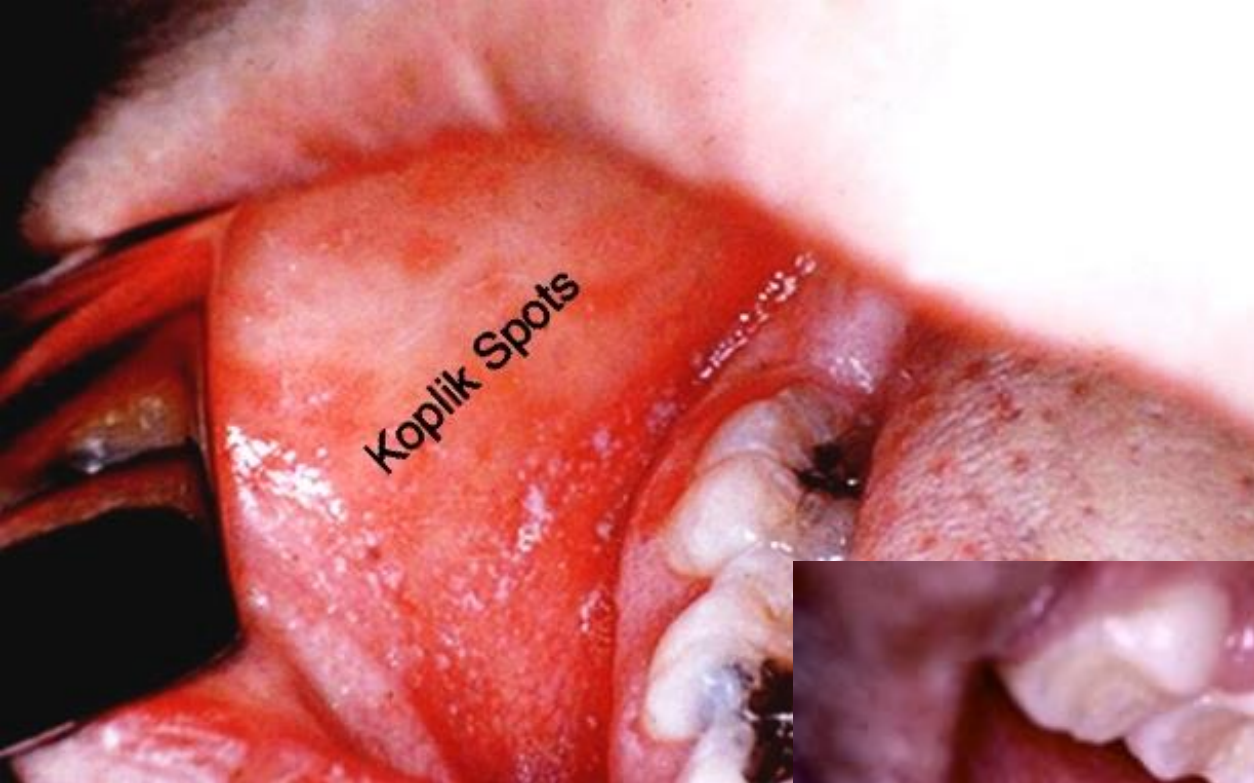Lung in the proliferative stage of the diffuse alveolar lesion in influenza.



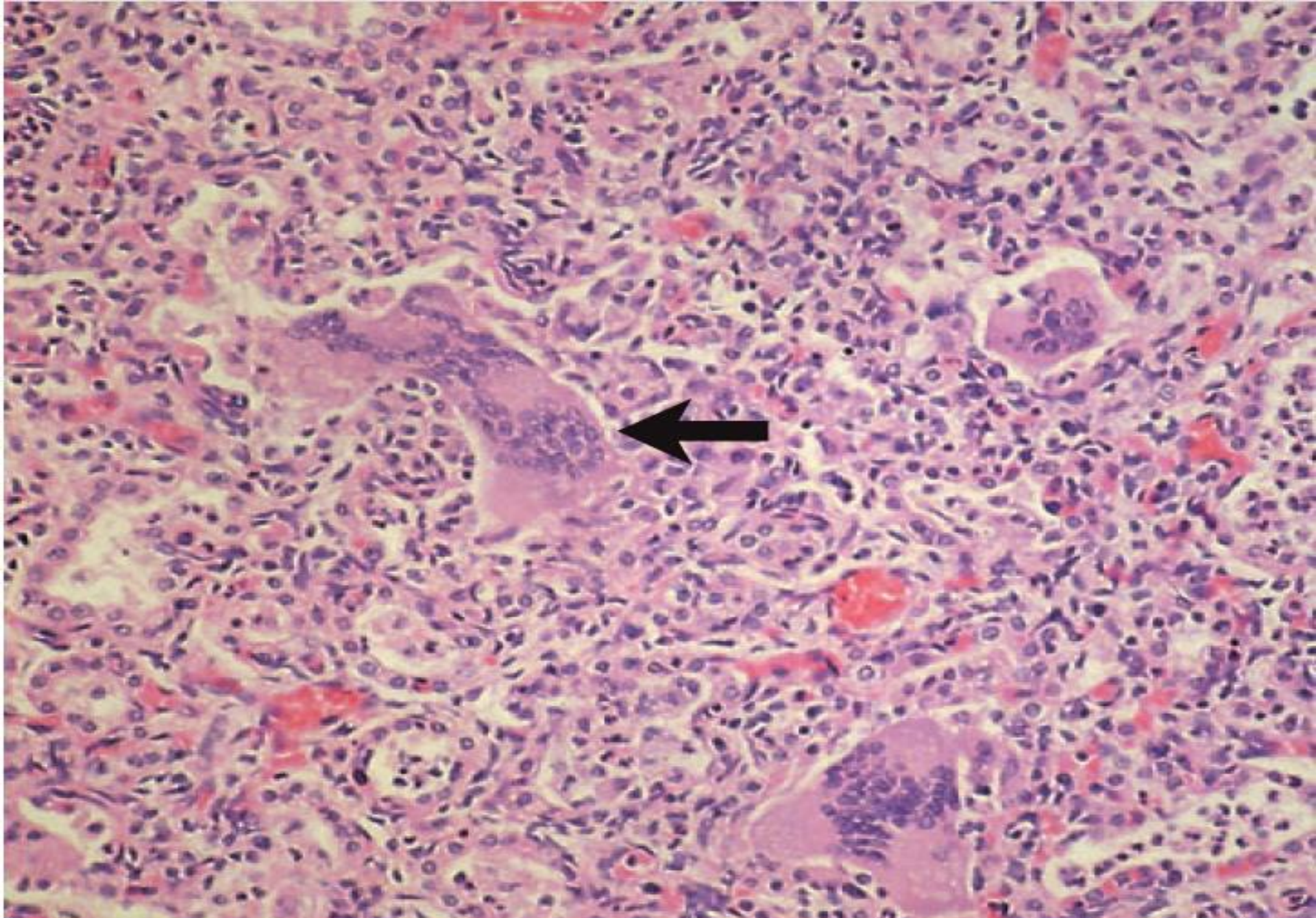
Influenza pneumonia associated with secondary infection.

Measles: Rash, conjunctivitis, and rhinitis





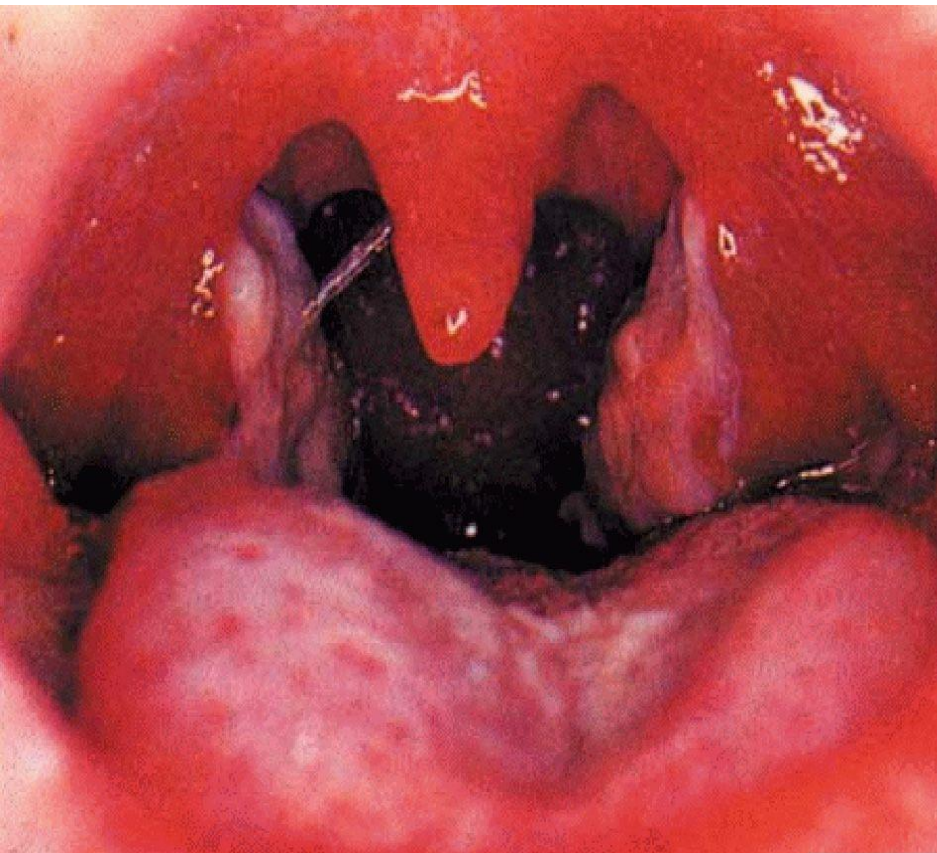
Measles enanthem (*whitish spots on the mucosa of the oral cavity*).



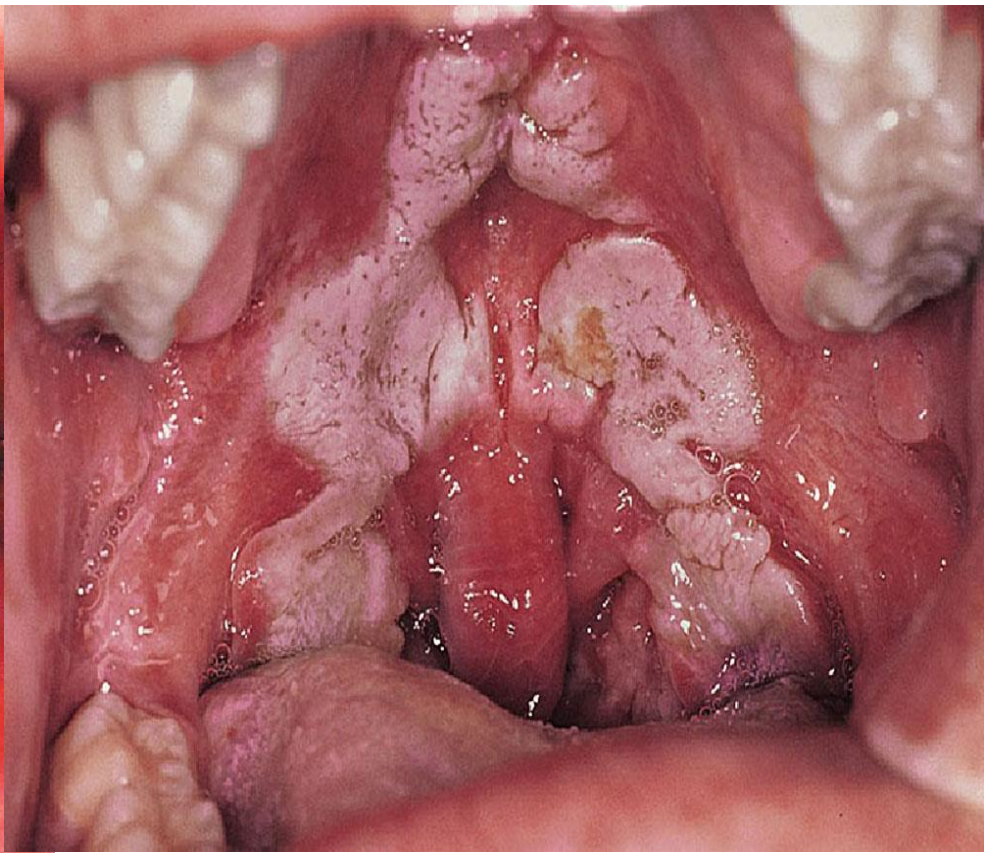
Giant cells pneumonia in measles. (*H-E stain*).



Diphtheritic (croupous) tracheitis.

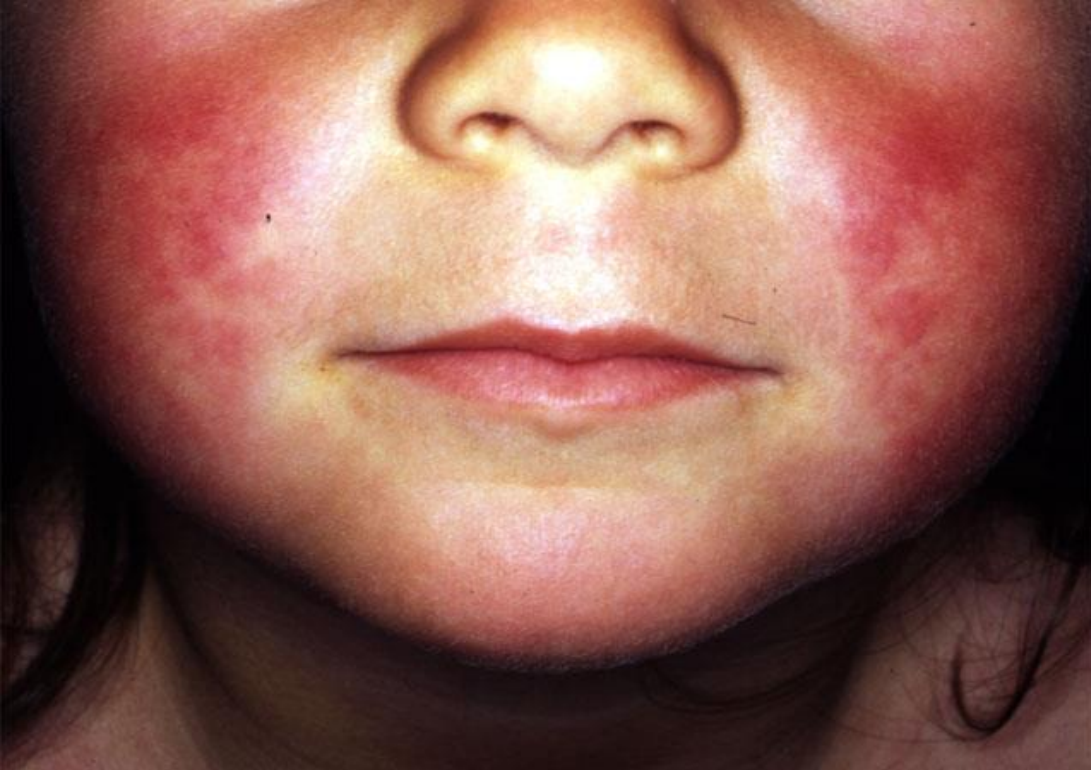

1



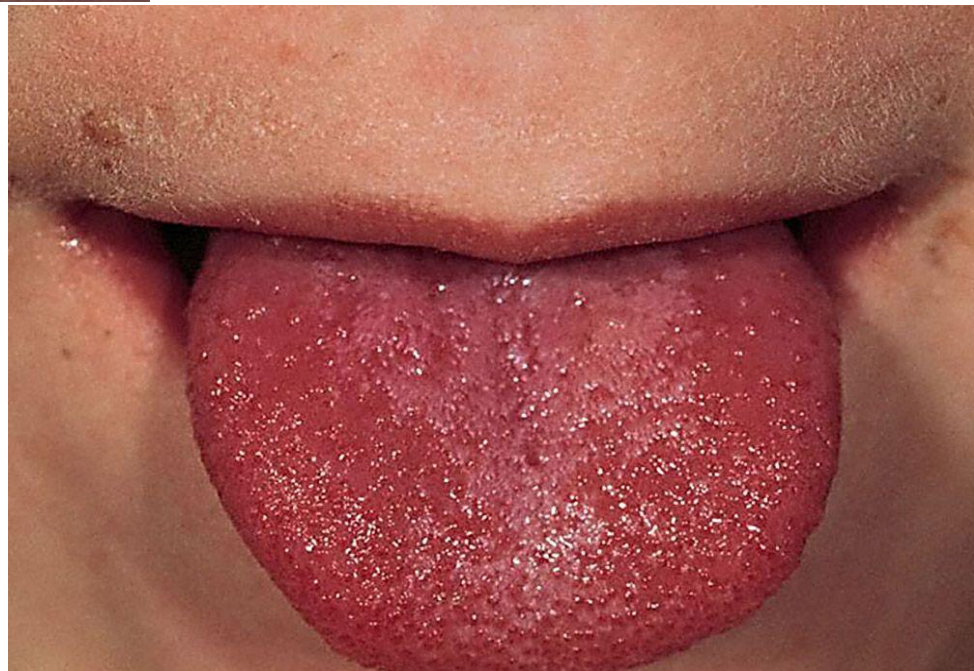
2

Pharyngeal diphtheria (1- localized form, 2 - toxic form)



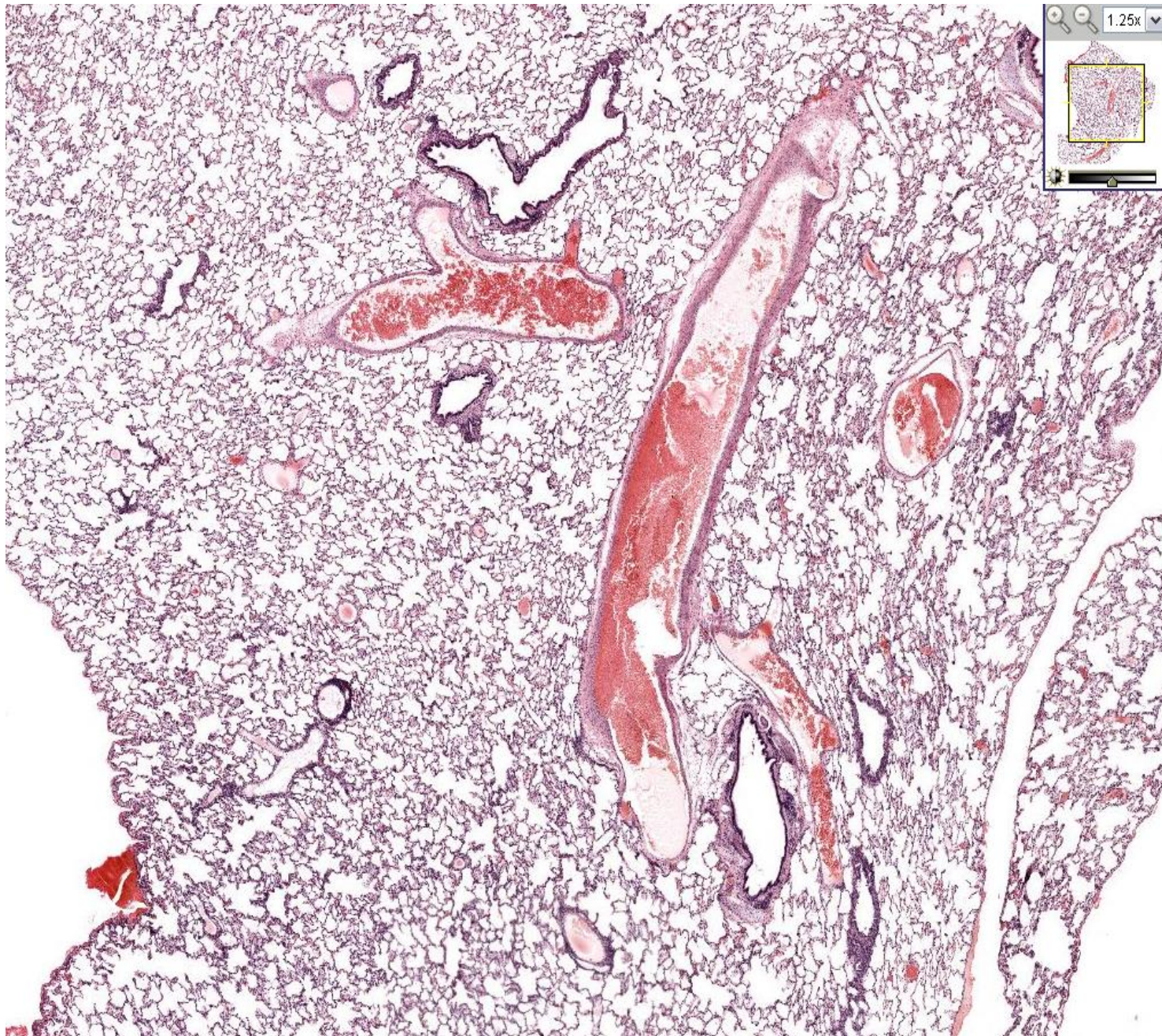
Strawberry tongue in scarlet fever.

**Scarlet fever, absence of rash
around the lips.**



Function of the Respiratory System

- Oversees gas exchanges (oxygen and carbon dioxide) between the blood and external environment
- Exchange of gasses takes place within the lungs in the alveoli(only site of gas exchange, other structures passageways
- Passageways to the lungs purify, warm, and humidify the incoming air
- Shares responsibility with cardiovascular system



Bronchi

Bronchioles

**Terminal
bronchioles**

Alveolar ducts

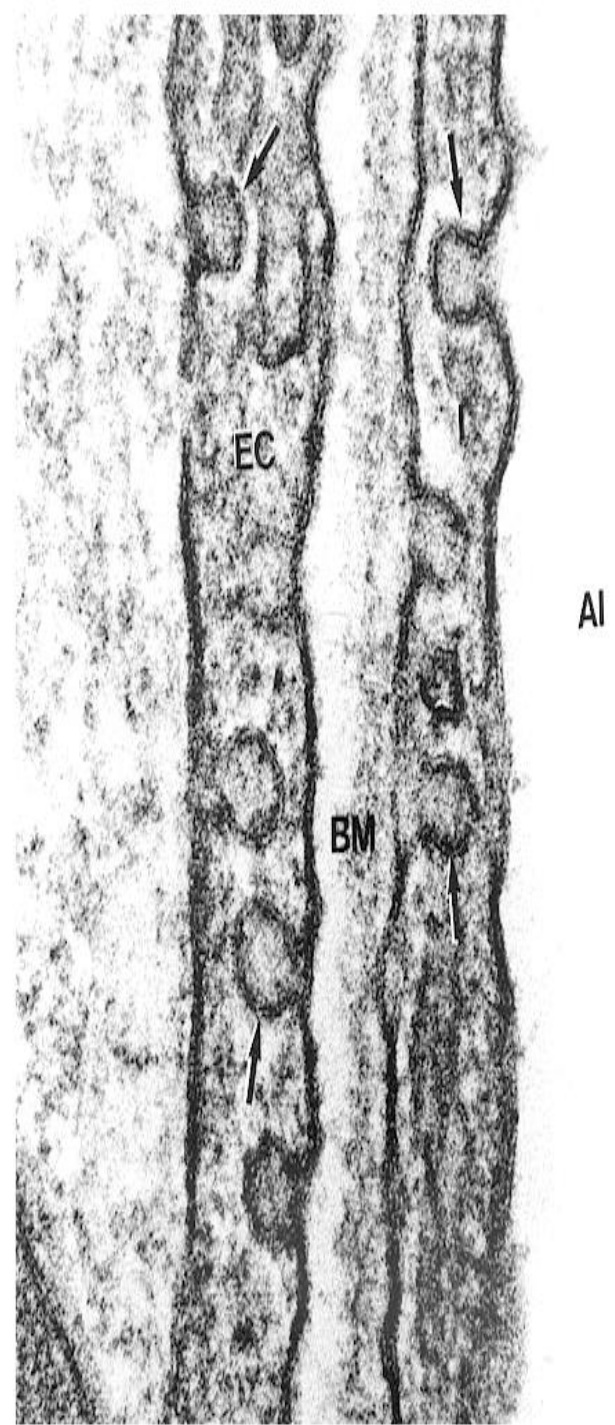
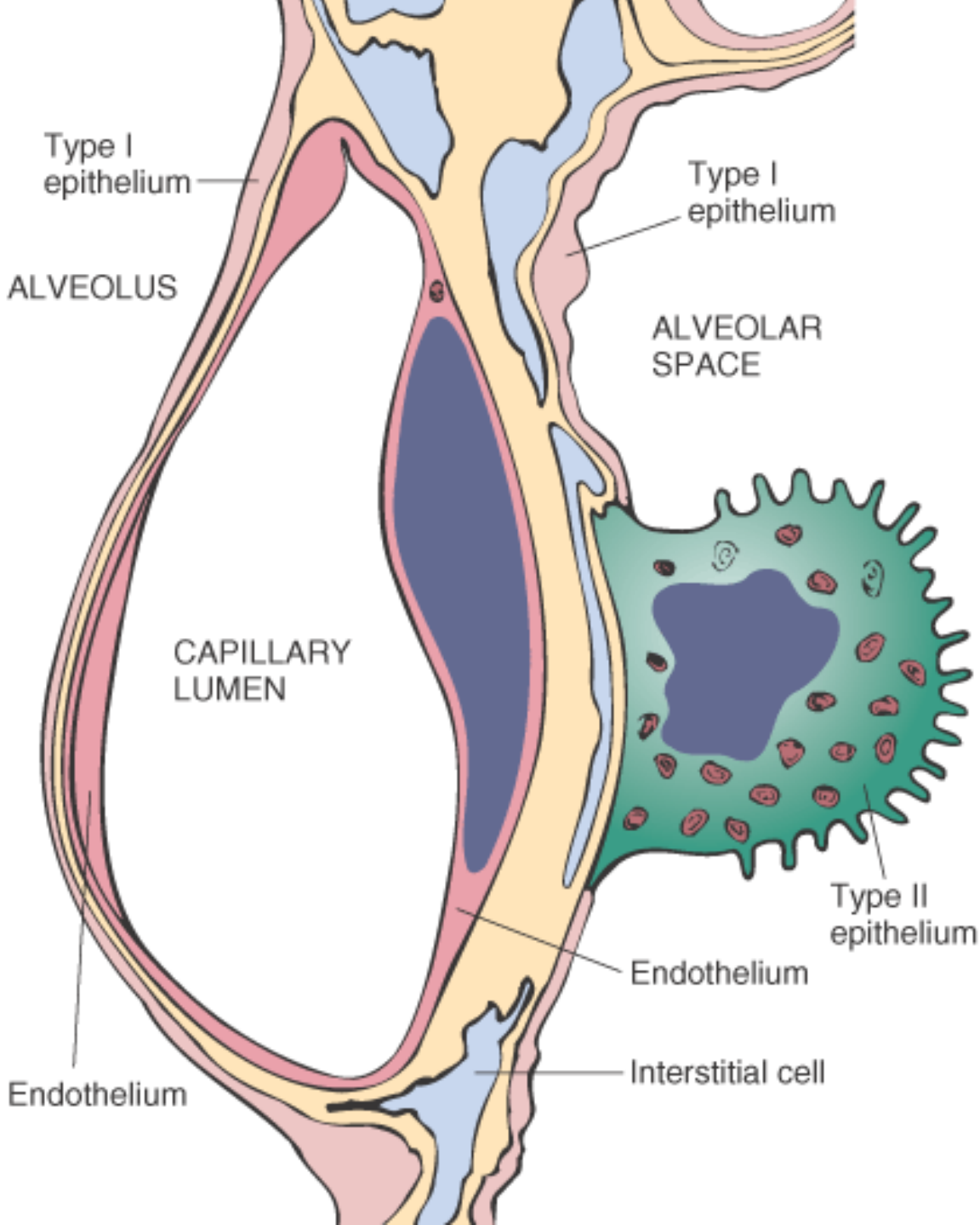
Alveoli

**Type 1
pneumocytes**

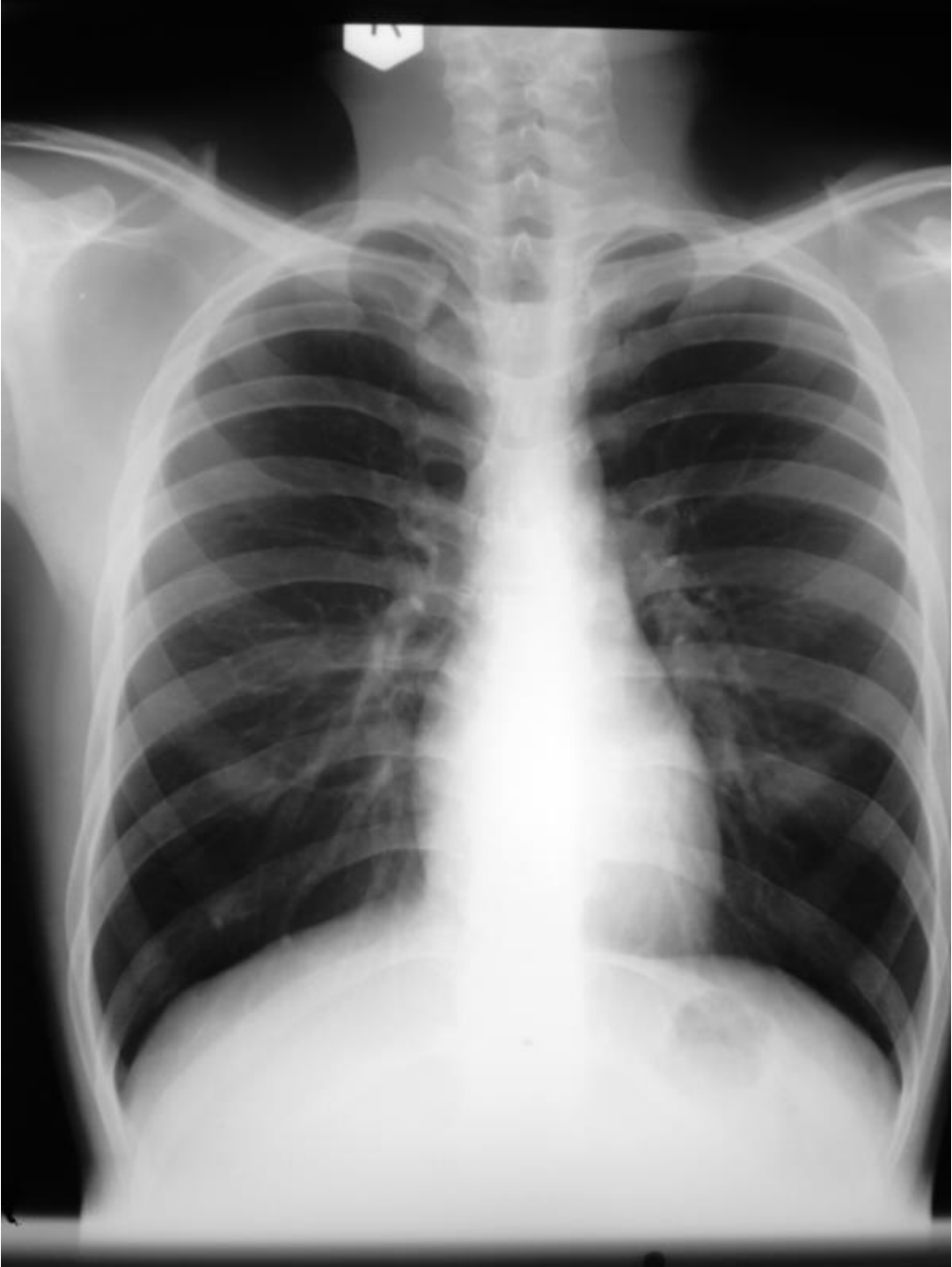**Type 2
pneumocytes**

Macrophages

Capillaries



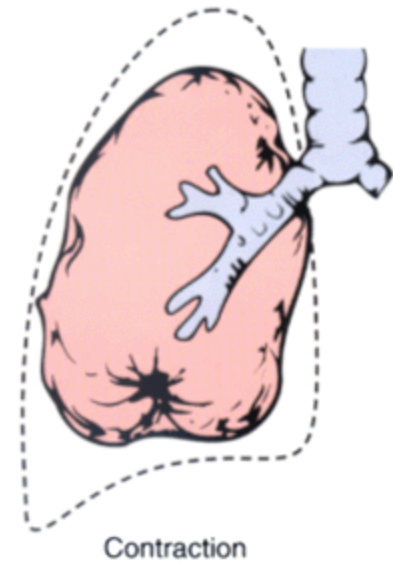
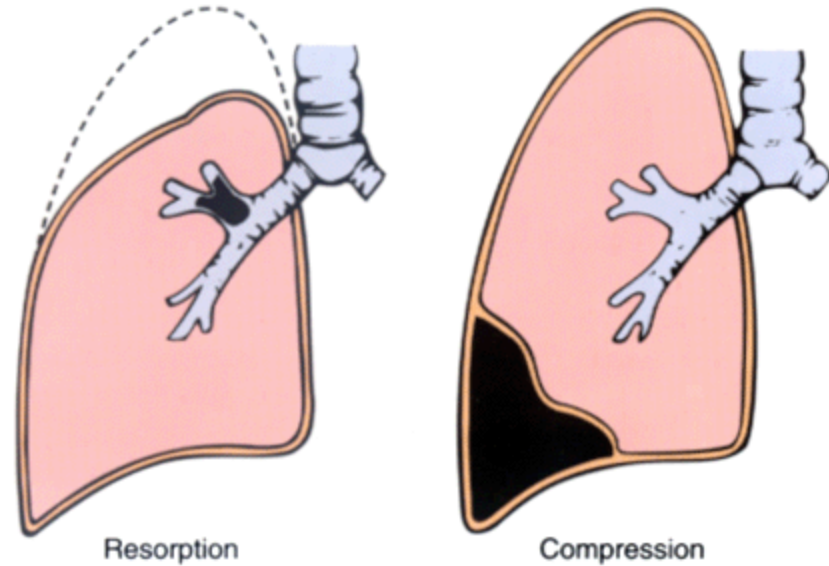
**N
O
R
M
A
L**



**C
X
R**

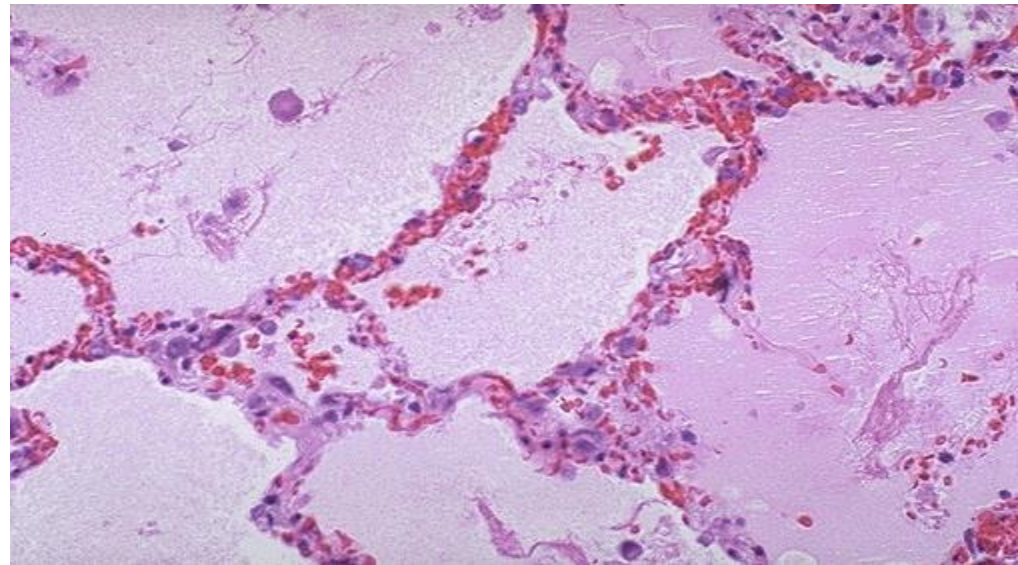
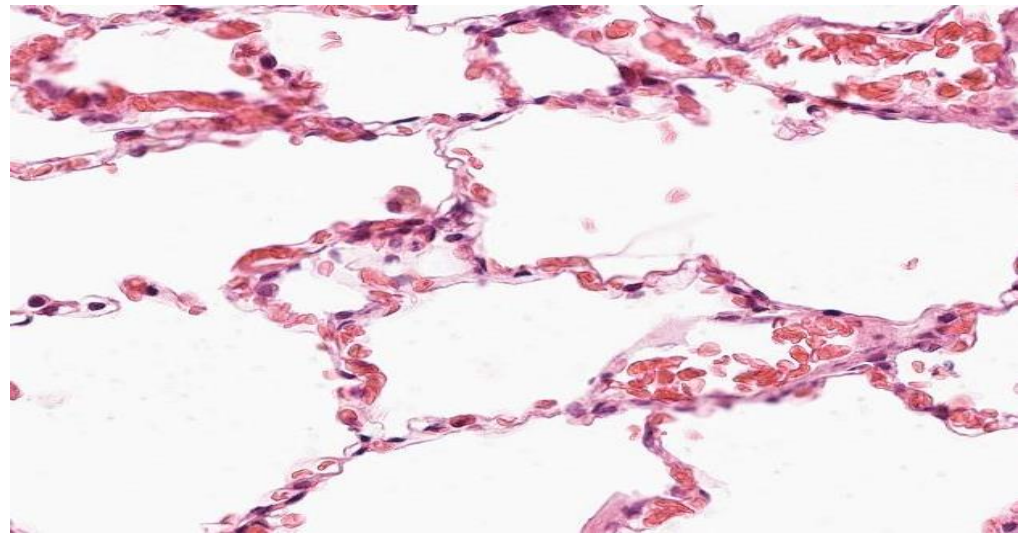
ATELECTASIS

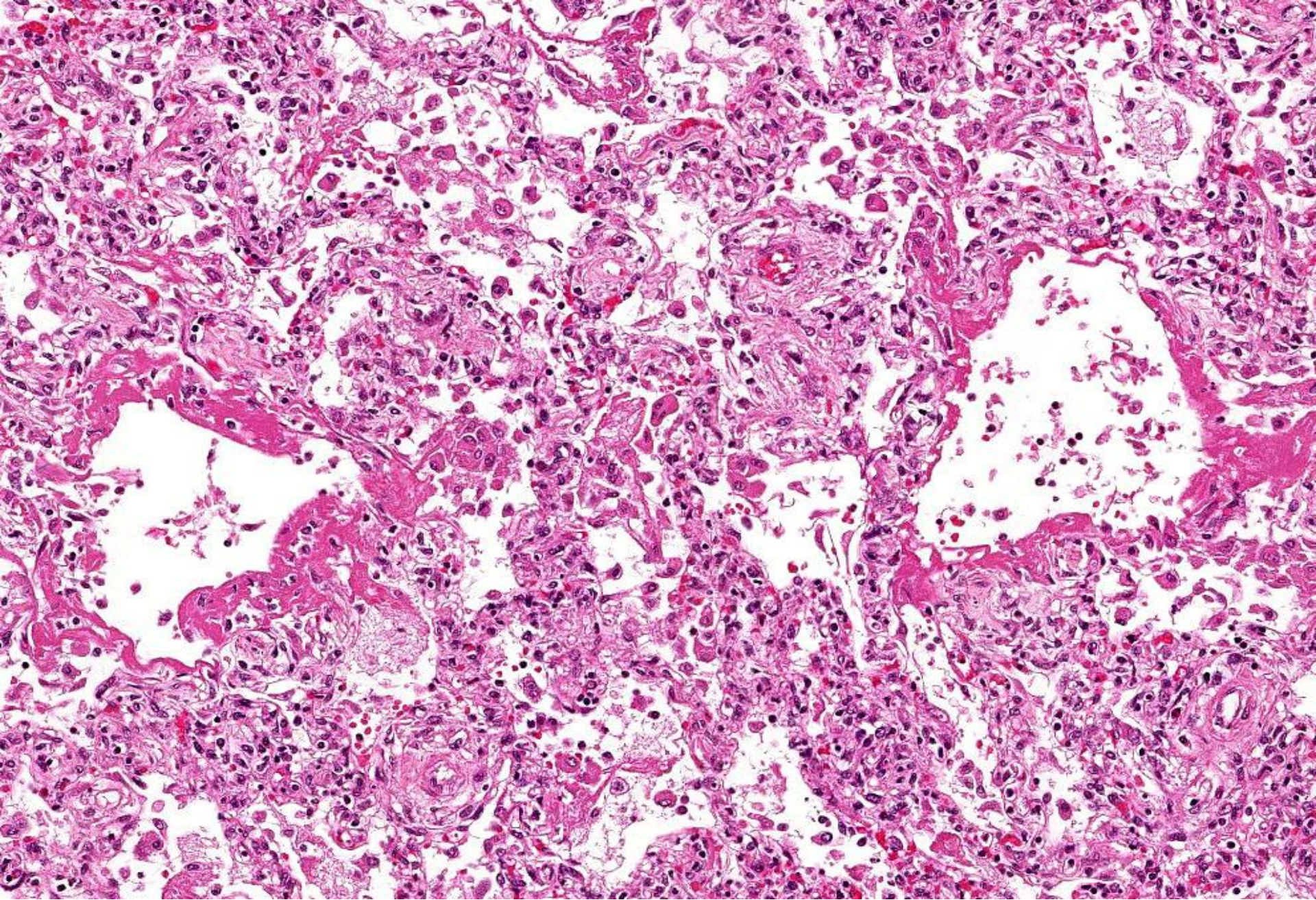
- **INCOMPLETE EXPANSION**
- **COLLAPSE**



PULMONARY EDEMA

- IN-creased venous pressure
- DE-creased oncotic pressure
- Lymphatic obstruction
- Alveolar injury





ARDS

ACUTE INTERSTITIAL PNEUMONIA

- **Think of it as ARDS with NO known etiology!**

OBSTRUCTION v. RESTRICTION

• OBSTRUCTION

- Air or blood?
- Large or small?
- Inspiration or Expiration?
- Obstruction is **SMALL AIRWAY EXPIRATION** obstruction, i.e., wheezing
- **HYPEREXPANSION** on CXR

• RESTRICTION

“Compliance”

“Infiltrative”

**REDUCED lung VOLUME,
DYSPNEA, CYANOSIS
REDUCED GAS TRANSFER
“GROUND GLASS” on
CXR**

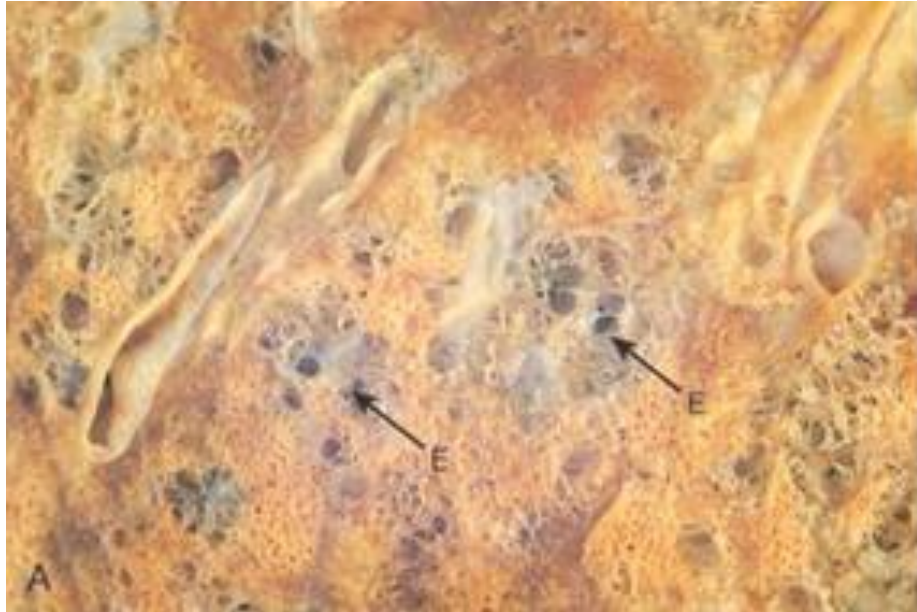
OBSTRUCTION (cOPD)

- **EMPHYSEMA** (almost always chronic)
- **CHRONIC BRONCHITIS** → emphysema
- **ASTHMA**
- **BRONCHIECTASIS**


EMPHYSEMA

- COPD, or “END-STAGE” lung disease
- Centri-acinar, Pan-acinar, Paraseptal, Irregular
- Like cirrhosis, thought of as END-STAGE of multiple chronic small airway obstructive etiologies
- NON-specific
- IN-creased crepittance, BULLAE (BLEBS)
- Clinically linked to recurrent pneumonias, and progressive failure

EMPHYSEMA

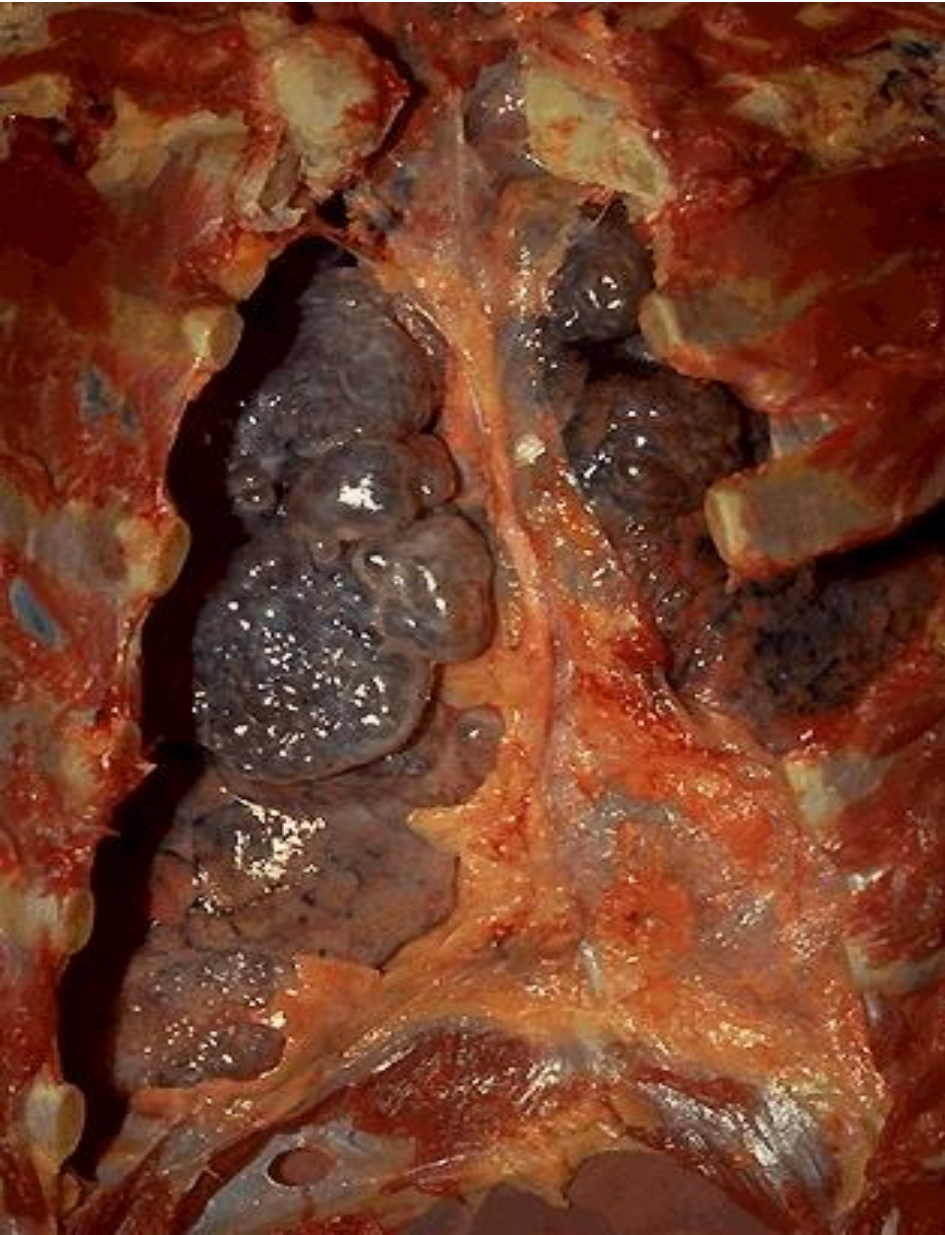


CENTRO-acinar



PAN-acinar

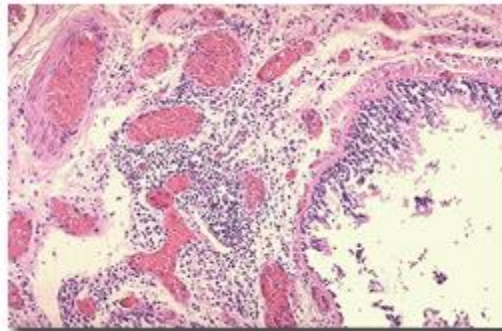
Bullae, or “peripheral blebs” are hallmarks of chronic obstructive lung disease, COPD.



CHRONIC BRONCHITIS

- **INHALANTS, POLLUTION, CIGARETTES**
- **CHRONIC COUGH**
- **CAN OFTEN PROGRESS TO EMPHYSEMA**

- **MUCUS hypersecretion, early, i.e. goblet cell increase**
- **CHRONIC bronchial inflammatory infiltrate**



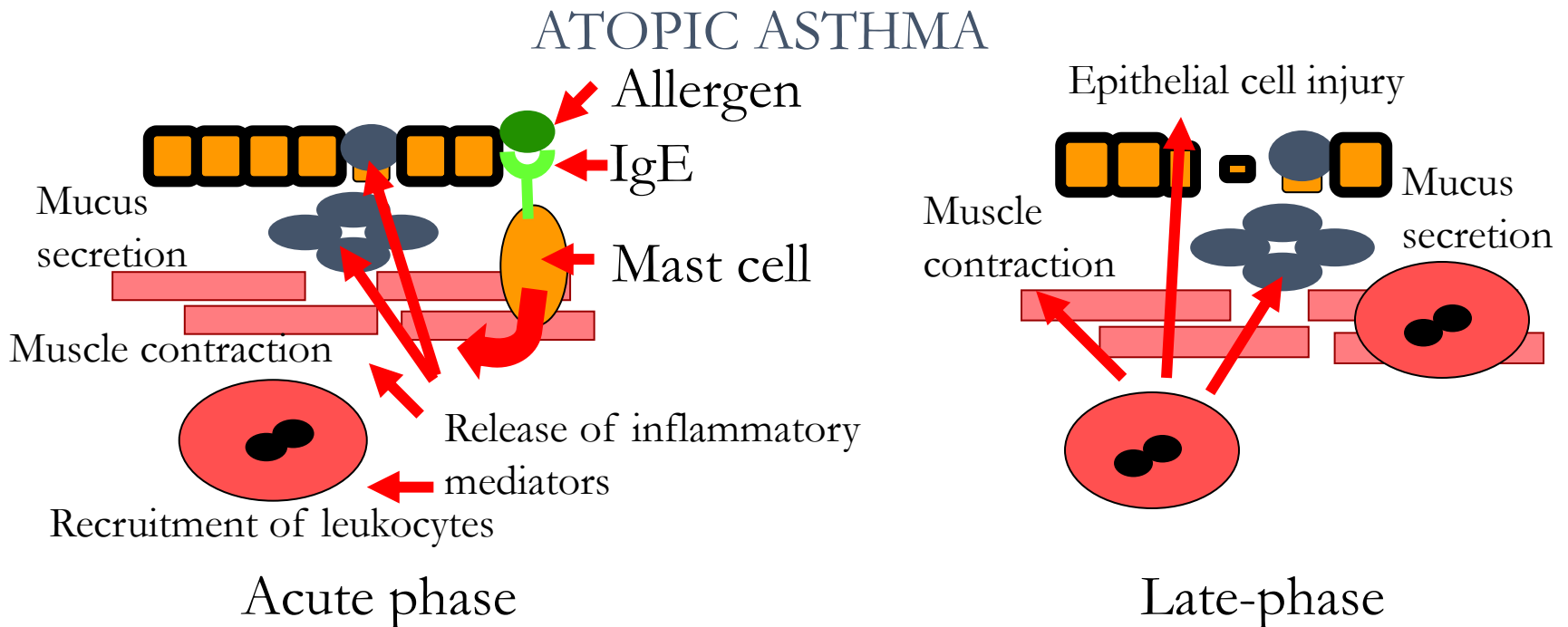
ASTHMA

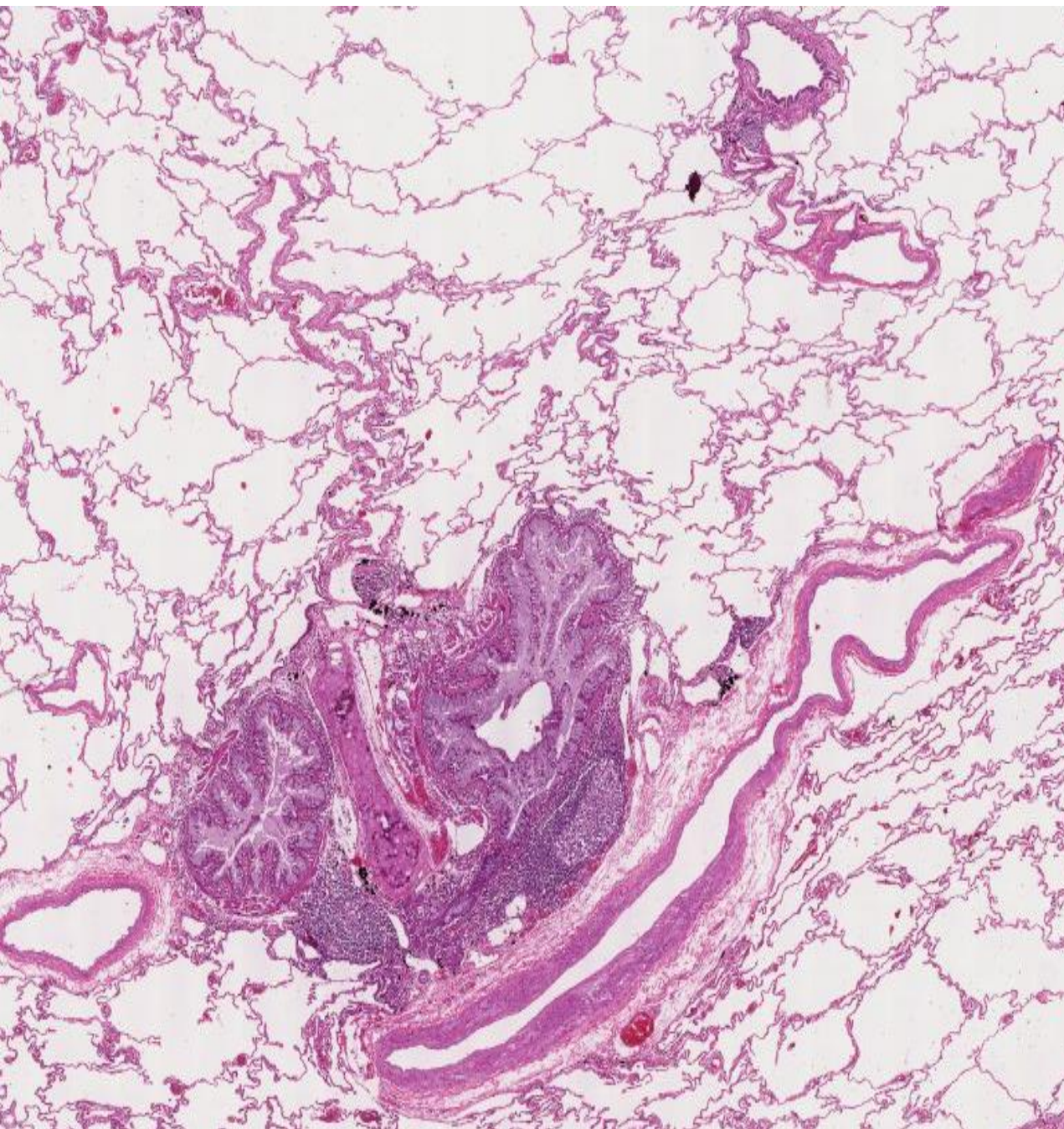
Similar to chronic bronchitis but:

- Wheezing is hallmark (**bronchospasm, i.e. “wheezing”**)
- **STRONG allergic role**, i.e., eosinophils, IgE, allergens
- Often starting in **CHILDHOOD**
- **ATOPIC (allergic) or NON-ATOPIC (infection)**
- Chronic small airway obstruction and infection
- **1) Mucus hypersecretion with plugging, 2) lymphocytes/eosinophils, 3) lumen narrowing, 4) smooth muscle hypertrophy**

Bronchial Asthma

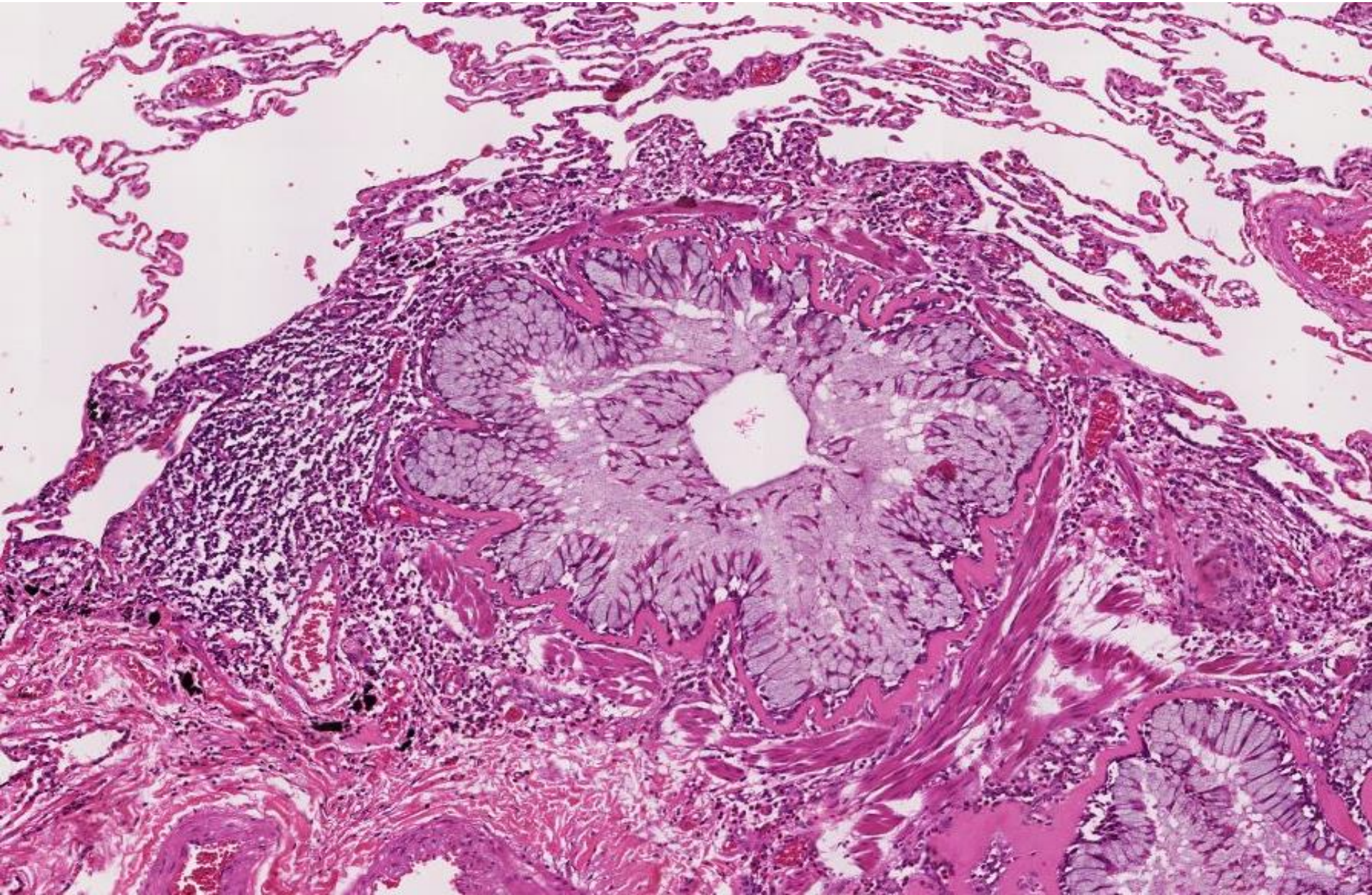
- **Chronic inflammatory disorder of the airways resulting in contraction of bronchial muscle**
- **Types**
 - **Extrinsic (atopic, allergic).**
 - Allergens: food, pollen, dust, etc.
 - **Intrinsic (non-atopic)**
 - Initiated by infections, drugs, pollutants, chemical irritants





Note the heavy inflammatory cell infiltrate around bronchioles and small bronchi.

What are the 4 classical histologic findings in bronchial asthma?



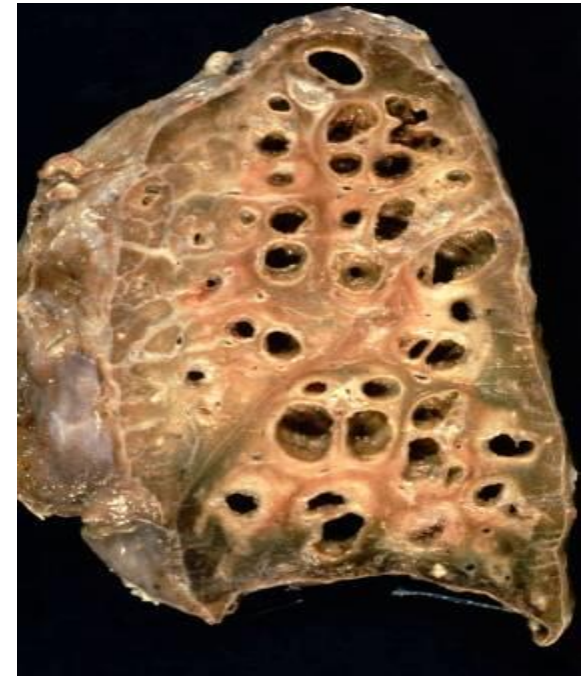BRONCHIECTASIS

DILATATION of the BRONCHUS, associated with, often, necrotizing inflammation

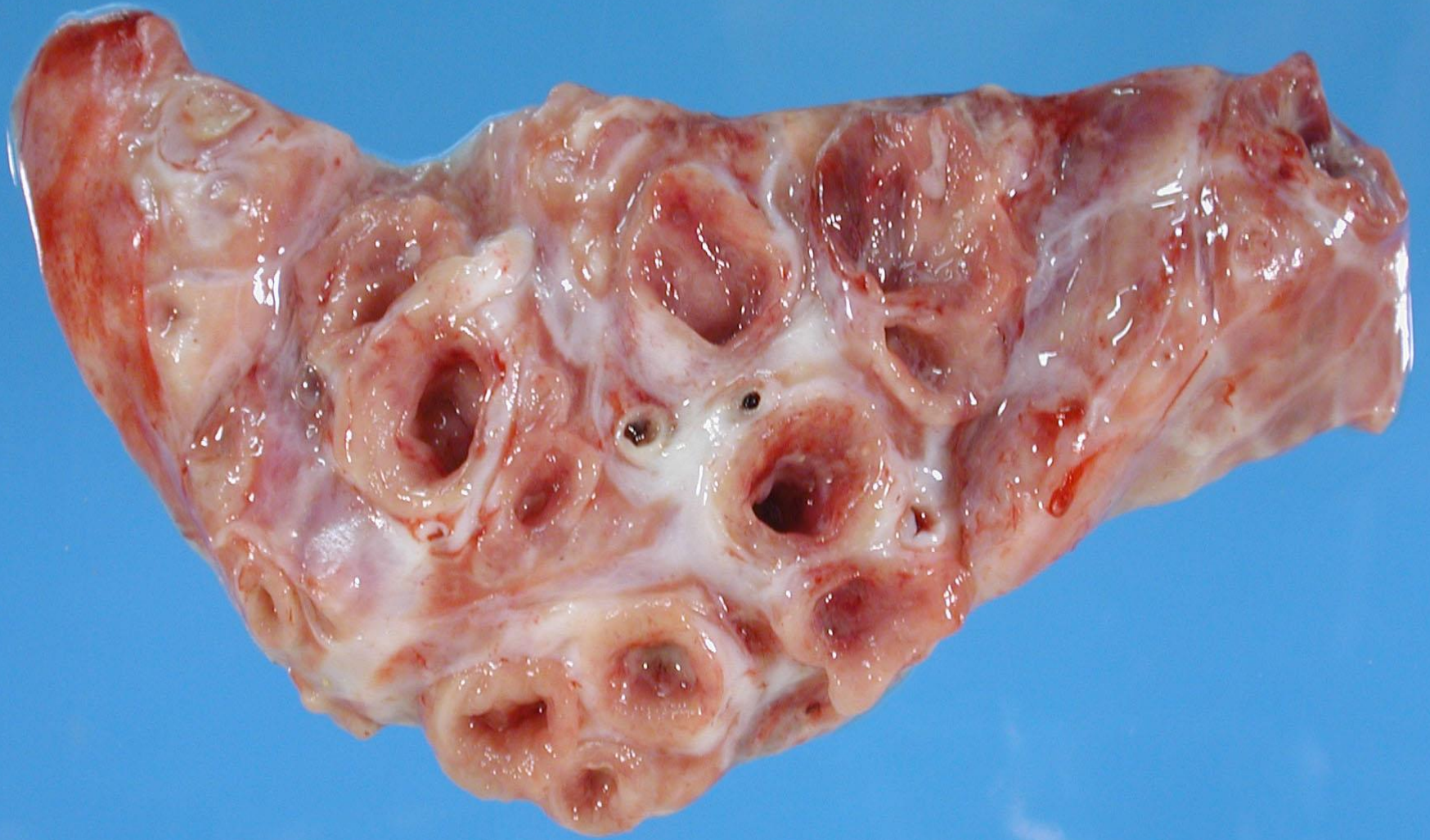- CONGENITAL

- **TB**, other bacteria, many viruses

- BRONCHIAL OBSTRUCTION (i.e., LARGE AIRWAY, NOT SMALL AIRWAY)
- Rheumatoid Arthritis, SLE, IBD (Inflammatory Bowel Disease)

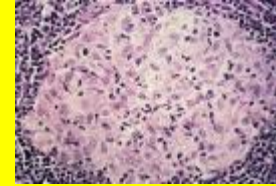
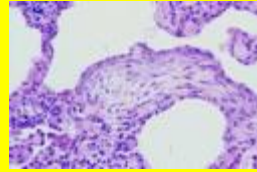


BRONCHIECTASIS

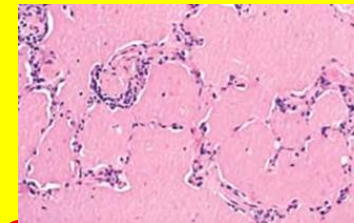
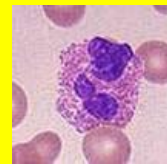


RESTRICTIVE (INFILTRATIVE)

- **REDUCED COMPLIANCE**, reduced gas exchange)
- Are also **DIFFUSE**
- **HETEROGENEOUS**



- **FIBROSING**
- **GRANULOMATOUS**
- **EOSINOPHILIC**
- **SMOKING RELATED**



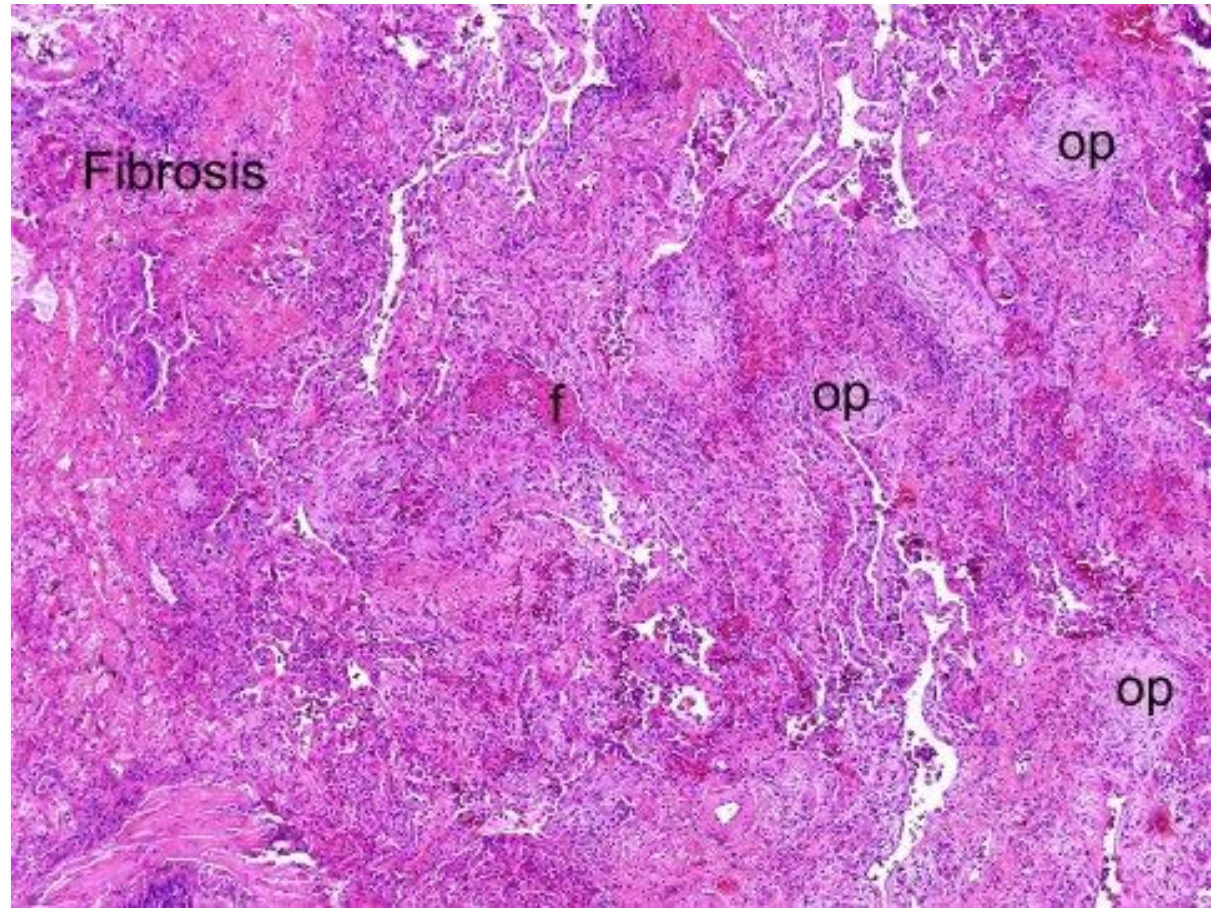
- **PAP (Pulmonary Alveolar Proteinosis)**

FIBROSING

- **“IDIOPATHIC” PULMONARY FIBROSIS (IPF)**
- **NONSPECIFIC INTERSTITIAL FIBROSIS**
- **“CRYPTOGENIC” ORGANIZING PNEUMONIA**
- **“COLLAGEN” VASCULAR DISEASES**
- **PNEUMOCONIOSES**
- **DRUG REACTIONS**
- **RADIATION CHANGES**

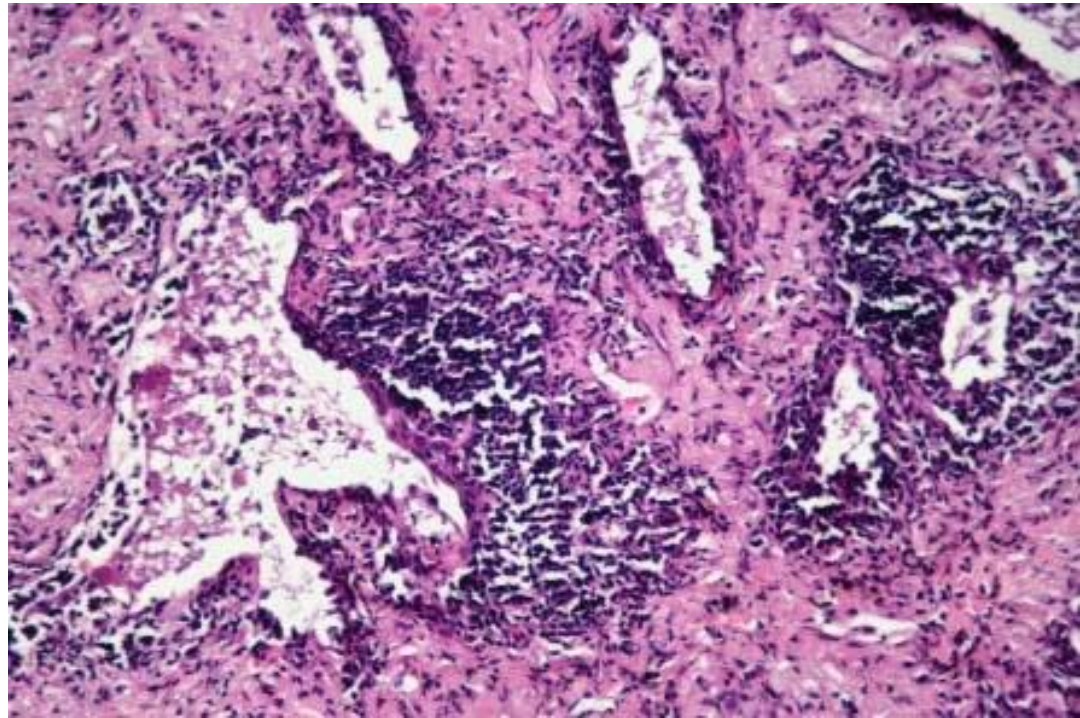
IPF (UIP)

- **IDIOPATHIC**, i.e., not from any usual cause, like lupus, scleroderma
- **FIBROSIS**



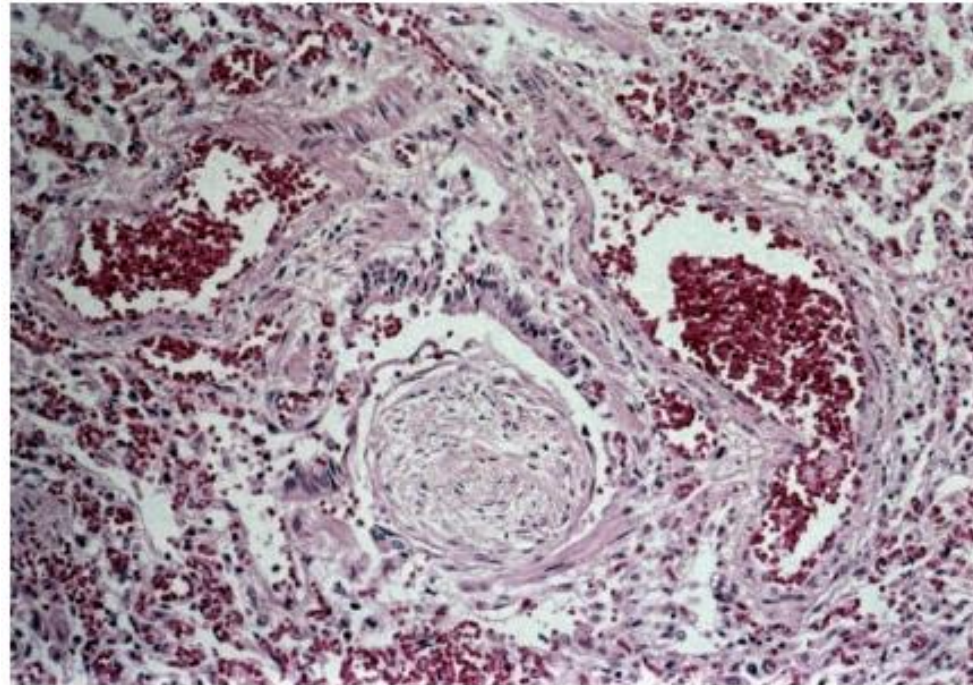
NON-SPECIFIC INTERSTITIAL PNEUMONIA

- **WASTEBASKET DIAGNOSIS**, of ANY pneumonia (pneumonitis) of any known or unknown etiology
 - **FIBROSIS**
 - **CELLULAR INFILTRATE** (LYMPHS & PLASMA CELLS)



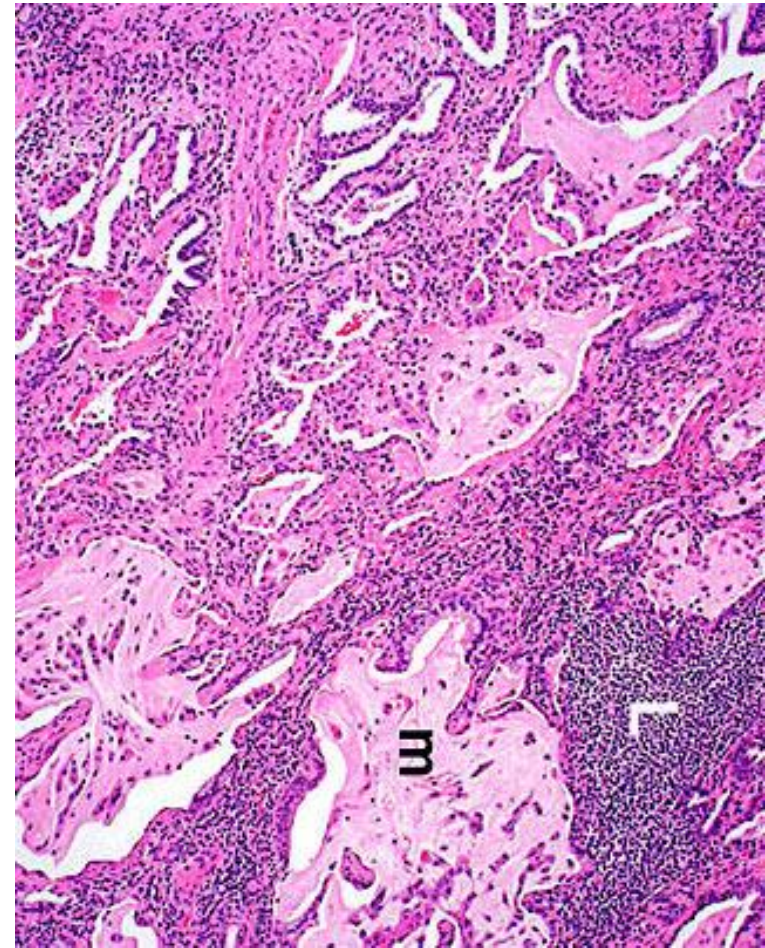
CRYPTOGENIC ORGANIZING PNEUMONIA (COP)

- IDIOPATHIC
- “BRONCHIOLITIS OBLITERANS”



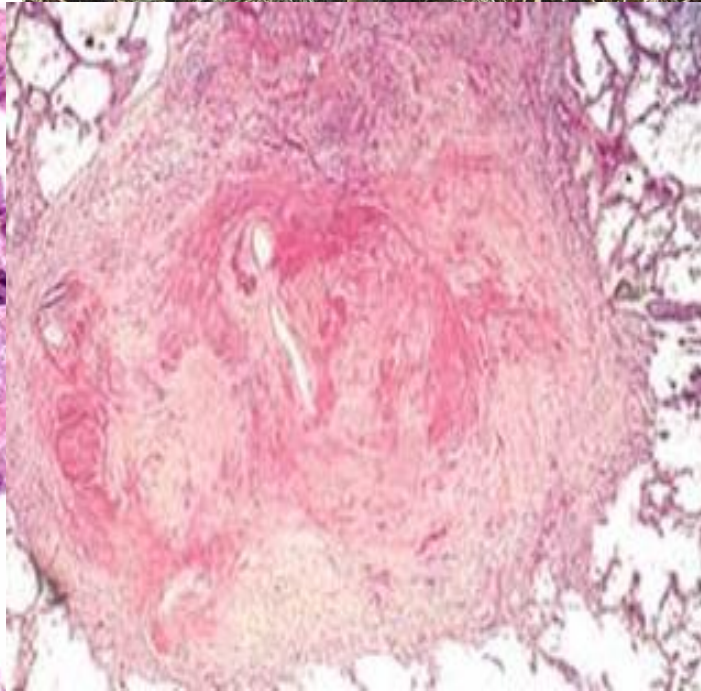
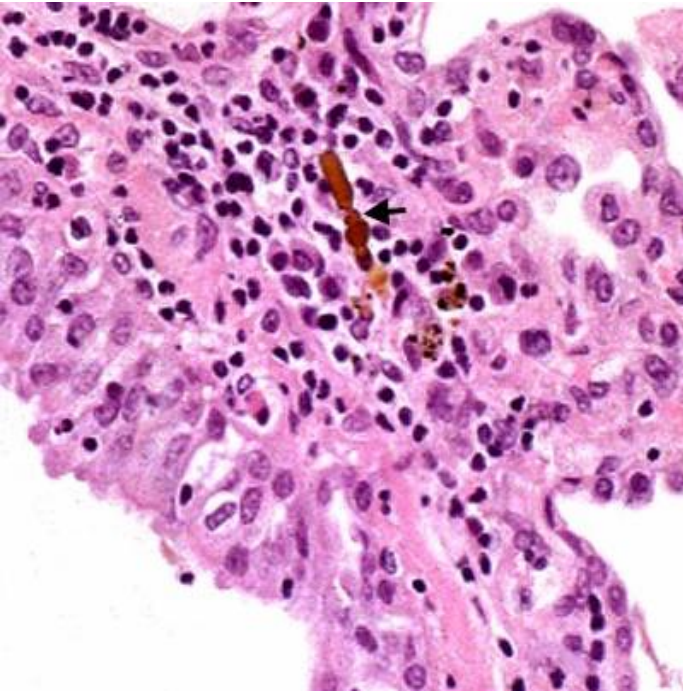
“COLLAGEN” VASCULAR DISEASES

- **Rheumatoid Arthritis**
- **SLE (“Lupus”)**
- **Progressive Systemic Sclerosis (Scleroderma)**



PNEUMOCONIOSES

- “OCCUPATIONAL”
- “COAL MINERS LUNG”
- DUST OR CHEMICALS OR ORGANIC MATERIALS
 - Coal (anthracosis)
 - Silica
 - Asbestos
- Be, FeO, BaSO₄, **CHEMO**
- HAY, FLAX, BAGASSE, INSECTICIDES, etc.



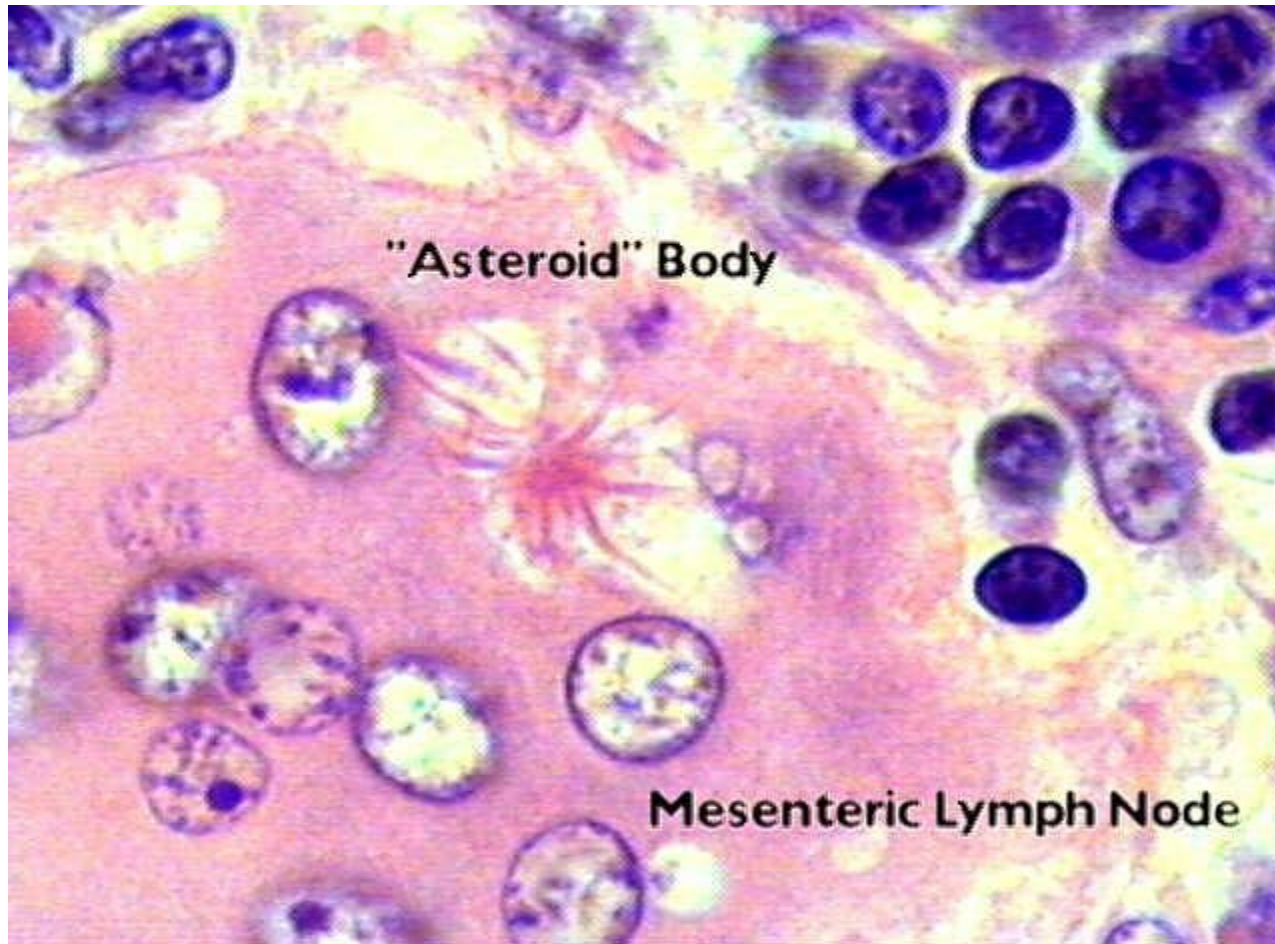
**Coal,
“bagasse”,
asbestos,
silica
nodules,
and
asbestos,
going
clockwise.**

GRANULOMATOUS

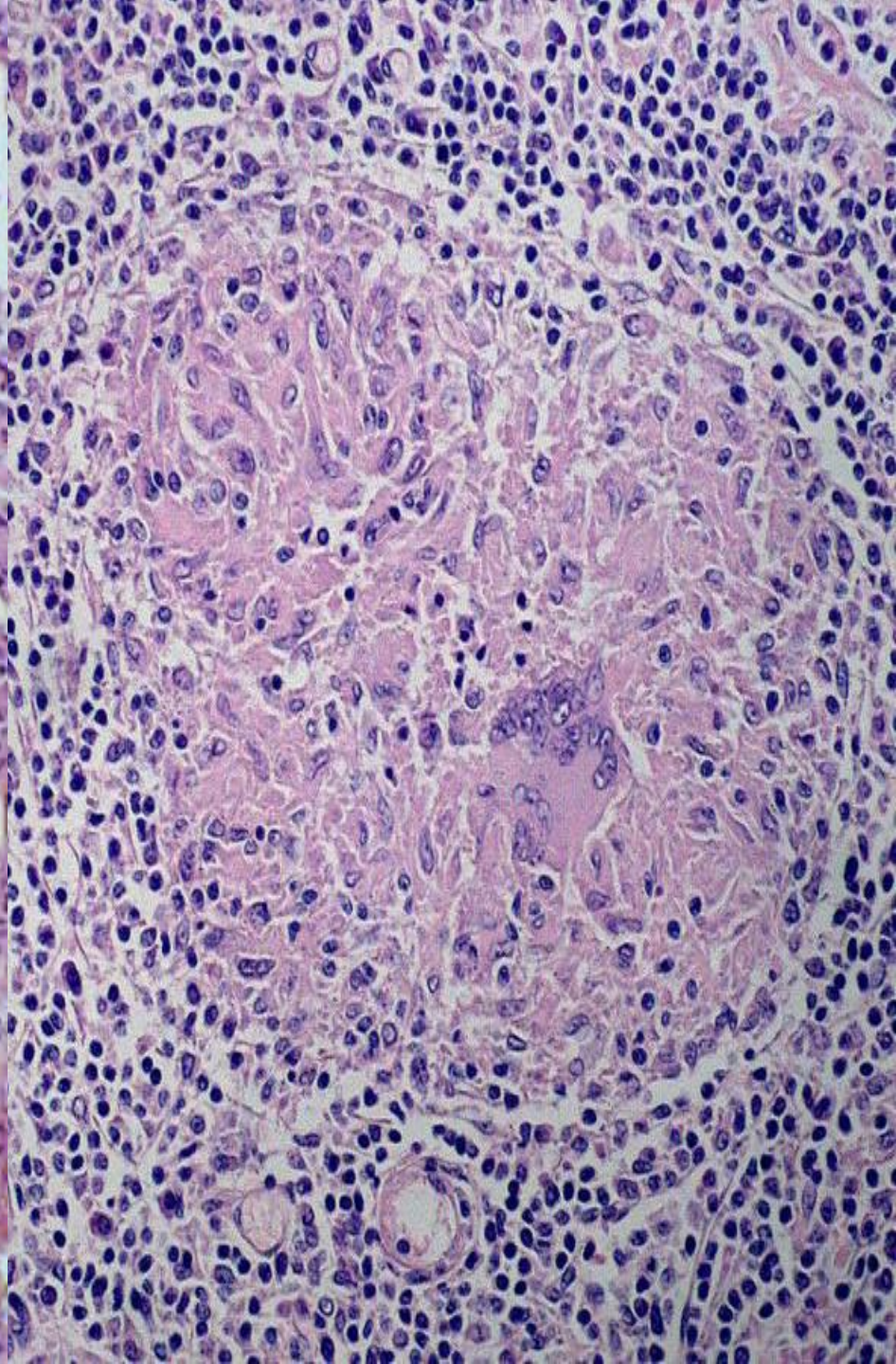
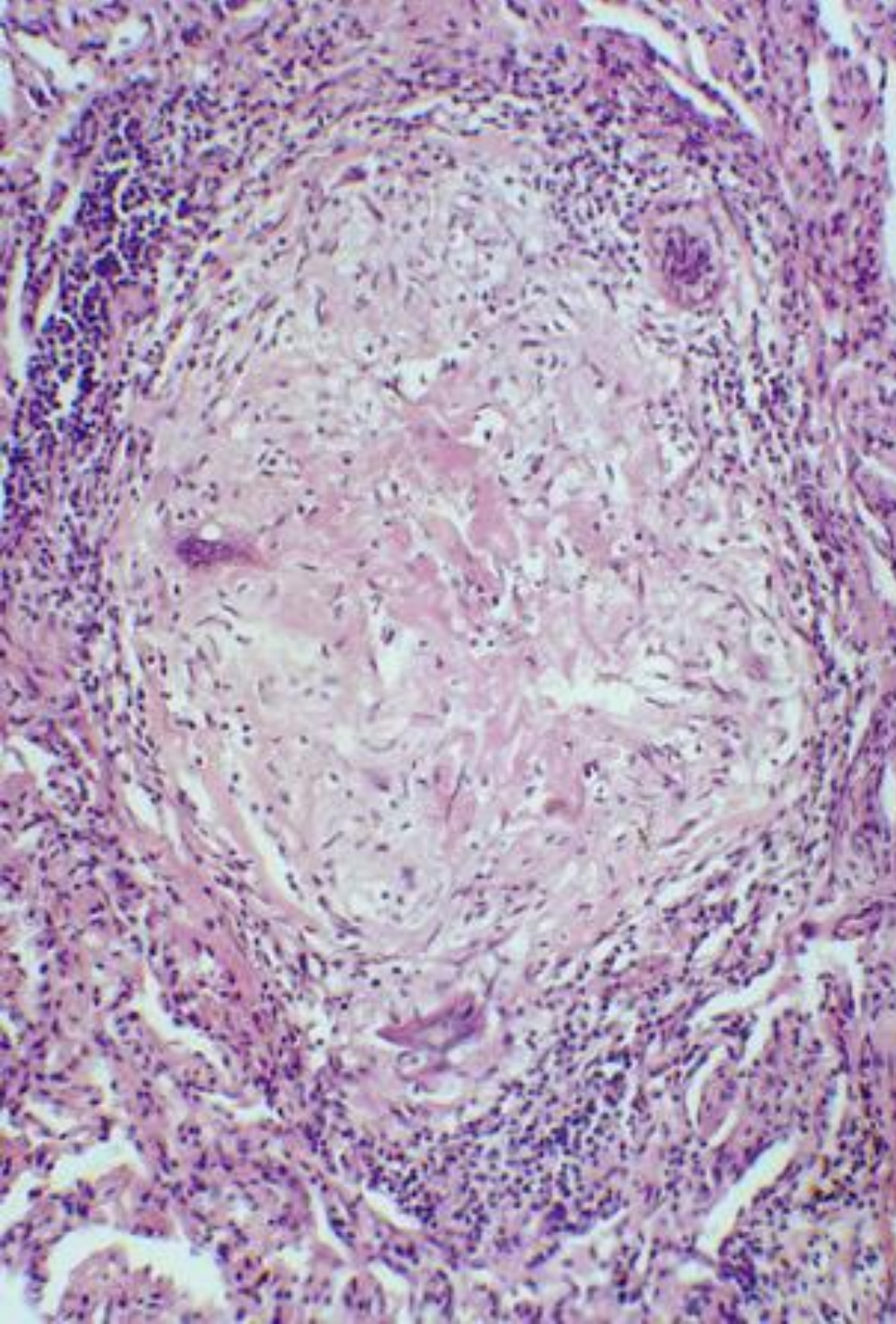
- **SARCOIDOSIS**, i.e., NON-caseating granulomas (IDIOPATHIC)
- **HYPERSENSITIVITY** (DUSTS, bacteria, fungi, Farmer's Lung, Pigeon Breeder's Lung)

SARCOIDOSIS

- **Mainly LUNG, but eye, skin or ANYWHERE**
- **UNKNOWN ETIOLOGY**
- **IMMUNE, GENETIC factors**
- **F>>M**
- **B>>W**
- **YOUNG ADULT BLACK WOMEN**



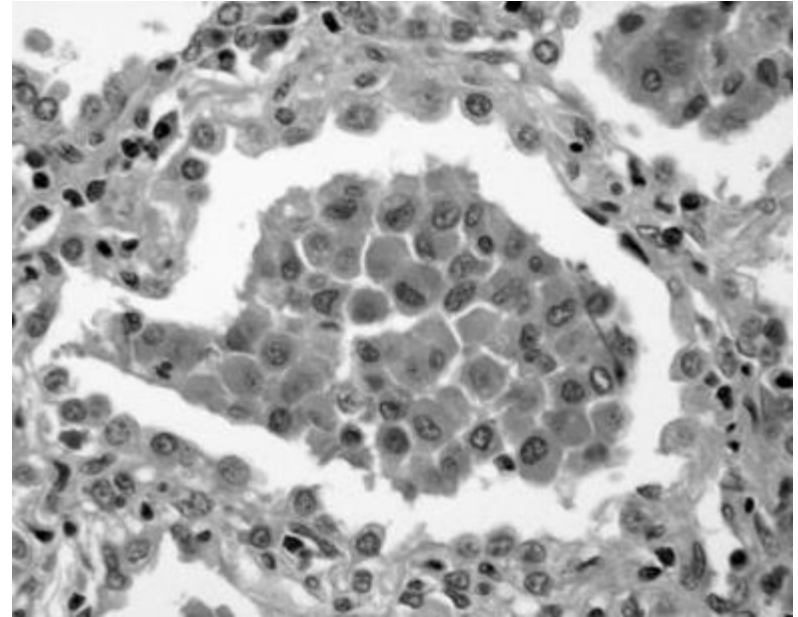
NON-Caseating Granulomas are the RULE
“Asteroid” bodies within these granulomas
are virtually diagnostic



SMOKING RELATED

- **DIP** (**D**esquamative **I**nterstitial **P**neumonia)

- M>>F
- CIGARETTES
- 100% Survival



**Alveolar
Macrophages**

Pulmonary tuberculosis

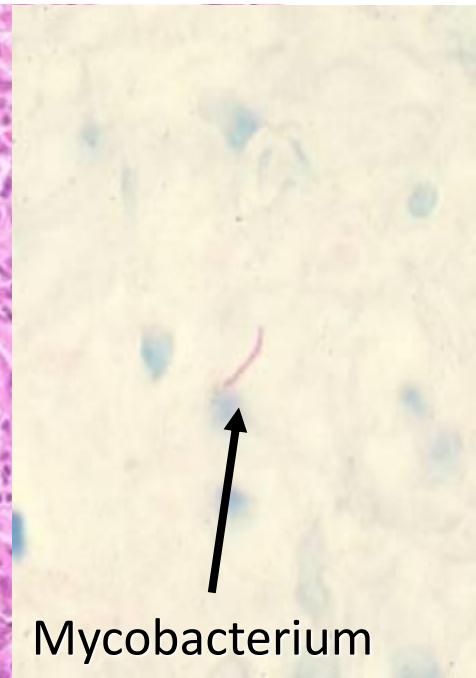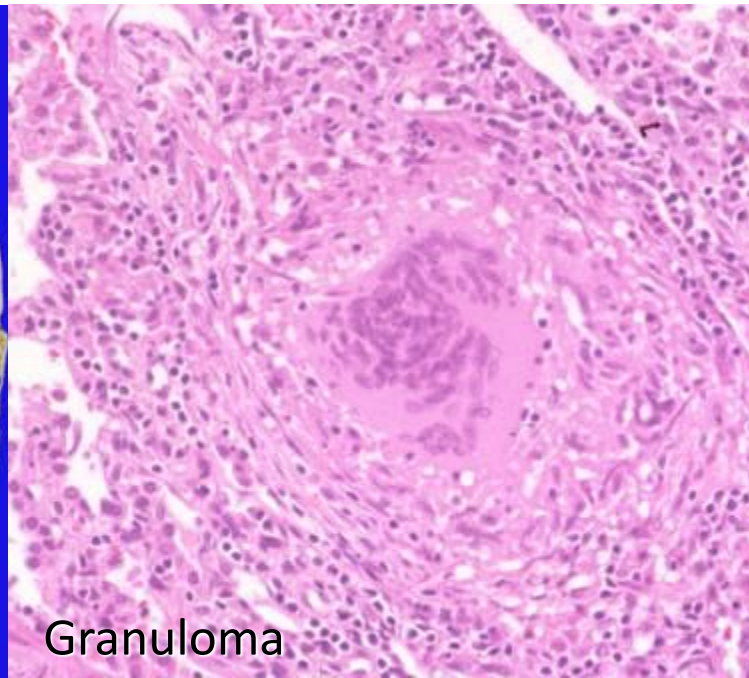
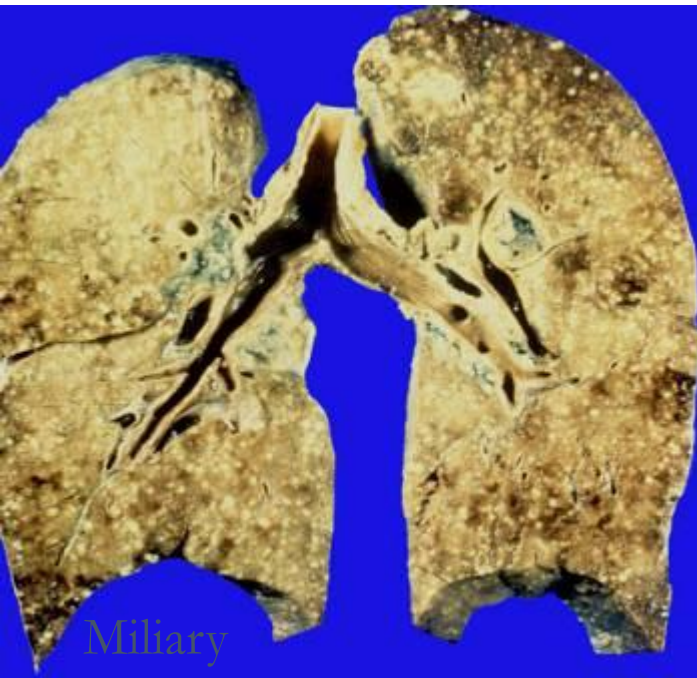
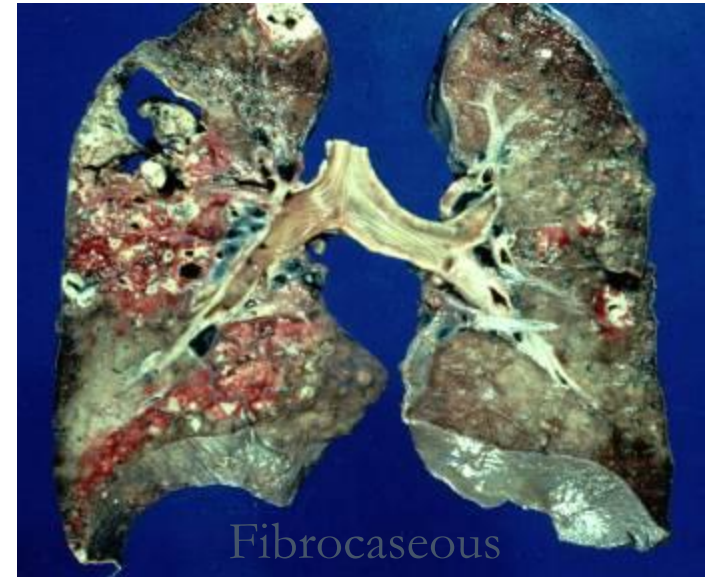
- Caused by *Mycobacterium tuberculosis*.
- Transmitted through inhalation of infected droplets
- Primary
 - Single granuloma within parenchyma and hilar lymph nodes (Ghon complex).
 - Infection does not progress (most common).
 - Progressive primary pneumonia
 - Miliary dissemination (blood stream).



Pulmonary tuberculosis

- **Secondary**

- Infection (mostly through reactivation) in a previously sensitized individual.
- **Pathology**
 - Cavitory fibrocaseous lesions
 - Bronchopneumonia
 - Miliary TB

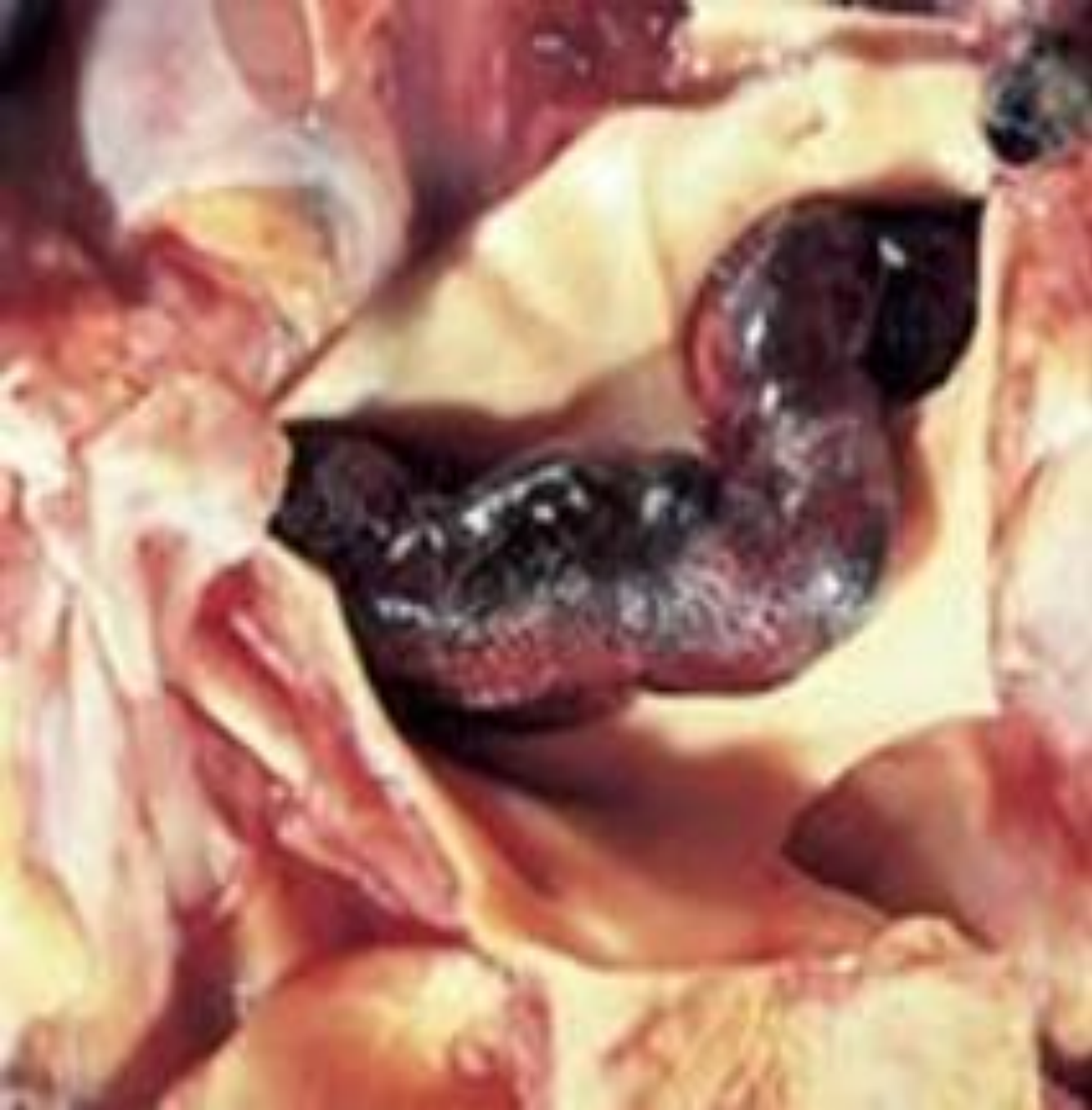

VASCULAR PULMONARY DISEASES

- **PULMONARY EMBOLISM** (with or usually WITHOUT infarction)
- **PULMONARY HYPERTENSION**, leading to cor pulmonale
- **HEMORRHAGIC SYNDROMES**
 - **GOODPASTURE SYNDROME**
 - **HEMOSIDEROSIS**, idiopathic
 - **WEGENER GRANULOMATOSIS**

P.E.

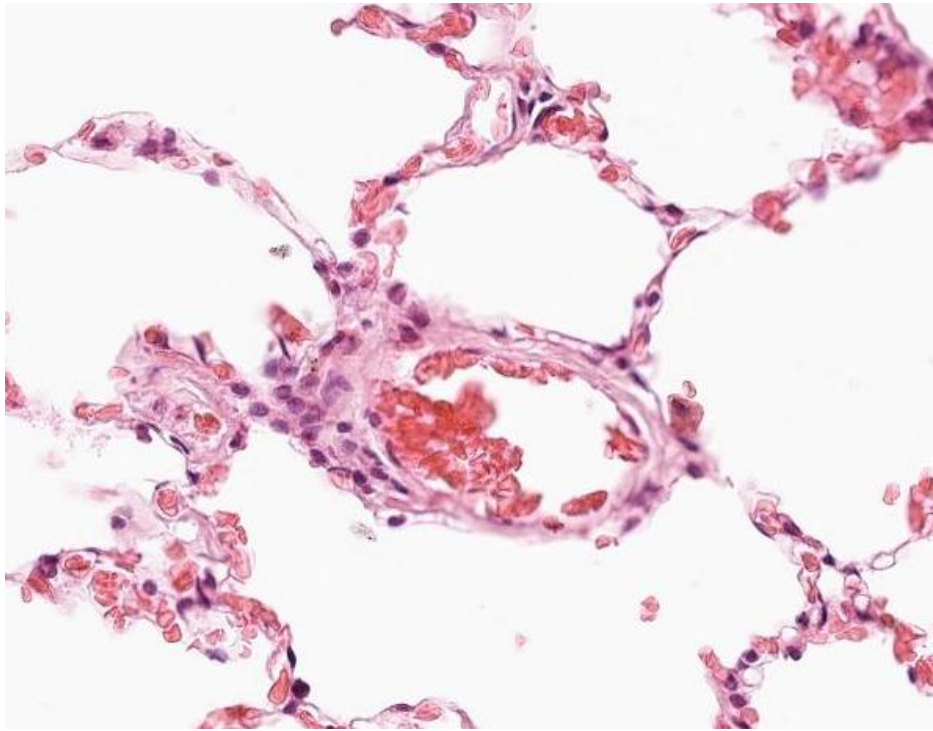
- Usually secondary to debilitated states with immobilization, or following surgery
- Usually deep leg and deep pelvic veins (DVT), NOT superficial veins
- Follows Virchow's triad, i.e., 1) flow problems, 2) endothelial disruption, 3) hypercoagulability
- Usually do NOT infarct, usually ventilate
- When they DO infarct, the infarct is hemorrhagic
- Decreased PO₂, acute chest pain, V/Q MIS-match
- DX: Chest CT, V/Q scan, angiogram
- RX: short term heparin, then long term coumadin



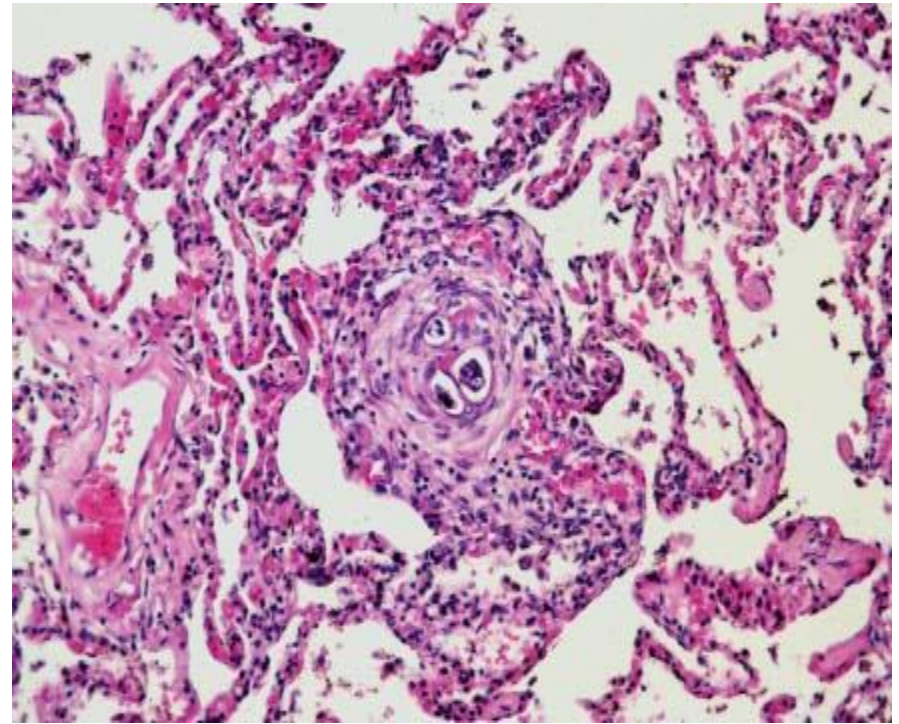
**GROSS
“saddle”
embolism**

PULMONARY HYPERTENSION

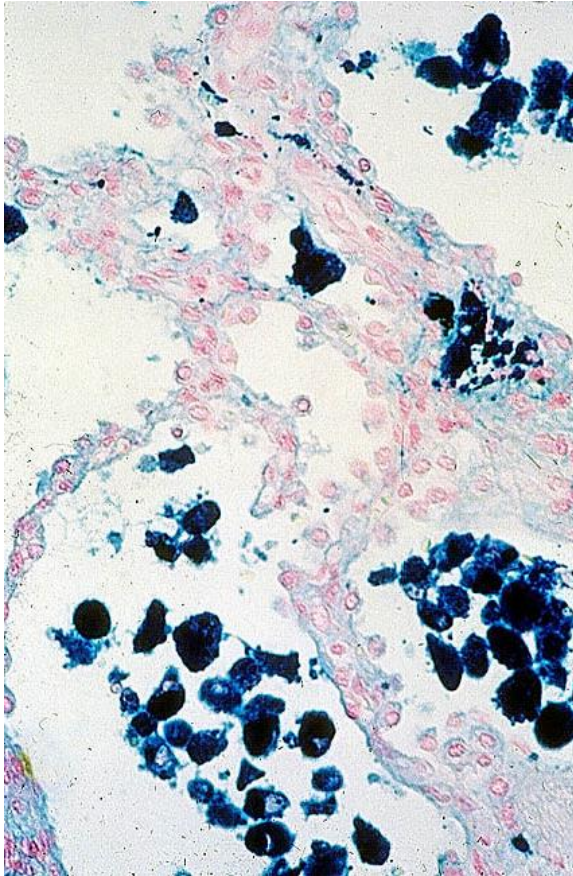
- **COPD, C"i"PD** (vicious cycle)
- **CHD** (Congenital HD, increased left atrial pressure)
- **Recurrent PEs**
- **Autoimmune, e.g., PSS (Scleroderma), i.e., fibrotic pulmonary vasculature**



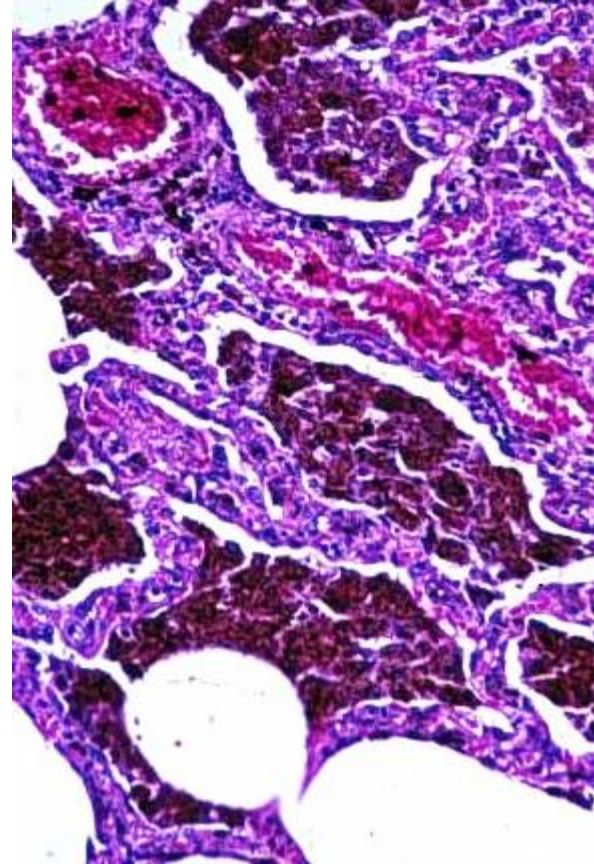
NORMAL pulmonary arteriole



VERY thickened arteriole in pulmonary hypertension

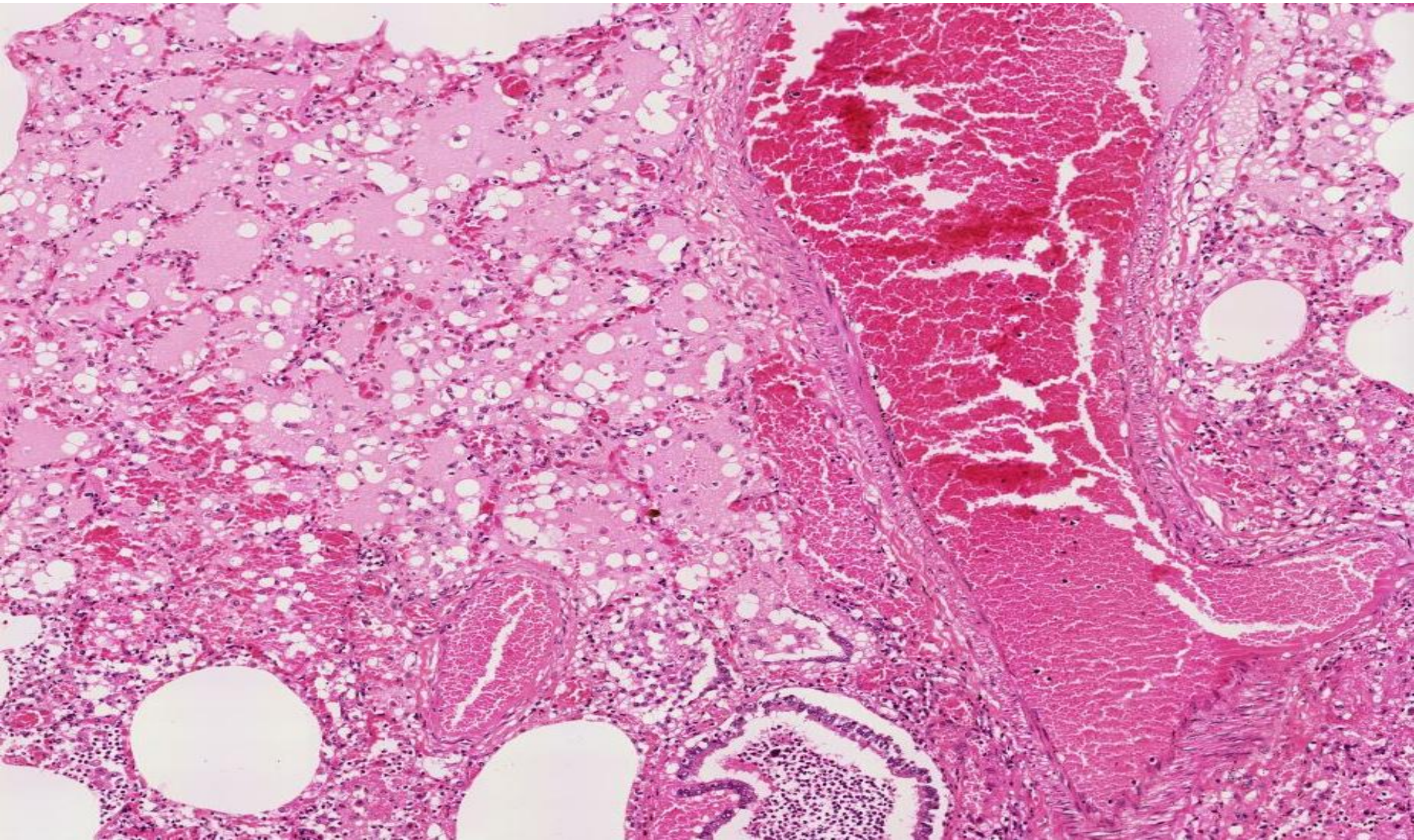


CHF, **CHRONIC**



IDIOPATHIC
PULMONARY
HEMOSIDEROSIS

PNEUMONIA



PULMONARY INFECTIONS

COMMUNITY-ACQUIRED BACTERIAL ACUTE PNEUMONIAS

Streptococcus Pneumoniae

Haemophilus Influenzae

Moraxella Catarrhalis

Staphylococcus Aureus

Klebsiella Pneumoniae

Pseudomonas Aeruginosa

Legionella Pneumophila

COMMUNITY-ACQUIRED ATYPICAL (VIRAL AND MYCOPLASMAL) PNEUMONIAS

Morphology.

Clinical Course.

Influenza Infections

Severe Acute Respiratory Syndrome (SARS)

NOSOCOMIAL PNEUMONIA

ASPIRATION PNEUMONIA

LUNG ABSCESS

Etiology and Pathogenesis.

CHRONIC PNEUMONIA

Histoplasmosis, Morphology

Blastomycosis, Morphology

Coccidioidomycosis, Morphology

PNEUMONIA IN THE IMMUNOCOMPROMISED HOST

PULMONARY DISEASE IN HUMAN IMMUNODEFICIENCY VIRUS INFECTION

BASIC CONSIDERATIONS

- PNEUMONIA vs. PNEUMONITIS
- DIFFERENTIATION from INJURIES, OBSTRUCTIVE DISEASES, RESTRICTIVE DISEASES, VASCULAR DISEASES
- DIFFERENTIATION FROM NEOPLASMS
- CLASSICAL STAGES of INFLAMMATION
- LOBAR- vs. BRONCHO-
- INTERSTITIAL vs. ALVEOLAR
- COMMUNITY vs. NOSOCOMIAL
- ETIOLOGIC AGENTS vs. HOST IMMUNITY
- 2 PRESENTING SYMPTOMS
- 2 DIAGNOSTIC METHODS
- **ANY ORGANISM CAN CAUSE PNEUMONIA!!!**

PREDISPOSING FACTORS

- **LOSS OF COUGH REFLEX**
- **DIMINISHED MUCIN or CILIA FUNCTION**
- **ALVEOLAR MACROPHAGE INTERFERENCE**
- **VASCULAR FLOW IMPAIRMENTS**
- **BRONCHIAL FLOW IMPAIRMENTS**

Although pneumonia is one of the most common causes of death, it usually does **NOT occur in healthy people spontaneously**

Classifications of PNEUMONIAS

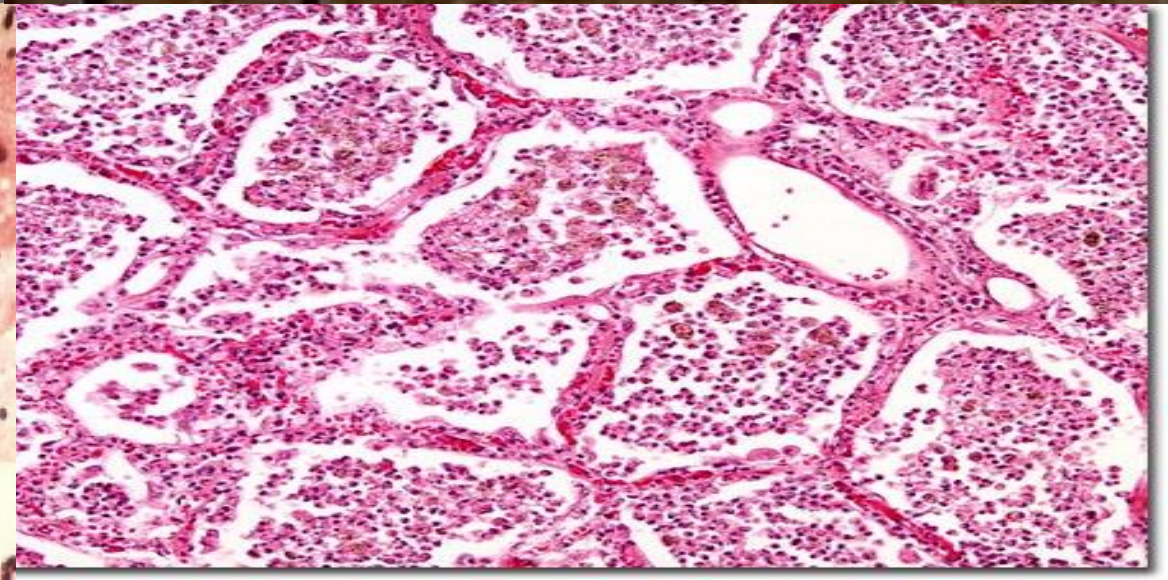
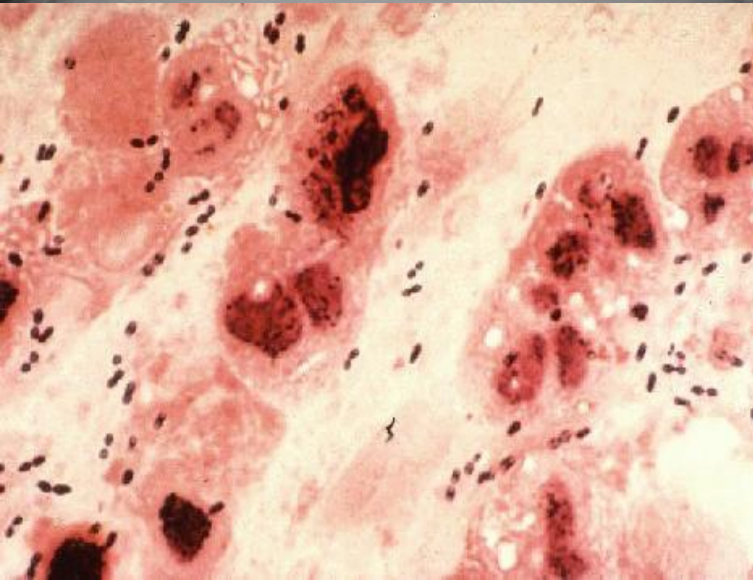
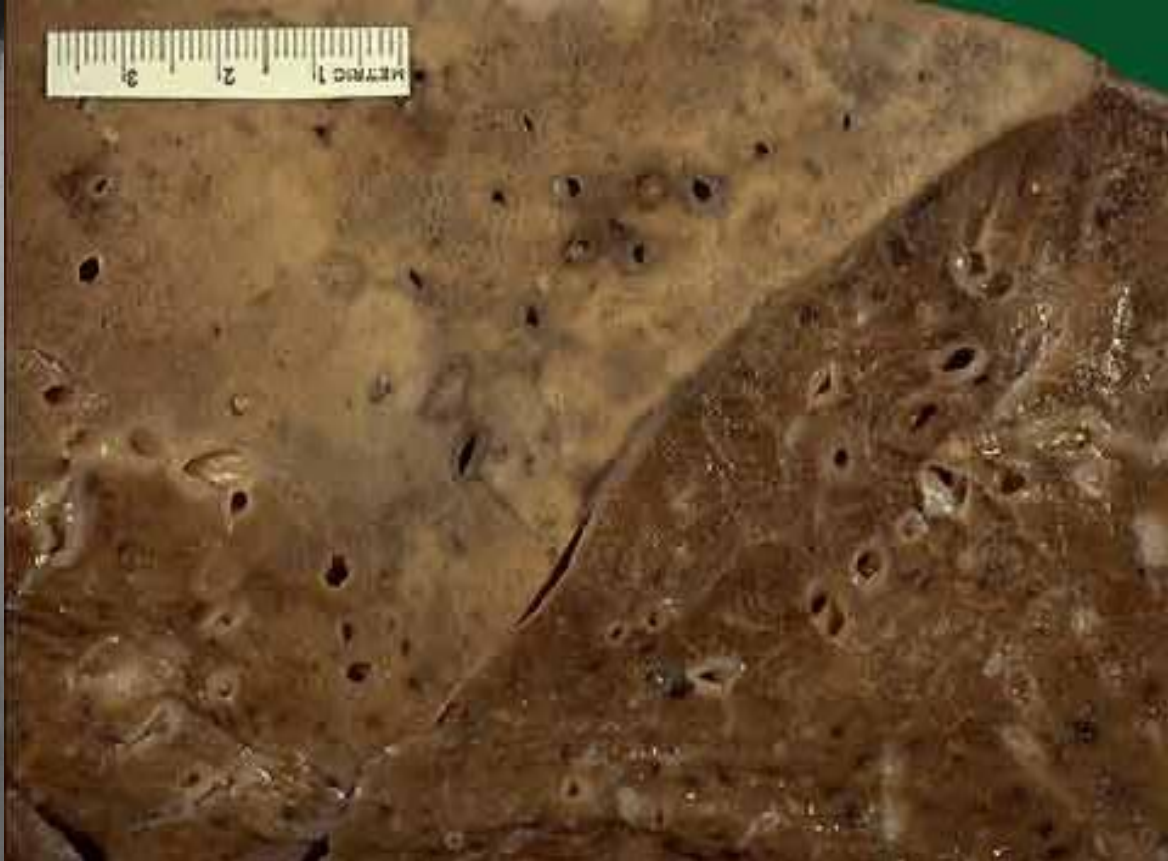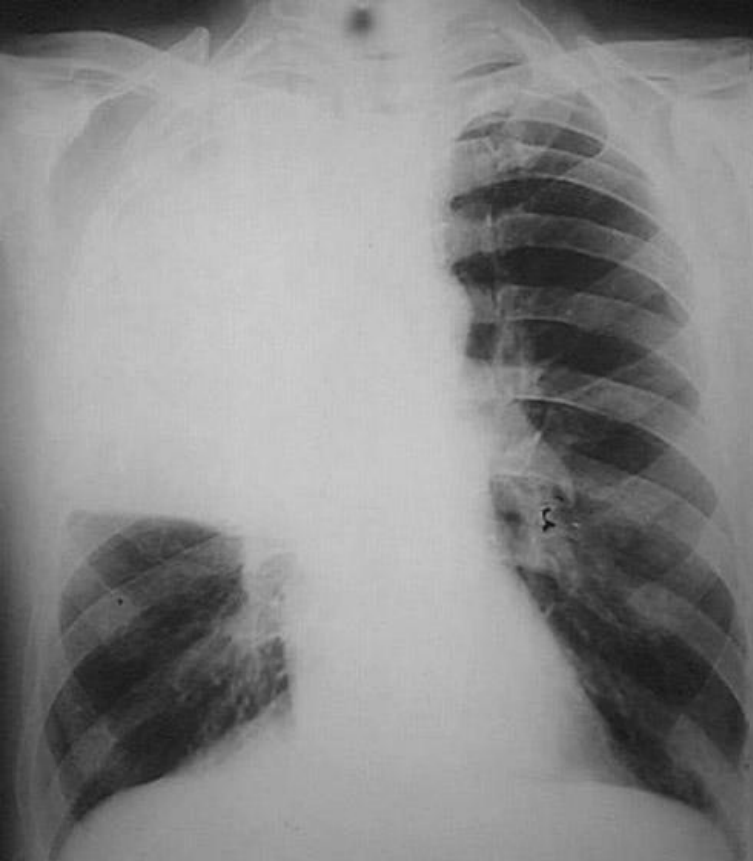
- **COMMUNITY ACQUIRED**
- **COMMUNITY ACQUIRED, ATYPICAL**
- **NOSOCOMIAL**
- **ASPIRATION**
- **CHRONIC**
- **NECROTIZING/ABSCESS FORMATION**
- **PNEUMONIAS in IMMUNOCOMPROMISED HOSTS**

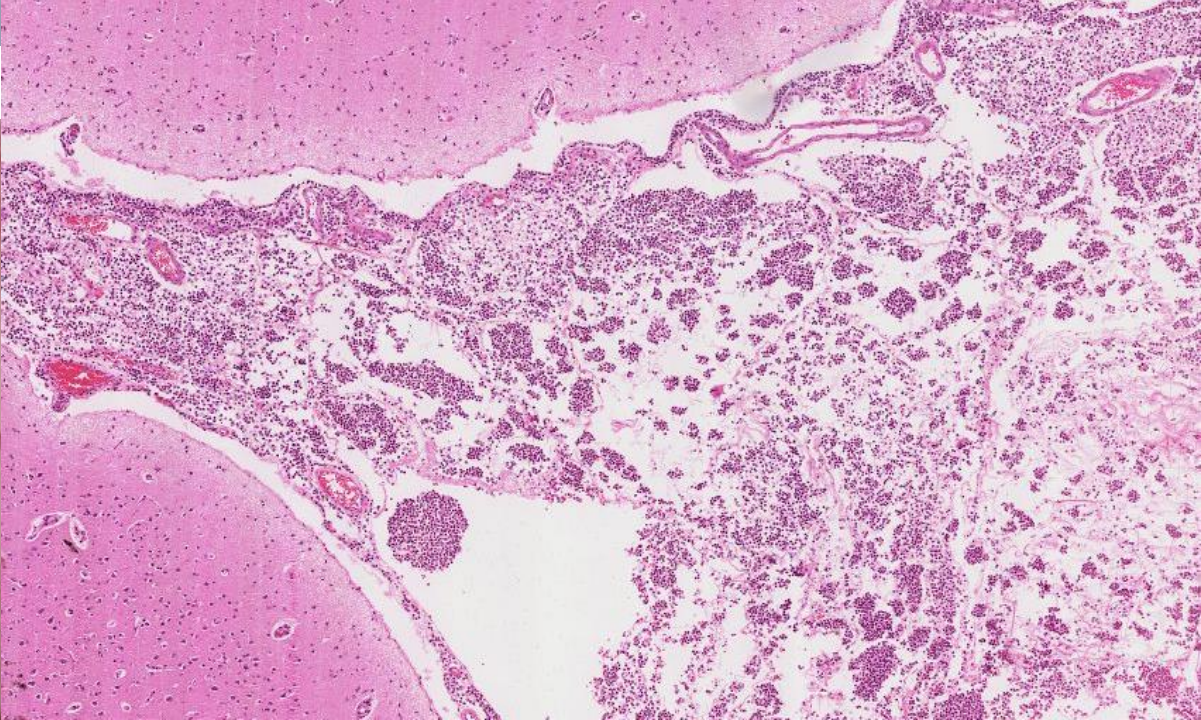
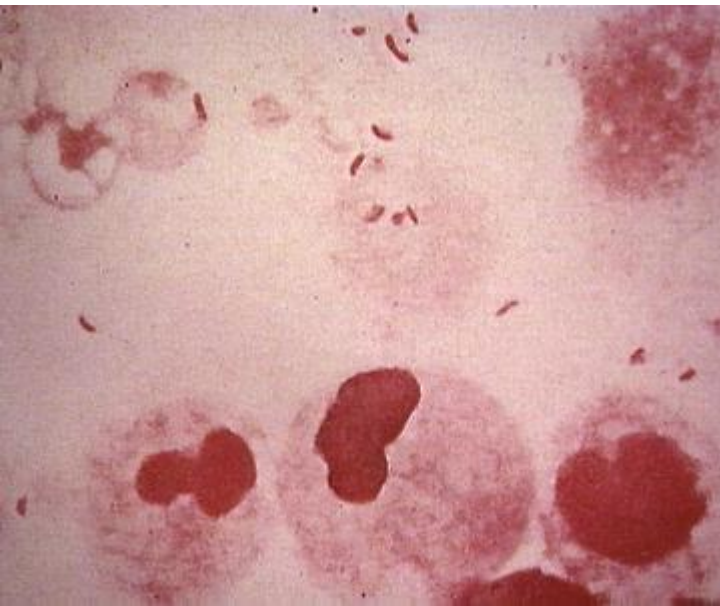
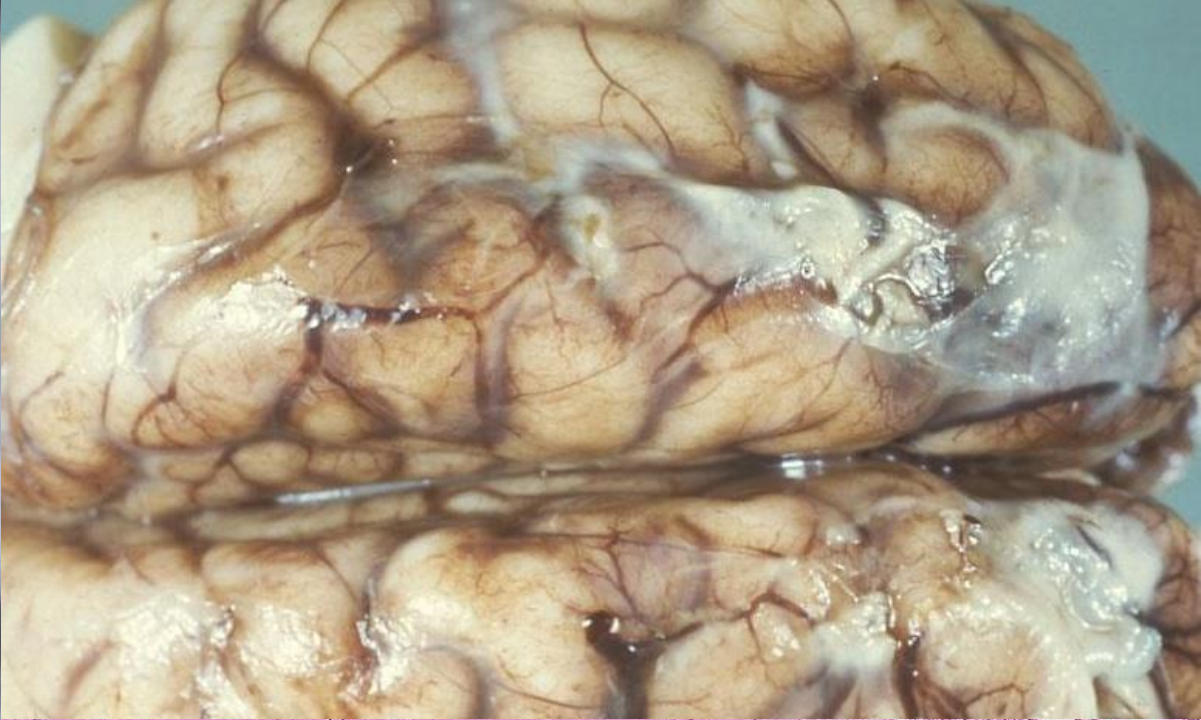
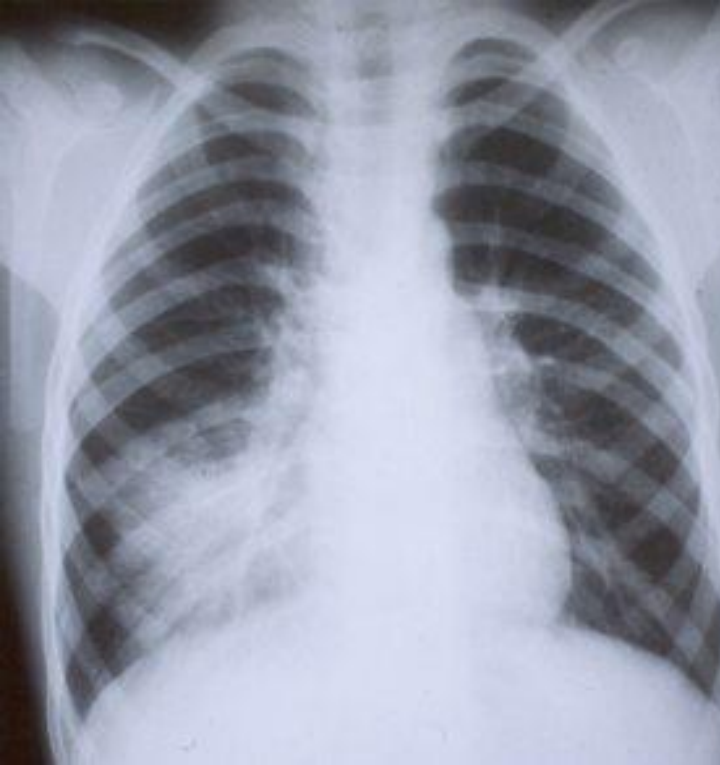COMMUNITY ACQUIRED

- **STREPTOCOCCUS PNEUMONIAE (i.e., “diplococcus”)**
- **HAEMOPHILUS INFLUENZAE (“H-Flu”)**
- **MORAXELLA**
- **STAPHYLOCOCCUS (STAPH)**
- **KLEBSIELLA PNEUMONIAE**
- **PSEUDOMONAS AERUGINOSA**
- **LEGIONELLA PNEUMOPHILIA**

STREPTOCOCCUS

- **The classic LOBAR pneumonia**
- **Normal flora in 20% of adults**
- **Only 20% of victims have + blood cultures**
- **“Penicillins” are often 100% curative**
- **Vaccines are often 100% preventive**





MORPHOLOGY

- ACUTE
- ORGANIZING
- CHRONIC
- FIBROSIS vs. FULL RESOLUTION

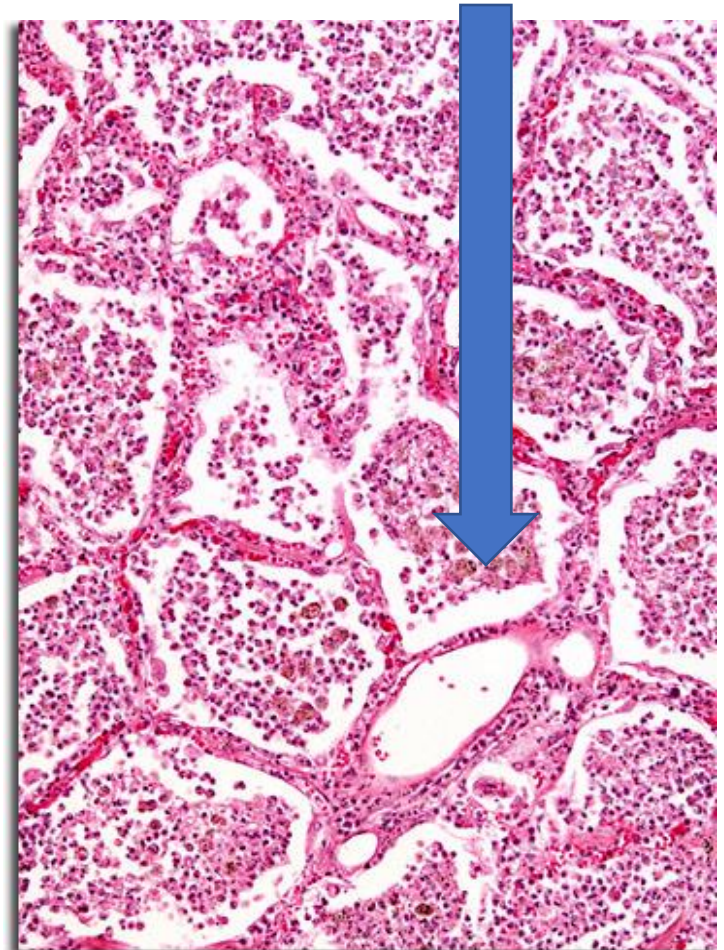
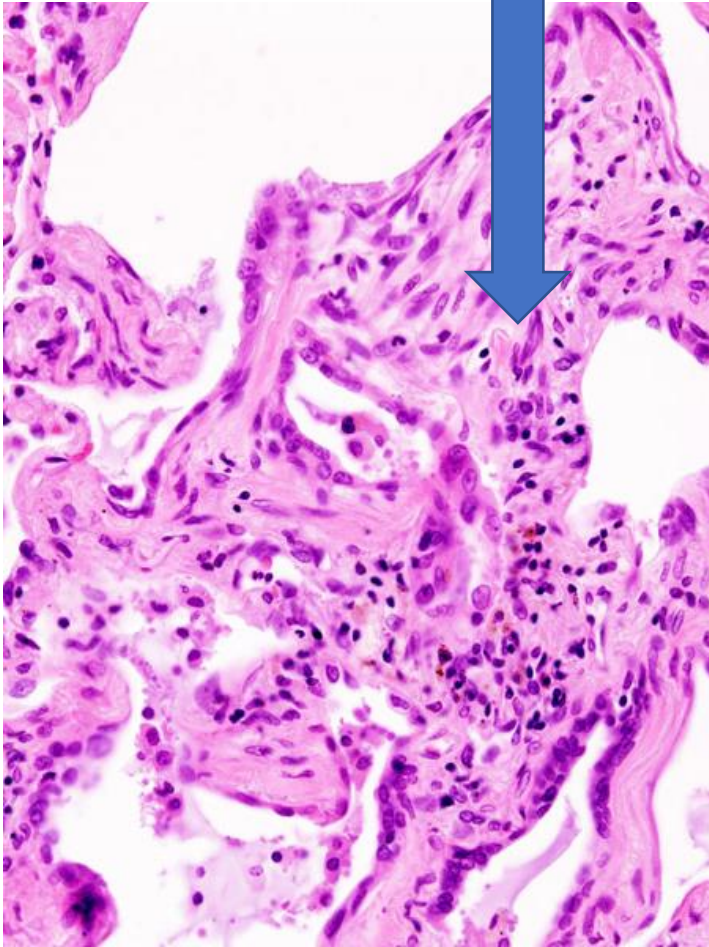
- “HEPATIZATION”, RED vs. GREY
- CONSOLIDATION

- “INFILTRATE”, XRAY vs. HISTOPATH

- Loss of “CREPITANCE”

VIRAL PNEUMONIAS

- Frequently “interstitial”, NOT alveolar



ASPIRATION PNEUMONIAS

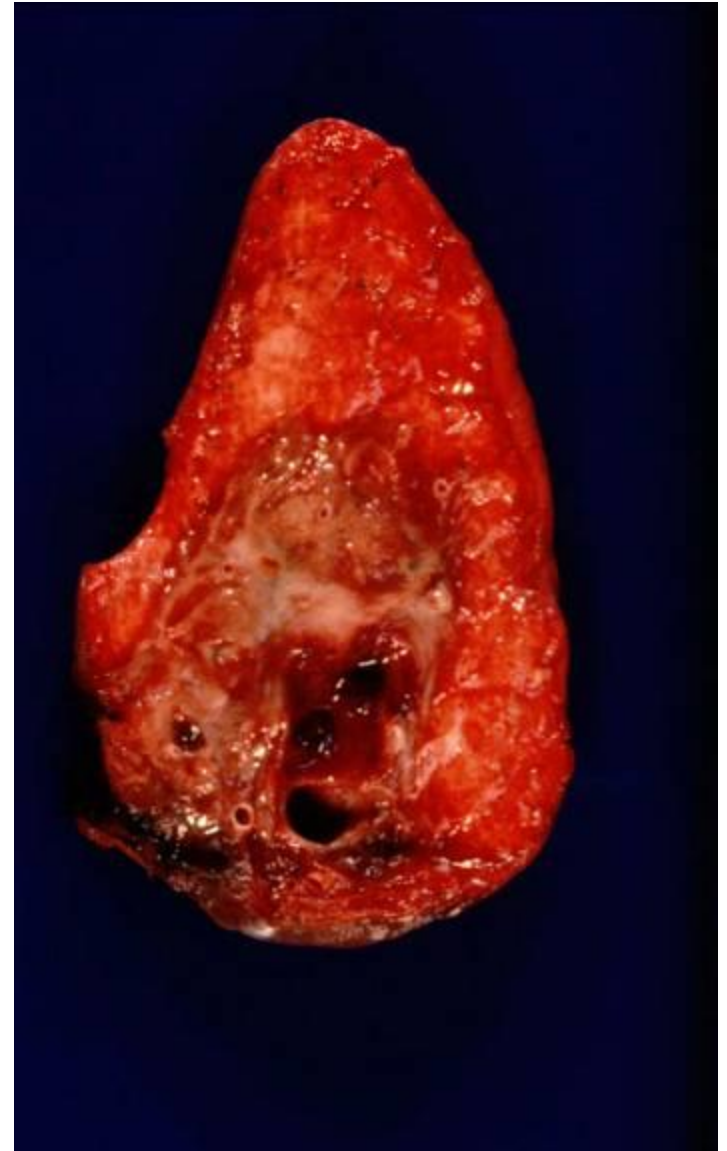- UNCONSCIOUS PATIENTS
- PATIENTS IN PROLONGED BEDREST
- LACK OF ABILITY TO SWALLOW OR GAG
- USUALLY CAUSED BY **ASPIRATION OF GASTRIC CONTENTS**
- POSTERIOR LOBES (gravity dependent) MOST COMMONLY INVOLVED, ESPECIALLY THE **SUPERIOR SEGMENTS** of the **LOWER LOBES**
- Often lead to **ABSCESSSES**

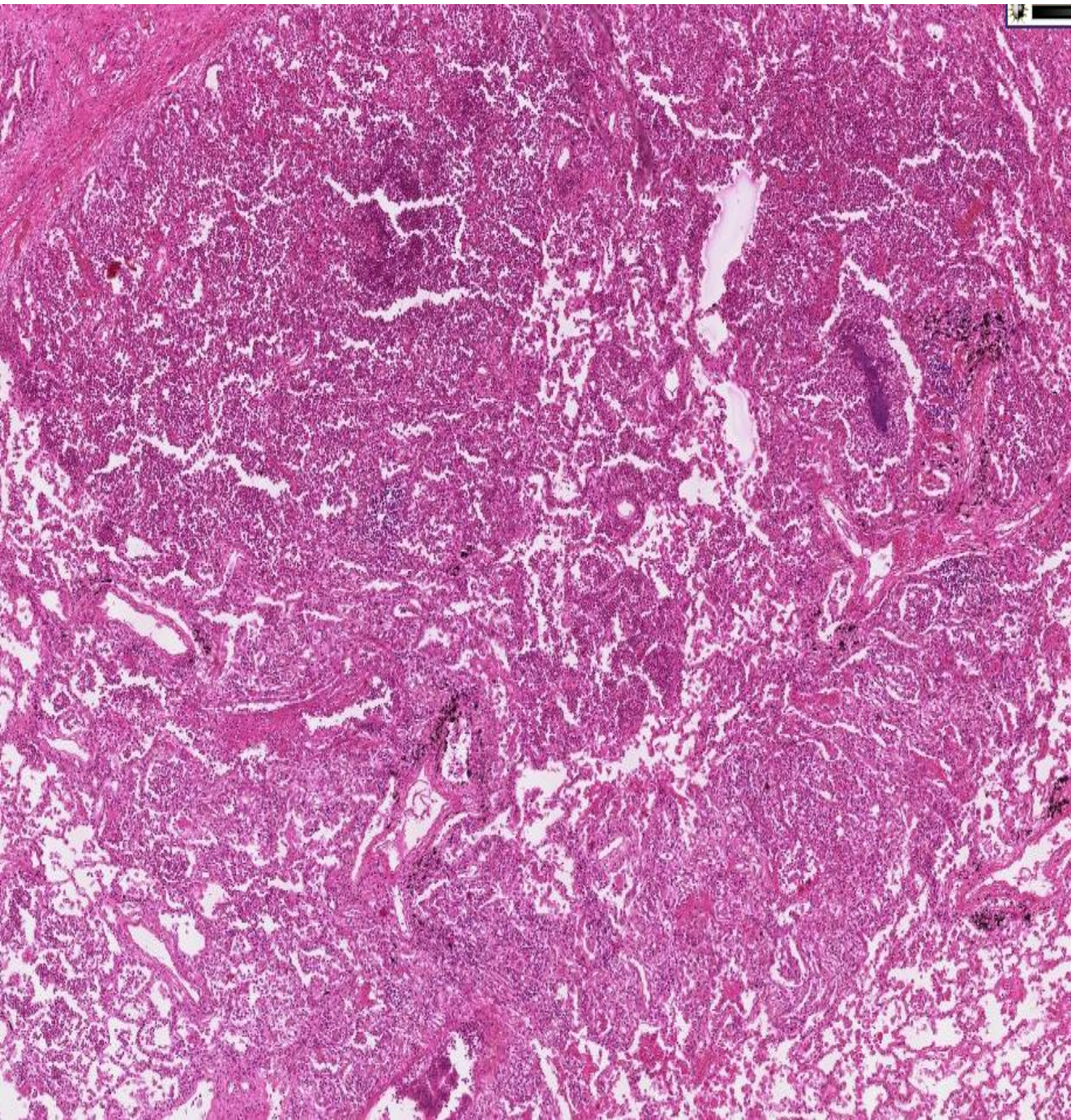
LUNG ABSCESSSES

- **ASPIRATION**
- **SEPTIC EMBOLIZATION**
- **NEOPLASIA**
- From **NEIGHBORING** structures:
 - ESOPHAGUS
 - SPINE
 - PLEURA
 - DIAPHRAGM
- **ANY pneumonia** which is severe and destructive, and UN-treated enough

Lung abscess

- **Localized suppurative necrosis**
- **Organisms commonly cultured:**
 - Staphylococci
 - Streptococci
 - Gram-negative
 - Anaerobes
 - Frequent mixed infections
- **Pathogenesis:**
 - Aspiration
 - Pneumonia
 - Septic emboli
 - Tumors
 - Direct infection





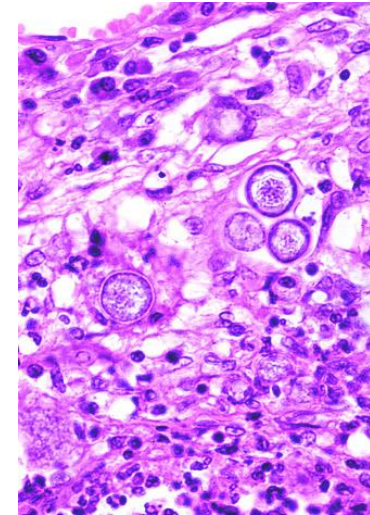
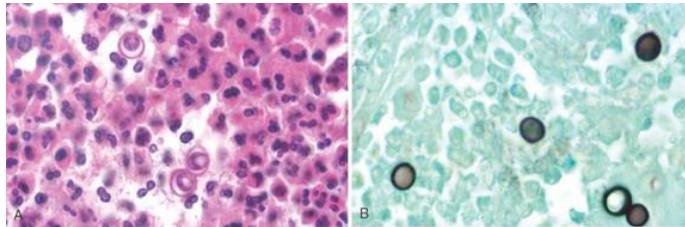
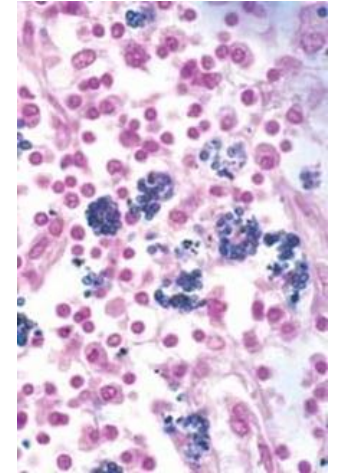
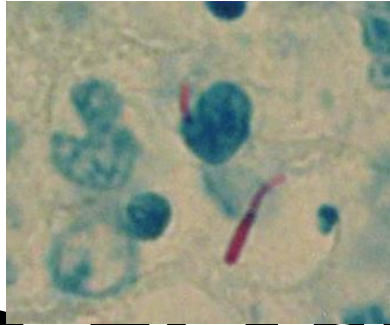
An abscess can be thought of as a pneumonia in which all of the normal lung outline can no longer be seen, and there is 100% pus.

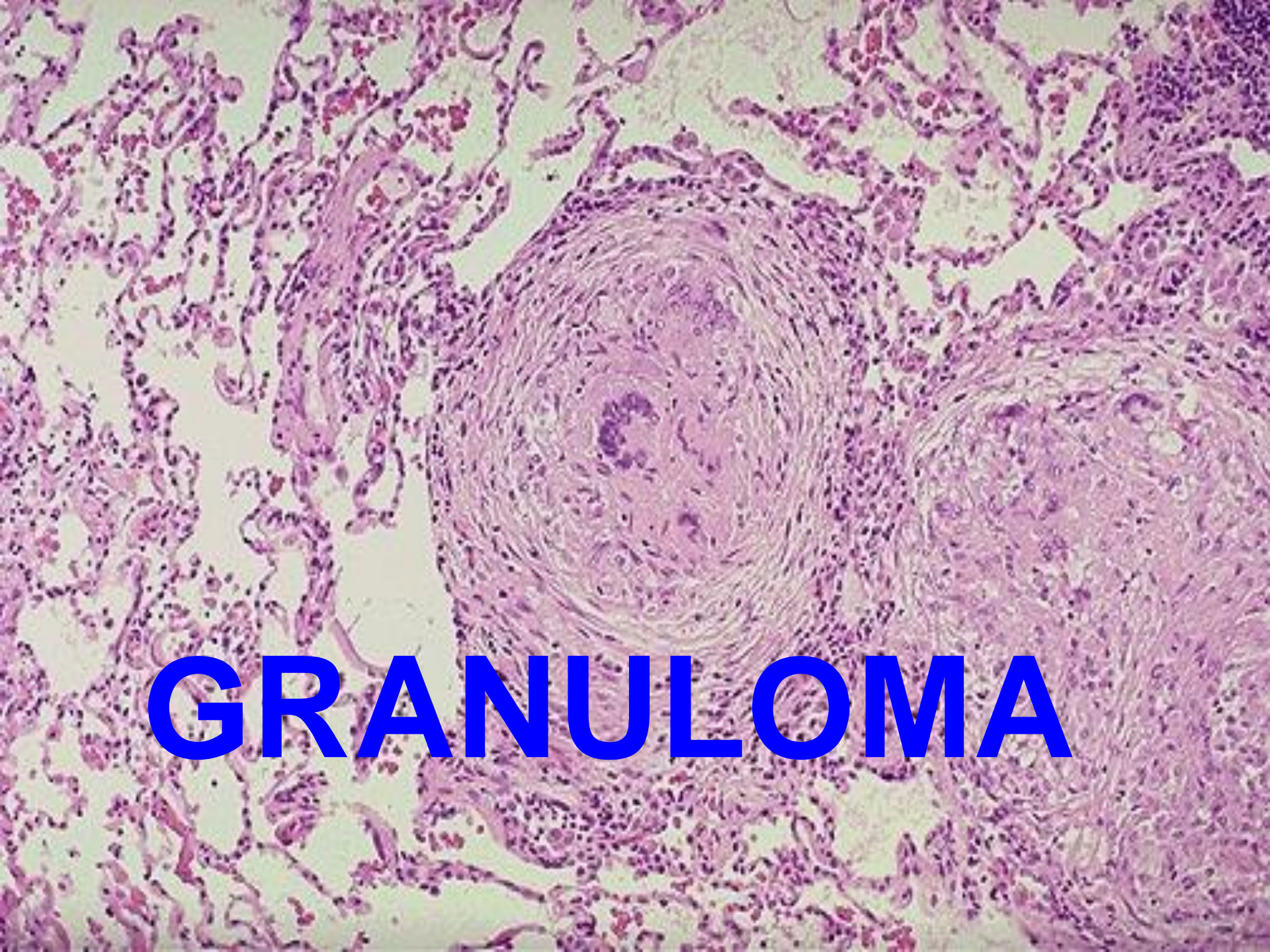
CHRONIC Pneumonias

- **USUALLY NOT** persistences of the community or nosocomial bacterial infections, but **CAN BE**, at least histologically
- Often **SYNONYMOUS** with the 4 classic fungal or **granulomatous** pulmonary infections, i.e., TB, Histo-, Blasto-, Coccidio-
- If you see pulmonary granulomas, think of a **CHRONIC** process, often years

CHRONIC Pneumonias

- TB
- HISTO-PLASMOSIS
- BLASTO-MYCOSIS
- COCCIDIO MYCOSIS





GRANULOMA

LUNG TUMORS

- Benign, malignant, epithelial, mesenchymal, but 90% are CARCINOMAS
- BIGGEST USA killer. Why? Ans: Prevalence not as high as prostate or breast but mortality higher. Only **15%** 5 year survival.
- **TOBACCO** has polycyclic aromatic hydrocarbons, such as benzopyrene, anthracenes, radioactive isotopes
- Radiation, asbestos, radon
- C-MYC, K-RAS, EGFR, HER-2/neu

PATHOGENESIS

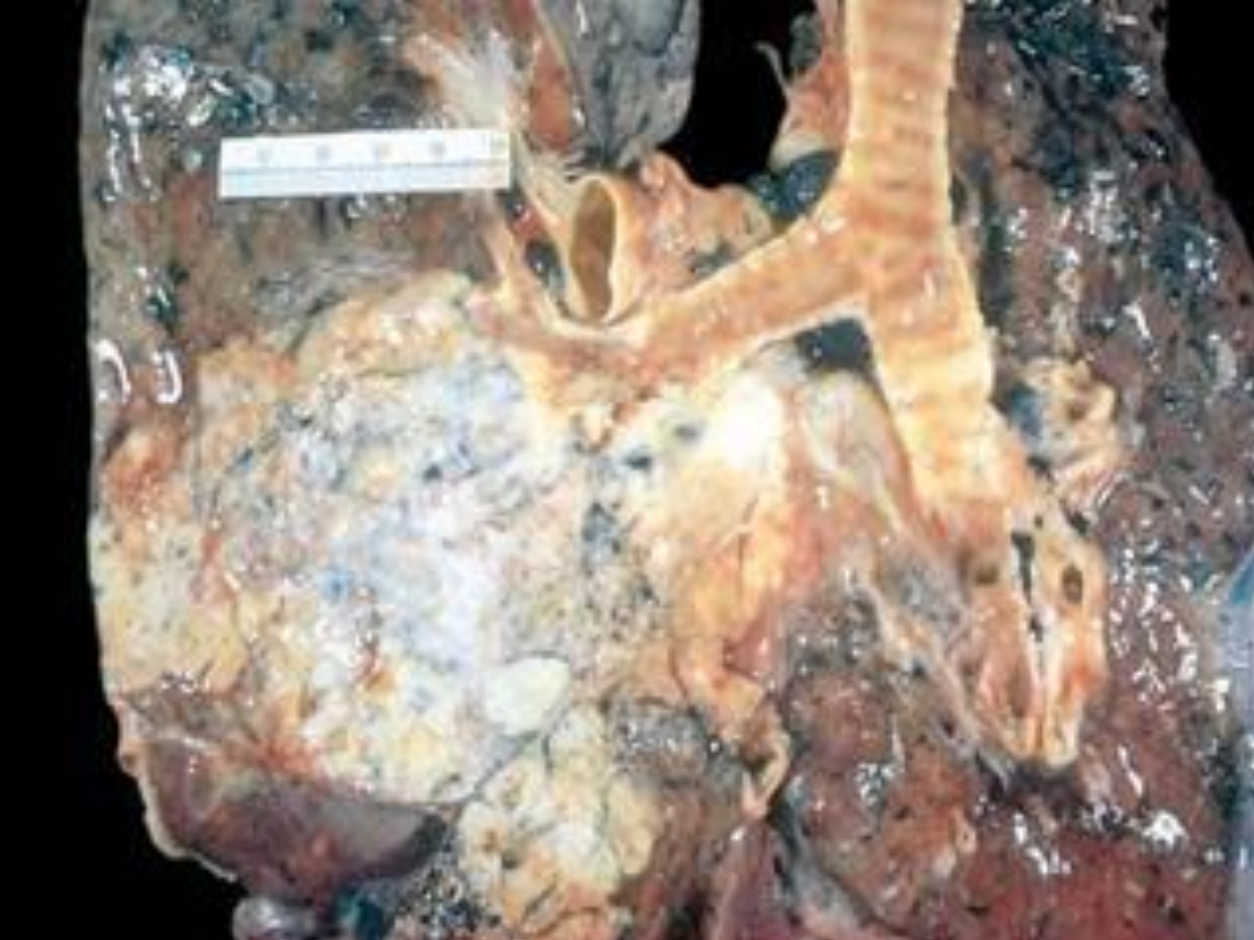- **NORMAL BRONCHIAL MUCOSA**
- **METAPLASTIC/DYSPLASTIC MUCOSA**
- **CARCINOMA-IN-SITU (squamous, adeno)**
- **INFILTRATING (i.e., “INVASIVE”) cancer**

TWO TYPES

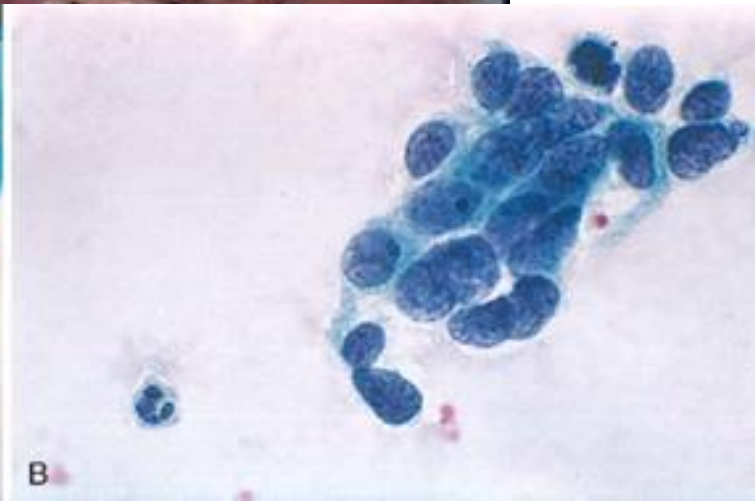
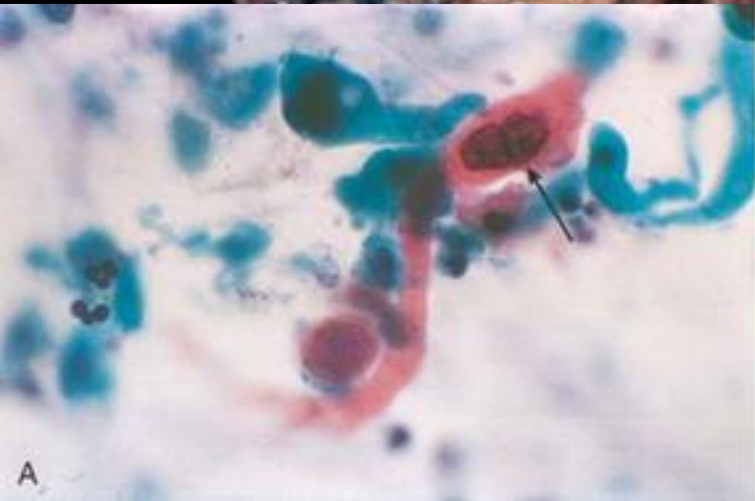
- **NON-SMALL CELL**
 - **SQUAMOUS CELL CARCINOMA**
 - **ADENOCARCINOMA**
 - **LARGE CELL CARCINOMA**
- **SMALL CELL CARCINOMA**

The BIG list

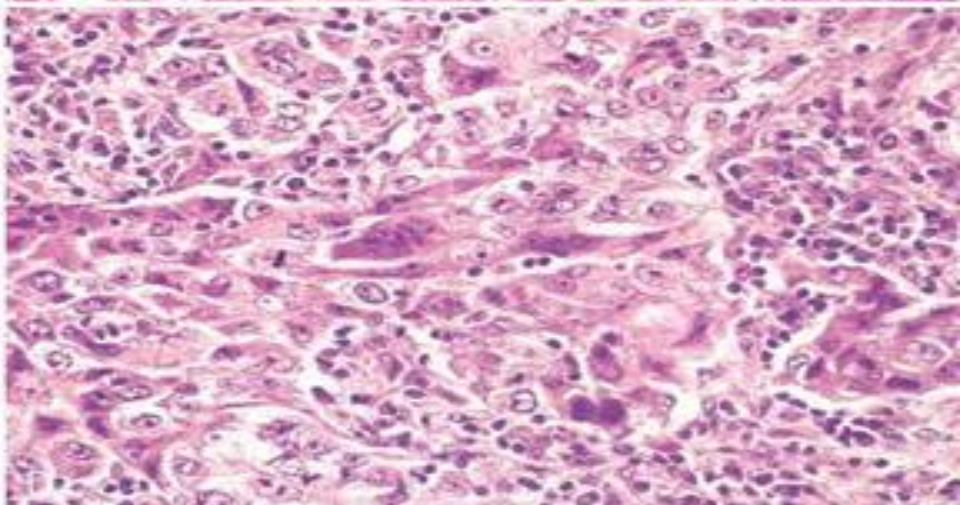
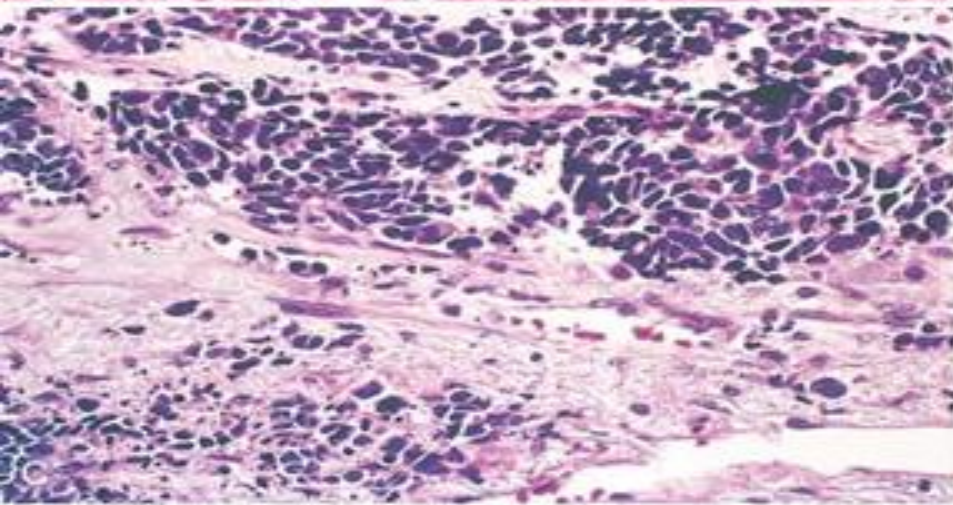
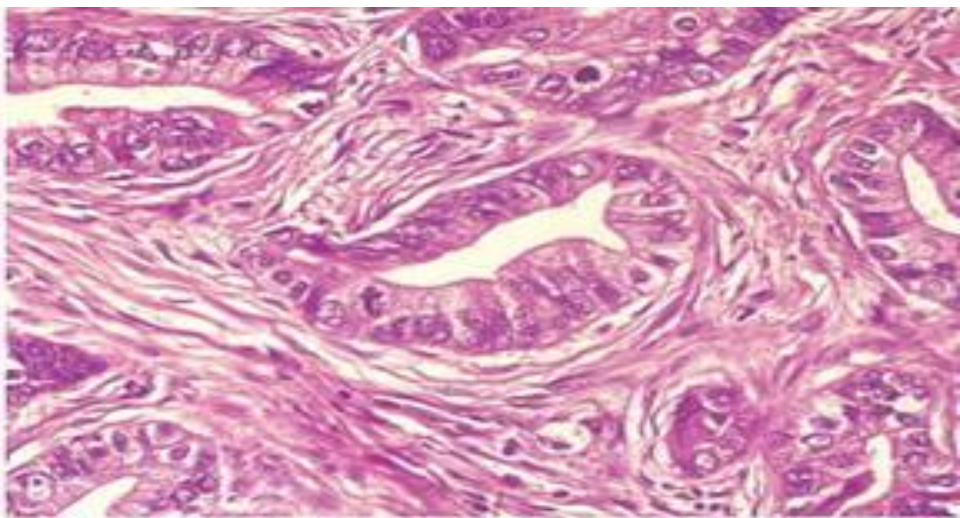
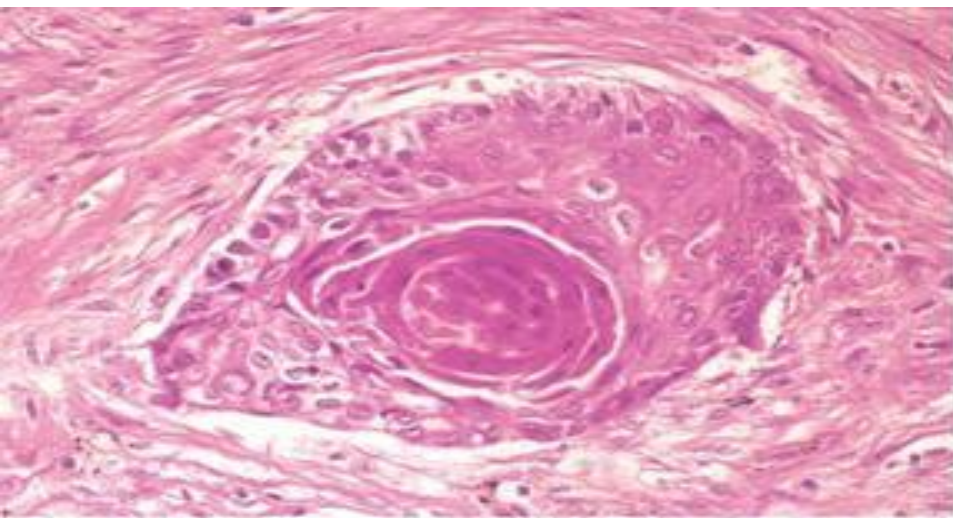
- Squamous cell carcinoma
- Small cell carcinoma
- Combined small cell carcinoma
- Adenocarcinoma: Acinar, papillary, bronchioloalveolar, solid, mixed subtypes
- Large cell carcinoma
- Large cell neuroendocrine carcinoma
- Adenosquamous carcinoma
- Carcinomas with pleomorphic, sarcomatoid, or sarcomatous elements
- Carcinoid tumor: Typical, atypical
- Carcinomas of salivary gland type
- Unclassified carcinoma



The classical squamous cell carcinoma starting in a large bronchus centrally, with bronchial obstruction. Adenocarcinomas tend to be more peripheral. Note the features of malignant cells on sputum cytology.



**Name the four most common histologic patterns of lung carcinoma and explain why!
Squamous, adeno, large, small.**



LOCAL effects of LUNG CANCER

Clinical Feature	Pathologic Basis
Pneumonia, abscess, lobar collapse	Tumor obstruction of airway
Lipid pneumonia	Tumor obstruction; accumulation of cellular lipid in foamy macrophages
Pleural effusion	Tumor spread into pleura
Hoarseness	Recurrent laryngeal nerve invasion
Dysphagia	Esophageal invasion
Diaphragm paralysis	Phrenic nerve invasion
Rib destruction	Chest wall invasion
SVC syndrome	SVC compression by tumor
Horner syndrome	Sympathetic ganglia invasion
Pericarditis, tamponade	Pericardial involvement
SVC, superior vena cava.	

METASTATIC TUMORS

- **LUNG** is the **MOST COMMON** site for all metastatic tumors, regardless of site of origin
- It is the site of **FIRST CHOICE** for **metastatic sarcomas** for purely anatomic reasons!

PLEURA

- **PLEURITIS**
- **PNEUMOTHORAX**
- **EFFUSIONS**
 - **HYDROTHORAX**
 - **HEMOTHORAX**
 - **CHYLOTHORAX**
- **MESOTHELIOMAS**

PLEURITIS

- Usual bacteria, viruses, etc.
- Infarcts
- Lung abscesses, empyema
- TB
- “Collagen” diseases, e.g., RA, SLE
- Uremia
- Metastatic

PNEUMOTHORAX

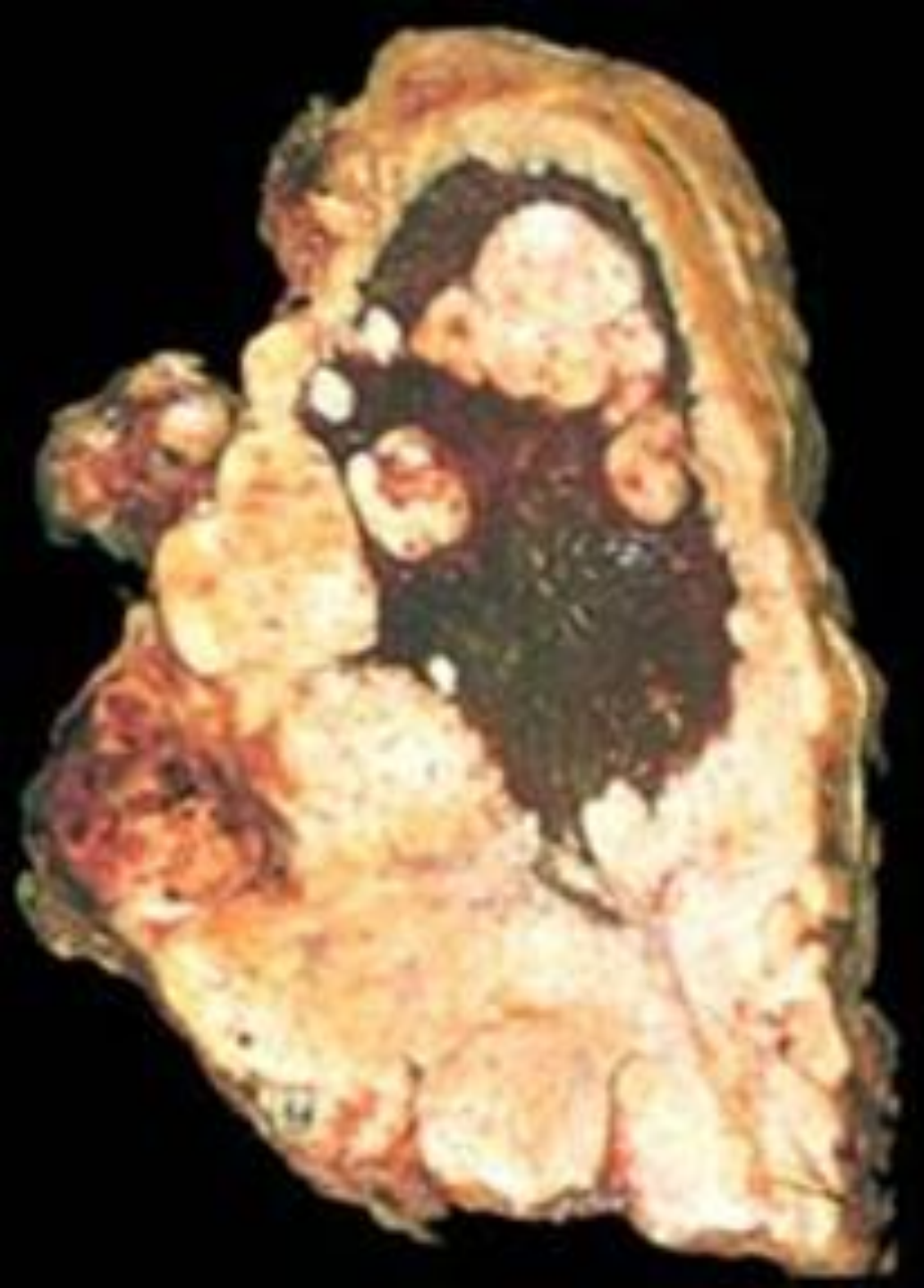- **SPONTANEOUS, TRAUMATIC, THERAPEUTIC**
- **OPEN or CLOSED**
- **“TENSION” pneumothorax, “valvular” effect**
- **“Bleb” rupture**
- **Perforating injuries**
- **Post needle biopsy**

EFFUSIONS

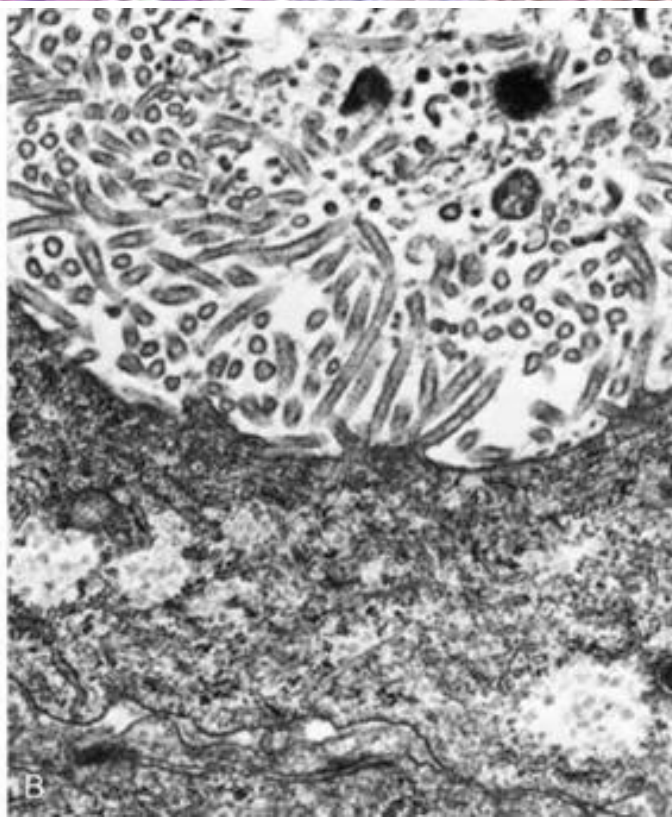
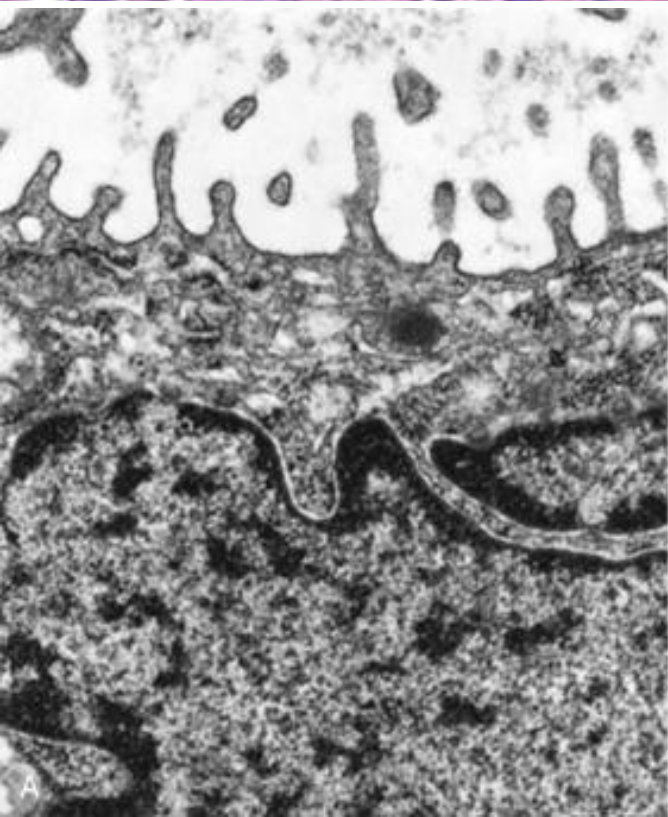
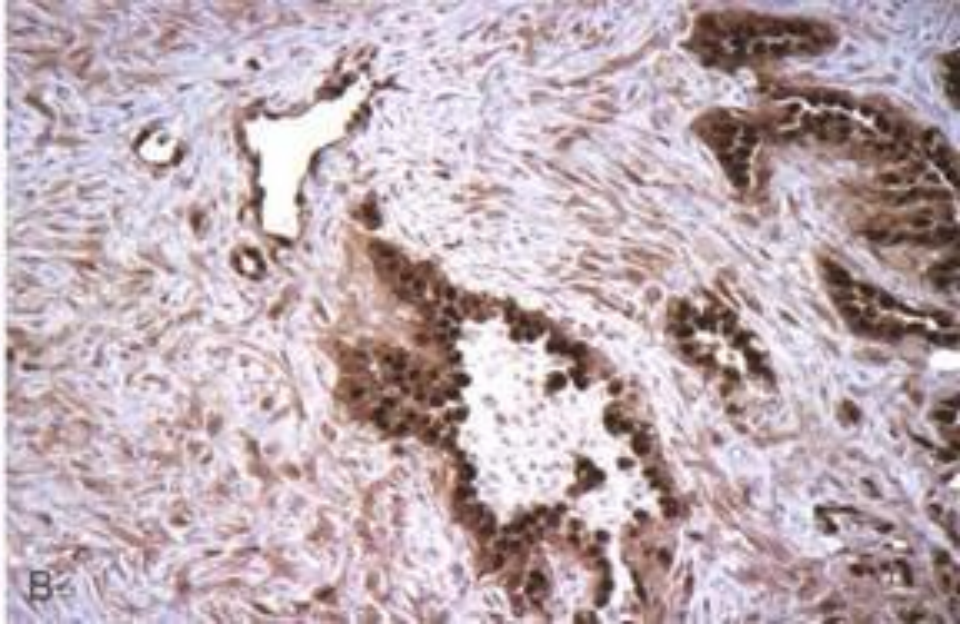
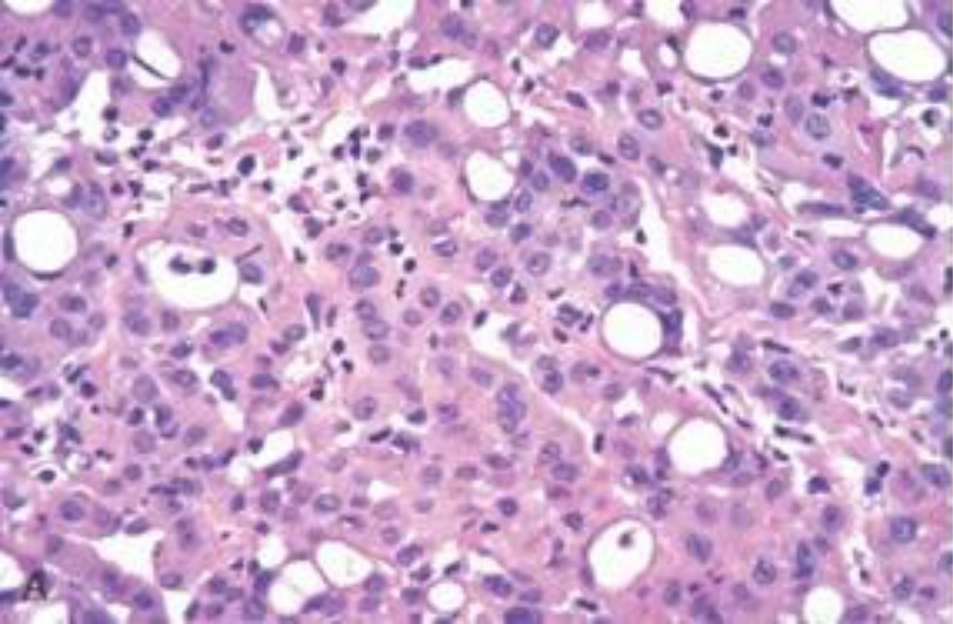
- **TRANSUDATE (HYDROTHORAX)**
- **EXUDATE (HYDROTHORAX)**
- **BLOOD (HEMOTHORAX)**
- **LYMPH (CHYLOTHORAX)**

MESOTHELIOMAS

- **“Benign” vs. “Malignant” differentiation does not matter, but a self limited localized nodule can be regarded as benign, and a spreading tumor can be regarded as malignant**
- **Visceral or parietal pleura, pericardium, or peritoneum**
- **Most are regarded as asbestos caused or asbestos “related”**



Typical growth appearance of a malignant mesothelioma, it compresses the lung from the **OUTSIDE**.



H&E,
IMMUNOCHEMISTRY

← EM